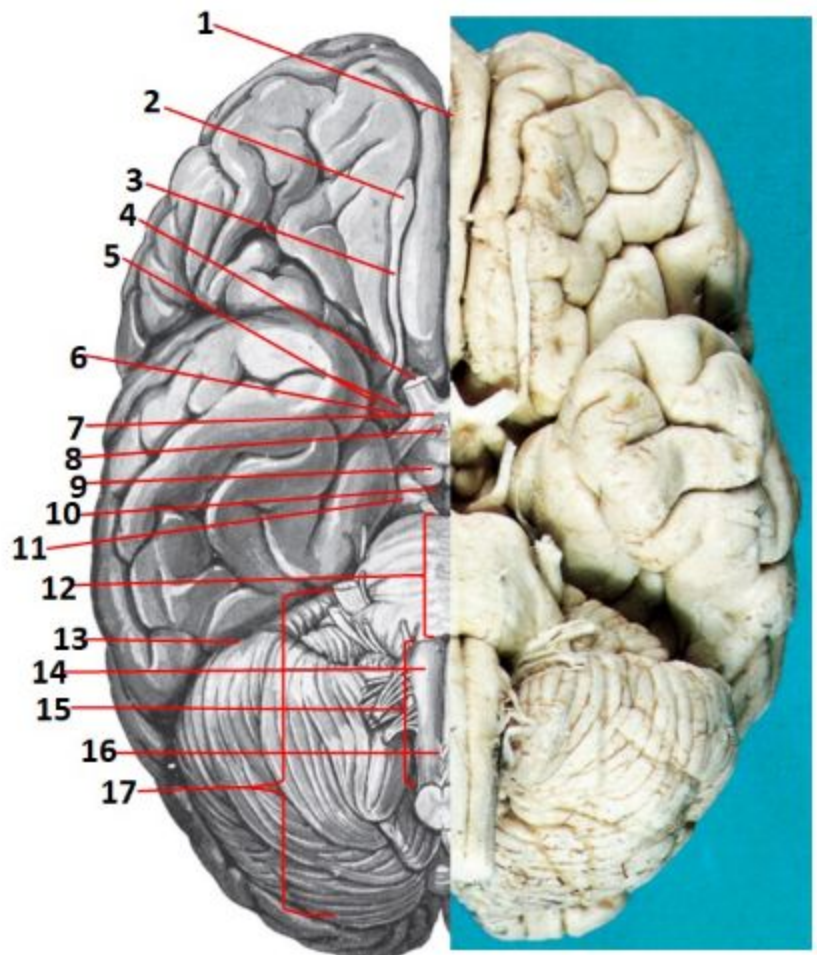


Мозг две
половины

начал
о



tractus olfactorii 3

Decussatio pyramidum 16

fissura transversa cerebri 13

trigonum olfactorium 5

Cerebellum 17

chiasma opticum 7

Pyramis 14

substantia perforata anterior 6

medulla oblongata 15

fissure longitudinalis cerebri 1

bulbi olfactorii 2

Nervus opticus 4

corpora mamillaria 9

fossa interpeduncularis, substantia perforata posterior 10

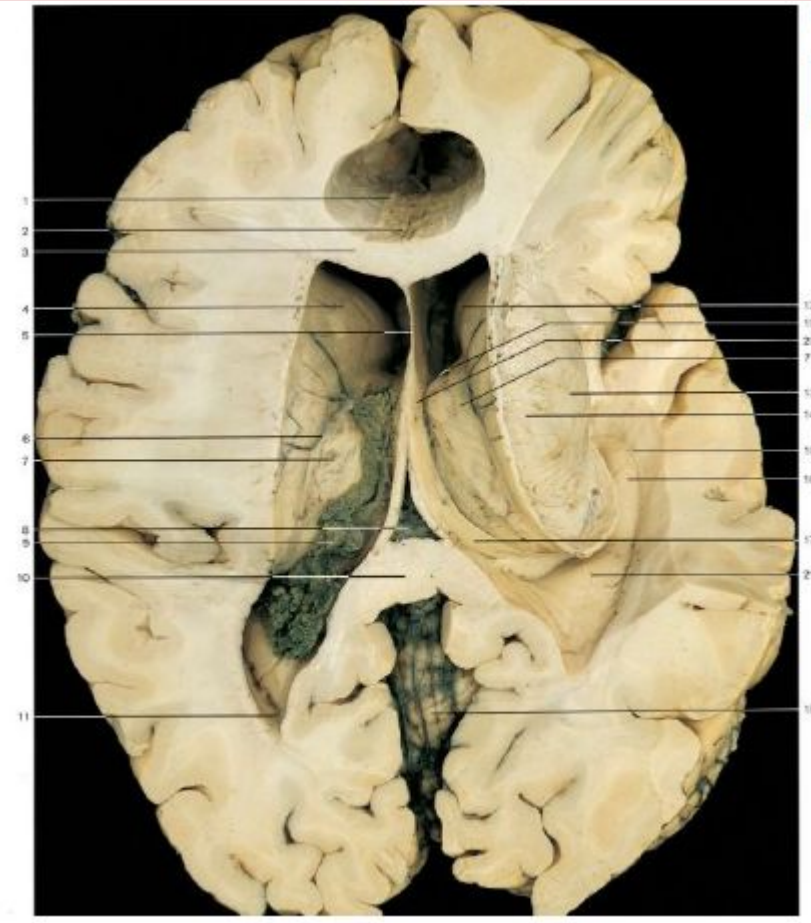
pedunculi cerebri 11

Pons 12

tuber cinereum, infundibulum 8

MO3

Г



septum pellucidum 5

hippocampus 16

Fornix 20

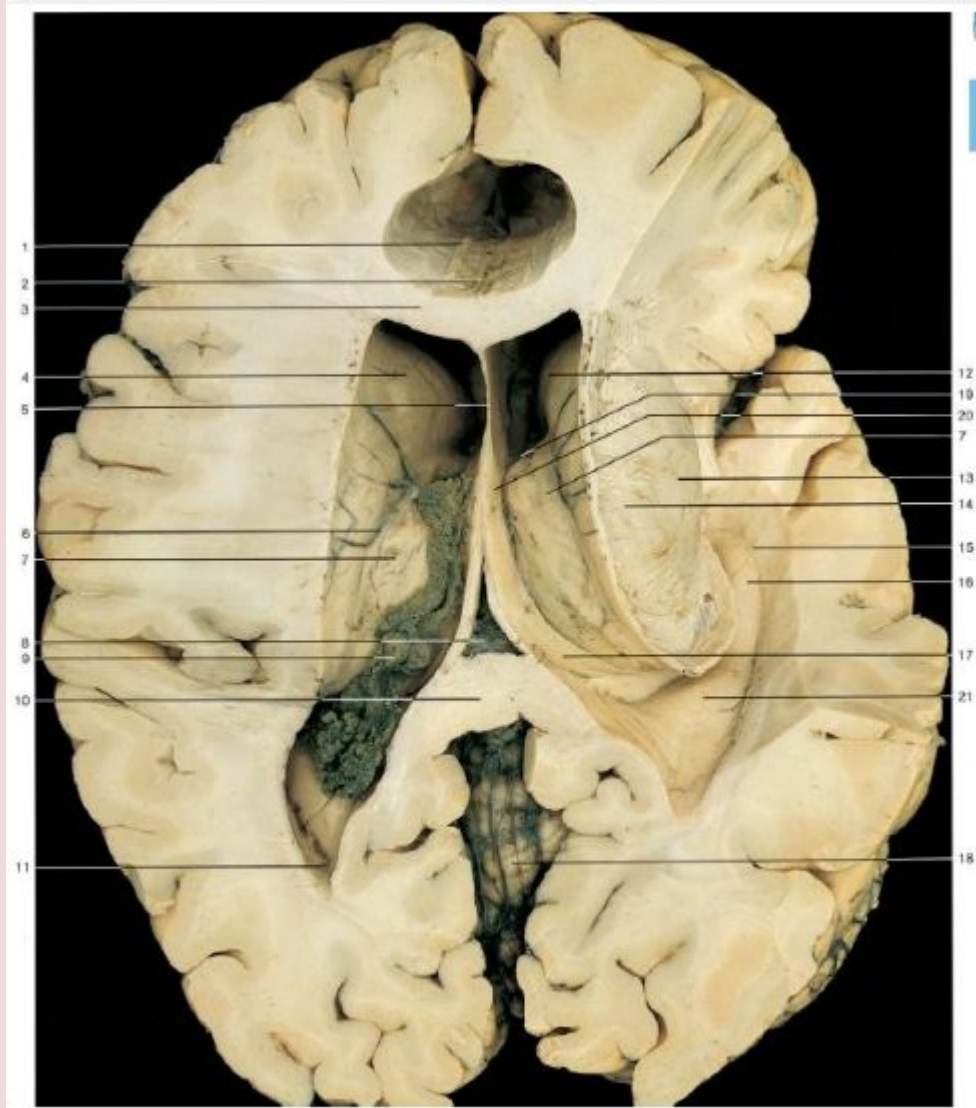
Talamus 7

ventriculus tertius 8

plexus choroideus ventriculus lateralis 9

MO3

Г



plexus choroideus ventriculi lateralis 9

Putamen 13

pes hippocampi 16

foramen interventriculare 19

cornu posterius ventriculi lateralis 11

vermis cerebelli 18

capsula interna 14

septum pellucidum cerebri 5

eminentia collateralis ventriculi lateralis 21

splenium corporis callosi 10

cornu anterius ventriculi lateralis 12

crura fornix 17

genu corporis callosi 3

caput nuclei caudati 4

stria terminalis 6

Thalamus 7

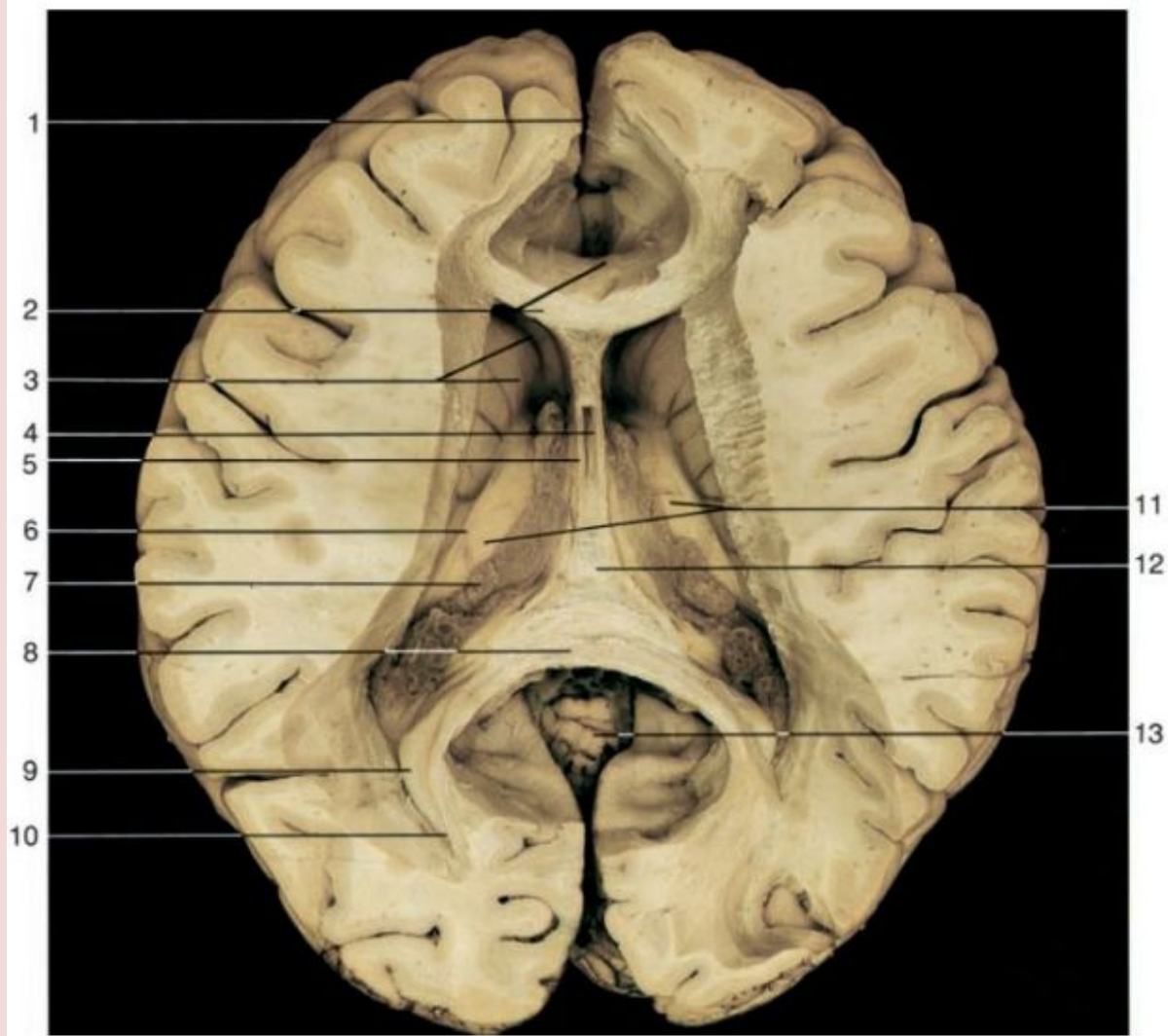
plexus choroideus ventriculus tertius 8

cornu inferius ventriculi lateralis 15

columna fornix 20

MO3

Г

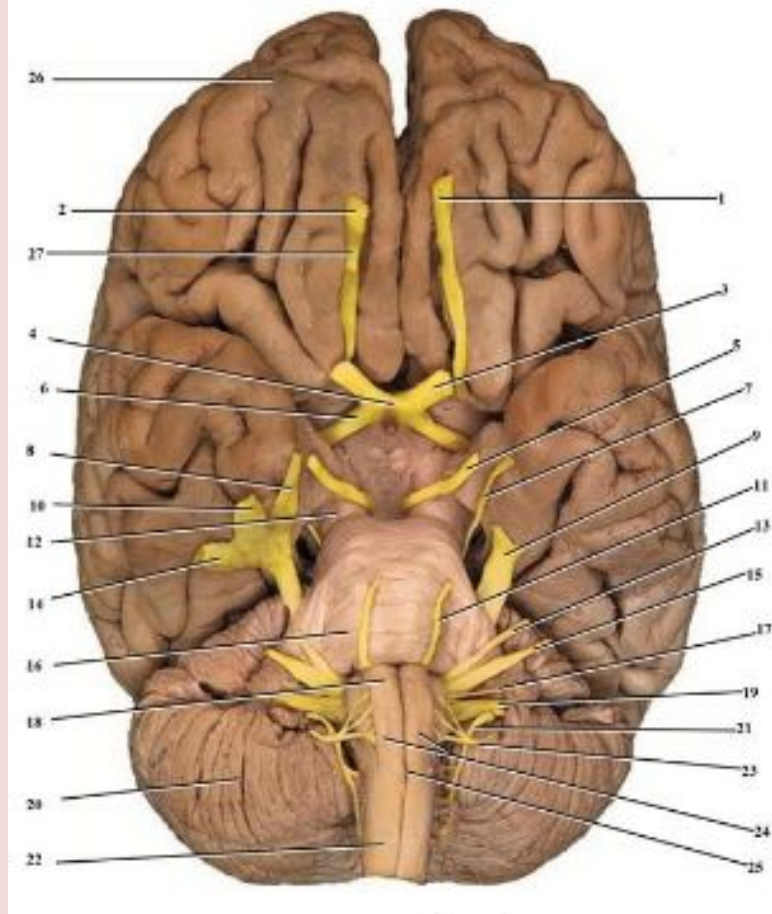


- fissura longitudinalis cerebri 1
- plexus choroideus ventriculi lateralis 7
- splenium corporis callosi 8
- cavitas septum pellucidum cerebri 4
- septum pellucidum cerebri 5
- Thalamus 11
- commissura fornicis 12
- vermis cerebelli 13
- stria terminalis 6
- genu corporis callosi 2
- caput nuclei caudati 3
- calcar avis 9
- cornu posterius ventriculi lateralis 10

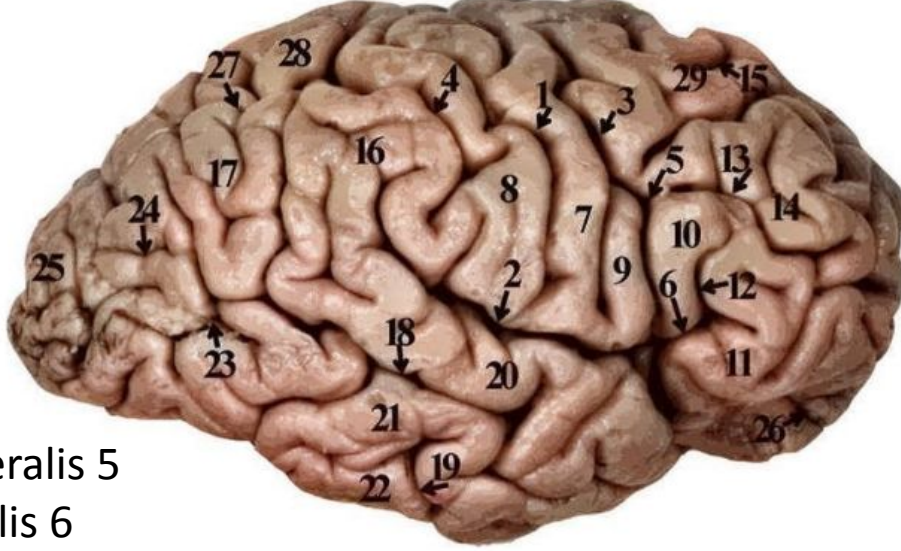
Мозг

10021

- nervus accessorius 21
- nervus facialis 13
- nervus glossofaringeus 17
- nervus trigeminus 9
- nervus abducens 11
- nervus vestibulocochlearis 15
- nervus opticus 3
- nervus vagus 19
- nervus olfactorius 1
- nervus oculomotorius 5
- nervus trochlearis 7
- nervus hypoglossus 23



Мозг полушария

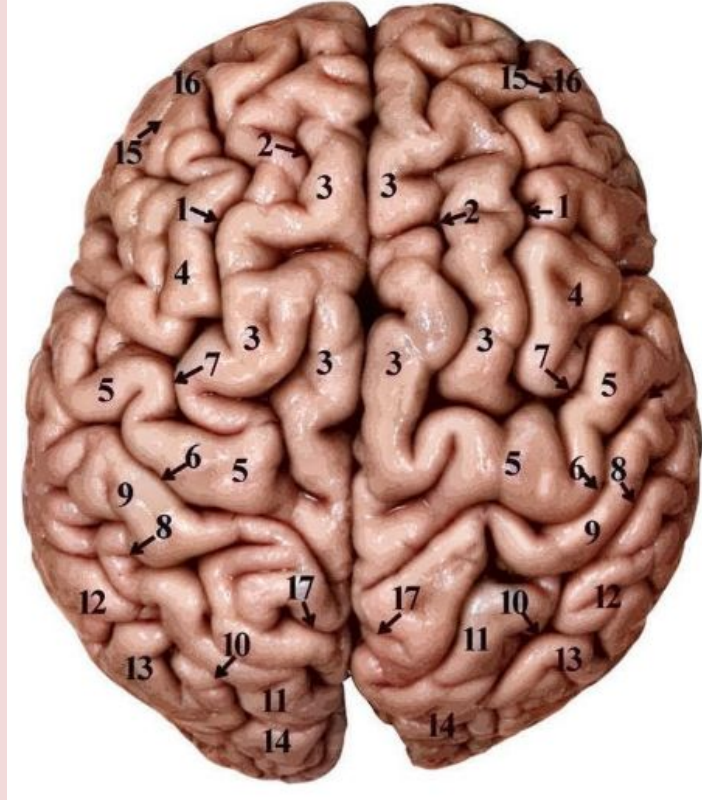


- Sulcus centralis 1
- Sulcus lateralis 2
- Sulcus precentralis 3
- Sulcus postcentralis 4
- Ramus ascendens sulci lateralis 5
- Ramus anterior sulci lateralis 6
- Gyrus precentralis 7
- Gyrus postcentralis 8
- Gyrus frontalis inferior pars opercularis 9
- Gyrus frontalis inferior pars triangularis 10
- Gyrus frontalis inferior pars orbitalis 11
- Sulcus radialis 12
- Sulcus frontalis inferior 13
- Gyrus frontalis medius 14
- Sulcus frontalis superior 15
- Gyrus supramarginalis 16
- Gyrus angularis 17
- Sulcus temporalis superior 18
- Sulcus temporalis inferior 19
- Gyrus temporalis superior 20
- Gyrus temporalis medius 21
- Gyrus temporalis inferior 22
- Sulcus occipitalis anterior 23
- Sulcus occipitalis lateralis 24
- Gyri occipitales 25
- Sulci orbitales 26
- Sulcus intraparietalis 27
- Lobulus parietalis superior 28
- Gyrus frontalis superior 29

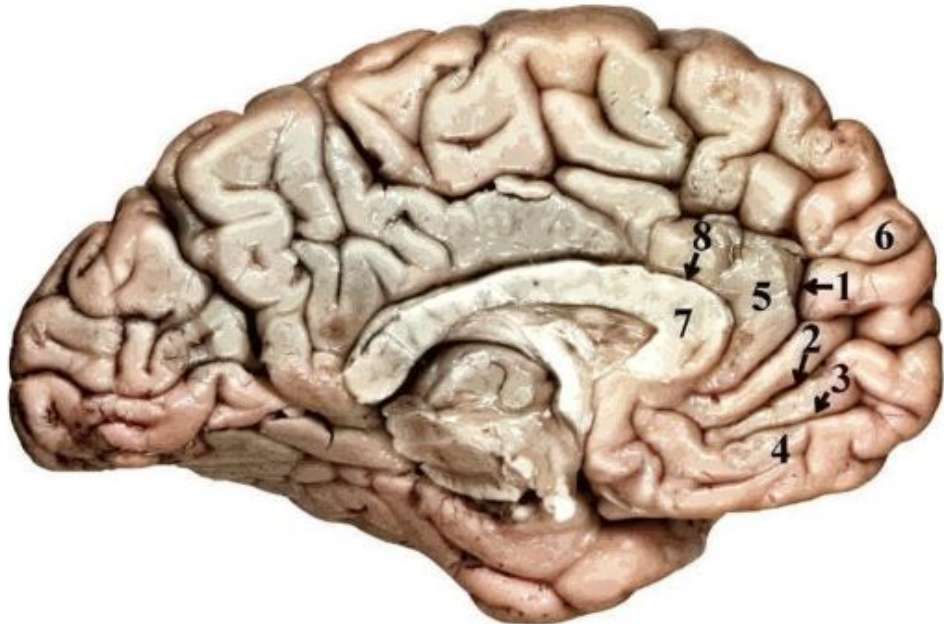
Мозг

полушария

- Sulcus frontalis superior 1
- Sulcus frontalis superior proprius 2
- Gyrus frontalis superior 3
- Gyrus frontalis medius 4
- Gyrus precentralis 5
- Sulcus centralis 6
- Sulcus precentralis 7
- Sulcus postcentralis 8
- Gyrus postcentralis 9
- Sulcus intraparietalis 10
- Lobulus parietalis superior 11
- Gyrus supramarginalis 12
- Gyrus angularis 13
- Gyri occipitales 14
- Sulcus frontalis inferior 15
- Gyrus frontalis inferior 16
- Ramus marginalis sulci cinguli 17



Мозг полушария



Sulcus cinguli 1

Sulcus rostralis superior 2

Sulcus rostralis inferior 3

Gyrus rectus 4

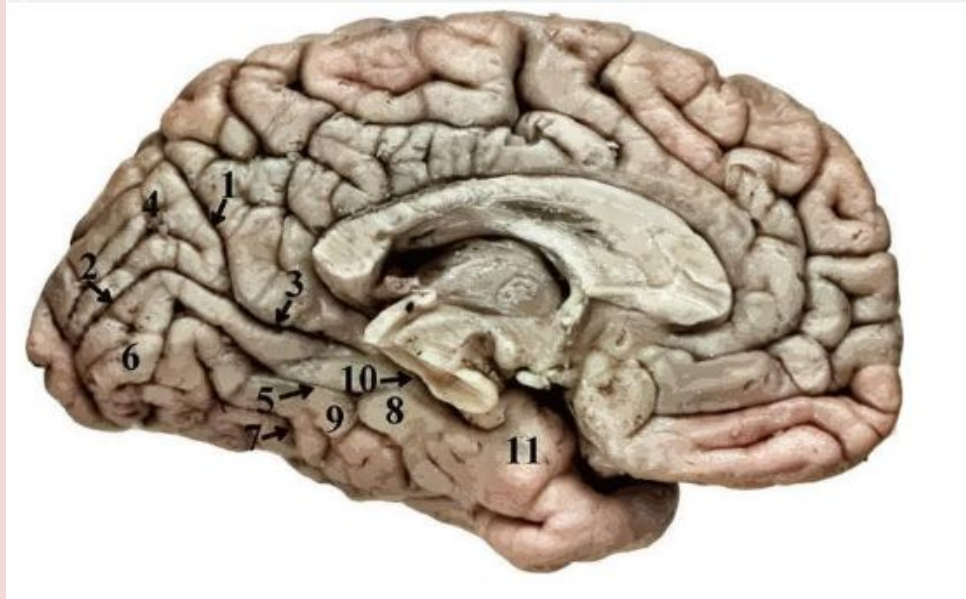Gyrus cinguli 5

Gyrus frontalis superior 6

Corpus callosum 7

Sulcus corporis callosi 8

Мозг полушария



Sulcus parietooccipitalis 1

Sulcus calcarinus 2

Truncus calcarinae 3

Cuneus 4

Sulcus collateralis 5

Gyrus lingualis 6

Sulcus occipitotemporalis 7

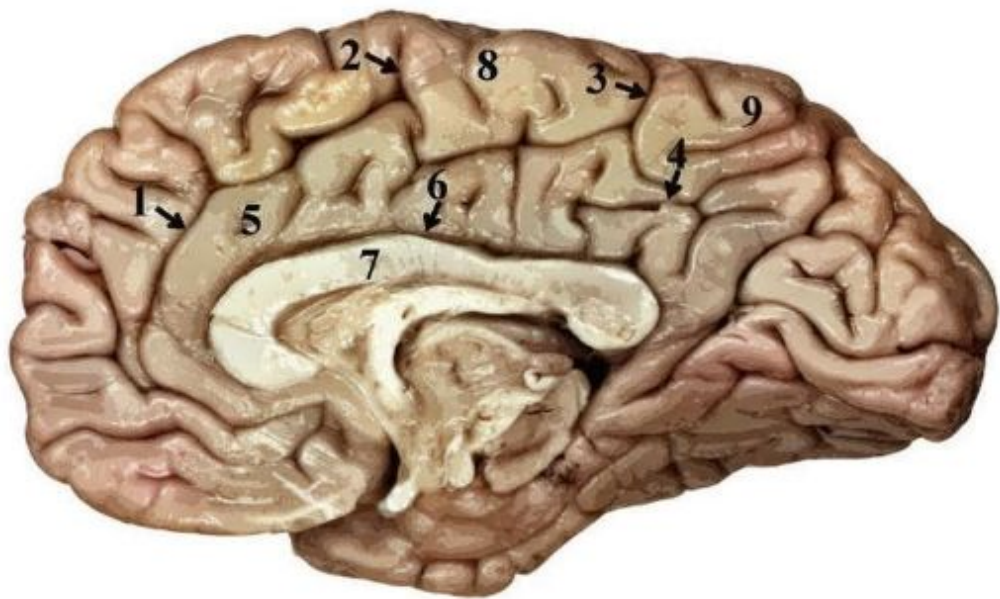
Gyrus parahippocampalis 8

Gyrus occipitotemporalis 9

Sulcus hippocampalis 10

Uncus hippocampi 11

Мозг борозды



Sulcus cinguli 1

Sulcus paracentralis 2

Ramus marginalis sulci cinguli 3

Sulcus subparietalis 4

Gyrus cinguli 5

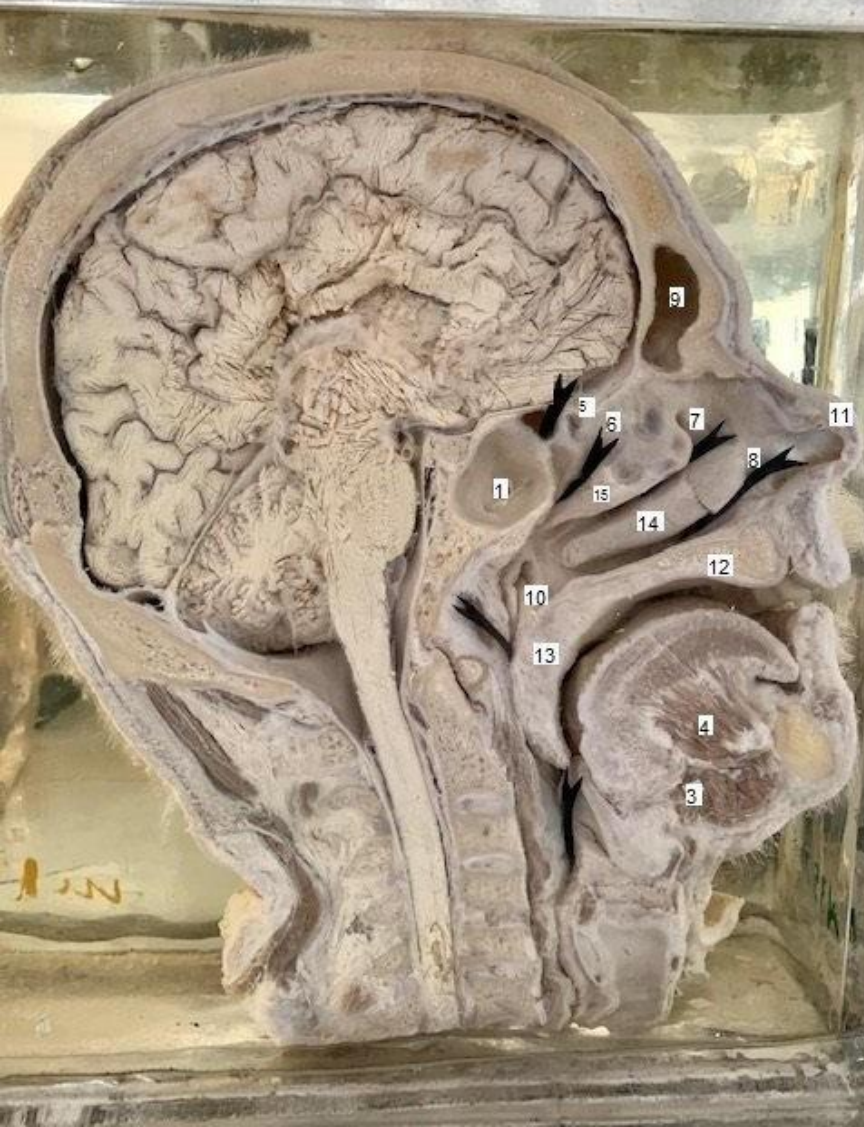
Sulcus corporis callosi 6

Corpus callosum 7

Lobulus paracentralis 8

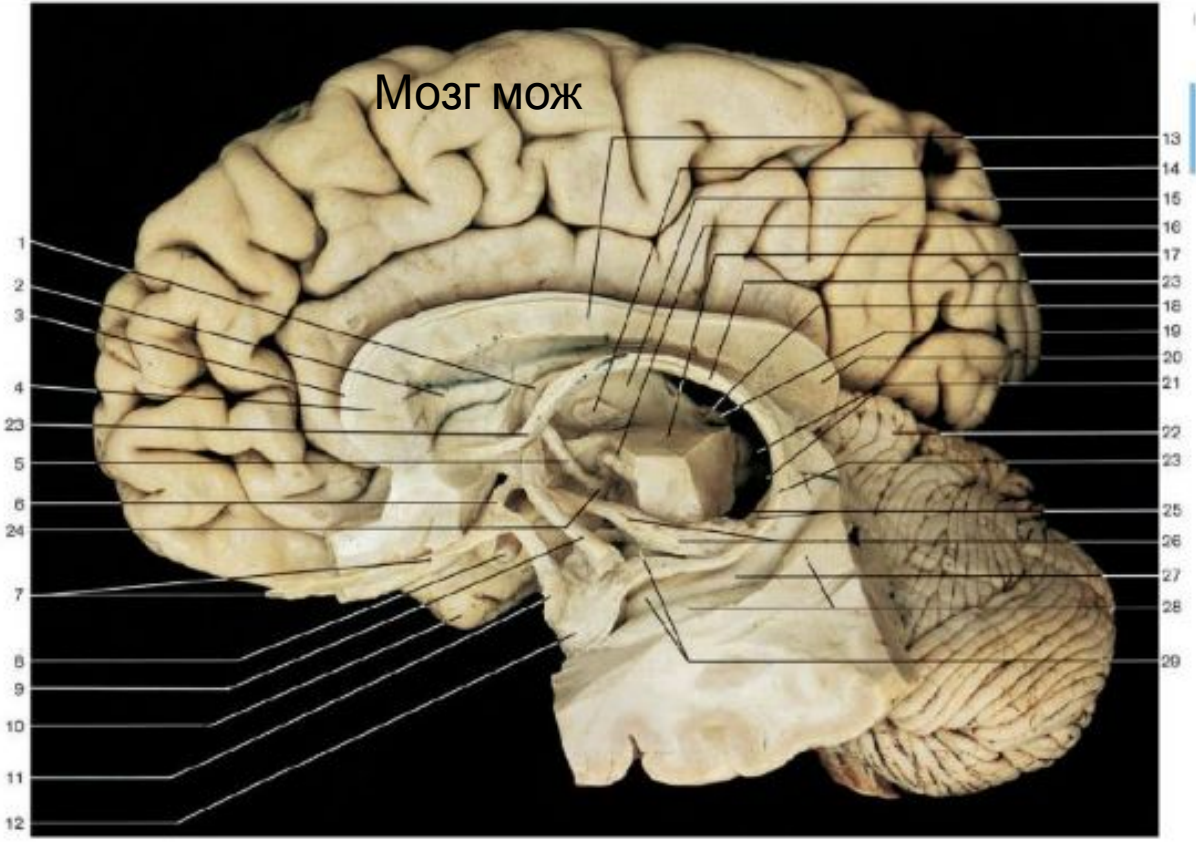
Precuneus 9

Мозг
НОС

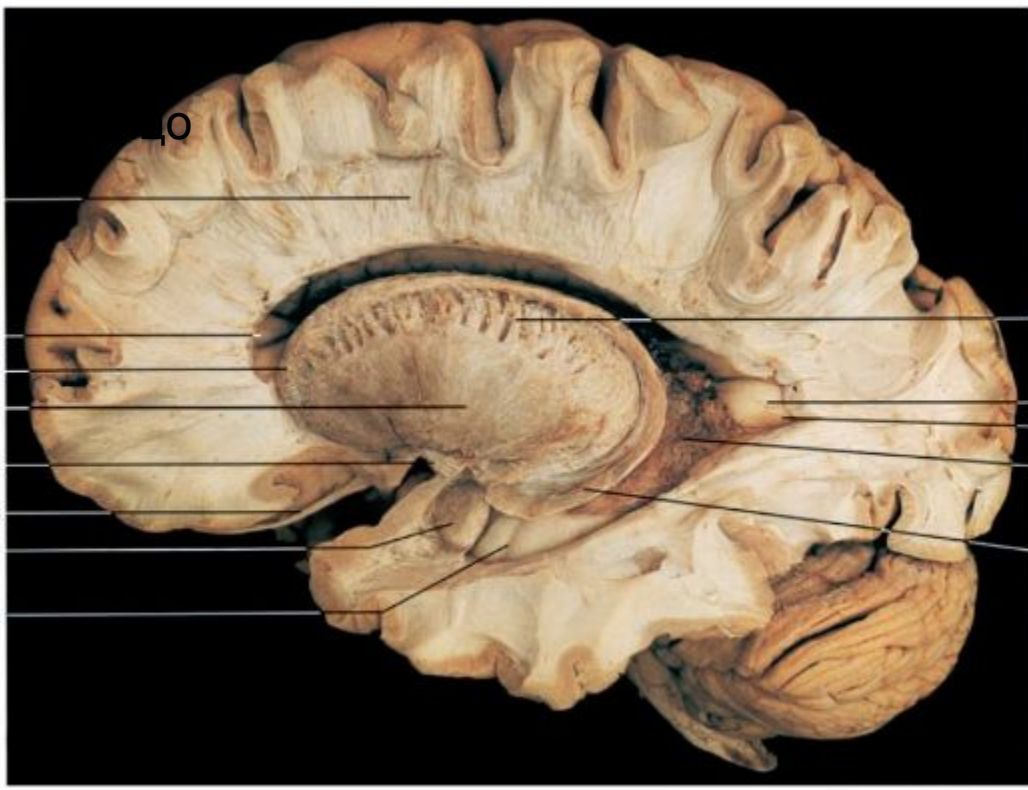


- concha nasalis superior 5
- meatys nasi inferior 8
- palatum durum 12
- meatys nasi medius 7
- meatys nasi superior 6
- nasus externus 11
- sinus sphenoidalis 1
- palatum molle 13
- sinus frontalis 9
- ostium pharyngeum tubae auditivae 10
- concha nasalis inferior 14
- concha nasalis media 15

Мозг мож

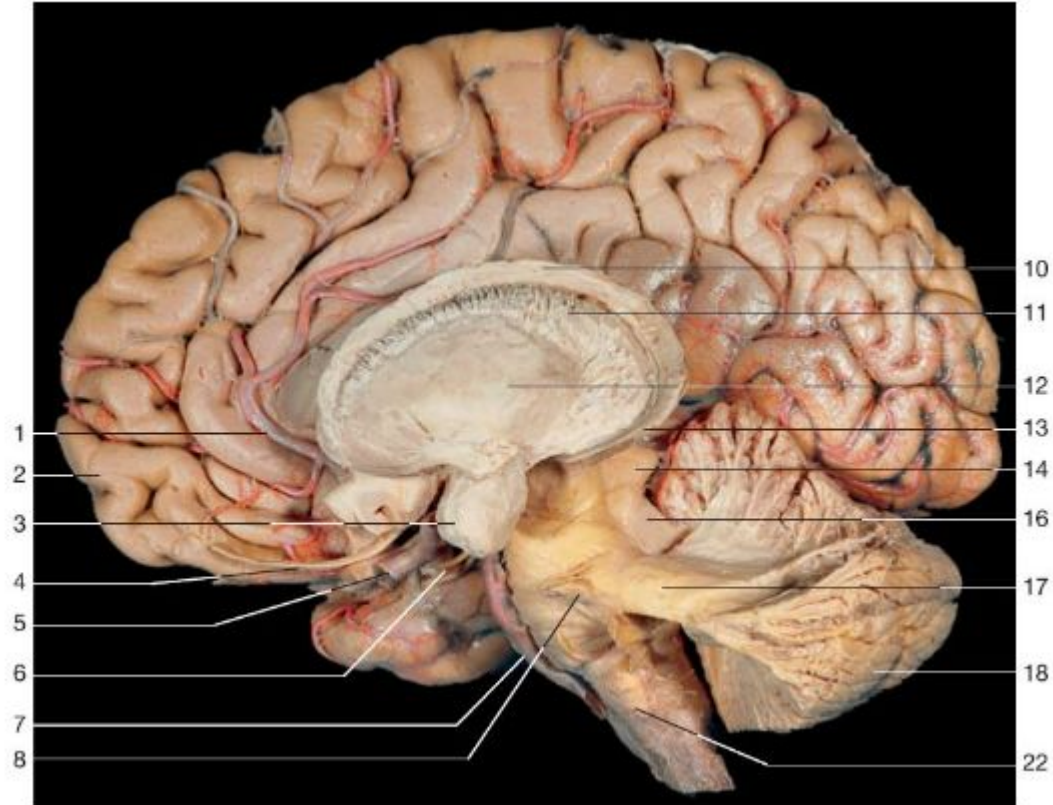


- bulbus olfactorius, tractus olfactorius 7
- stria olfactorius medialis 6
- stria olfactorius lateralis 11
- corpus amygdaloideum 12
- corpus collosum 4
- hippocampus 27
- Fornix 1



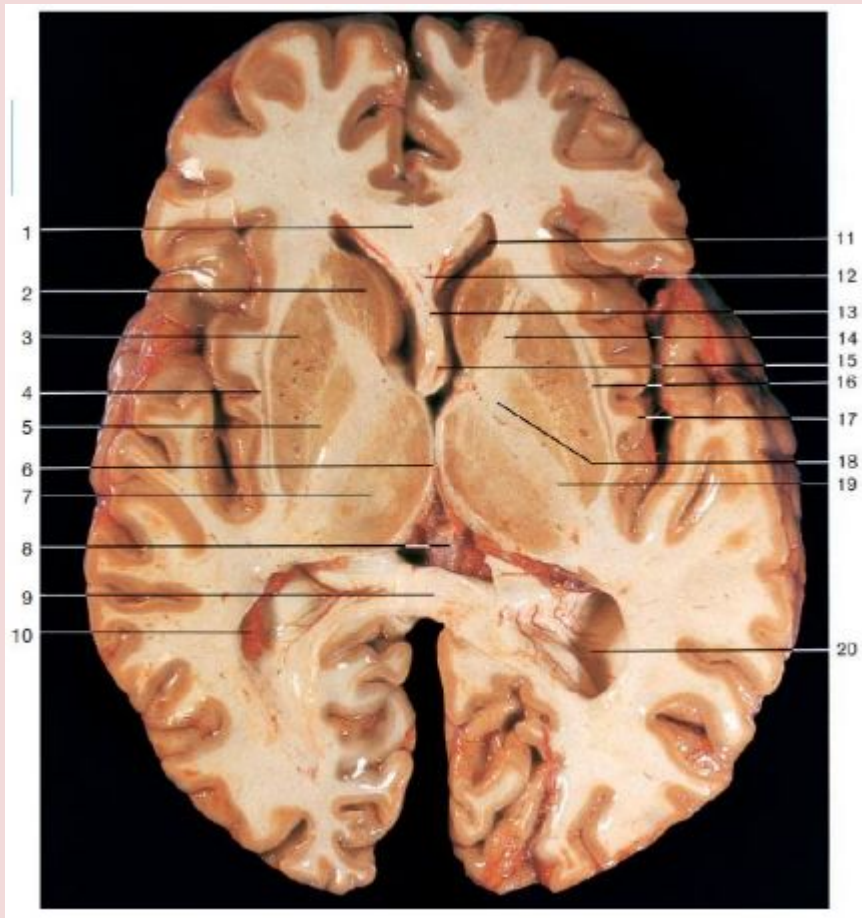
- caput nuclei caudati 3
- tractus olfactorius 6
- capsula interna 9
- cauda nuclei caudati 13
- commissura anterior 5
- corona radiata 1
- Putamen 4
- corpus amygdaloideum 7

Мозг яйцо



- pedunculi cerebelli media 17
- corpus amygdaloideum 3
- cauda nuclei caudati 13
- nervus trigeminus 8
- Oliva 22
- tractus olfactorius 4
- pedunculi cerebelli superior 16
- tectum mesencephali 14

Мозг строение



thalamus 7

splenium corpus callosum 9

Clastrum 4

plexus chorioideus ventriculi laterales 10

cornu posterior ventriculi laterales 20

septum pellucidum 13

capsula externa 16

Putamen 3

corpus pineale 8

genus corpus callosum 1

caput nuclei caudati 2

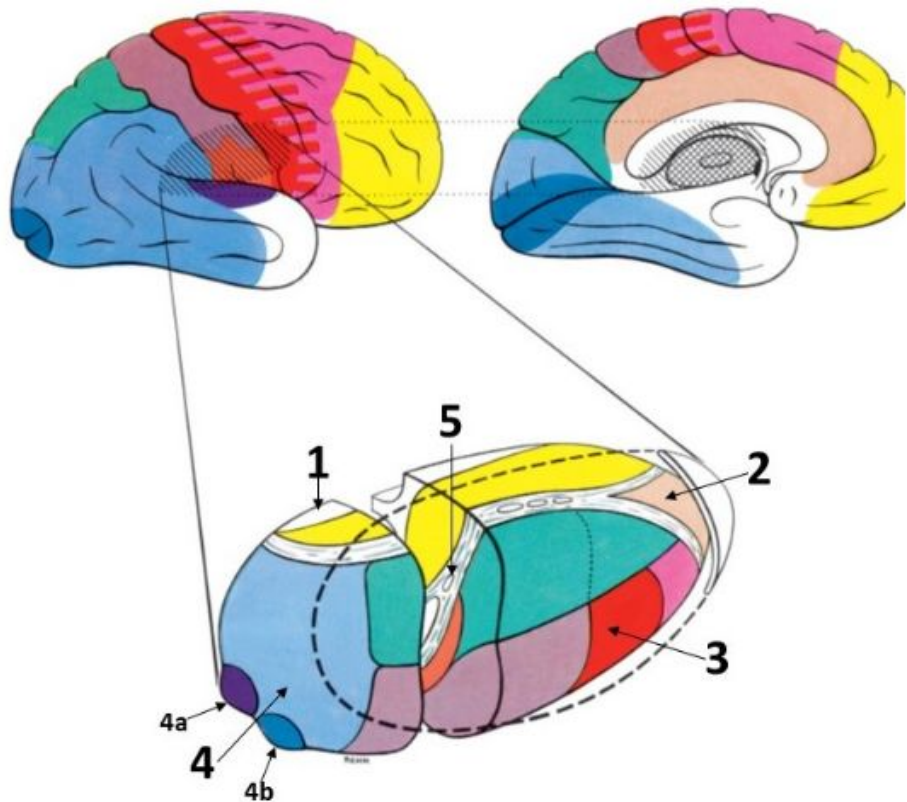
globus pallidus 5

ventriculus tertius 6

переднее бедро capsula interna 14

заднее бедро capsula interna 19

колени capsula interna 18

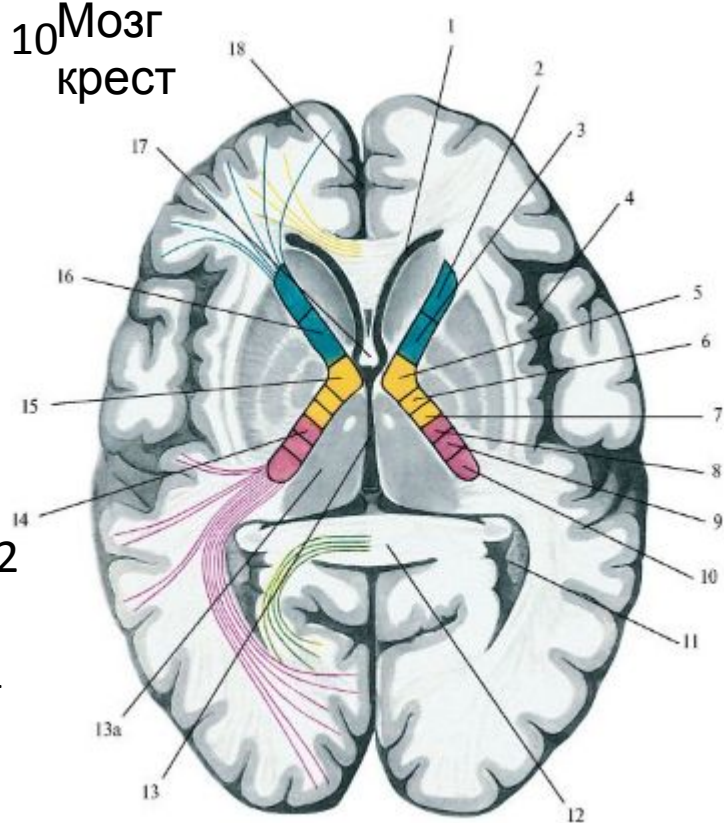


Мозг
цветной

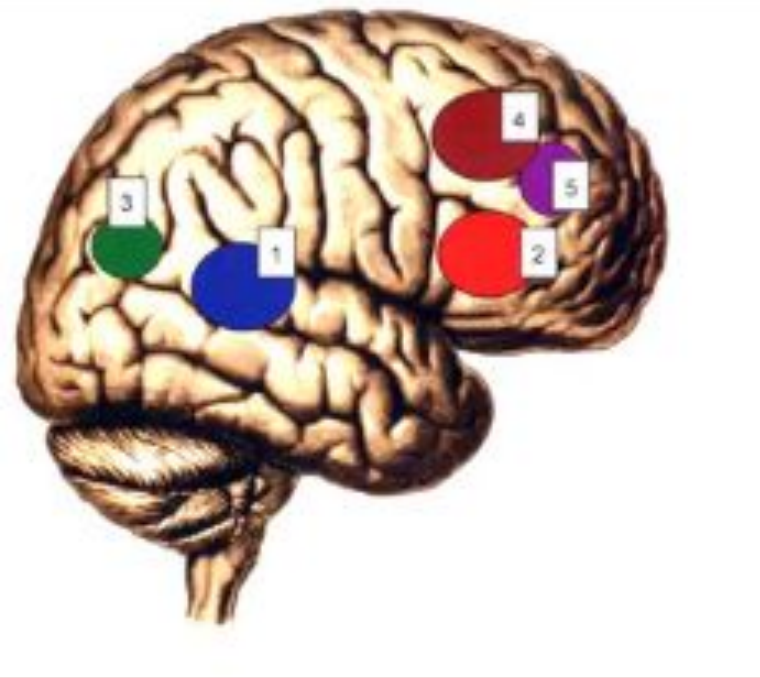
- nuclei mediani thalami 1
- corpus geniculatum laterale 4B
- nuclei posteriors, pulvinares thalami 4
- corpus geniculatum mediale 4A
- nucll. mediales thalami 5
- nucll. ventrolaterales thalami 3
- nucll. anteriores thalami 2

5/7

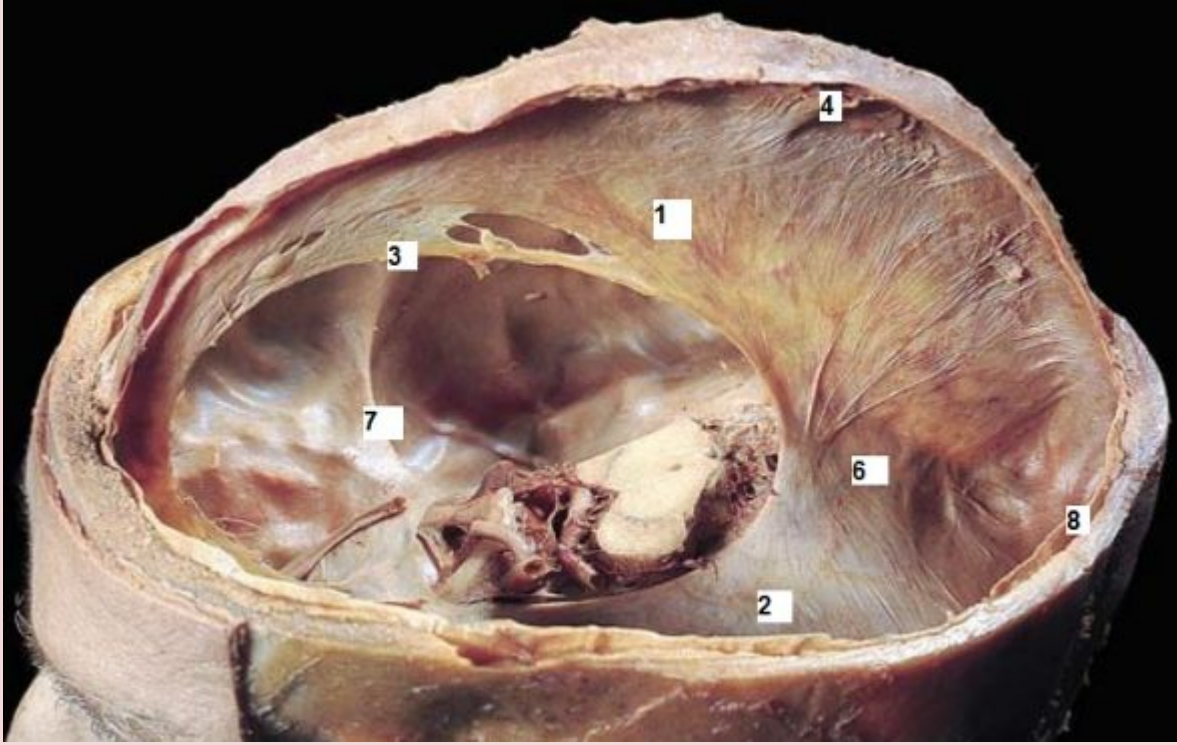
- Мозг крест
 центральный зрительный путь 10
 crus anterior capsulae internaе 16
 ventriculus tertius 13
 tractus corticonucleais 5
 fissura longitudinalis cerebri 18
 Thalamus 13A
 tractus occipitotemporo-pontinus 8
 tractus corticospinalis 6
 tractus talamocorticalis 7
 radiationes thalamicae anteriores 2
 Insula 4
 cornu anterior ventriculi lateralis 1
 tractus frontopontinus 3
 центральный слуховой путь 9
 plexus chorioideus ventriculi laterales 11
 splenium corporis callosi 12
 crus posterior 14
 genu capsulae internaе 15
 septum pellucidum 17



Мозг ядра

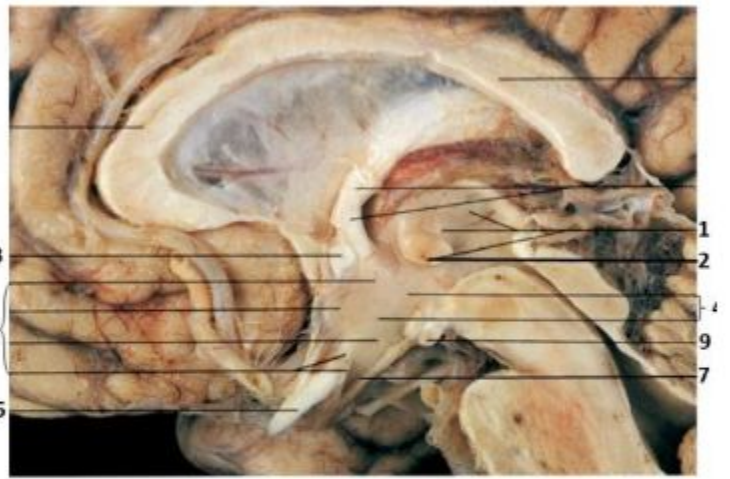
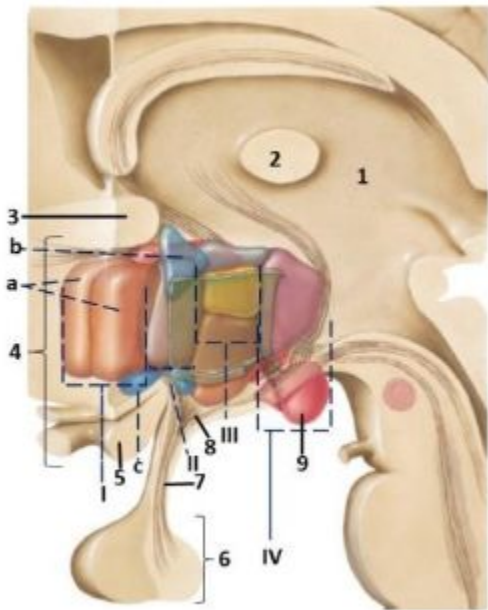


- Ядро слухового анализатора устной речи (центр Вернике) 1
- Ядро двигательного анализатора (артикуляция) речи (центр Брока) 2
- Ядро зрительного анализатора письменной речи 3
- Ядро двигательного анализатора письменной речи 4



sinus petrosus superior 7
sinus sagittalis superior 4
sinus rectus 6
tentorium cerebelli 2
Diploe 5
falx cerebri 1
sinus sagittalis inferior 3
dura mater encephali 8

Мозг
любим



супраоптическое ядро С

Thalamus 1

adhesio interthalamica 2

паравентрикулярное ядро В

regio subthalamica 4

hypophysis cerebri 6

преоптическое ядро А

corpora mamillaria 8

задняя группа ядер IV

commissure anterior 3

chiasma opticum 5

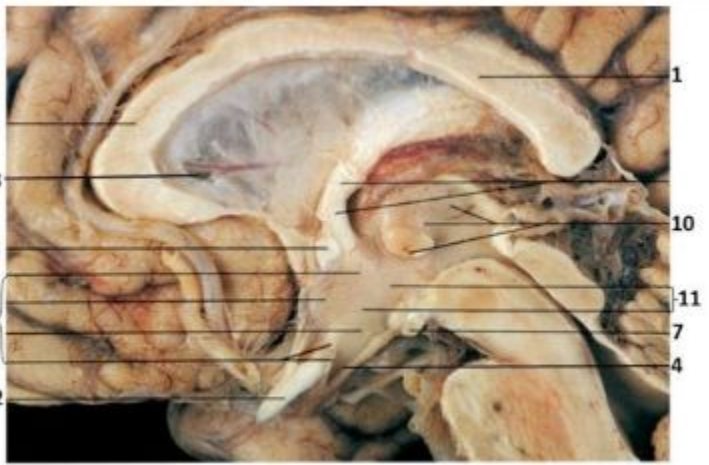
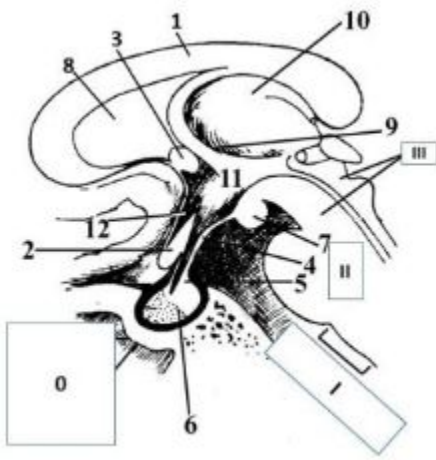
Infundibulum 7

преоптическая группа ядер I

передняя группа ядер II

срединная группа ядер III

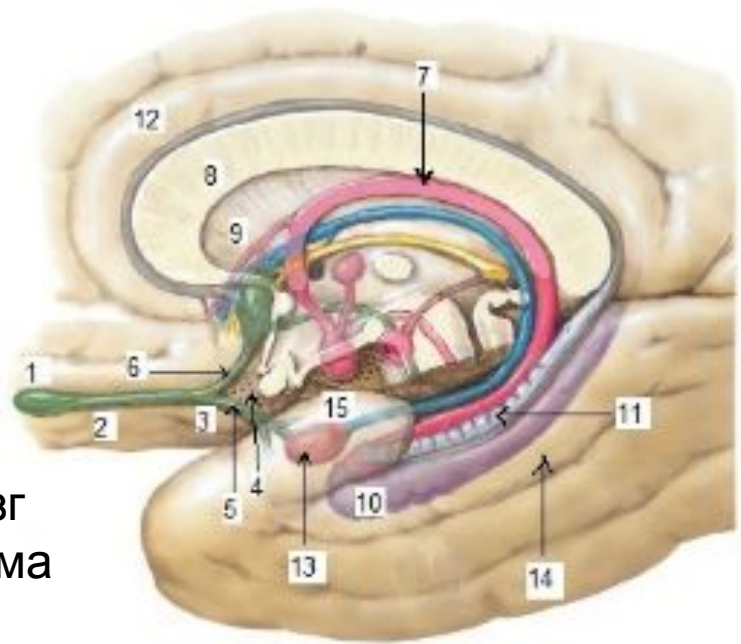
13/15



- hypophysis cerebri 6
- sella turcica 0
- medulla oblongata I
- sulcus hypothalamicus 9
- corpus callosum 1
- lamina terminalis 12
- corpora mamillaria 7
- Pons II
- chiasma opticum 2
- septa pellucidum 8
- commissure anterior 3
- tuber cinereum 4
- Infundibulum 5
- thalamus, adhesio interthalamica 10
- regio subthalamica 11
- Mesencephalon III

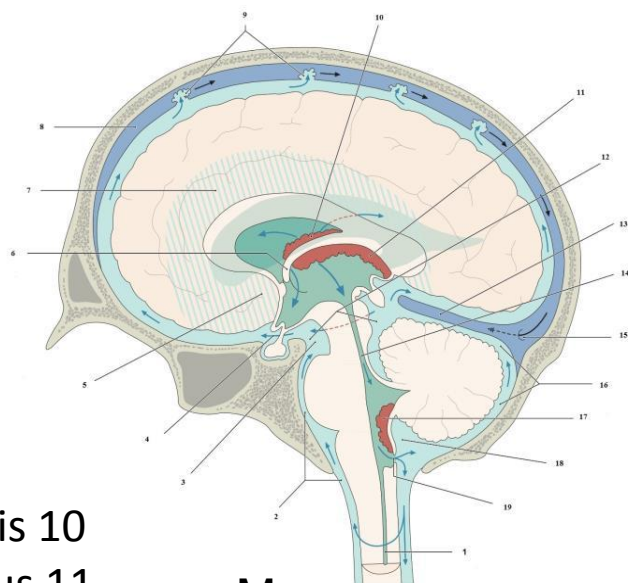
Мозг
схема

- bulbus olfactorius 1
- tractus olfactorius 2
- trigonum olfactorium 3
- substantia perforata anterior 4
- stria olfactorius medialis 5
- stria olfactorius lateralis 6
- Fornix 7
- corpus collosum 8
- septum pellucidum 9
- hippocampus 10
- gyrus dentatus 11
- gyrus cingule 12
- corpus amygdaloideum 13
- gyrus parahippocampalis 14
- uncus hippocampi 15

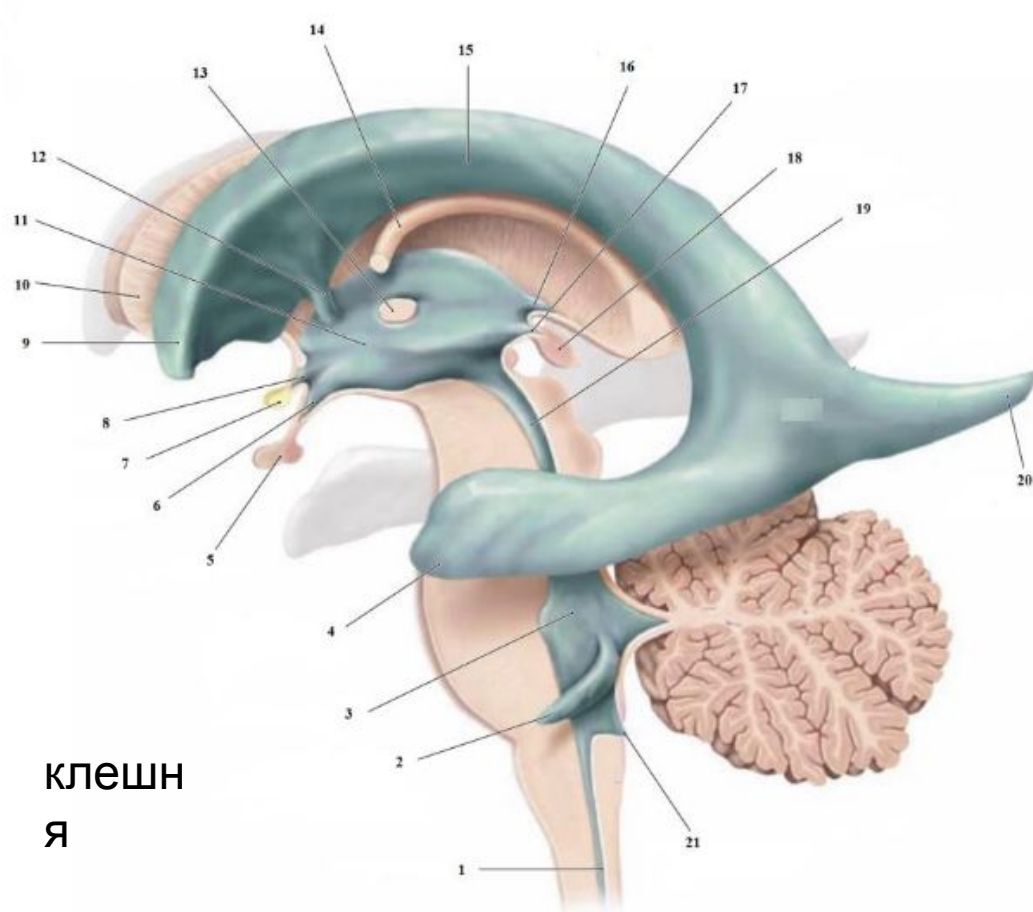


Мозг
схема

- canalis centralis 1
- cisterna pontomedullary 2
- cisterna interpeduncularis 3
- cisterna chiasmatica 4
- cisterna lamina terminalis 5
- foramen interventriculare 6
- cisterna interhemispherica 7
- sinus sagittalis superior 8
- granulationes arachnoidales 9
- plexus choroideus ventriculi lateralis 10
- plexus choroideus ventriculus tertius 11
- cisterna ambiens 12
- sinus rectus 13
- aqueductus cerebri 14
- confluens sinuum 15
- cisterna vermis 16
- plexus choroideus ventriculus quartus 17
- cisterna cerebellomedullaris 18
- apertura medialis ventriculi quarti 19



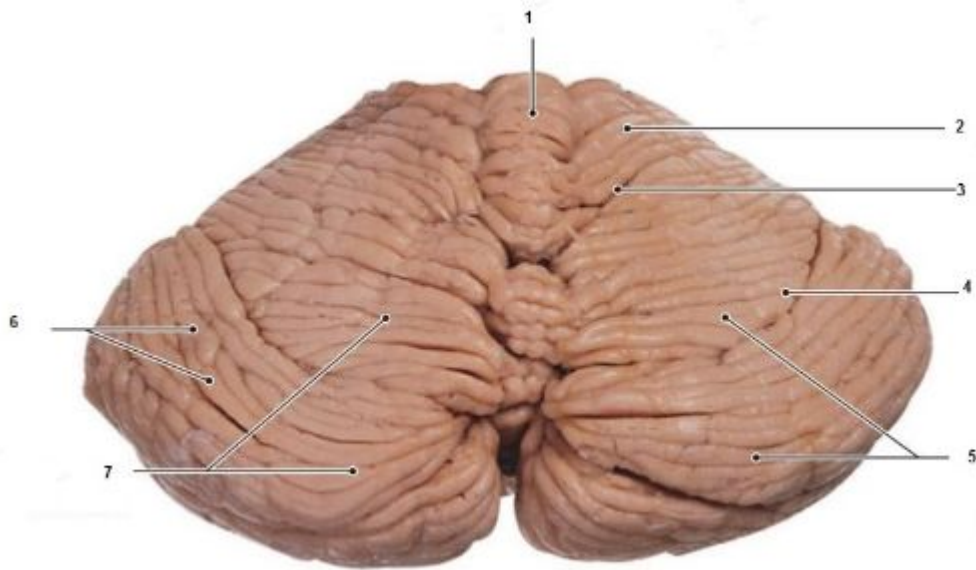
Мозг
схема



КЛЕШН Я

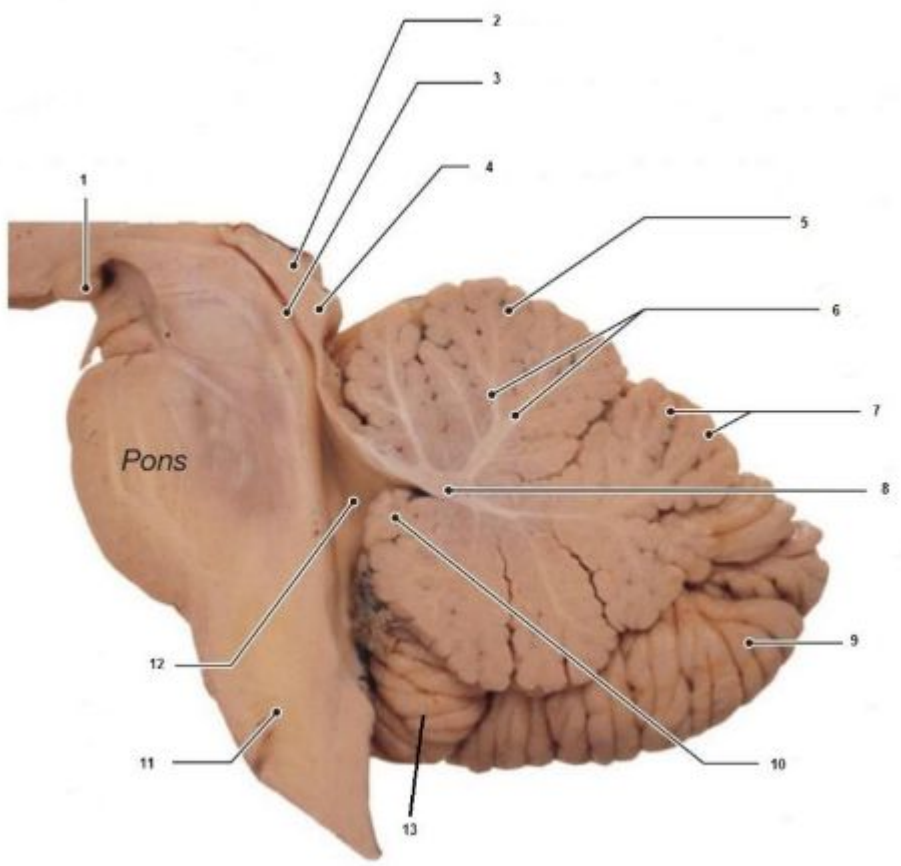
cornu anterius ventriculi lateralis 9
 cornu posterius ventriculi lateralis 20
 recessus pinealis 17
 foramen interventriculare 12
 pars centralis ventriculi lateralis 15
 chiasma opticum 7
 cornu inferius ventriculi lateralis 4
 ventriculus tertius 11
 apertura mediana ventriculi quarti 21
 fornix cerebri 14

adhesio interthalamica 13
 aquaeductus mesencephali 19
 canalis centralis 1
 recessus suprapinealis 16
 infundibulum recessus 6
 recessus lateralis ventriculi quarti 2
 ventriculus quartus 3
 Hypophysis 5
 recessus suprachiasmaticus 8
 corpus callosum 10
 corpus pineale 18



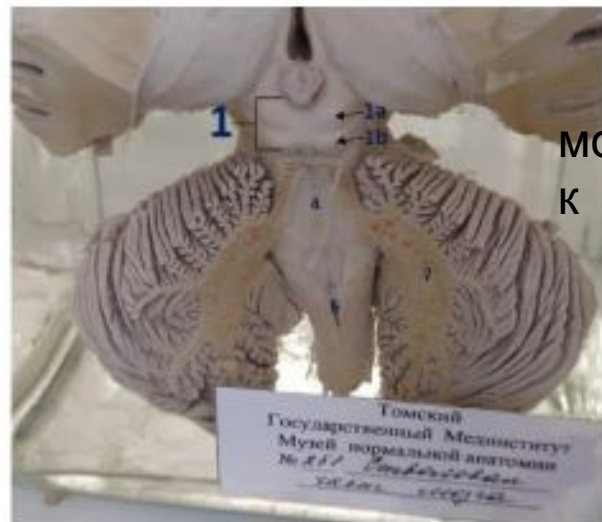**МОЖЕЧО
К**

- hemispheria cerebelli dextra 5
- folia cerebelli 7
- lobus posterior cerebelli 4
- hemispheria cerebelli sinistra 6
- lobus anterior cerebelli 2
- fissurae cerebelli 3
- Vermis 1

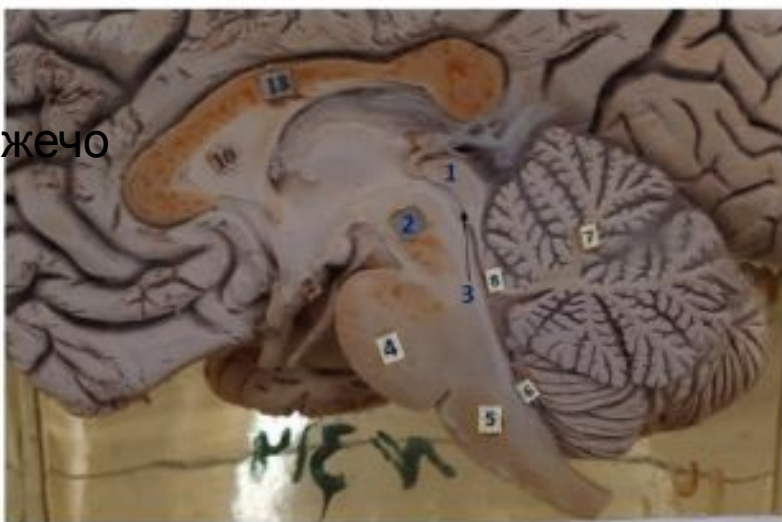

Можечок половина

- lobus posterior cerebelli 9.
- Nodulus 10
- arbor vitae cerebelli 6.
- nucleus fastigii 8.
- lobus anterior cerebelli 5.
- cortex cerebelli 7.
- Flocculus 13

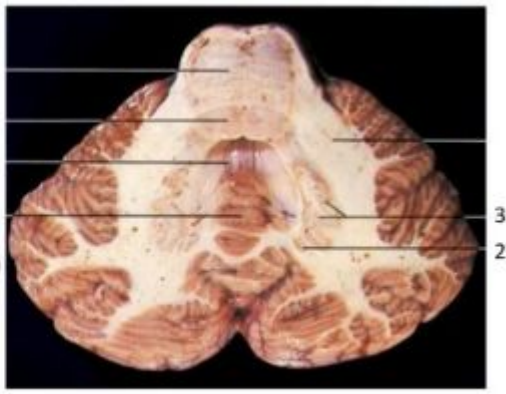
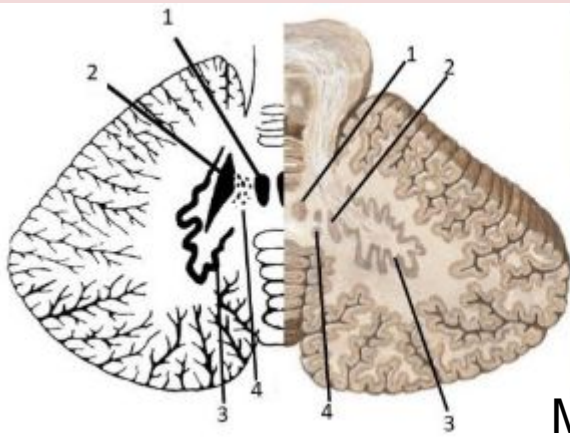


мозжечо
к



- Pedunculi cerebri 2
- Colliculi superiores 1A
- Pedunculus cerebellaris inferior 6
- Aqueductus cerebri 3
- Pons 4
- Medulla oblongata 5
- Tectum mesencephali 1
- Cerebellum 7
- Pedunculis cerebellaris superior 8
- Colliculi inferiores 1B

8/10



Можечок

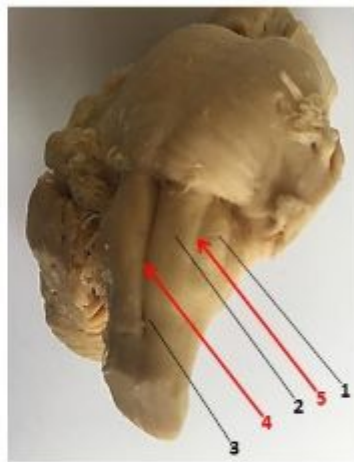
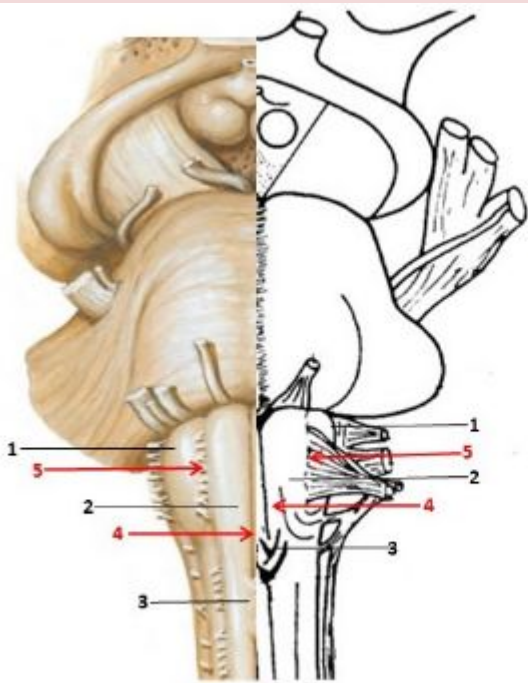
ядра

nucleus globosus 4

nucleus emboliformis 2

nucleus dentatus 3

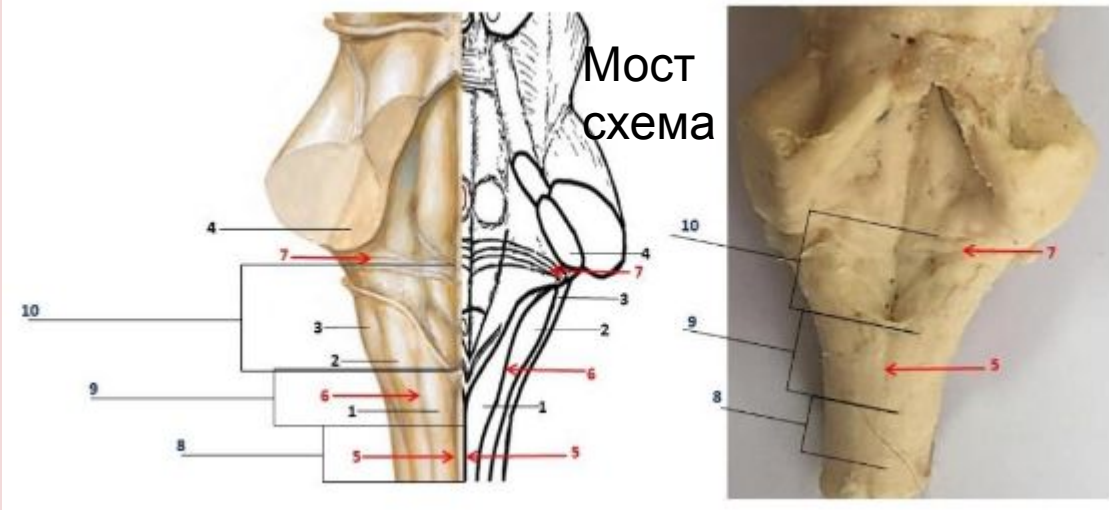
nucleus fastigii 1



Мост
схема

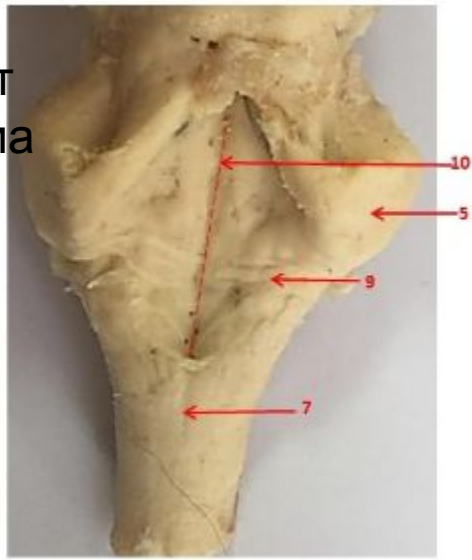
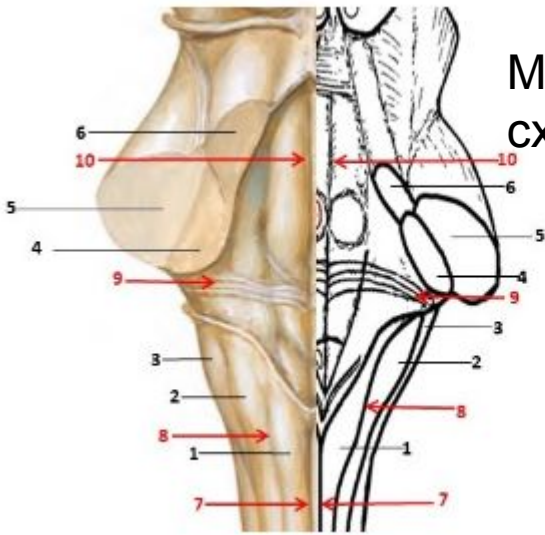
- Sulcus mediana anterior 4
- Sulcus anterolateralis 5
- Oliva 1
- Pyramis medullae oblongatae 2
- Decussatio pyramidum 3

Мост схема



- Pedunculus cerebellaris inferior 4'
- Tuberculum cuneatum 2
- Sulcus medianus posterior 5
- Striae medullares ventriculi quarti 7
- Tuberculum gracile 1
- Pars rostralis 8
- Sulcus posterolateralis 6
- Pars centralis 9
- Oliva 3
- Pars caudalis 10

Мост схема



Tuberculum cuneatum 2

Sulcus posterolateralis 8

Pedunculus cerebellaris superior 6

Pedunculus cerebellaris medius 5

Pedunculus cerebellaris inferior 4

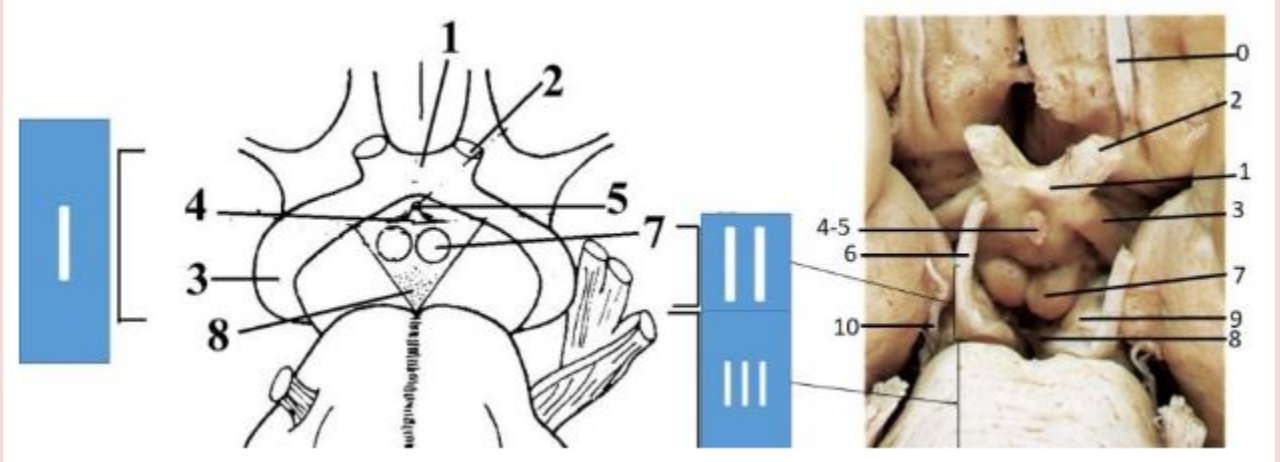
Oliva 3

Sulcus medianus posterior 7

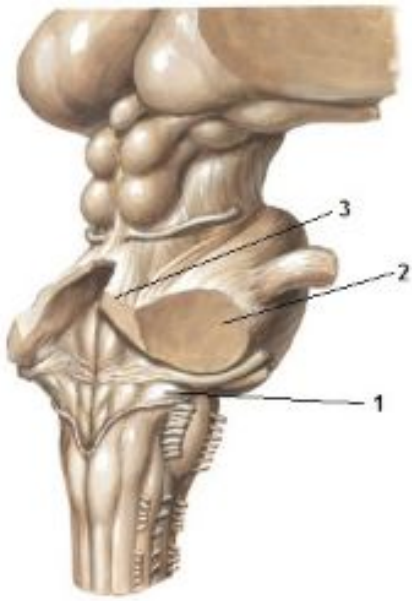
Tuberculum gracile 1

Striae medullares ventriculi quarti 9

Sulcus medianus 10

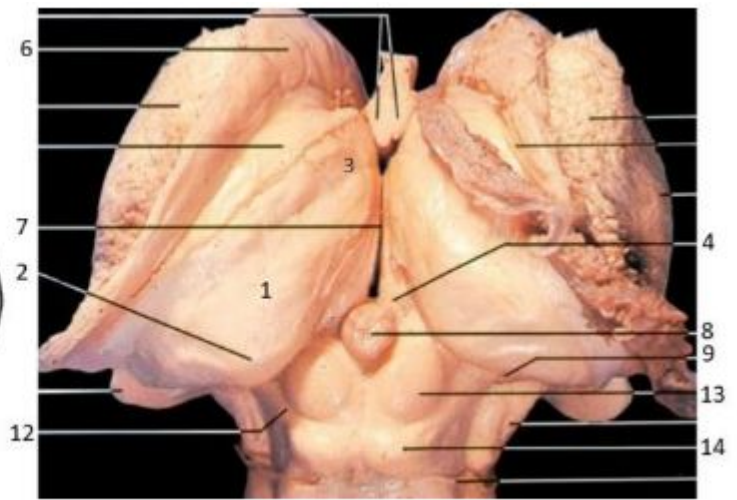
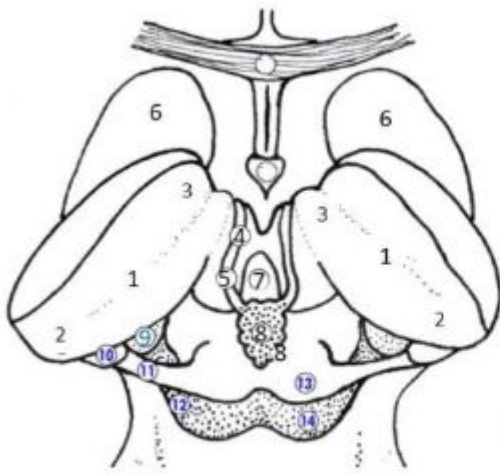


- tr. Olfactorius 0
- tr. opticus 3
- chiasma opticum 1
- corpora mamillaria 7
- tuber cinereum 4
- n. opticus, II 2
- Infundibulum 5
- n. oculomotorius (III) 6
- substantia perforate posterior 8
- crus cerebri 9
- n. trochlearis (IV) 10
- Diencephalon I
- Mesencephalon II
- Pons III

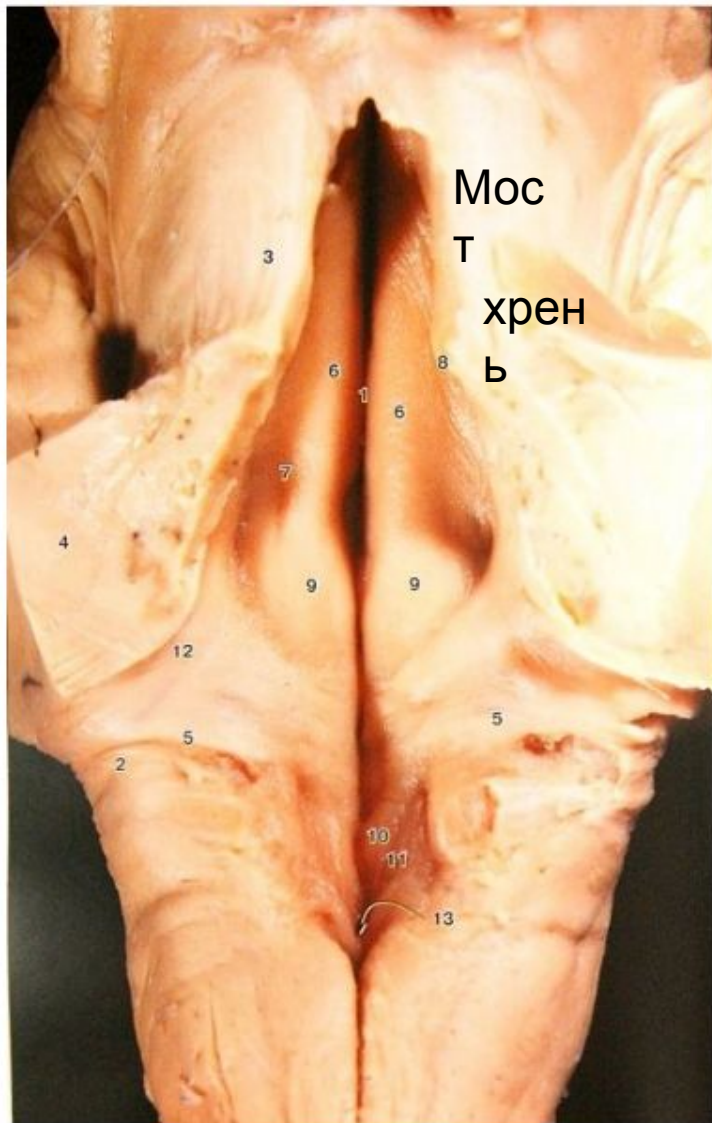


pedunculis cerebellaris superior 3
pedunculis cerebellaris medius 2
pedunculis cerebellaris inferior 1

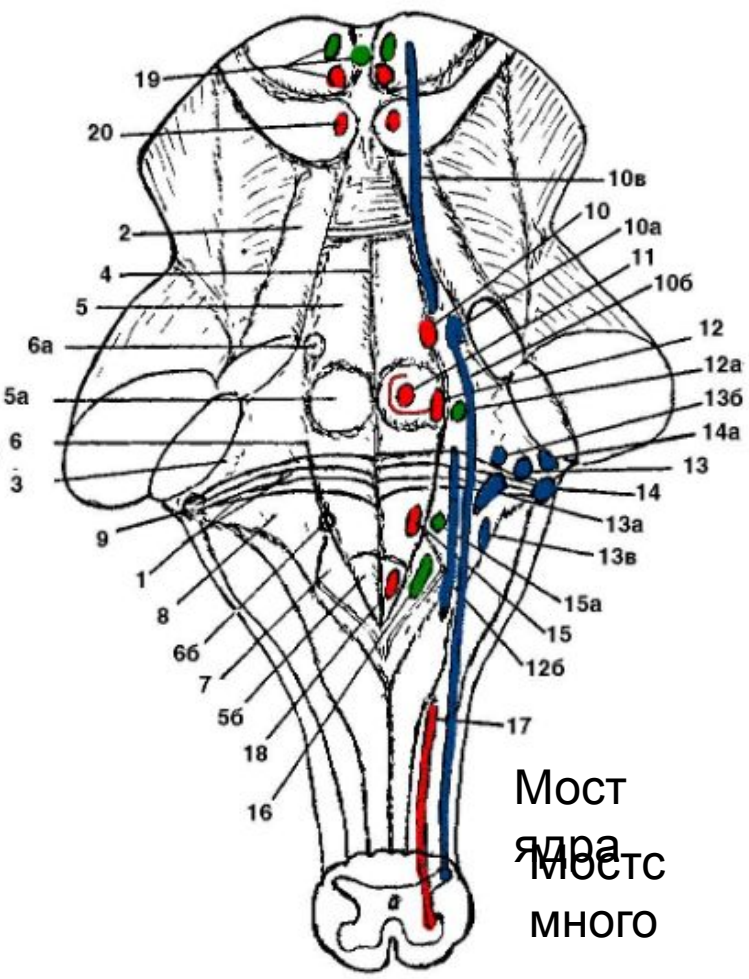
1/3



- caput nuclei caudati 6
- brachium colliculi superioris 12
- epiphysis cerebri, corpus pineale 8
- pulvinar thalami 2
- brachium colliculi inferioris 11
- Habenula 5
- tuberculum anterius thalami 3
- corpus geniculatum mediale 9
- Thalamus 1
- trigonum habenulae 4
- ventriculus tertius 7
- corpus geniculatum laterale 10
- colliculus superior 13
- colliculus inferior 14



- pedunculis cerebellaris superior 3
- area vestibularis 12
- eminentia medialis 6
- tuberculum facialis 9
- pedunculis cerebellaris inferio 2
- striae medullaris, seu acustici 5
- sulcus medianus 1.
- sulcus limitans 7
- canalis centralis 13
- trigonum nervi hypoglossi 10
- pedunculis cerebellaris medius 4
- locus caeruleus 8
- trigonum nervi vag 11

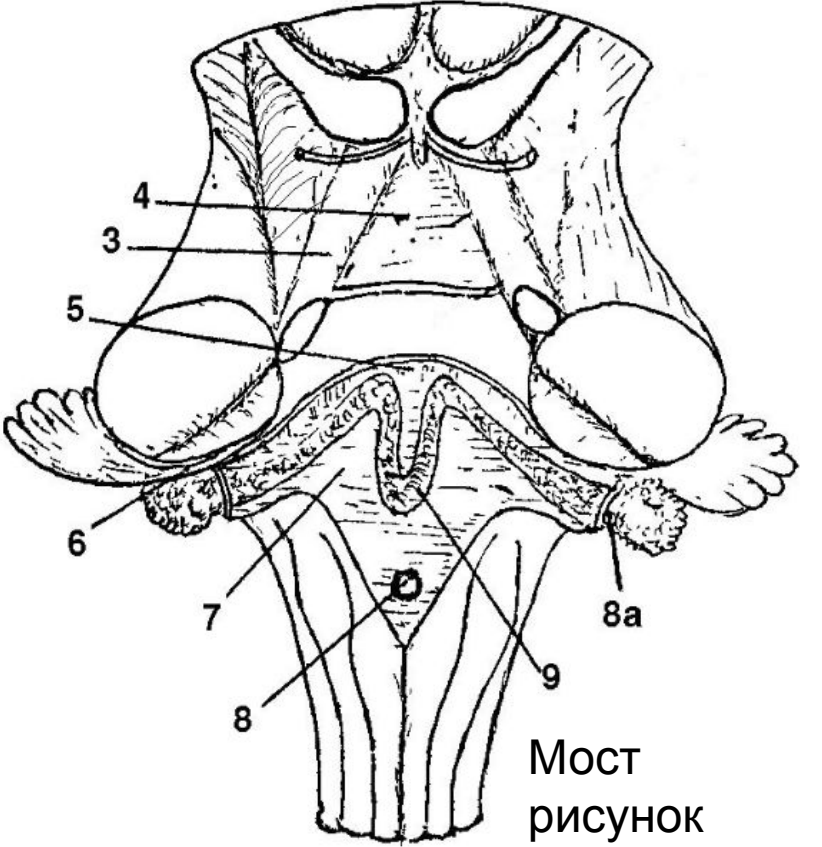


- trigonum nervi hypoglossi 5Б
- tuberculum facialis 5A
- sulcus medianus 4
- tuberculum acusticus 9
- pedunculis cerebellaris inferior 3
- fovea inferior 6Б
- pedunculis cerebellaris superior 2
- fovea superior 6A
- striae medullaris, seu acustici 1
- eminentia medialis 5
- sulcus limitans 6
- trigonum nervi vagi s. ala cinerea 7
- area vestibularis 8

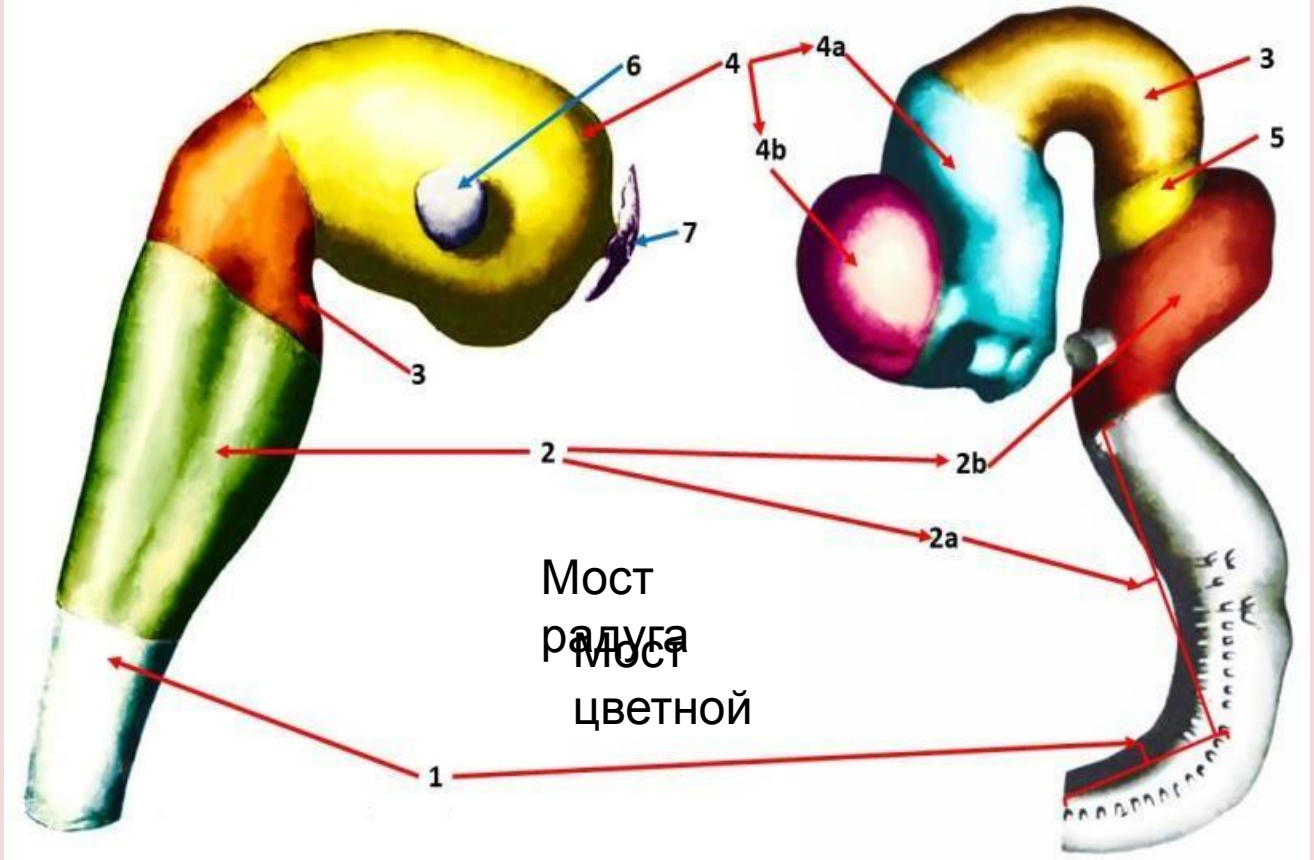
Мост
ядро
Моста
МНОГО

- nucl. salivatorius inferior 15A
- nucl. Ambiquus 15
- nucleus mesencephalicus 10B
- nucl. inferior n. vestibulo-cochlearis 13B
- nucl. superior n. vestibulo-cochlearis 13Б
- nucl. dorsalis nervi cochlearis 14
- nucleus facialis 12
- nucl. spinalis n. Accessorii 17
- nucl. n. Trochlearis 20
- nucl. n. Hypoglossi 5Б
- nucl. medialis n. vestibulo-cochlearis 13A
- nucleus tr. solitarii, seu nucleus solitarius 12Б
- nucleus motorius nervus trigeminis 10
- nucleus sensorius principalis, seu pontinus 10A
- nucleus tractus spinalis nervus trigeminis 10Б

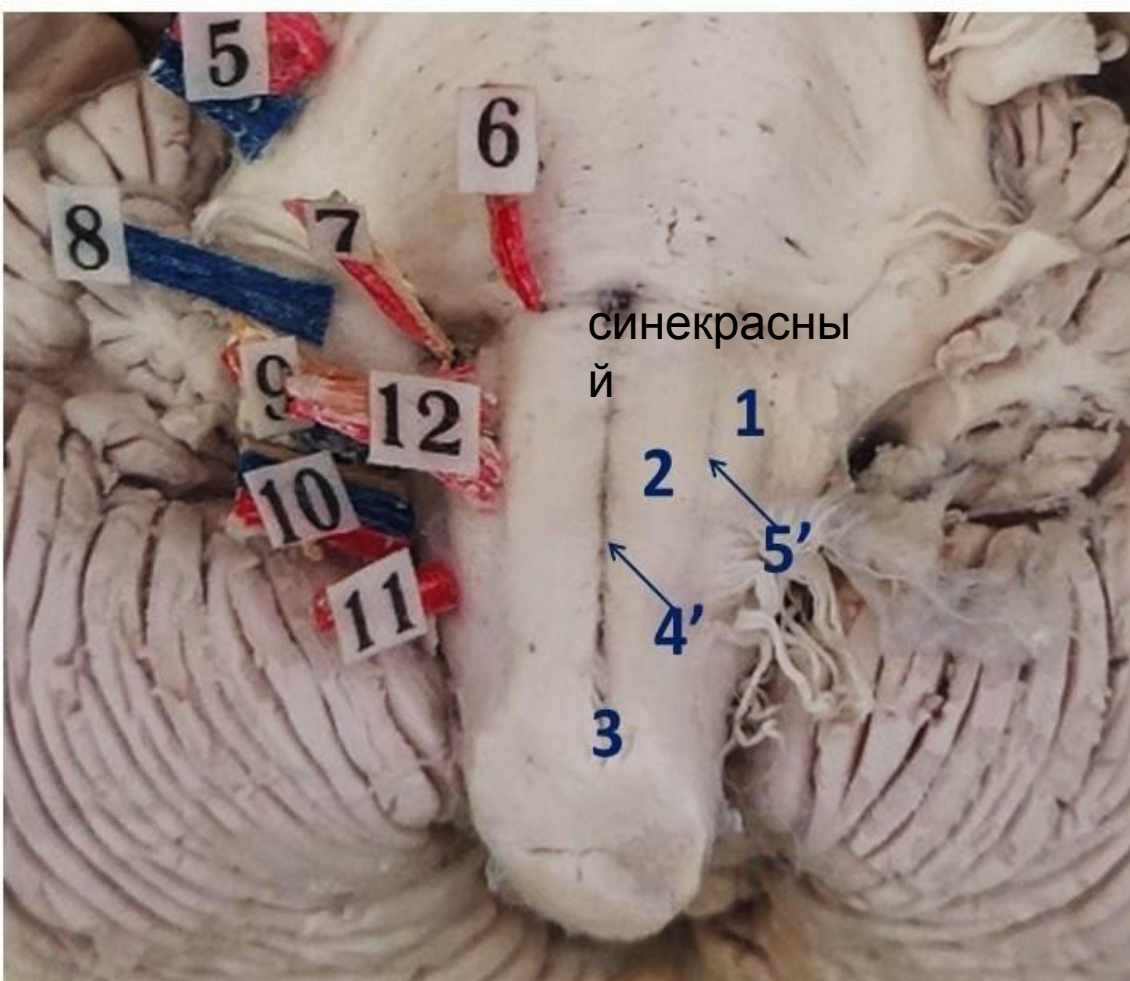
- nucleus abducentis 11
- nucleus solivatorius superior 12A
- nucl. lateralis n. vestibulo-cochlearis 13
- nucl. ventralis n. Cochlearis 14A
- nucl. dorsalis n. Vagi 16
- nuclii n. Oculomotorii 19



- velum medullaris inferior 5
- velum medullaris superior 4
- apertura mediana ventriculi 8
- pedunculi cerebellaris superior 3
- pedunculi flocculi 6
- tela chorioidea 7
- aperturæ lateralis 8A
- plexus chorioideus ventriculi quarti 9



- Diencephalon 4A
- Telencephalon 4B
- Vesicula optica 6
- Proencephalon 4
- Medulla spinalis 1
- Metencephalon 2B
- Isthmus 5
- Mesencephalon 3
- Rhomdencephalon 2
- Myelencephalon 2A
- Neuroporus anterior 7



Nervus vestibulocochlearis 8

Oliva 1

Nervus vagus 10

Pyramis medullae oblongatae; Pyramis bulbi 2

Nervus hypoglossus 12

Nervus glossopharyngeus 9

Sulcus anterolateralis 5'

Sulcus mediana anterior 4'

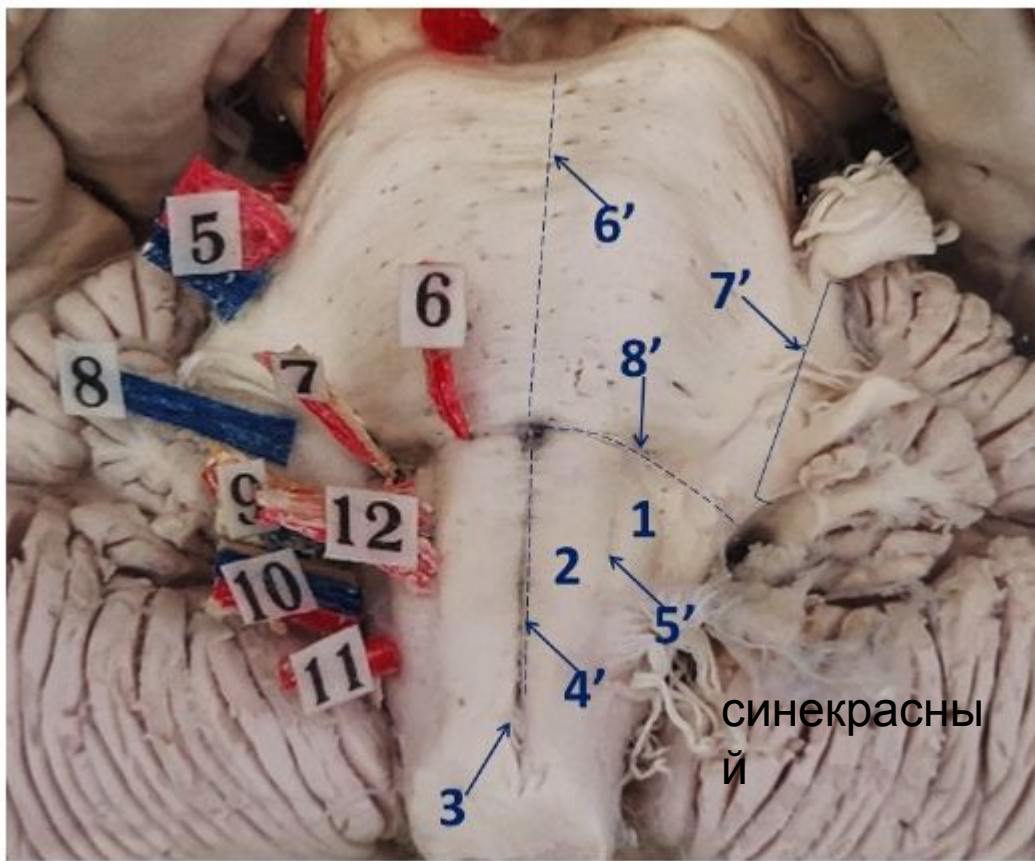
Nervus accessorius 11

Decussatio pyramidum 3

Nervus trigeminus 5

Nervus abducens 6

Nervus facialis 7



Nervus hypoglossus 12

Nervus accessorius 11

Nervus vagus 10

Nervus vestibulocochlearis 8

Nervus facialis 7

Sulcus anterolateralis 5'

Pyramis medullae oblongatae; Pyramis bulbi 2

Nervus glossopharyngeus 9

Sulcus bulbopontinus 8'

Nervus trigeminus 5

Oliva 1

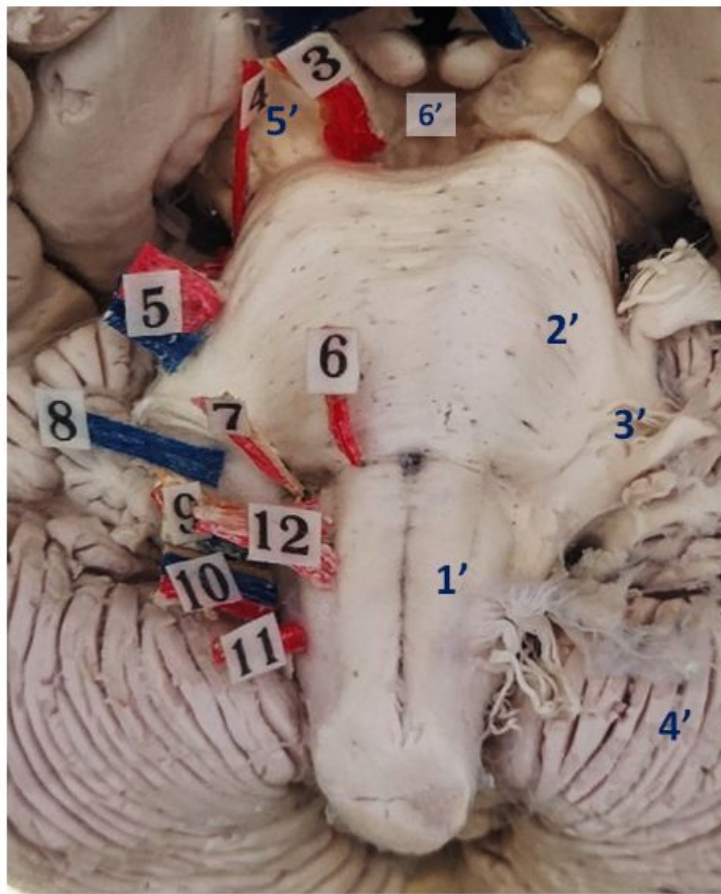
Decussatio pyramidum 3

Sulcus mediana anterior 4'

Nervus abducens 6

Sulcus basilaris 6'

Pedunculus cerebellaris medius 7'



синекрасны
й

Pons 2'

Nervus glossopharyngeus 9

Nervus oculomotorius 3

Nervus accessorius 11

Cerebellum 4'

Pedunculi cerebri 5'

Pedunculus cerebellaris medius 3'

Nervus trochlearis 4

Nervus vagus 10

Nervus facialis 7

Medulla oblongata 1'

Fossa interpeduncularis, substantia perforata posterior 6'

Nervus abducens 6

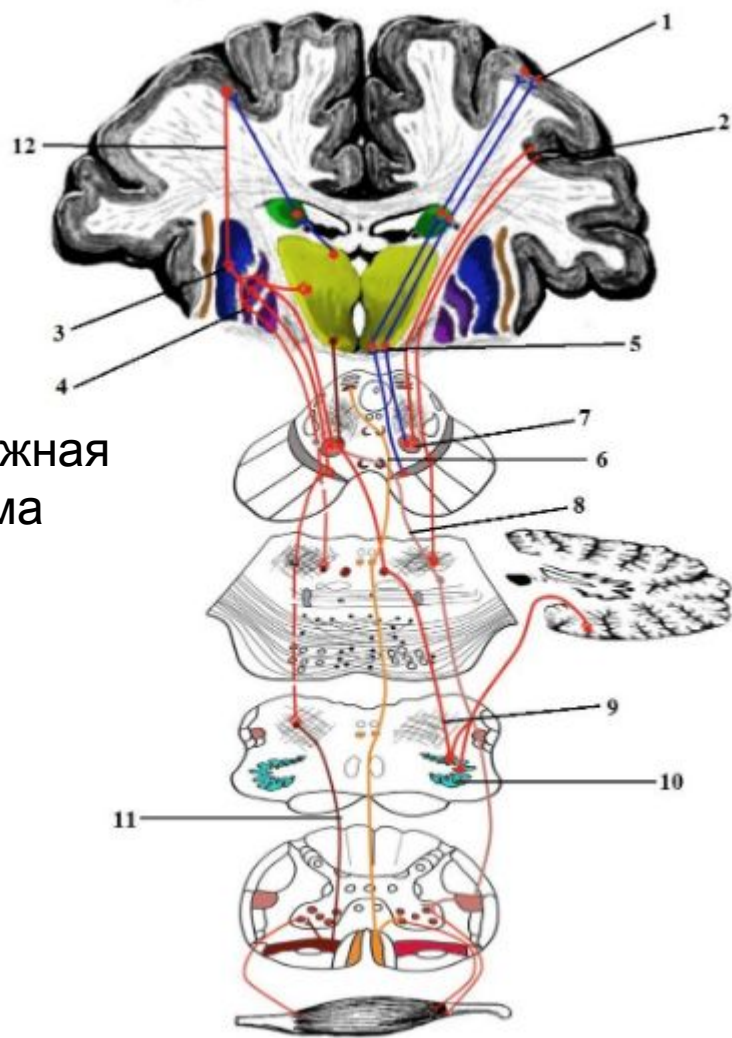
Nervus vestibulocochlearis 8

Nervus hypoglossus 12

Nervus trigeminus 5

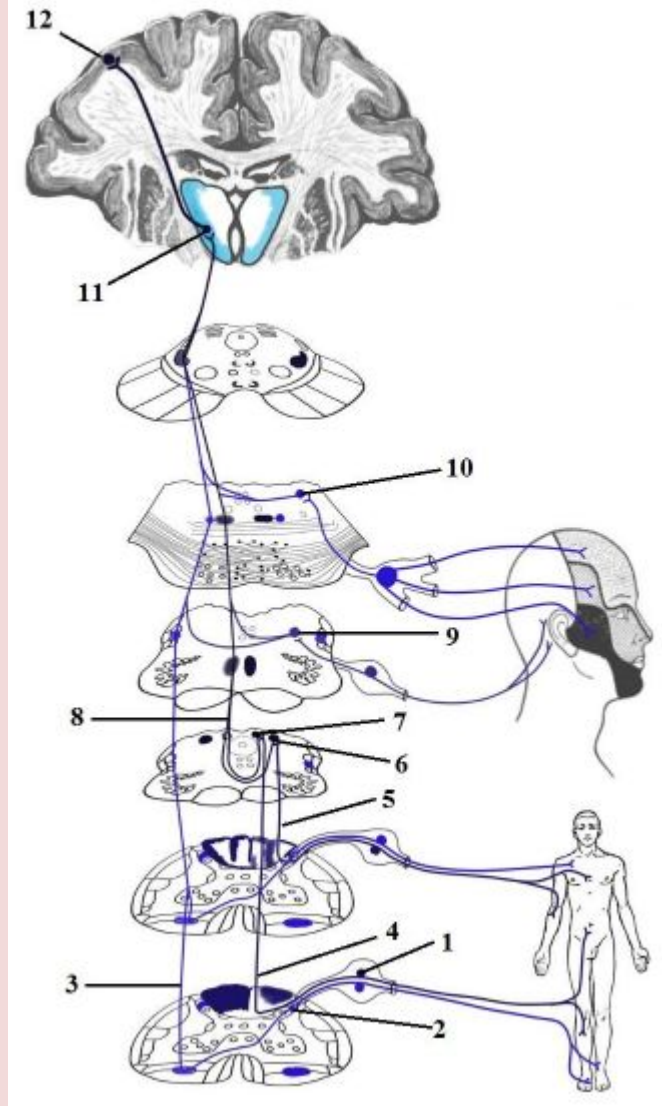
- tractus rubrospinalis 8
- tractus corticostriatalis 12
- Putamen 3
- nucleus ruber 7
- Thalamus 5
- globus pallidus 4
- lobus frontalis 1
- lobus temporalis 2
- tractus tectospinalis 6
- tractus thalamorubroolivarius 9
- Oliva 10
- tractus reticulospinalis 11

Сложная
схема



Сложная
схема

- nucleus solitarius 9
- nucleus pontinus nervi trigemini 10
- n.fasciculus cuneatus 7
- nucleus thalamus lateralis 11
- fasciculus gracilis 4
- nucleus thalamus lateralis et lobulus paracentralis 12
- ganglion spinale 1
- lemniscus medialis 8
- substantia gelatinosa 2
- tractus spinocerebellaris anterior 3
- fasciculus cuneatus 5
- n.fasciculus gracilis 6



Сложная
схема

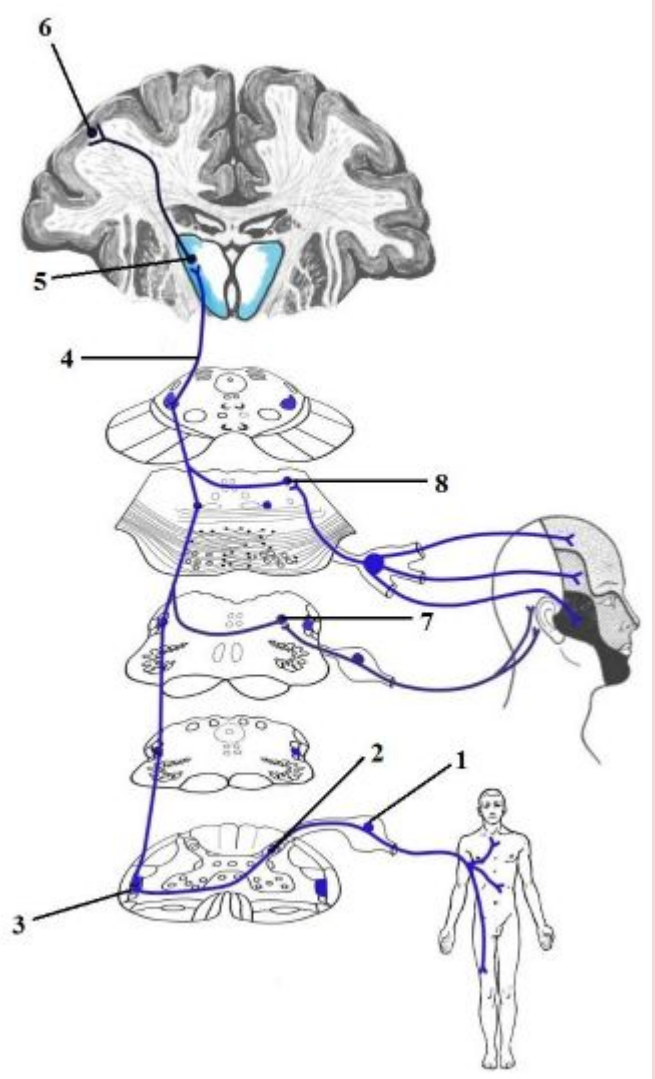
tractus spinothalamicus lateralis 3
ganglion spinale 1
nucleus proprius cornu posterior 2
lemniscus medialis 4

вентролатеральные ядра
таламуса 5

постцентральная извилина и
верхняя теменная доля 6

nucleus solitarius 7

nucleus sensorius principalis nervi
trigemini 8



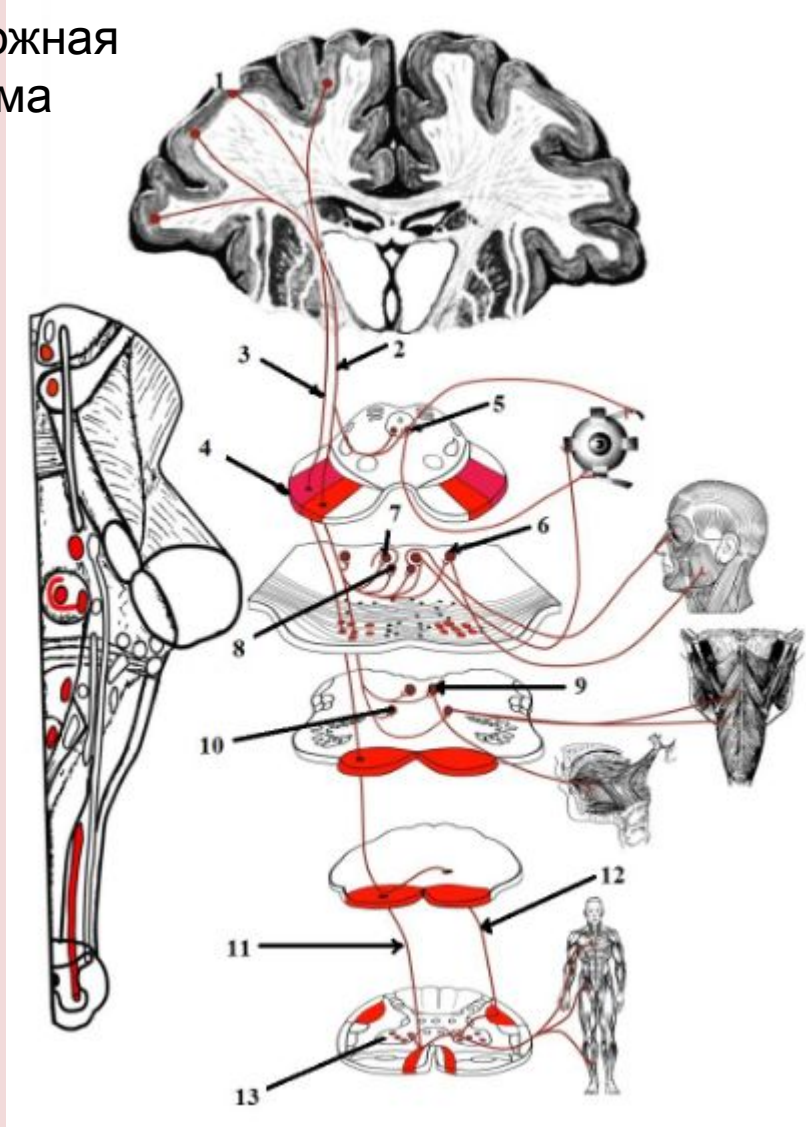
Сложная
схема

n. nervi abducens 7
tractus corticospinalis 3
n. nervi hypoglossi 9
pedunculi cerebri 4
n. motorius nervi trigemini 6
tractus corticonuclearis 2
tr. corticospinalis anterior 11
пирамидные нейроны 1

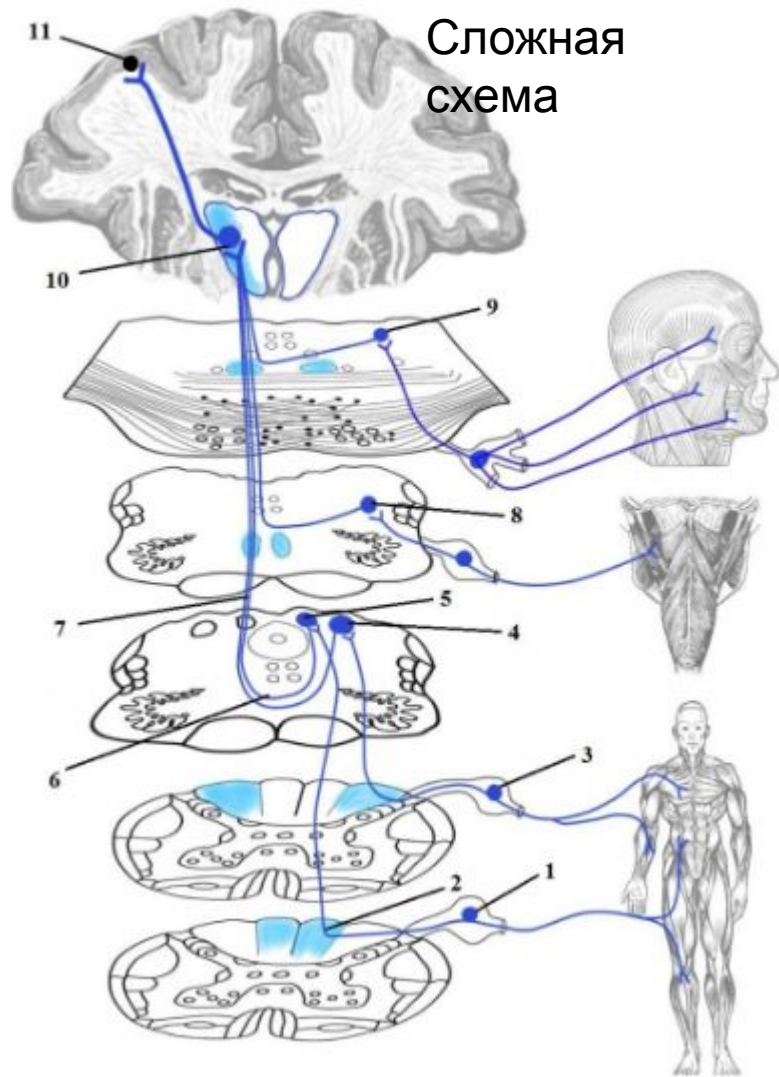
α-мотонейроны передних
рогов спинного мозга 13

nn. nervi oculomotorii et
trochlearis 5

n. motorius nervi facialis 8
nucleus ambiguus 10
tr. corticospinalis lateralis 12



Сложная
схема

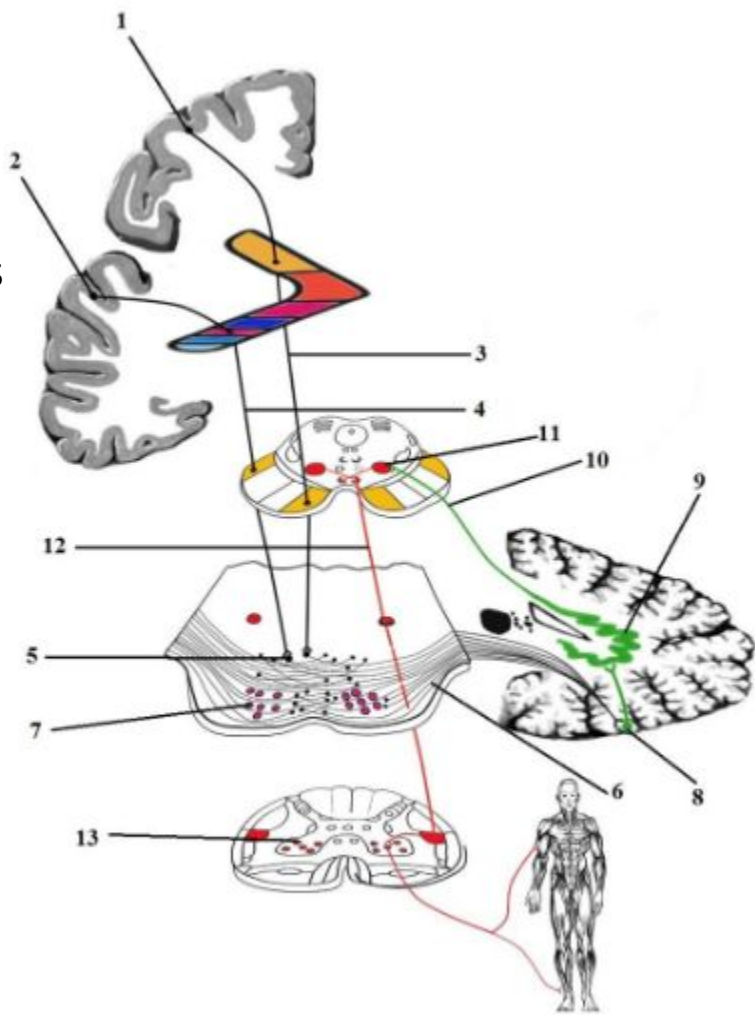


- lemniscus medialis 7
- ganglion spinale Th13-Co3 1
- nucleus mesencephalicus 9
- nucleus gracilis 5
- fasciculus gracilis 2
- gyrus precentralis 11
- ganglion spinale C1-Th12 3
- nucleus cuneatus 4
- decussatio lemniscorum 6
- nucleus solitarius 8
- nucleus ventrolaterales 10
- fasciculus cuneatus 12

10/12

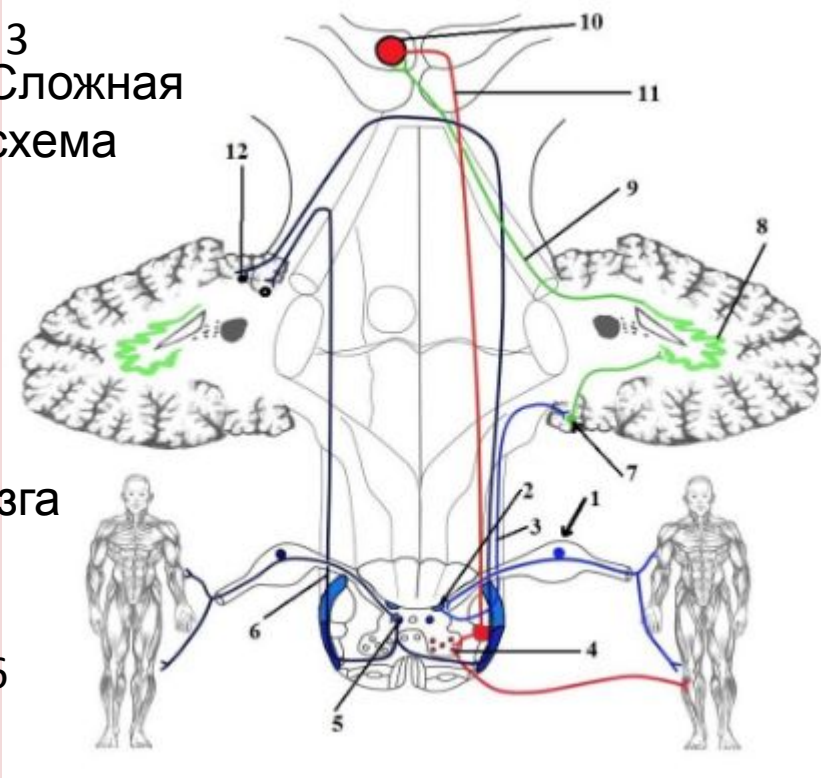
Сложная
схема

- tractus pyramidalis
- tractus rubrospinalis
- tractus occipito-temporo-pontinus
- nucleus pontinus
- nucleus dentatus
- tractus pontocerebellaris
- nucleus ruber
- tractus frontopontinus
- lobus temporalis
- lobus frontalis
- кора полушарий мозжечка
- tractus dentorubralis
- малые α -мотонейроны



- tr. spinocerebellaris posterior 3
- кора верхнего червя 7
- nucleus dentatus 8
- кора нижнего червя 12
- nucleus ruber 10
- tr. Dentorubralis 9
- ganglion spinale 1
- nucl. Thoracicus 2
- МОТОНЕЙРОНЫ СПИННОГО МОЗГА 4
- 4
- nucl. intermedio medialis 5
- tr. spinocerebellaris anterior 6
- tractus rubrospinalis 11

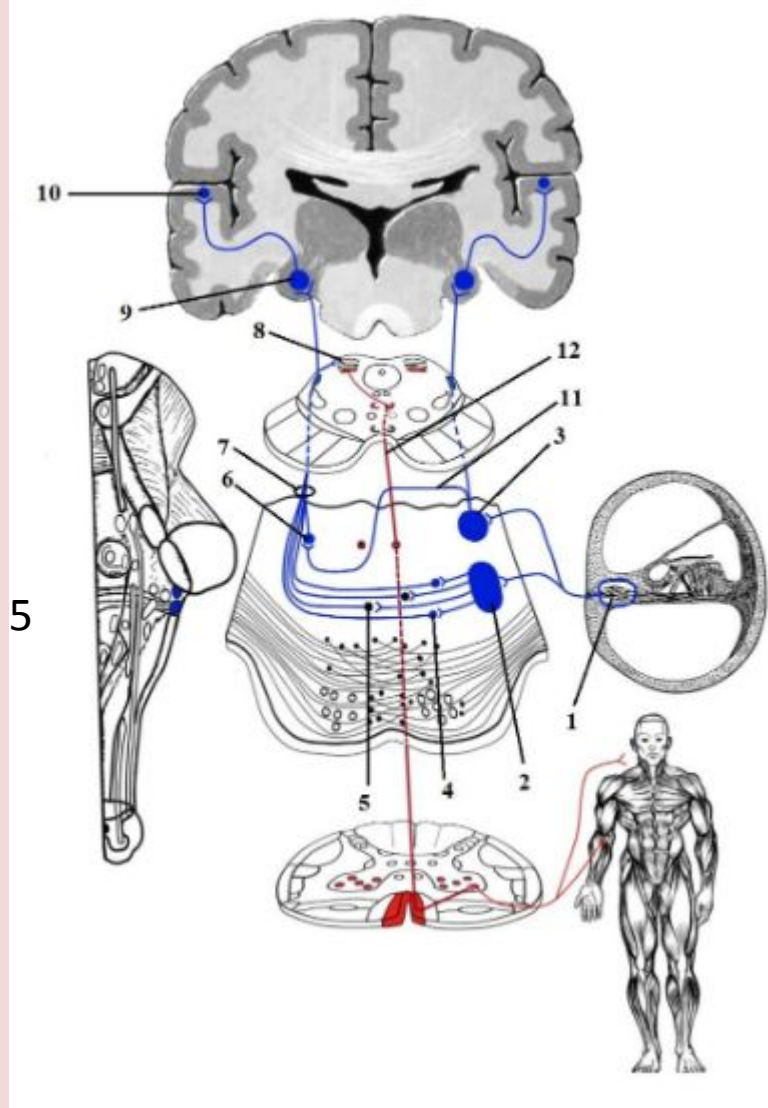
Сложная
схема

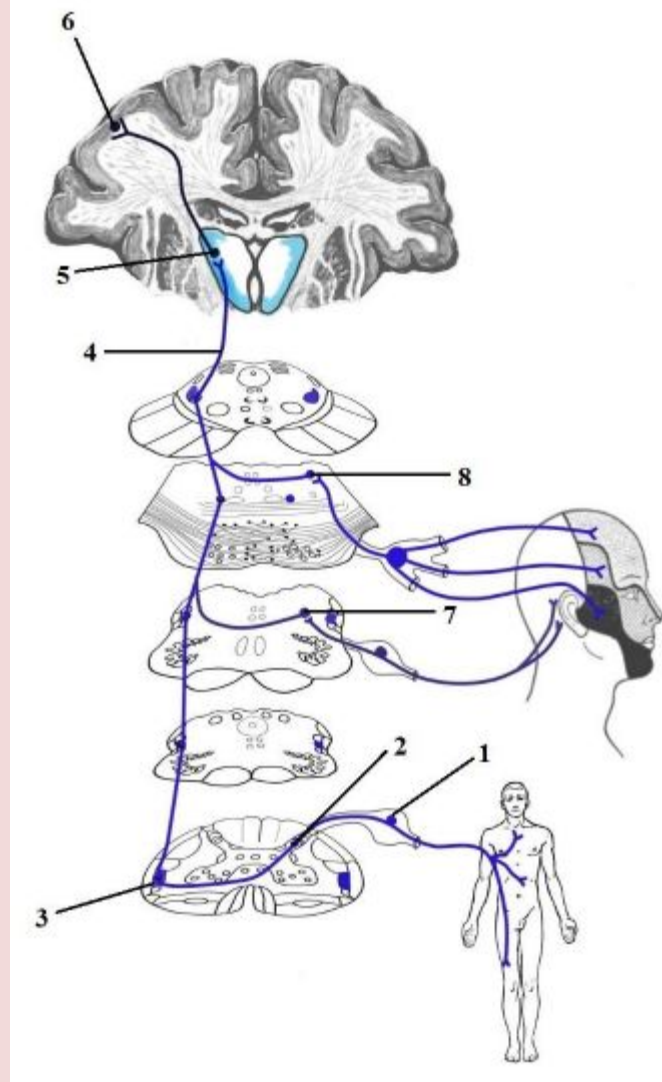


nucl.olivae superiores 4
lemniscus lateralis 7
nucleus colliculi inferioris 8

биполярные клетки
спирального узла улитки
внутреннего уха 1

stria medullaris (acustica) 11
nucl. n. cochleares ventralis 2
nucl. proprii corporis trapezoidei 5
corpus geniculatum mediale 9
gyrus temporalis superior 10
nucl. n. cochleares dorsalis 3
nucl. lemniscus lateralis 6
tractus tectospinalis 12





вентролатеральные ядра таламуса 5

lemniscus medialis 4

ganglion spinale 1

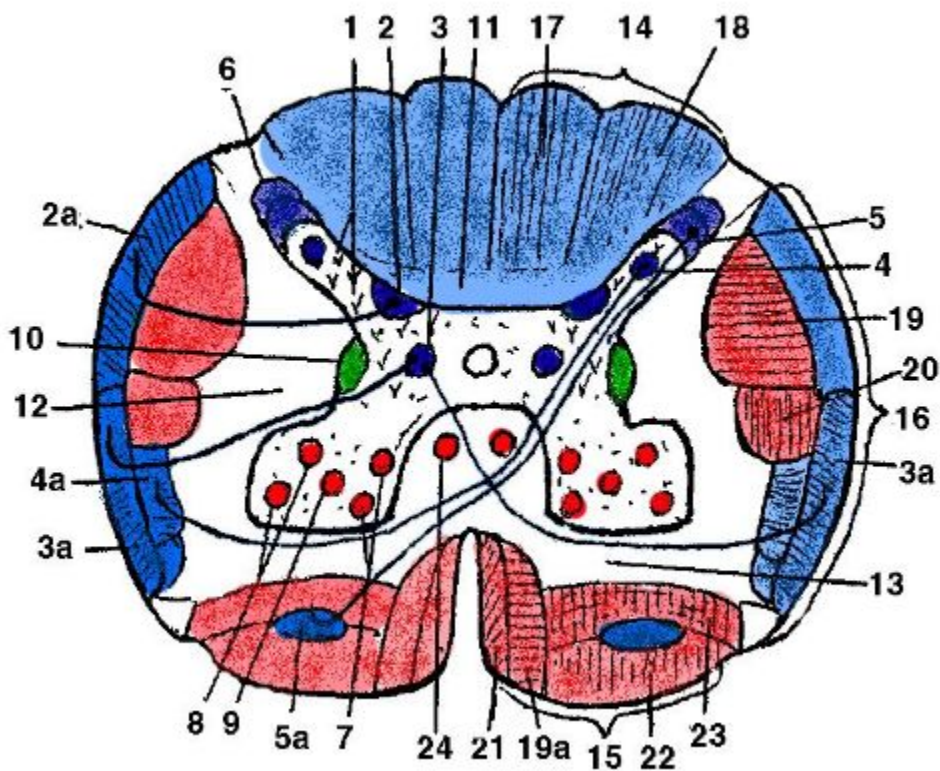
nucleus proprius cornu posterior 2

nucleus solitarius 7

tractus spinothalamicus lateralis 3

постцентральная извилина и верхняя теменная
долька 6

nucleus sensorius principalis nervi trigemini 8



fasciculi proprii funikulus posterior 11

cellulae dissiminatae 1

fasciculus cuniatus 18

tractus corticospinalis lateralis 19

латеральные передние и задние
двигательные ядра 8

tractus rubrospinalis 20

медиальные передние и задние
двигательные ядра 7

nucleus intermedio medialis 3

tractus spinothalamicus anterior 5A

zona spongiosa 6

tractus vestibulospinalis 22

tractus corticospinalis anterior 19A

substantia gelatinosa 5

fasciculi proprii funikulus lateralis 12

tractus tectospinalis 21

tractus spinocerebellaris posterior 2A

nucleus thoracicus 2

tractus spinocerebellaris anterior 3A

nucleus proprius cornu posterior 4

tractus spinothalamicus lateralis 4A

центральное двигательное ядро 9

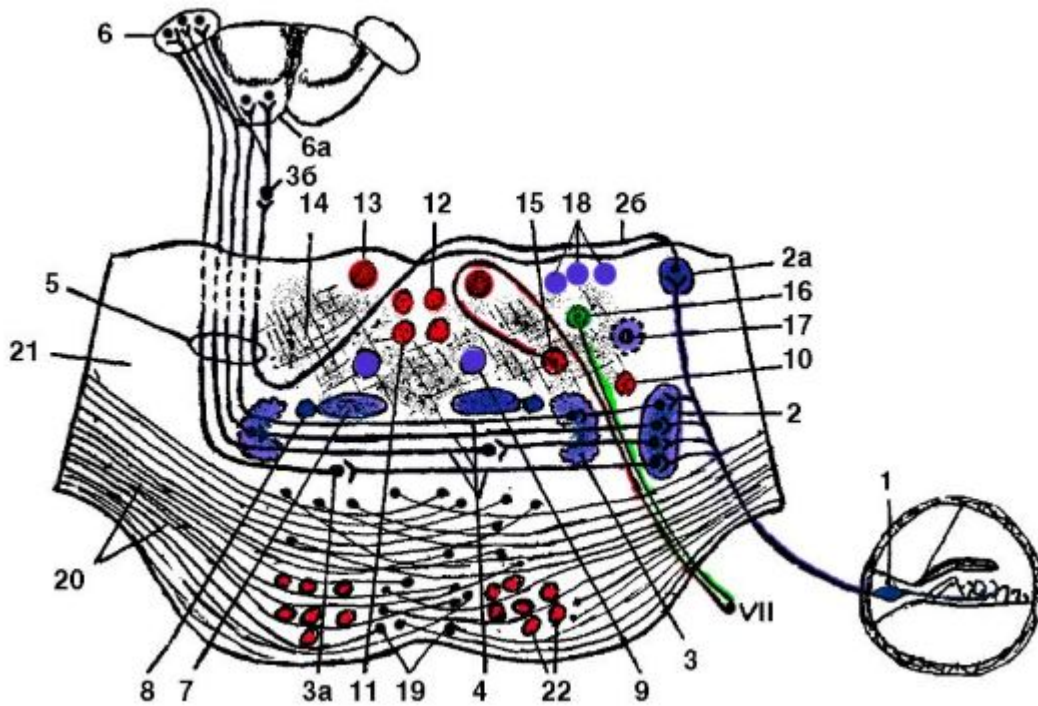
nucleus intermedio lateralis 10

fasciculi proprii funikulus anterior 13

fasciculus gracilis 17

tractus reticulospinalis 23

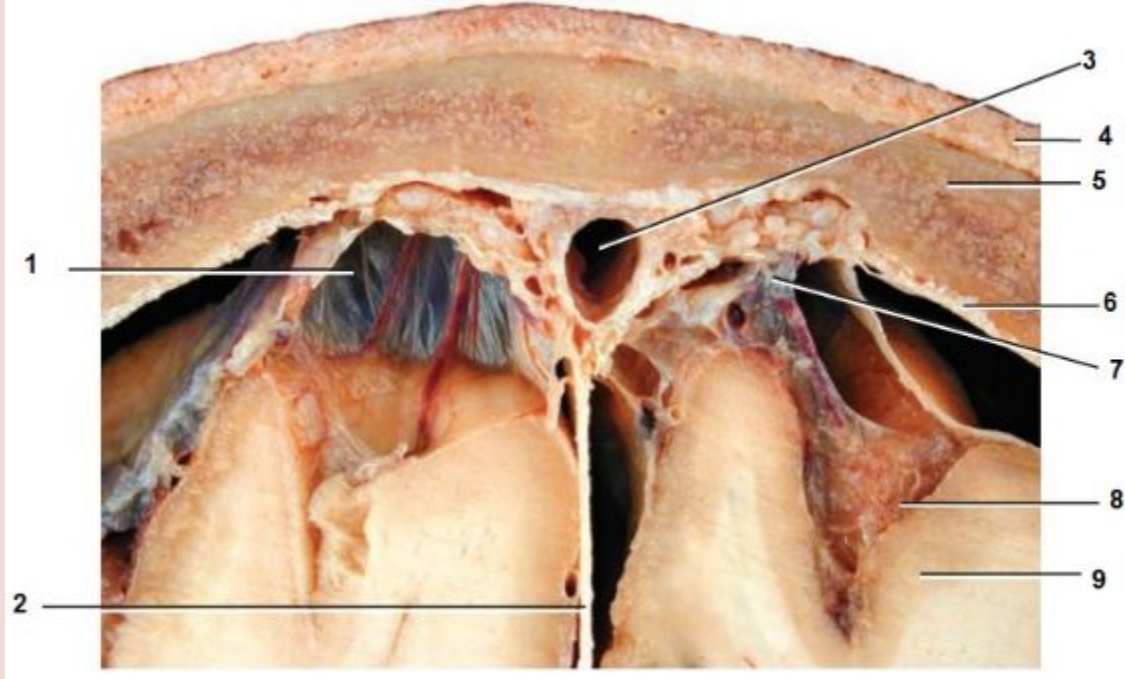
Fasciculus longitudinalis medialis 24



Lemniscus medialis 7
 corpus geniculatum mediale 6
 tr. Thalamo-rubroolivaris 9
 nucl. n. cochleares ventralis 2
 tractus rubrospinalis 10
 nuclei proprii pontis 19
 nucl. proprii corporis trapezoidei 3A
 tr. spinocerebellaris anterior 8
 nucl. n. abducentis 13
 stria medullaris (acustica) 2B
 corpus trapezoidei 4
 pedunculi cerebellares medii 21
 tr. Tectospinalis 11
 nucl. olivae superiores 3

биполярные клетки спирального узла улитки внутреннего уха 1

nucl. n. cochleares dorsalis 2A
 lemniscus lateralis 5
 colliculi inferius 6A
 fasciculus longitudinalis medialis 12
 nucl. salivatorius superior 16
 nucl. tr. spinalis nervi trigemini 17
 nuclei nervi vestibularis 18
 tr. Pontocerebellaris 20
 tractus pyramidalis 22
 formatio reticularis 14



spatium subarachnoidale 1

falx cerebri 2.

sinus sagittalis superior 3.

Dermis 4

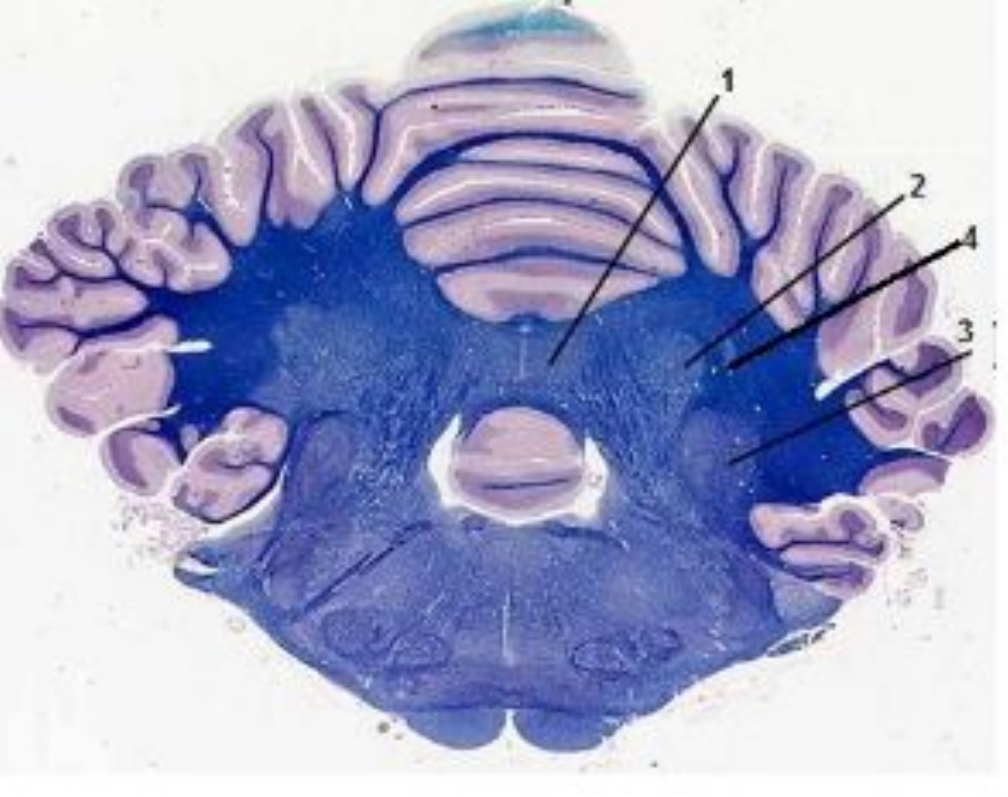
os parietále 5.

dura mater encephali 6

arachnoidea mater encephali 7

pia mater encephali 8.

Cortex cerebri 9.



- nucleus dentatus 3
- nucleus fastigii 1
- nucleus emboliformis 2
- nucleus globosus 4



бронх
и

bronchus principalis sinister 3

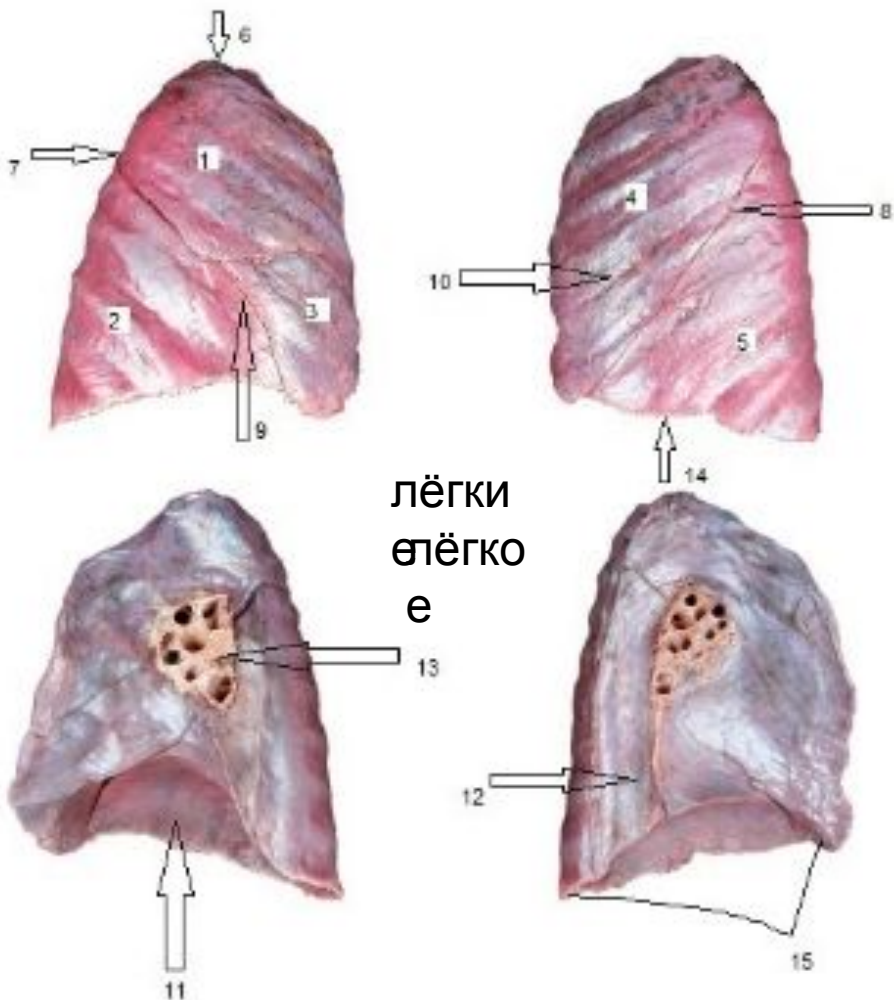
bronchus lobaris 4

bronchus principalis dexter 2

Trachea 1

bifurcatio tracheae 7

bronchus segmentalis 5

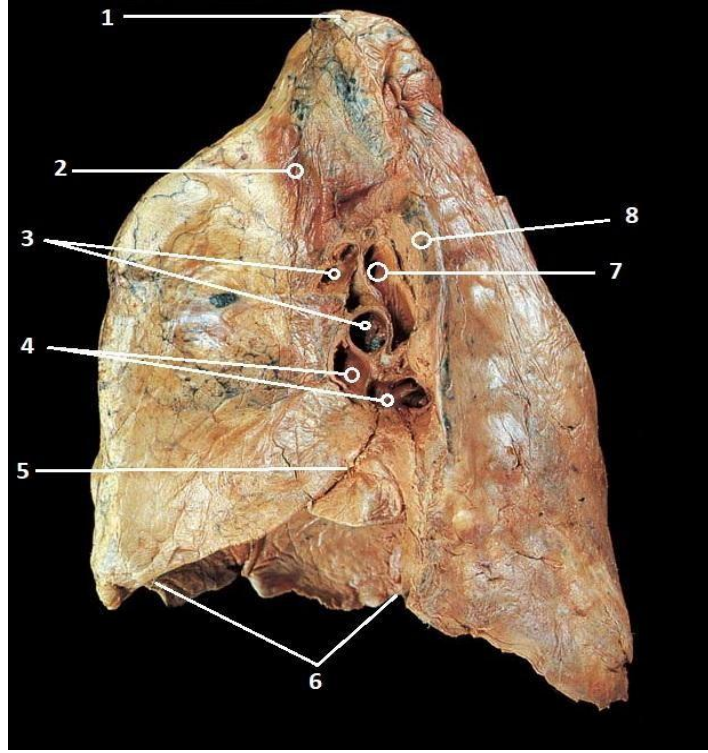


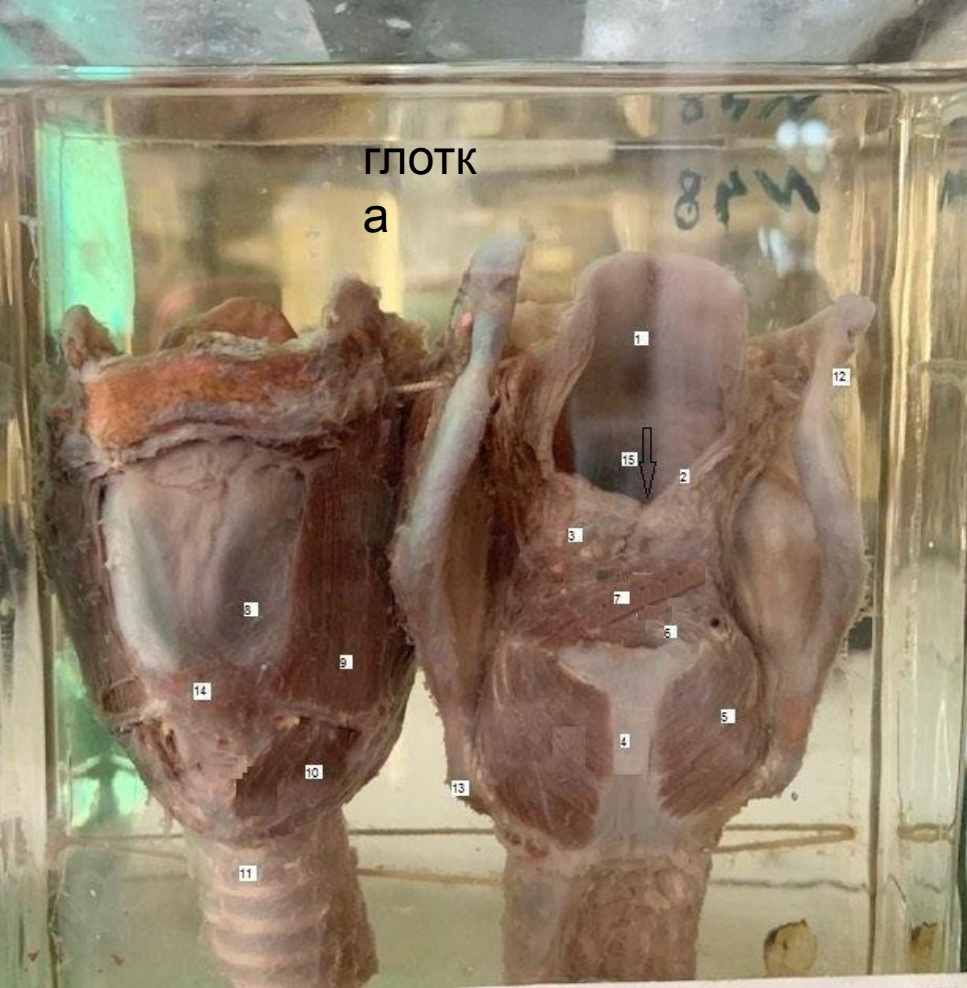лѐжки
стѐгко
е

- lobus inferior pulmonis sinistri 5
- fissura obliqua pulmonis sinistri 8
- lobus superior pulmonis dextri 1
- facies costalis pulmonis 10
- lobus superior pulmonis sinistri 4
- facies diaphragmatica pulmonis 11
- lobus medius pulmonis dextri 3
- hilus pulmonis 13
- facies medialis pulmonis 12
- fissura horizontalis pulmonis dextri 7
- lobus inferior pulmonis dextri 2
- apex pulmonis 6
- fissura obliqua pulmonis dextri 9
- margo inferior pulmonis 14
- basis pulmonis 15

ЛЕГКО

1	Apex pulmonis
2	Impressio vena cavae superior
3	A.pulmonales dexter
4	v.Pulmonales dexter
5	Fissura obliqua
6	Facies diaphragmatica
7	Bronchus principales dexter
8	Impressio venae azygos





cornu superior 12

m. arytenoideus obliquus 7

Trachea 11

cornu inferior 13

cartilago arytaenoidea 3

conus elasticus 14

cartilago thyreoidea 8

m. Hyrohyoideus 9

Epiglottis 1

Plica aryepiglottica 2

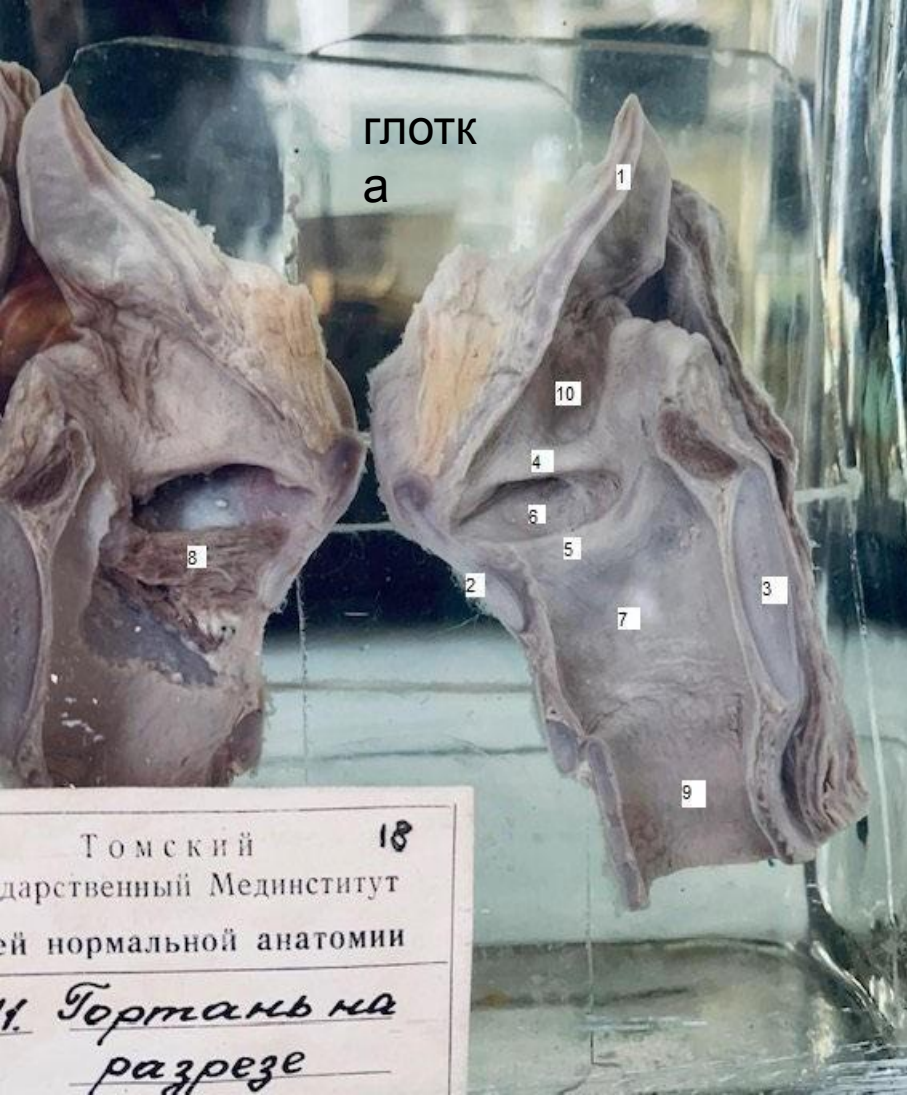cartilago cricoidea 4

m. cricoarytenoideus posterior 5

m. arytenoideus transversus 6

m. Crirothyroideus 10

aditis laryngis 15

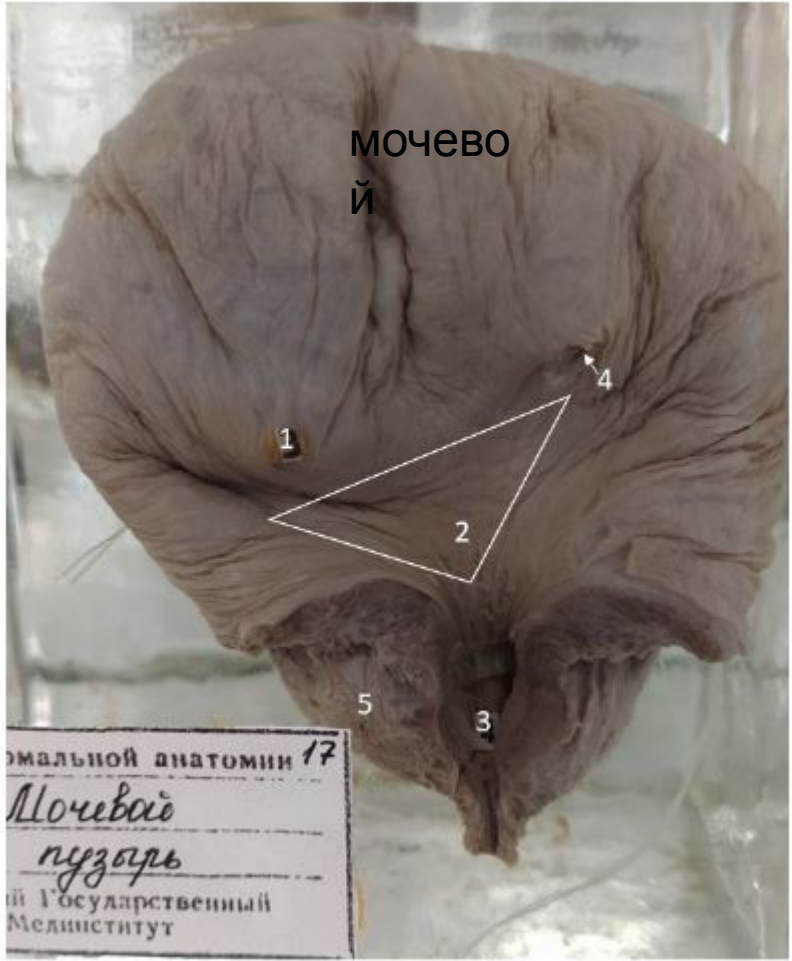


ГЛОТКА
а

- Trachea 9
- cartilago thyreoidea 2
- ventriculus laryngis 6
- (cavitas infraglottica 7
- m. Vocalis 8
- plica vestibularis 4
- cartilago cricoidea 3
- Epiglottis 1
- plica vocalis 5
- vestibulum laryngis 10

Томский 18
дарственный Мединститут
ей нормальной анатомии
И. Горюнов на
разрезе

МОЧЕВО
Й



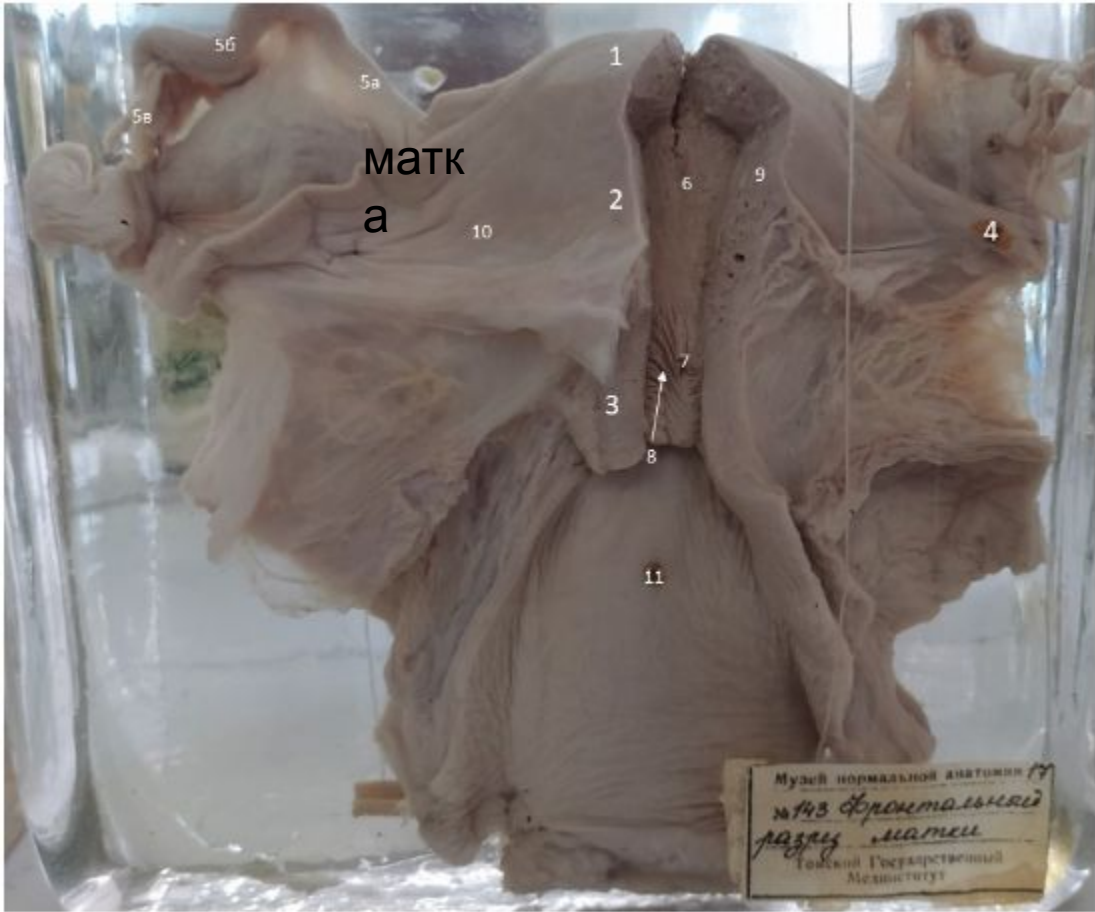
Prostata 5

Tunica mucosa 1

Trigonum vesicae 2

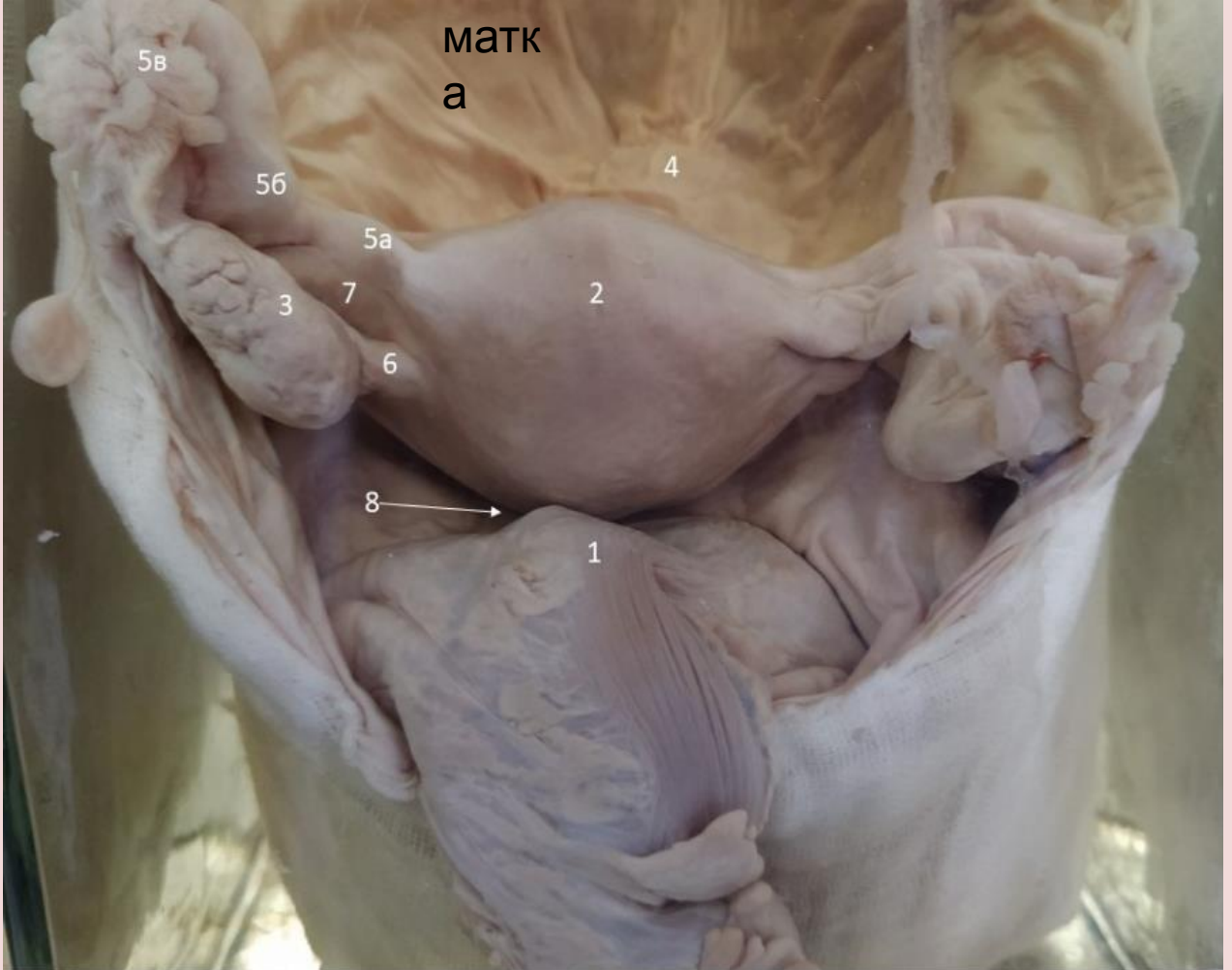Ostium ureteris 4

Ostium urethrae internum, urethra masculina 3



матка

- Lig. teres uteri 4
- Cervix uteri 3
- Myometrium 9
- VAGINA 11
- TUBA UTERINA, ampulla 5Б
- Plicae palmatae 8
- TUBA UTERINA, isthmus 5A
- TUBA UTERINA, infundibulum 5B
- Fundus uteri 1
- Corpus uteri 2
- Cavitas uteri 6
- Canalis cervicis uteri 7
- Lig. latum uteri 10



UTERUS 2

Lig. latum uteri 7

TUBA UTERINA, infundibulum 5B

VESICA URINARIA 4

TUBA UTERINA, isthmus 5A

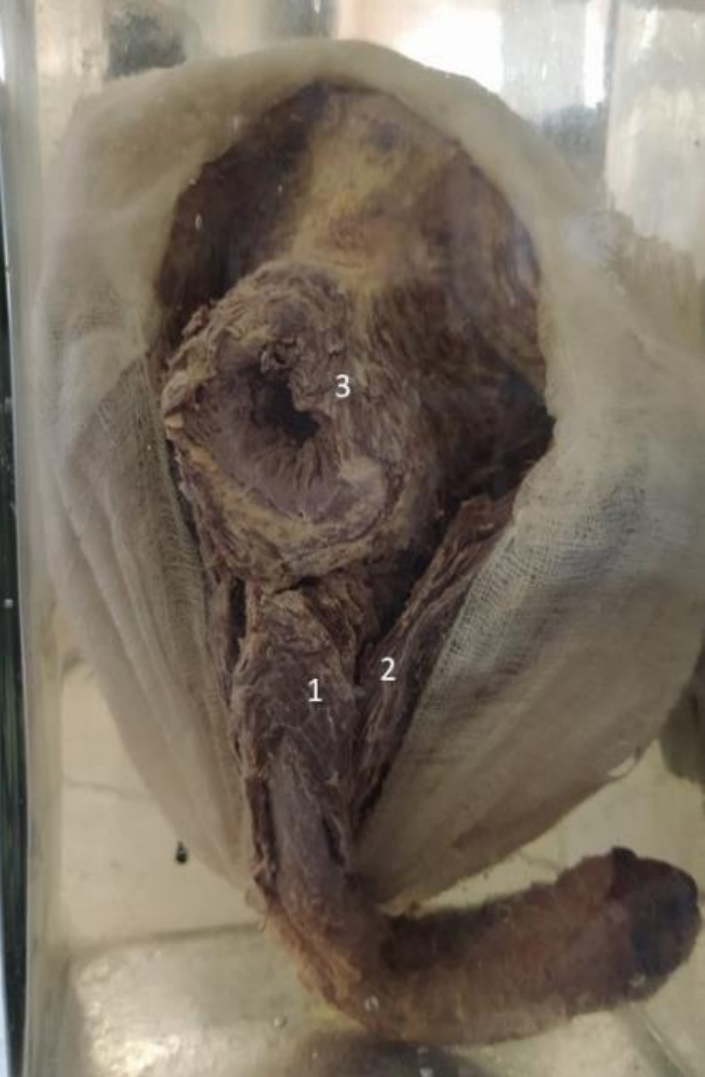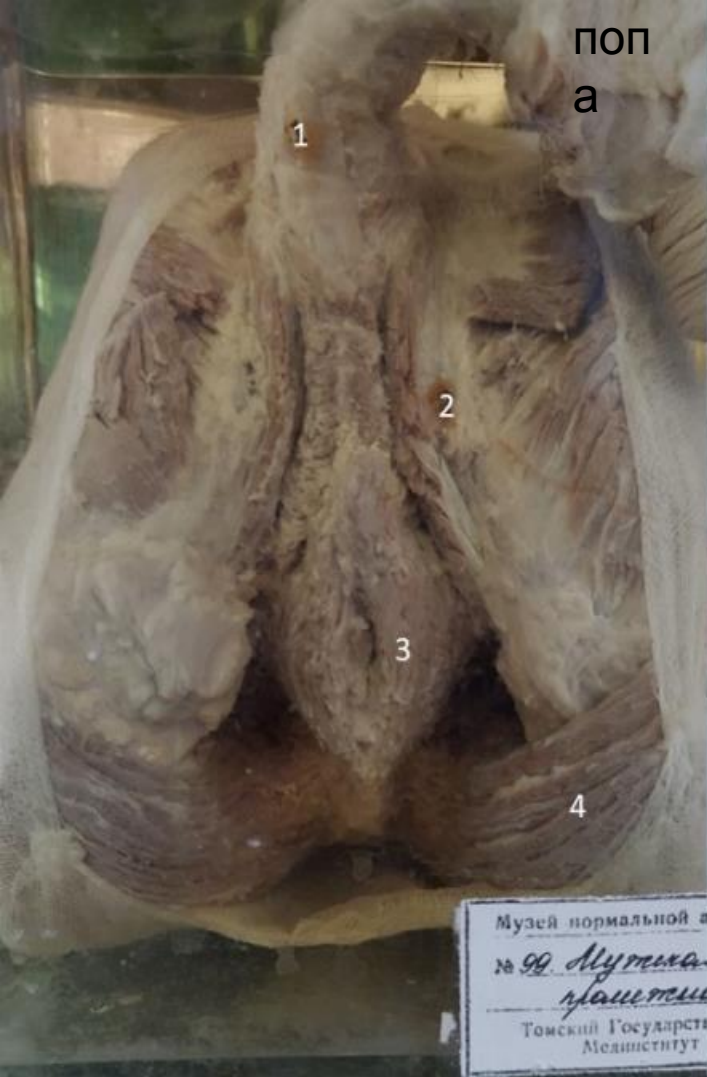excavatio rectouterina 8

OVARIUM 3

TUBA UTERINA, ampulla 5B

RECTUM 1

Lig. ovarii proprium 6

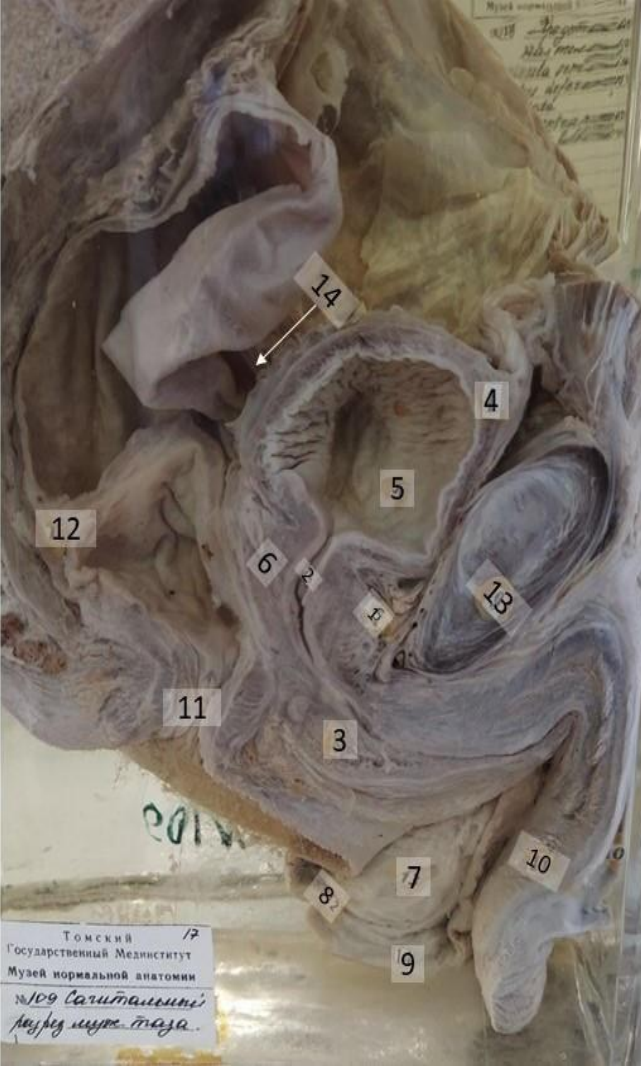

M. Ischiocavernosus 2

M. Bulbospongiosus 1

M. sphincter ani externus (levator ani) 3

m. gluteus maximus 4



PROSTATA 6

Excavatio rectovesicalis 14

Symphysis pubica 13

VESICA URINARIA, tunica muscularis 4

SCROTUM 9

Anus 11

Bulbus penis 3

PENIS 10

GLANDULA BULBOURETHRALIS 1

TESTIS 7

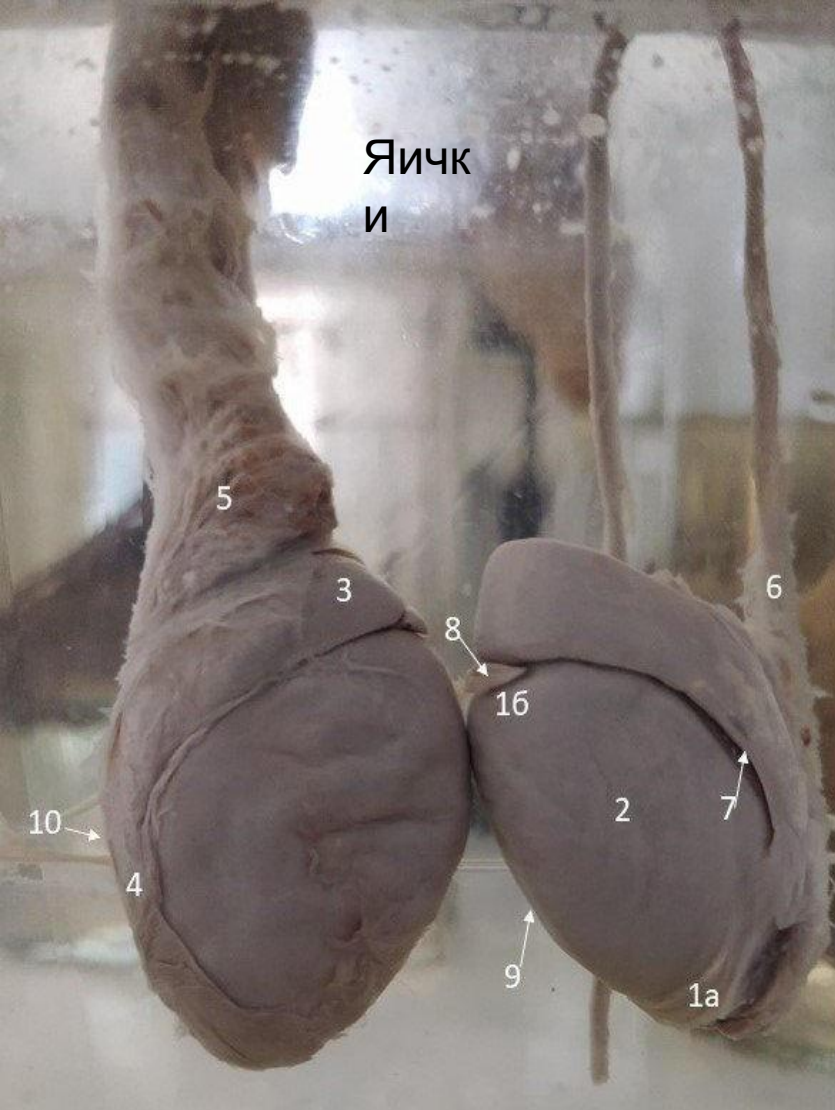RECTUM 12

VESICA URINARIA, tunica mucosa 5

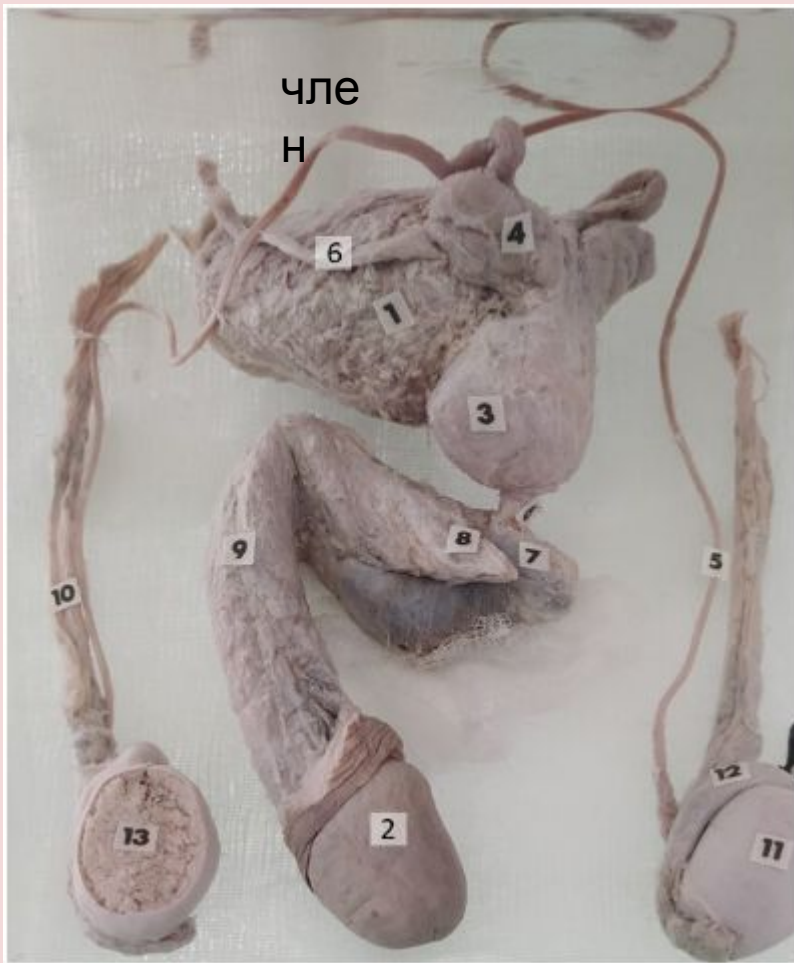Ureter, pars prostatica 2

Testis, tunica serosa 8

Яичк
и



- Sinus epididymidis 7
- Corpus epididymidis 4
- Caput epididymidis 3
- Facies lateralis 2
- Margo anterior 9
- DUCTUS DEFERENS 6
- Polus superior 1Б
- Polus inferior 1А
- FUNICULUS SPERMATICUS 5
- Margo posterior 10
- Appendix epididymidis 8



FUNICULUS SPERMATICUS 10

PROSTATA 3

Corpus penis 9

GLANDULA SEMINALIS 4

Parenchyma testis 13

Ureter 6

Glans penis 2

TESTIS 11

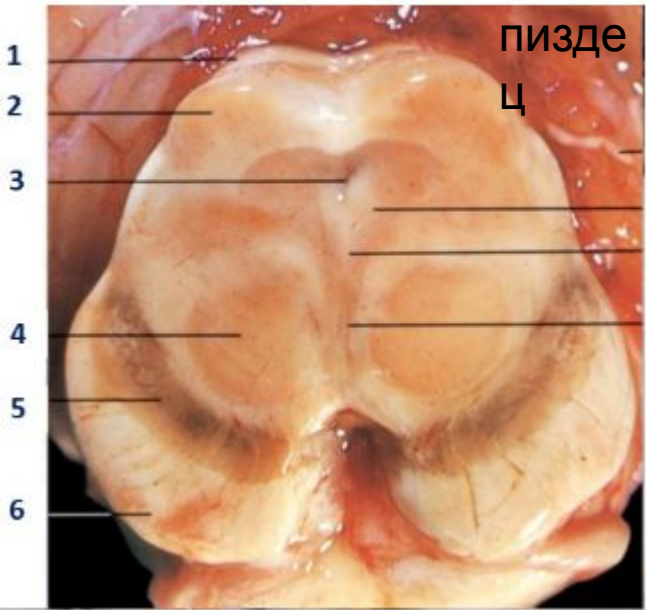
Corpus cavernosum penis, crus penis 8

DUCTUS DEFERENS 5

EPIDIDYMIS 12

VESICA URINARIA 1

Bulbus penis 7



Colliculi superiores 1

Nucleus ruber 4

Aqueductus cerebri 3

Pedunculi cerebri, basis 6

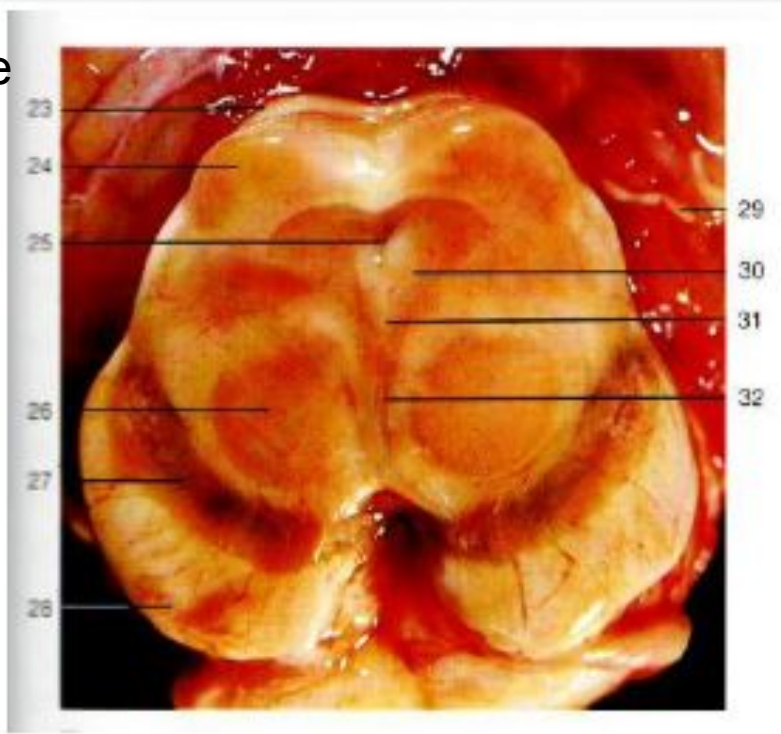
Colliculi inferiores 2

Substantia nigra 5

пизде

Ц

- substantia nigra 27
- nucl. nervus oculomotorius 31
- substantia grisea centralis 30
- nucleus ruber 26
- aquaeductus cerebri 25
- colliculus superior 23
- colliculus inferior 24
- pedunculi cerebri 28
- radix nervus oculomotorius 32



Препарат ПОЗВОНОЧНИК

Pars thoracica 12

Pars lumbalis 5

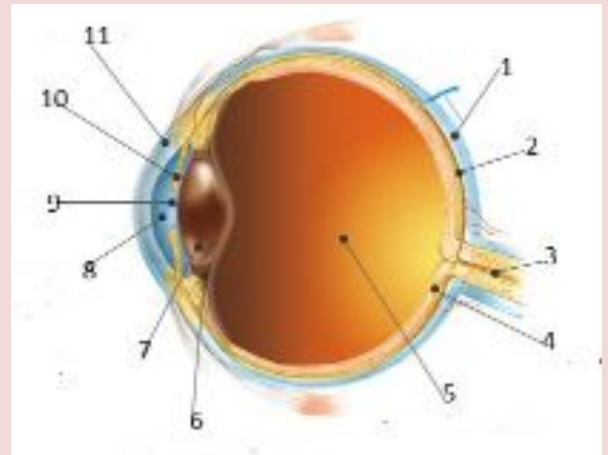
Pars sacralis 5

Pars cervicalis 8

Pars coccygea 3

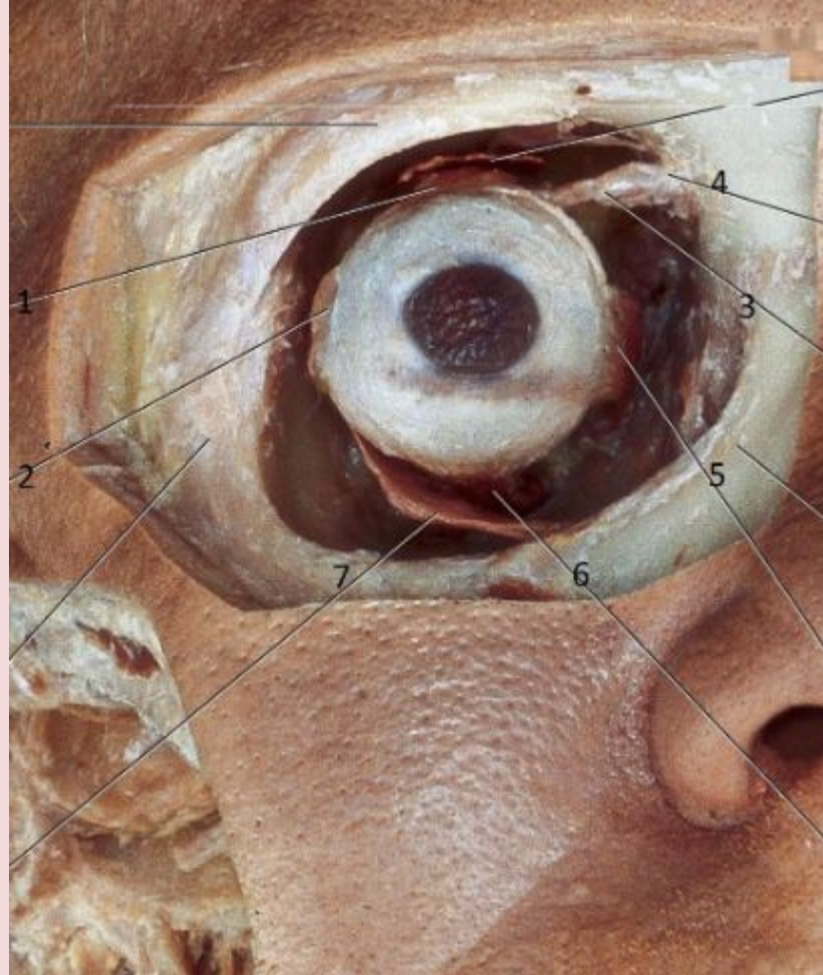


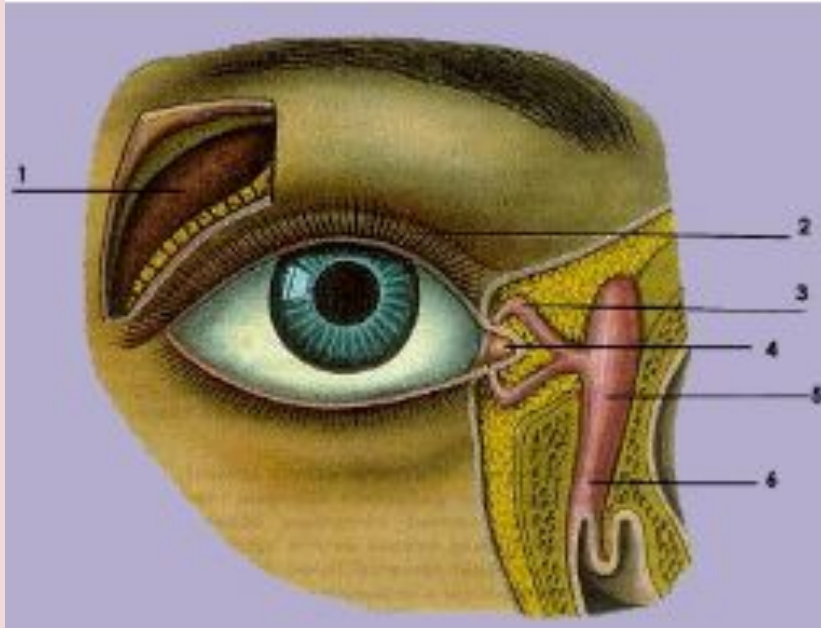
передняя камера глаза 8
Склера 1
Роговица 11
Зрачок 9
стекловидное тело 5
ресничный поясok 6
Радужка 10
Хрусталик 7
Сетчатка 4
сосудистая оболочка 2
зрительный нерв 3



m. rectus medialis 5
m. obliquus superior 3
m. rectus lateralis 2
m. rectus inferior 6
m. rectus superior 1
m. obliquus inferior 7
Trochlea 4

Глаз
мышцы





верхний слезный каналец (canaliculus lacrimalis superior)

3

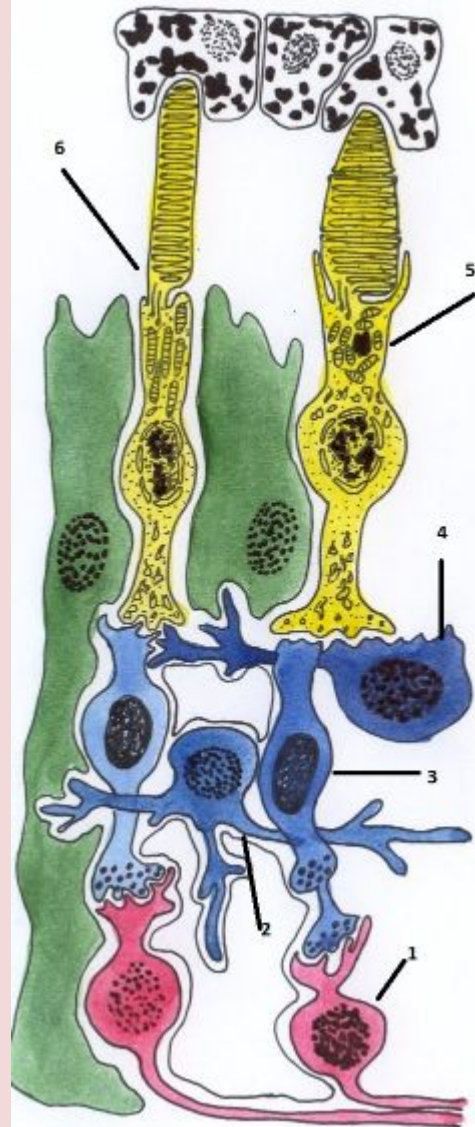
слезная железа (glandula lacrimalis) 1

слезный мешок (saccus lacrimalis) 5

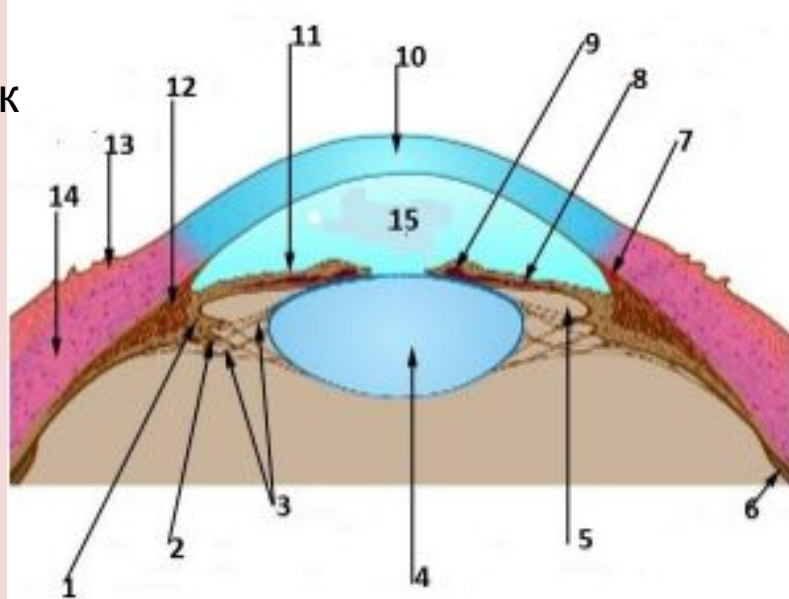
слезное озеро (lacus lacrimalis) 4

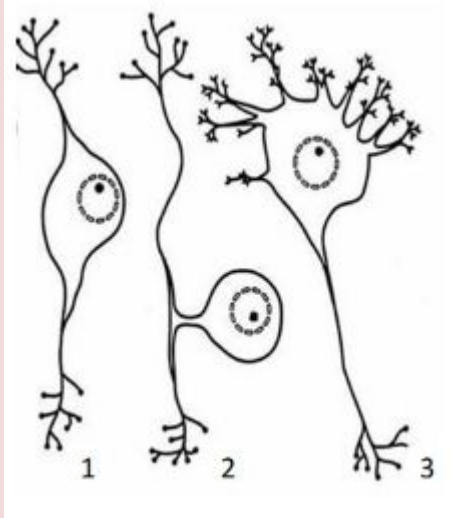
носослезный проток (ductus nasolacrimalis) 6

палочковые фоторецепторы 6
биполярные нейроны 3
колбочковые фоторецепторы 5
5
амакринные нейроны 2
горизонтальные нейроны 4
ганглионарные нейроны 1



Роговица 10
мышца расширяющая зрачок
8
Склера 14
венозный синус склеры 7
зубчатая линия 6
задняя камера глаза 5
Хрусталик 4
ресничная мышца 12
ресничные отростки 2
ресничный поясок 3
ресничное тело 1
Радужка 11
передняя камера глаза 15
мышца суживающая зрачок 9
Конъюнктивa 13

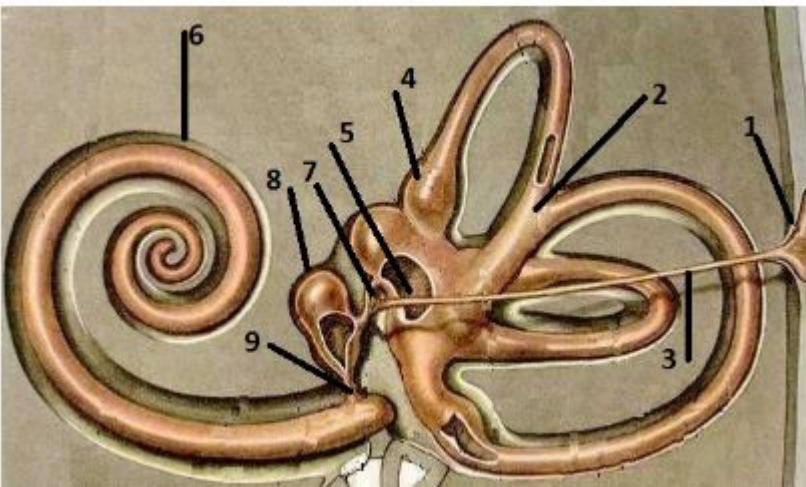




Биполярный нейрон 1

Мультиполярный нейрон 3

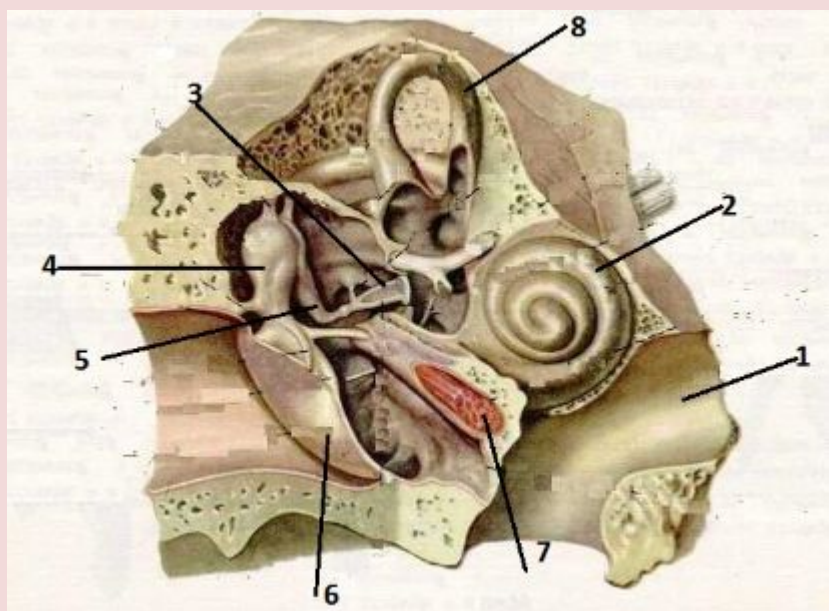
Псевдоуниполярный нейрон 2

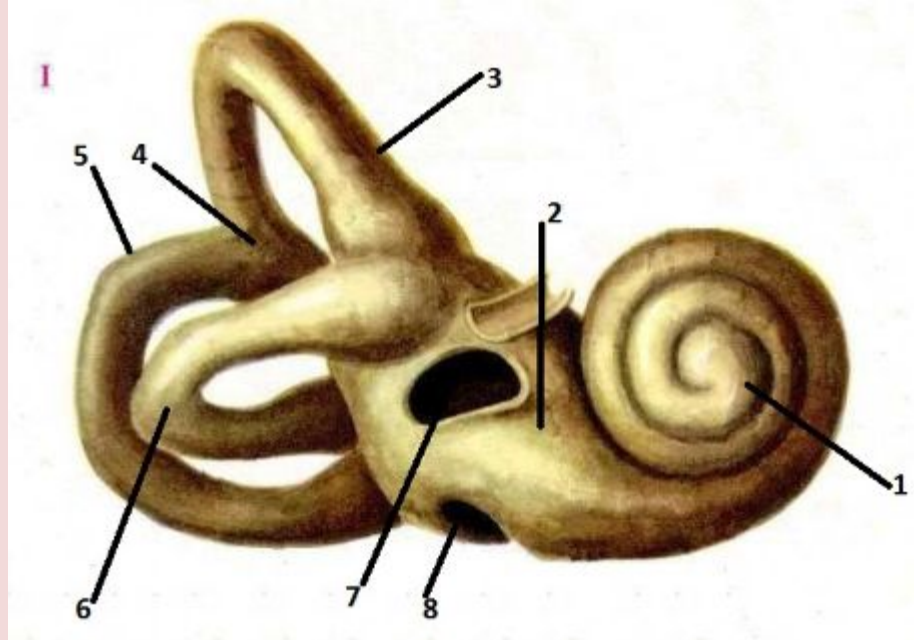


Ухо
улитка

- saccus endolymphaticus 1
- Utriculus 5
- crus membranacea commune 2
- ampula membranacea anterior 4
- ductus endolymphaticus 3
- ductus cochlearis 6
- Sacculus 8
- ductus utriculosaccularis 7
- ductus reuniens 9

Наковальня 5
мышца напрягающая 7
барabanную перепонку 2
Улитка 2
слуховая труба 1
барabanная перепонка 6
Молоточек 4
Стремечко 3
полукружный канал 8





Улитка 1

окно улитки 8

задний полукружный канал 5

передний полукружный канал 3

окно преддверия 7

Преддверие 2

латеральный полукружный канал 6

общая ножка переднего и заднего

каналов 4

crus breve incudis 1

basis stapedis 8

articulatio incudomallearis 10

processus lenticularis 9

manubrium mallei 7

caput mallei 3

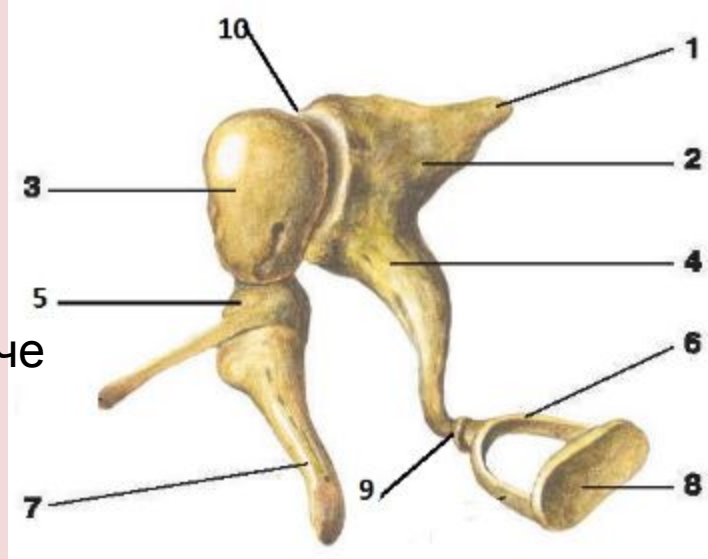
crus stapedis 6

Incus 2

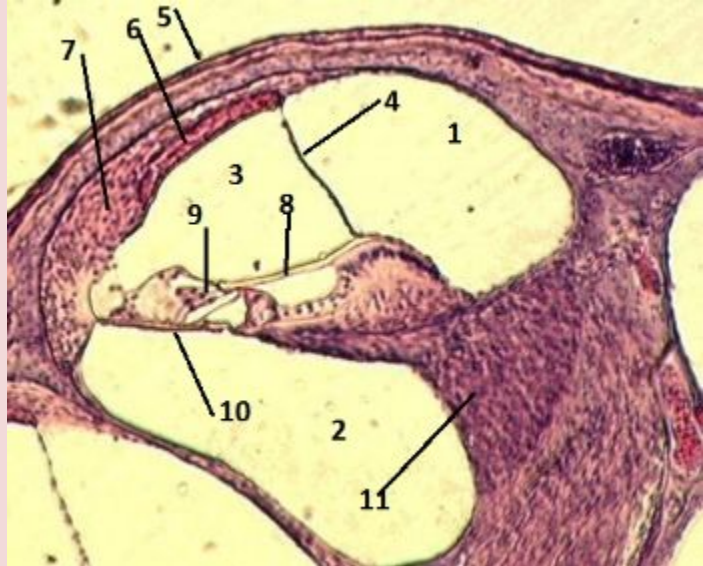
collum mallei 5

crus longum incudis 4

МОЛОТОЧЕ
К



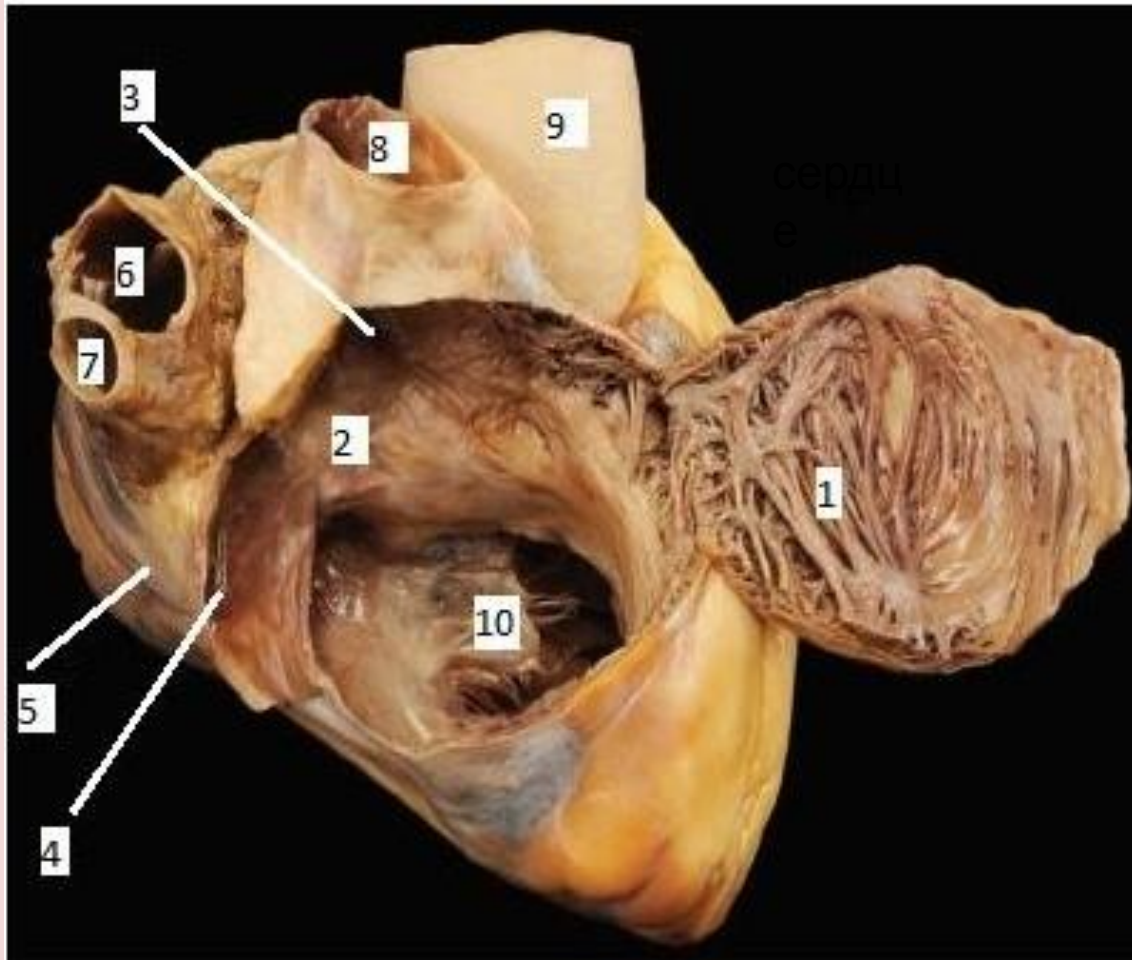
базиллярная пластинка 10
спиральный ганглий 11
покровная мембрана 8
сосудистая полоска 6
вестибулярная лестница
улитки 1
барабанная лестница улитки 2
спиральный орган 9
костный лабиринт 5



латеральная стенка
улиткового протока 7

преддверная стенка
улиткового протока 4

улитковый проток 3



auricula dextra 1

septum interatriale 2

ostium sinus coronarius 4

fossa ovalis 3

sinus coronarius 5

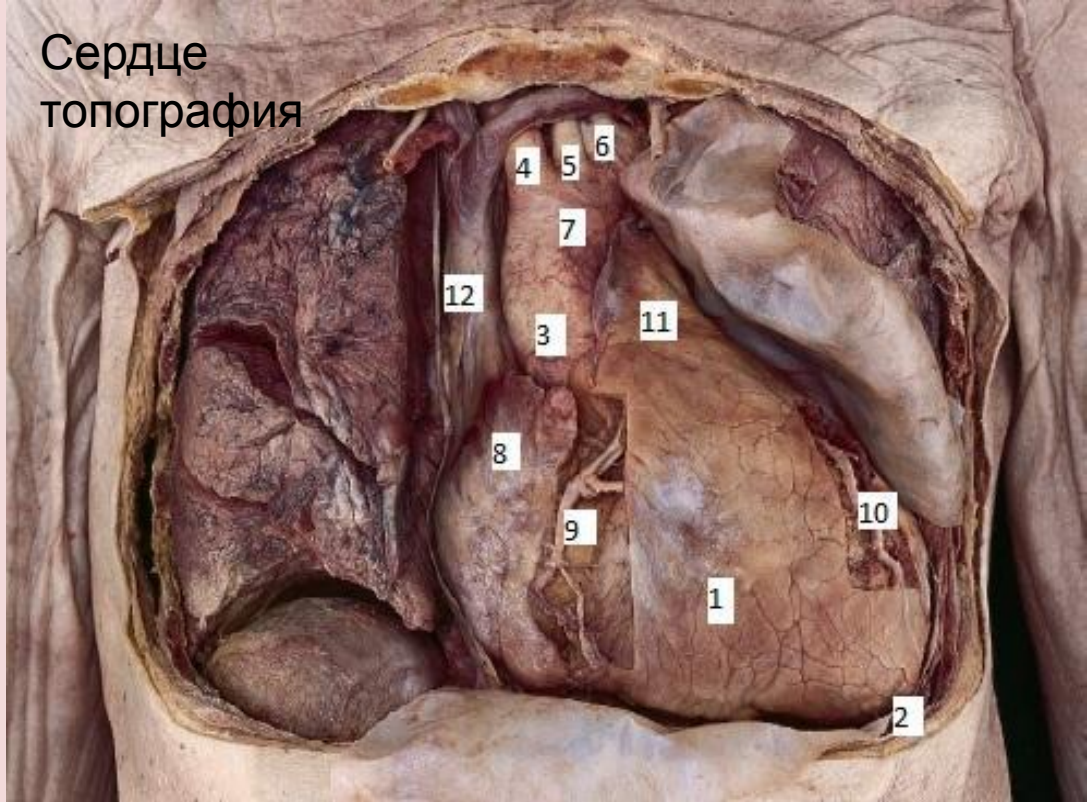
ostium vena pulmonalis dextra superior 6

ostium vena pulmonalis dextra inferior 7

vena cava superior 8

Aorta 9

Сердце топография



facies sternocostalis cordis 1

apex cordis 2

pars ascendens aortae 3

truncus brachiocephalicus 4

arteria carotis communis sinistra 5

arteria subclavia sinistra 6

arcus aortae 7

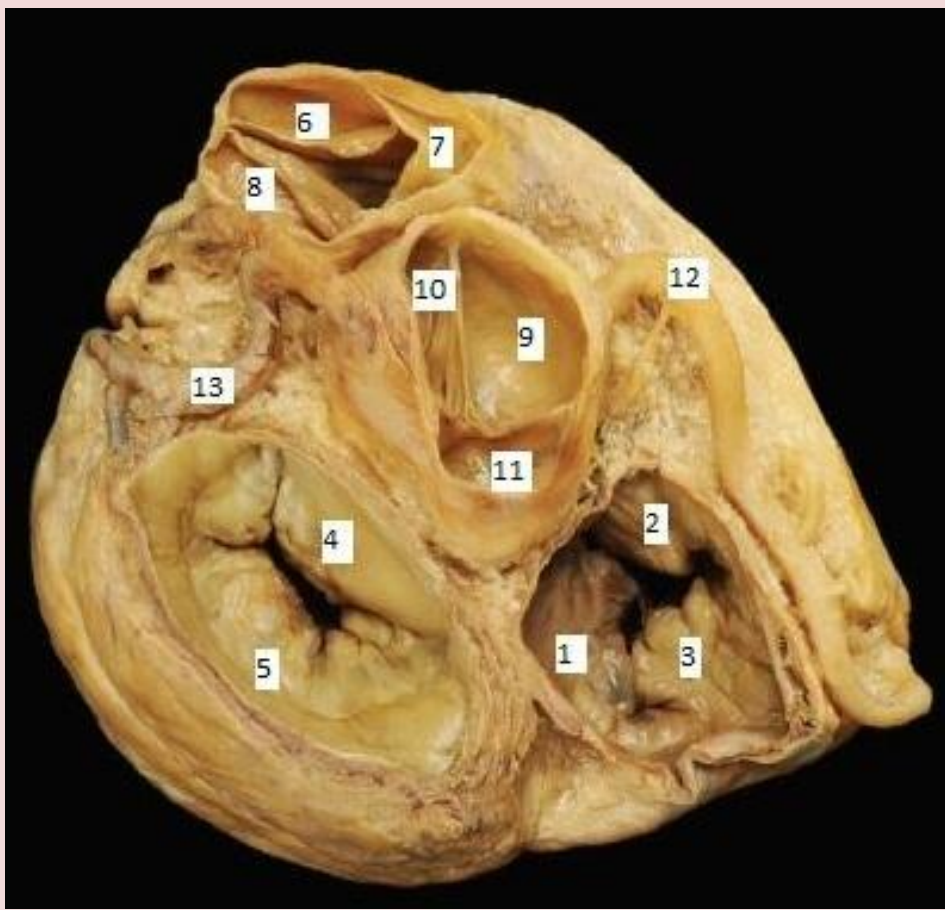
auricula dextra 8

arteria coronaria dextra 9

arteria coronaria sinistra 10

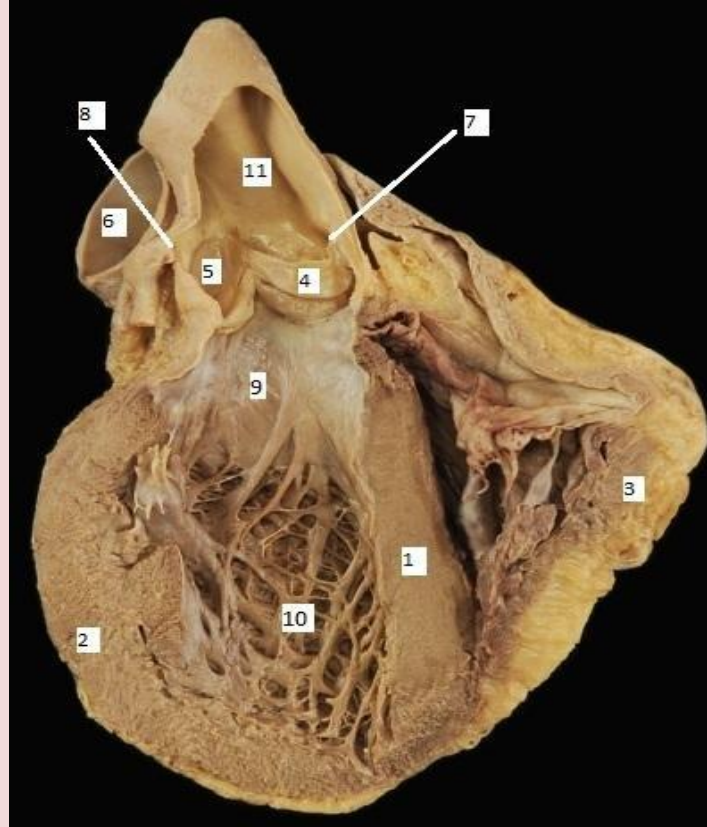
truncus pulmonalis 11

vena cava superior 12



- cuspid septalis valvae atrioventricularis dextrae 1
cuspid anterior valvae atrioventricularis dextrae 2
cuspid posterior valvae atrioventricularis dextrae 3
cuspid anterior valvae atrioventricularis sinistrae 4
cuspid posterior valvae atrioventricularis sinistrae 5
valvula semilunaris anterior valvae trunci pulmonalis 6
valvula semilunaris dextra valvae trunci pulmonalis 7
valvula semilunaris sinistra valvae trunci pulmonalis 8
valvula semilunaris dextra valvae aortae 9
valvula semilunaris sinistra valvae aortae 10
valvula semilunaris posterior valvae aortae 11
arteria coronaria dextra 12
arteria coronaria sinistra 13

сердце



septum interventriculare 1

ventriculus sinister 2

ventriculus dexter 3

valvula semilunaris dextra valvae aortae 4

valvula semilunaris sinistra valvae aortae 5

truncus pulmonalis 6

ostium arteria coronaria dextra 7

ostium arteria coronaria sinistra 8

conus arteriosus 9

trabeculae carneae 10

Aorta 11

ostium venae cavae inferioris 1

vena cava superior 2

ventriculus dexter 3

atrium dexter 4

atrium sinister 5

vena cordis magna 6

сердц
е

ramus circumflexus arteriae
coronariae Sinistrae 7

arteria coronaria dextra 8

ramus interventricularis posterior
arteriae coronaria dextra 9

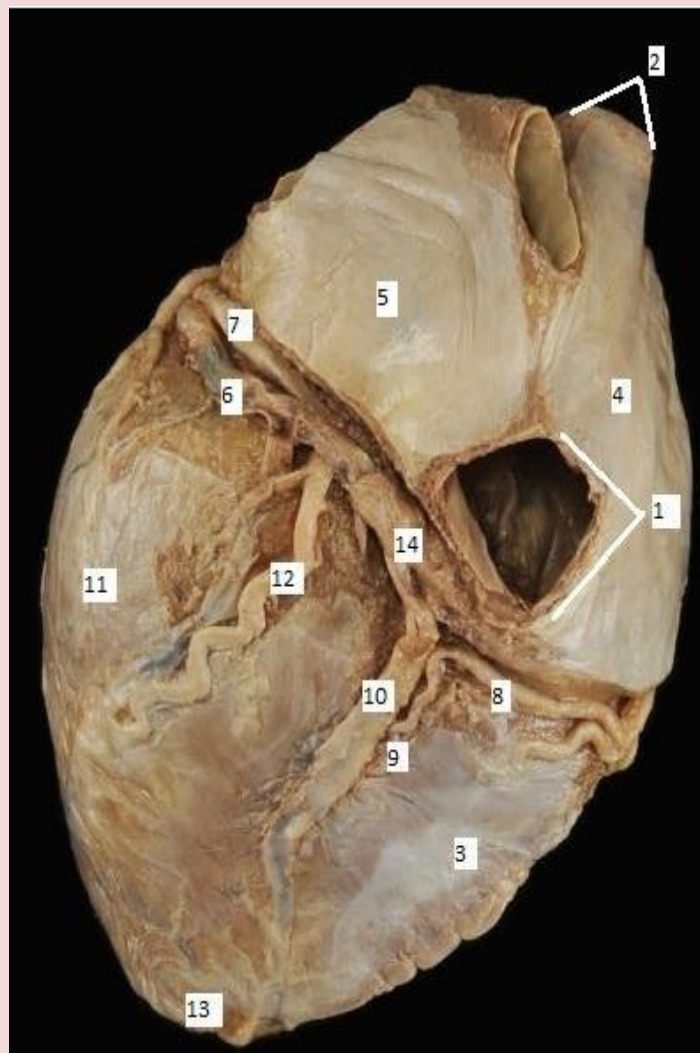
vena cordis media 10

ventriculus sinister cordis 11

vena ventriculi sinistri posterior 12

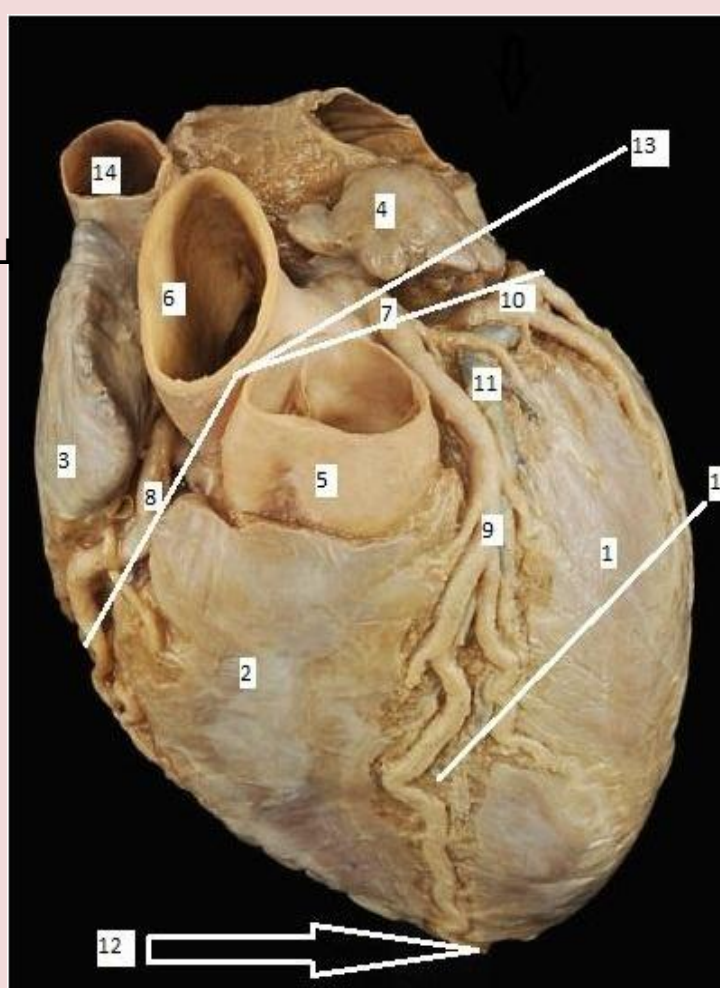
apex cordis 13

sinus coronarius cordis 14

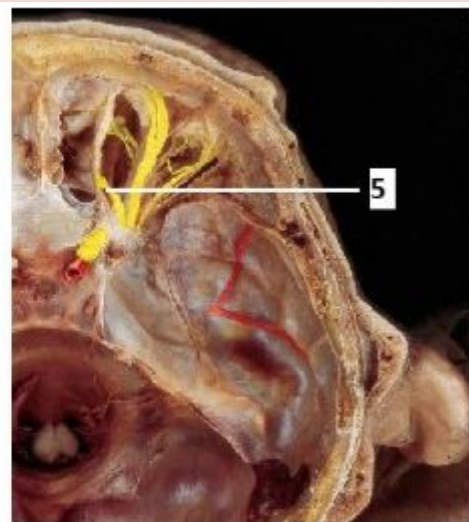
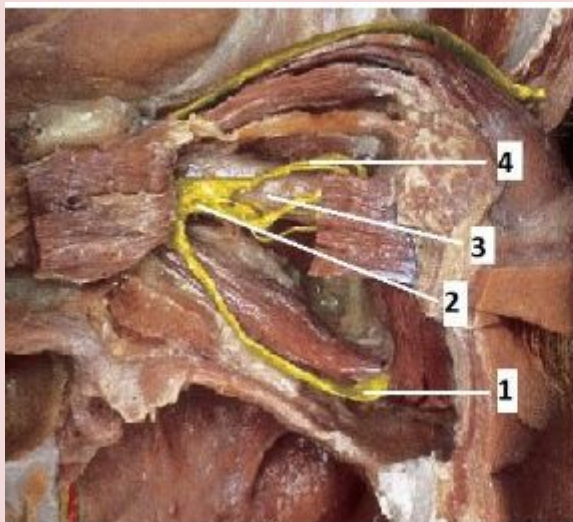


- ventriculus sinister cordis 1
 ventriculus dexter cordis 2
 auricula dextra 3
 auricula sinistra 4
 truncus pulmonalis 5
 Aorta 6
 arteria coronaria sinistra 7
 arteria coronaria dextra 8
 ramus interventricularis anterior 9
 ramus circumflexus 10
 vena cordis magna 11
 apex cordis 12
 basis cordis 13
 vena cava superior 14
 sulcus interventricularis anterior 15

сердце



Нервы
глаз



Глаз

нервы

- ramus inferior nervi oculomotorii 1
- nervus opticus 3
- nervus trochlearis 5
- ganglion ciliare 2
- ramus superior nervi oculomotorii 4

Нервы

глаз

nervus ethmoidalis anterior 1

nervus trochlearis 6

nervus supratrochlearis 2

nervus lacrimalis 4

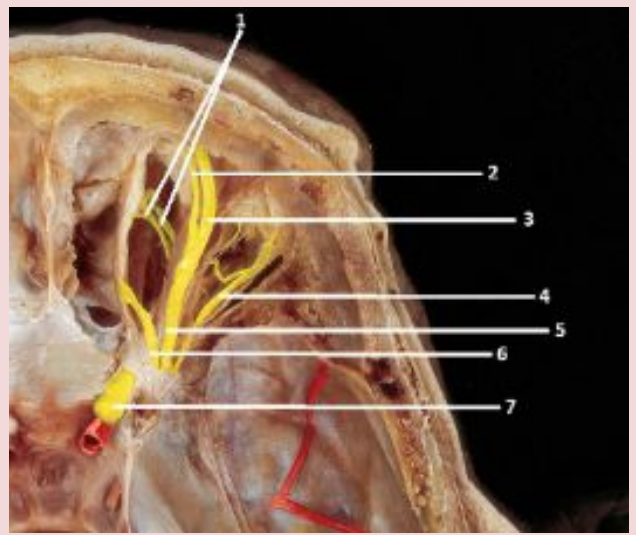
nervus supraorbitalis 3

nervus frontalis 5

nervus opticus 7

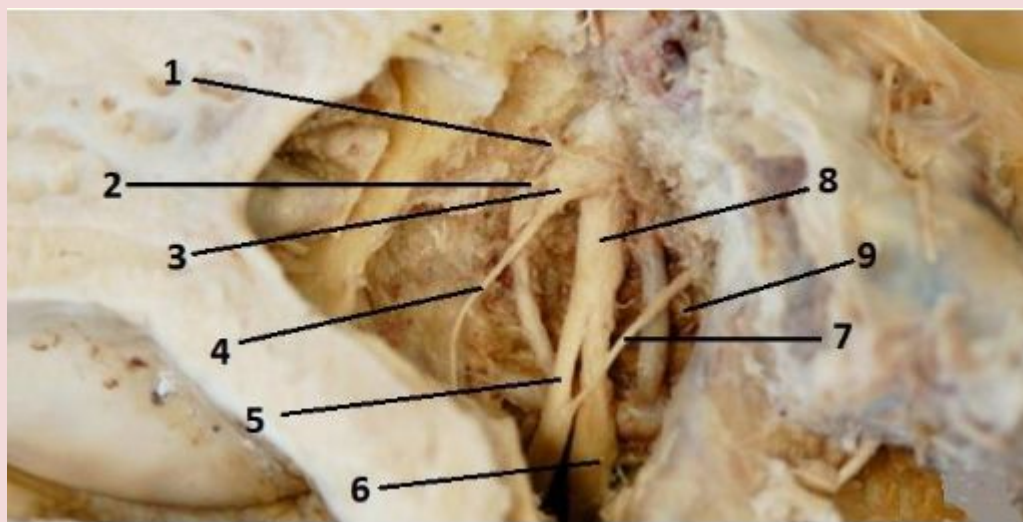
Глаз

нервы



Нервы
глаз

Глаз
нервы



ramus communicans nervus canalis pterygoideus 1

nervus musculus tensor veli palatini 2

nervus lingualis 5

nervus musculus pterygoideus medialis 4

chorda tympani 7

nervus mandibularis 8

ganglion oticum 3

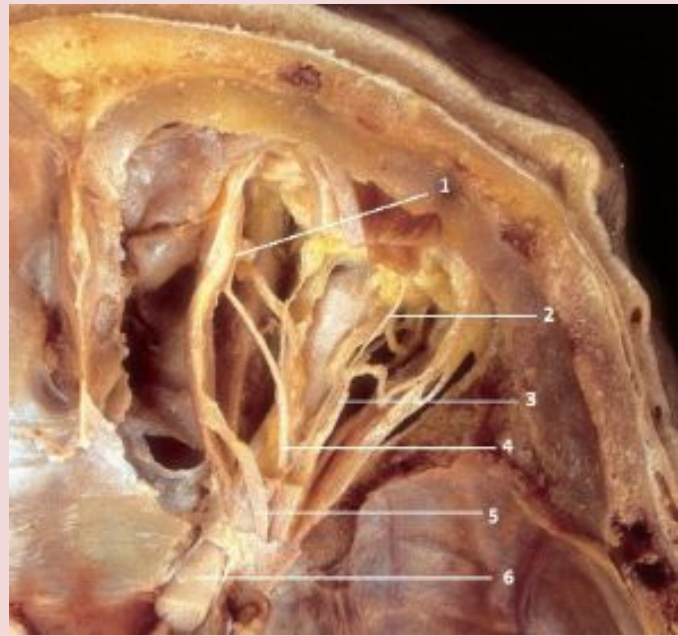
nervus alveolaris inferior 6

nervus auriculotemporalis 9

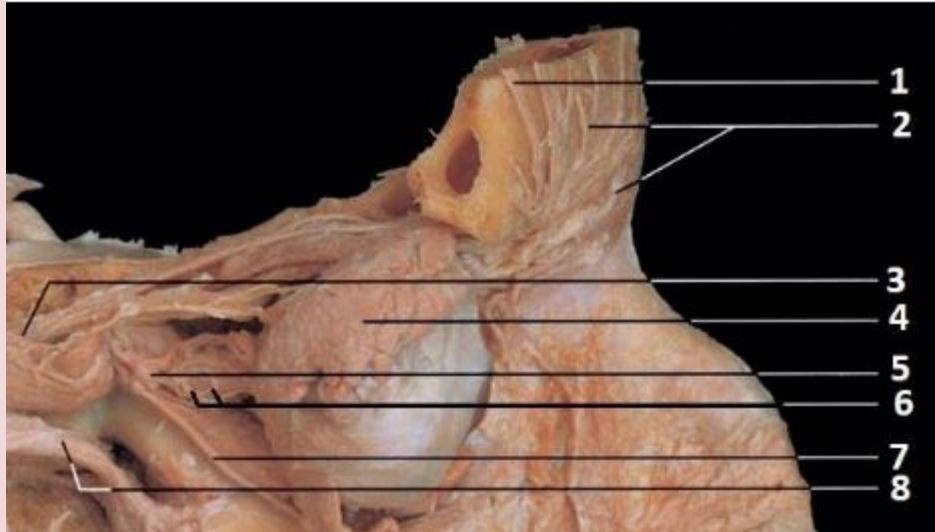
Нервы
глаз

- nervus ciliaris longus 2
- nervus trochlearis 5
- nervus opticus 6
- nervus nasociliaris 4
- nervus ethmoidalis anterior 1
- nervus lacrimalis 3

Глаз
нервы



Глаз
Нервы
глаз



- nervus ophthalmicus 3
- ramus inferior nervi oculomotorii 7
- nervus supraorbitalis 1
- nervus maxillaris 8
- nervus ciliares breves 6
- glandula lacrimalis 4
- nervus supratrochlearis 2
- ganglion ciliare 5

Лицо

Артерии
лицо

arteria facialis 1

arteria angularis 2

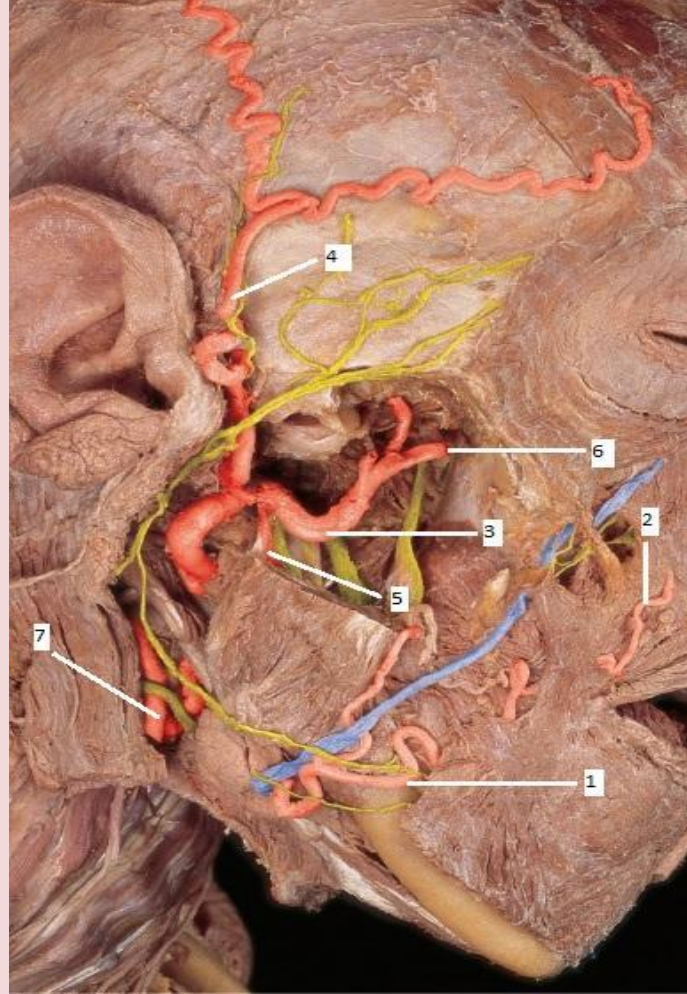
arteria maxillaris 3

arteria temporalis superficialis 4

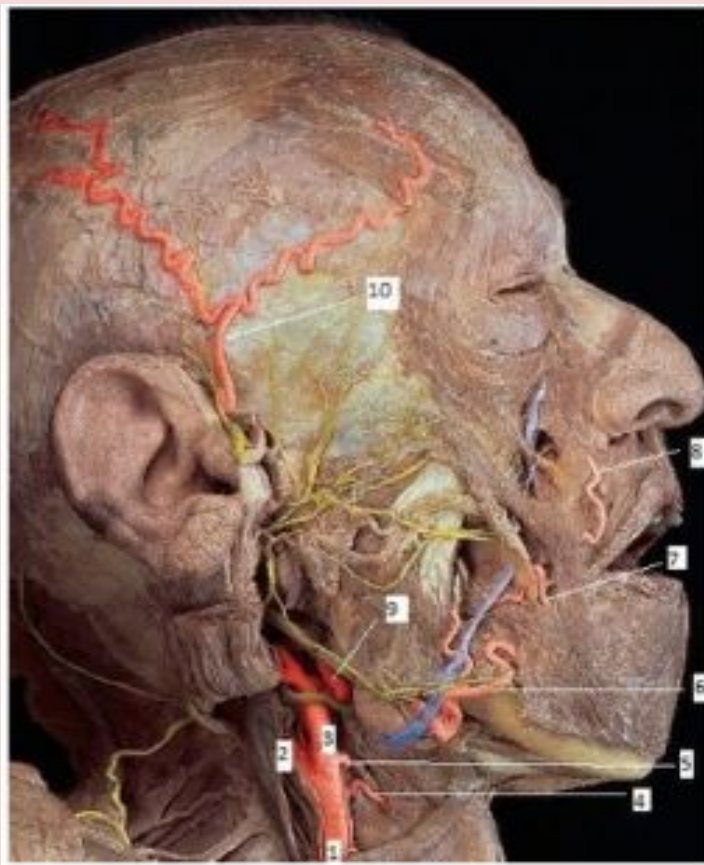
arteria alveolaris inferior 5

arteria infraorbitalis 6

arteria carotis interna 7

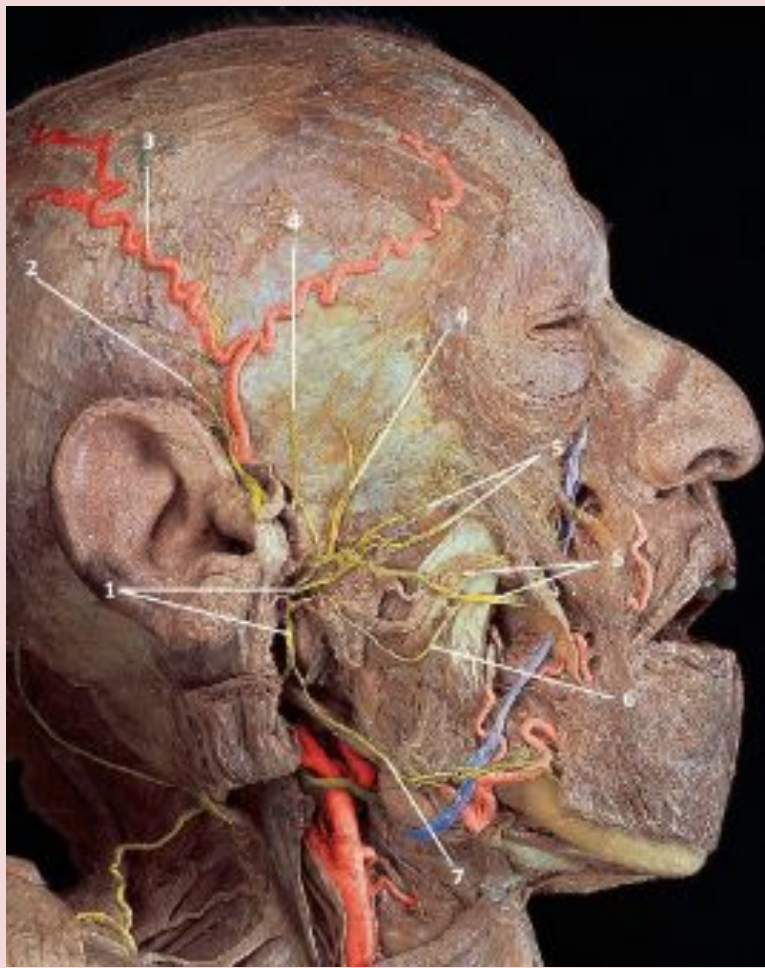


Лицо
артерии
Артерии
лицо



- arteria carotis communis 1
- arteria carotis interna 2
- arteria carotis externa 3
- arteria thyroidea superior 4
- arteria lingualis 5
- arteria facialis 6
- arteria labialis superior 7
- arteria angularis 8
- arteria maxillaris 9
- arteria temporalis superficialis 10

Лицо
артерии
Лицо
Артерии



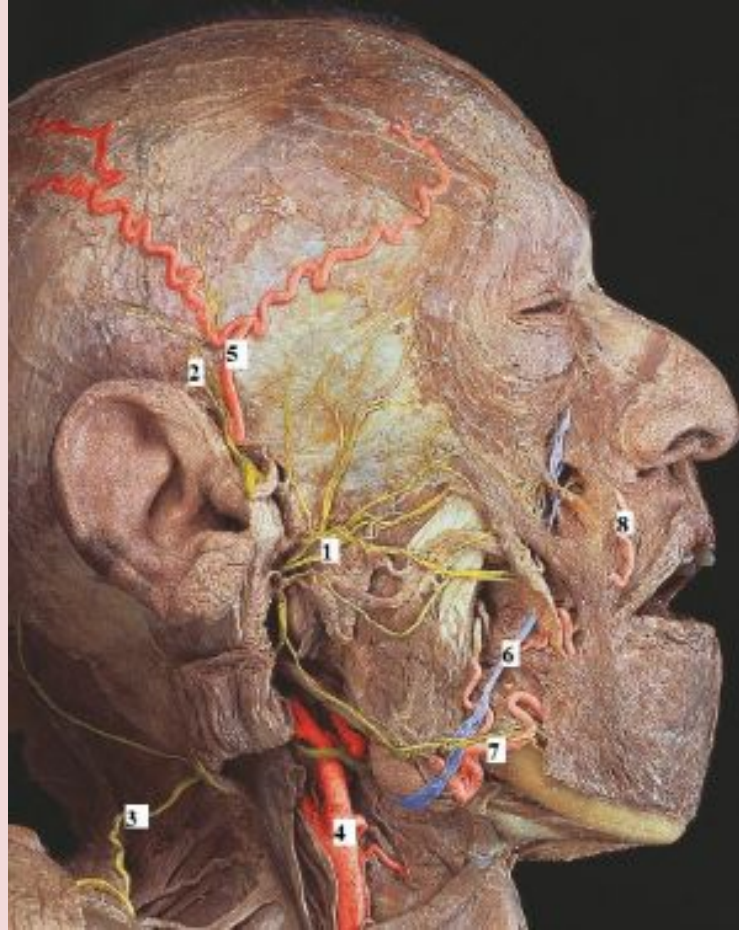
- ramus temporalis nervus facialis 4
- arteria temporalis superficialis 3
- nervus facialis 1
- ramus buccalis nervus facialis 6
- nervus auriculotemporalis 2
- ramus zygomaticus nervus facialis 5
- ramus marginalis mandibulae nervus facialis 7

Лицо

Артерии

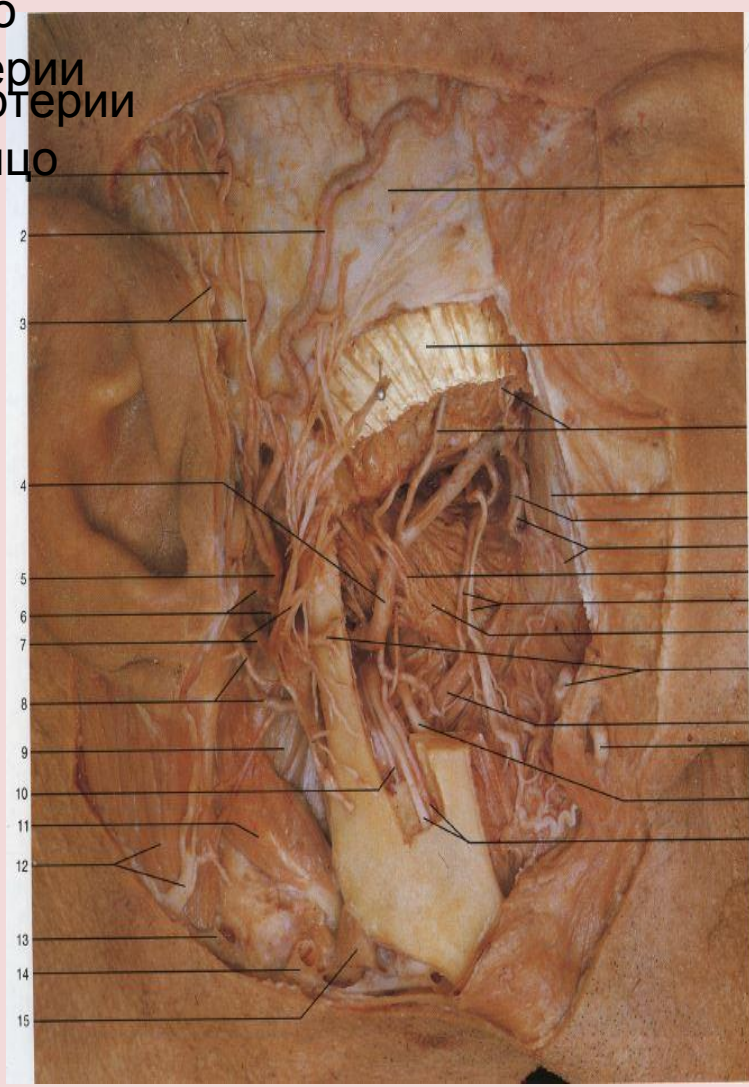
Лицо

- nervus auriculotemporalis 2
- arteria facialis 7
- arteria carotis externa 4
- arteria temporalis superficialis 5
- nervus facialis 1
- nervus accessorius 3
- vena facialis 6
- arteria labialis superior 8



- ramus parietalis arteria
- temporalis superficialis 1.
- ramus frontalis arteria
- temporalis superficialis 2.
- arteria maxillaris 4.
- arteria auricularis posterior 8.
- arteria temporalis profunda 18.
- arteria alveolaris superior posterior 20.
- arteria sphenopalatina 21.
- arteria meningea 22.
- arteria buccalis 23.
- arteria pterygoideus lateralis 24.
- arteria transversa faciei 25.
- arteria facialis 27.
- arteria alveolaris inferior 29.

Лицо
 артерии
 Артерии
 лицо

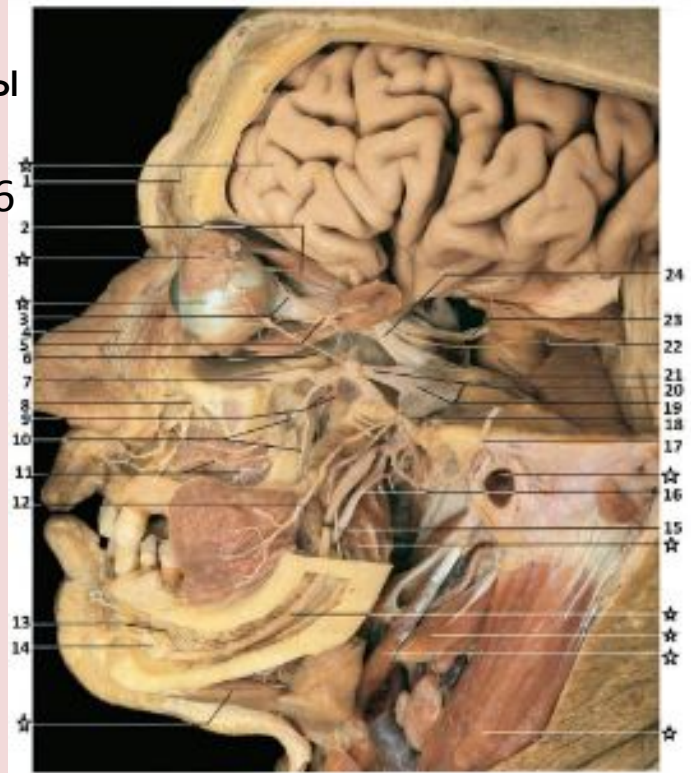


Лицо

Нервы

лицо

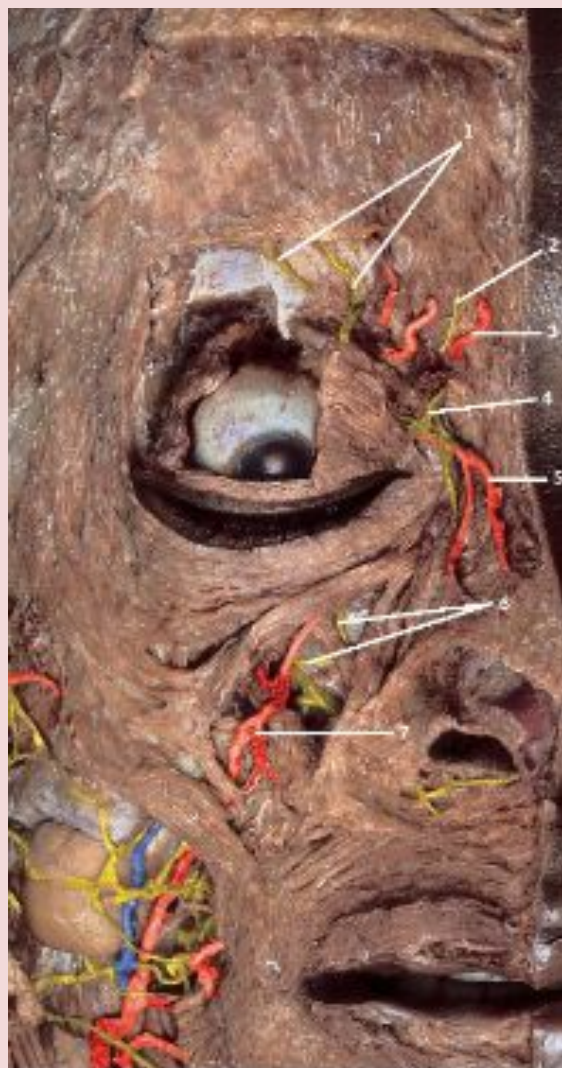- plexus dentalis inferior 13
- nervus mandibularis 18
- nervus lingualis et chorda tympani 16
- nervus trochlearis 22
- nervus alveolaris inferior 15
- nervus maxillaris 20
- nervus trigeminus 21
- nervus mentalis 14
- nervus auriculotemporalis 17
- ganglion trigeminale 19
- nervus oculomotorius 23
- nervus ophthalmicus 24



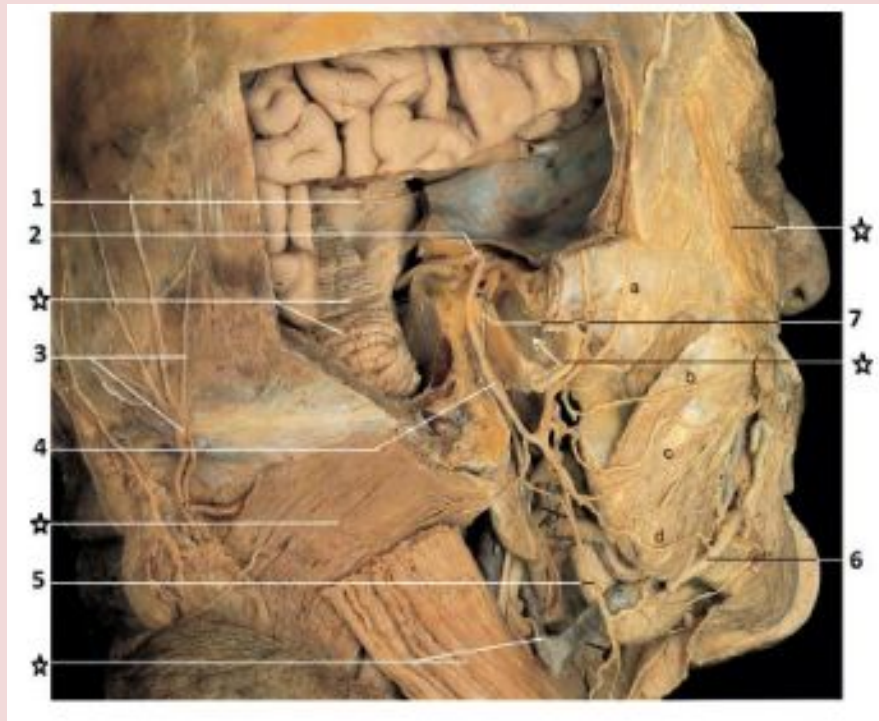
- ramus nasalis externus nervus ethmoidalis anterior 4
- ganglion pterygopalatinum 9
- nervus supraorbitalis 1
- nervus ciliaris brevis 3
- ganglion ciliare 5
- nervus infraorbitalis 7
- nervus alveolaris superior posterior 10
- plexus dentalis superior 11
- nervus buccalis 12
- nervus lacrimalis 2
- nervus zygomaticus 6
- pes anserinus minor 8

Лицо
Нервы
лицо

- arteria dorsalis nasi 5
- nervus supratrochlearis 2
- arteria facialis 7
- arteria supratrochlearis 3
- nervus infratrochlearis 4
- nervus supraorbitalis 1
- nervus infraorbitalis 6



Нервы
лицо
лицо



ramus cervicalis nervi facialis 5

nervus trochlearis 1

ramus marginalis mandibulae nervus facialis d

ramus temporalis nervus facialis a

nervus facialis 4

nervus occipitalis major 3

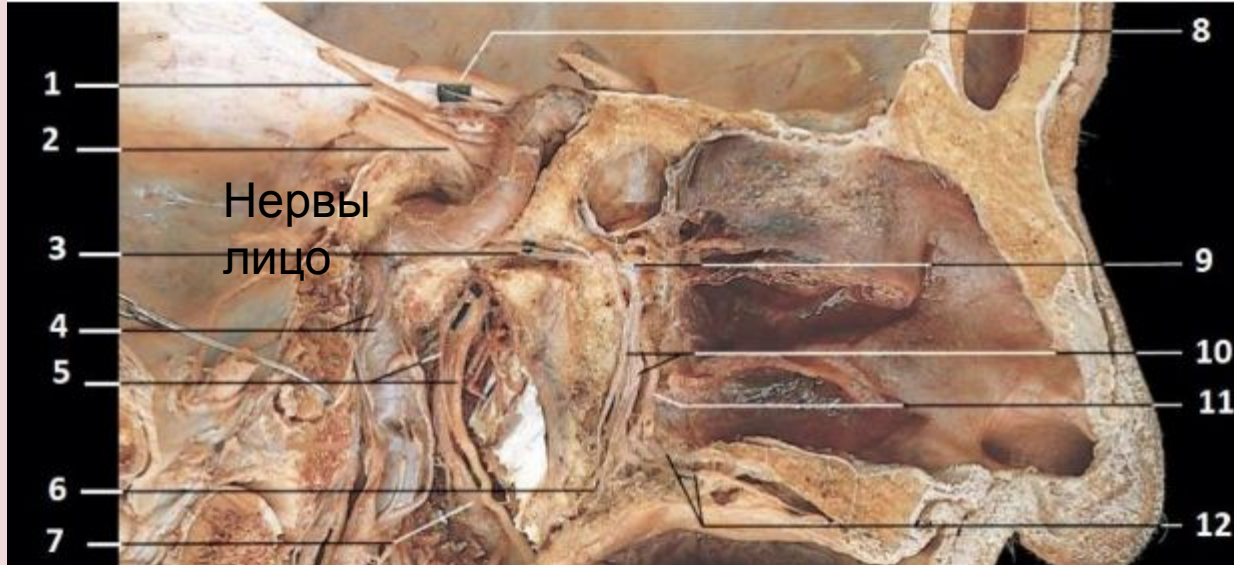ramus buccalis nervus facialis c

ramus zygomaticus nervus facialis b

ganglion geniculi 2

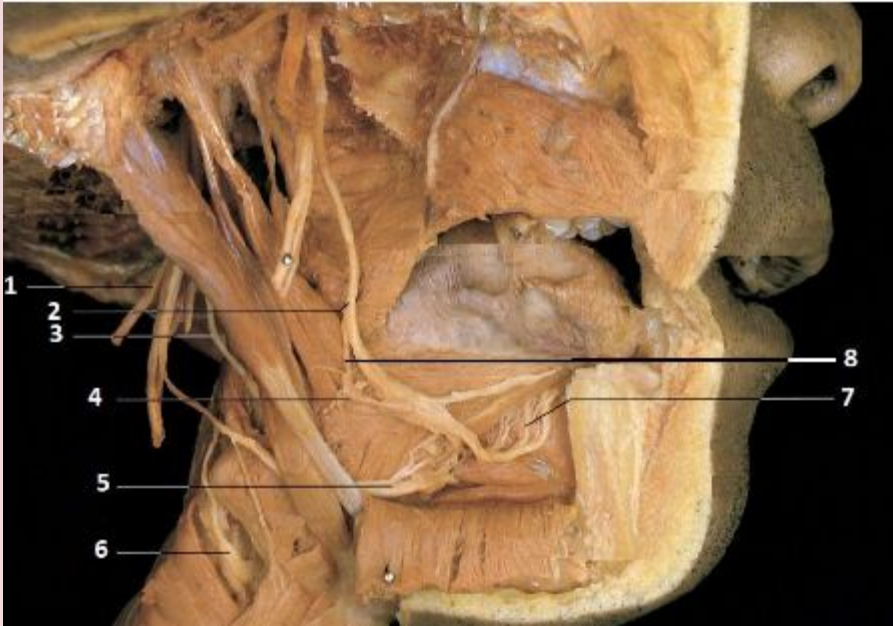
arteria facialis 6

chorda tympani 7



- nervus trochlearis 1
- nervus petrosus major 8
- nervus alveolaris inferior 7
- nervi palatini 10
- radix motoria nervus trigeminus 2
- nervus palatinus minor 6
- nervus palatinus major 12
- arteria palatina descendens 11
- ganglion pterygopalatinum 9
- nervus canalis pterygoidei 3
- plexus caroticus internus 4
- nervus lingualis et nervus lingualis et 5

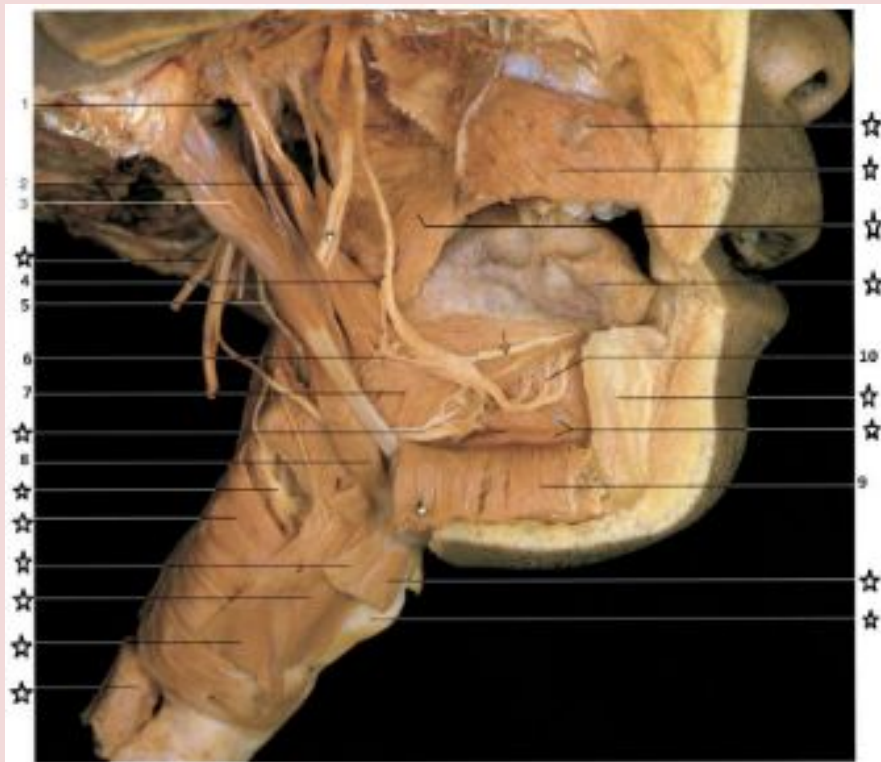
Лицо
нервы



Лицо
нервы
ервы лицо

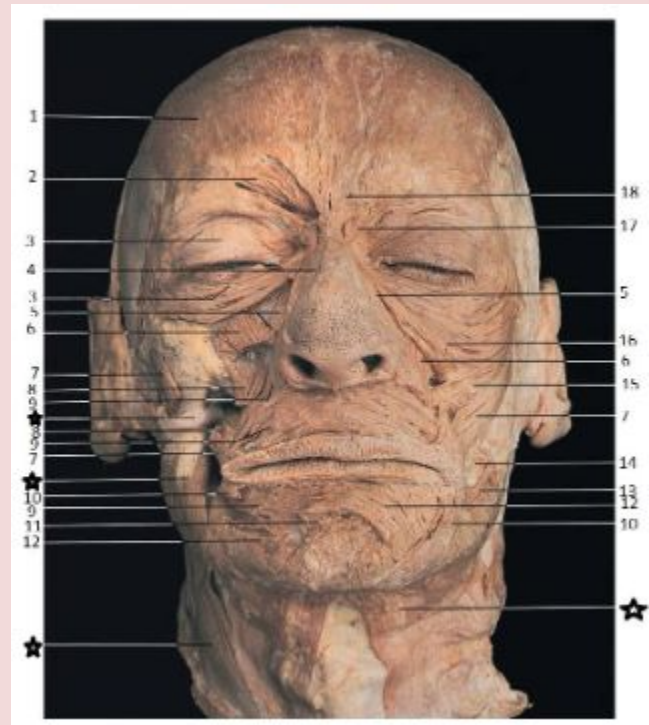
chorda tympani 8
nervus hypoglossus 5
nervus lingualis 2
nervus laryngeus superior 6
ganglion submandibulare 4
nervus vagus 1
nervus glossopharyngeus 3
ramus terminalis nervus lingualis 7

Мышцы глотка



- musculus stylohyoideus 8
- musculus mylohyoideus 9
- musculus hyoglossus 7
- processus styloideus 1
- musculus styloglossus 2
- nervus lingualis 4
- nervus glossopharyngeus 5
- venter posterior musculus digastricus 3
- ganglion submandibulare 6
- ramus terminalis nervus lingualis 10

Мышцы лицо



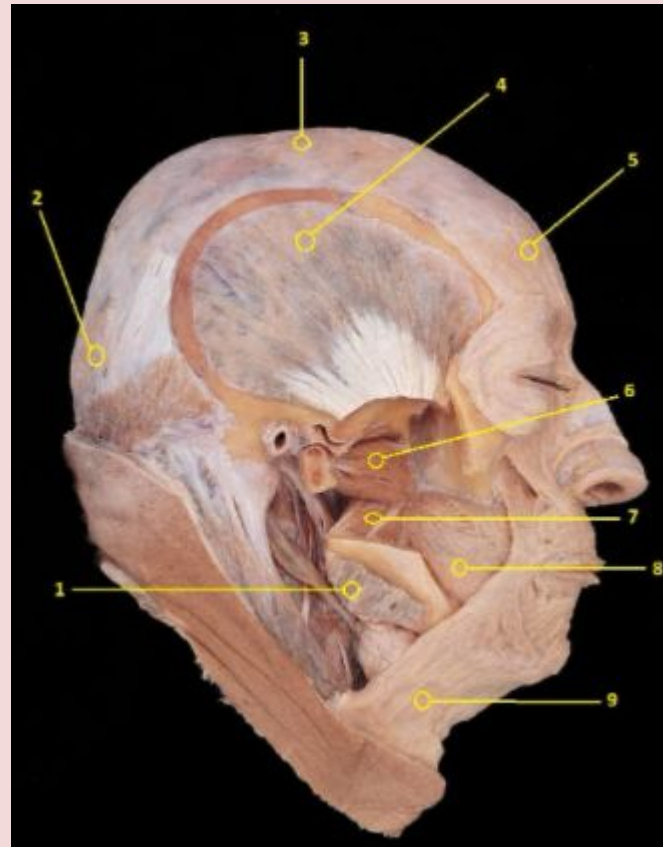
pars alaris musculus nasalis 9
venter frontalis musculus epicranii 1
musculus depressor anguli oris 10
musculus zygomaticus major 7
musculus levator anguli oris 8
musculus levator labii superioris 6
musculus corrugator supercilii 2
pars palpebralis musculus orbicularis oculi 3
pars transversa musculus nasalis 4
musculus levator labii superioris alaeque nasi 5

musculus depressor labii inferioris 12
pars orbitalis musculus orbicularis oculi 16
musculus risorius 13
musculus buccinator 14
musculus zygomaticus minor 15
musculus mentalis 11
musculus depressor supercilii 17
musculus procerus 18

Мышцы

лицо

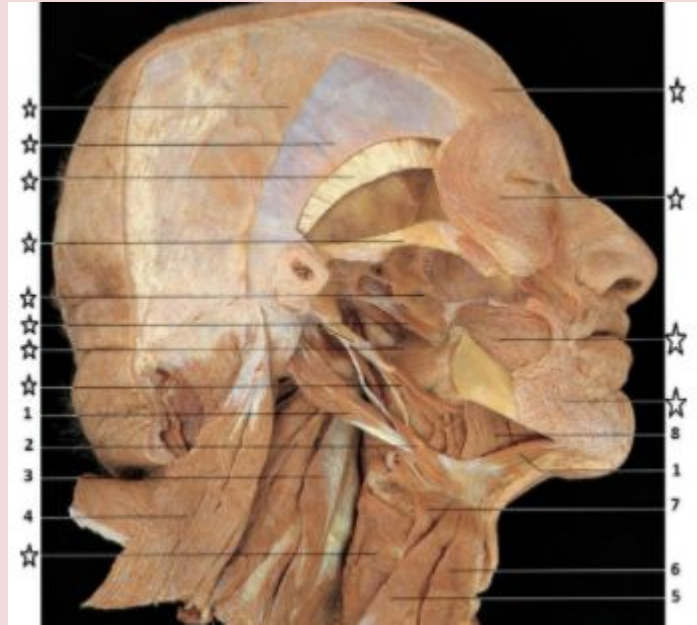
- 1. venter frontalis musculus epicranii
- 2. galea aponeurotica
- 3. musculus buccinator
- 4. musculus pterygoideus medialis
- 5. musculus pterygoideus lateralis
- 6. musculus masseter
- 7. musculus platysma
- 8. venter occipitalis musculi epicranii
- 9. musculus temporalis

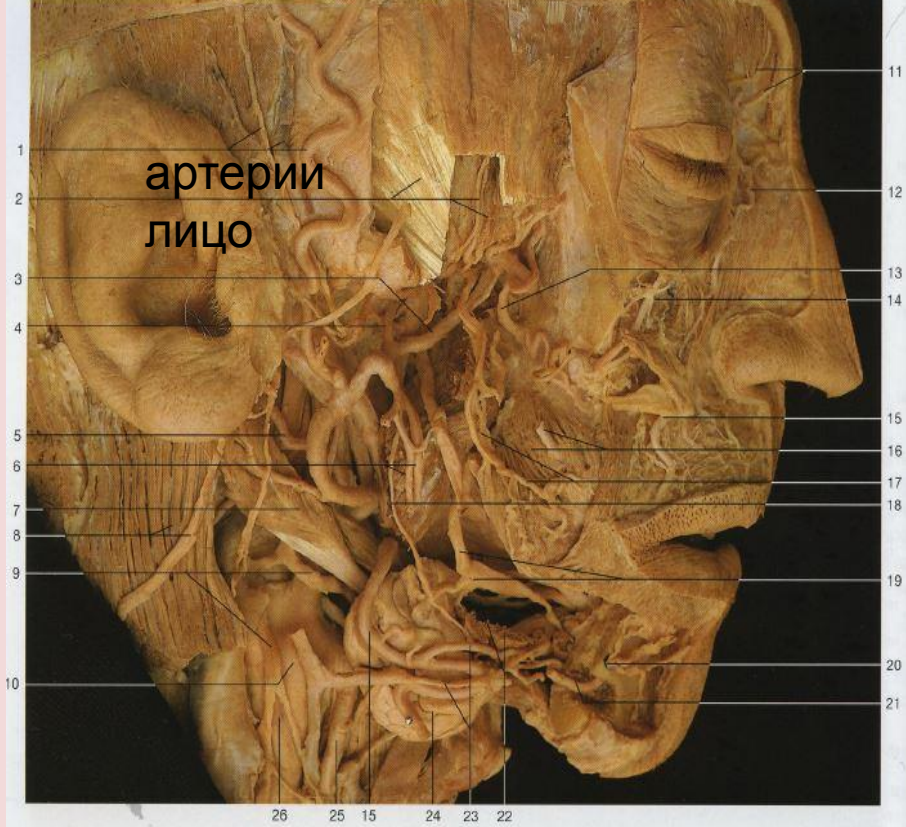

Мышцы

лицо

- musculus thyrohyoideus 7
- musculus longus capitis 3
- musculus stylohyoideus 2
- musculus sternohyoideus 6
- musculus digastricus 1
- musculus sternocleidomastoideus 4
- musculus omohyoideus 5
- musculus mylohyoideus 8





arteria temporalis superficialis 1

arteria temporalis profundus 2

arteria maxillaris 3

arteria meningea media 4

arteria occipitalis 5

arteria alveolaris inferior 6

arteria carotis externa 10

arteria angularis 12

arteria alveolaris superior
posterior 13

arteria facialis 15

arteria buccalis 17

arteria mentalis 23

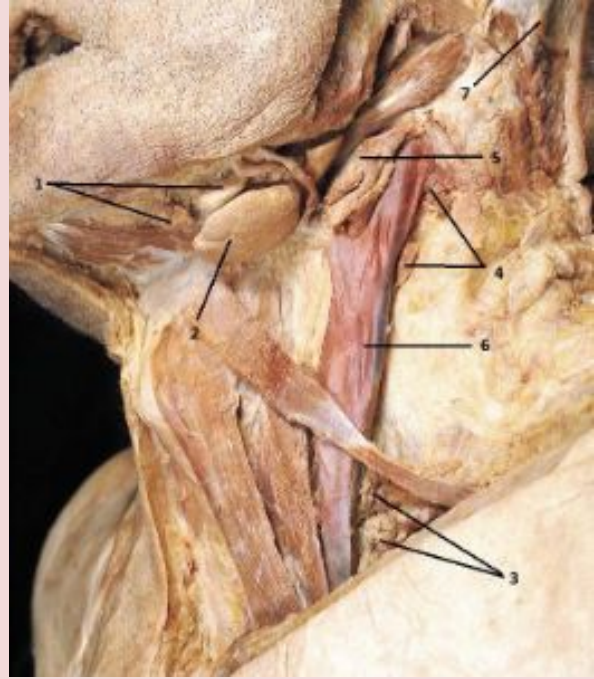
arteria thyroidea inferior 25

arteria carotis communis 26

Лимфа

шея

- noduli lymphatici supraclaviculares 3
- noduli lymphatici submandibularis 1
- noduli lymphatici cervicales profundi 4
- glandula submandibularis 2
- noduli lymphatici jugulodigastrici 5
- vena jugularis interna 6
- noduli lymphatici mastoidei 7



Нервы

шея

nervus supraclavicularis 6

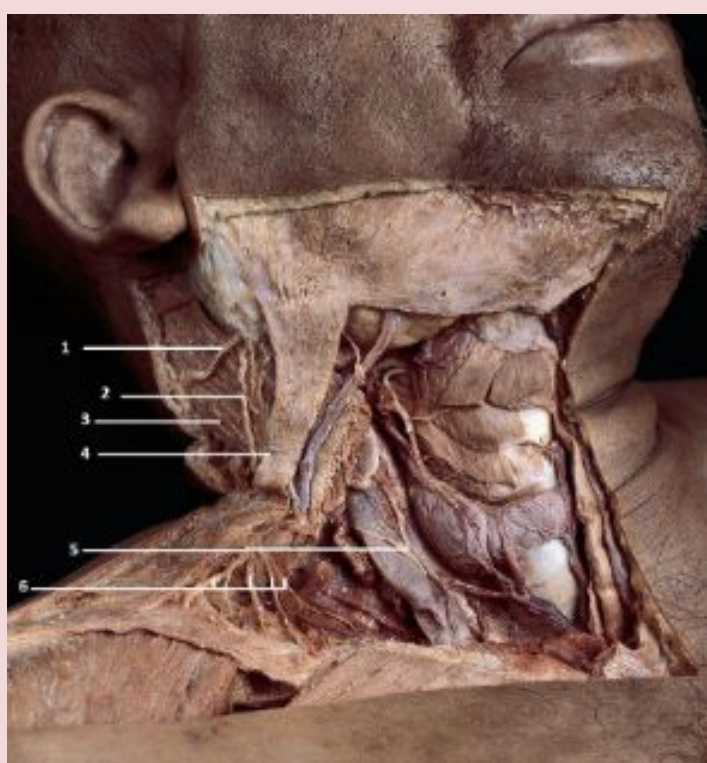
nervus transversus colli 1

ansa cervicalis 5

nervus auricularis magnus 2

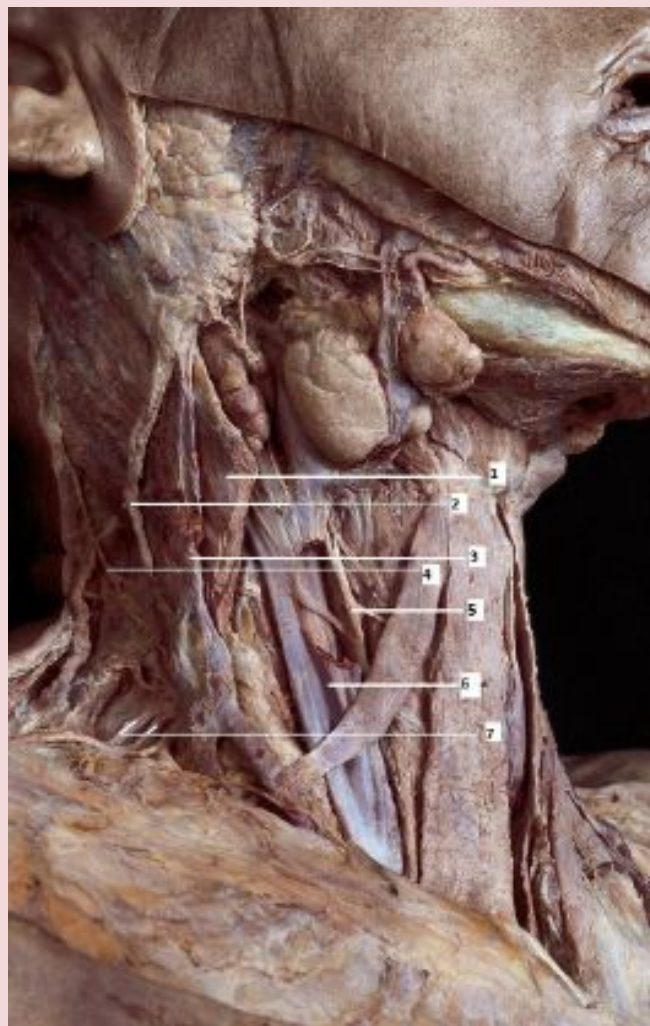
musculus sternocleidomastoideus 3

musculus platysma 4



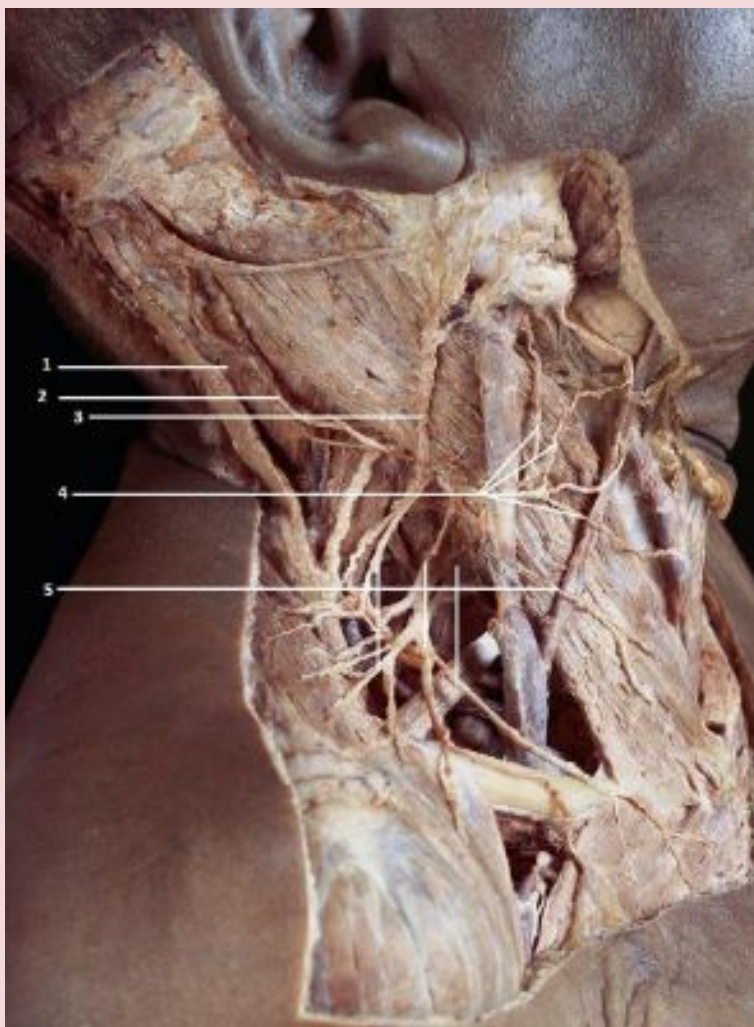
Нервы шея

- nervus occipitalis minor 4
- vena jugularis interna 6
- musculus sternocleidomastoideus 1
- ansa cervicalis 5
- nervus auricularis magnus 2
- vena jugularis externa 3
- nervus supraclavicularis 7



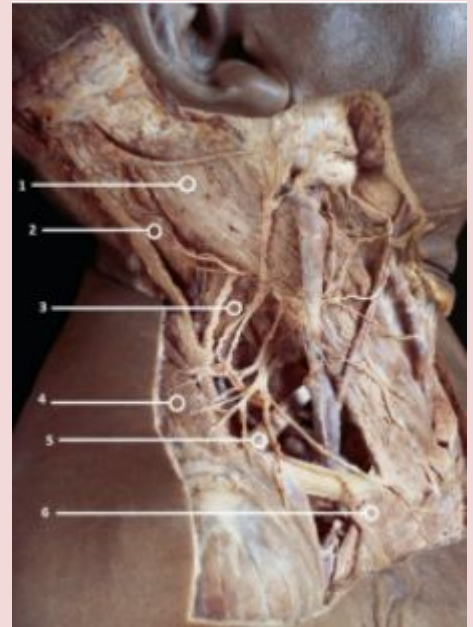
Нервы

- Шейя
- nervus auricularis magnus 3
 - nervus occipitalis minor 2
 - nervus supraclavicularis 5
 - musculus splenius capitis 1
 - nervus transversus colli 4



Мышцы шея

- musculus omohyoideus 5
- musculus sternocleidomastoideus 1
- musculus scalenus posterior 3
- musculus splenius capitis 2
- musculus trapezius 4
- musculus pectoralis major 6



Нервы

шея

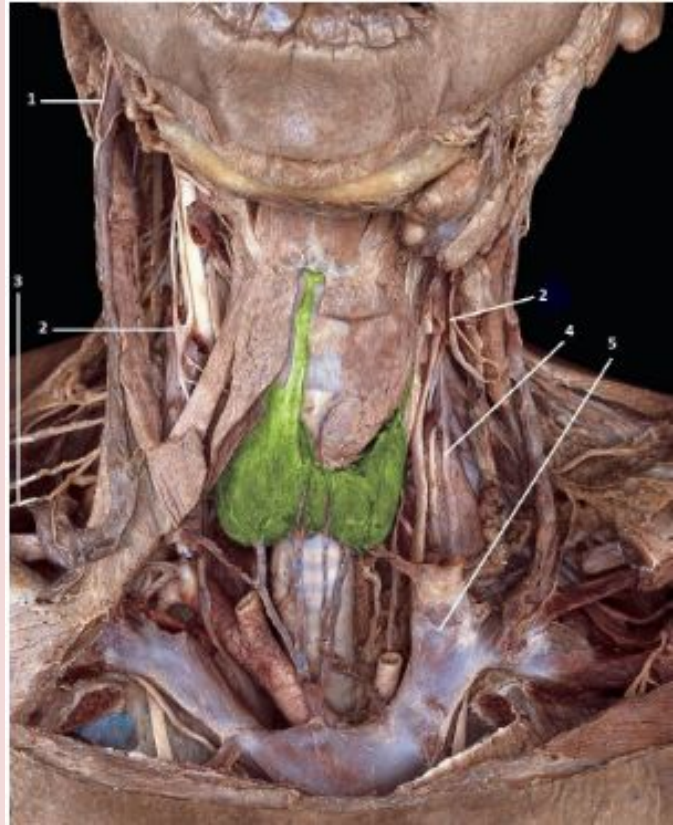
truncus brachiocephalicus sinister 5

nervus phrenicus 4

ansa cervicalis 2

nervus auricularis magnus 1

nervus supraclavicularis 3

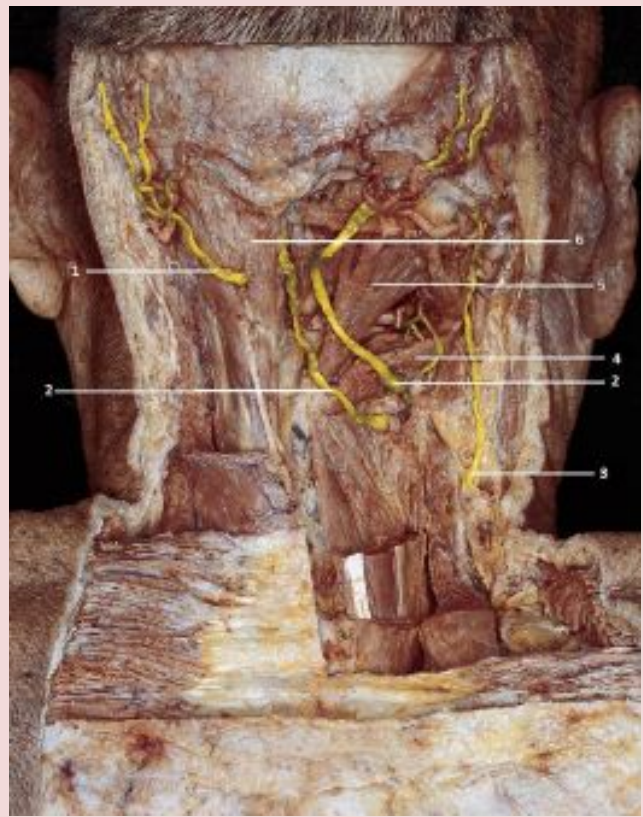


Мышцы

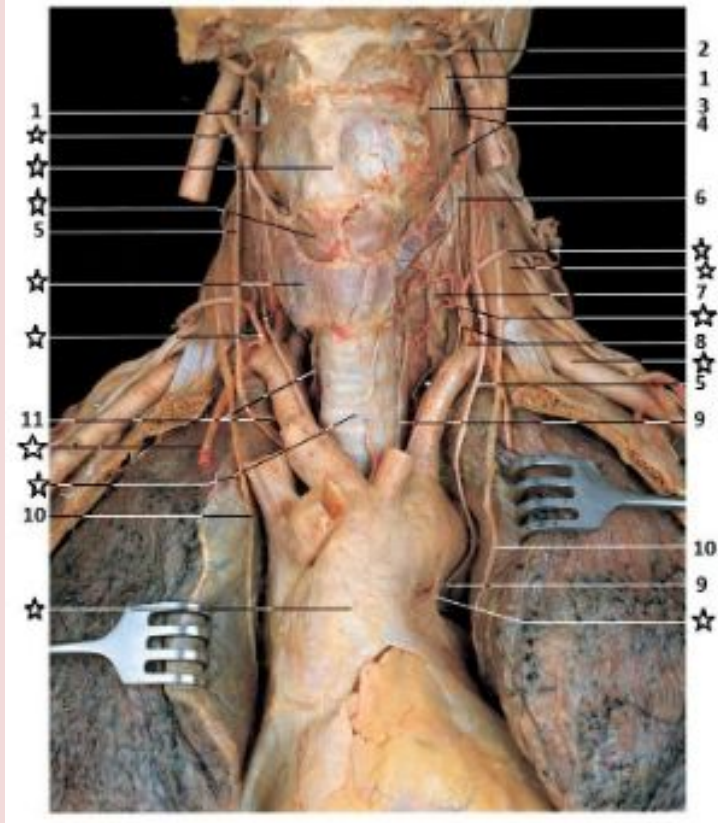
Шея

Нервы

- musculus semispinalis capitis 6
- nervus occipitalis (C3) 2
- nervus occipitalis major 1
- musculus obliquus capitis inferior 4
- nervus occipitalis minor 3
- musculus rectus capitis posterior major 5



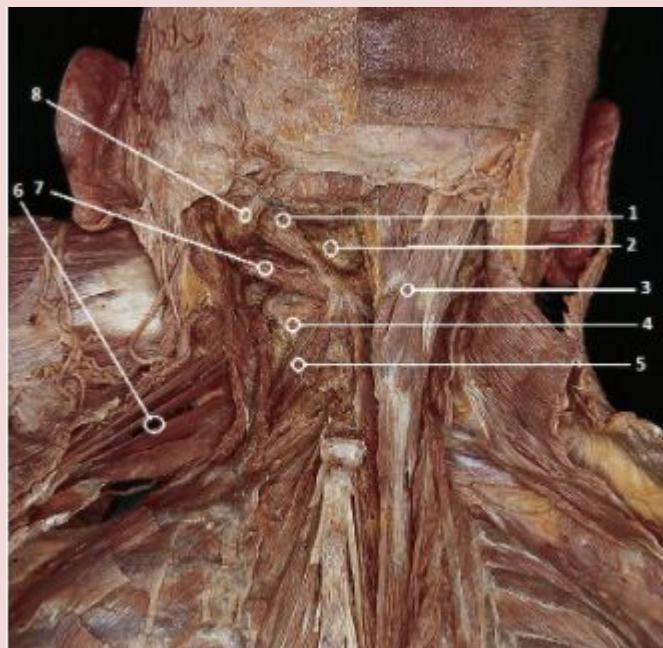
Нервы шея



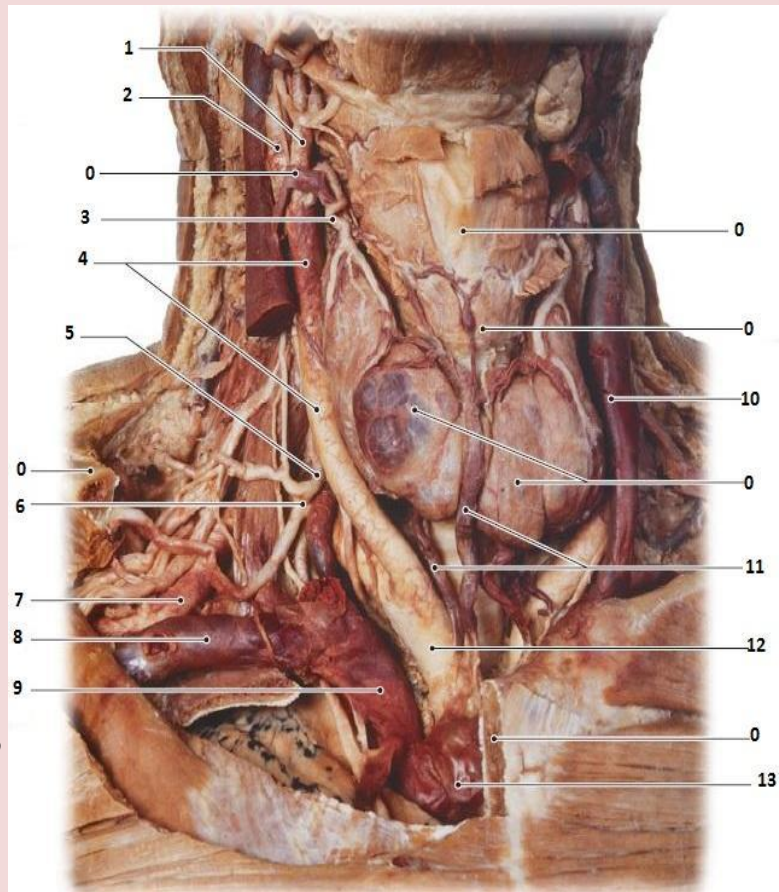
- ganglion cervicale superius 1
- ramus externus nervus laryngeus superior 4
- nervus laryngeus recurrens dexter 11
- nervus phrenicus 10
- nervus vagus 5
- ganglion cervicale medium 7
- truncus sympathicus 6
- nervus laryngeus recurrens sinister 9
- nervus hypoglossus 2
- ramus internus nervus laryngeus superior 3
- nervi cervicales cardiaci inferior 8

Мышцы шея

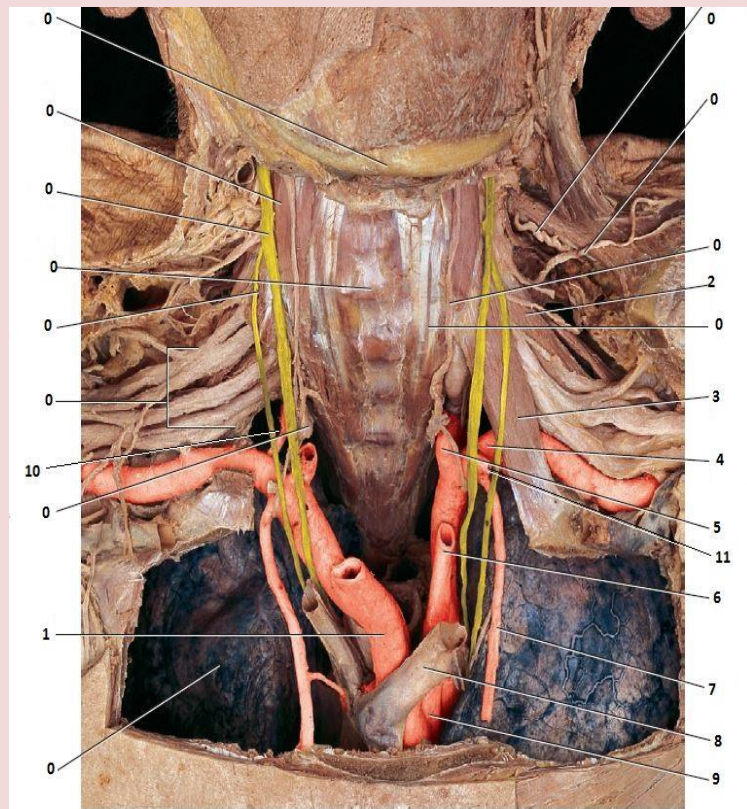
- musculus obliquus capitis inferior 7
- musculus semispinalis capitis 3
- musculus levator scapulae 6
- musculus semispinalis cervicis 5
- musculus obliquus capitis superior 8
- musculus rectus capitis posterior minor 2
- musculus rectus capitis posterior major 1
- musculus multifidus 4



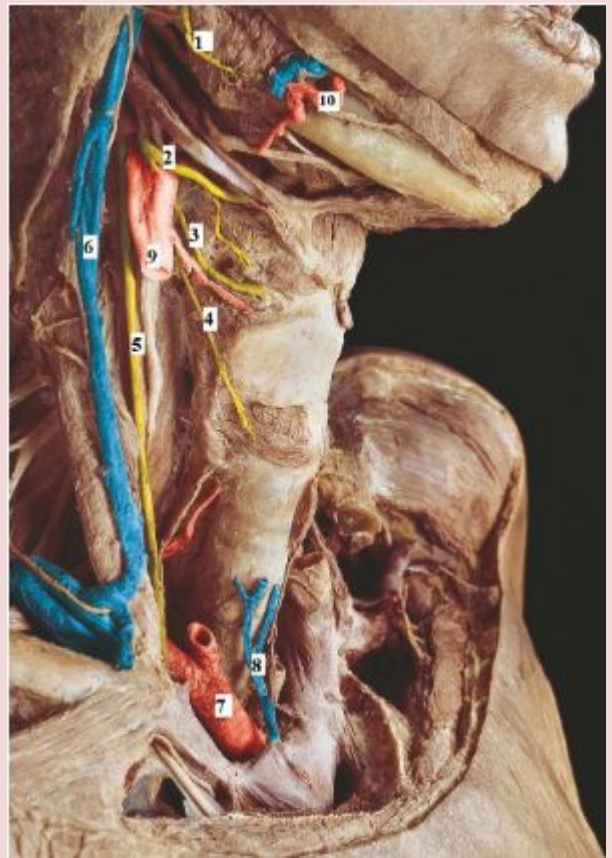
- arteria carotis externa 1
- arteria carotis interna 2
- arteria thyroidea superior 3
- arteria carotis communis 4
- arteria thyroidea inferior 5
- truncus thyrocervicalis 6
- arteria subclavia 7
- vena subclavia 8
- vena brachiocephalica dextra 9
- vena jugularis interna 10
- vena thyroidea inferior 11
- truncus brachiocephalicus 12
- vena brachiocephalica sinistra 13



- truncus brachiocephalicus 1
- musculus scalenus medius 2
- musculus scalenus anterior 3
- arteria subclavia 4
- arteria vertebralis 5
- arteria carotis communis sinistra 6
- arteria thoracica interna 7
- vena brachiocephalica sinistra 8
- arcus aortae 9
- arteria cervicalis ascendens 10
- truncus thyrocervicalis 11

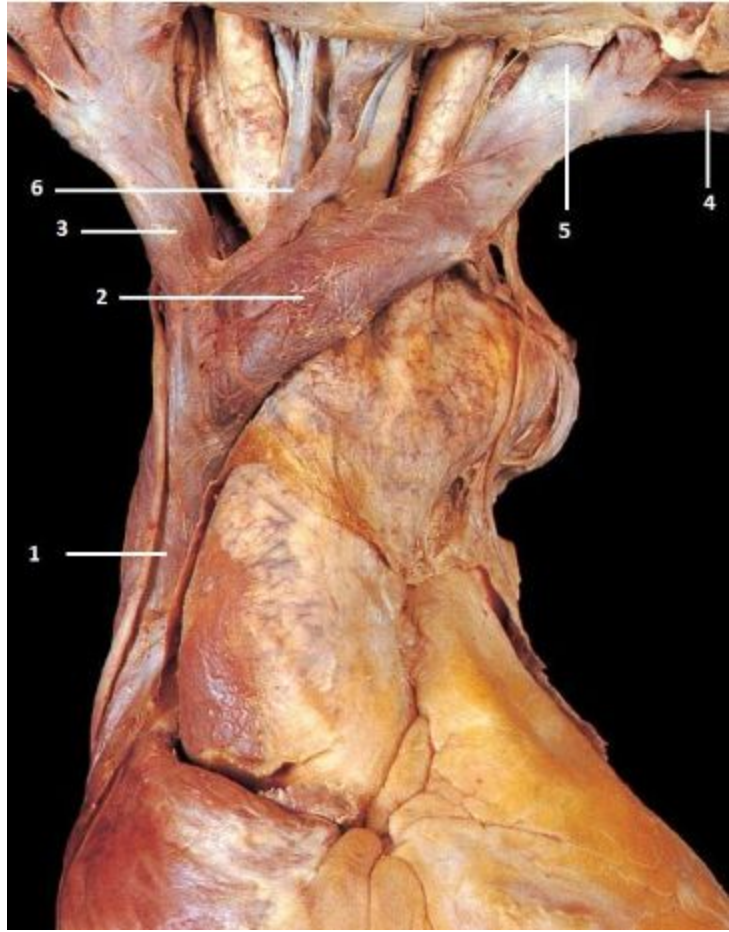


- vena jugularis interna 6
- arteria carotis communis 9
- arteria facialis 10
- nervus laryngeus superior 3
- vena thyroidea inferior 8
- nervus vagus 5
- ramus mandibularis nervus facialis 1
- nervus hypoglossus 2
- nervus laryngeus inferior 4
- arteria brachiocephalica 7

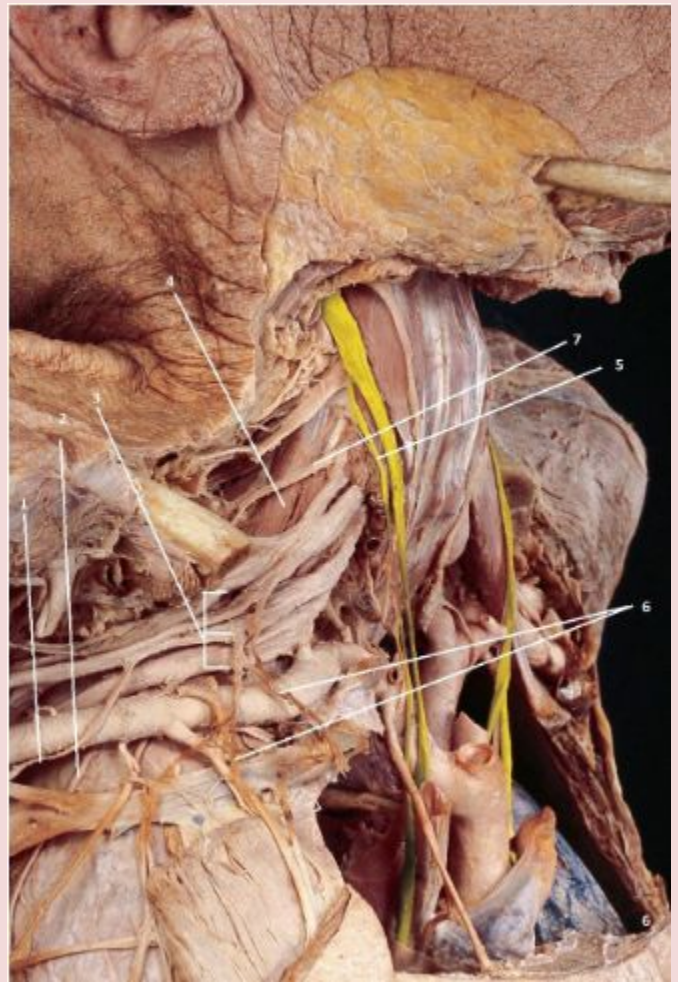


- vena thyroidea inferior 6
- vena brachiocephalica sinistra 2
- vena jugularis interna sinistra 5
- vena cava superior 1
- vena brachiocephalica dextra 3
- vena subclavia sinistra 4

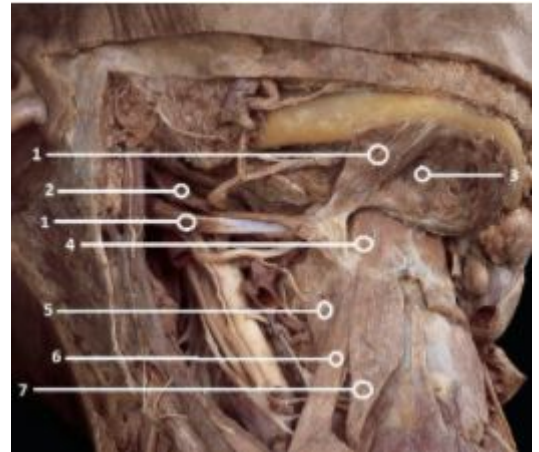
5
из 6



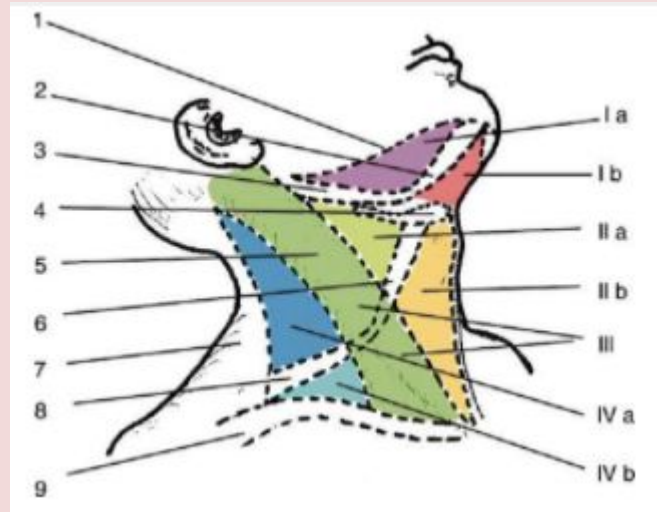
- nervus thoracodorsalis 1
- nervus thoracicus longus 2
- plexus brachialis 3
- musculus scalenus anterior 4
- nervus phrenicus 5
- nervus pectoralis major et minor 6
- nervus dorsalis scapulae 7



musculus stylohyoideus 2
musculus thyrohyoideus 4
musculus omohyoideus 6
musculus sternothyroideus 4/5
musculus digastricus 1
musculus mylohyoideus 3
musculus sternohyoideus 7

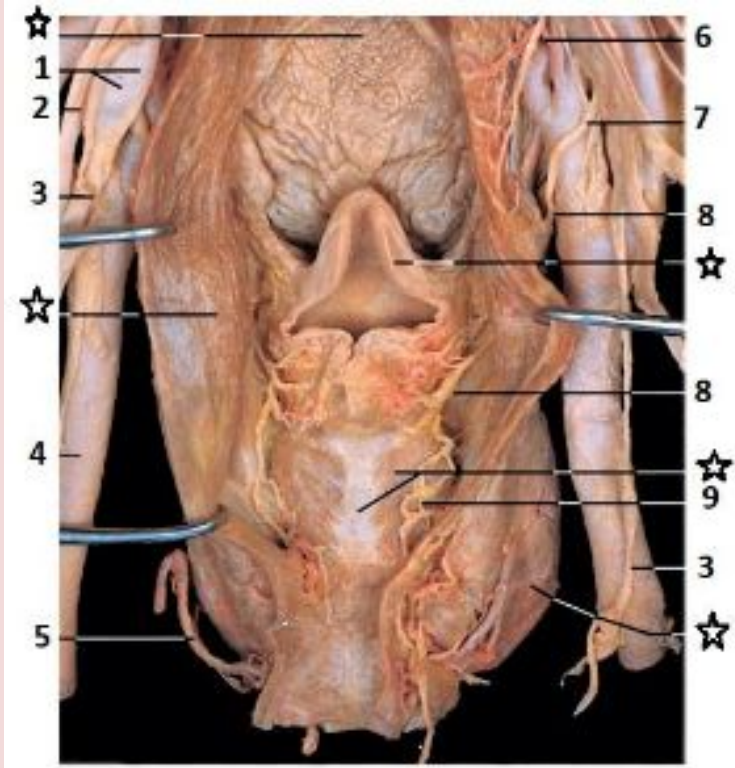


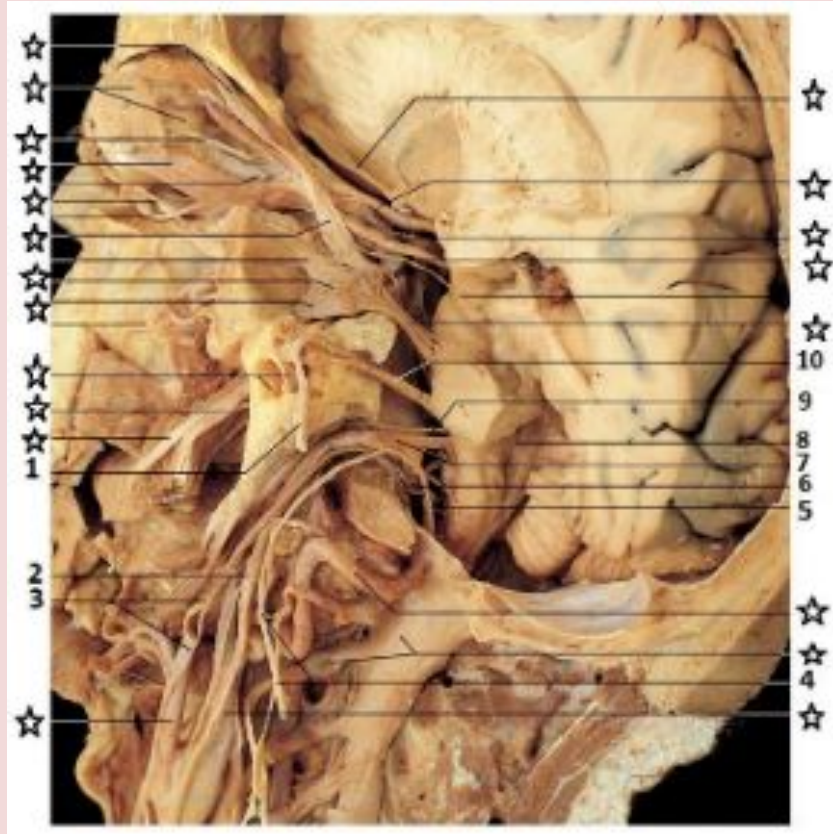
trigonum omotrapezoideum IVa
 trigonum omoclaviculare IVb
 trigonum submentale Ib
 regio sternocleidomastoideus III
 trigonum submandibulare Ia
 trigonum caroticum IIa
 trigonum omotracheale IIb



truncus sympathicus 3
 nervus laryngeus recurrens 9
 nervus laryngeus superior 7
 arteria carotis communis 4
 arteria thyroidea inferior 5
 ganglion cervicale superius 1
 nervus vagus 2
 nervus glossopharyngeus 6

 Ramus internus nervus laryngeus
 superior 8





nervus vagus 2

nervus hypoglossus pars cranialis 6

nervus vestibulocochlearis 10

nervus hypoglossus 3

nervus glossopharyngeus pars cranialis 9

nervus accessorius radix spinalis 4

nervus accessorius radix cranialis 5

nervus facialis 1

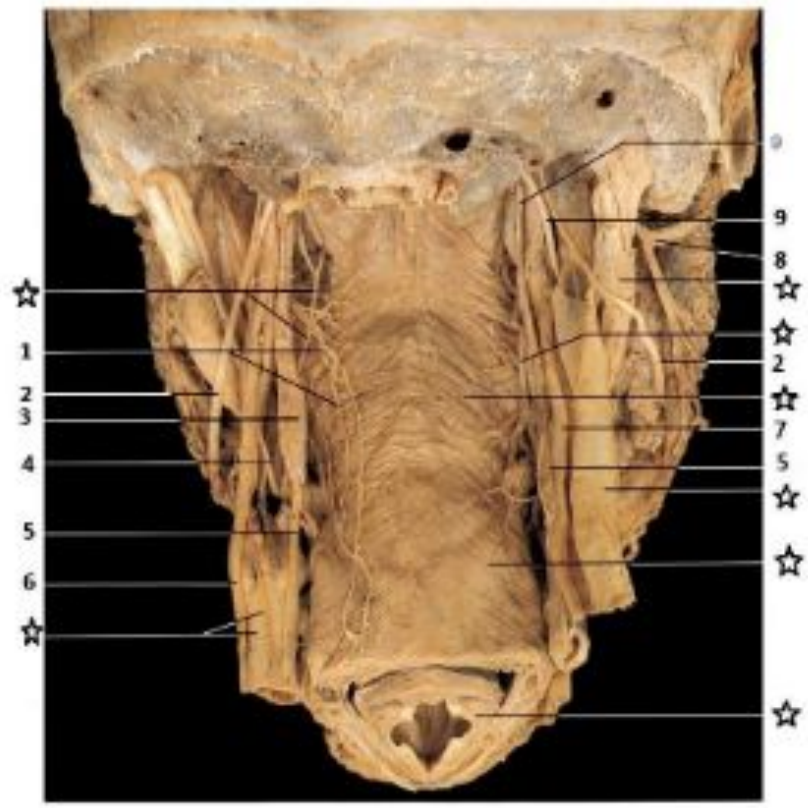nervus vagus pars cranialis 7

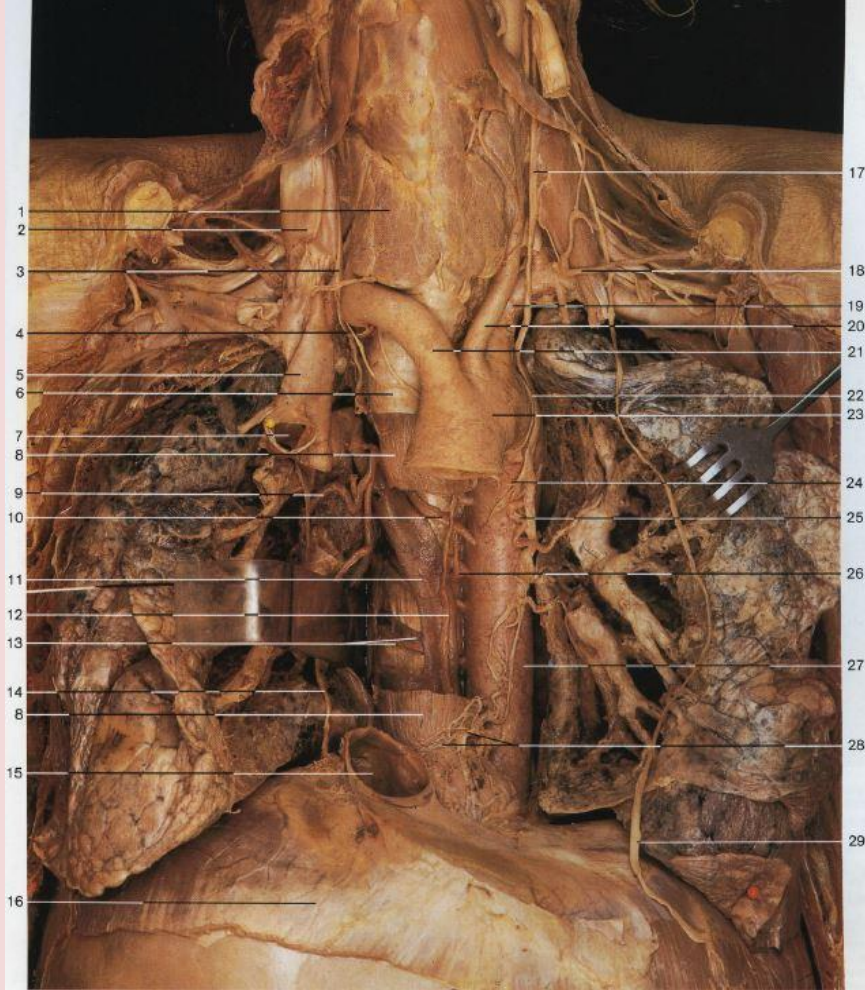
fossa rhomboidea 8

10

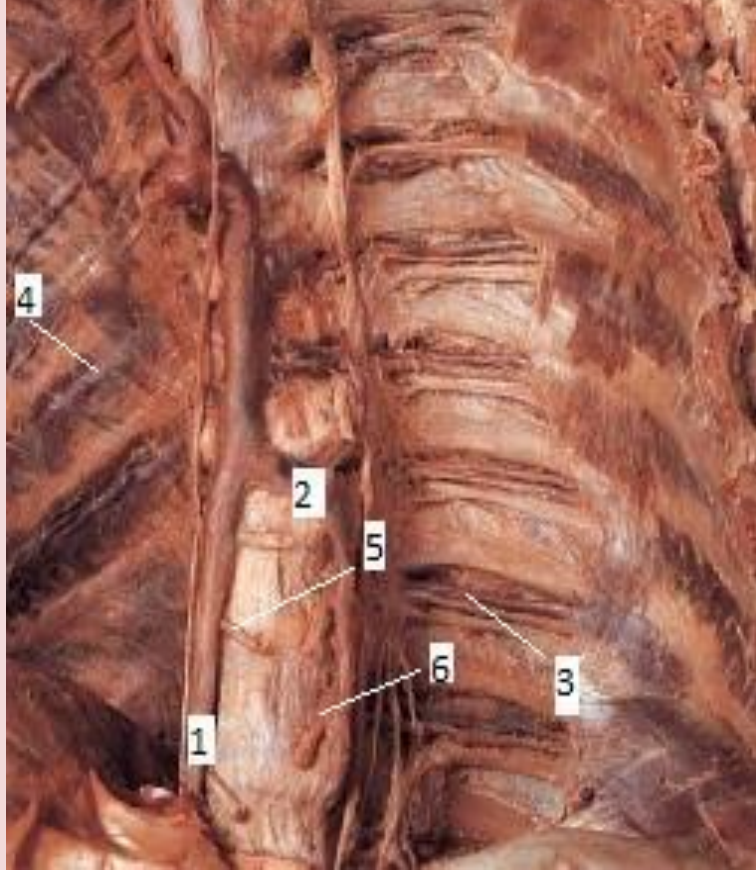из 10

nervus vagus dexter 7
 ganglion cervicale superius 3
 plexus pharyngeus 1
 truncus sympathicus 5
 nervus vagus sinister 6
 nervus accessorius 2
 nervus laryngeus superior 4
 nervus facialis 8
 nervus hypoglossus 9
 nervus glossopharyngeus 10





- arteria bronchialis dextra 9
- arteria intercostalis posterior 10.
- vena azygos 11.
- vena cava inferior 15.
- arteria subclavia sinistra 19.
- arteria carotis communis sinistra 20.
- truncus brachiocephalicus 21.
- arcus aortae 22.
- arteria bronchialis sinistra 25
- aorta thoracica 27.



vena azygos 1

vena hemiazygos 2

vena intercostalis posterior sinistra 3

vena intercostalis posterior dextra 4

arteria intercostalis posterior dextra 5

arteria intercostalis posterior sinistra 6

arteria carotis communis
dextra 1

arteria subclavia dextra 2

truncus brachiocephalicus 4

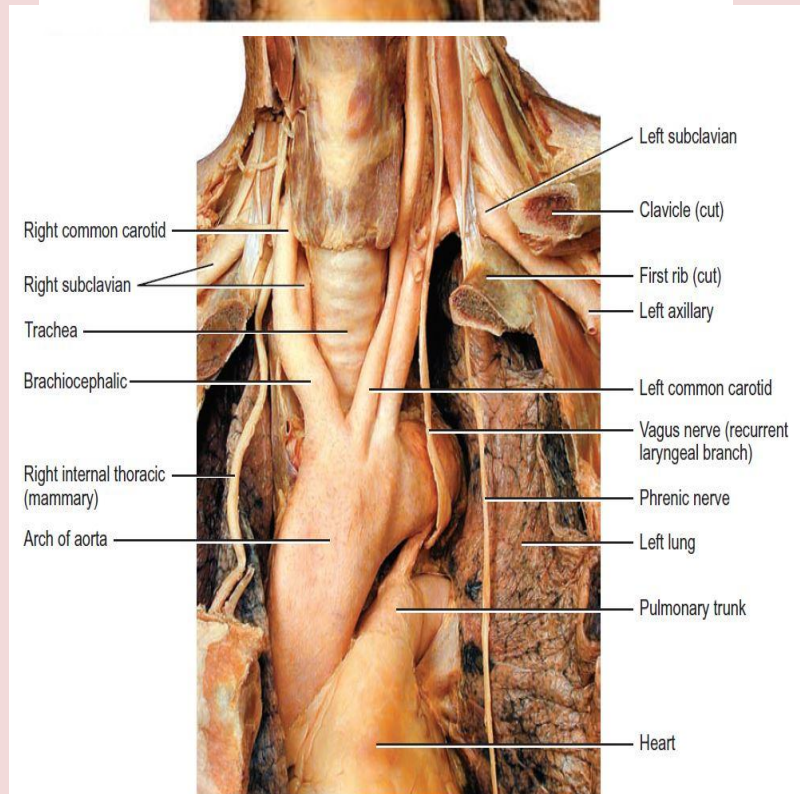
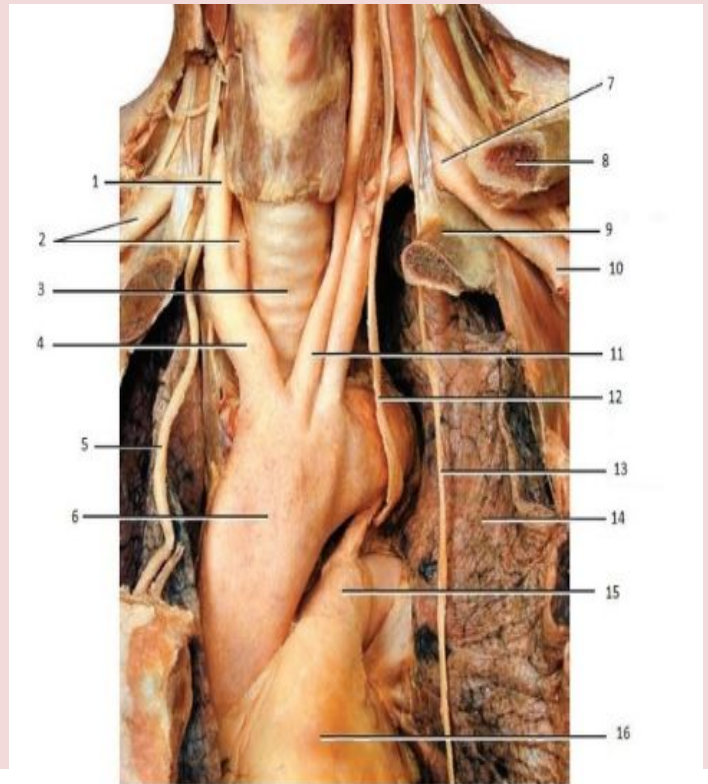
arcus aortae 6

arteria subclavia sinistra 7

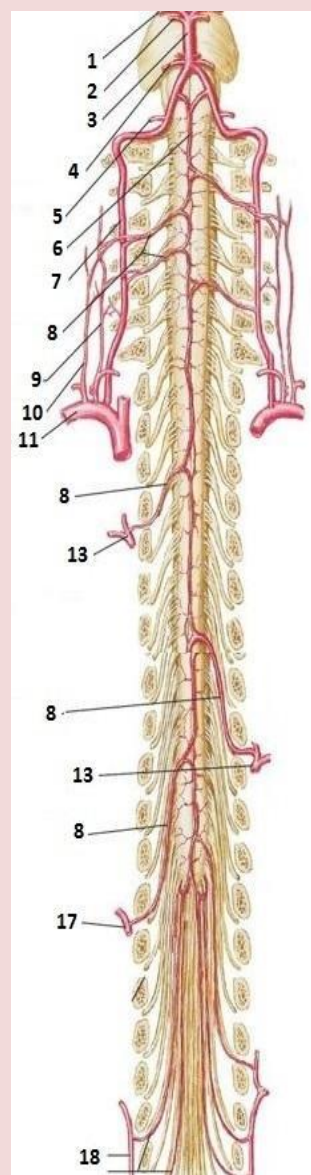
arteria carotis communis
sinistra 11

truncus pulmonalis 15

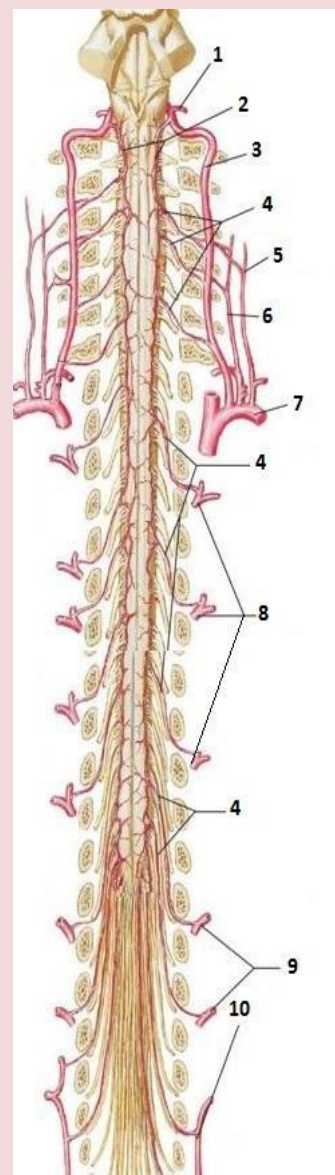
cor 16



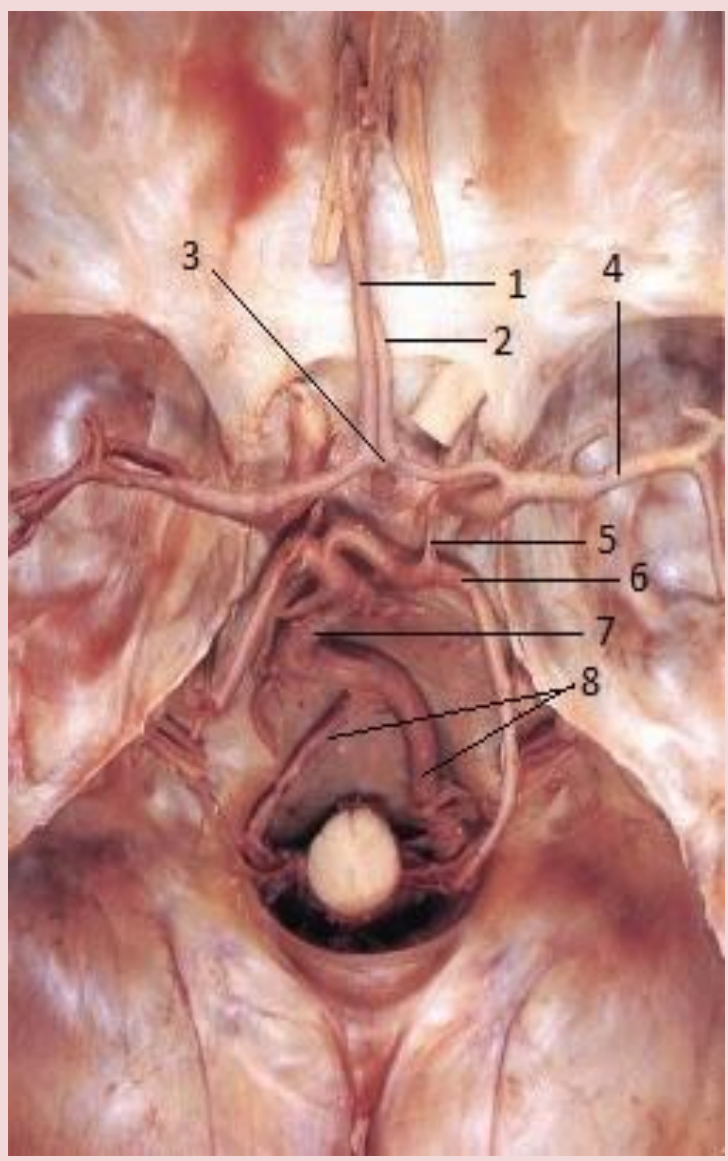
- arteria communicans posterior 1
- arteria cerebellaris superior 2
- arteria basilaris 3
- arteria cerebellaris inferior anterior 4
- arteria cerebellaris inferior posterior 5
- arteria spinalis anterior 6
- arteria vertebralis 7
- arteria medullaris segmentalis 8
- arteria cervicalis ascendens 9
- arteria cervicalis profunda 10
- arteria subclavia 11
- arteria intercostalis posterior 13
- arteria lumbalis 17
- arteria sacralis lateralis et media 18



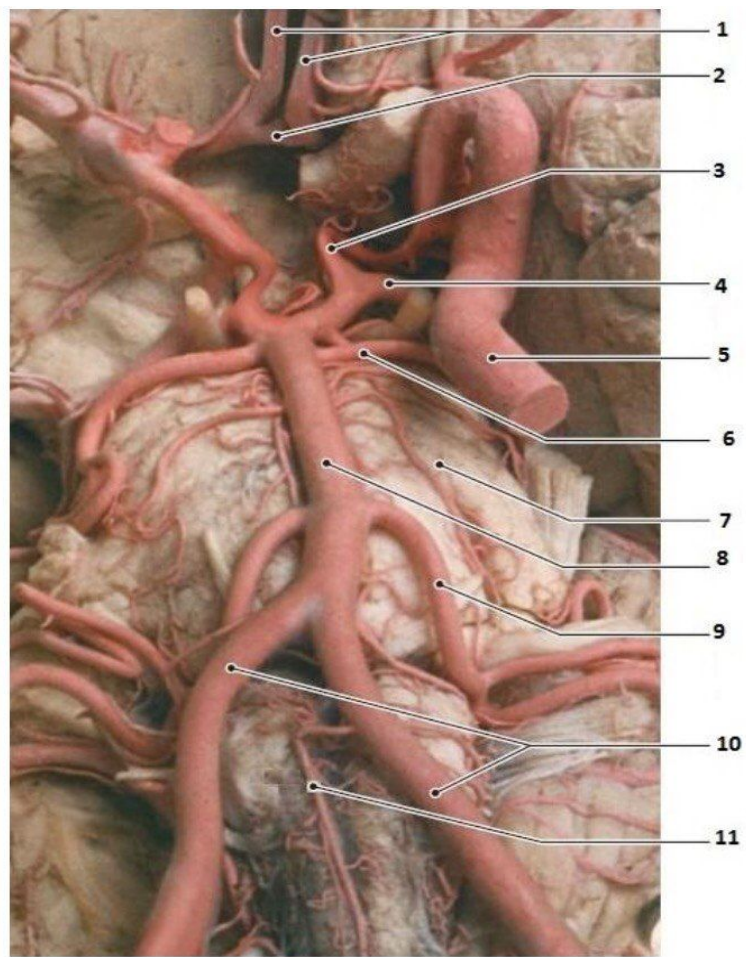
- arteria cerebellaris inferior posterior 1
- arteria spinalis posterior 2
- arteria vertebralis 3
- arteria medullaris segmentalis 4
- arteria cervicalis profunda 5
- arteria cervicalis ascendens 6
- arteria subclavia 7
- arteria intercostalis posterior 8
- arteria lumbalis 9
- arteria sacralis lateralis et media 10

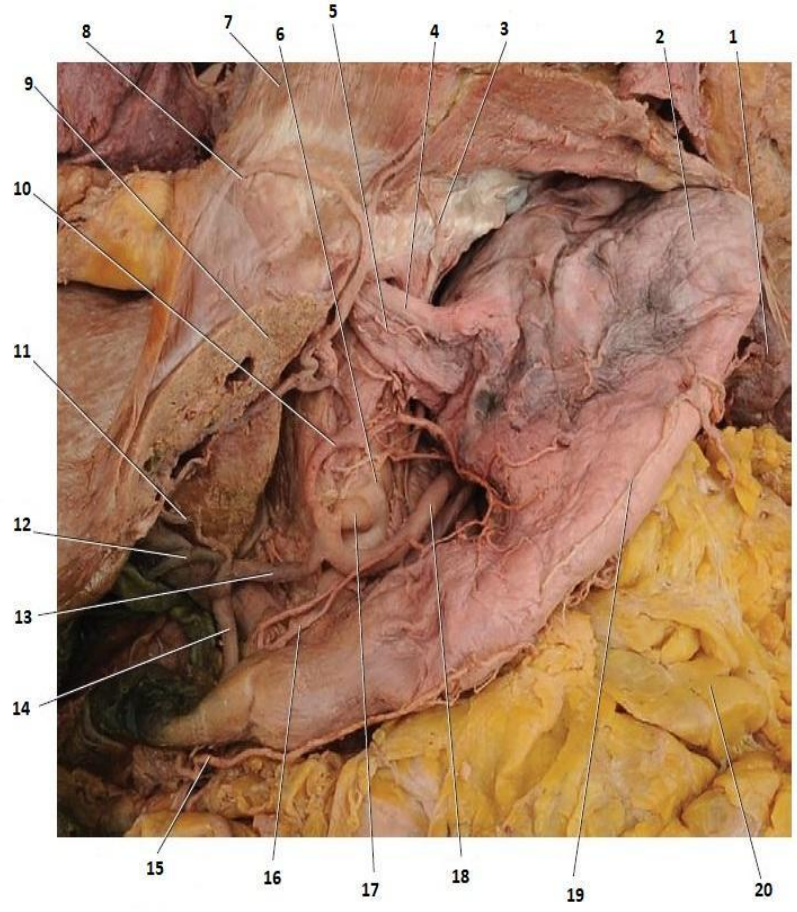


- arteria cerebri anterior sinistra 1
- arteria cerebri anterior dextra 2
- arteria communicans anterior 3
- arteria cerebri media 4
- arteria communicans posterior 5
- arteria cerebri posterior 6
- arteria basilaris 7
- arteria vertebralis 8



- arteria cerebri anterior 1
- arteria cerebri media 2
- arteria communicans posterior 3
- arteria cerebri posterior 4
- arteria carotis interna 5
- arteria cerebellaris superior 6
- arteria pontis 7.
- arteria basilaris 8.
- arteria cerebelli inferior anterior 9.
- arteria vertebralis 10.
- arteria spinalis anterior 11.





- aorta abdominalis 6
- arteria cystica 11
- arteria hepatica propria 12
- arteries oesophagus 5
- arteria gastrica sinistra 10
- Gepar 9
- arteria gastroduodenalis 14
- Gaster 2
- Splén 1
- arteria phrenica inferior sinistra 3
- Oesophagus 4
- Diafragma 7
- arteria phrenica inferior dextra 8
- arteria hepatica communis 13
- arteria gastroepiploica dextra 15
- omentum majus 20
- arteria gastrica dextra 16
- arteria gastrica dextra 17
- arteria lienalis 18
- arteria gastroepiploica sinistra 19

arteria colica media 3

arteria et vena colica dextra 4

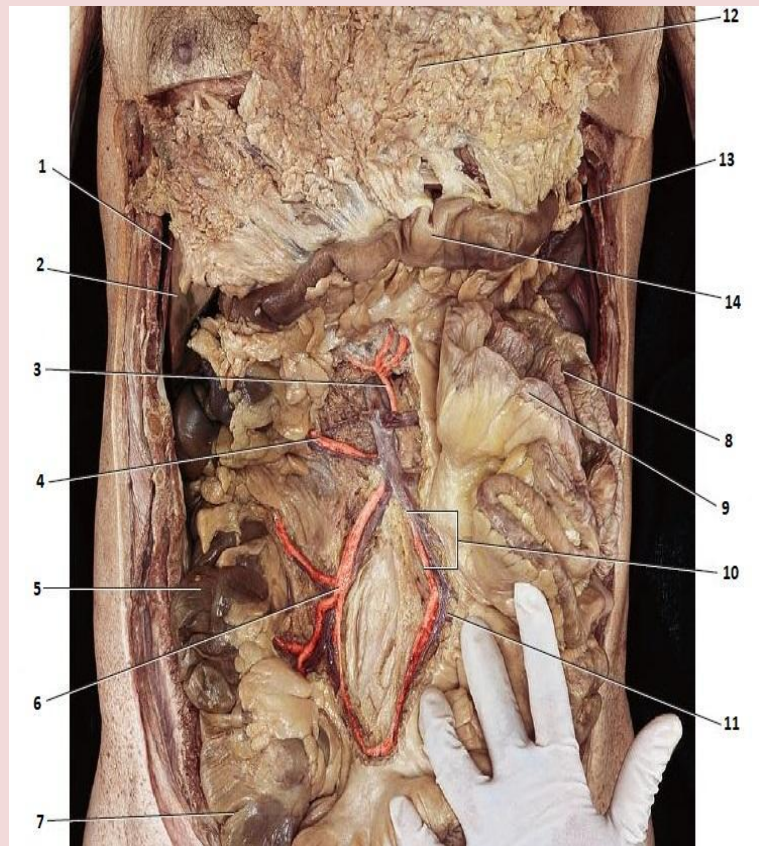
arteria et vena ileocolica 6

colon ascendens 5

Diafragma 1

Gepar 2

Cecum 7



colon descendens 8

arteria et vena mesenterica superior 10

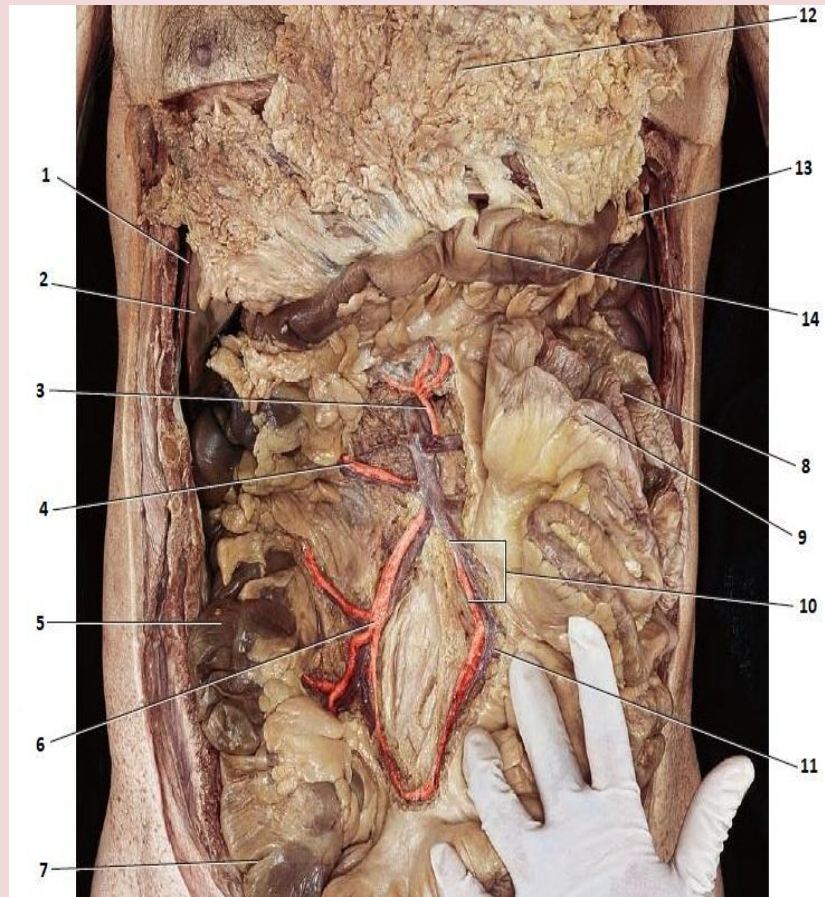
omentum majus 12

flexura coli sinistra 13

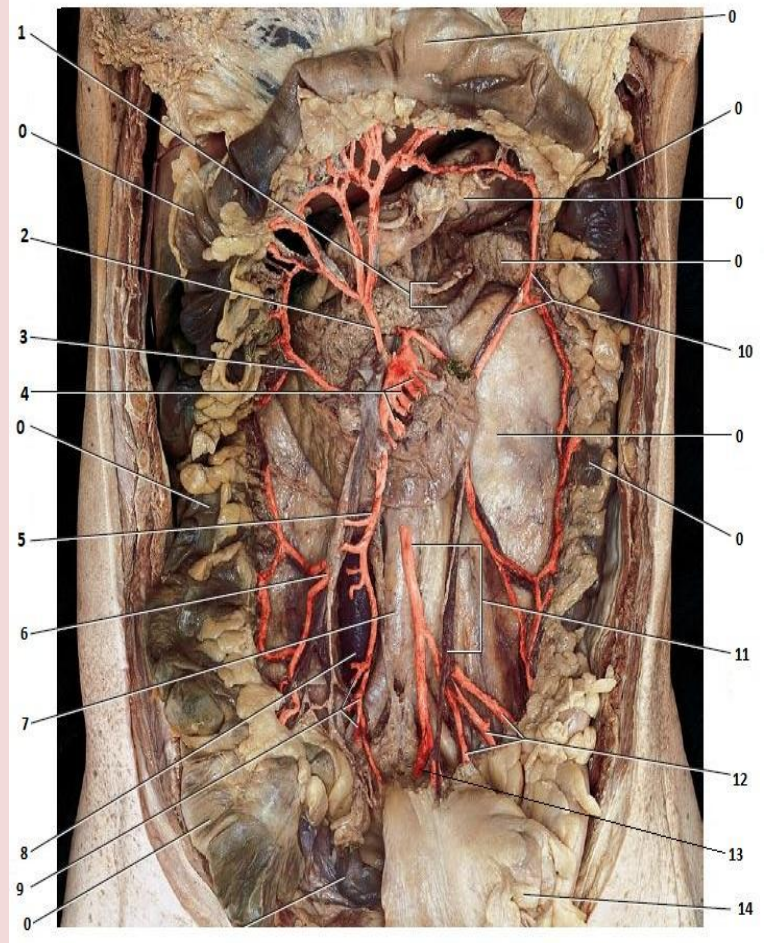
Jejunum 9

arteria intestinalis 11

colon transversum 14



- arteria marginalis coli 10
- arteria mesenterica inferior 11
- arteria ileum 9
- colon sigmoideum 14
- arteria rectalis superior 13
- arteria sigmoidea 12



arteria ileocolica 6

vena cava inferior 8

arteria ejunalis 4

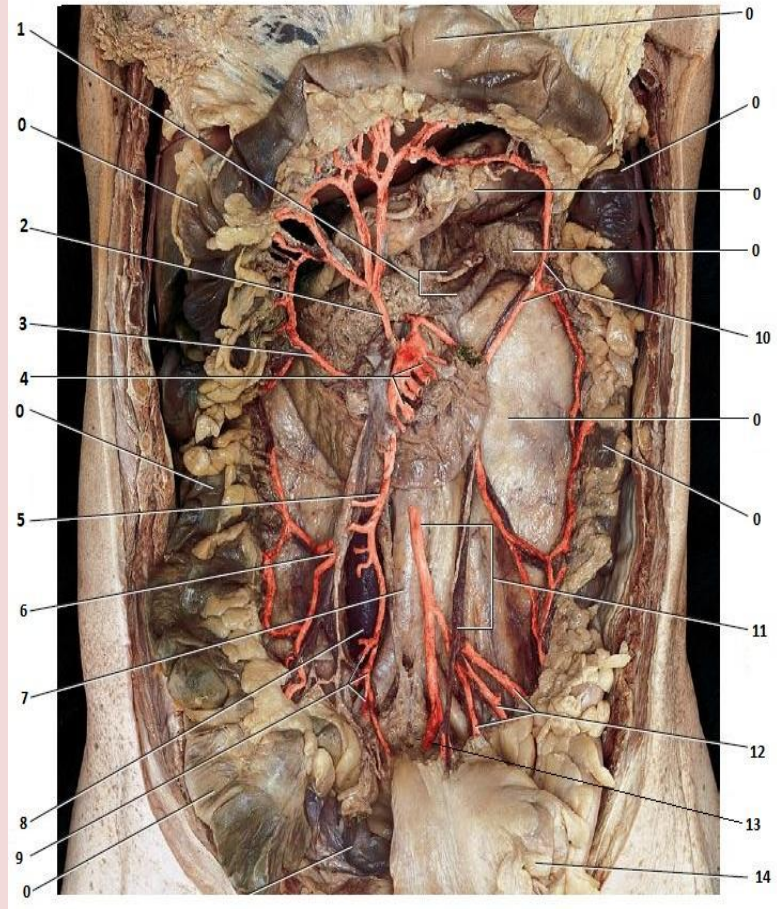
Aorta 7

arteria colica media 2

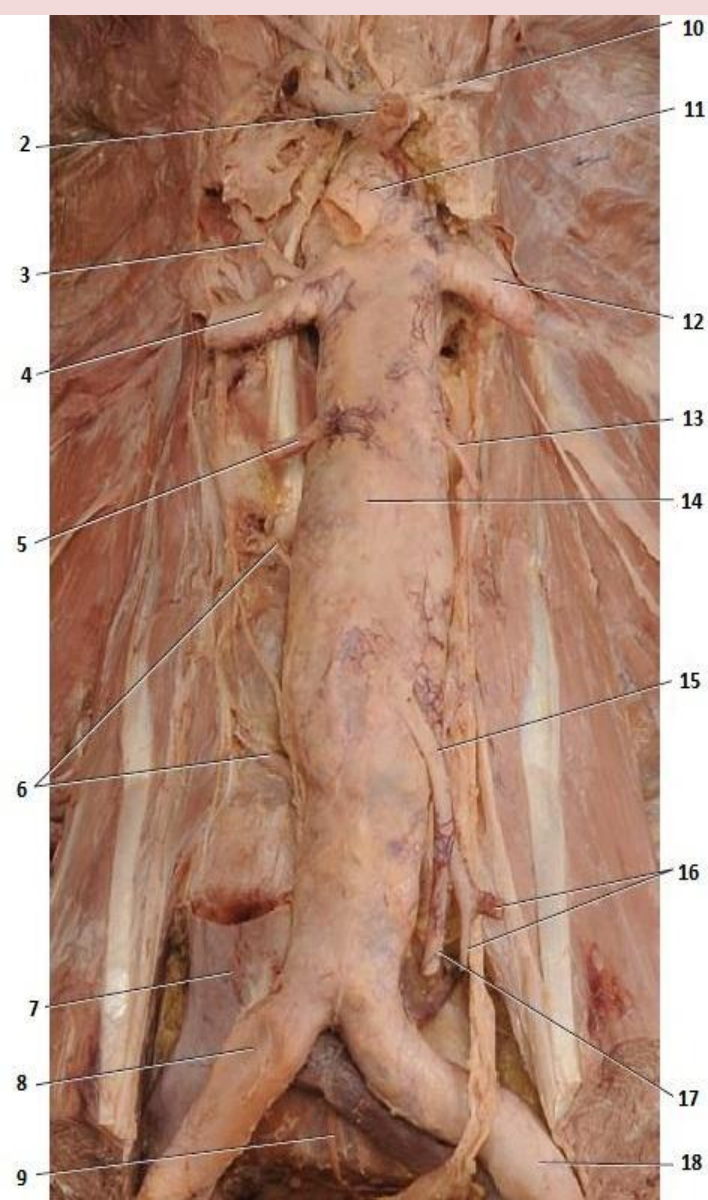
arteria et vena colica dextra 3

arteria et vena lienalis 1

arteria et vena mesenterica superior 5

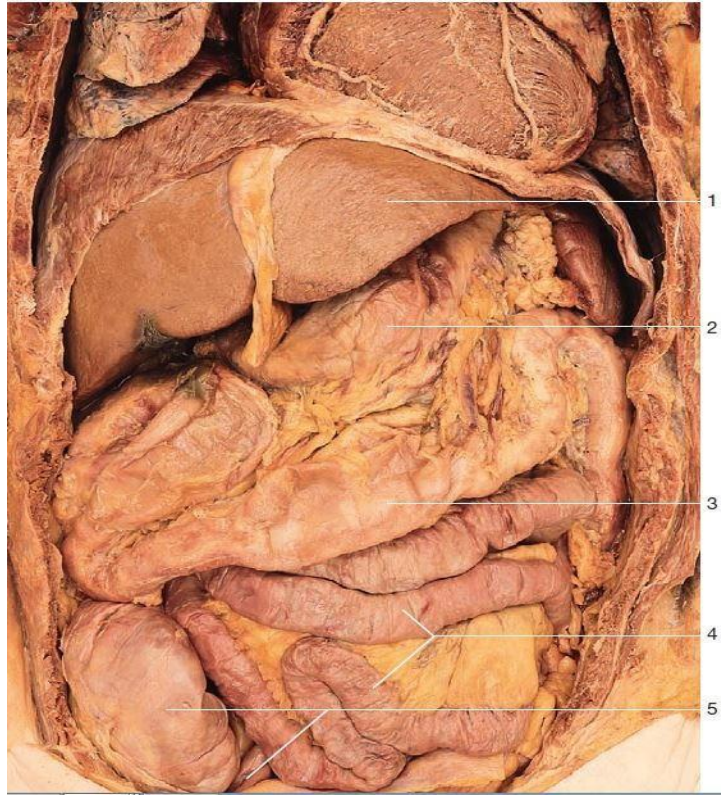


truncus celiacus 2
 arteria renalis sinistra 12
 arteria iliaca communis dextra 8
 arteria mesenterica inferior 15
 arteria renalis dextra 4
 arteria rectalis superior 17
 aorta abdominalis 14
 arteria testicularis dextra 5
 arteria frenica inferior 1
 arteria iliaca communis sinistra 18
 arteria testicularis sinistra 13
 arteria lumbalis 6
 arteria suprarenalis media dextra 3
 arteria frenica inferior 10
 vena cava inferior 7
 arteria sacralis mediana 9
 arteria mesenterica superior 11
 arteria sigmoidea 16



Брюшин а

1	Hepar
2	Gaster
3	Colon transversum
4	Intenstinum tenue
5	Caecum et appendix



arteria et vena mesenterica superior 2

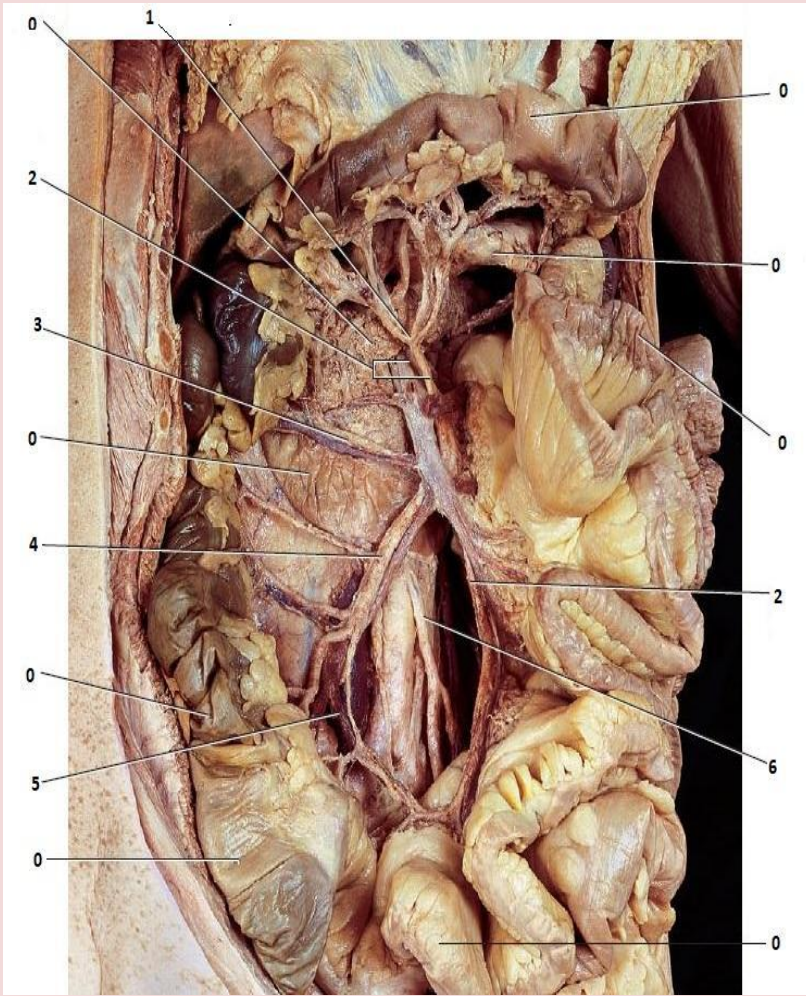
arteria colica media 1

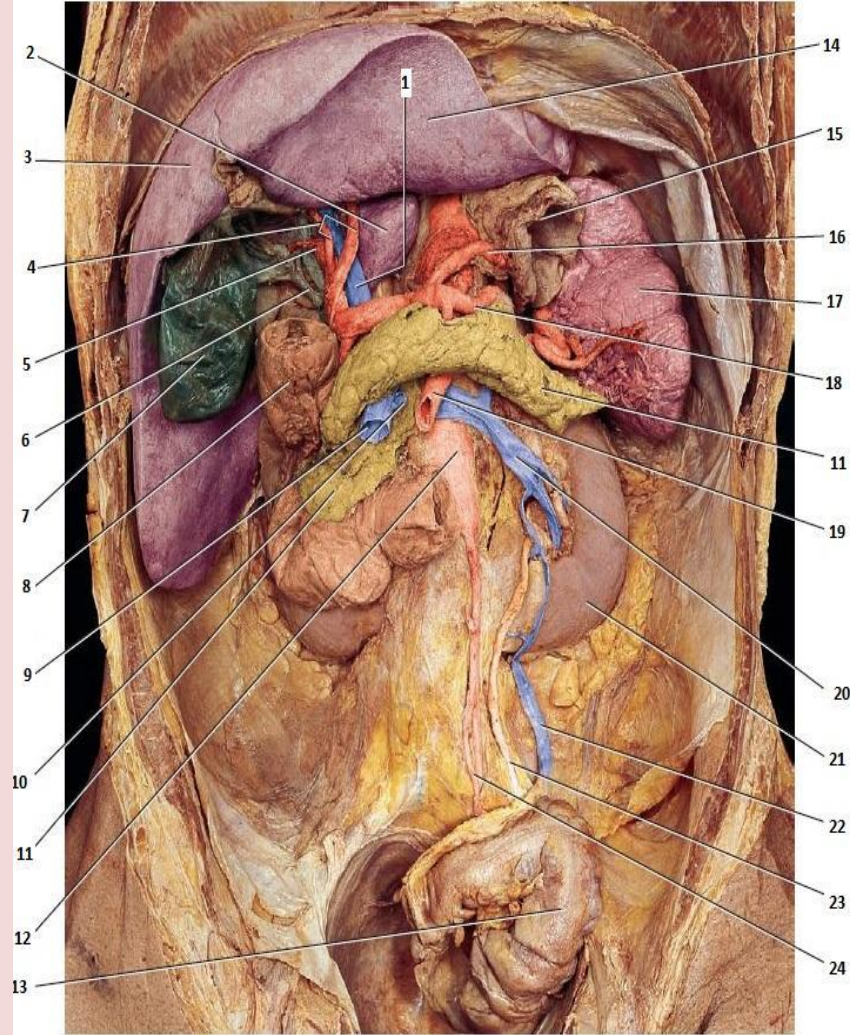
vena cava inferior 5

arteria mesenterica inferior 6

arteria et vena colica dextra 3

arteria et vena ileocolica 4





vena portae 1

Aorta 12

lobus dexter 3

vena mesenterica superior 9

arteria hepatica dextra et sinistra 4

lobus caudatus 2

colon sigmoideum 13

ductus cysticus 6

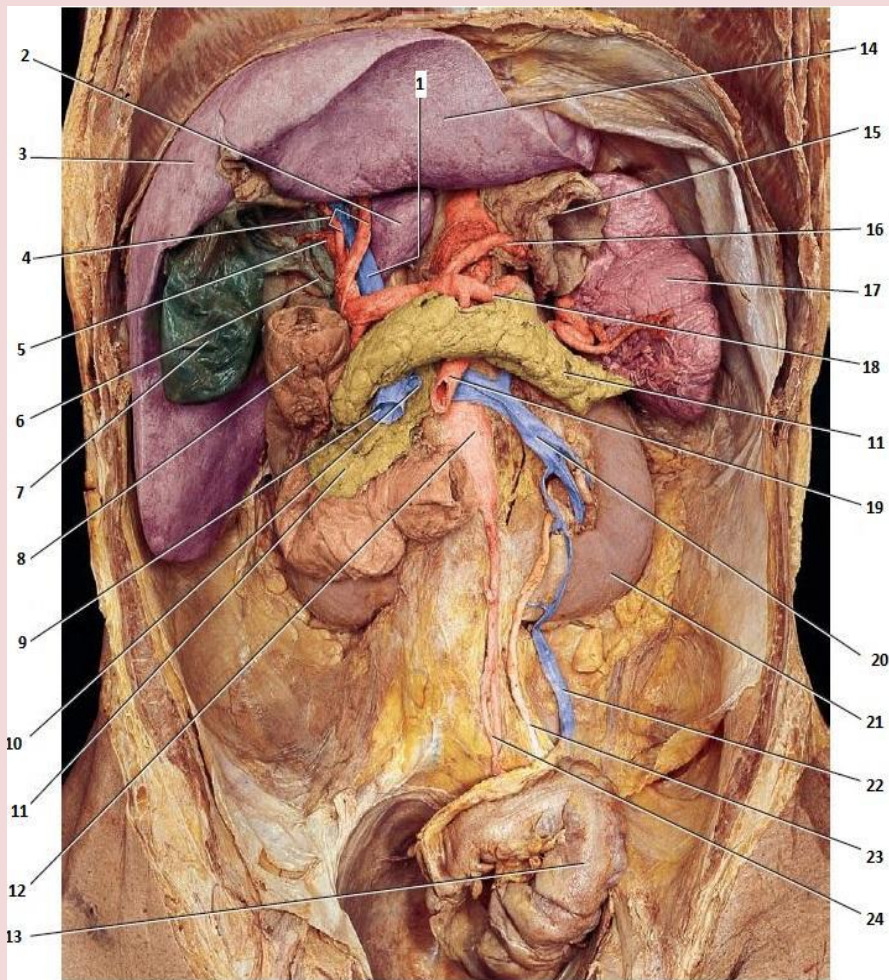
Duodenum 8

arteria cistica 5

vesica fellea 7

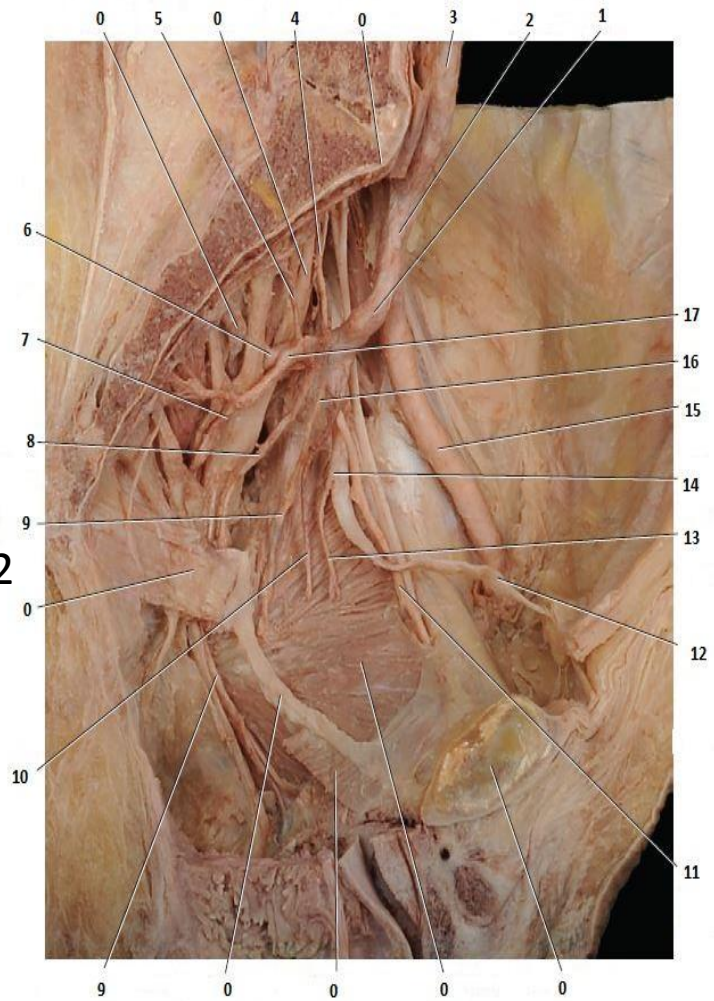
vena lienalis 10

Pancreas 11



- arteria mesenterica superior 19
- lobus sinister 14
- vena testicularis sinistra 22
- ren sinister 21
- arteria gastrica sinistra 16
- Pancreas 11
- arteria mesenterica inferior 24
- Gaster 15
- Lien 17
- arteria lienalis 18
- vena renale sinistra 20
- ureter sinister 23

- a iliaca interna 1
- arteria pudenda interna 8
- arteria iliolumbalis 4
- arteria glutea inferior 6
- arteria uterina 10
- arteria glutea superior 7
- arteria sacralis lateralis 5
- a iliaca communis 2
- aorta abdominalis 3
- arteria rectalis media 9
- ligamentum umbilicale mediale 12
- arteria obturatoria 11
- arteria vesicalis superior 13
- arteria umbilicalis 14
- arteria iliaca externa 15
- arteria iliaca interna truncus anterior 16
- arteria iliaca interna truncus posterior 17



musculus piriformis 16

musculus gracilis 22

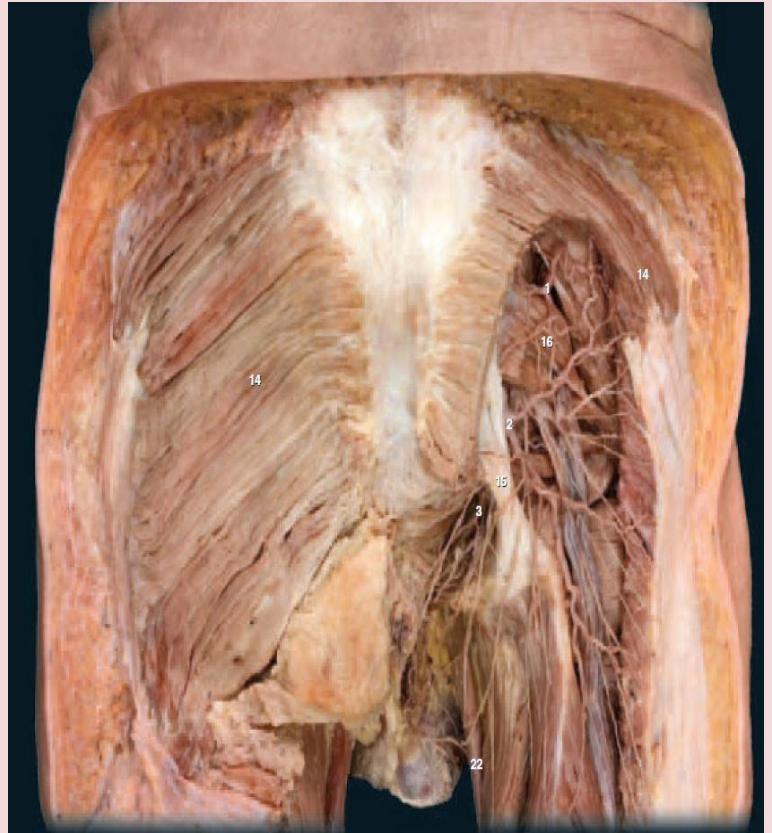
arteria glutea superior 1

ligamentum sacrotuberale 15

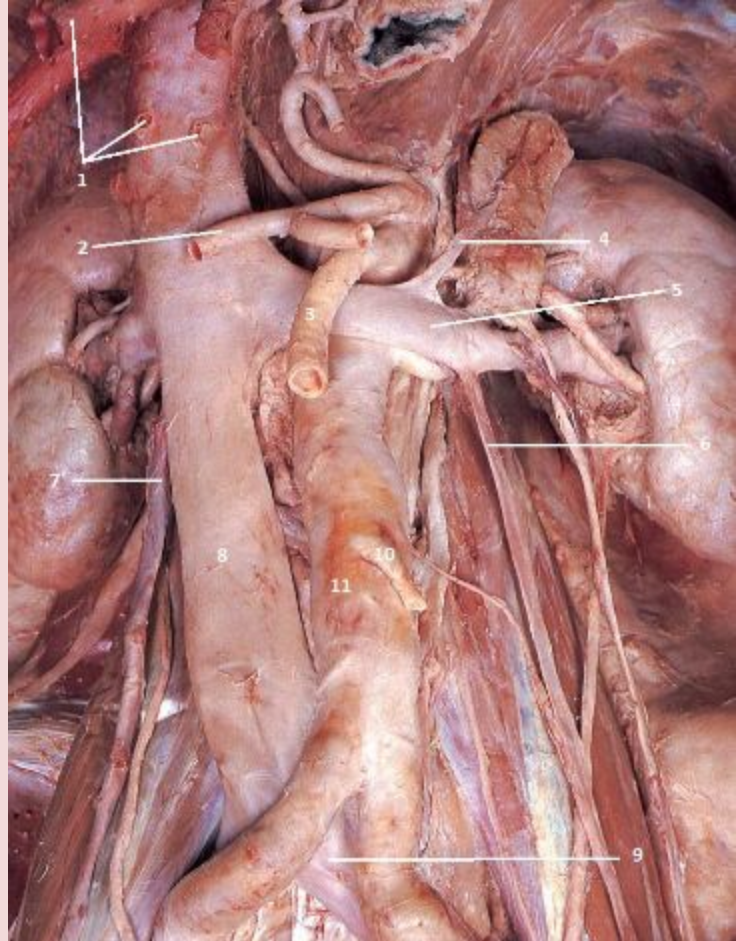
musculus gluteus maximus 14

arteria glutea inferior 2

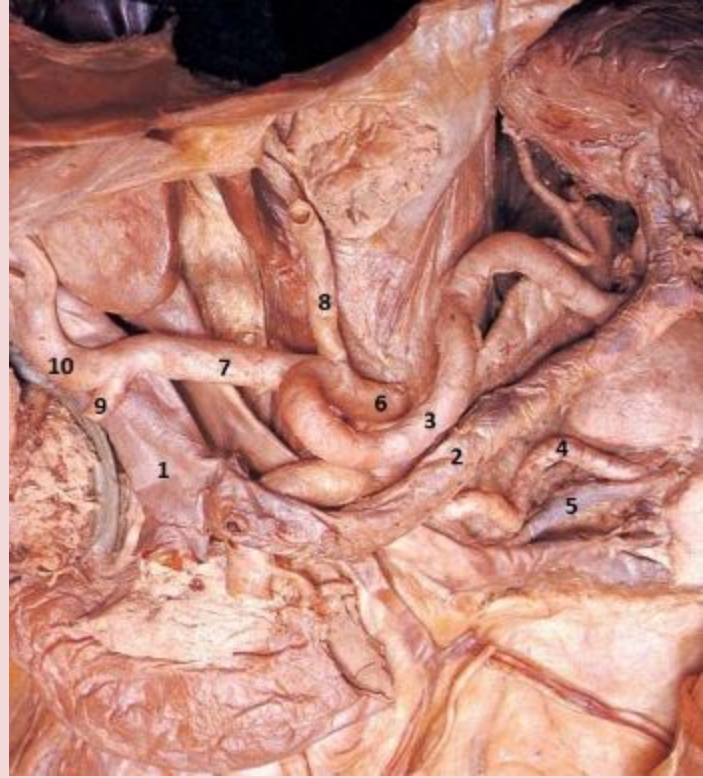arteria pudenda interna 3



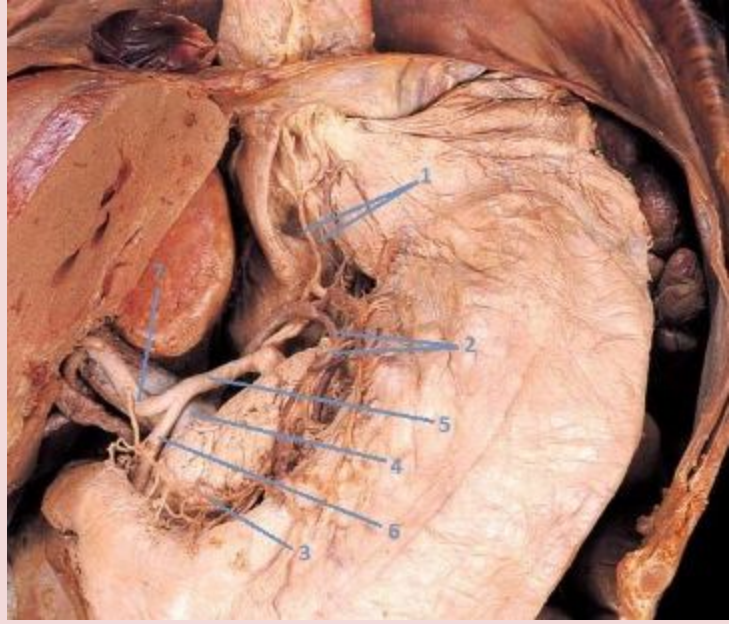
vena renale sinistra 5
vena cava inferior 8
arteria mesenterica superior 3
vena testicularis dextra 7
Aortae 11
arteria hepatica 2
vena hepatica 1
vena suprarenale 4
vena testicularis sinistra 6
vena iliaca communis 9
arteria mesenterica inferior 10

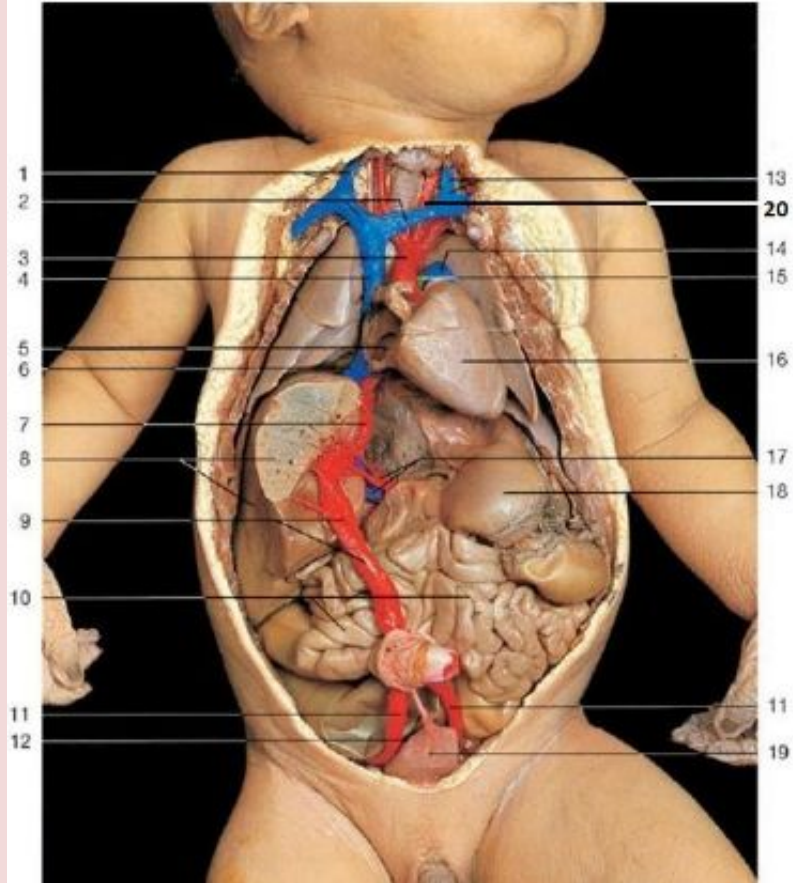


- arteria hepatica communis 7
- arteria gastrica sinistra 8
- arteria hepatica propria 10
- arteria mesenterica superior 4
- vena lienalis 2
- vena porta 1
- arteria lienalis 3
- vena mesenterica superior 5
- truncus coeliacus 6
- arteria gastroduodenalis 9



- arteria et vena gastrica sinistra 2
- arteria gastroduodenalis 6
- arteria gastrica dextra 3
- arteria hepatica propria 7
- arteria et vena oesophageales 1
- vena porta 4
- arteria hepatica communis 5

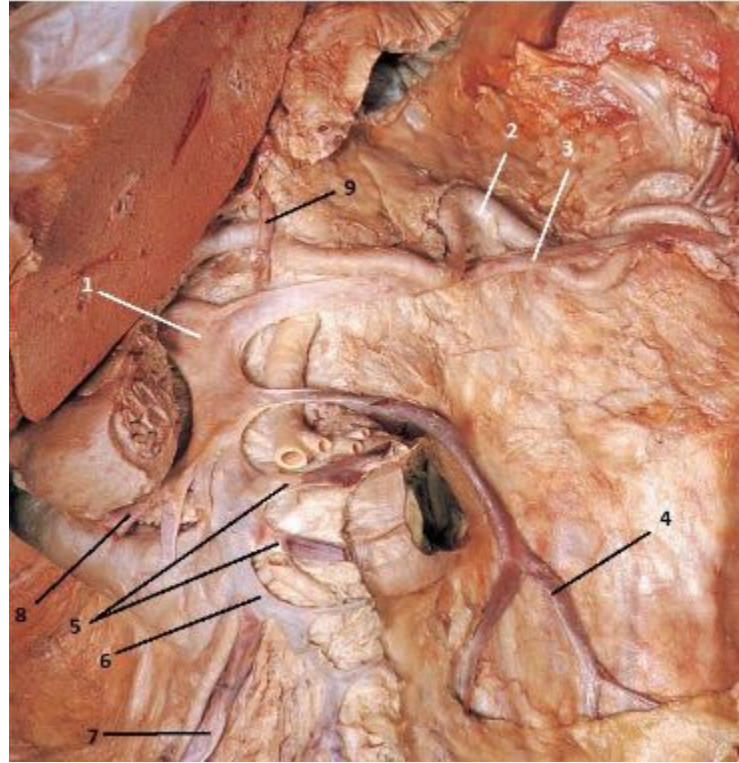




vesica urinaria 19
 arteria umbilicalis 11
 arteria carotis communis 20
 arteria pulmonalis sinistra 14
 vena jugularis interna sinistra 13
 Urachus 12
 ductus arteriosus 15
 ventriculus dexter 16
 arteria hepatica et vena porta 17
 Gaster 18

vena cava superior 4
 arcus aortae 3
 Hepar 8
 intestinum tenue 10
 vena umbilicalis 9
 vena brachiocephalica dextra et
 sinistra 2
 foramen ovale 5
 vena jugularis interna dextra 1
 vena cava inferior 6
 ductus venosus 7

- vena jejunales 5.
- vena colica dextra 8
- vena gastrica sinistra 9.
- vena ileocolica 7
- vena mesenterica inferior 4.
- arteria lienalis 2.
- vena lienalis 3.
- vena portae 1.
- vena colica media 6



Aorta 4

truncus coeliacus 7

arteria testicularis 5

arteria renale 8

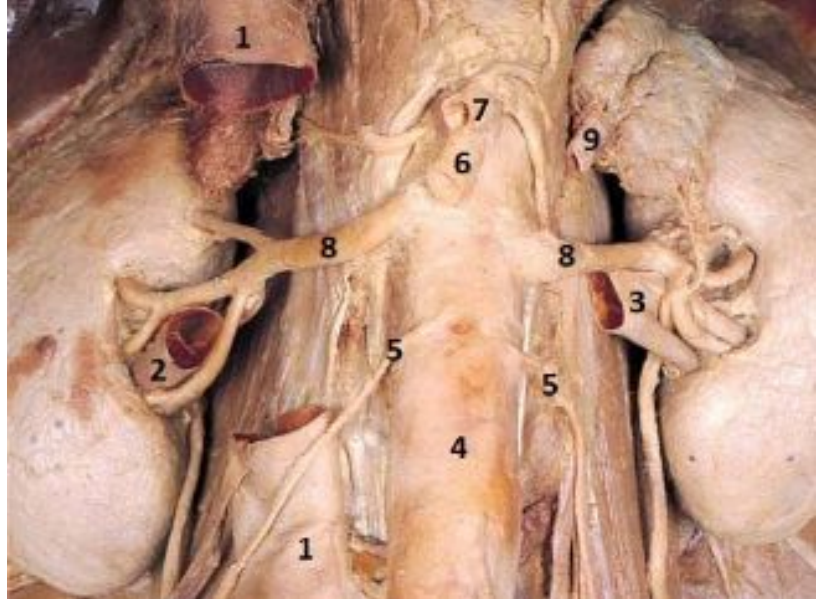arteria mesenterica superior 6

vena suprarenale 9

vena cava inferior 1

vena renale dextra 2

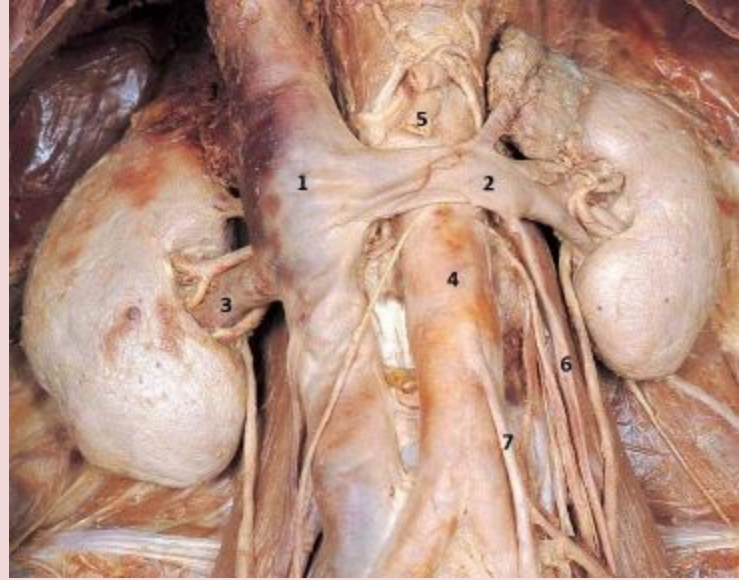
vena renale sinistra 3



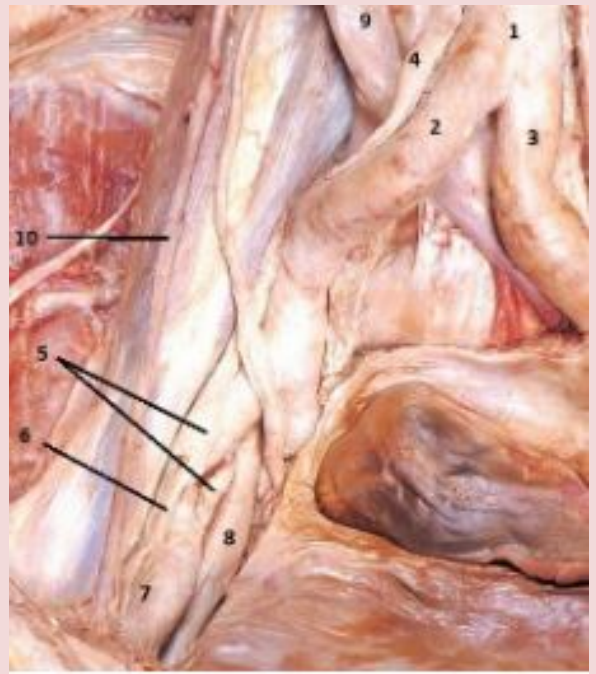8

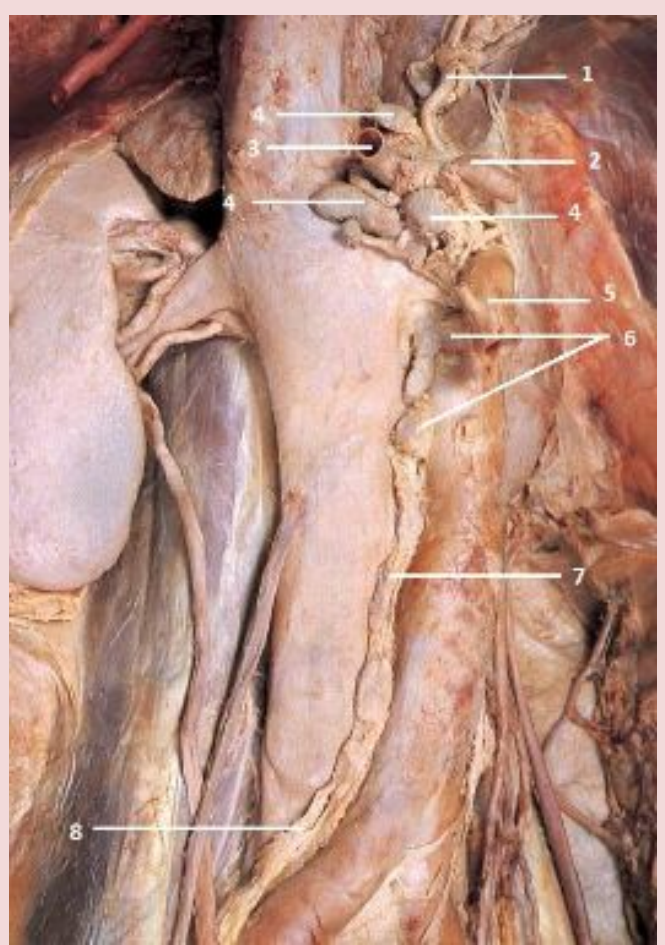
из 9

arteria mesenterica superior 5
vena testicularis 6
vena renale dextra 3
vena renale sinistra 2
vena cava inferior 1
Aorta 4
arteria mesenterica inferior 7



vena iliaca externa 8
nodus lymphaticus iliacus communis 4
arteria iliaca communis dextra 2
Aorta 1
vena testicularis 10
vasa efferentia iliaca externa 6
nodus lymphaticus iliacus externus 5
arteria iliaca communis sinistra 3
arteria iliaca externa 7
vena cava inferior 9





arteria lienalis 2

arteria gastrica sinistra 1

nodi lymphoidei mesenterici superiores 6

noduli lymphatici colici 4

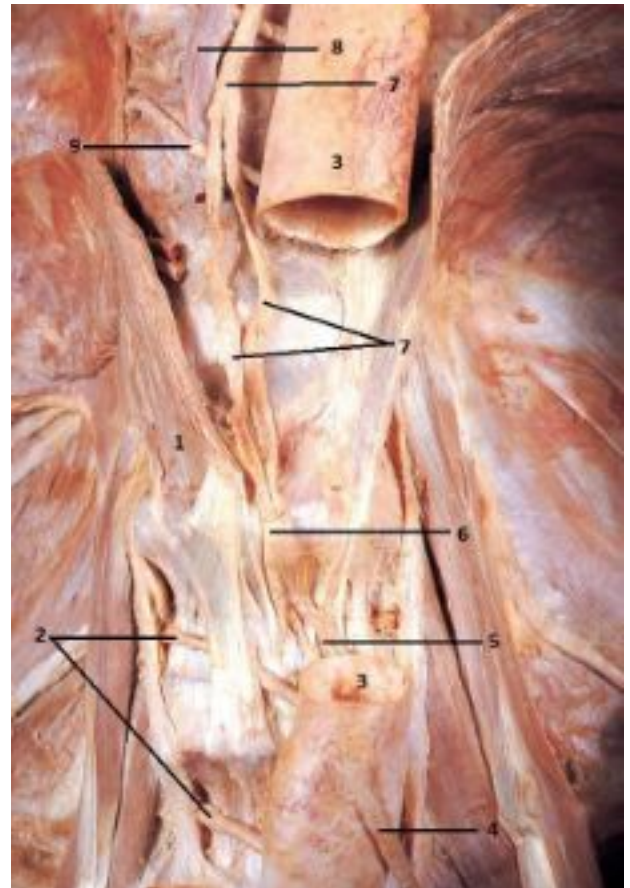
vasa efferentia iliaca externa 8

nodi lymphoidei aortici lateralis 7

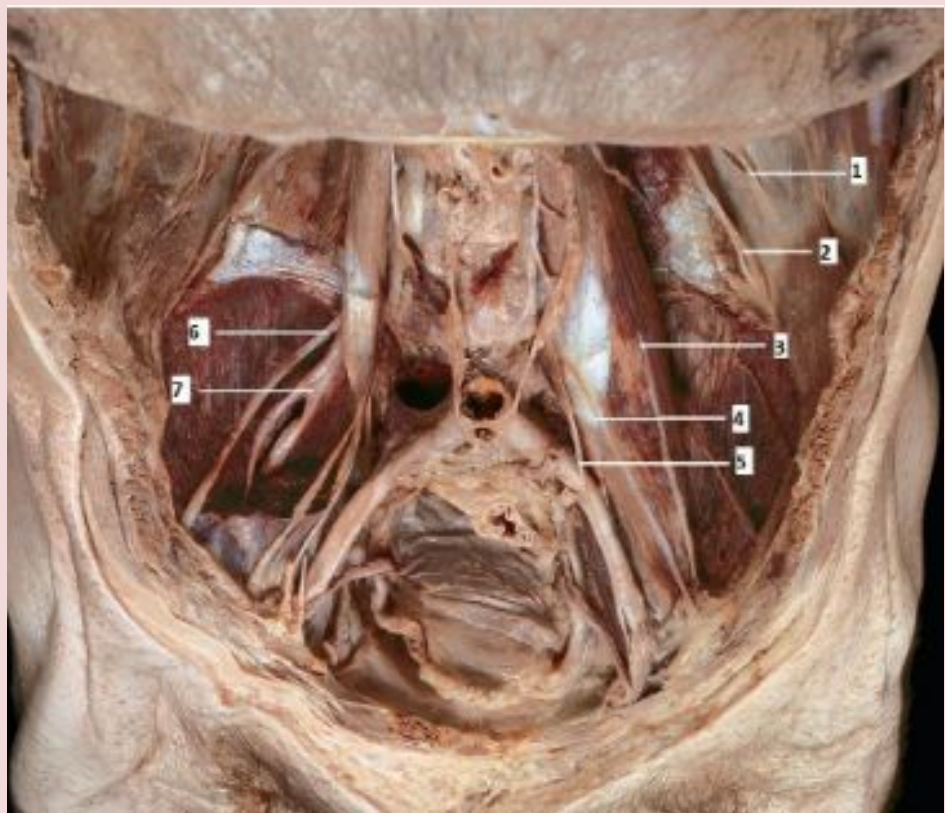
arteria hepatica communis 3

arteria mesenterica superior 5

truncus lumbalis 5
vena azygos 8
aorta abdominalis 3
arteria intercostalis posterior 9
ductus thoracicus 7
arteria lumbalis 2
crus dexterum diaphragmatis 1
aorta abdominalis 3
cisterna chyli 6



8
и3 9



nervus iliohypogastricus 1

nervus obturatorius 5

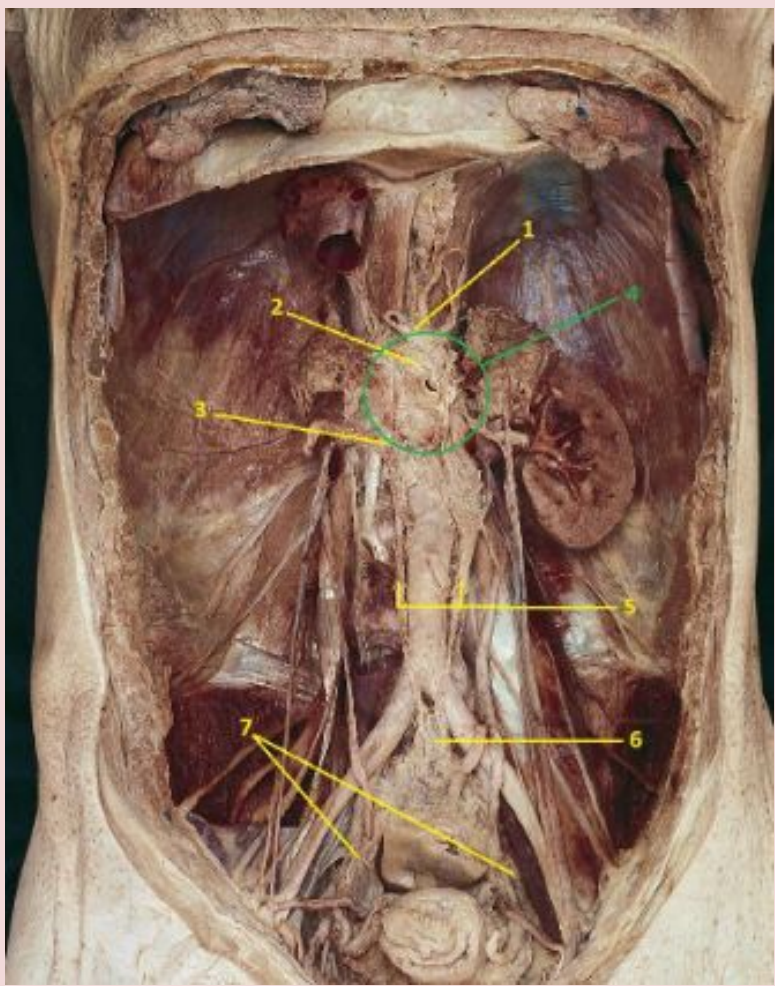
ramus femoralis nervus genitofemoralis 4

nervus cutaneus femoris lateralis 6

nervus femoris 7

nervus ilioinguinalis 2

ramus genitalis nervus genitofemoralis 3



plexus hypogastricus inferior 7

ganglion coeliacum 1

plexus coeliacus et plexus mesentericus superior 4

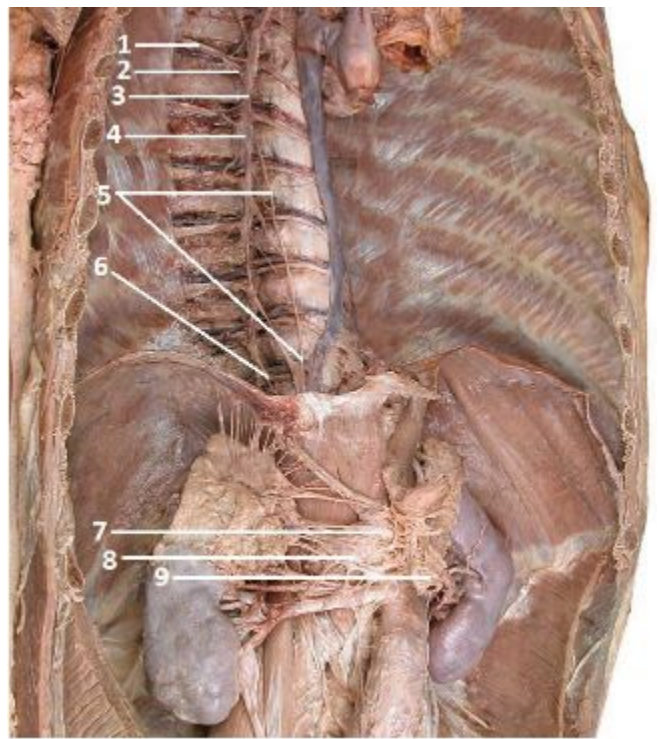
ganglion aorticorenale 3

ganglion mesentericum superior 2

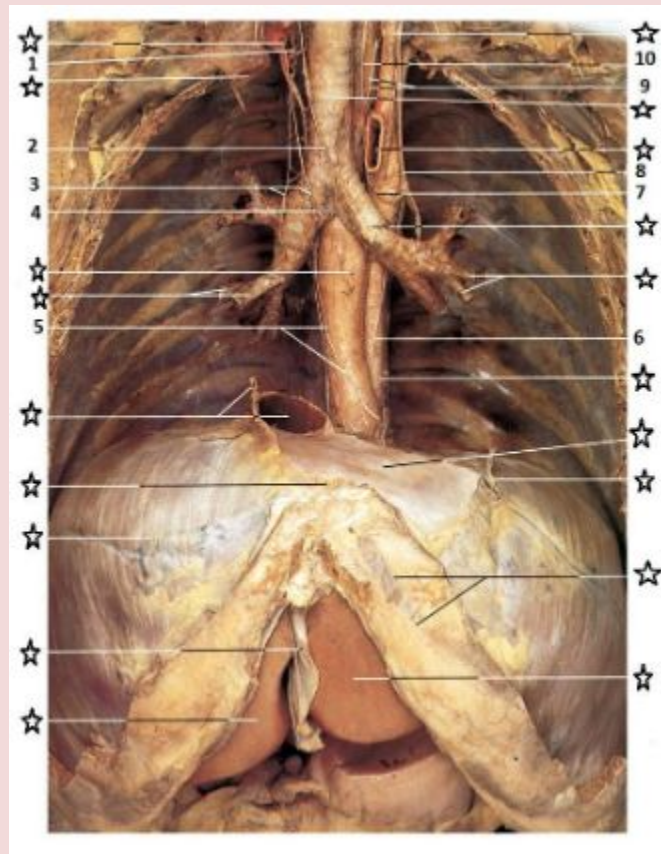
nervus hypogastricus 5

plexus hypogastricus superior 6

ganglion mesentericum superior 9
ganglion coeliacum 7
nervus splanchnicus major 5
nervus splanchnicus minor 6
ramus anterior nervi spinalis 2
ramus communicans albus 1
truncus sympathicus 3
ganglion truncus sympathicus 4
ganglion aorticorenale 8

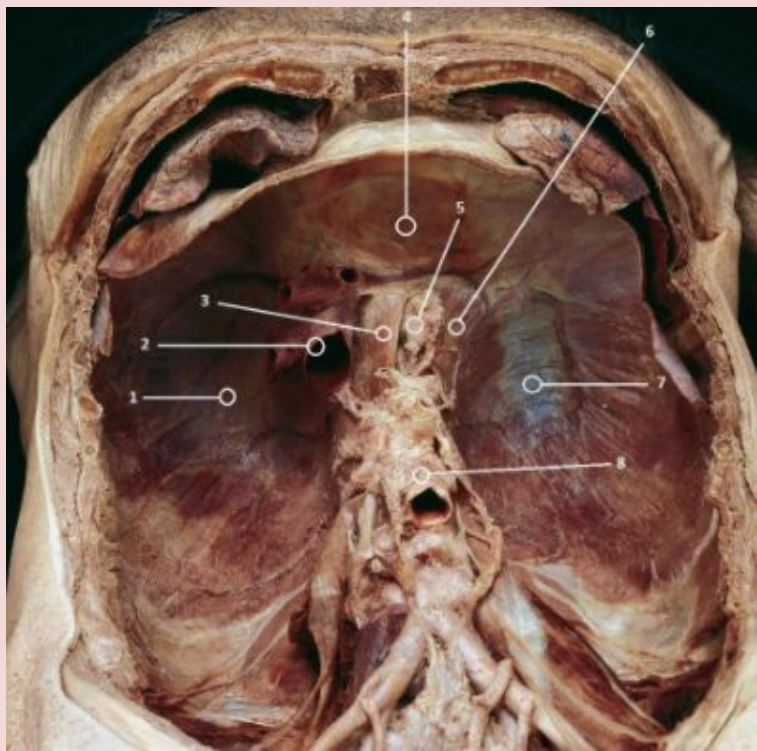


7
из 9

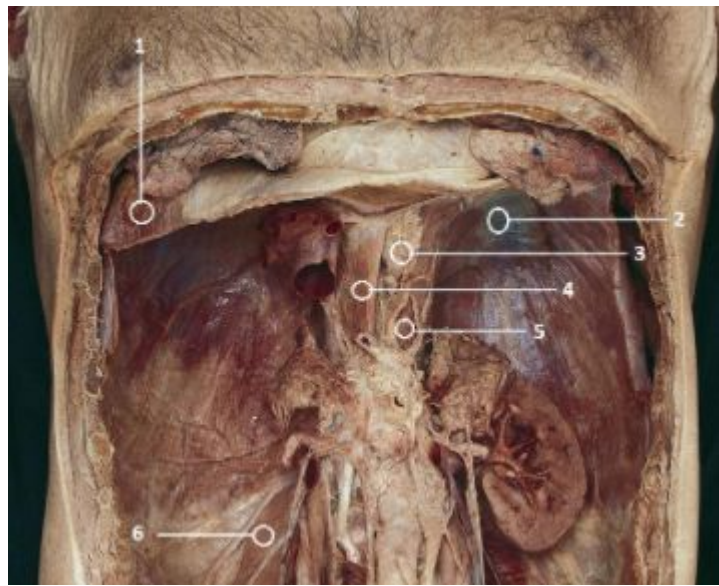


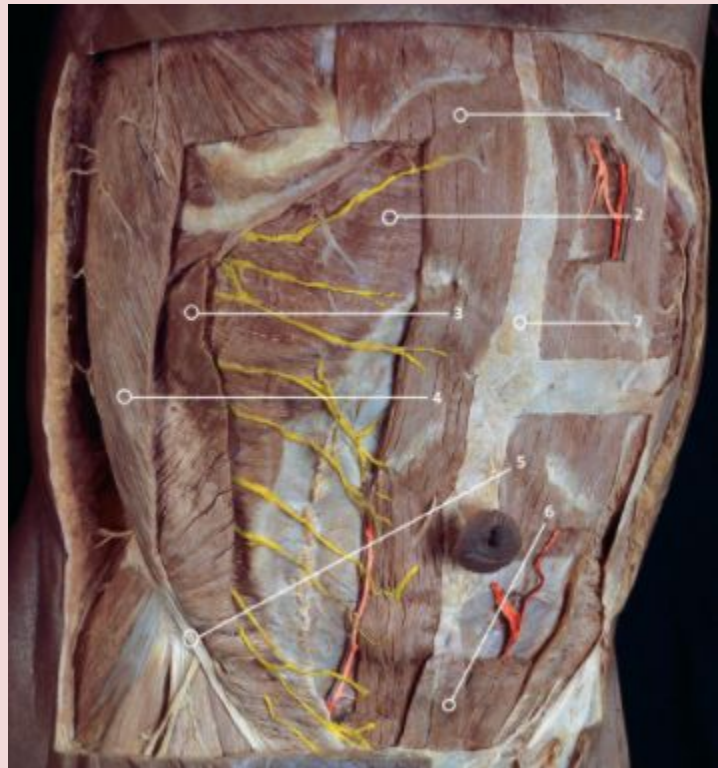
- nervus vagus sinister 8
- nervus vagus sinister 8
- nervus laryngeus recurrens 7
- plexus pulmonalis 4
- nervus cardiacus cervicalis inferior 3
- ramus oesophageus nervus vagus sinister 6
- nervus cardiacus cervicalis superior 2
- nervus laryngeus recurrens dexter 1
- plexus oesophageus 9
- nervus laryngeus recurrens sinister 10

centrum tendineum 4
foramen vena cava diaphragm 2
hiatus oesophageus 5
правый купол диафрагмы 1
crus sinistrum diaphragm 6
crus dextrum diaphragm 3
левый купол диафрагмы 7
hiatus aorticus 8



crus dextrum diaphragm 4
musculus phrenicus 1
crus sinistrum diaphragm 5
musculus quadratus lumborum 6
hiatus aorticus 3
centrum tendineum 2



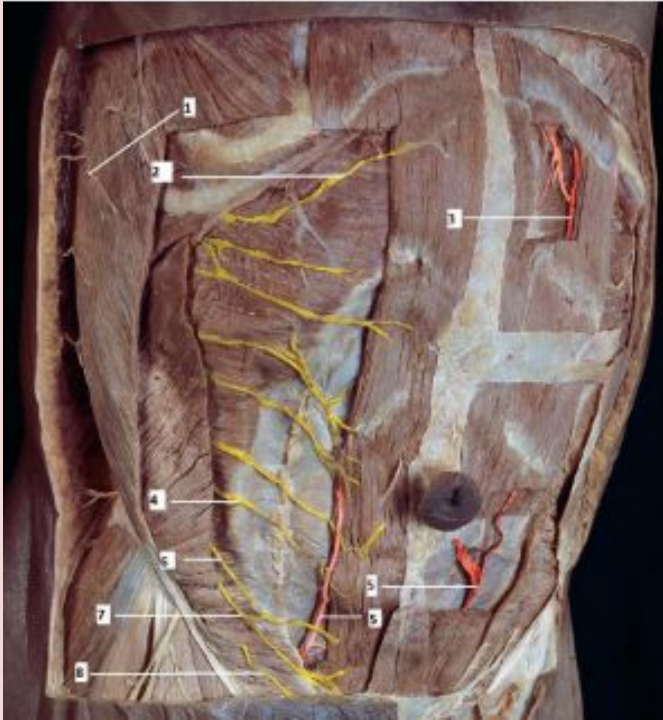


- musculus obliquus abdominis internus 3
- musculus rectus abdominis 1
- musculus obliquus abdominis externus 4
- ligamentum inguinale 5
- musculus transversus abdominis 2
- musculus pyramidalis 6
- linea alba 7

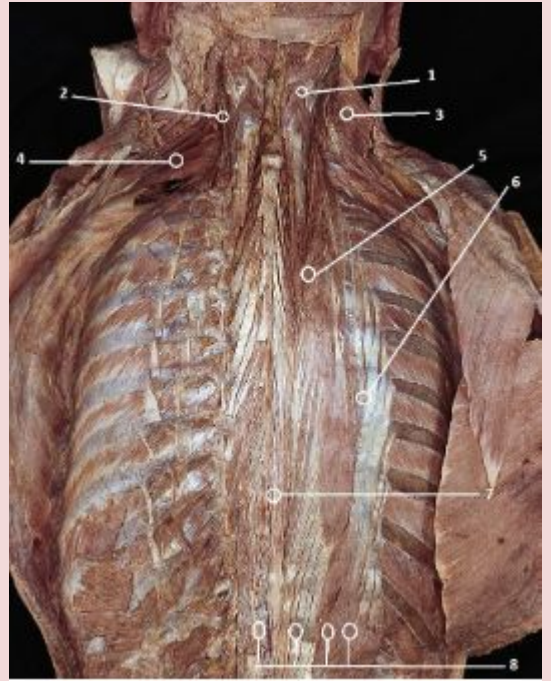
- nervi intercostales Th6 2
- nervi intercostales Th11 4
- nervus iliohypogastricus 7
- arteria epigastrica inferior 5

- ramus cutaneus lateralis pectoralis
- nervi intercostales 1

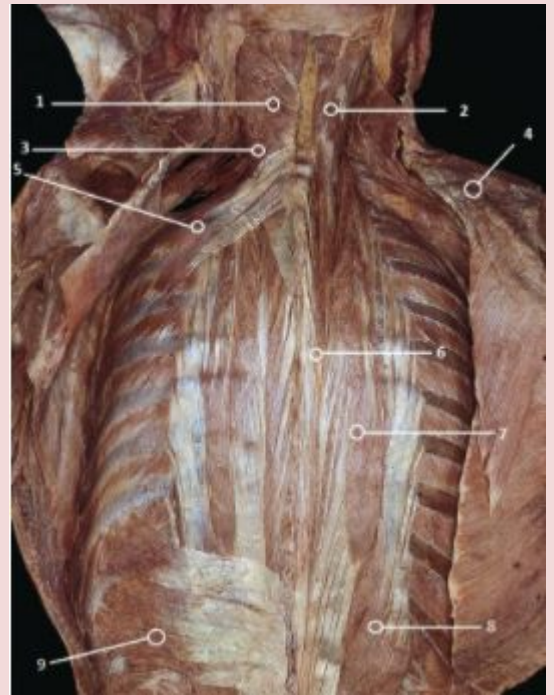
- arteria epigastrica superior 3
- nervus subcostalis 6
- nervus ilioinguinalis 8



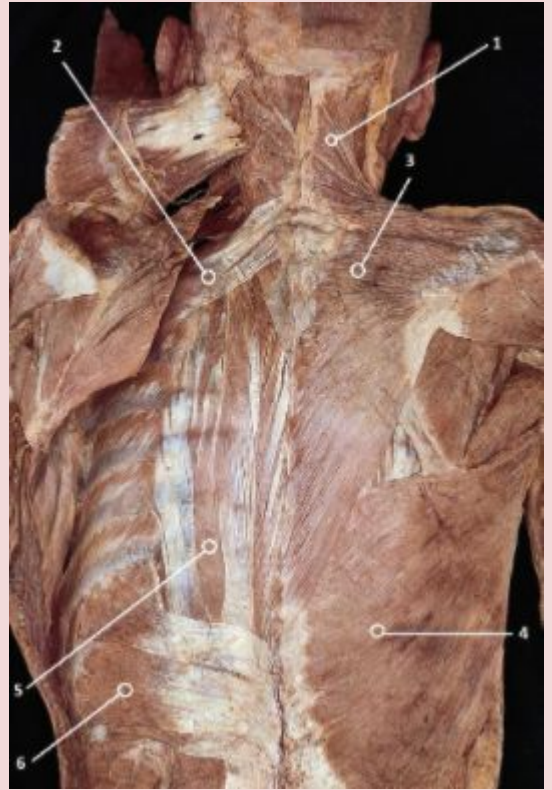- musculus semispinalis capitis 1
- musculus iliocostalis 6
- musculus erector spinae 8
- musculus spinalis 7
- musculus longissimus capitis 2
- musculus splenius capitis 3
- musculus levator scapulae 4
- musculus longissimus thoracis 5



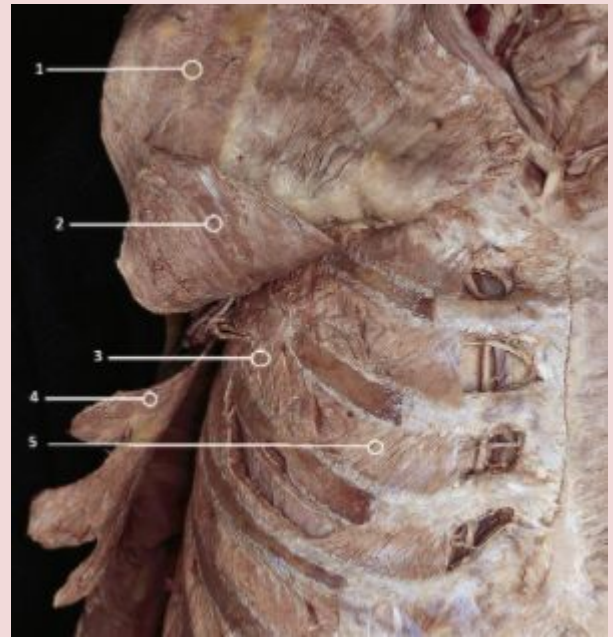
- musculus splenius capitis 2
- musculus iliocostalis 8.
- musculus semispinalis cervicis 3
- musculus semispinalis capitis 1
- musculus serratus posterior superior 5.
- musculus trapezius 4
- musculus spinalis 6.
- musculus longissimus 7.
- musculus serratus posterior inferior 9



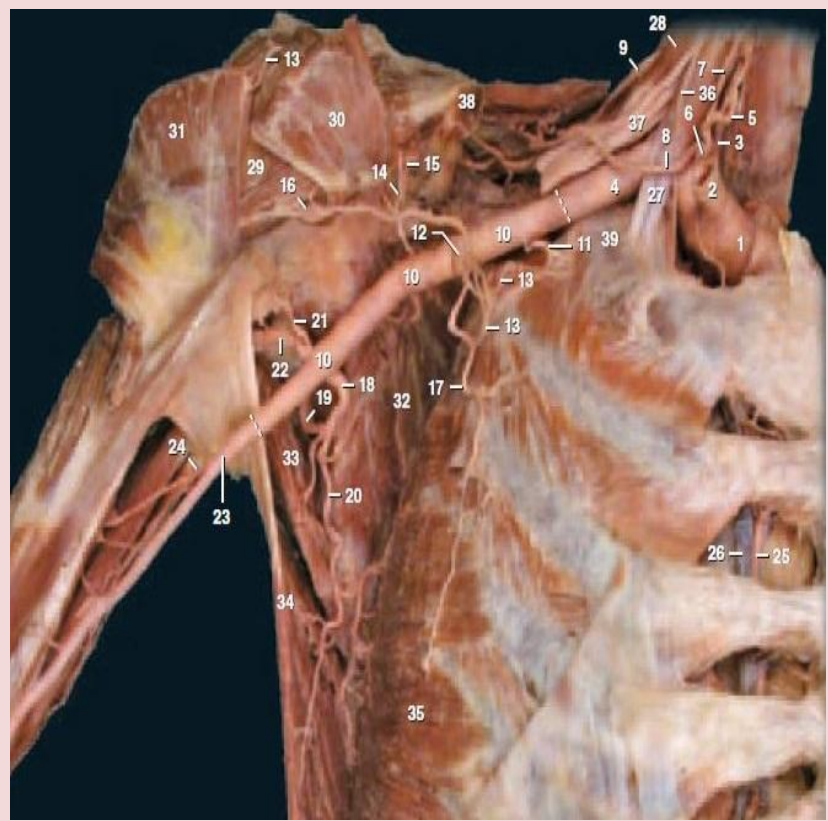
- musculus serratus posterior inferior 6
- musculus erector spinae 5
- musculus latissimus dorsi 4
- musculus trapezius 3
- musculus serratus posterior superior 2
- musculus splenius capitis 1

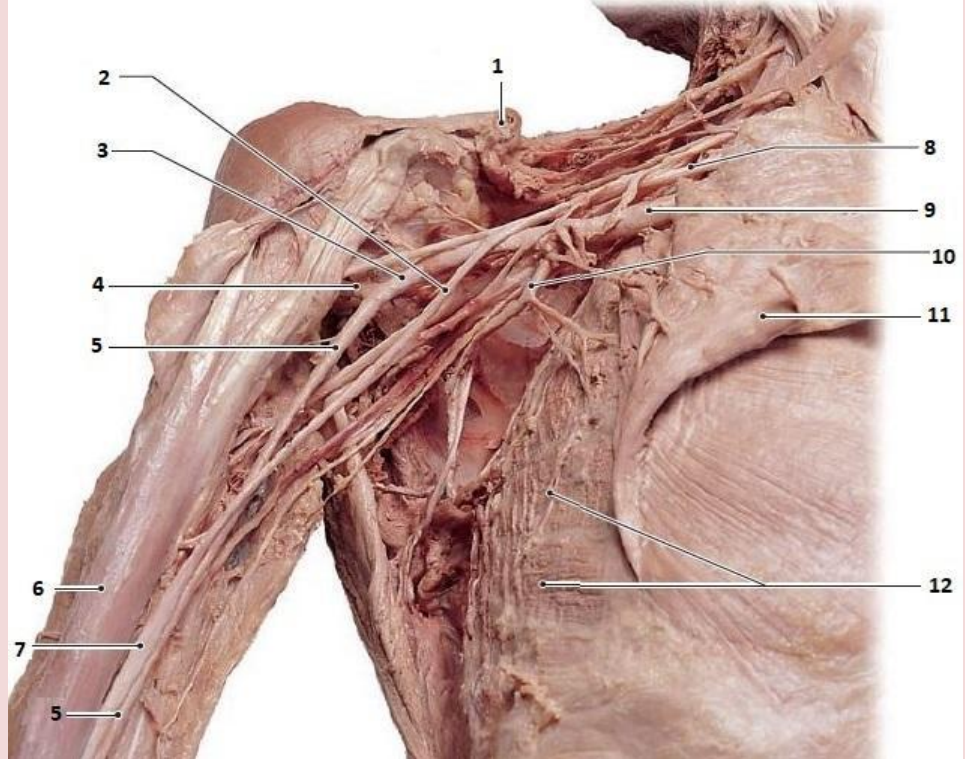


musculus pectoralis major 1
musculus intercostalis internus 5
musculus intercostalis externus 3
musculus pectoralis minor 2
musculus serratus anterior 4



- truncus brachiocephalicus 1
- arteria carotis communis 2
- arteria cervicalis ascendens 3
- arteria subclavia 4
- arteria thyroidea inferior 5
- truncus thyrocervicalis 6
- arteria vertebralis 7
- arteria suprascapularis 8
- arteria dorsalis scapulae 9
- arteria axillaris 10
- arteria thoracica superior 11
- arteria thoracoacromialis 12
- arteria pectoralis 13
- arteria acromialis 14
- arteria clavicularis 15
- arteria deltoidea 16
- arteria thoracica lateralis 17
- arteria subscapularis 18
- arteria circumflexa scapulae 19
- arteria thoracodorsalis 20
- arteria circumflexa humeri posterior 21
- arteria circumflexa humeri anterior 22
- arteria thoracica interna 25
- vena thoracica 26





- musculus serratus anterior 12
- arteria axillaris 3
- arteria subclavia 9
- musculus biceps brachii 6
- arteria subscapularis 10
- arteria profunda brachii 4
- Clavicula 1
- arteria brachialis 5
- musculus pectoralis major 11

musculus pectoralis major 1

ramus deltoideus arteria
thoracoacromialis 2

musculus biceps brachii 3

arteria brachialis 4

arteria thoracodorsalis 5

musculus pectoralis minor 6

ramus clavicularis arteria
Thoracoacromialis 7

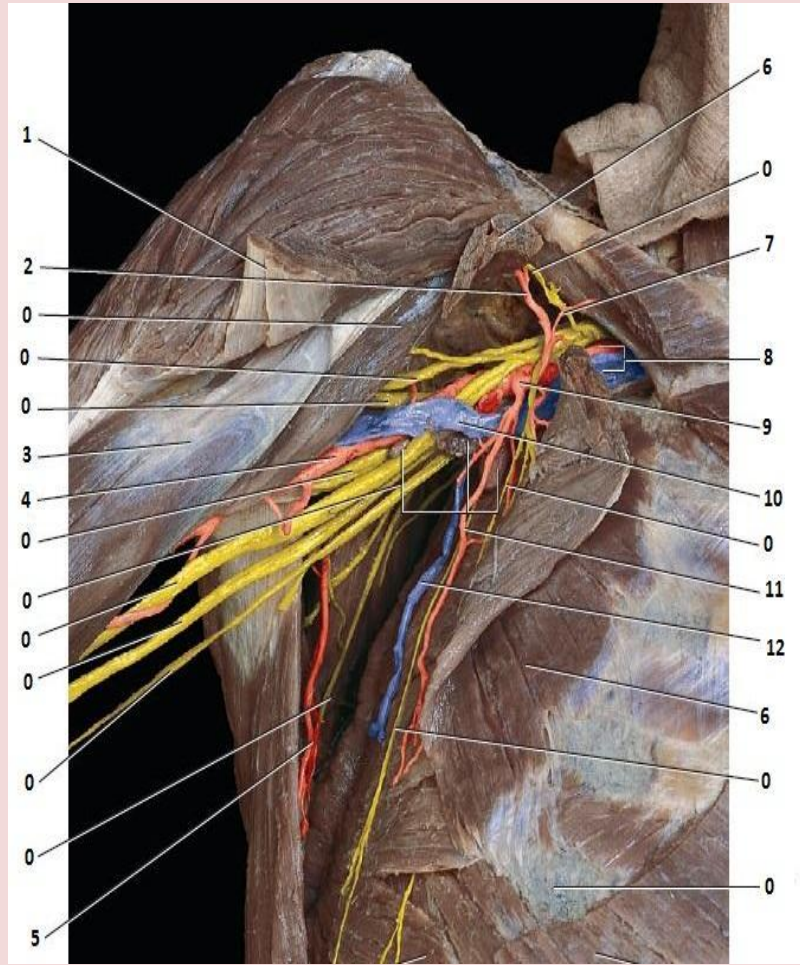
arteria et vena subclavia 8

arteria thoracoacromialis 9

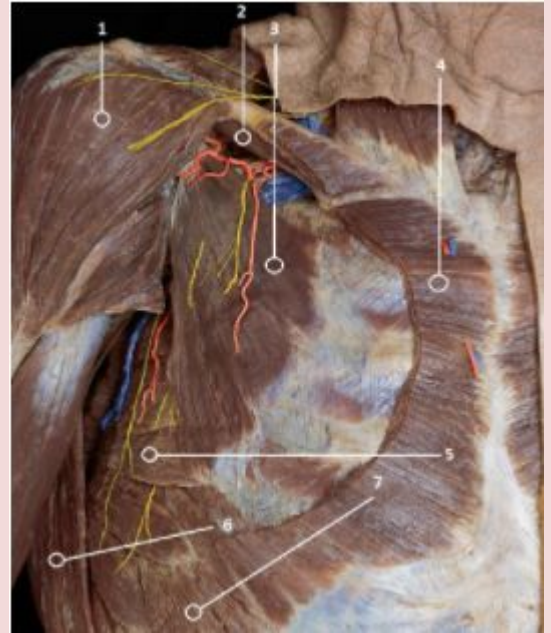
vena axillaris 10

arteria thoracica lateralis 11

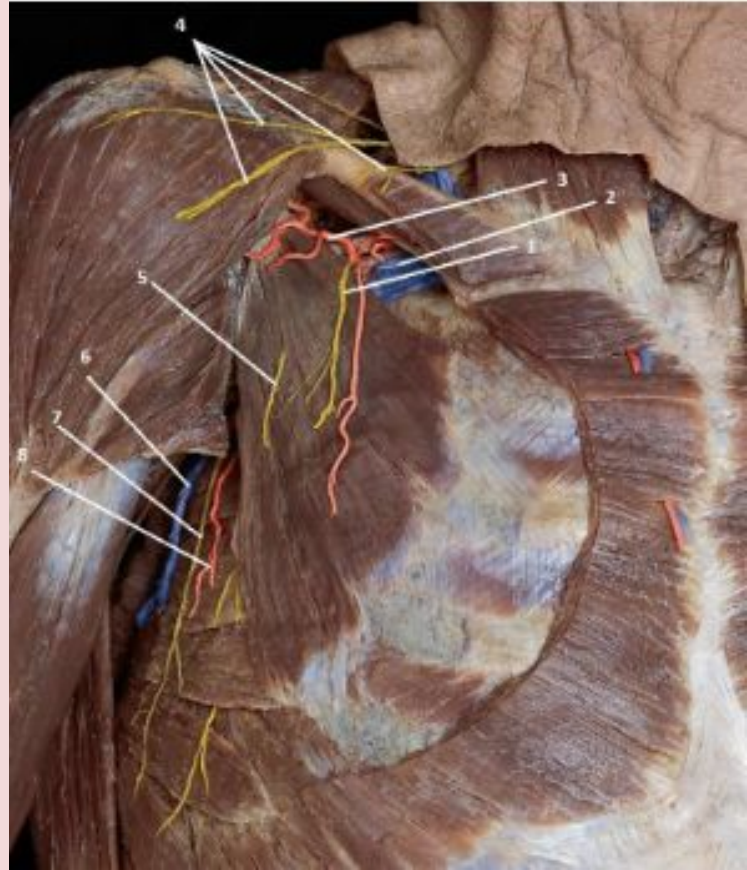vena thoracoepigastrica 12



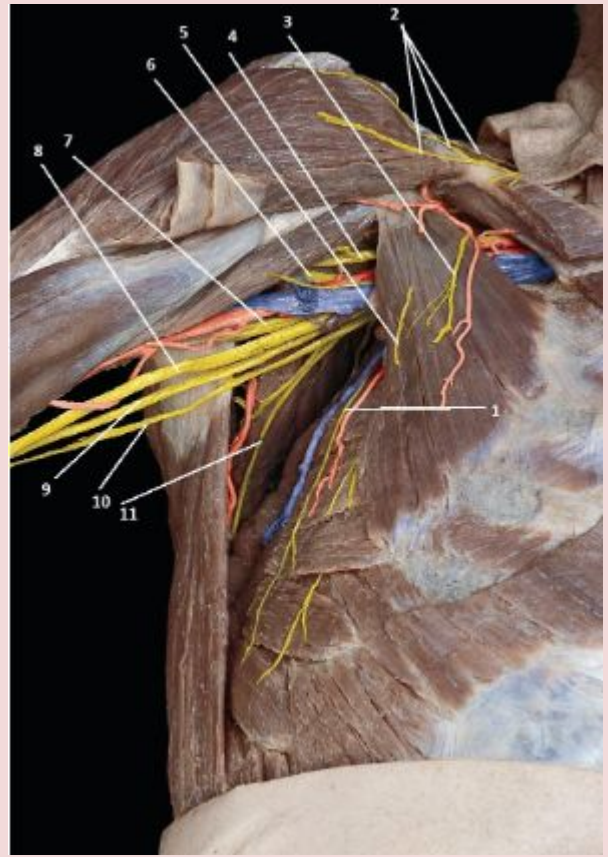
- musculus pectoralis major 4
- musculus obliquus abdominis externus 7
- musculus deltoideus 1
- musculus subclavius 2
- musculus latissimus dorsi 6
- musculus serratus anterior 5
- musculus pectoralis minor 3



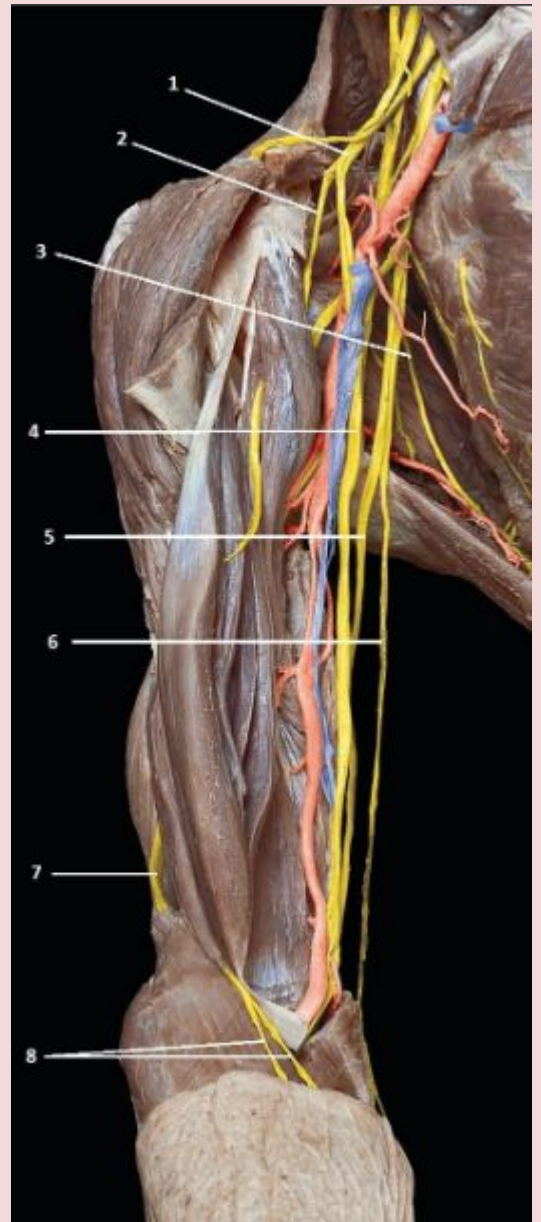
- nervus pectoralis medialis 5
- nervus pectoralis lateralis 1
- nervus supraclavicularis 4
- arteria thoracoacromialis 3
- vena thoracoepigastrica 6
- vena subclavia 2
- nervus thoracicus longus 7
- arteria thoracica lateralis 8



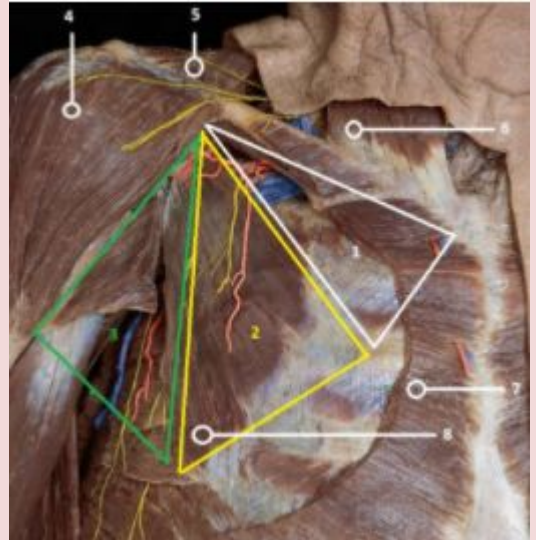
- nervus cutaneus brachii medialis 10
- nervus musculocutaneus 4
- nervus pectoralis medialis 5
- nervus supraclavicularis 2
- nervus ulnaris 9
- nervus thoracicus longus 1
- nervus thoracodorsalis 11
- nervus pectoralis lateralis 3
- nervus axillaris 6
- nervus radialis 7
- nervus medianus 8



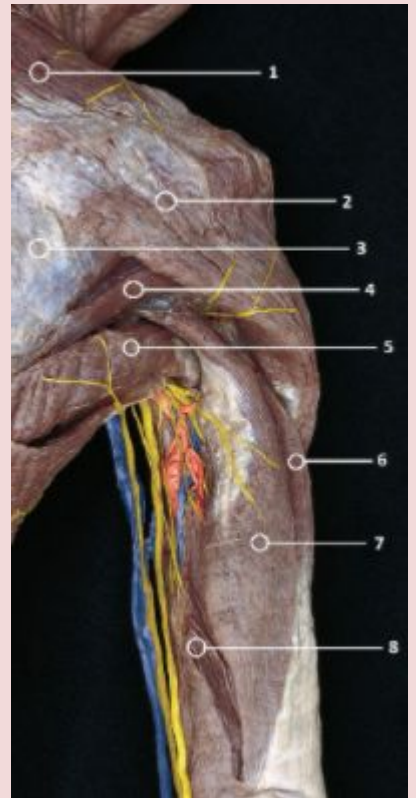
nervus thoracodorsalis 3
nervus cutaneus antebrachii lateralis 8
nervus radialis 7
nervus musculocutaneus 2
nervus cutaneus antebrachii medialis 6
nervus medianus 4
fasciculus lateralis 1
nervus ulnaris 5



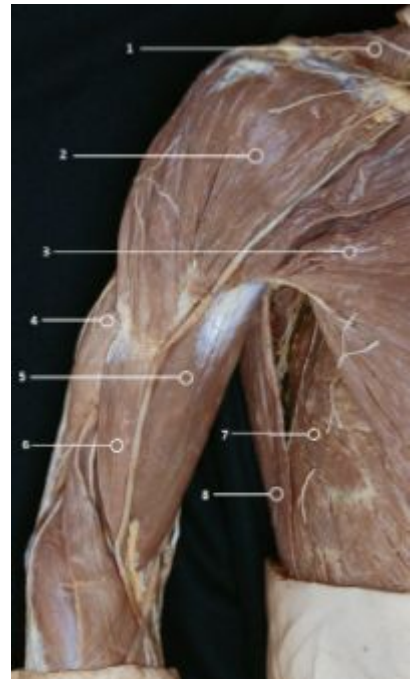- trigonum clavipectorale 1
- musculus pectoralis minor 8
- musculus trapezius 5
- trigonum subpectorale 3
- musculus sternocleidomastoideus 6
- trigonum pectorale 2
- musculus deltoideus 4
- musculus pectoralis major 7



musculus trapezius 1
musculus teres minor 4
caput laterale musculi tricipitis brachii 6
musculus teres major 5
musculus deltoideus 2
musculus infraspinatus 3
caput longum musculi tricipitis brachii 7
caput mediale musculi tricipitis brachii 8

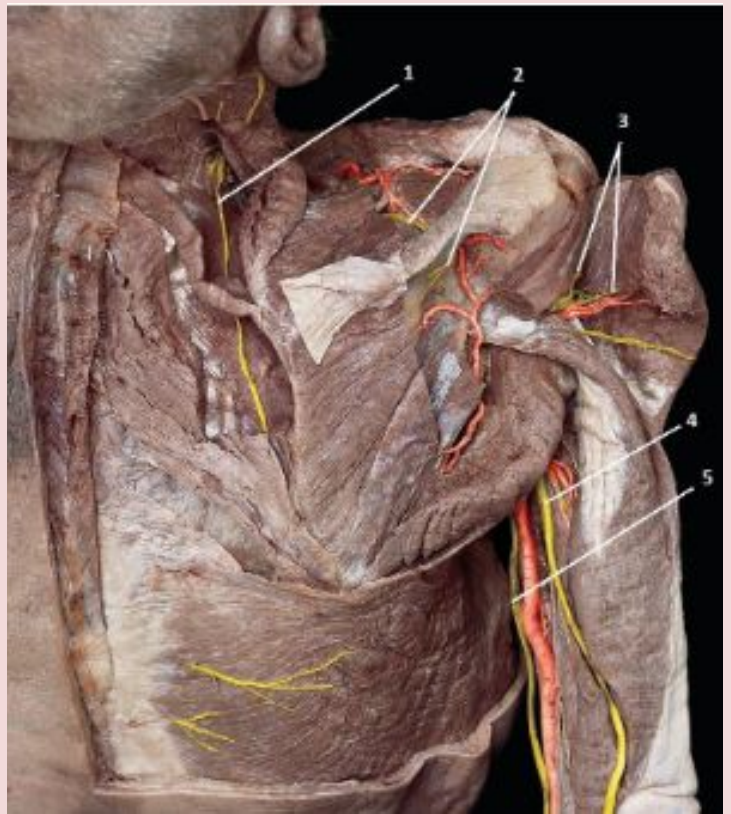


musculus trapezius 1
musculus deltoideus 2
musculus latissimus dorsi 8
musculus deltoideus 2
musculus brachialis 6
musculus triceps brachii 4
musculus biceps brachii 5
musculus serratus anterior 7

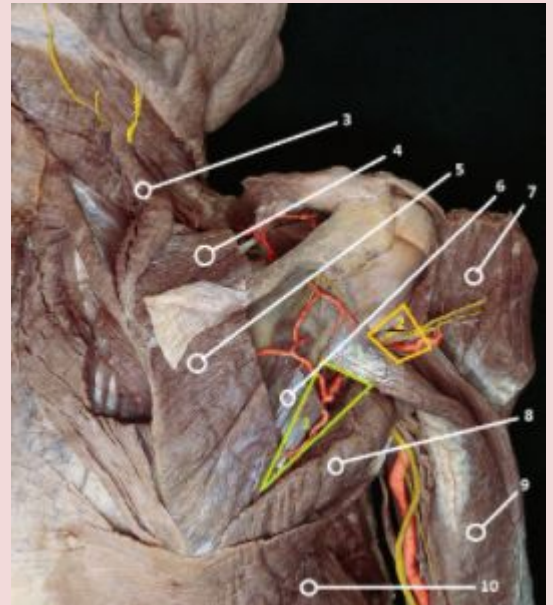


7
из 8

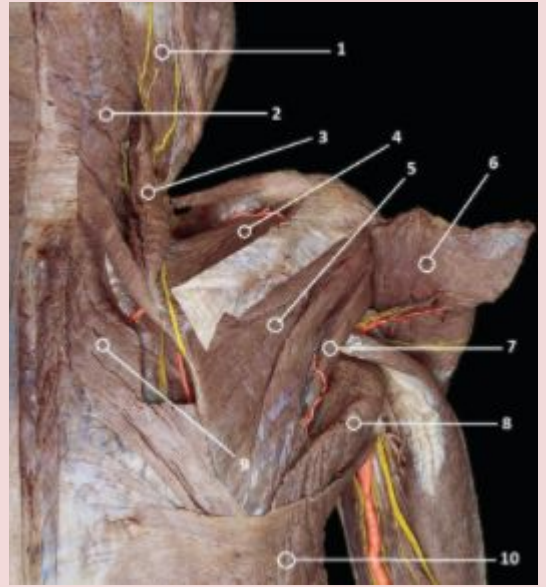
- nervus suprascapularis 2
- nervus axillaris 3
- nervus dorsalis scapula 1
- nervus ulnaris 4
- nervus medianus 5



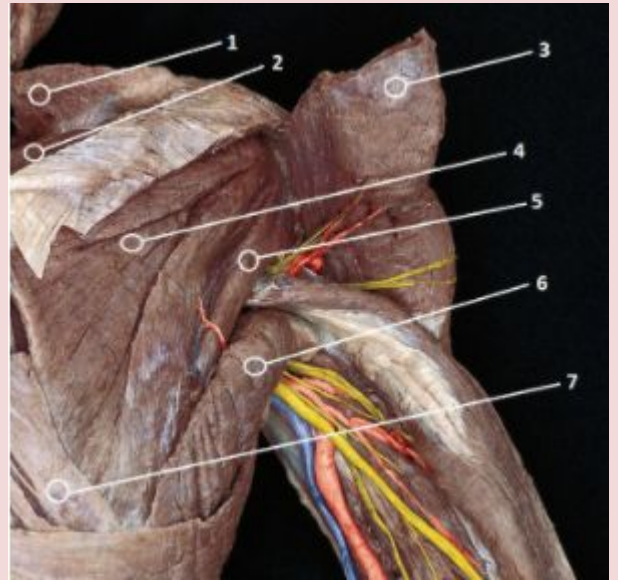
musculus levator scapulae 3
musculus latissimus dorsi 10
musculus teres minor 6
foramen trilaterum 1
caput longum musculi tricipitis brachii 9
musculus infraspinatus 5
musculus supraspinatus 4
foramen quadrilaterum 2
musculus deltoideus 7
musculus teres major 8



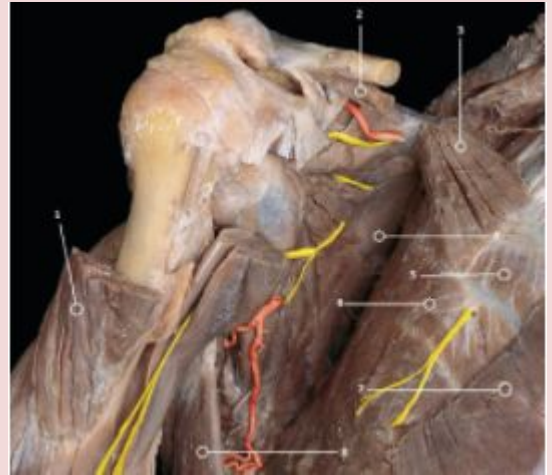
musculus supraspinatus 4
musculus teres minor 7
musculus teres major 8
musculus sternocleidomastoideus 1
musculus levator scapulae 3
musculus splenius capitis 2
musculus infraspinatus 5
musculus deltoideus 6
musculus rhomboideus major 9
musculus latissimus dorsi 10

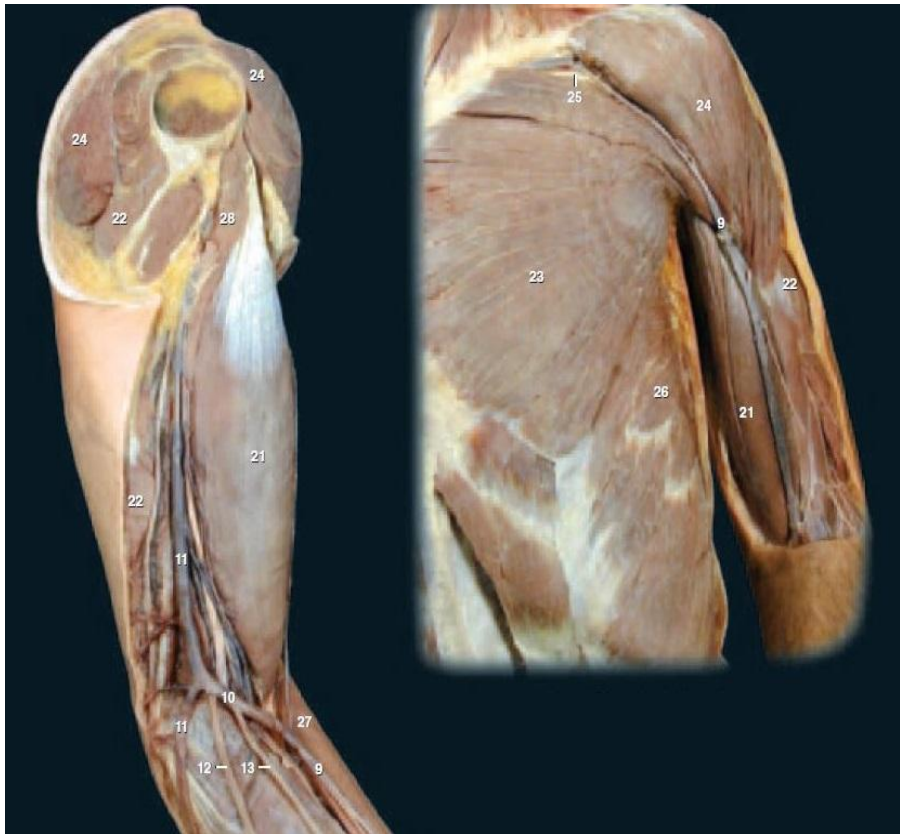

- musculus infraspinatus 4
- musculus trapezius 1
- musculus teres major 6
- musculus rhomboideus 7
- musculus teres minor 5
- Musculus deltoideus 3
- Musculus supraspinatus 2



- musculus latissimus dorsi 8
- musculus subclavius 2
- musculus serratus anterior 3
- musculus subscapularis 4
- musculus deltoideus 1
- musculus pectoralis minor 6
- musculus intercostalis externus 5
- musculus pectoralis major 7





- vena antebrachii mediana 12
- vena intermedia cubiti 10
- vena basilica 11
- vena cephalica 9
- vena cephalica accessoria 13

arteria ulnaris 3

arteria radialis 8

arteria collateralis ulnaris inferior 1

arteria recurrens radialis 9

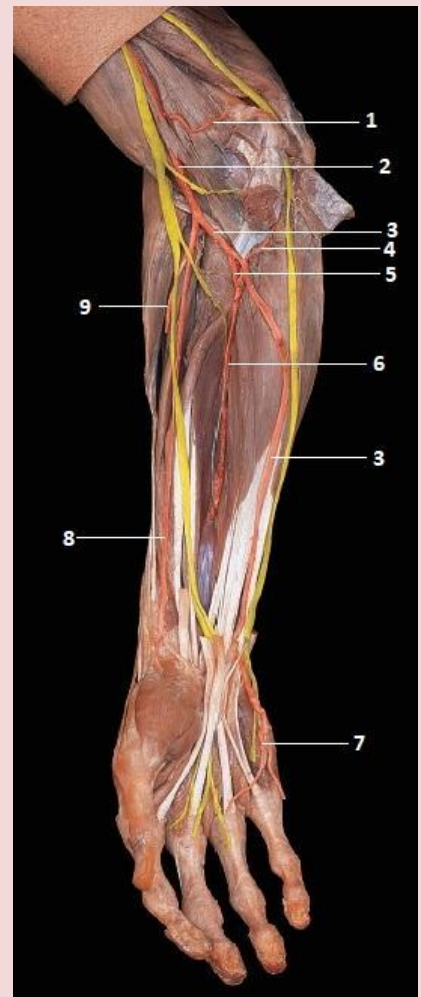
arcus palmaris superficialis 7

arteria interossea anterior 6

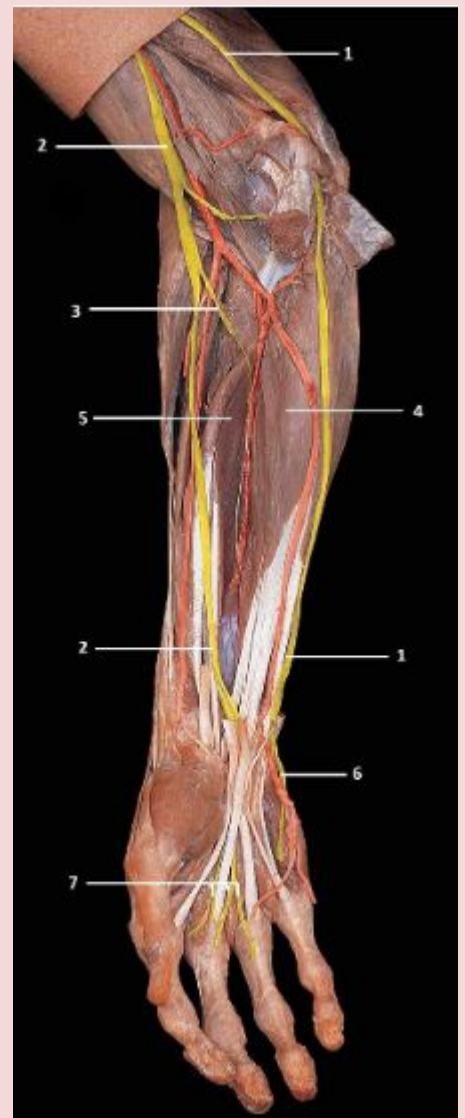
arteria brachialis 2

arteria recurrens ulnaris anterior 4

arteria interossea communis 5



nervus digitalis palmaris communis 7
ramus palmaris nervi ulnaris 6
nervus ulnaris 1
nervus interosseus anterior 3
nervus medianus 2
musculus flexor digitorum profundus 4
musculus flexor pollicis longus 5



musculus brachioradialis 2

musculus flexor carpi radialis 6

arcus palmaris superficialis 8

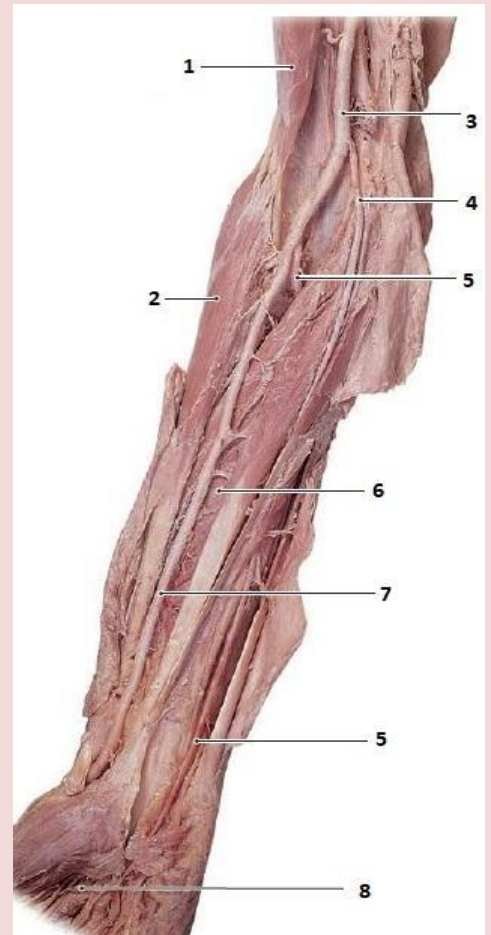
arteria ulnaris 5

arteria collateralis ulnaris inferior 4

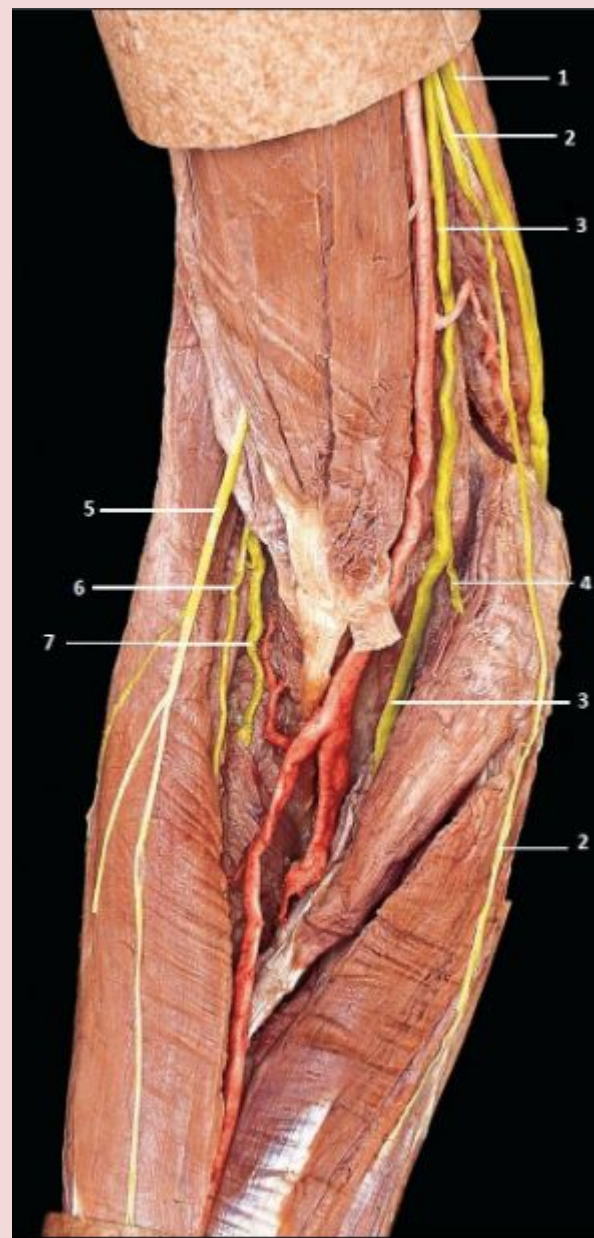
musculus biceps brachii 1

arteria brachialis 3

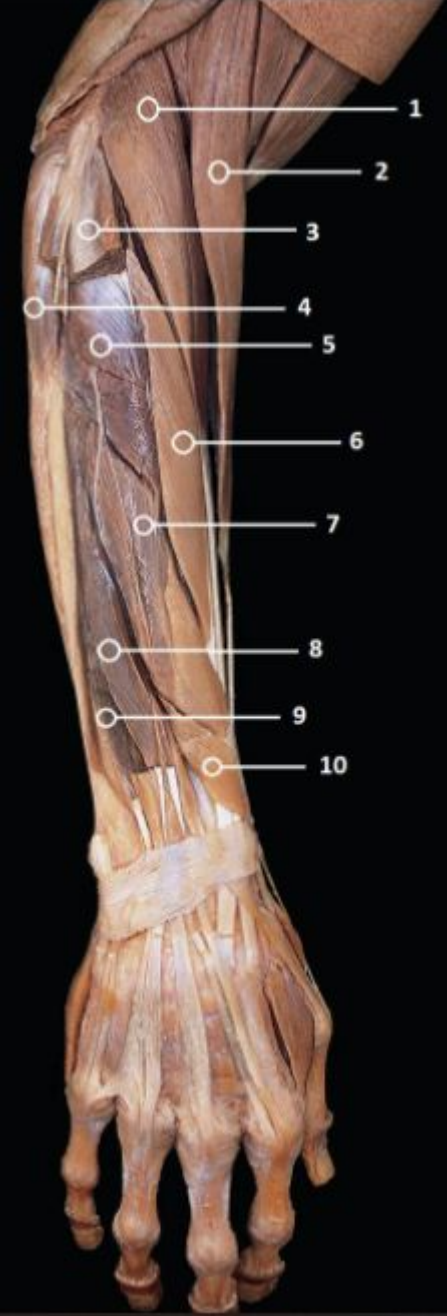arteria radialis 7



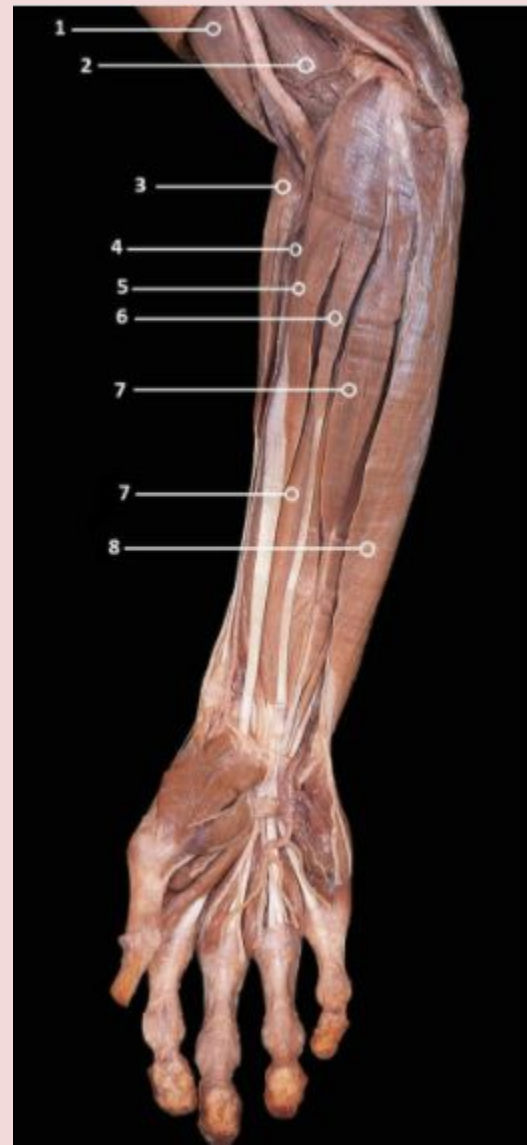nervus cutaneus antebrachii lateralis 5
ramus profundus nervi radialis 7
nervus ulnaris 1
ramus pronator teres nervus medianus 4
ramus superficialis nervi radialis 6
nervus cutaneus antebrachii medialis 2
nervus medianus 3

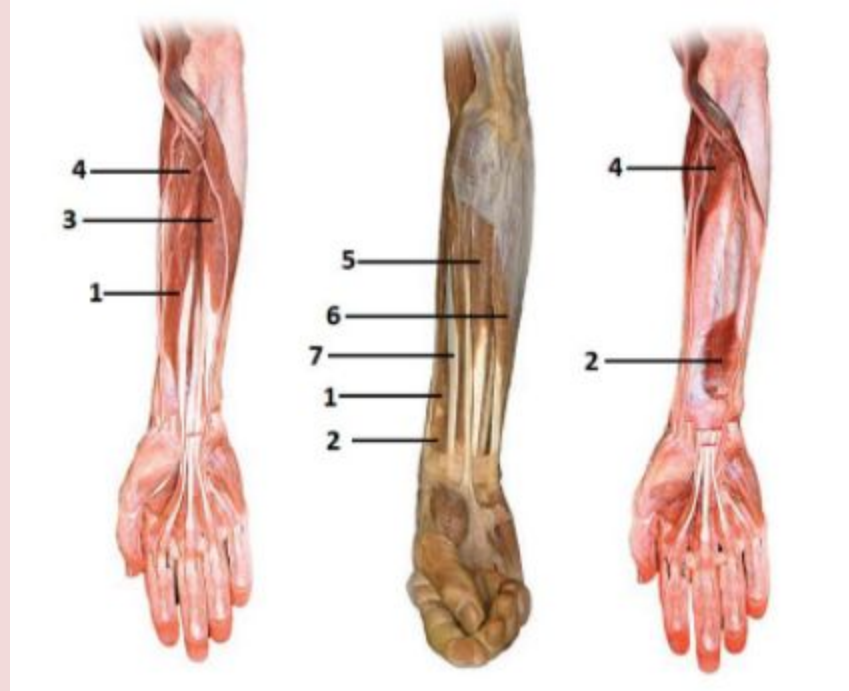


- musculus brachioradialis 2
- musculus extensor digitorum 3
- musculus anconeus 4
- musculus extensor pollicis longus 8
- musculus abductor pollicis longus 7
- musculus extensor carpi radialis longus 1
- musculus supinator 5
- musculus extensor carpi radialis brevis 6
- musculus extensor indicis 9
- musculus extensor pollicis brevis 10

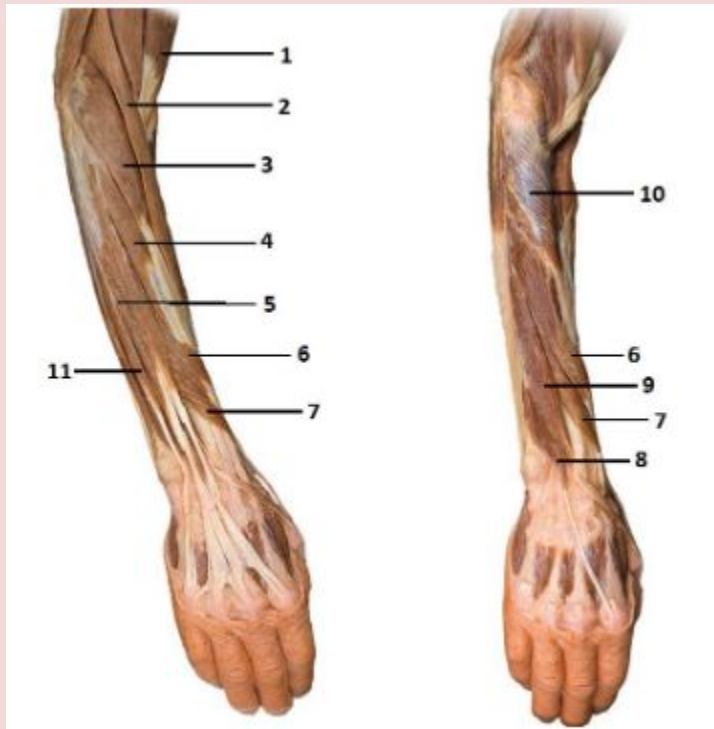


- musculus flexor carpi radialis 5
- musculus biceps brachii 1
- musculus flexor digitorum superficialis 7
- musculus flexor carpi ulnaris 8
- musculus brachialis 2
- musculus pronator teres 4
- musculus brachioradialis 3
- musculus palmaris longus 6



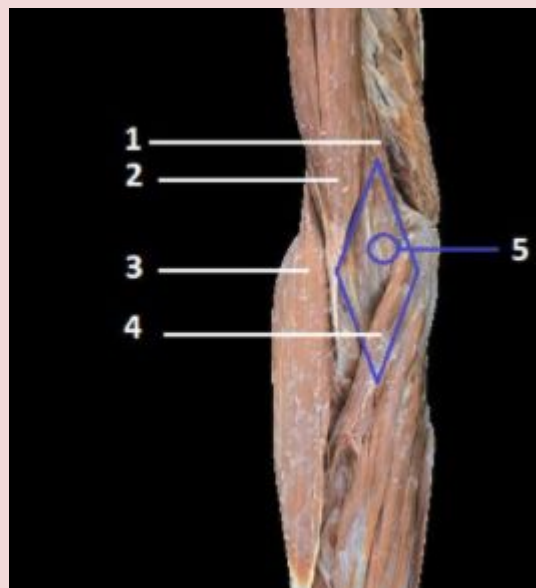


- musculus flexor carpi ulnaris 6.
- musculus flexor digitorum profundus 3.
- musculus flexor carpi radialis 7
- musculus flexor digitorum superficialis 5
- musculus flexor pollicis longus 1.
- musculus pronator quadratus 2.
- musculus supinator 4.



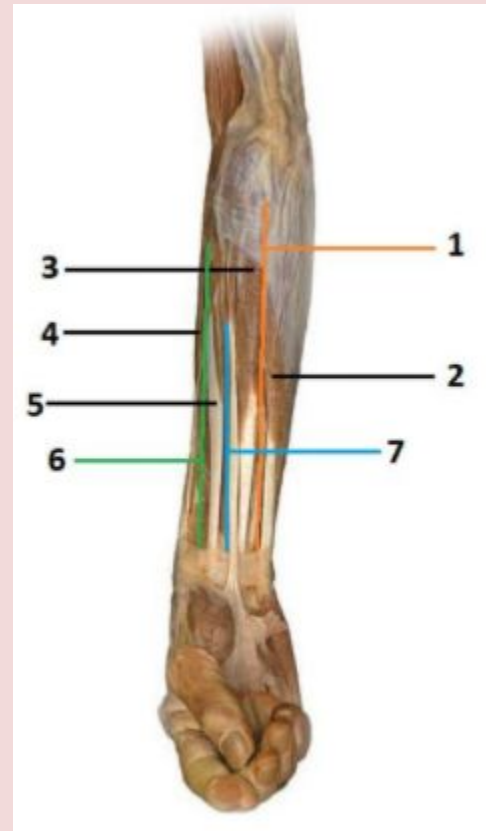
- musculus extensor pollicis longus 9
- musculus extensor carpi radialis brevis 4
- musculus biceps brachii 1
- musculus extensor indicis 8
- musculus abductor pollicis longus 6
- musculus extensor digiti minimi 11
- musculus brachioradialis 2
- musculus extensor carpi radialis longus 3
- musculus extensor digitorum 5
- musculus extensor pollicis brevis 7
- musculus supinator 10

musculus brachialis 2
musculus biceps brachii 1
musculus pronator teres 4
musculus brachioradialis 3
fossa cubitalis 5

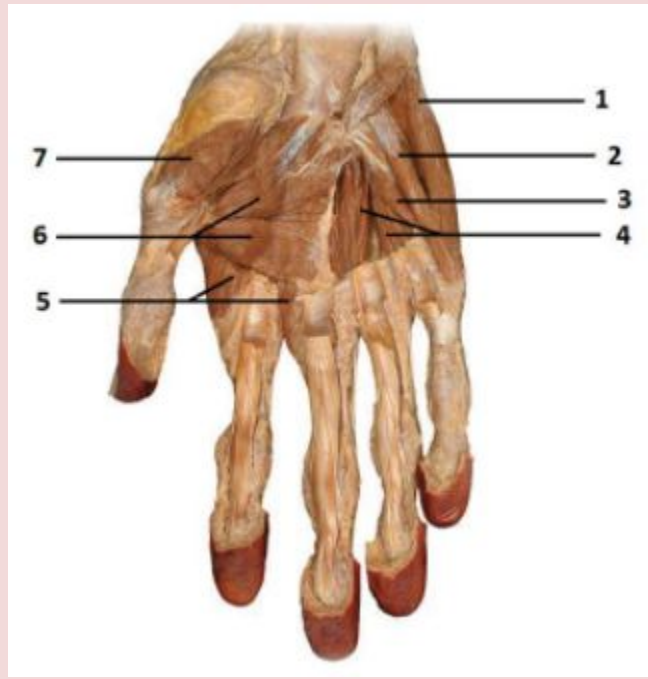


2
из 5

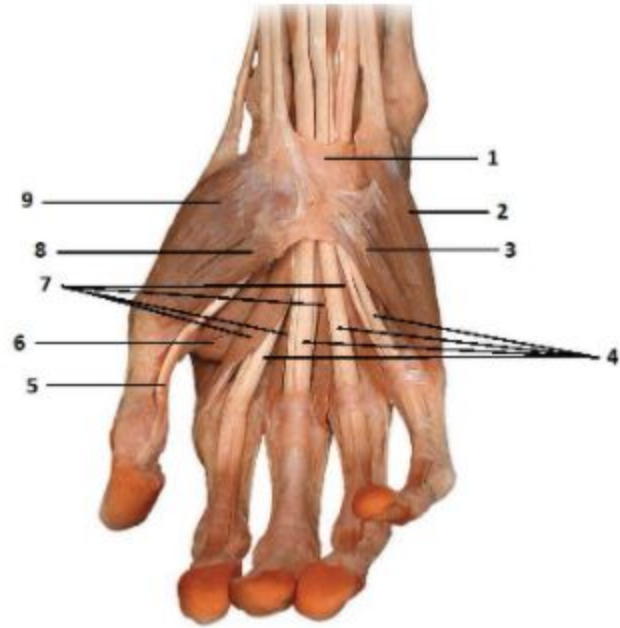
musculus brachioradialis 4
sulcus radialis 6
musculus flexor digitorum superficialis 3
sulcus ulnaris 1
musculus flexor carpi ulnaris 2
musculus flexor carpi radialis 5
sulcus medianus 7



- musculus abductor digiti minimi 1
- musculus interosseus dorsalis 5
- musculus adductor pollicis 6
- musculus flexor digiti minimi brevis 2
- musculus opponens digiti minimi 3
- musculus interosseus palmaris 4
- musculus abductor pollicis brevis 7



musculus abductor digiti minimi 2
musculus adductor pollicis 6
retinaculum flexorum 1
musculus abductor pollicis brevis 9
musculus lumbricales 7
tendo musculus flexor pollicis longus 5
musculus flexor digiti minimi brevis 3
tendo musculus flexor digitorum superficialis 4
musculus flexor pollicis brevis 8



arteria ulnaris 1

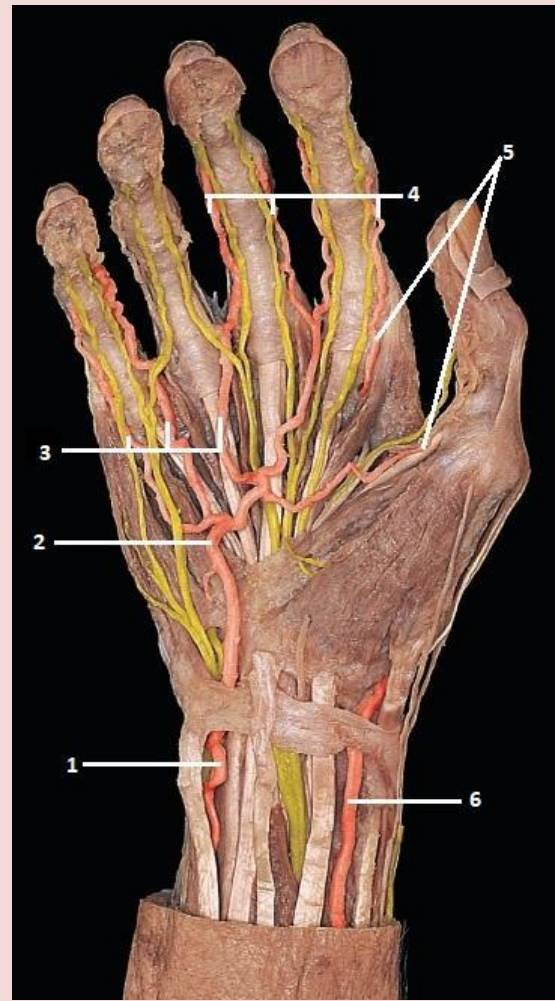
arcus palmaris superficialis 2

arteria digitalis palmaris communis 3

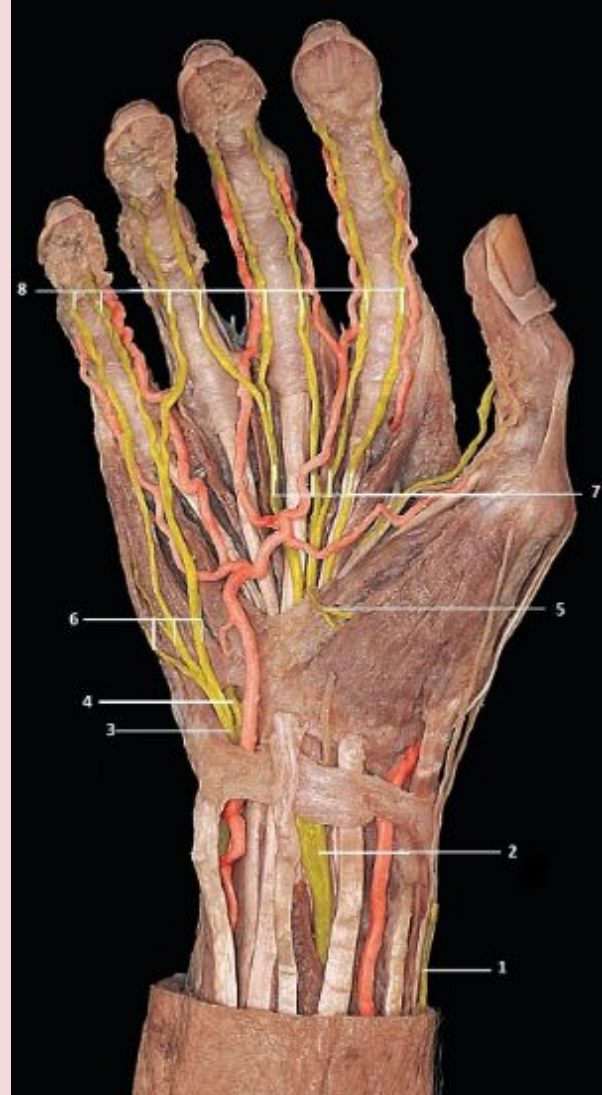arteria digitalis palmaris propria 4

arteria princeps pollicis 5

arteria radialis 6



nervus digitalis palmaris propria 8
nervus medianus 2
ramus profundus nervi ulnaris 4
ramus superficialis nervi ulnaris 3
ramus superficialis nervi radialis 1
nervus medianus recurrens 5
nervus digitalis palmaris communis nervi ulnaris 6
nervus digitalis palmaris communis nervi medianus 7



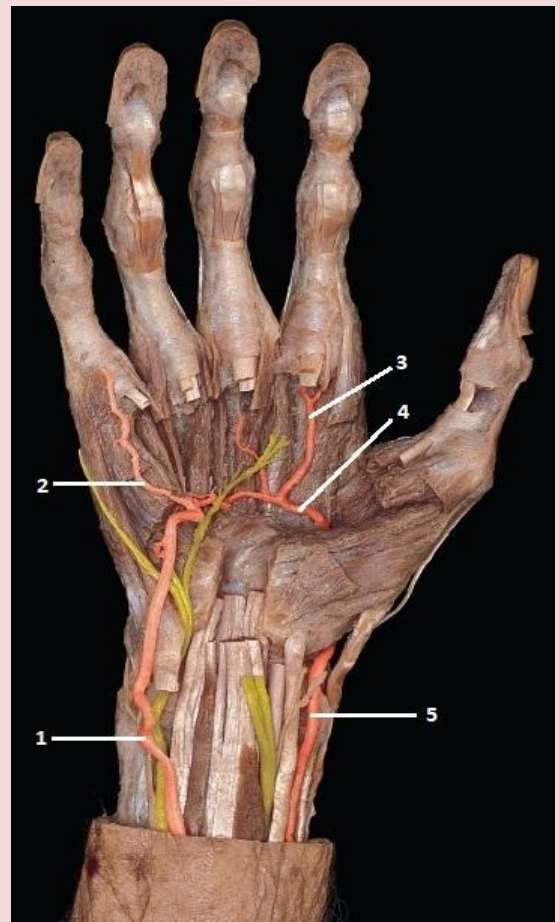
arcus palmaris profundus 4

arteria digitalis palmaris communis 2

arteria metacarpea palmaris 3

arteria ulnaris 1

arteria radialis 5



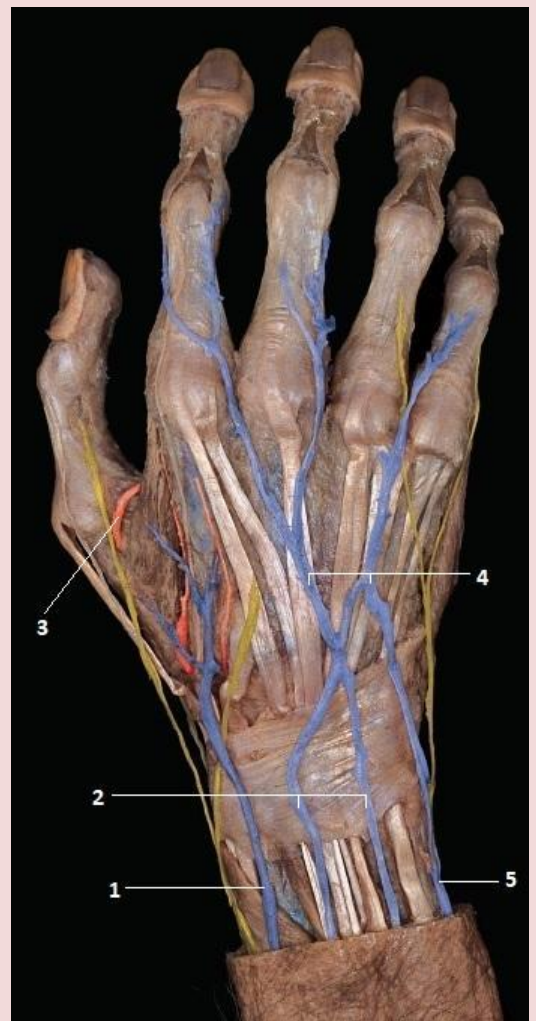
arteria princeps pollicis 3

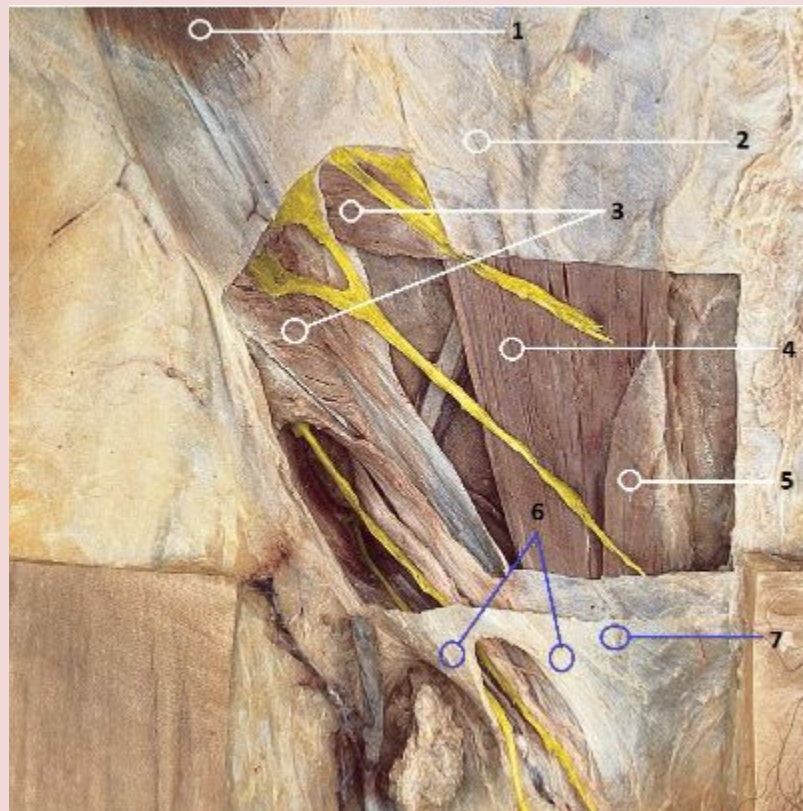
vena basilica 5

plexus venosus dorsalis manus 4

vena cephalica 1

ductus vena cefalica 2





влагалище прямой мышцы живота 2

musculus obliquus abdominis externus 1

musculus rectus abdominis 4

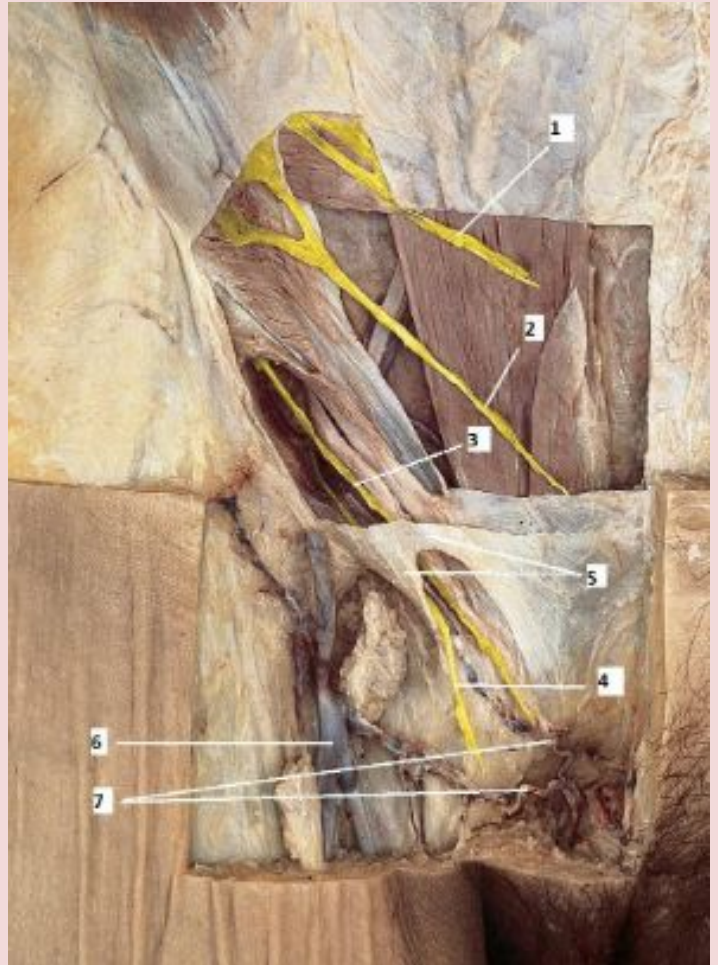
anulus inguinalis superficialis 6

musculus obliquus abdominis internus 3

musculus pyramidalis 5

апоневроз musculus obliquus abdominis externus 7

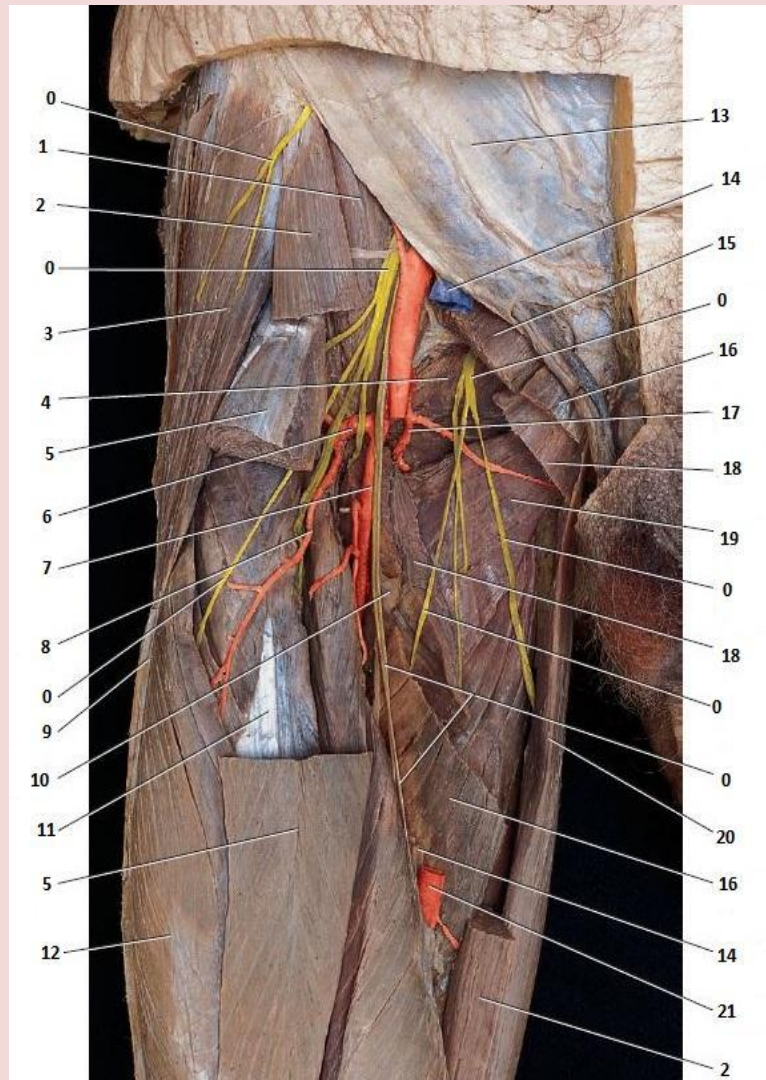
- ramus genitalis nervus genitofemoralis 4
- nervus iliohypogastricus 2
- vena saphena magna 6
- nervus subcostalis 1
- anulus inguinalis superficialis 5
- nervus ilioinguinalis 3
- vena pudenda externa 7



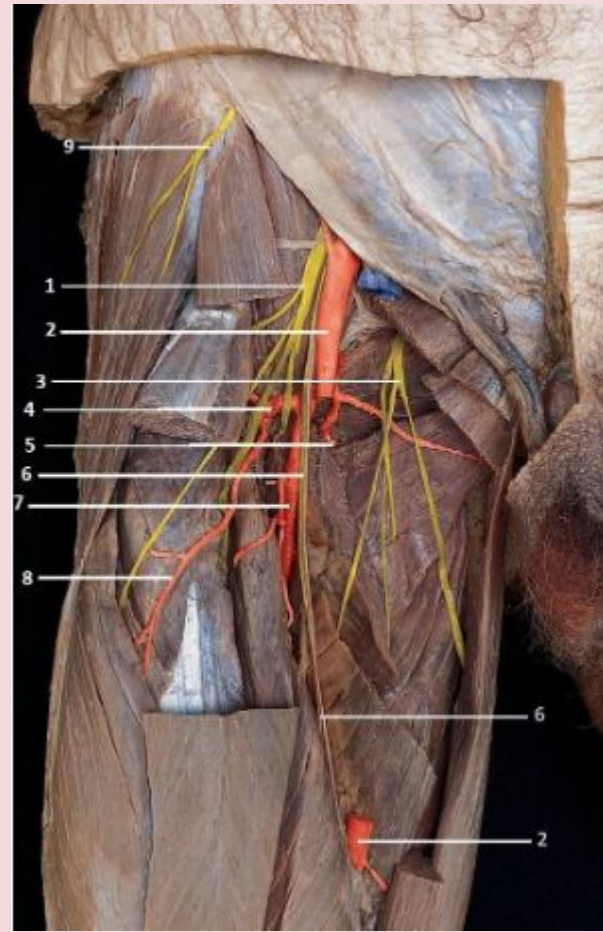
musculus rectus femoris 5
 musculus sartorius 2
 tractus iliotibialis 9
 musculus iliacus 1
 arteria femoral profunda 7
 musculus obturatorius externus 4
 musculus vastus intermedius 11

 ramus descendens arteria
 circumflexa femoris lateralis 6

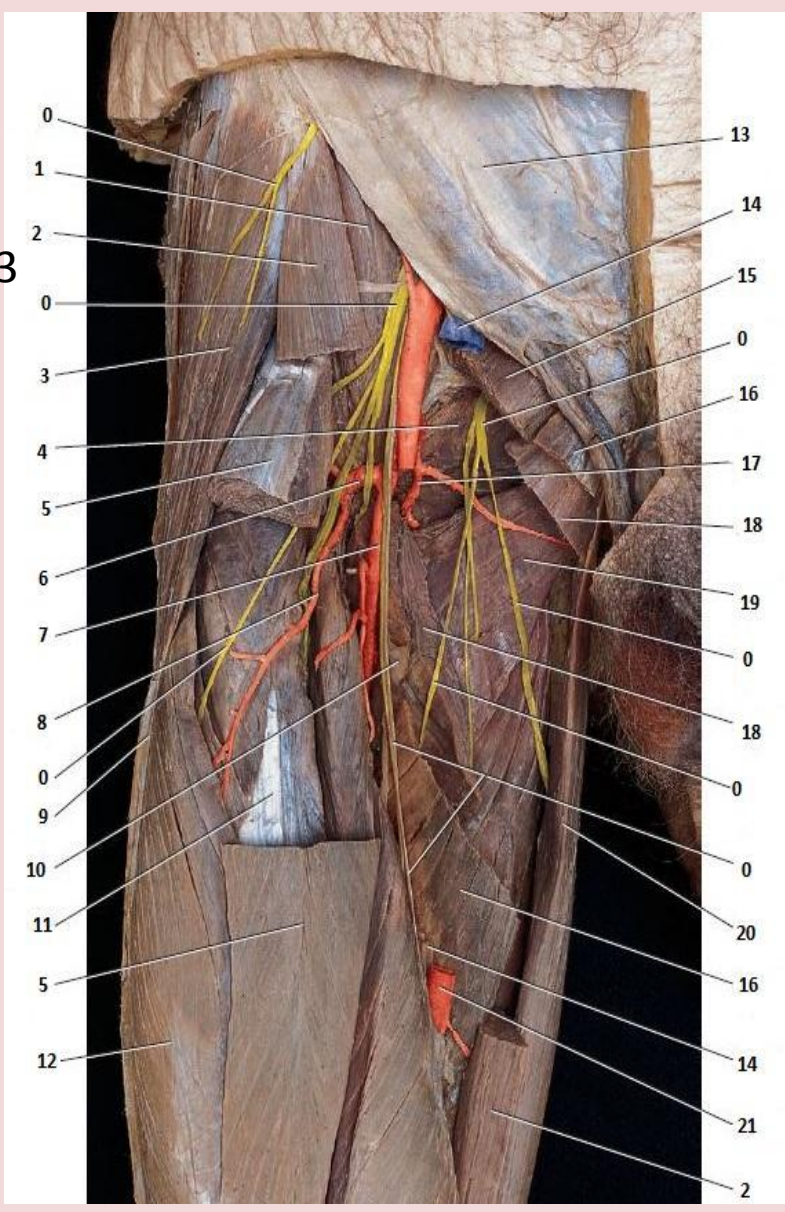
 vena femoralis 10
 musculus tensor fasciae latae 3
 arteria circumflexa femoris
 lateralis 8
 musculus vastus lateralis 12

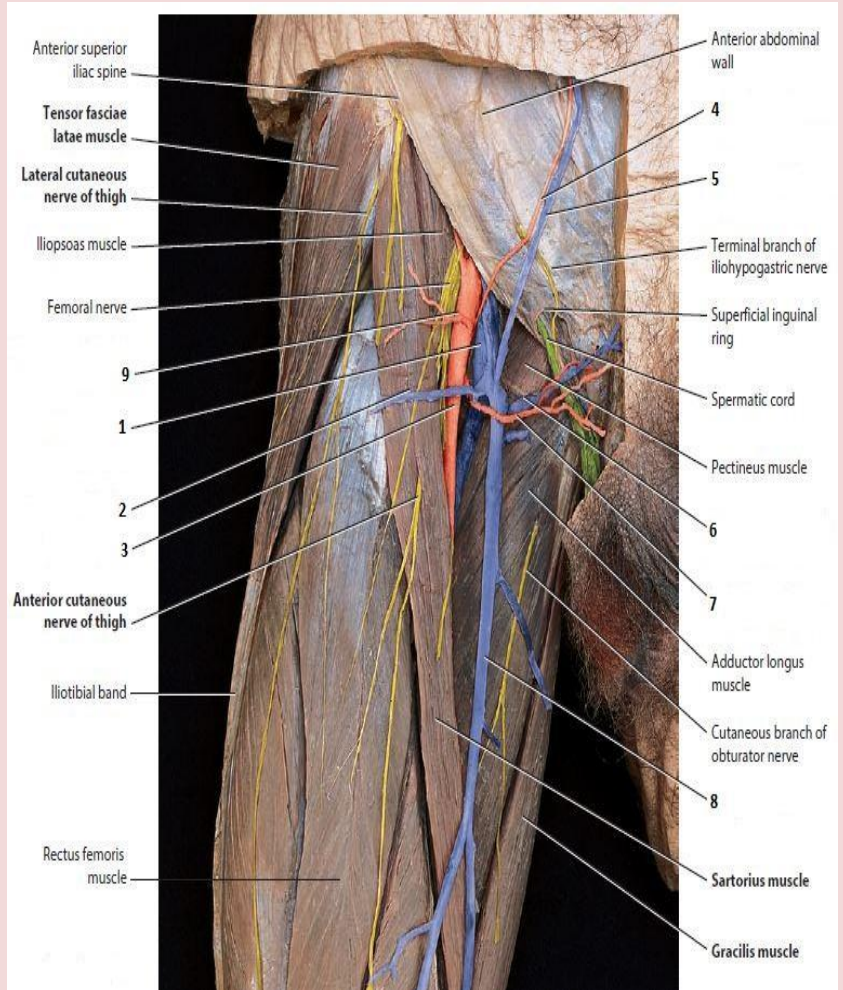


nervus cutaneus femoris lateralis 9
arteria femoralis profunda 7
arteria circumflexa femoris lateralis 4
nervus femoralis 1
arteria femoralis 2
nervus obturatorius 3
arteria circumflexa femoris medialis 5
ramus descendens arteria circumflexa
femoris lateralis 8
nervus saphenus 6



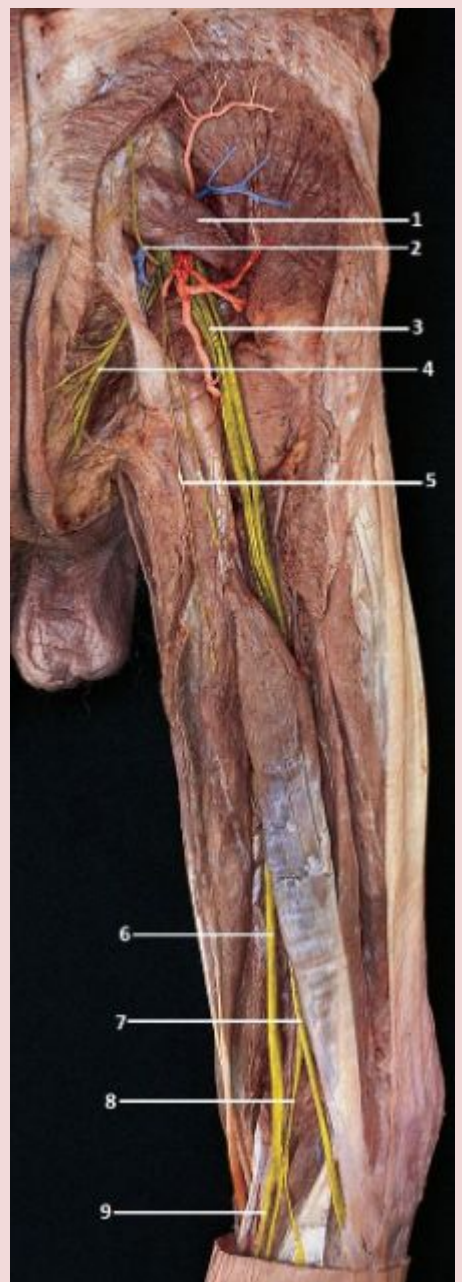передняя брюшная стенка 13
 arteria femoralis 21
 musculus sartorius 2
 musculus adductor magnus 19
 musculus pectineus 15
 vena femoralis 14
 musculus adductor longus 16
 arteria circumflexa femoris
 medialis 17
 musculus adductor brevis 18
 musculus gracilis 20



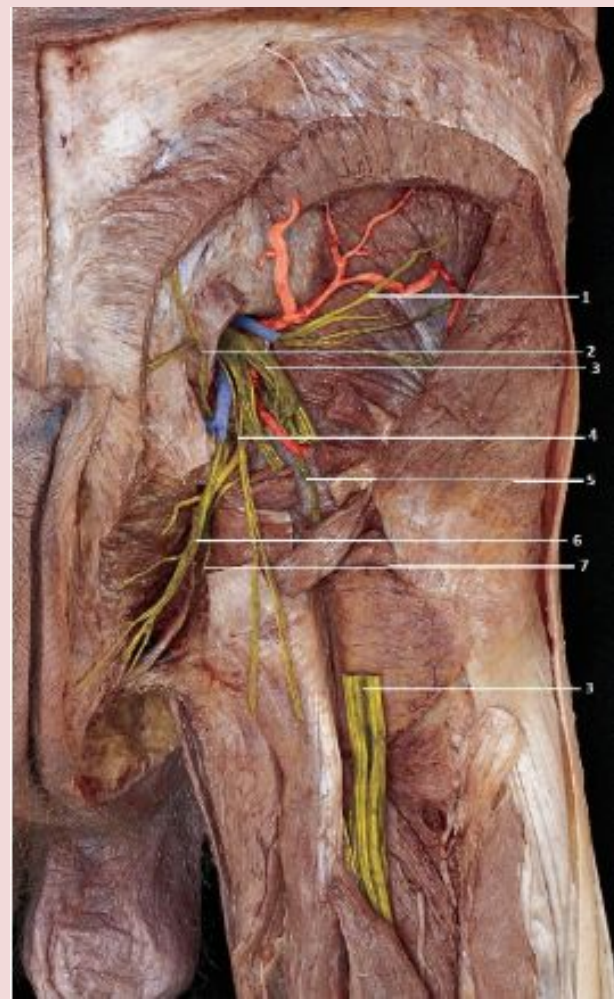


- vena pudenda externa 6
- arteria epigastrica superficialis 4
- vena circumflexa ilium superficialis 2
- vena femoralis 1
- arteria circumflexa ilium superficialis 9
- arteria pudenda externa 7
- arteria femoralis 3
- vena epigastrica superficialis 5
- vena saphena magna 8

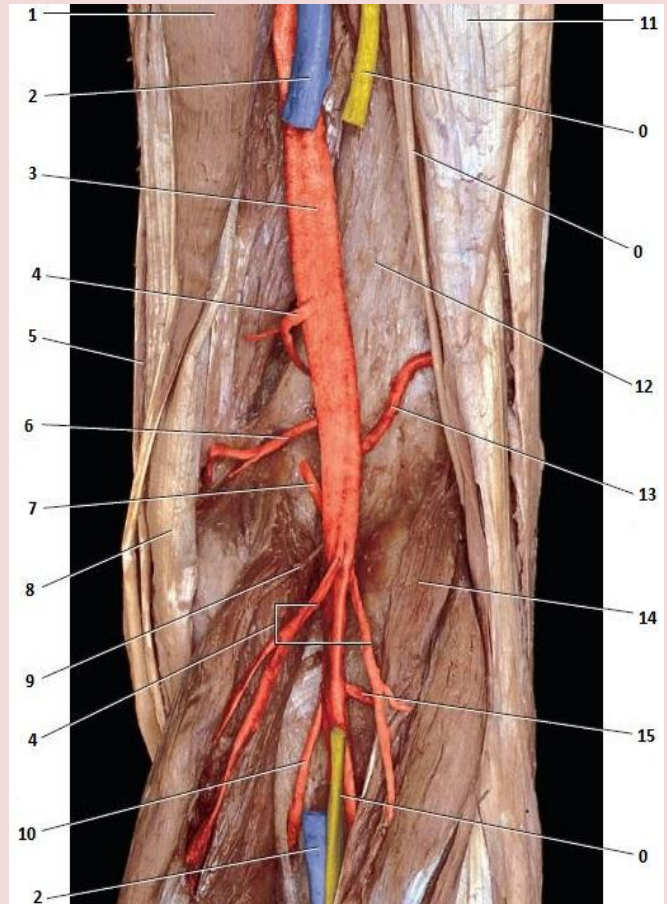
nervus cutaneus surae medialis 9
musculus piriformis 1
nervus fibularis communis 7
nervus tibialis 6
nervus cutaneus surae lateralis 6
nervus gluteus inferior 2
nervus ischiadicus 3
nervi rectales inferiores 4
nervus cutaneus femoris posterior 5



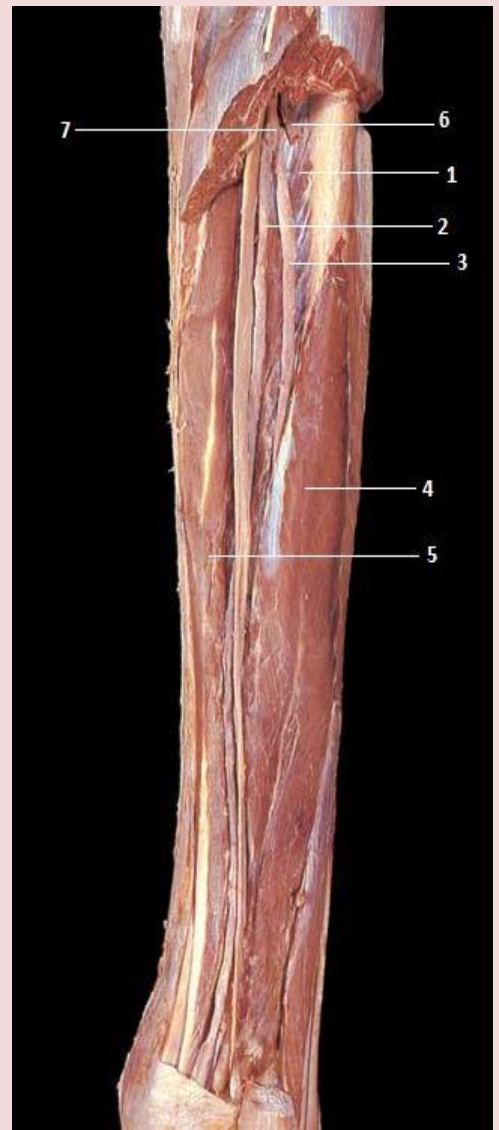
- nervus musculus quadratus femoris 5
- nervus gluteus inferior 2
- nervus cutaneus femoris posterior 4
- nervus gluteus superior 1
- nervus ischiadicus 3
- nervus pudendus 6
- nervus musculus obturatorius internus 7



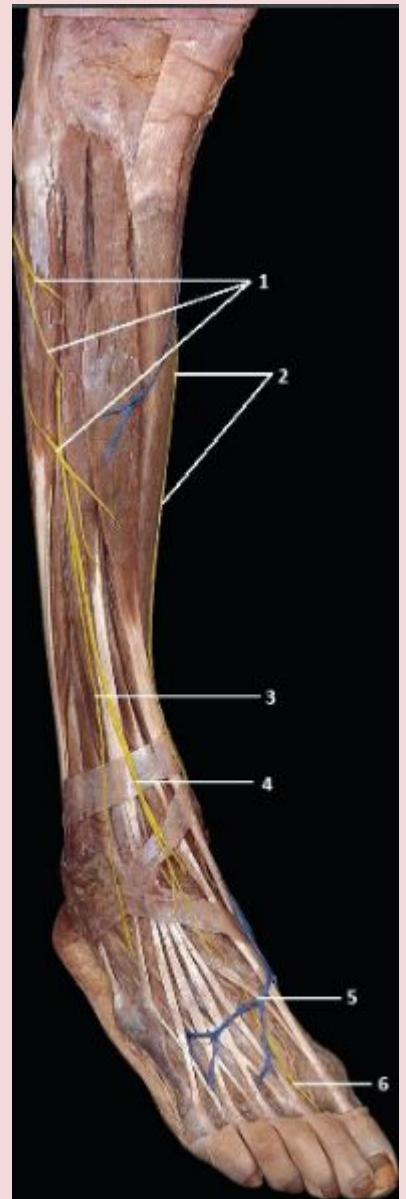musculus plantaris 14
 arteria genus superior laterali 13
 arteria genus inferior laterali 15
 arteria poplitea 3
 ramus muscularis arteria tibialis 9
 musculus semimembranosus 8
 arteria suralis 4
 arteria genus media 7
 musculus biceps femoris 11
 vena poplitea 2
 musculus semitendinosus 1
 arteria gracilis 5
 arteria genus superior medialis 6
 arteria genus inferior medialis 10
 facies poplitea 12



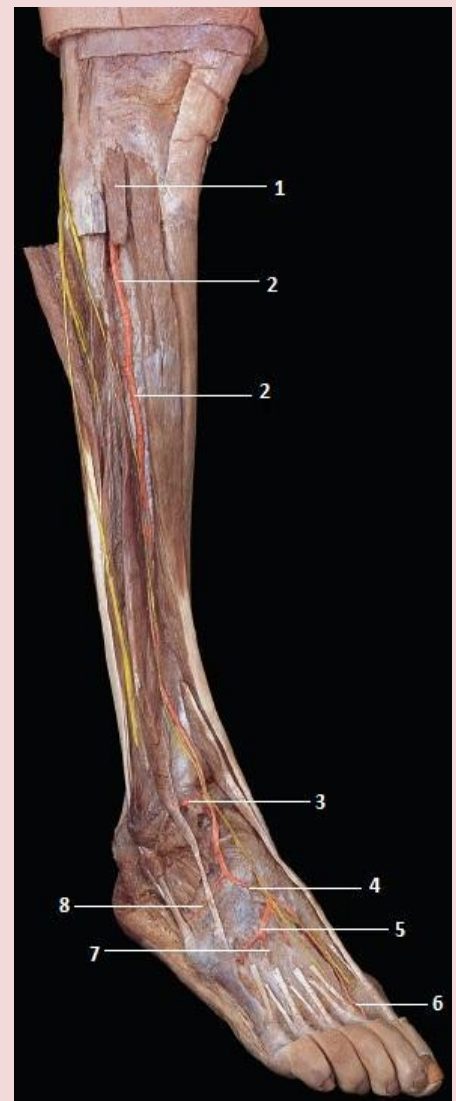vena poplitea 5
arteria poplitea 7
arteria tibialis posterior 2
arteria fibularis 3
musculus flexor hallucis longus 4
musculus tibialis posterior 1
musculus flexor digitorum longus 5



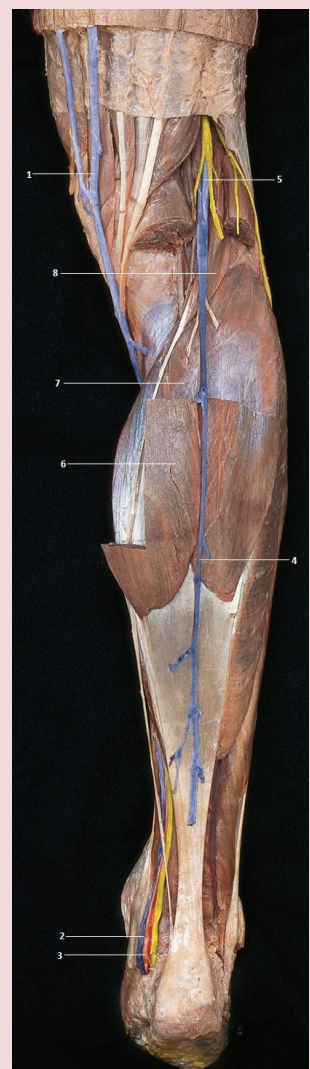
nervus cutaneus dorsalis intermedius 3
nervus saphenus 2
nerve cutaneus surae lateralis 1
arcus venosus dorsalis pedis 5
nervus cutaneus dorsalis medialis 4
nervus fibularis profundus 6



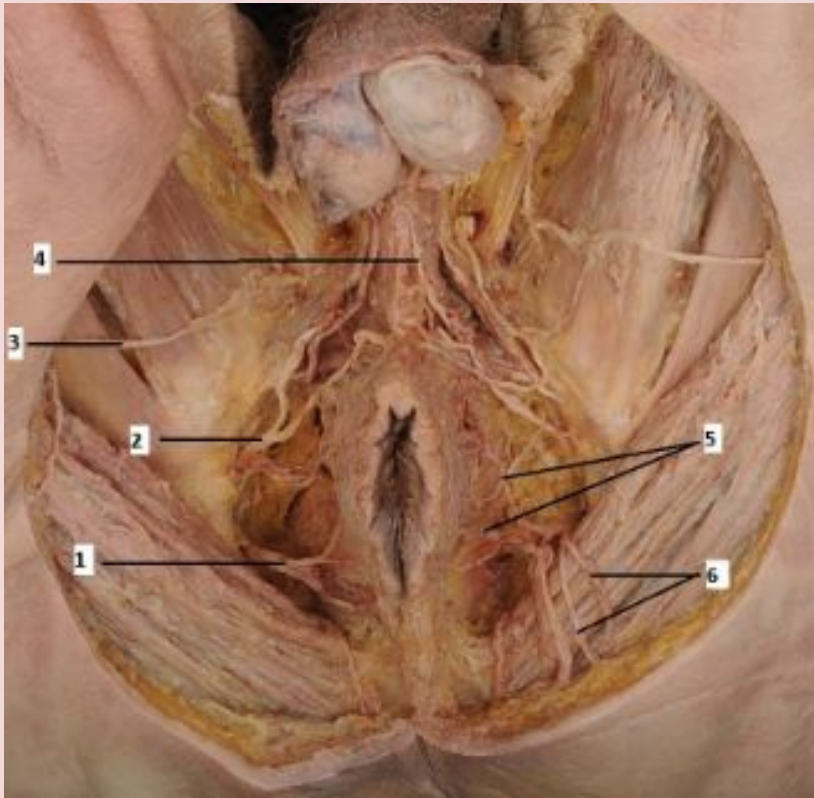
- arteria metatarsa dorsalis 7
- arteria tarsea lateralis 8
- arteria dorsalis pedis 4
- arteria tibialis anterior 2
- arteria malleolaris anterior lateralis 3
- musculus extensor hallucis longus 1
- arteria arcuata 5
- arteria metatarsa dorsalis prima 6



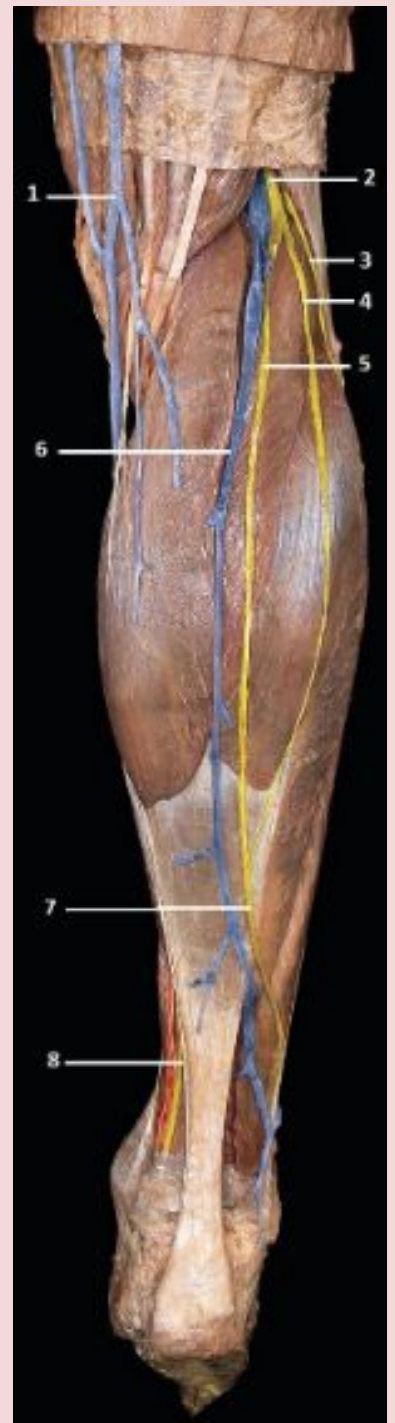
vena tibialis posterior 2
vena saphena magna 1
musculus gastrocnemius 6
vena saphena parva 4
musculus plantaris 8
arteria tibialis posterior 3
vena poplitea 5
musculus soleus 7



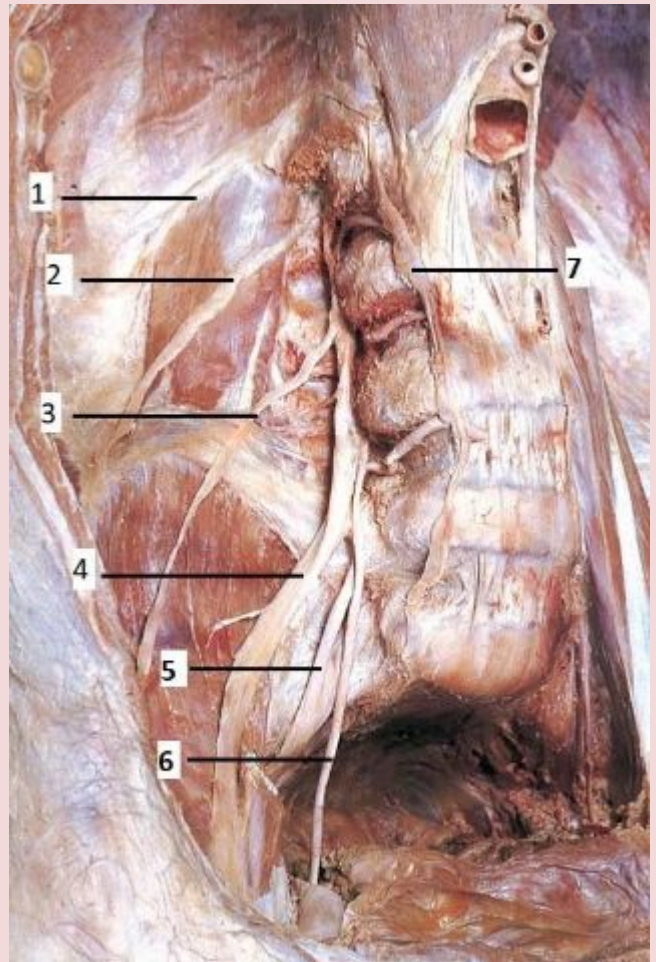
- nervi perinei 2
- nervi rectales inferiores 5
- nervus obturatorius 3
- nervi clunium inferiores 6
- nervus pudendus 1
- nervi scrotales posteriores 4



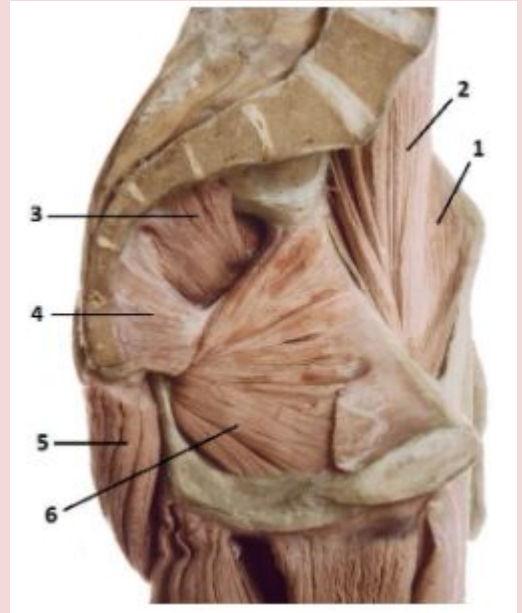
- vena saphena parva 6.
- nervus cutaneus surae lateralis 4.
- nervus tibialis 2.
- nervus suralis 7.
- vena saphena magna 1.
- nervus fibularis communis 3.
- nervus cutaneus surae medialis 5.
- nervus tibialis 8.



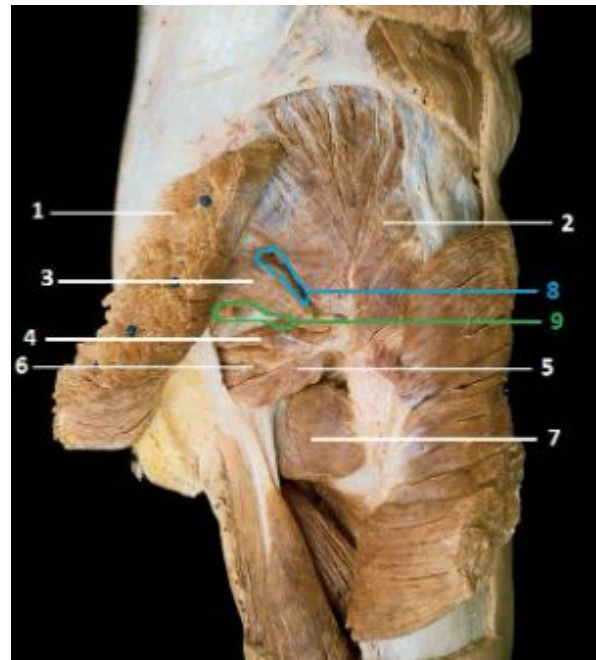
- nervus obturatorius 6
- truncus lumbosacralis 5
- nervus iliohypogastricus 2
- nervus subcostalis 1
- nervus cutaneus femoris lateralis 3
- nervus femoralis 4
- truncus sympathicus 7



musculus obturatorius internus 6
musculus iliacus 1
musculus piriformis 3
musculus psoas major 2
musculus coccygeus 4
musculus gluteus maximus 5

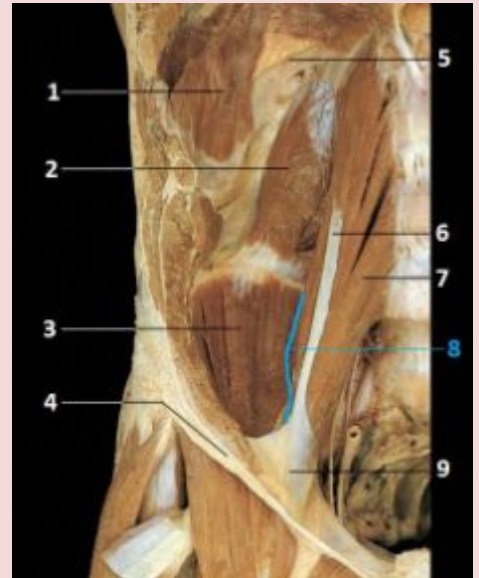


musculus gluteus maximus 1
foramen infrapiriforme 9
musculus gemellus inferior 6
musculus obturatorius internus 5
musculus piriformis 3
musculus gemellus superior 4
musculus gluteus medius 2
musculus quadratus femoris 7
foramen suprapiriforme 8

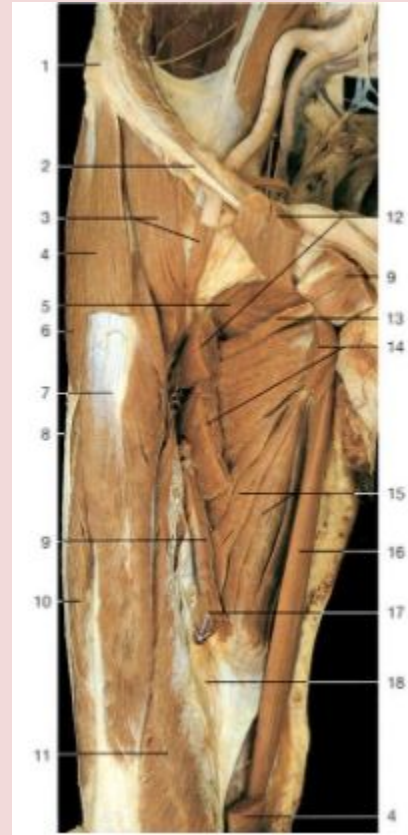


7
из 9

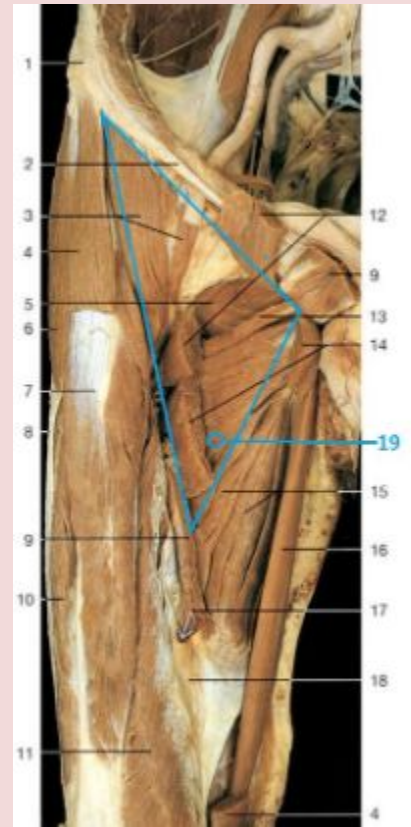
costae 12 5
musculus psoas major 7
arcus iliopectineus 9
musculus psoas minor 6
musculus phrenicus 1
musculus iliacus 3
musculus quadratus lumborum 2
ligamentum inguinale 4
sulcus iliopsoas 8



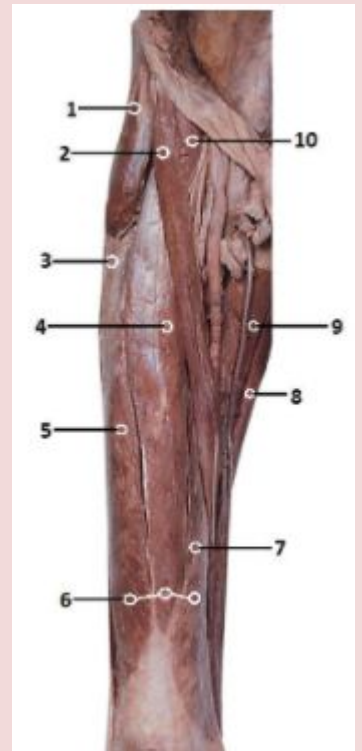tractus iliotibialis 8
musculus adductor longus 9
musculus tensor fasciae latae 6
musculus rectus femoris 7
spina iliaca anterior superior 1
ligamentum inguinale 2
musculus iliopsoas 3
musculus sartorius 4
musculus obturatorius externus 5



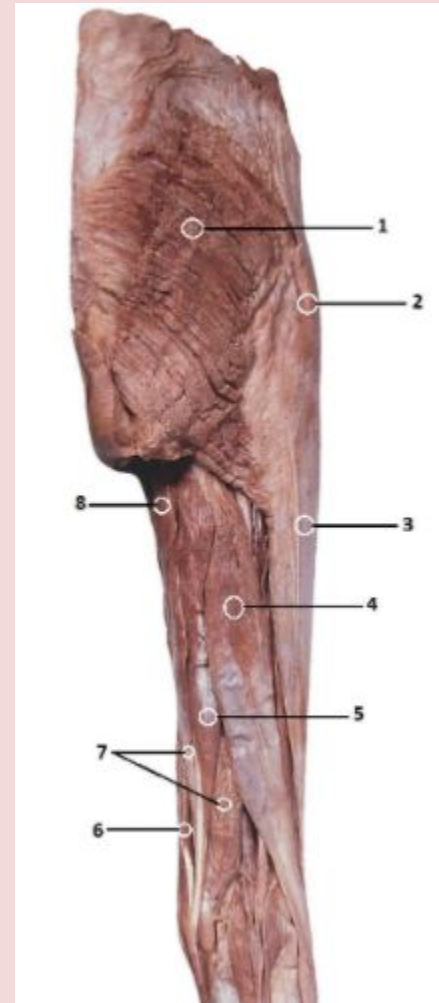
- canalis adductorius 17
- musculus adductor minimus 13
- musculus gracilis 16
- musculus vastus lateralis 10
- trigonum femorale 19
- lamina vastoadductoria 18
- musculus vastus medialis 11
- musculus pectineus 12
- musculus adductor brevis 14
- musculus adductor magnus 15



musculus vastus lateralis 5
musculus rectus femoris 4
musculus gracilis 8
musculus sartorius 2
musculus tensor fasciae latae 1
musculus vastus medialis 7
musculus quadriceps femoris 6
tractus iliotibialis 3
musculus adductor longus 9
musculus iliopsoas 10

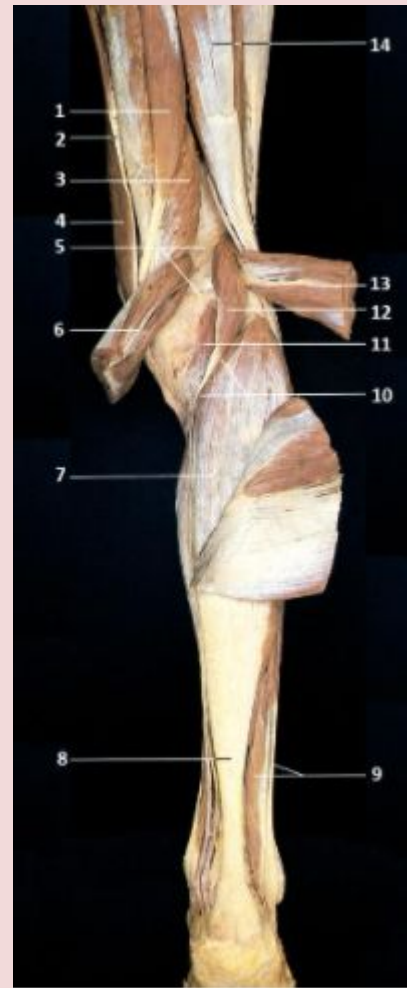

musculus semimembranosus 7
musculus gracilis 6
musculus gluteus maximus 1
musculus semitendinosus 5
musculus adductor magnus 8
tractus iliotibialis 3
musculus tensor fasciae latae 2
musculus biceps femoris 4

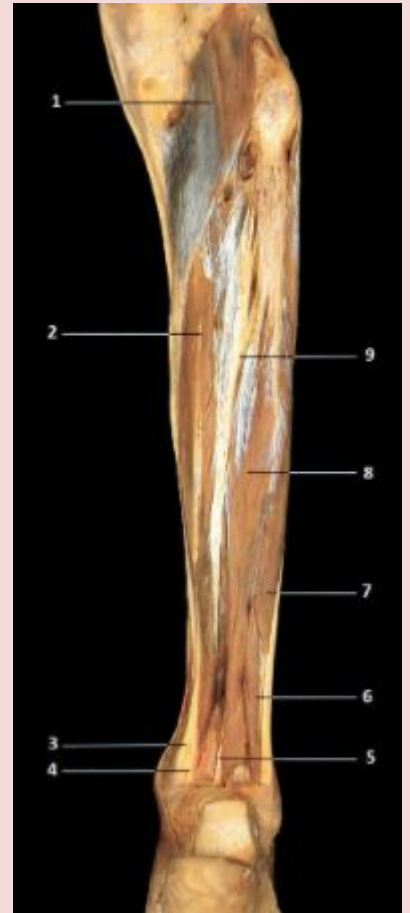


caput mediale musculi gastrocnemii 6
musculus gracilis 2
musculus semitendinosus 1
musculus sartorius 4
tendo achillis 8
musculus semimembranosus 3
fossa poplitea 5
musculus soleus 7

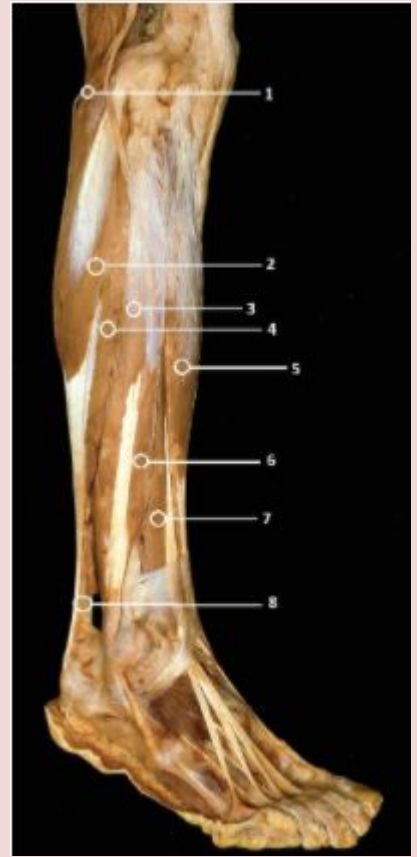caput laterale musculi gastrocnemii 13
musculus popliteus 11
musculus biceps femoris 14
musculus peroneus longus et brevis 9
musculus soleus 10
musculus plantaris 12



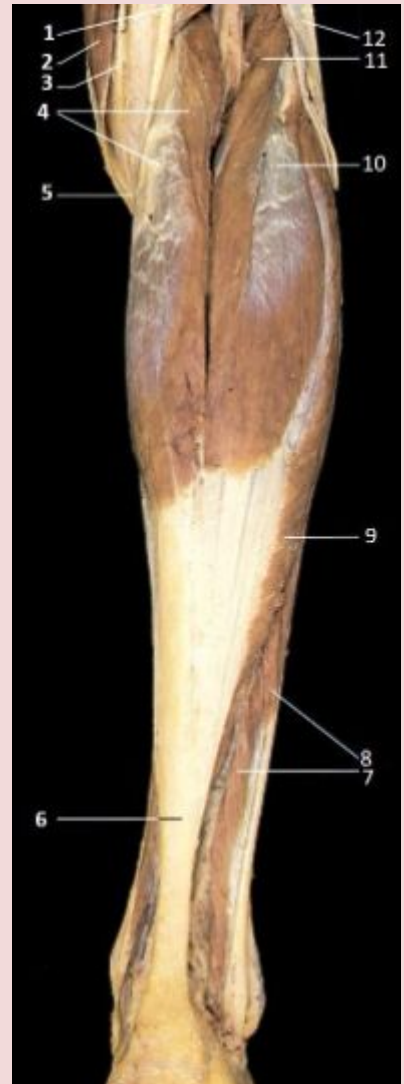musculus popliteus 1
musculus peroneus brevis 6
musculus flexor hallucis longus 8
tendo musculus flexor digitorum longus 4
musculus tibialis posterior 9
musculus flexor digitorum longus 2
tendo musculus tibialis posterior 3
tendo musculus flexor hallucis longus 5
musculus peroneus longus 7



musculus fibularis brevis 6
tendo achillis 8
musculus extensor digitorum longus 7
musculus popliteus 1
musculus tibialis anterior 5
musculus gastrocnemius 2
musculus fibularis longus 3
musculus soleus 4

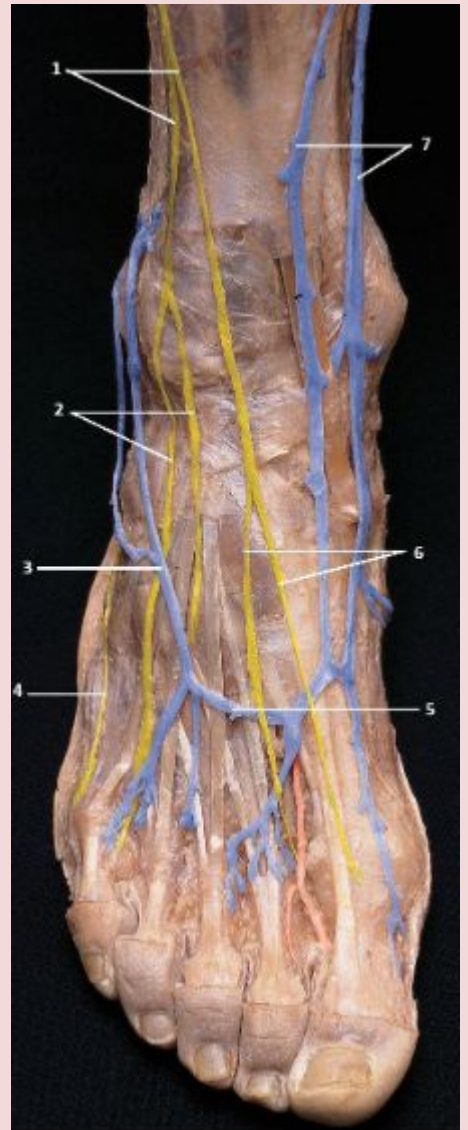


- musculus soleus 9
- musculus plantaris 11
- musculus gracilis 3
- caput mediale musculi gastrocnemii 4
- musculus peroneus brevis 7
- musculus semitendinosus 1
- caput laterale musculi gastrocnemii 10
- musculus sartorius 2
- pes anserinus 5
- tendo achillis 6
- musculus peroneus longus 8
- musculus biceps femoris 12



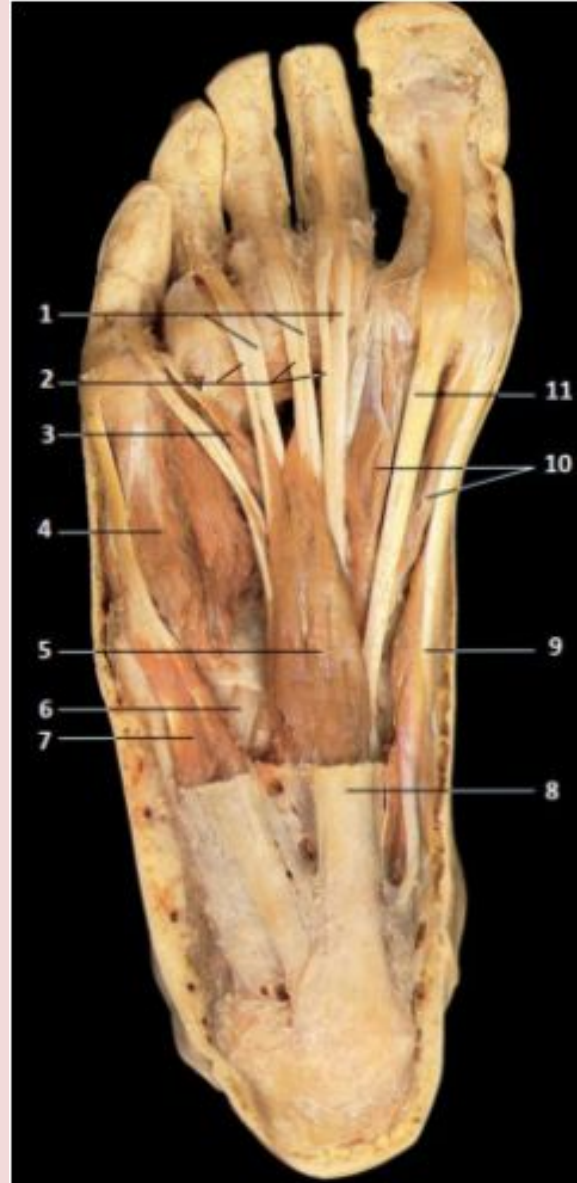
Вены стопа

- nervus cutaneus dorsalis intermedius 2
- nervus cutaneus dorsalis lateralis 4
- vena saphena parva 3
- nervus cutaneus dorsalis medius 6
- arcus venosus dorsalis pedis 5
- nervus fibularis superficialis 1
- vena saphena magna 7

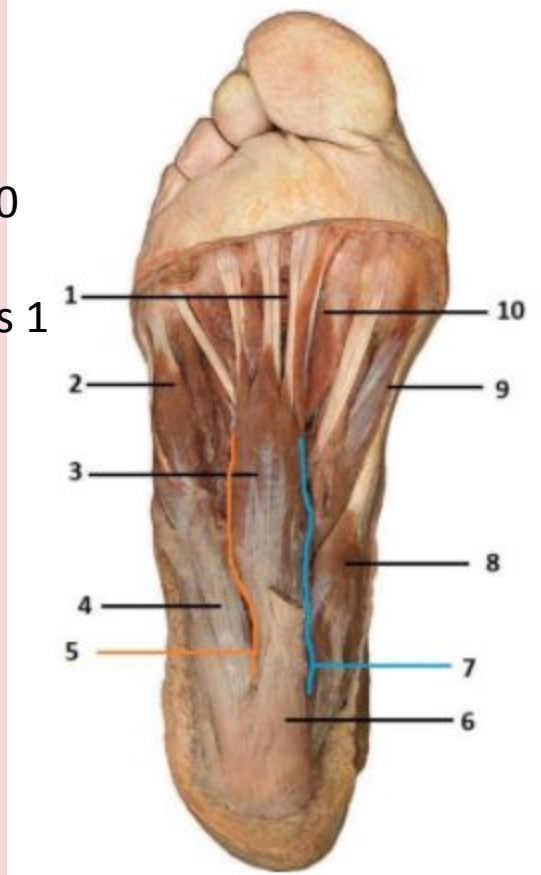


aponeurosis plantaris 8
 musculus flexor hallucis brevis 10
 musculus abductor digiti minimi 7
 tendo musculus flexor digitorum brevis 2
 tendo musculus flexor hallucis longus 11
 musculus lumbricales 3
 musculus flexor digitorum brevis 5
 tendo musculus flexor digitorum longus 1
 musculus flexor digiti minimi 4
 tendo musculus peroneus longus 6
 musculus abductor hallucis brevis 9

**Мышцы
стопа**



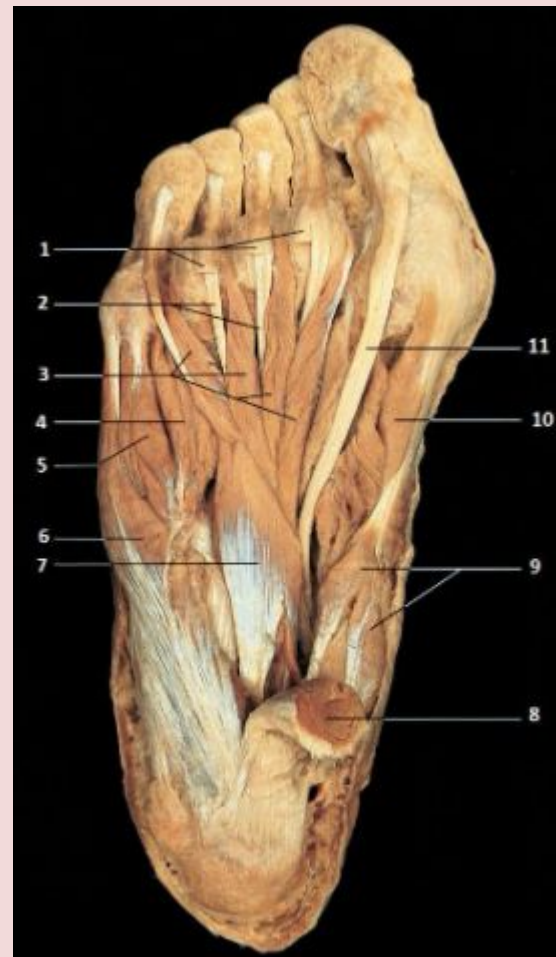
aponeurosis plantaris 6
caput obliquum musculi adductoris hallucis 10
musculus flexor hallucis brevis 9
caput transversum musculi adductoris hallucis 1
musculus flexor digitorum brevis 3
musculus abductor hallucis 8
musculus abductor digiti minimi 4
musculus flexor digiti minimi brevis 2
sulcus plantaris lateralis 5
sulcus plantaris medialis 7



Мышцы
стопа

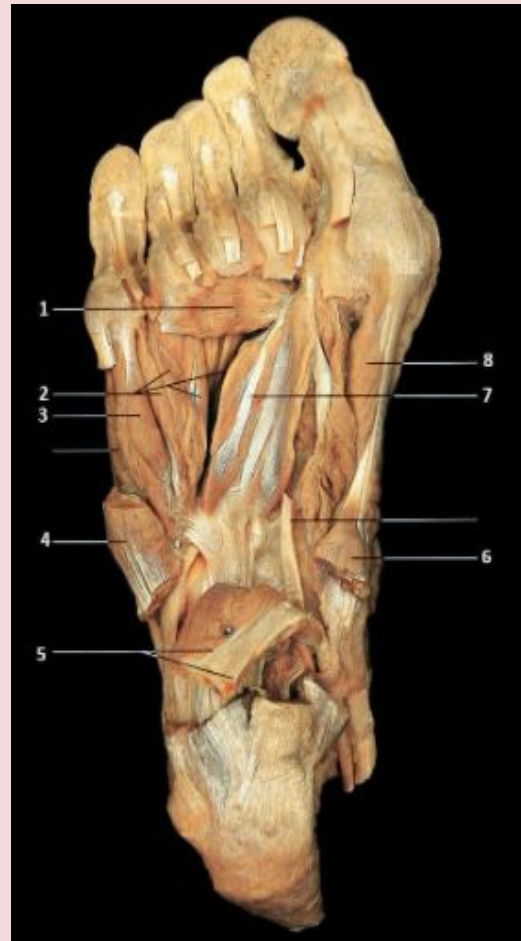
tendo musculus flexor hallucis longus 11
tendo musculus flexor digitorum brevis 1
musculus flexor hallucis brevis 10
musculus abductor digiti minimi 6
musculus interosseus 4
musculus flexor digiti minimi brevis 5
tendo musculus flexor digitorum longus 2
musculus flexor digitorum brevis 8
musculus lumbricales 3
musculus quadratus plantae 7
musculus abductor hallucis 9

Мышцы стопа

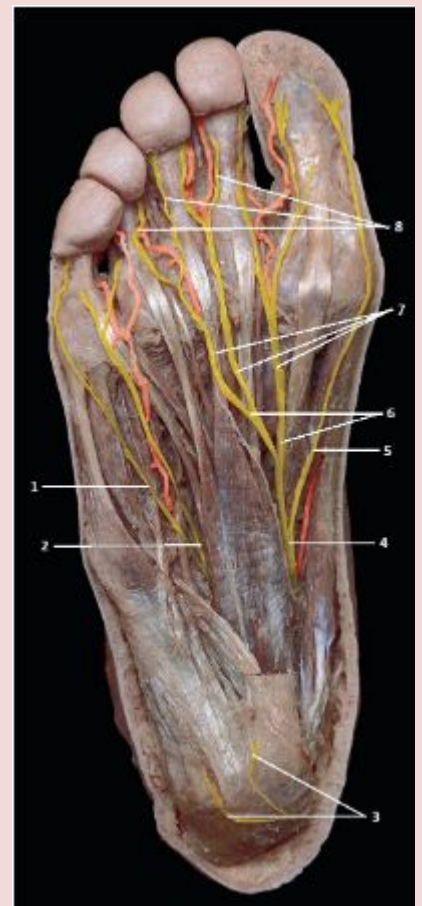


Мышцы стопа

- musculus flexor digiti minimi brevis 3
- musculus abductor digiti minimi 4
- caput obliquum musculi adductoris hallucis 7
- musculi interossei 2
- caput transversum musculi adductoris hallucis 1
- musculus quadratus plantae 5
- musculus abductor hallucis 6
- musculus flexor hallucis brevis 8



nervus digitalis plantaris proprius 8
ramus calcaneus medialis 3
ramus digitali nervus palmaris nervi mediani 6
nervus digitalis plantaris communis 7
ramus superficialis nervus plantaris lateralis 1
nervus hallucis plantaris medialis 5
nervus plantaris lateralis 2
nervus plantaris medialis 4



Нервы
стопа

Артерии

стопа

arteria plantaris medialis 1

musculus adductor hallucis caput obliquum 7

arteria metatarssea plantaris 3

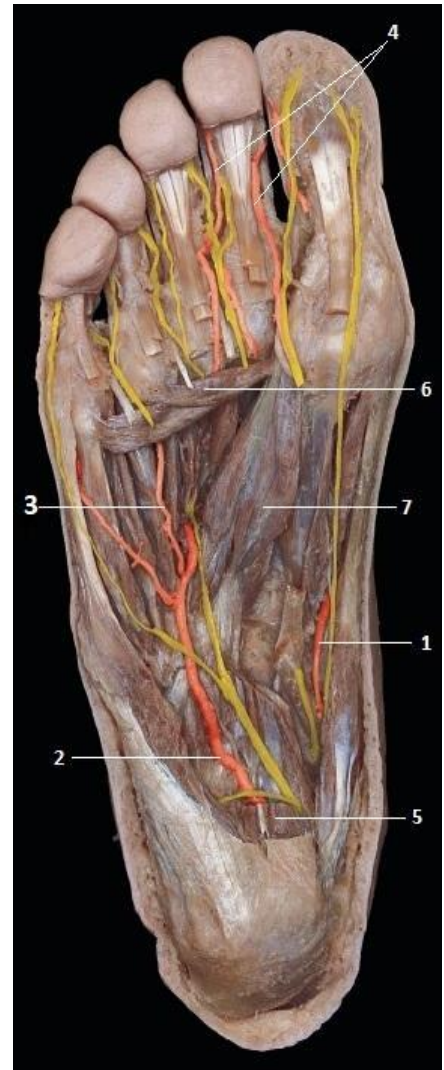
musculus adductor hallucis caput transversum 6

arteria digitalis plantaris 4

musculus adductor hallucis caput transversum 6

arteria plantaris lateralis 2

musculus flexor digitorum brevis 5



Артерии стопа

arteria plantaris lateralis 2

arcus plantaris 4

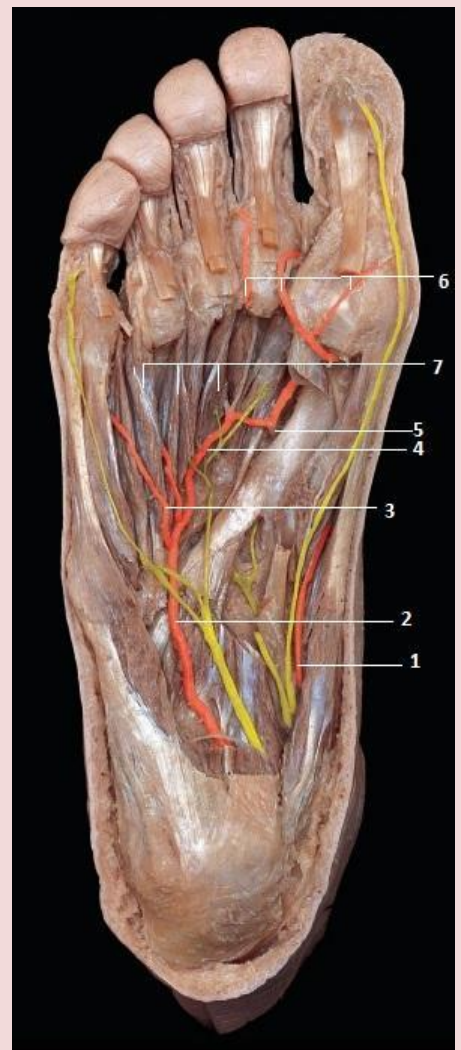
arteria digitalis palmaris communis 6

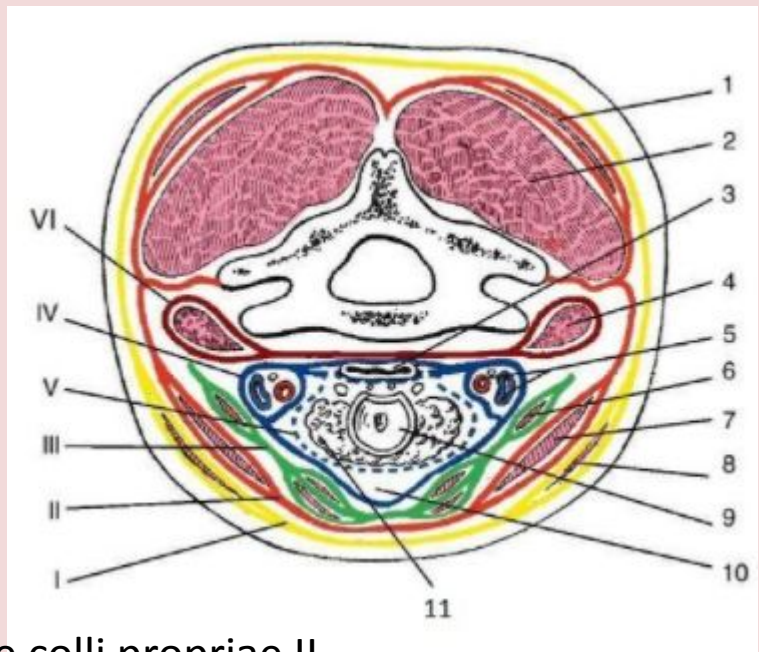
musculi interossei dorsales 7

arteria plantaris medialis 1

arteria metatarssea plantaris 3

ramus plantaris arteria dorsalis pedis 5





fascia superficialis I

lamina superficialis fasciae colli propriae II

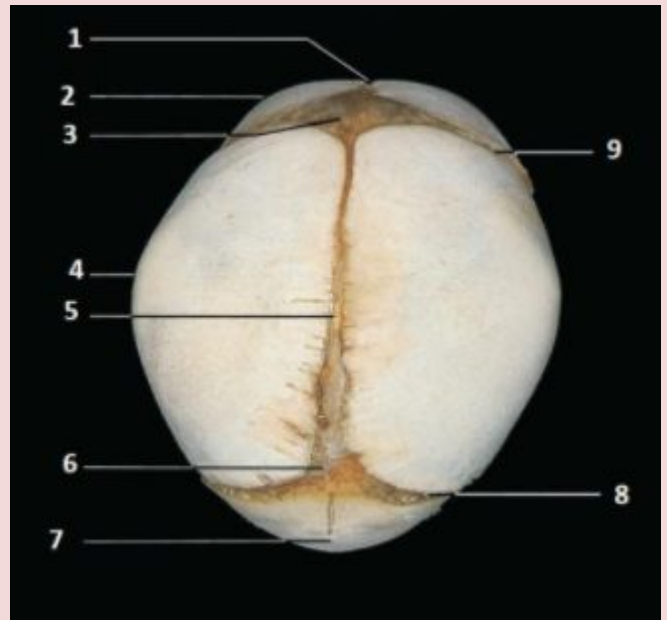
lamina profunda fasciae colli propriae III

lamina visceralis fasciae endocervicalis IV

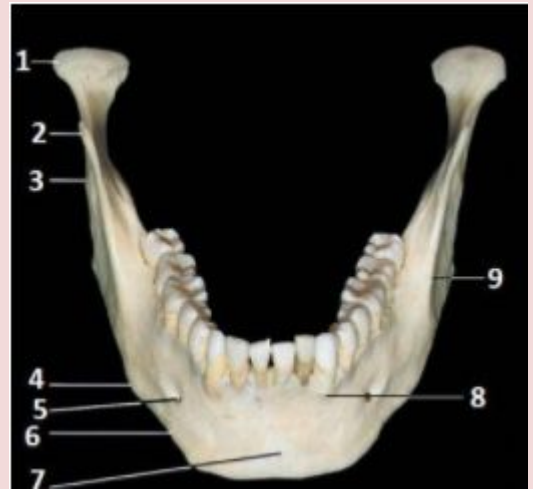
fascia prevertebralis V

lamina parietalis fasciae endocervicalis VI

fonticulus lambdoideus 6
fonticulus anterior 3
sutura frontalis 1
sutura lambdoidea 8
sutura coronoidea 9
sutura sagittalis 5
tuber occipitale 7
tuber frontalis 2
tuber parietale 4

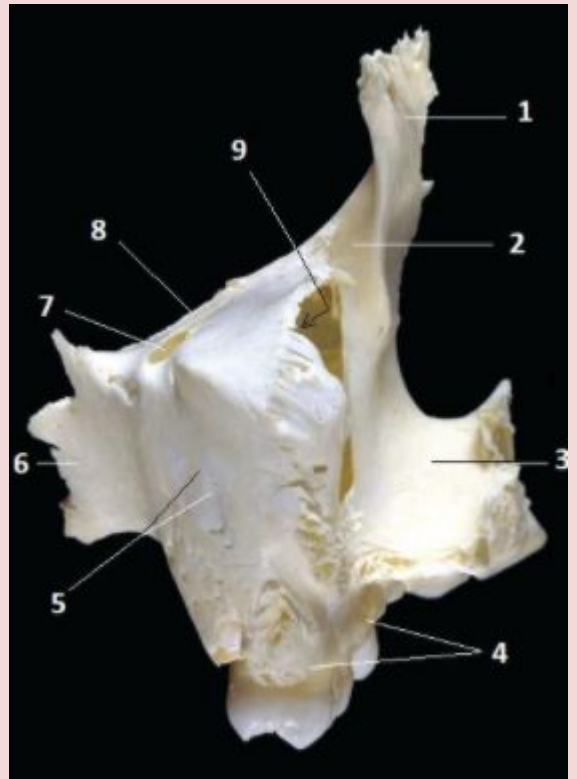


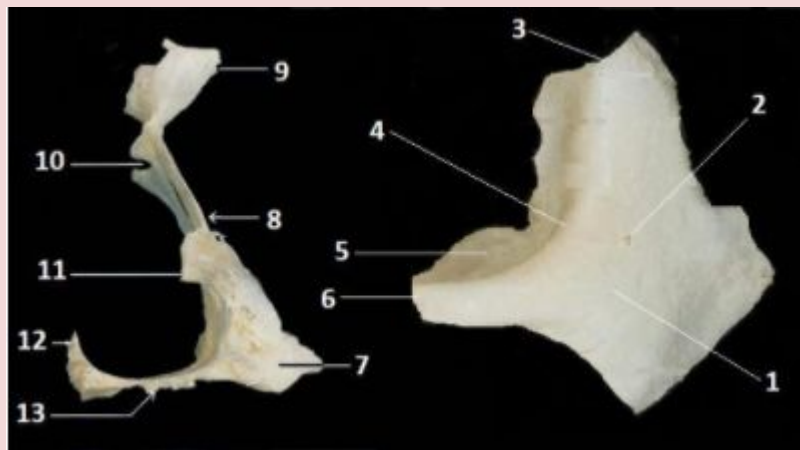protuberantia mentalis 7.
foramen mentale 5.
processus coronoideus 2.
linea obliqua 9
tuberositas masseterica 3
arcus alveolaris mandibulae 8
processus condylaris 1
corpus mandibulae 6.
angulus mandibulae 4.



6
из 9

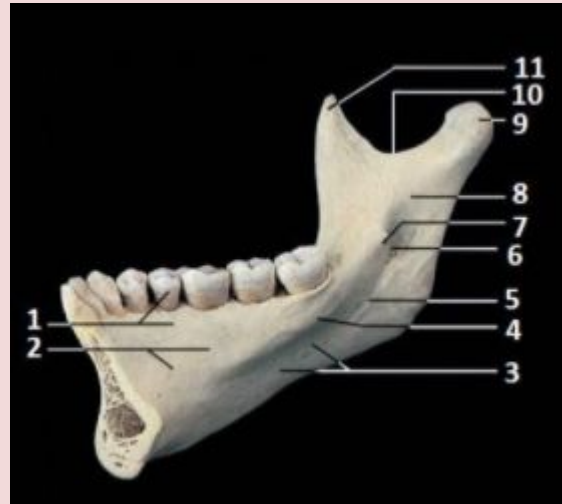
processus zygomaticus 6
processus alveolaris 4.
processus palatinus 3.
sulcus intraorbitalis 7
tuber maxillae 5
facies orbitalis 8
processus frontalis 1.
sulcus lacrimalis 2.
sinus maxillaris 9



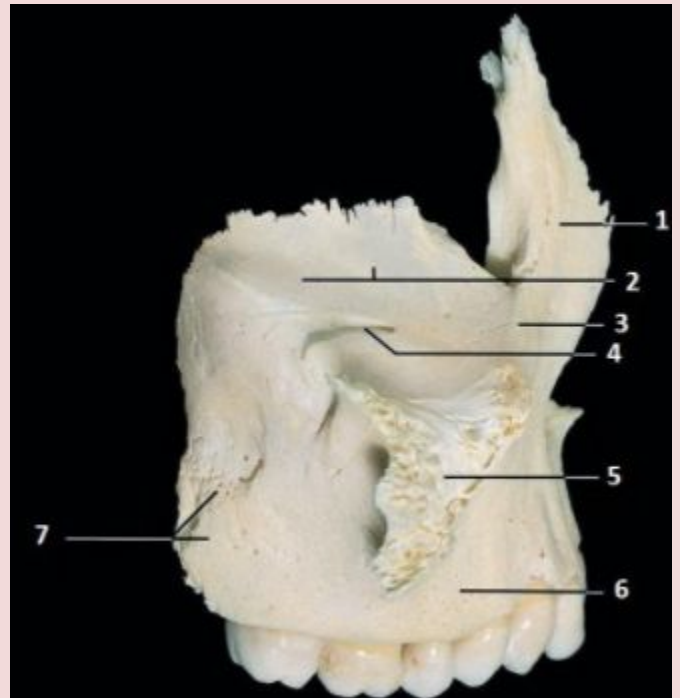


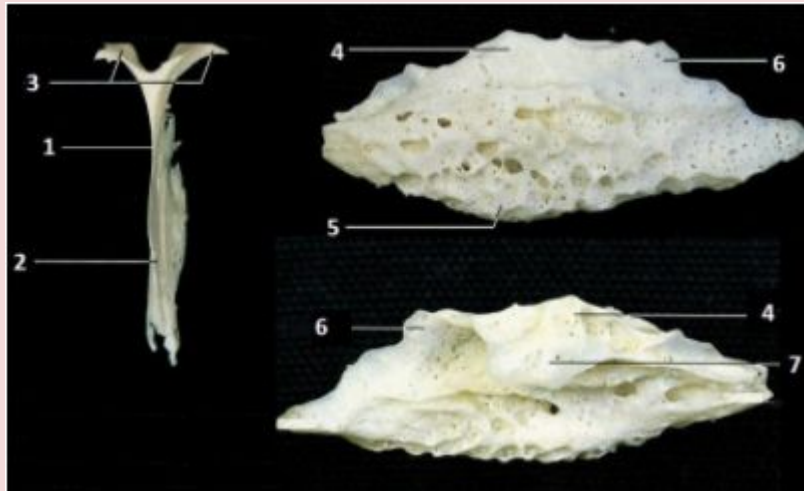
- acies lateralis os zygomaticum 1.
- facies orbitalis os zygomaticum 5
- incisura sphenopalatina 10.
- processus pyramidalis os palatinum 7.
- crista nasalis 12.
- margo orbitalis os zygomaticum 4
- crista conchalis 11.
- foramen zygomaticoorbitale 2 .
- processus frontalis os zygomaticum 3
- os zygomaticum 1
- lamina perpendicularis 8.
- processus orbitalis 9.
- lamina horizontalis 13.

sulcus mylohyoideus 5
foramen mandibulae 6
ramus mandibulae 8
processus coronoideus 11
fossa sublingualis 2
incisura mandibulae 10
fovea submandibularis 3
arcus alveolaris mandibulae 1
linea mylohyoidea 4
lingula mandibulae 7
caput mandibulae 9



processus zygomaticus 5
tuber maxillae 7
processus frontalis os maxilla 1
sulcus intraorbitalis 4
facies orbitalis maxillae 2
margo infraorbitalis 3
processus alveolaris 6





processus lacrimalis concha nasalis inferior 6

ala vomeris 3

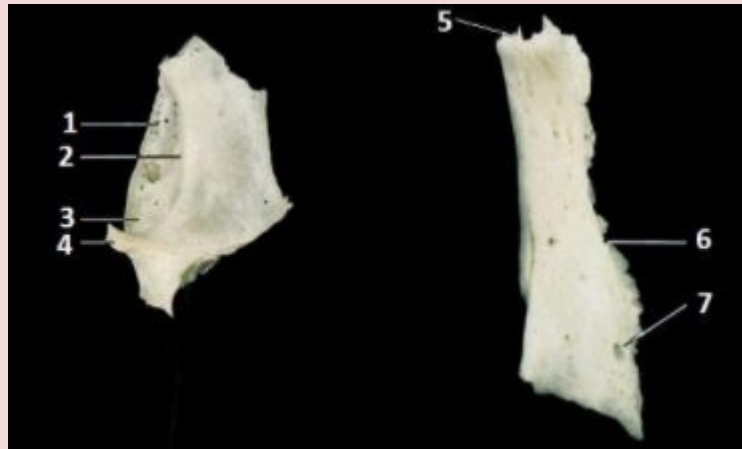
processus maxillaris concha nasalis inferior 7

Vomer 1

margo posterior vomeris 2

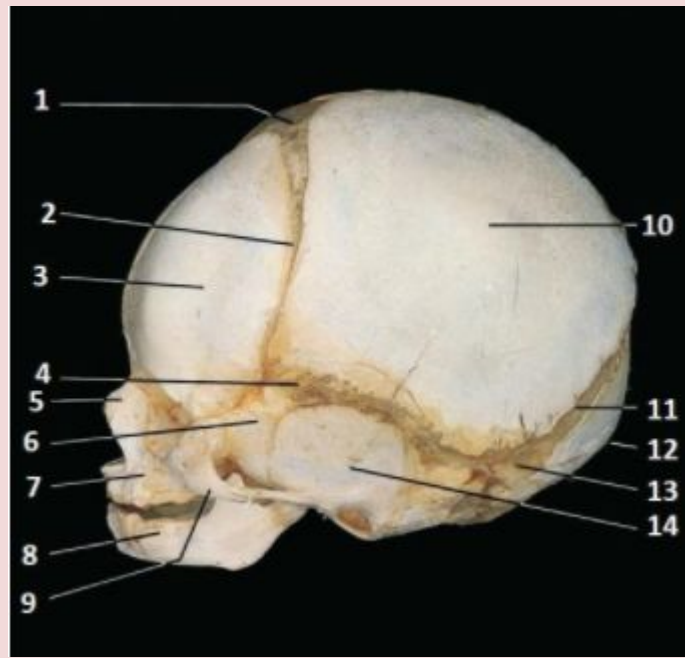
margo inferior concha nasalis inferior 5

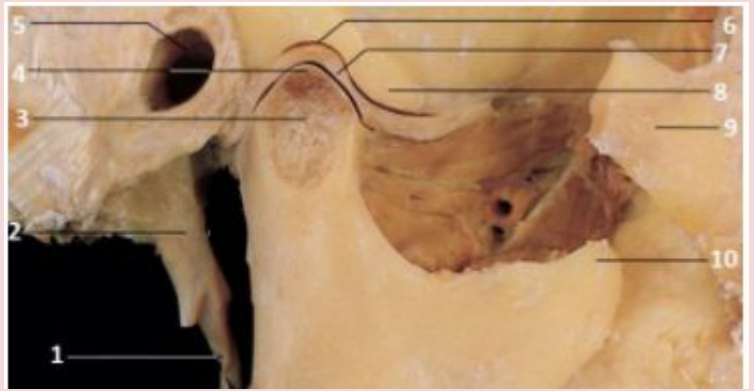
processus ethmoidalis concha nasalis inferior 4



- hamulus lacrimalis 4
- margo lateralis os nasale 6
- fossa sacculi lacrimalis 3
- foramen os nasale 7
- margo superior os nasale 5
- sulcus lacrimalis 1
- crista lacrimalis posterior 2

fonticulus mastoideus 13
sutura lambdoidea 11
sutura coronoidea 2
tuber frontalis 3
ala major ossis sphenoidalis 6
fonticulus sphenoidalis 4
os nasale 5
tuber occipitale 12
fonticulus anterior 1
Maxilla 7
Mandibula 8
os zygomaticum 9
tuber parietale 10
squama temporalis 14

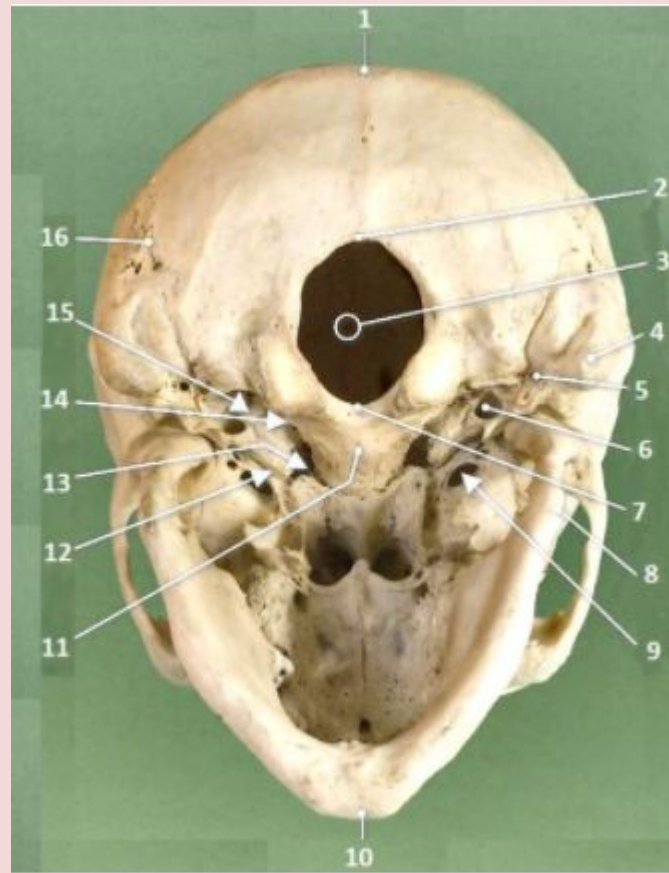




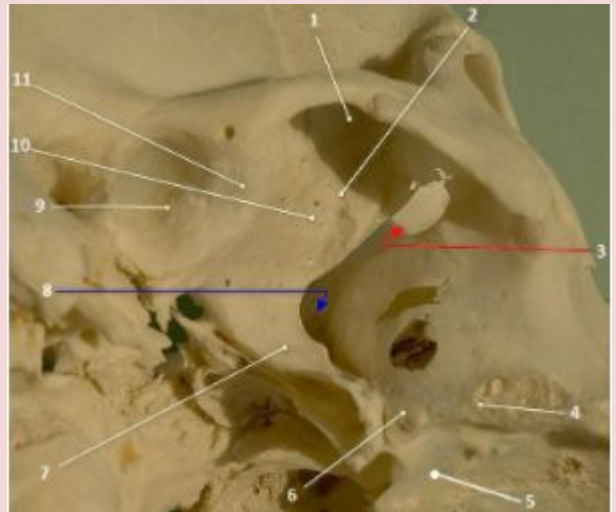
- meatus acusticus externus 5
- processus coronoideus 10
- processus condylaris 3
- processus styloideus 2
- fossa mandibularis 6
- ligamentum stylomandibulare 1
- facies articularis processus condylaris 4
- tuberculum articulare 8
- discus articularis 7
- os zygomaticum 9

fissura sphenopetrosa 12
protuberantia mentalis 10
foramen lacerum 13
sutura occipitomastoidea 16
foramen ovale 9
tuberculum pharyngeum 11
fissura petrooccipitalis 14
foramen jugulare 15

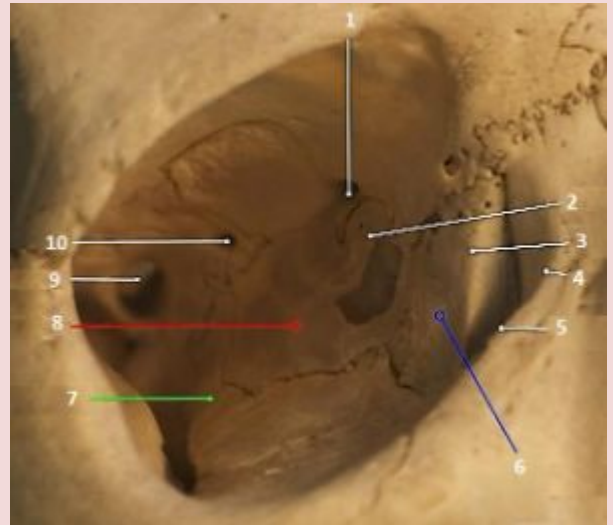
foramen stylomastoideum 5
margo anterior foramen magnum 2
foramen magnum 3
margo posterior foramen magnum 7
os occipitale 1
processus mastoideus 4
canalis caroticus 6
angulus mandibulae



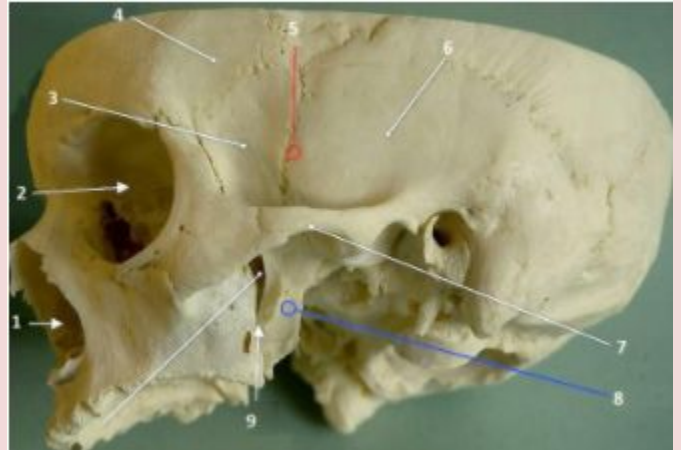
- fissura orbitalis inferior 3
- fossa pterygopalatina 8
- processus alveolaris 4
- fossa temporalis 1
- ala major ossis sphenoidalis 10
- fossa mandibularis 9
- tuberculum articulare 11
- palatum osseum 5
- crista infratemporalis 2
- tuber maxillae 6
- lamina lateralis processus pterygoidei 7

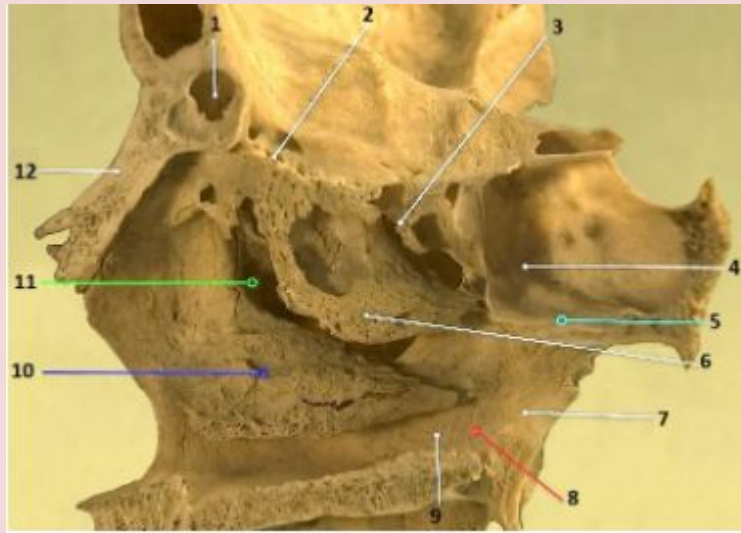


- crista lacrimalis anterior 4
- crista lacrimalis posterior 3
- lamina orbitalis ossis ethmoidalis 8
- paries medialis orbitae 2
- foramen ethmoidale anterius 1
- processus orbitalis ossis palatini 7
- margo medialis 5
- os lacrimale 6
- canalis opticus 9
- foramen ethmoidale posterius 10



- apertura piriformis 1
- aditus orbitae 2
- squama temporalis 6
- fossa infratemporalis 8
- facies temporalis 4
- ala major ossis sphenoidalis 3
- fossa temporalis 5
- arcus zygomaticus 7
- fossa pterygopalatina 9





os sphenoidale 5

lamina perpendicularis ossis palatini 9

os lacrimale 11

concha nasalis superior 3

os palatinum 8

concha nasalis inferior 10

os nasale 12

sinus frontalis 1

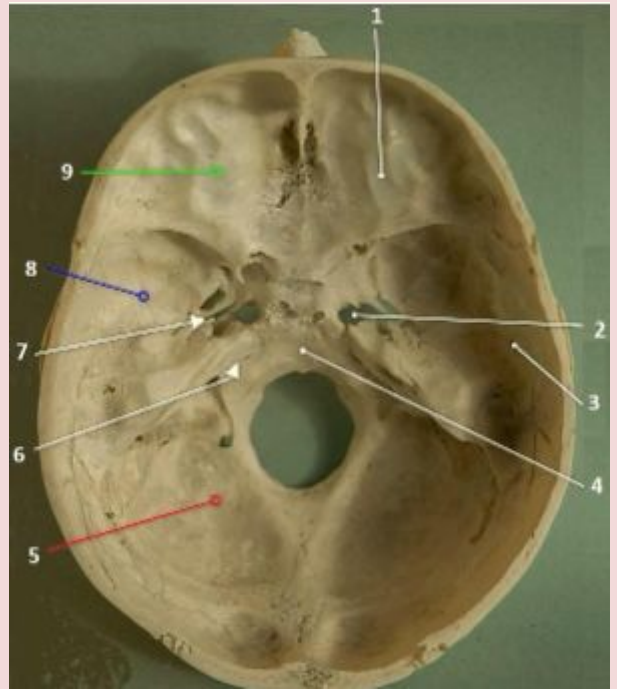
lamina cribrosa 2

sinus sphenoidalis 4

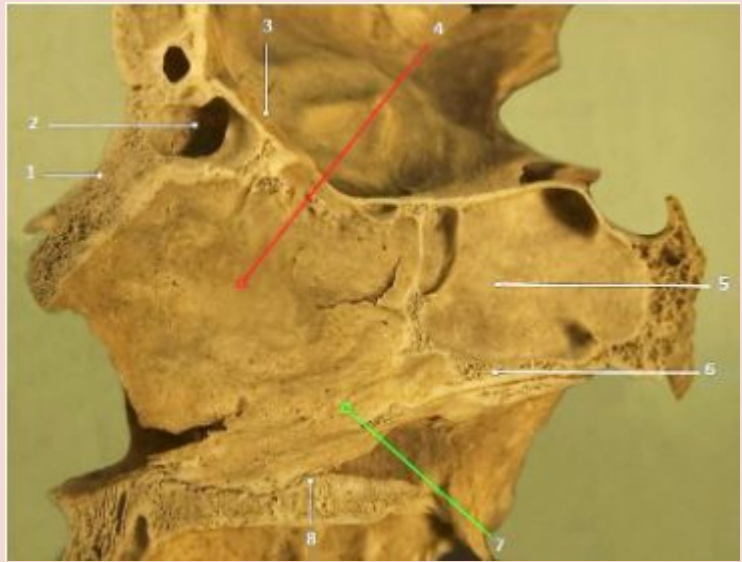
concha nasalis media 6

lamina medialis processus pterygoidei 7

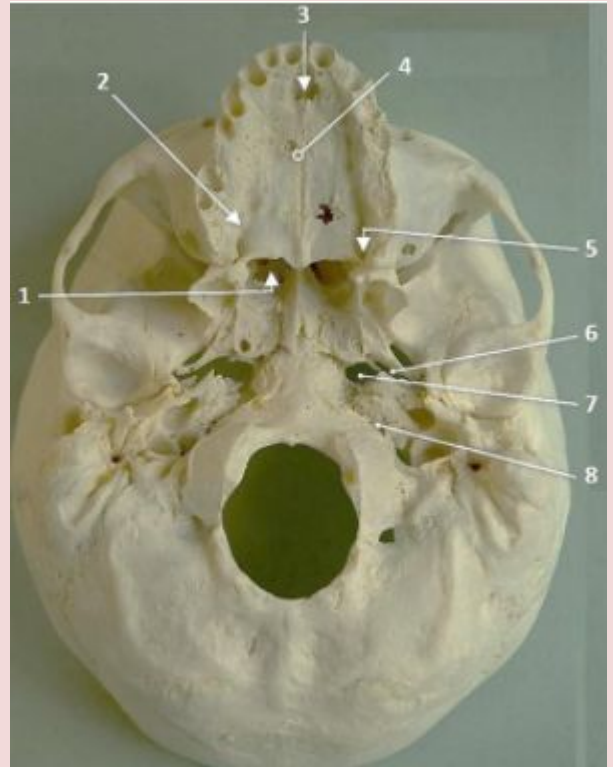
foramen lacerum 2
fossa cranii media 8
Clivus 4
fossa cranii anterior 9
fossa cranii posterior 5
fissura sphenopetrosa 7
fissura petrooccipitalis 6
impressiones digitatae 1
sulci arteriosi 3

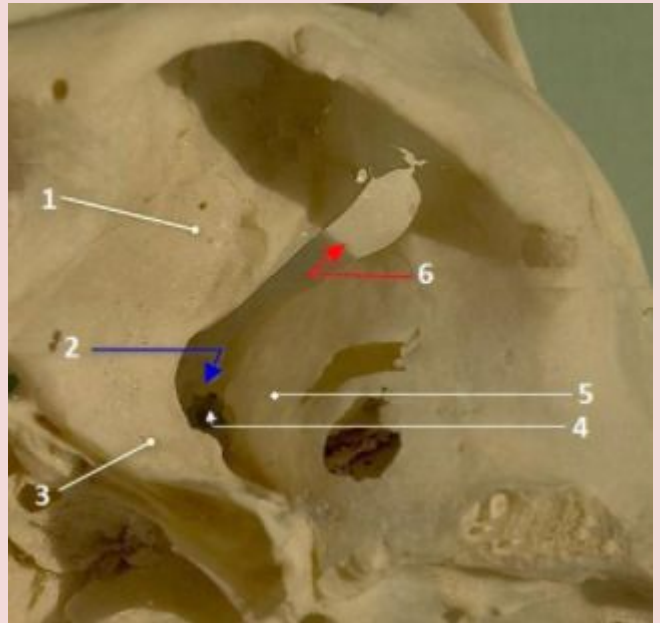


crista nasalis 8
lamina perpendicularis 4
os nasale 1
crista galli 3
Vomer 7
sinus frontalis 2
sinus sphenoidalis 5
rostrum sphenoidale 6



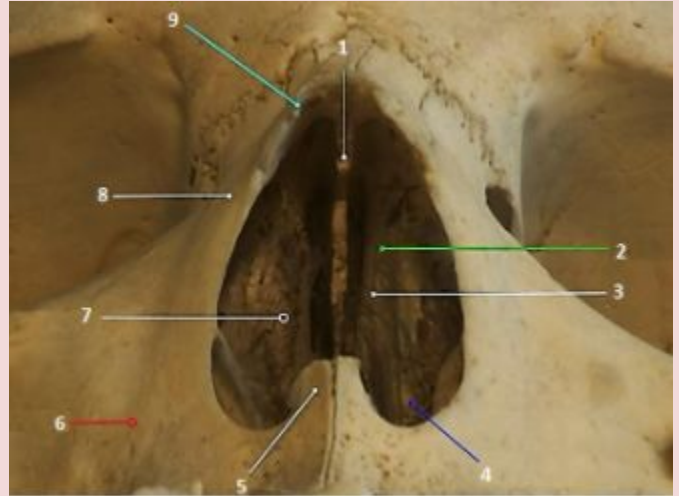palatum osseum 4
fissura sphenopetrosa 6
foramen lacerum 7
fissura petrooccipitalis 8
canalis palatinus major 5
Choanae 1
canalis palatinus minor 2
canalis incisivus 3

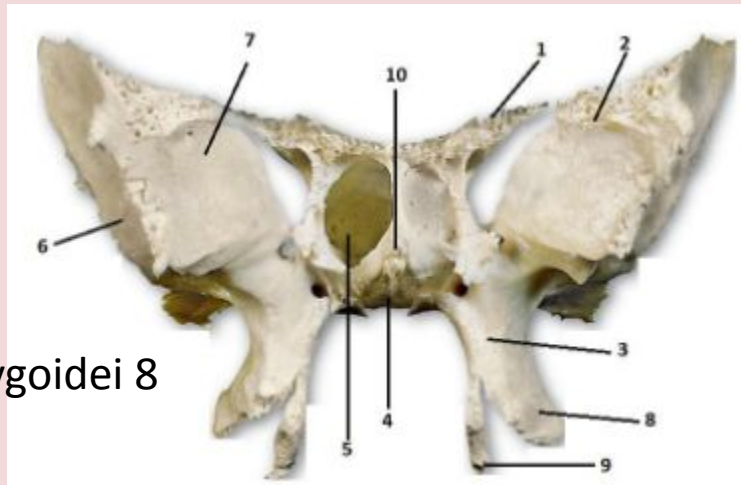




- ala major ossis sphenoidalis 1
- fossa pterygopalatina 2
- tuber maxillae 5
- foramen sphenopalatinum 4
- lamina lateralis processus pterygoidei 3
- fissura orbitalis inferior 6

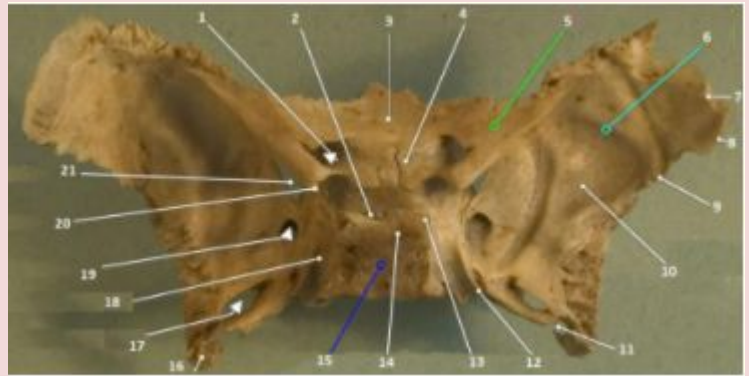
os nasale 9
os ethmoidale 2
concha nasalis media 3
spina nasalis anterior 5
apertura piriformis 7
lamina perpendicularis ossis ethmoidalis 1
concha nasalis inferior 4
Maxilla 6
processus frontalis os maxilla 8





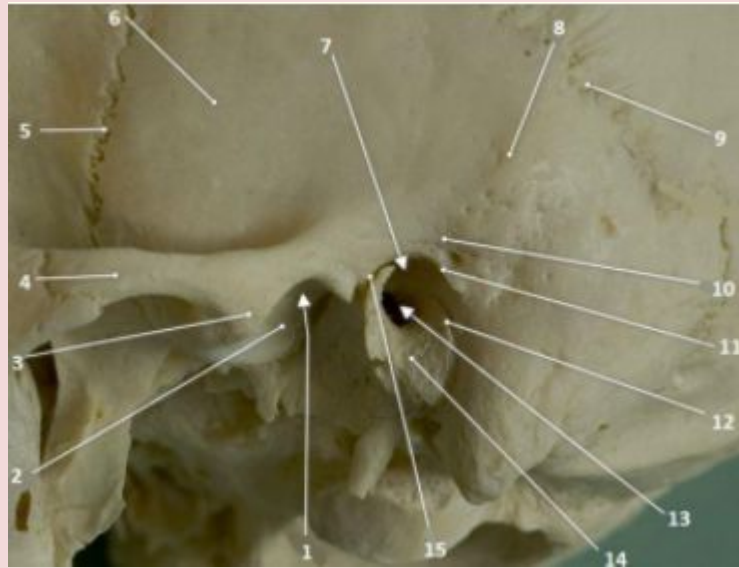
- lamina lateralis processus pterygoidei 8
- ala major ossis sphenoidalis 2
- corpus ossis sphenoidalis 4
- lamina medialis processus pterygoidei 9
- ala minor ossis sphenoidalis 1
- facies temporalis 6
- facies orbitalis 7
- processus pterygoideus ossis sphenoidalis 3
- sinus sphenoidalis 5
- rostrum sphenoidale 10

facies cerebralis 10
canalis opticus 1
sulcus chiasmatis 4
jugum sphenoidale 3
ala minor 5
sella turcica 2
ala major 6
Margo frontalis 7
margo parietalis 8
margo squamosus 9

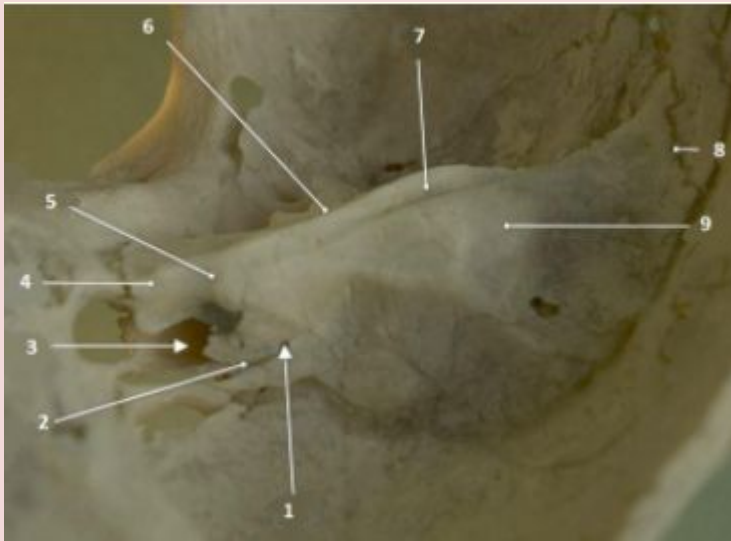


processus clinoides posterior 13
lingula sphenoidalis 12
dorsum sellae 14
foramen rotundum 19
corpus sphenoidalis 15
processus clinoides anterior 20
foramen spinosum 11
spina ossis sphenoidalis 16
foramen ovale 17
sulcus caroticus 18
fissura orbitalis superior 21

pars tympanica 14
crista supramastoidea 8
margo parietalis 9
meatus acusticus externus 13
fissura tympanosquamosa 15
foveola suprameatica 10
spina suprameatica 11
fissura tympanomastoidea 12

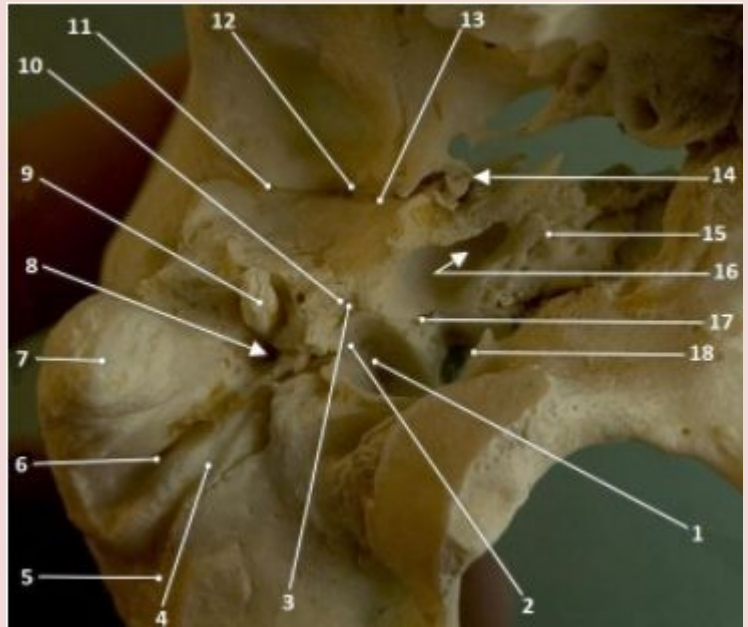


facies articularis 2
processus zygomaticus 4
facies temporalis 6
tuberculum articulare 3
fossa mandibularis 1
margo sphenoidalis 5
incisura tympanica 7




- sulcus nervi petrosi superioris 7
- eminentia arcuata 9
- impressio trigeminalis 5
- sulcus nervi petrosi majoris 2
- margo superior partis petrosae 6
- fissura petrosquamosa 8
- hiatus canalis nervi petrosi majoris 1
- canalis caroticus 3
- apex partis petrosae 4

processus mastoideus 7
 canaliculus mastoideus 2
 foramen stylomastoideum 8
 processus styloideus 9
 sulcus arteria occipitalis 4
 fossa jugularis 1
 canaliculus tympanicus 3
 margo occipitalis 5
 incisura mastoidea 6

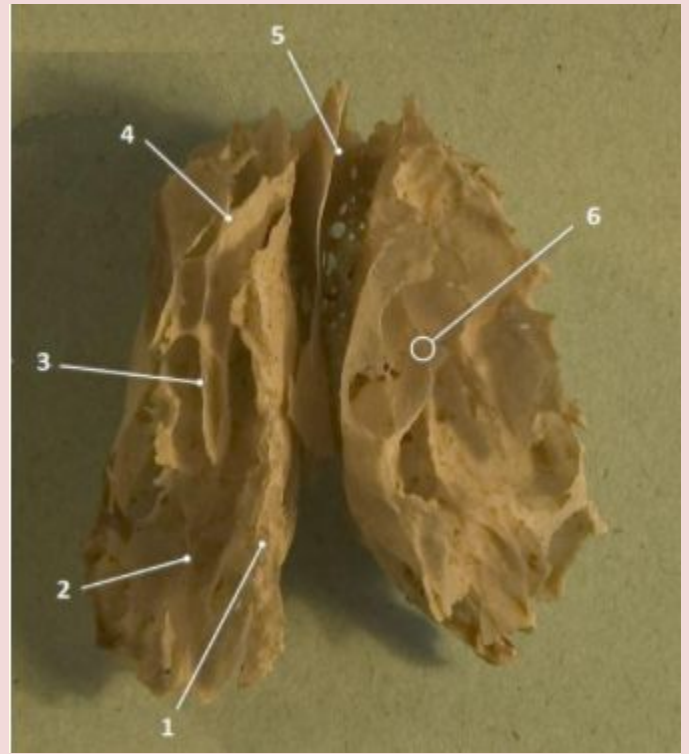


fissura petrosquamosa 12
 fossula petrosa 10
 apertura canaliculi cochleae 17
 foramen jugulare 18
 fissura petrotympanica 13
 apex partis petrosae 15
 fissura tympanosquamosa 11
 canalis musculotubarius 14
 canalis caroticus 16


lamina cribrosa 5
cellulae ethmoidales 1
foramina cribrosa 4
concha nasalis media 2
lamina orbitalis 3
crista galli 6



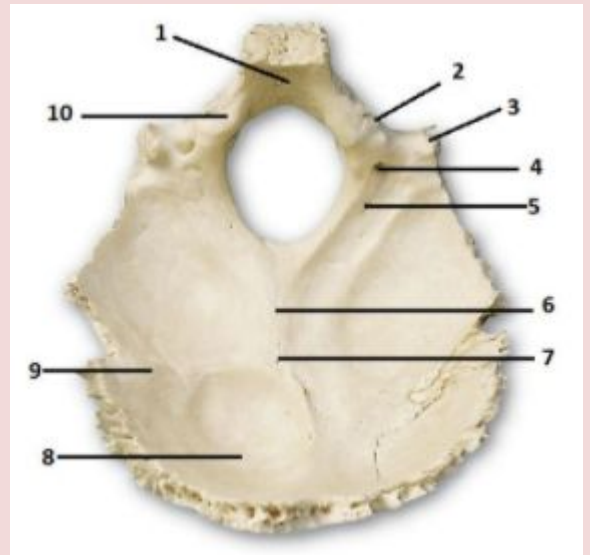
labyrinthus ethmoidalis 6
cellulae ethmoidales anteriores 4
cellulae ethmoidales mediae 3
cellulae ethmoidales posteriores 2
concha nasalis media 1
lamina perpendicularis 5



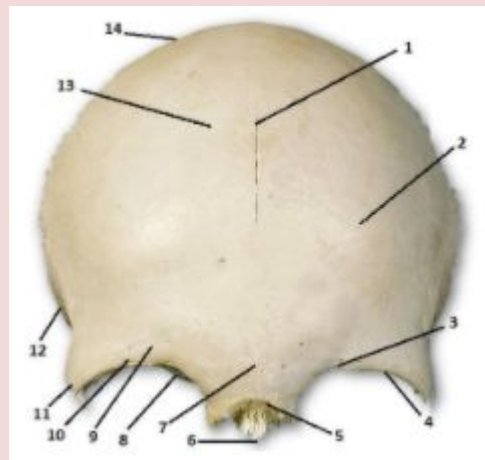
crista frontalis 2
margo parietalis 8
foramen cecum 3
margo nasalis 4
sulcus sinus sagittalis superioris 1
spina nasalis 5
pars orbitalis 6
facies interna 7



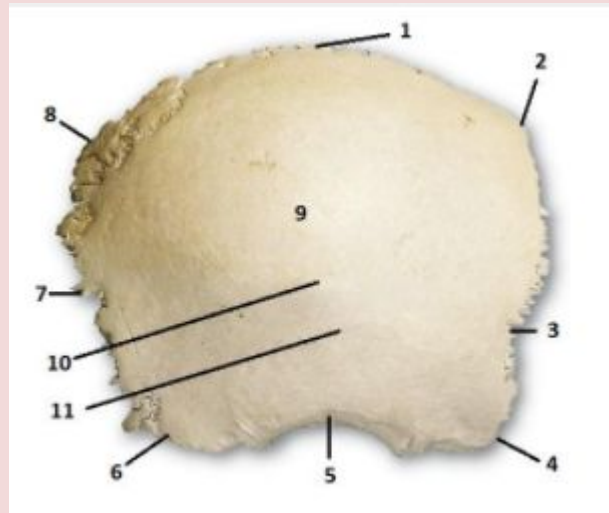
pars basilaris 1
squama occipitalis 8
incisura jugularis 2
protuberantia occipitalis interna 7
canalis condylaris 4
crista occipitalis interna 6
processus jugularis 3
sulcus sinus sigmoidei 5
sulcus sinus transversus 9
tuberculum condylaris 10



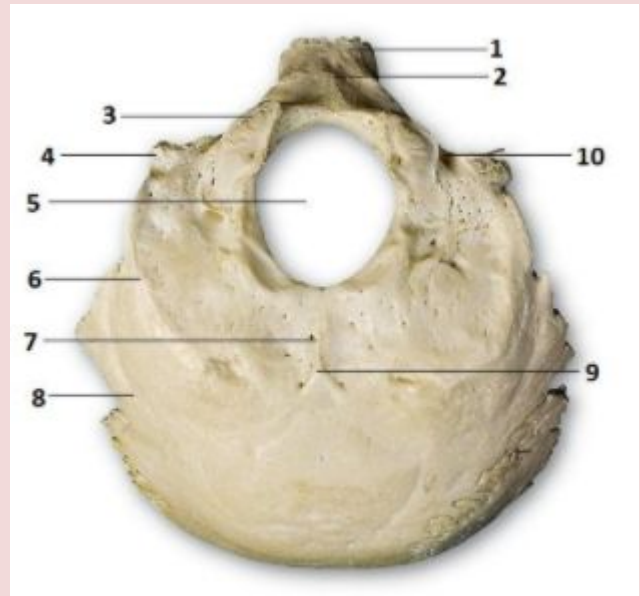
foramen supraorbitale 10
incisura frontalis 3
facies temporalis 12
Glabella 7
sutura frontalis 1
margo parietalis 14
processus zygomaticus 11
squama frontalis 13
tuber frontale 2
Margo supraorbitalis 4
pars nasalis 5
spina nasalis 6
pars orbitalis 8
arcus superciliaris 9

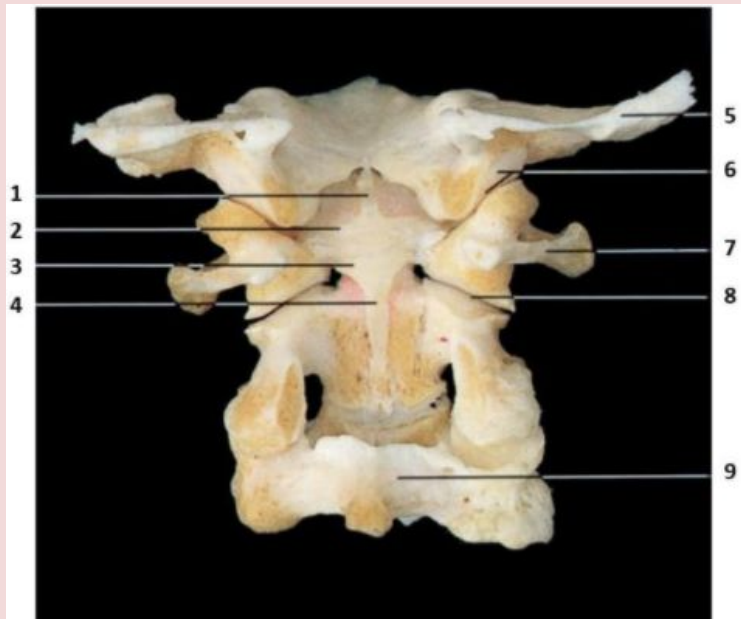


tuber occipitale 9
angulus occipitalis 8
linea nuchae inferior 11
angulus sphenoidalis 4
angulus mastoideus 6
linea nuchae superior 10
margo squamosa 5
angulus frontalis 2
margo sagittalis 1
margo frontalis 3
margo occipitalis 7



pars basilaris 1
processus jugularis 4
canalis condylaris 10
protuberantia occipitalis externa 9
foramen magnum 5
condylus occipitalis 3
tuberculum pharyngeum 2
linea nuchae inferior 6
crista occipitalis externa 7
linea nuchae superior 8





Ligg. Alaria 2

processus transversus (foramen transversarium) 7

Fasciculi longitudinales superior 1

CIII 9

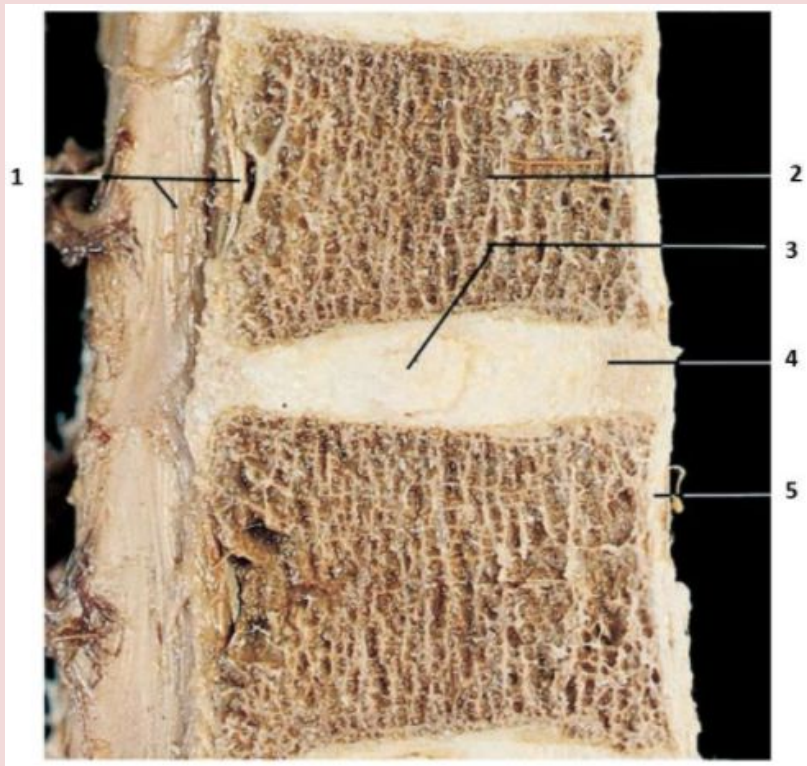
Lig. transversum atlantis 3

Articulatio atlantoaxialis lateralis 8

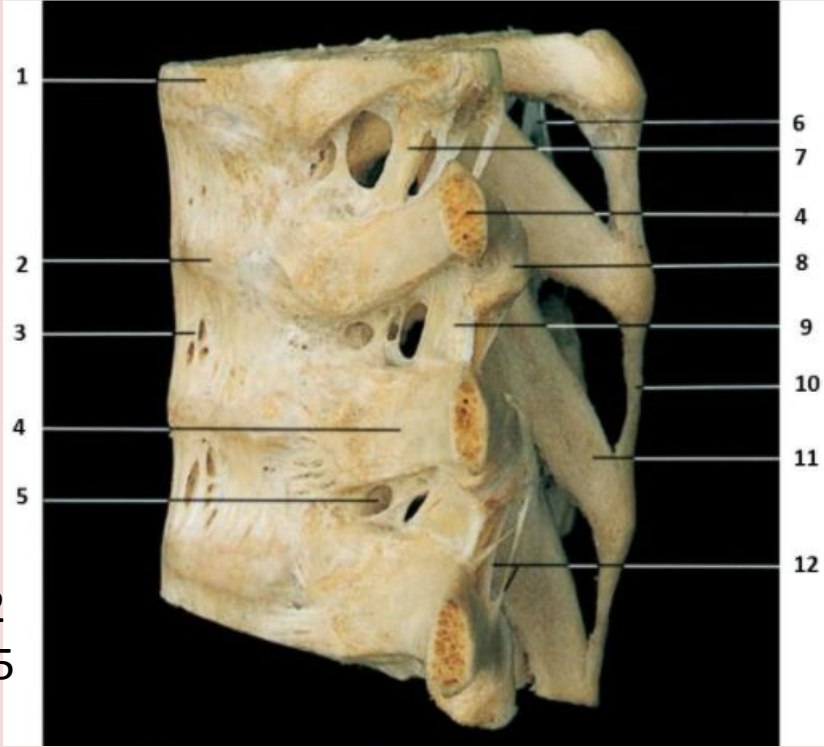
Fasciculi longitudinales inferior 4

os occipitale 5

Articulatio **atlantooccipitalis** 6



- Nucleus pulposus discus intervertebralis 3
- corpus vertebrae 2
- Anulus fibrosus discus intervertebralis 4
- Lig. longitudinale posterius 1
- Lig. longitudinale anterius 5



ligg. Interspinalia 6

ligg. Intertransversaria 12

foramen intervertebrale 5

processus spinosus 11

lig. costotransversarium superius 7/9

ligg. Intertransversaria 12

Costae 4

discus intervertebralis 2

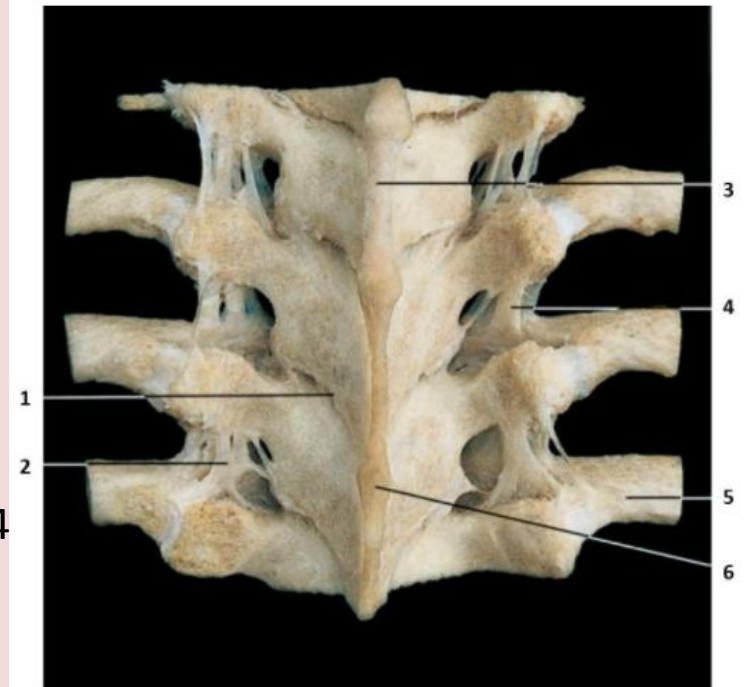
lig. longitudinale anterius 3

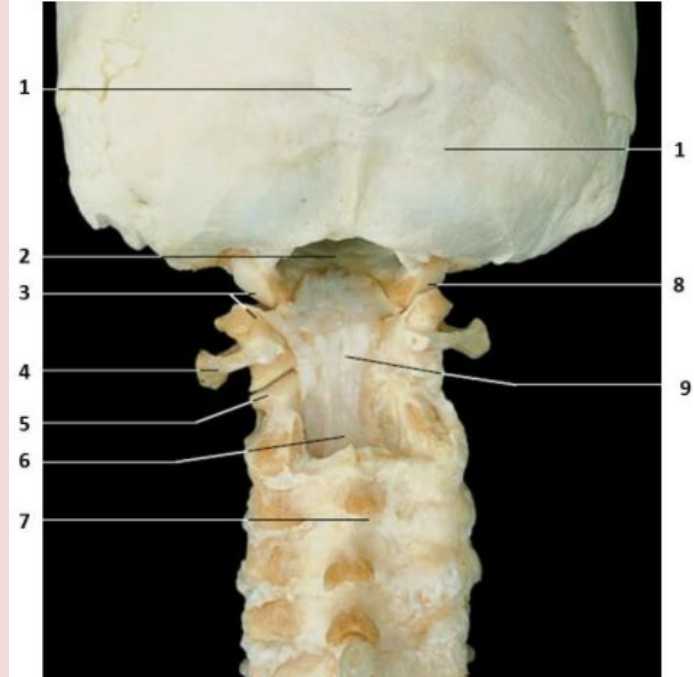
Corpus vertebrae 1

processus transversus 8

lig. Supraspinale 10

Lig. Supraspinale 3
Ligg. Intertransversaria 2
processus spinosus 6
Lig.flavum 1
Lig. costotransversarium superius 4
Costae 5





processus spinosus 7

condylus occipitalis 8

Articulatio atlantoaxialis lateralis 5

os occipitale 1

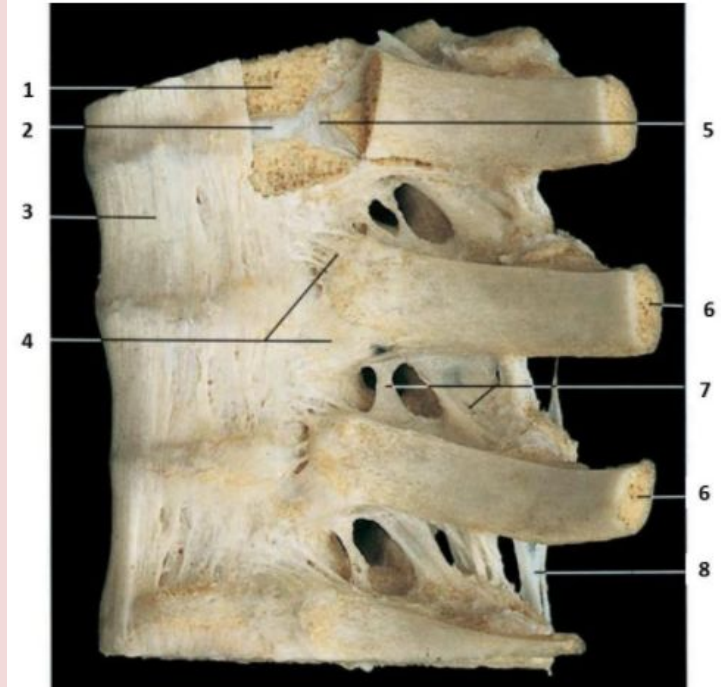
membrana tectoria 9

Foramen magnum 2

Articulatio **atlantooccipitalis 3**

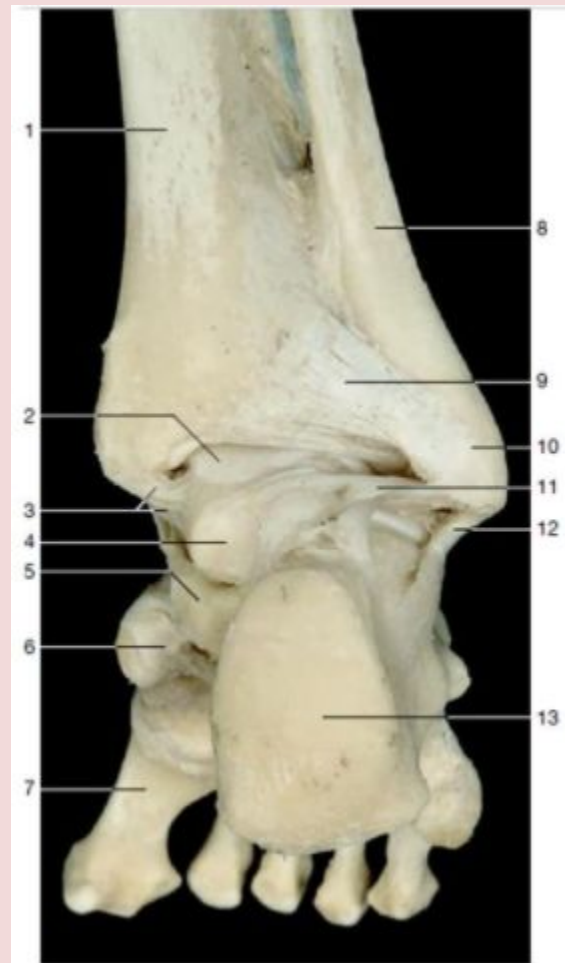processus transversus (foramen transversarium) 4

Lig. longitudinale posterius 6

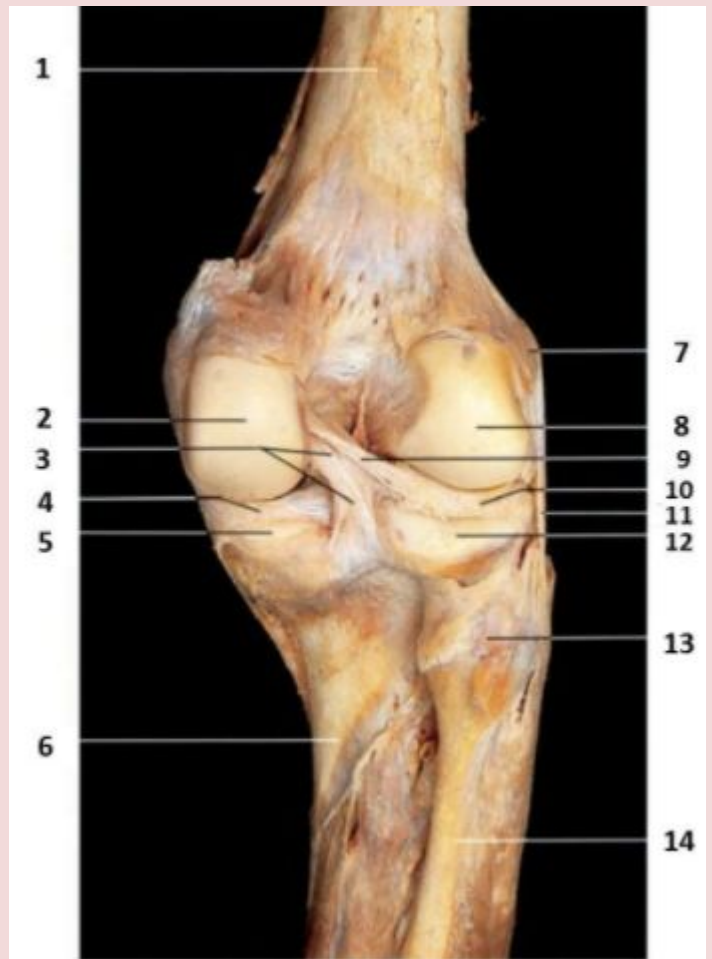


- Lig. capitis costae radiatum 4
- Lig. longitudinale anterius 3
- corpus vertebrae 1
- corpus costae 6
- discus intervertebralis 2
- Lig. capitis costae intraarticulare 5
- Lig. costotransversarium superius 7
- Ligg. Intertransversaria 8

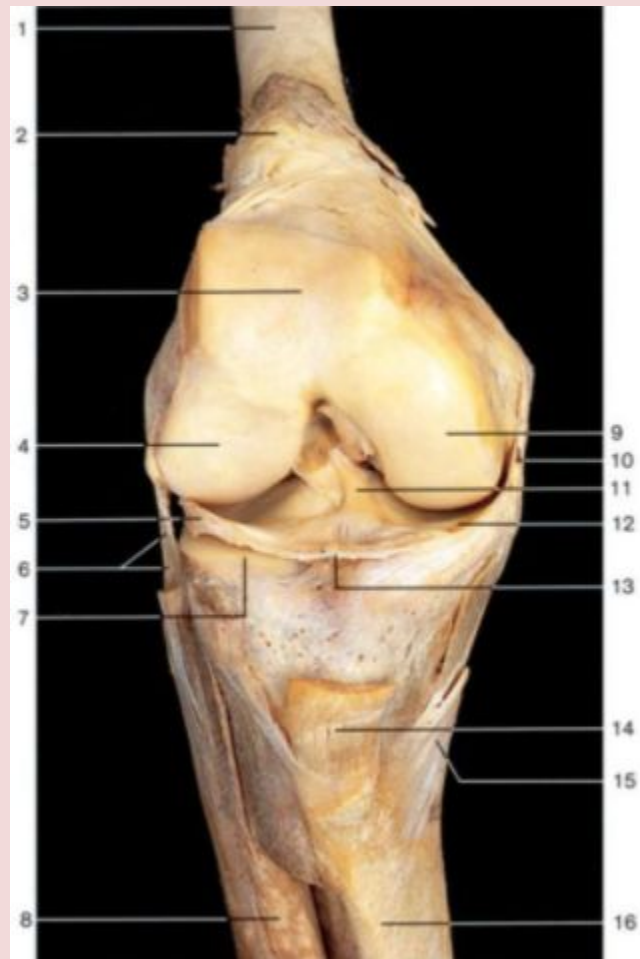
lig. Calcaneofibulare 12
Fibula 8
lig. talofibulare posterius 11
malleolus lateralis 10
Tibia 1
os naviculare 6
lig. collaterale mediale; lig. Deltoideum 3
trochlea tali 2
Talus 4
sustentaculum tali 5
os metatarsale I 7
lig. tibiofibulare posterior 9
tuber calcanei 13



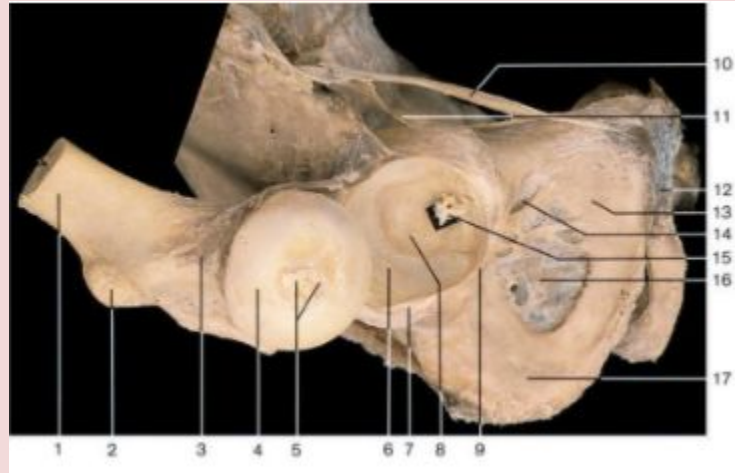
caput fibulae 13
 lig. collaterale fibulare 11
 condylus medialis femoris 2
 meniscus lateralis 10
 epicondylus lateralis femoris 7
 condylus lateralis femoris 8
 Tibia 6
 lig. meniscefemorale posterius 9
 Fibula 14
 condylus lateralis tibiae 12
 Femur 1
 lig. cruciatum posterius 3
 meniscus medialis 4
 condylus medialis tibiae 5

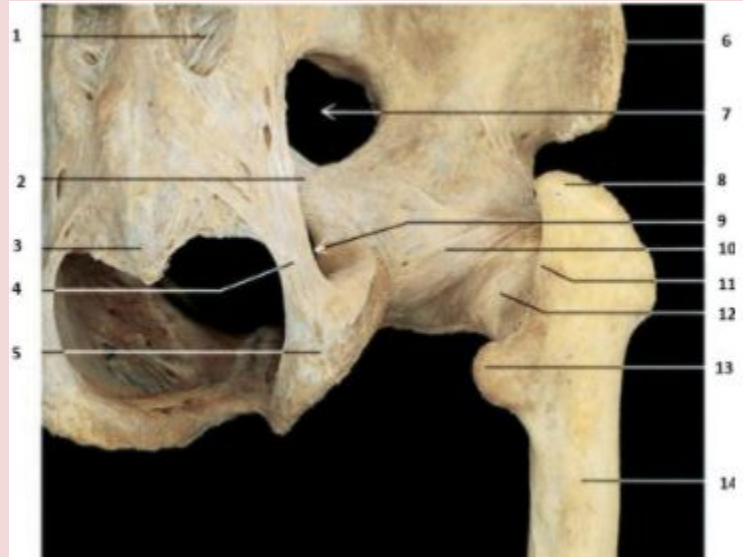


meniscus lateralis 5
 capsula articularis 2
 facies patellaris femoris 3
 condylus lateralis femoris 4
 Fibula 8
 lig. collaterale fibulare 6
 condylus medialis femoris 9
 lig. Patellae 14
 lig. cruciatum anterius 11
 Femur 1
 condylus lateralis tibiae 7
 lig. collaterale tibiale 10
 meniscus medialis 12
 lig. transversum genus 13
 tendo mm. sartorius, semitendinosus, gracilis 15
 Tibia 16



lig. capitis femoris 15
Ischium 17
arcus iliopectineus 11
symphysis pubica 12
canalis obturatorius 14
Pubis 13
lig. Inguinale 10
membrana obturatoria 16





lig. Ischiofemorale 10

trochanter minor 13

tuber ischii 5

foramen ischiadicum minus 9

crista intertrochanterica os femoris 11

lig. Sacrotuberale 4

foramen ischiadicum majus 7

lig sacroiliaca posteriora 1

zona orbicularis articulationis coxae 12

Femur 14

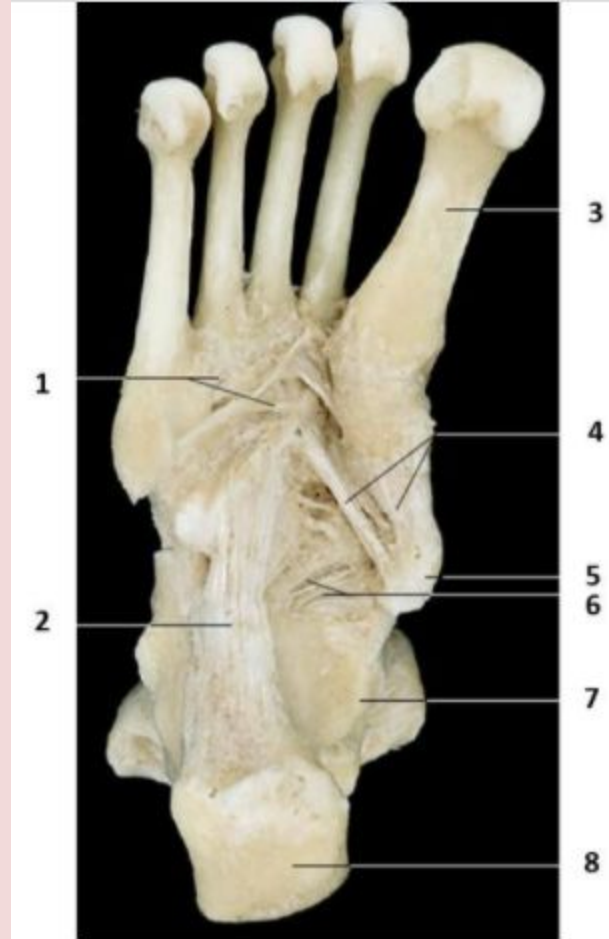lig. Sacrospinale 2

Coccyx 3

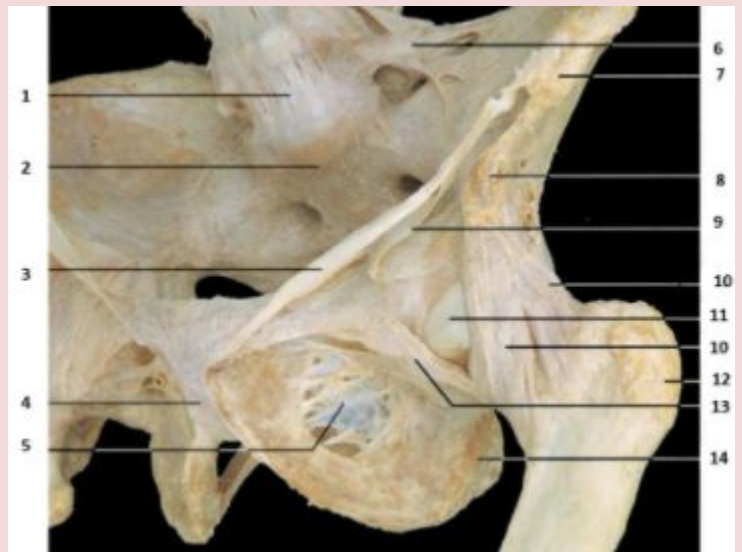
crista iliaca 6

trochanter major 8

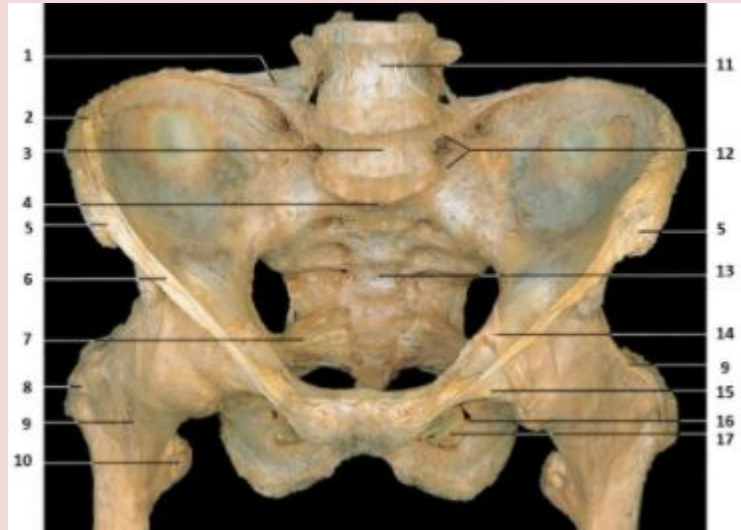os metatarsale I 3
ligg. tarsometatarsalia plantaria 1
sustentaculum tali 7
lig. calcaneonavicularia plantaria 6
lig. cuneonavicularia plantaria 4
tuber calcanei 8
lig. plantare longum 2
os naviculare 5



spina iliaca anterior superior 7
 arcus iliopectineus 9
 caput femoris 11
 promontorium ossis sacri 2
 membrana obturatoria 5
 lig. Inguinale 3
 spina iliaca anterior inferior 8
 symphysis pubica 4
 lig. longitudinale anterius 1
 lig. Iliolumbale 6
 lig. Iliofemorale 10
 trochanter major 12

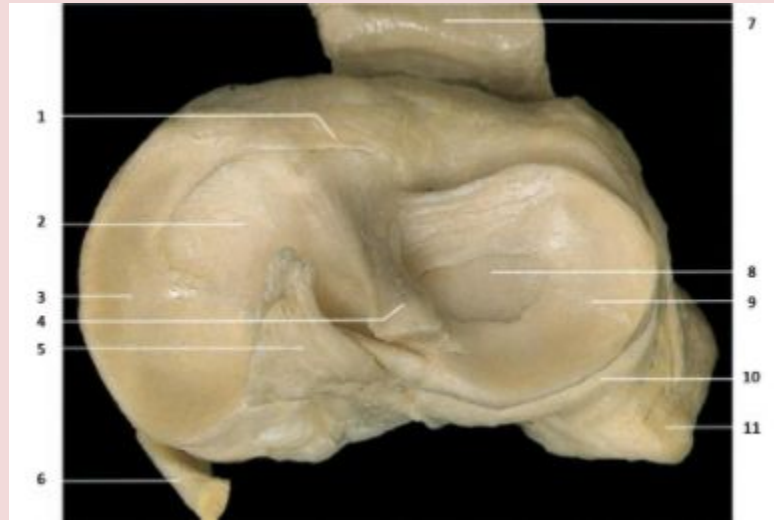


arcus iliopectineus 14
membrana obturatoria 17
lig. Pubofemorale 15
Sacrum 13
canalis obturatorius 16
L IV 11
lig.sacroiliaca anteriora 12
lig. Iliofemorale 9
trochanter minor 10

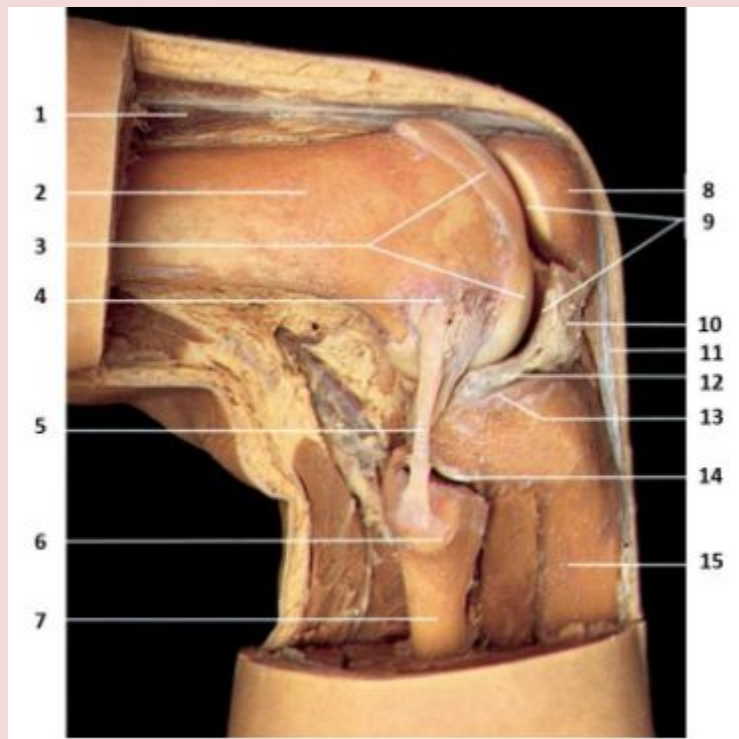


lig. Sacrospinale 7
trochanter major 8
promontorium ossis sacri 4
spina iliaca anterior superior 5
lig. iliungunale 6
lig. Iliolumbale 1
crista iliaca 2
L V 3

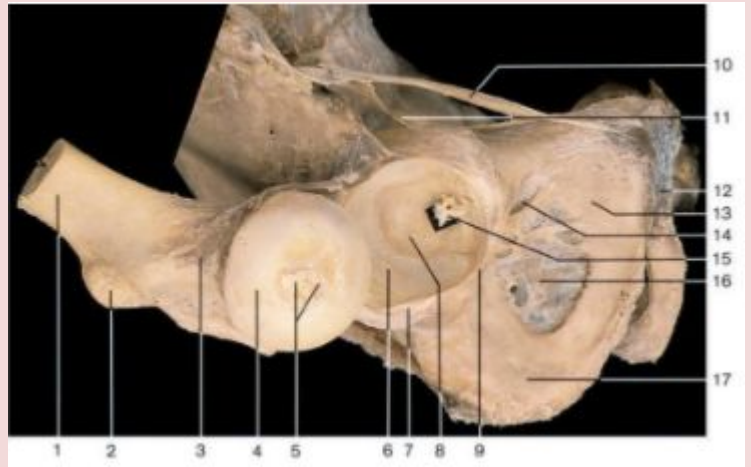
lig. cruciatum anterius 4
condylus lateralis tibiae 8
capsula articularis 10
tendo m. semimembranosus 6
lig. Patellae 7
lig. cruciatum posterius 5
lig. transversum genus 1
condylus medialis tibiae 2
meniscus medialis 3
meniscus lateralis 9
caput fibulae 11



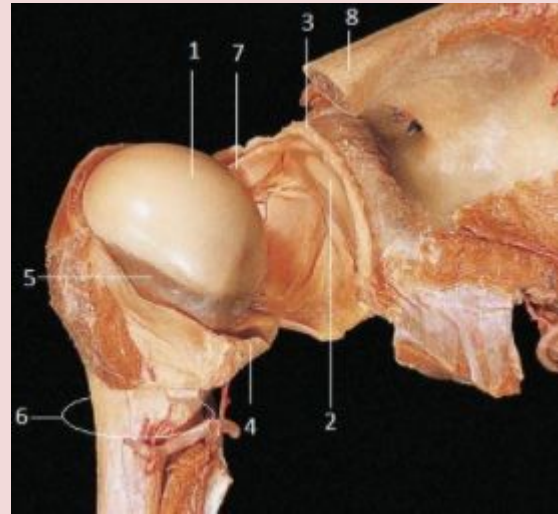
caput fibulae 6
Fibula 7
Patella 8
Femur 2
Tibia 15
epicondylus lateralis femoris 4
corpus adiposum infrapatellare 10
lig. collaterale fibulare 5
articulatio tibiofibularis 14
m.quadriceps femoris 1
condylus lateralis femoris 3
cavitas articularis 9
lig. Patellae 11
meniscus lateralis 12
condylus lateralis tibiae 13

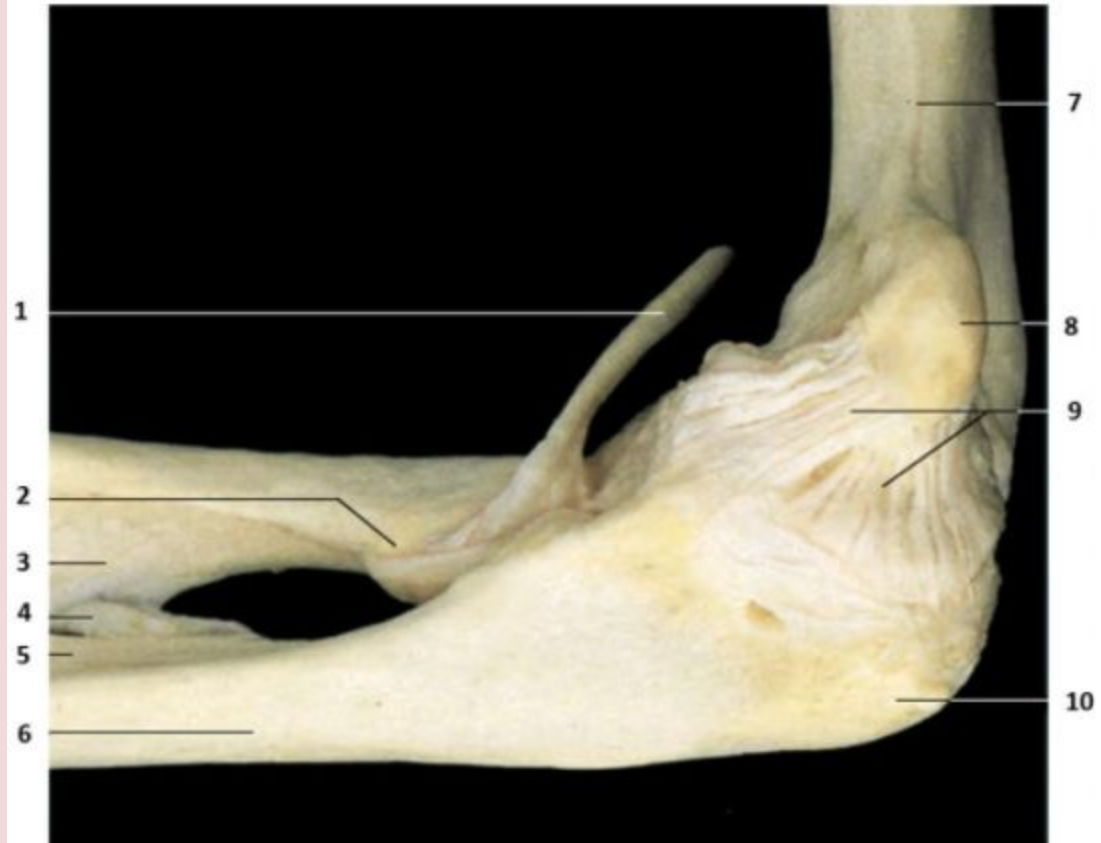

- labrum acetabuli 7
- facies lunata ossis coxae 6
- Femur 1
- fovea capitis ossis femoris 5
- collum femoris 3
- caput femoris 4
- trochanter minor 2
- fossa acetabuli os coxae 8
- lig. transversum acetabuli 9



collum chirurgicum 6
collum anatomicum 5
cavitas glenoidalis 2
caput humeri 1
labrum glenoidale 3
capsula articularis 4
vagina synovialis musculus biceps brachii 7
spina scapulae 8





Radius 3

Ulna 6

tuberositas radii 2

lig. collaterale ulnare 9

membrana interossea antebrachii 5

epicondylus medialis humeri 8

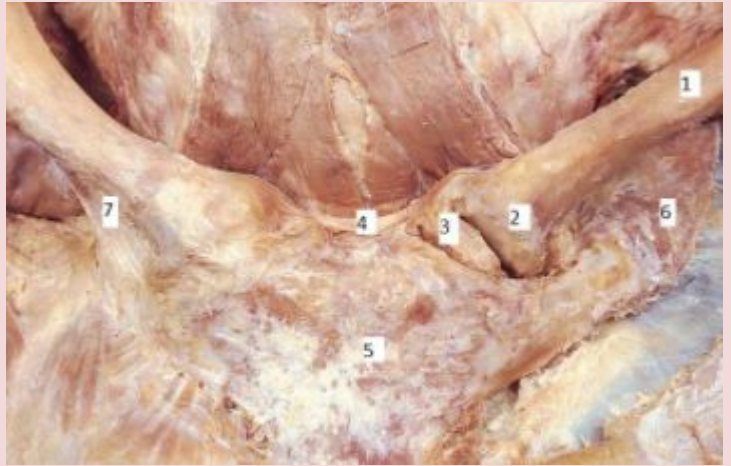
Olecranon 10

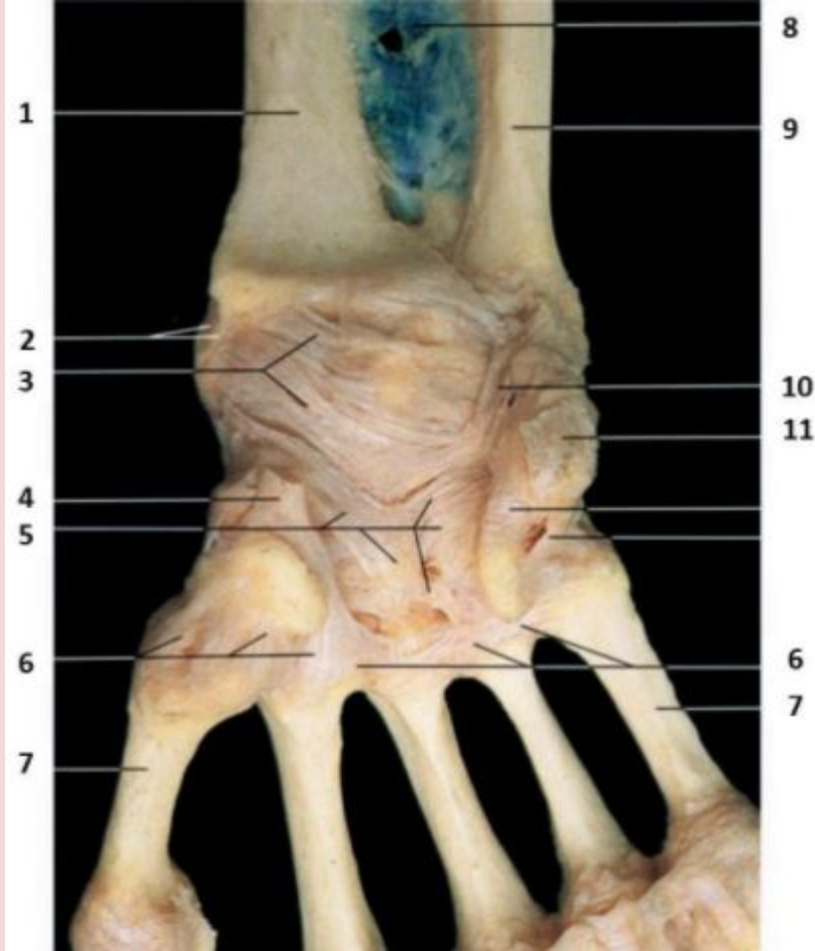
Humerus 7

tendo m.biceps brachii 1

chorda obliqua 4

corpus claviculae 1
discus articularis 3
manubrium sterni 5
ligamenti costoclavicularis 7
extremities sternalis claviculae 2
ligamentum interclaviculare 4
costae prima 6





tendo m.flexor carpi ulnaris 11

lig. carpi radiatum 5

Radius 1

ligg. carpometacarpalia palmaria 6

processus styloideus radii 2

os metacarpale I 7

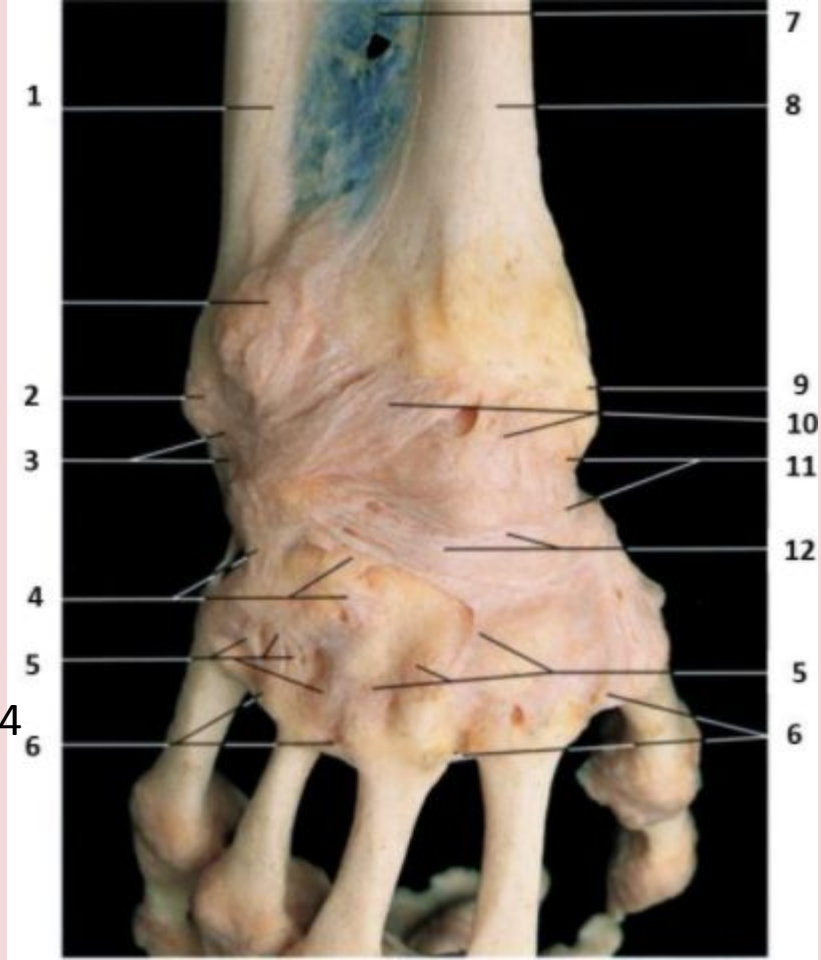
lig. ulnocarpale palmare 10

Ulna 9

lig. radiocarpale palmare 3

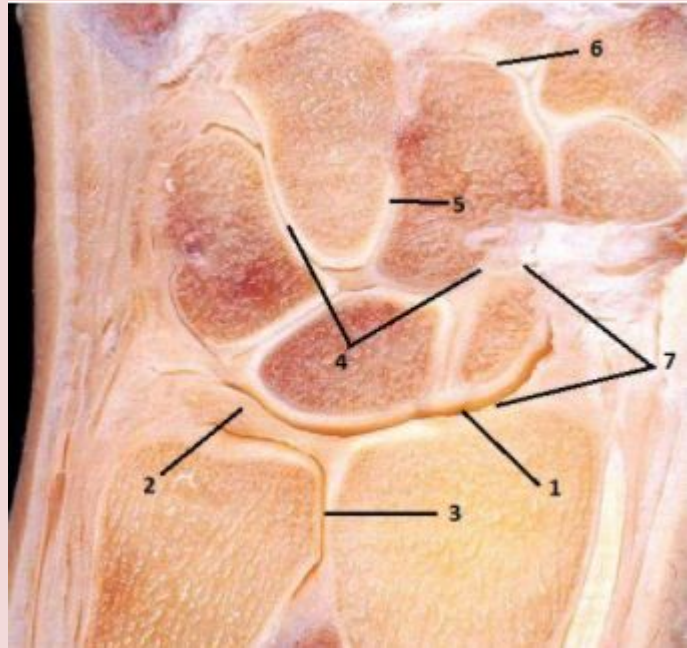
tendo m.flexor carpi radialis 4

membrana interossea antebrachii 8

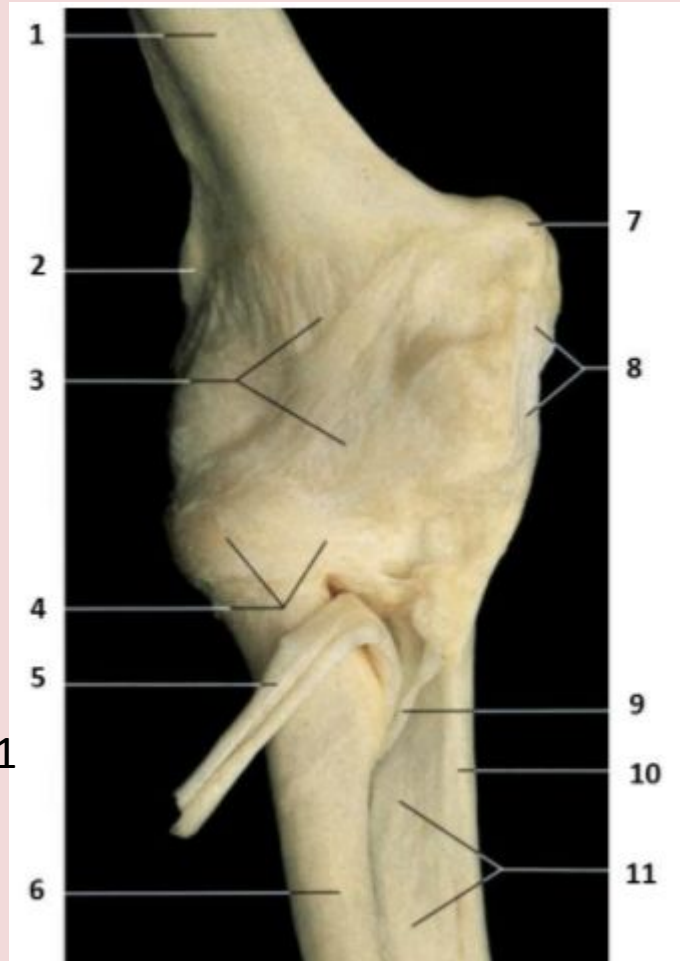


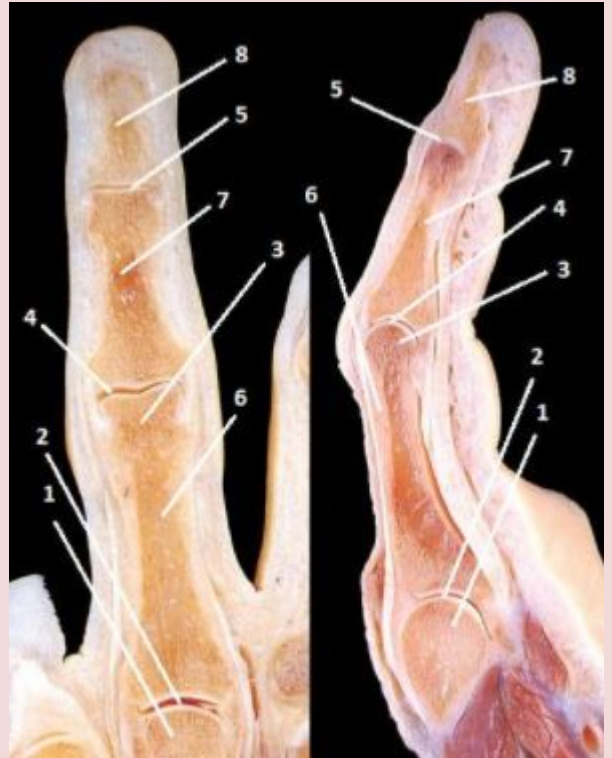
- ligg. intercarpalia interossea 4
- capsula articularis 12
- Radius 8
- Ulna 1
- caput ulnae 2
- ligg. metacarpalia dorsalia 6
- ligg. carpometacarpalia dorsalia 5
- lig. collaterale carpi radia 11
- lig. radiocarpale dorsale 10
- membrana interossea antebrachii 7
- lig. collaterale carpi ulnare 3
- processus styloideus radii 9

- articulatio mediocarpea 4
- articulatio intercarpea 5
- discus articularis 2.
- articulatio manus 7
- articulatio radiocarpea 1.
- articulatio radioulnaris distalis 3.
- articulatio carpometacarpea 6.



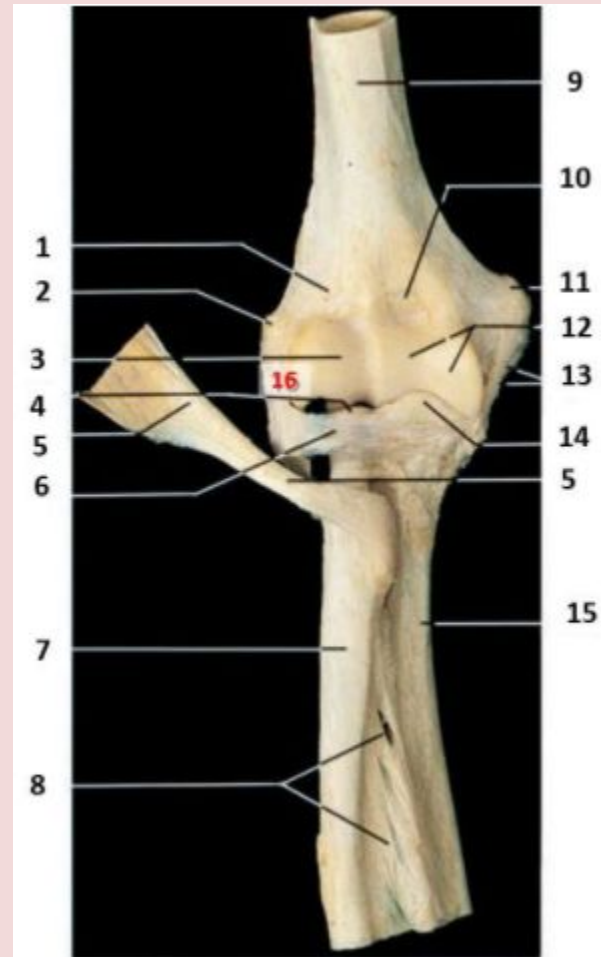
Lig. anulare radii 4
Chorda obliqua 9
Humerus 1
tendo m.biceps brachii 5
epicondylus lateralis humeri 2
Ulna 10
capsula articularis 3
Radius 6
epicondylus medialis humeri 7
Lig. collaterale ulnare 8
Membrana interossea antebrachii 11

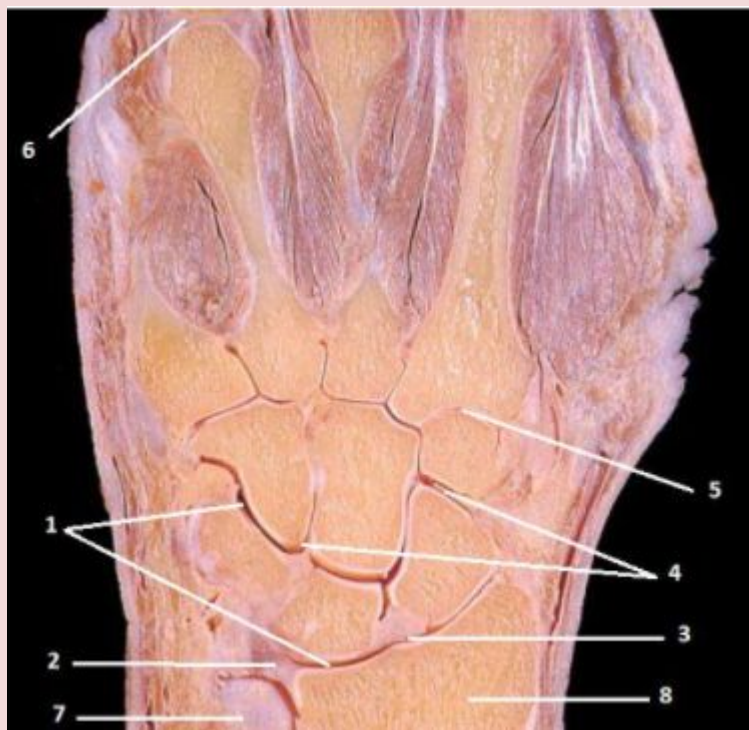




- caput phalangis 3.
- caput ossis metacarpi 1.
- phalanx distalis 8.
- phalanx media 7.
- phalanx proximalis 6.
- articulatio interphalangeal proximalis 4.
- articulatio interphalangeal distalis 5.
- articulatio metacarpophalangeal 2.

Humerus 9
 Radius 7
 processus coronoideus humeri 14
 caput radii 4
 Ulna 15
 lig. collaterale radiale 13
 tendo m.biceps brachii 5
 membrana interossea antebrachii 8
 lig. anulare radii 6
 epicondylus medialis humeri 11
 trochlea humeri 12
 fossa radialis humeri 1
 epicondylus lateralis humeri 2
 capitulum humeri 3
 fossa coronoidea humeri 10
 lig. collaterale ulnare 13
 lig. collaterale radii 16





articulatio mediocarpea 4

Ulna 7

discus articularis 2

articulatio metacarpophalangeal 6

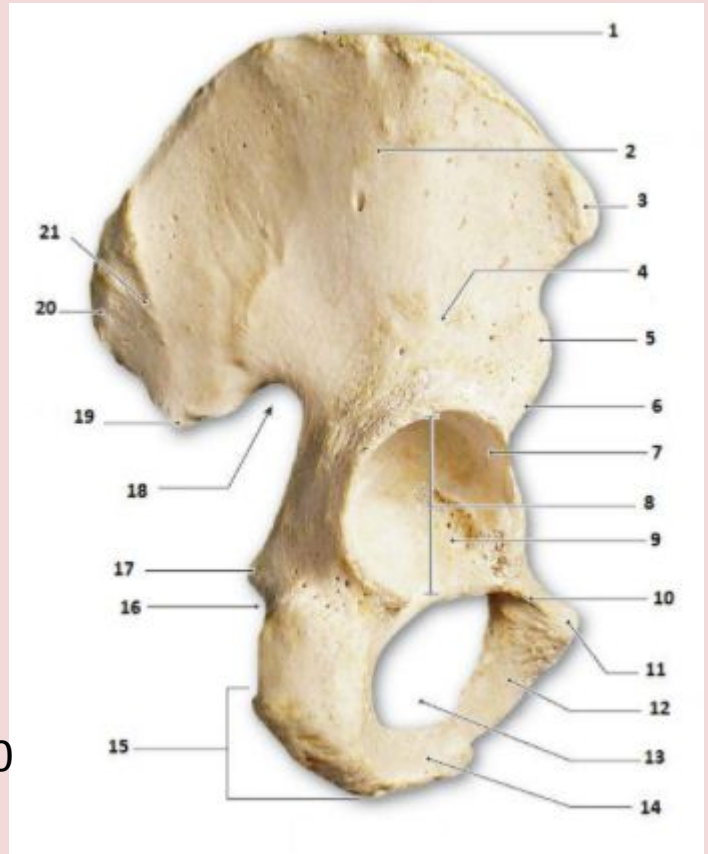
articulatio carpometacarpea 5

articulatio manus 1

articulatio radiocarpea 3

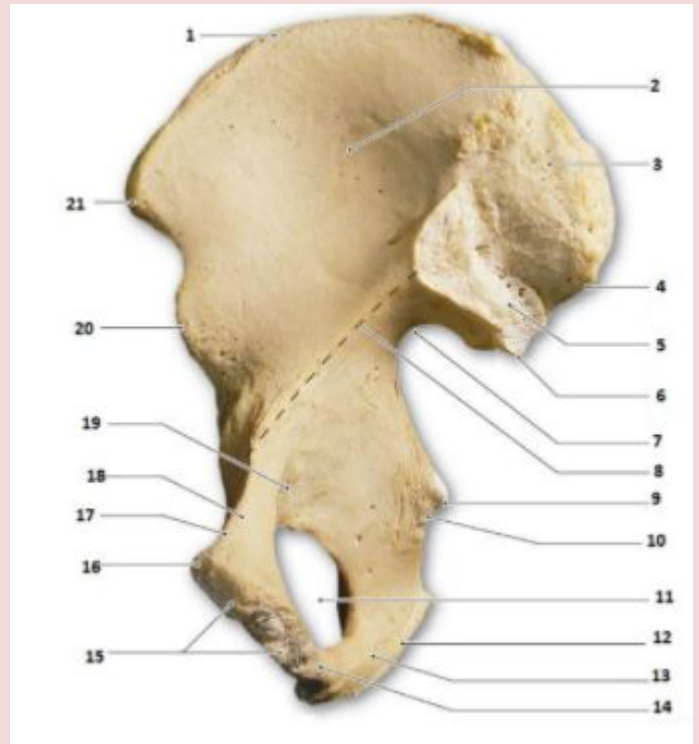
Radius 8

incisura ischiadica minor 16
 tuber ischiadicum 15
 foramen obturatum 13
 spina iliaca posterior inferior 19
 tuberculum pubicum 11
 incisura ischiadica major 18
 spina ischiadica 17
 ramus inferior ossis pubis 12
 ramus ossis ischii 14
 spina iliaca posterior superior 20
 Linea glutea Posterior 21
 crista iliaca 1



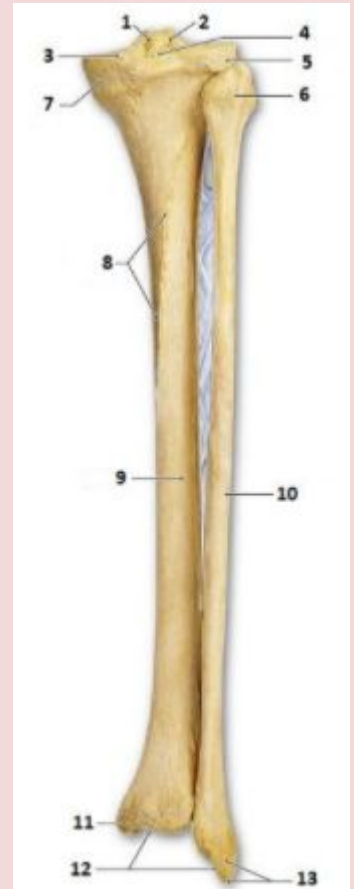
crista iliaca 1.
 spina iliaca anterior superior 3.
 linea glutea inferior 4.
 ramus superior ossis pubis 10.
 incisura iliaca inferior 6.
 fossa acetabuli 9.
 linea glutea anterior 2.
 spina iliaca anterior inferior 5.
 facies lunata acetabuli 7.
 Acetabulum 8.

spina iliaca posterior superior 4
facies auricularis 5
linea arcuata 8
spina iliaca posterior inferior 6
tuberositas ilica 3
incisura ischiadica minor 10
incisura ischiadica major 7
crista iliaca 1
fossa iliaca 2
spina ischiadica 9



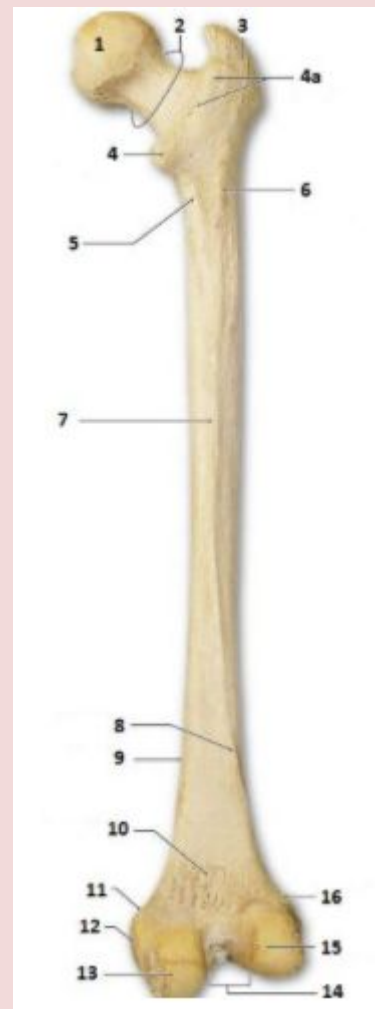ramus ossis ischii 13.
tuberculum pubicum 16
foramen obturatum 11.
spina iliaca anterior inferior 20
facies symphysealis 15
ramus superior ossis pubis 18
tuber ischiadicum 12.
ramus inferior ossis pubis 14
linea pectinea 17
sulcus obturatorius 19
spina iliaca anterior superior 21

facies articularis inferior tibia et fibula 12
malleolus medialis 11
tuberculum intercondylare mediale 1
malleolus lateralis 13
caput fibulae 6
tuberculum intercondylare laterale 2
Tibia 9
facies articularis condylus medialis 3
area intercondylaris anterior 4
condylus lateralis 5
condylus medialis 7
margo anterior 8
Fibula 10

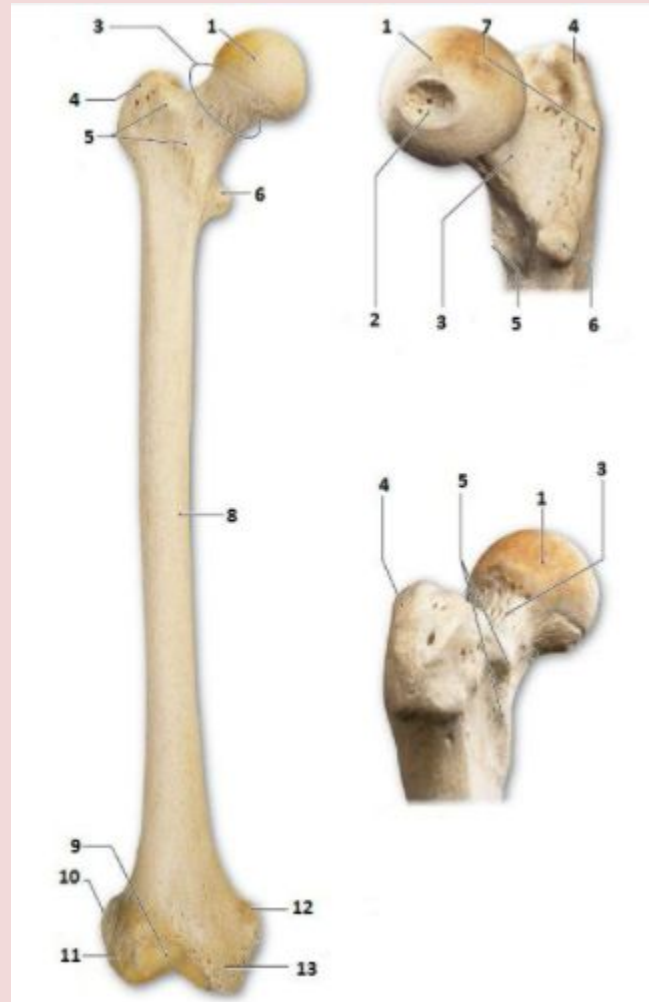


tuberculum adductorium 11.
epicondylus medialis 12.
facies poplitea 10.
crista supracondylaris medialis 9
epicondylus lateralis 16
condylus lateralis 15
crista supracondylaris lateralis 8
condylus medialis 13.
fossa intercondylaris 14.

tuberositas glutea 6
linea intertrochanterica 4a
caput femoris 1
linea pectinea 5
collum femoris 2
trochanter minor 4
trochanter major 3
linea aspera 7

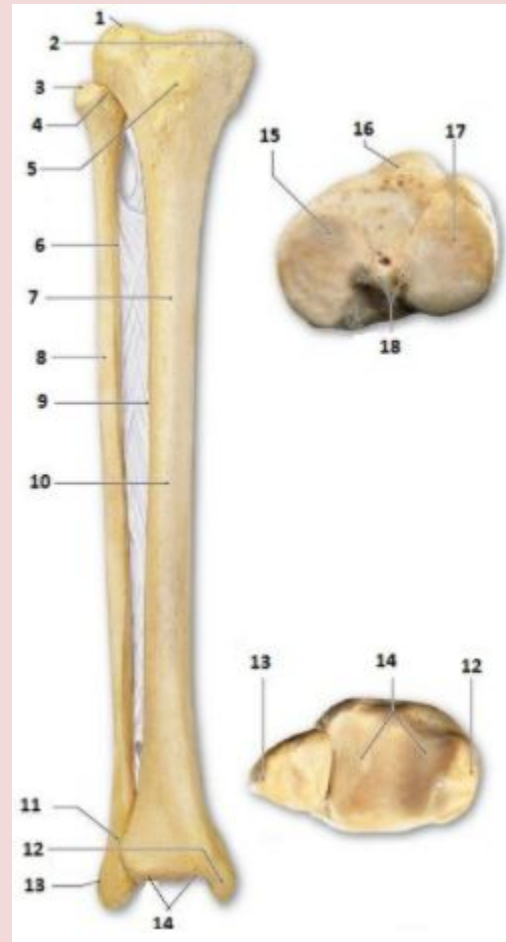


trochanter major 4
 fovea capitis femoris 2
 linea intertrochanterica 5
 condylus medialis 13
 epicondylus lateralis 10
 collum femoris 3
 epicondylus medialis 12
 condylus lateralis 11
 corpus femoris 8
 caput femoris 1
 trochanter minor 6
 crista intertrochanterica 7
 facies patellaris 9

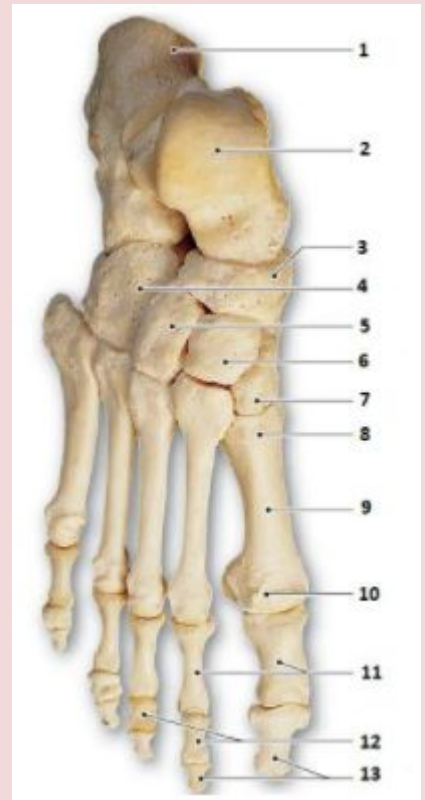


facies articularis fibularis 4
 margo anterior 7
 condylus medialis 2
 condylus lateralis 1
 margo interosseus lateralis 6
 tuberositas tibiae 5
 caput fibulae 3
 margo interosseus medialis 9
 corpus fibulae 8

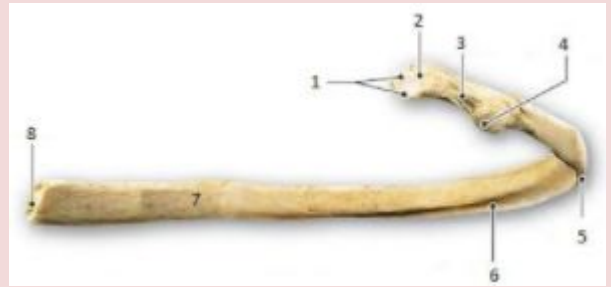incisura fibularis 11
 tuberositas intercondylaris 18
 malleolus lateralis 13
 malleolus medialis 12
 facies articularis condylus medialis 15
 corpus tibiae 10
 facies articularis inferior 14
 tuberositas tibiae 16
 facies articularis condylus lateralis 17



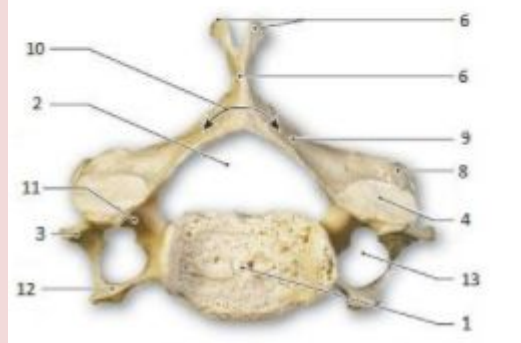
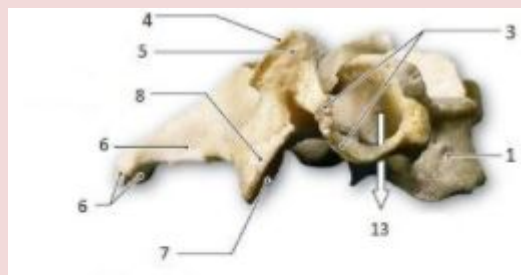
phalanx proximalis 11
phalanx intermedius 12
phalanx distalis 13
Calcaneus 1
os naviculare 3
corpus ossis metatarsi 9
os cuneiforme intermedium 6
basis ossis metatarsi 8
Talus 2
os cuneiforme laterale 5
os cuboideum 4
os cuneiforme mediale 7
caput ossis metatarsi 10



collum costae 3
facies articularis capitis costae 1
corpus costae 7
sulcus costae 6
tuberculum costae 4
caput costae 2
angulus costae 5
extremitas anterior costae 8

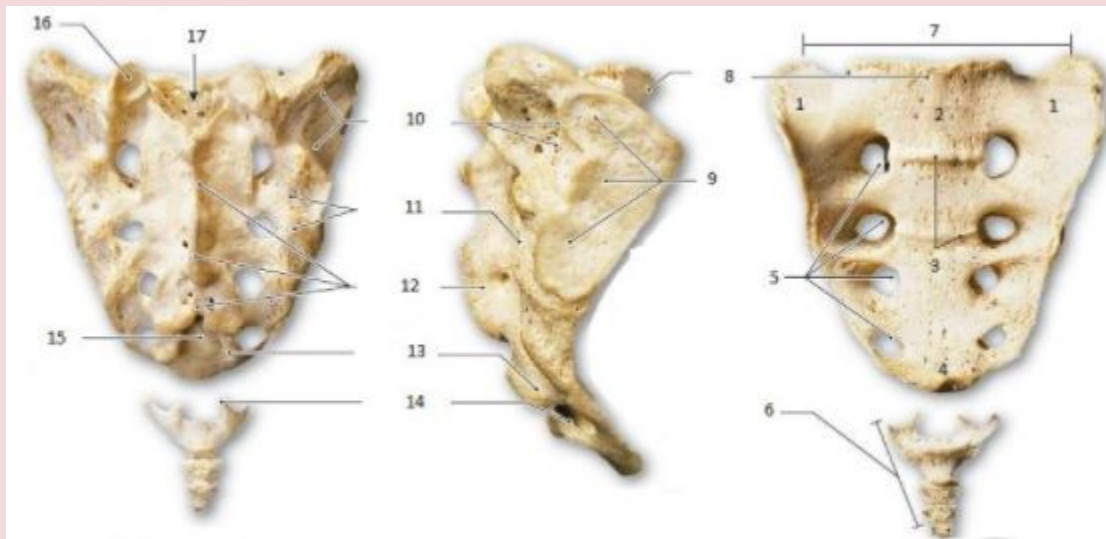

processus articularis inferior 8
 arcus vertebrae 10
 processus articularis superior 5
 facies articularis superior 4.
 processus transversus 3.
 facies articularis inferior 7.
 foramen processus transversi 13
 lamina arcus vertebrae 9
 corpus vertebrale 1.
 foramen vertebrale 2.
 processus spinosus 6
 pedunculi arcus vertebrae 11
 tuberculum anterius processus transversi 12



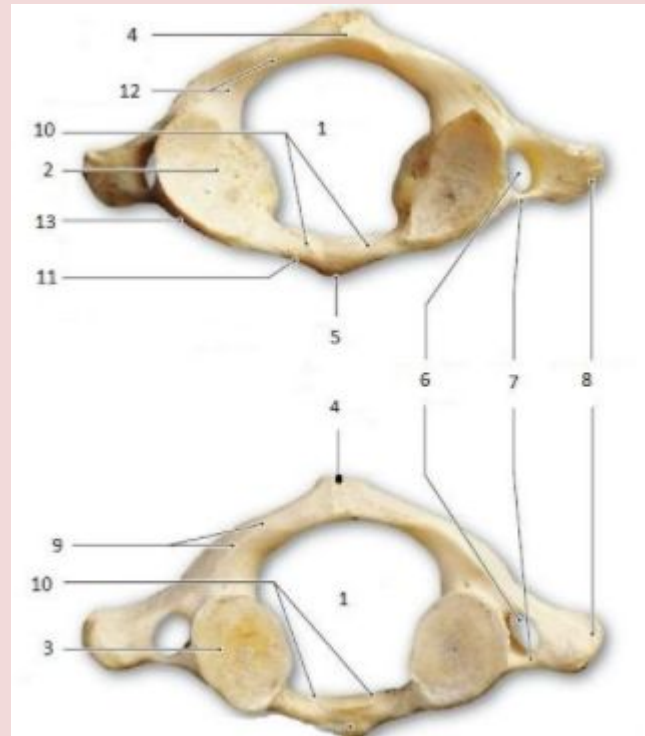
ПОЗВОНО

К



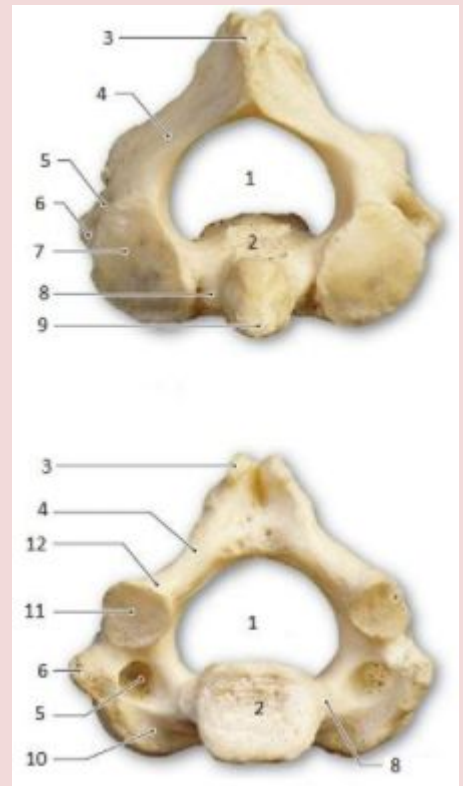
- basis ossis sacri 7
- linea transversa os sacrum 3
- tuberositas ossis sacri 10
- foramina pelvina 5
- canalis sacralis 17
- facies pelvina 2
- cornu coccygeum 14
- crista sacralis lateralis 11
- promontorium os sacrum 8
- hiatus sacralis 15
- processus articularis superior os sacrum 16
- os coccygis 6
- ala sacralis 1
- apex ossis sacri 4
- facies auricularis ossis sacri 9
- crista sacralis mediana 12
- cornu sacrale 13

ПОЗВОНОК
К



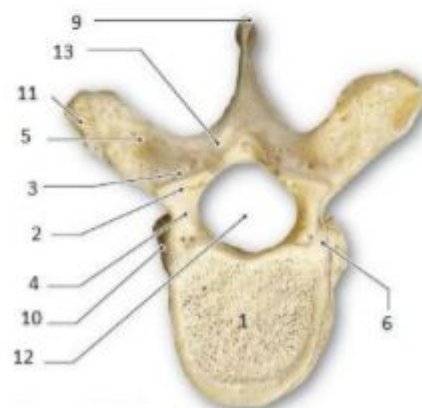

- foramen processus transversi 6
- facies articularis dentis 10
- sulcus arteria vertebralis 12
- facies articularis superior 2
- facies articularis inferior 3
- tuberculum anterius processus transversi 7
- massa lateralis 13
- foramen vertebrale 1
- arcus posterior atlantis 9
- arcus anterior atlantis 11
- tuberculum posterior atlantis 4
- tuberculum arcus anterior atlantis 5
- processus transversus 8

processus articularis inferior 12
processus spinosus 3
facies articularis superior 7
facies articularis inferior 11
foramen vertebrale 1
Dens 9
processus transversus 6
foramen processus transversi 5
corpus vertebrale 2
pedunculi arcus vertebrae 8
arcus vertebrae 4
processus articularis superior 10



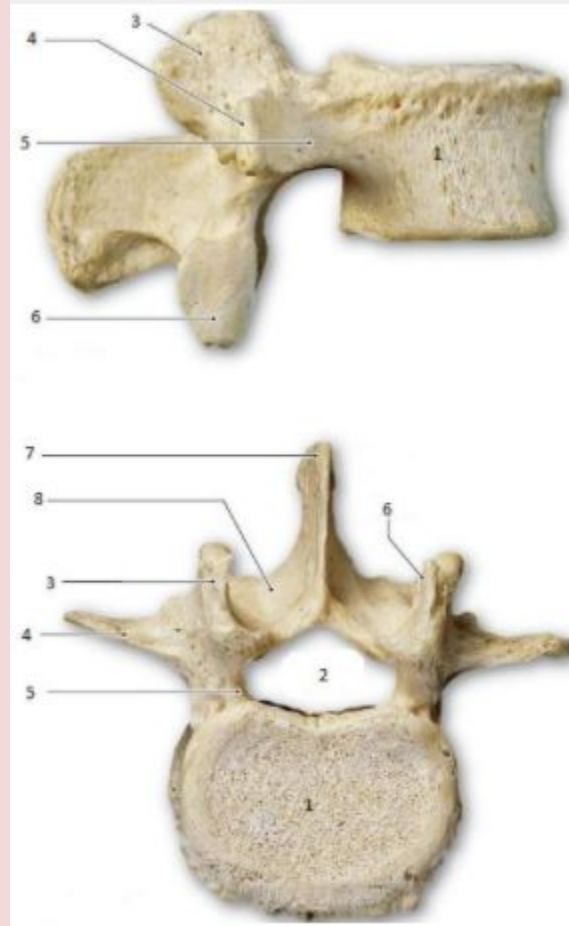
ПОЗВОНО
К

fovea costalis superior 6.
 processus articularis inferior 8
 processus transversus 5.
 corpus vertebrale 1.
 facies articularis inferior 8
 foramen vertebrale 12.
 incisura vertebralis inferior 7.
 processus spinosus 9.
 pedunculi arcus vertebrae 4.
 fovea costalis processus transversus 11.
 processus articularis superior 3
 fovea costalis inferior 10.
 lamina arcus vertebrae 13

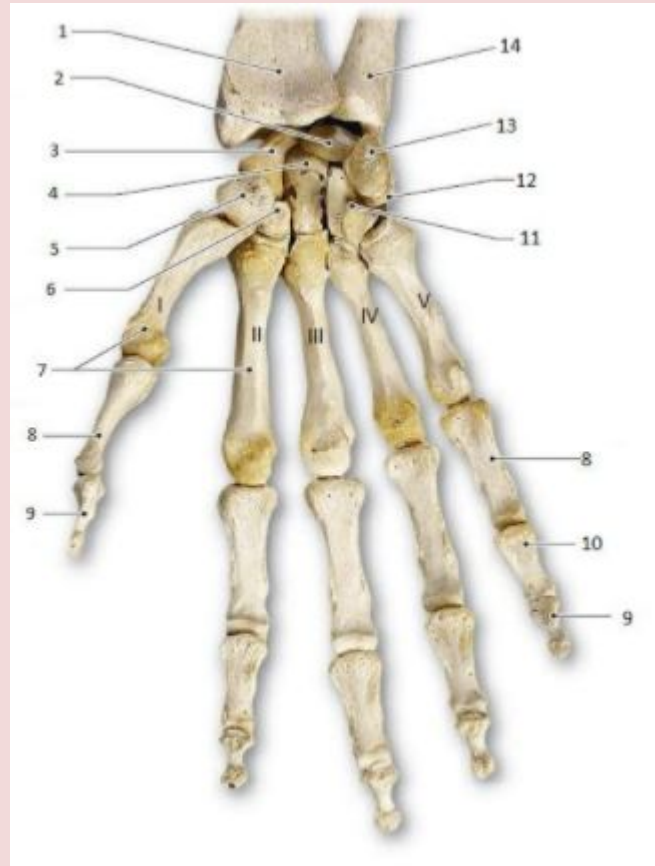


ПОЗВОНО
 К

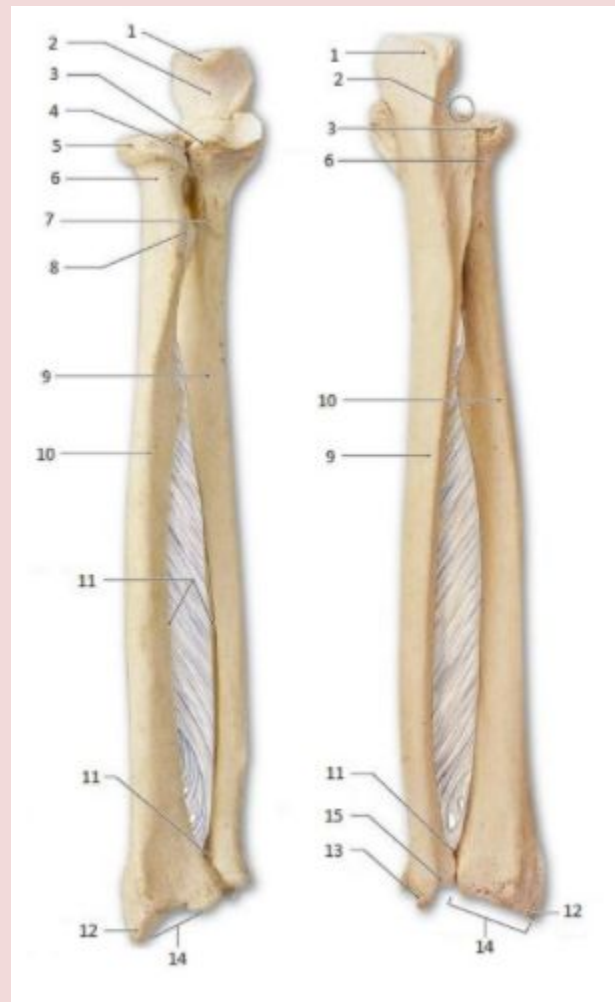processus articularis inferior 6
lamina arcus vertebrae 8
processus transversus 4
processus spinosus 7
processus articularis superior 3
corpus vertebrale 1
foramen vertebrale 2
pedunculi arcus vertebrae 5



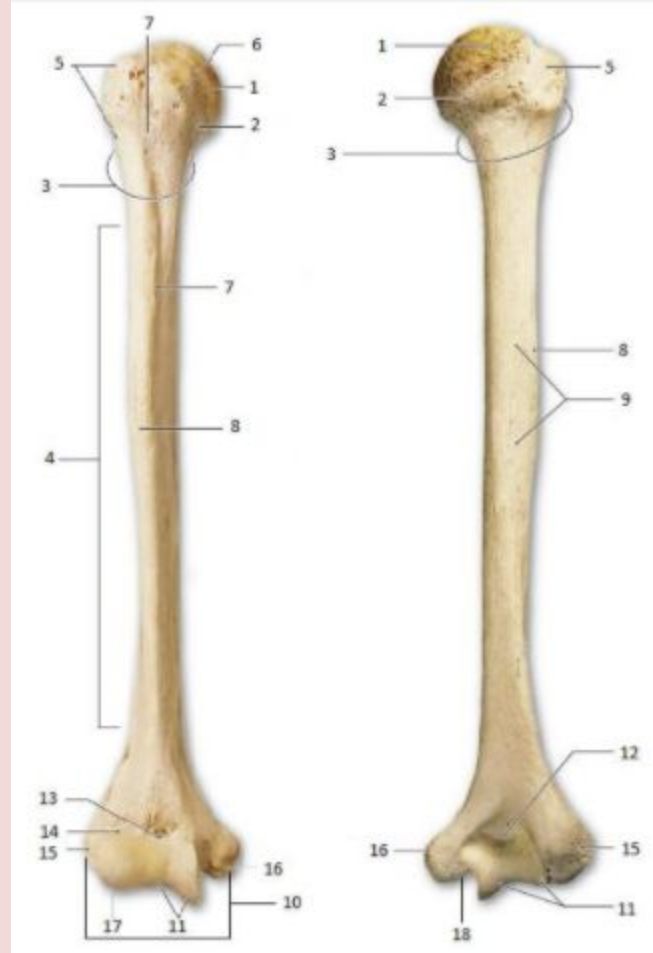
phalanx intermedius 10.
phalanx distalis 9.
os trapezoideum 6.
os trapezium 5.
ossa metacarpi 7.
os triquetrum 12
Radius 1.
os pisiforme 13
phalanx proximalis 8.
os capitatum 4.
os lunatum 2.
os scaphoideum 3.
os hamatum 11.
Ulna 14



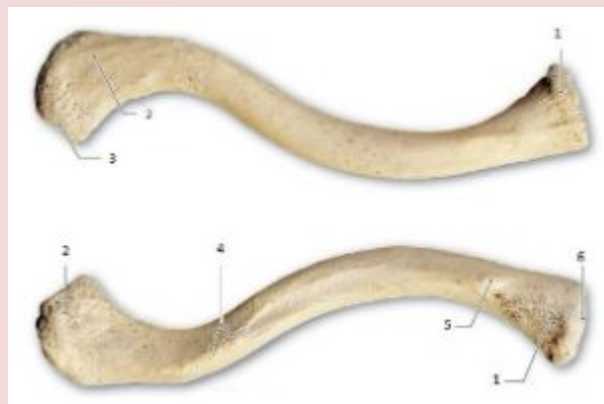tuberositas radii 8
 collum radii 6
 tuberositas ulnae 7
 circumferentia radialis 5
 margo interosseus 11
 Ulna 9
 processus styloideus ulnae 13
 processus coronoideus 3
 extremitas distalis radii 14
 Olecranon 1
 incisura trochlearis 2
 incisura radialis 4
 Radius 10
 processus styloideus radii 12

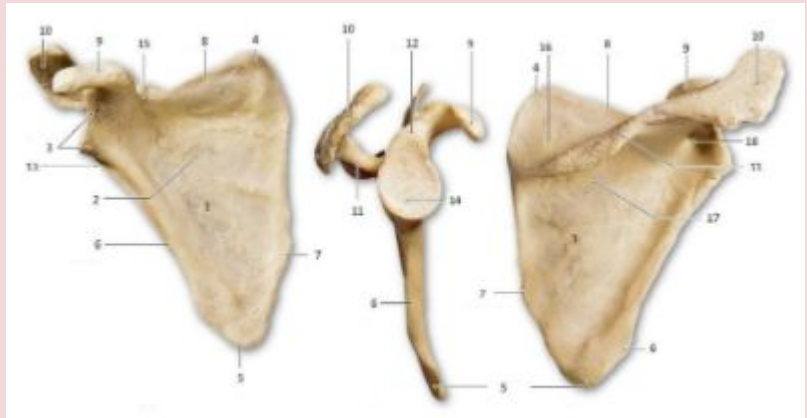


epicondylitis lateralis 15
 trochlea humeri 11
 fossa olecrani 12
 corpus humeri 4
 fossa radialis 14
 capitulum humeri 17
 condylus humeri 10
 sulcus intertubercularis 7
 collum anatomicum 2
 tuberculum majus 5
 sulcus nervi radialis 9
 caput humeri 1
 collum chirurgicum 3
 tuberculum minus 6
 tuberositas deltoidea 8
 fossa coronoidea 13
 epicondylitis medialis 16
 sulcus nervi ulnaris 18



facies articularis sternalis 6
extremitas sternalis 1
facies articularis acromialis 3
extremitas acromialis 2
tuberculum conoideum 4
tuberositas costolaviculares 5



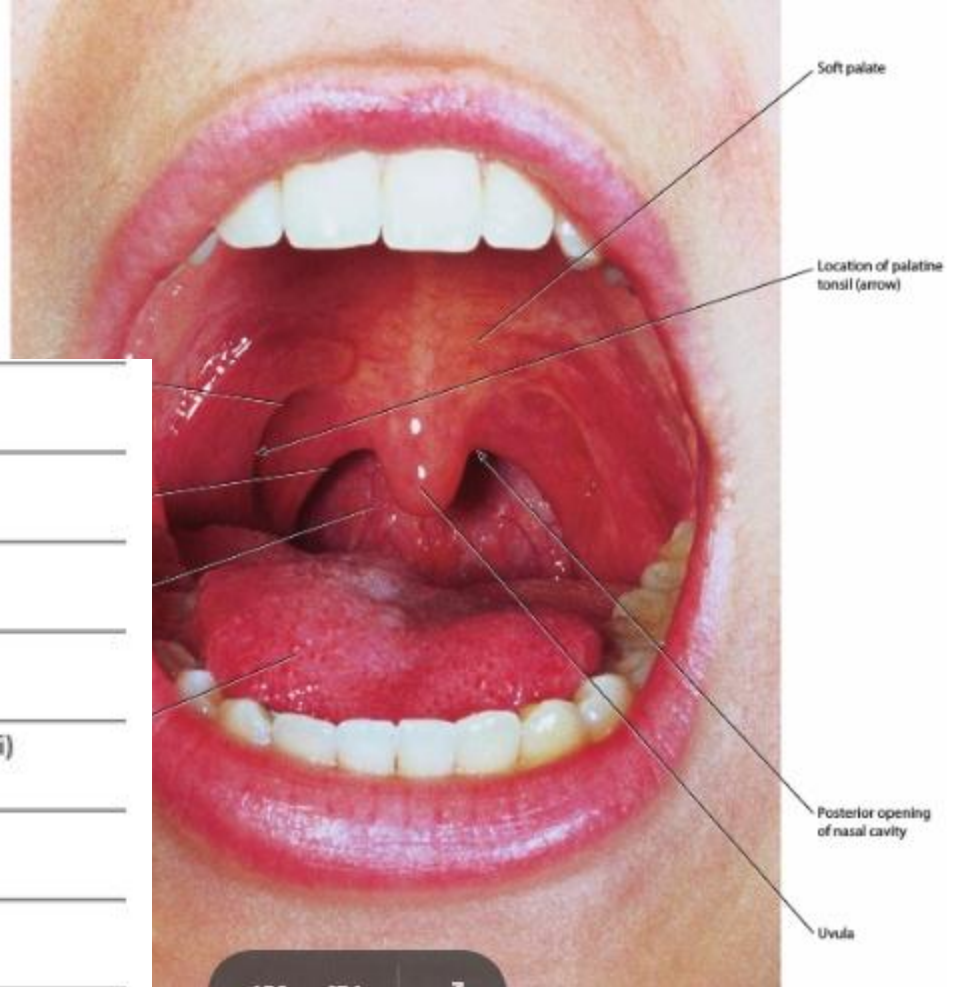


- Acromion 10
- tuberculum infraglenoidale 13
- processus coracoideus 9
- angulus inferior scapulae 5
- margo lateralis scapulae 6
- collum scapulae 18
- incisura scapulae 15
- angulus superior scapulae 4
- margo superior scapulae 8
- fossa supraspinata 16
- margo medialis scapulae 7
- corpus scapulae 1
- fossa subscapularis 2
- angulus lateralis scapulae 3
- spina scapulae 11
- tuberculum supraglenoidale 12
- cavitas glenoidalis 14
- fossa infraspinata 17

po
T

Palatoglossal
arch

1	labium inferior
2	labium superior
3	angulus oris
4	lingua
5	palatum molle (raphe palati)
6	uvula
7	arcus palatoglossus
8	arcus palatopharyngeus
9	tonsilla palatina (palatum molle)

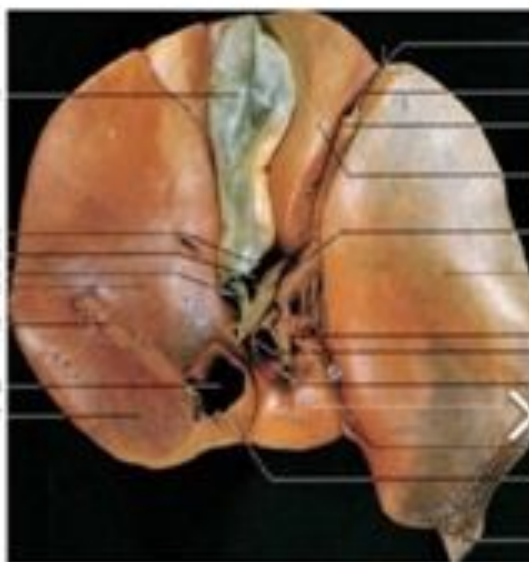


печень

ь

БРЮШИНА ПЕЧЕНЬ

1	Fundus vesicae fellea
2	Peritoneum
3	a. cysticus
4	ductus cysticus
5	lobus hepatis dexter
6	Vena cava inferior
7	Голая зона печени
8	Incisura ligamenti teretis
9	Ligamentus teres
10	Lig. falciforme hepatis
11	Lobus quadratus hepatis
12	Ductus hepaticus communis
13	Lobus hepatis dexter
14	A. Hepatica propria
15	Ductus choledochus

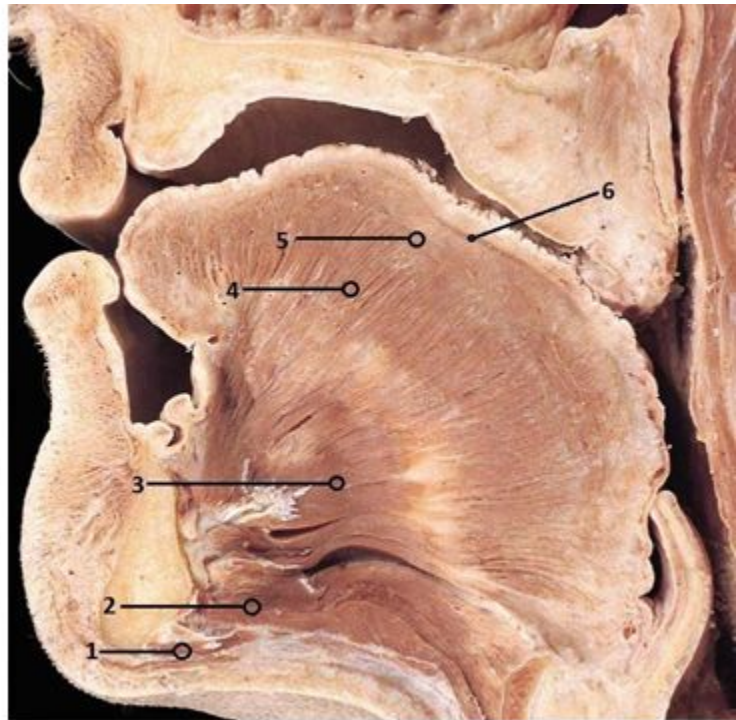


16	Vena portae
17	Lobus caudatus
18	Lig.venosum
19	Lig. venae cavae inferioris
20	Lig. triangulare sinistrum

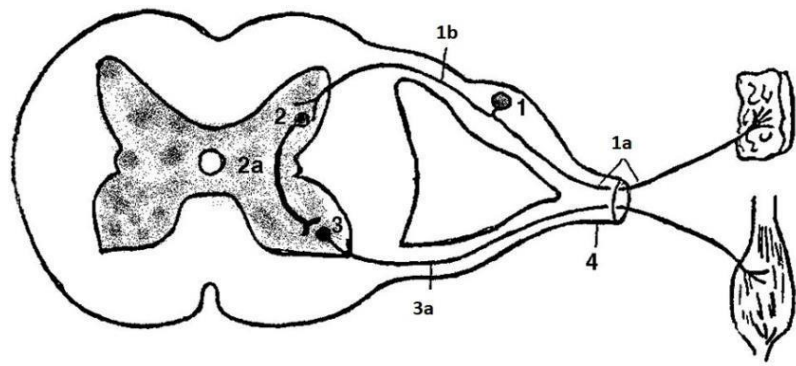
ЯЗЫК

ЯЗЫК

1	m. mylohyoideus
2	m. geniohyoideus
3	m. genioglossus
4	m. transversus lingua
5	m. longitudinalis superior
6	Aponeurosis lingua



Простая дуга



1 псевдоуниполярные клетки воспринимающ. 1-й нейрон.

1а периферические отростки дендриты псевдоунип.кл

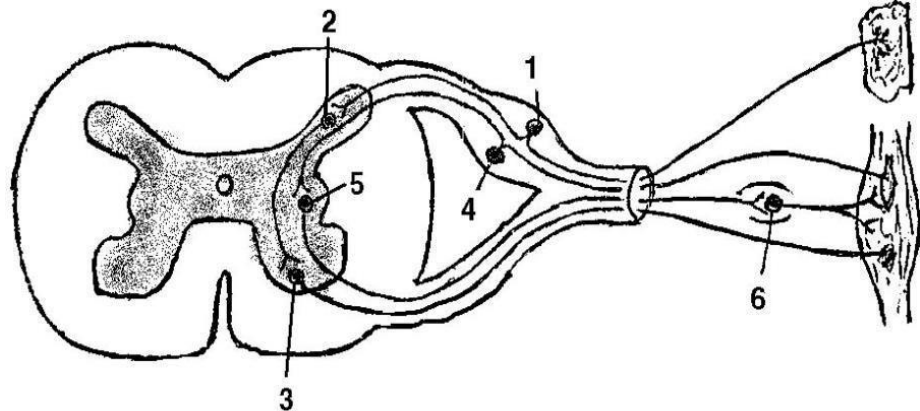
1б центральные отростки аксоны

2 вставочный второй нейрон

3 двигательный третий нейрон

3а Аксон двиг нейрона

Сложная дуга

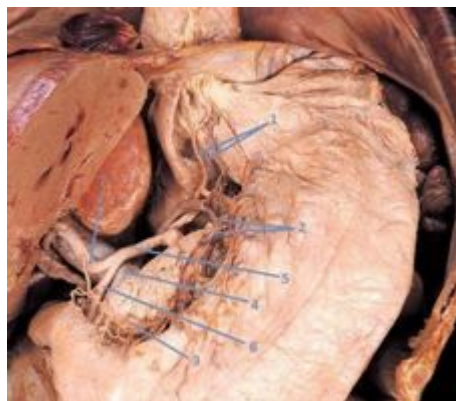

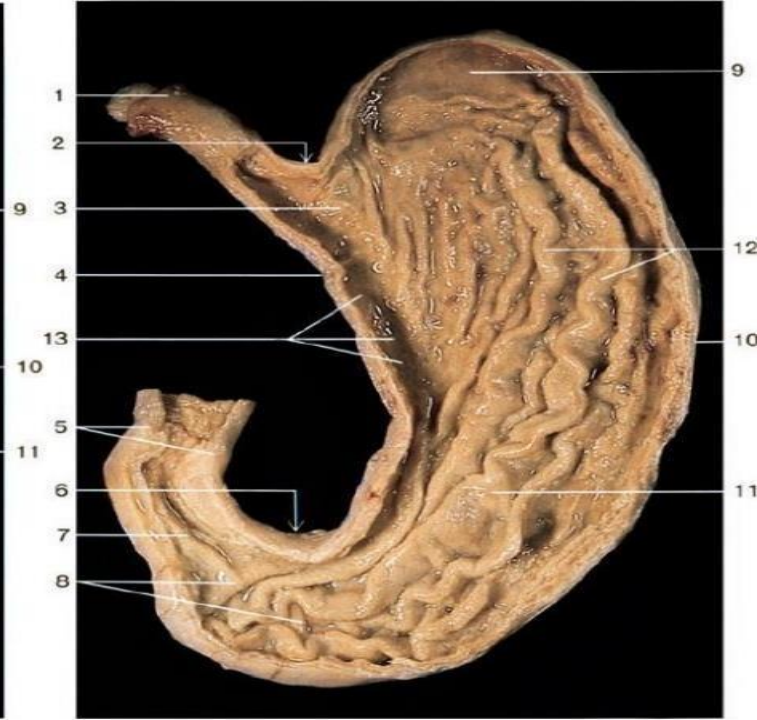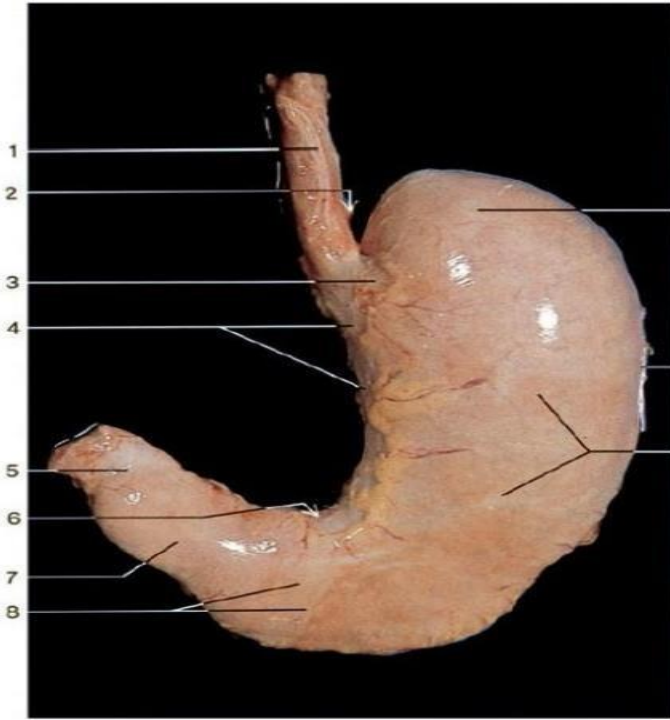
1	Рецепторный нейрон межпозвоночного узла, получающий импульсы от рецепторов кожи
2	Вставочный нейрон заднего рога
3	Эффекторный нейрон (двигательный) переднего рога, вызывающий сокращение мышцы
4	Рецепторный нейрон, получающий импульсы от проприоцептора
5	У – мотонейрон бокового рога, регулирующий обмен веществ в мышце и проприорецепторе
6	Периферический вегетативный нейрон в периферическом симпатическом узле

1

Желудок

1	a. et v. oesophageae
2	vena gastrica sinistra
3	arteria gastrica dextra
4	vena portae
5	a. hepatica communis
6	a. gastroduodenalis
7	a. hepatica propria





Желудо

к

1	Oesophagus
2	Incisura cardiaca
3	Pars cardiaca
4	Curvatura gastrica minor
5	Pylorus
6	Incisura angularis
7	Antrium pyloricum
8	Pars pylorica
9	Fundus gastrica
10	Curvatura gastrica major
11	Corpus gastricum
12	Plicae gastricae