ФУНКЦИОНАЛЬНАЯ АНАТОМИЯ МОЧЕВЫДЕЛИТЕЛЬНОЙ СИСТЕМЫ

(Е.С. ОКОЛОКУЛАК)

Функции почек

ЗАПОМНИ!
И ЗНАЙ!

I. Участвуют в поддержании постоянного состава внутренней среды;

II. Участвуют в регуляции артериального давления (синтез ринита);

III. Стимулируют образование эритроцитов;

IV. Образуют биологически активные вещества.

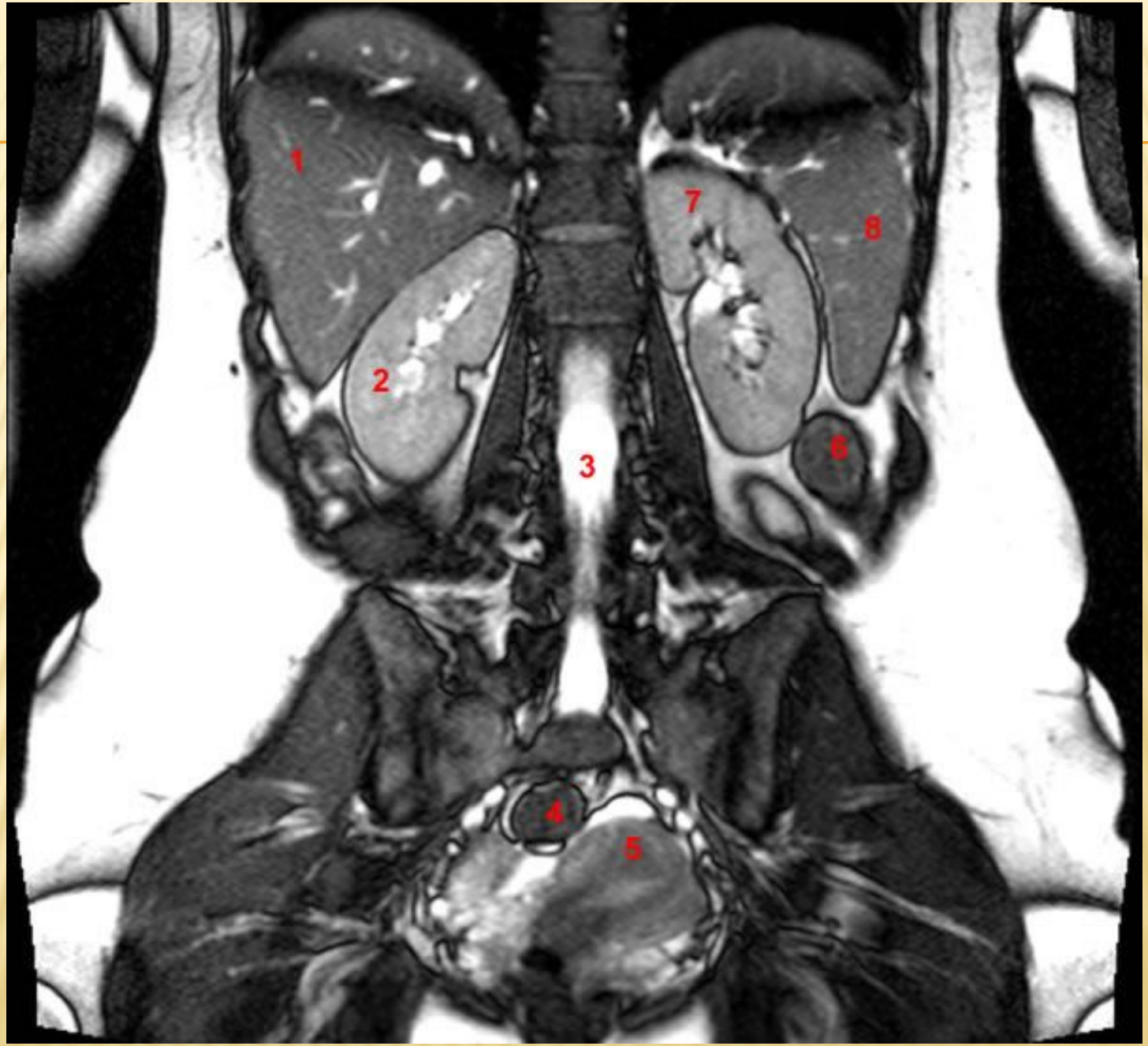
1
2
3
4
5
6
7
8

СКЕЛЕТОТОПИЯ:

верхний полюс левой почки располагается на середине 11-го грудного позвонка, нижний - верхний край 3-го поясничного позвонка, 12-е ребро пересекает левую почку почти по середине.

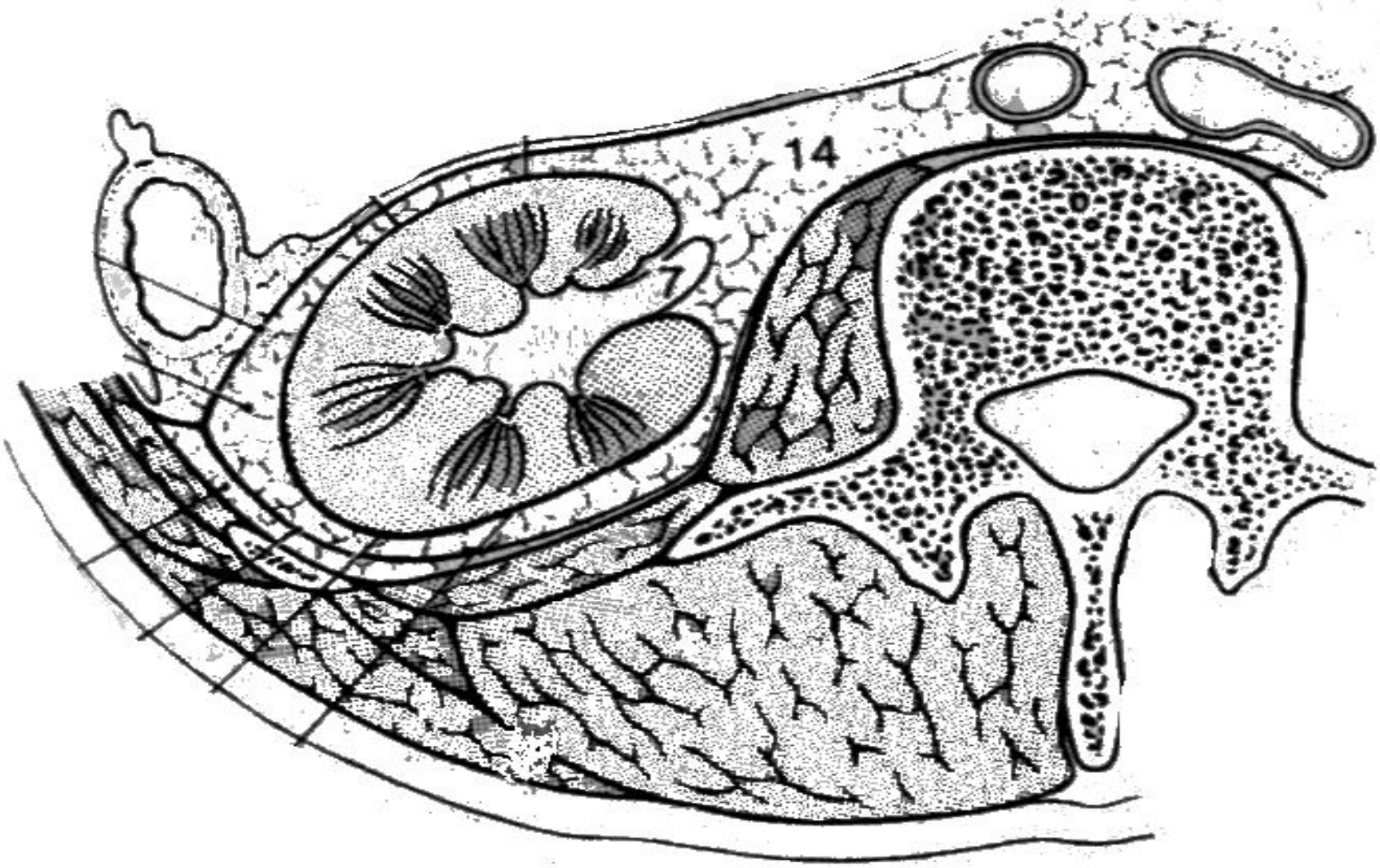
14
7

ФИКСИРУЮЩИЙ АППАРАТ ПОЧЕК.

1. Жировая капсула (*capsula adiposa*).
2. Почечная фасция (*fascia renalis*)
3. Почечные сосуды (артерия, вена, мочеточник).
4. Мышечное ложе (m.psoas major, m. quadratus lumborum).
5. Внутрибрюшное давление.

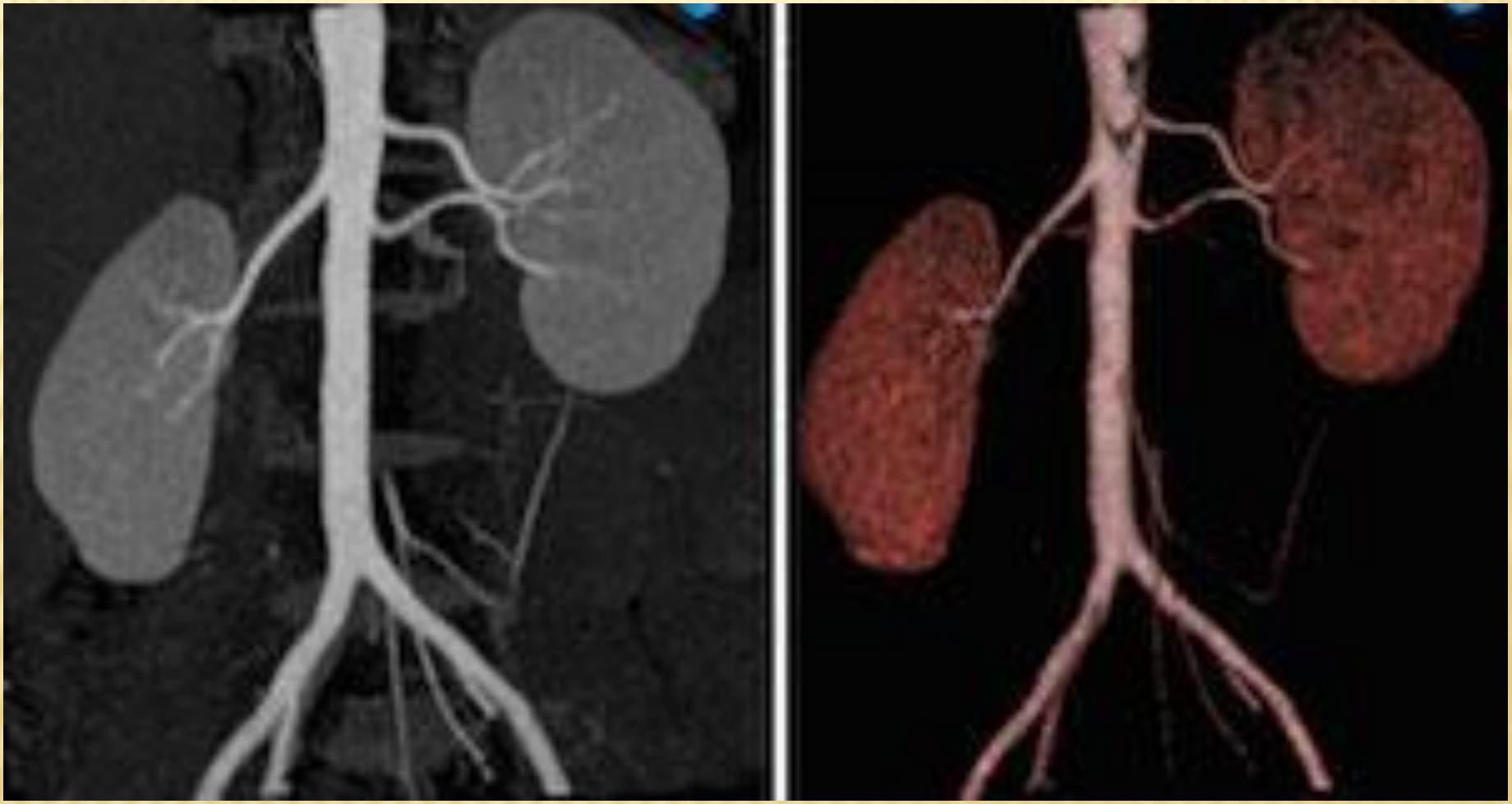

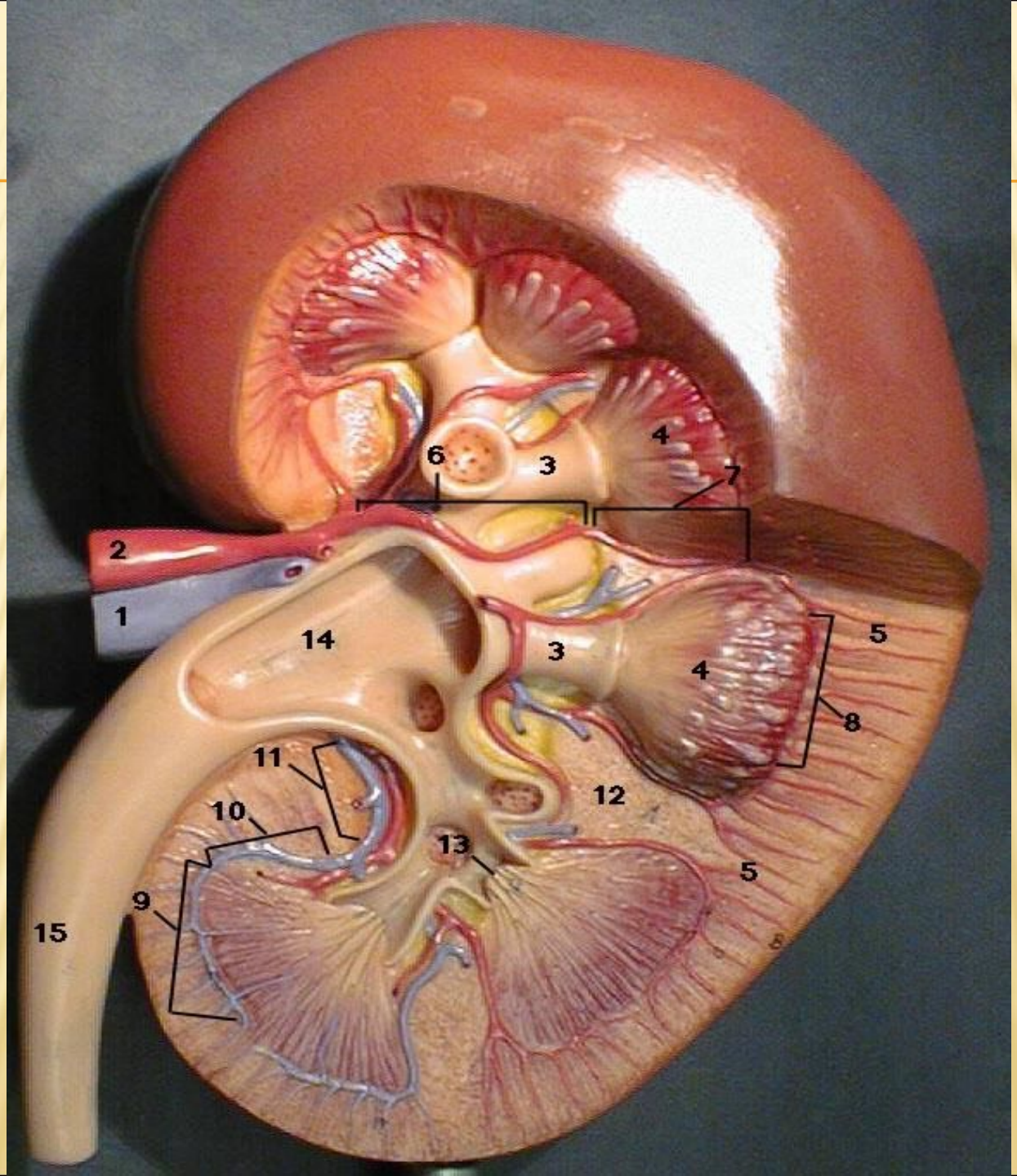
1
2
3
4
5
6
7
8
9
10
11
12
13
14
15

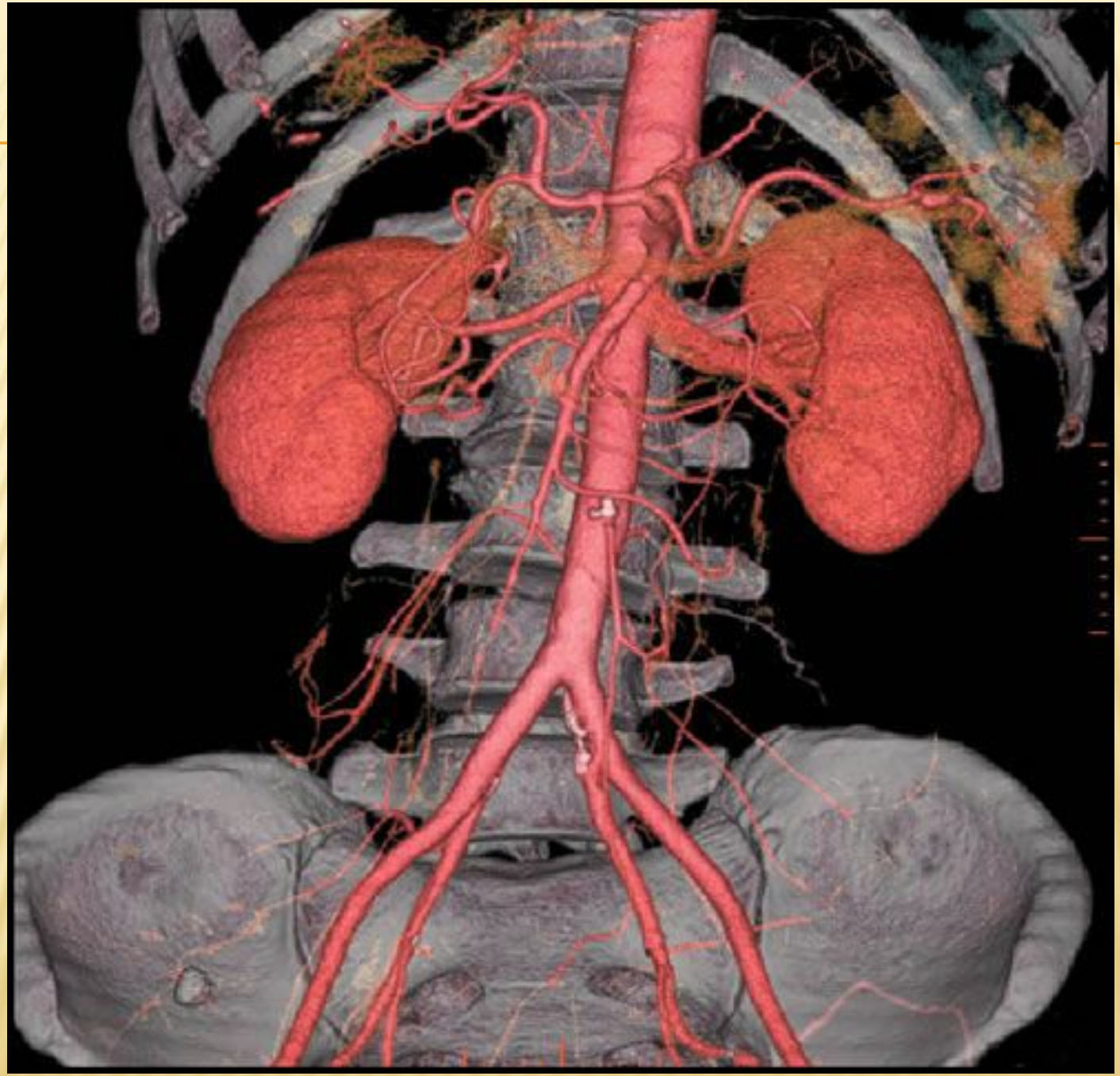

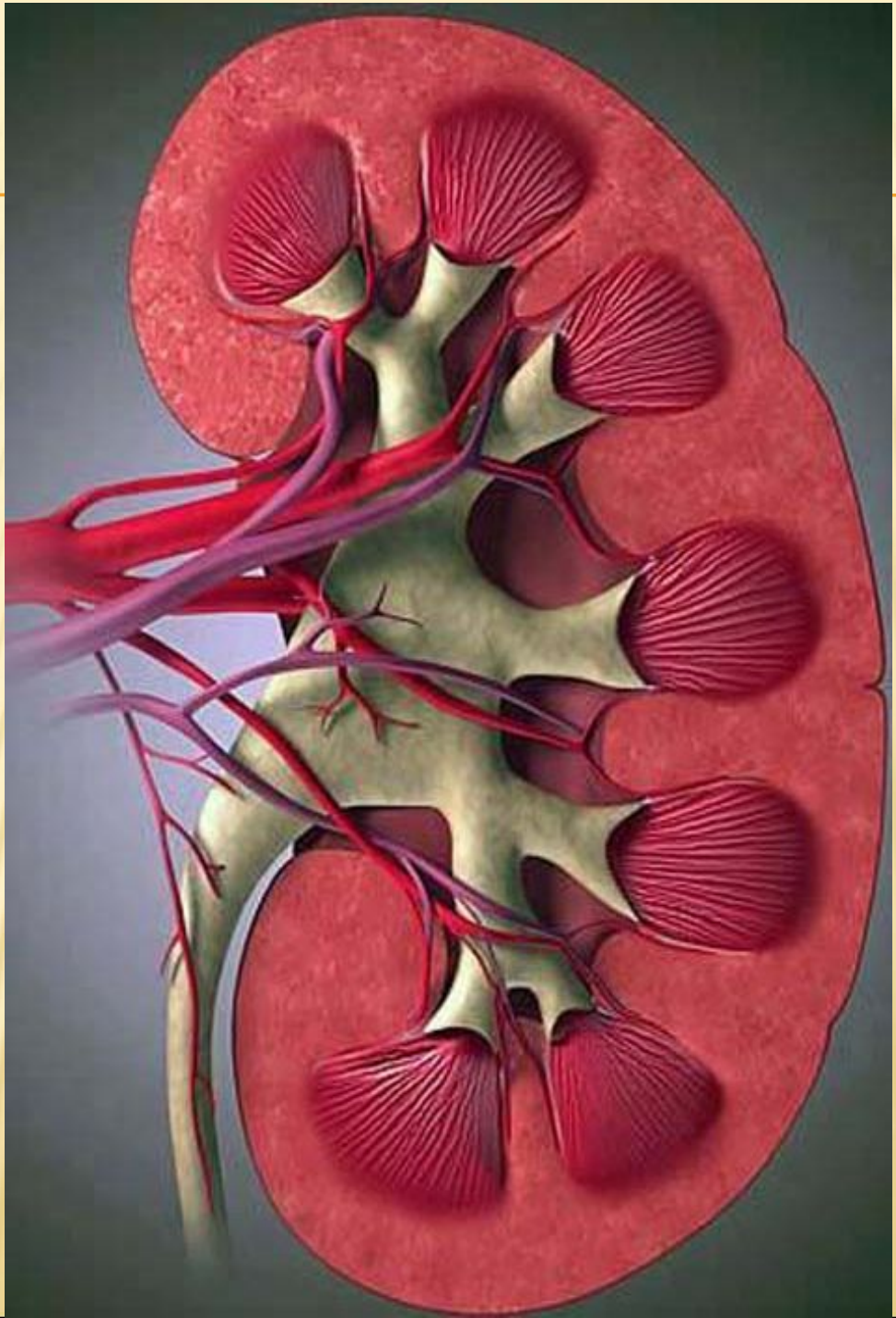

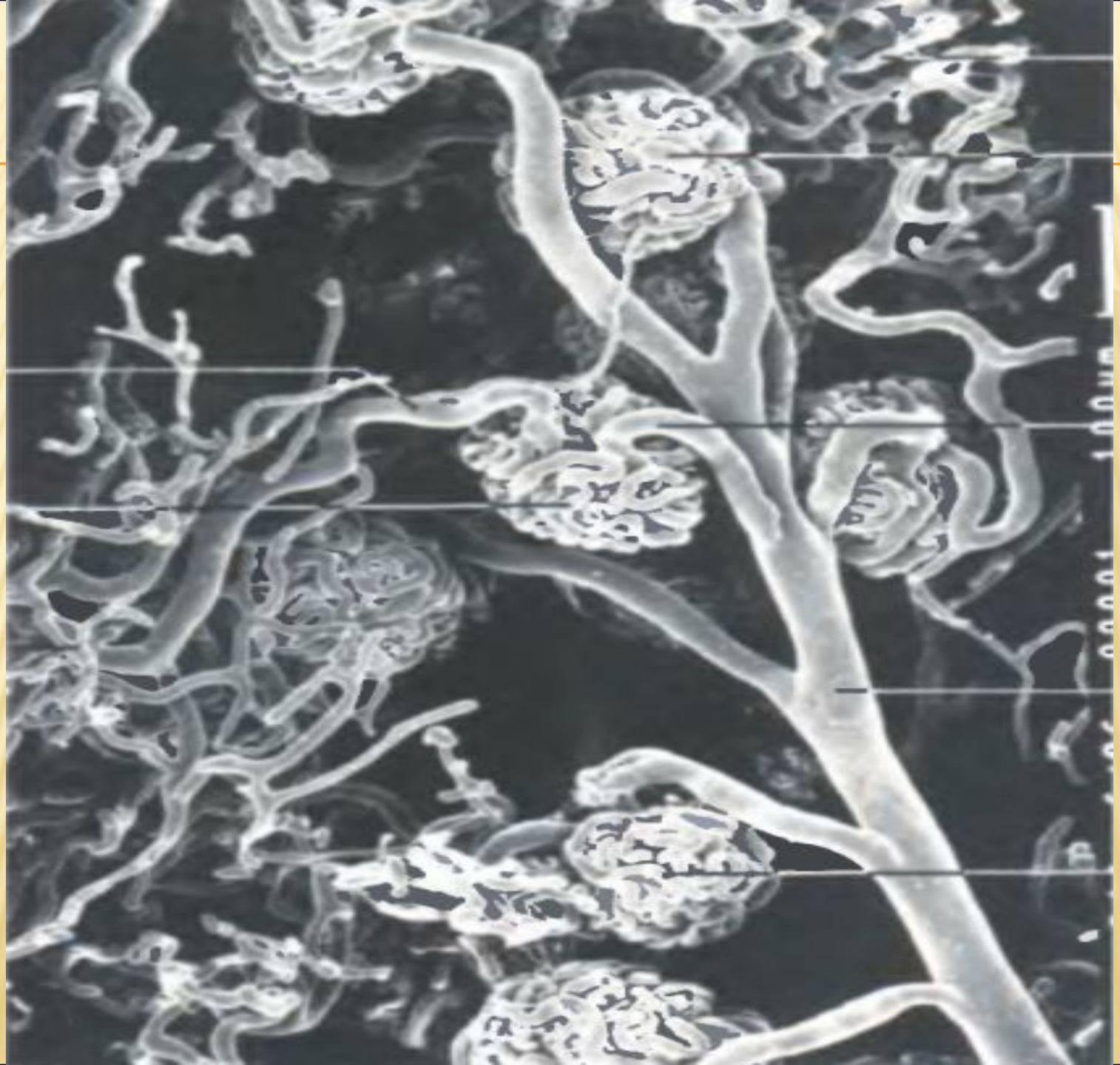

Detailed structure of a nephron

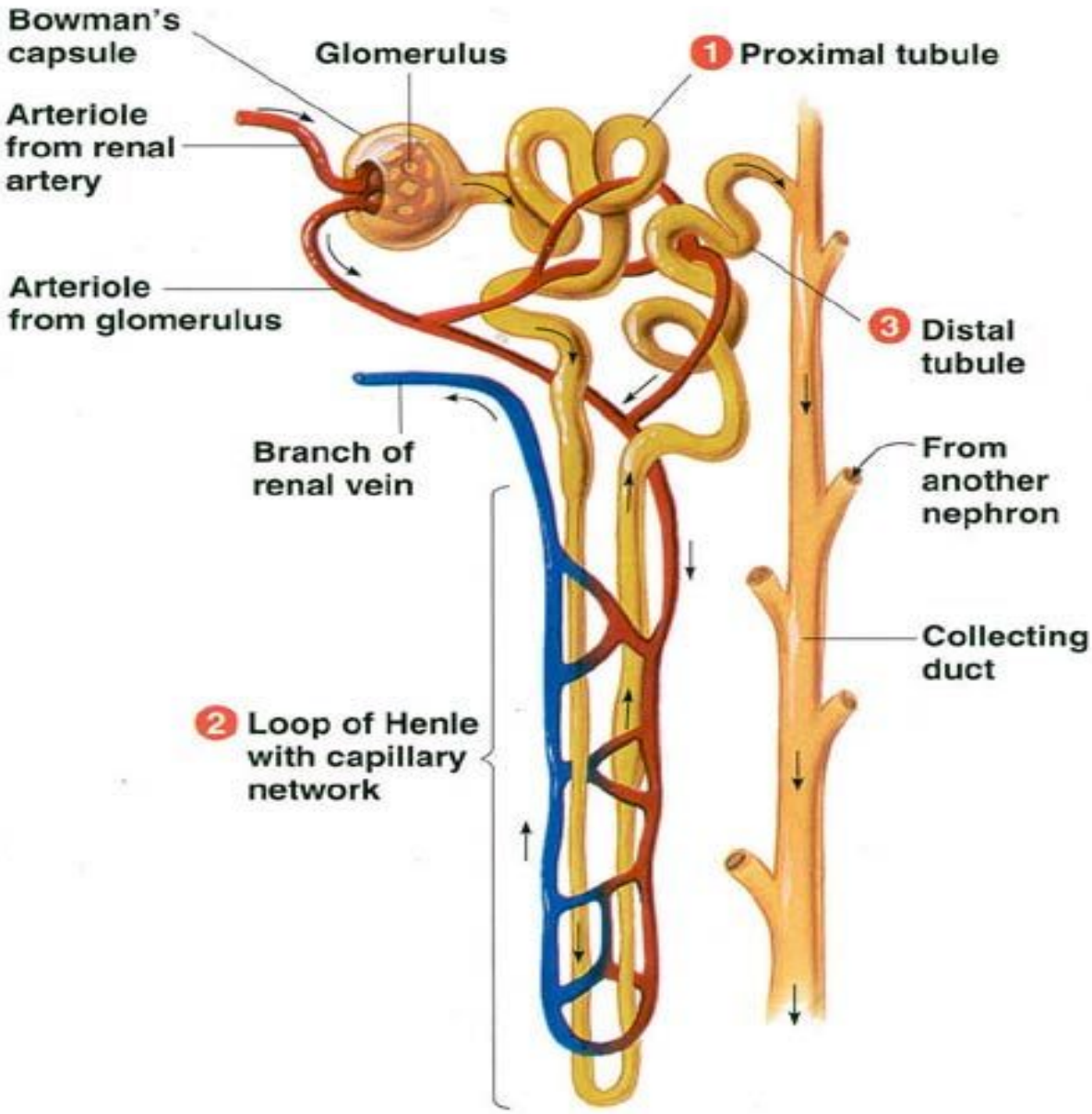

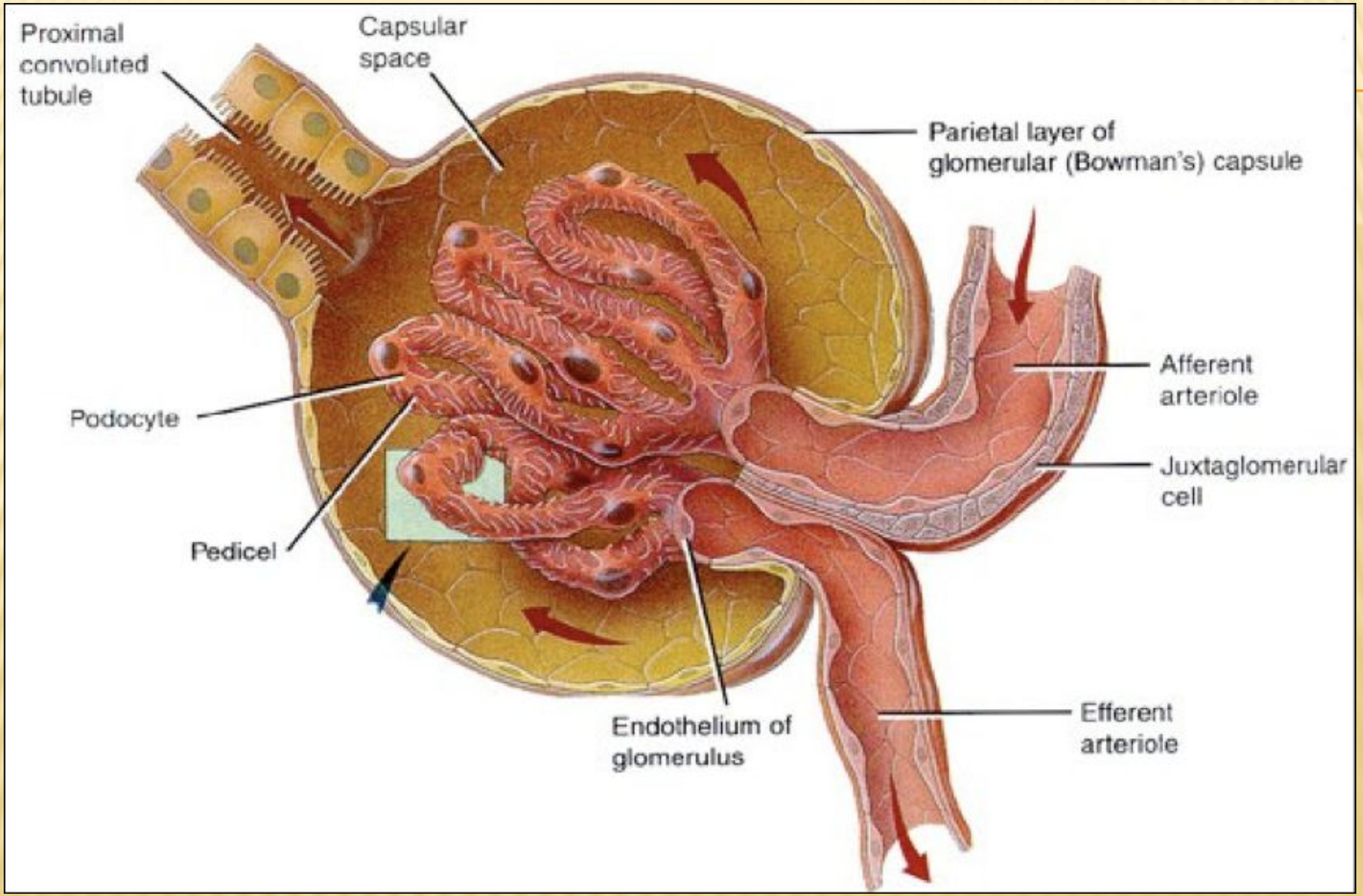
Proximal convoluted tubule
Capsular space
Parietal layer of glomerular (Bowman's) capsule
Afferent arteriole
Juxtaglomerular cell
Podocyte
Pedicel
Endothelium of glomerulus
Efferent arteriole

СТРУКТУРНО-ФУНКЦИОНАЛЬНАЯ ЕДИНИЦА ПОЧКИ

Клубочек, окруженный капсулой (почечное тельце Мальпиги-Шумлянского), извитой каналец I и II-ого порядка, петля Генле и вставочный отдел образуют структурно функциональную единицу почки - *нефрон*.

Какой процесс в организме иллюстрируют эти числа?

- 1500 литров
- 150 литров
- 1,5 литра

ОТВЕТ:

1500 л крови фильтруется за сутки через клубочки;
150 л первичной мочи образуется;
1,5 литра – вторичной.

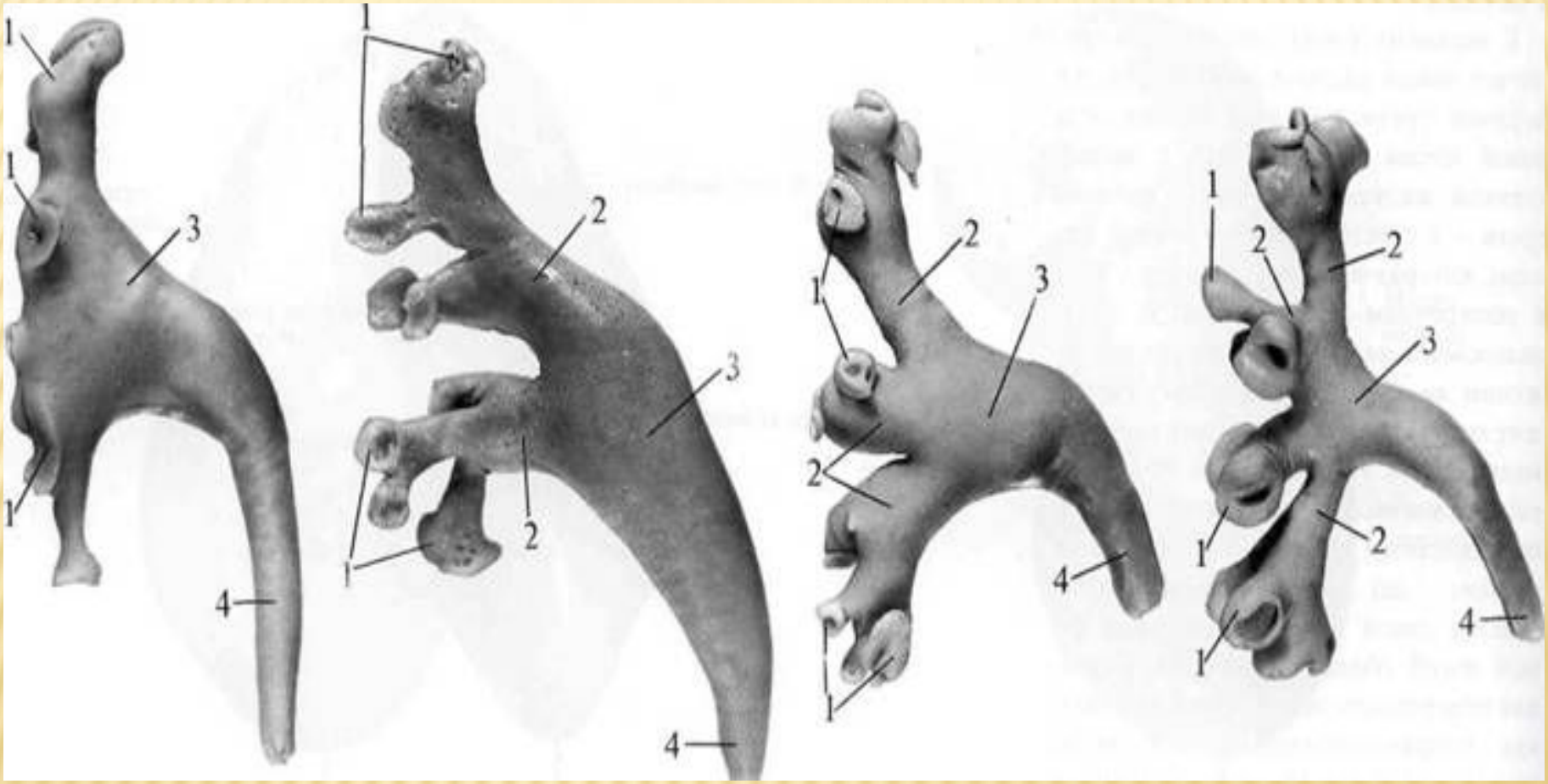
1
1
3
1
4
1
2
3
1
2
4
2
1
3
2
4
1
1
2
2
3
1
2
1
4

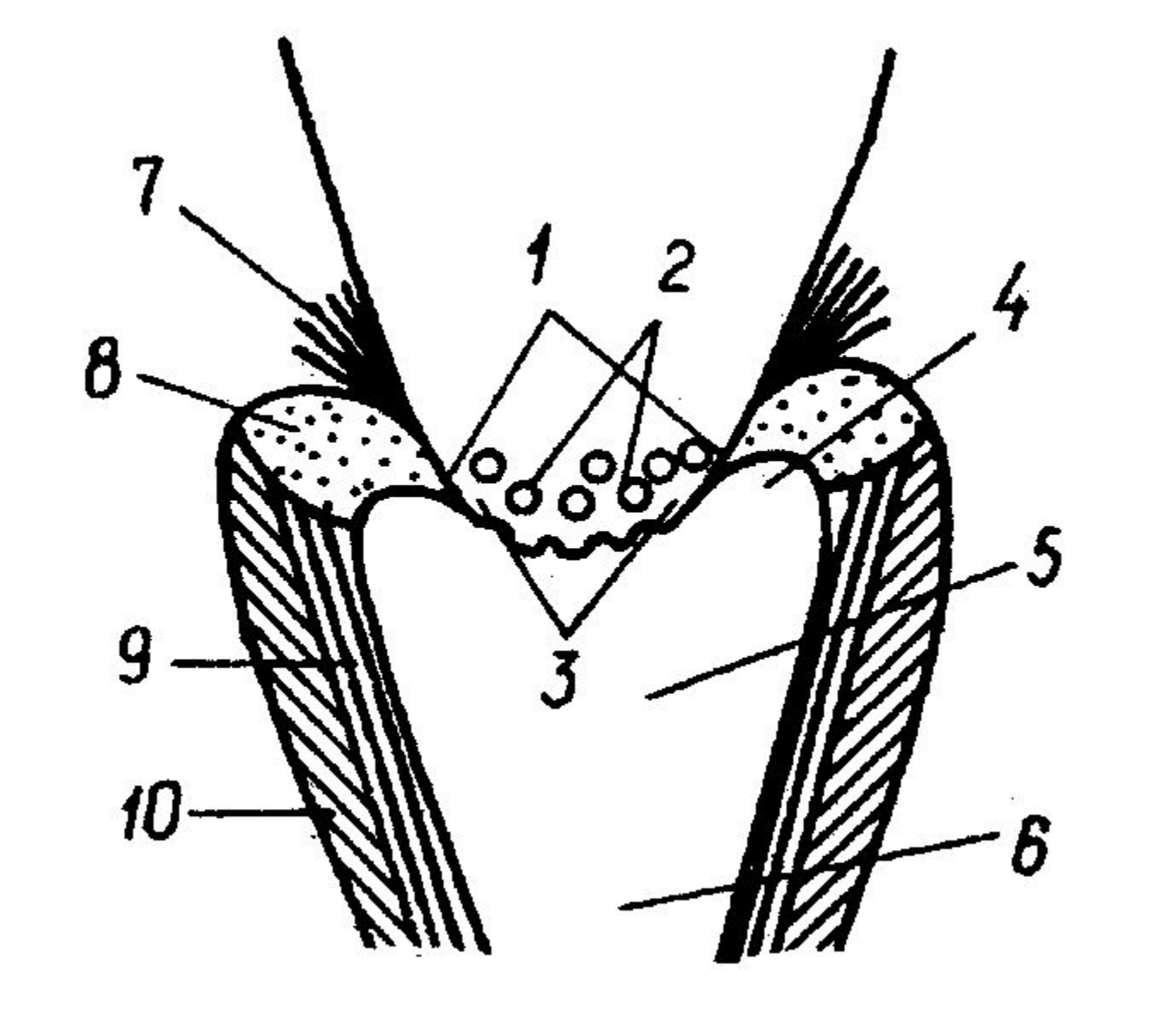
7
1
2
4
8
5
9
3
10
6

ФОРНИКАЛЬНЫЙ АППАРАТ

неисчерченные мышечные волокона (m. sphincter fornicis), соединитель-ная ткань, кровеносные и лимфати-ческие сосуды, нервные волокона, а также вспомогательные мышцы (m. levator fornicis, m. longitudinalis caly-cis, m. sphiralis calycis)



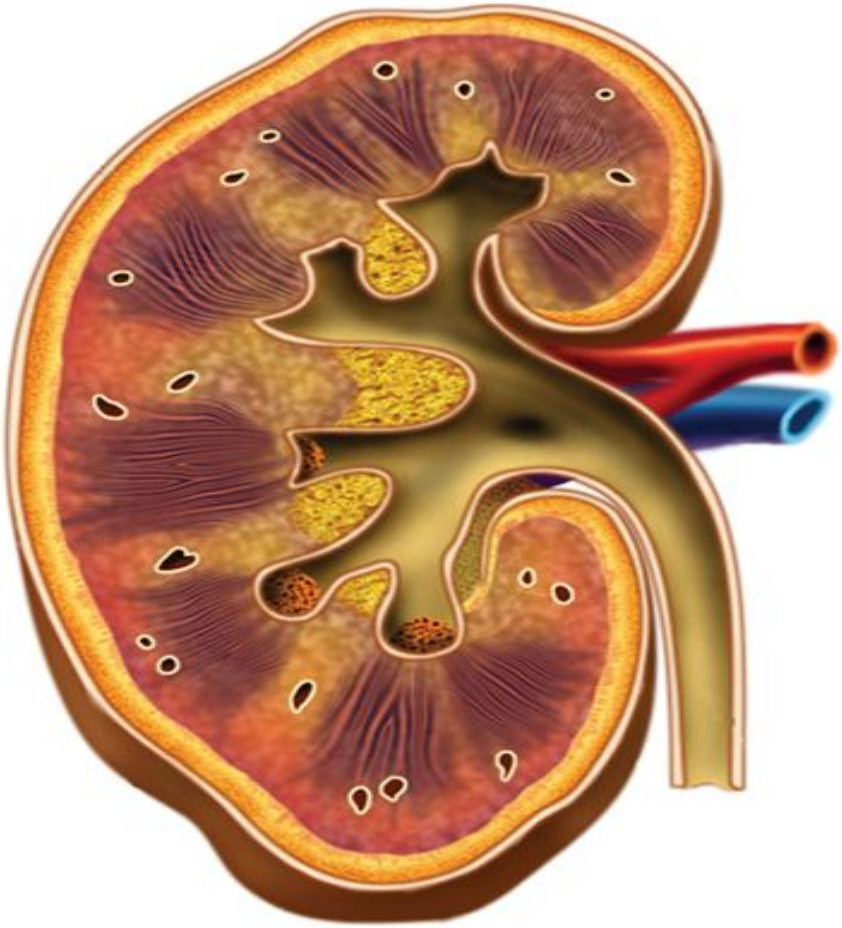

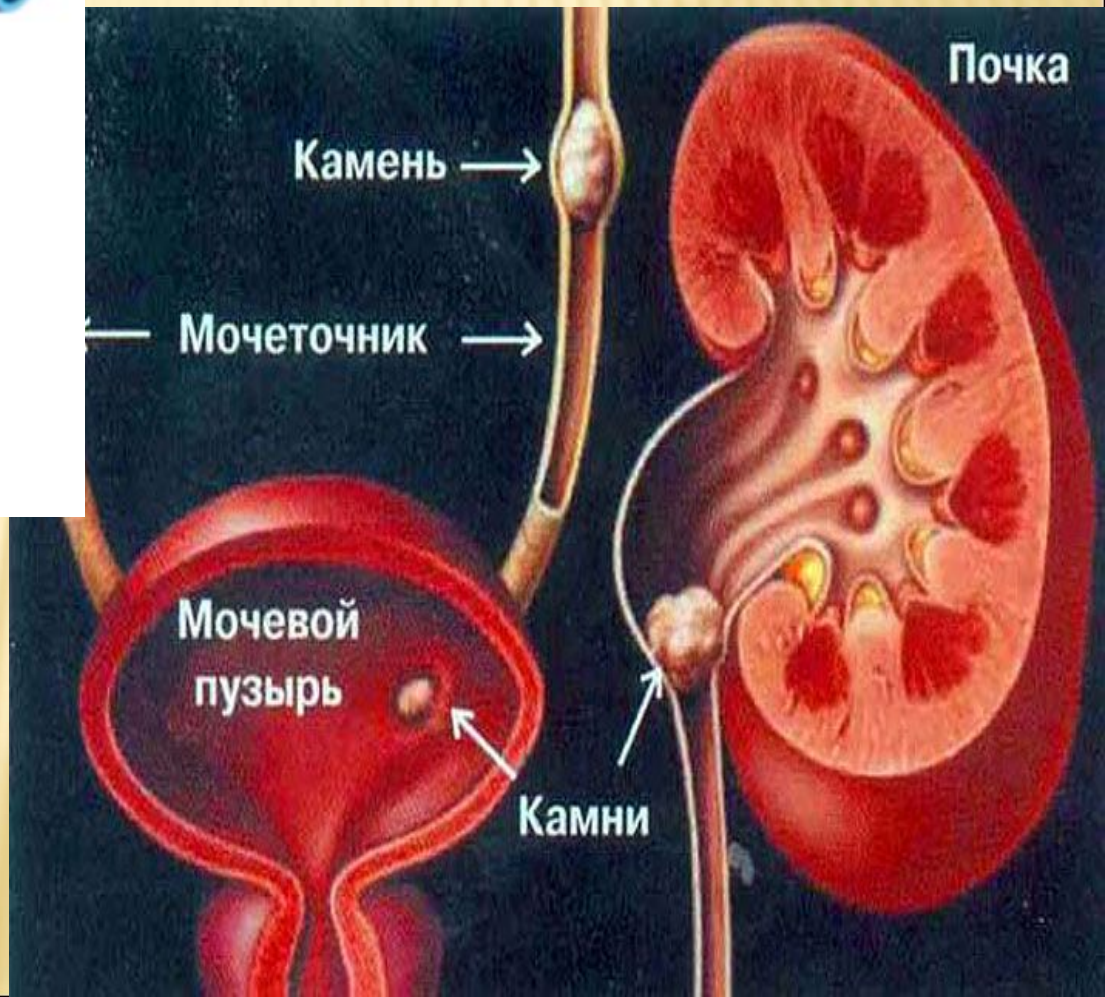
Почка
Камень
Мочеточник
Мочевой пузырь
Камни

Камни

Камень

Тень камня

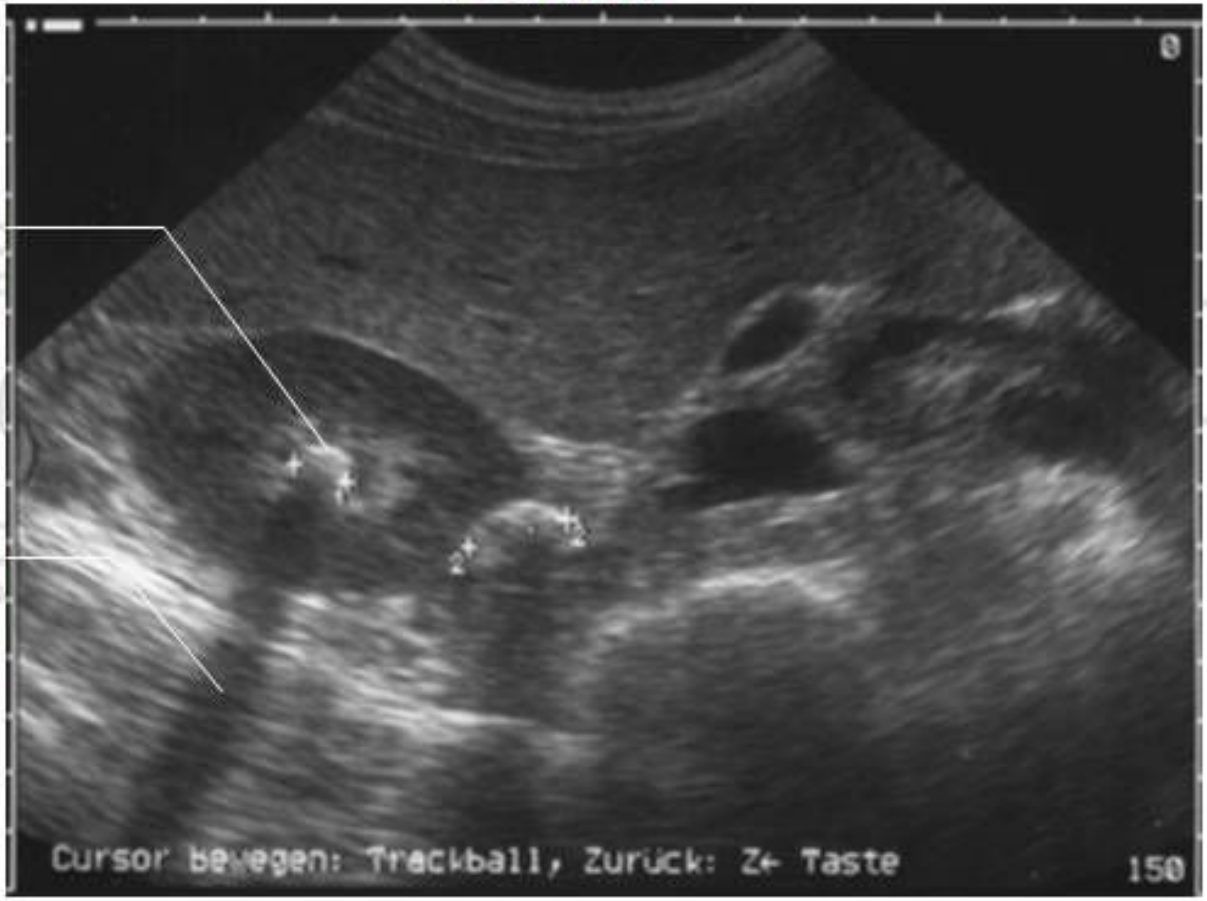

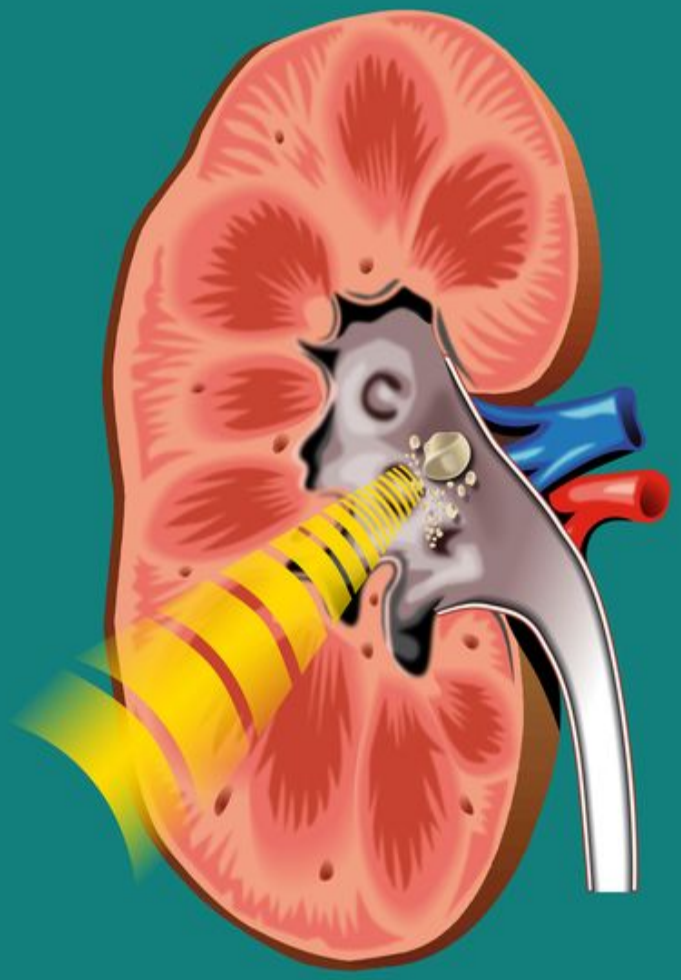

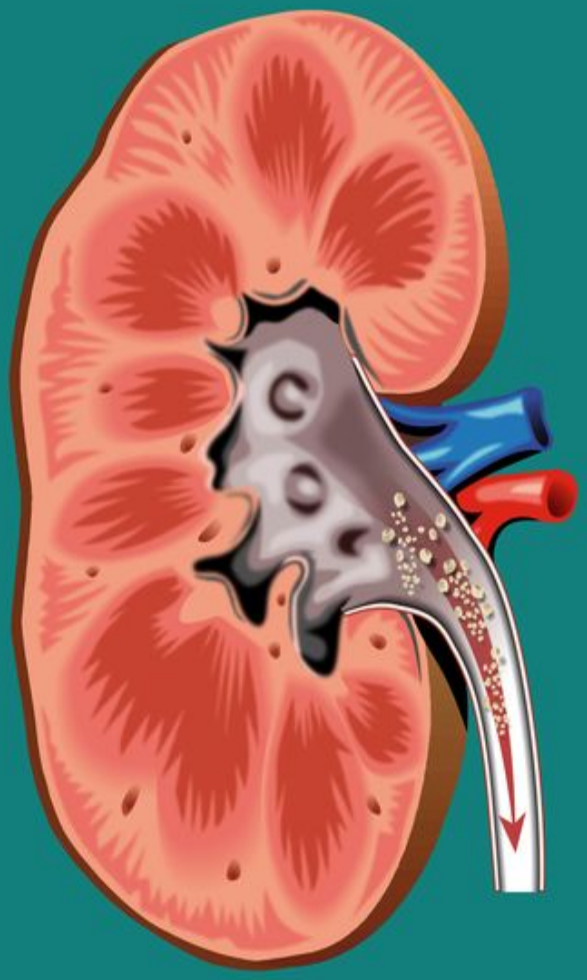

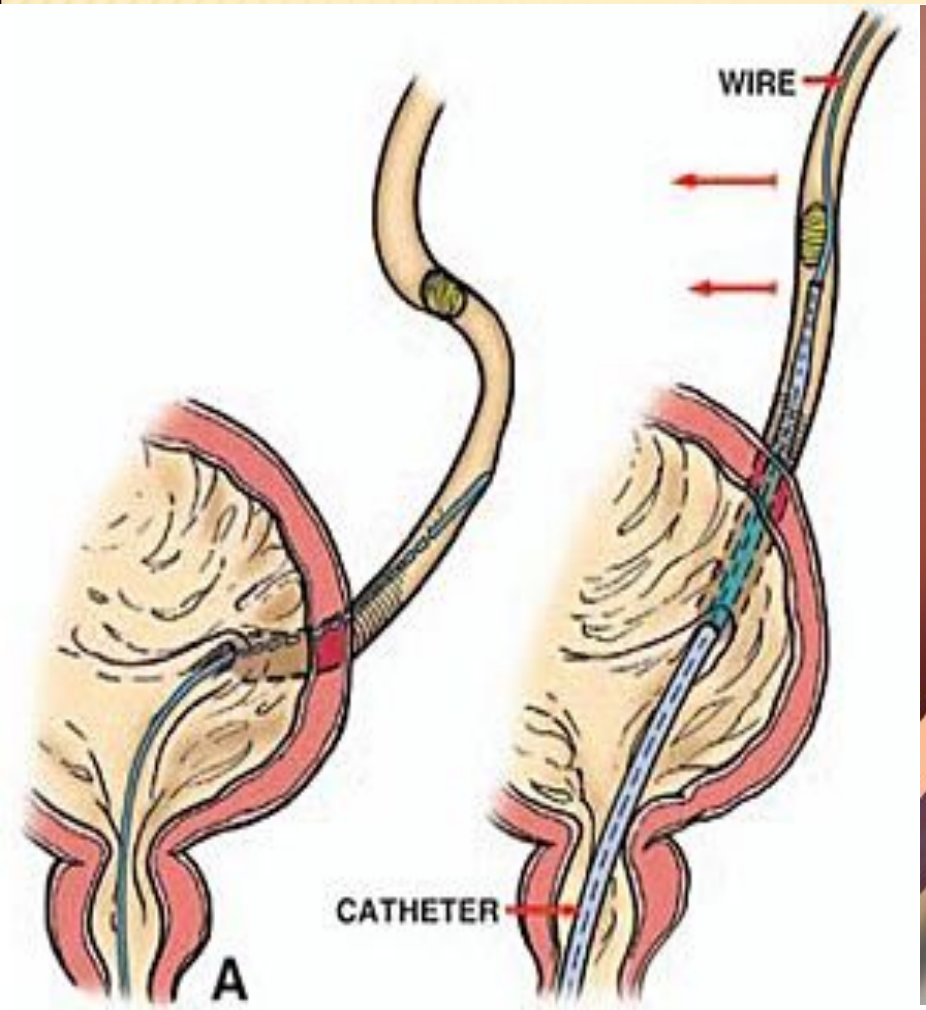
WIRE
CATHETER
A

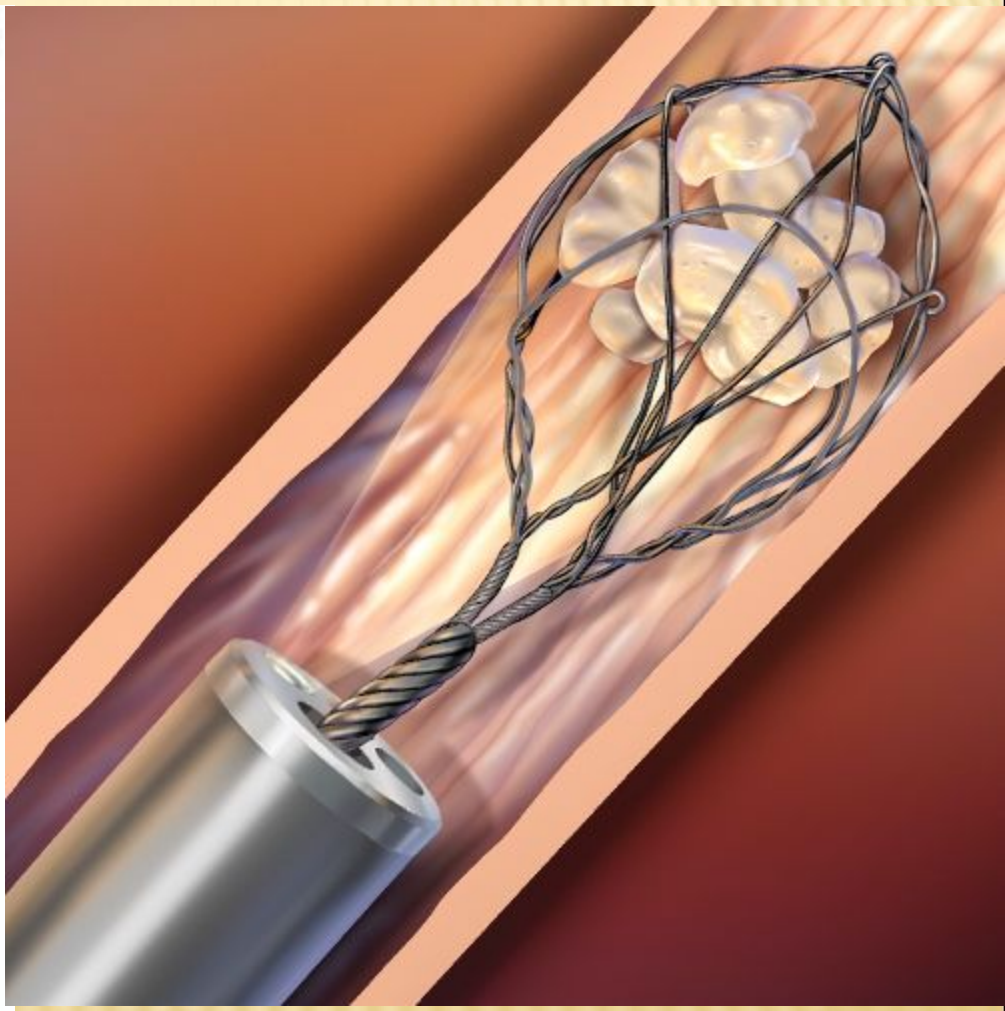

паренхиматозная
киста почки

Polycystic Kidney Disease

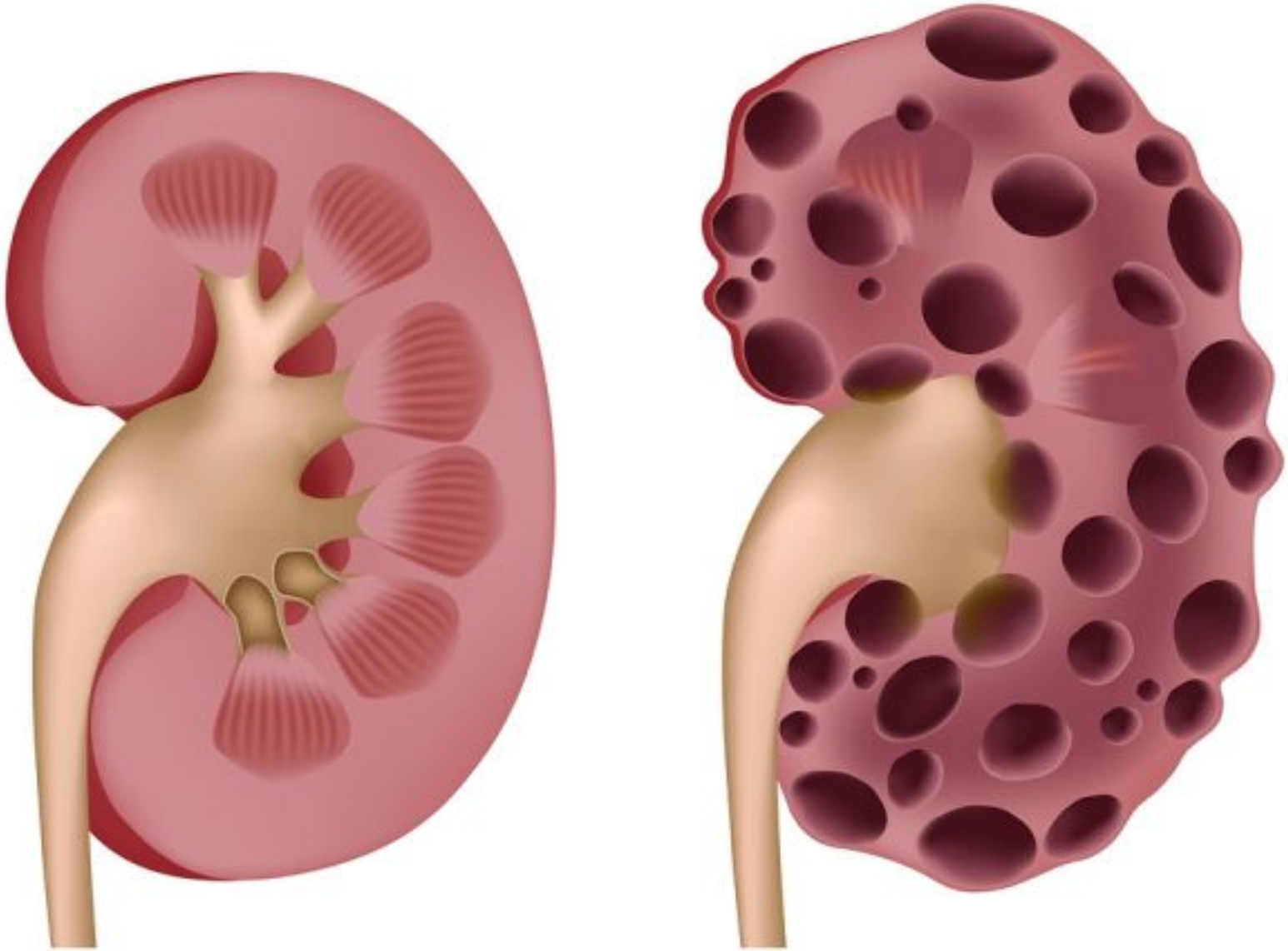

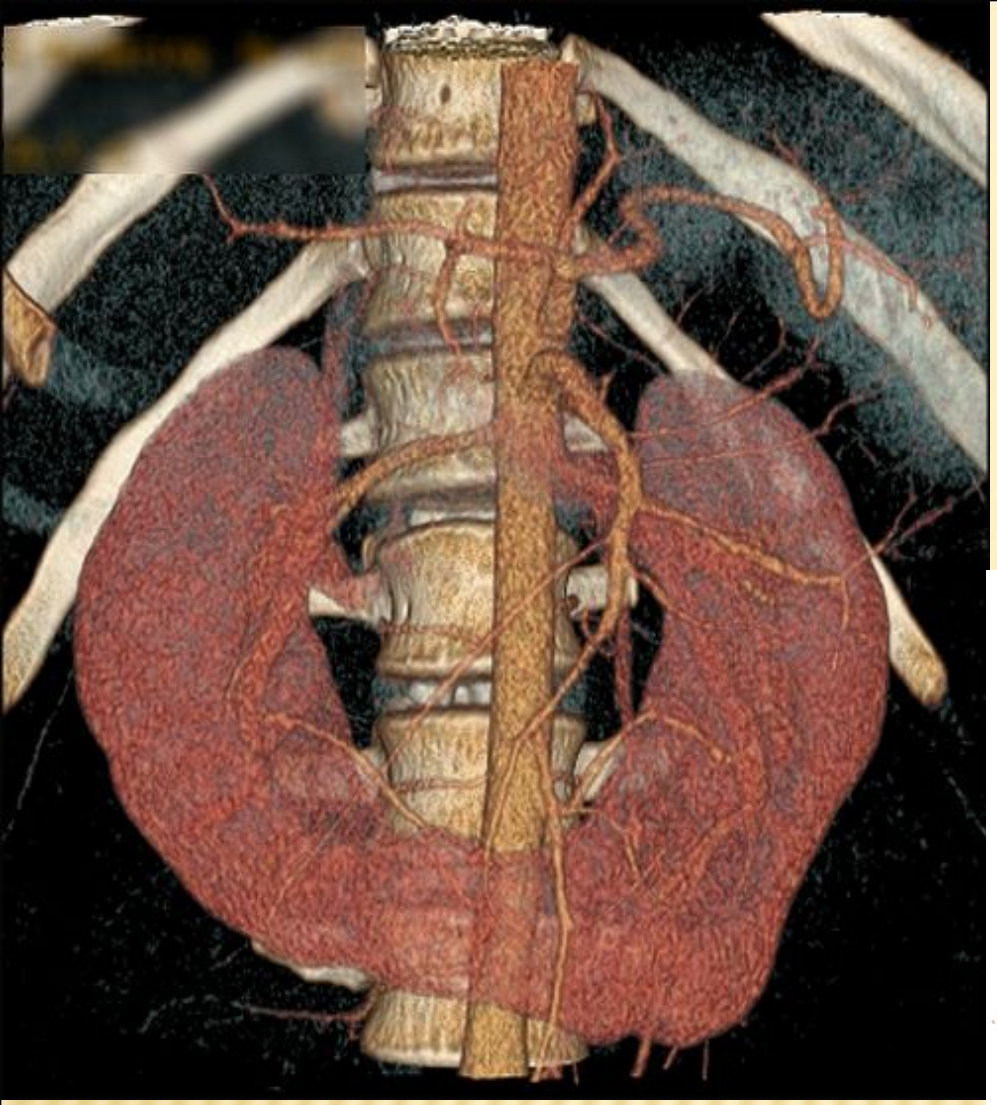

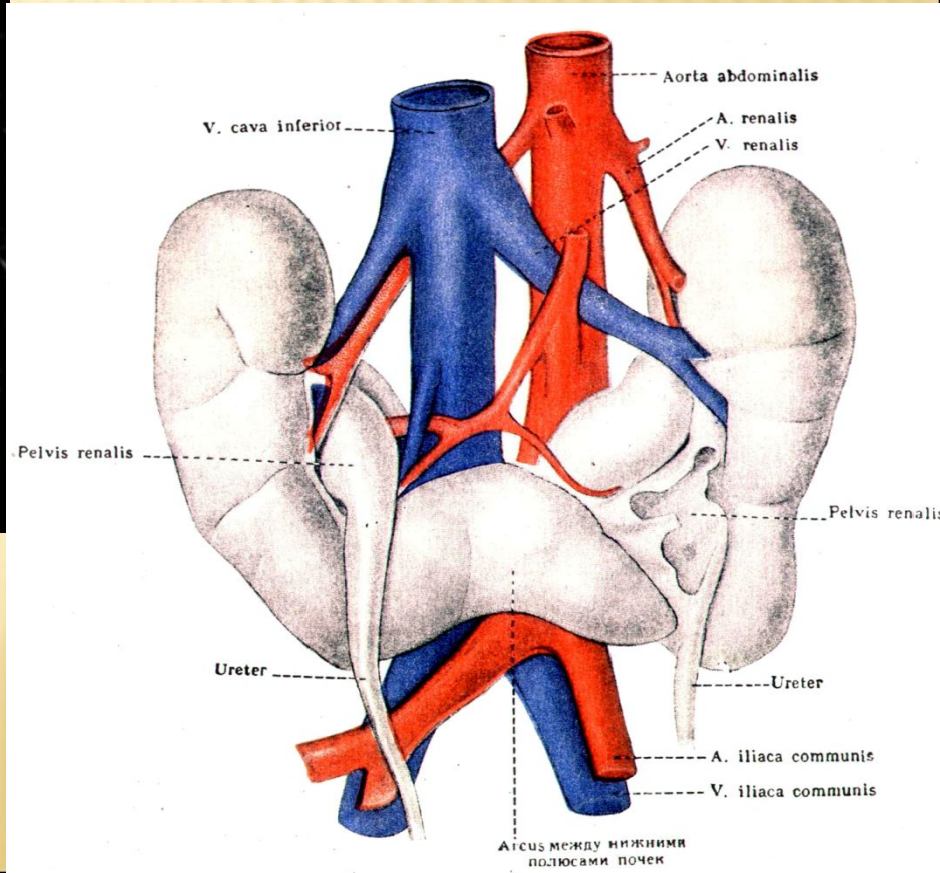
Aorta abdominalis
V. cava inferior
A. renalis
V. renalis
Pelvis renalis
Pelvis renalis
Ureter
Ureter
A. iliaca communis
V. iliaca communis
Arcus между нижними
полюсами почек

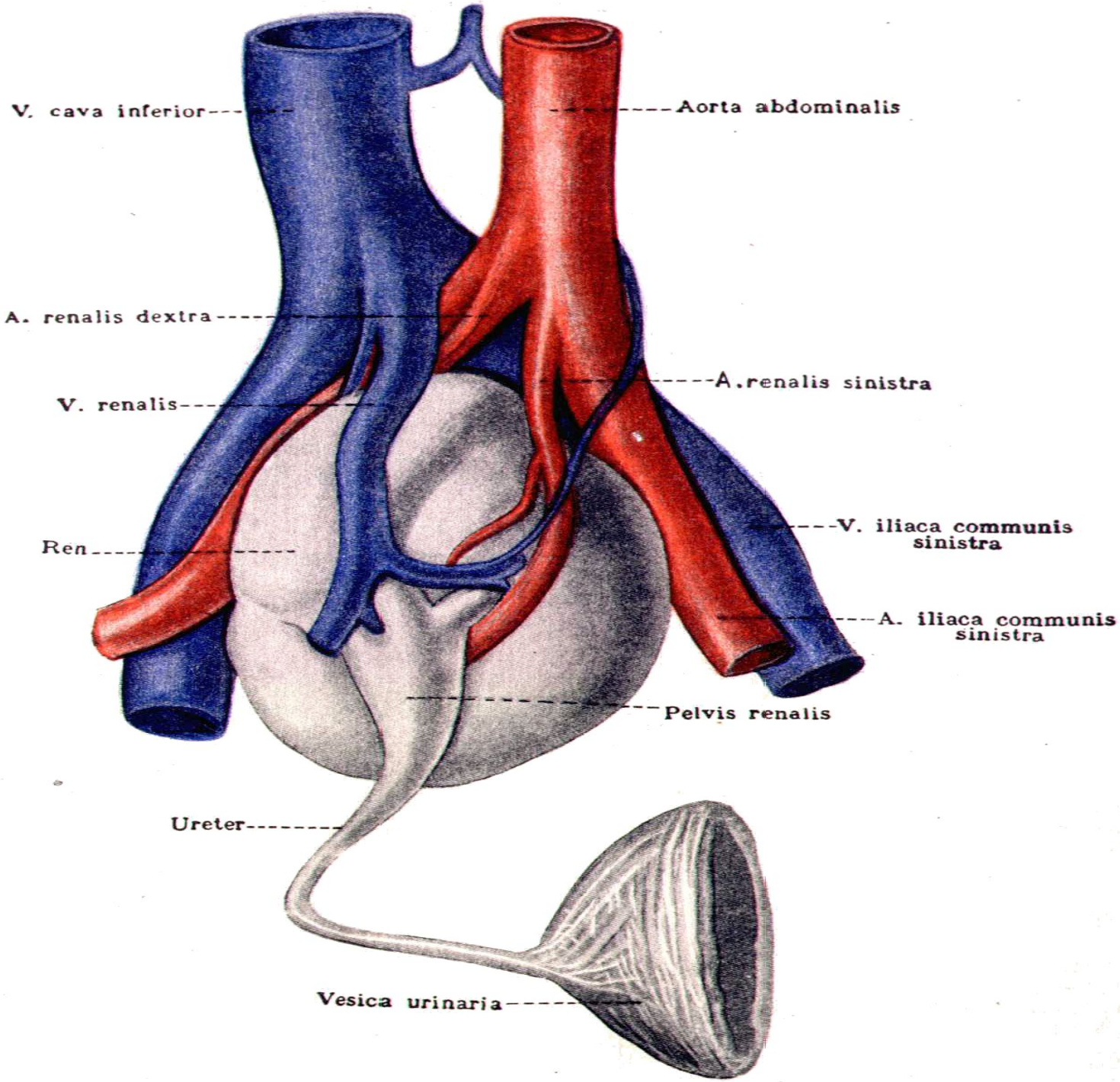
V. cava inferior
Aorta abdominalis
A. renalis dextra
A. renalis sinistra
V. renalis
V. iliaca communis sinistra
Ren
A. iliaca communis sinistra
Pelvis renalis
Ureter
Vesica urinaria

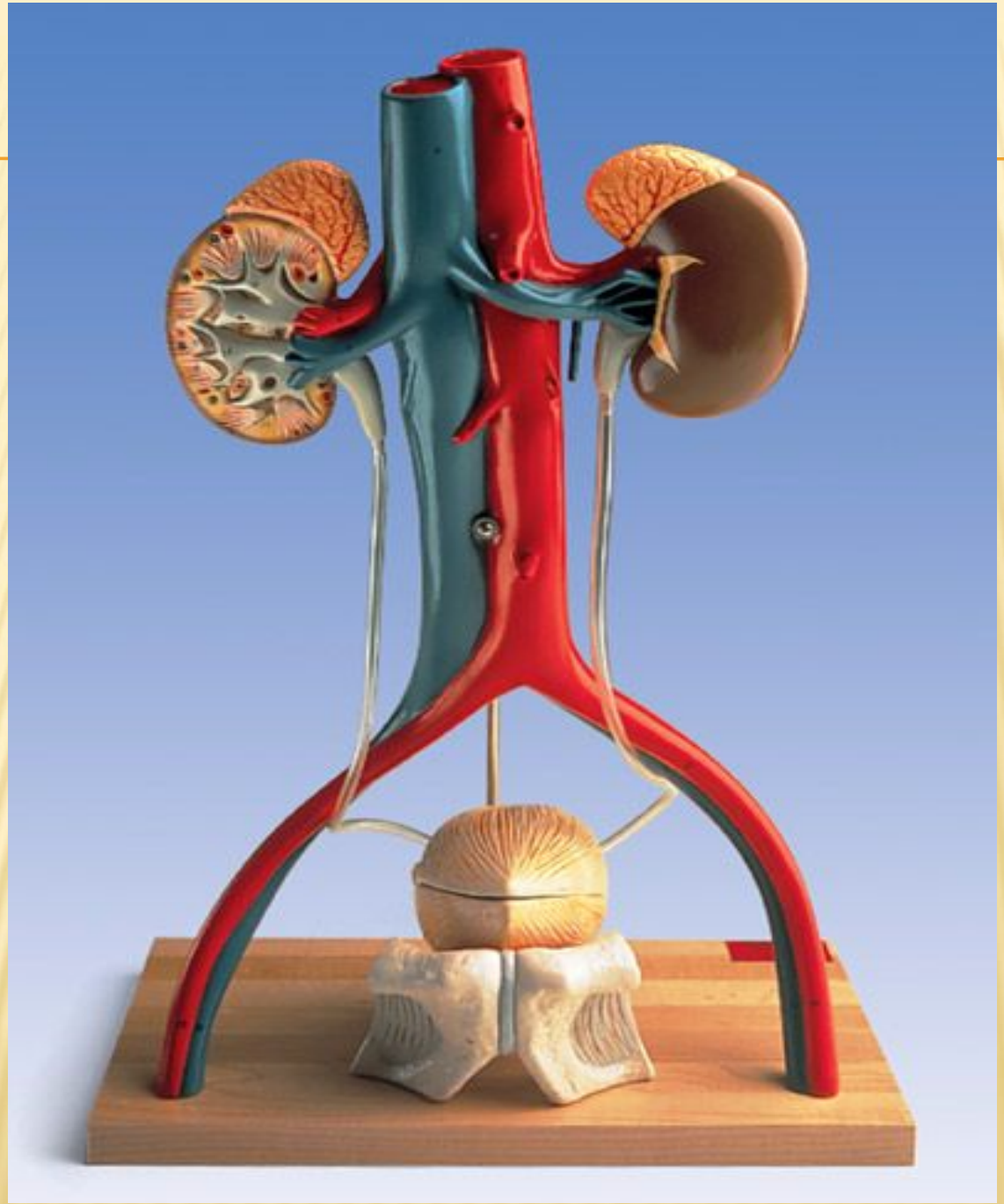

МОЧЕТОЧНИК

- ***брюшная часть*** (*pars abdominalis*) до места перегиба его через l.terminalis в полость малого таза;
- ***тазовая часть*** (*pars pelvina*)
- ***внутристеночная часть*** (*pars intramuralis*) непосредственно в стенке мочевого пузыря.

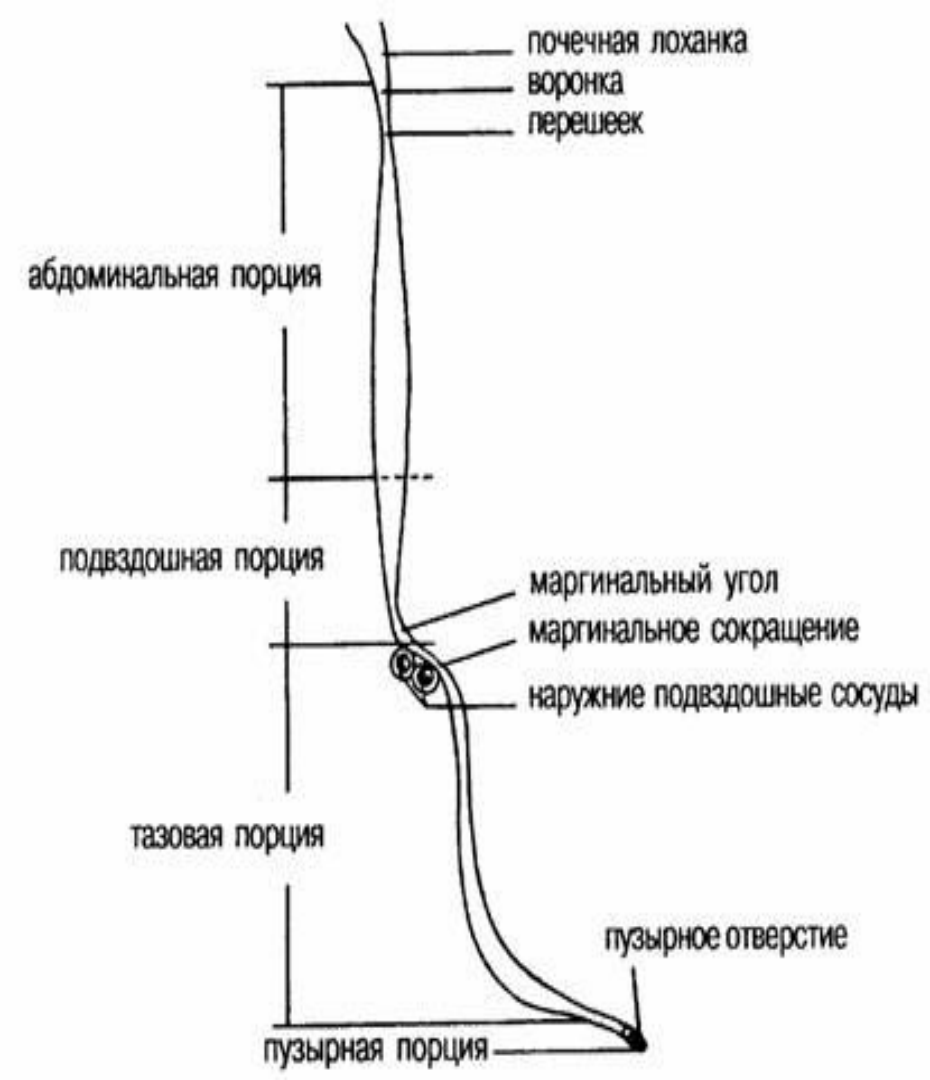

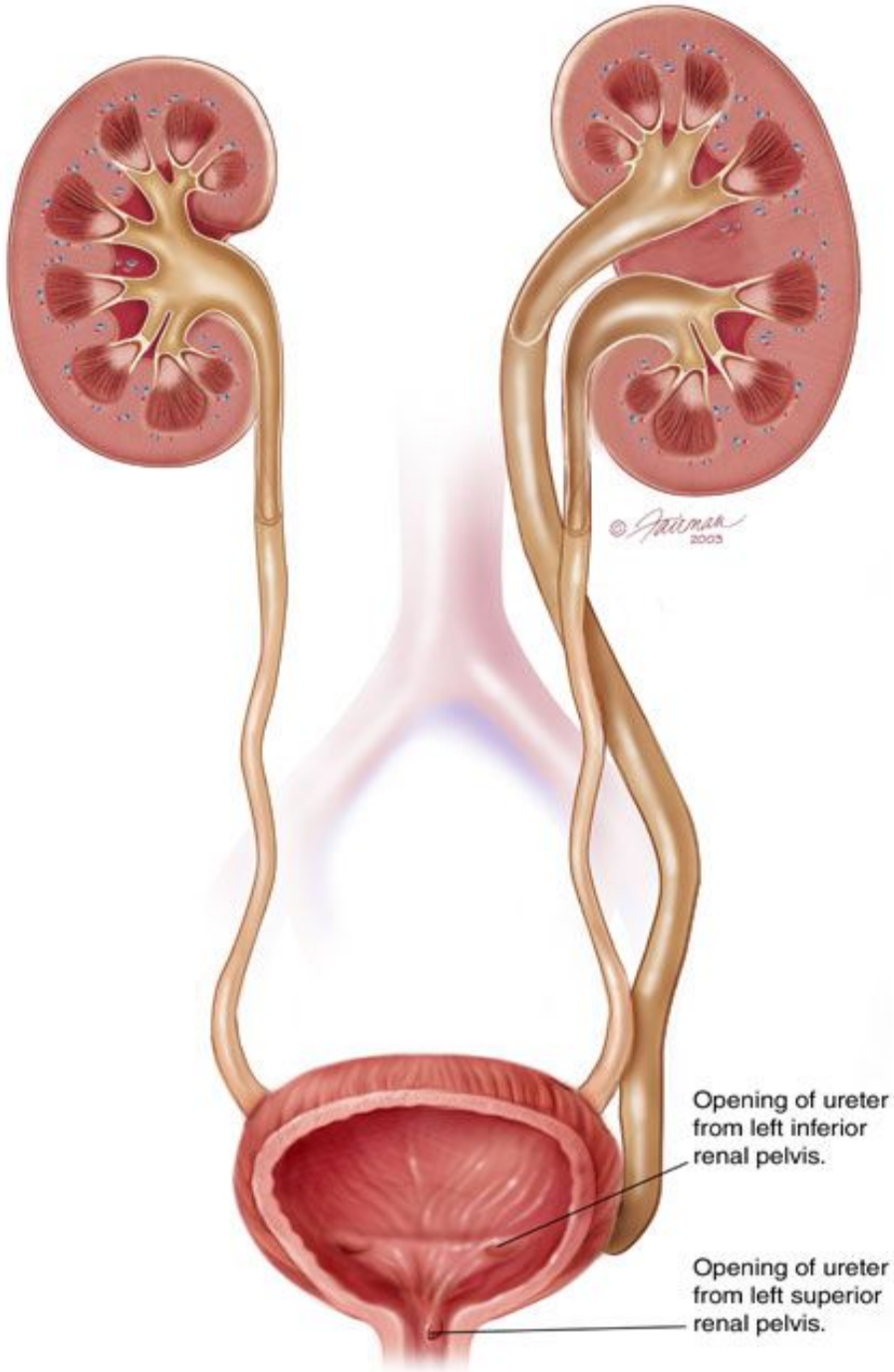
Opening of ureter from left inferior renal pelvis.
Opening of ureter from left superior renal pelvis.

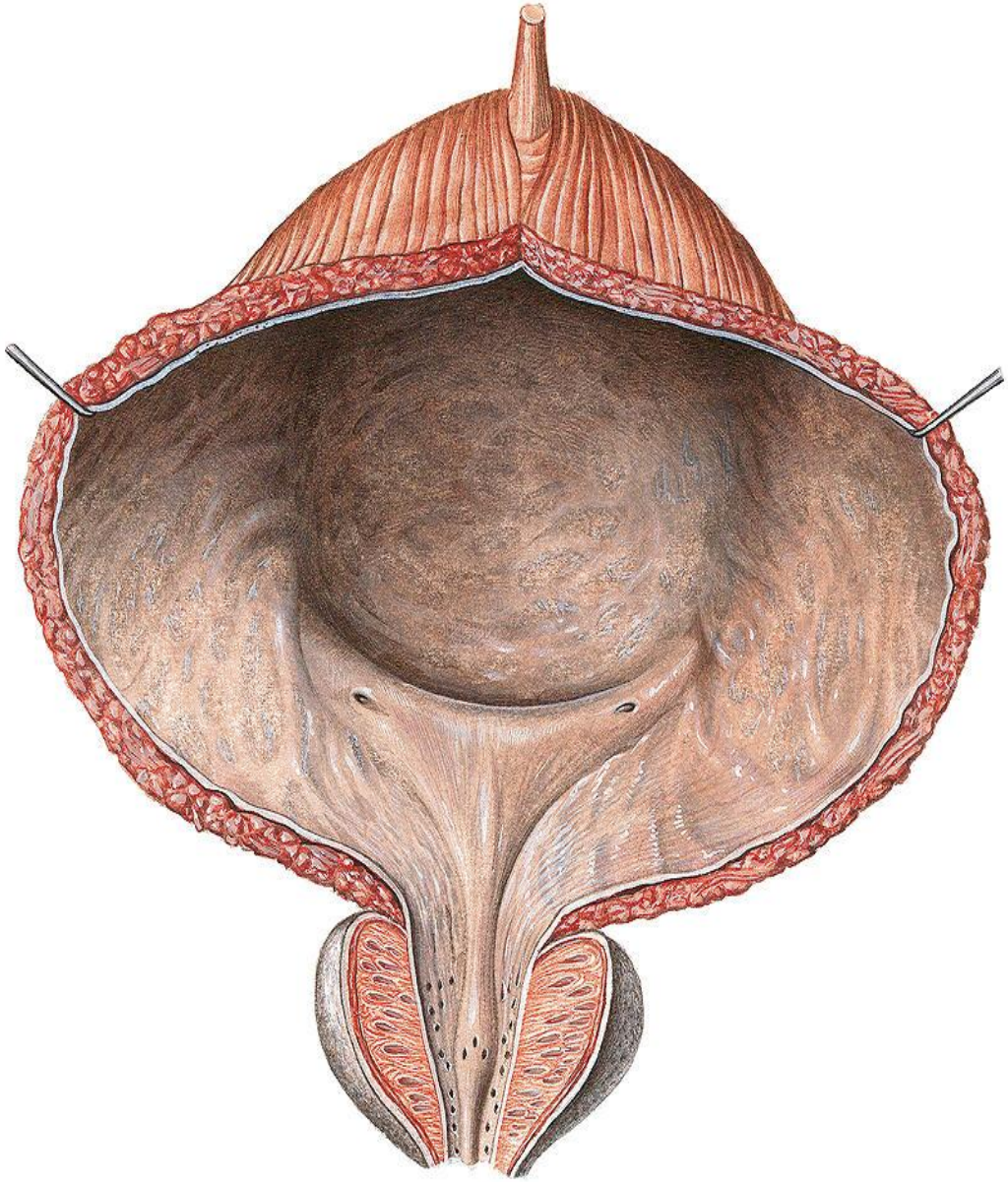

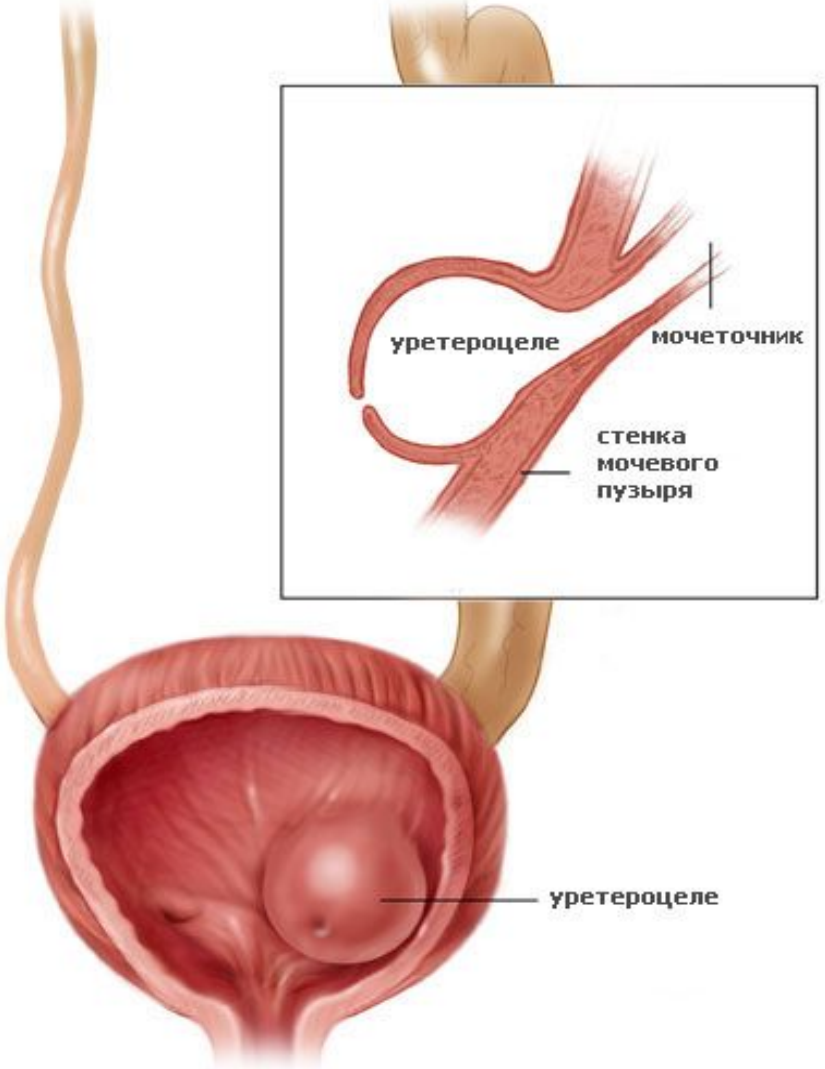
уретероцеле
мочеточник
стенка
мочевого
пузыря
уретероцеле

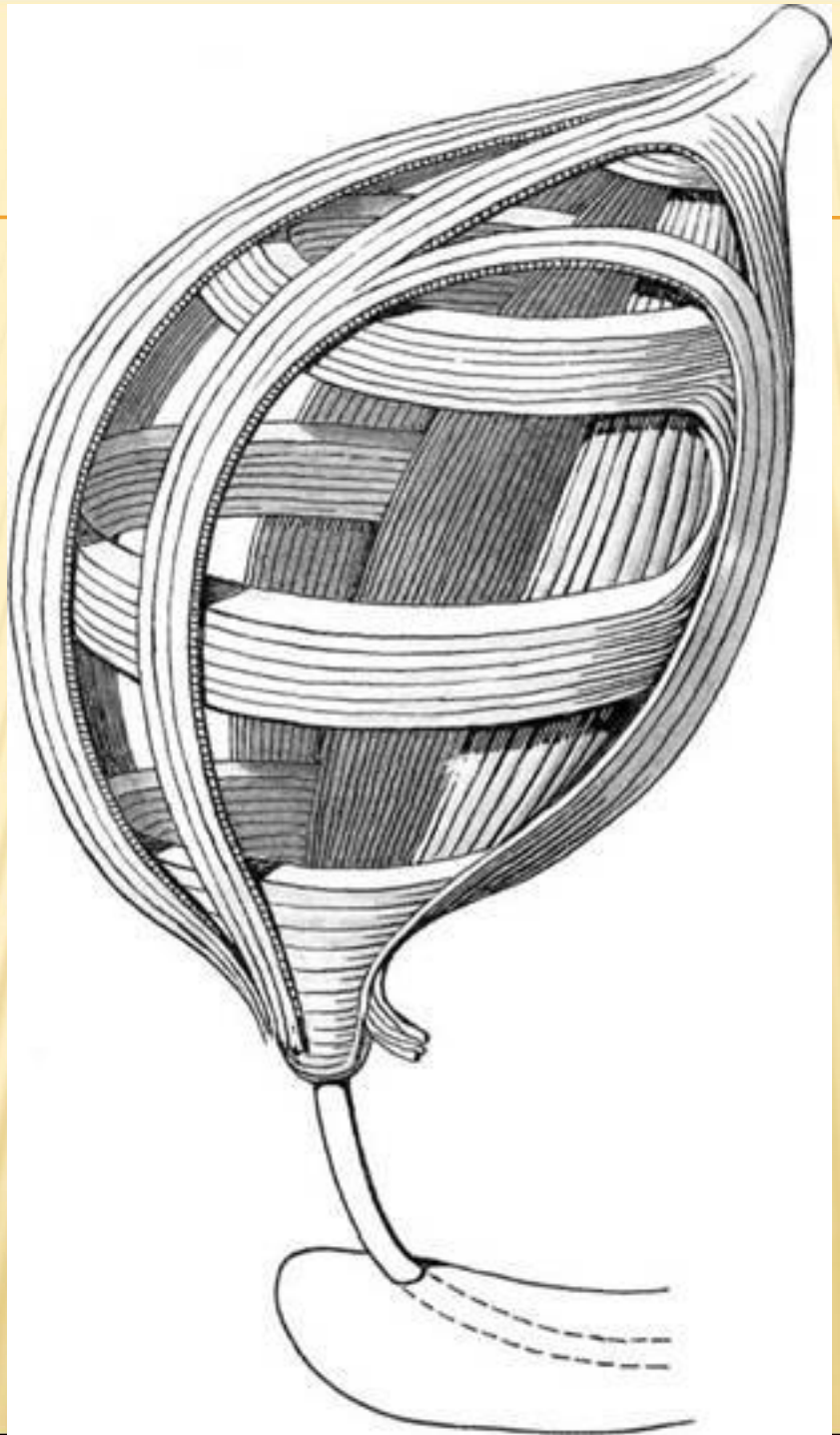

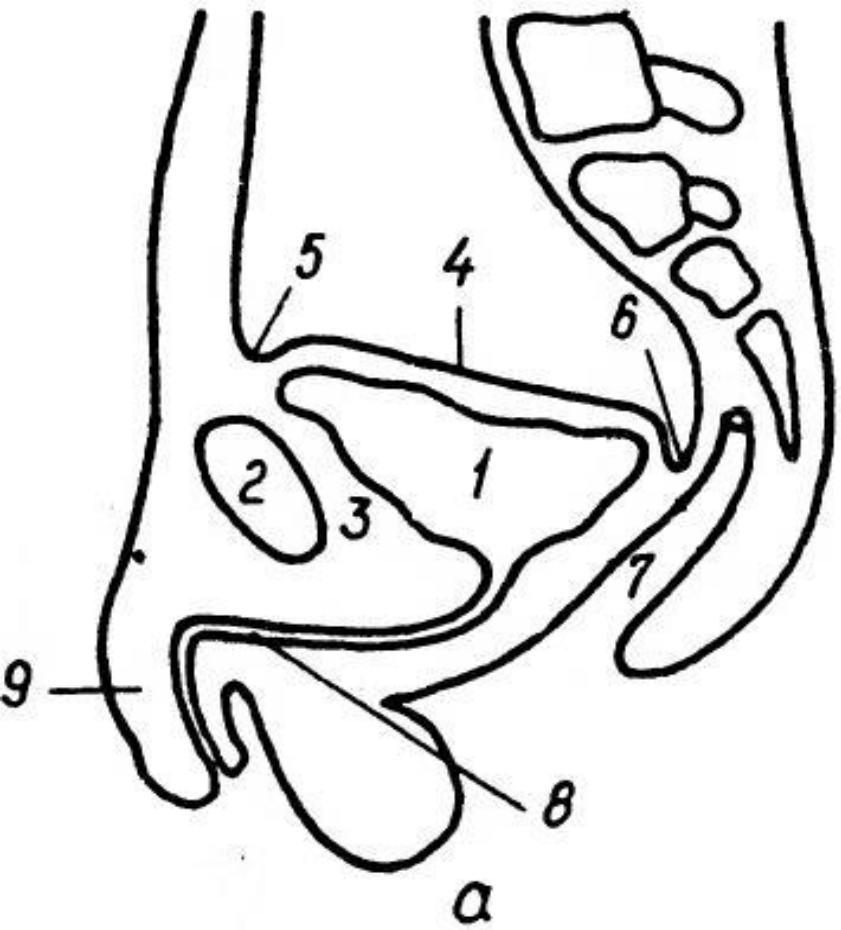
5
4
6
1
2
3
7
9
8
а

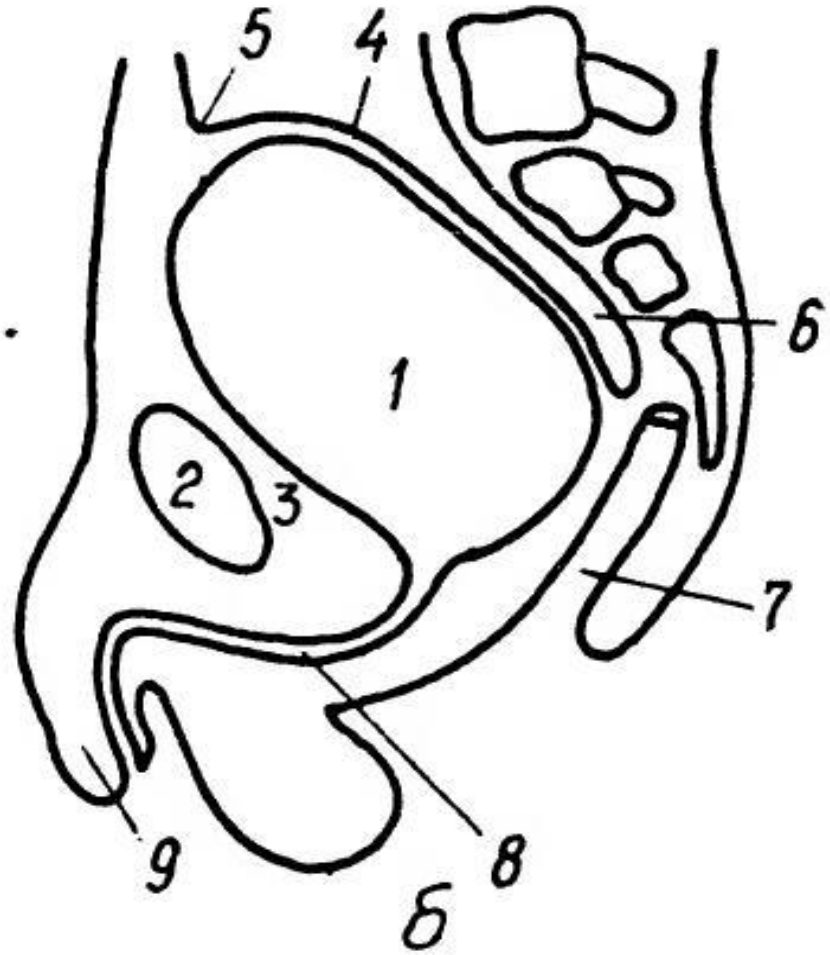
5
4
6
1
2
3
7
9
8
б

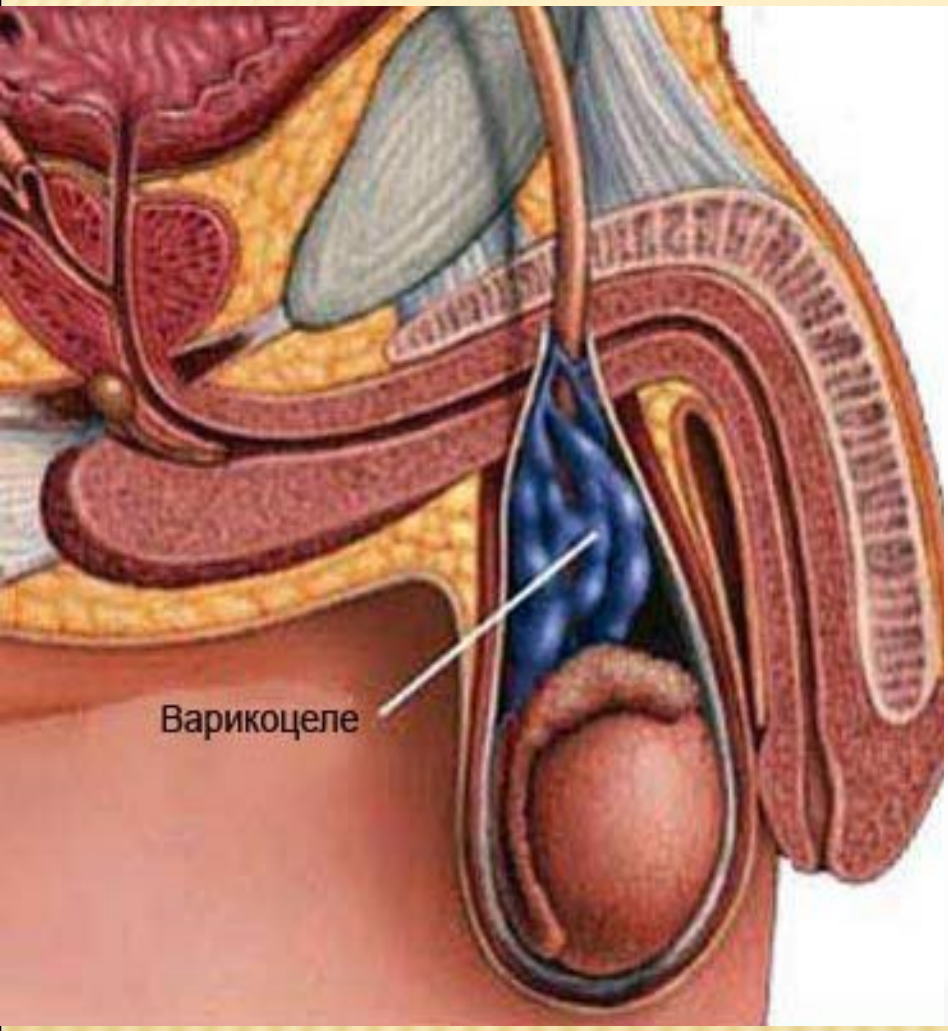
Варикоцеле

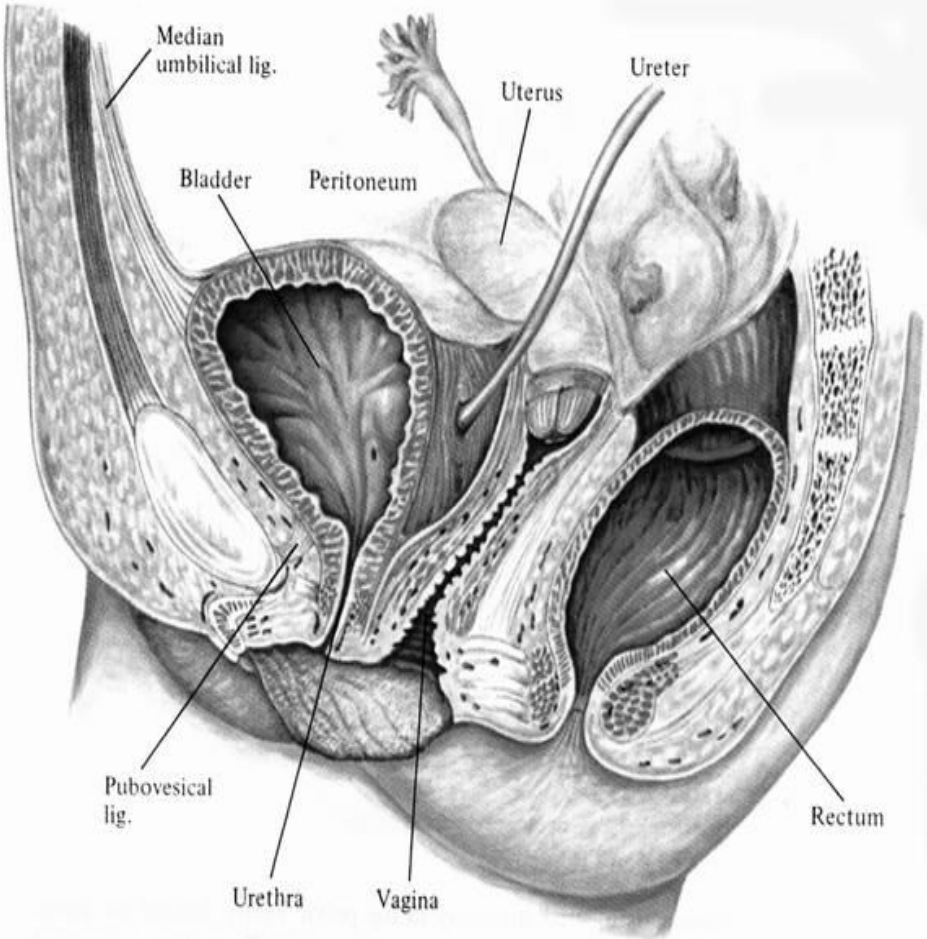
Median
umbilical lig.
Uterus
Ureter
Bladder
Peritoneum
Pubovesical
lig.
Urethra
Vagina
Rectum

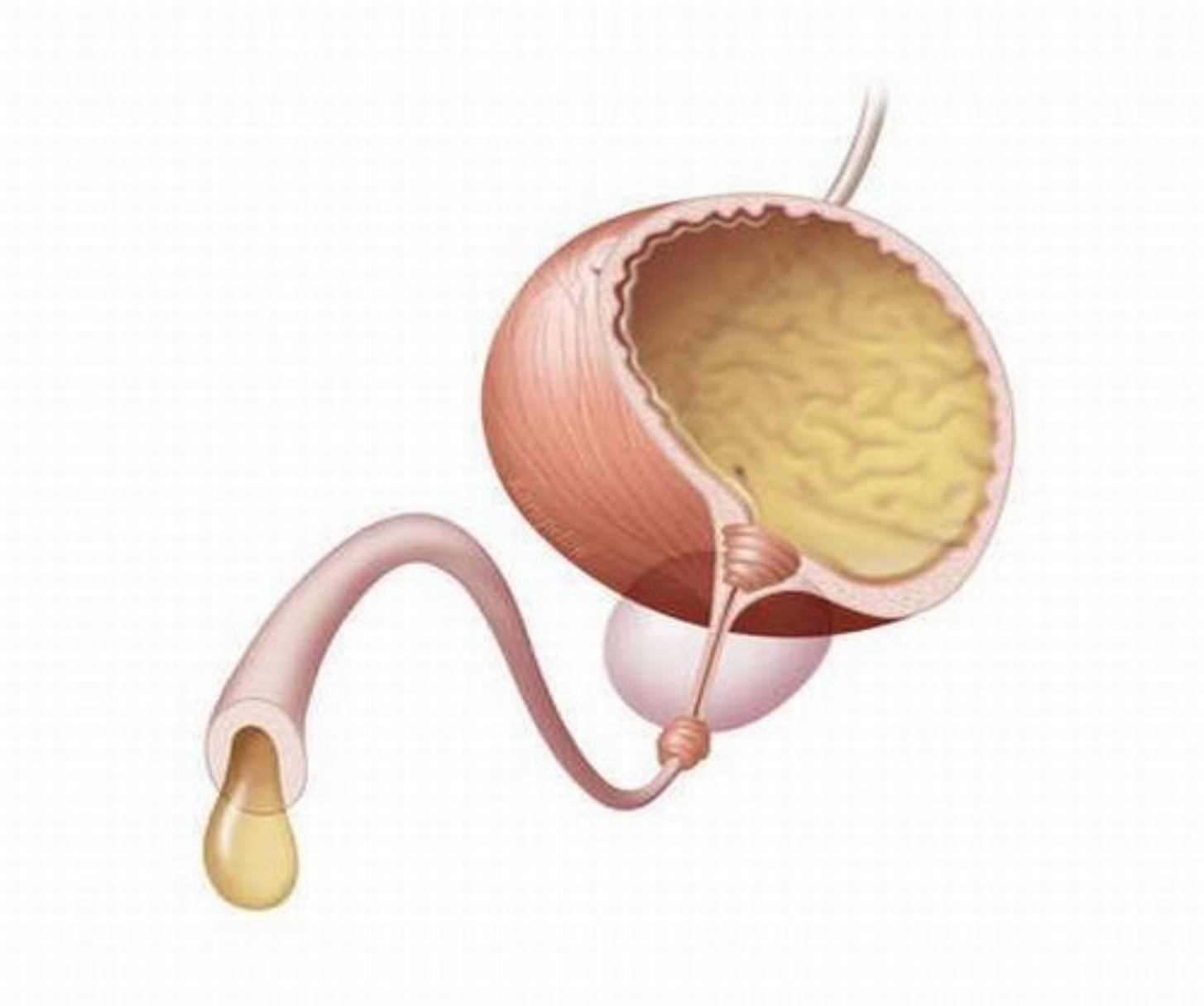

Bladder

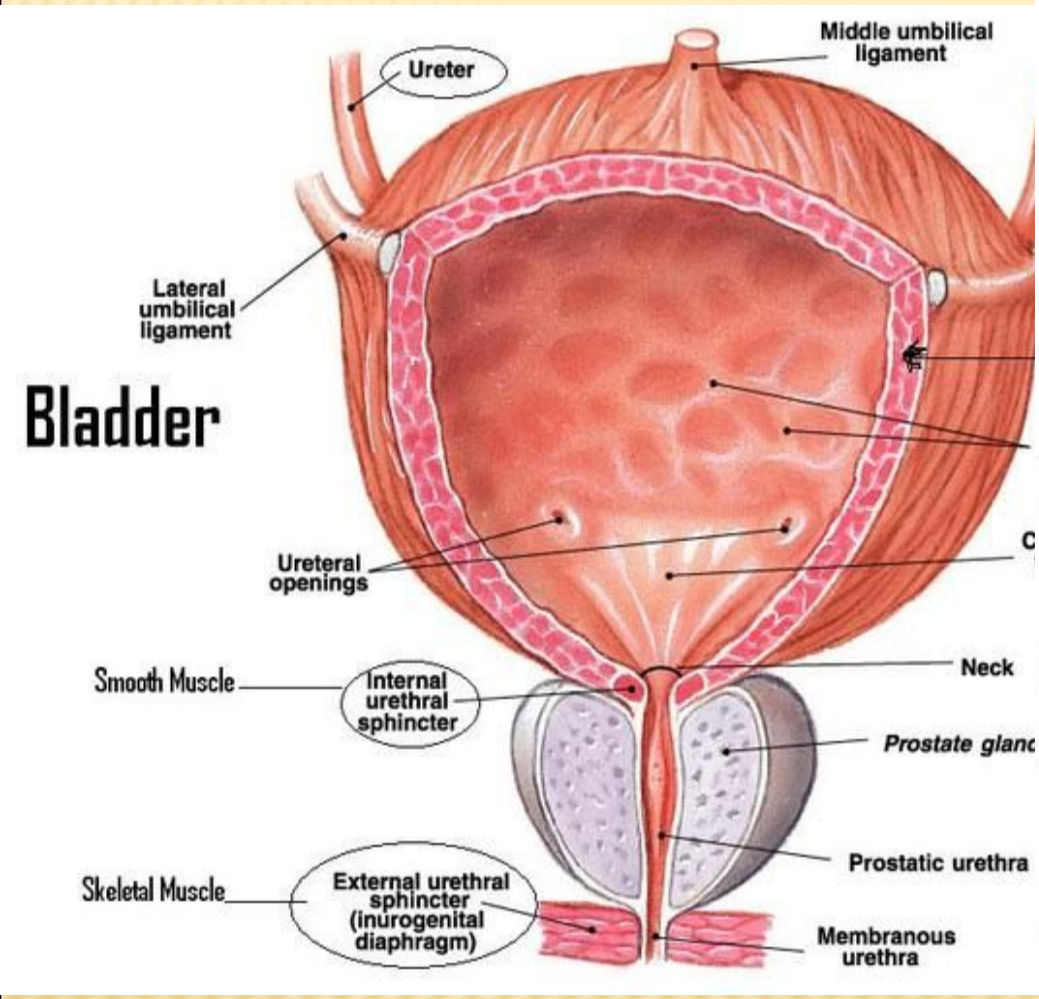
Ureter
Middle umbilical ligament
Lateral umbilical ligament
Ureteral openings
Smooth Muscle
Internal urethral sphincter
Neck
Prostate glanc
Prostatic urethra
Skeletal Muscle
External urethral sphincter (inurogenital diaphragm)
Membranous urethra

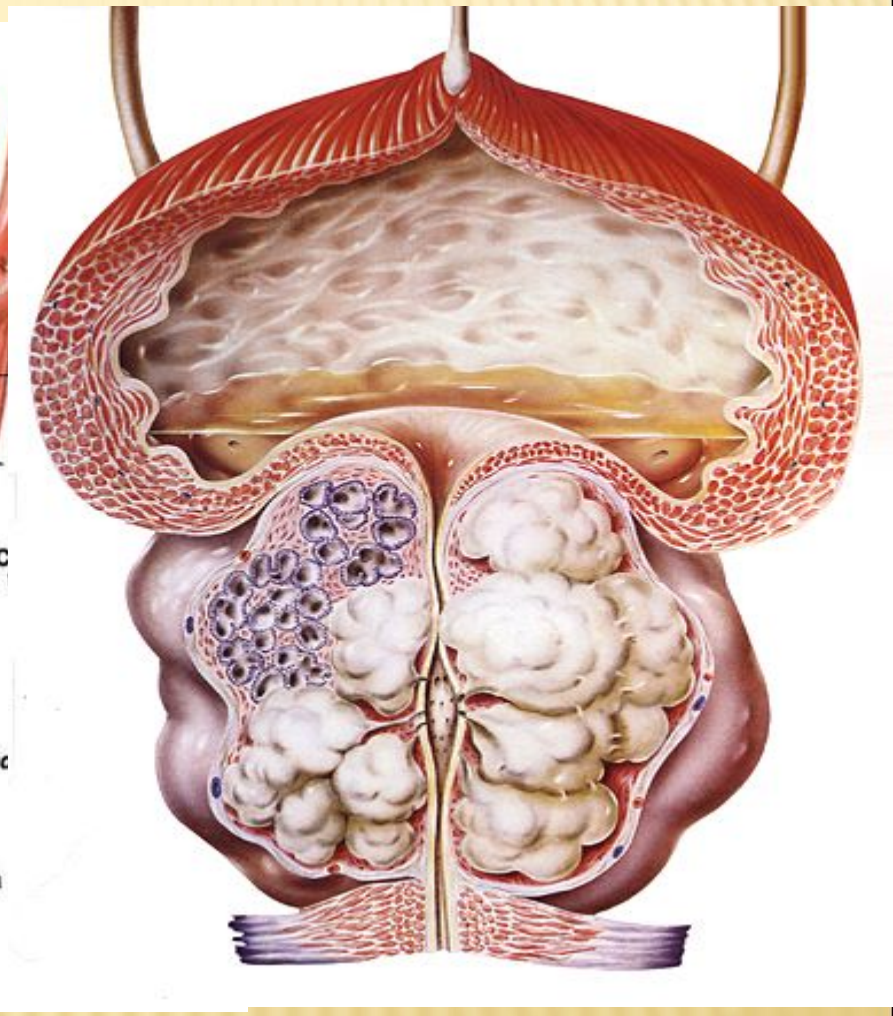

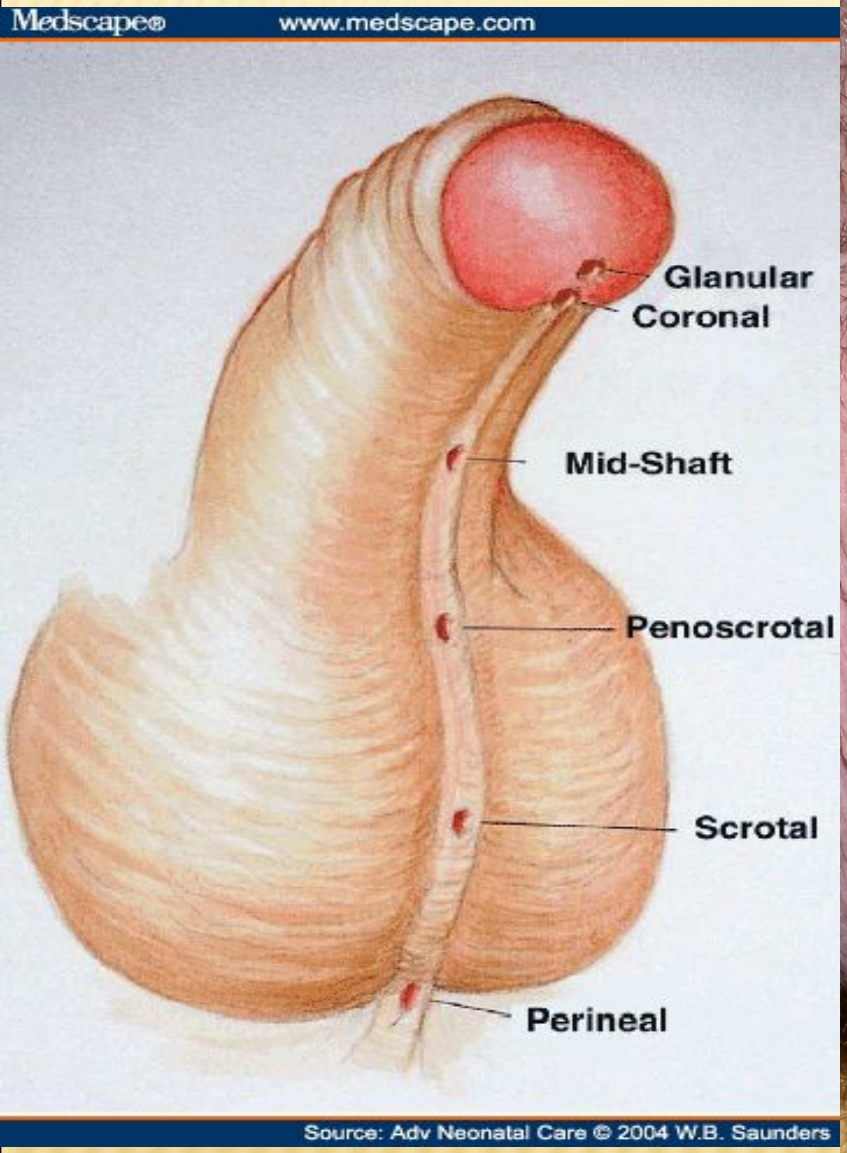
Medscape®
www.medscape.com
Glanular
Coronal
Mid-Shaft
Penoscrotal
Scrotal
Perineal
Source: Adv Neonatal Care © 2004 W.B. Saunders