Severity of Aortic Stenosis

	AVA (cm^2)	Mean (mm Hg)
Normal	3.0 - 4.0	
Mild	1.0 - 1.5	< 25
Moderate	0.8 - 1.0	25 - 50
Severe	≤ 0.75	≥ 50

* Gradient dependent on LV systolic function and CO

Dimensionless Severity Index

- LVOT diameter not measurable
- Dimensionless index $= \frac{TVI_{LVOT}}{TVI_{AV}}$
- Severity index < 0.25 indicates severe AS

Dimensionless Severity Index

- LVOT diameter not measurable
- Dimensionless index $= \frac{TVI_{LVOT}}{TVI_{AV}}$
- Severity index < 0.25 indicates severe AS

	Aortic Sclerosis	Mild	Moderate	Severe
Aortic Stenosis				
Aortic jet velocity (m/s)	<2.6 m/s	2.6–3.0	3–4	>4
Mean gradient (mm Hg)	—	<20 (30*)	20–40	>40 (50*)
AVA (cm^2)	—	>1.5	1.0–1.5	<1.0
Indexed AVA (cm^2/m^2)		>0.85	0.60–0.85	<0.6
Velocity ratio		>0.50	0.25–0.50	<0.25
		Mild	**Moderate**	**Severe**
Mitral Stenosis				
Mean gradient (mm Hg)		5	5–10	>10
MVA (cm^2)		>1.5	1.0–1.5	<1.0
Pulmonary systolic pressure (mm Hg)		<30	30–50	>50

AVA, aortic valve area; MVA, mitral valve area.
*ESC guidelines use higher mean gradient cutoffs as shown in parantheses.

CW Doppler Assessment of AR

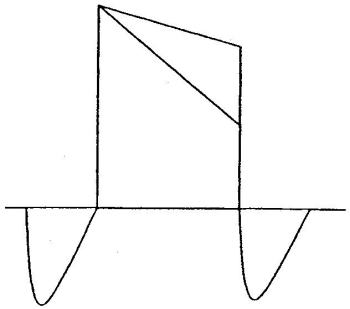

- Density of signal reflects RV
- Duration: holodiastolic
- Pressure half-time
  - Mild AR > 400 msec
  - Severe AR < 250 msec

AR Regurgitant Jet Area

- PSAX view of AR color flow jet immediately adjacent to aortic valve
- Regurgitant jet area/LVOT area ratio

Grade I	< 5%
Grade II	5 - 24%
Grade III	25 - 59%
Grade IV	≥ 60%

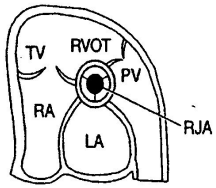

Adapted from: The Echo Manual - Second Edition

TABLE 12–7 Quantitative Evaluation of Aortic Regurgitant Severity (ASE Guidelines)

Parameter	Mild	Moderate	Severe
Jet width/LVOT (%)	<25	25–65	>65
Vena contracta (cm)	<0.3	0.3–0.6	>0.6
Pressure half-time (ms)	>500	200–500	<200
Regurgitant volume (mL/beat)	<30	30–60	>60
Regurgitant fraction (%)	<30	30–50	>50
Regurgitant orifice area (cm^2)	<0.10	0.1–0.3	>0.30

ASE, American Society of Echocardiography; LVOT, left ventricular outflow tract.

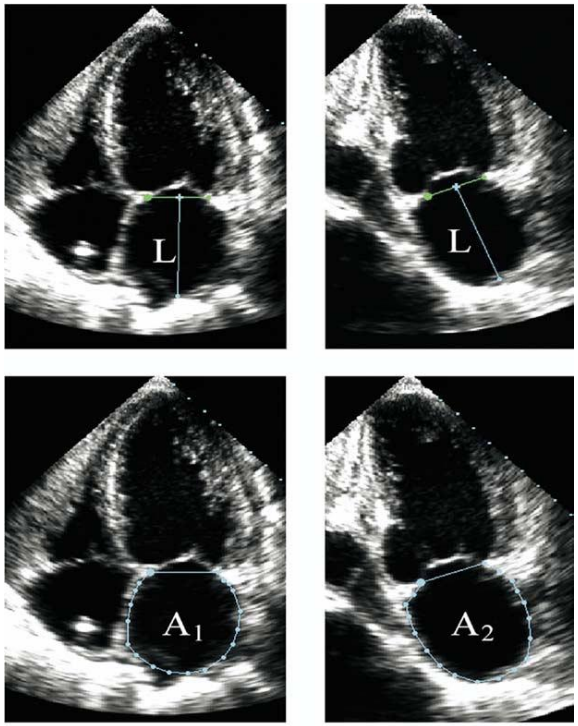

A4C **A2C**

Left Atrial Volume =

$$8/3\pi[(A_1)(A_2)/(L)]\ *$$

* (L) is the shortest of either the A4C or A2C length

Table 4 Qualitative and quantitative parameters useful in grading aortic regurgitation severity

	Mild	Moderate		Severe
Structural parameters				
LA size	Normal*	Normal or dilated		Usually dilated**
Aortic leaflets	Normal or abnormal	Normal or abnormal		Abnormal/flail, or wide coaptation defect
Doppler parameters				
Jet width in LVOT –Color Flow[ζ]	Small in central jets	Intermediate		Large in central jets; variable in eccentric jets
Jet density–CW	Incomplete or faint	Dense		Dense
Jet deceleration rate –CW (PHT, ms)[ψ]	Slow > 500	Medium 500-200		Steep < 200
Diastolic flow reversal in descending aorta –PW	Brief, early diastolic reversal	Intermediate		Prominent holodiastolic reversal
Quantitative parameters[φ]				
VC width, cm[ζ]	< 0.3	0.3-0.60		> 0.6
Jet width/LVOT width, %[ζ]	< 25	25-45	46-64	≥ 65
Jet CSA/LVOT CSA, %[ζ]	< 5	5-20	21-59	≥ 60
R Vol, ml/beat	< 30	30-44	45-59	≥ 60
RF, %	< 30	30-39	40-49	≥ 50
EROA, cm^2	< 0.10	0.10-0.19	0.20-0.29	≥ 0.30

AR, Aortic regurgitation; *CSA*, cross sectinal area; *CW*, continuous wave Doppler; *EROA*, effective regurgitant orifice area; *LV*, left ventricle; *LVOT*, left ventricular outflow tract; *PHT*, pressure half-time; *PW*, pulsed wave Doppler; *R Vol*, regurgitant volume; *RF*, regurgitant fraction; *VC*, vena contracta.

* Unless there are other reasons for LV dilation. Normal 2D measurements: LV minor axis ≤ 2.8 cm/m^2, LV end-diastolic volume ≤ 82 ml/m^2 (2).

** Exception: would be acute AR, in which chambers have not had time to dilate.

ζ At a Nyquist limit of 50–60 cm/s.

ψ PHT is shortened with increasing LV diastolic pressure and vasodilator therapy, and may be lengthened in chronic adaptation to severe AR

φ Quantitative parameters can sub-classify the moderate regurgitation group into mild-to-moderate and moderate-to-severe regurgitation as shown.

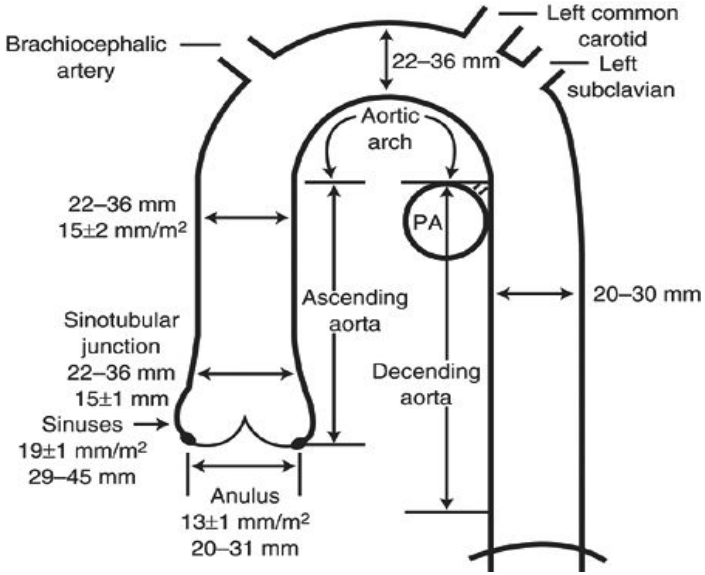

Dimensionless Severity Index

- LVOT diameter not measurable
- Dimensionless index = $\frac{TVI_{LVOT}}{TVI_{AV}}$
- Severity index < 0.25 indicates severe AS

Table 4 Qualitative and quantitative parameters useful in grading aortic regurgitation severity

	Mild	Moderate		Severe
Structural parameters				
LA size	Normal*	Normal or dilated		Usually dilated**
Aortic leaflets	Normal or abnormal	Normal or abnormal		Abnormal/flail, or wide coaptation defect
Doppler parameters				
Jet width in LVOT –Color Flow[ζ]	Small in central jets	Intermediate		Large in central jets; variable in eccentric jets
Jet density–CW	Incomplete or faint	Dense		Dense
Jet deceleration rate –CW (PHT, ms)[ψ]	Slow > 500	Medium 500-200		Steep < 200
Diastolic flow reversal in descending aorta –PW	Brief, early diastolic reversal	Intermediate		Prominent holodiastolic reversal
Quantitative parameters[φ]				
VC width, cm[ζ]	< 0.3	0.3-0.60		> 0.6
Jet width/LVOT width, %[ζ]	< 25	25-45	46-64	≥ 65
Jet CSA/LVOT CSA, %[ζ]	< 5	5-20	21-59	≥ 60
R Vol, ml/beat	< 30	30-44	45-59	≥ 60
RF, %	< 30	30-39	40-49	≥ 50
EROA, cm^2	< 0.10	0.10-0.19	0.20-0.29	≥ 0.30

AR, Aortic regurgitation; *CSA*, cross sectinal area; *CW*, continuous wave Doppler; *EROA*, effective regurgitant orifice area; *LV*, left ventricle; *LVOT*, left ventricular outflow tract; *PHT*, pressure half-time; *PW*, pulsed wave Doppler; *R Vol*, regurgitant volume; *RF*, regurgitant fraction; *VC*, vena contracta.

* Unless there are other reasons for LV dilation. Normal 2D measurements: LV minor axis ≤ 2.8 cm/m^2, LV end-diastolic volume ≤ 82 ml/m^2 (2).

** Exception: would be acute AR, in which chambers have not had time to dilate.

[ζ] At a Nyquist limit of 50–60 cm/s.

[ψ] PHT is shortened with increasing LV diastolic pressure and vasodilator therapy, and may be lengthened in chronic adaptation to severe AR

[φ] Quantitative parameters can sub-classify the moderate regurgitation group into mild-to-moderate and moderate-to-severe regurgitation as shown.

Severity of Aortic Stenosis

	AVA (cm^2)	Mean (mm Hg)
Normal	3.0 - 4.0	
Mild	1.0 - 1.5	< 25
Moderate	0.8 - 1.0	25 - 50
Severe	≤ 0.75	≥ 50

* Gradient dependent on LV systolic function and CO

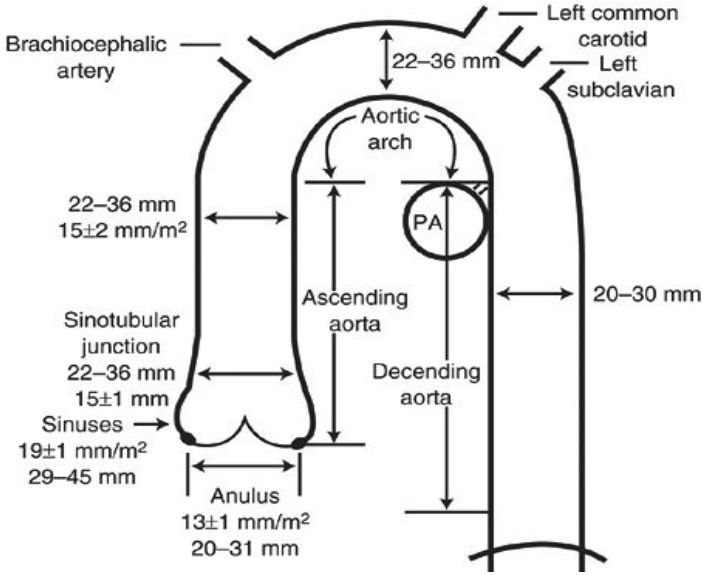

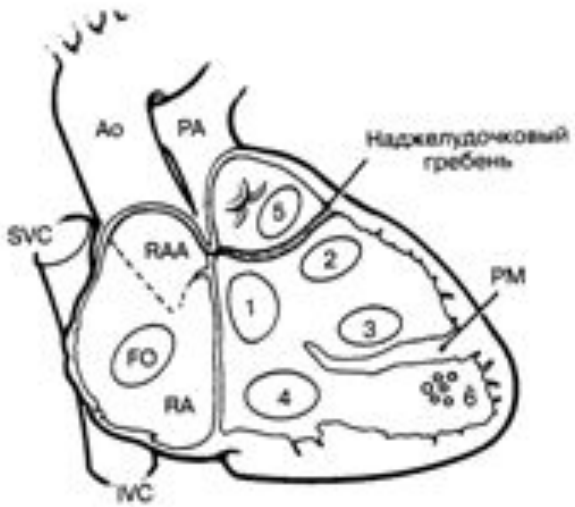

Рис. 7.63. Схема поверхности межжелудочковой перегородки со стороны правого желудочка. На схеме представлены наиболее часто встречающиеся положения дефектов перегородки. PA – легочная артерия; Ao – аорта; RA – правое предсердие; SVC – верхняя полая вена; IVC – нижняя полая вена; RAA – ушко правого предсердия; FO – овальное отверстие; PM – папиллярная мышца; отделы перегородки: 1 – мембранозная межжелудочковая перегородка; 2 – межжелудочковая перегородка области оттока; 3 – трабекулярная перегородка; 4 – перегородка области притока; 5 – субартериальный отдел; 6 – дистальные множественные септальные дефекты типа «швейцарского сыра».

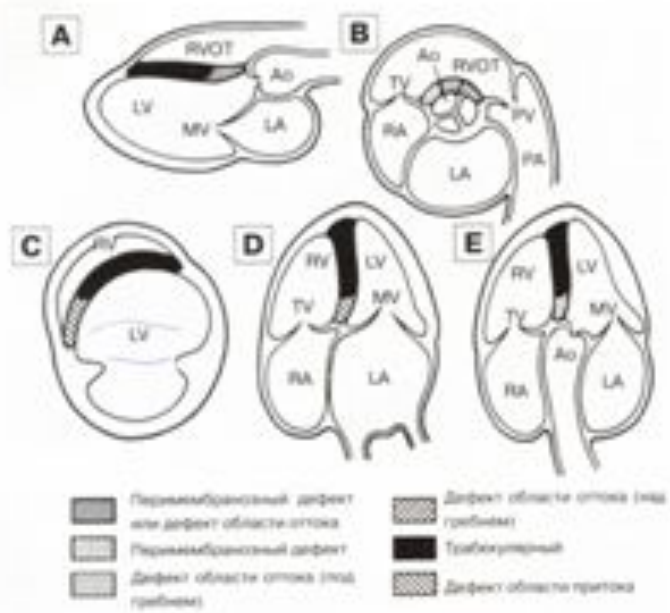

Рис. 7.64. Схема локализации различных типов дефектов межжелудочковой перегородки по данным двухмерной эхокардиографии. Подробности см. в тексте. Ao – аорта; LA – левое предсердие; LV – левый желудочек; RA – правое предсердие; RV – правый желудочек; RVOT – выносящий тракт правого желудочка; MV – митральный клапан; TV – трикуспидальный клапан; PV – легочный клапан.

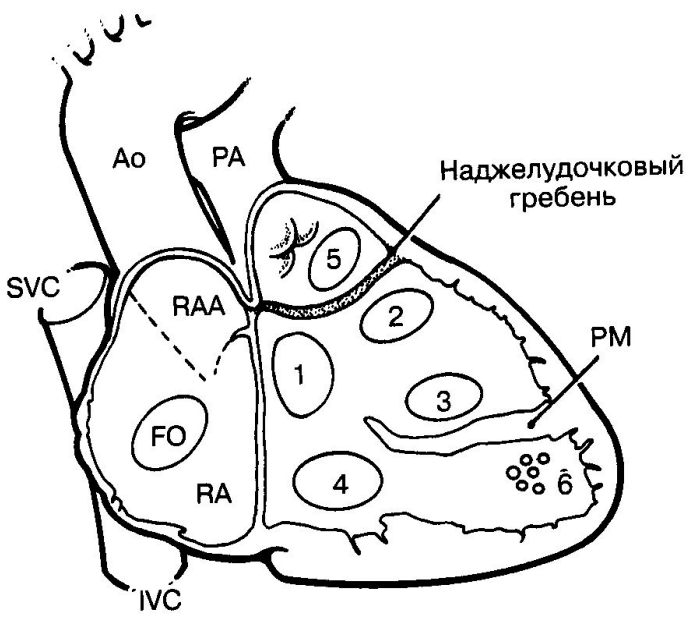

Рис. 7.63. Схема поверхности межжелудочковой перегородки с стороны правого желудочка. На схеме представлены наиболе часто встречающиеся положения дефектов перегородки. PA – ле гочная артерия; Ao – аорта; RA – правое предсердие; SVC – вер няя полая вена; IVC – нижняя полая вена; RAA – ушко правог предсердия; FO – овальное отверстие; PM – папиллярная мыш ца; отделы перегородки: 1 – мембранозная межжелудочковая пе регородка; 2 – межжелудочковая перегородка области оттока; 3 трабекулярная перегородка; 4 – перегородка области приток 5 – субартериальный отдел; 6 – дистальные множественные сеп тальные дефекты типа «швейцарского сыра».

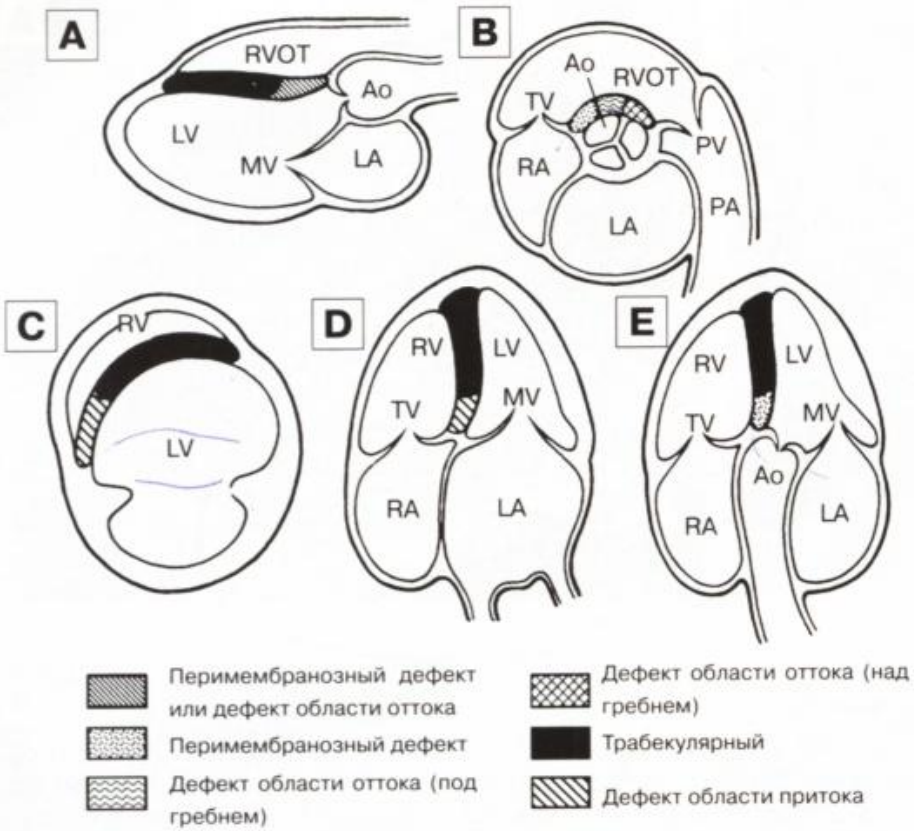

Рис. 7.64. Схема локализации различных типов дефектов межжелудочковой перегородки по данным двухмерной эхокардиографии. Подробности см. в тексте. Ao – аорта; LA – левое предсердие; LV – левый желудочек; RA – правое предсердие; RV – правый желудочек; RVOT – выносящий тракт правого желудочка; MV – митральный клапан; TV – трикуспидальный клапан; PV – легочный клапан.

Патология правых отделов:
Систолическая функция
TAPSE (экскурсия фиброзного кольца) <1.6 см
Pulsed Doppler-peak velocity at the annulus (скорость движения трикуспидального кольца) <10 см/с (11,5)
Pulsed Doppler MPI (функциональный индекс)>0.40 Tissue Doppler MPI >0.55
dP/dT<400 мм.рт.ст/с
FAC (фракция изменения площади) <35%
Диастолическая функция
E/A ratio — <0.8 or>2.1
E/E' ratio — >6
Deceleration time <120 мс