ДЫХАТЕЛЬНАЯ СИСТЕМА

HO
C

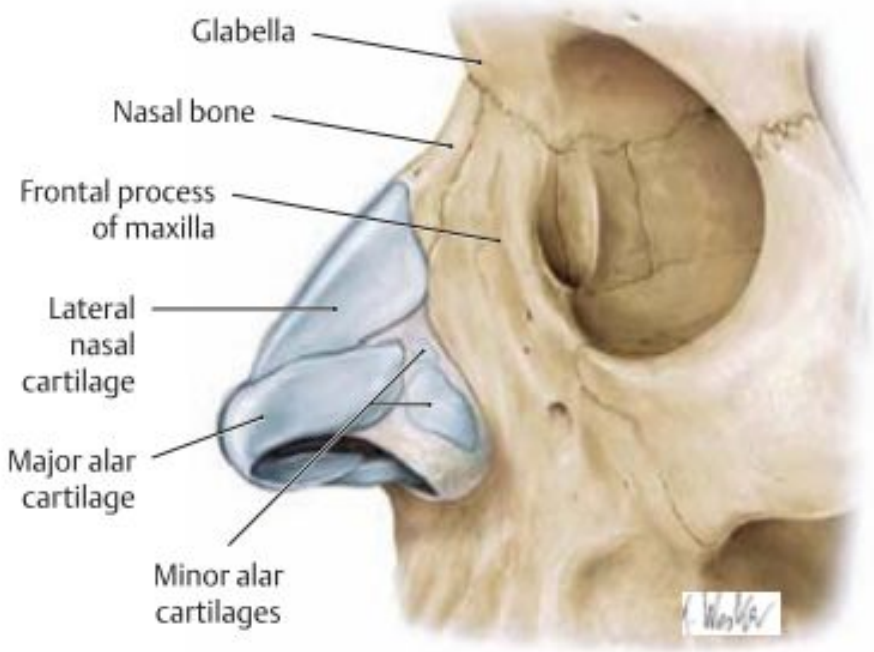
Glabella
Nasal bone
Frontal process of maxilla
Lateral nasal cartilage
Major alar cartilage
Minor alar cartilages

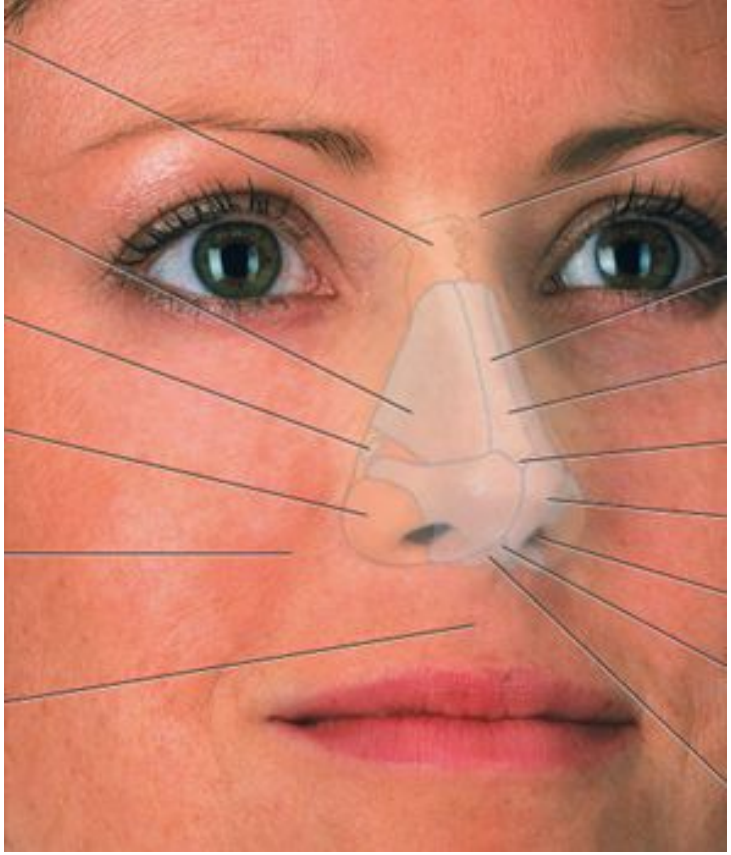

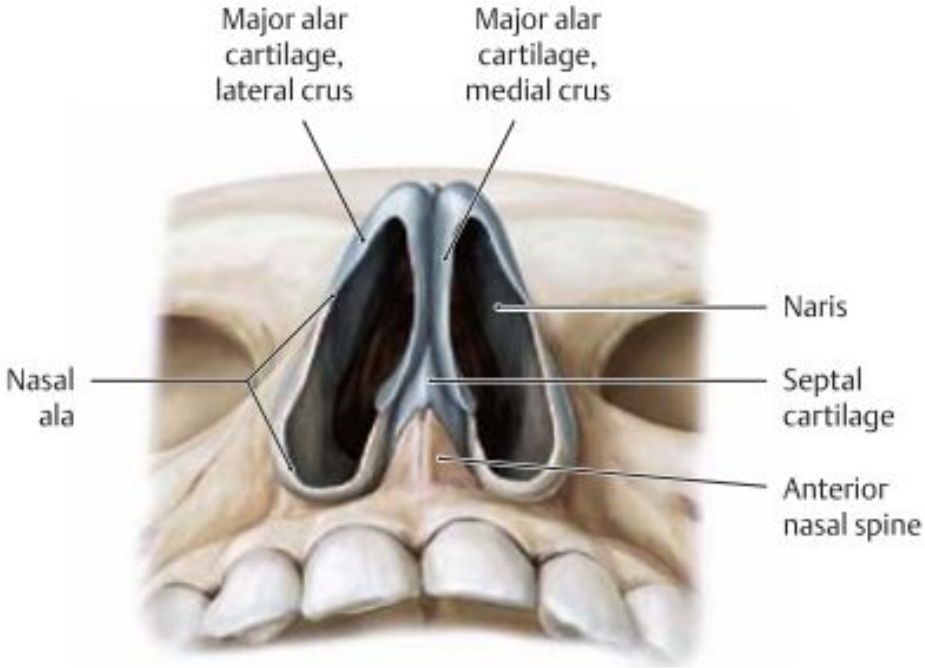
Major alar cartilage, lateral crus
Major alar cartilage, medial crus
Naris
Nasal ala
Septal cartilage
Anterior nasal spine

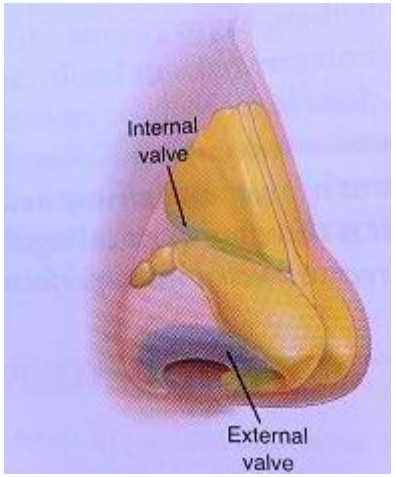
Internal valve
External valve

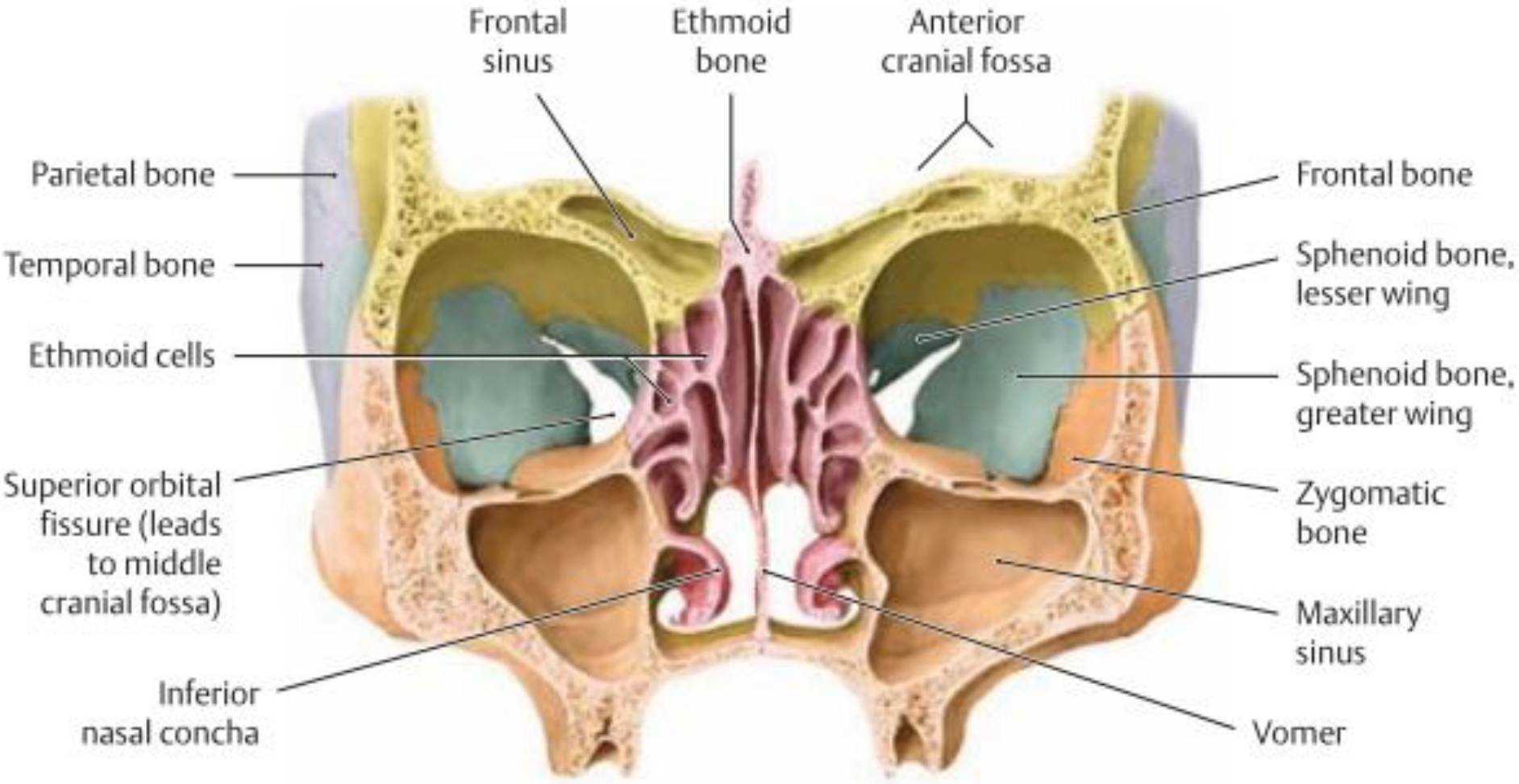
Frontal sinus
Ethmoid bone
Anterior cranial fossa
Parietal bone
Temporal bone
Ethmoid cells
Superior orbital fissure (leads to middle cranial fossa)
Inferior nasal concha
Frontal bone
Sphenoid bone, lesser wing
Sphenoid bone, greater wing
Zygomatic bone
Maxillary sinus
Vomer

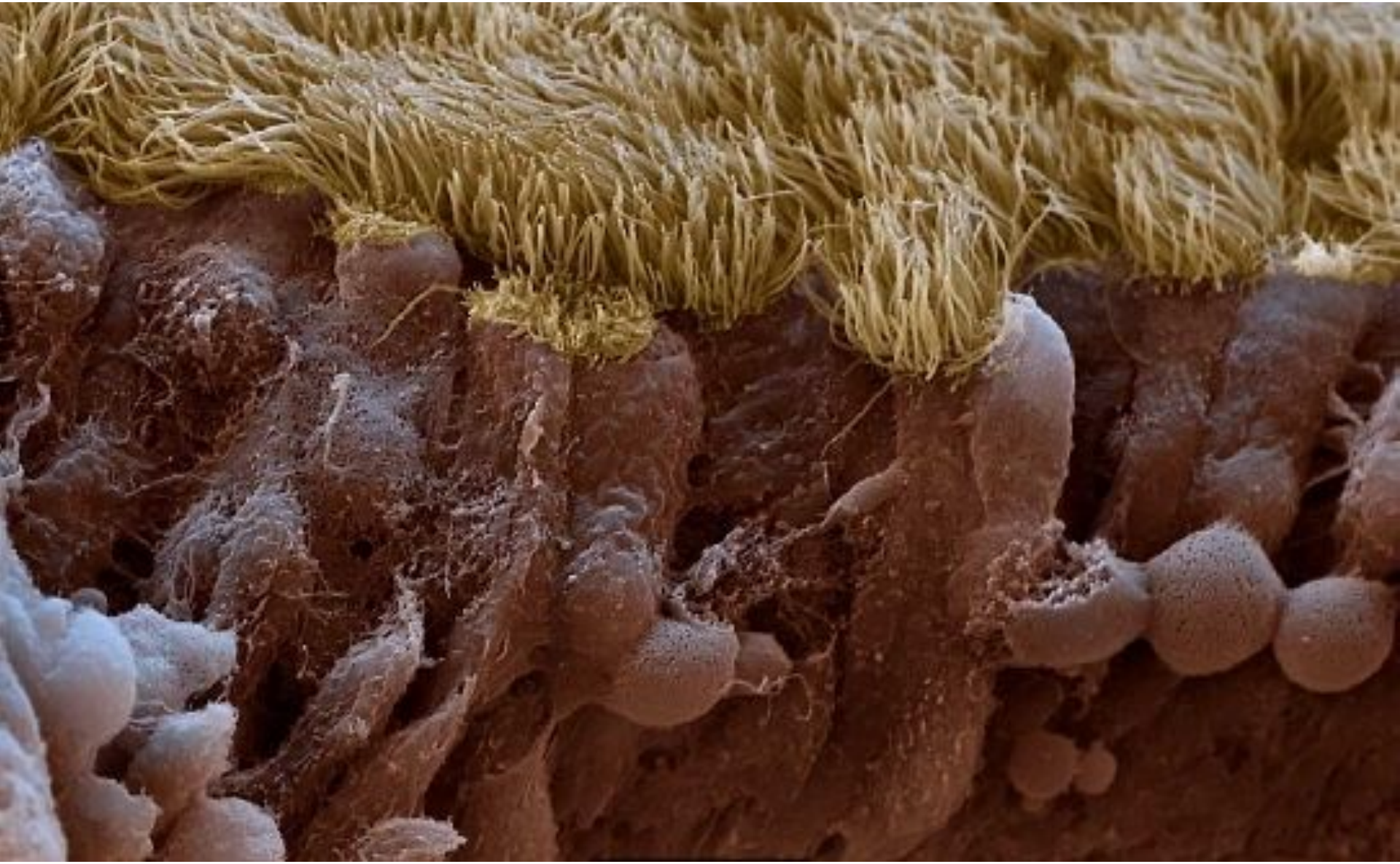

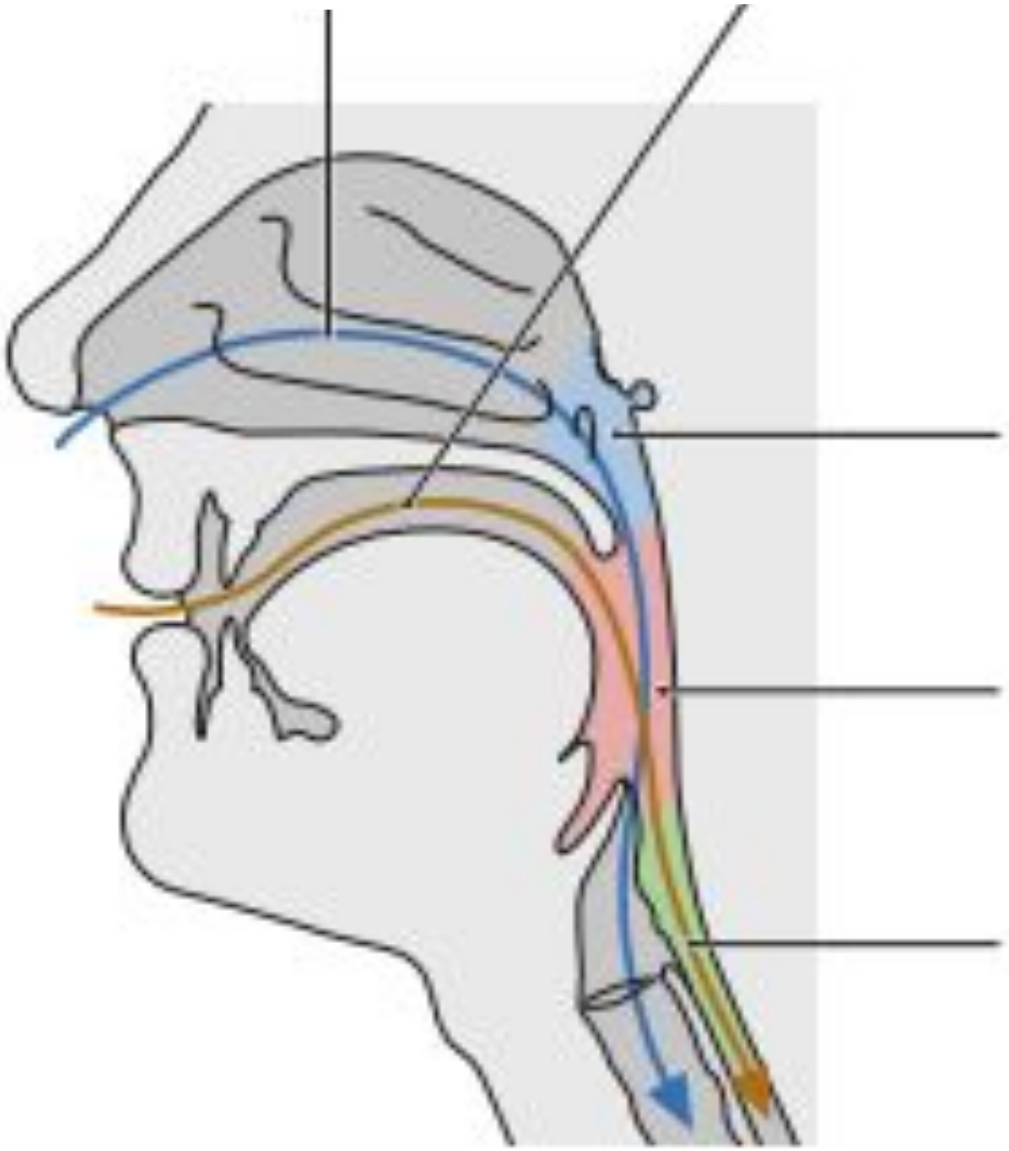
ДЫХАТЕЛЬНЫЕ ПУТИ
ПИЩЕВАРИТЕЛЬНЫЙ ТРАКТ
НОСОГЛОТКА
РОТОГЛОТКА
ГОРТАНОГЛОТКА

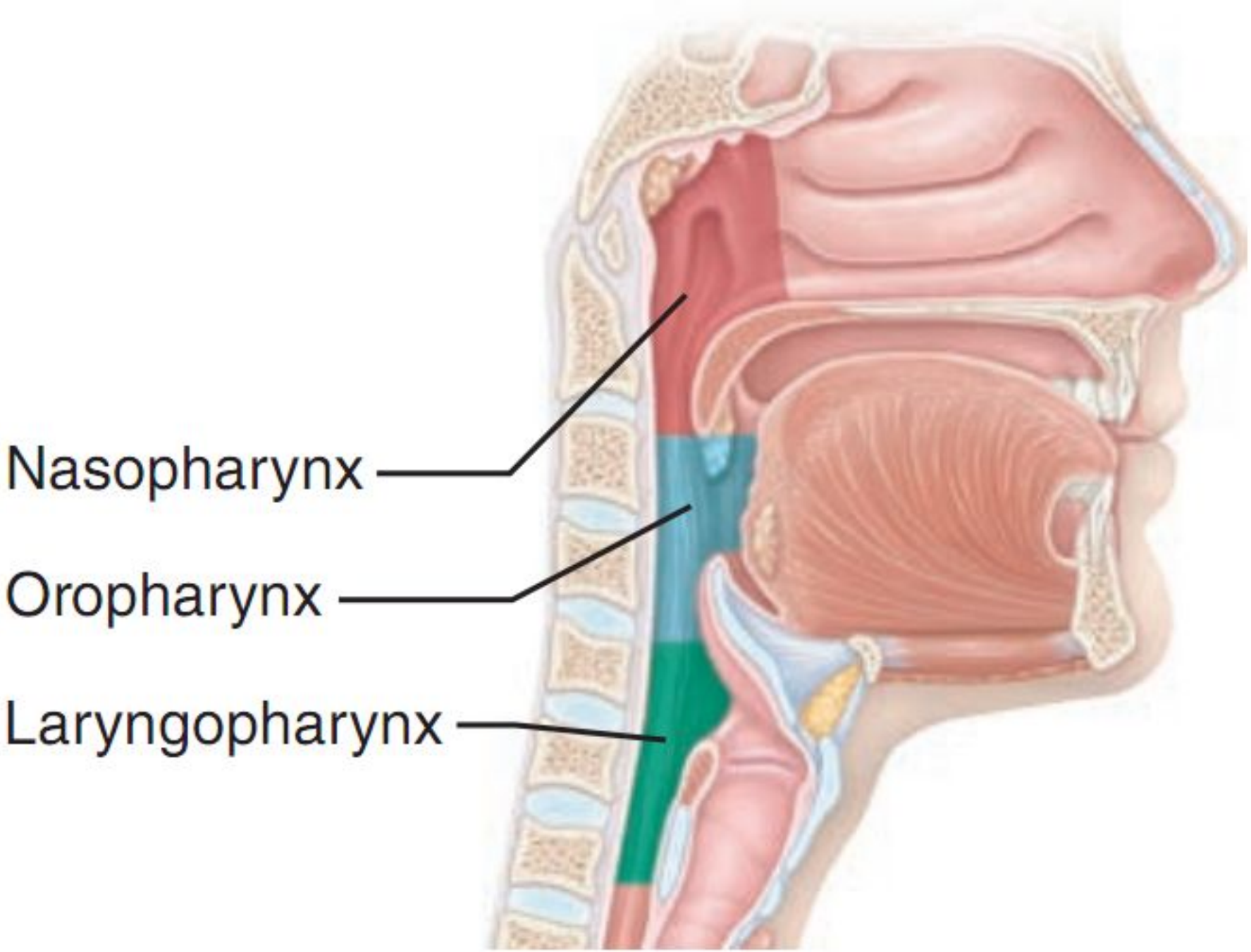
Nasopharynx
Oropharynx
Laryngopharynx

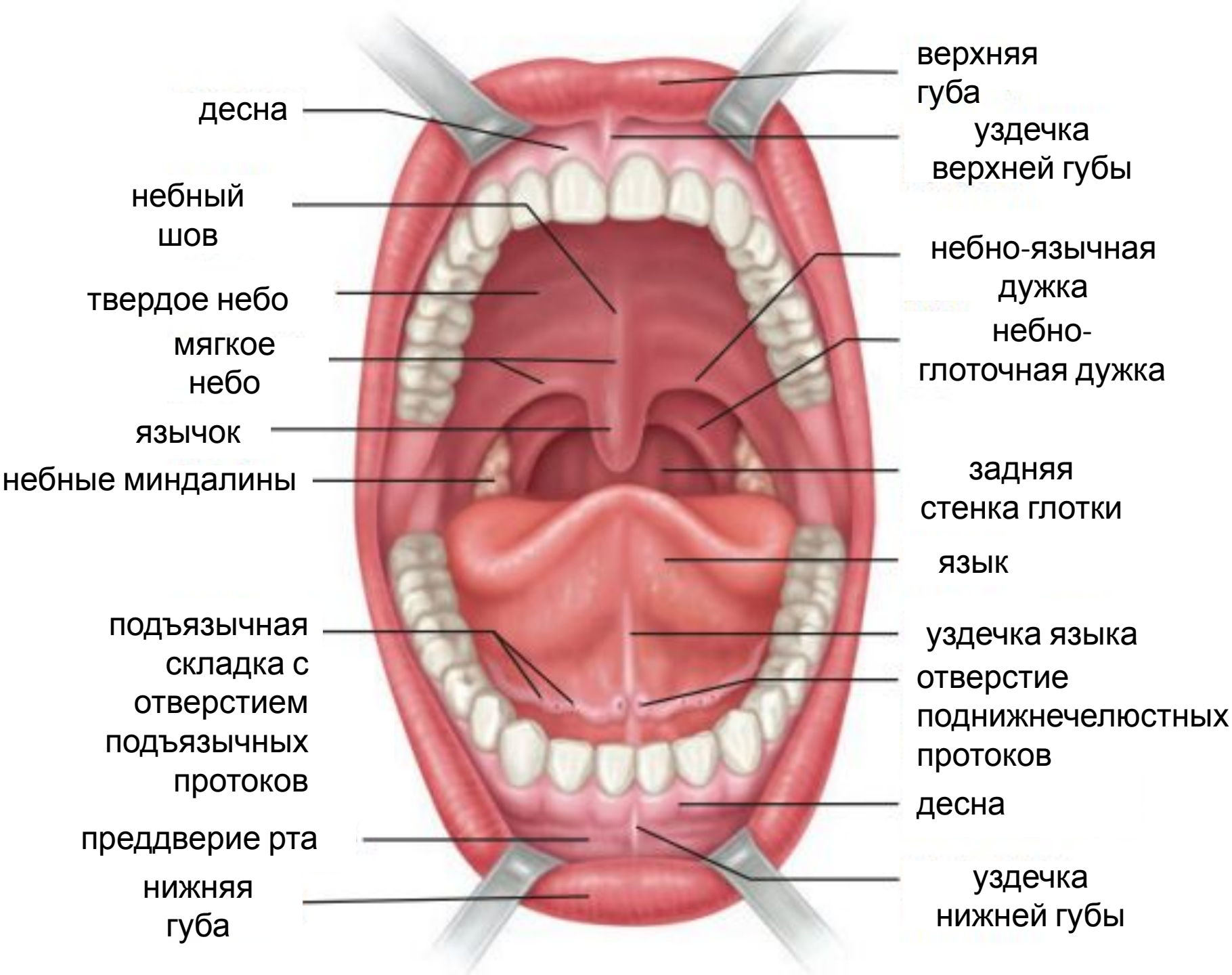
десна
небный шов
твердое небо
мягкое небо
язычок
небные миндалины
подъязычная складка с отверстием подъязычных протоков
преддверие рта
нижняя губа
верхняя губа
уздечка верхней губы
небно-язычная дужка
небно-глоточная дужка
задняя стенка глотки
язык
уздечка языка
отверстие поднижнечелюстных протоков
десна
уздечка нижней губы

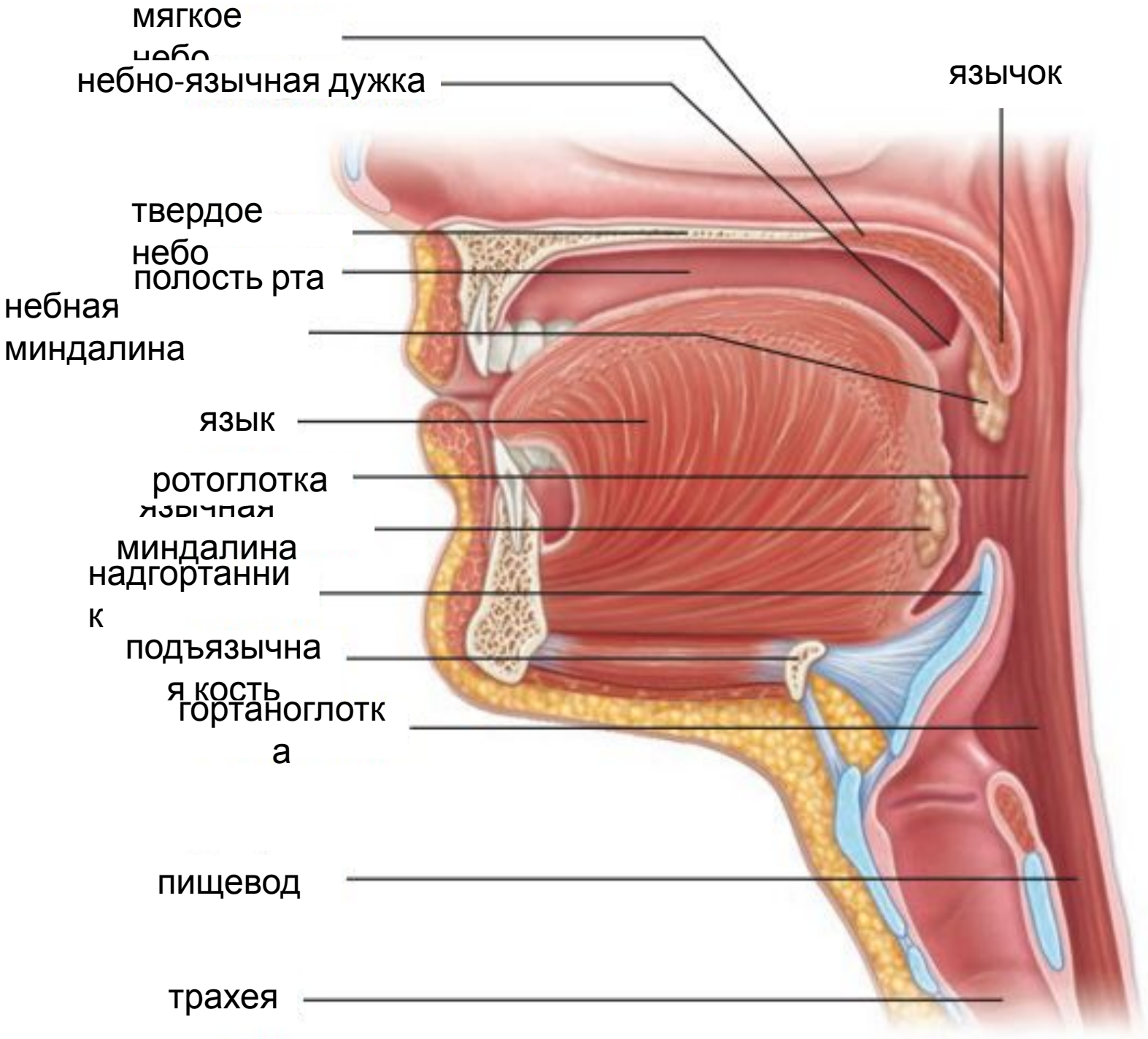
мягкое небо
небно-язычная дужка
язычок
твердое небо
полость рта
небная миндалина
язык
ротоглотка
язычная миндалина
надгортанник
подъязычная кость
гортаноглотка
пищевод
трахея

Хрящи гортани

Соединяются друг с другом, а также с подъязычной костью при помощи суставов и связок

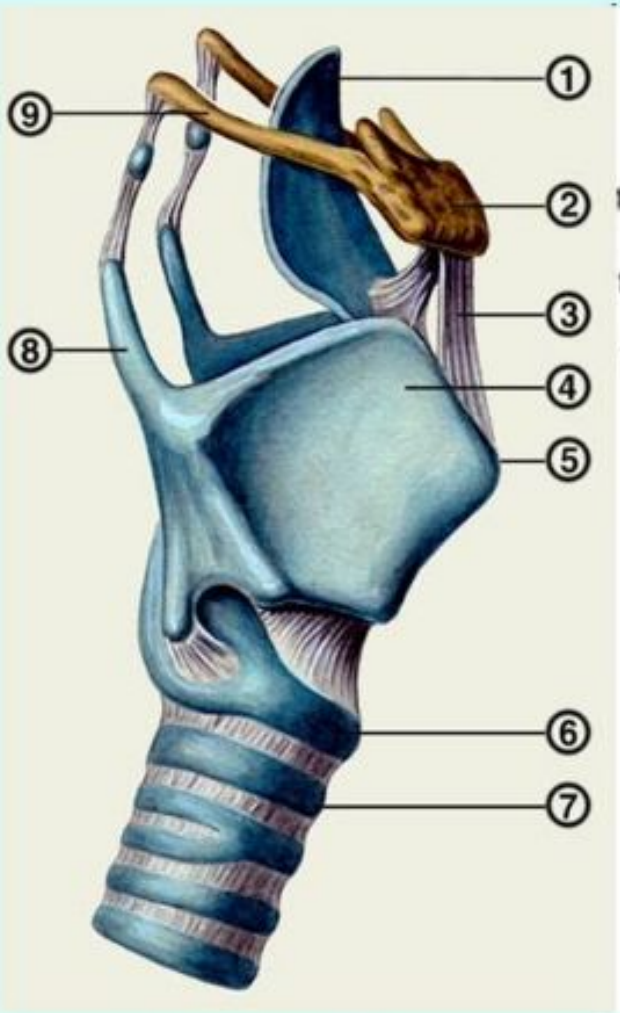

Вид сбоку

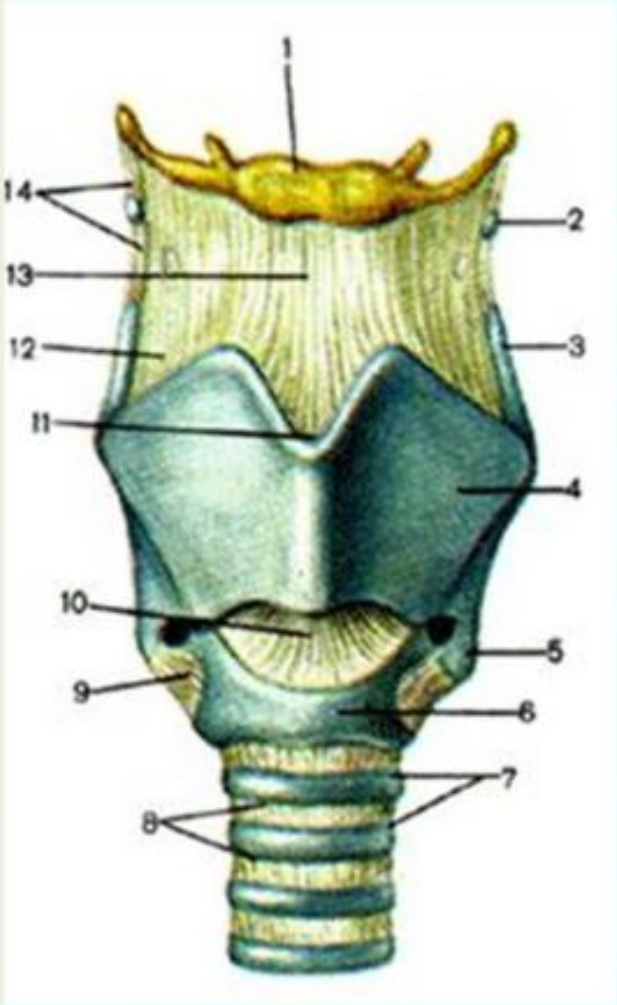

Вид спереди

- ***непарные (3):***

- щитовидный: гиалиновый
- перстневидный: гиалиновый
- надгортанник: эластический

- ***парные (3):***

- черпаловидный: гиалиновый
- рожковидный: гиалиновый
- клиновидный: эластический

2 сустава:

- ***перстнещитовидный:*** вокруг фронтальной оси
- ***перстнечерпаловидный:*** вокруг вертикальной оси

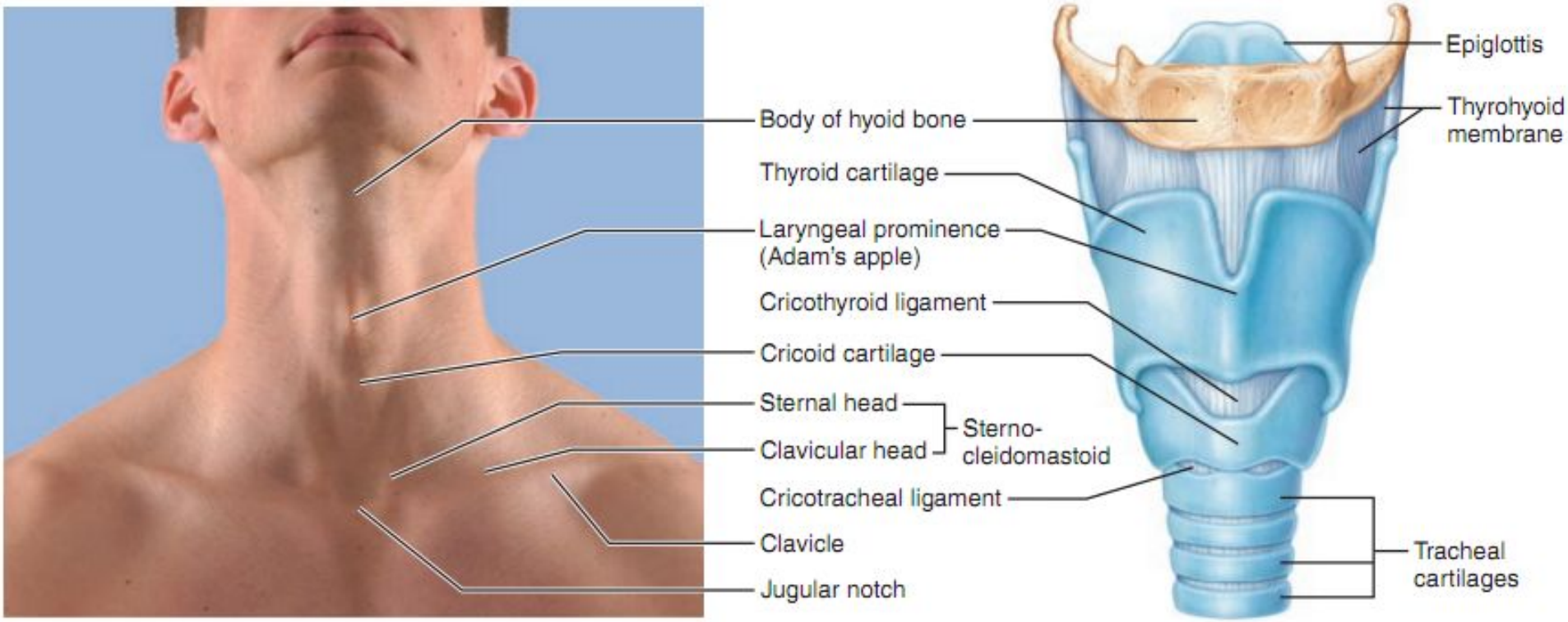
Body of hyoid bone
Thyroid cartilage
Laryngeal prominence
(Adam's apple)
Cricothyroid ligament
Cricoid cartilage
Sternal head
Clavicular head
Sterno-
cleidomastoid
Cricotracheal ligament
Clavicle
Jugular notch
Epiglottis
Thyrohyoid
membrane
Tracheal
cartilages

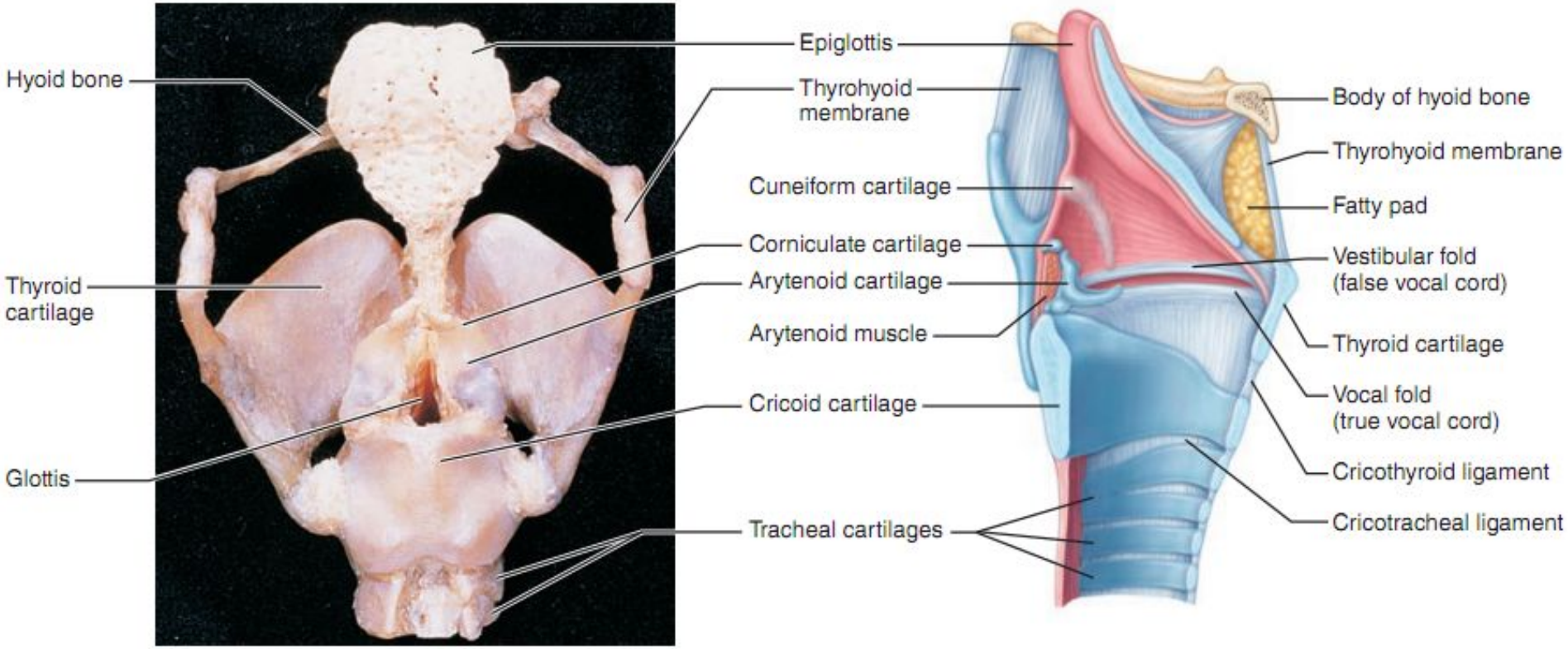
Hyoid bone
Thyroid cartilage
Glottis
Epiglottis
Thyrohyoid membrane
Cuneiform cartilage
Corniculate cartilage
Arytenoid cartilage
Arytenoid muscle
Cricoid cartilage
Tracheal cartilages
Body of hyoid bone
Thyrohyoid membrane
Fatty pad
Vestibular fold (false vocal cord)
Thyroid cartilage
Vocal fold (true vocal cord)
Cricothyroid ligament
Cricotracheal ligament

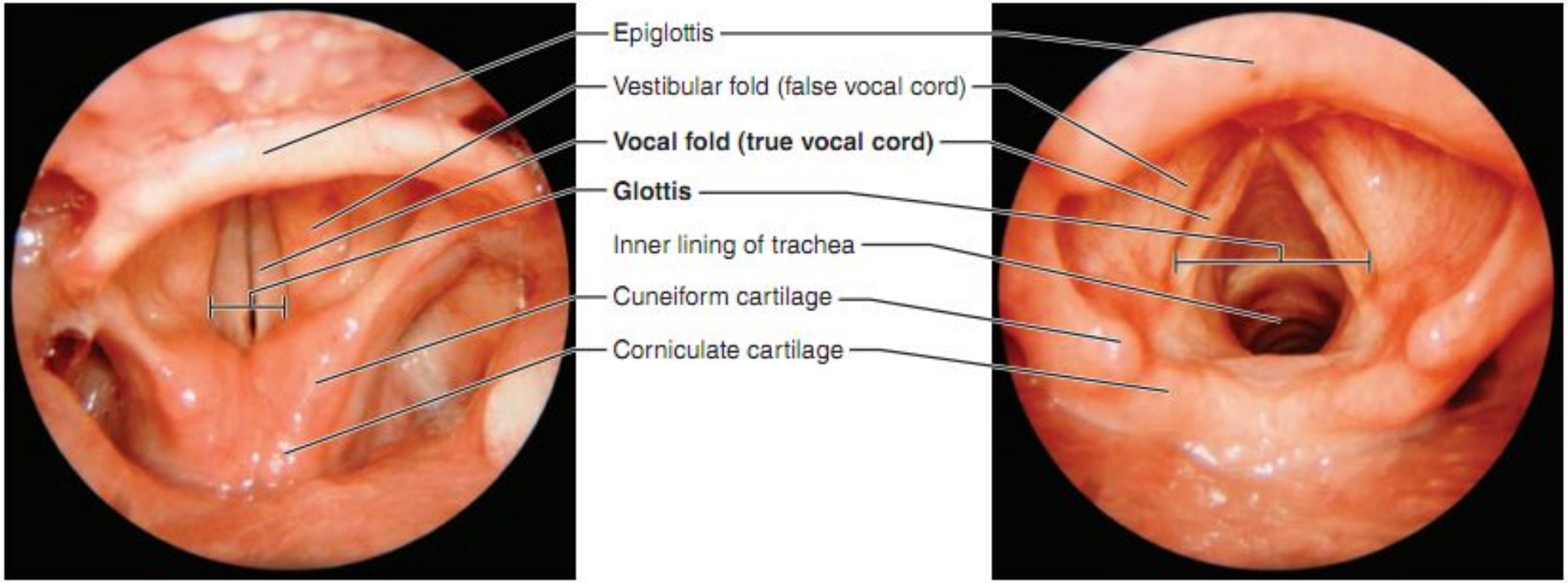
Epiglottis
Vestibular fold (false vocal cord)
Vocal fold (true vocal cord)
Glottis
Inner lining of trachea
Cuneiform cartilage
Corniculate cartilage

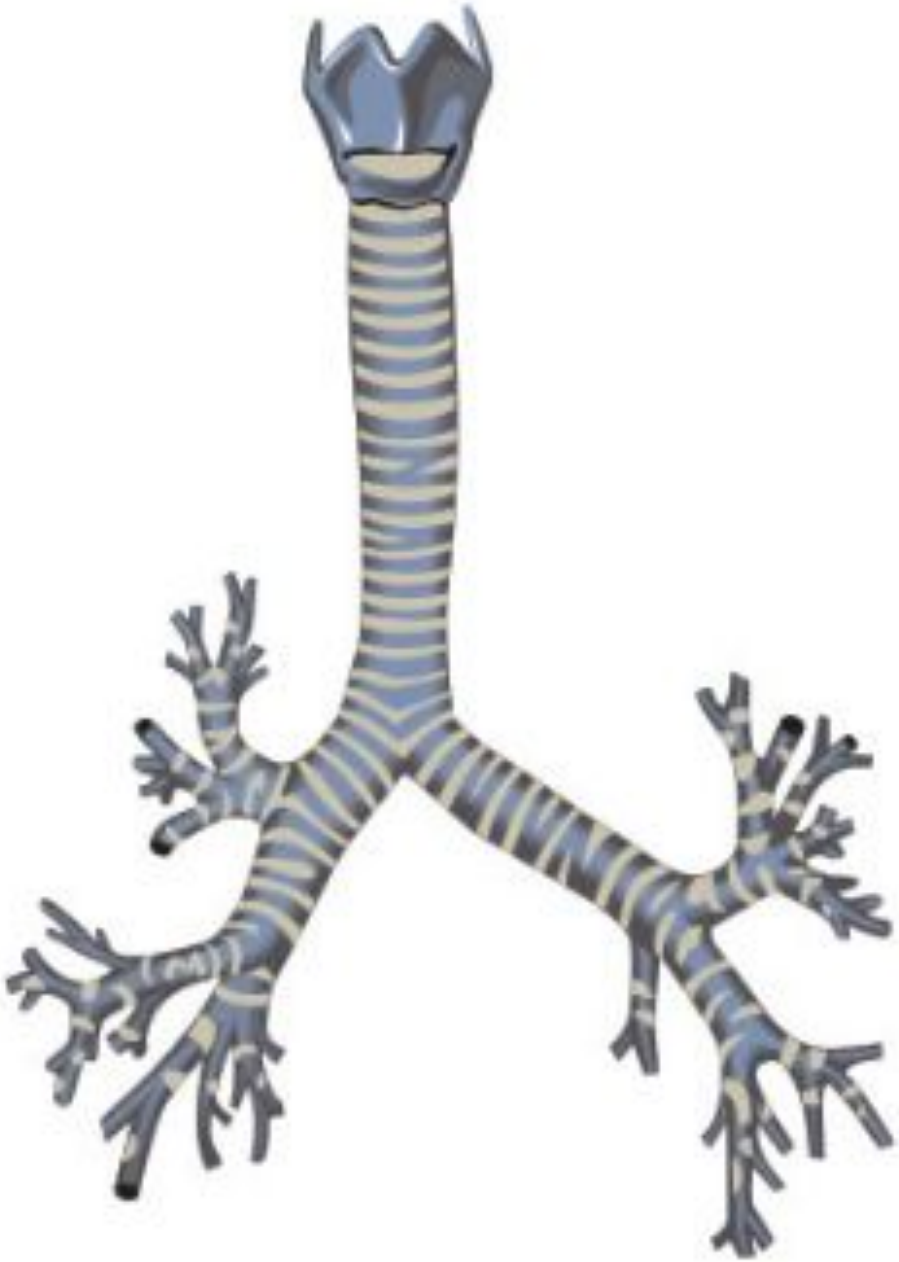

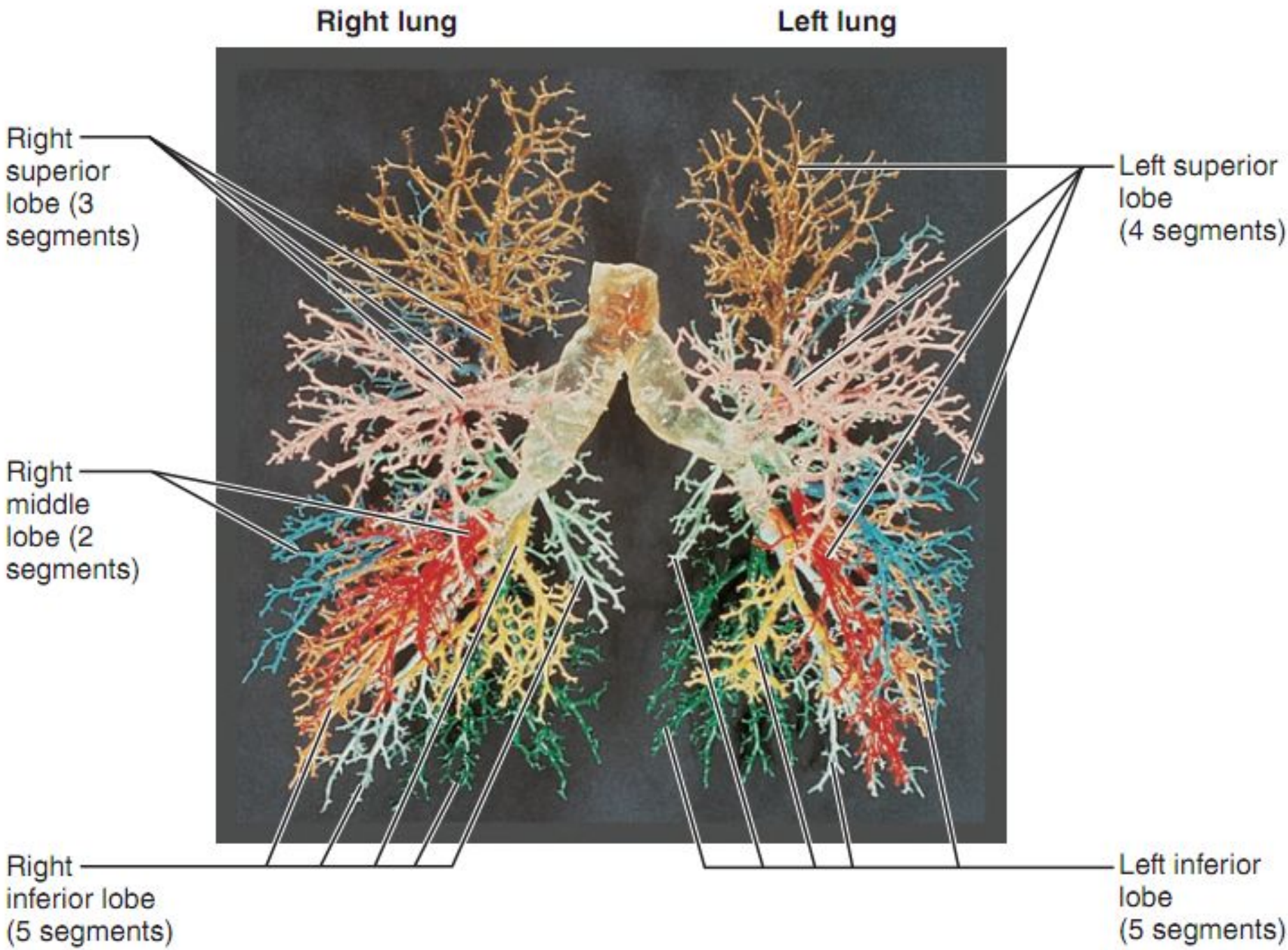
Right lung
Left lung
Right superior lobe (3 segments)
Left superior lobe (4 segments)
Right middle lobe (2 segments)
Right inferior lobe (5 segments)
Left inferior lobe (5 segments)

Posterior

Goblet cell

Mucosa

- Pseudostratified ciliated columnar epithelium
- Lamina propria (connective tissue)

Esophagus

Trachealis

Submucosa

Seromucous gland in submucosa

Lumen of trachea

Hyaline cartilage

Adventitia

Anterior

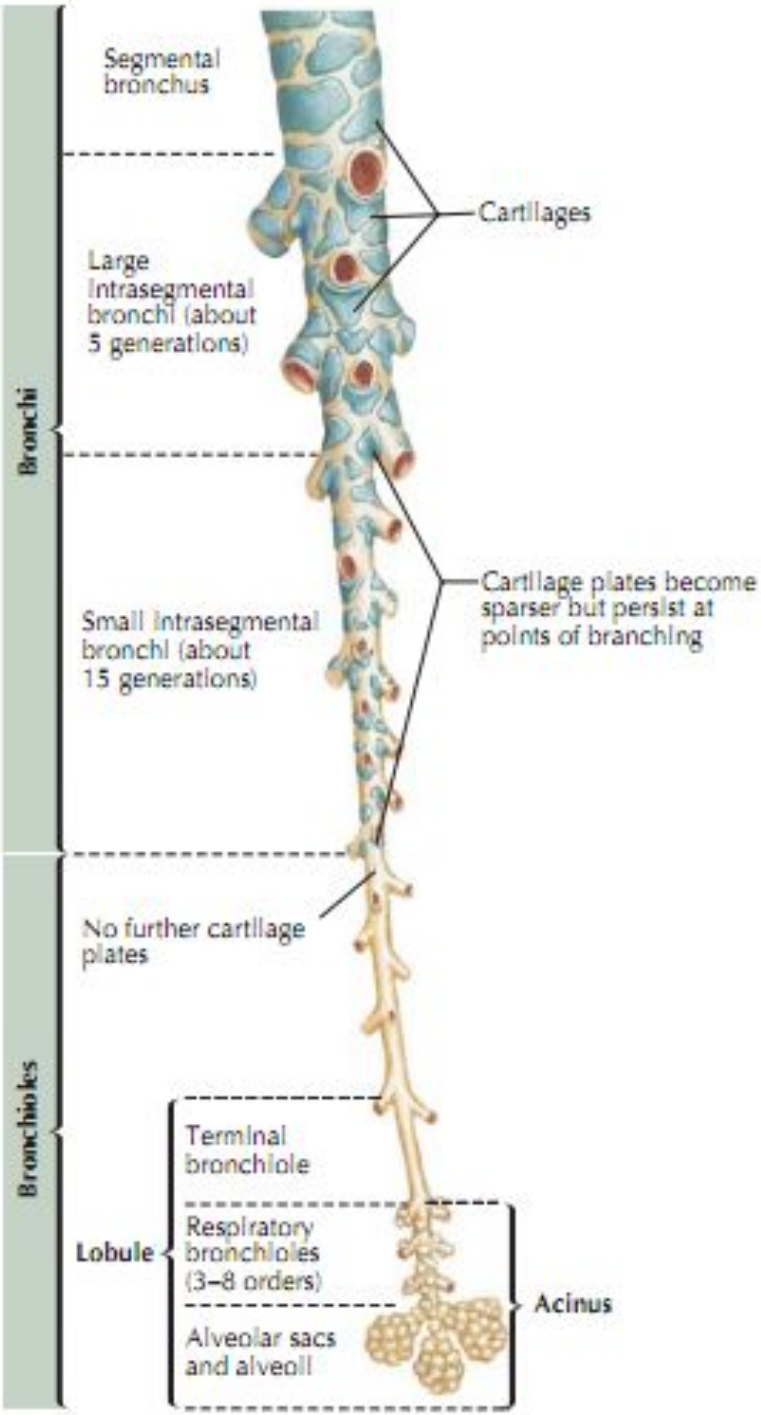
Segmental bronchus
Cartilages
Large intrasegmental bronchi (about 5 generations)
Bronchi
Cartilage plates become sparser but persist at points of branching
Small intrasegmental bronchi (about 15 generations)
No further cartilage plates
Bronchioles
Terminal bronchiole
Lobule
Respiratory bronchioles (3–8 orders)
Acinus
Alveolar sacs and alveoli

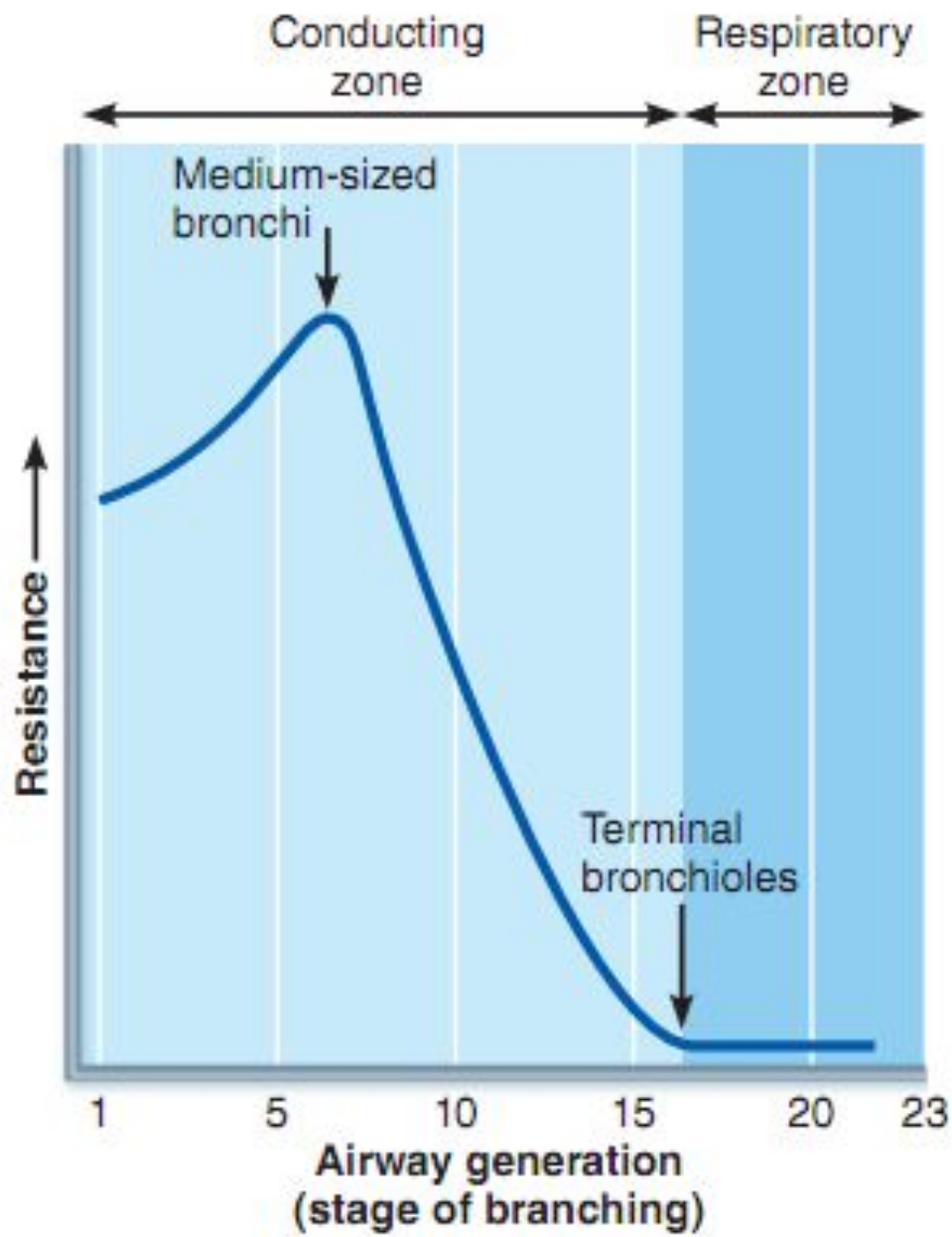
Conducting zone
Respiratory zone
Medium-sized bronchi
Terminal bronchioles
Resistance
1
5
10
15
20
23
Airway generation (stage of branching)

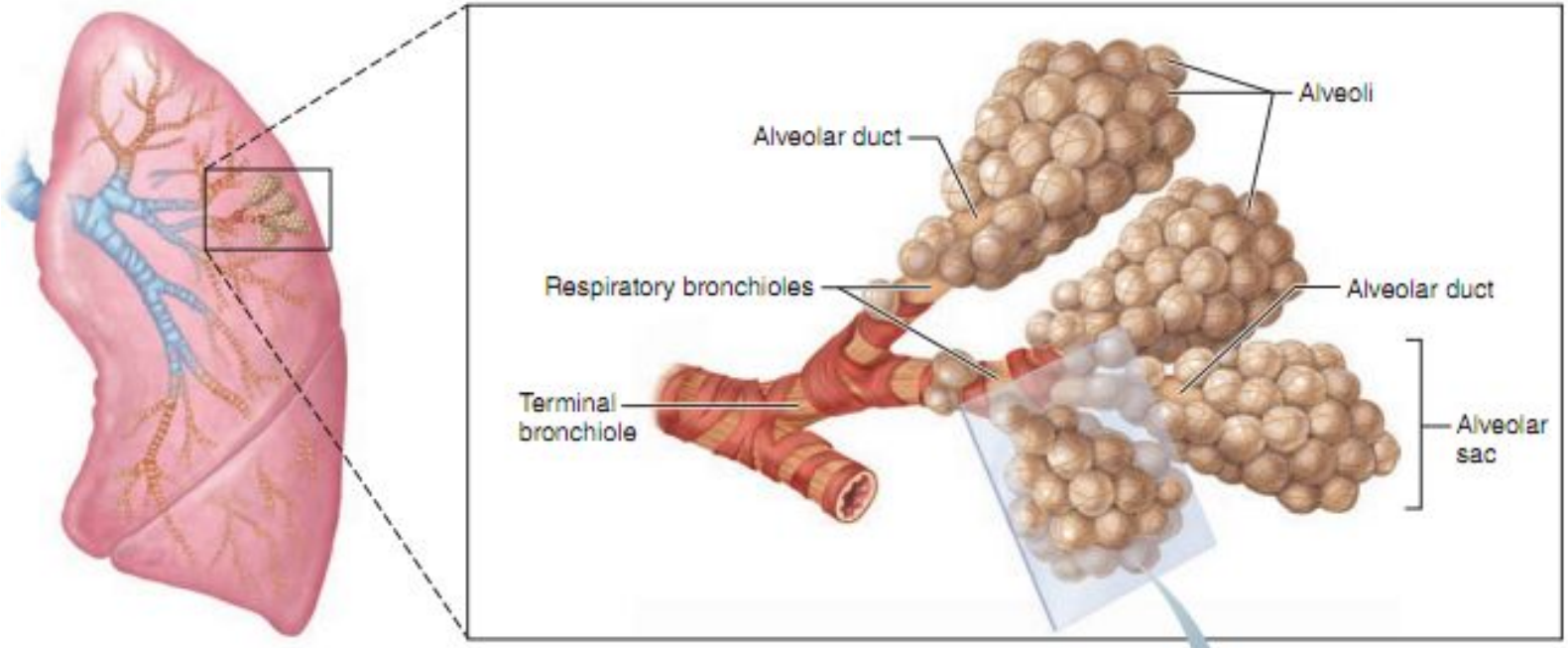
Alveoli
Alveolar duct
Respiratory bronchioles
Alveolar duct
Terminal bronchiole
Alveolar sac

(a)

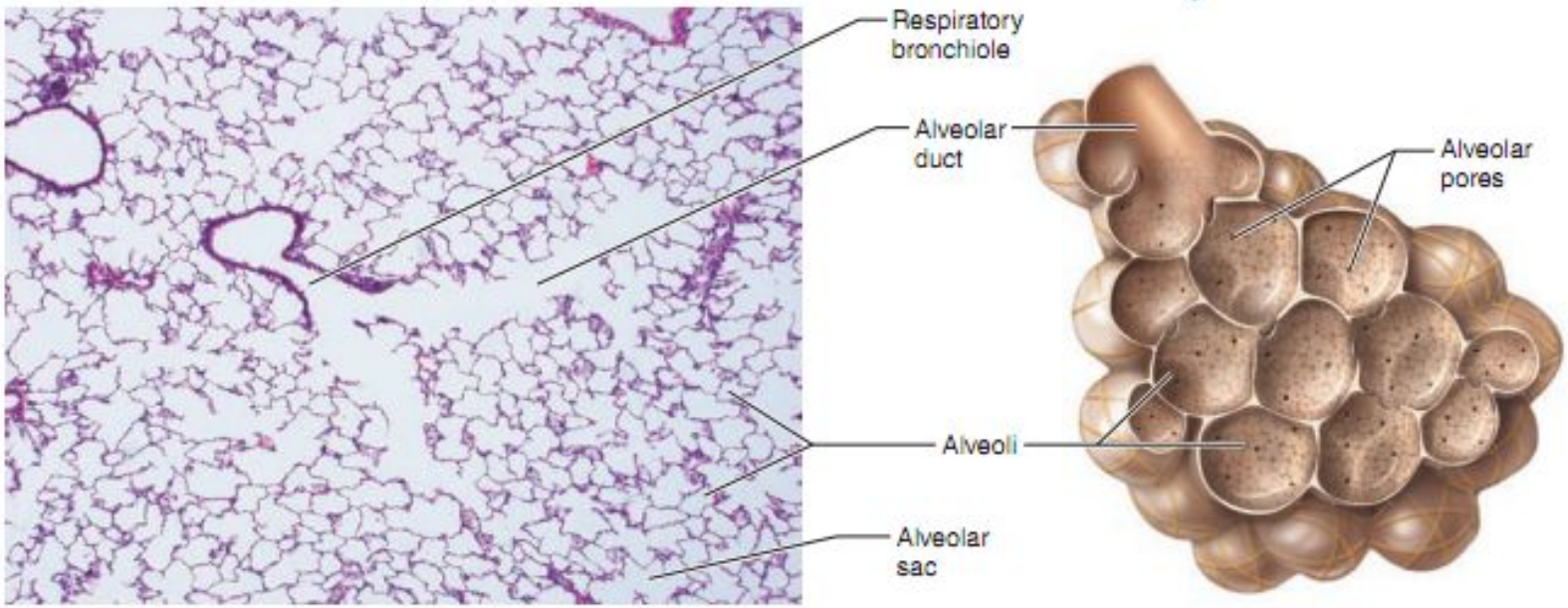
Respiratory bronchiole
Alveolar duct
Alveolar pores
Alveoli
Alveolar sac

(b)

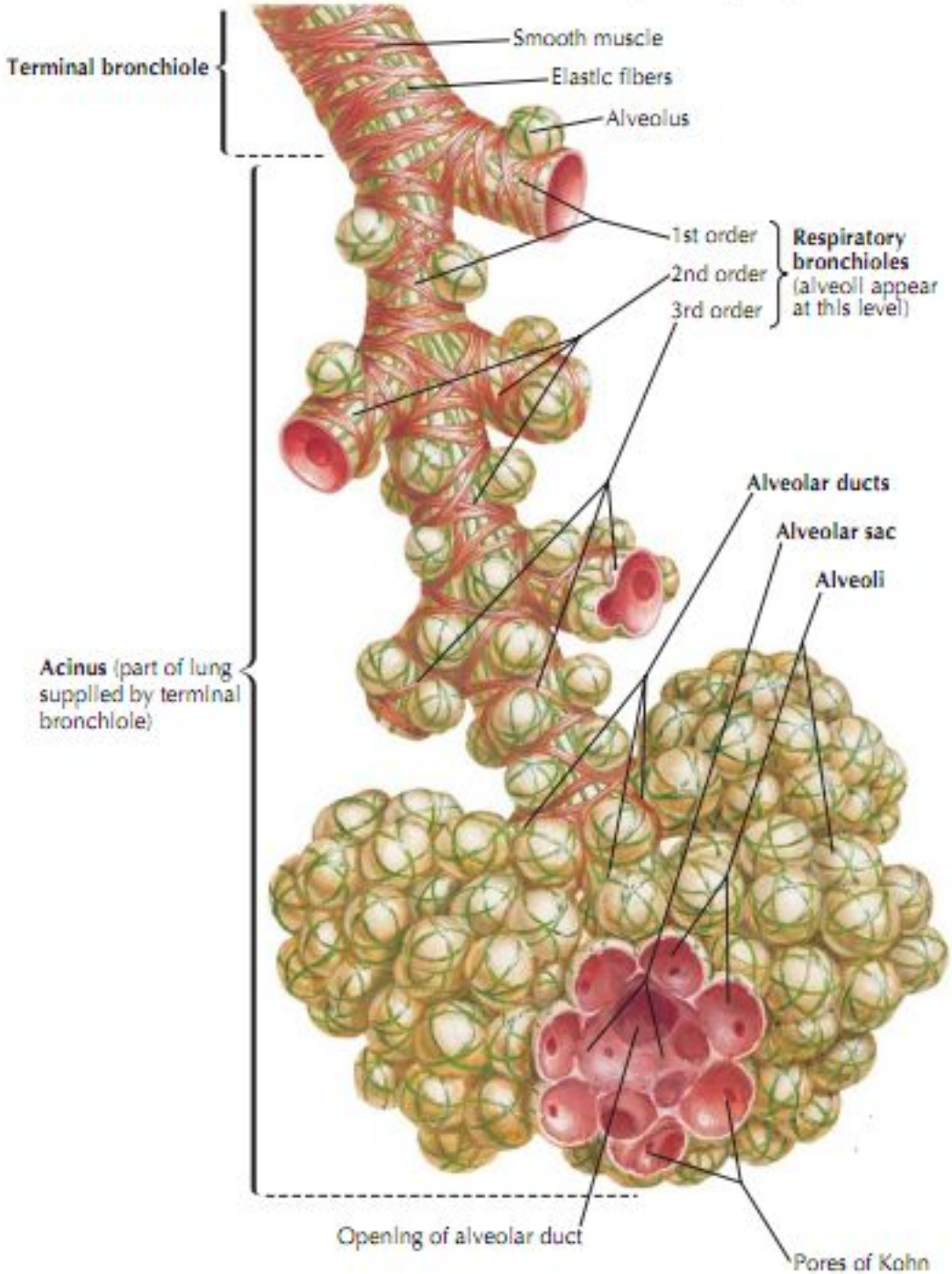
Terminal bronchiole
Smooth muscle
Elastic fibers
Alveolus
1st order
2nd order
3rd order
Respiratory bronchioles (alveoli appear at this level)
Alveolar ducts
Alveolar sac
Alveoli
Acinus (part of lung supplied by terminal bronchiole)
Opening of alveolar duct
Pores of Kohn

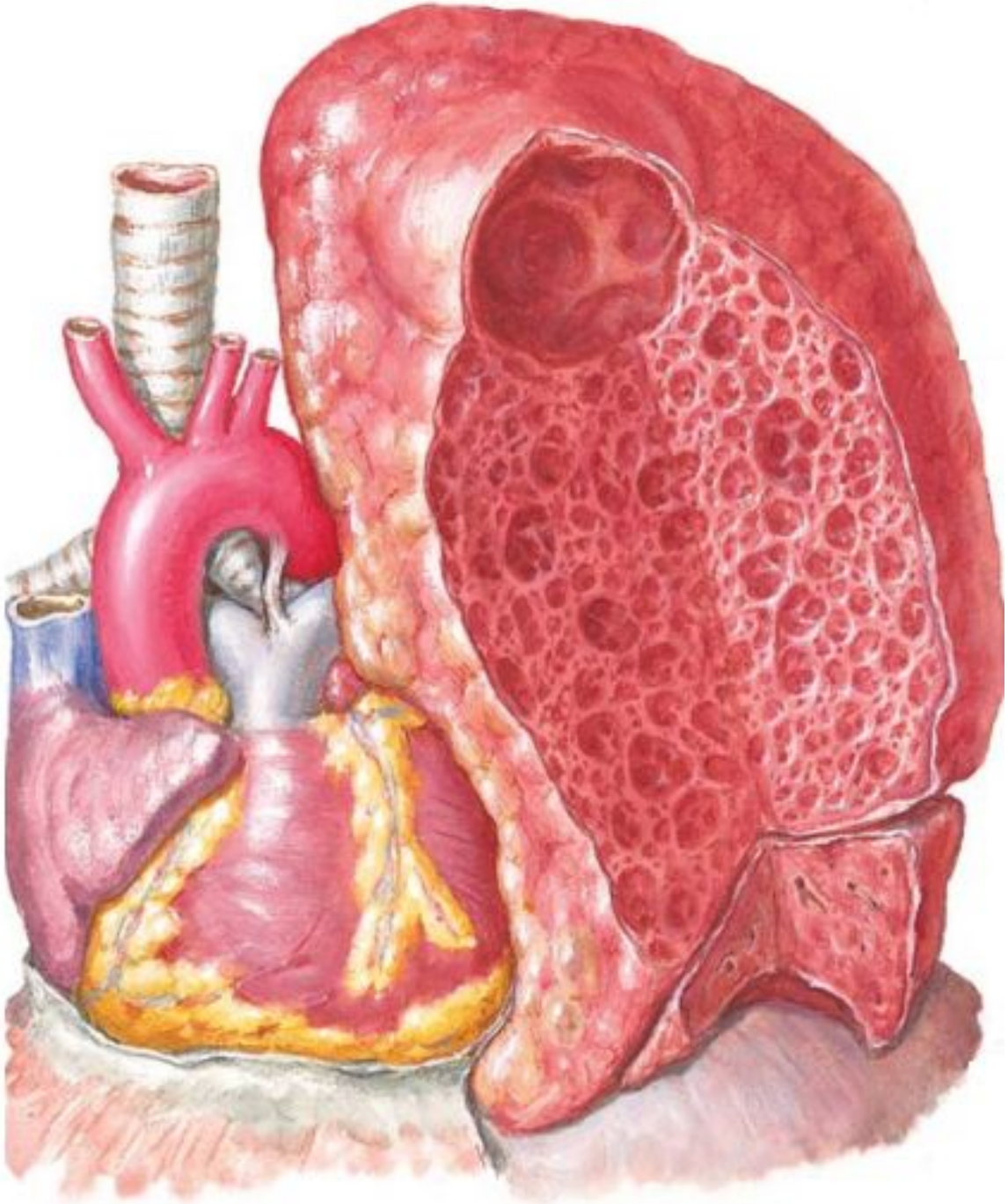

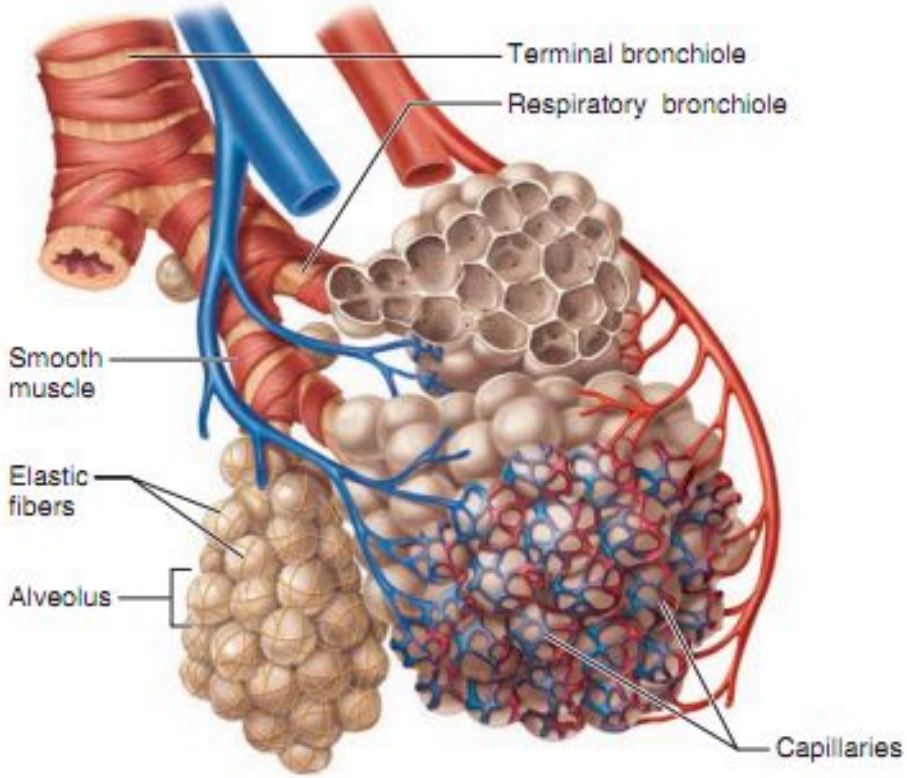
Terminal bronchiole
Respiratory bronchiole
Smooth muscle
Elastic fibers
Alveolus
Capillaries

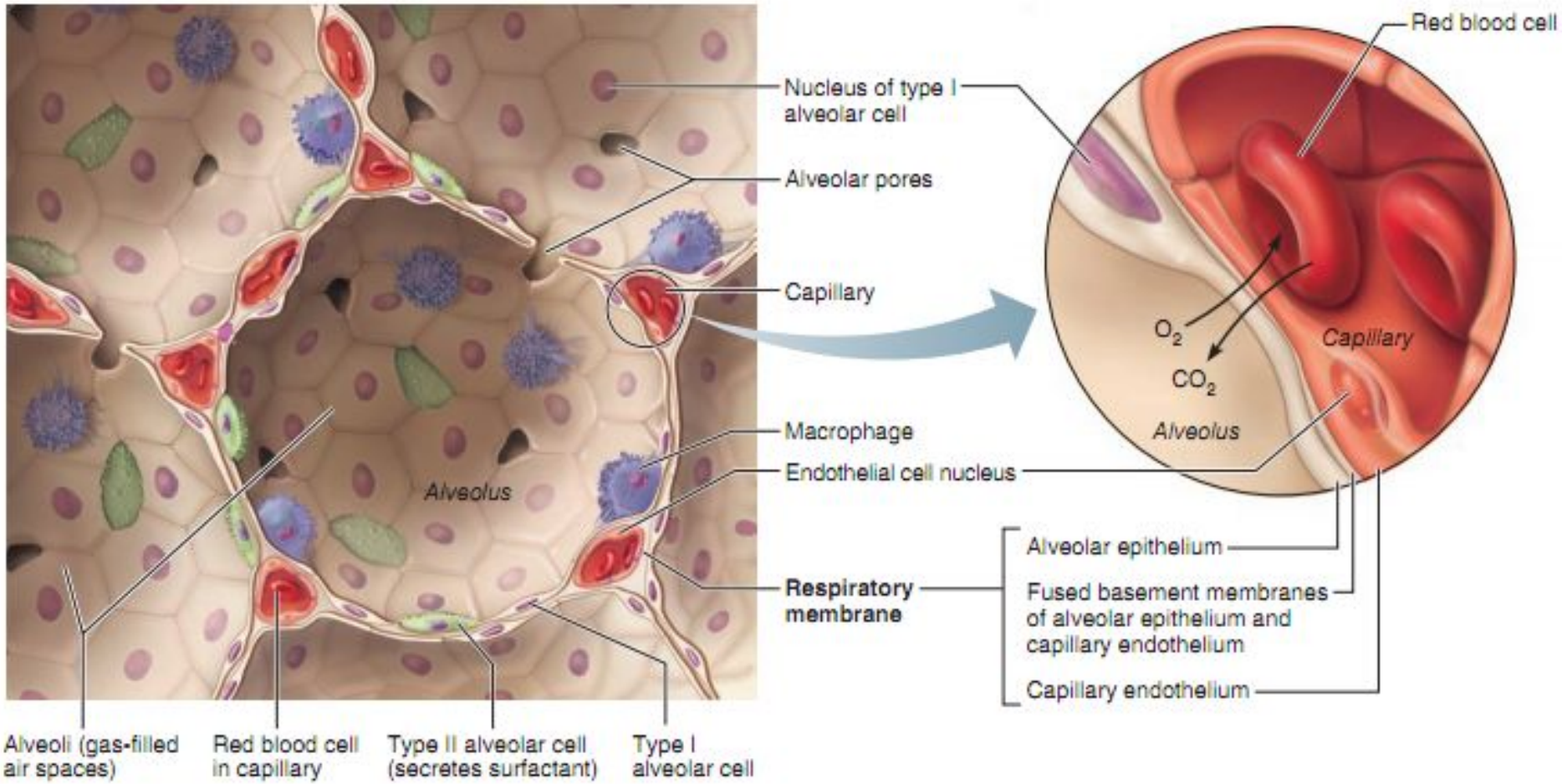
Nucleus of type I alveolar cell
Alveolar pores
Capillary
Macrophage
Endothelial cell nucleus
Alveolus
Respiratory membrane
Alveoli (gas-filled air spaces)
Red blood cell in capillary
Type II alveolar cell (secretes surfactant)
Type I alveolar cell
Red blood cell
O_2
CO_2
Capillary
Alveolus
Alveolar epithelium
Fused basement membranes of alveolar epithelium and capillary endothelium
Capillary endothelium

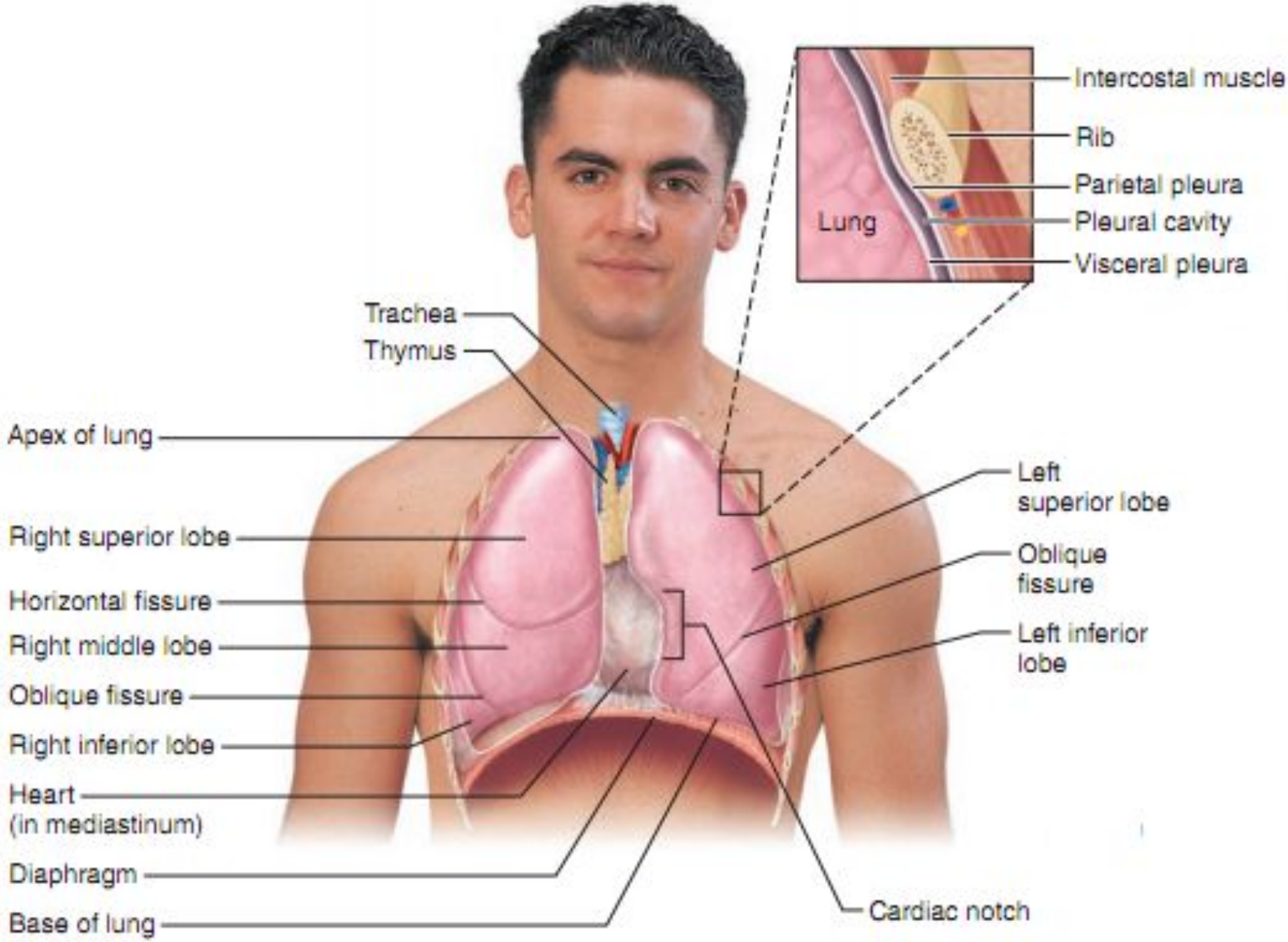
Intercostal muscle
Rib
Parietal pleura
Lung
Pleural cavity
Visceral pleura
Trachea
Thymus
Apex of lung
Left
superior lobe
Right superior lobe
Oblique
fissure
Horizontal fissure
Right middle lobe
Left inferior
lobe
Oblique fissure
Right inferior lobe
Heart
(in mediastinum)
Diaphragm
Base of lung
Cardiac notch

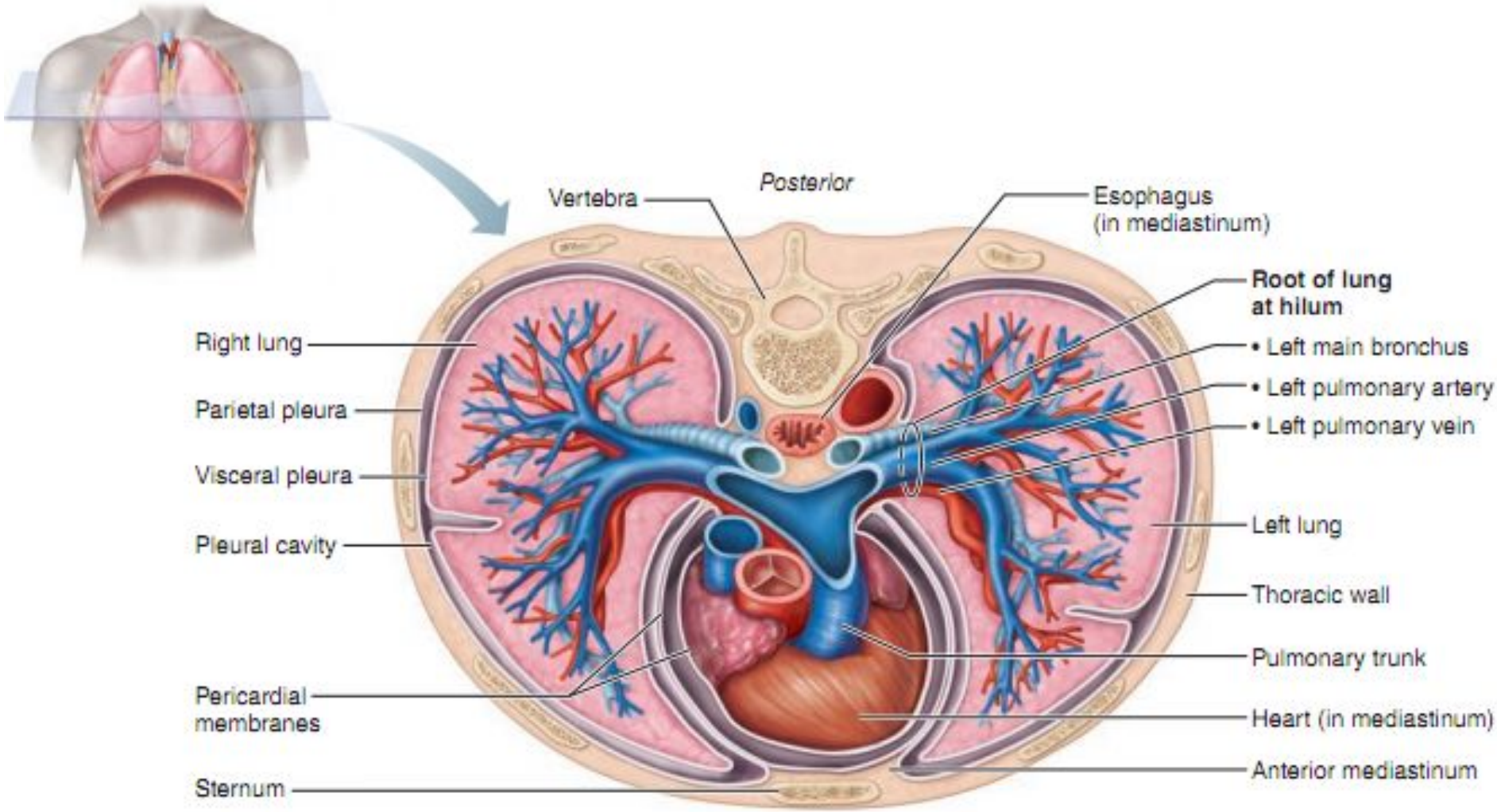
Posterior
Vertebra
Esophagus
(in mediastinum)
Root of lung
at hilum
• Left main bronchus
• Left pulmonary artery
• Left pulmonary vein
Right lung
Parietal pleura
Visceral pleura
Pleural cavity
Left lung
Thoracic wall
Pulmonary trunk
Pericardial
membranes
Heart (in mediastinum)
Anterior mediastinum
Sternum

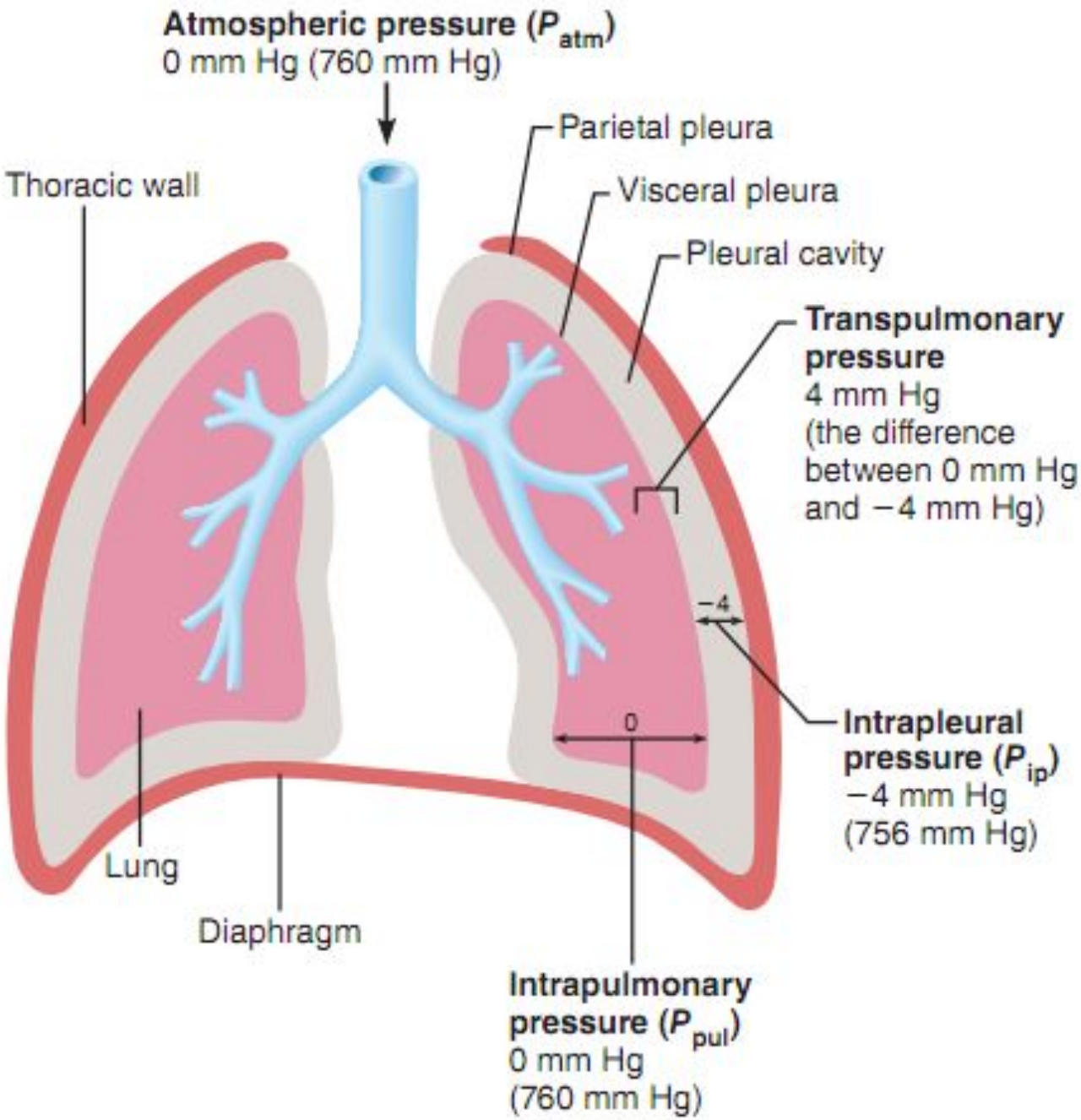
Atmospheric pressure (P_{atm})
0 mm Hg (760 mm Hg)
Parietal pleura
Thoracic wall
Visceral pleura
Pleural cavity
Transpulmonary pressure
4 mm Hg
(the difference between 0 mm Hg and −4 mm Hg)
−4
0
Intrapleural pressure (P_{ip})
−4 mm Hg
(756 mm Hg)
Lung
Diaphragm
Intrapulmonary pressure (P_{pul})
0 mm Hg
(760 mm Hg)

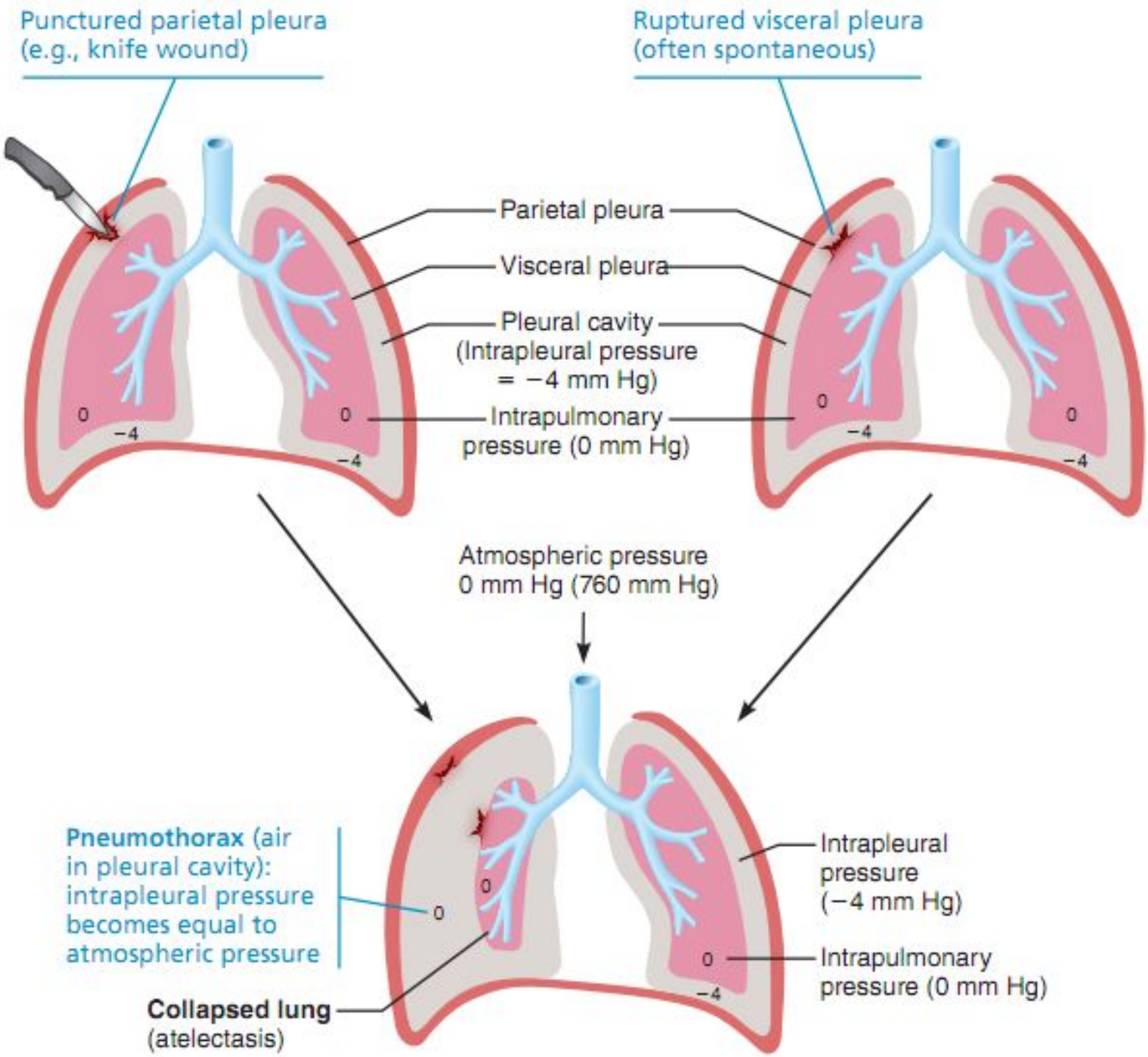
Punctured parietal pleura
(e.g., knife wound)
Ruptured visceral pleura
(often spontaneous)
Parietal pleura
Visceral pleura
Pleural cavity
(Intrapleural pressure
= −4 mm Hg)
Intrapulmonary
pressure (0 mm Hg)
0
−4
0
−4
0
−4
0
−4
Atmospheric pressure
0 mm Hg (760 mm Hg)
Pneumothorax (air
in pleural cavity):
intrapleural pressure
becomes equal to
atmospheric pressure
0
0
Collapsed lung
(atelectasis)
Intrapleural
pressure
(−4 mm Hg)
0
−4
Intrapulmonary
pressure (0 mm Hg)

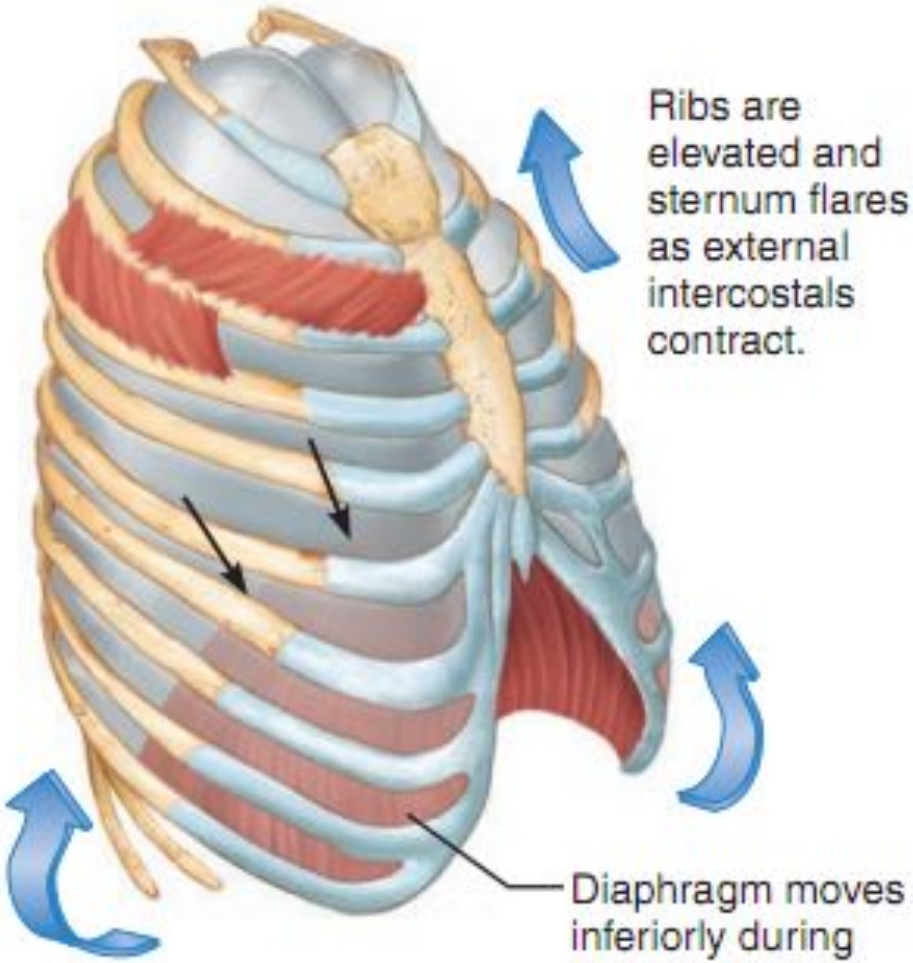
Ribs are elevated and sternum flares as external intercostals contract.
Diaphragm moves inferiorly during contraction.

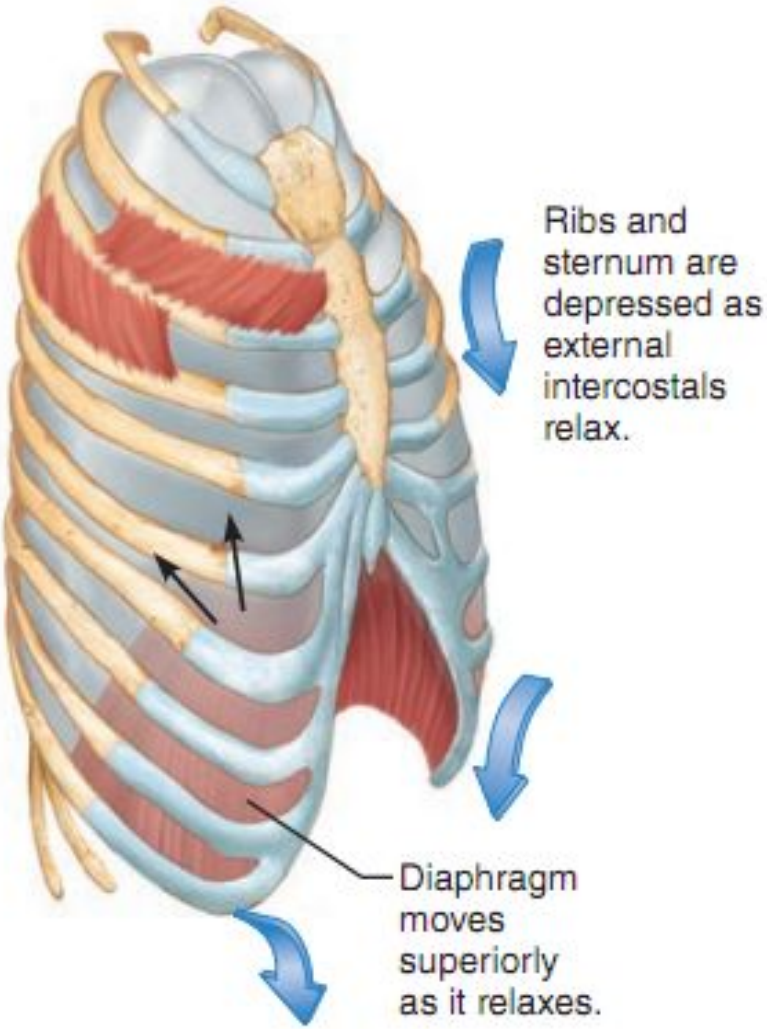
Ribs and sternum are depressed as external intercostals relax.
Diaphragm moves superiorly as it relaxes.

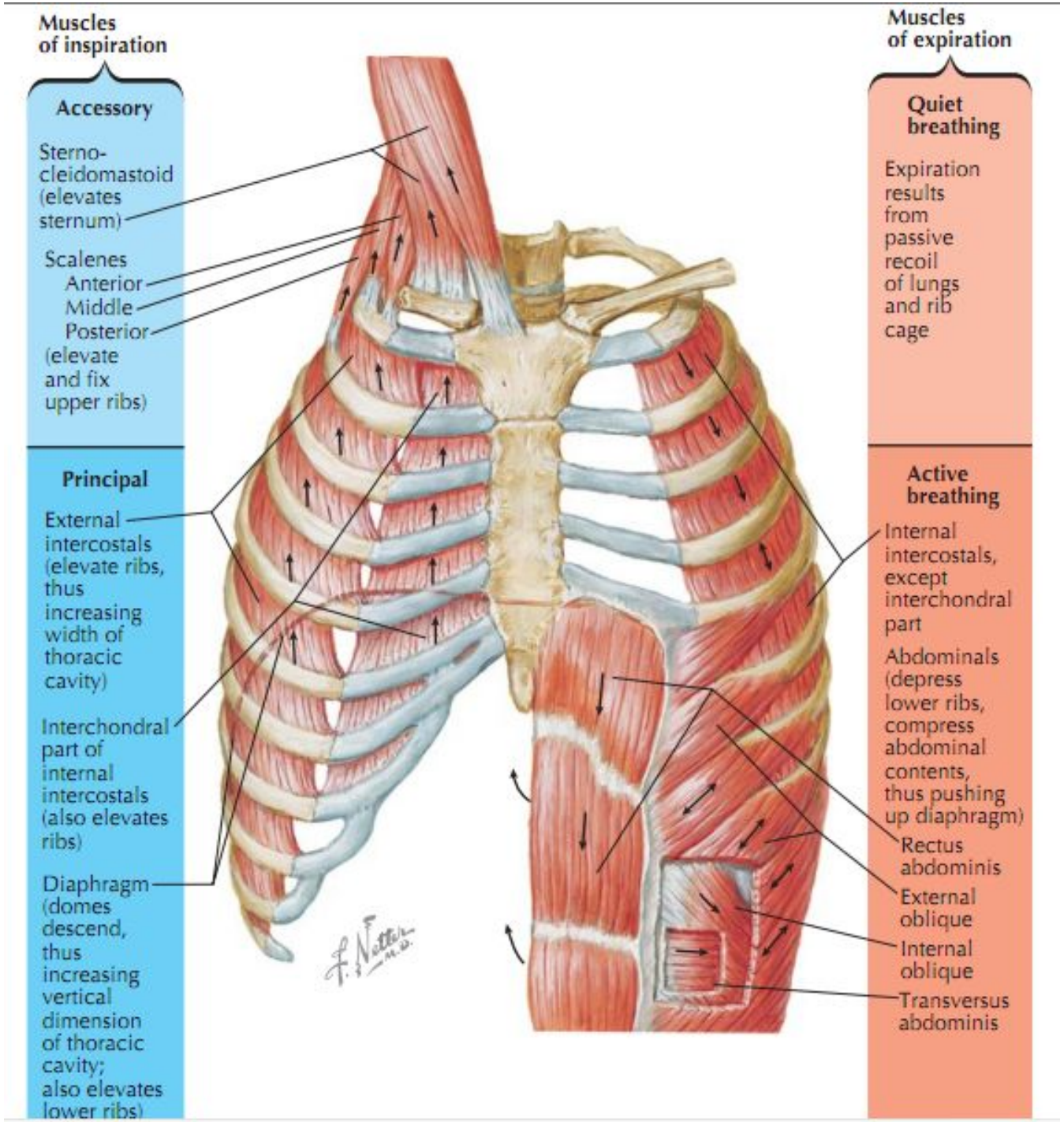
Muscles of inspiration
Accessory
Sterno-cleidomastoid (elevates sternum)
Scalenes
Anterior
Middle
Posterior
(elevate and fix upper ribs)
Principal
External intercostals (elevate ribs, thus increasing width of thoracic cavity)
Interchondral part of internal intercostals (also elevates ribs)
Diaphragm (domes descend, thus increasing vertical dimension of thoracic cavity; also elevates lower ribs)
Muscles of expiration
Quiet breathing
Expiration results from passive recoil of lungs and rib cage
Active breathing
Internal intercostals, except interchondral part
Abdominals (depress lower ribs, compress abdominal contents, thus pushing up diaphragm)
Rectus abdominis
External oblique
Internal oblique
Transversus abdominis
F. Netter M.D.

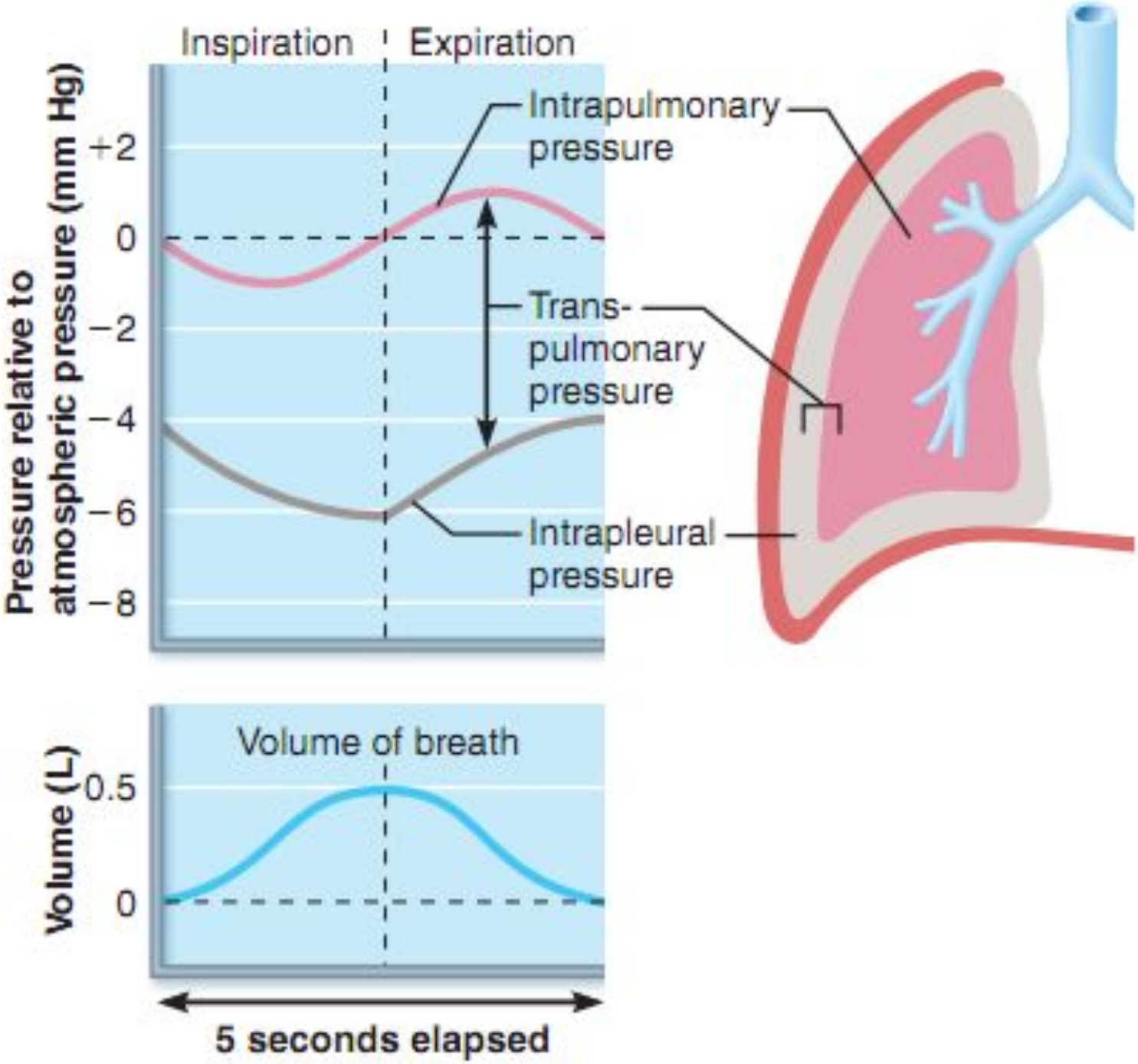
Inspiration
Expiration
Pressure relative to atmospheric pressure (mm Hg)
+2
0
−2
−4
−6
−8
Intrapulmonary pressure
Trans-pulmonary pressure
Intrapleural pressure
Volume of breath
Volume (L)
0.5
0
5 seconds elapsed

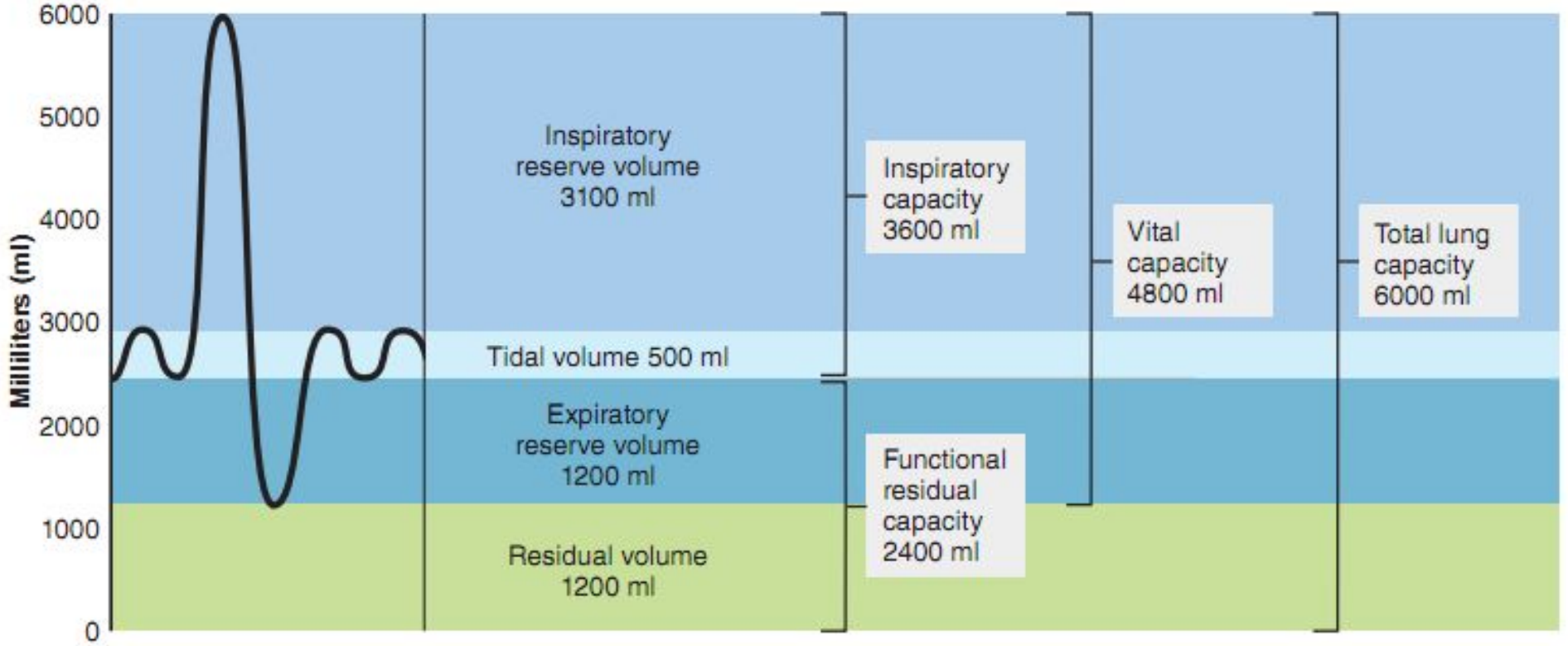

Spirographic record for a male

Table 22.4 Comparison of Gas Partial Pressures and Approximate Percentages in the Atmosphere and in the Alveoli

	ATMOSPHERE (SEA LEVEL)		*ALVEOLI*	
GAS	APPROXIMATE PERCENTAGE	PARTIAL PRESSURE (mm Hg)	APPROXIMATE PERCENTAGE	PARTIAL PRESSURE (mm Hg)
N_2	78.6	597	74.9	569
O_2	20.9	159	13.7	104
CO_2	0.04	0.3	5.2	40
H_2O	0.46	3.7	6.2	47
	100.0%	760	100.0%	760

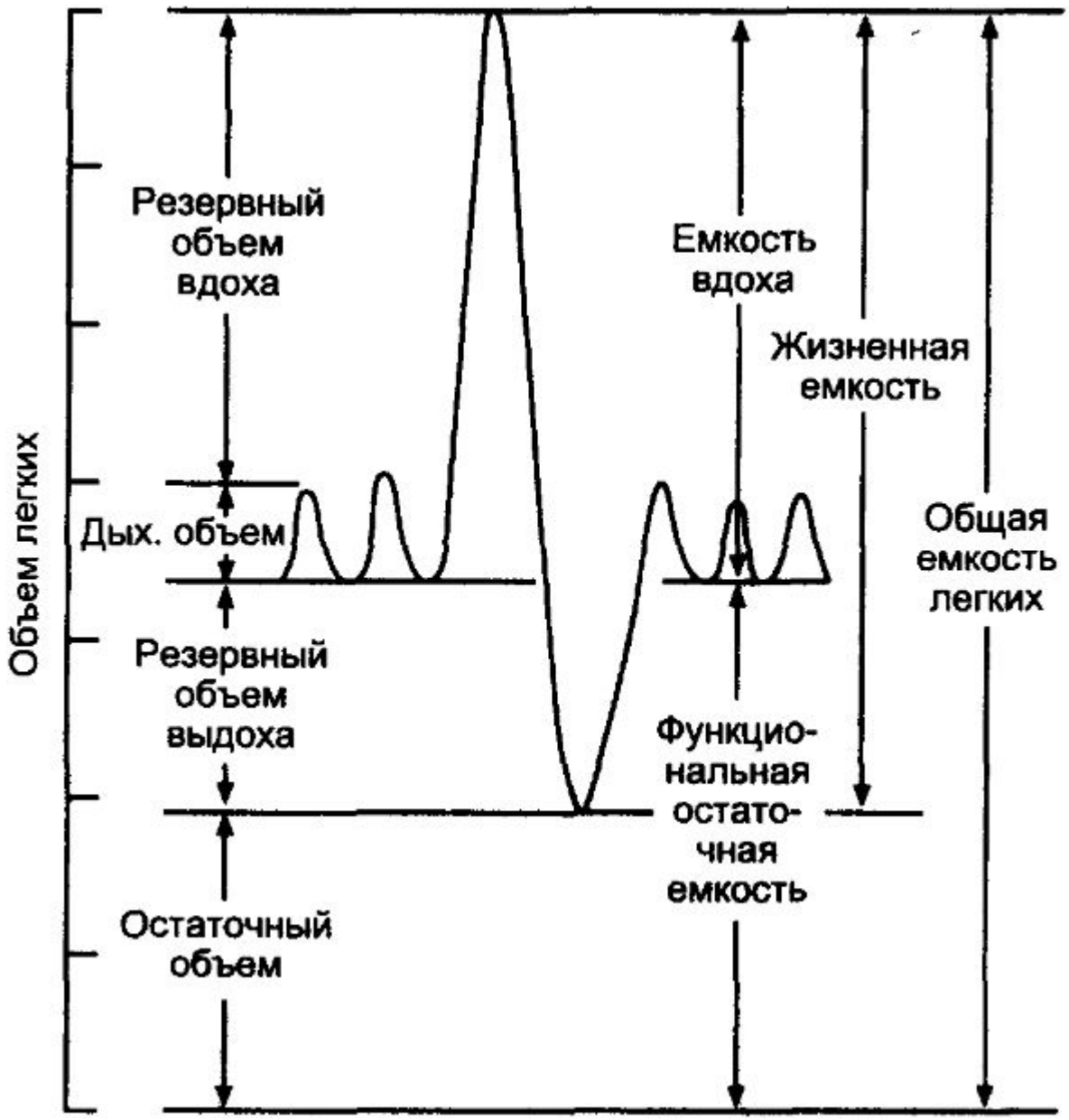
Объем легких
Резервный объем вдоха
Дых. объем
Резервный объем выдоха
Остаточный объем
Емкость вдоха
Жизненная емкость
Общая емкость легких
Функцио-нальная остато-чная емкость

$$\underset{\text{(ml/min)}}{\text{AVR}} = \underset{\text{(breaths/min)}}{\text{frequency}} \times \underset{\text{(ml/breath)}}{(\text{TV} - \text{dead space})}$$

Table 22.3 Effects of Breathing Rate and Depth on Alveolar Ventilation of Three Hypothetical Patients

BREATHING PATTERN OF HYPOTHETICAL PATIENT	DEAD SPACE VOLUME (DSV)	TIDAL VOLUME (TV)	RESPIRATORY RATE*	MINUTE VENTILATION (MVR)	ALVEOLAR VENTILATION (AVR)	% EFFECTIVE VENTILATION (AVR/MVR)
I—Normal rate and depth	150 ml	500 ml	20/min	10,000 ml/min	7000 ml/min	70%
II—Slow, deep breathing	150 ml	1000 ml	10/min	10,000 ml/min	8500 ml/min	85%
III—Rapid, shallow breathing	150 ml	250 ml	40/min	10,000 ml/min	4000 ml/min	40%

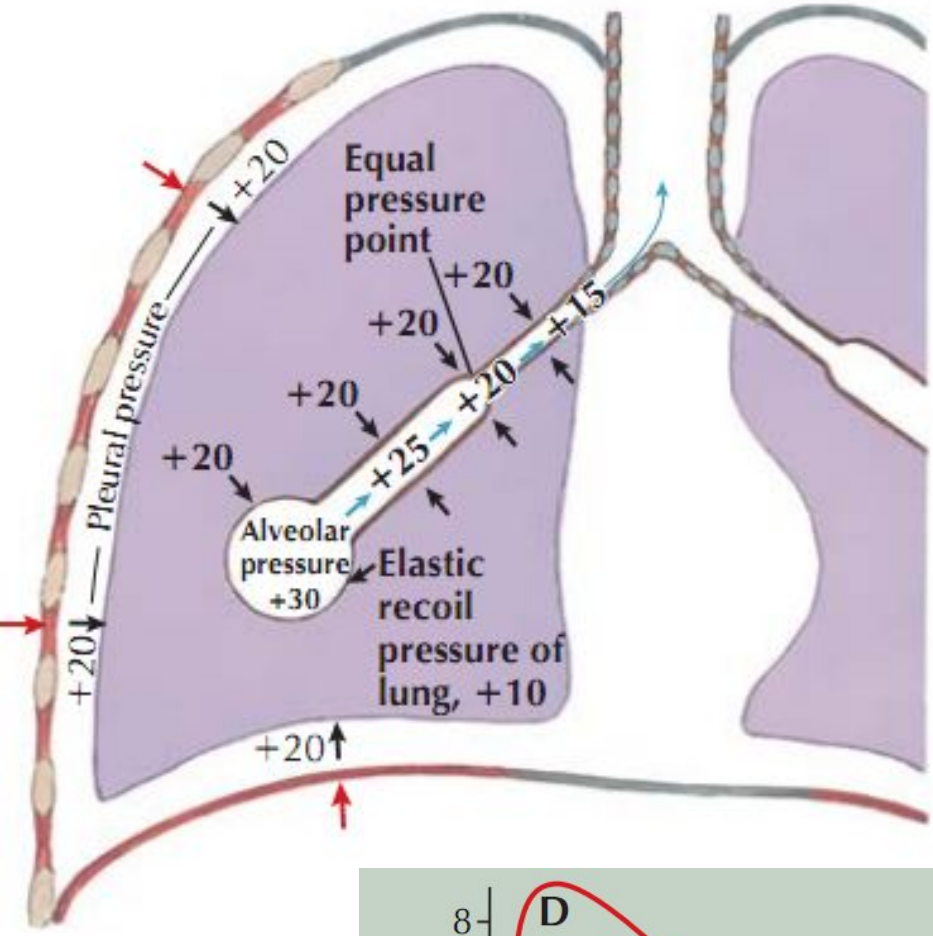
Equal pressure point
+20
+20
+20
+20
+20
+15
+20
+25
Pleural pressure
+20
+20
+20
Alveolar pressure +30
Elastic recoil pressure of lung, +10

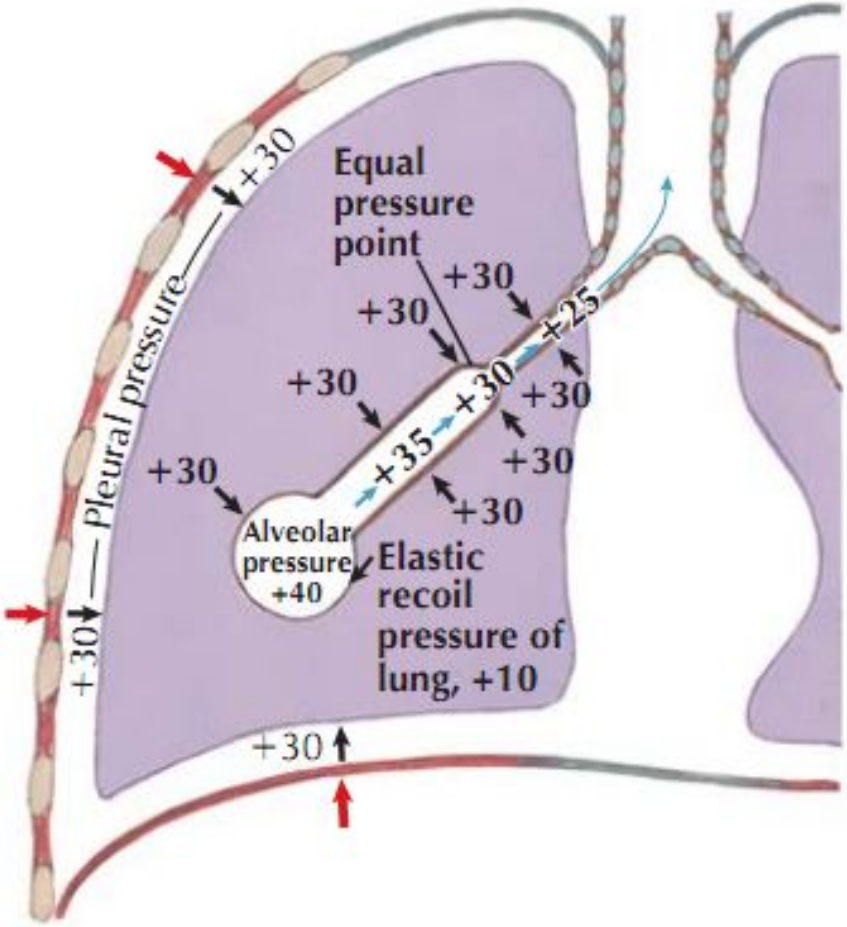
Equal pressure point
+30
+30
+30
+30
+25
+30
+30
+35
+30
+30
+30
Pleural pressure
+30
+30
+30
Alveolar pressure +40
Elastic recoil pressure of lung, +10

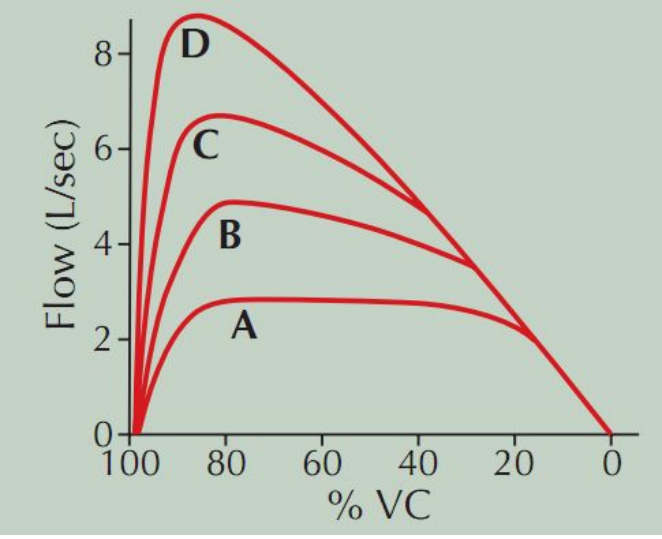
Flow (L/sec)
8
6
4
2
0
D
C
B
A
100
80
60
40
20
0
% VC

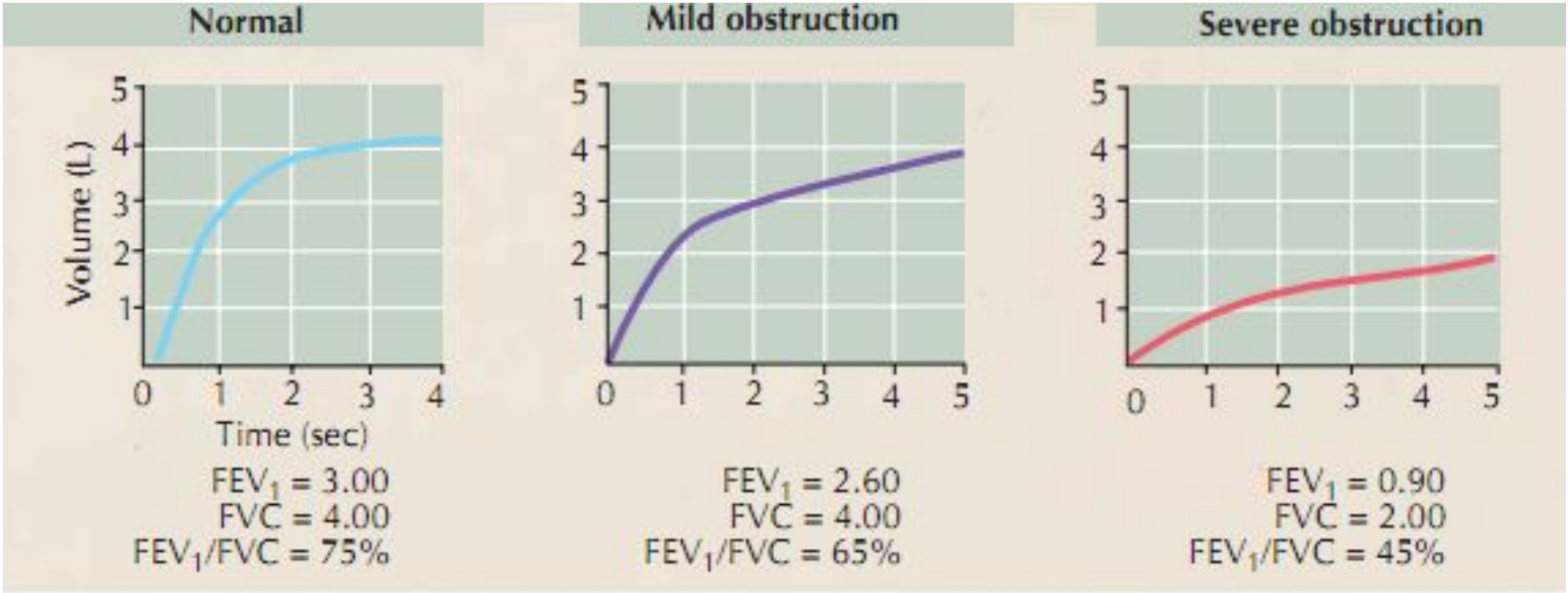
Normal
Mild obstruction
Severe obstruction
Volume (L)
Time (sec)
FEV1 = 3.00
FVC = 4.00
FEV1/FVC = 75%
FEV1 = 2.60
FVC = 4.00
FEV1/FVC = 65%
FEV1 = 0.90
FVC = 2.00
FEV1/FVC = 45%

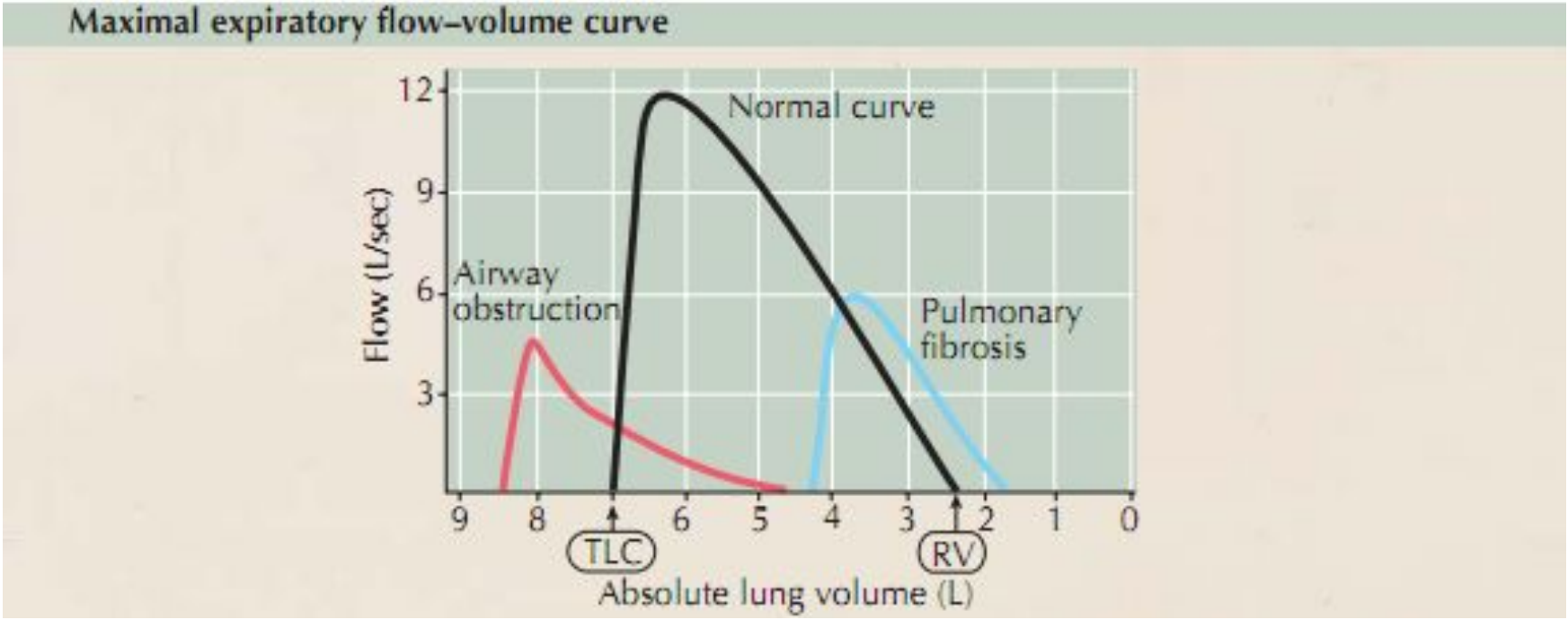
Maximal expiratory flow–volume curve
Normal curve
Airway obstruction
Pulmonary fibrosis
Flow (L/sec)
TLC
RV
Absolute lung volume (L)

INTERRELATIONSHIPS OF CHRONIC BRONCHITIS AND EMPHYSEMA

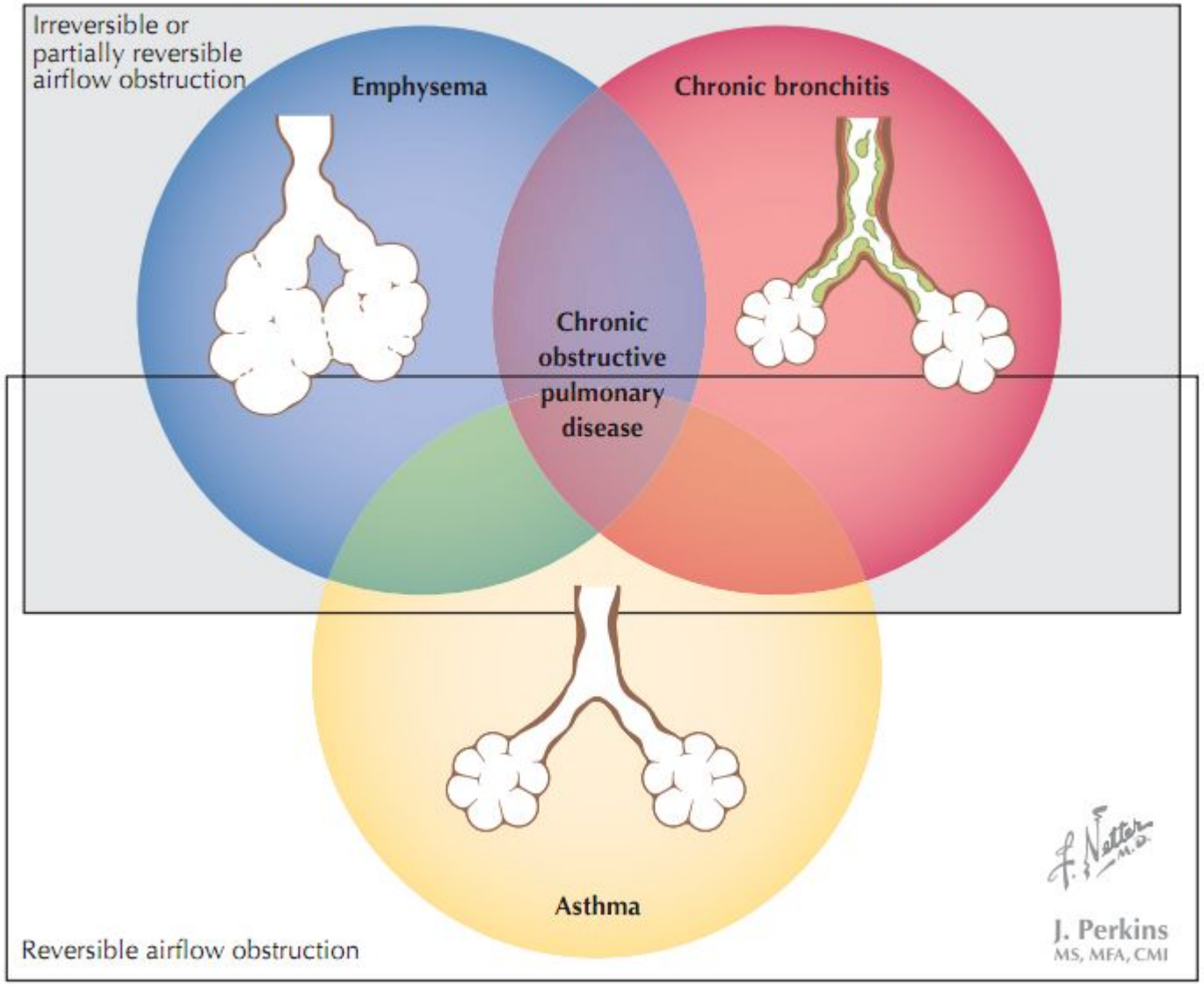

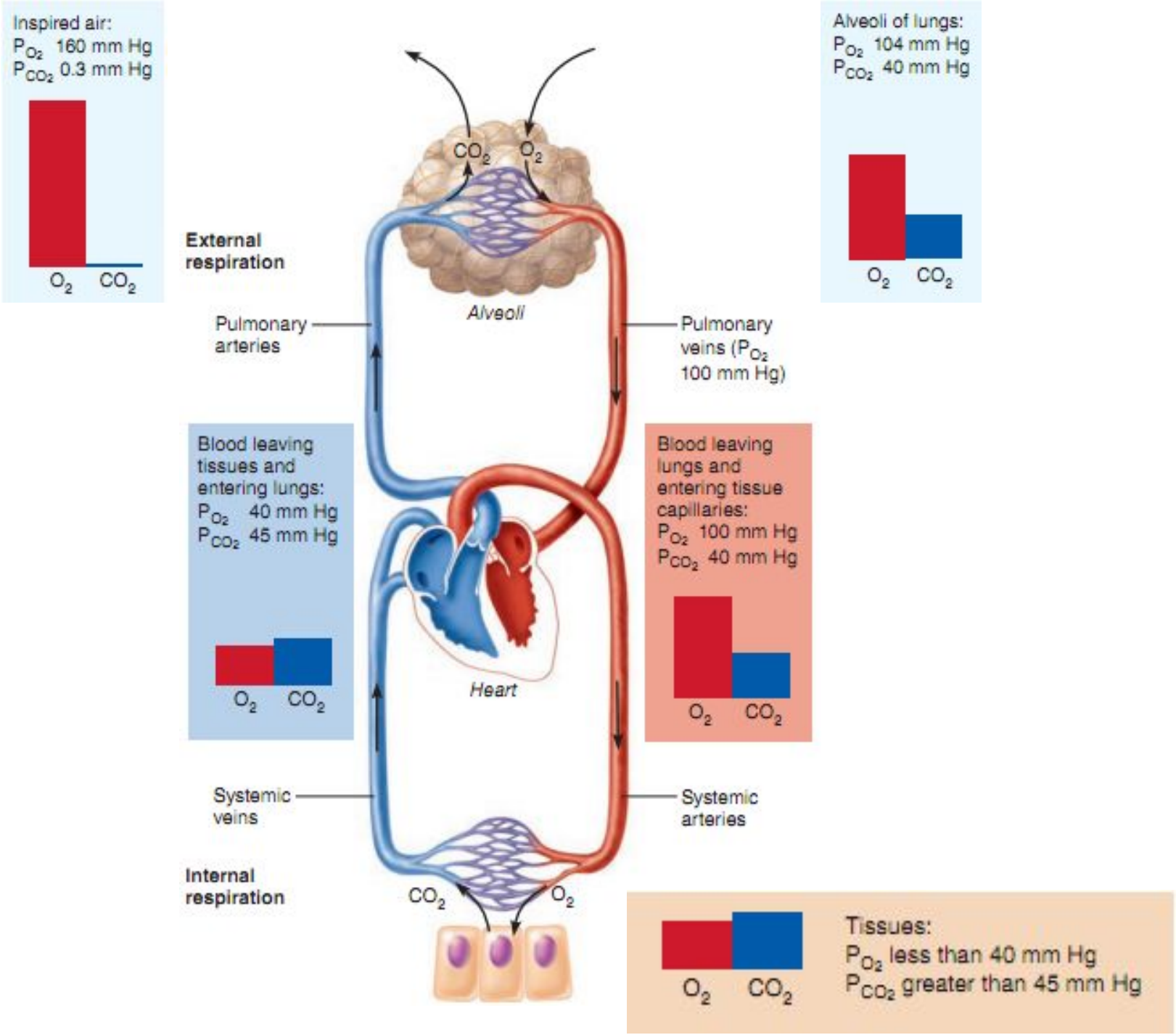
Inspired air:
P_{O_2} 160 mm Hg
P_{CO_2} 0.3 mm Hg
O_2 CO_2
Alveoli of lungs:
P_{O_2} 104 mm Hg
P_{CO_2} 40 mm Hg
O_2 CO_2
CO_2 O_2
External respiration
Alveoli
Pulmonary arteries
Pulmonary veins (P_{O_2} 100 mm Hg)
Blood leaving tissues and entering lungs:
P_{O_2} 40 mm Hg
P_{CO_2} 45 mm Hg
O_2 CO_2
Blood leaving lungs and entering tissue capillaries:
P_{O_2} 100 mm Hg
P_{CO_2} 40 mm Hg
O_2 CO_2
Heart
Systemic veins
Systemic arteries
Internal respiration
CO_2 O_2
O_2 CO_2
Tissues:
P_{O_2} less than 40 mm Hg
P_{CO_2} greater than 45 mm Hg

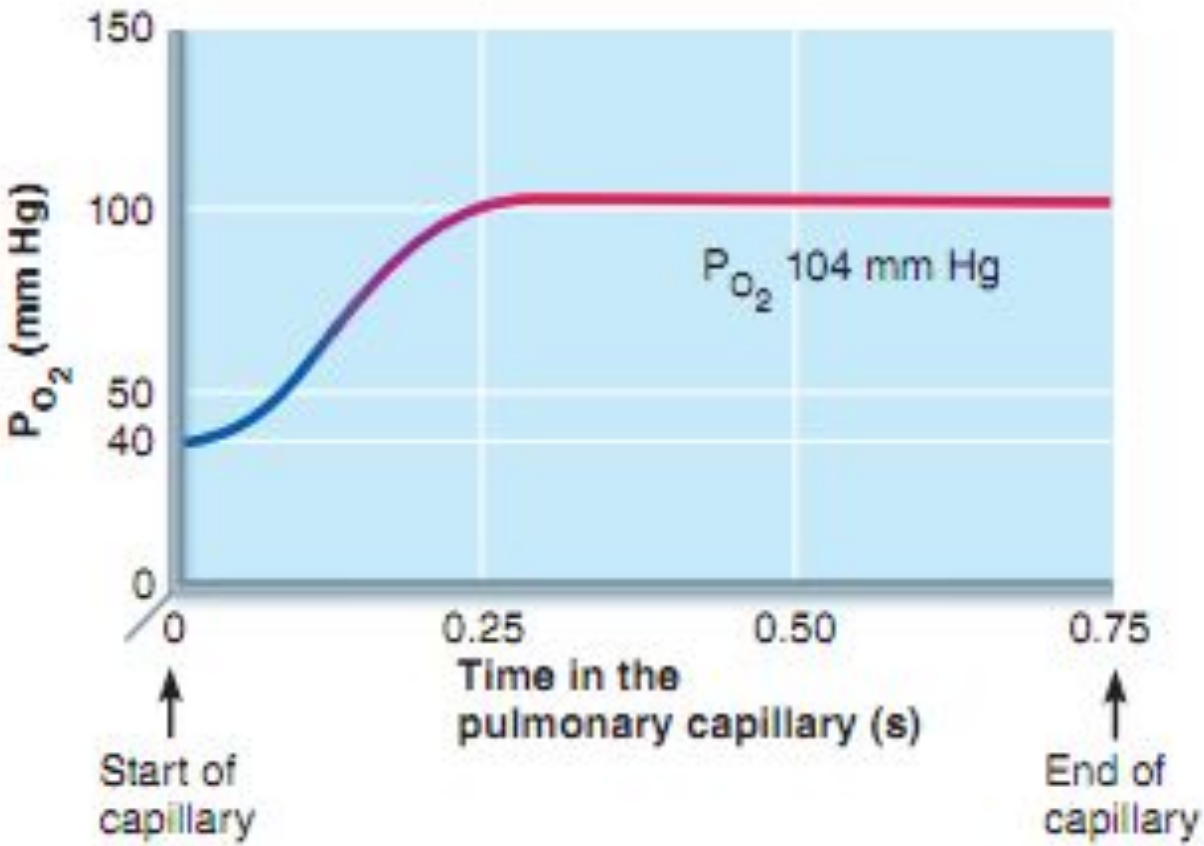
150
100
50
40
0
P_{O_2} (mm Hg)
P_{O_2} 104 mm Hg
0
0.25
0.50
0.75
Time in the pulmonary capillary (s)
Start of capillary
End of capillary

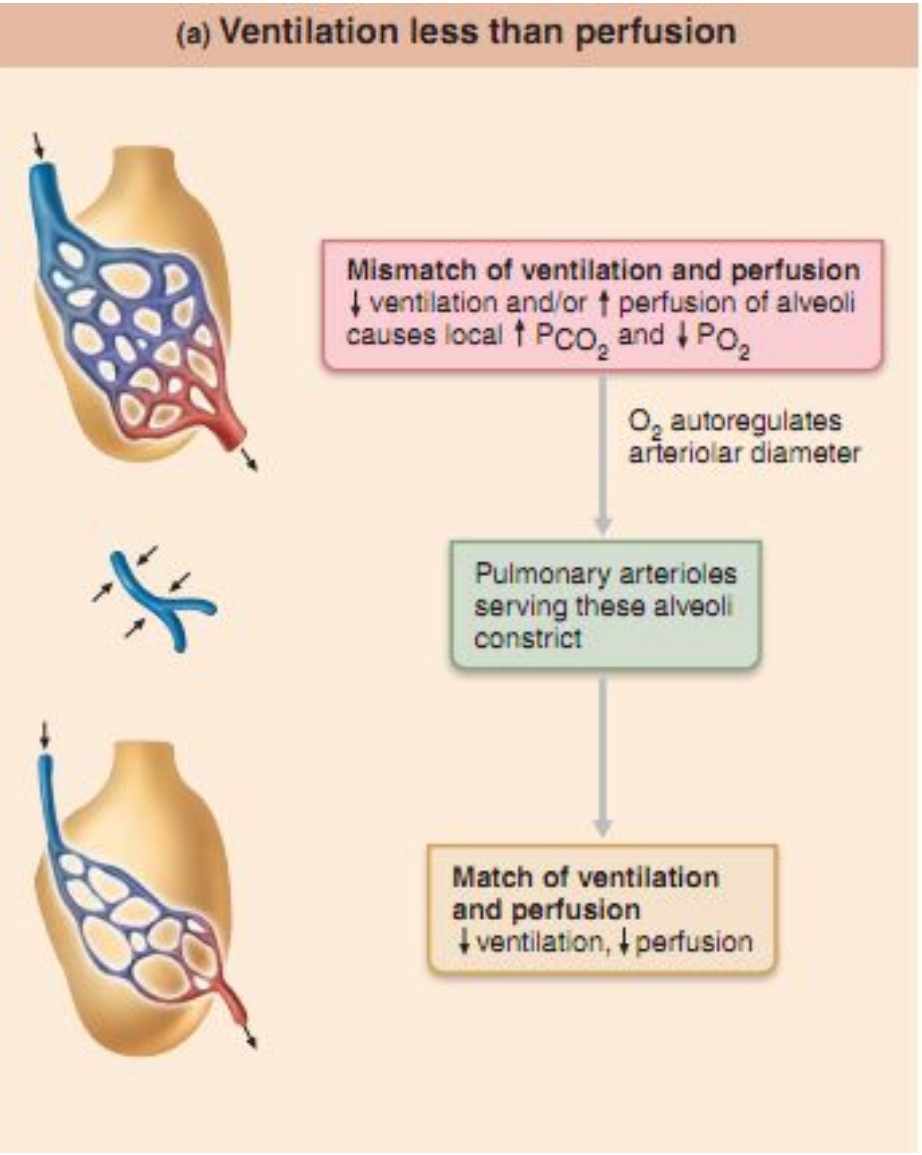
(a) Ventilation less than perfusion
Mismatch of ventilation and perfusion
↓ ventilation and/or ↑ perfusion of alveoli causes local ↑ P_{CO_2} and ↓ P_{O_2}
O_2 autoregulates arteriolar diameter
Pulmonary arterioles serving these alveoli constrict
Match of ventilation and perfusion
↓ ventilation, ↓ perfusion

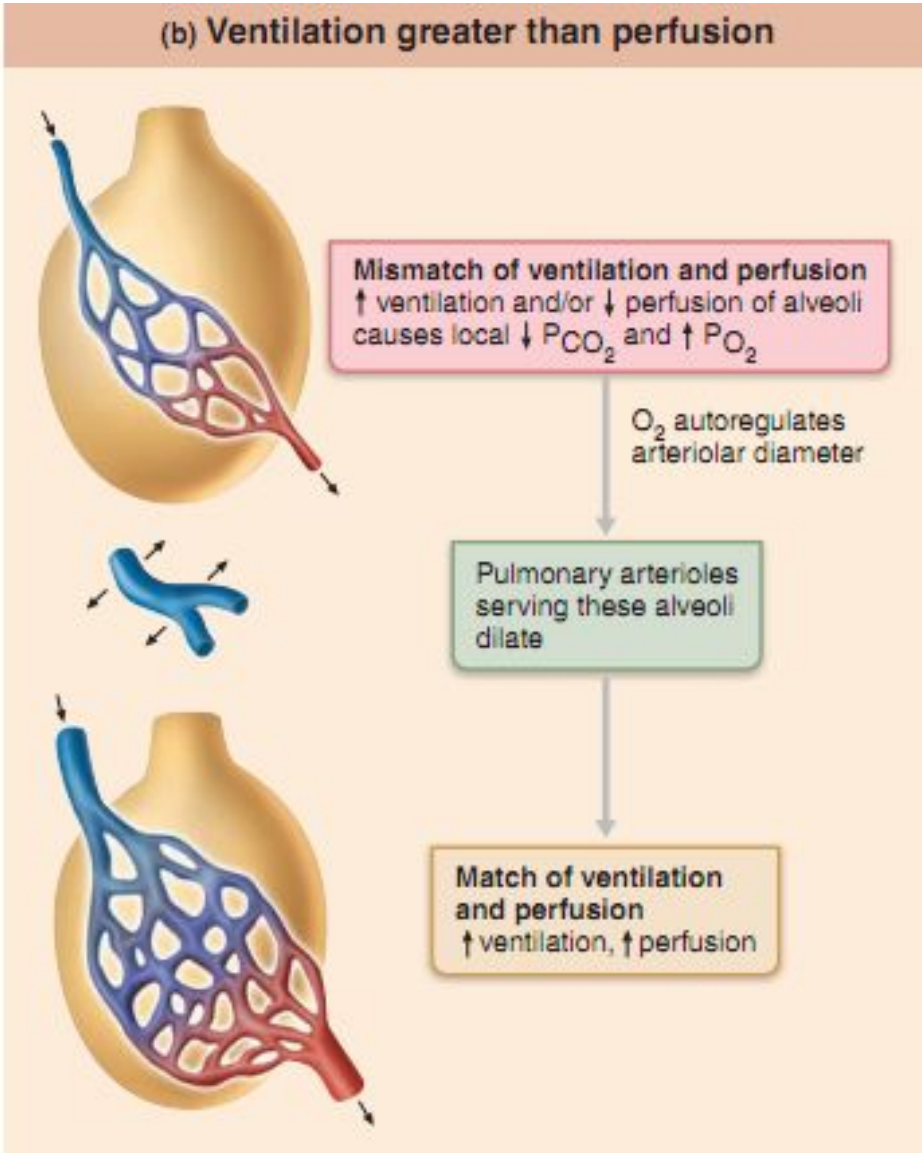
(b) Ventilation greater than perfusion
Mismatch of ventilation and perfusion
↑ ventilation and/or ↓ perfusion of alveoli causes local ↓ P_{CO_2} and ↑ P_{O_2}
O_2 autoregulates arteriolar diameter
Pulmonary arterioles serving these alveoli dilate
Match of ventilation and perfusion
↑ ventilation, ↑ perfusion