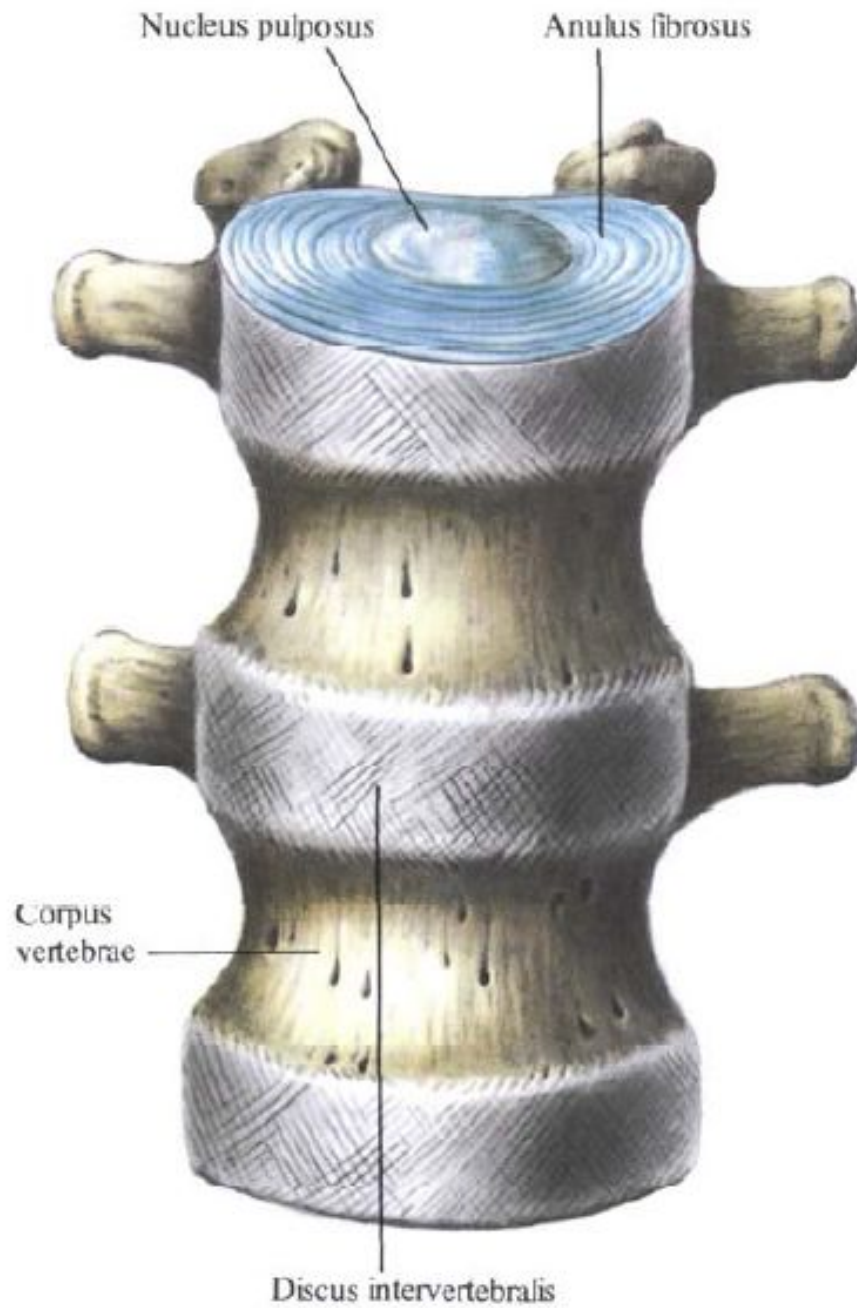
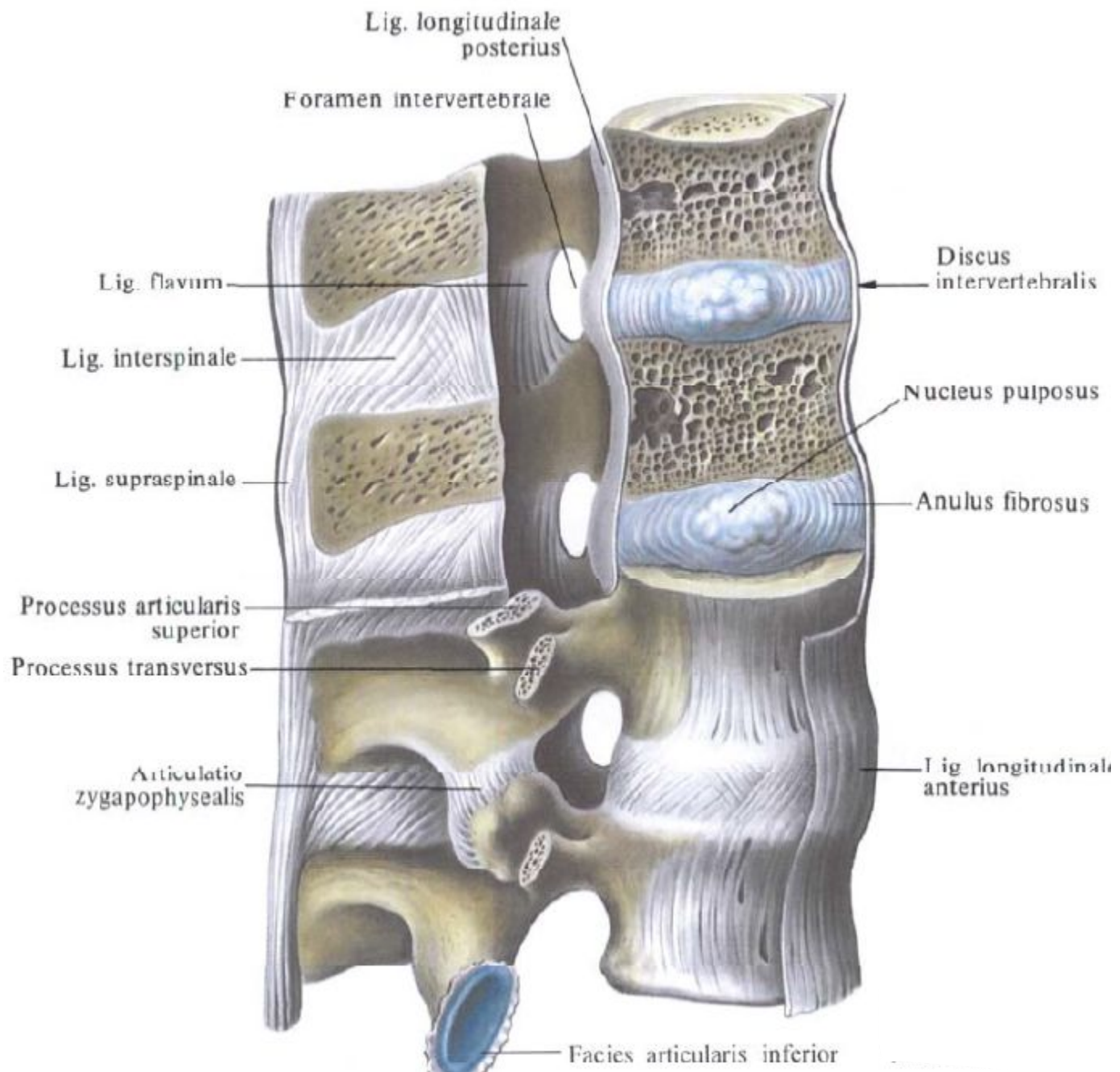


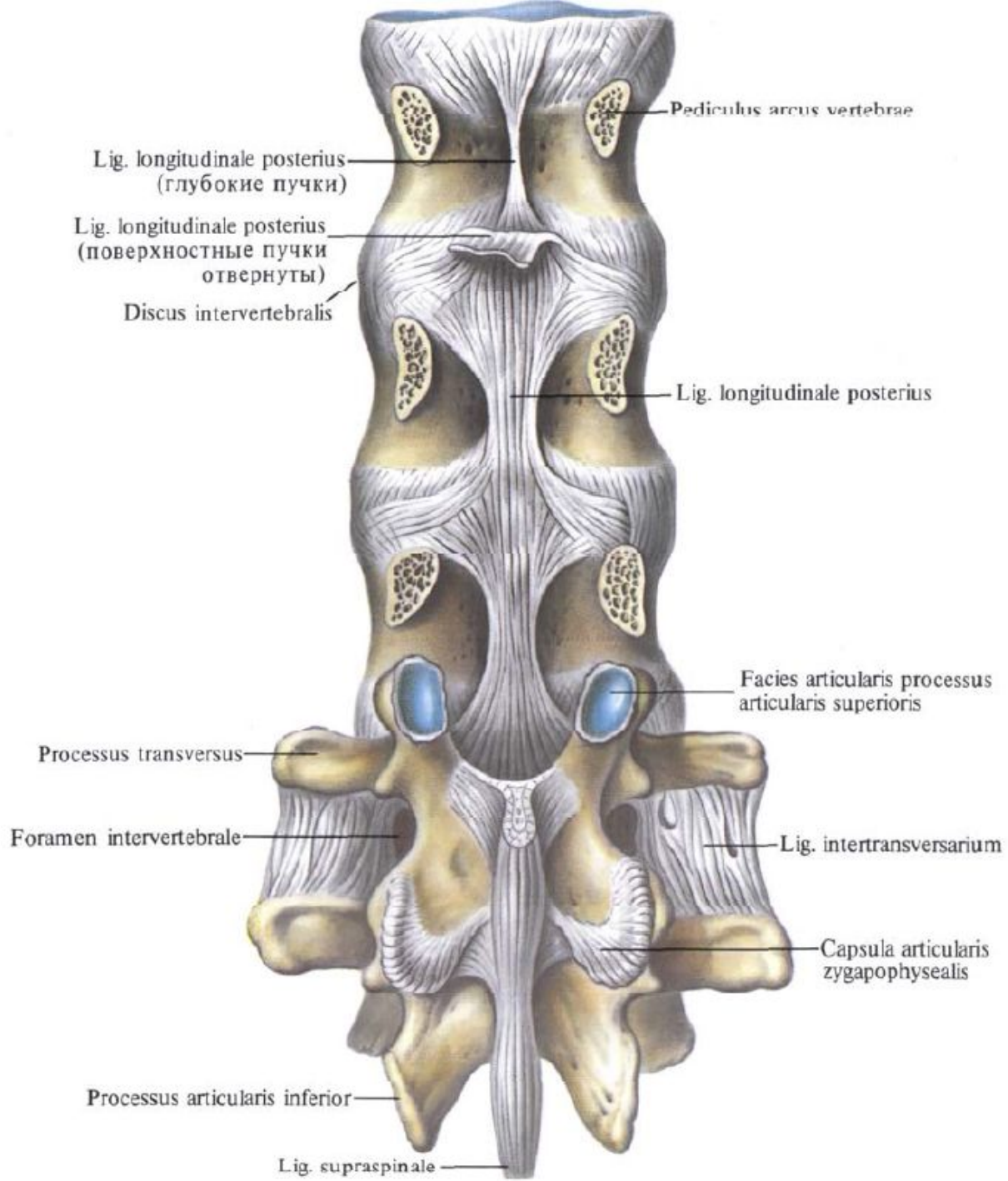
Артрология

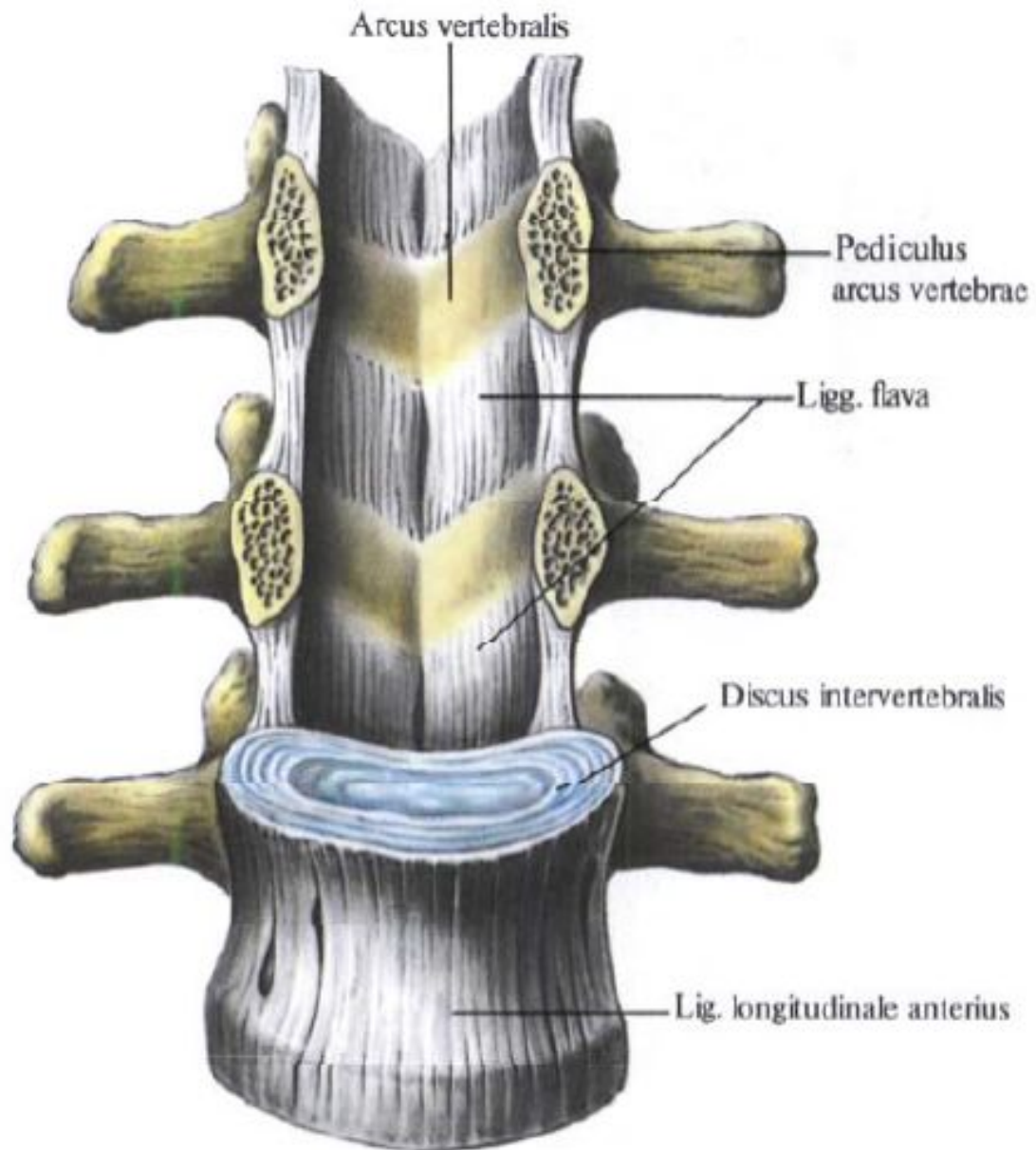
Занятие №1

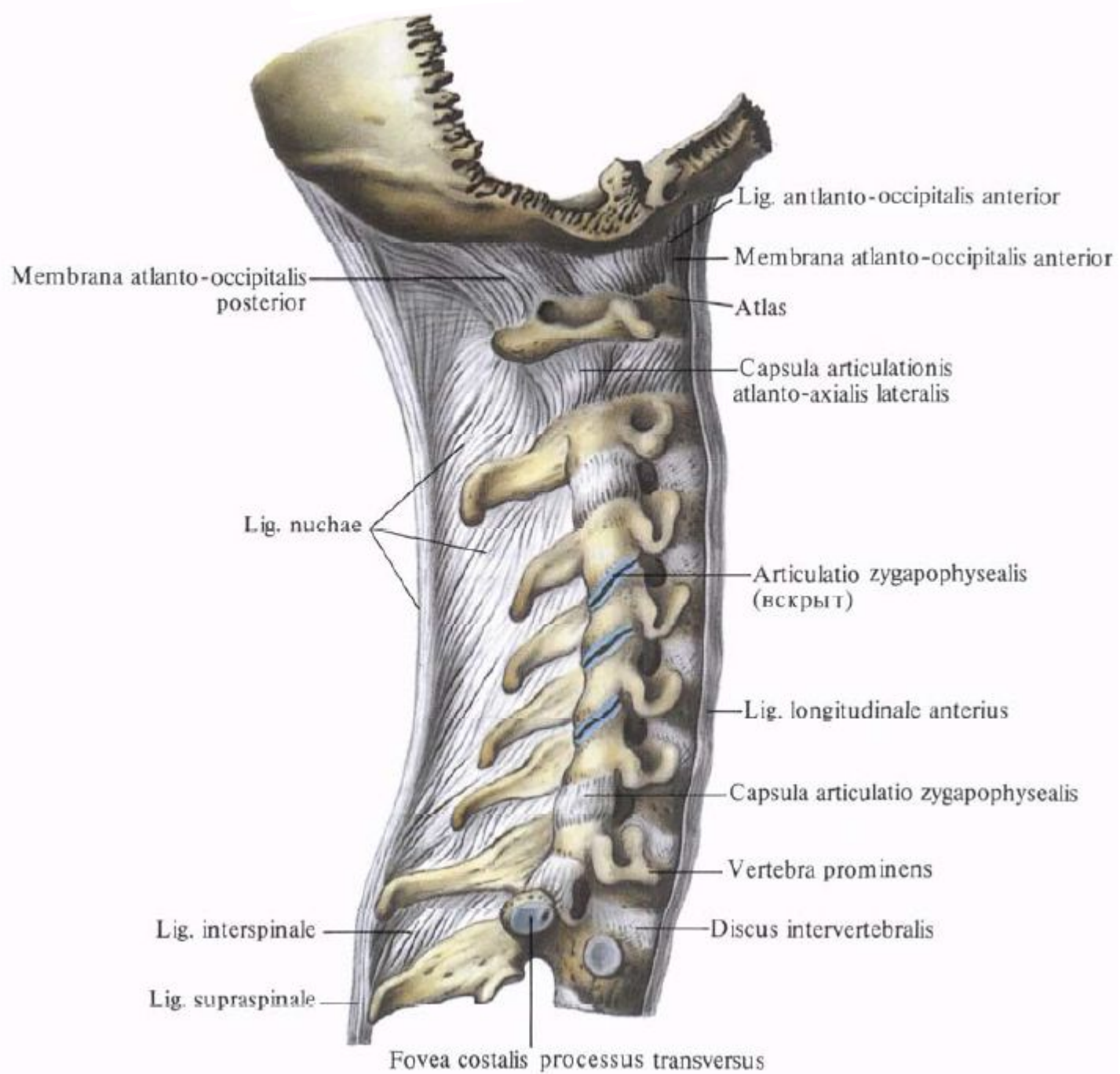
Общая артросиндесмология. Соединение
между позвонками и черепом.
Позвоночный столб в целом.

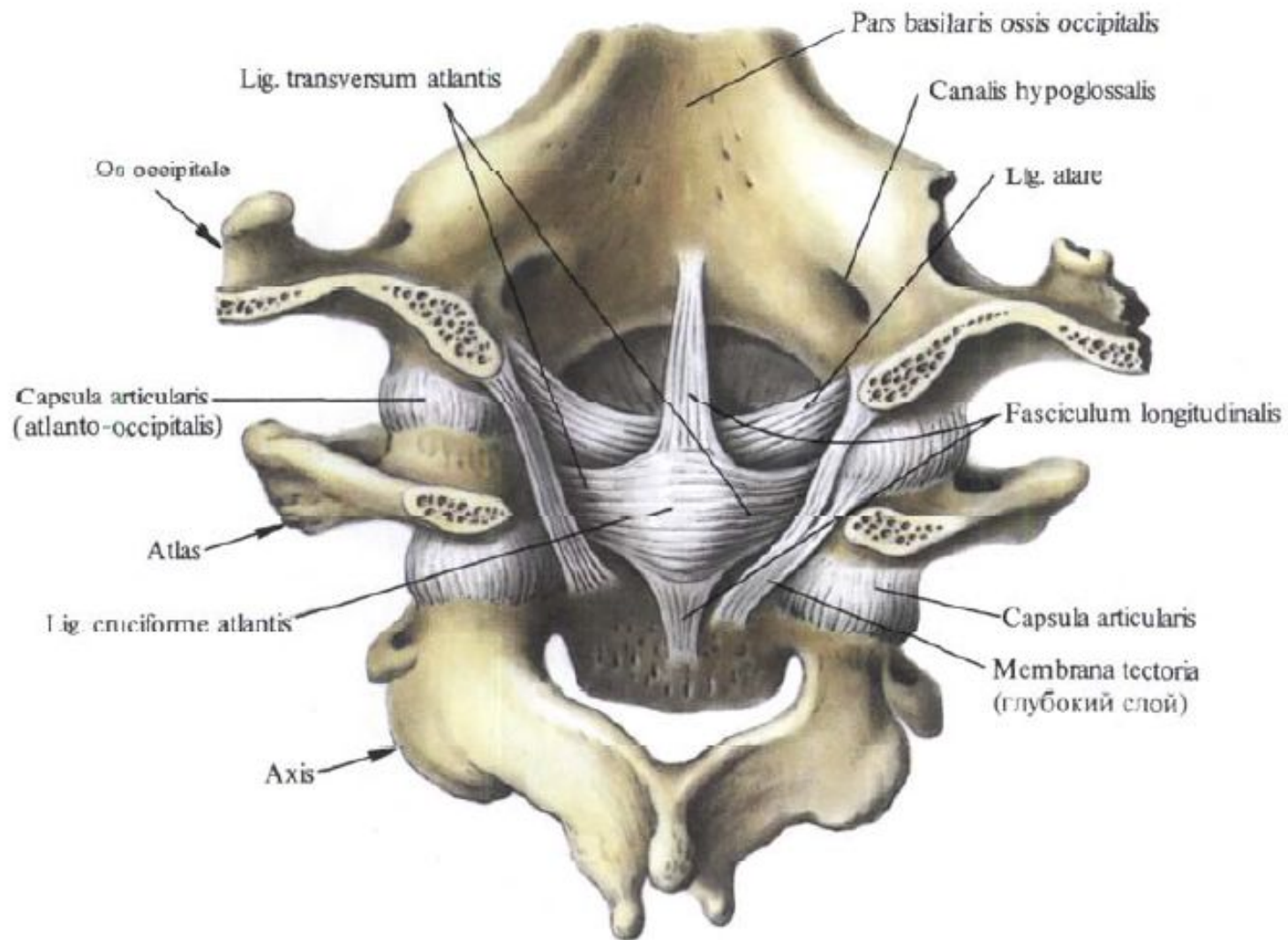


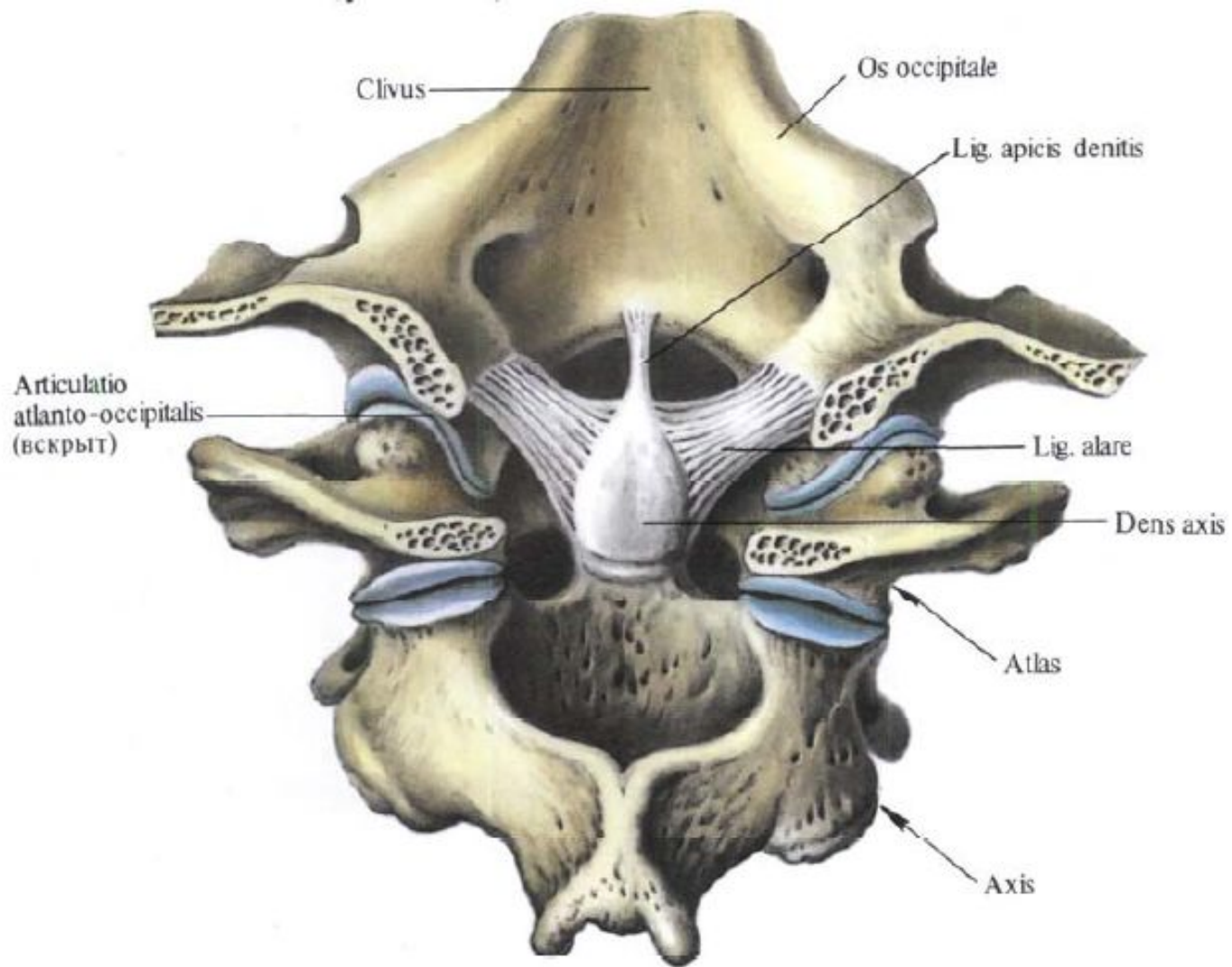


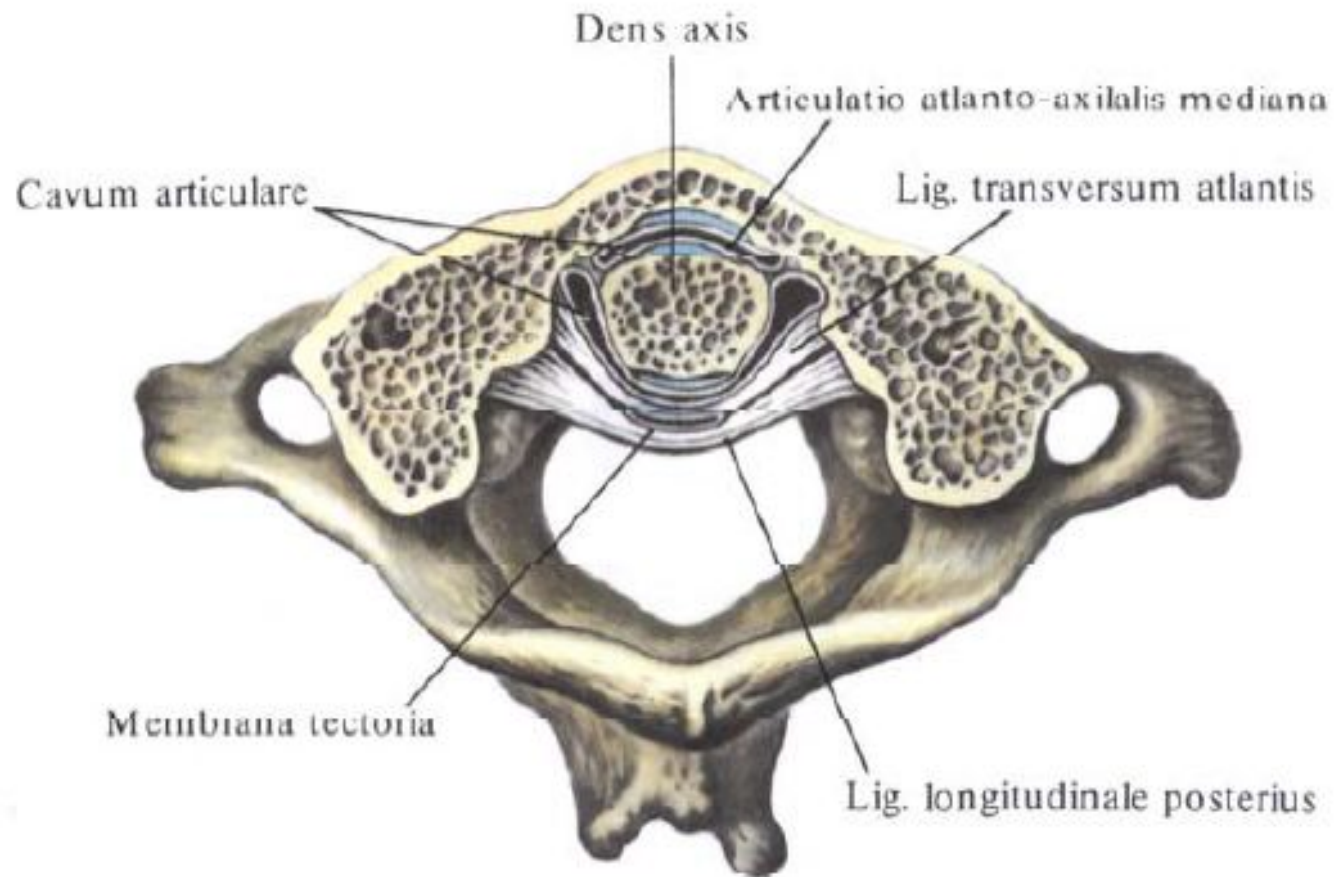






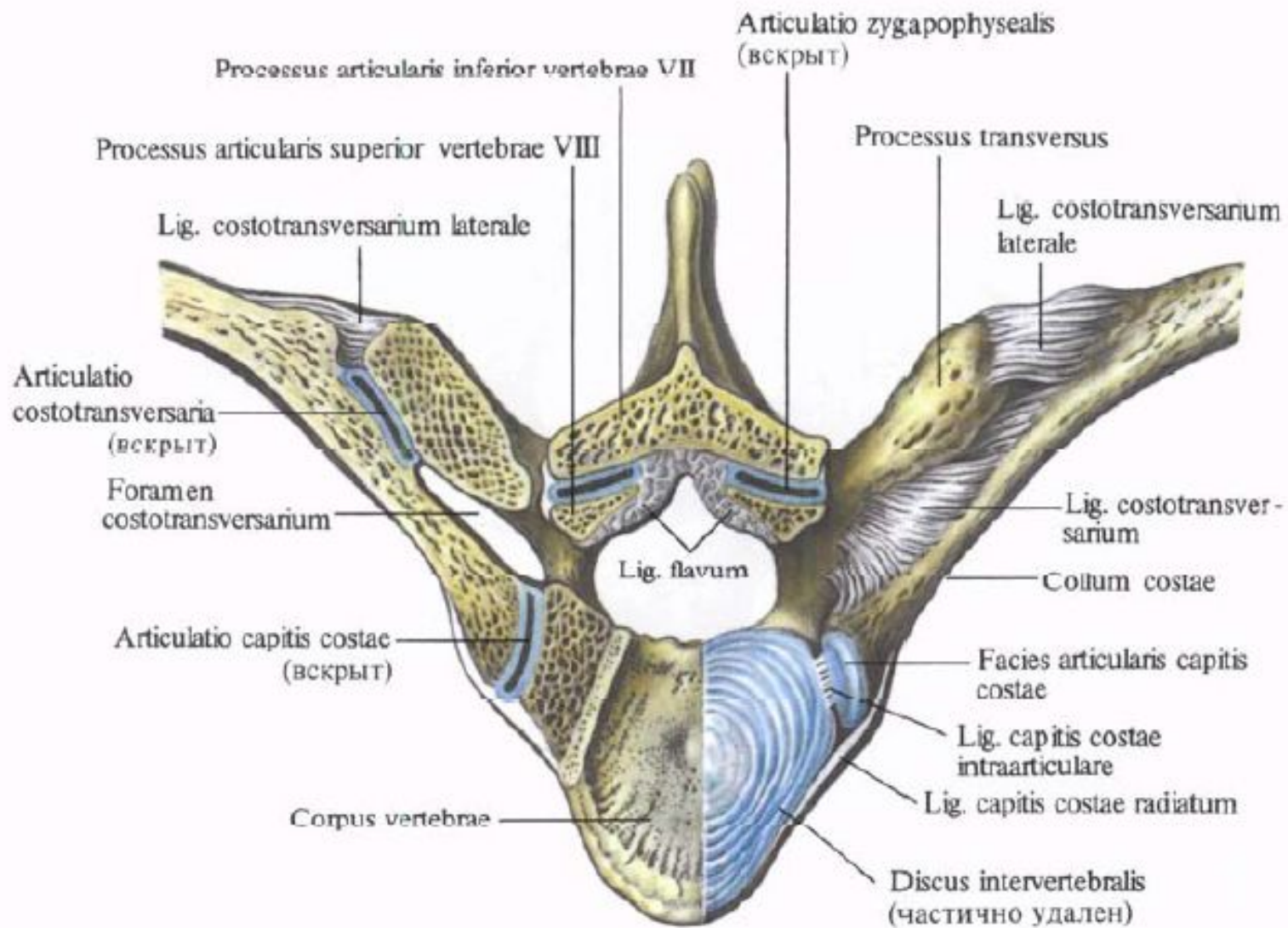


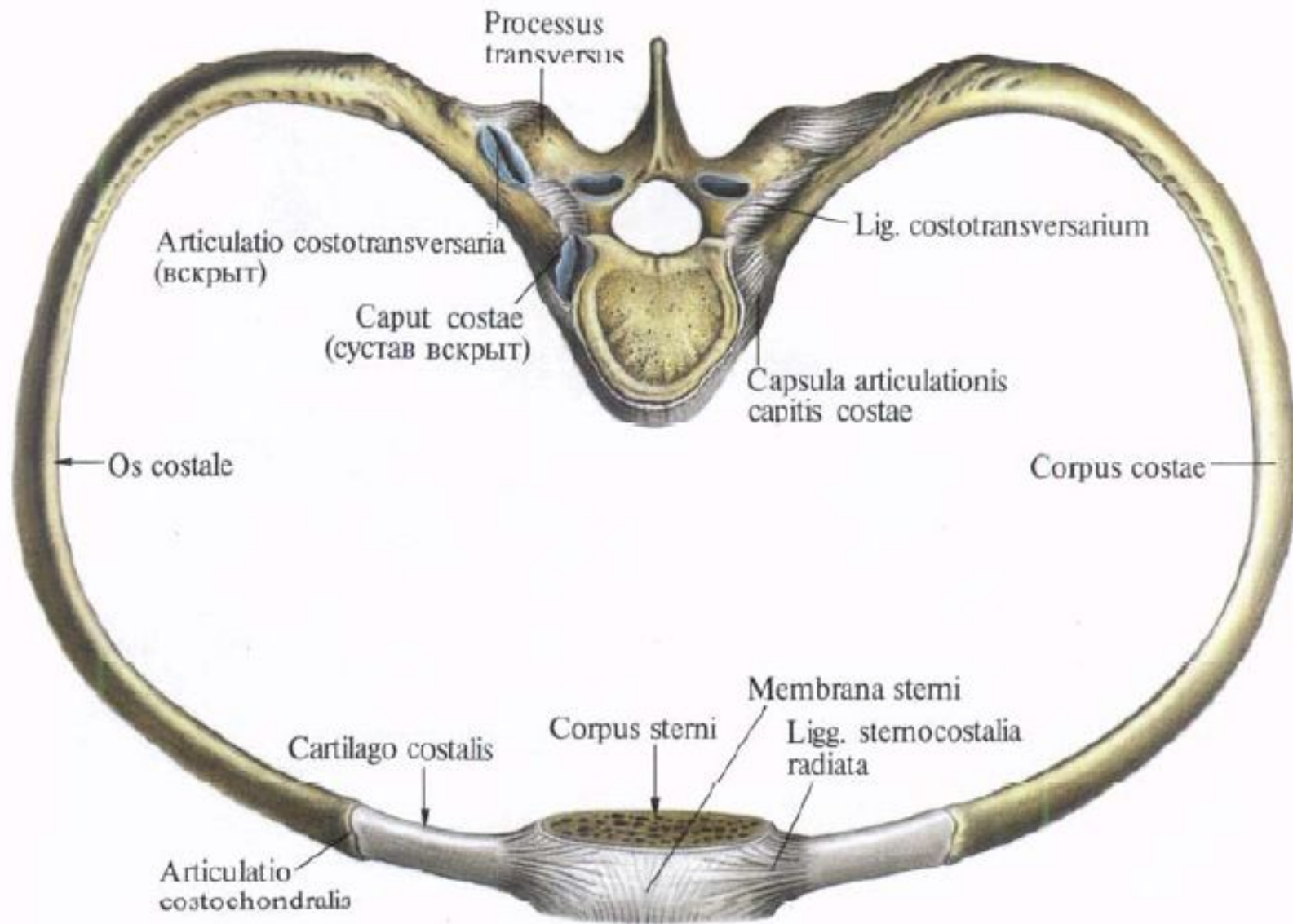


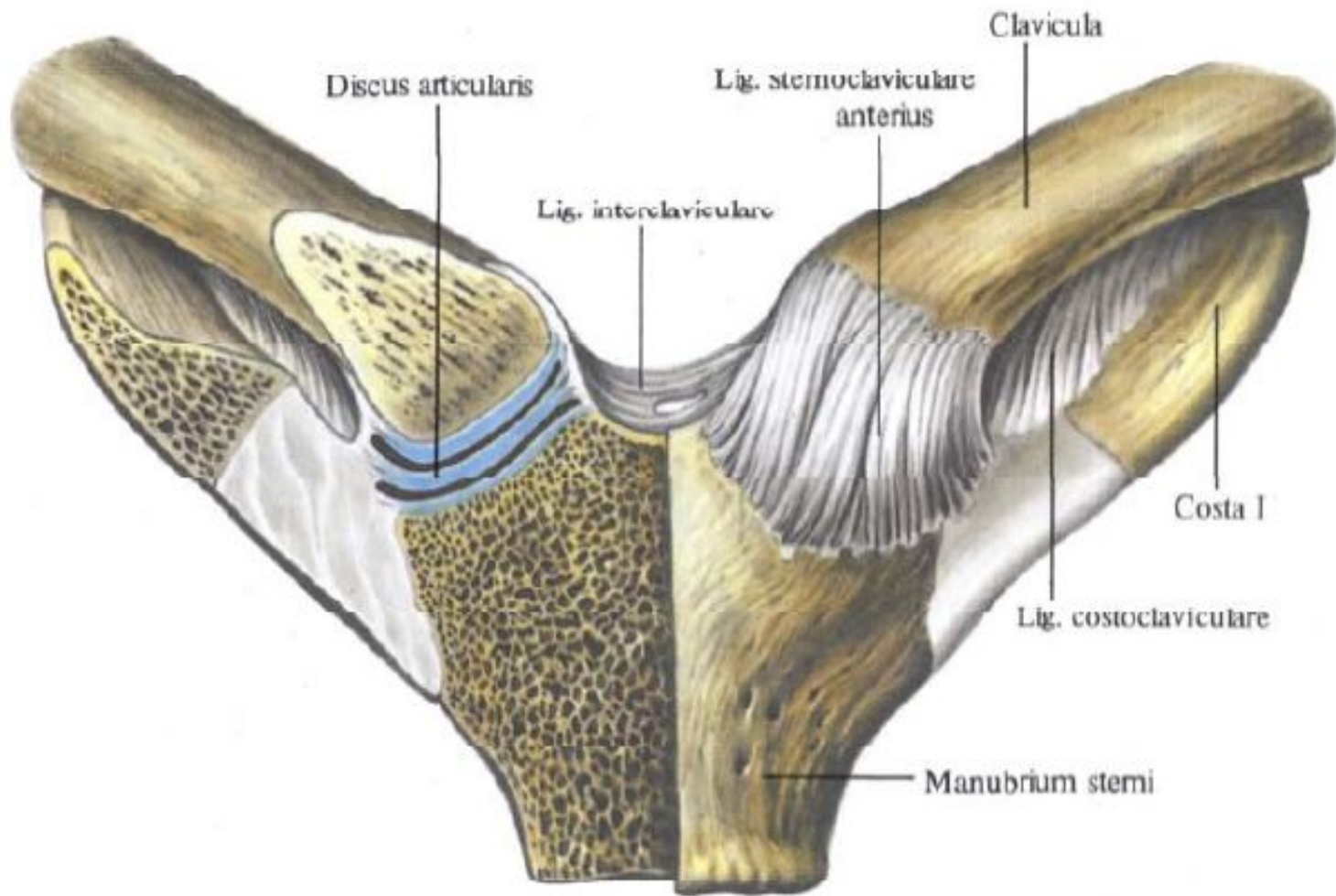


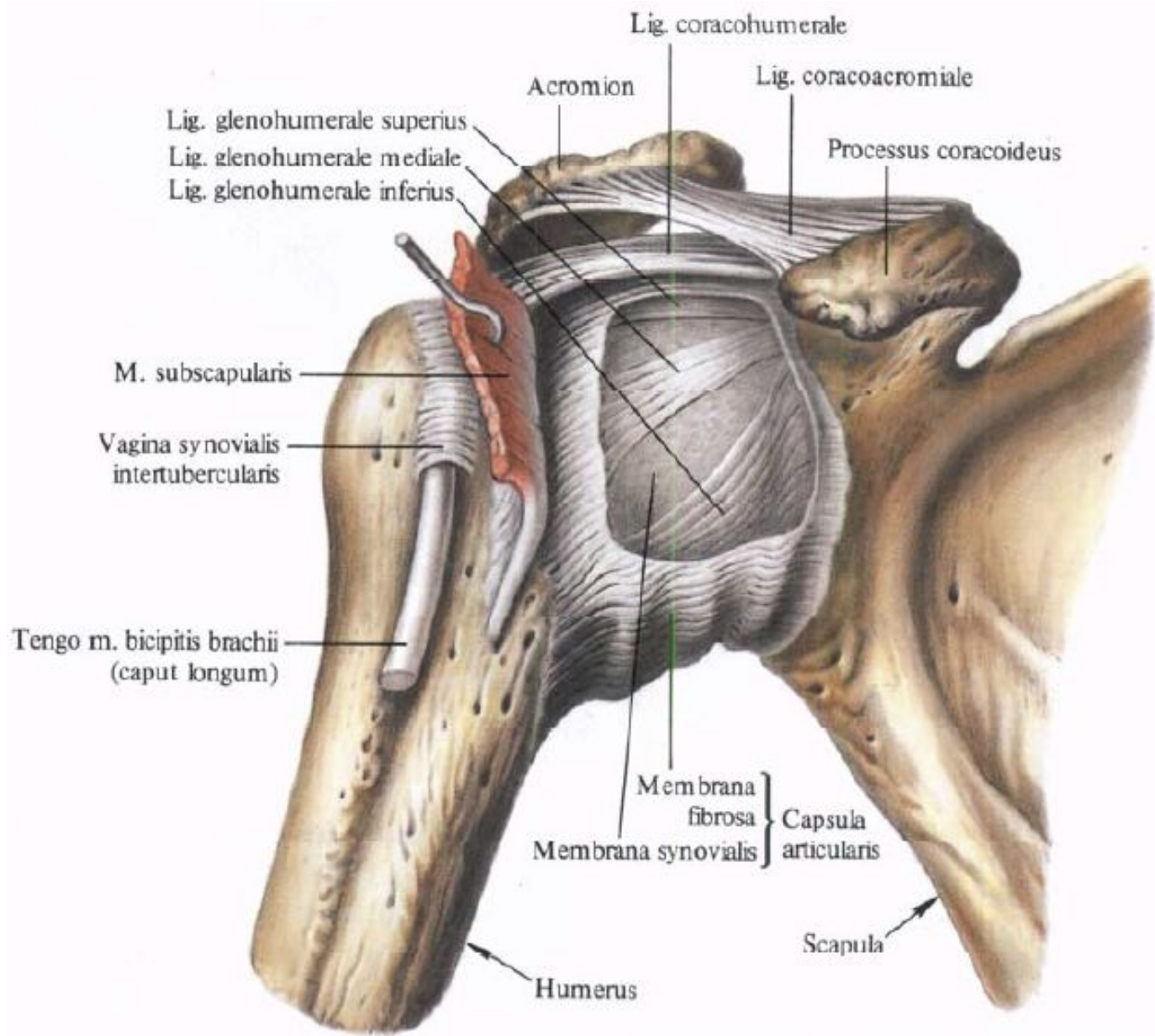
Занятие №2

Соединение ребер с позвонками, грудиной, между собой. Грудная клетка в целом. Соединение костей пояса верхней конечности и плечевой сустав.









Lig. coracohumerale

Acromion

Lig. coracoacromiale

Lig. glenohumerale superius

Lig. glenohumerale mediale

Lig. glenohumerale inferius

Processus coracoideus

M. subscapularis

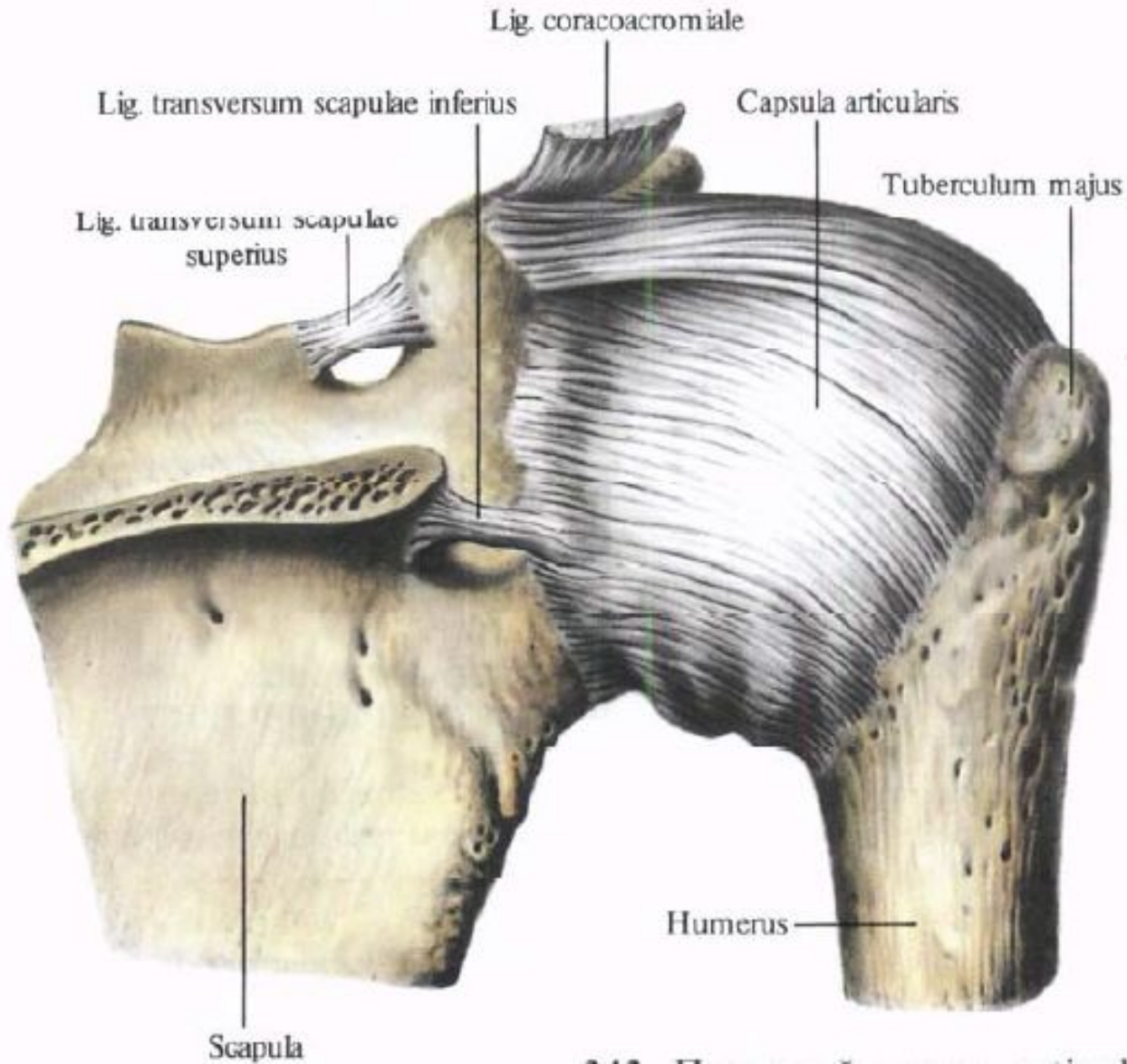
Vagina synovialis
intertubercularis

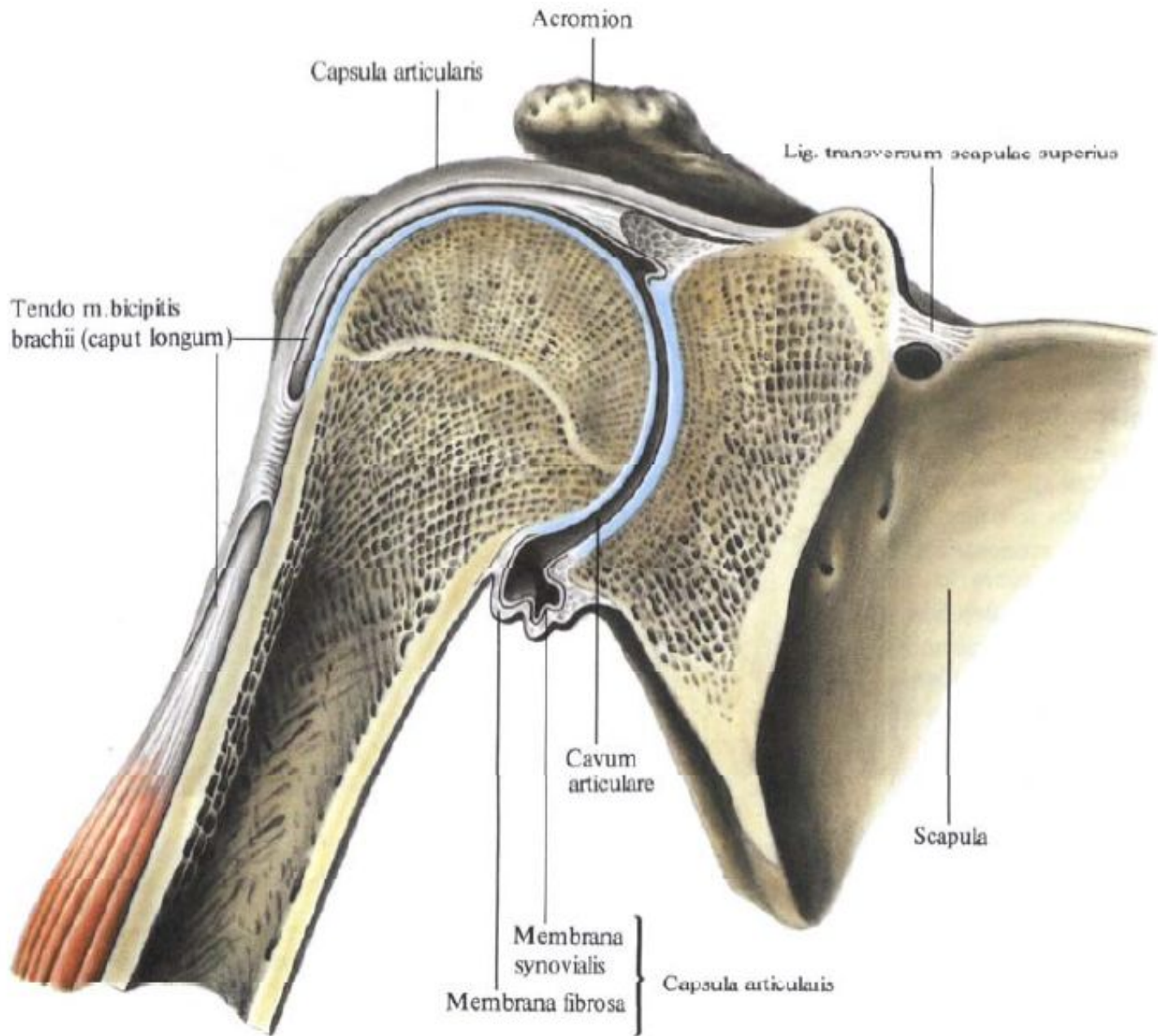
Tengo m. bicipitis brachii
(caput longum)

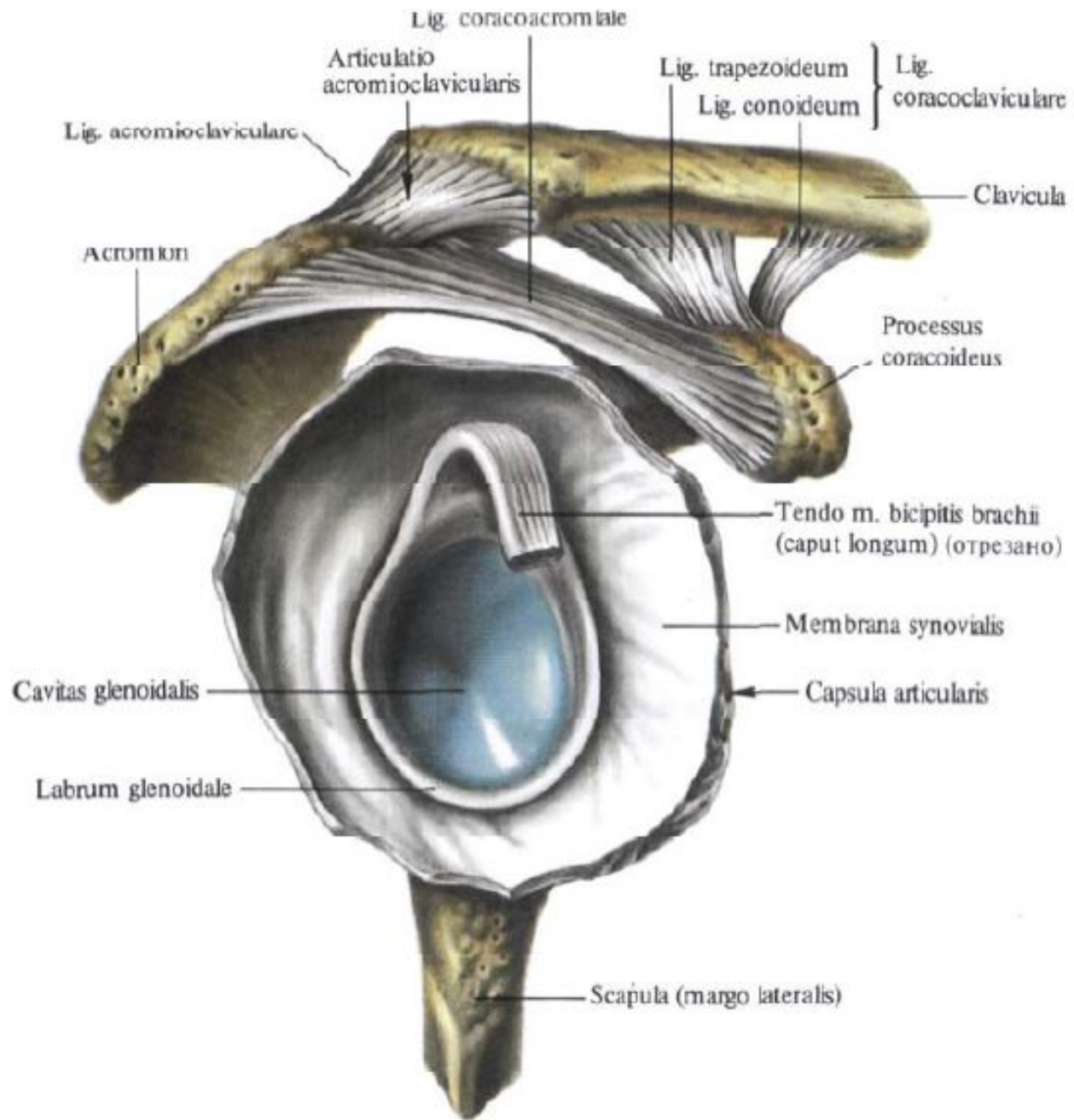
Membrana fibrosa }
Membrana synovialis } Capsula articularis

Humerus

Scapula

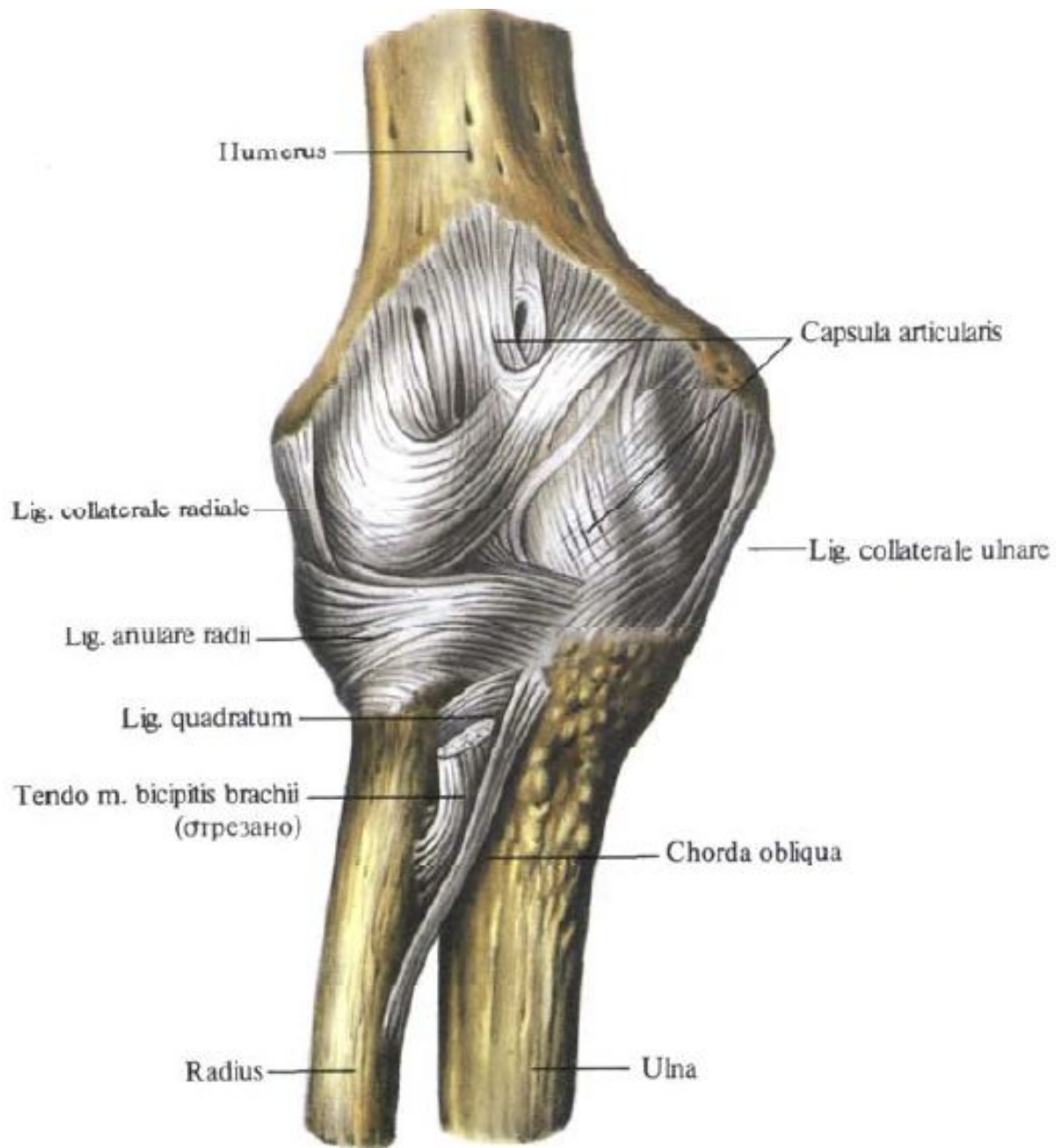


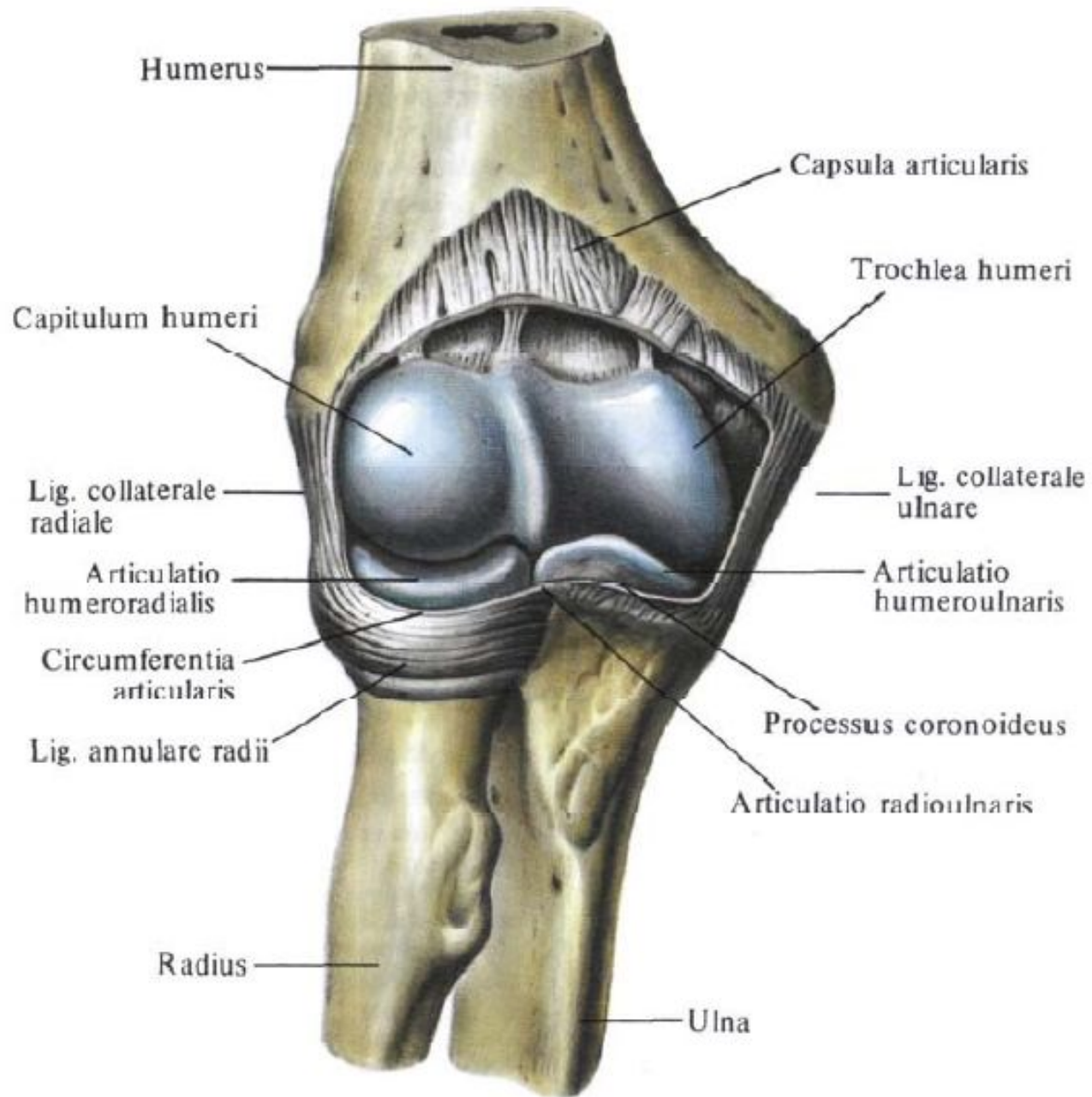


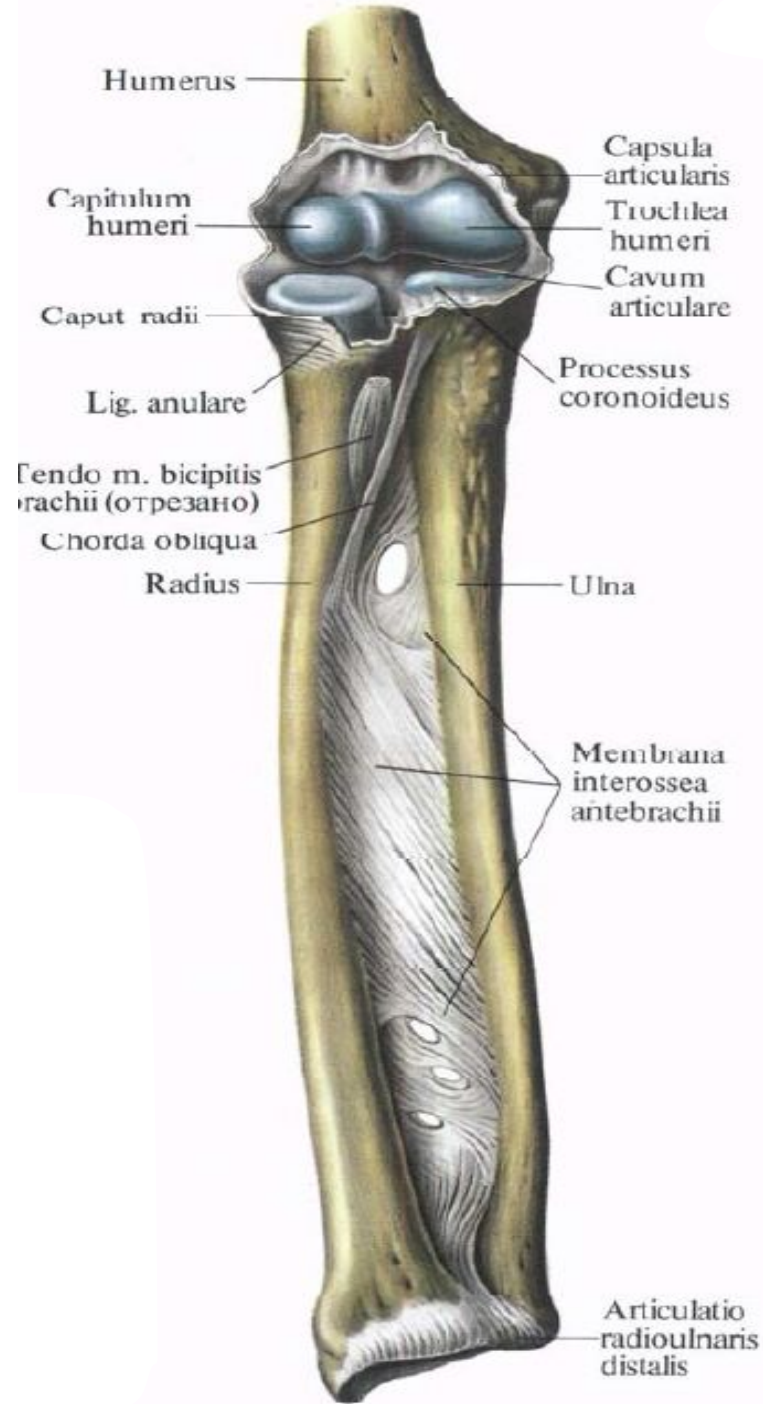


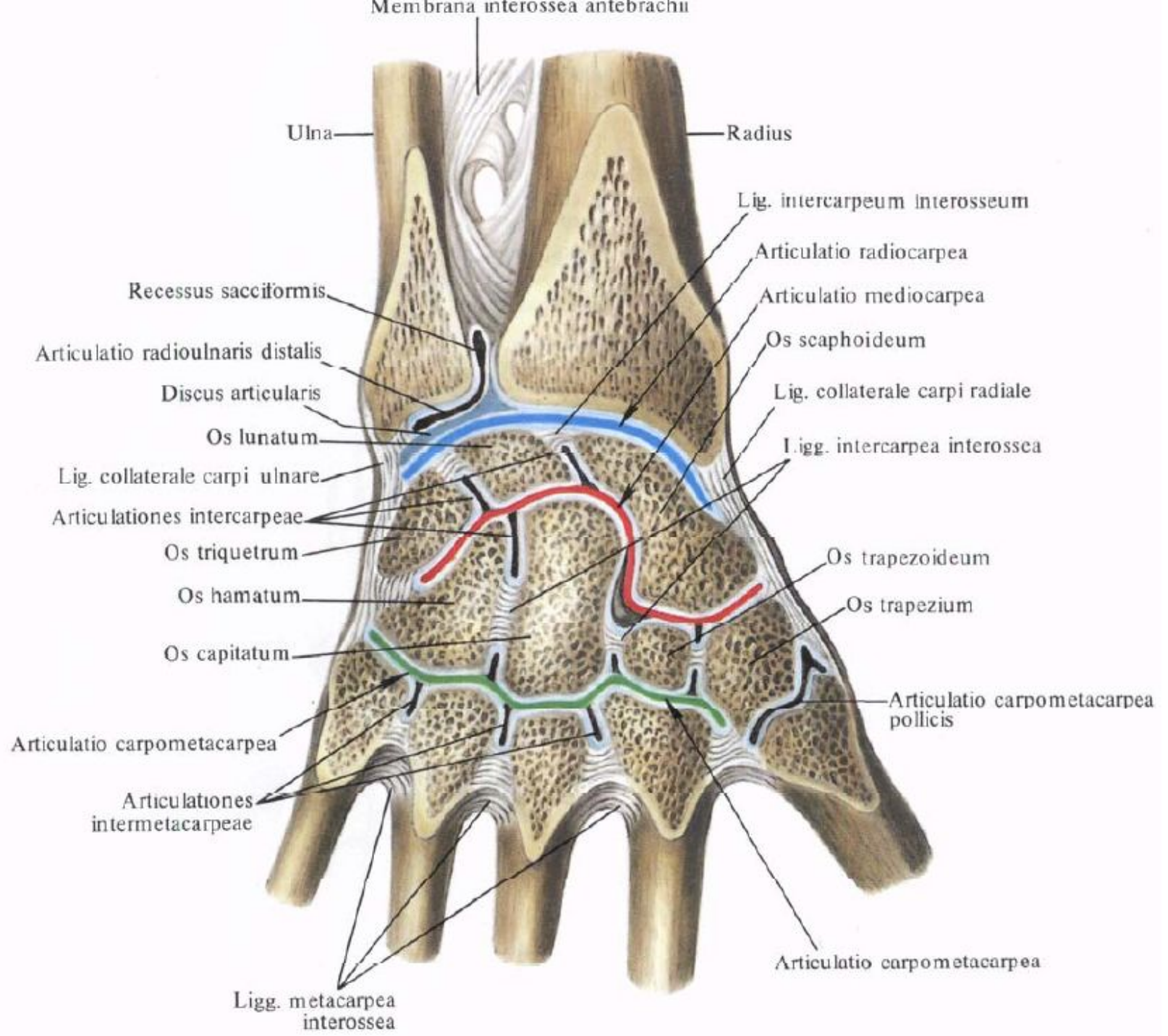
Занятие №3

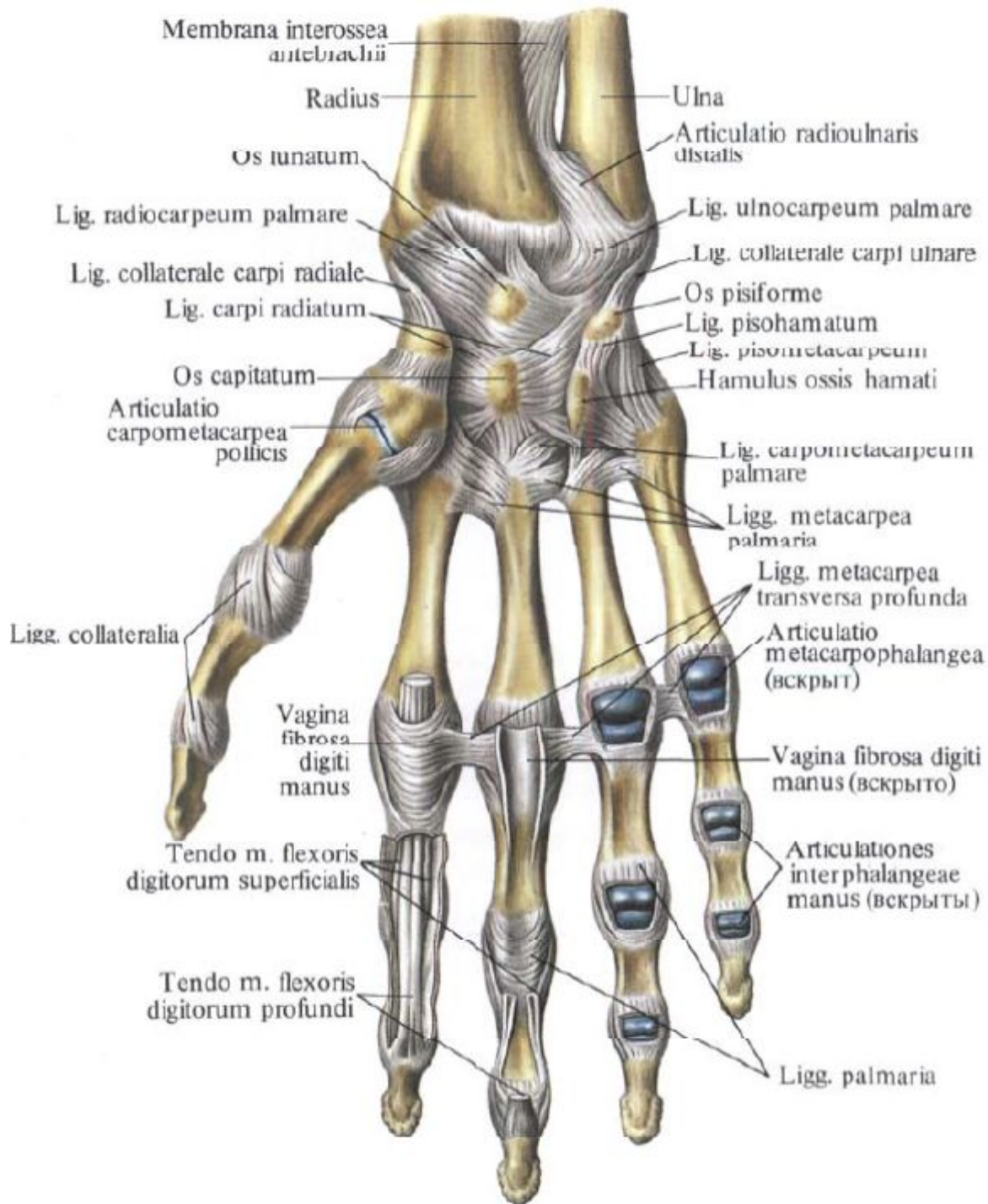
Локтевой сустав, лучезапястный сустав,
суставы кисти.

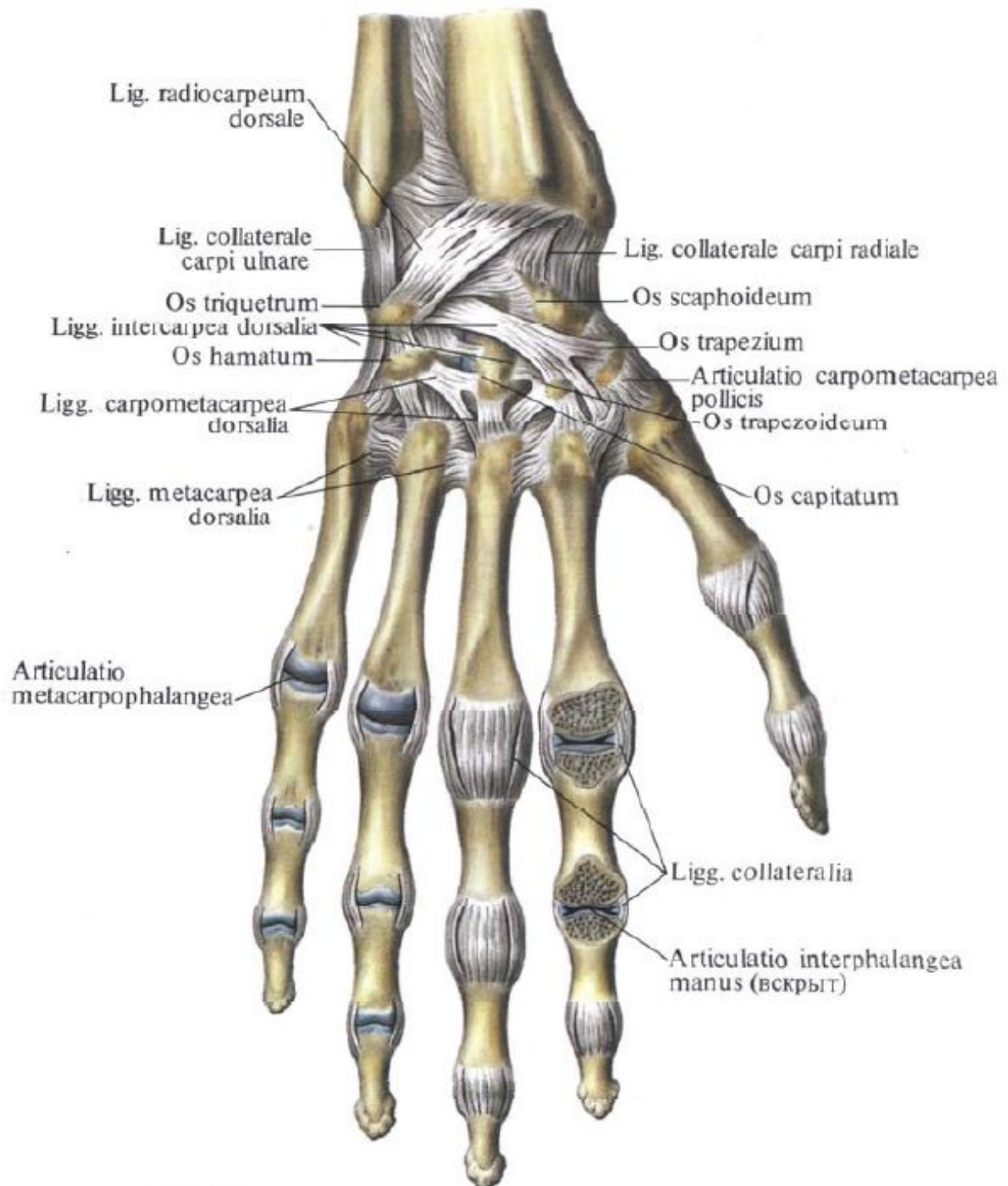






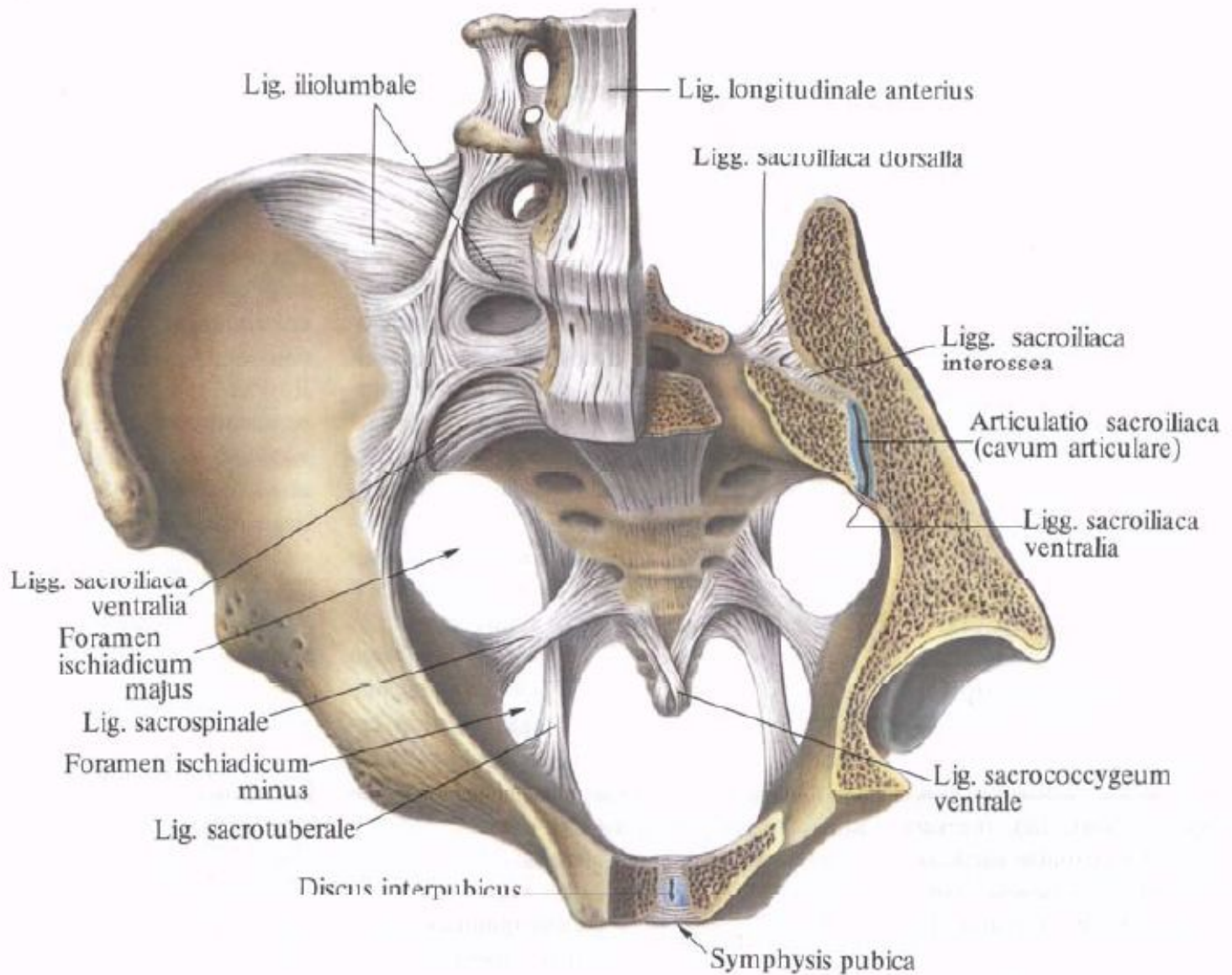


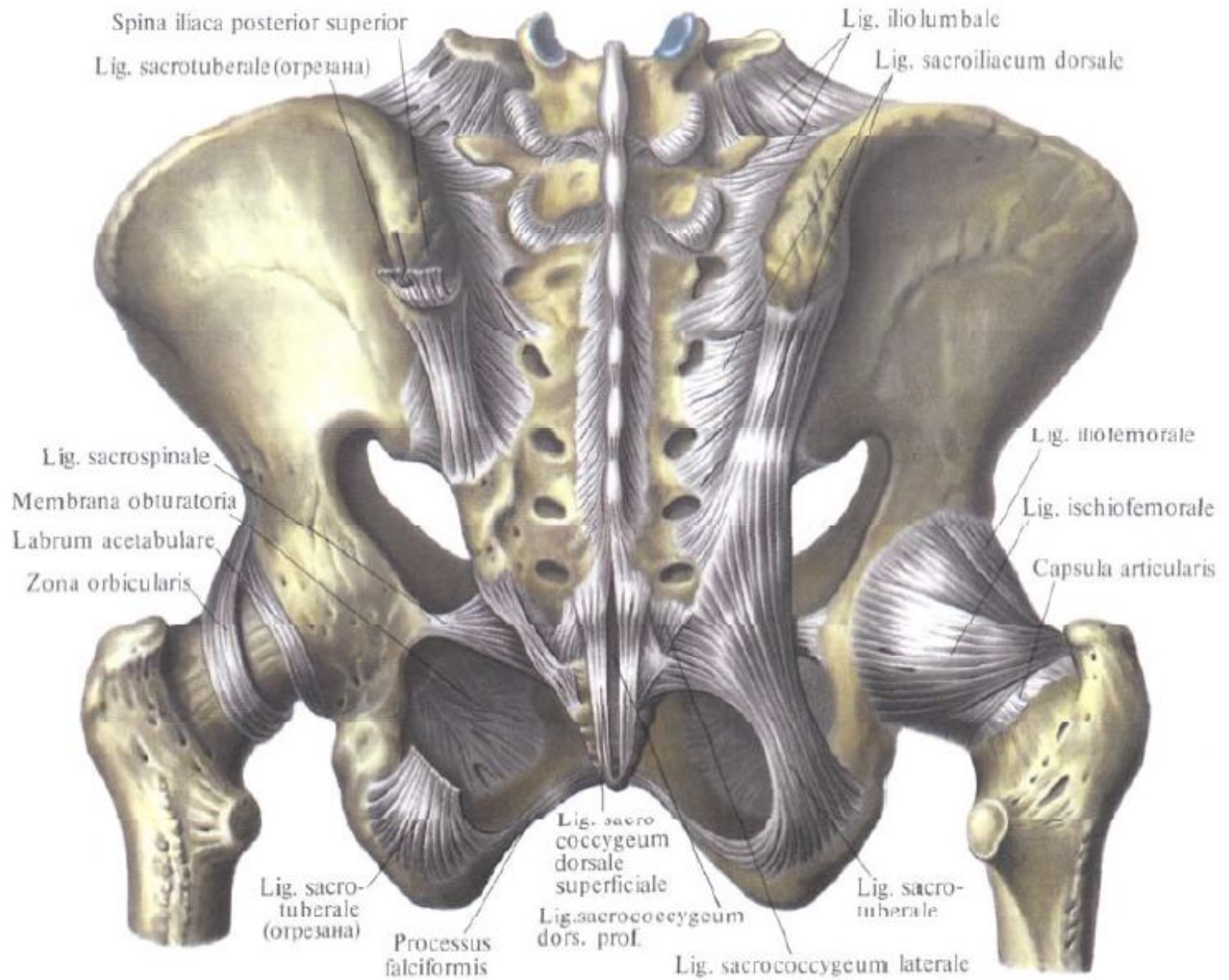


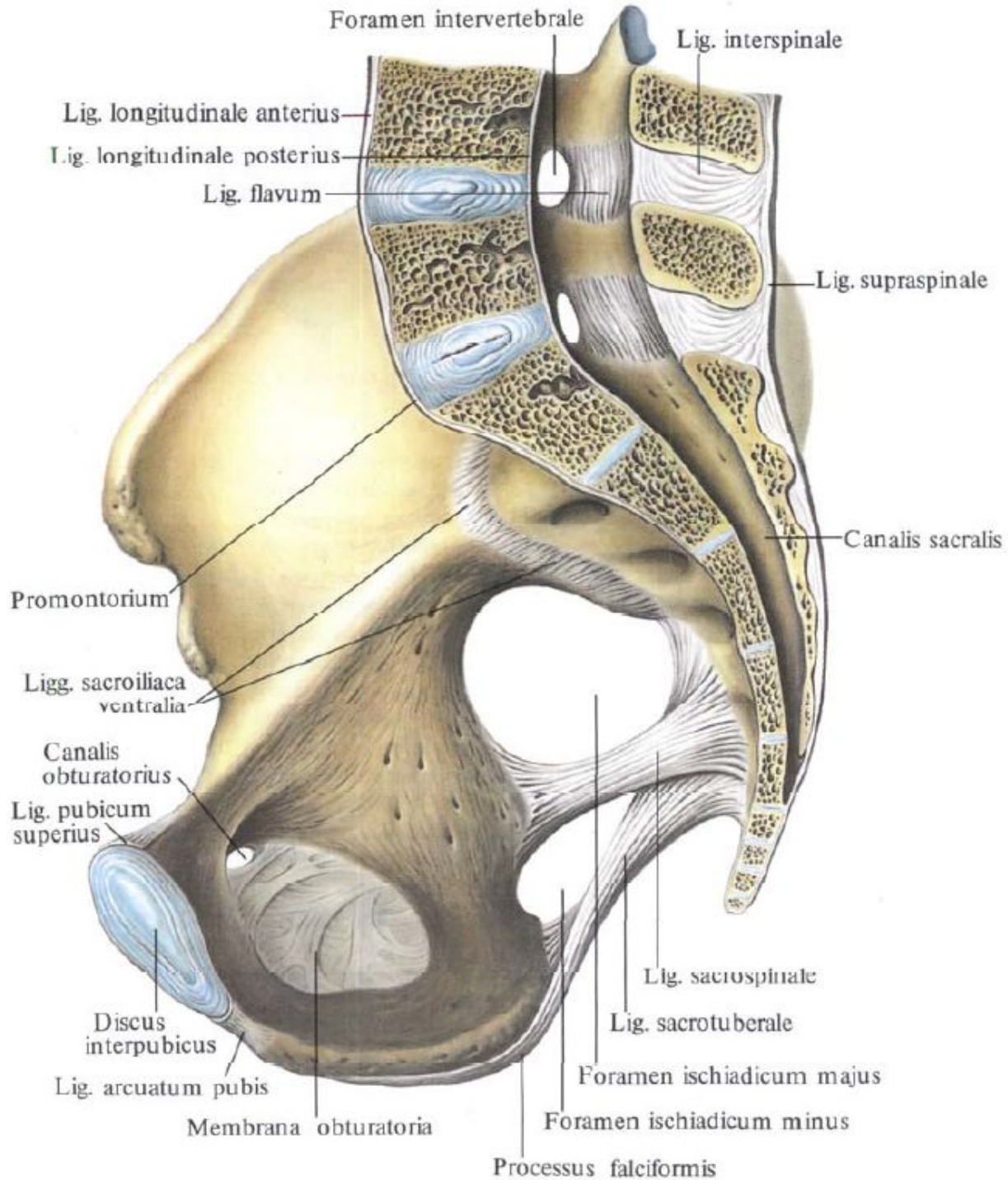


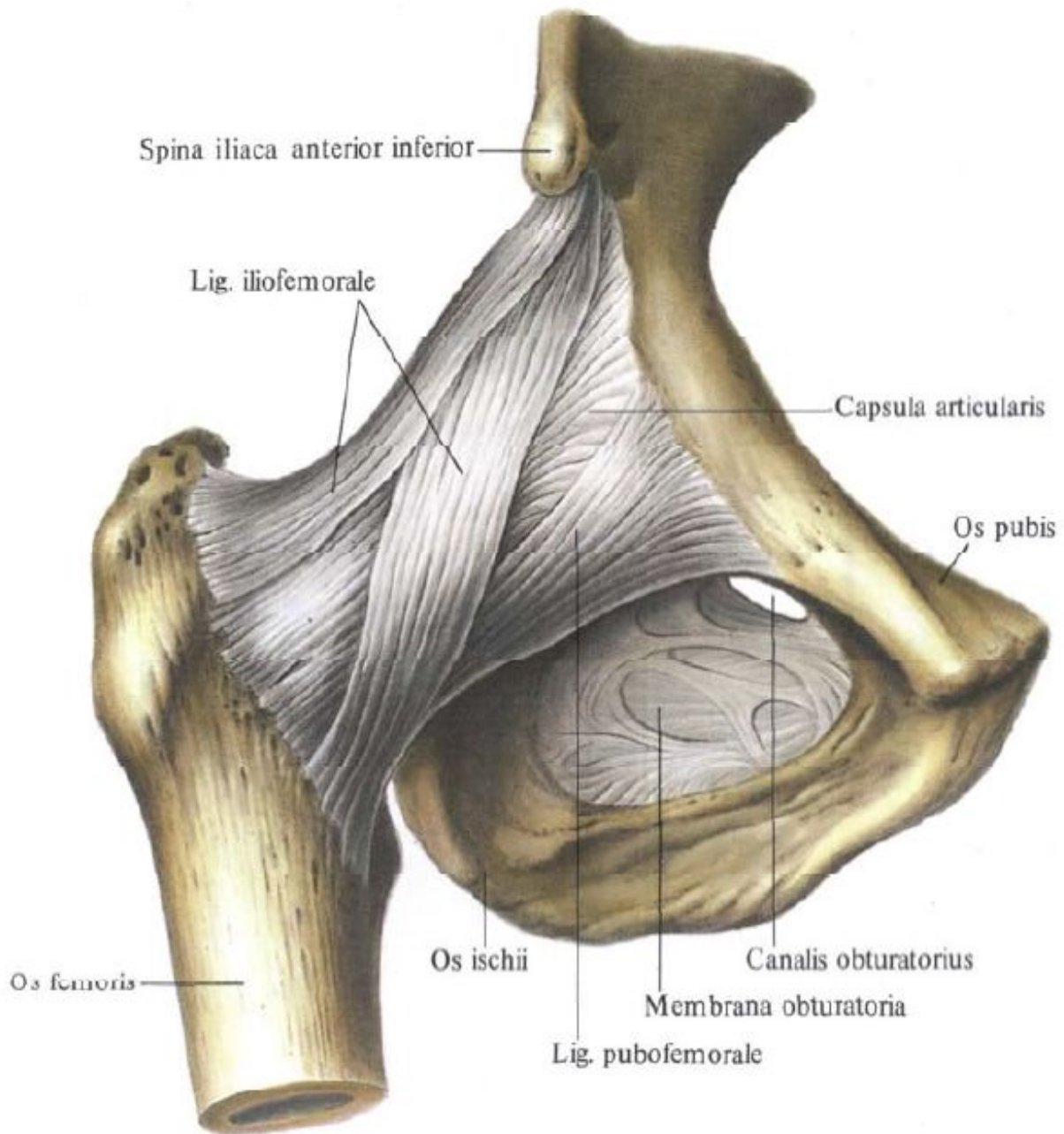
Занятие №4

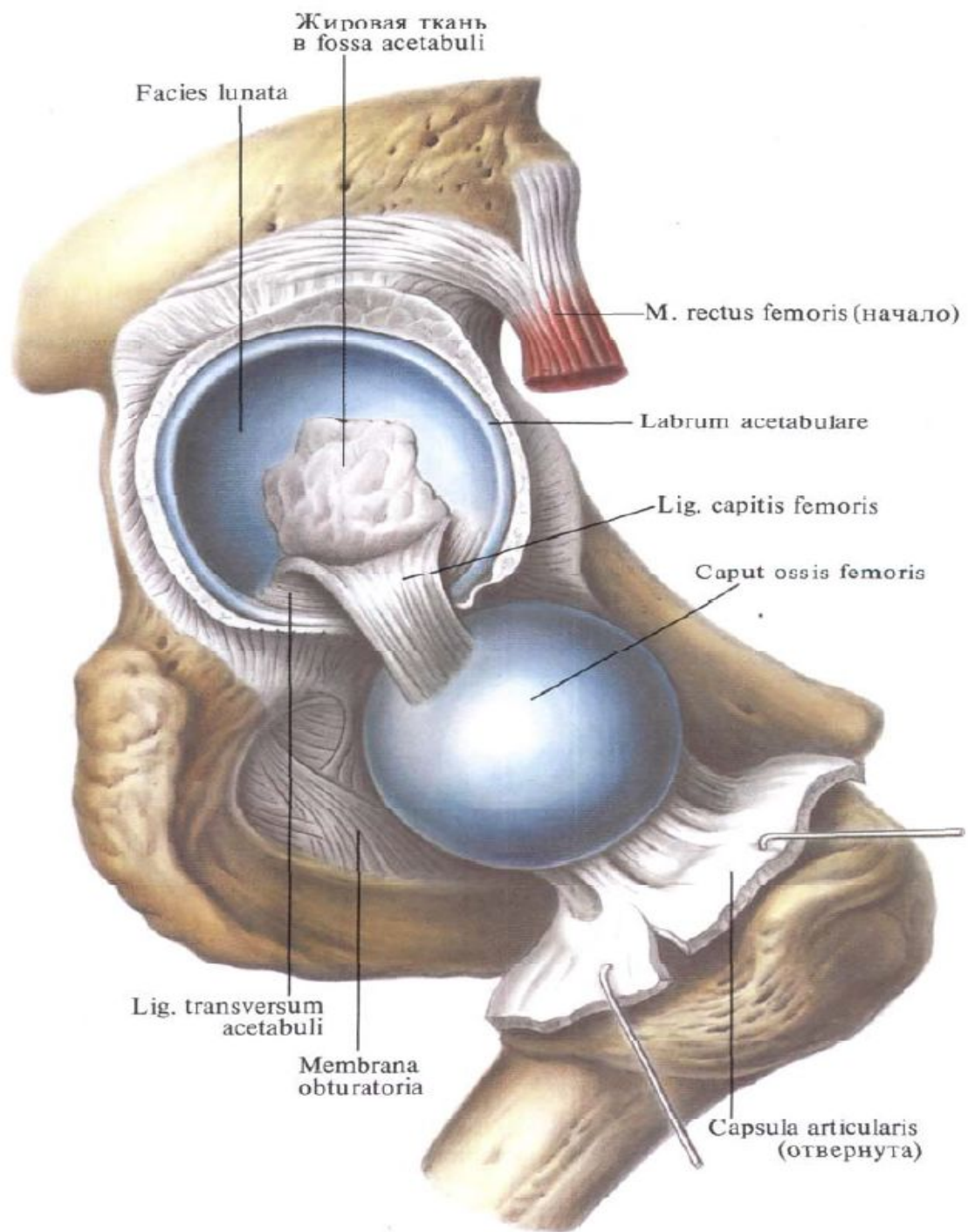
Соединение костей таза. Тазобедренный
сустав.





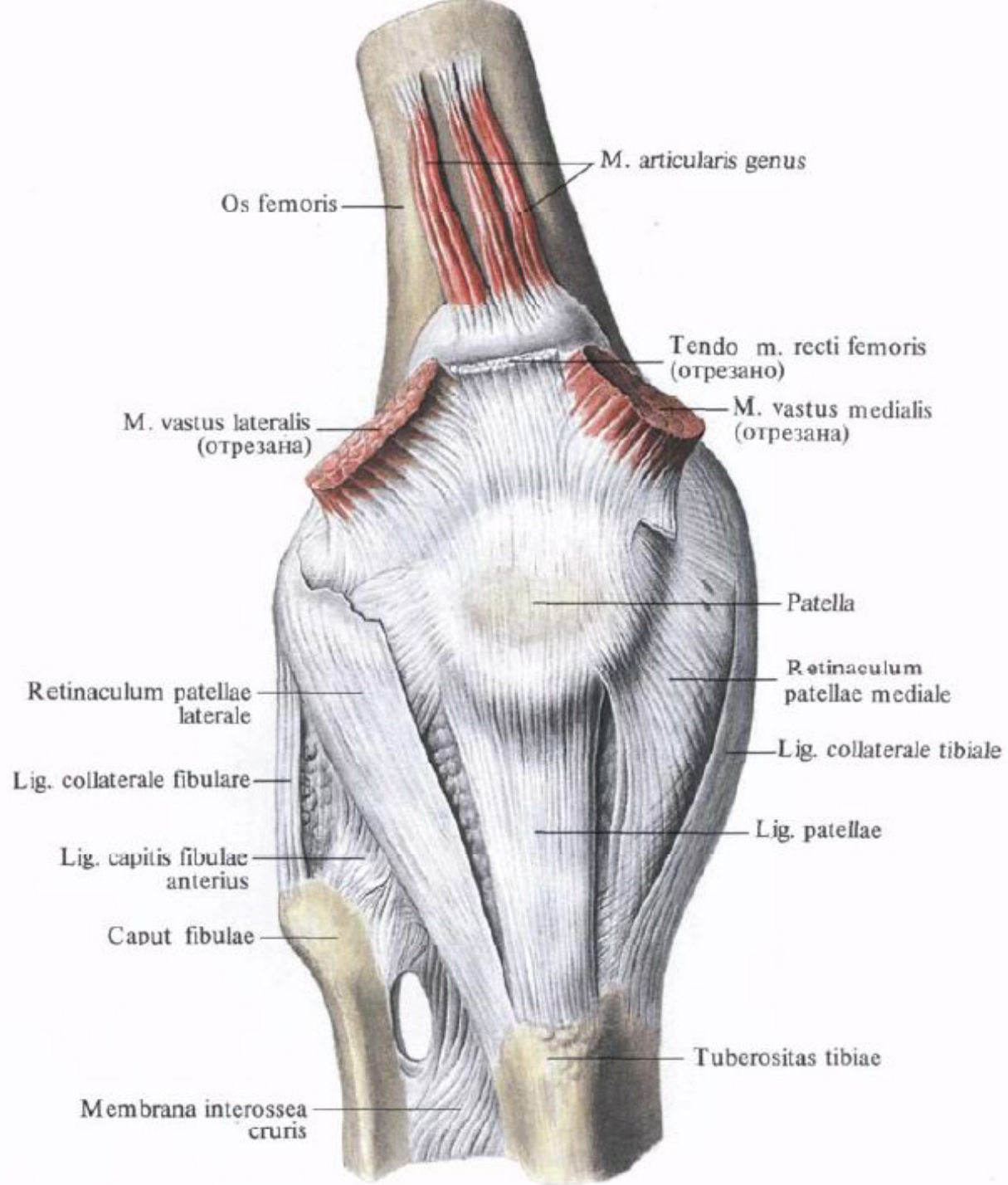


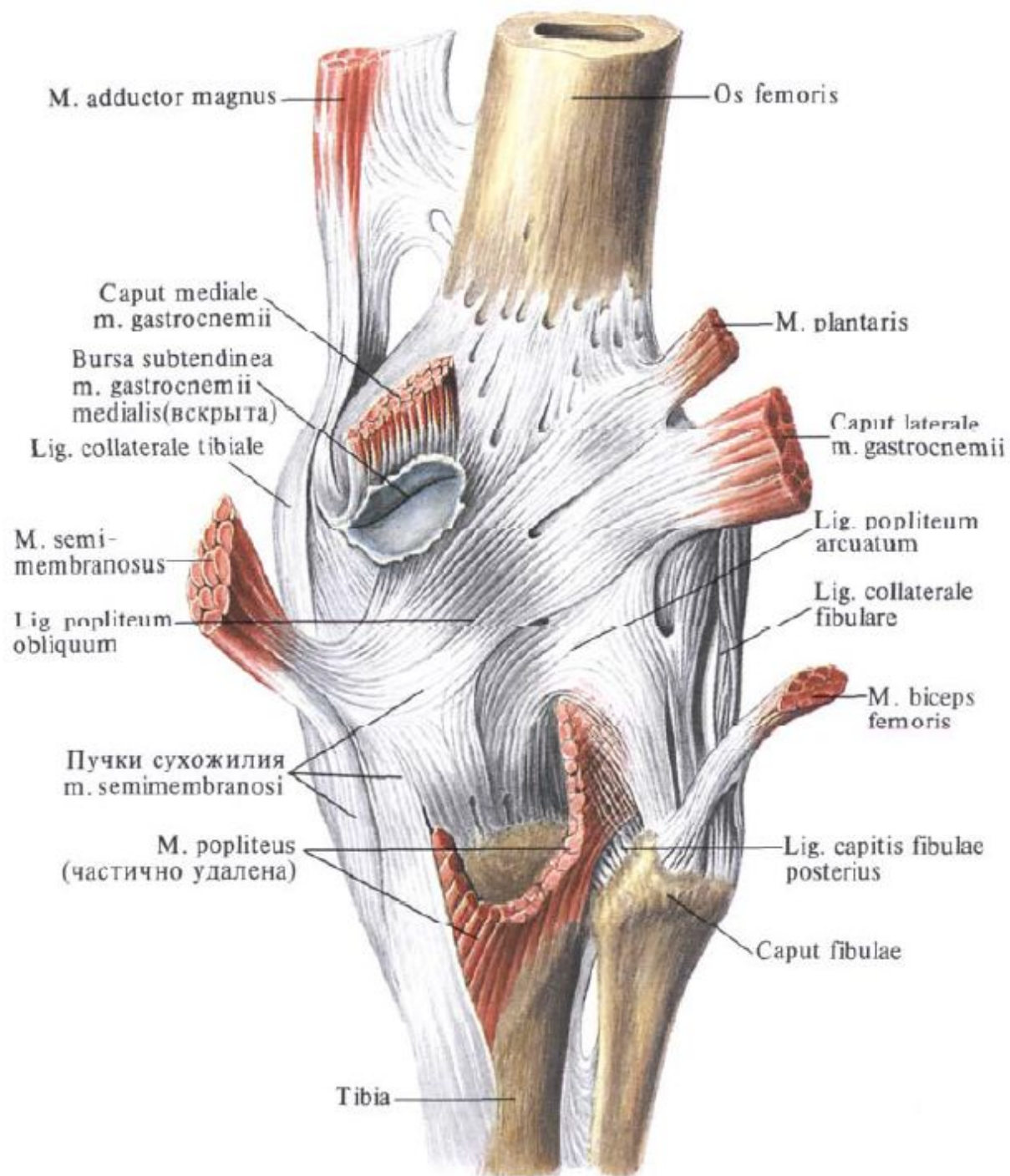


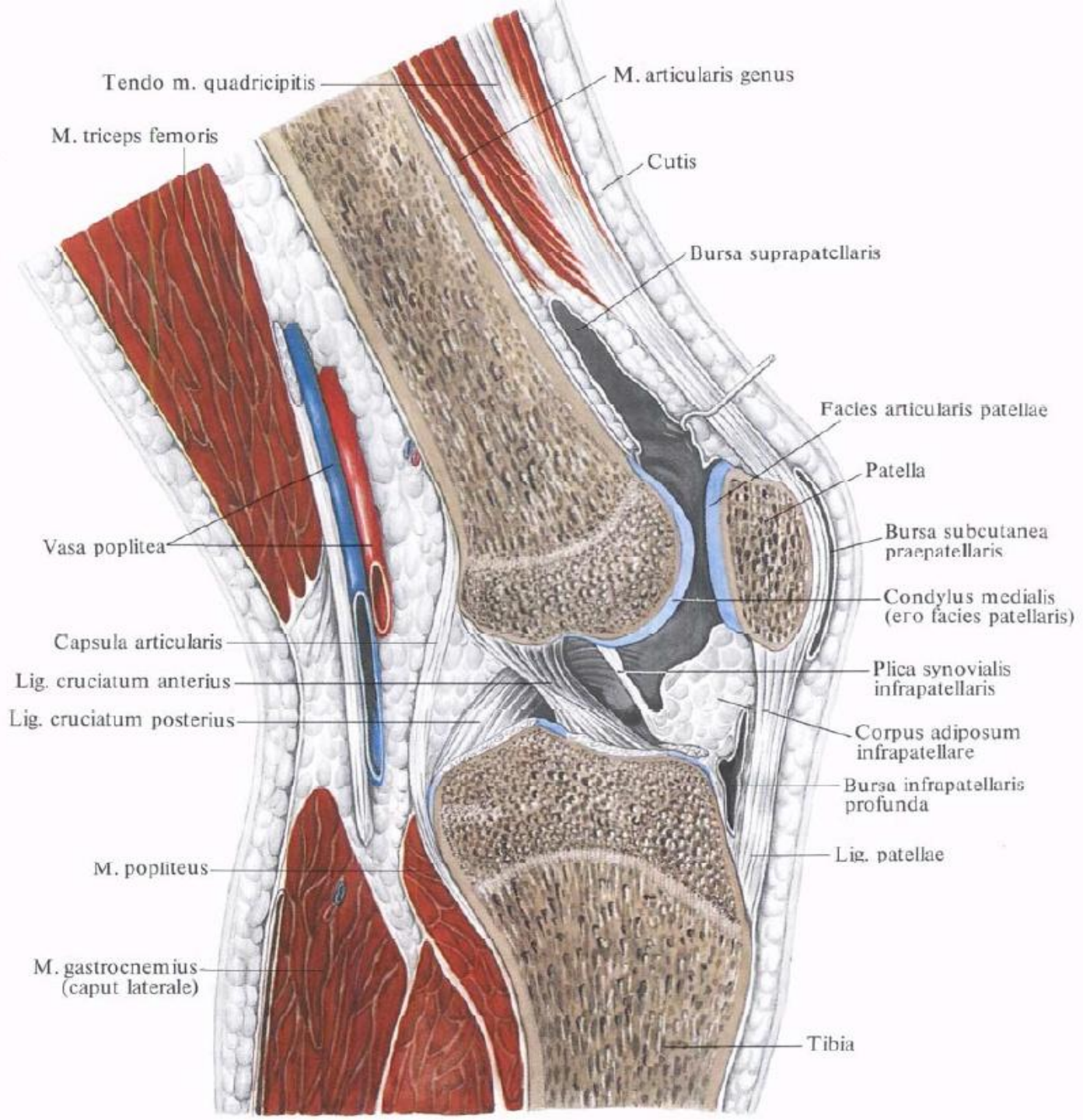


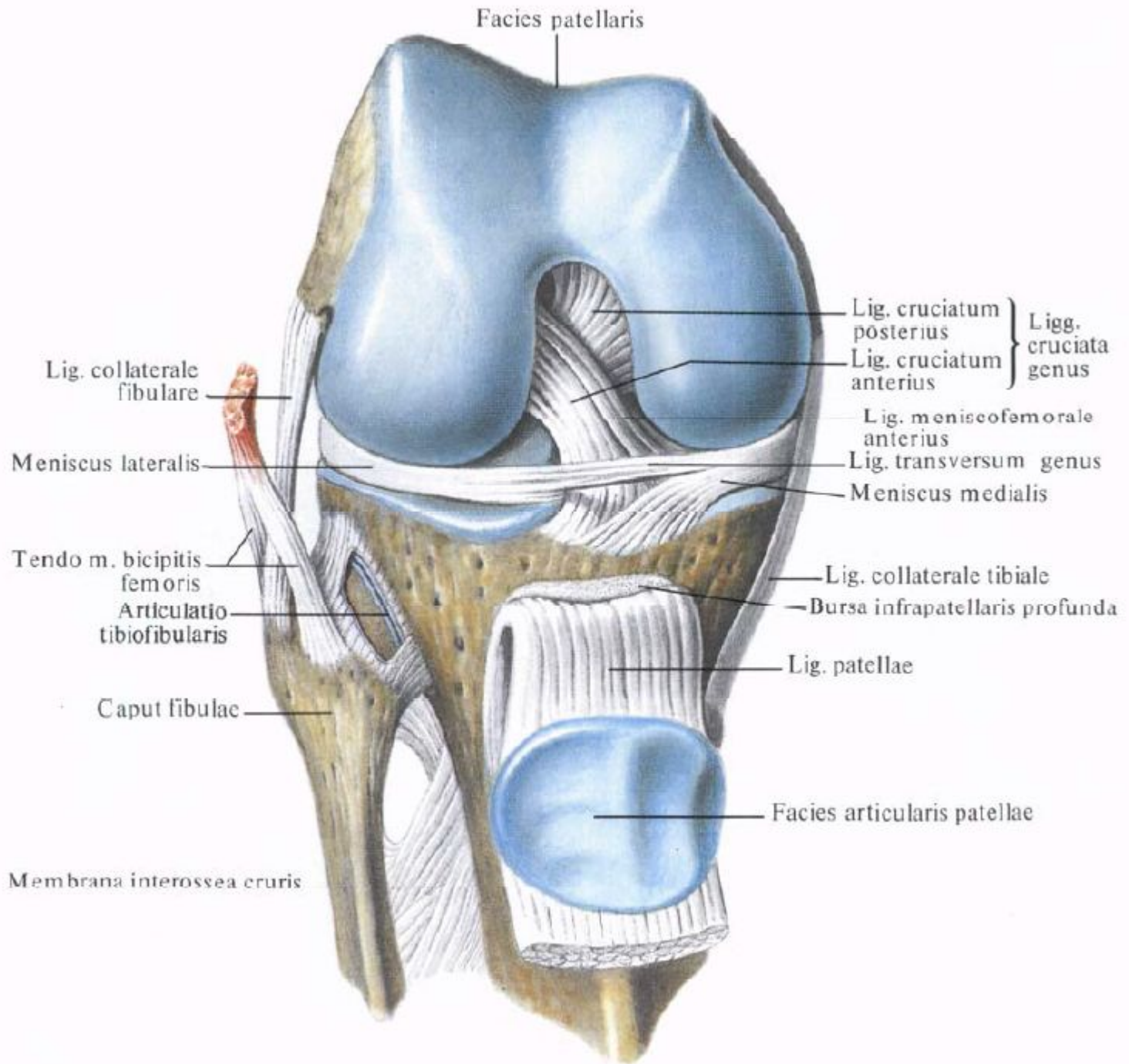
Занятие №5

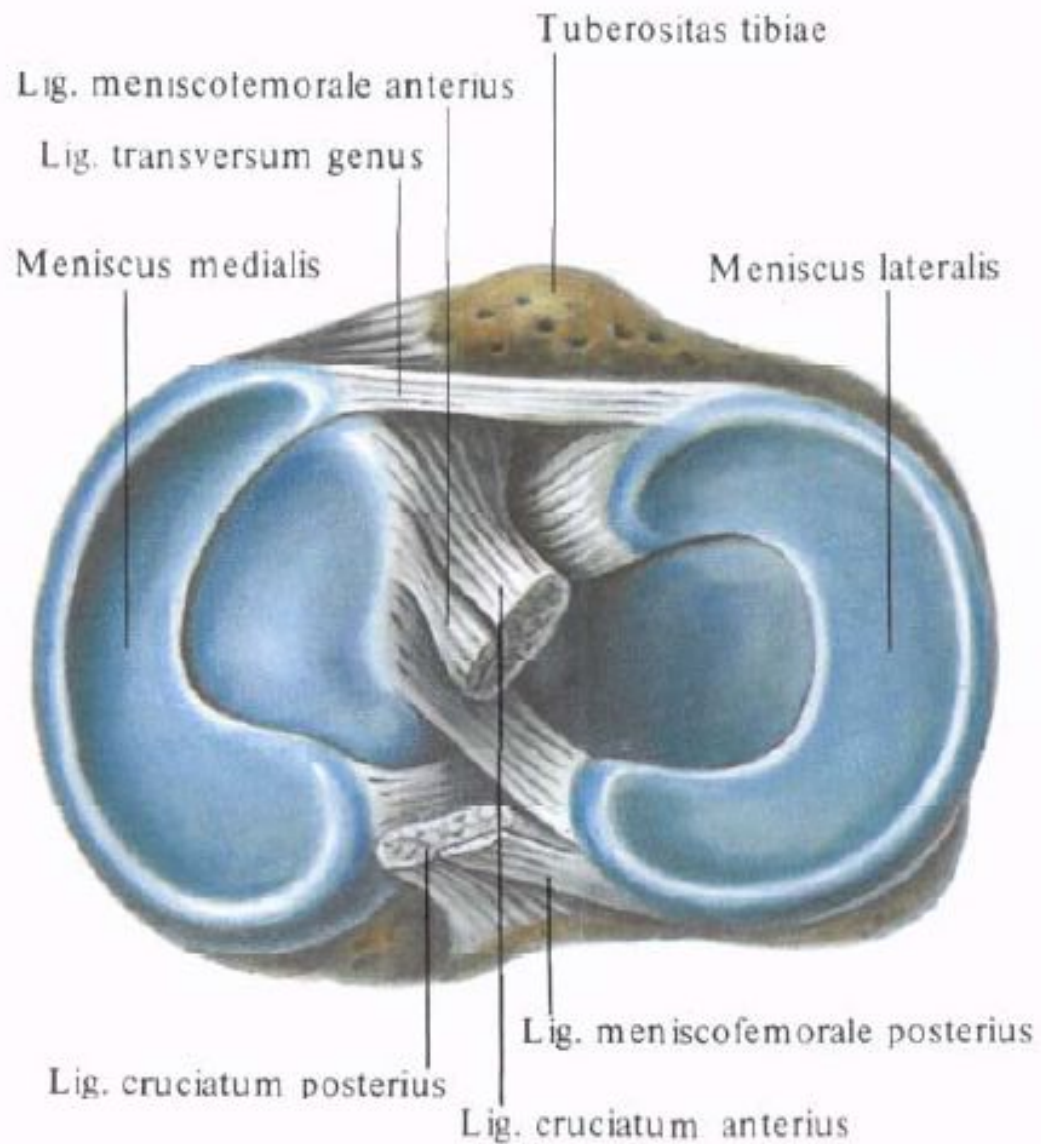
Коленный сустав. Соединение костей голени. Соединение костей стопы. Стопа в целом. Своды стопы.

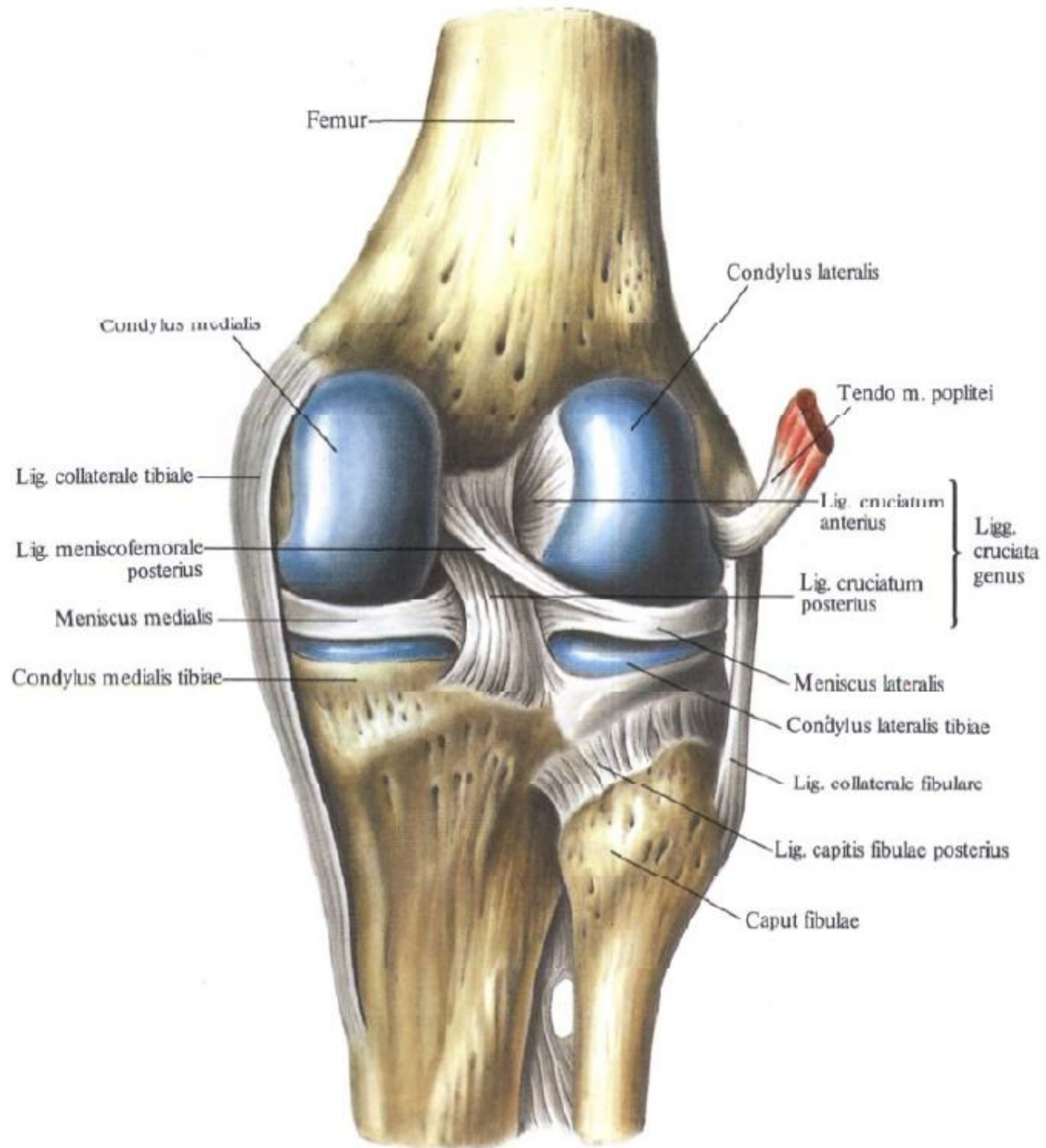












Lig. capitis
fibulae anterioris

Membrana
interossea
cruris

Fibula →

← Tibia

Lig. tibiofibulare
anterioris



