

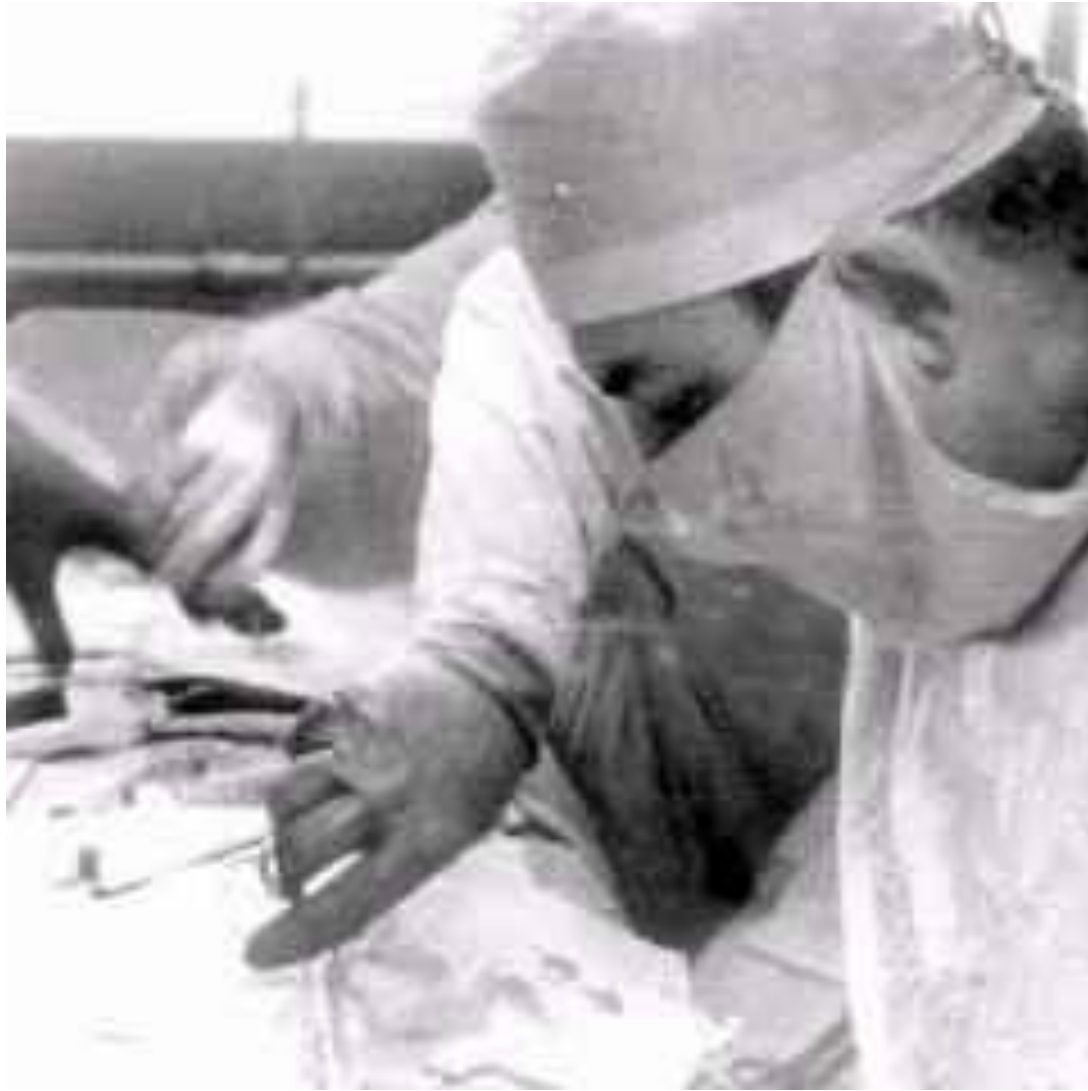
VLADIMIR VLADIMIROVICH  
VINOGRADOV

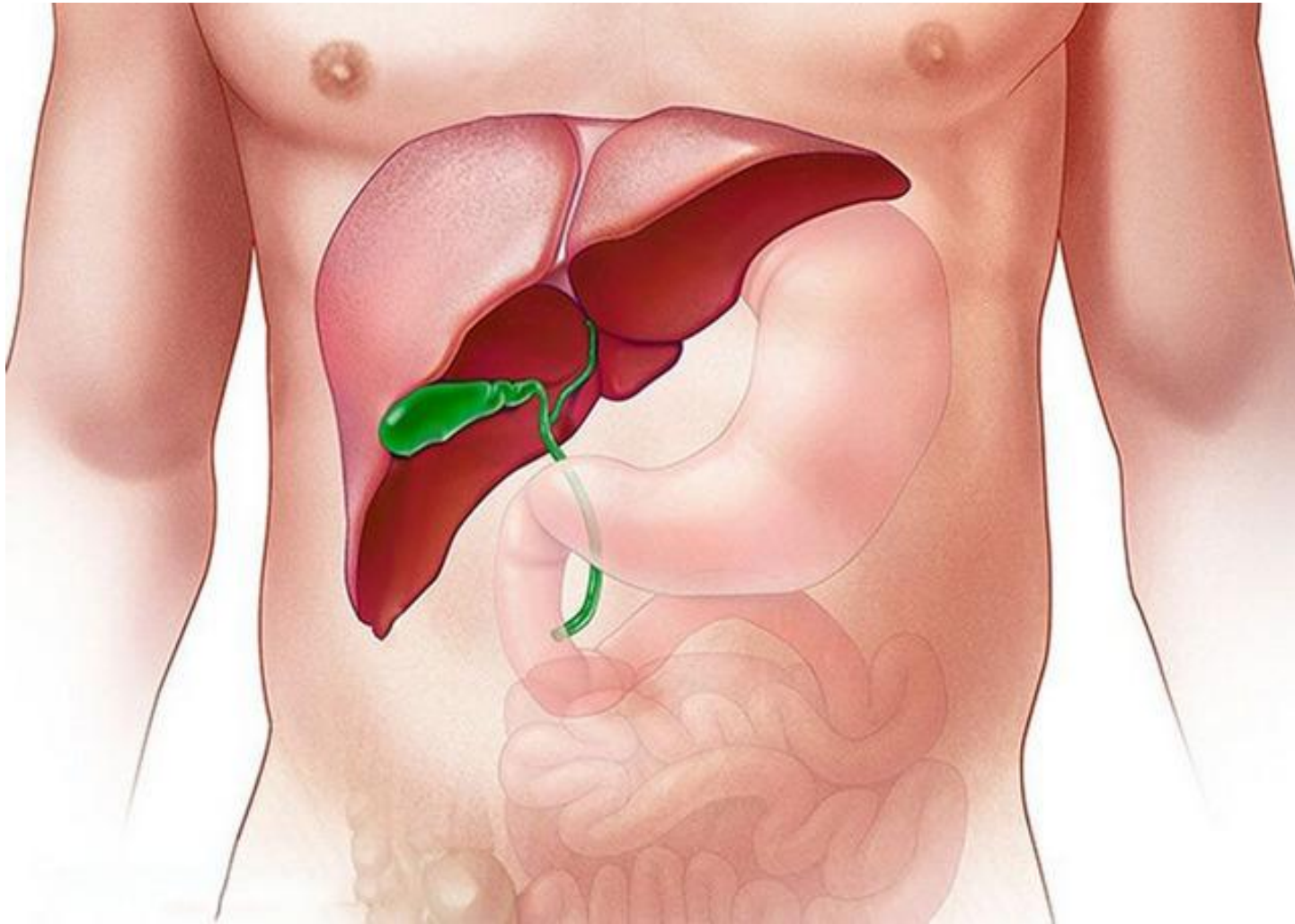




V LADIMIR  
V LADIMIROVICH  
V INOGRADOV  
(1920- 1986)



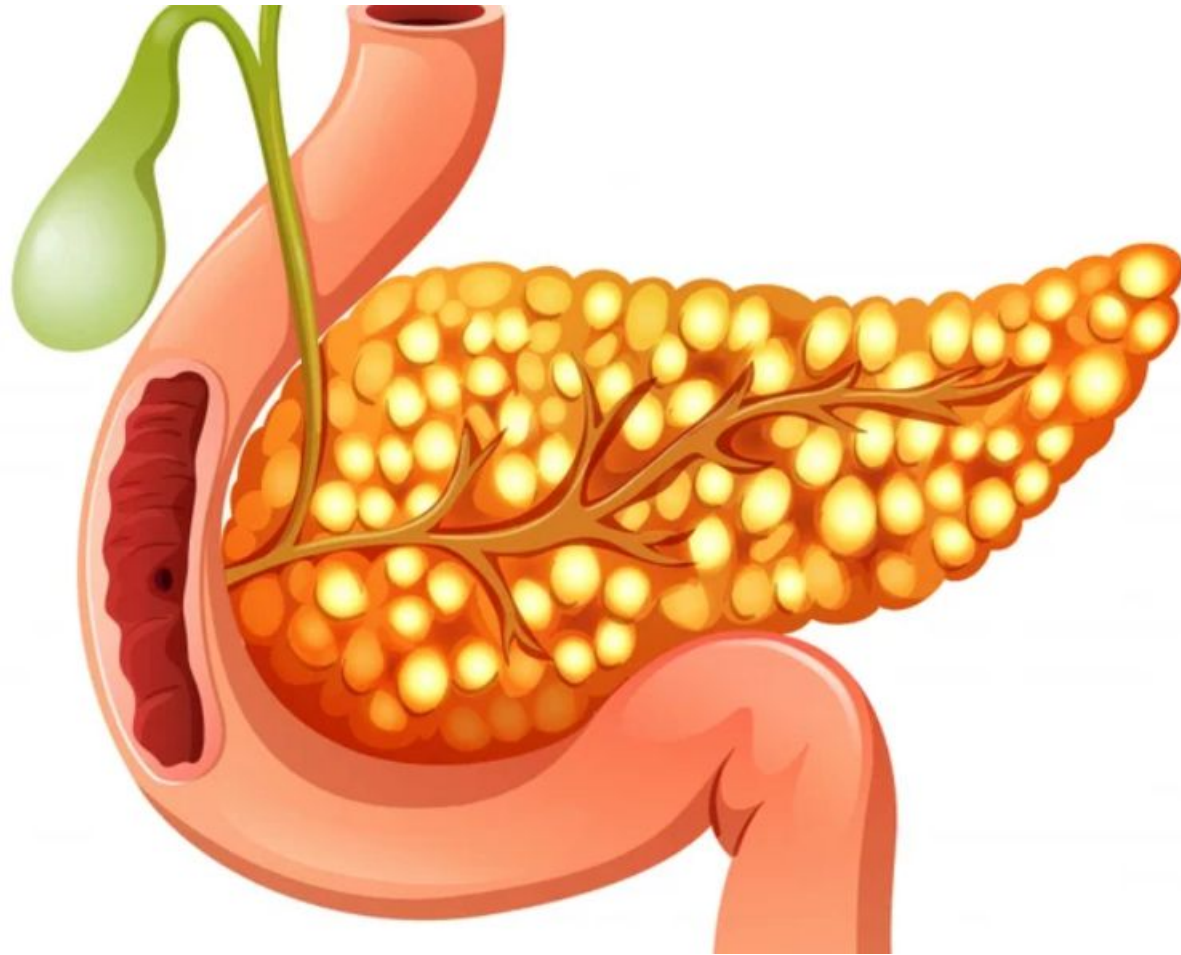




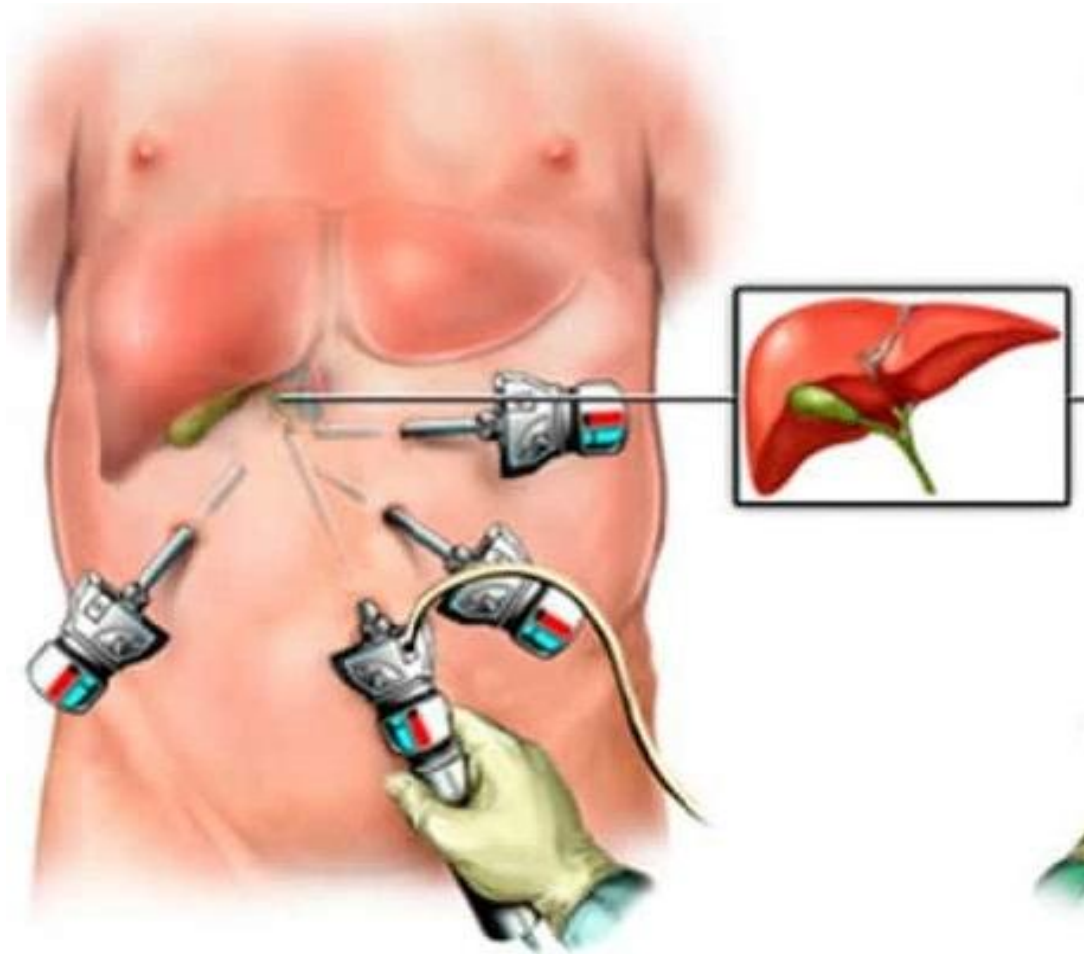
**GALL BLADDER**



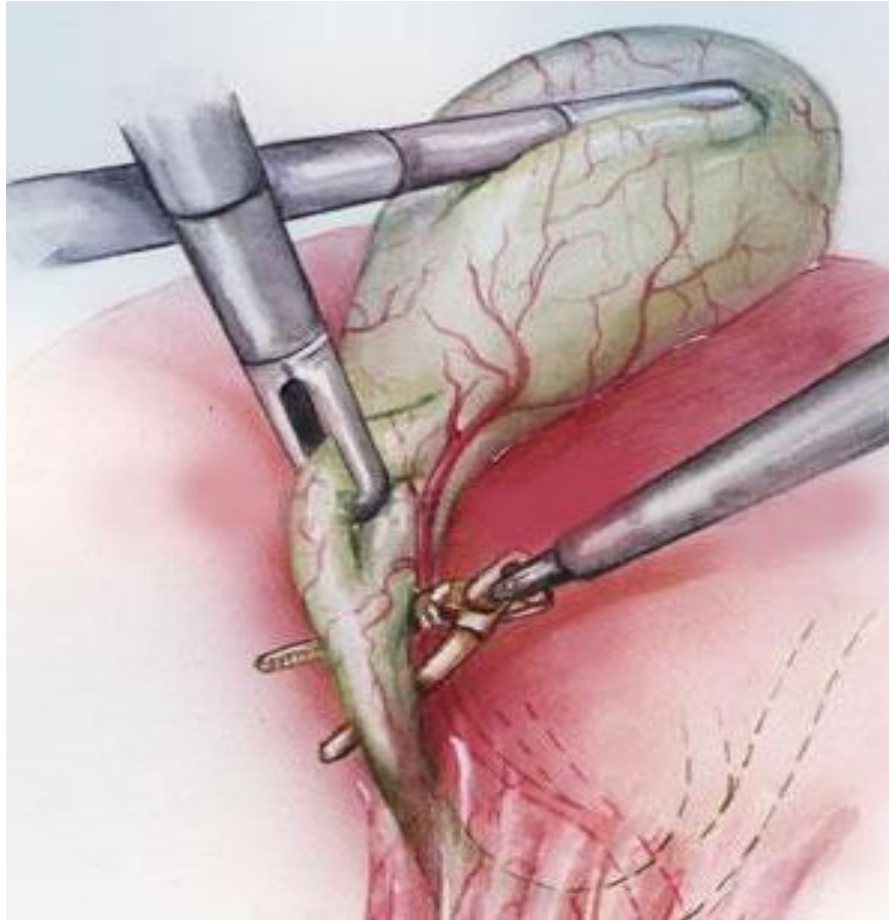
# PANCREAS



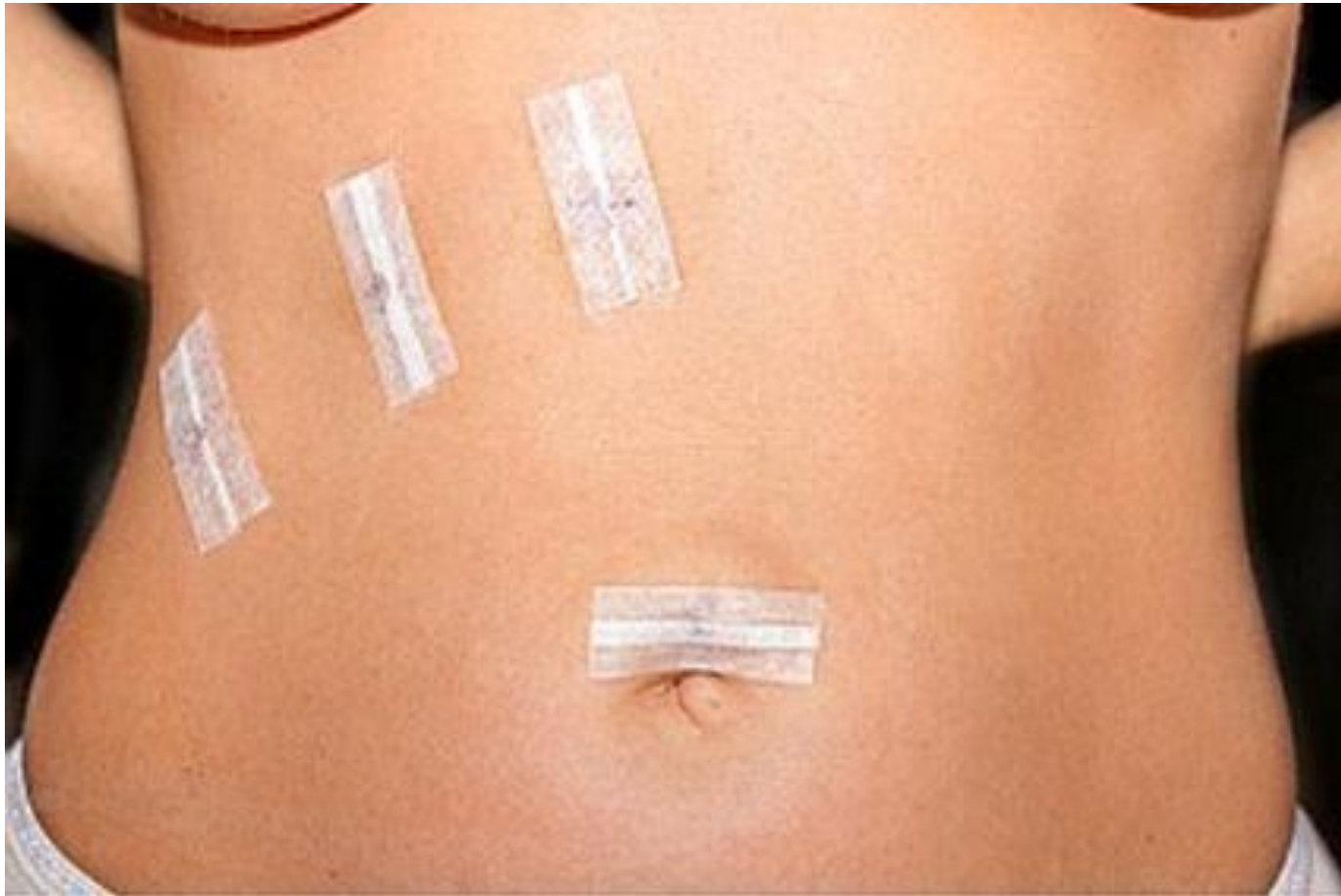# LAPAROTOMY



# LAPAROTOMY



# POSTOPERATIVE WOUNDS







THANKS FOR YOUR  
ATTENTION

