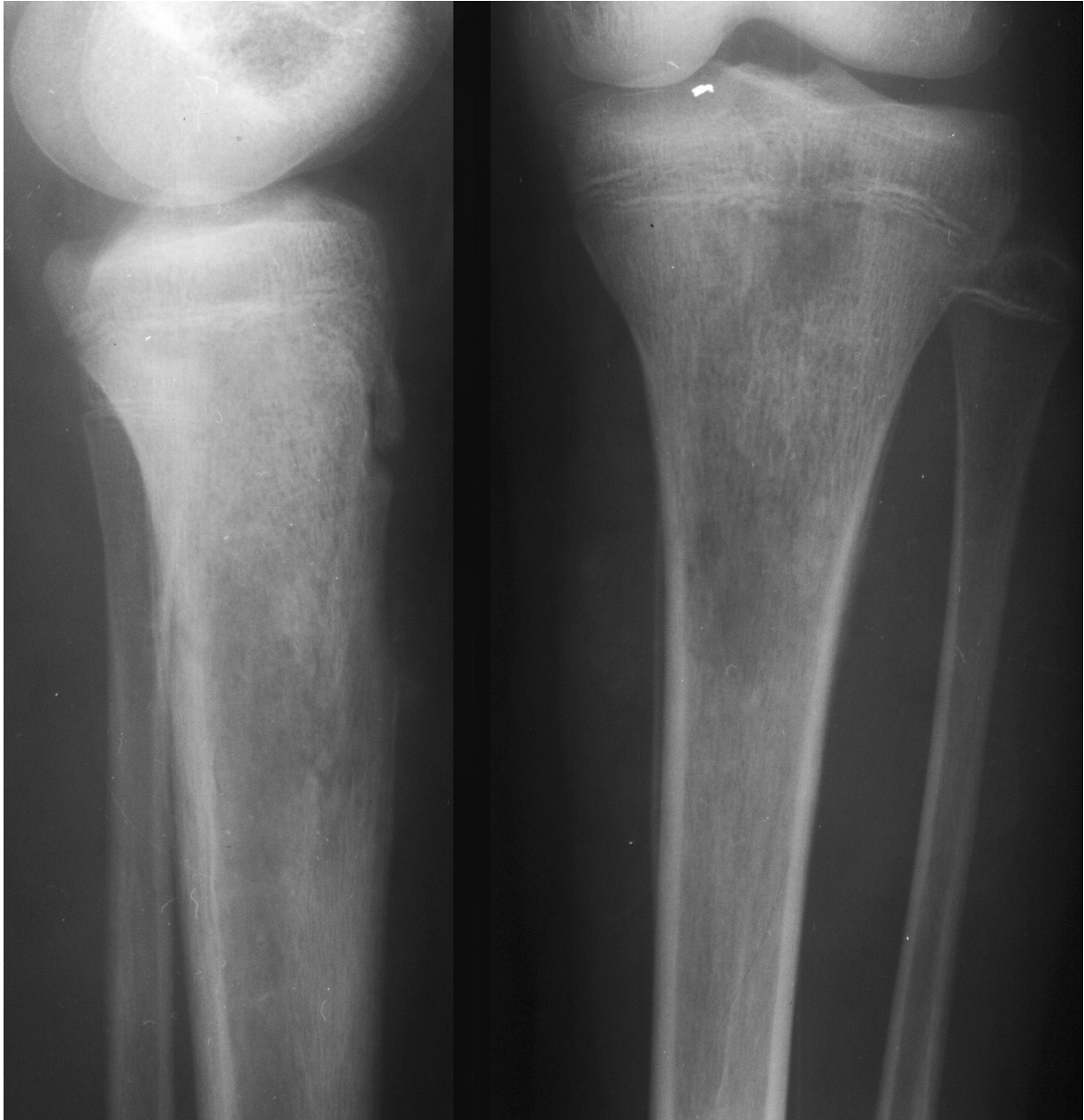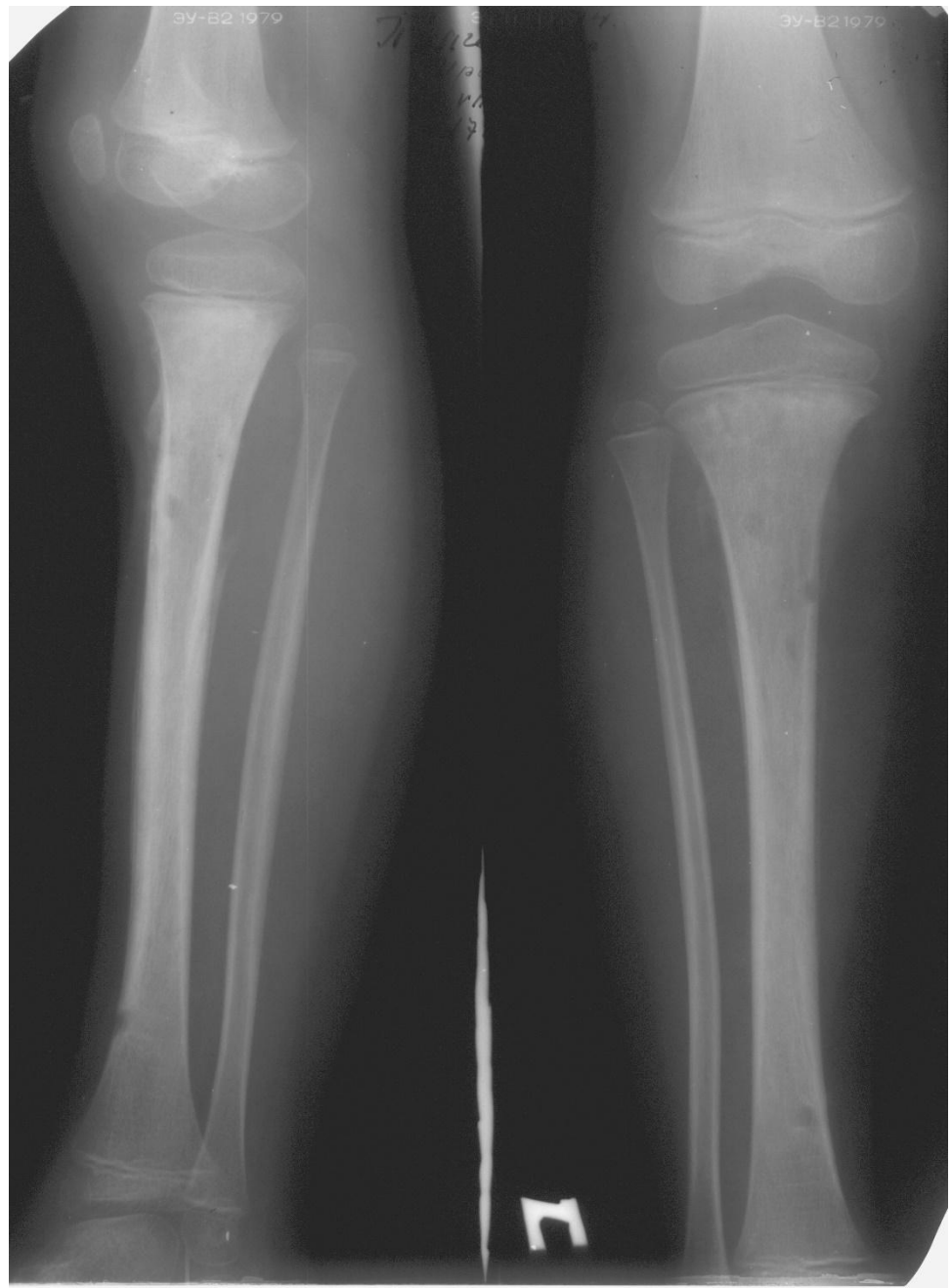

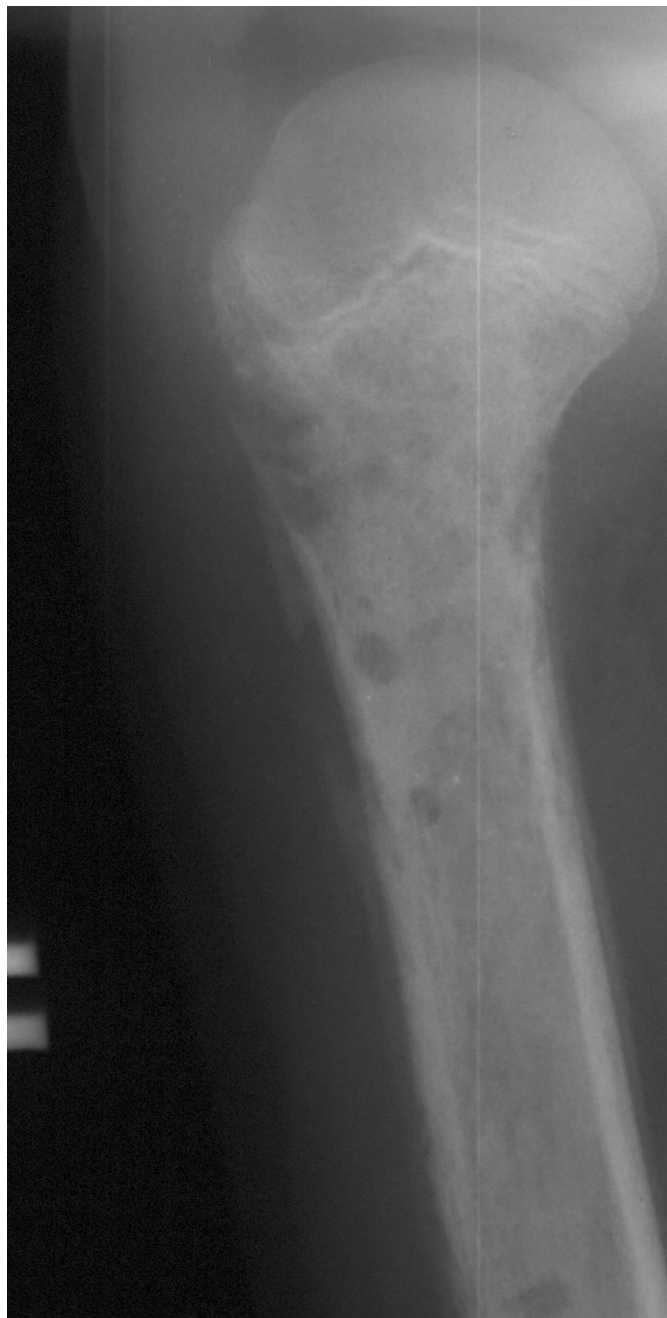
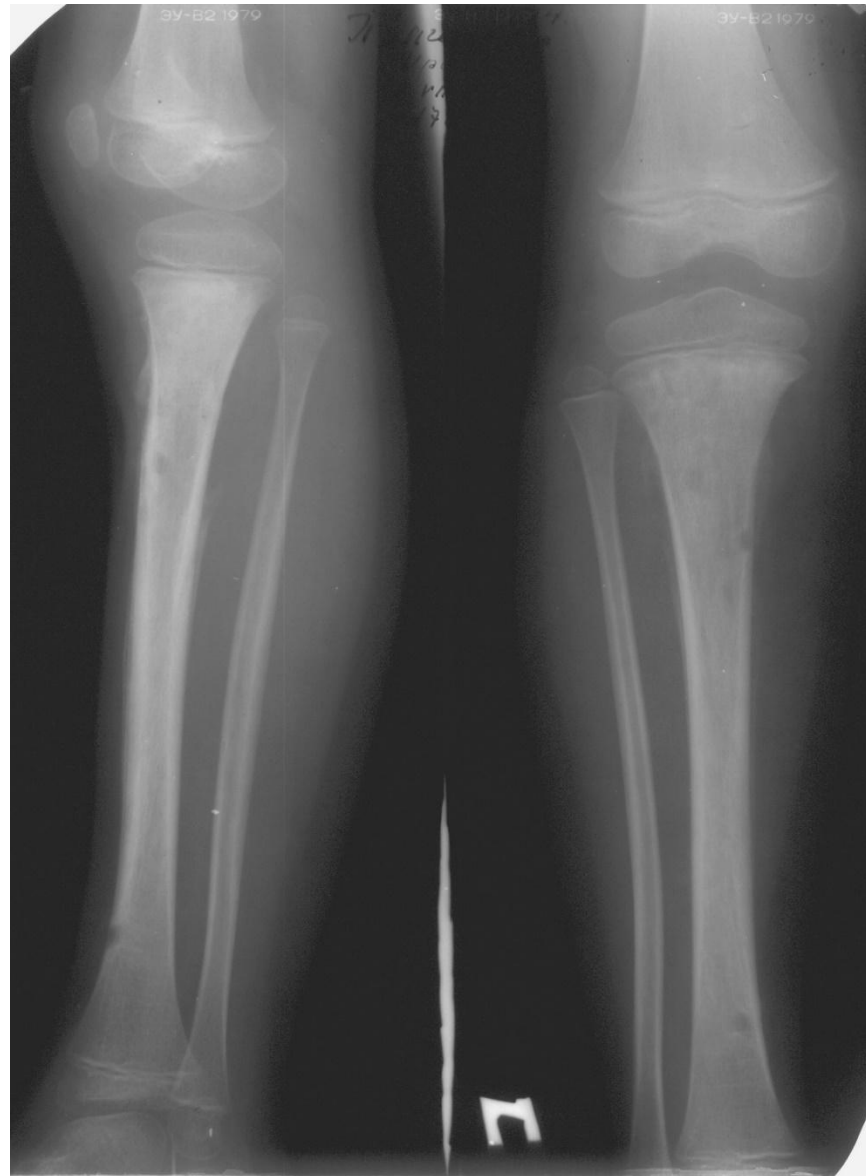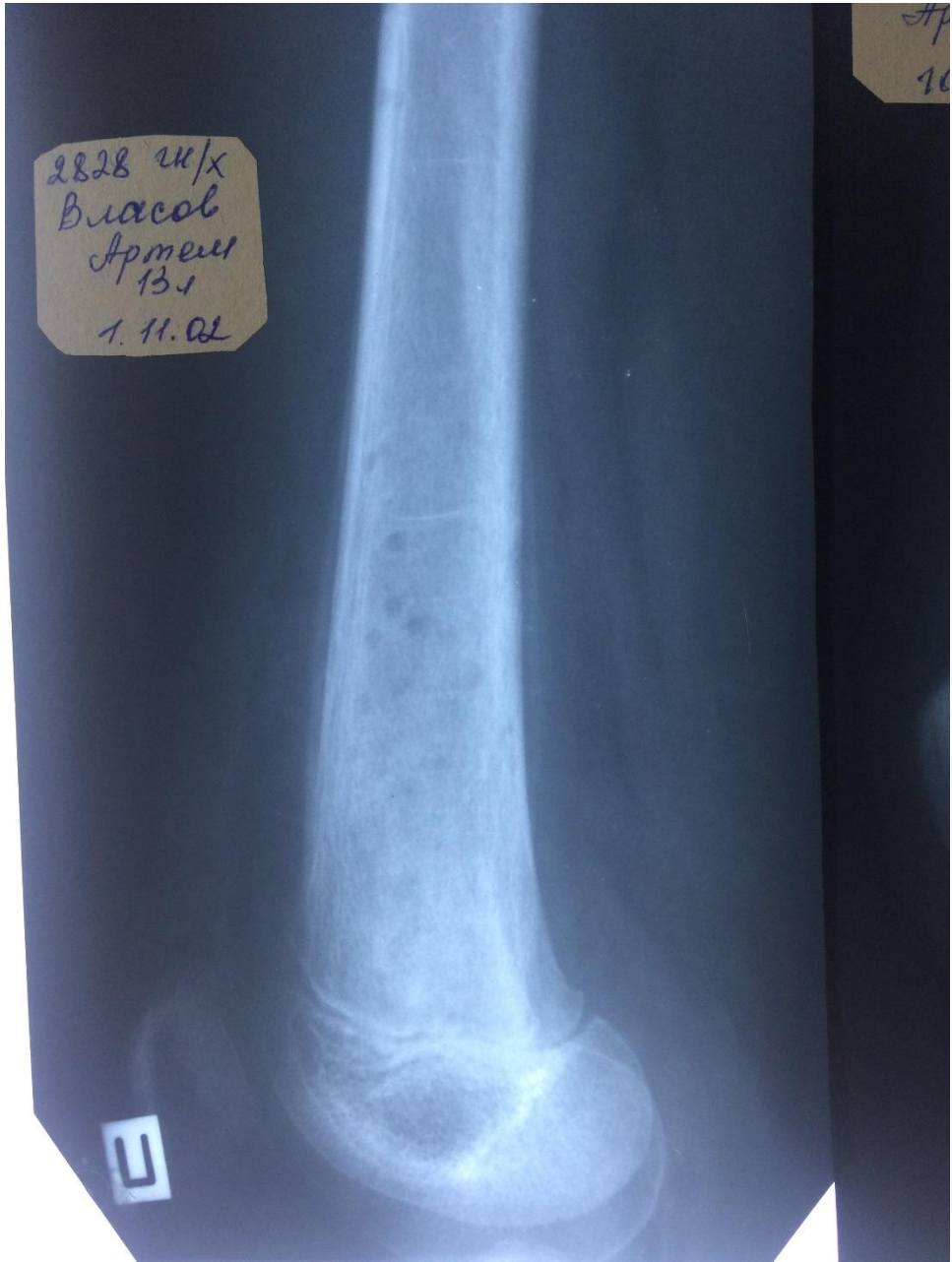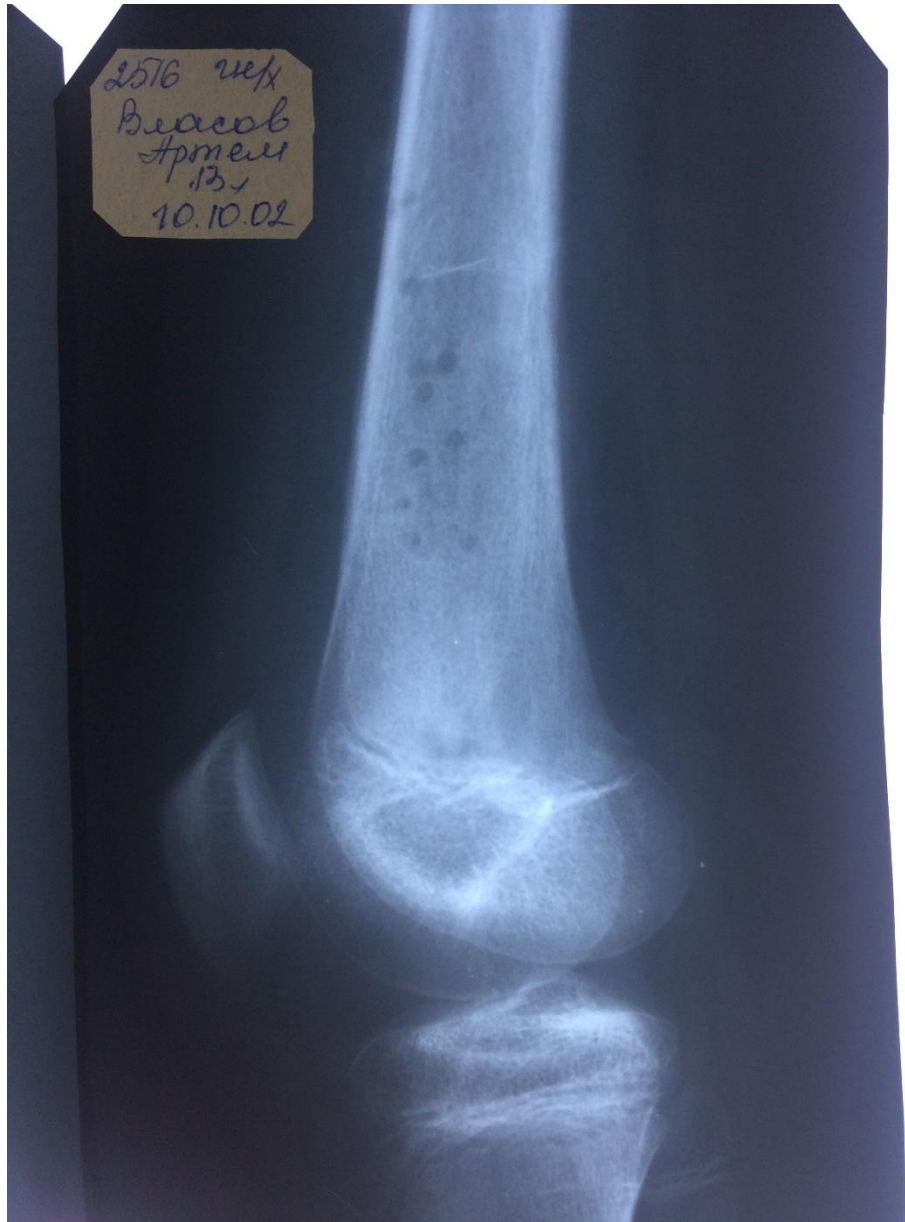Практическое занятие  
«Воспалительные  
заболевания опорно-  
двигательного аппарата»

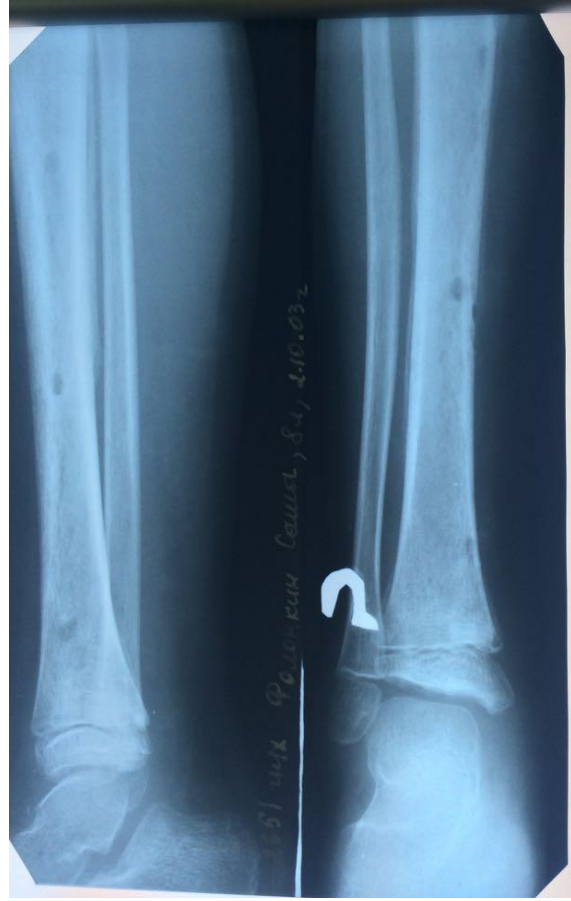
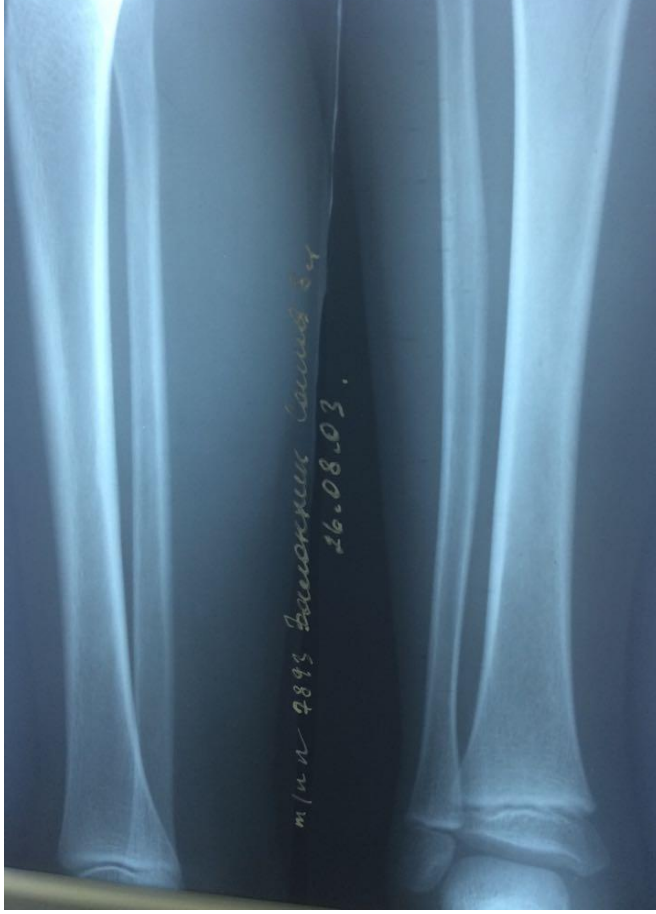


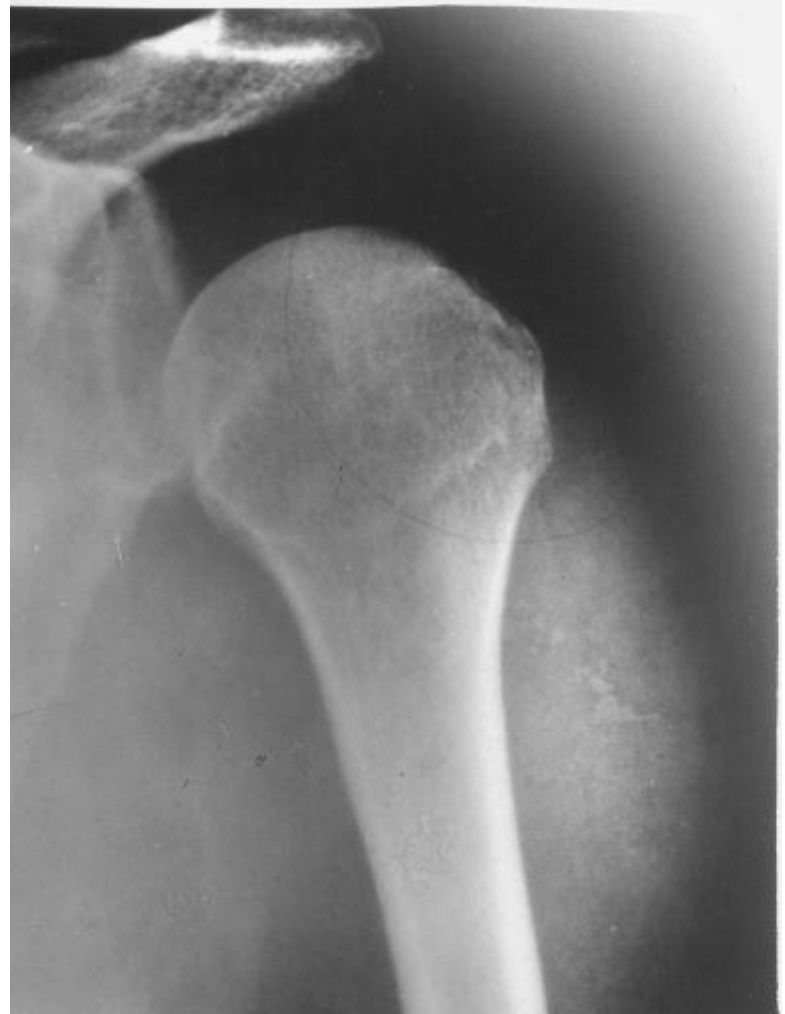
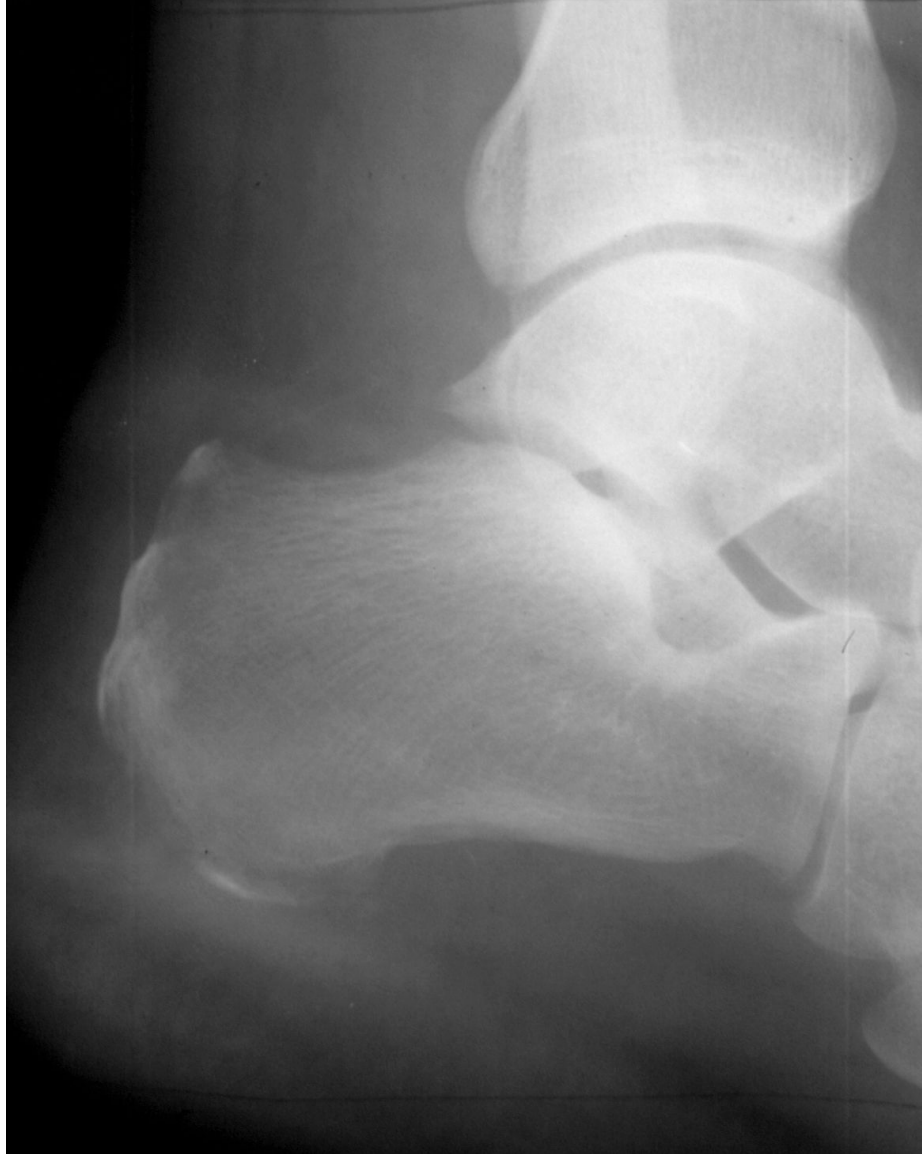


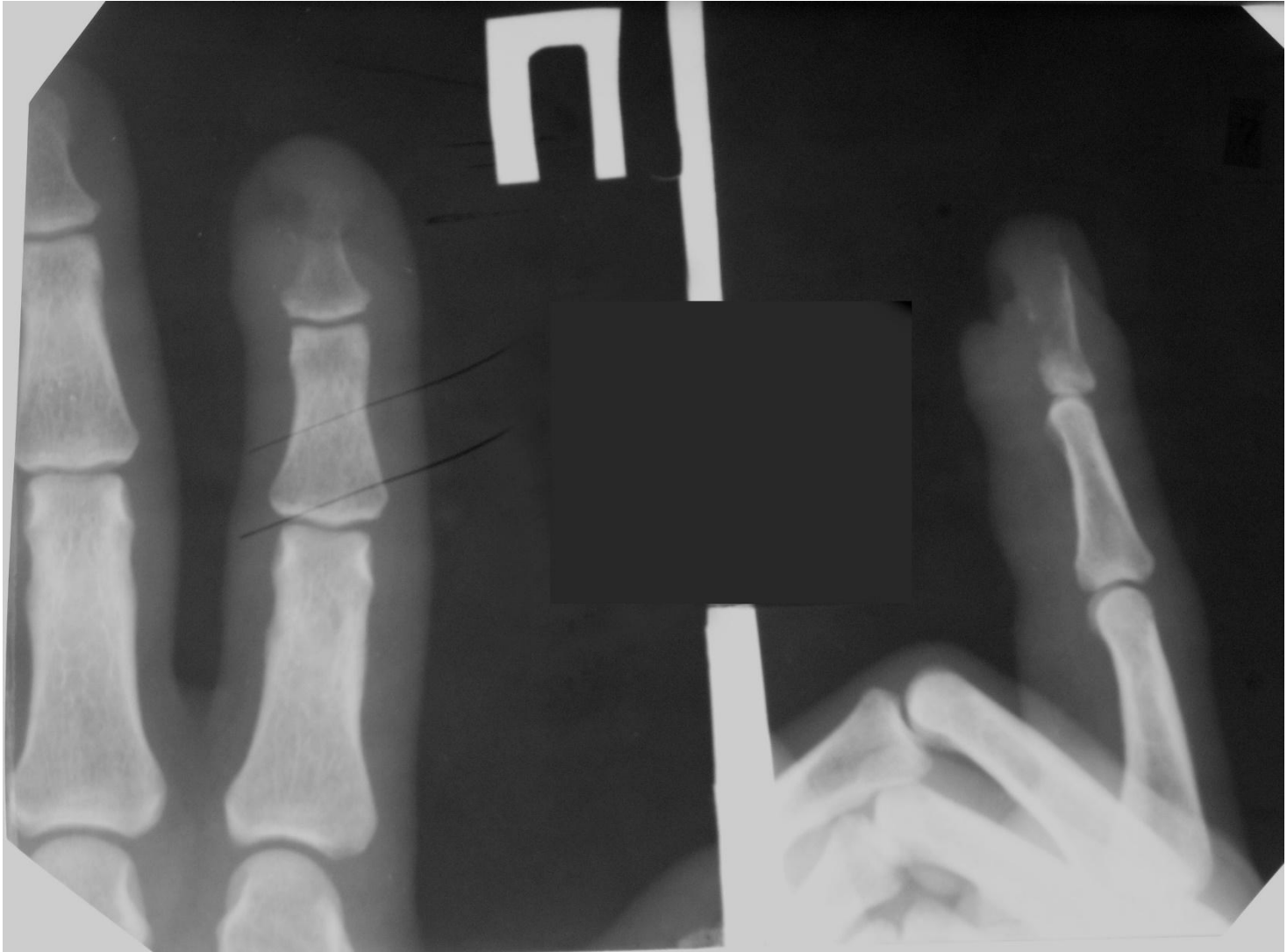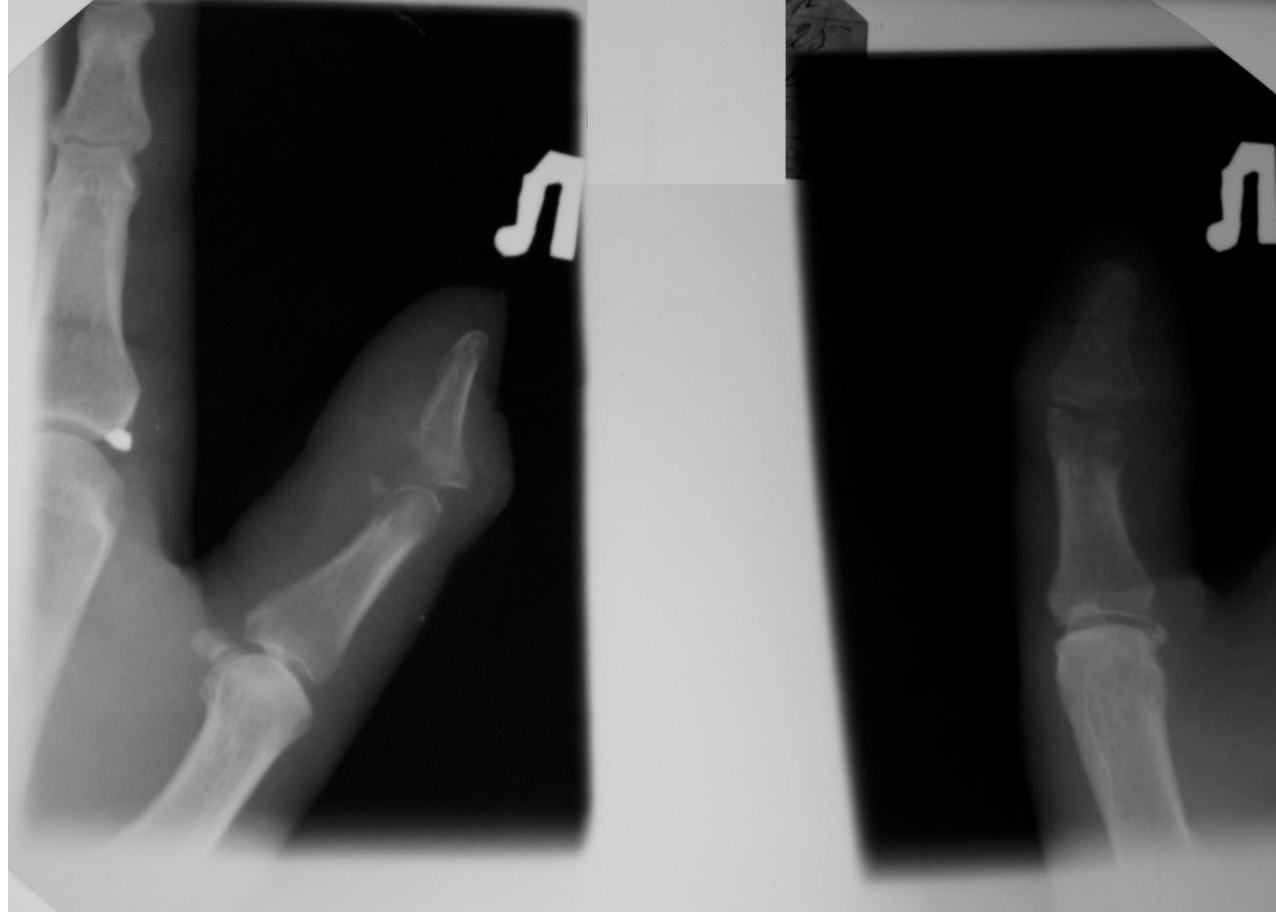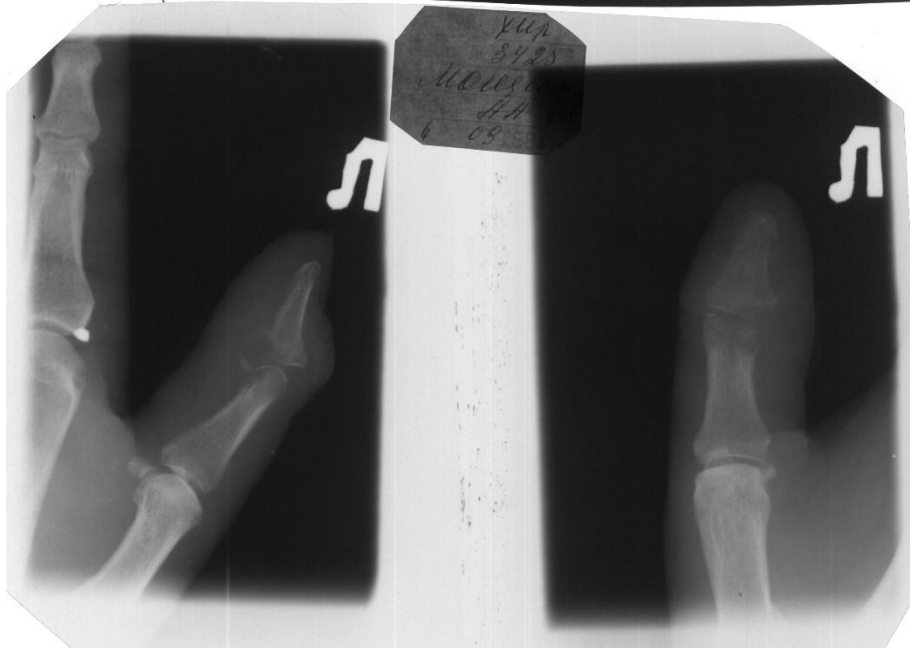
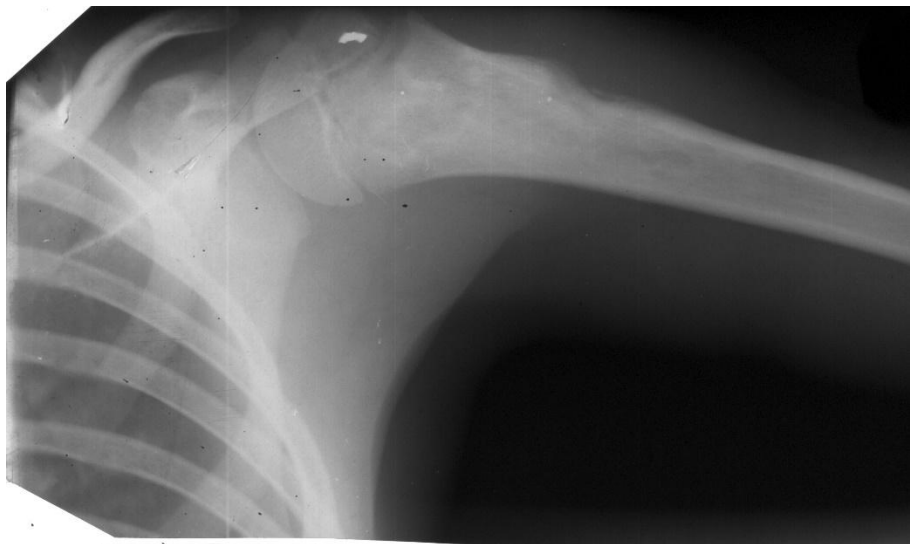






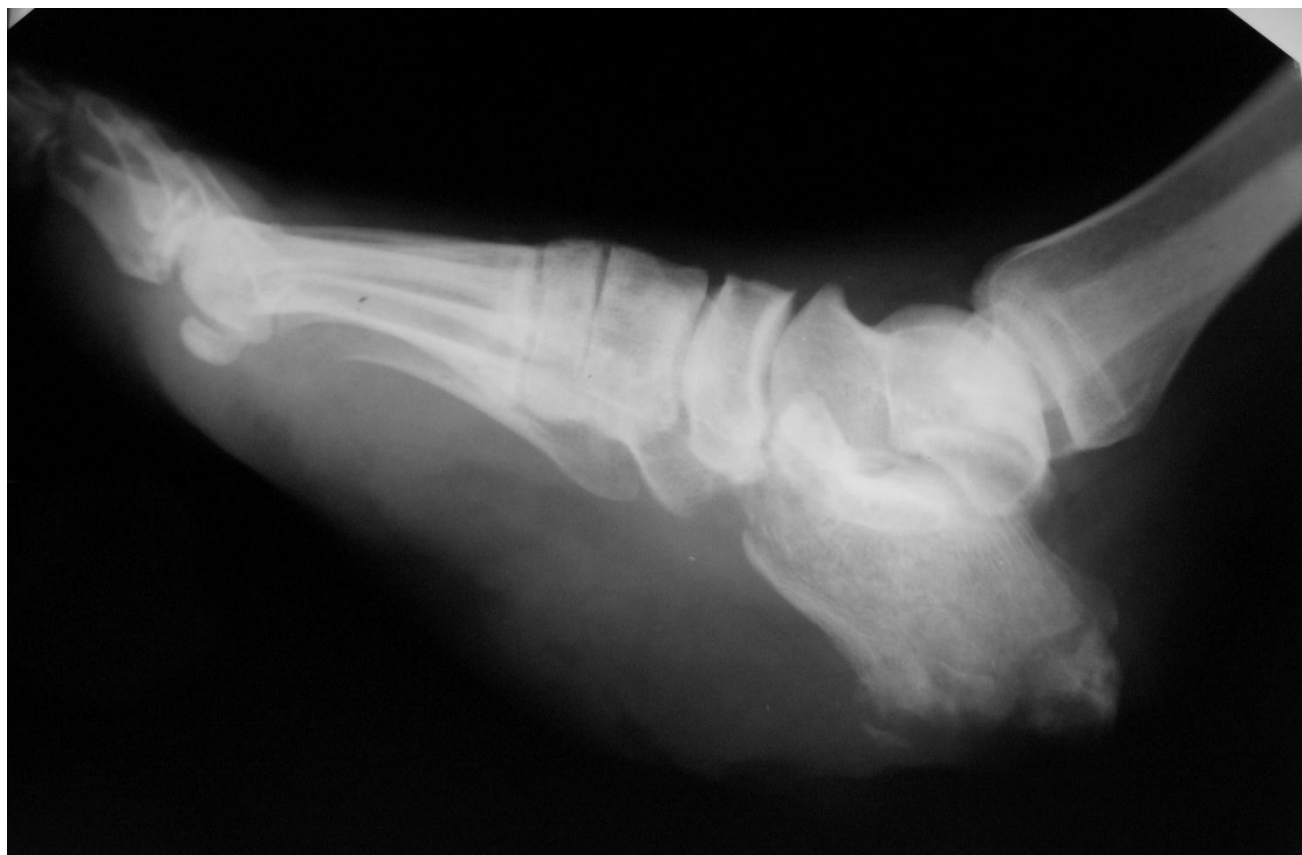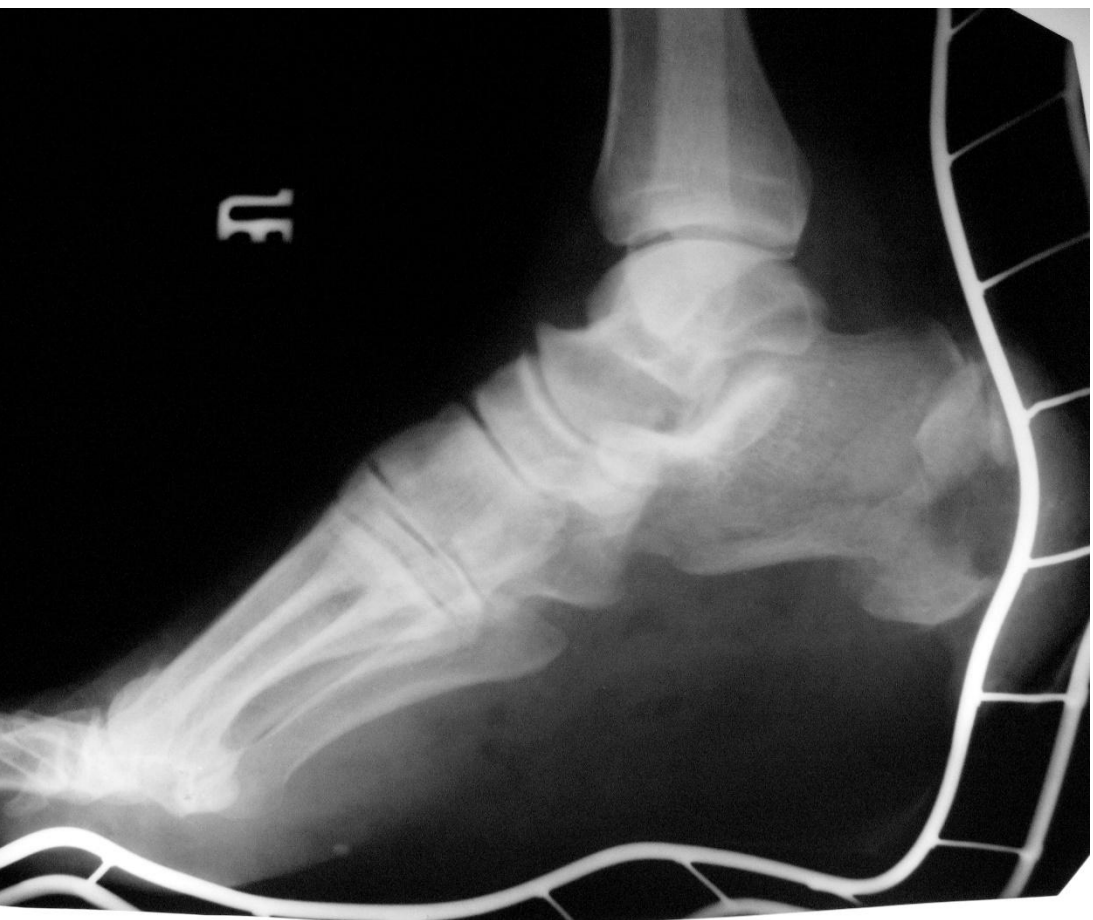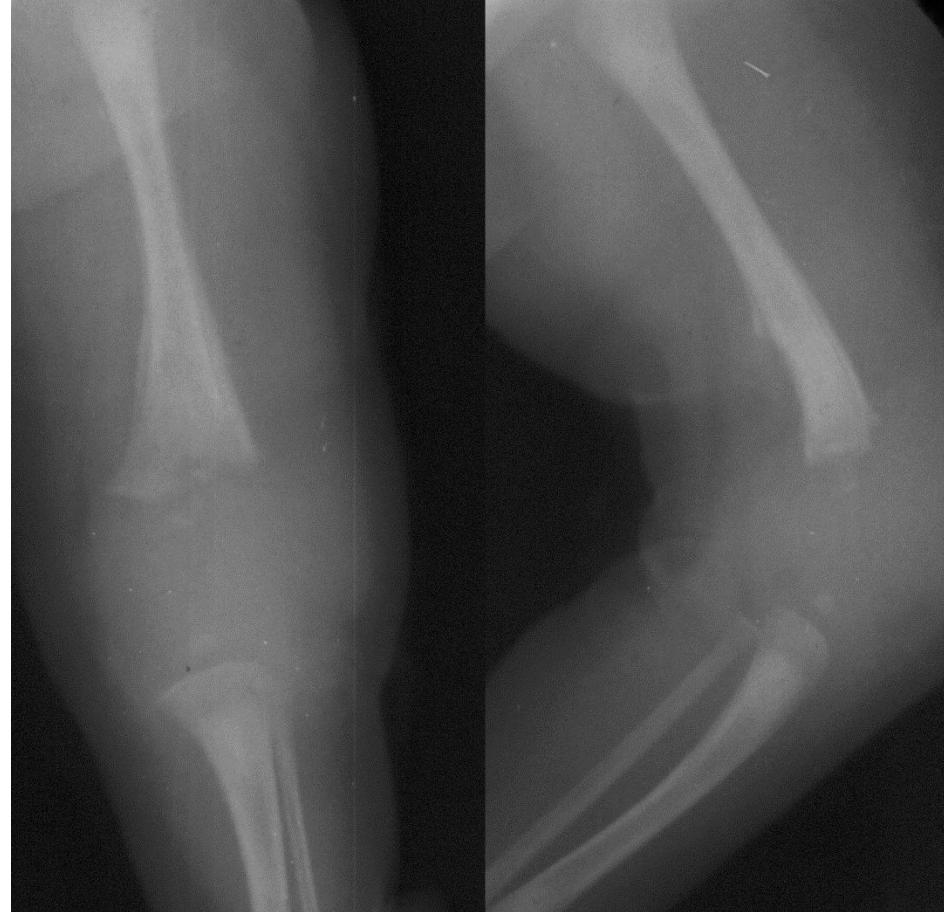








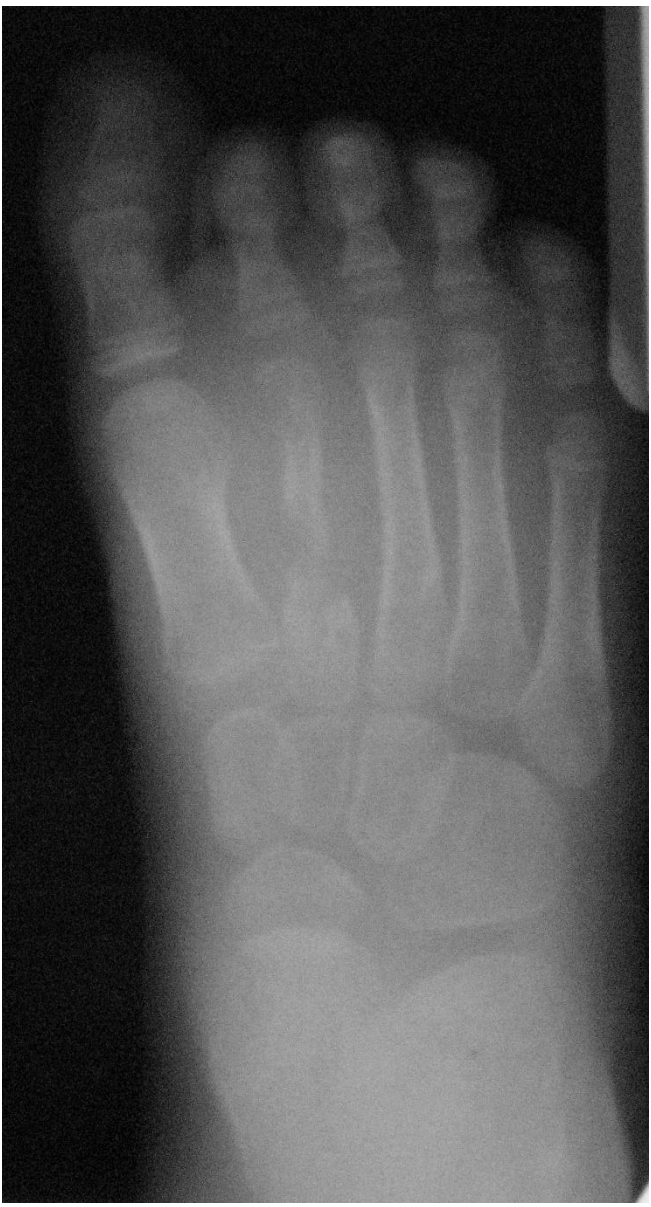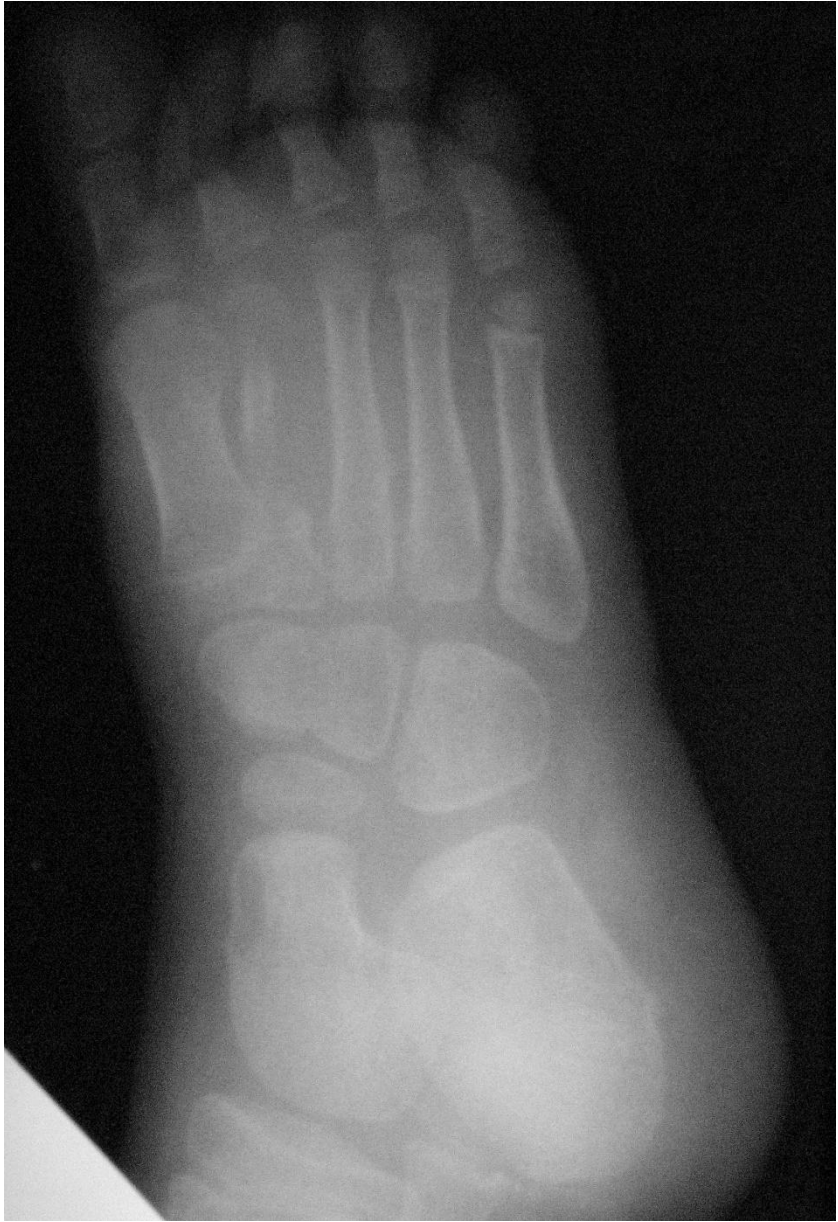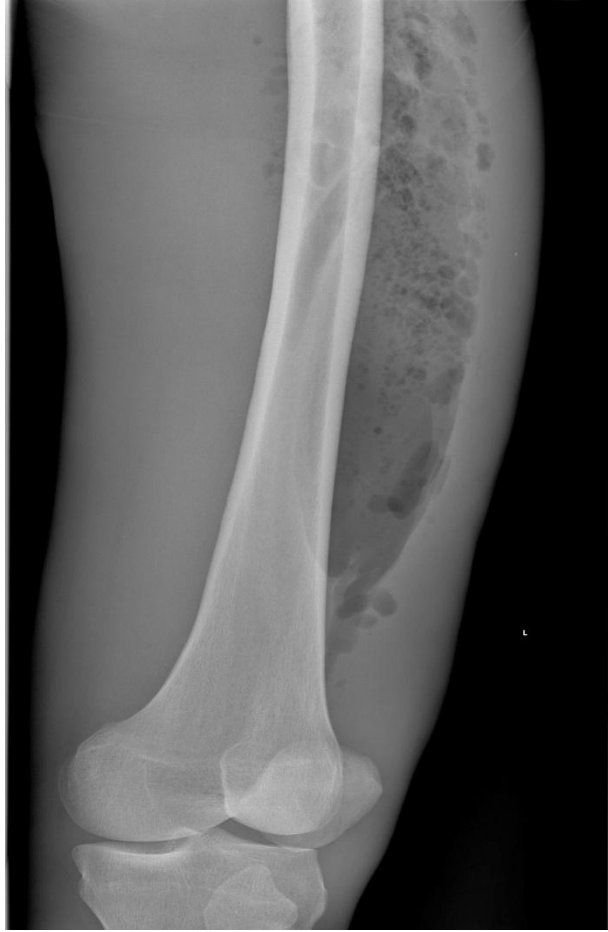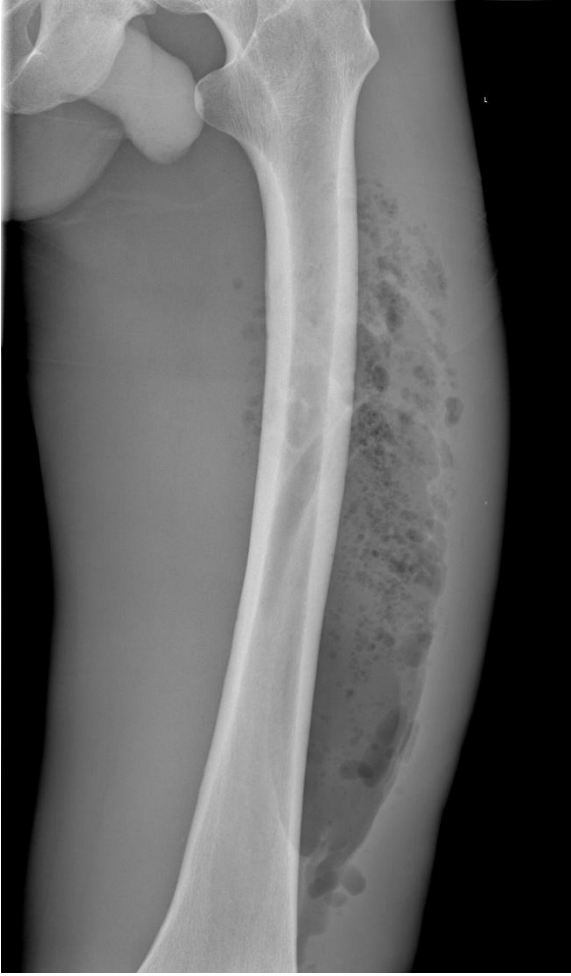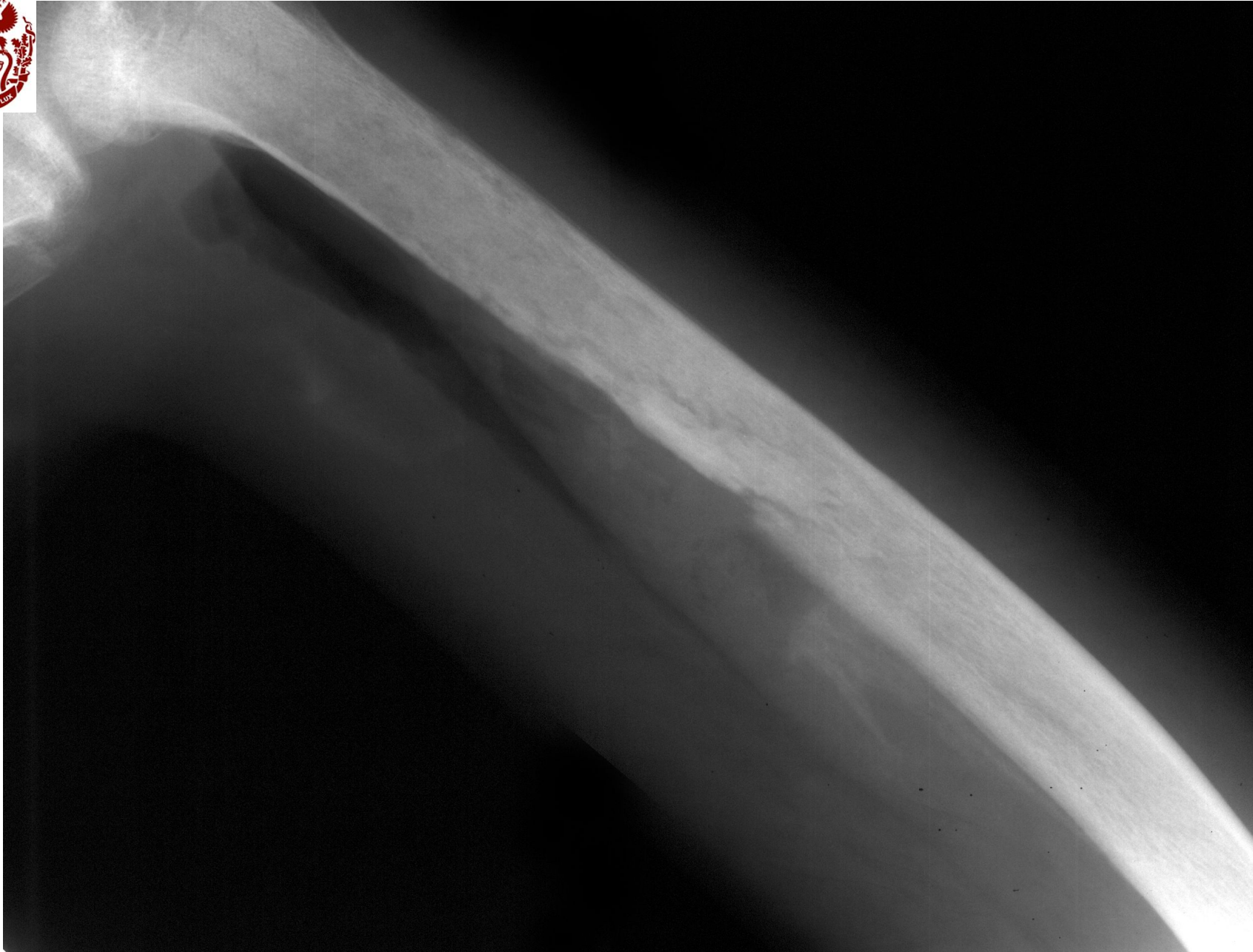


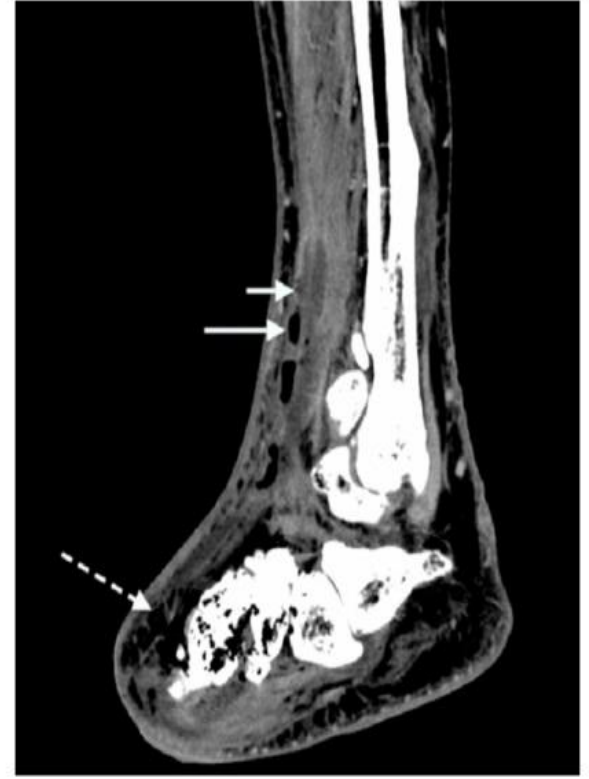
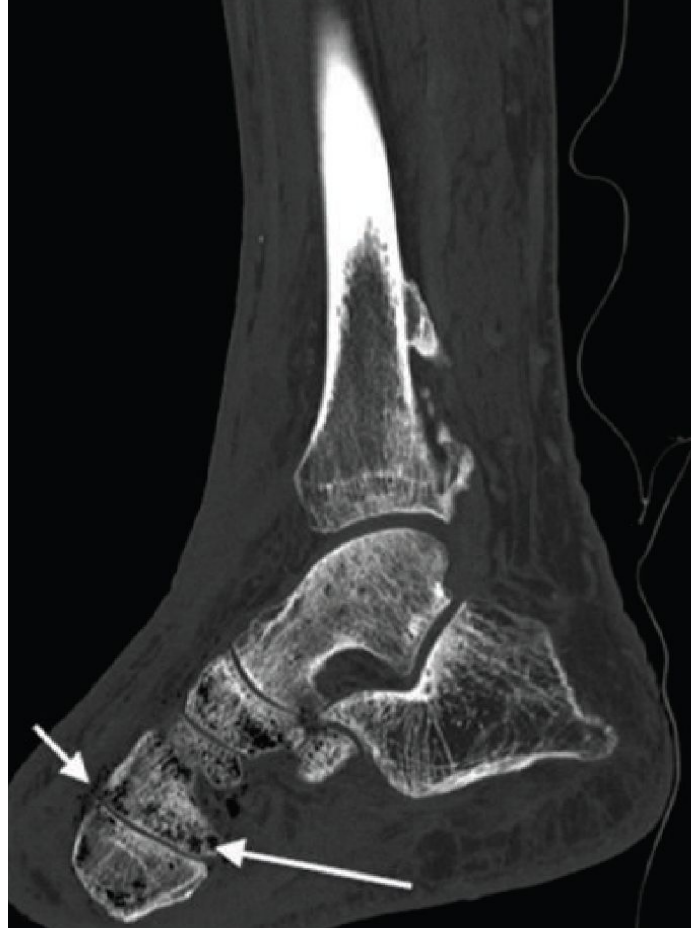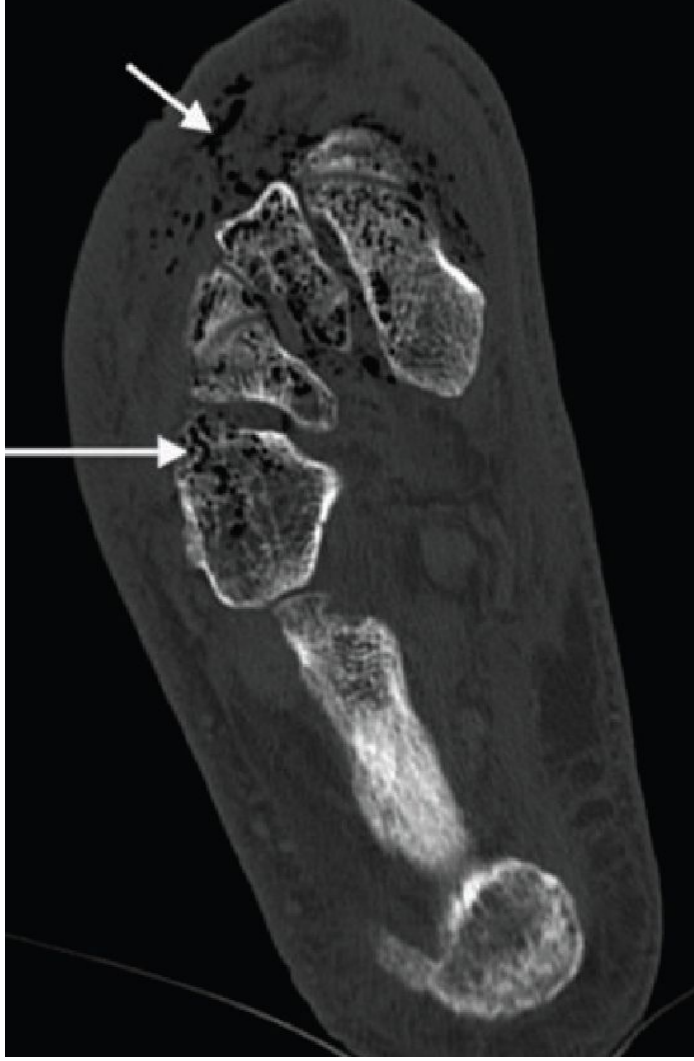






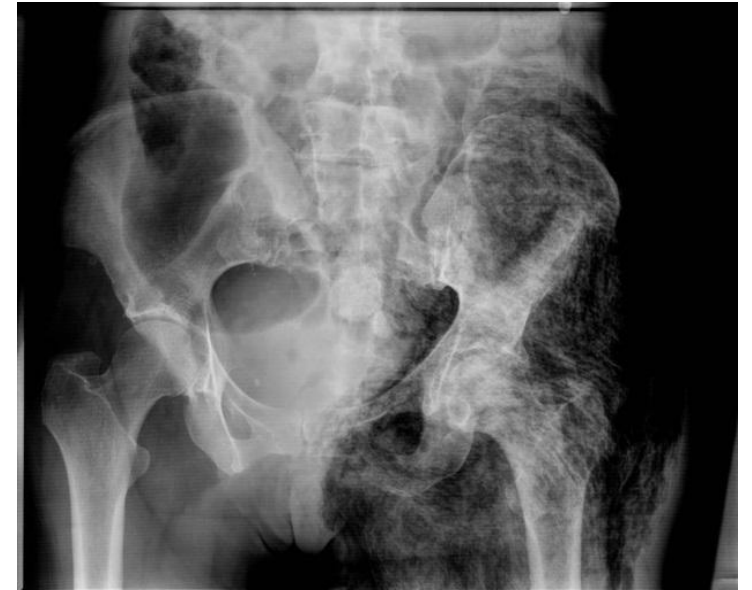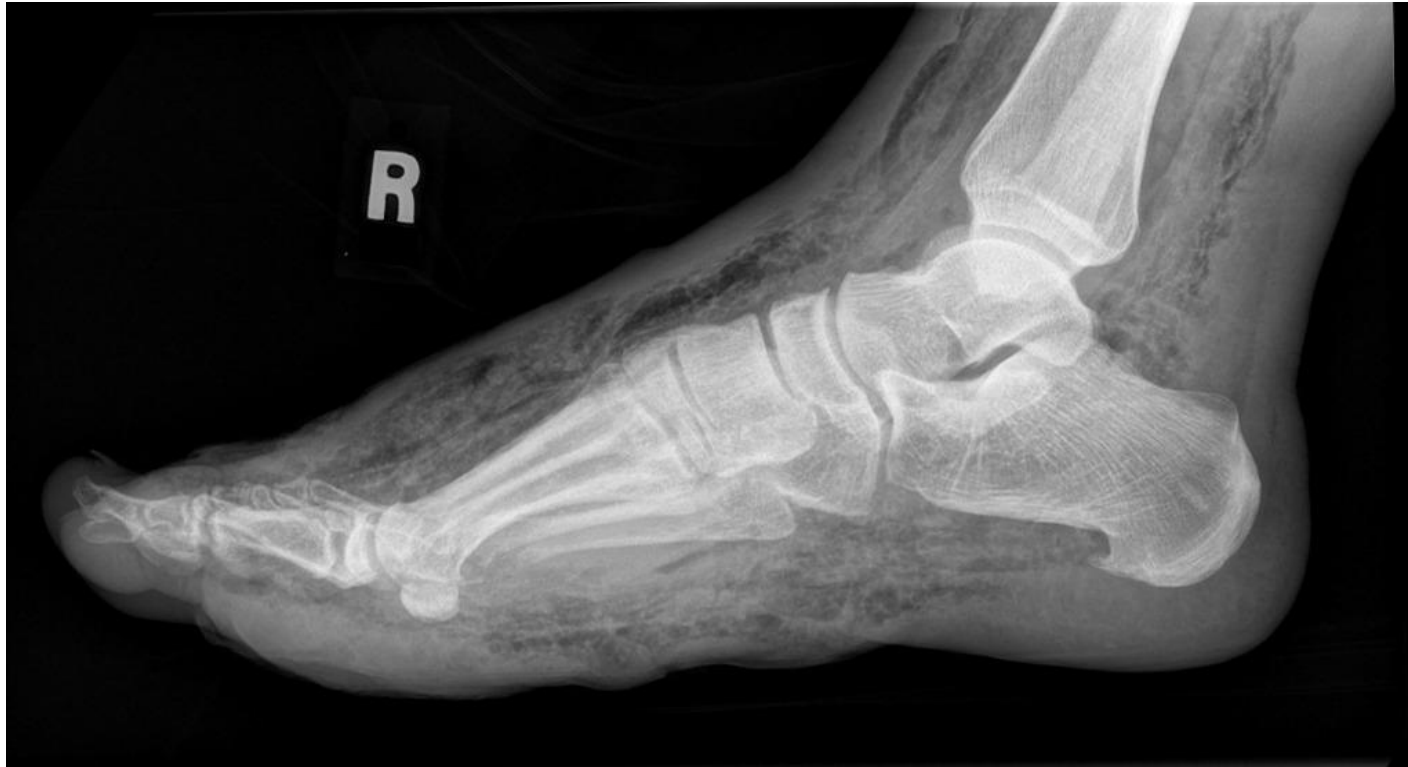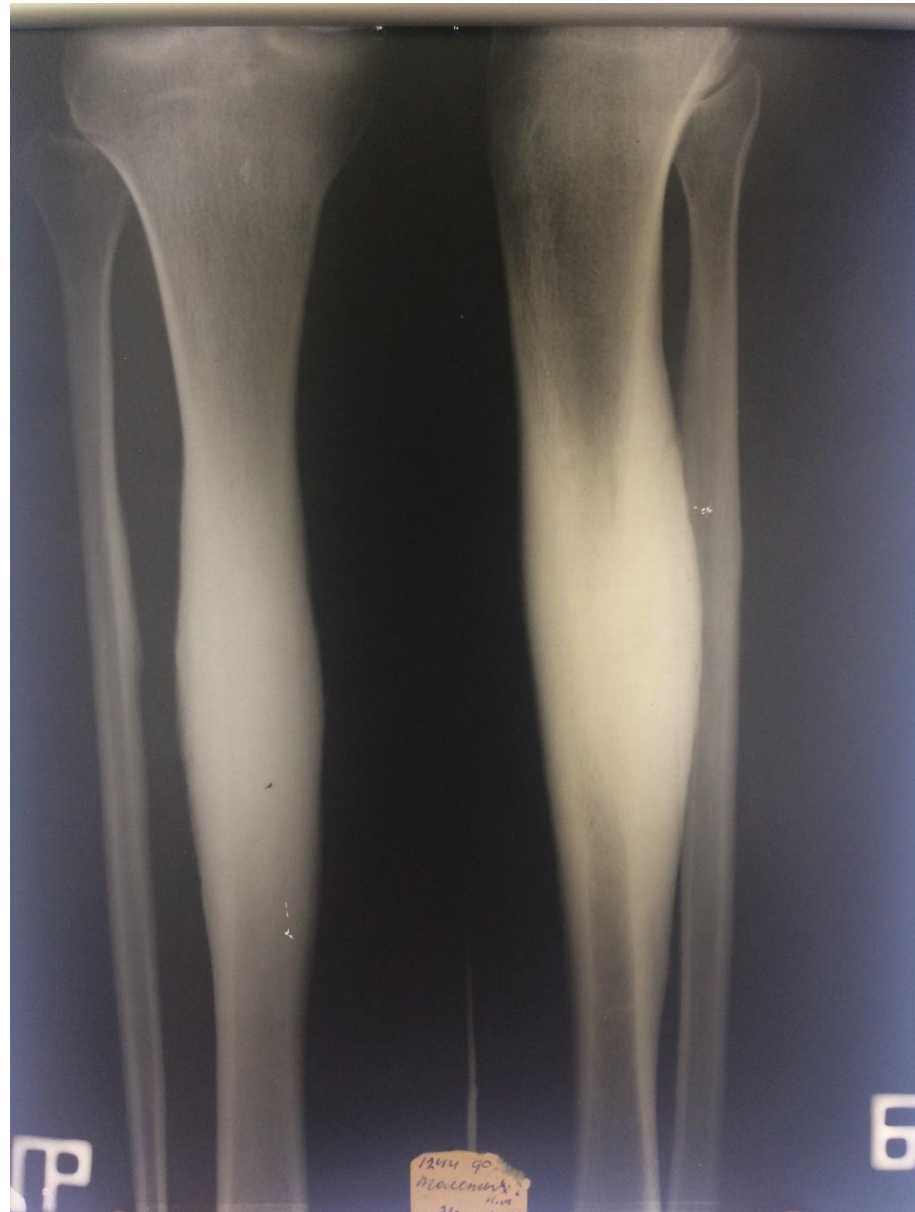




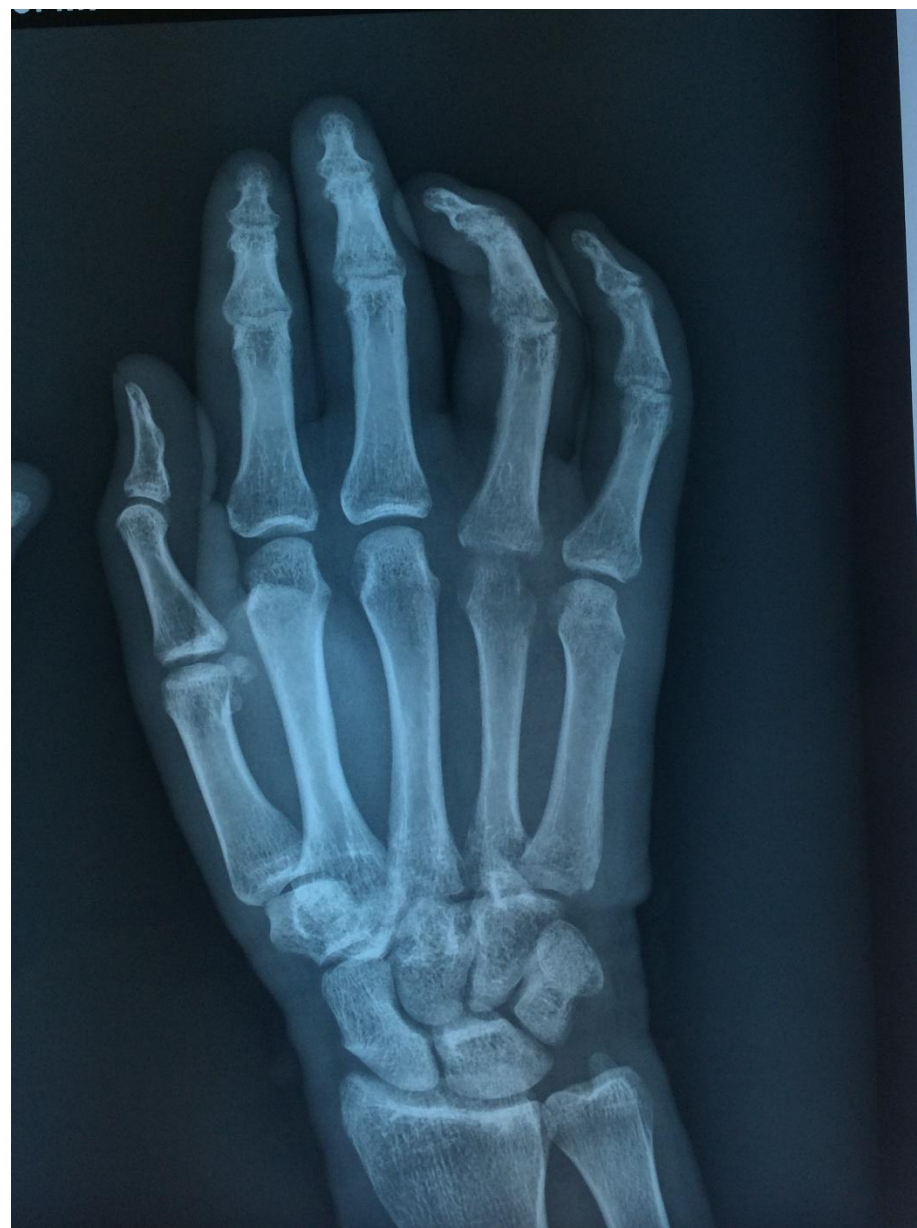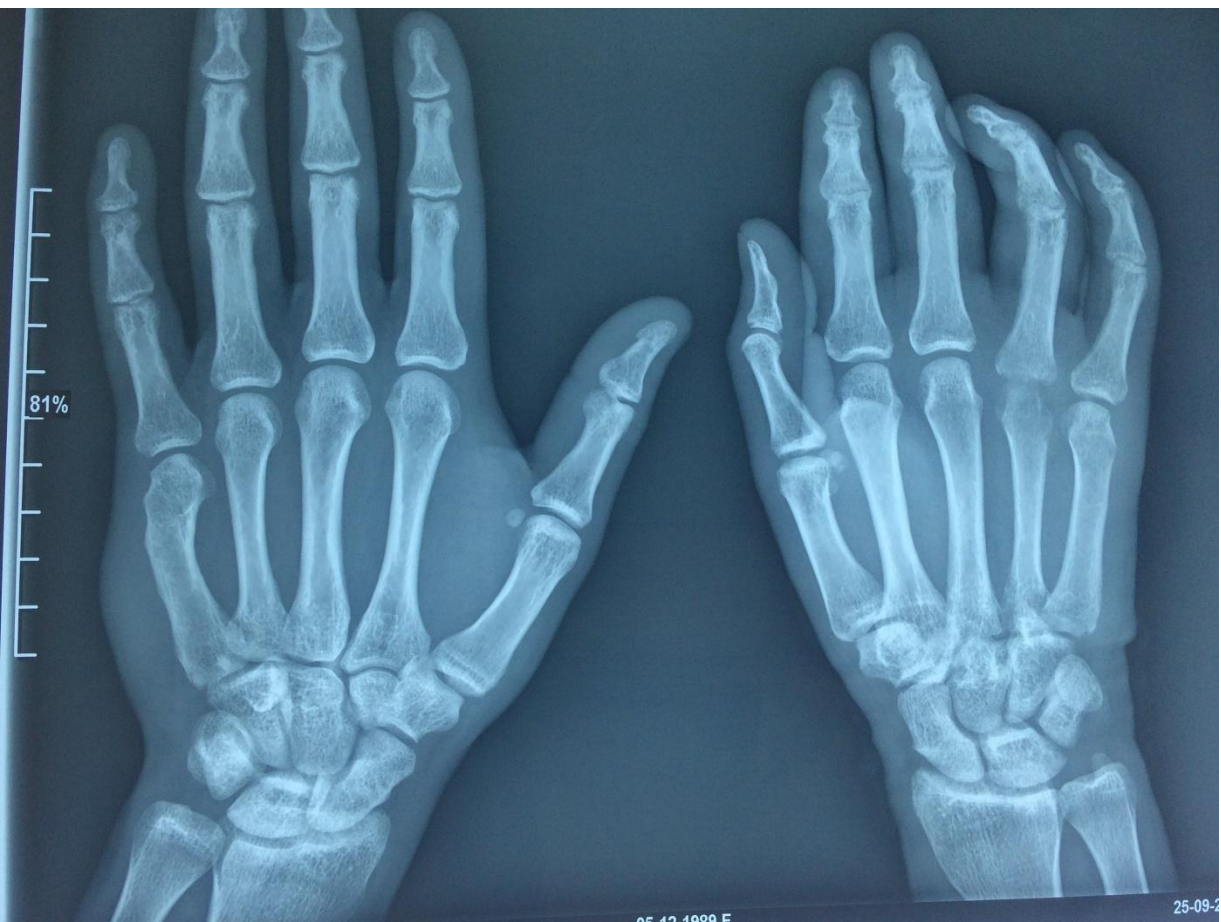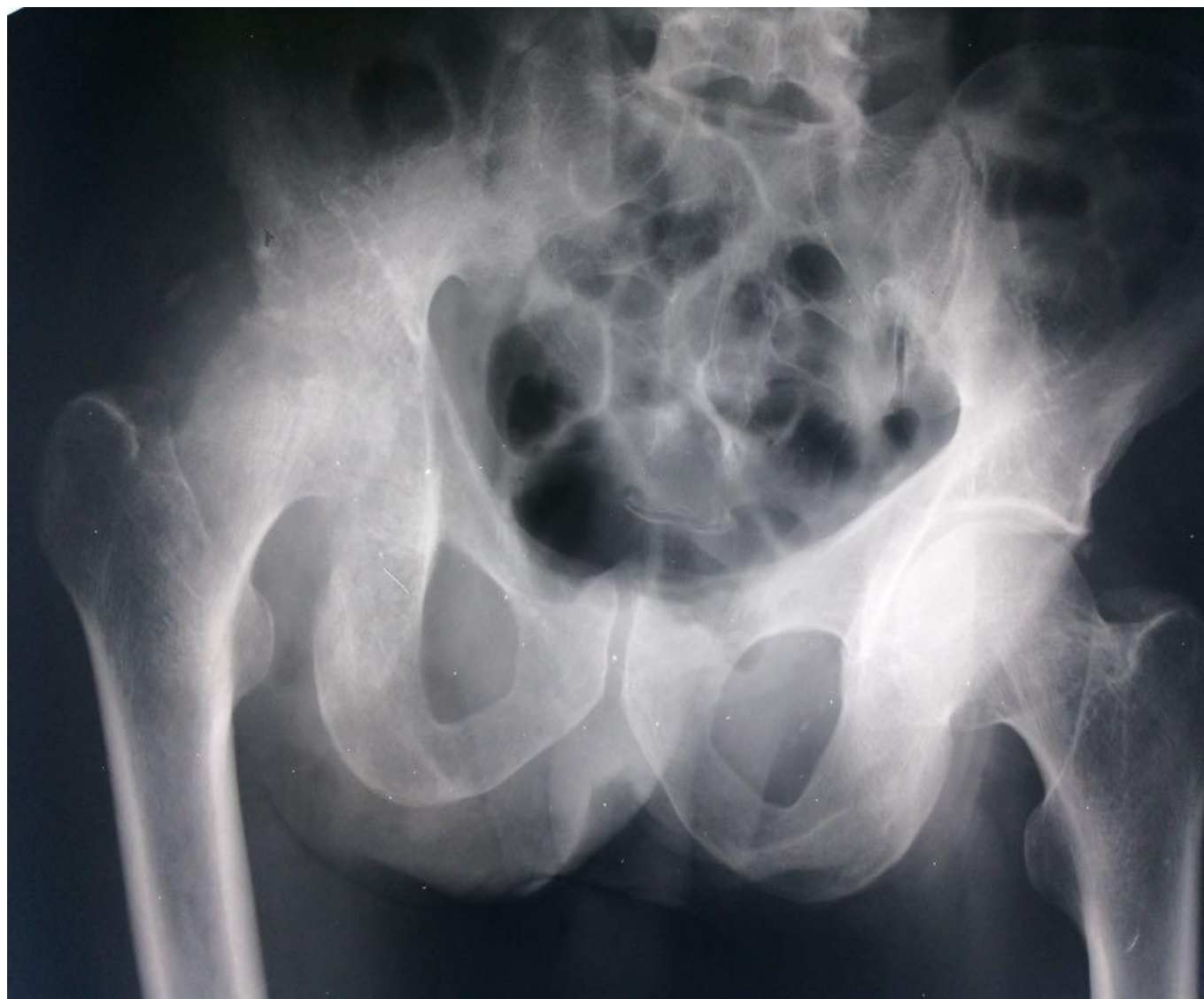










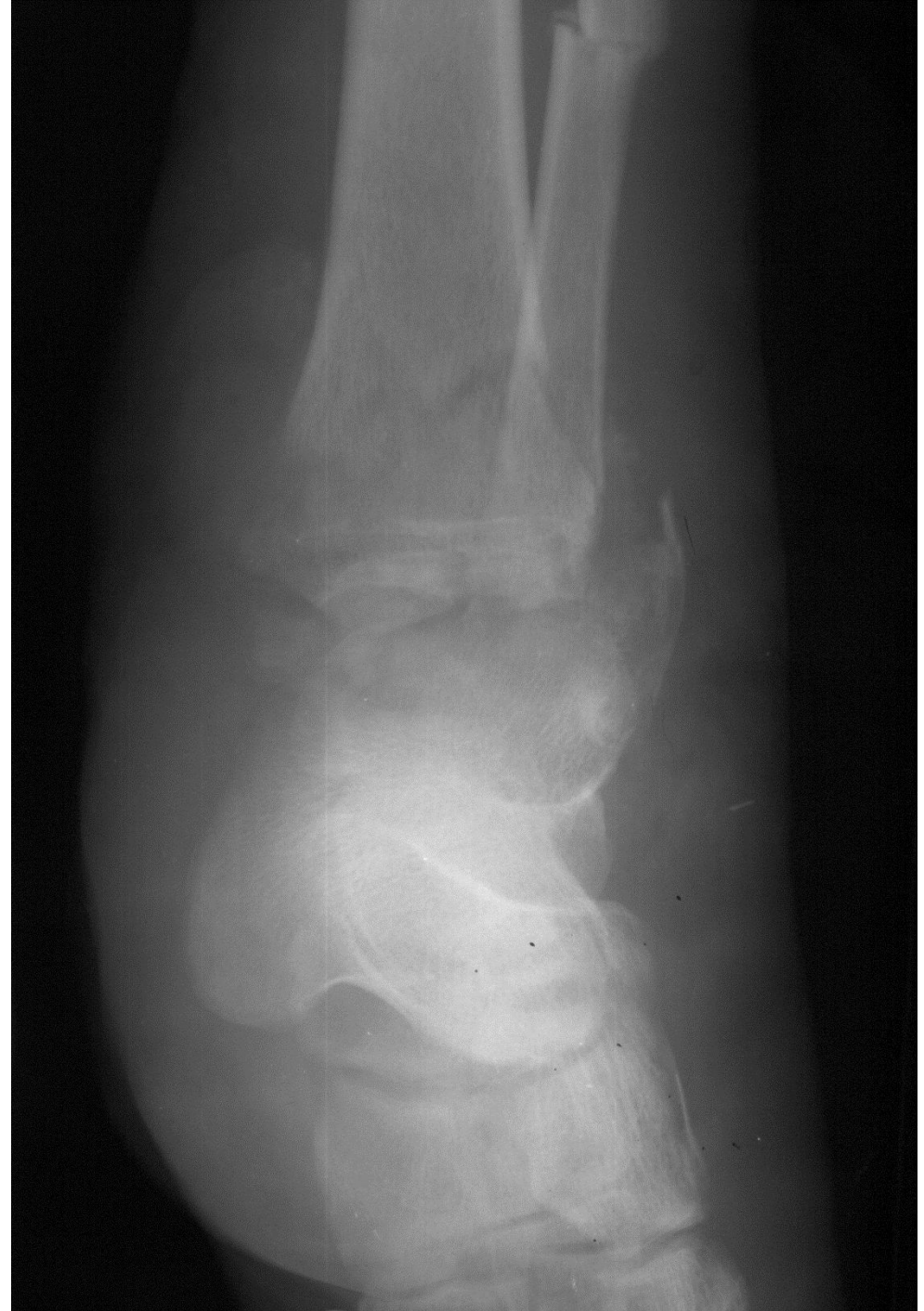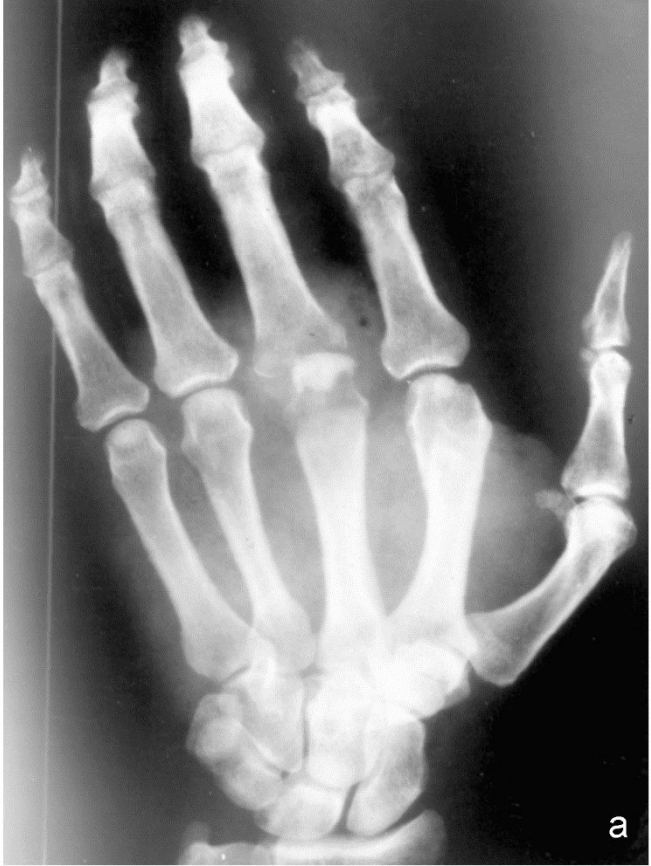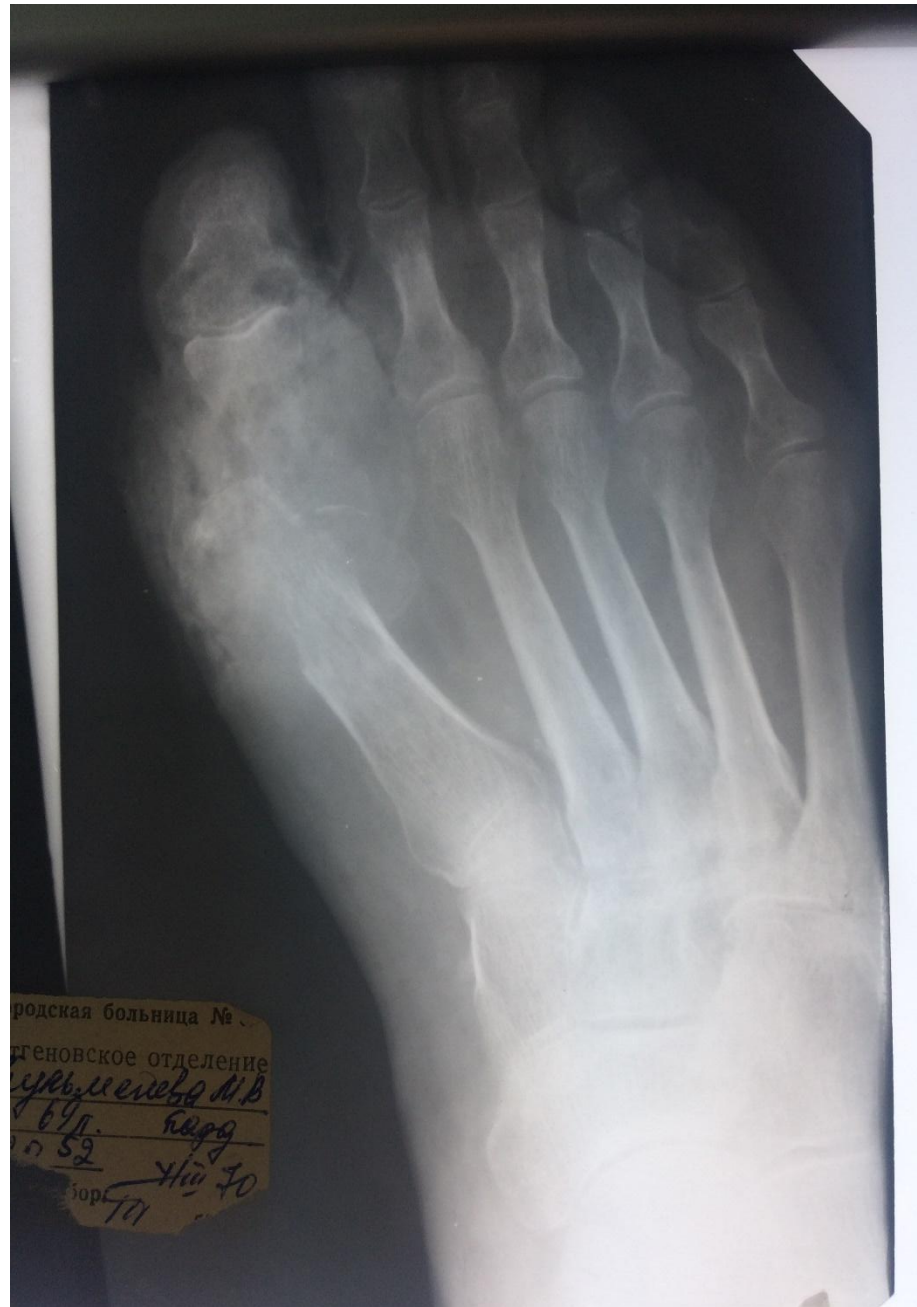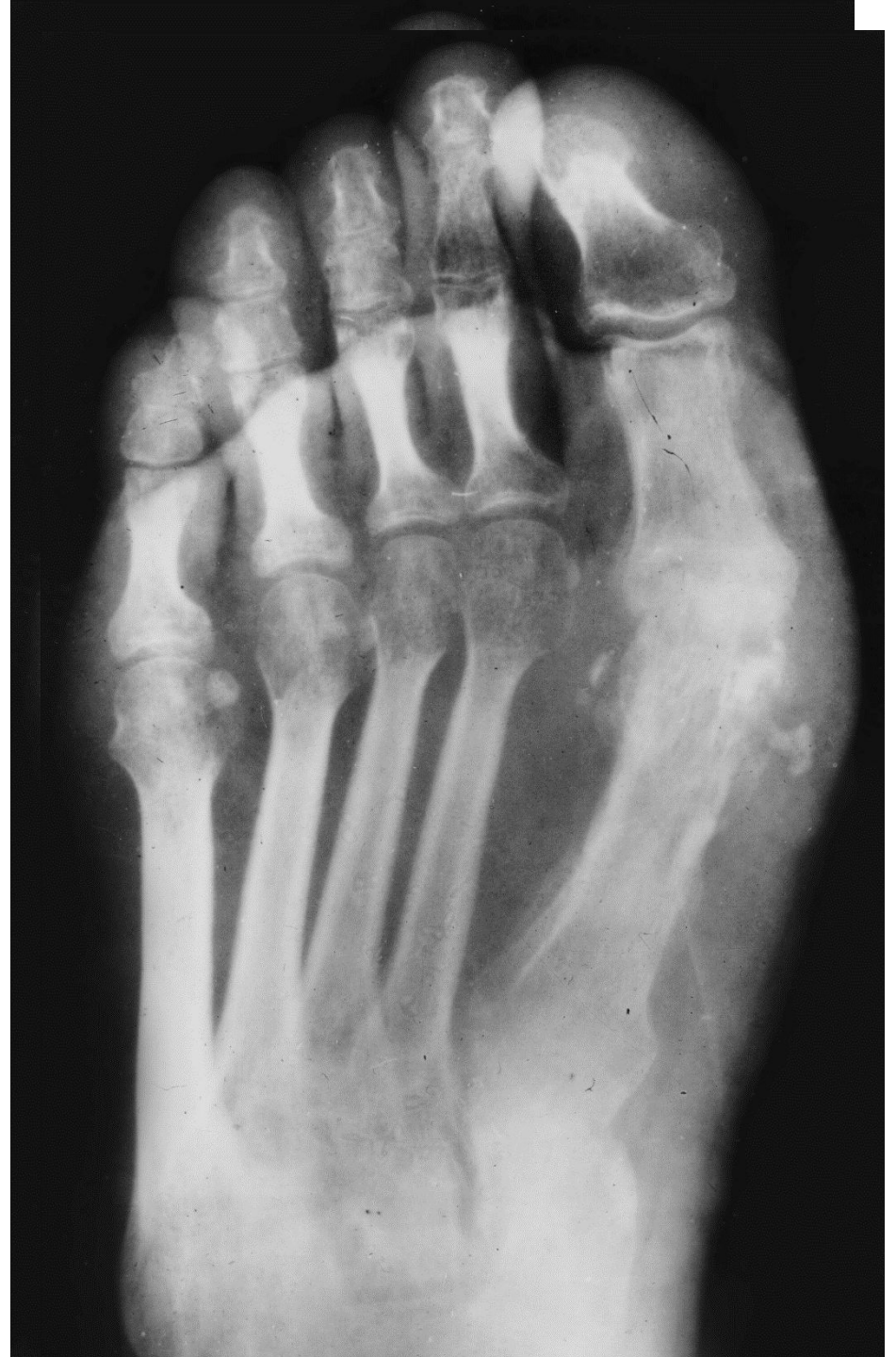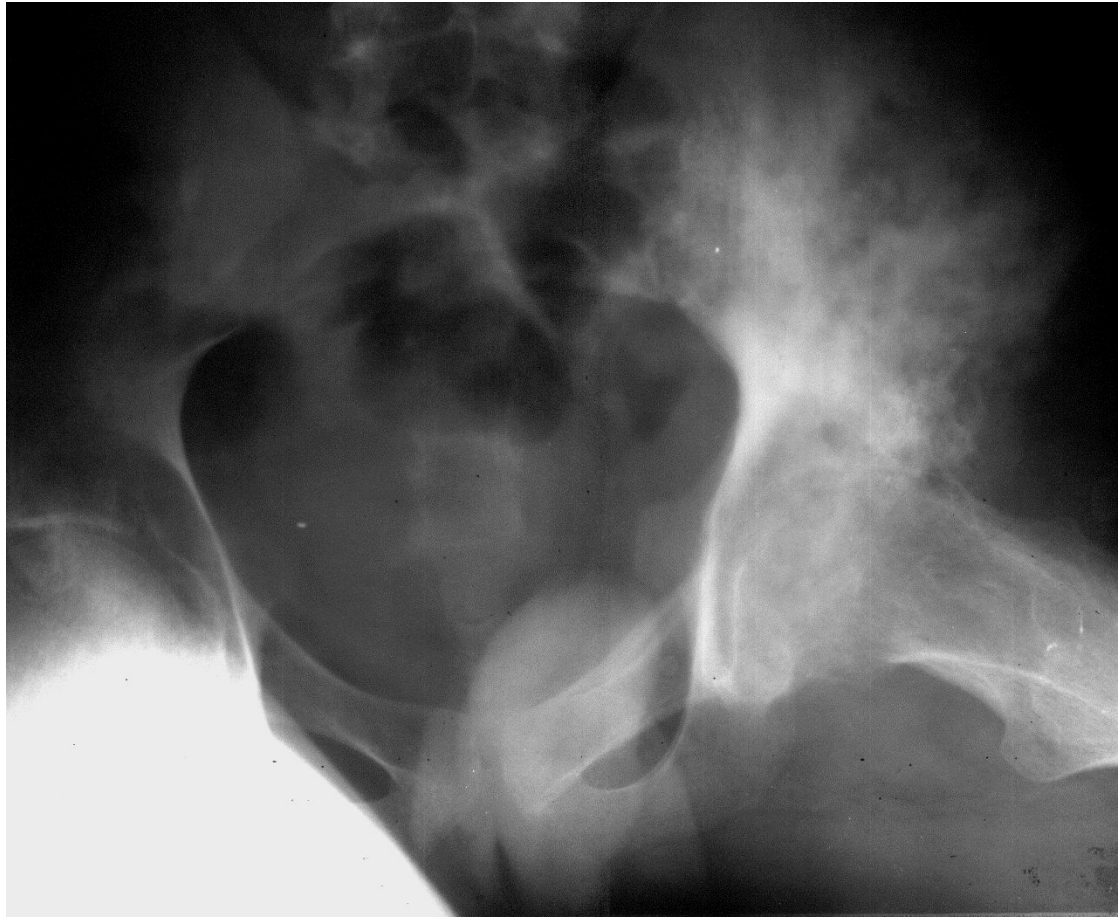






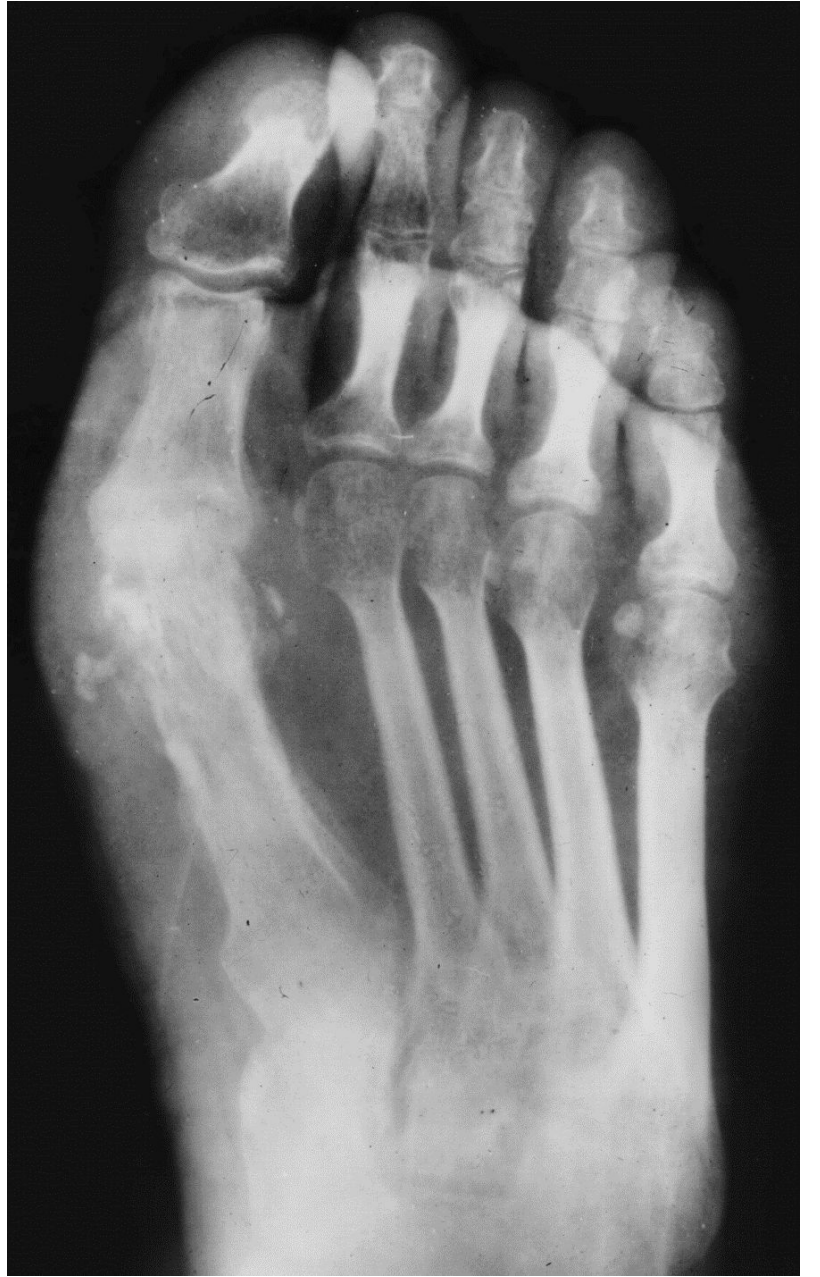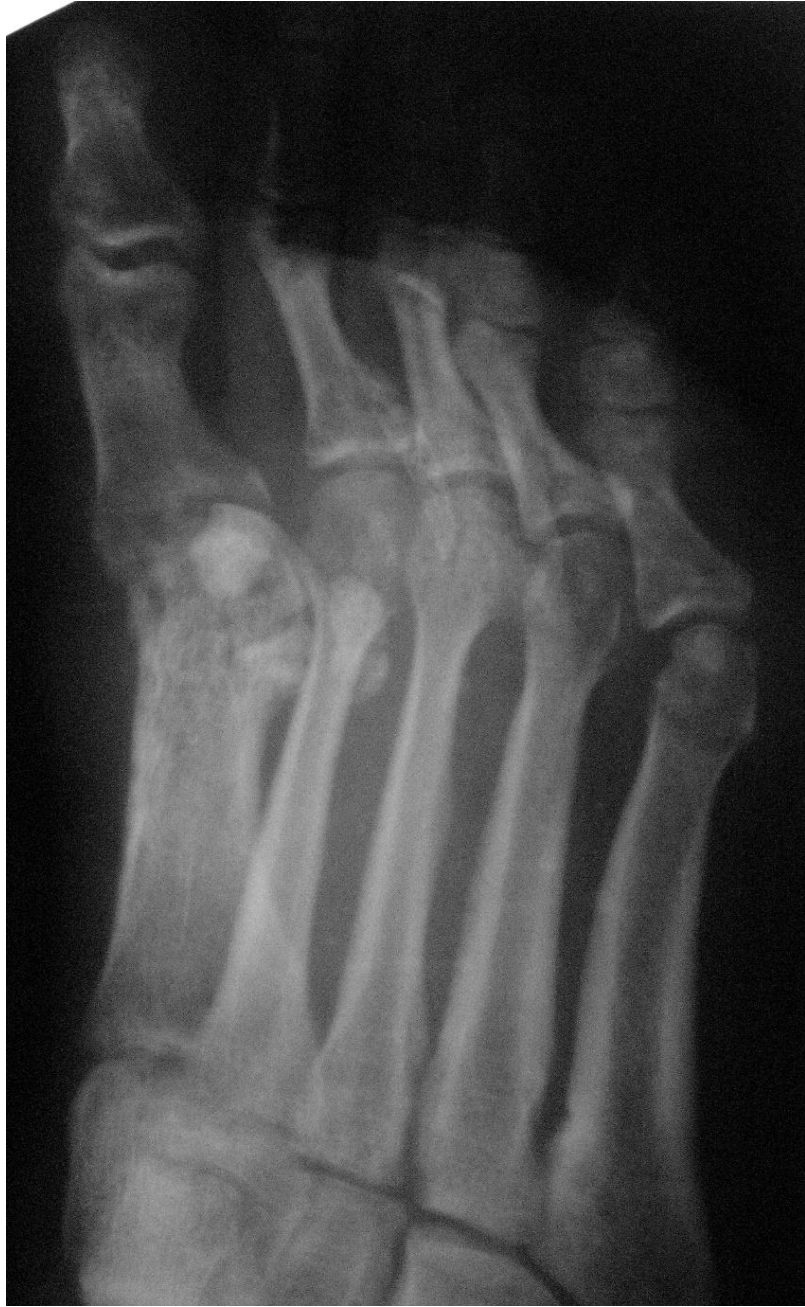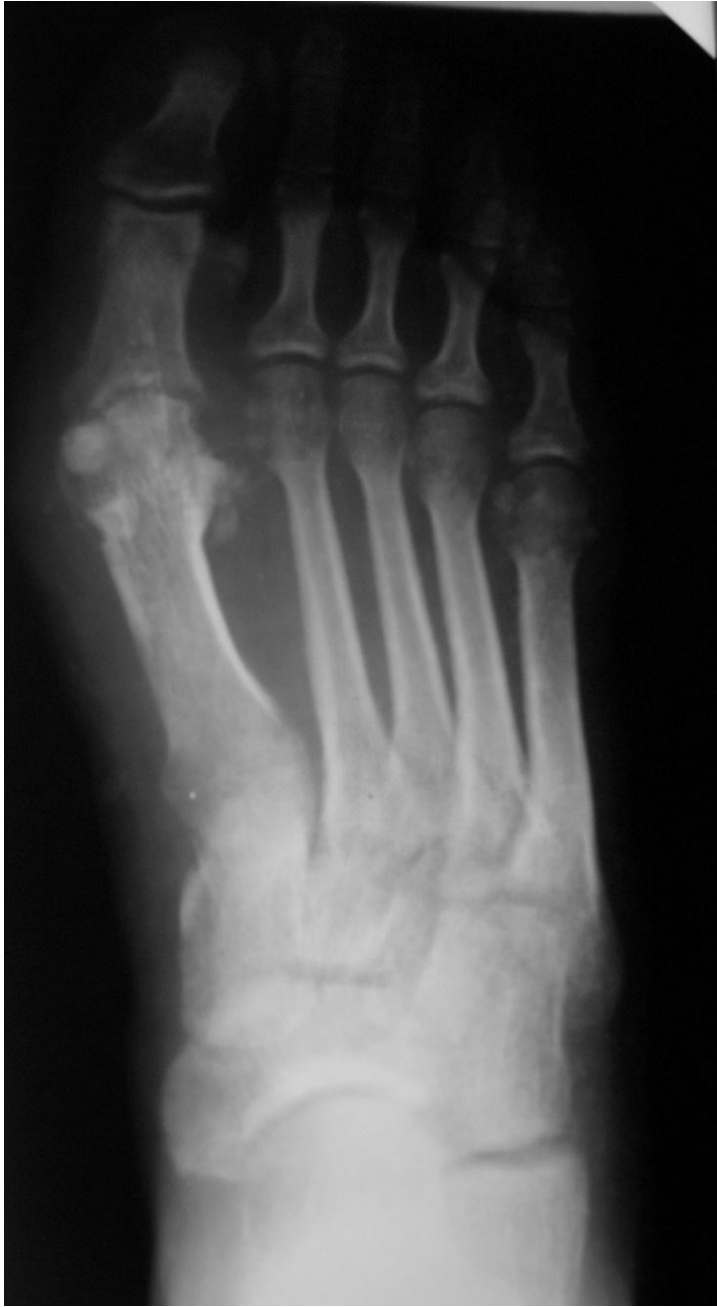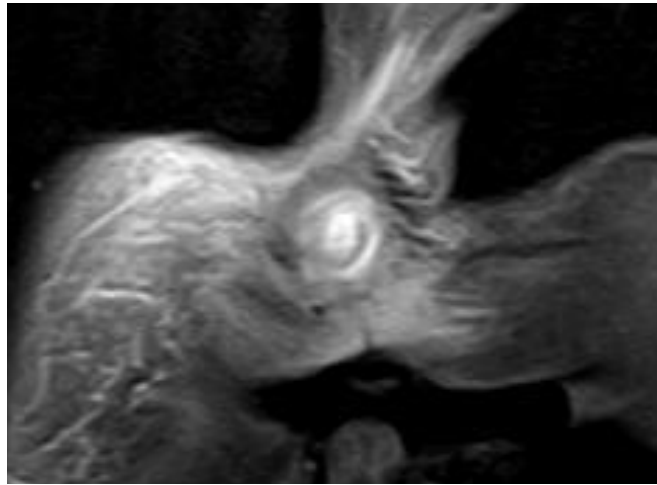
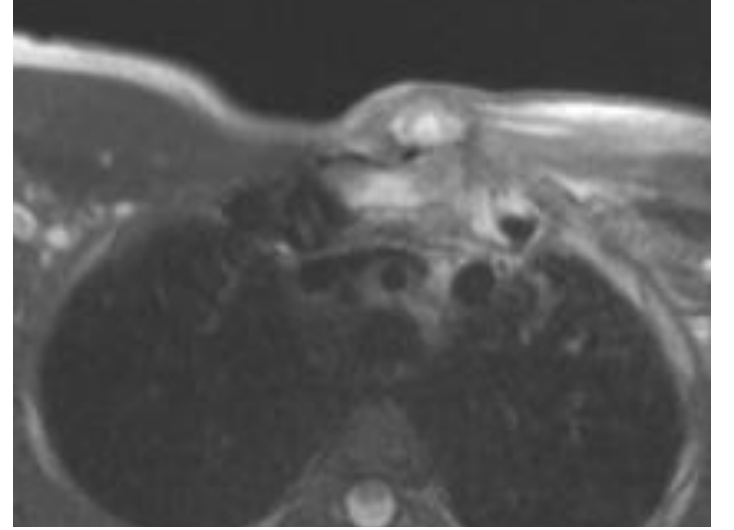
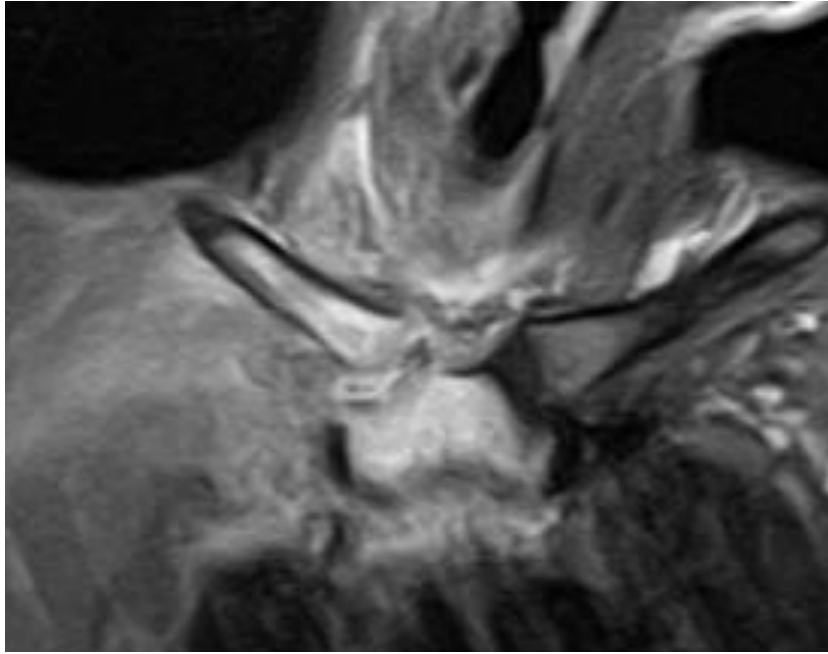


Родская больница № ...  
Рентгеновское отделение  
Сурьменев М.В.  
69л. Жен.  
n 52  
1970 г.р.

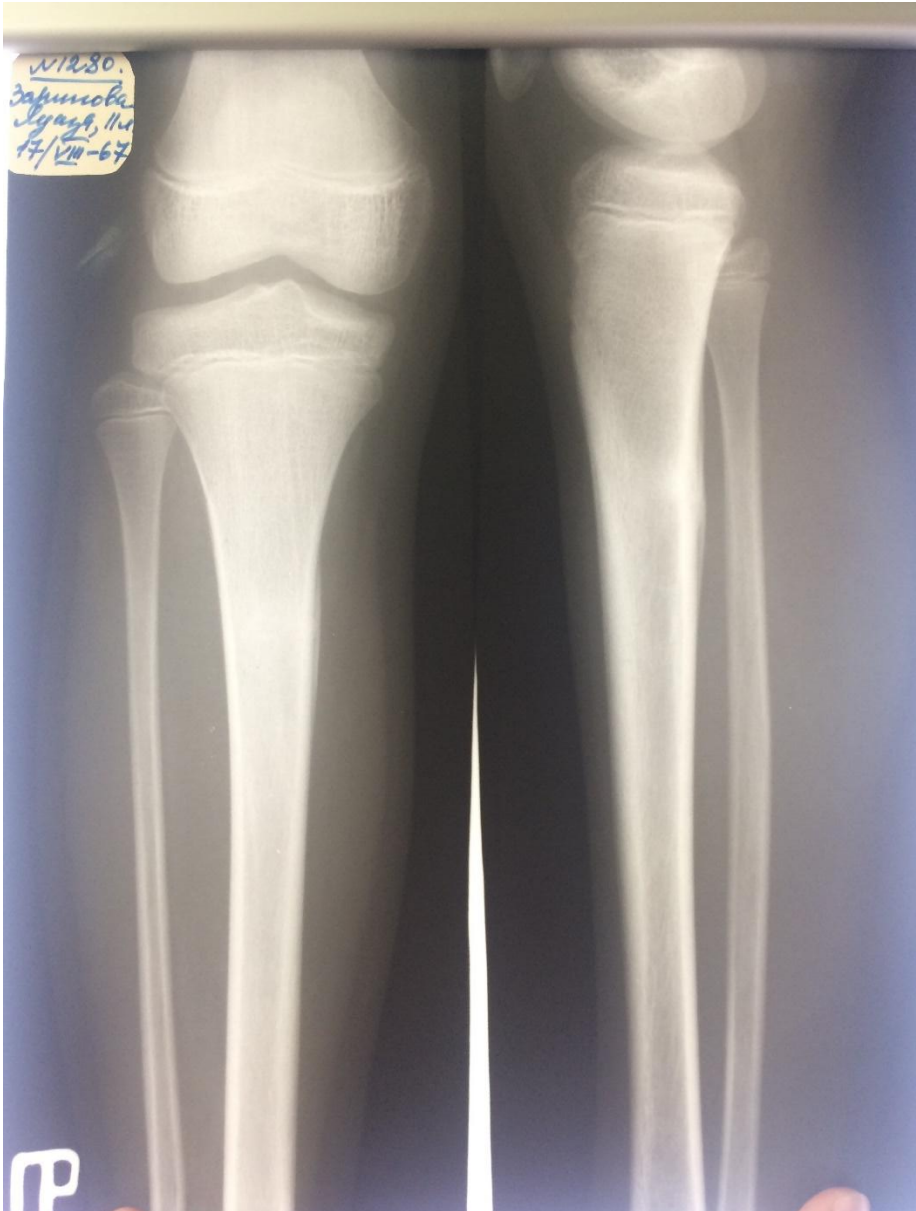


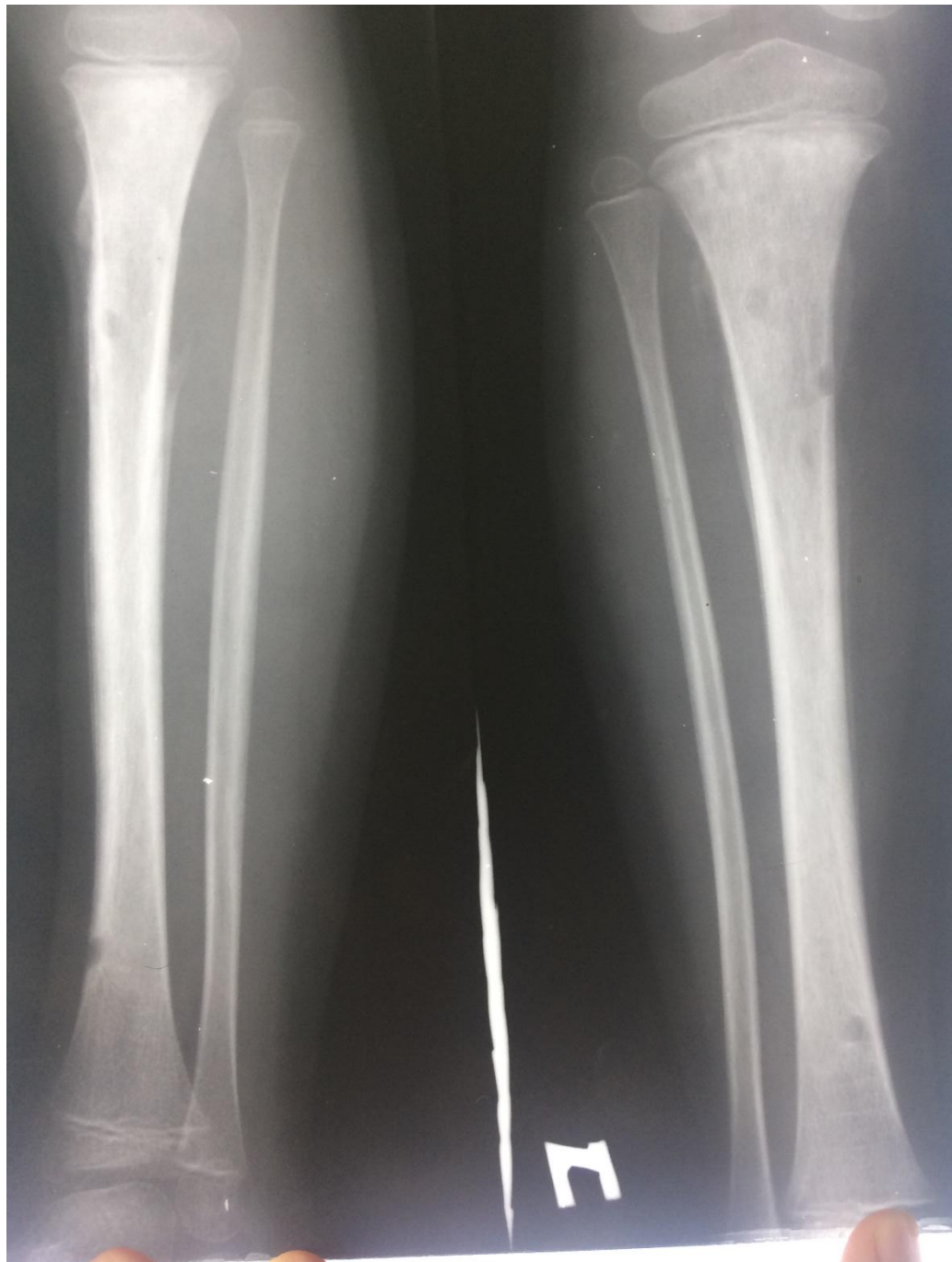


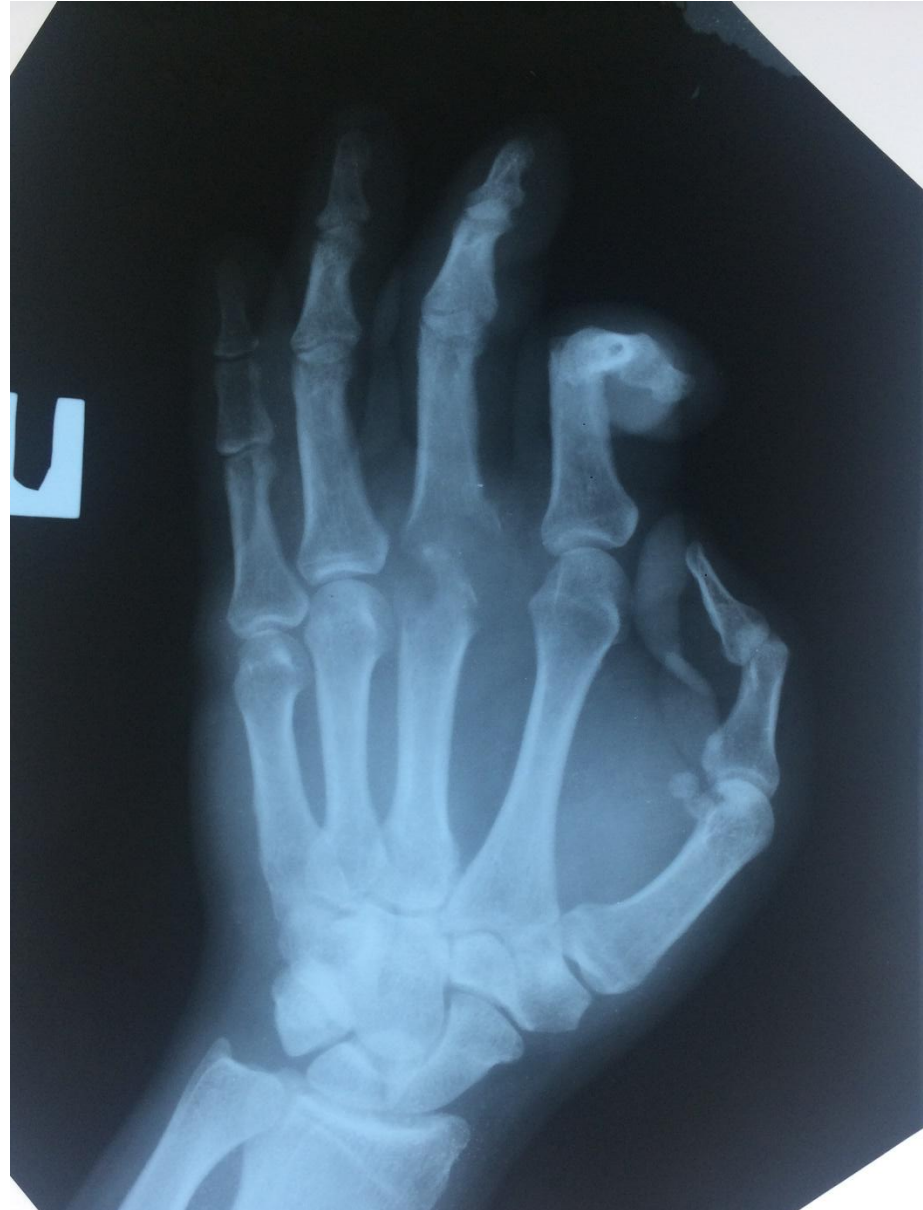


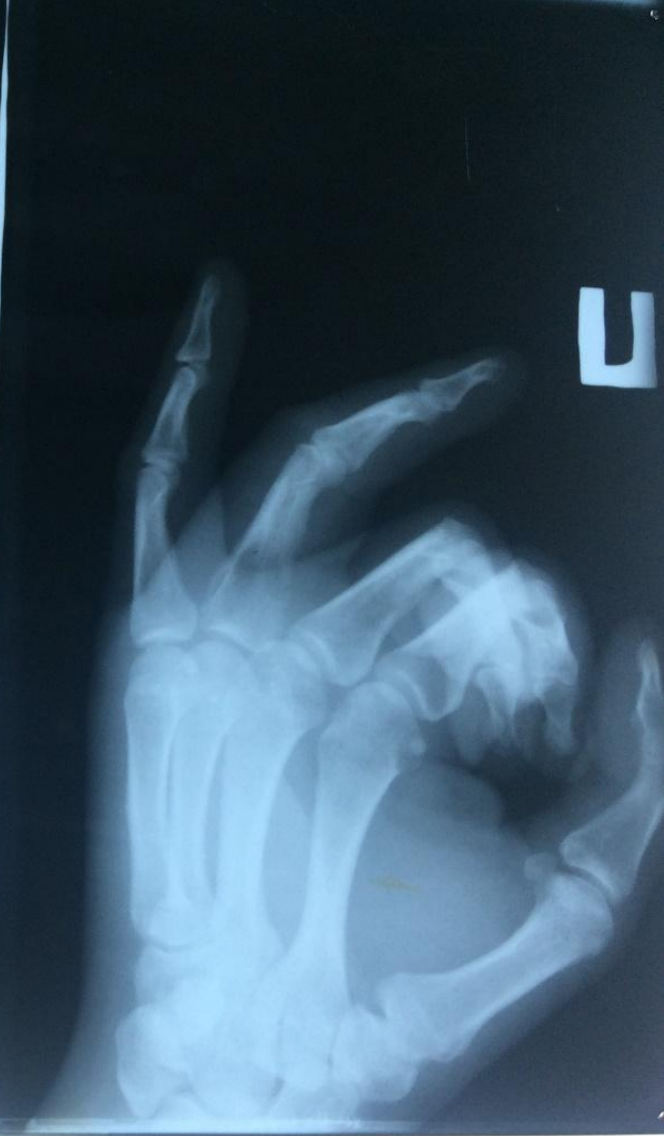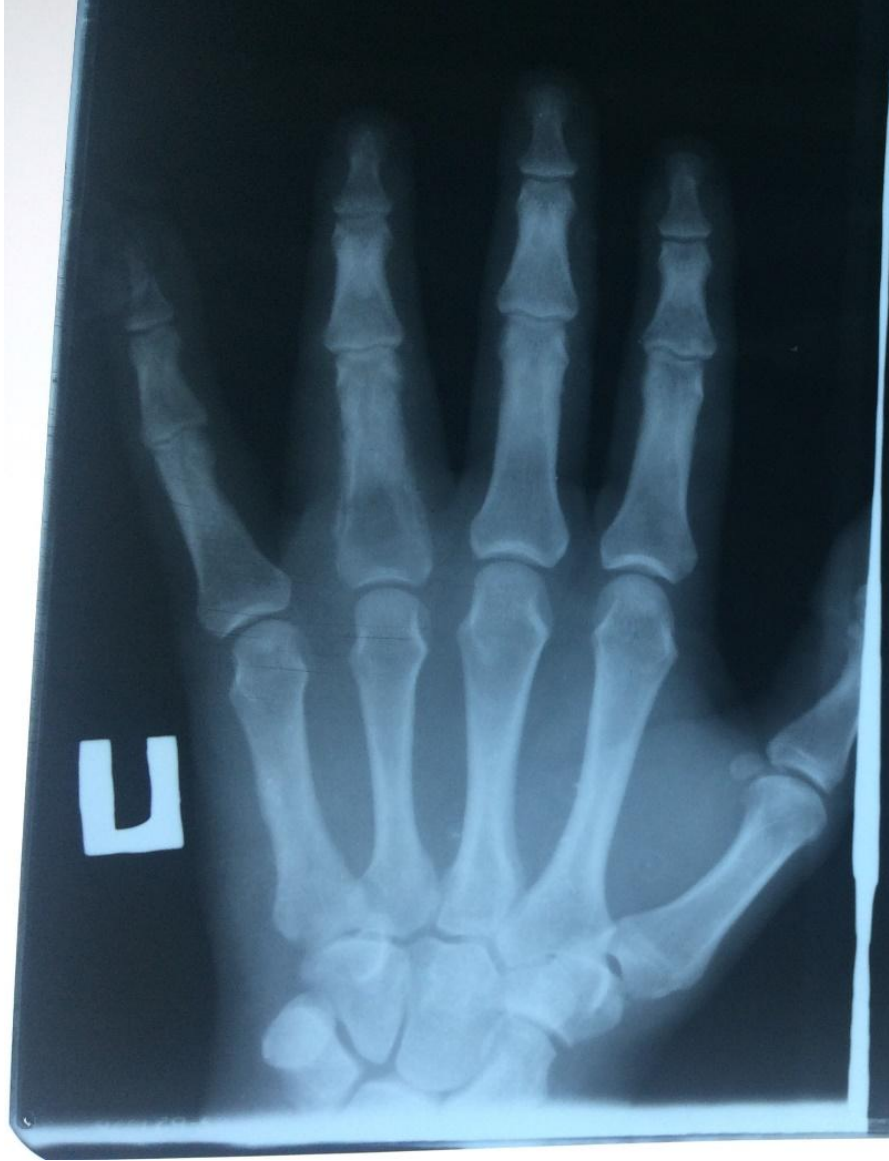N1230.  
Зарубова  
Людмила, 11 лет  
17/VII-67

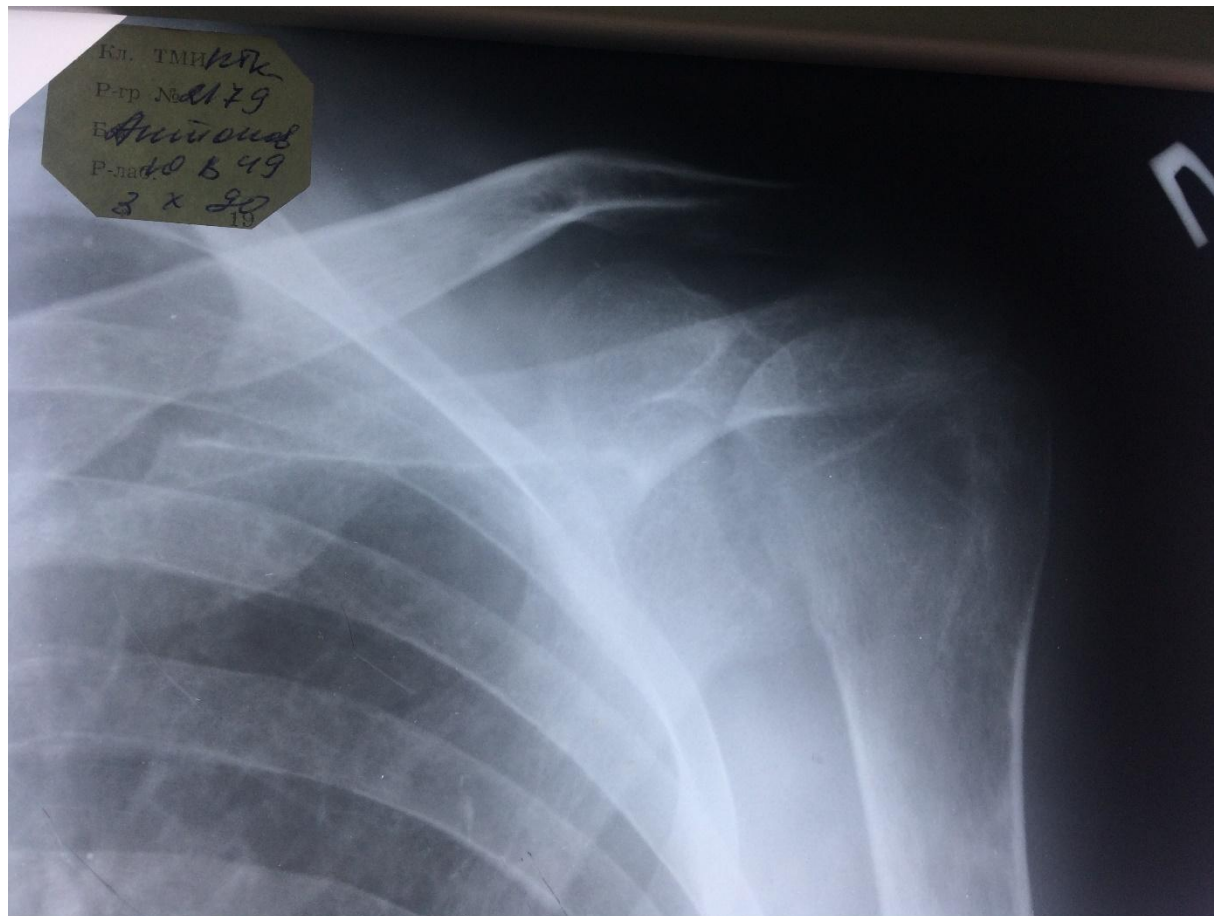


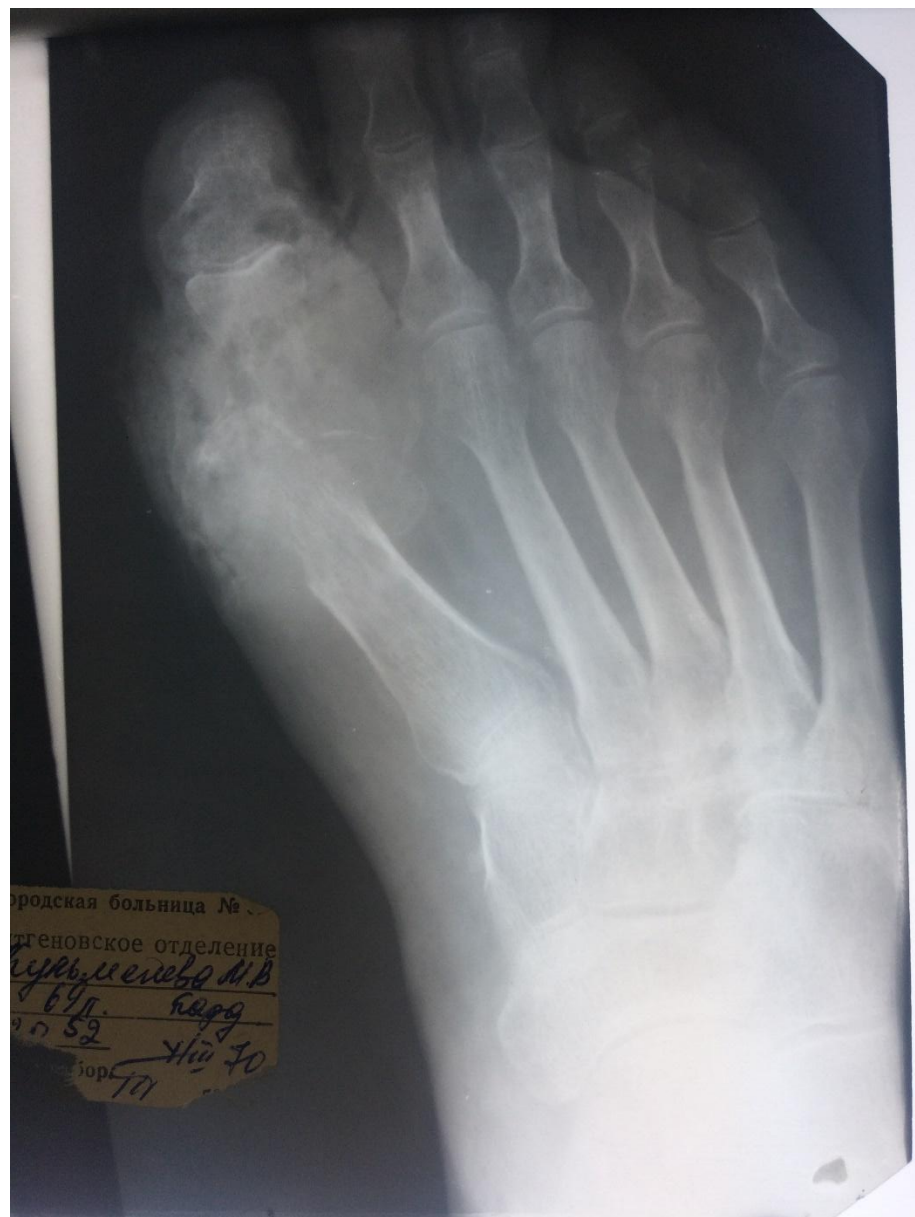



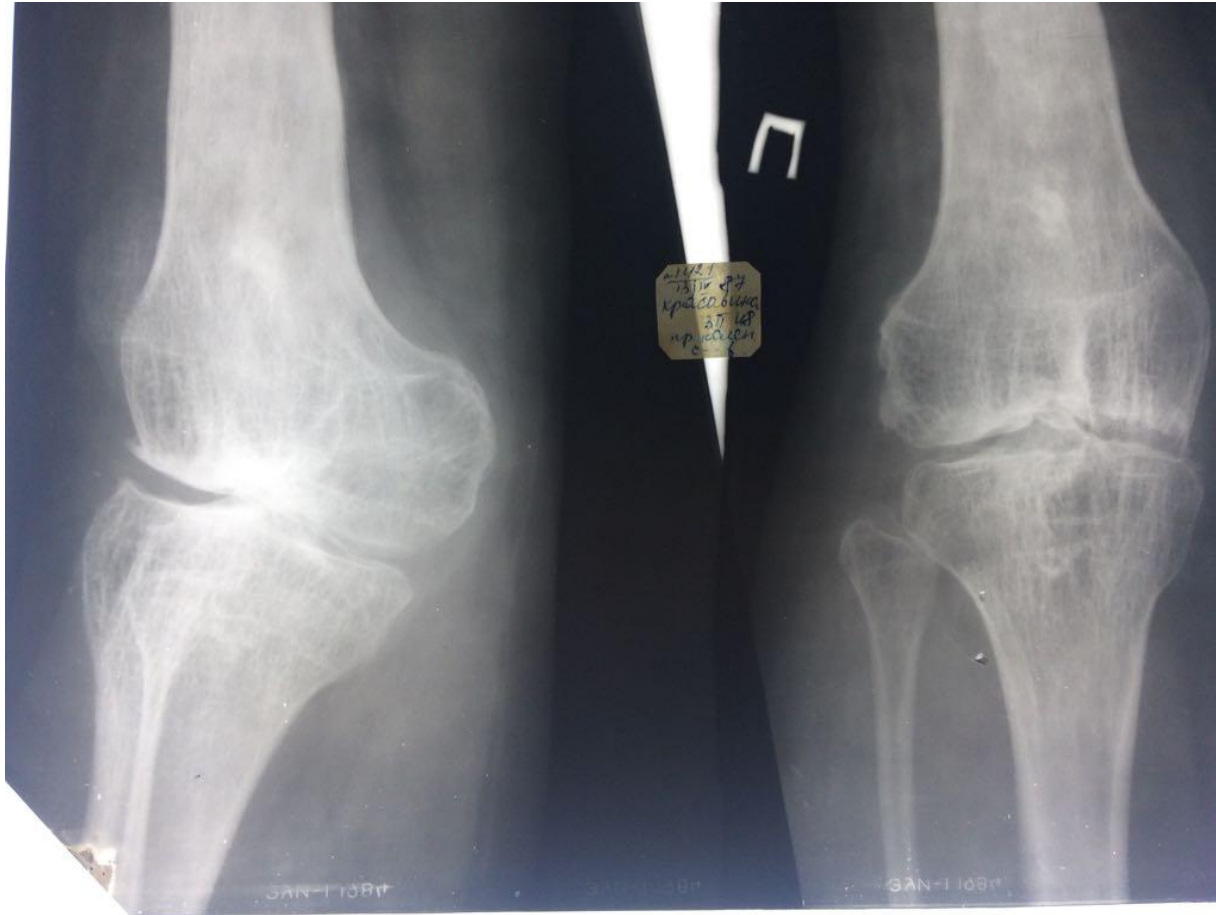



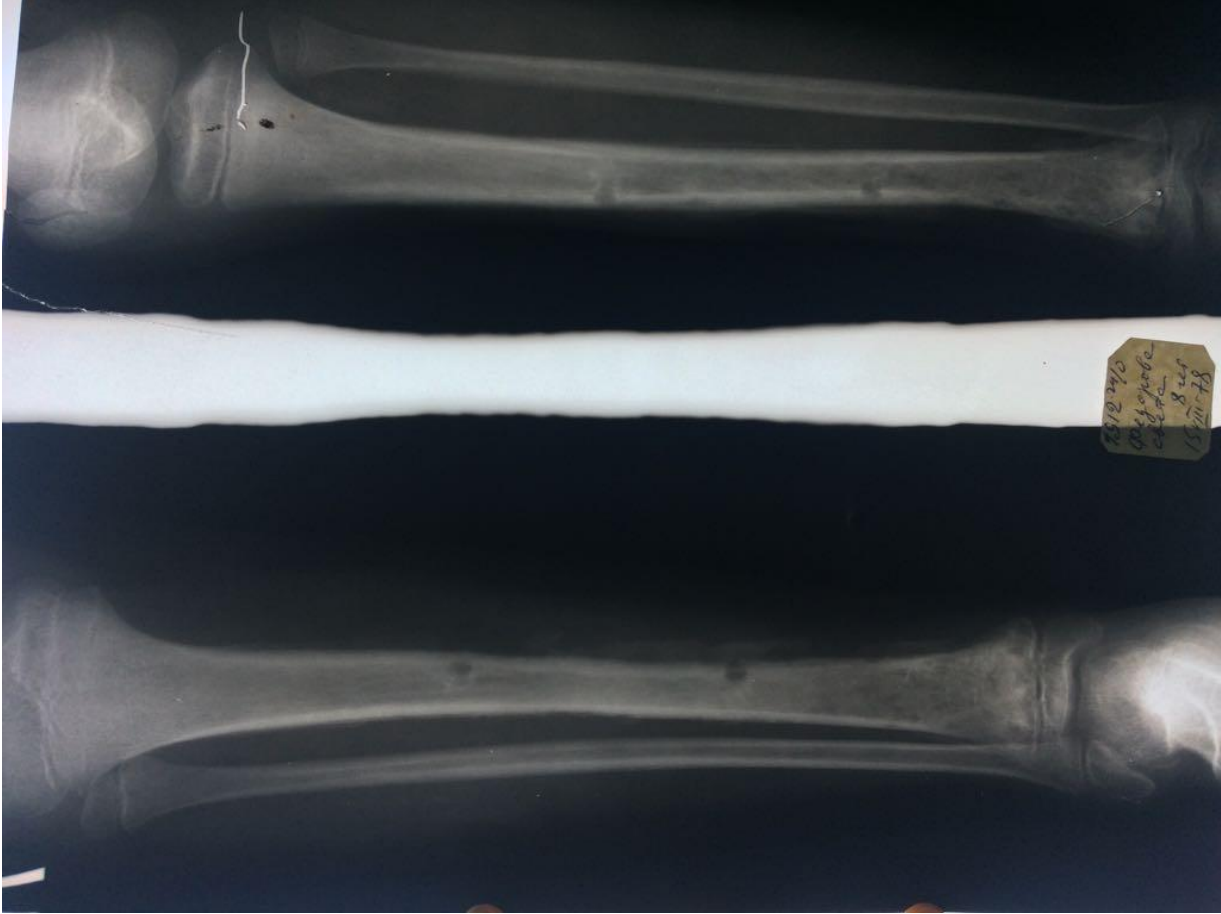




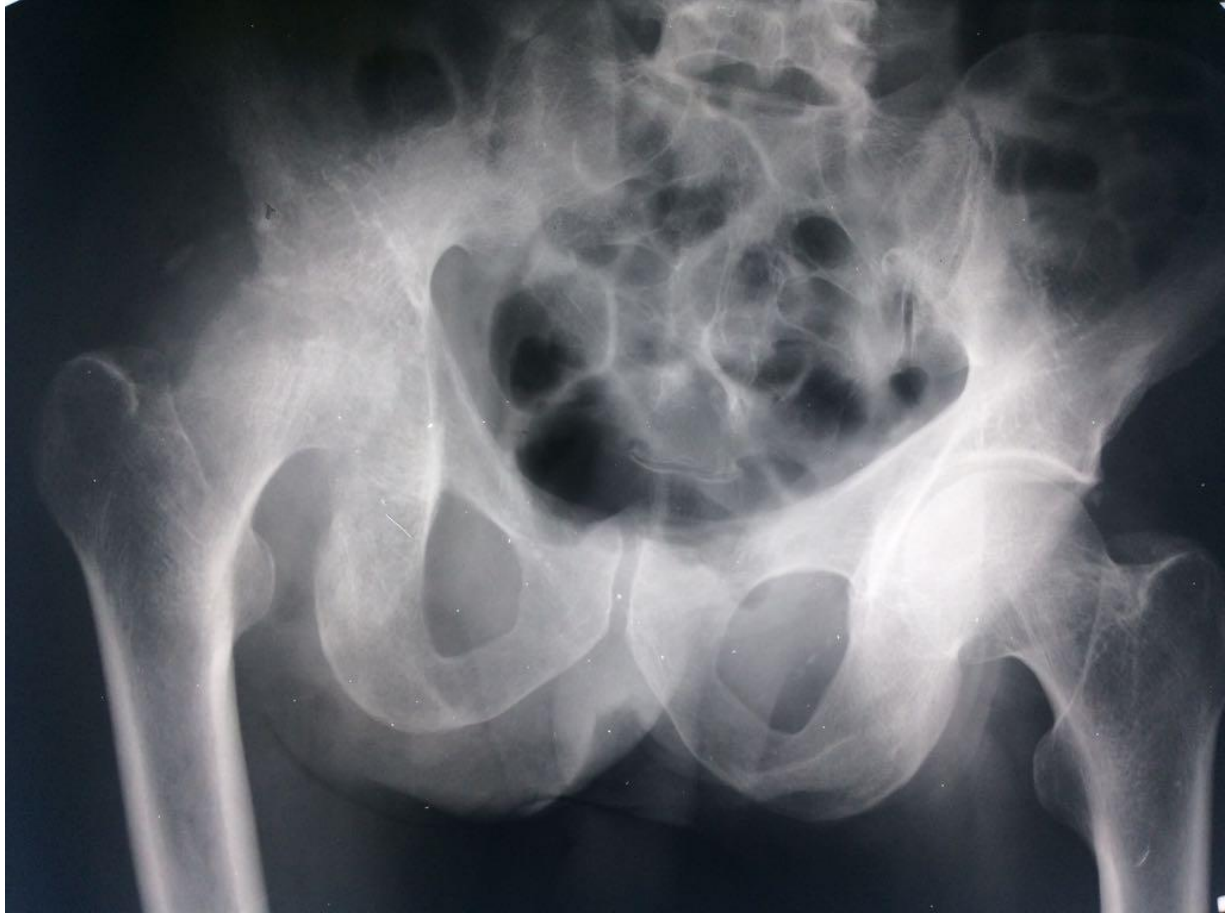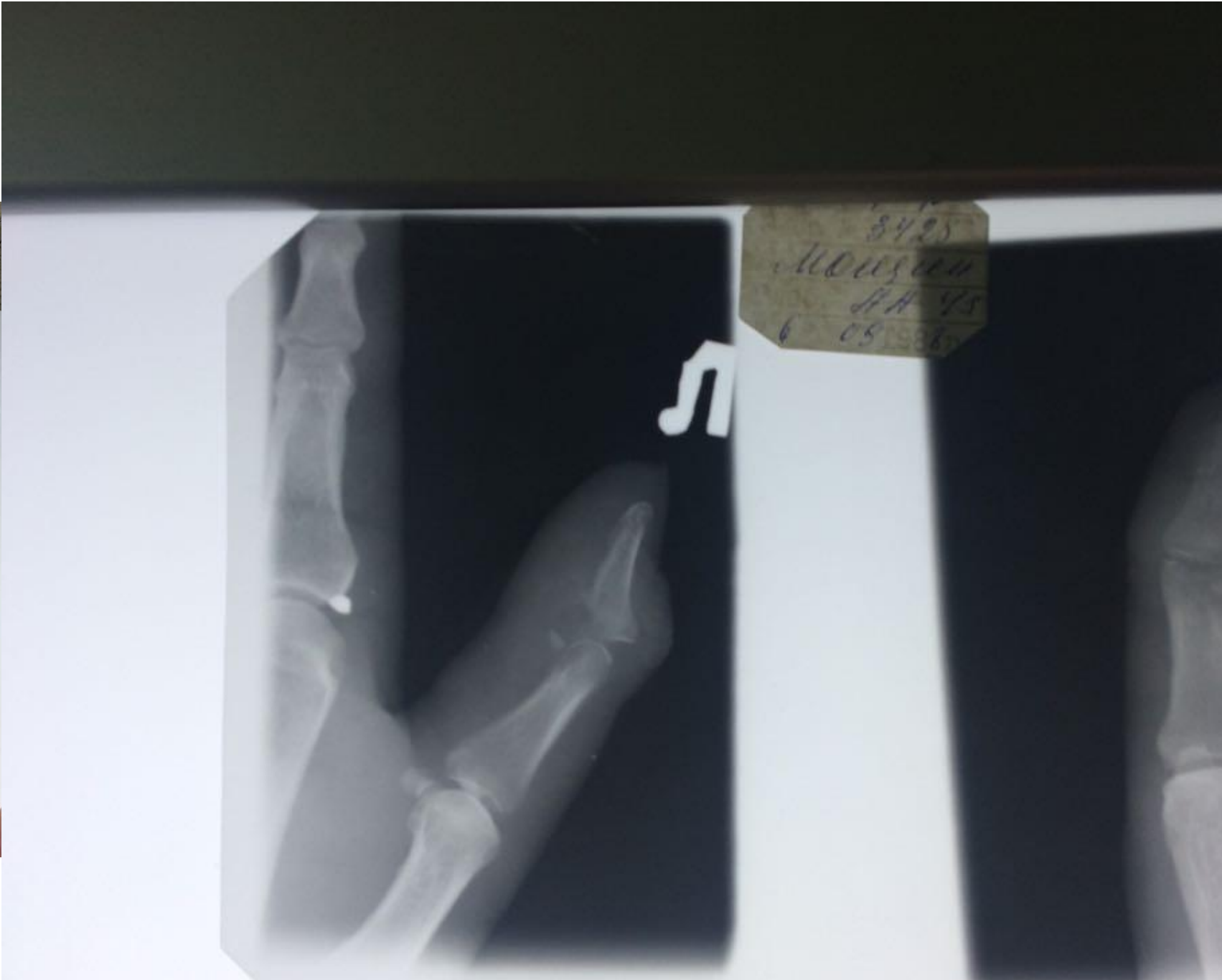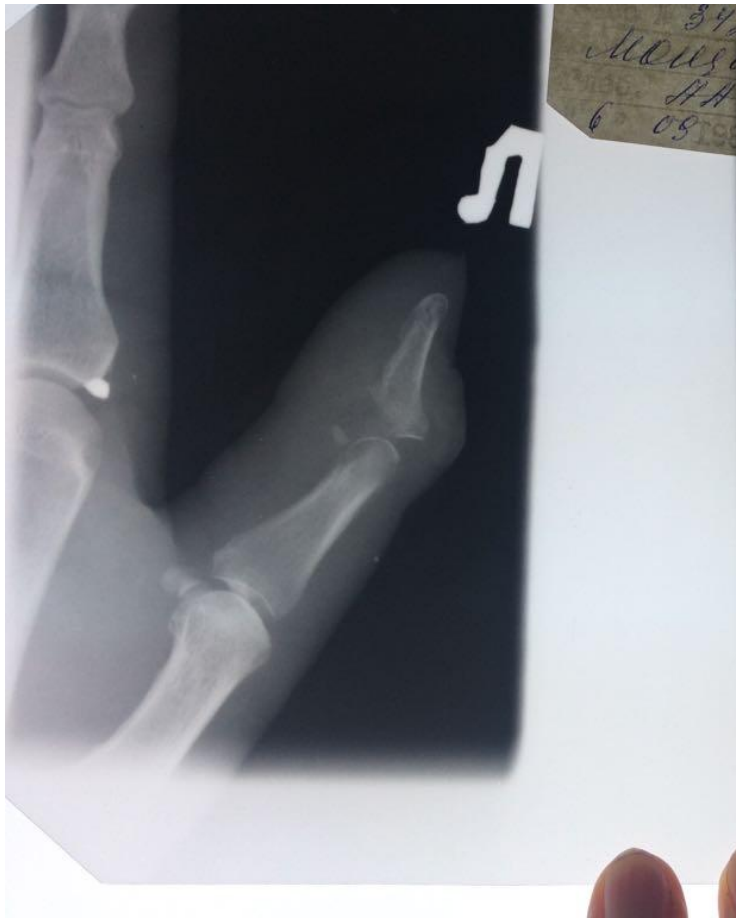ородская больница № .  
твенное отделение  
Сурь, К. С. М. В.  
647. К. С. М. В.  
52  
Л. С. М. В.  
70

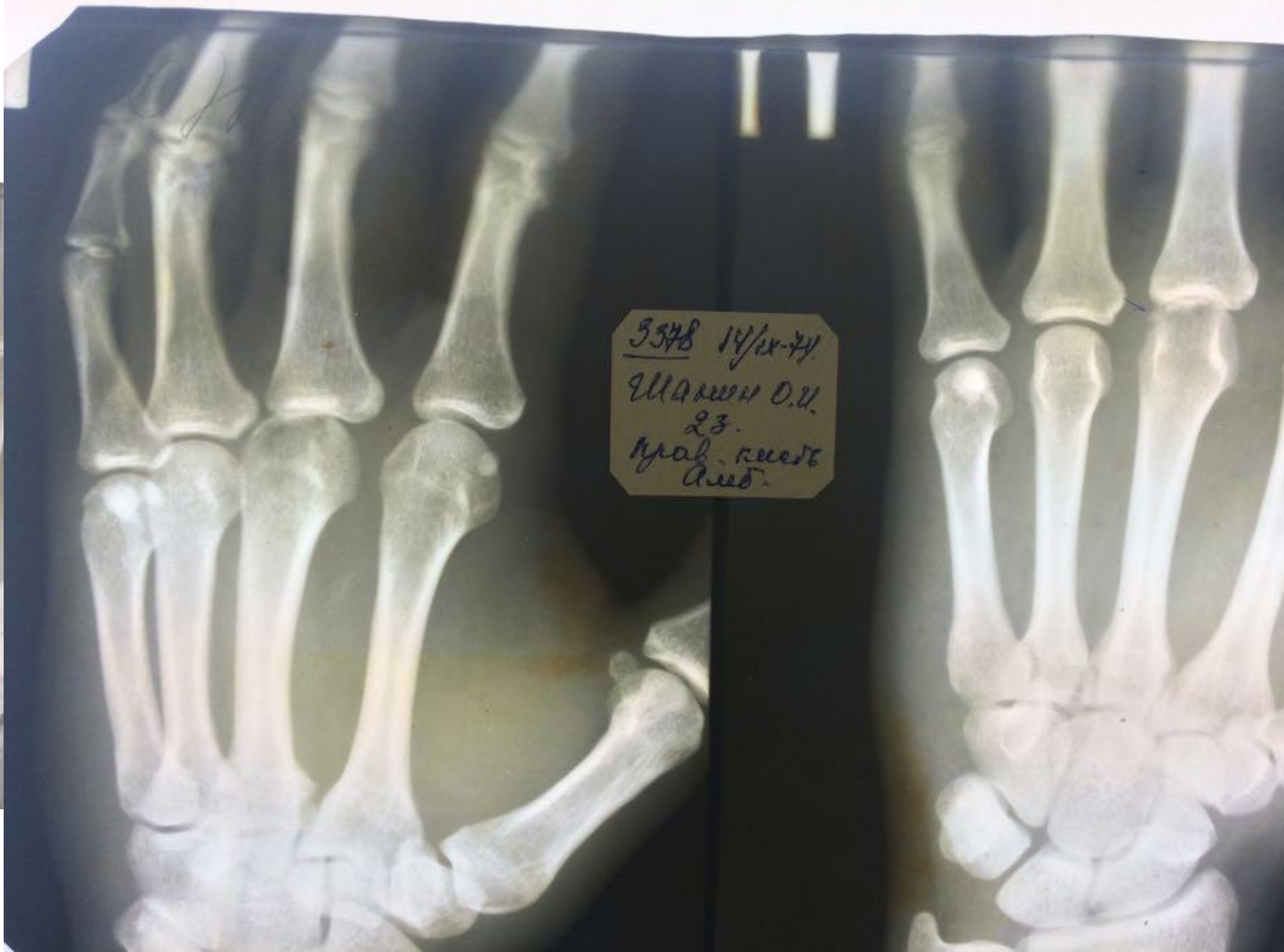
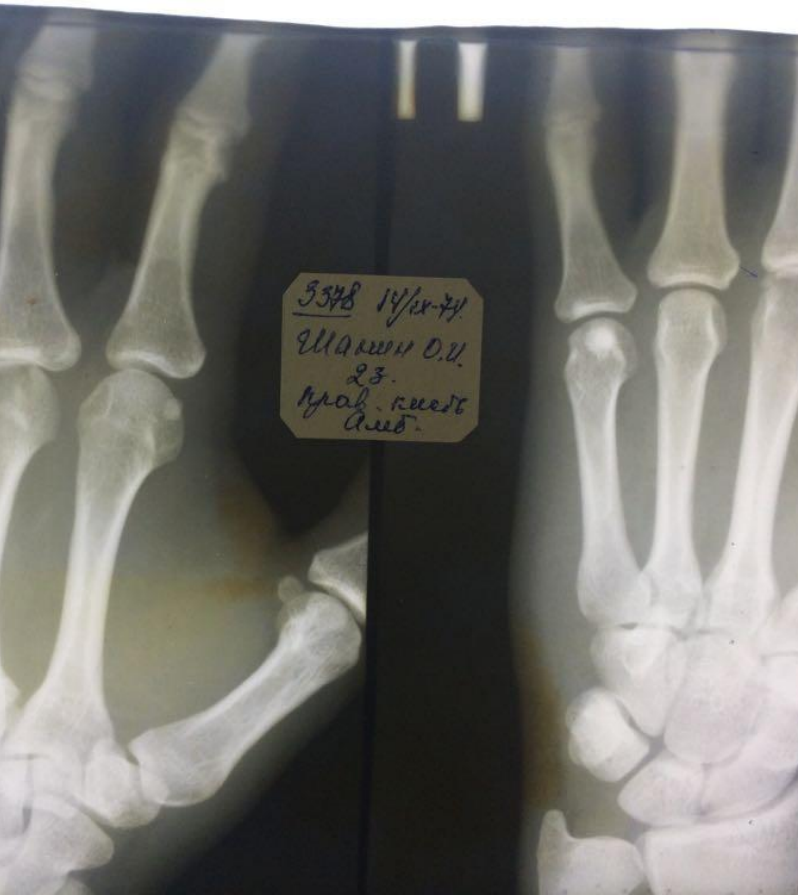




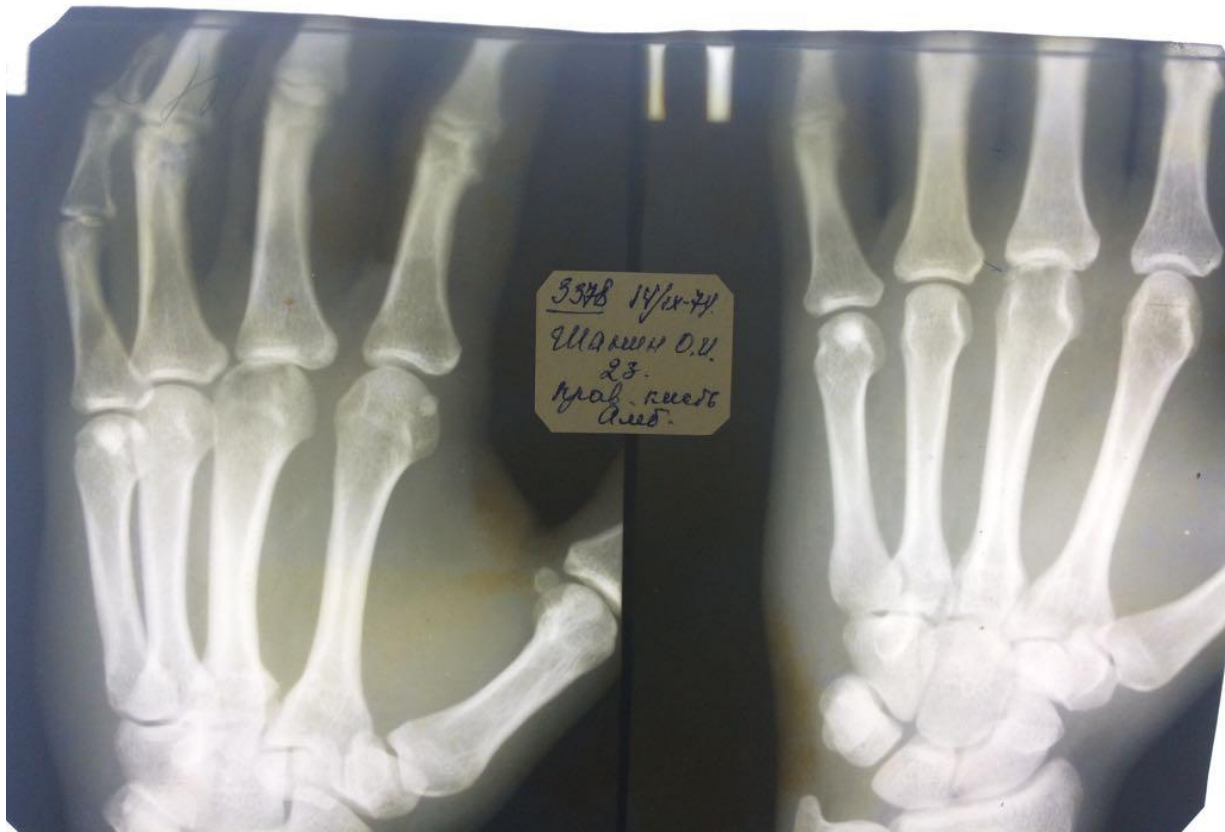




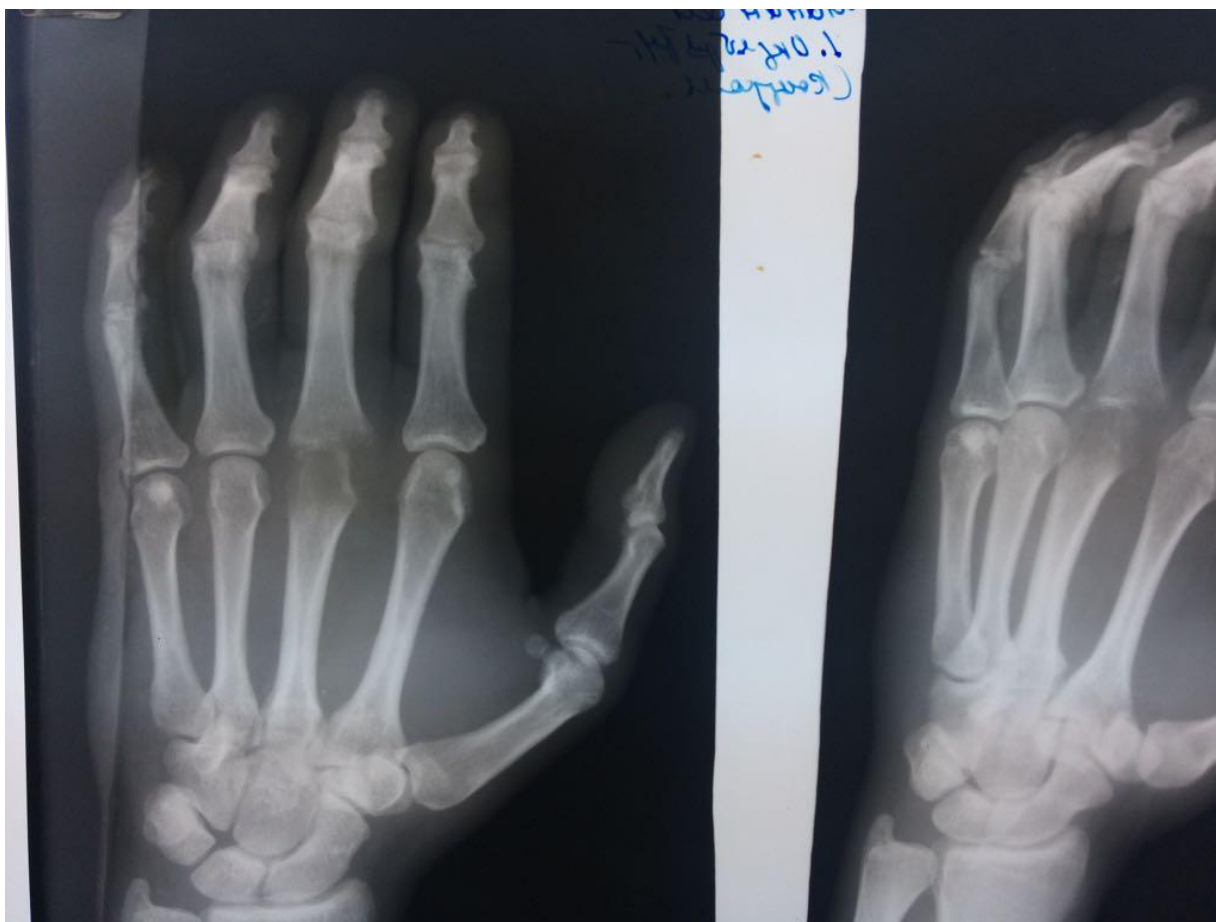


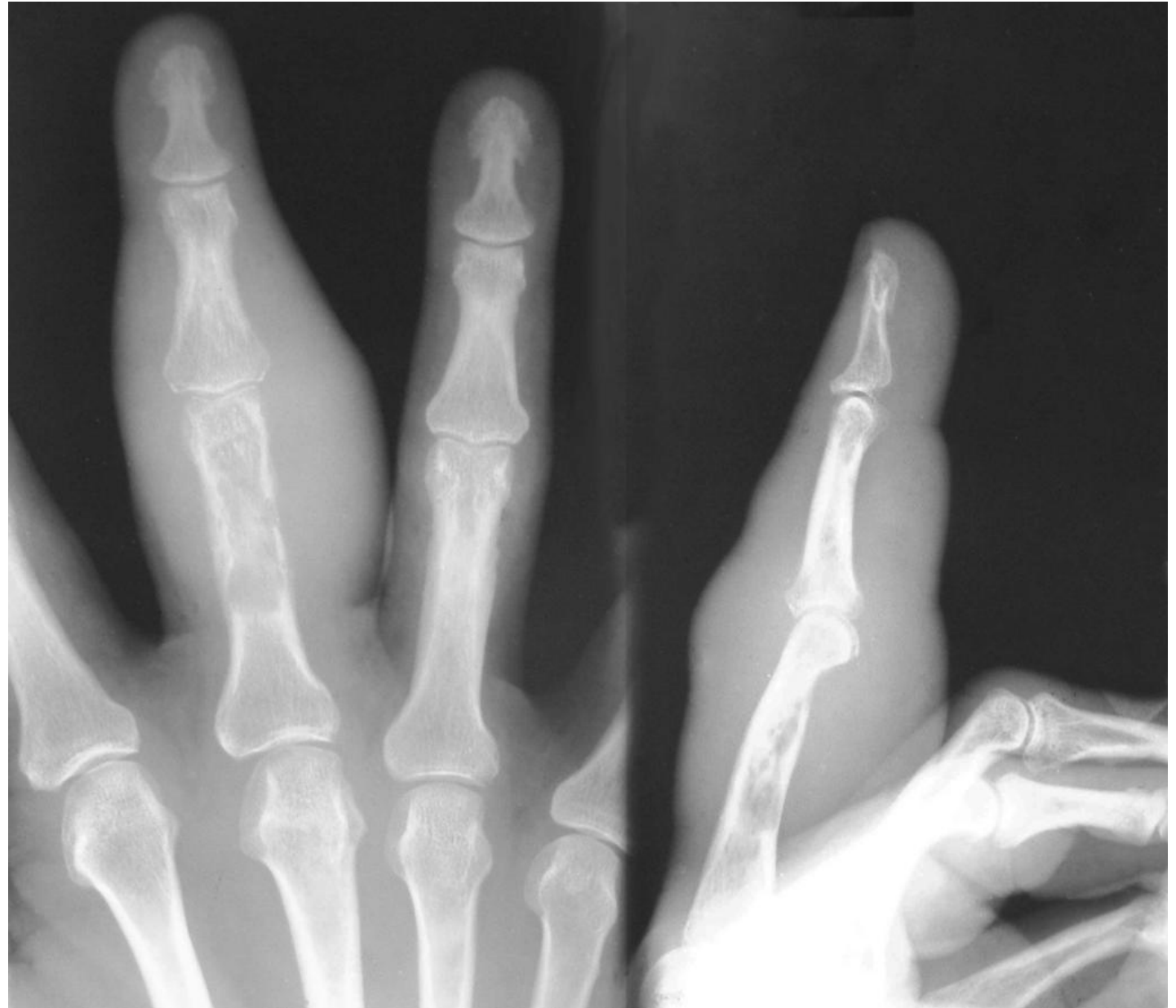
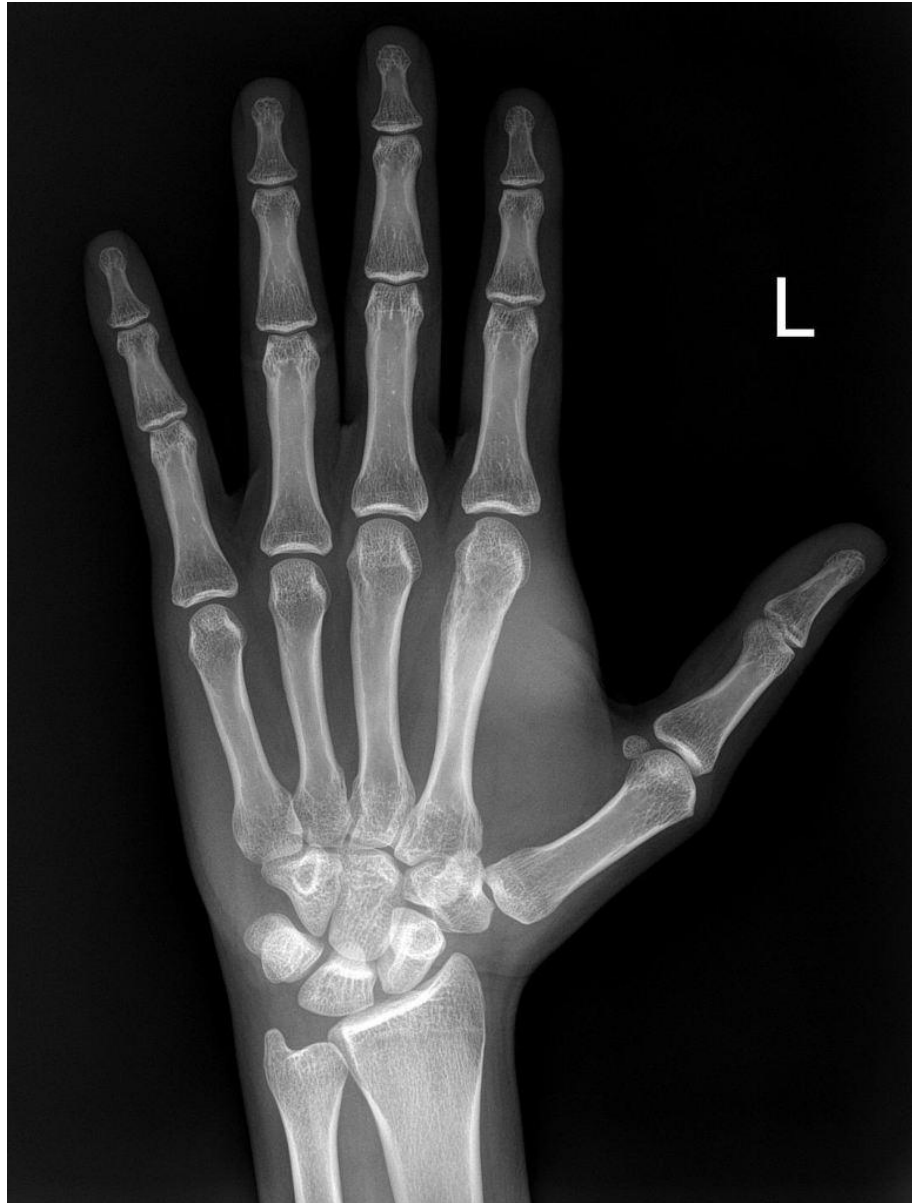
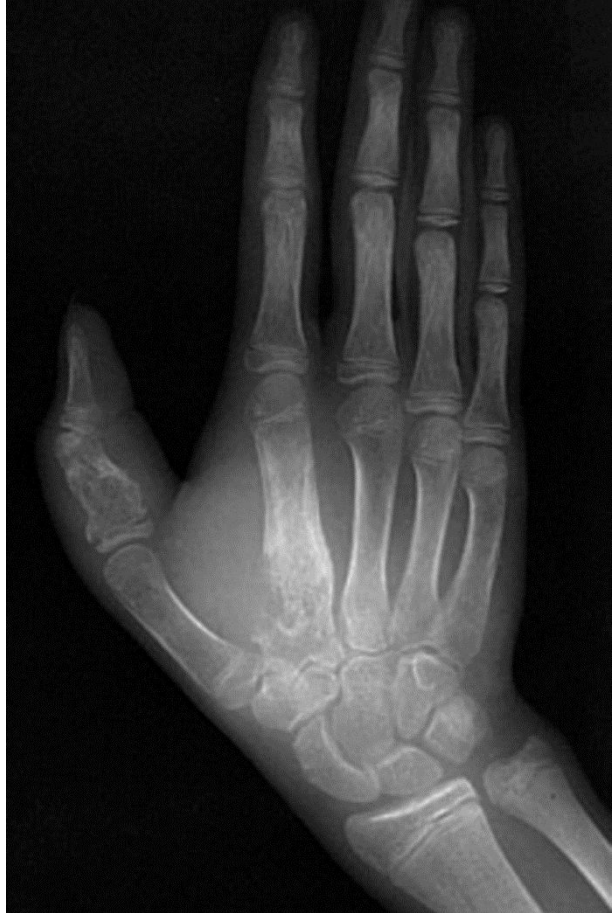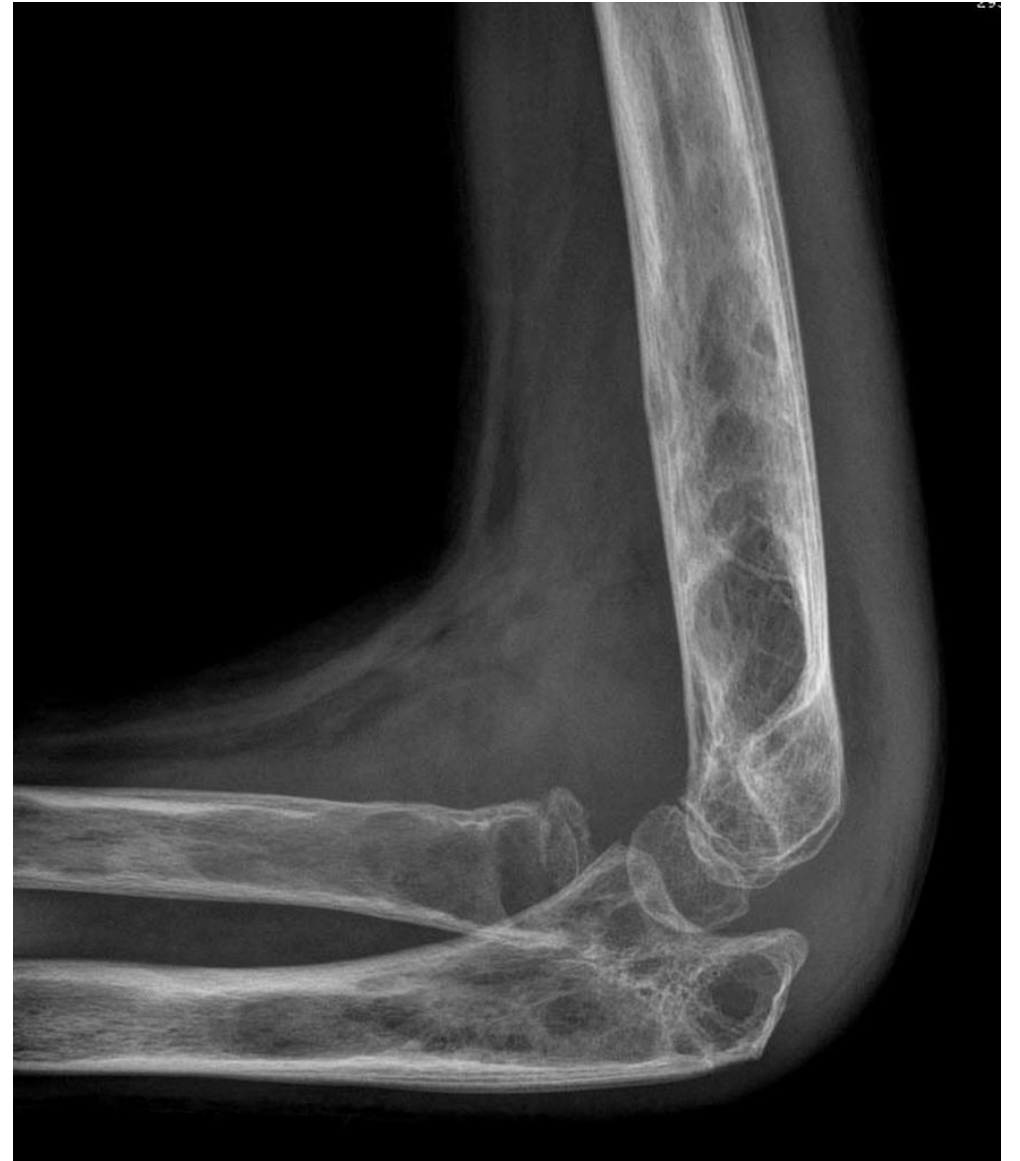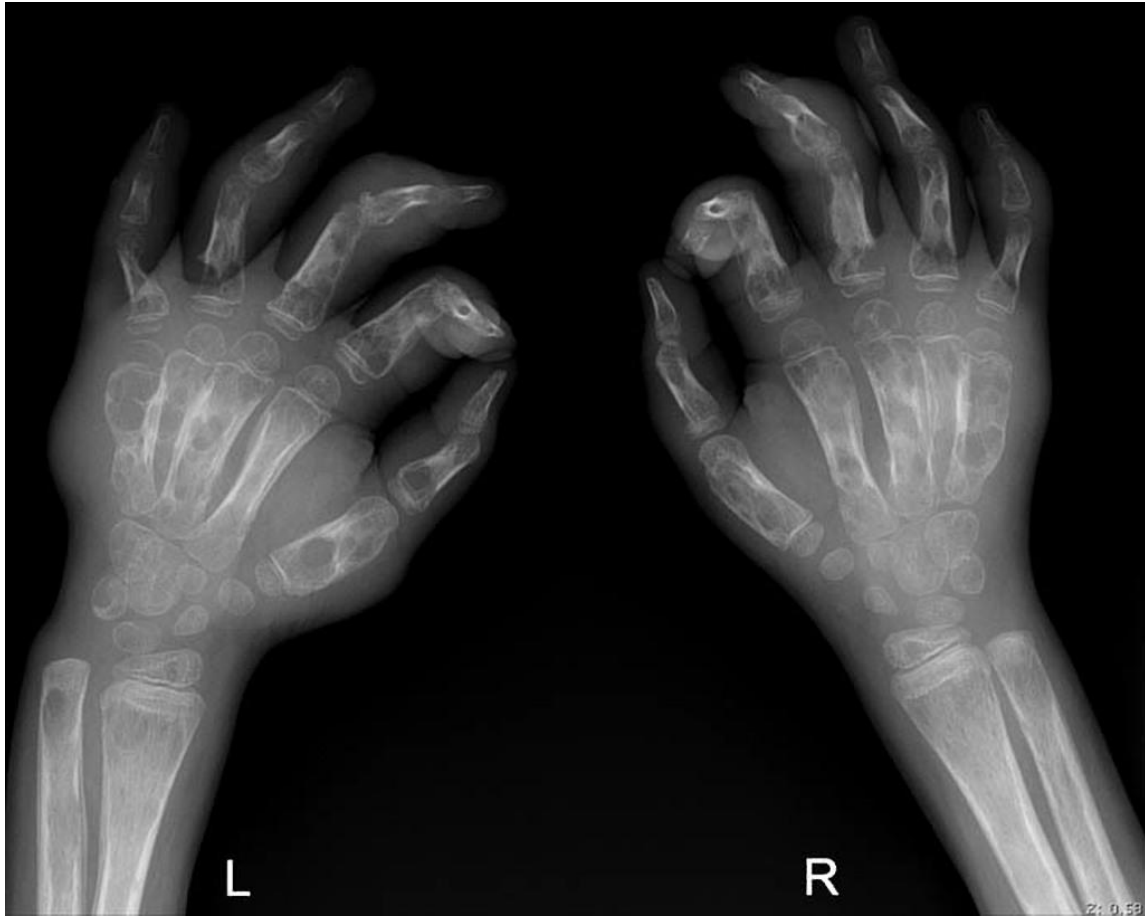5378 14/ix-74  
Шамши О.У.  
23.  
Крив. кисть  
лев.

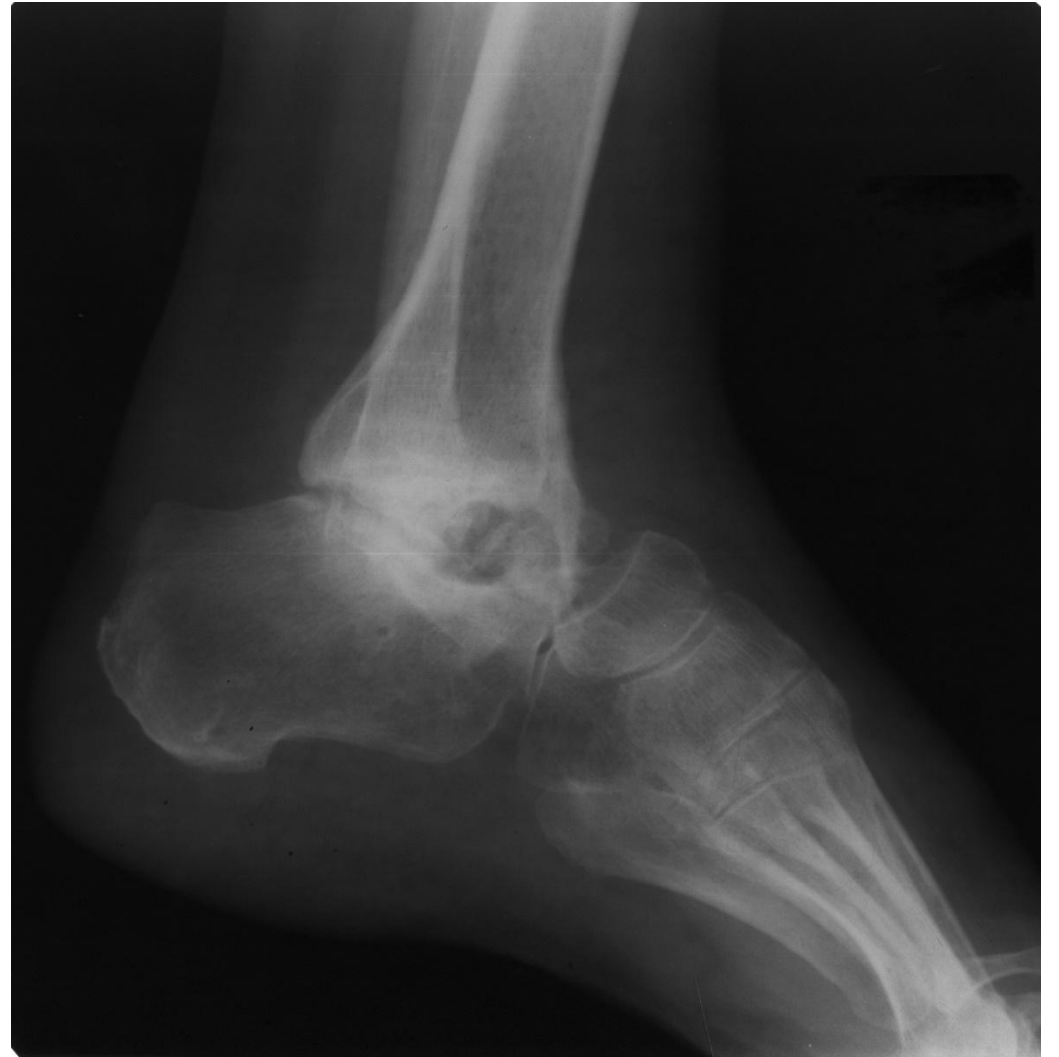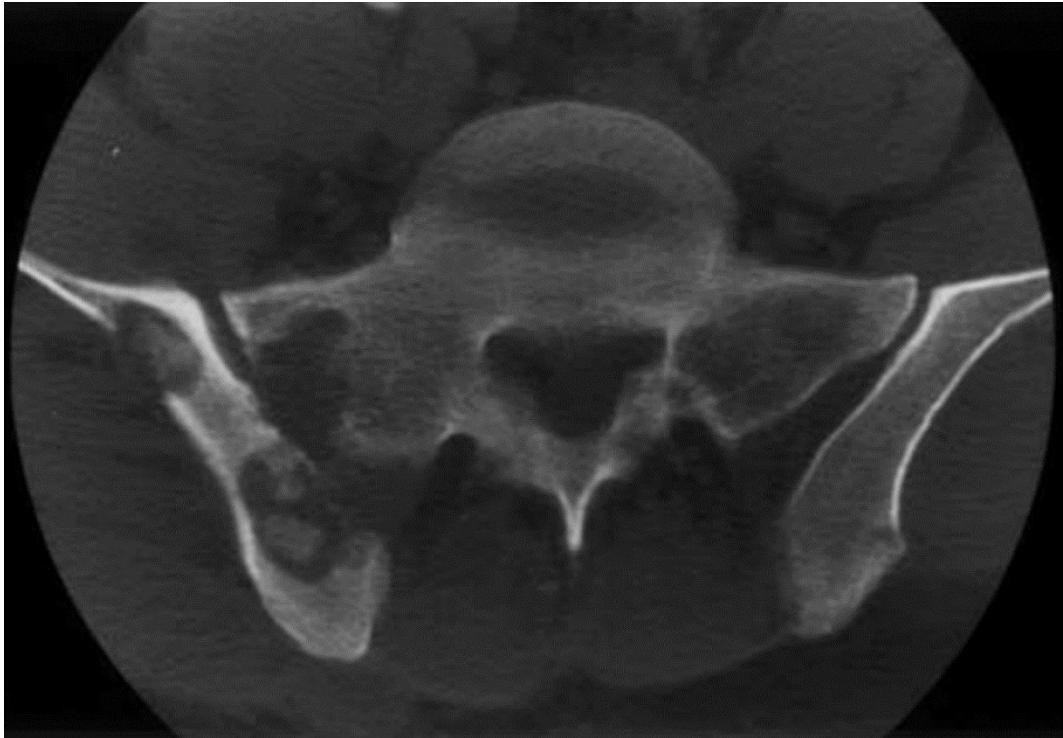


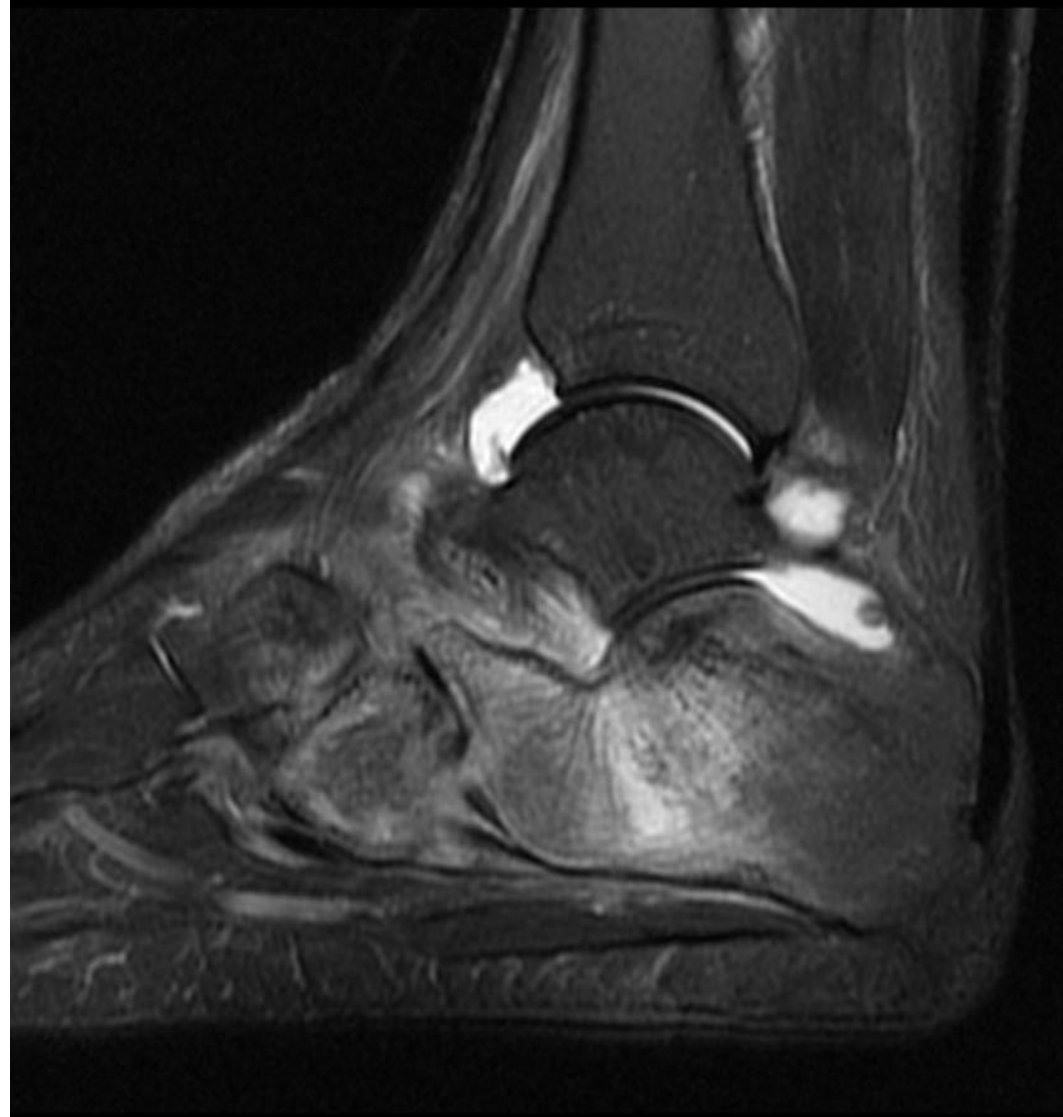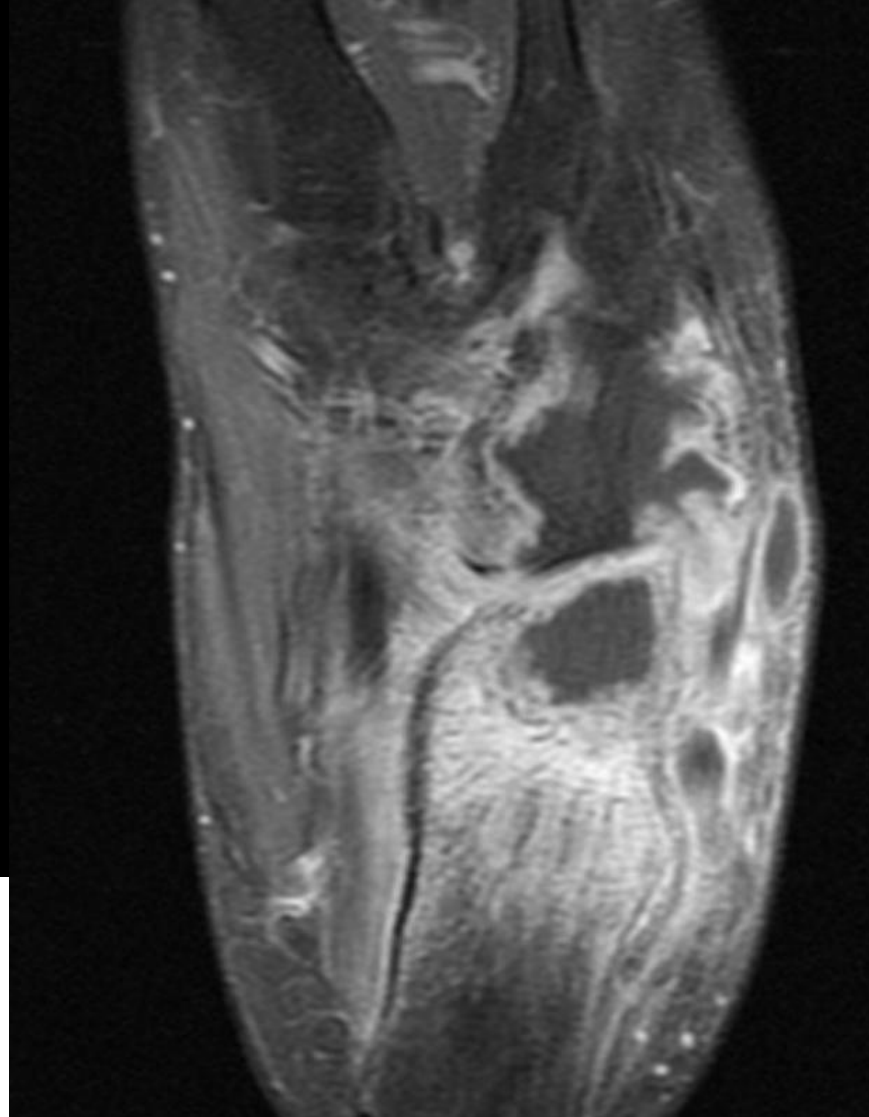


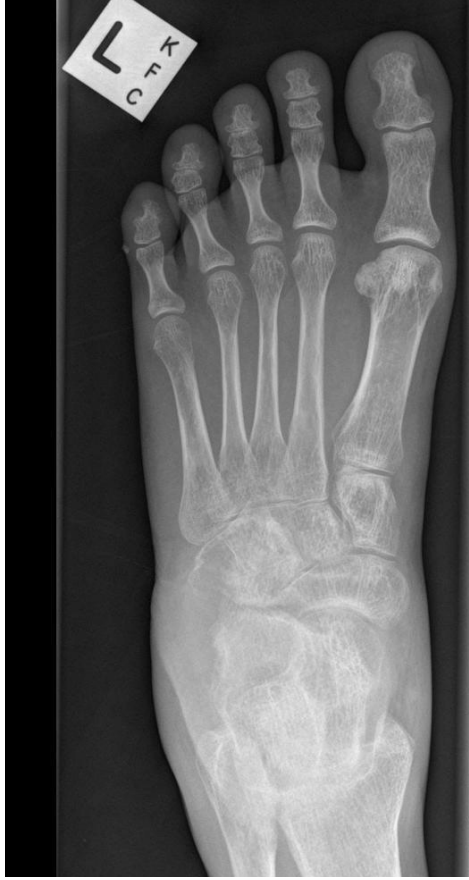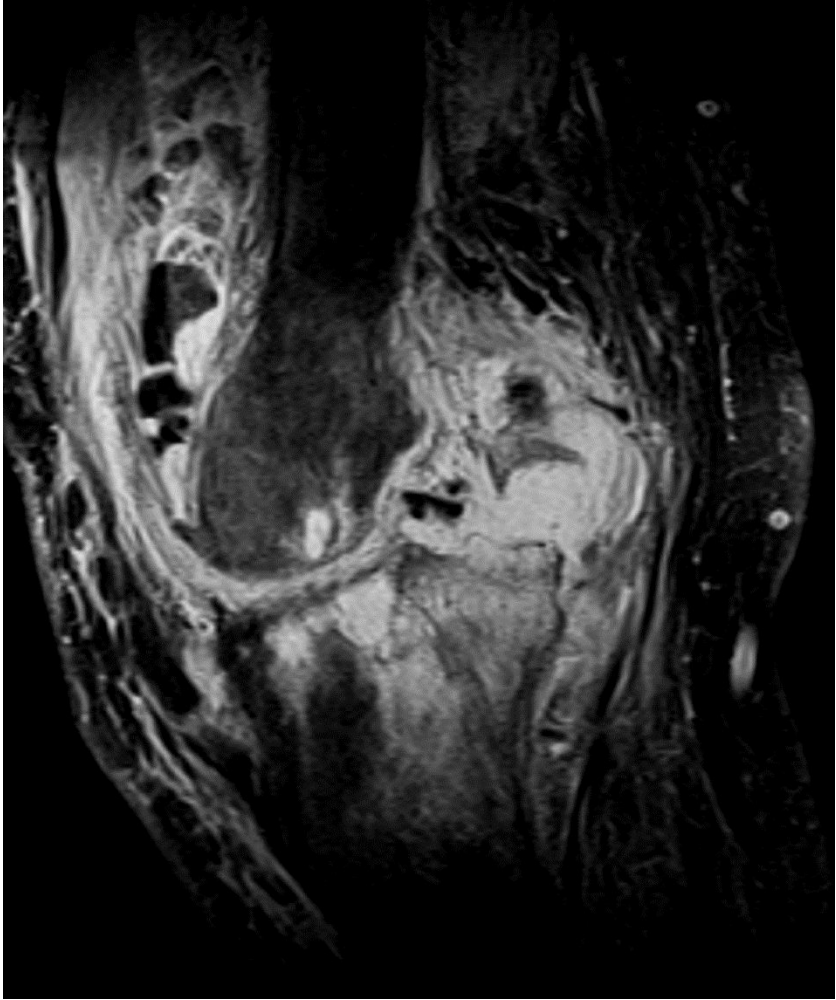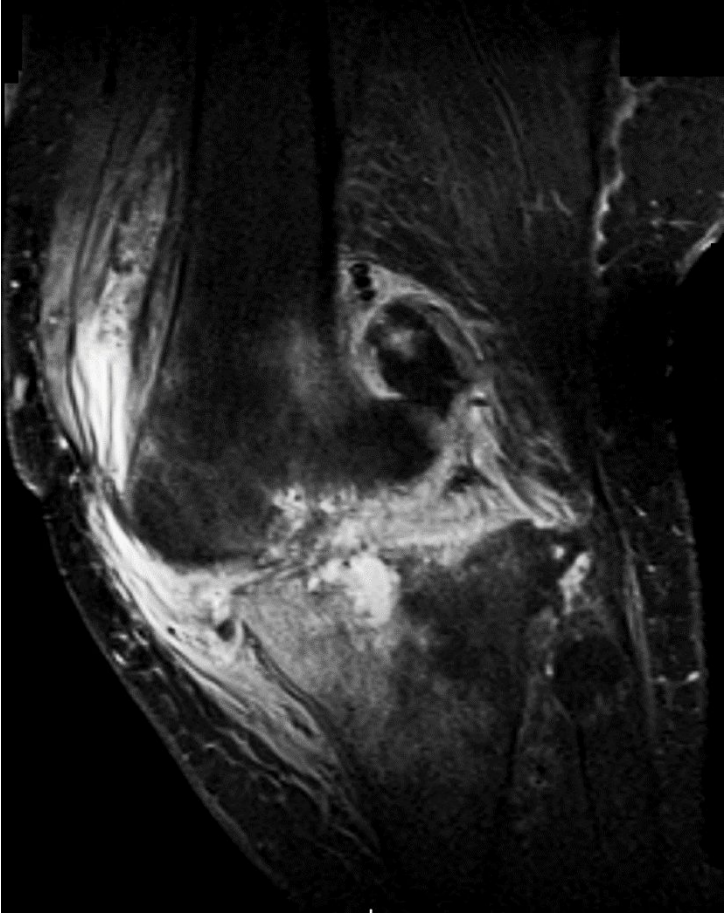


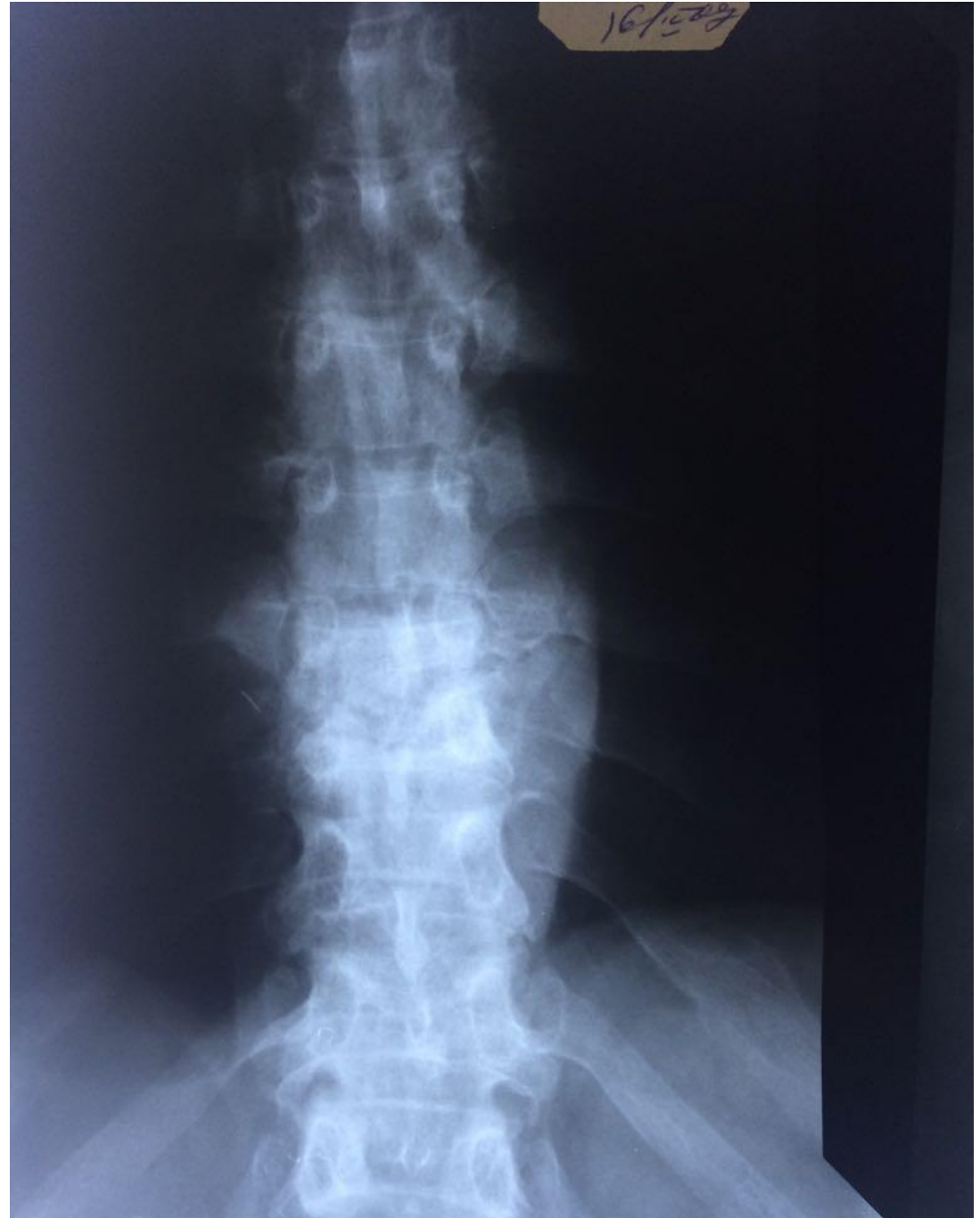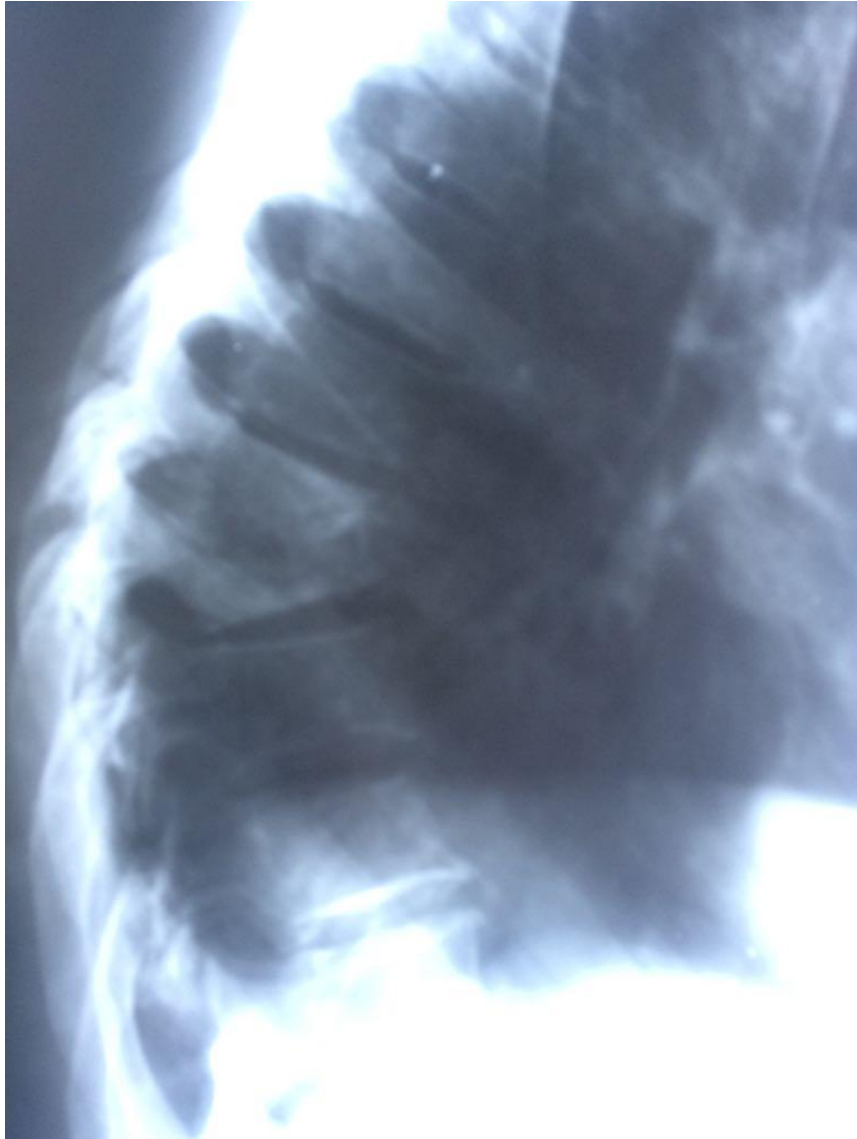








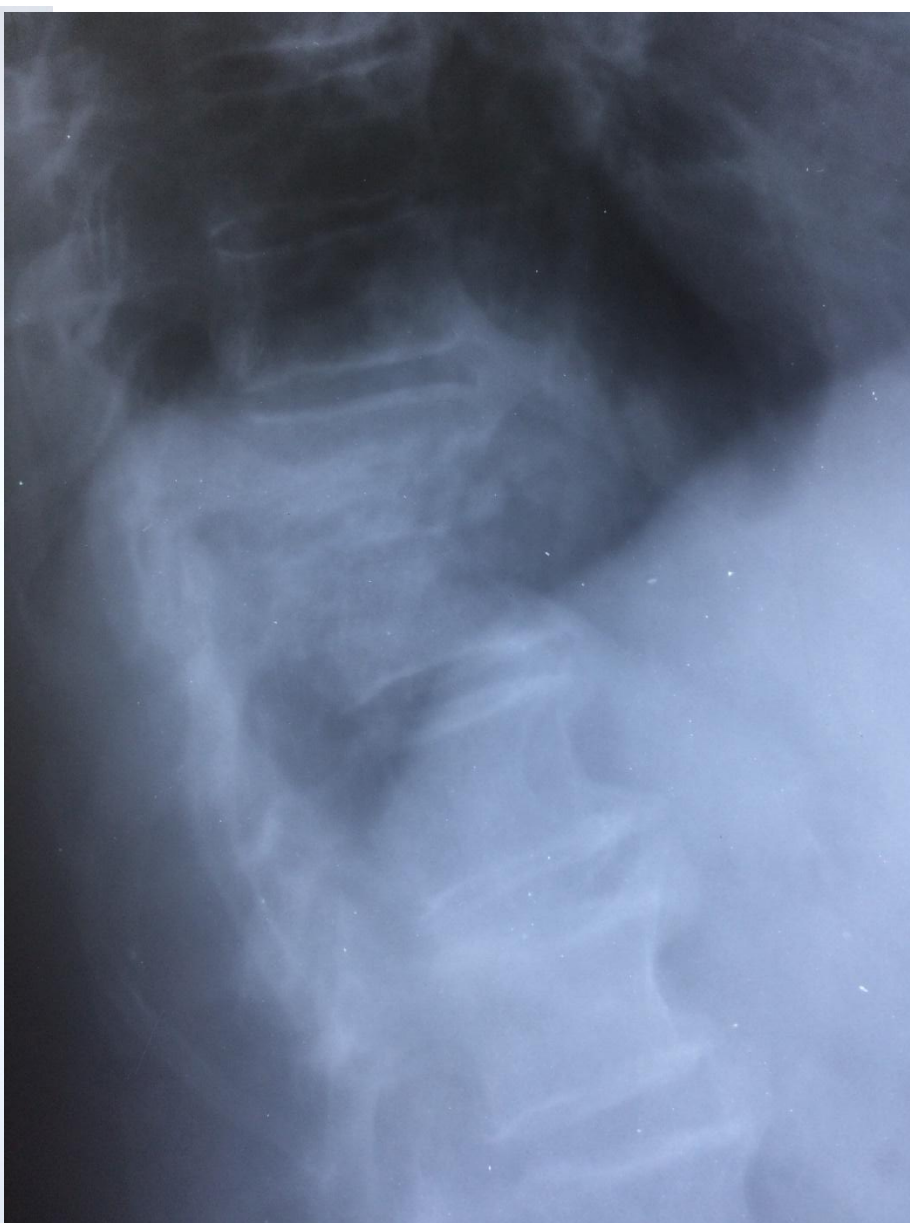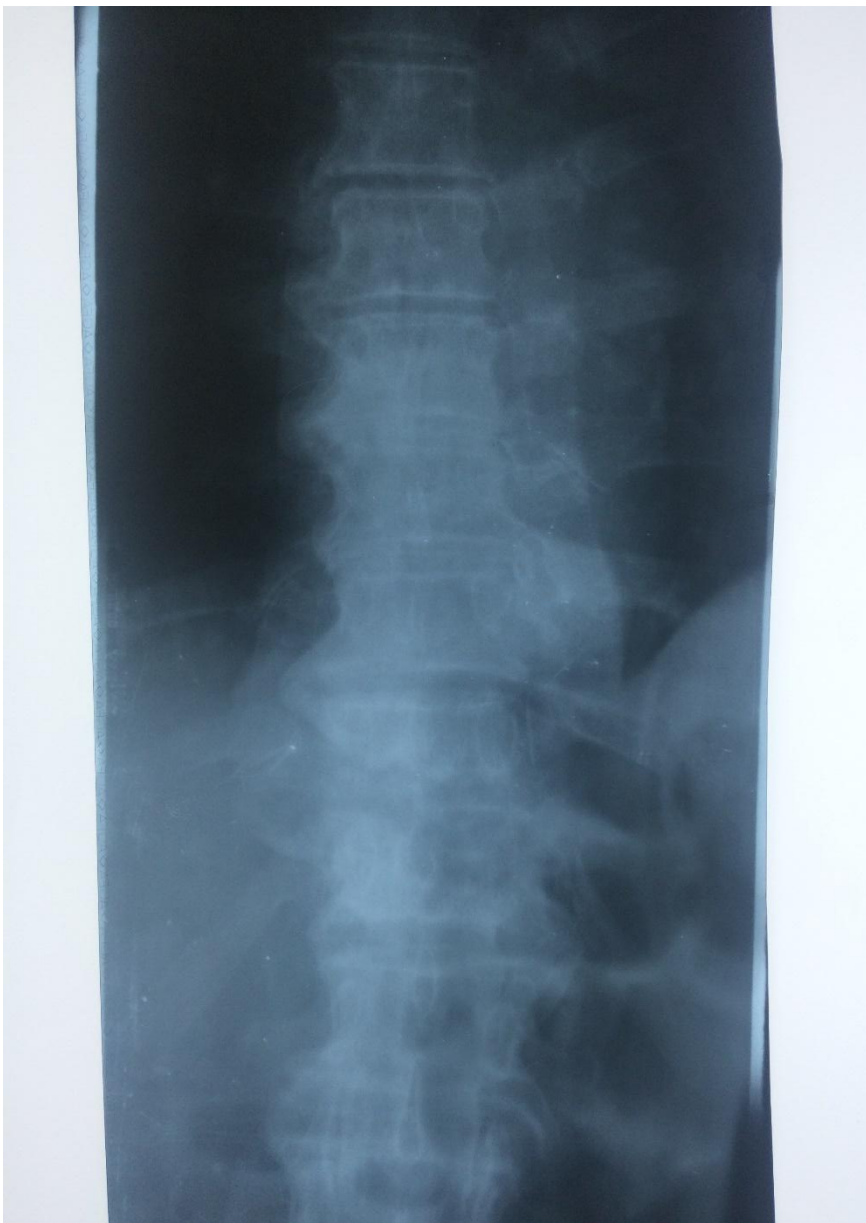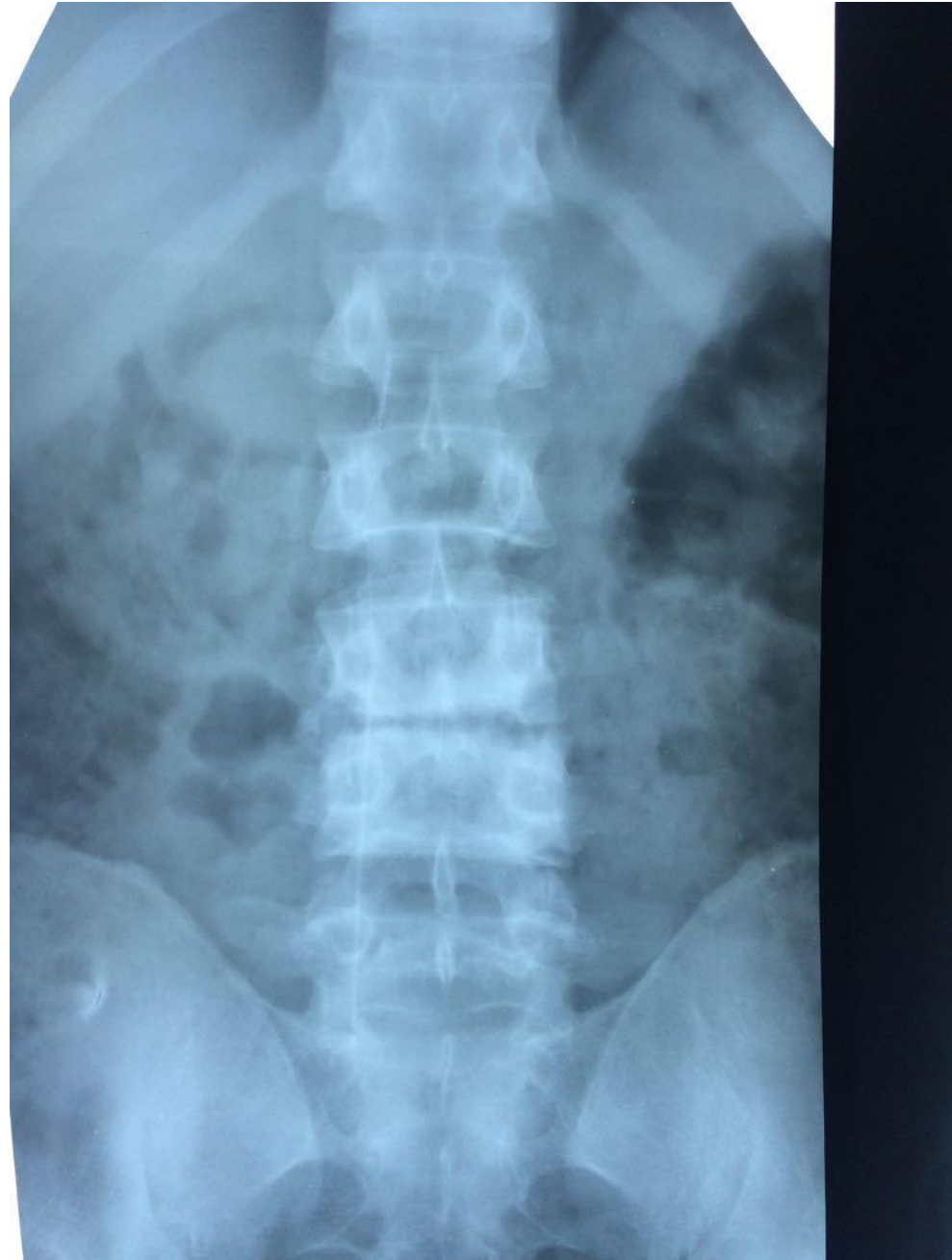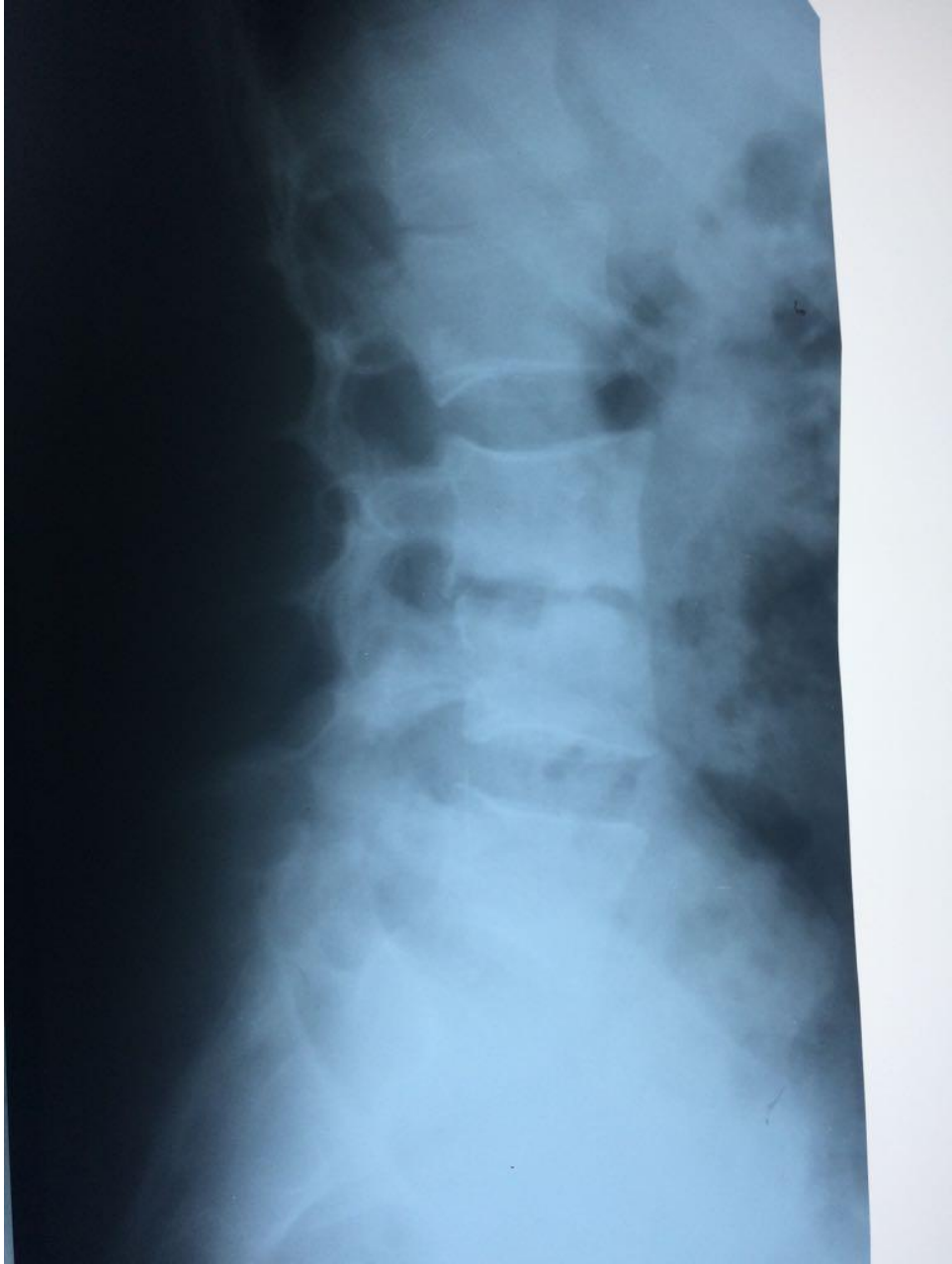


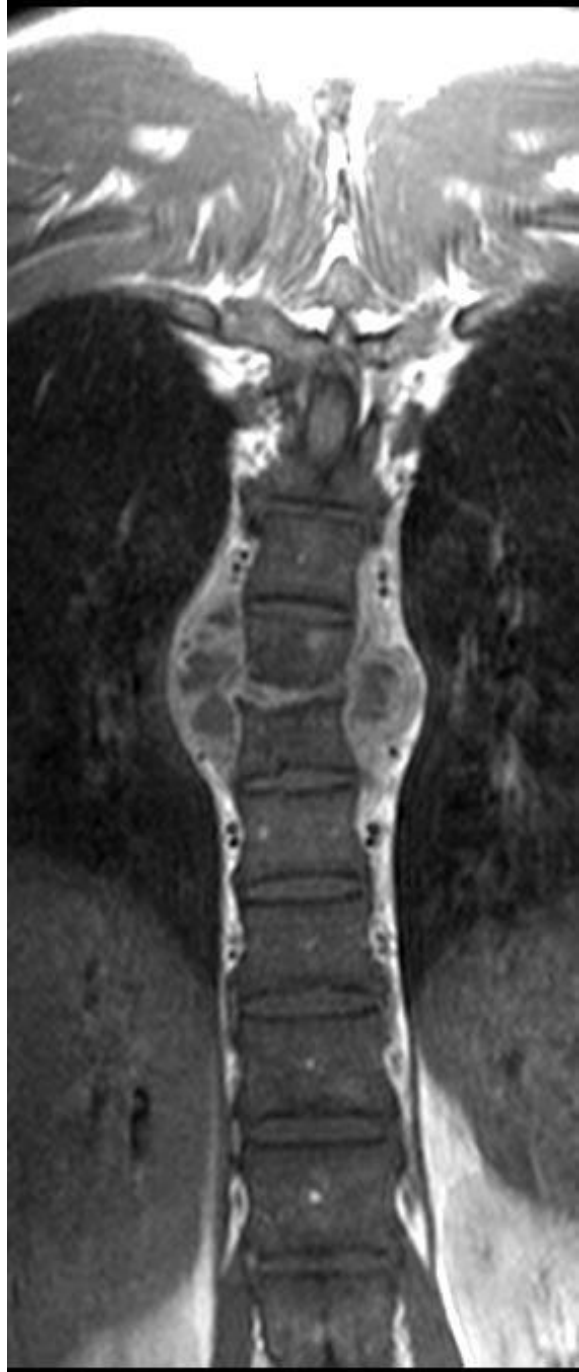




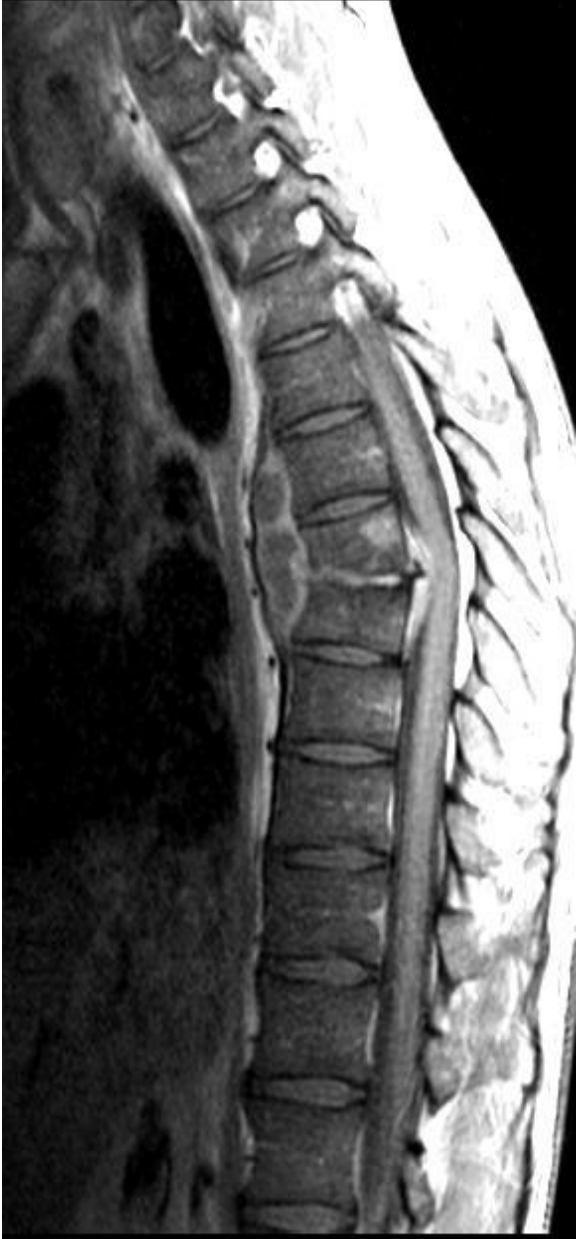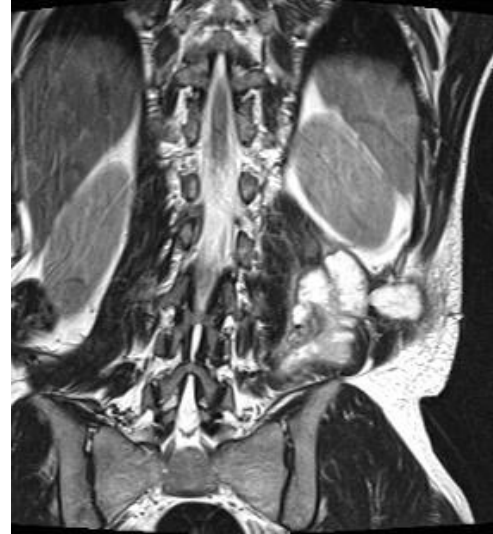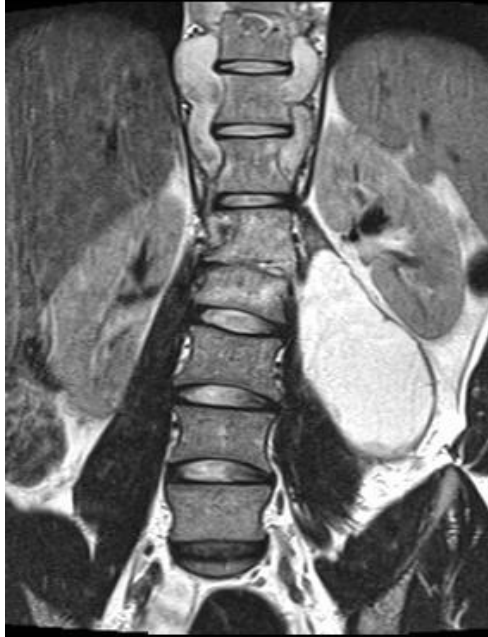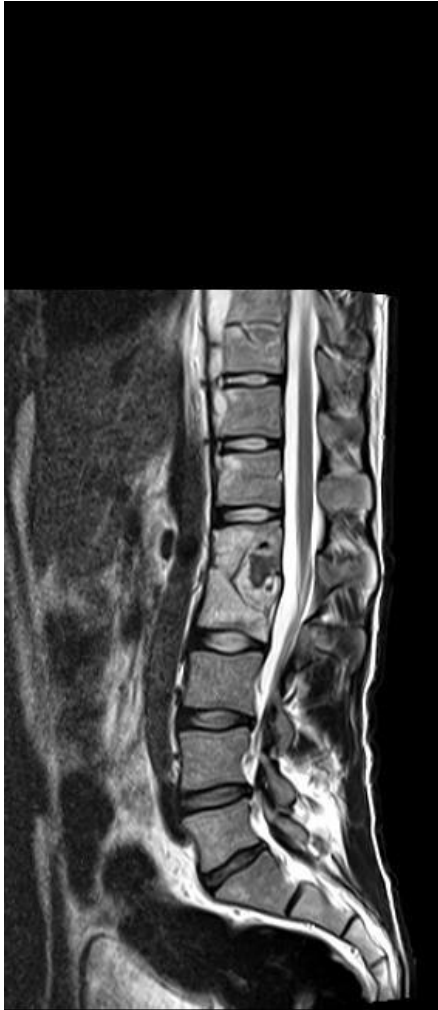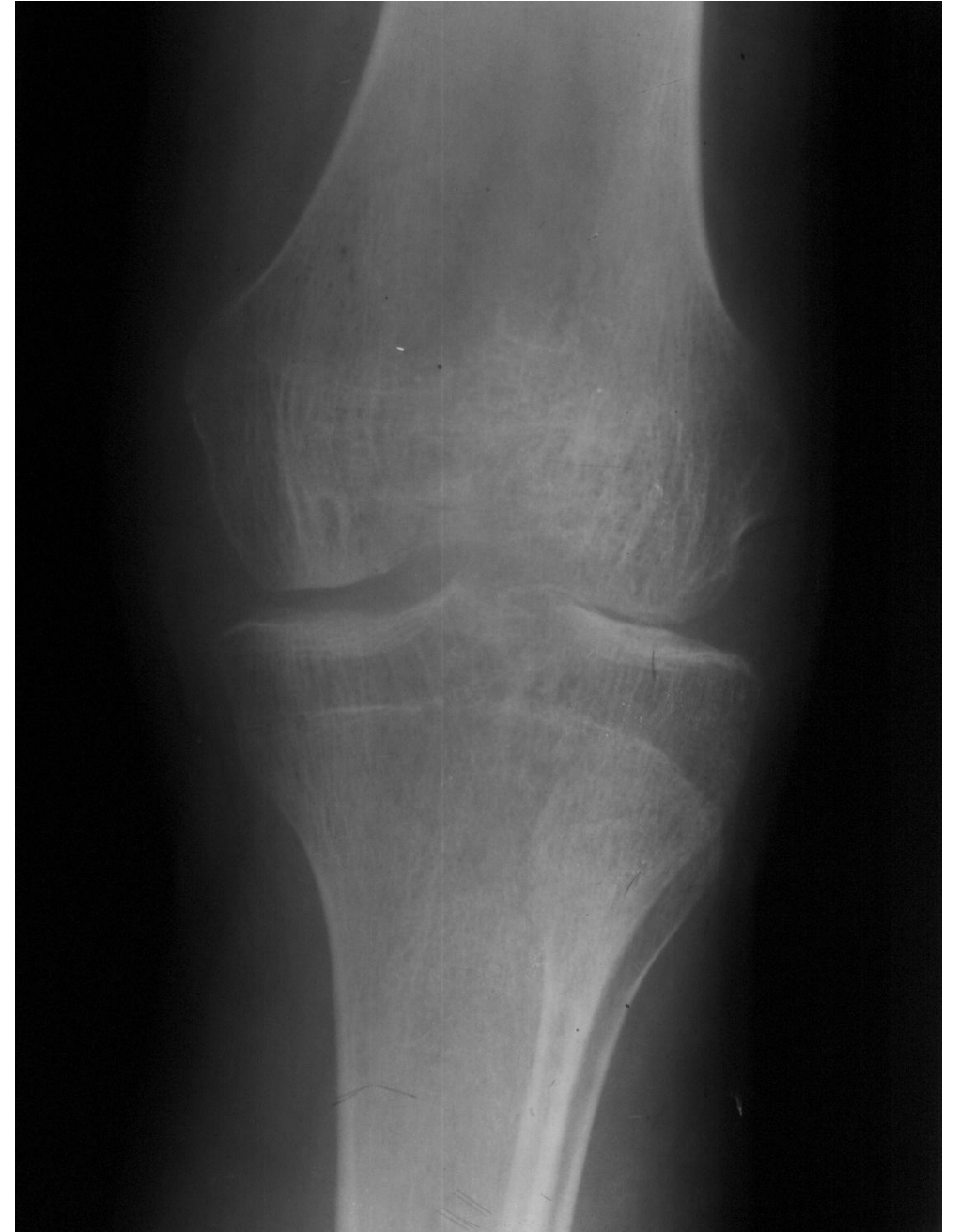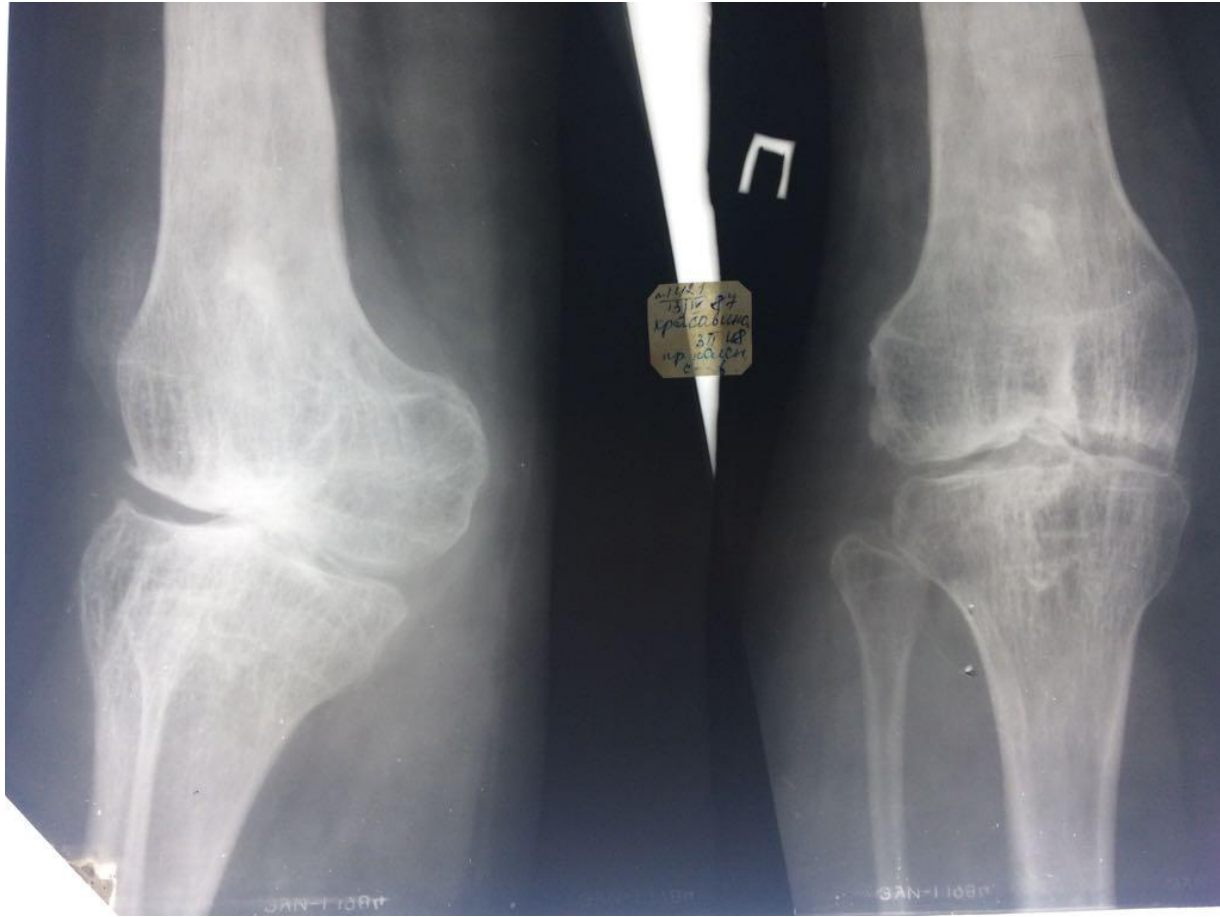








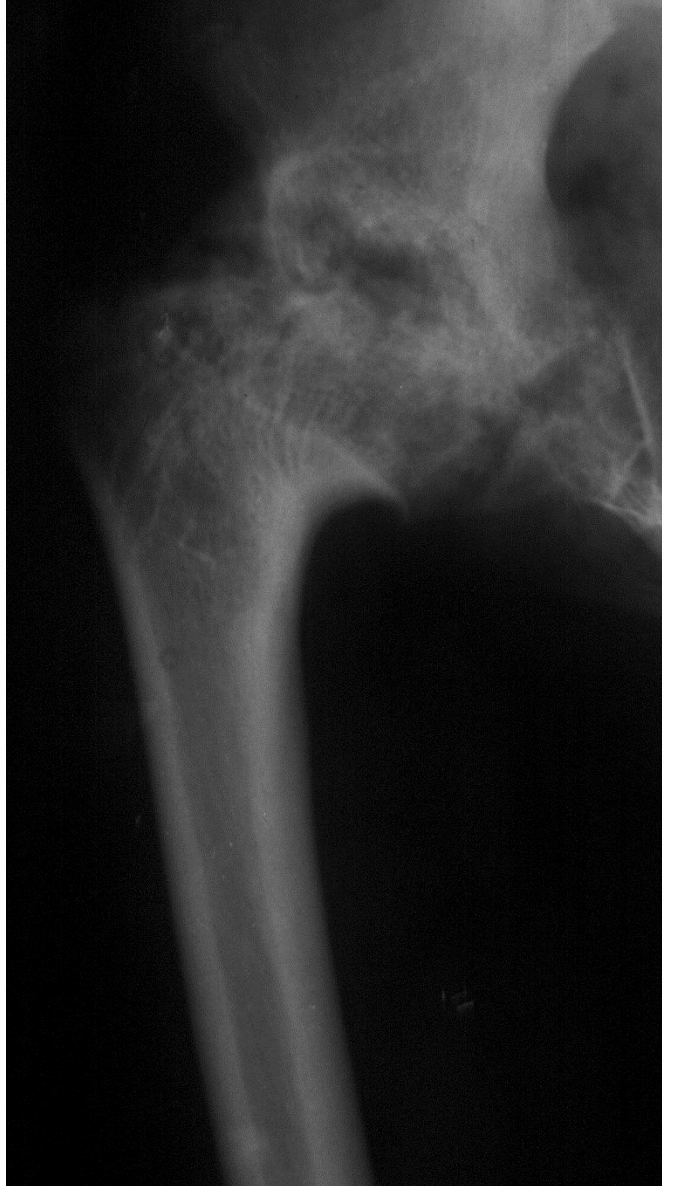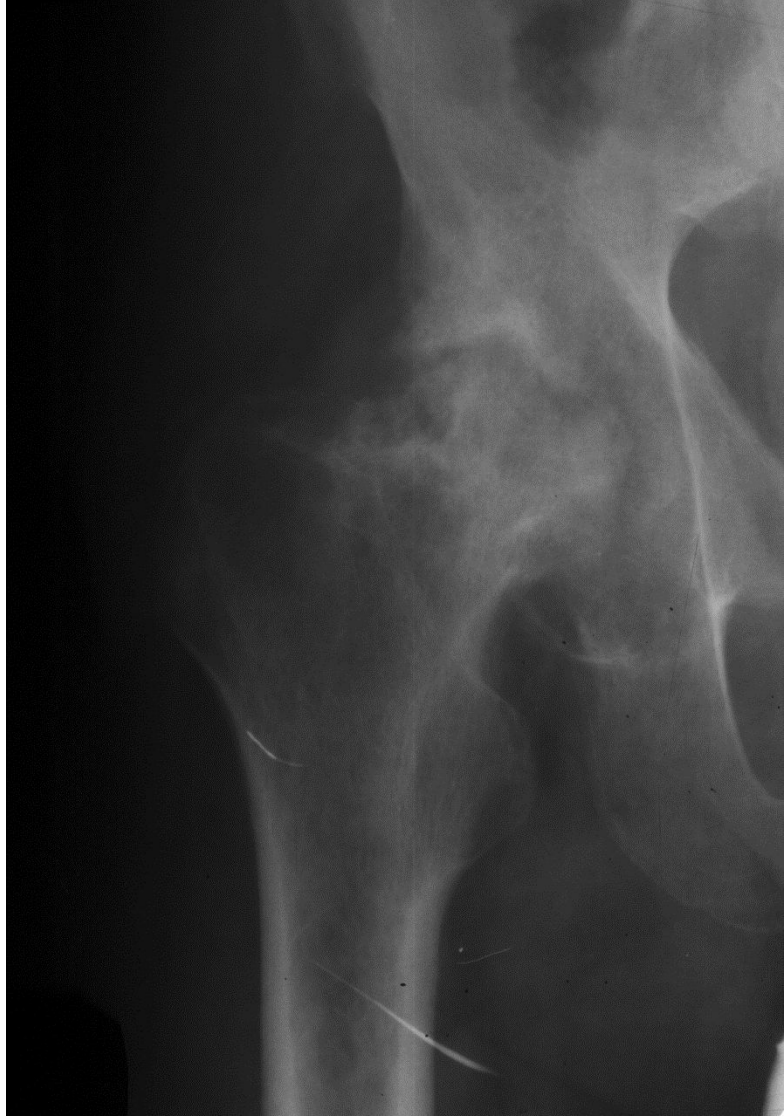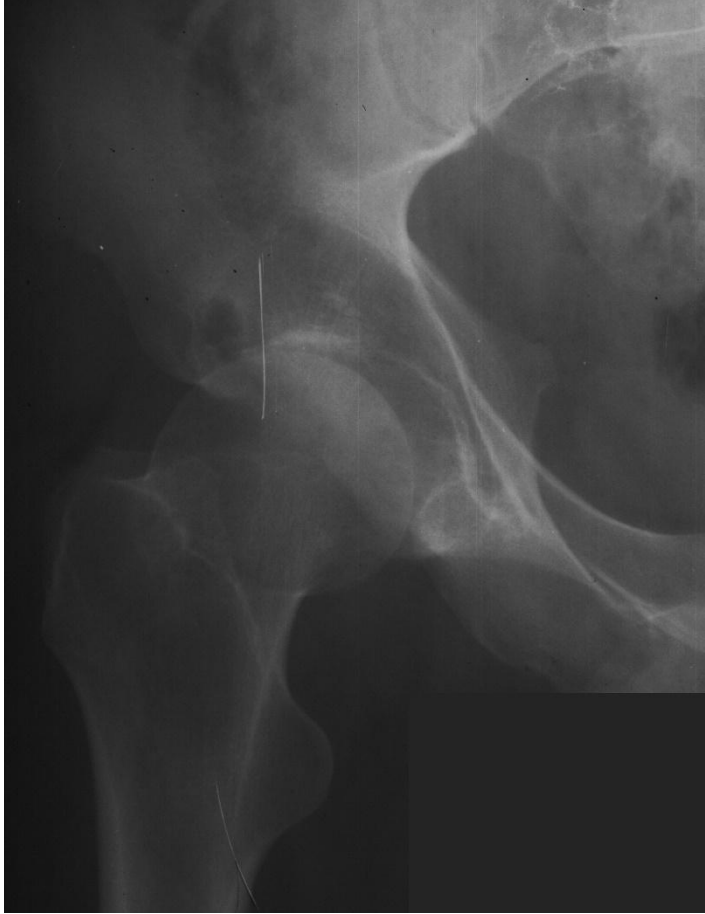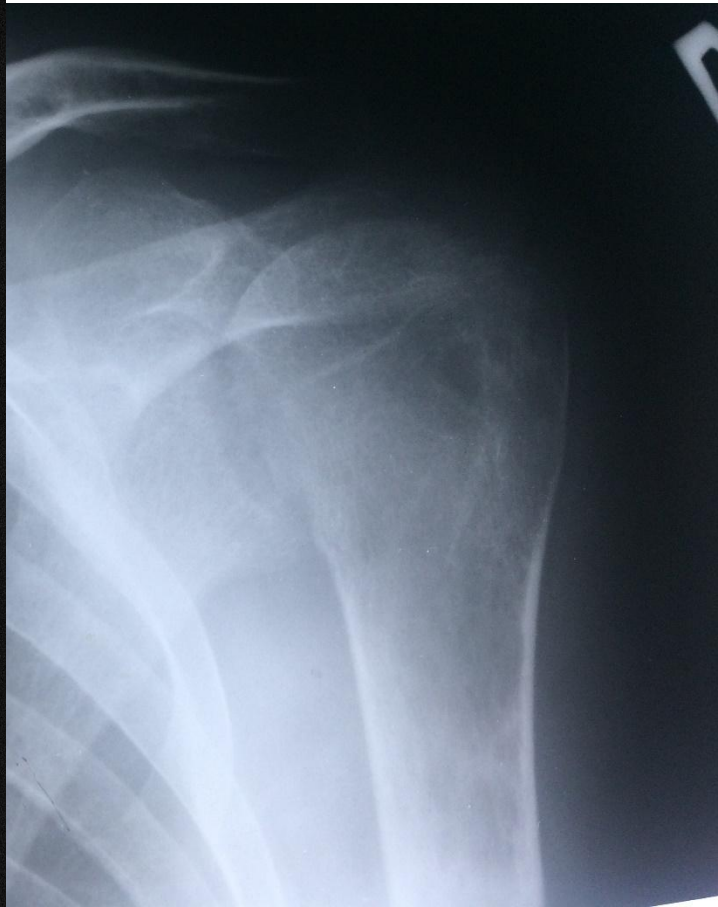
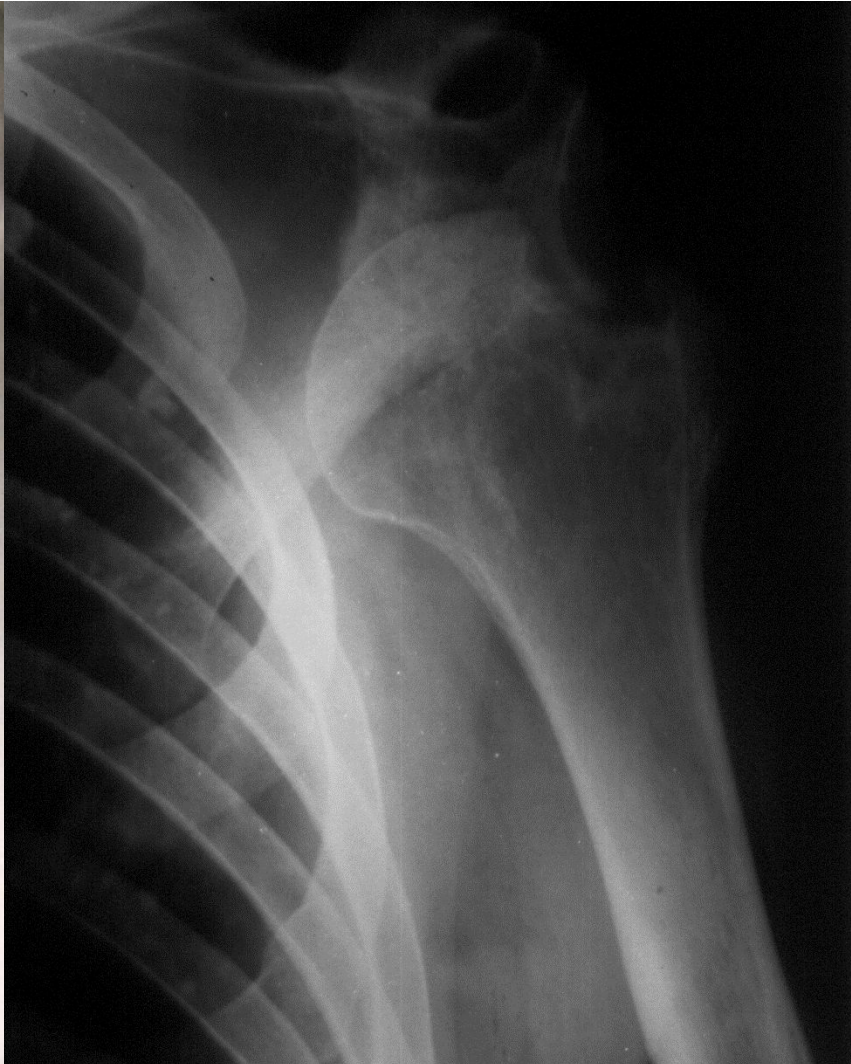


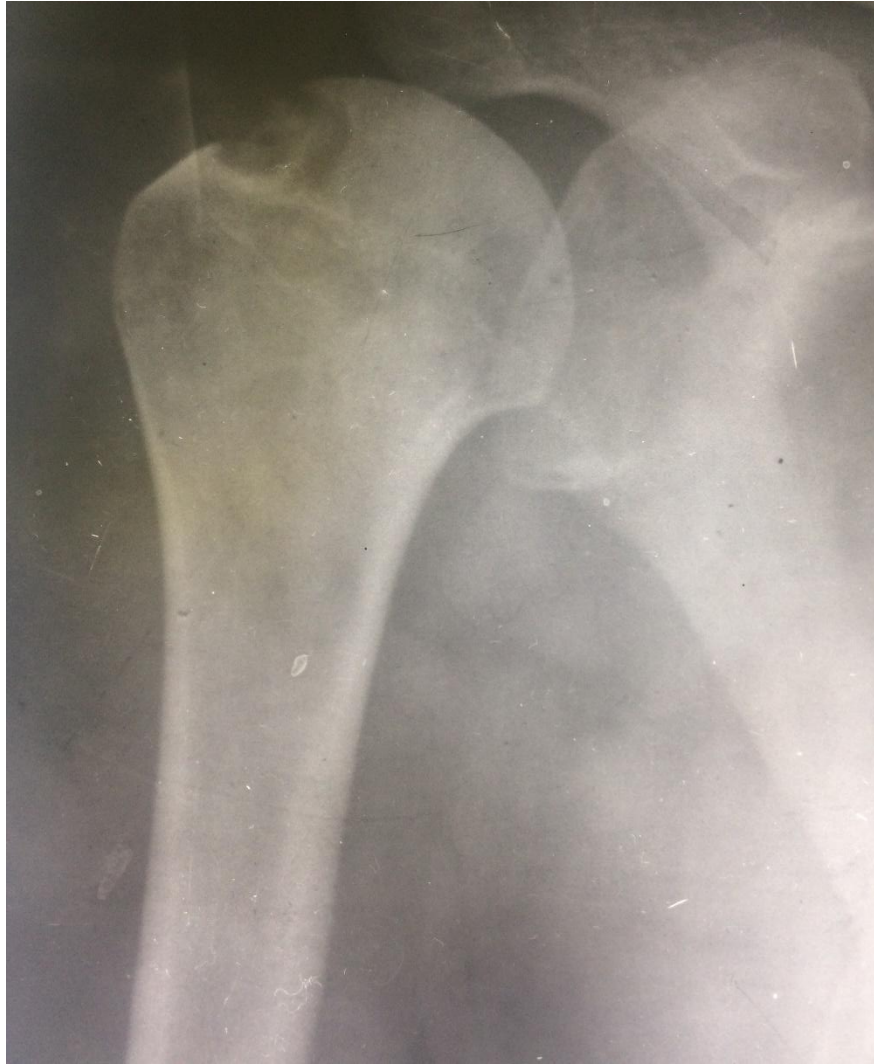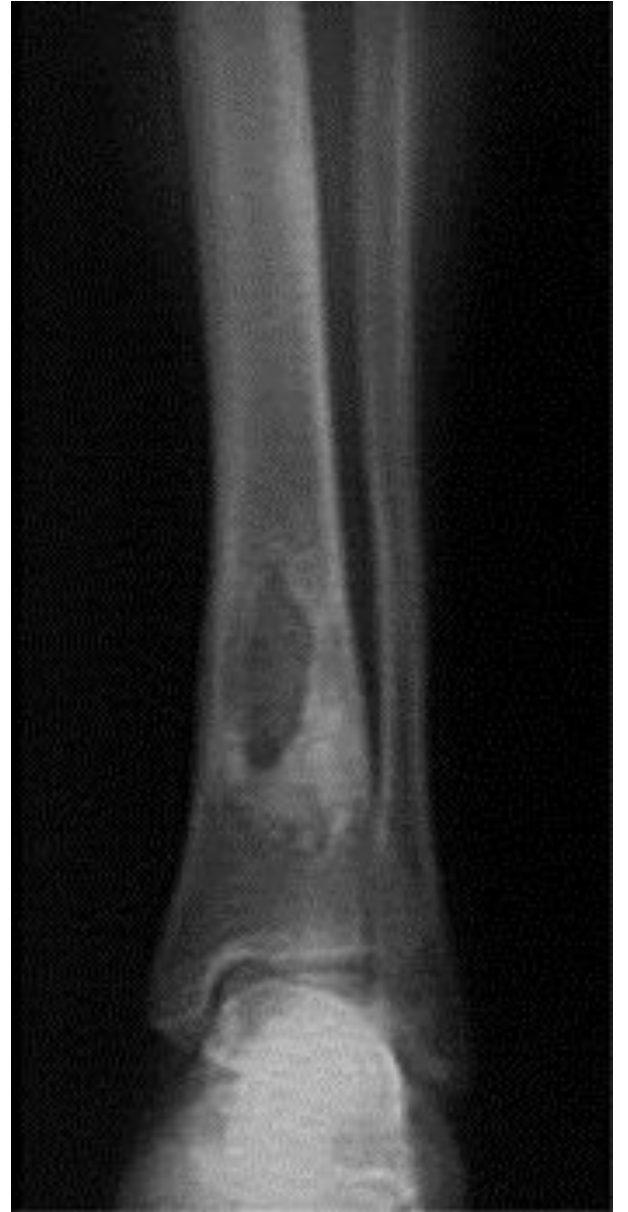


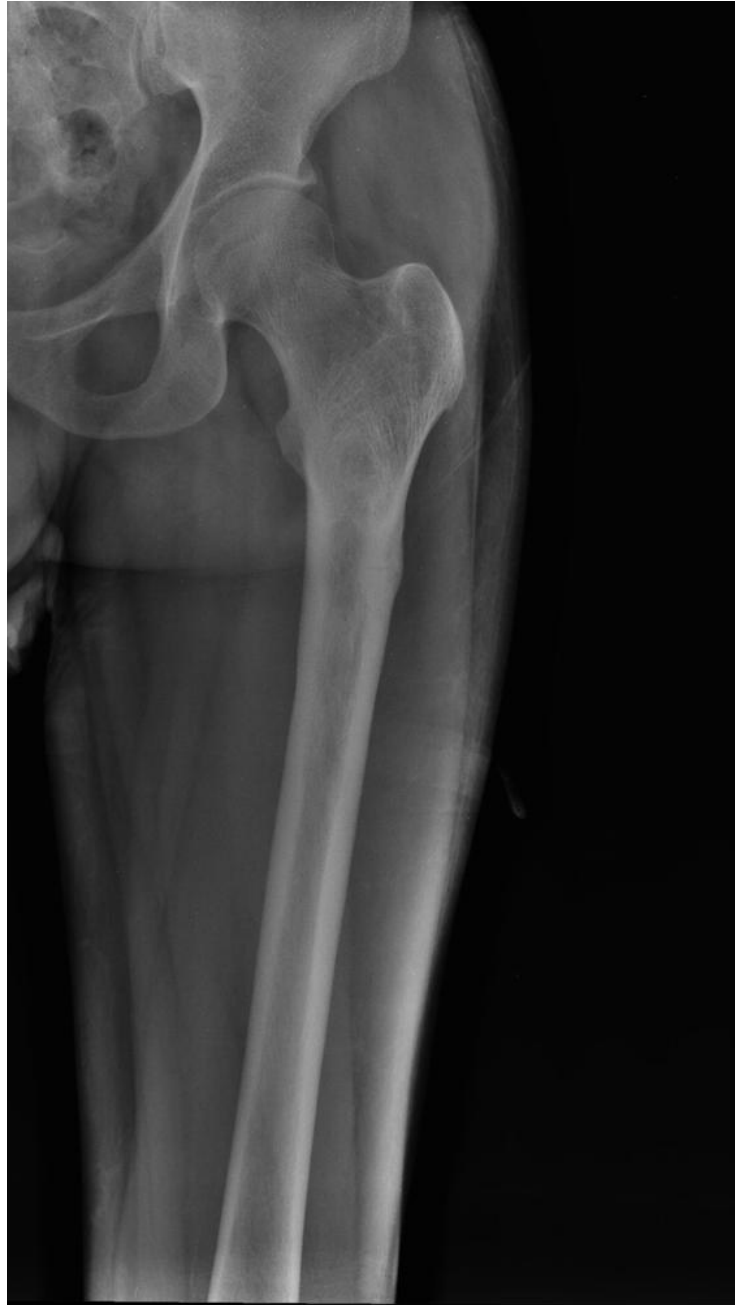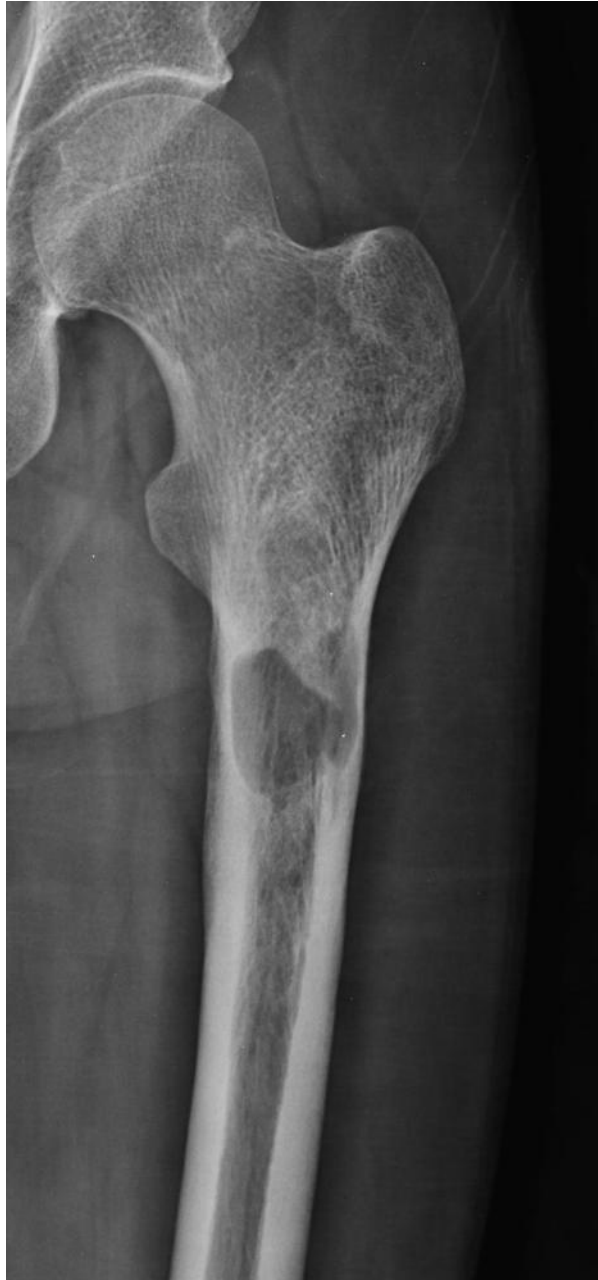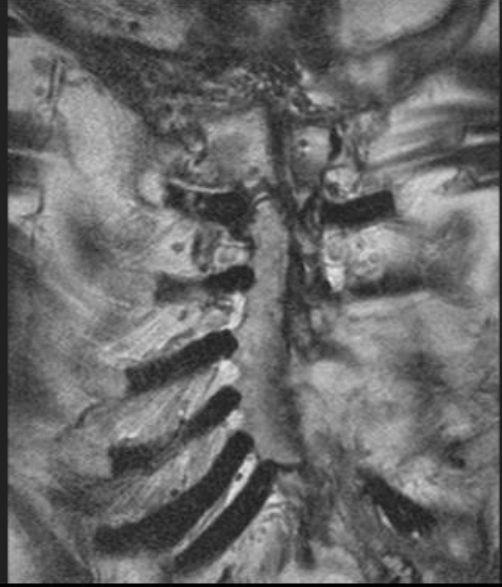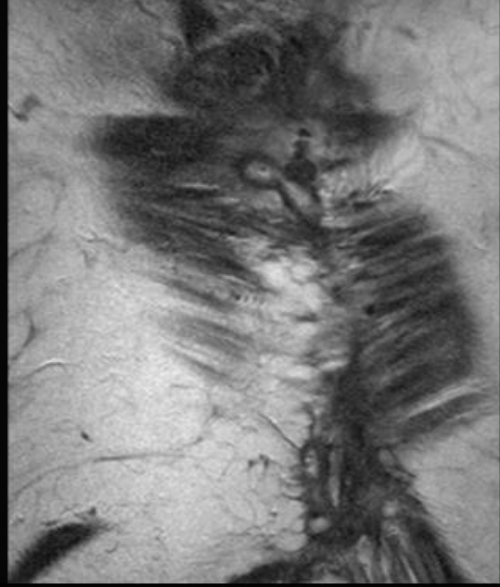
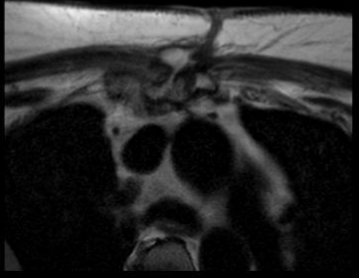


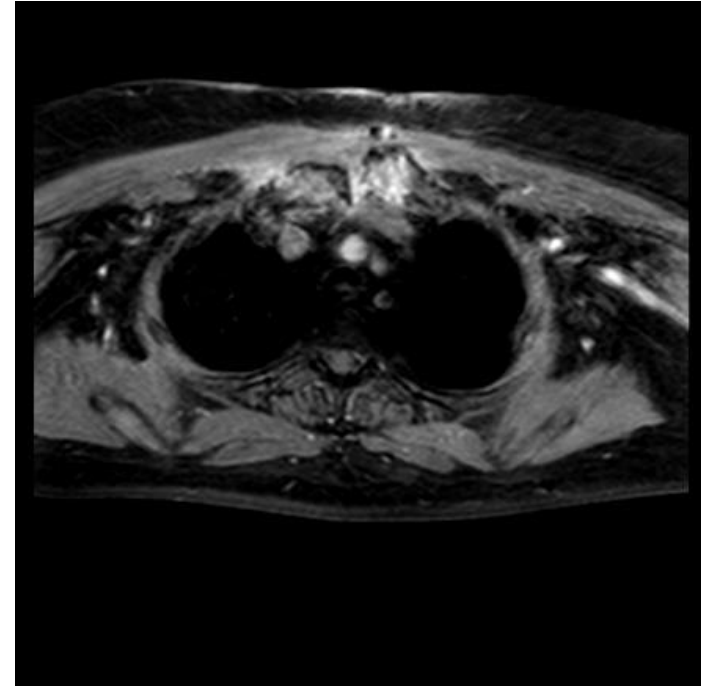
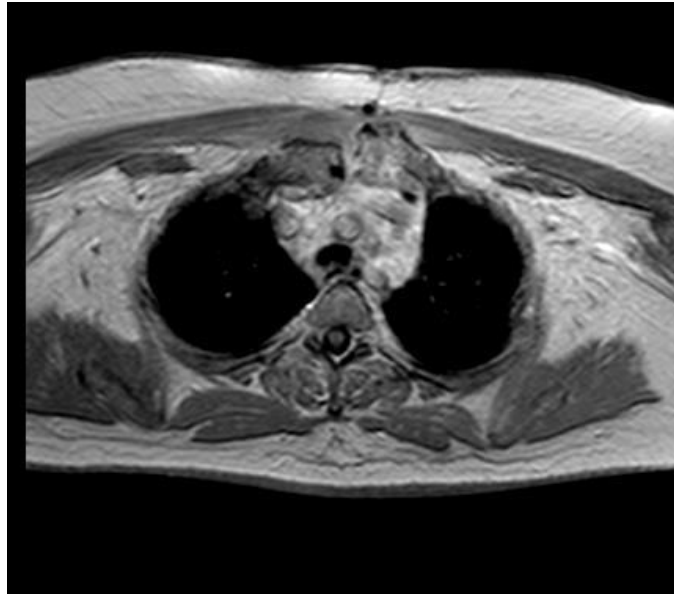
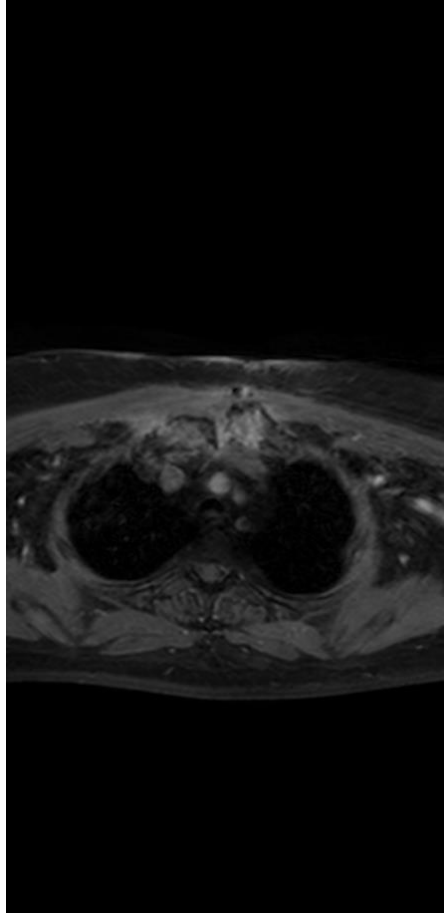


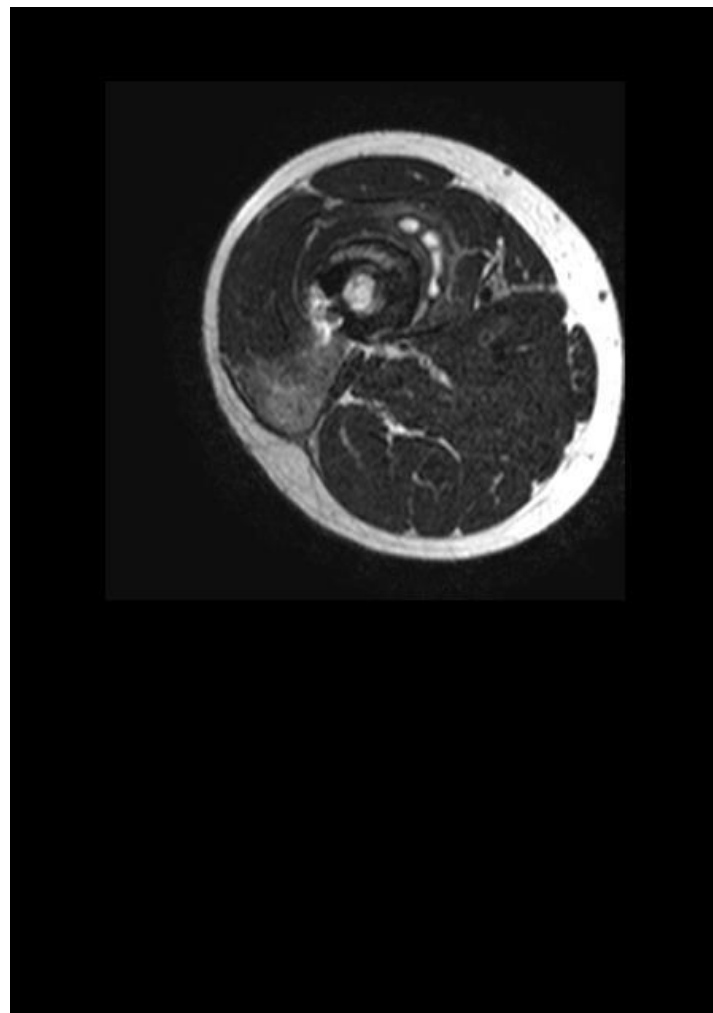
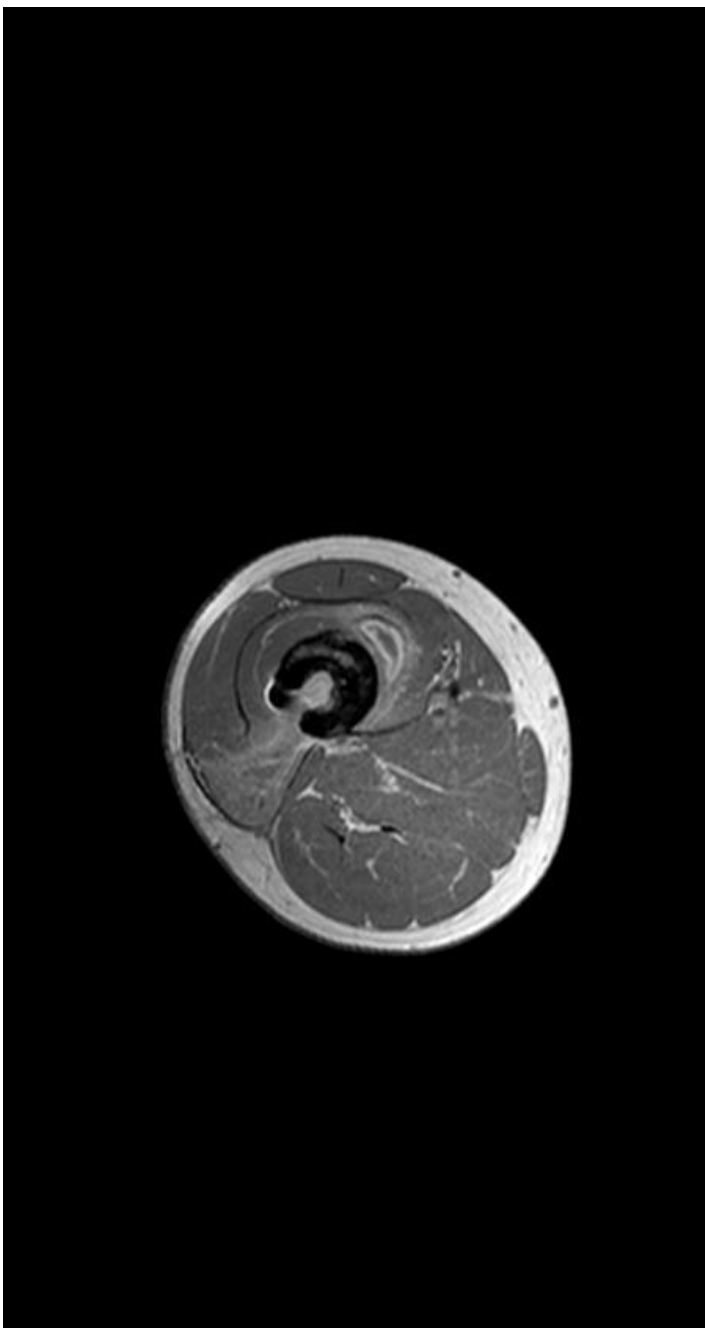
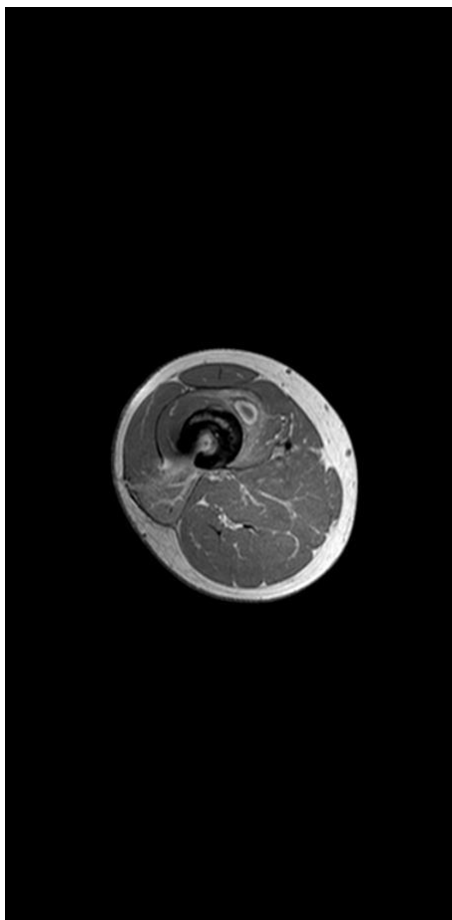




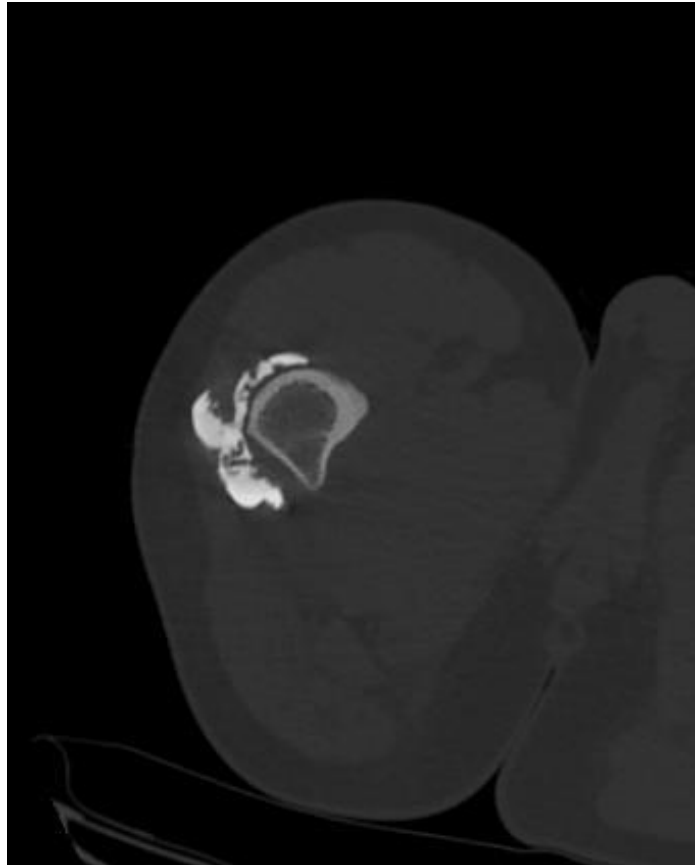
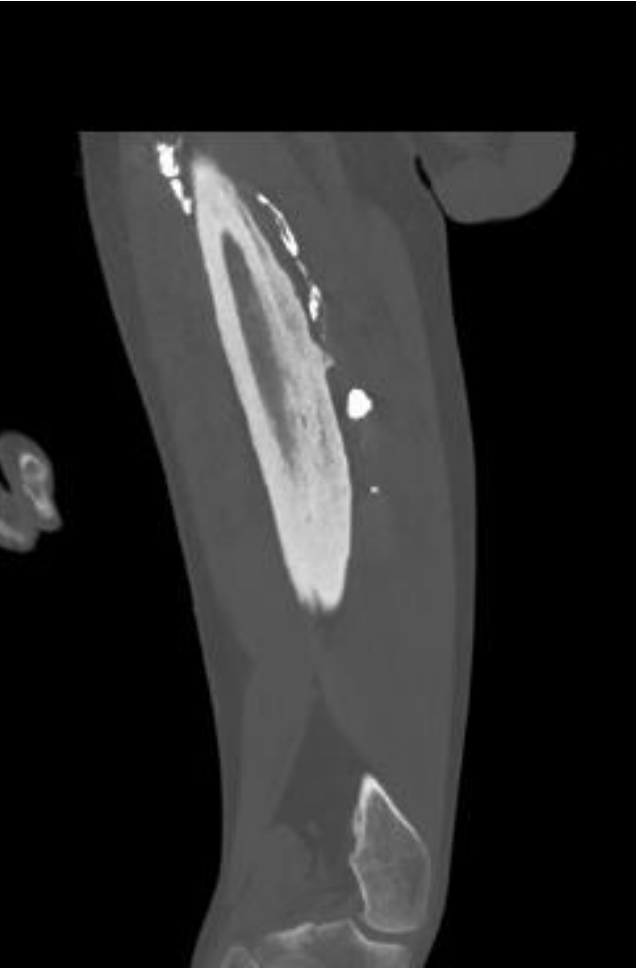
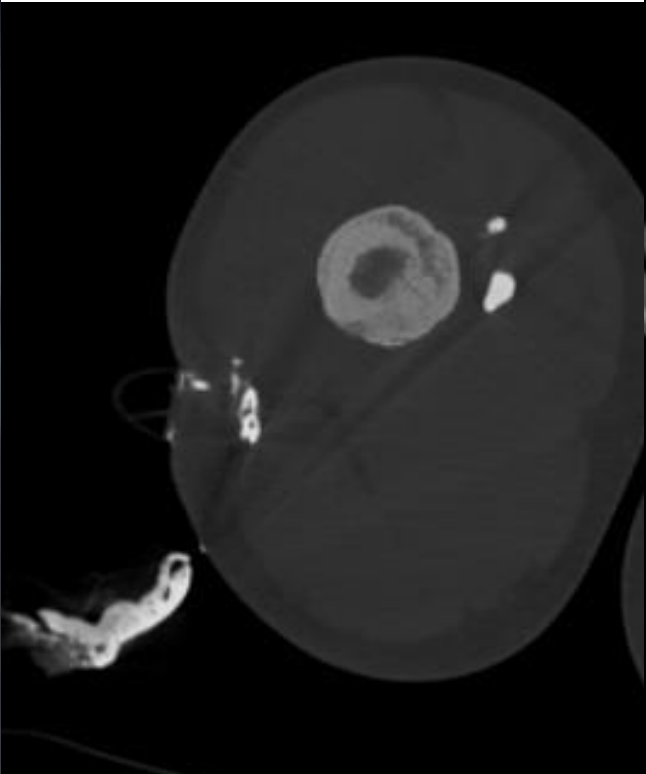




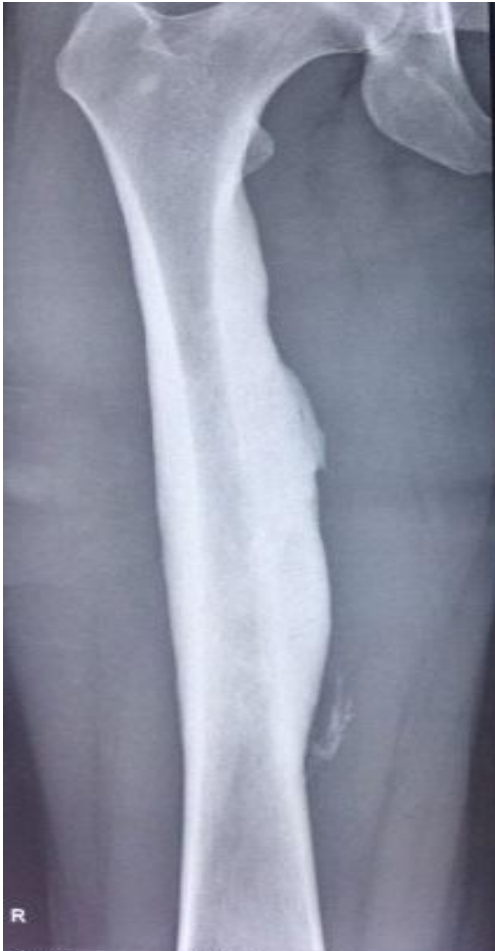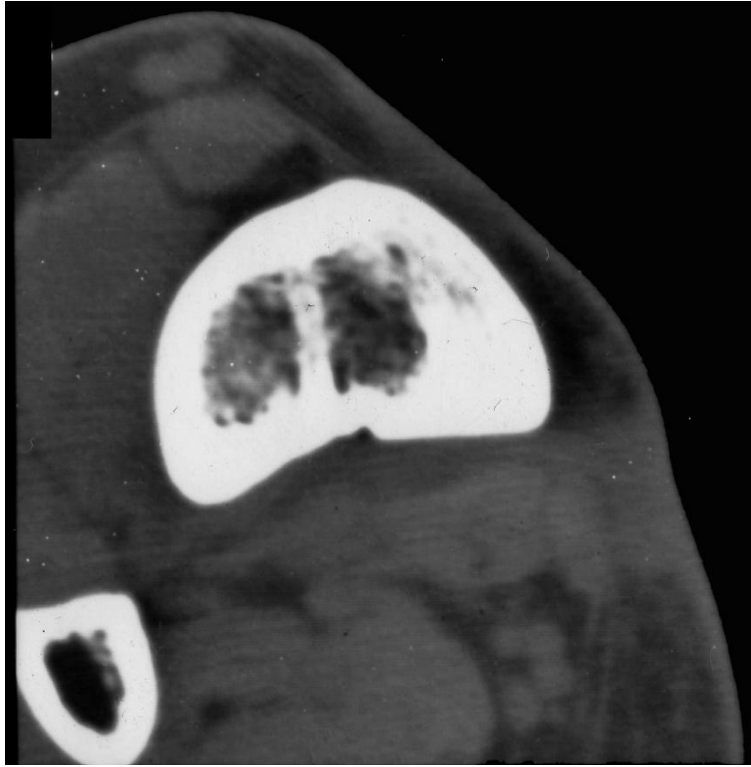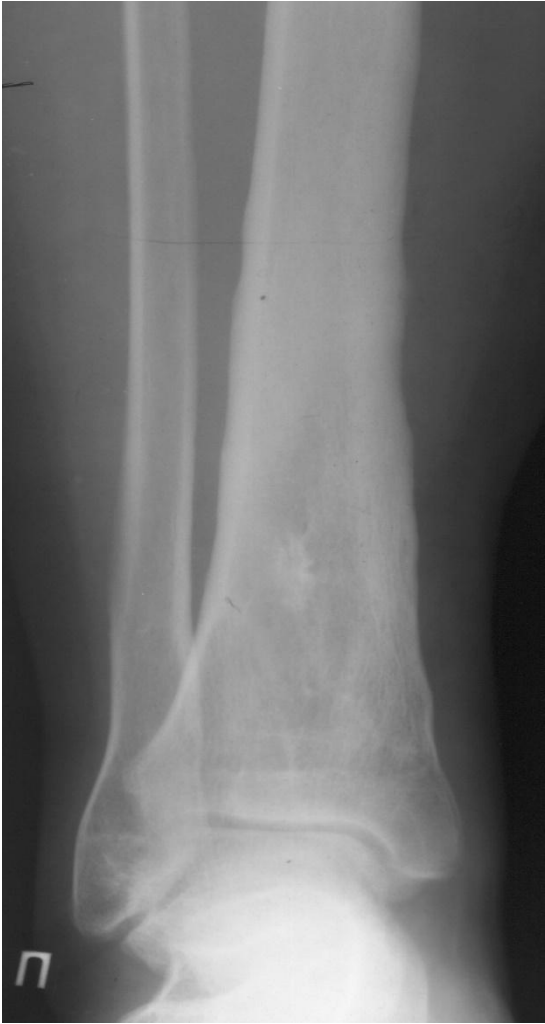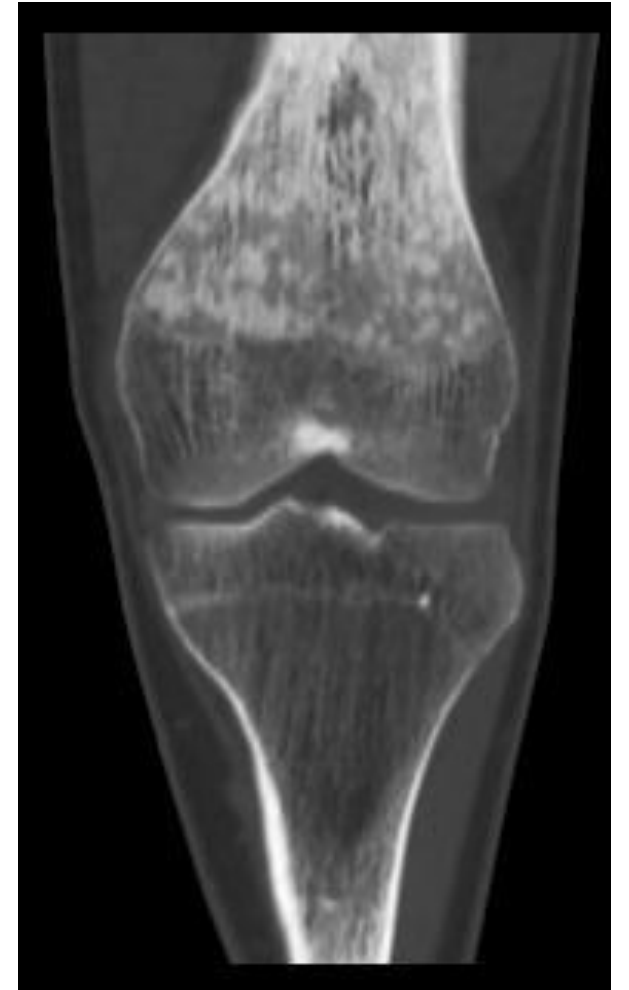
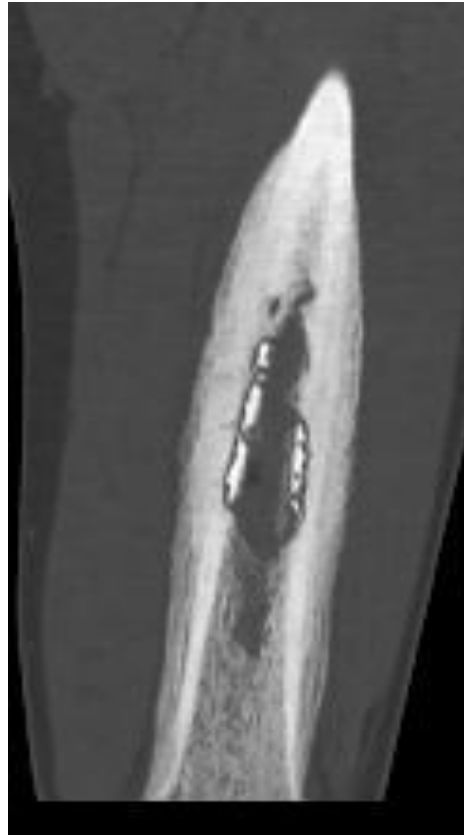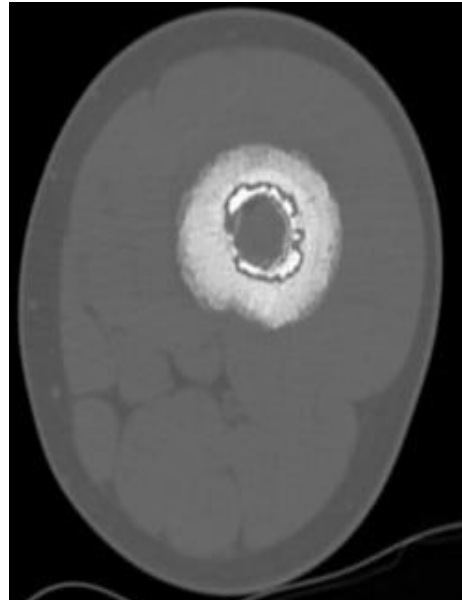


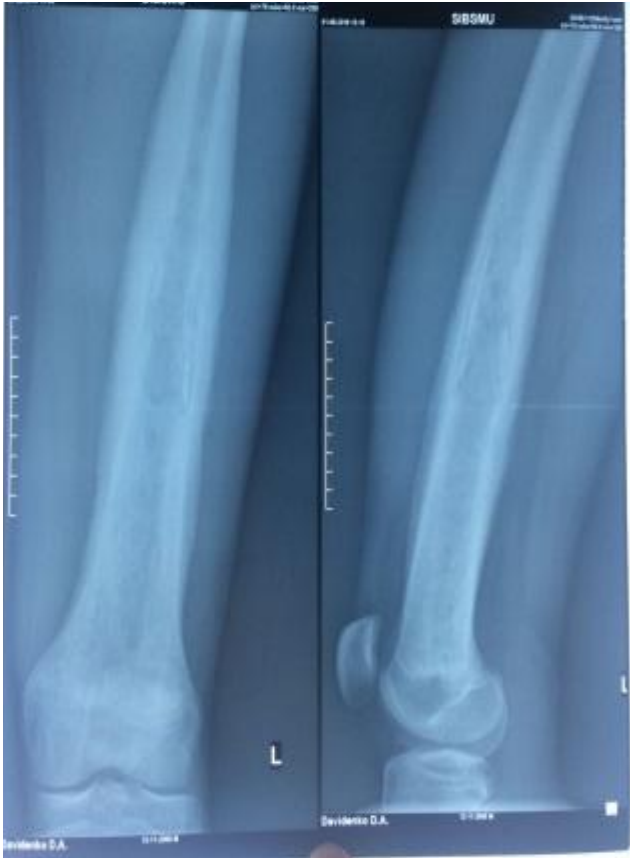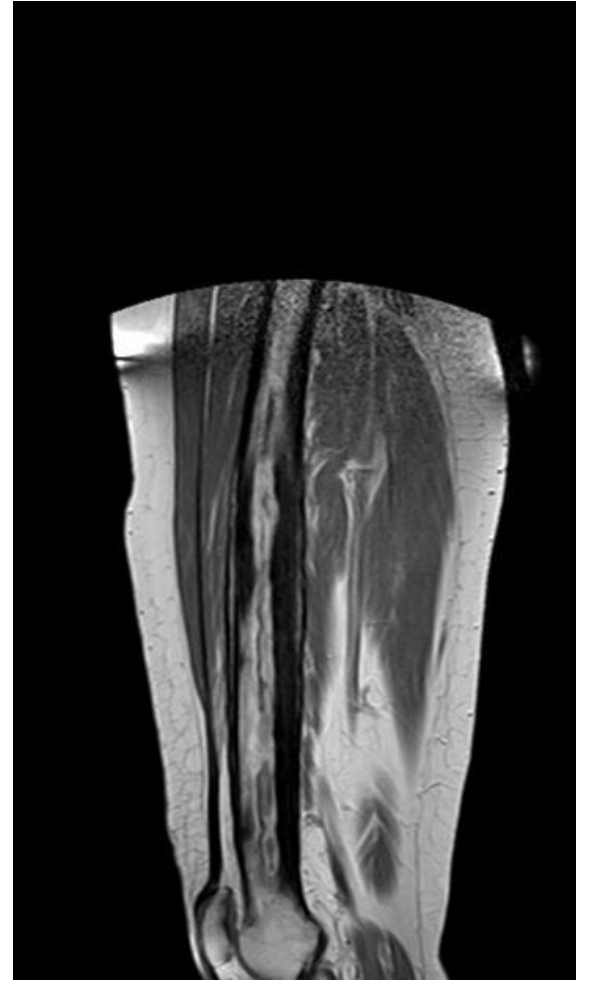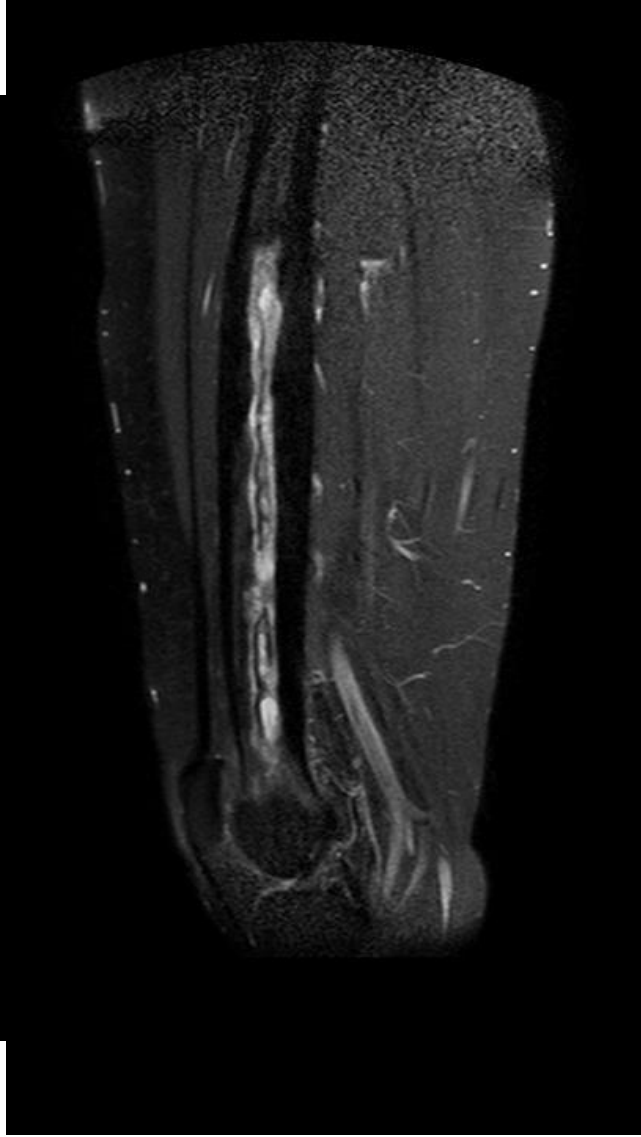


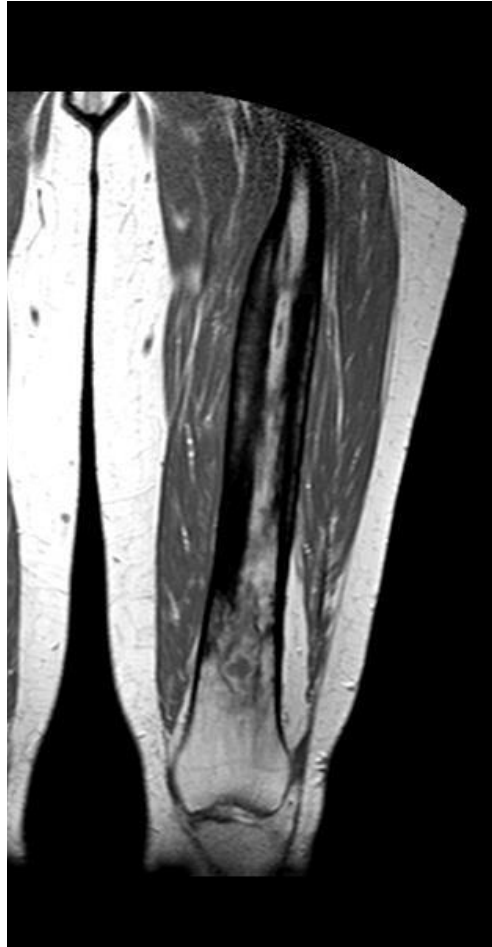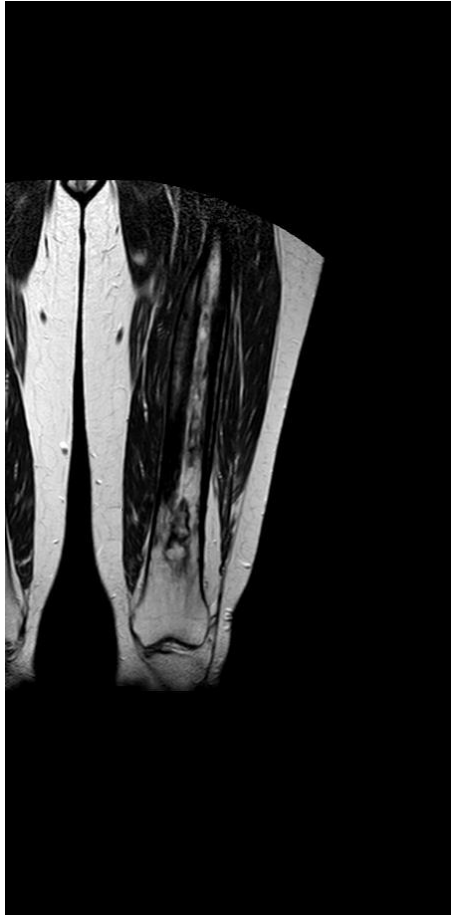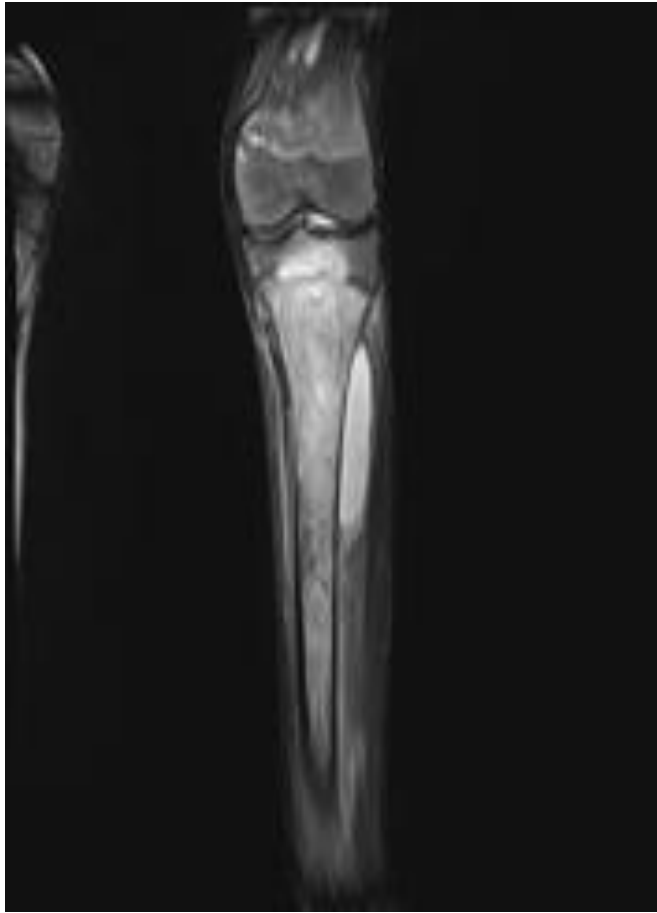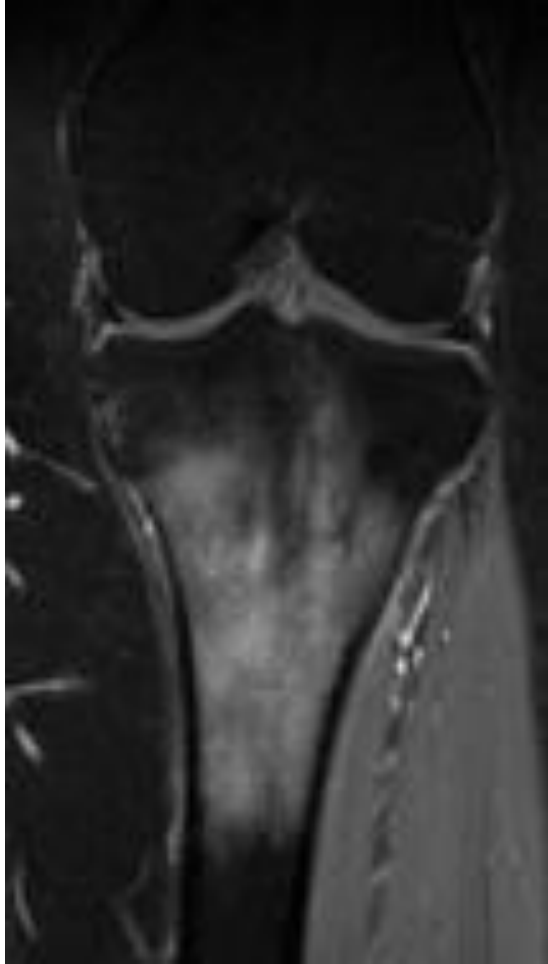




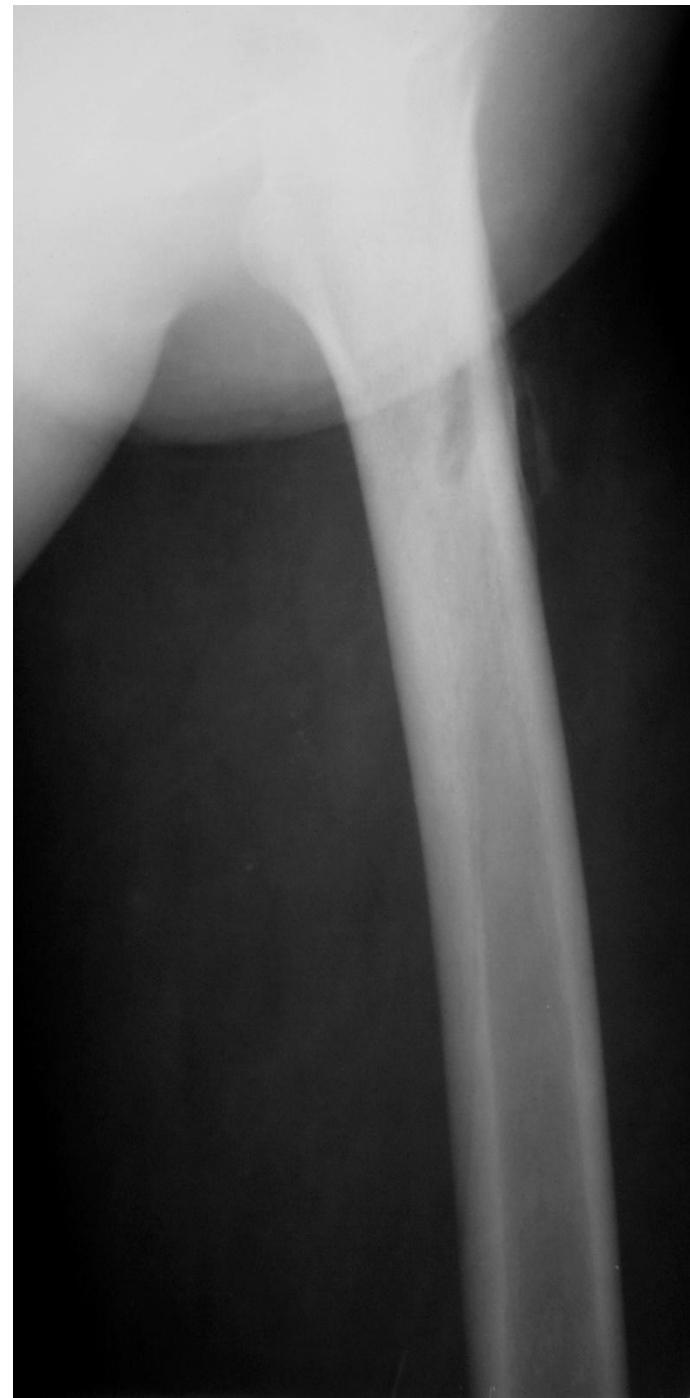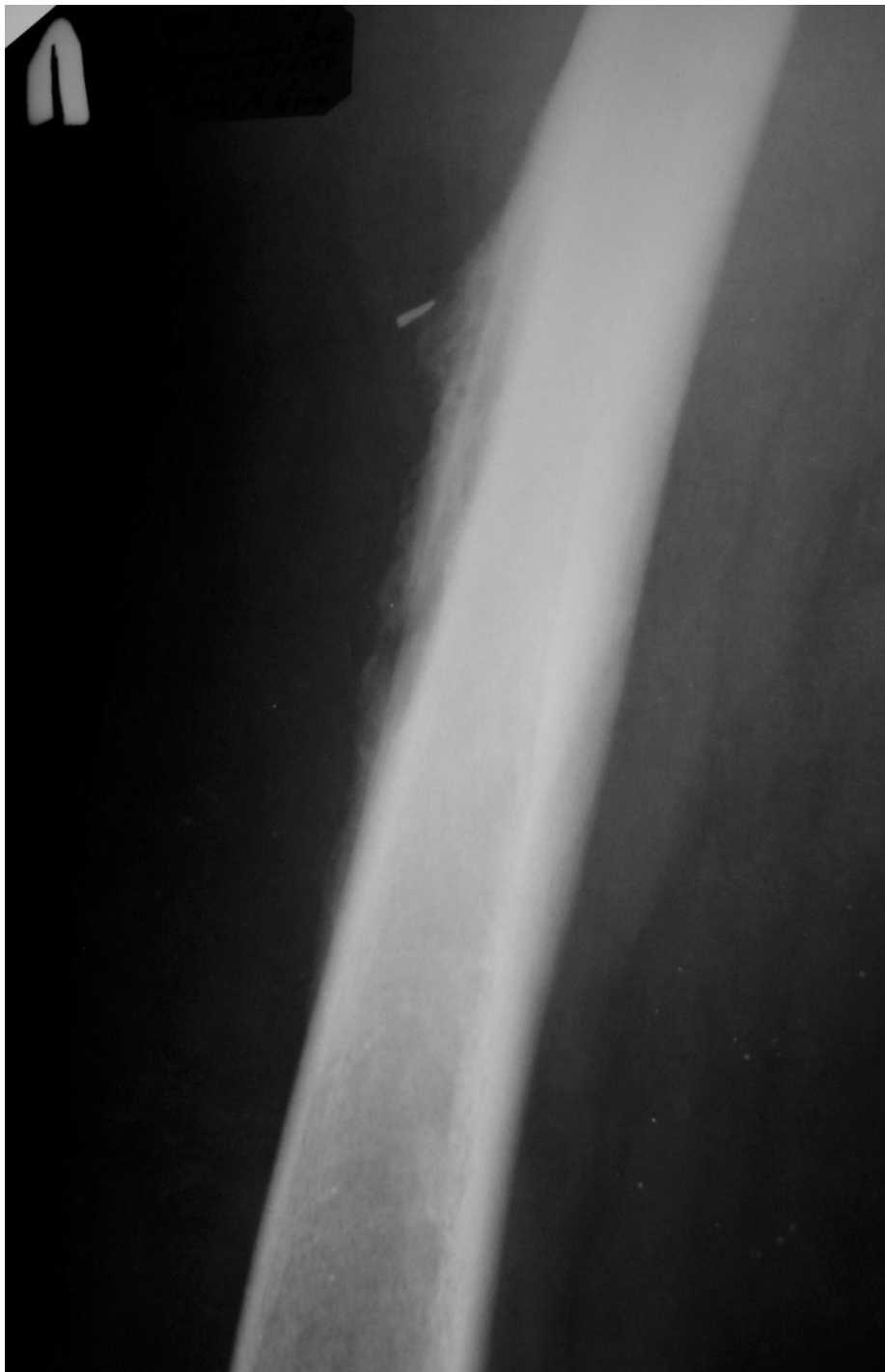


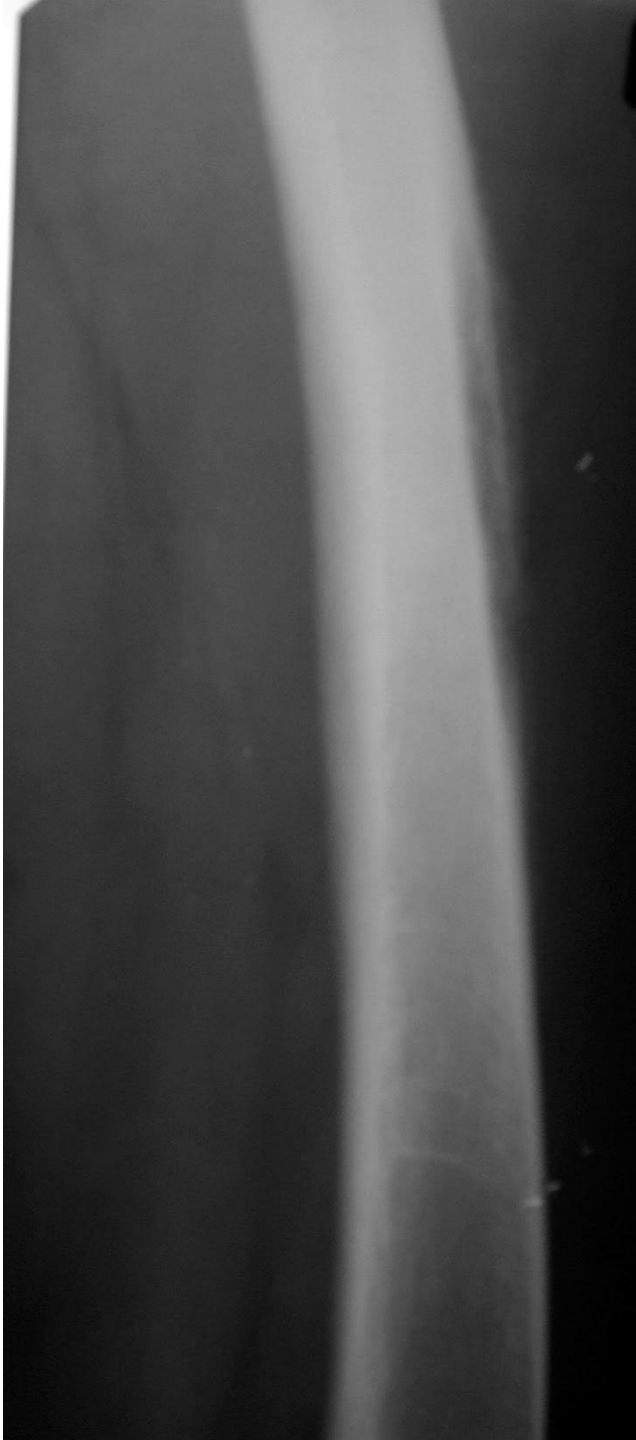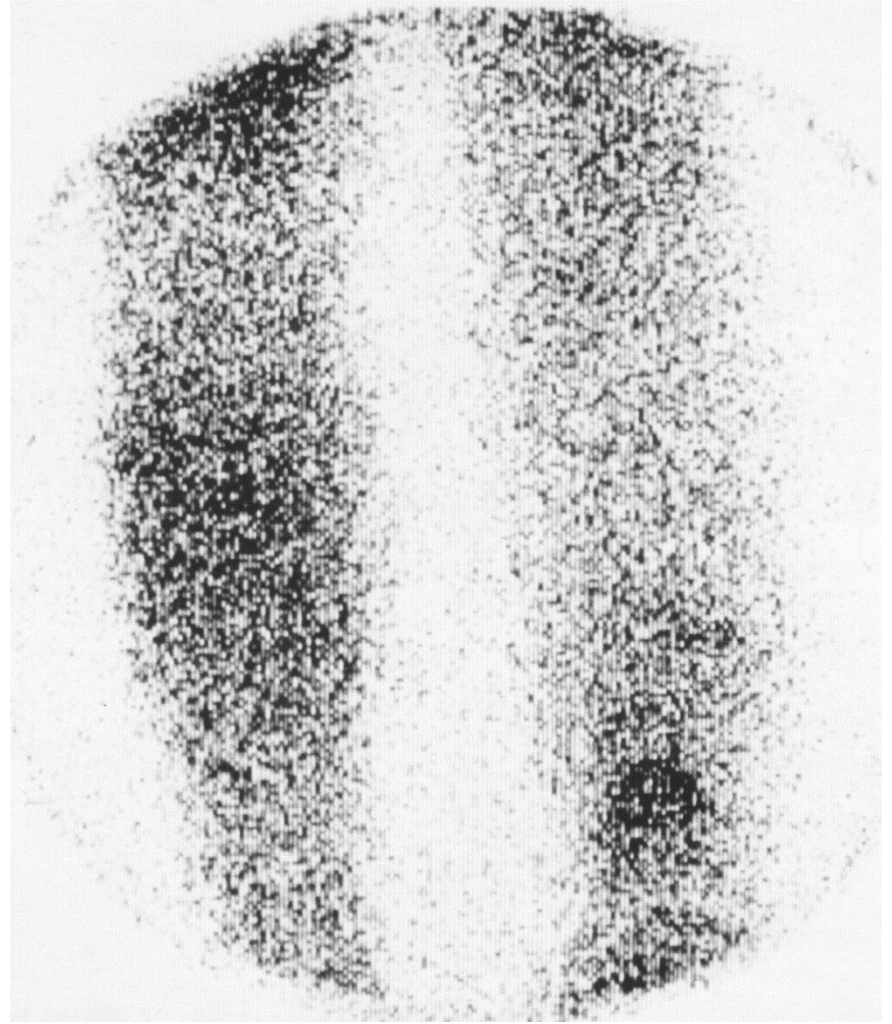
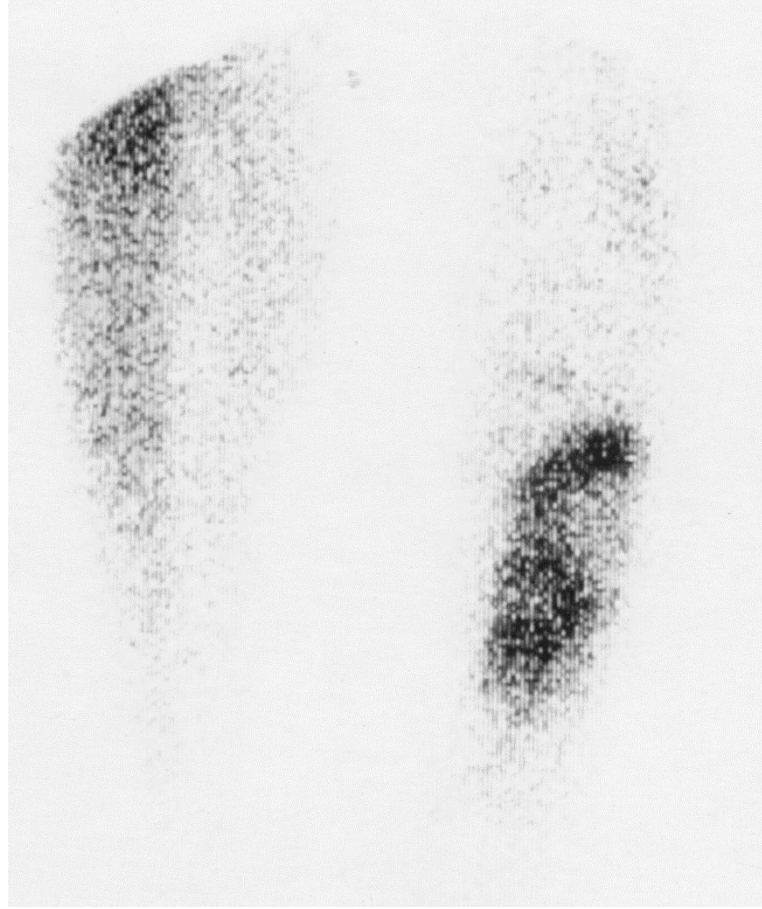


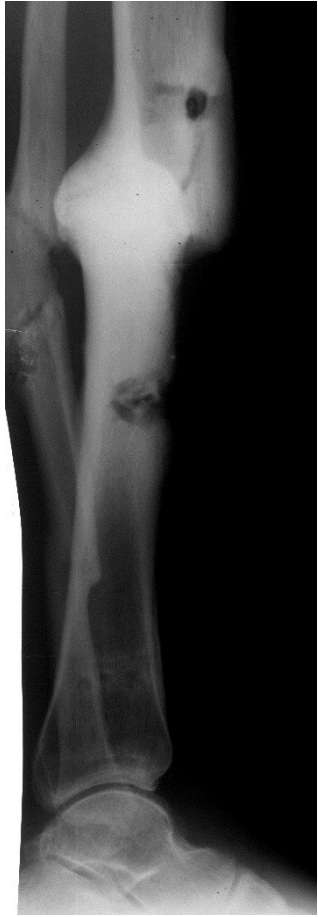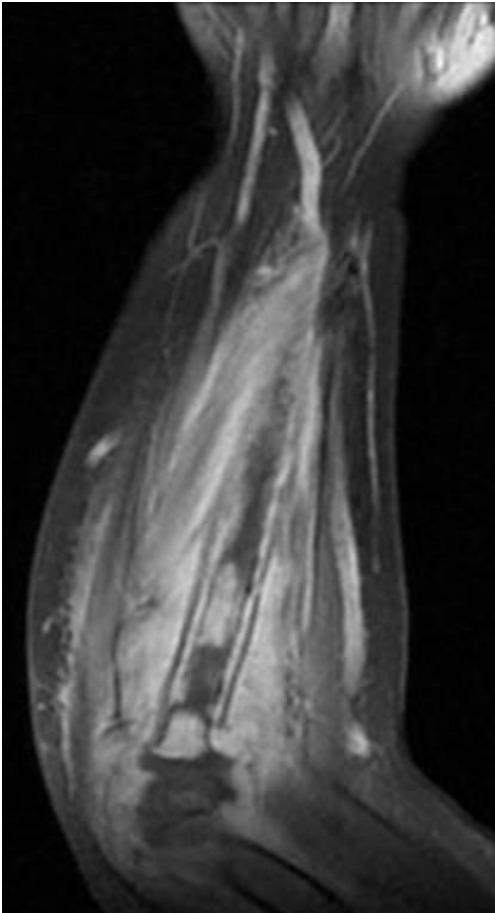
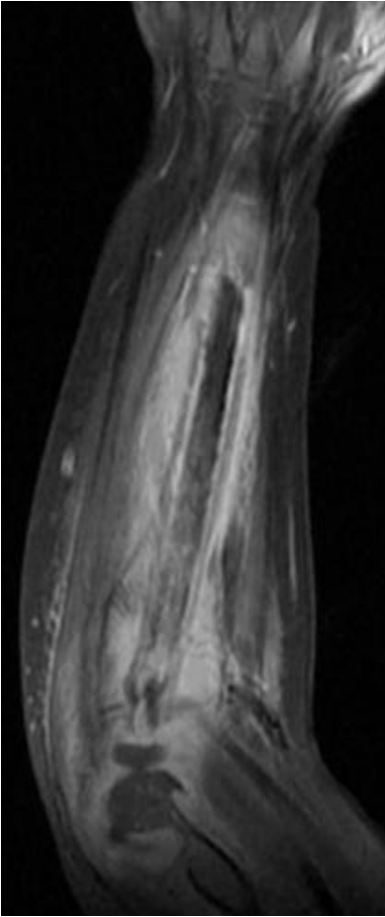




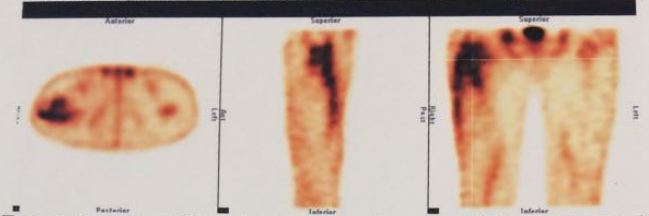









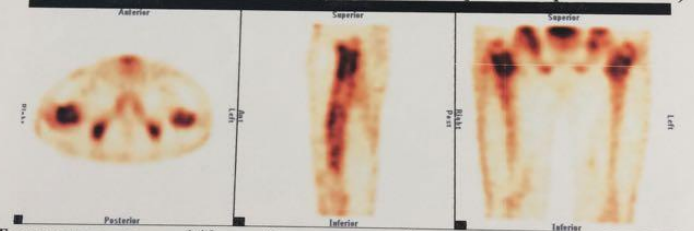
Томосцинтиграмма 20 мин (на уровне головки правой бедренной кости)



Томосцинтиграмма 20 мин (на уровне диафиза правой бедренной кости)



Томосцинтиграмма 140 мин (на уровне головки правой бедренной кости)



Томосцинтиграмма 140 мин (на уровне диафиза правой бедренной кости)



