Клиническая анатомия крупных суставов

доцент кафедры хирургических болезней с курсом травматологии и ортопедии СибГМУ

Ларин
Михаил Алексеевич

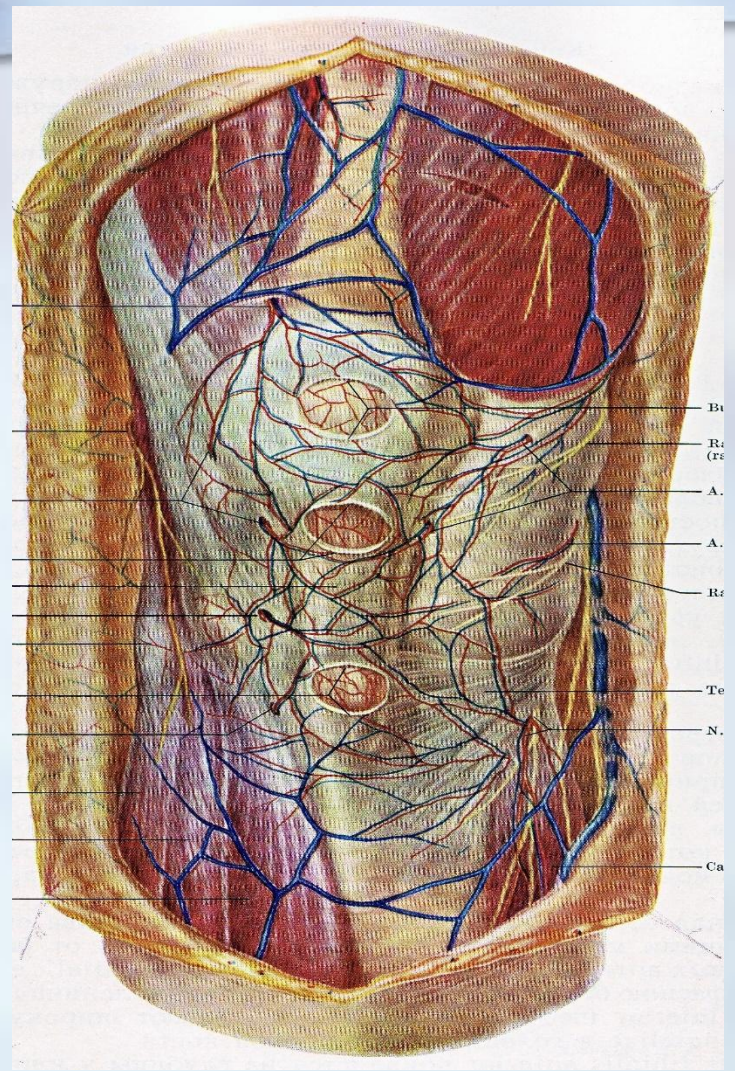
Bu
Ra
(Ra
A.
A.
Ra
Te
N.
Ca

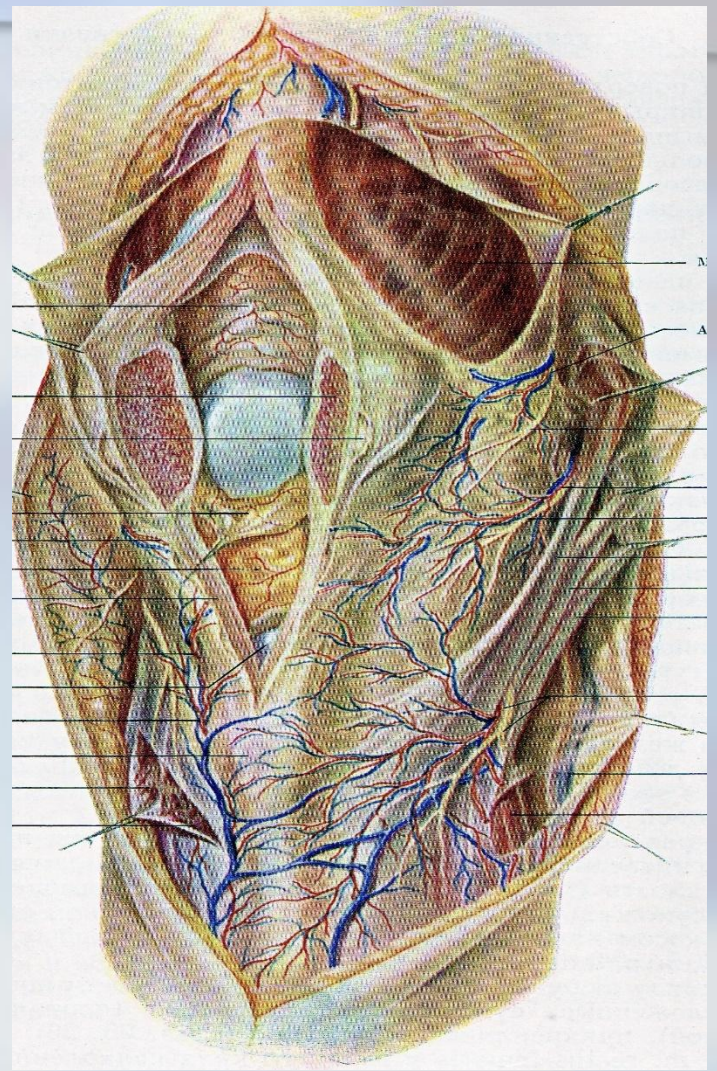
M
A

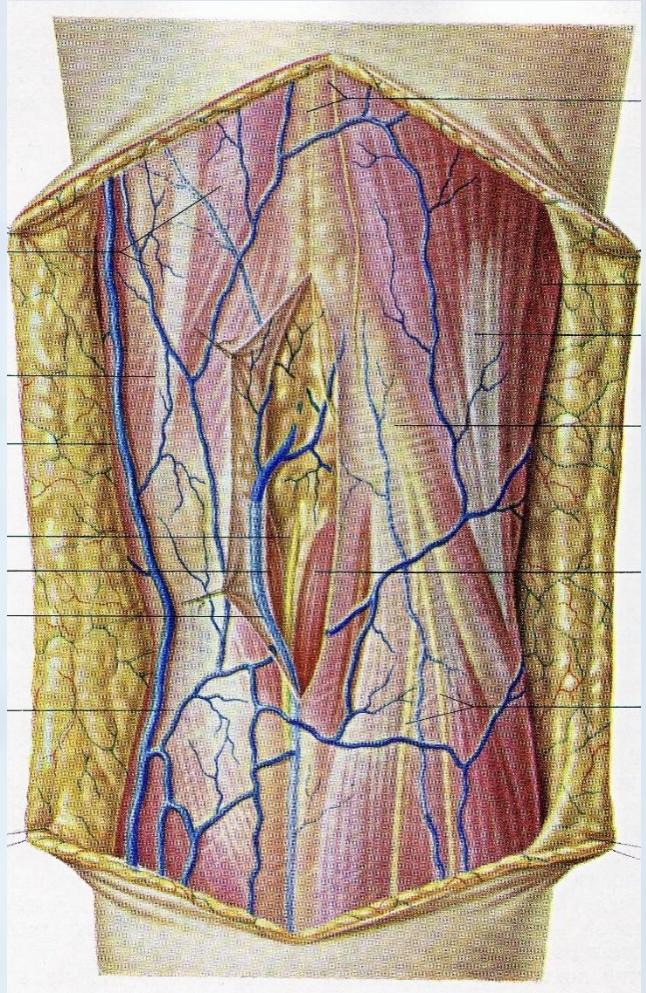

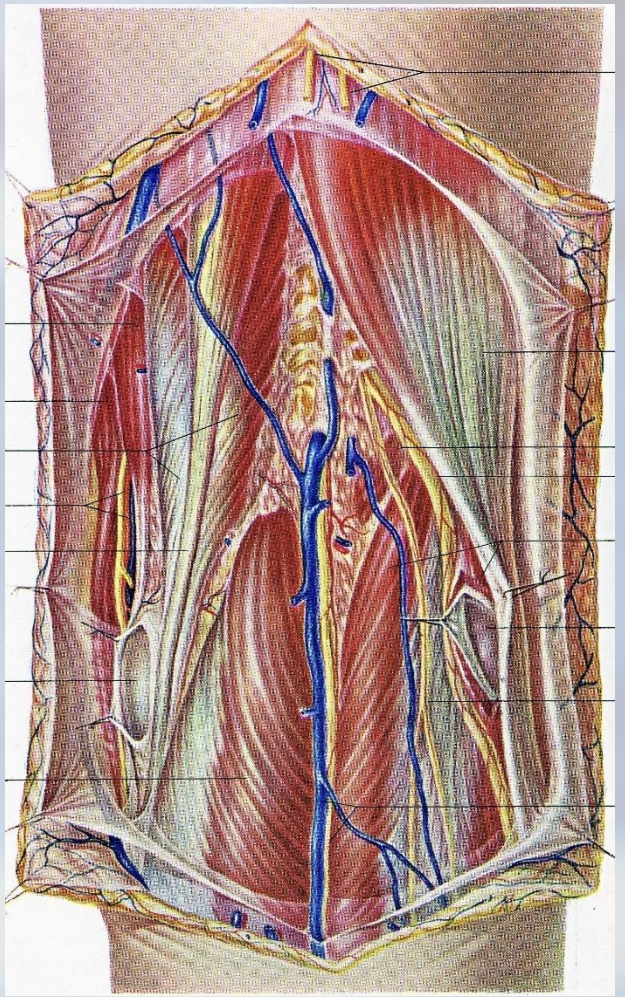

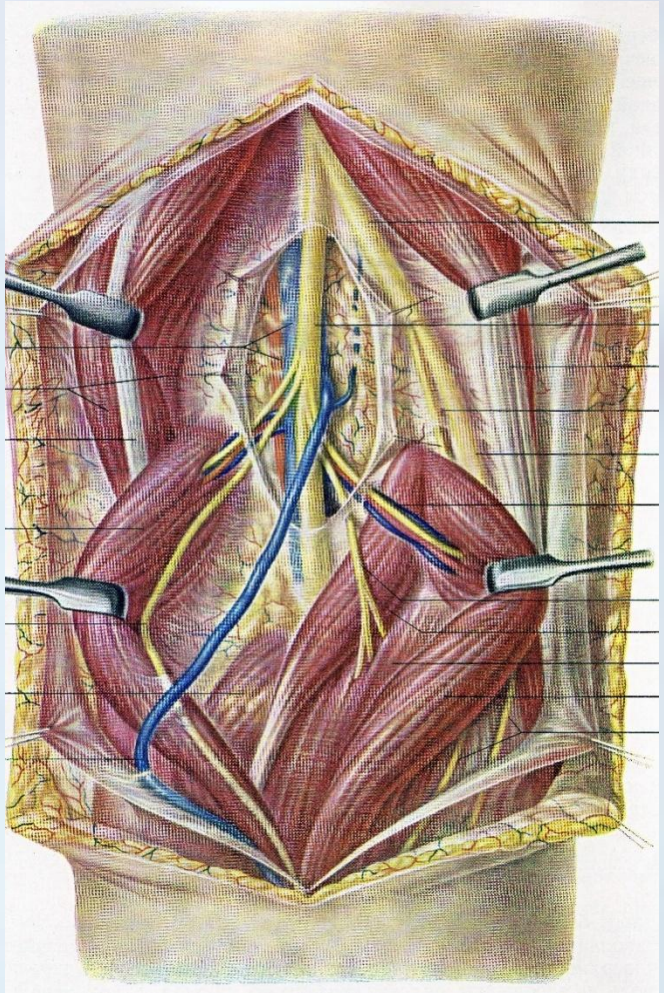

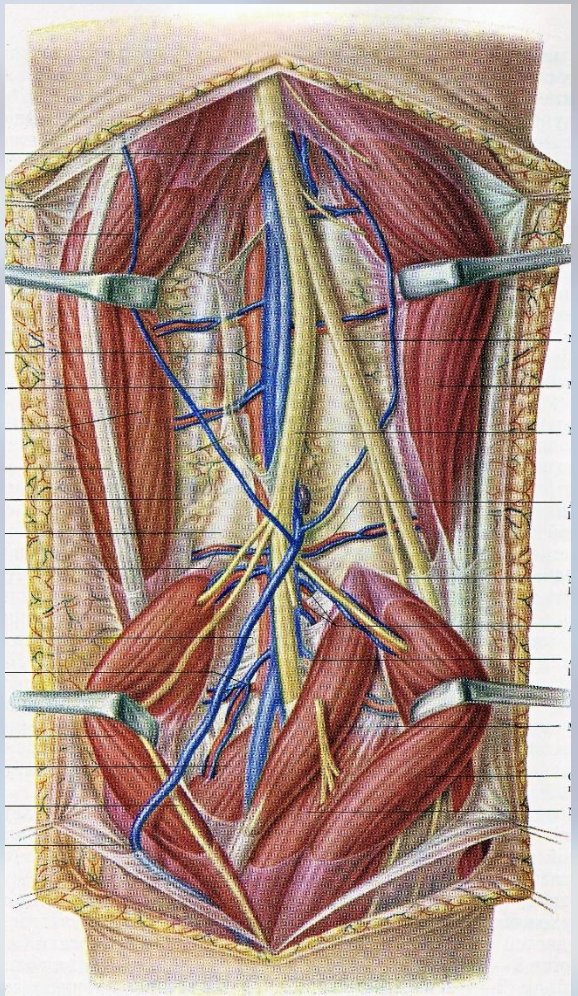

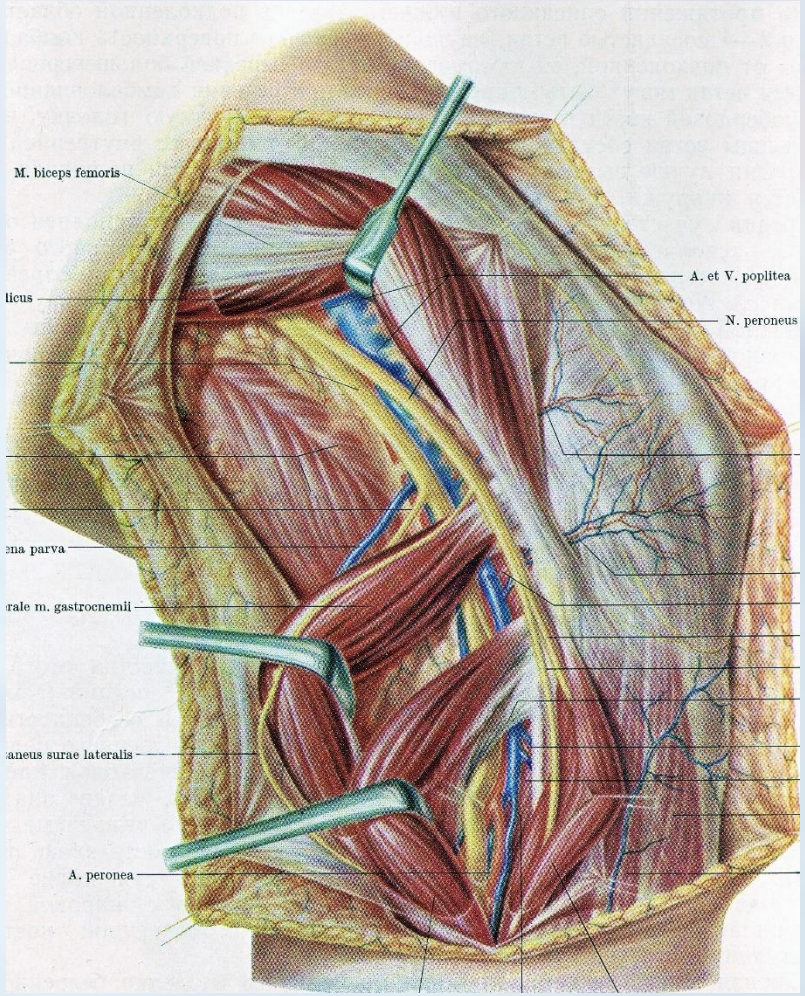
M. biceps femoris
licus
ena parva
rale m. gastrocnemii
aneus surae lateralis
A. peronea
A. et V. poplitea
N. peroneus

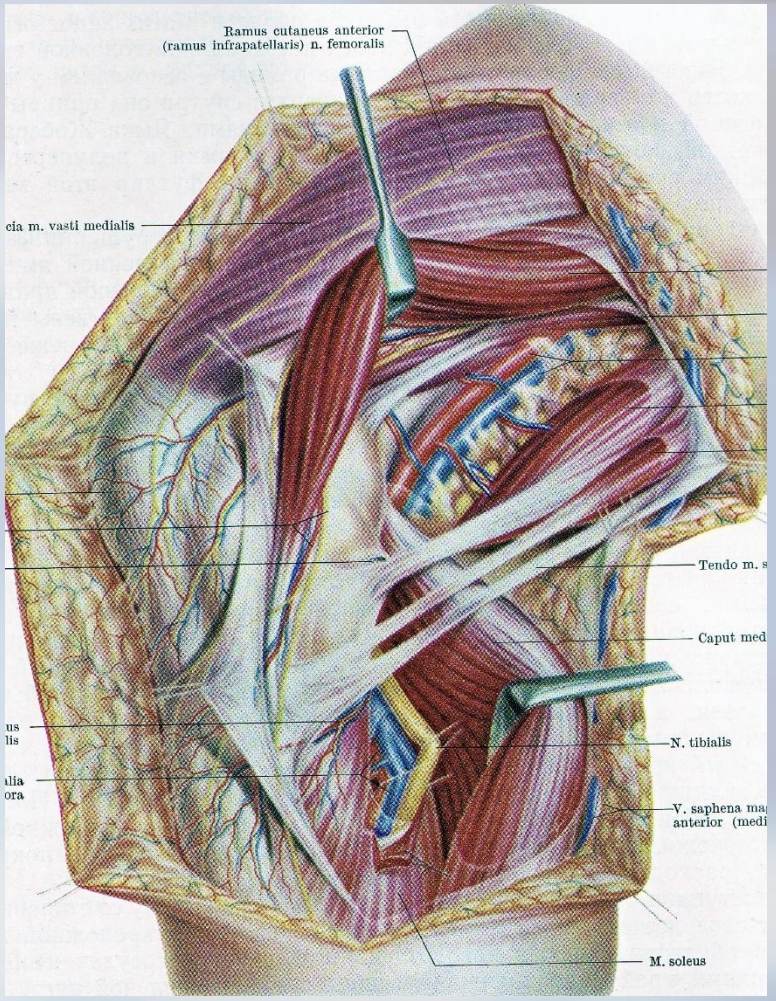
Ramus cutaneus anterior
(ramus infrapatellaris) n. femoralis
cia m. vasti medialis
Tendo m. s
Caput med
N. tibialis
V. saphena ma
anterior (medi
M. soleus

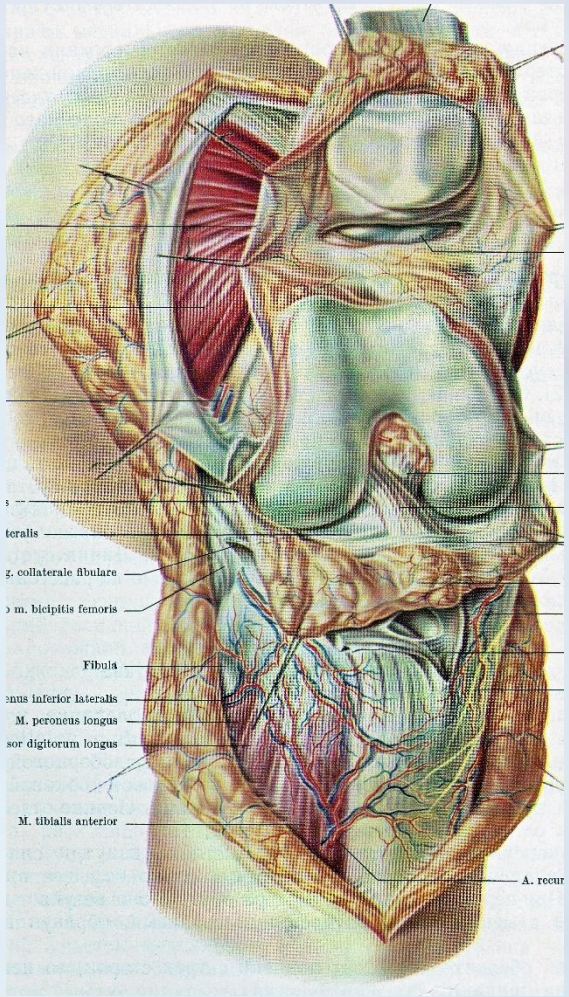
teralis
g. collaterale fibulare
m. bicipitis femoris
Fibula
enus inferior lateralis
M. peroneus longus
sor digitorum longus
M. tibialis anterior
A. recur

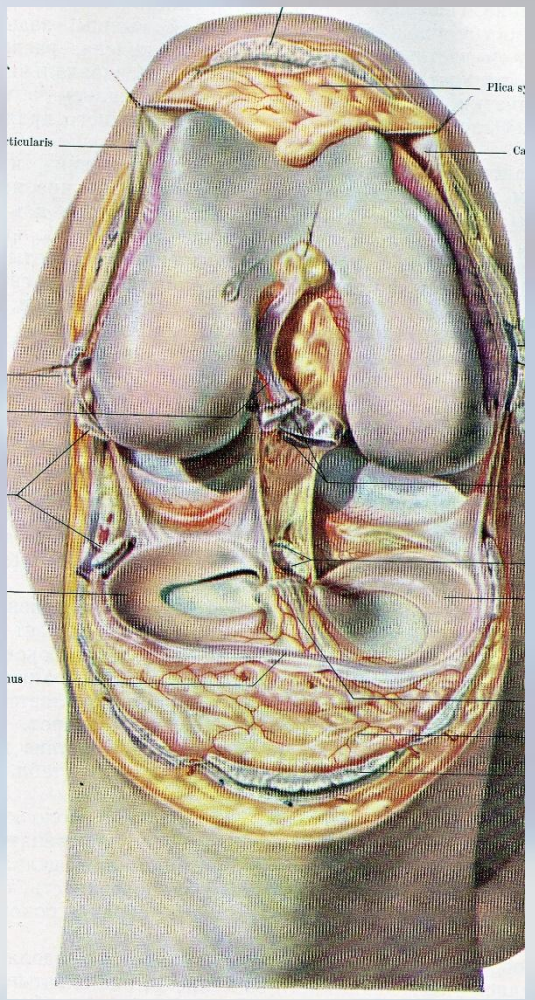
Plica s
ticularis
Ca
nus

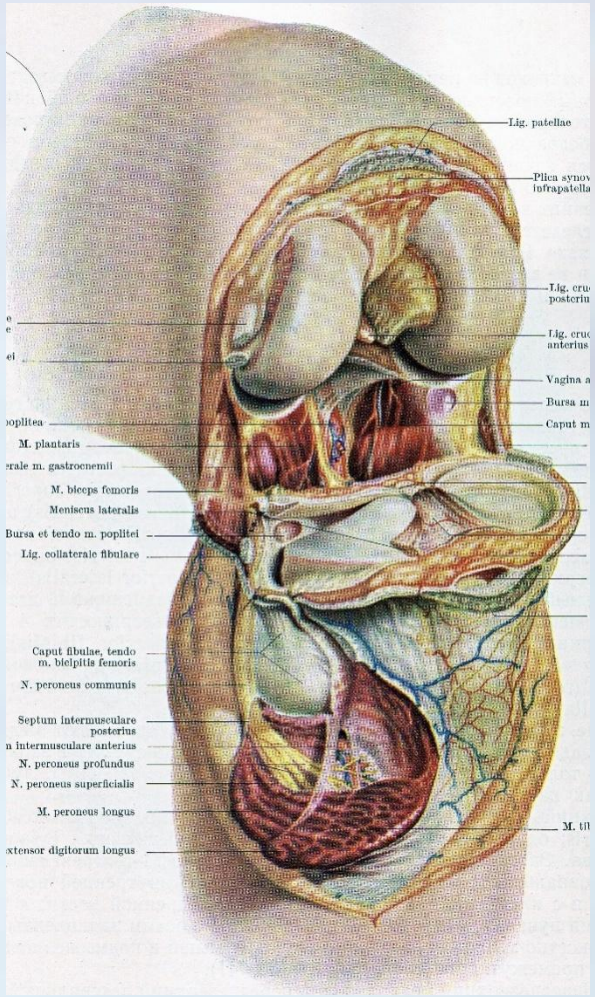
Lig. patellae
Plica synov
infrapatella
Lig. cru
posteriu
Lig. cru
anterius
Vagina a
Bursa m
Caput m
M. plantaris
M. biceps femoris
Meniscus lateralis
Bursa et tendo m. poplitei
Lig. collaterale fibulare
Caput fibulae, tendo
m. bicipitis femoris
N. peroneus communis
Septum intermusculare
posterius
N. peroneus profundus
N. peroneus superficialis
M. peroneus longus

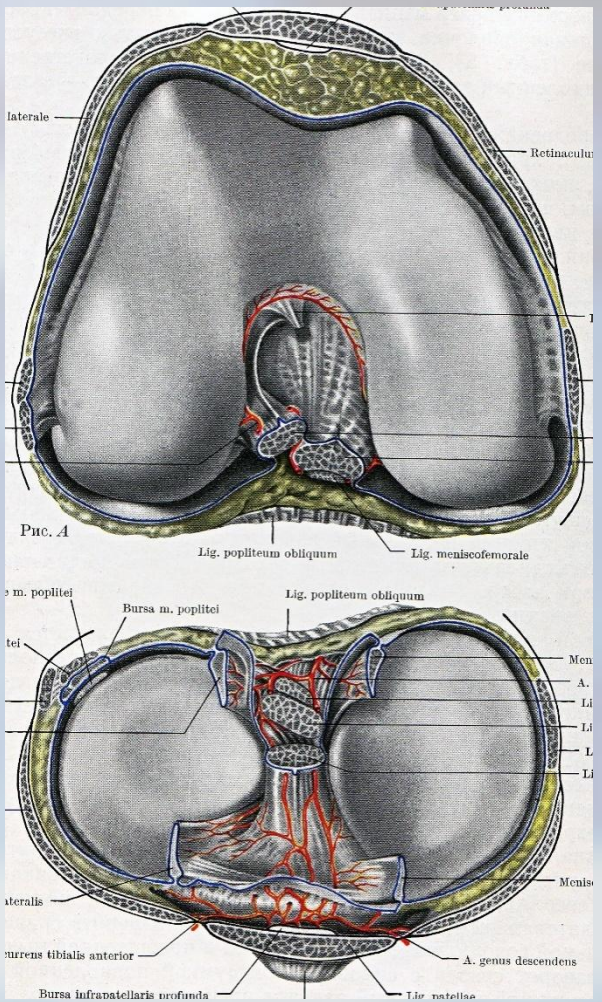
Рис. А
Lig. popliteum obliquum
Lig. meniscofemorale
Bursa m. poplitei
Lig. popliteum obliquum
A. genus descendens

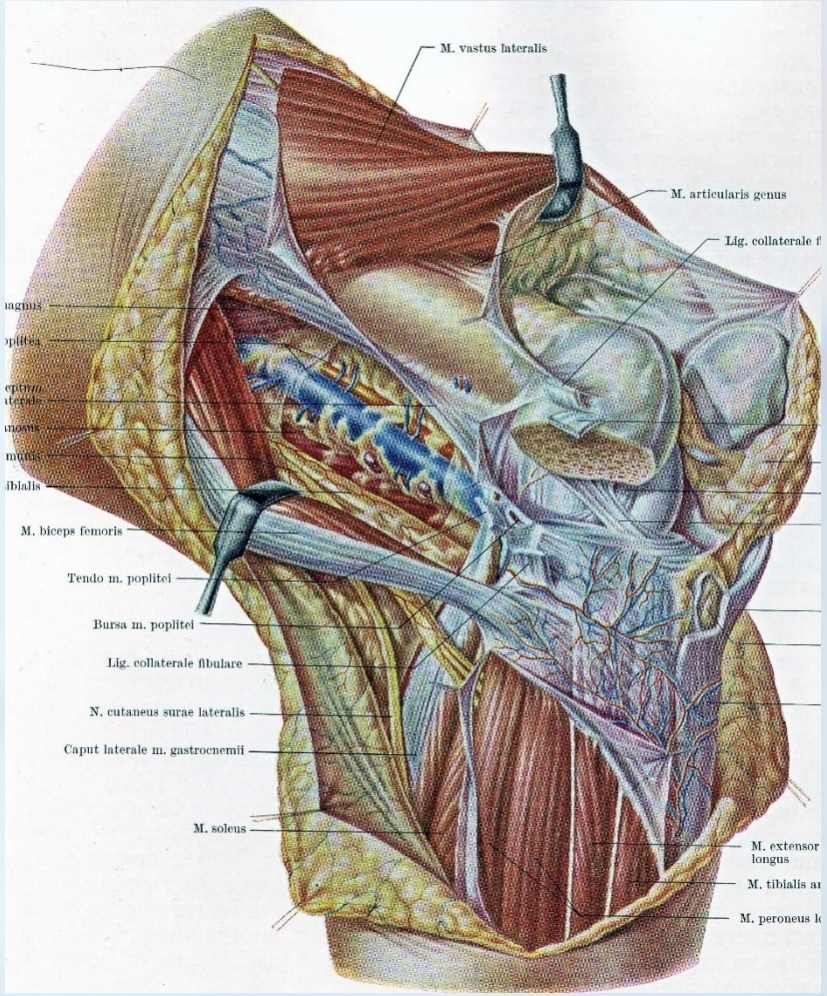
M. vastus lateralis
M. articularis genus
M. biceps femoris
Tendo m. poplitei
Bursa m. poplitei
Lig. collaterale fibulare
N. cutaneus surae lateralis
Caput laterale m. gastrocnemii
M. soleus
M. extensor longus

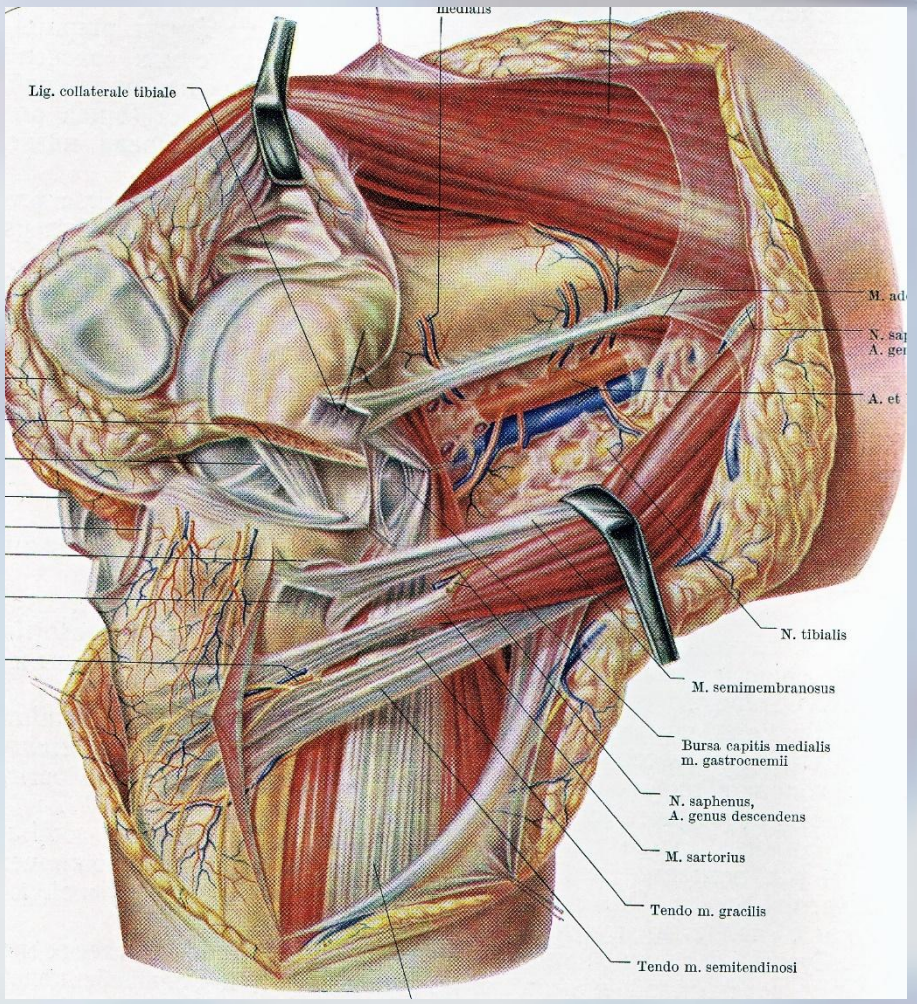
Lig. collaterale tibiale
N. tibialis
M. semimembranosus
Bursa capitis medialis m. gastrocnemii
N. saphenus, A. genus descendens
M. sartorius
Tendo m. gracilis
Tendo m. semitendinosi

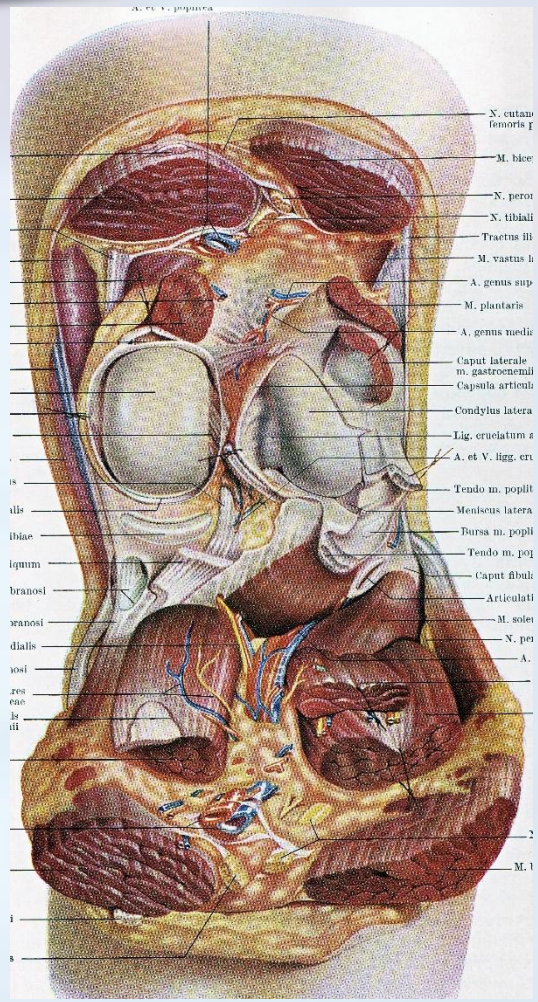
N. tibiali
Tractus ili
M. vastus l
A. genus sup
M. plantaris
A. genus media
Caput laterale
m. gastrocnemii
Capsula articula
Condylus latera
Lig. cruciatum a
A. et V. ligg. cru
Tendo m. poplit
Meniscus latera
Bursa m. popli
Tendo m. pop
Caput fibula
Articulati
M. soleu
N. pe
A.

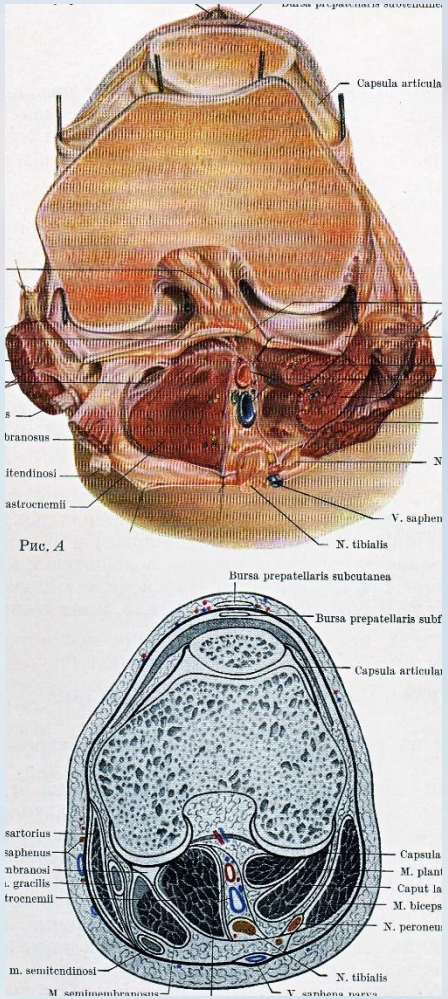
Capsula articula
V. saphen
N. tibialis
Рис. А
Bursa prepatellaris subcutanea
Bursa prepatellaris subf
Capsula articula
sartorius
saphenus
Capsula
M. plant
Caput la
M. biceps
N. peroneu
m. semitendinosi
N. tibialis

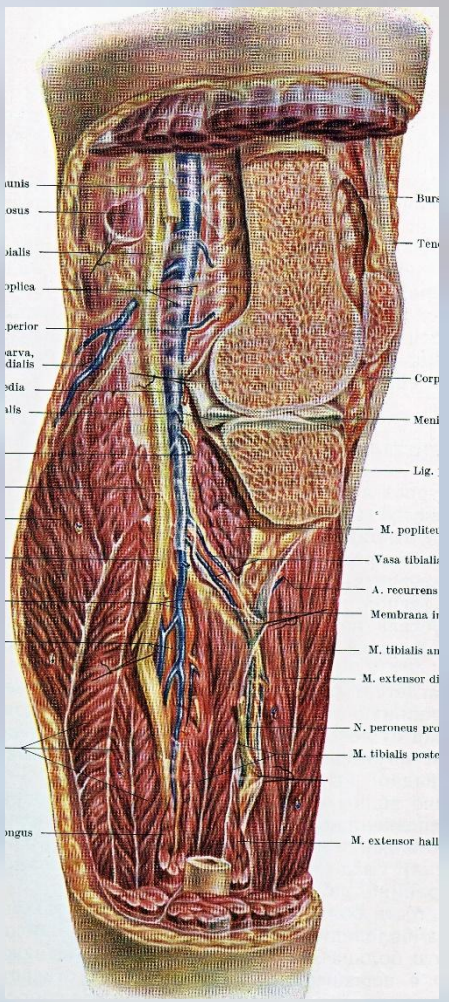
Bur
Ten
Corp
Meni
Lig.
M. poplite
Vasa tibiali
A. recurrens
Membrana i
M. tibialis an
M. extensor di
N. peroneus pro
M. tibialis poste
M. extensor hall

Nn.
Crista

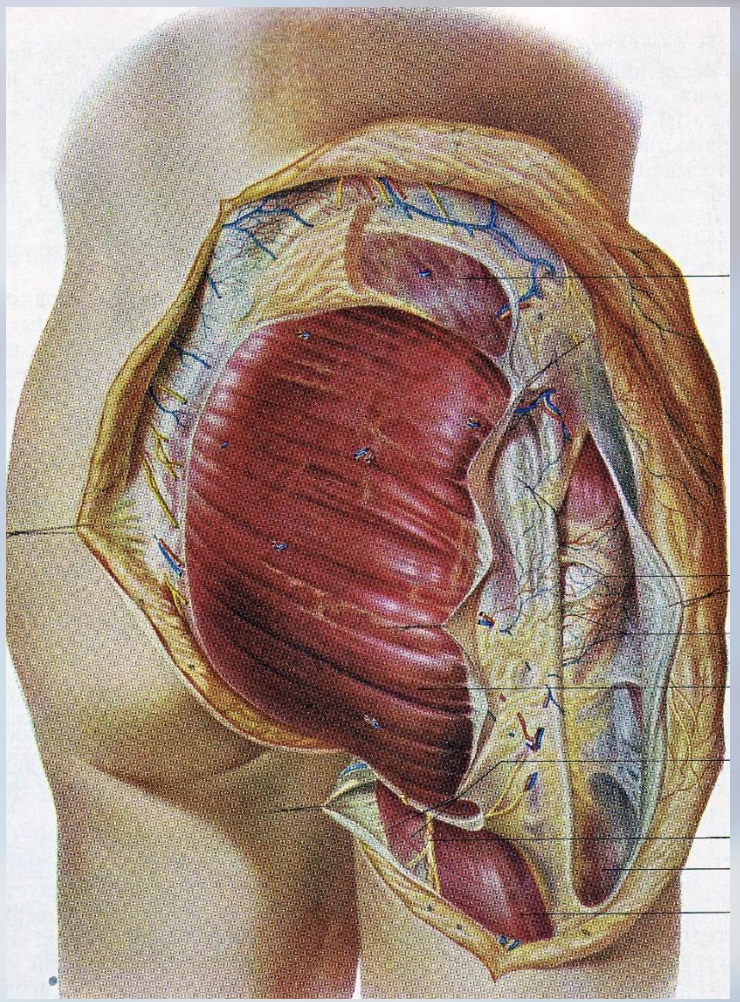

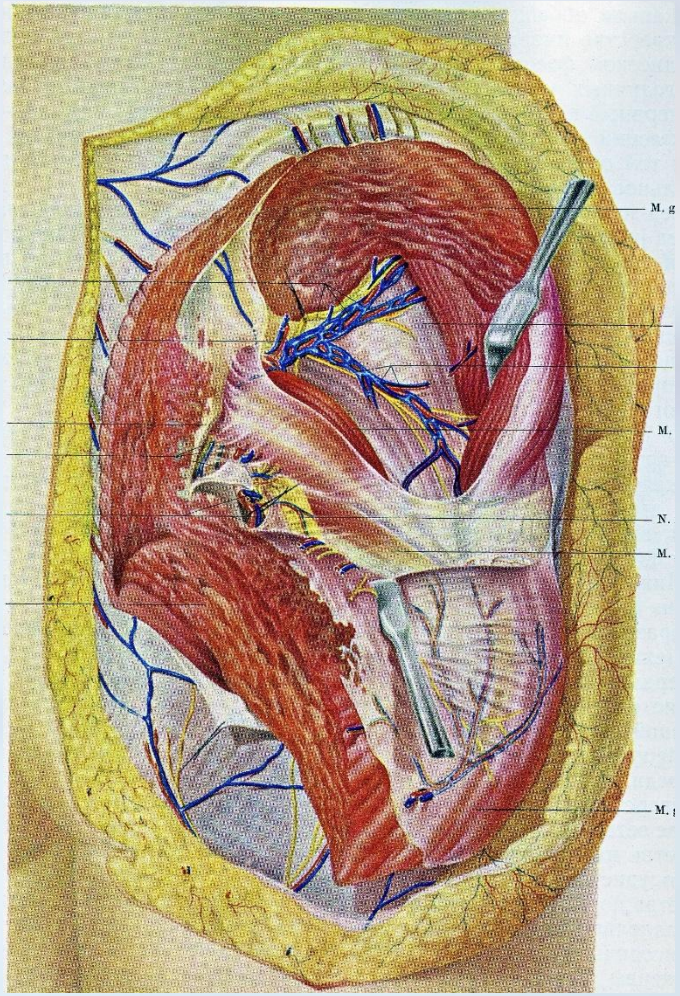
M. g
M.
N.
M.
M.

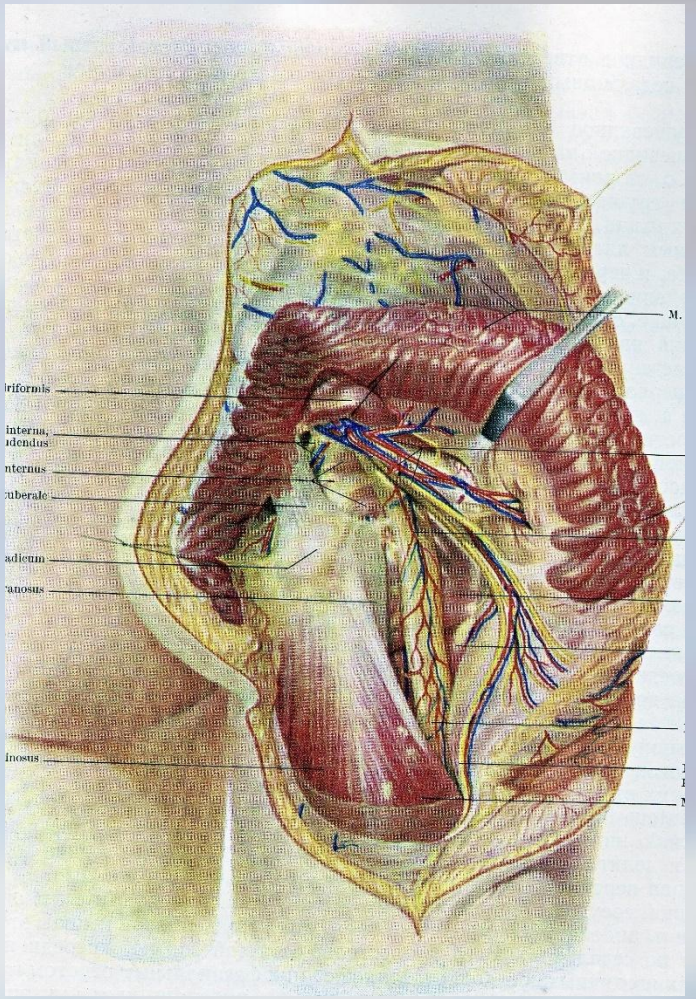
M.
riformis
interna,
ndendus
nternus
uberale
adicum
anosus
inosus

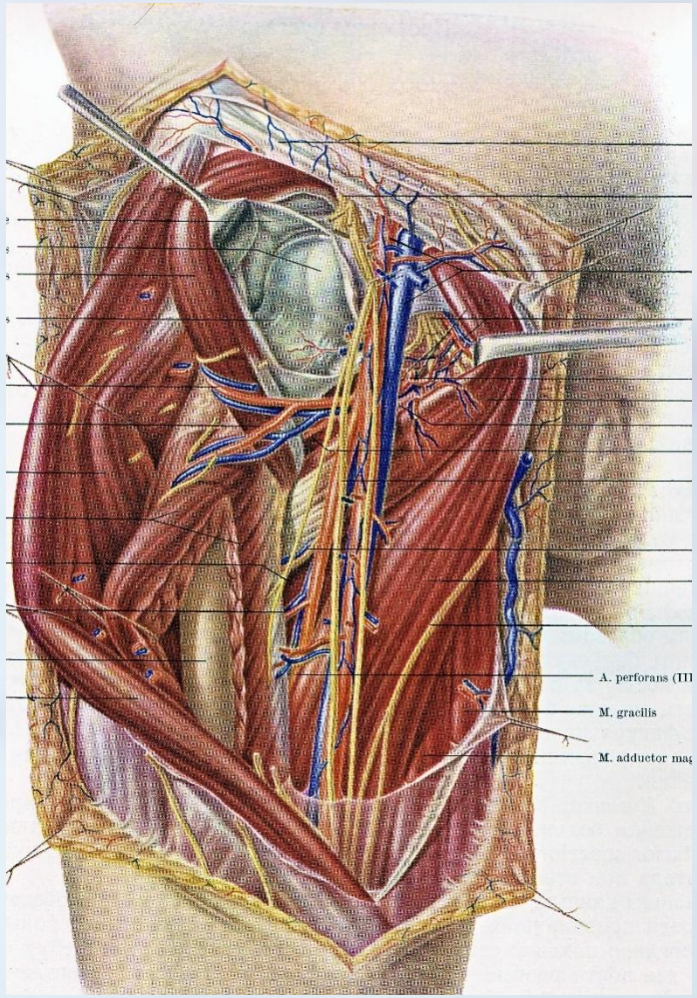
A. perforans (III
M. gracilis
M. adductor mag

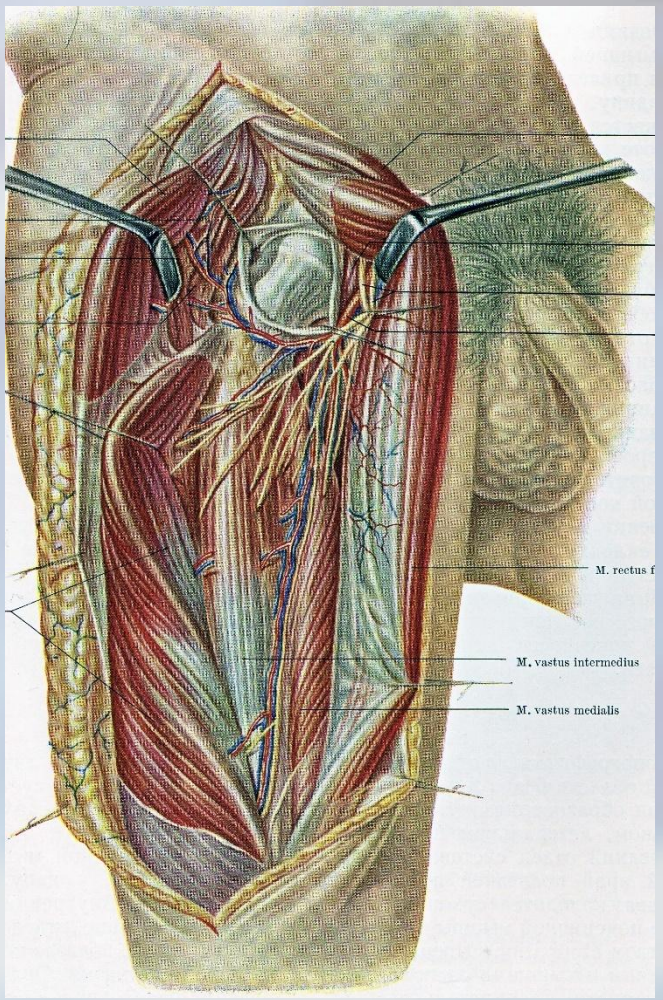
M. rectus f
M. vastus intermedius
M. vastus medialis

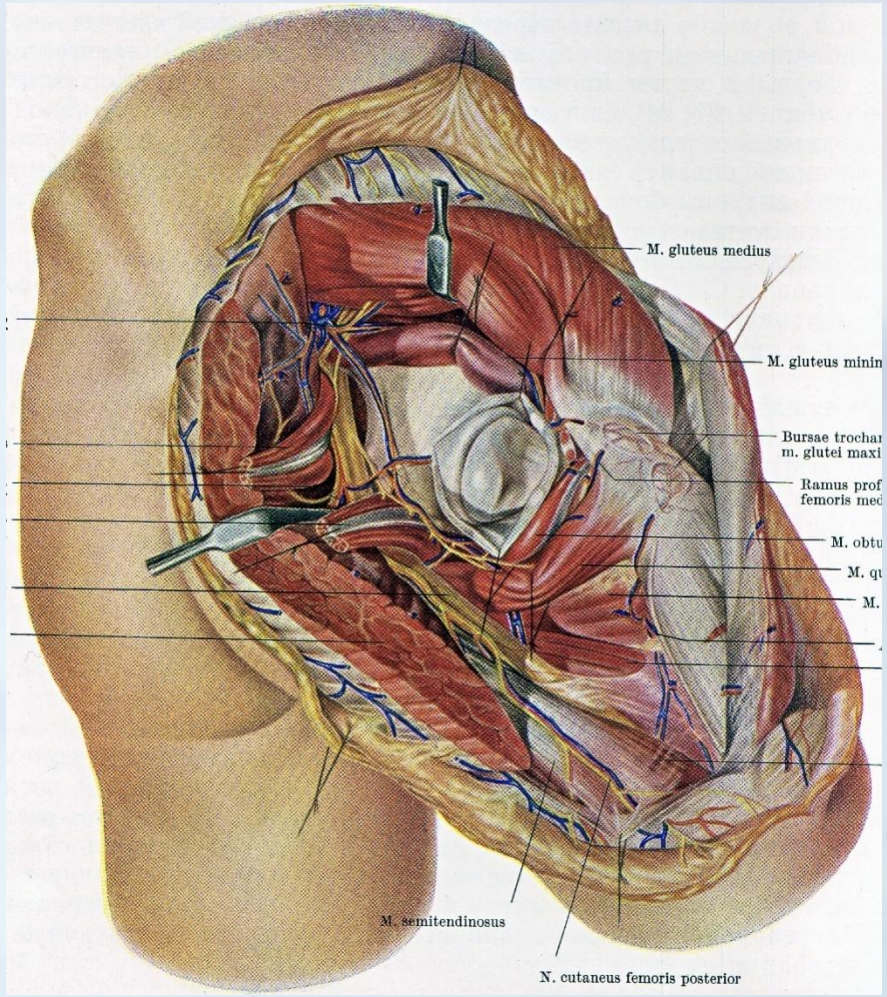
M. gluteus medius
M. gluteus minin
Bursae trochar
m. glutei maxi
Ramus prof
femoris med
M. obtu
M. qu
M.
M. semitendinosus
N. cutaneus femoris posterior

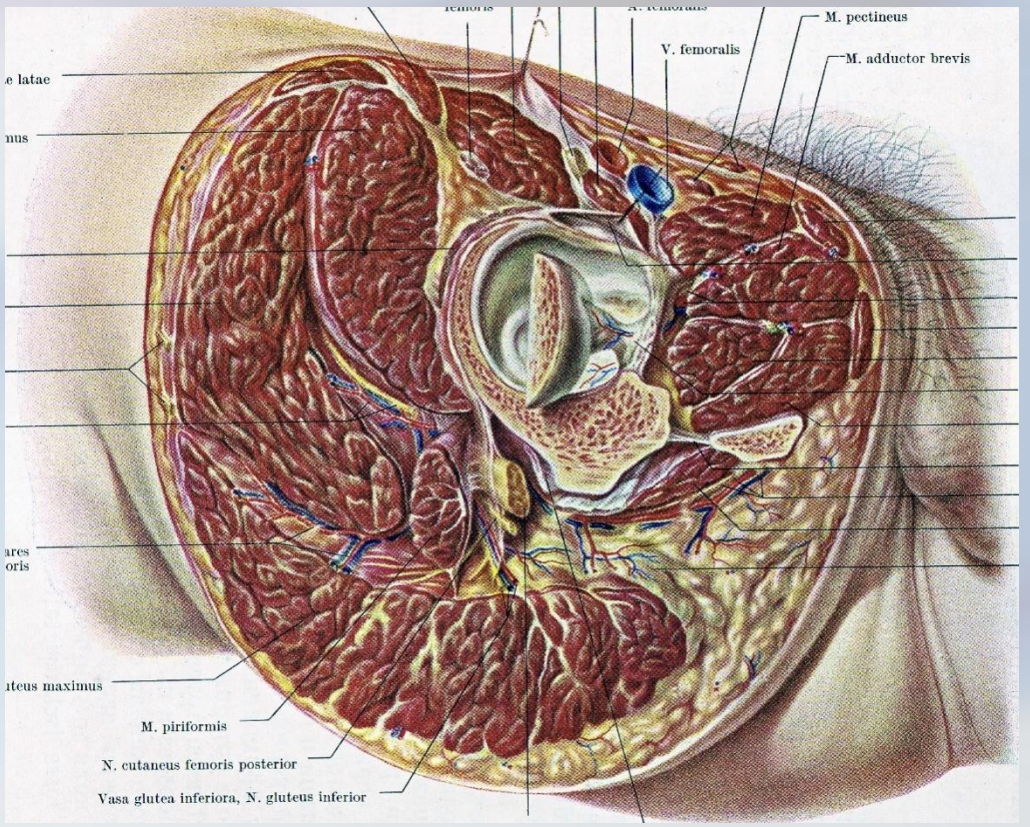
M. pectineus
V. femoralis
M. adductor brevis
e latae
nus
ares
oris
teus maximus
M. piriformis
N. cutaneus femoris posterior
Vasa glutea inferiora, N. gluteus inferior

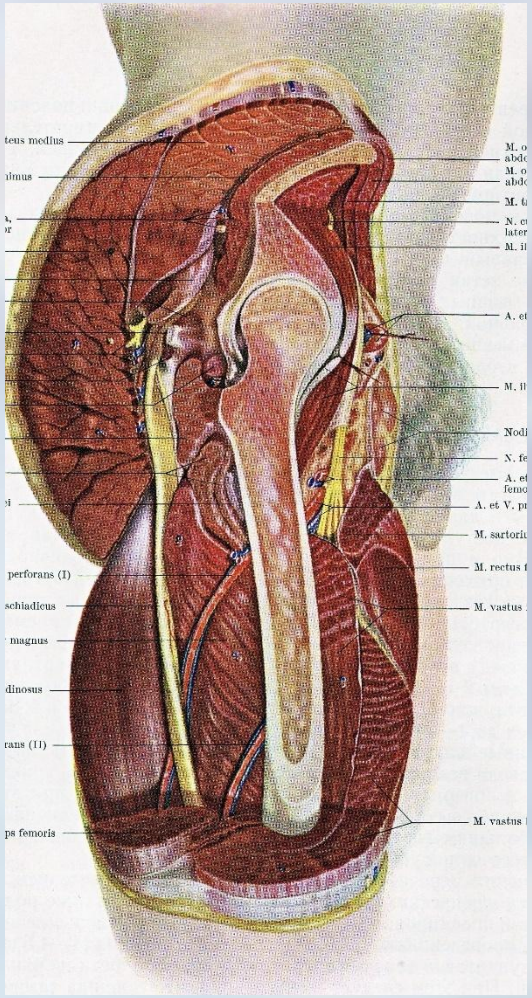
teus medius
imus
perforans (I)
schiadicus
magnus
dinosus
rans (II)
ps femoris
M. vastus
M. sartoriu
M. rectus
A. et V. pr
Nodi
N. fe
A. et
femo
M. vastus

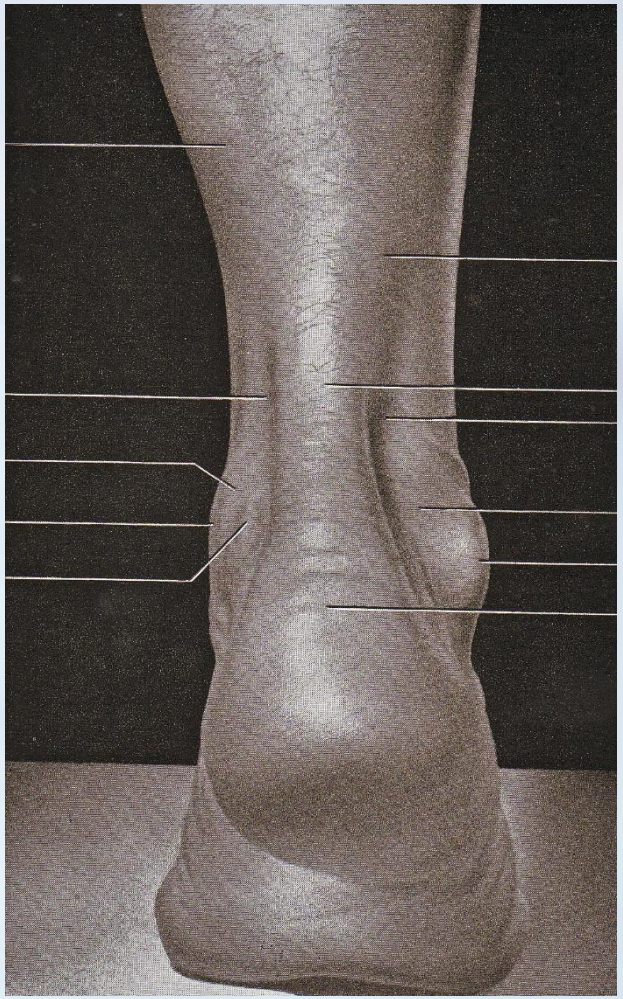

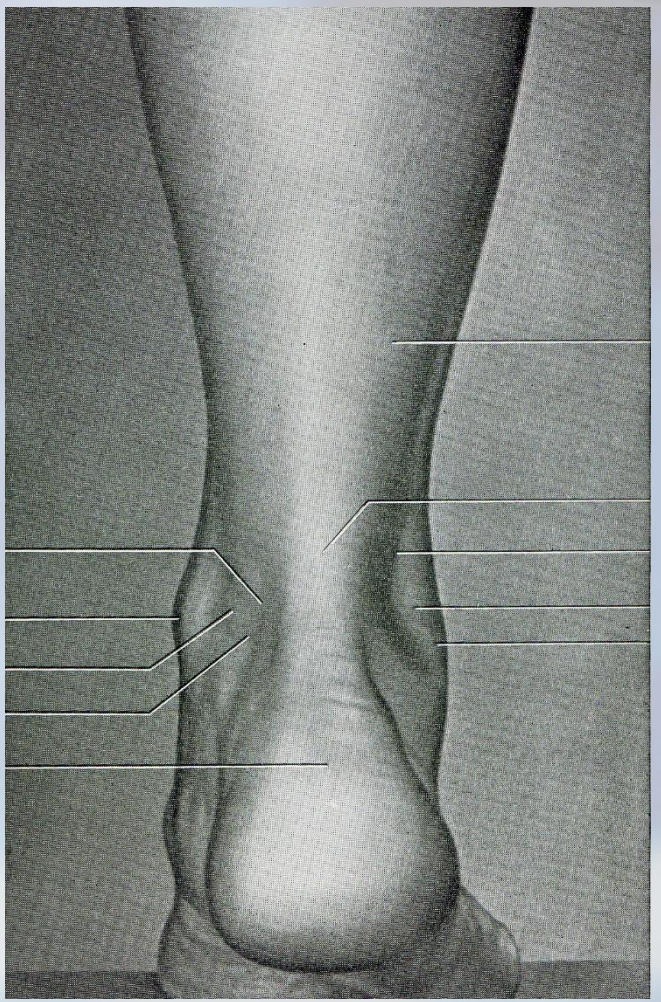

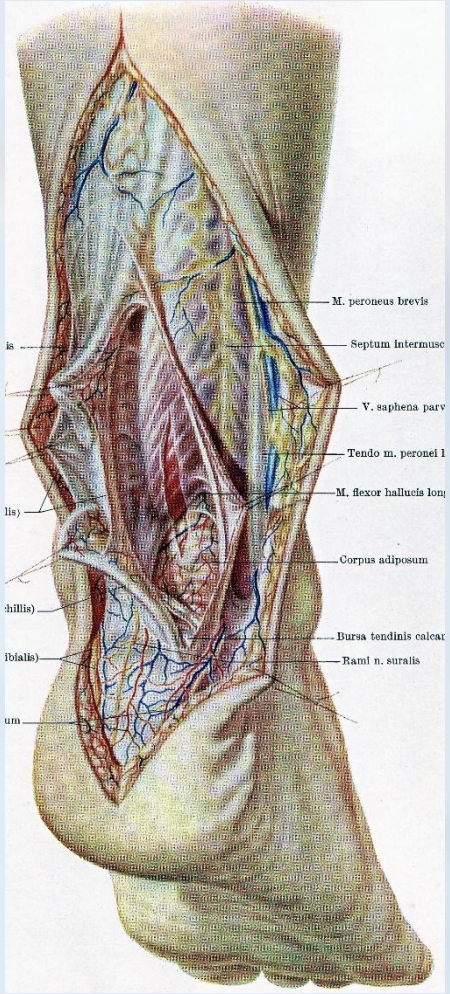
M. peroneus brevis
Septum intermusc
V. saphena parv
Tendo m. peronei l
M. flexor hallucis lon
Corpus adiposum
Bursa tendinis calcar
Rami n. suralis

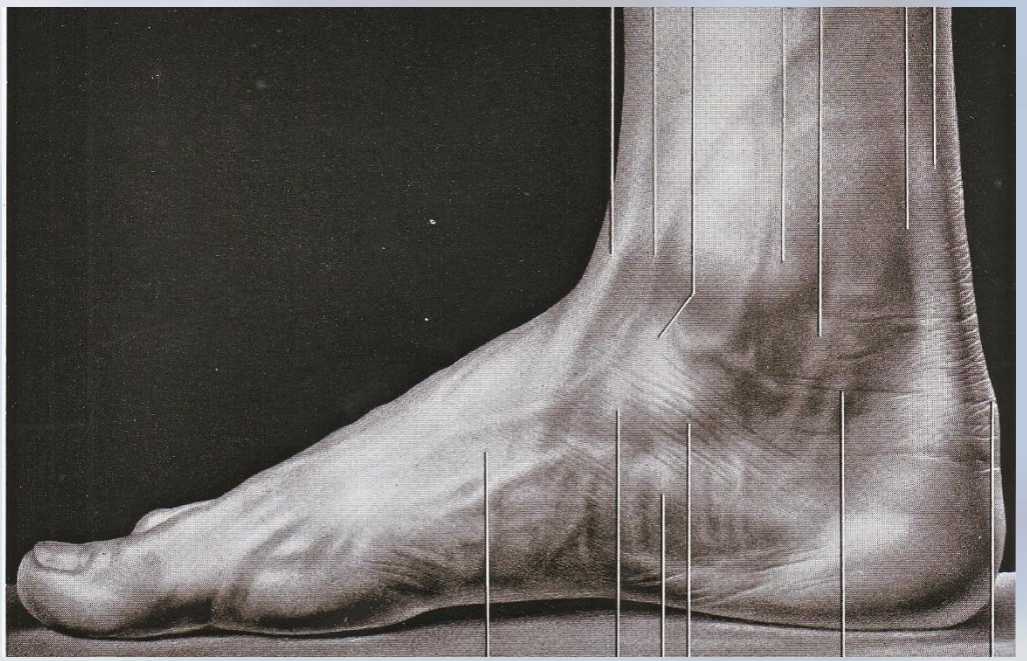

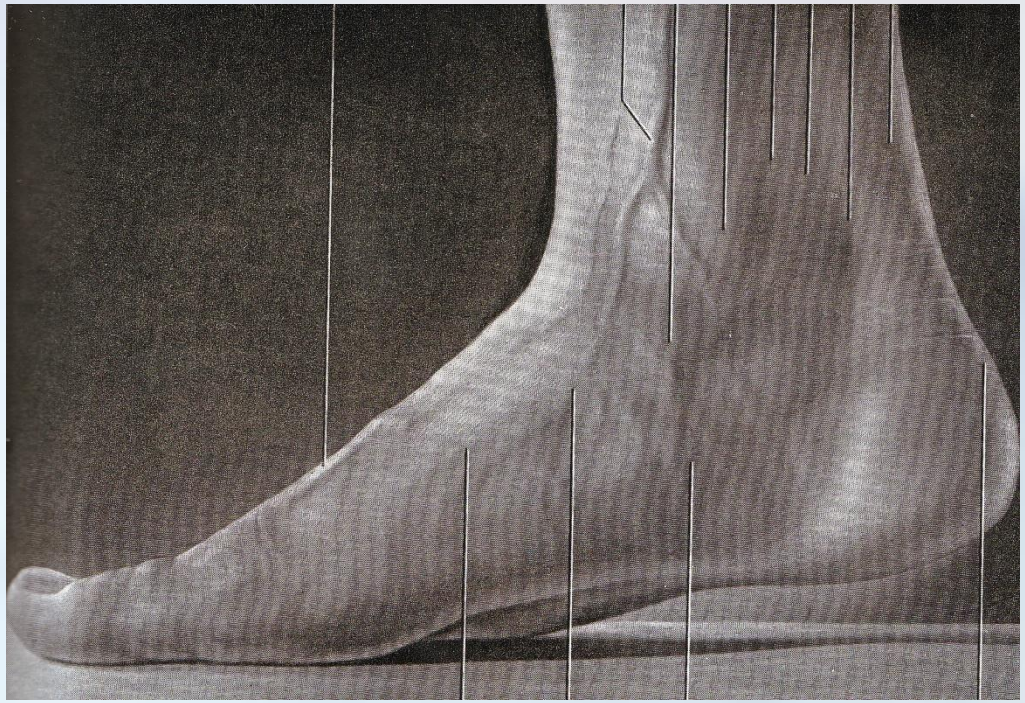

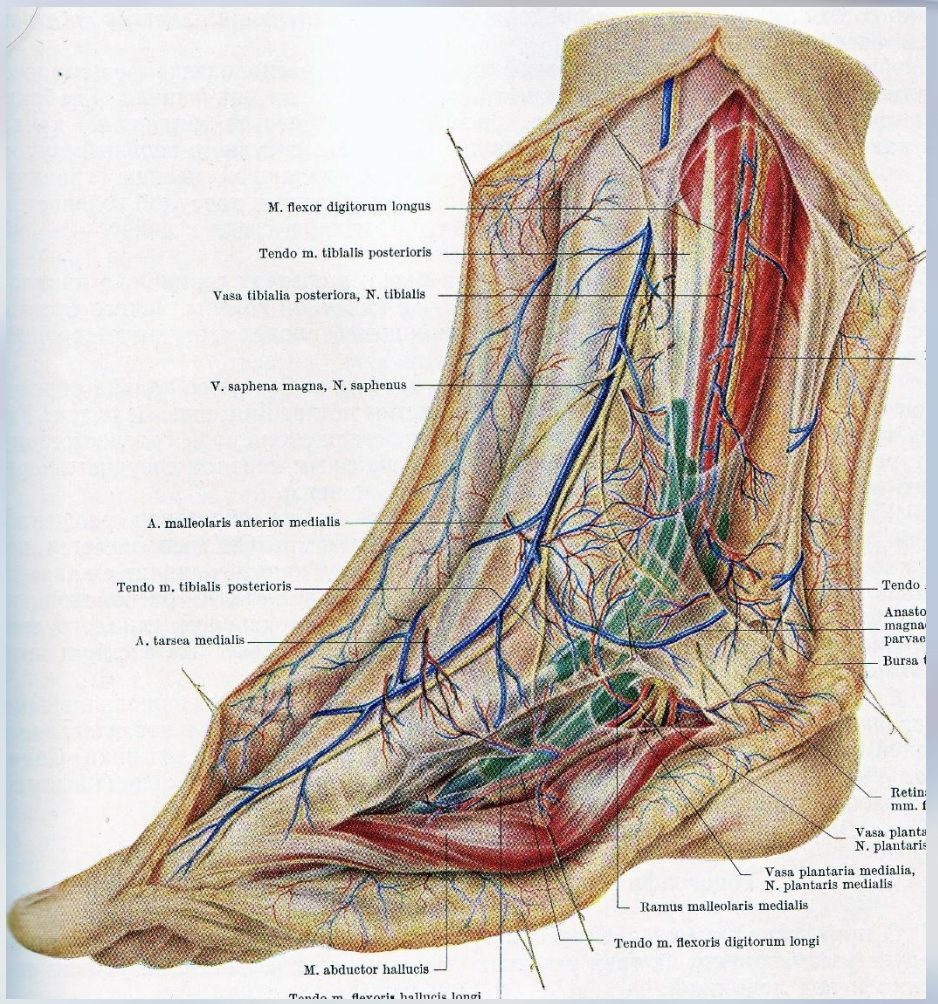
M. flexor digitorum longus
Tendo m. tibialis posterioris
Vasa tibialia posteriora, N. tibialis
V. saphena magna, N. saphenus
A. malleolaris anterior medialis
Tendo m. tibialis posterioris
A. tarsea medialis
Vasa plantaria medialia,
N. plantaris medialis
Ramus malleolaris medialis
Tendo m. flexoris digitorum longi
M. abductor hallucis

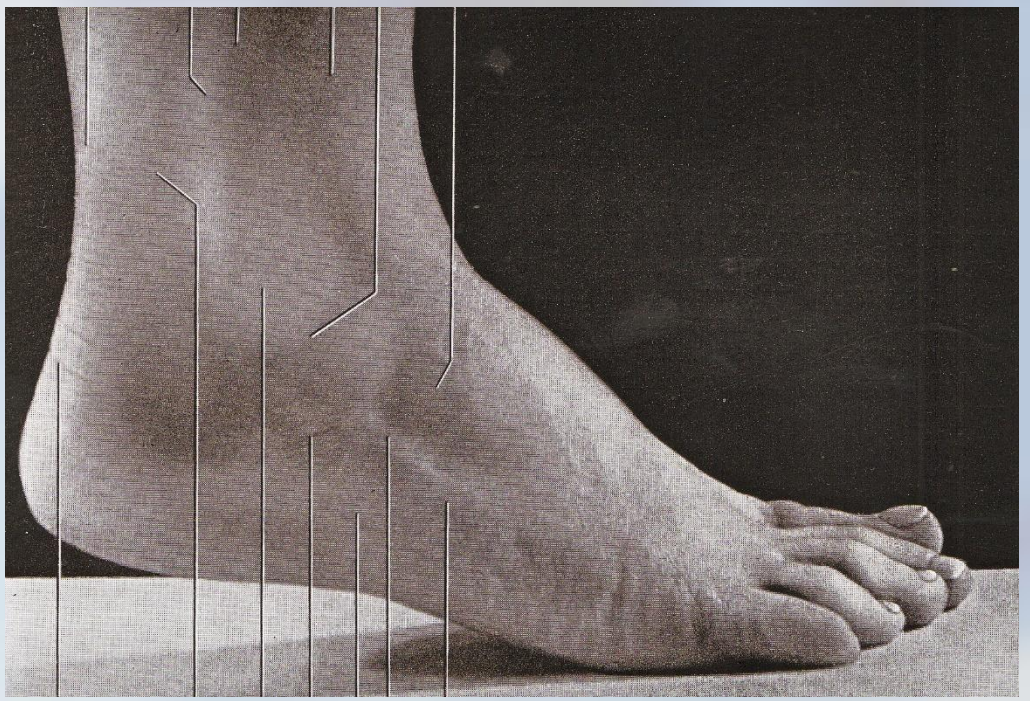

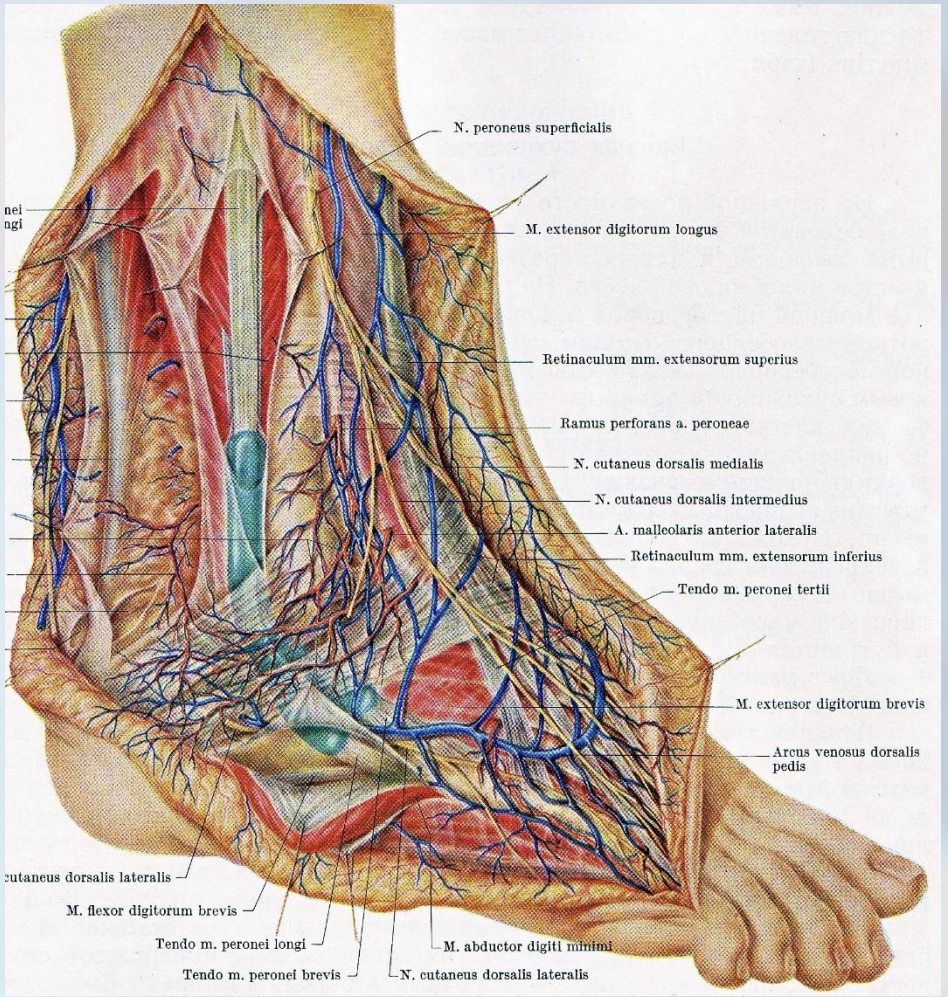
N. peroneus superficialis
nei
ngi
M. extensor digitorum longus
Retinaculum mm. extensorum superius
Ramus perforans a. peroneae
N. cutaneus dorsalis medialis
N. cutaneus dorsalis intermedius
A. malleolaris anterior lateralis
Retinaculum mm. extensorum inferius
Tendo m. peronei tertii
M. extensor digitorum brevis
Arcus venosus dorsalis pedis
cutaneus dorsalis lateralis
M. flexor digitorum brevis
Tendo m. peronei longi
Tendo m. peronei brevis
M. abductor digiti minimi
N. cutaneus dorsalis lateralis

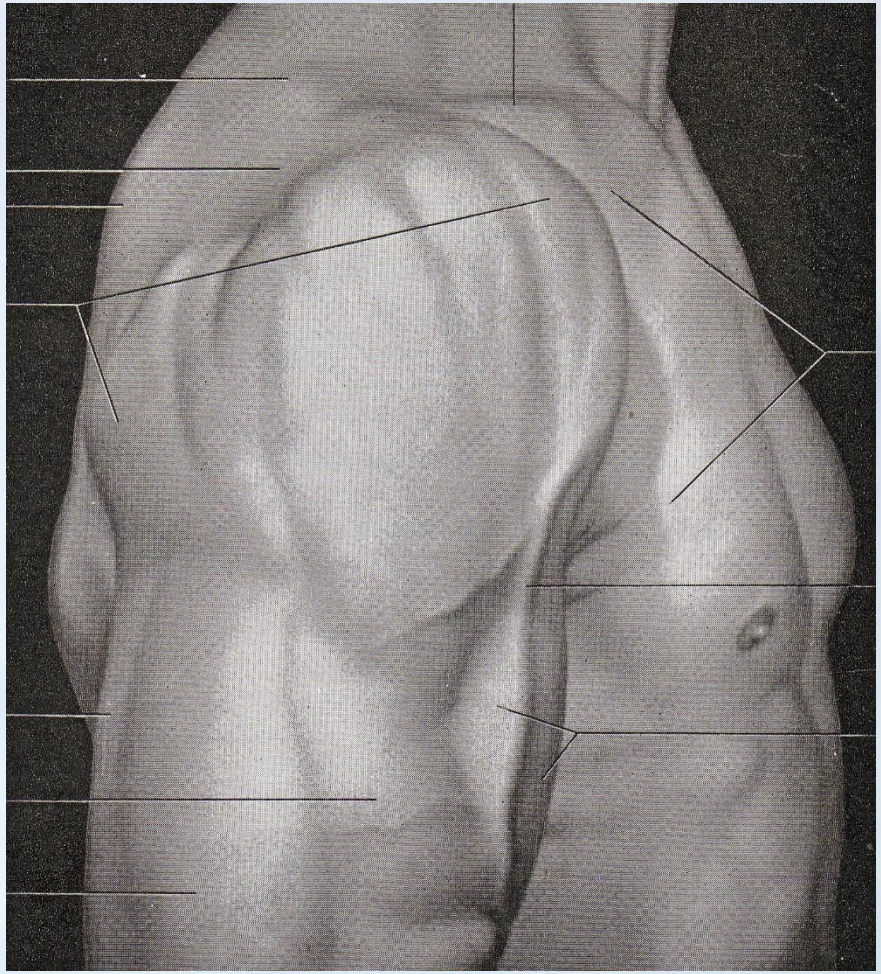

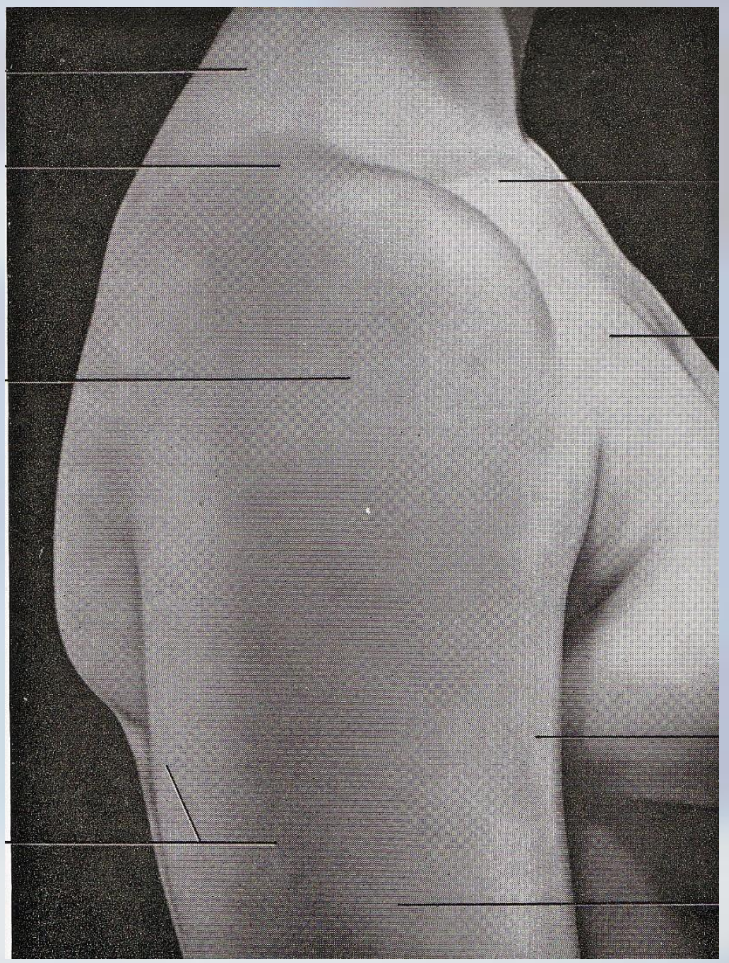

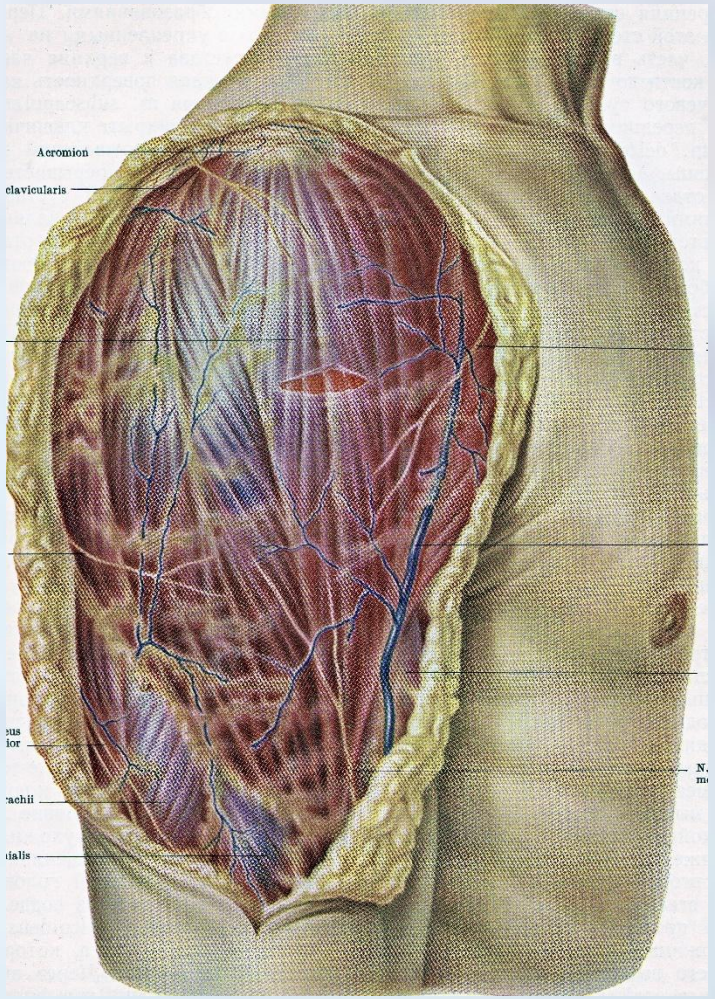
Acromion
clavicularis

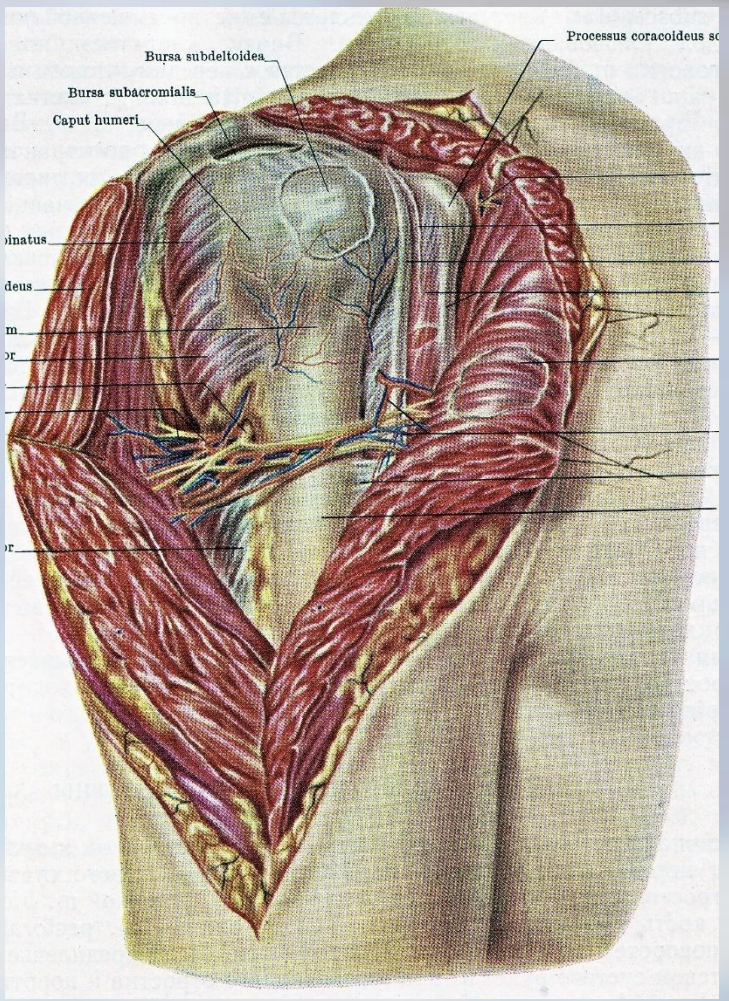
Processus coracoideus sc
Bursa subdeltoidea
Bursa subacromialis
Caput humeri

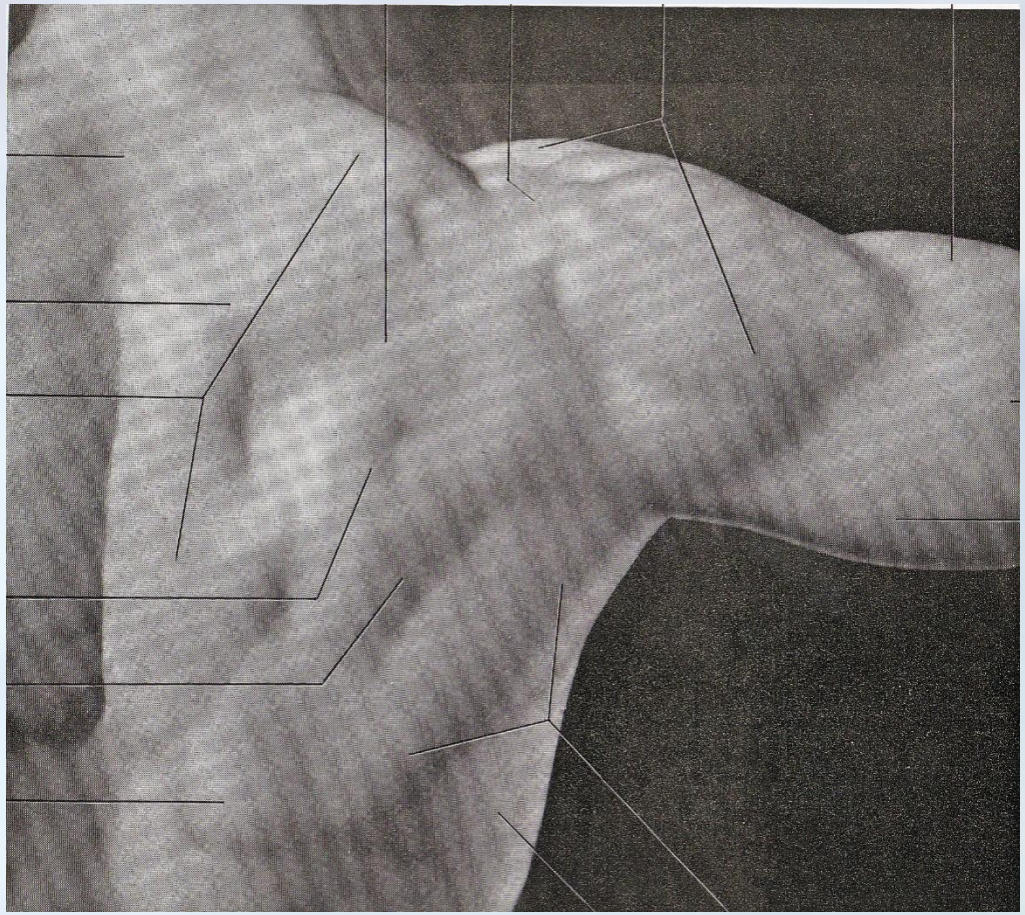

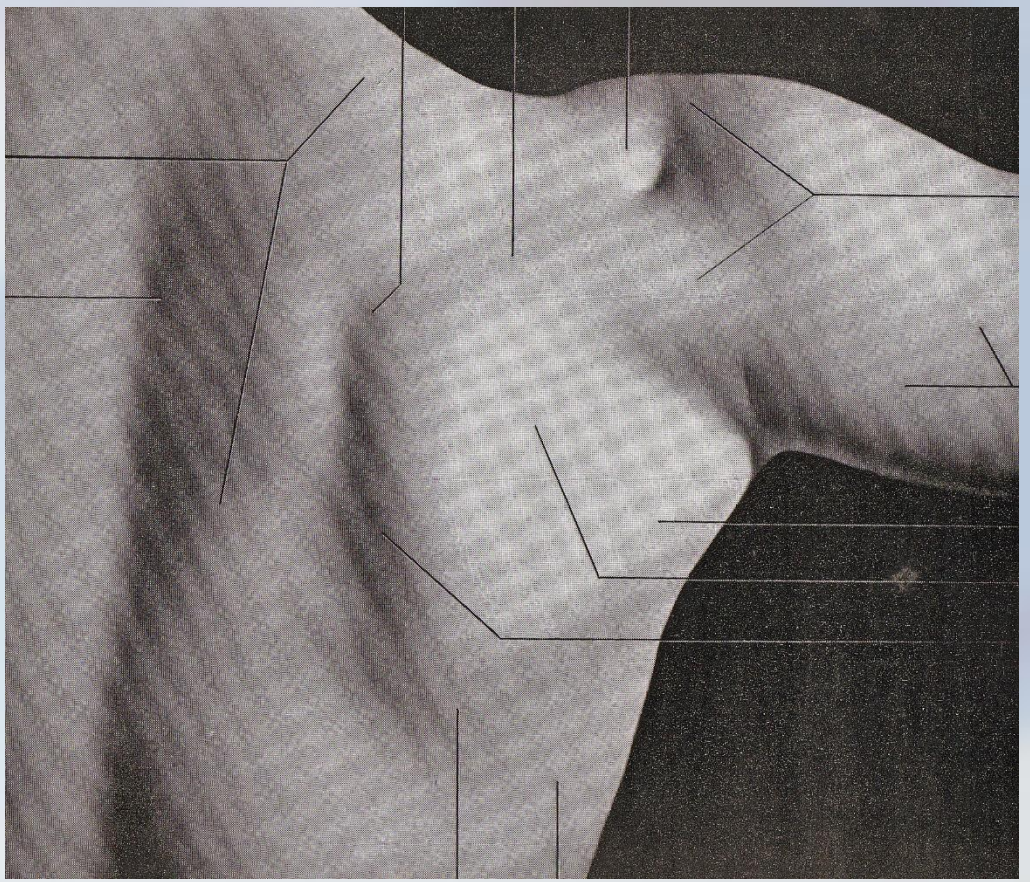

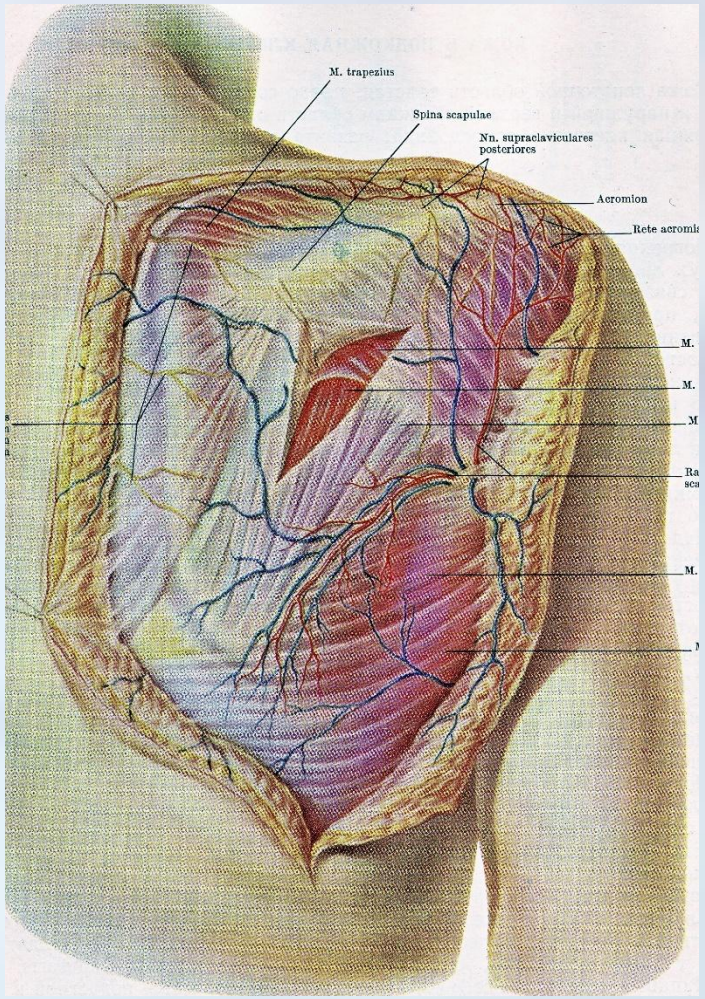
M. trapezius
Spina scapulae
Nn. supraclaviculares posteriores
Acromion
Rete acromi
M.
M.
M
Ra
sca
M.

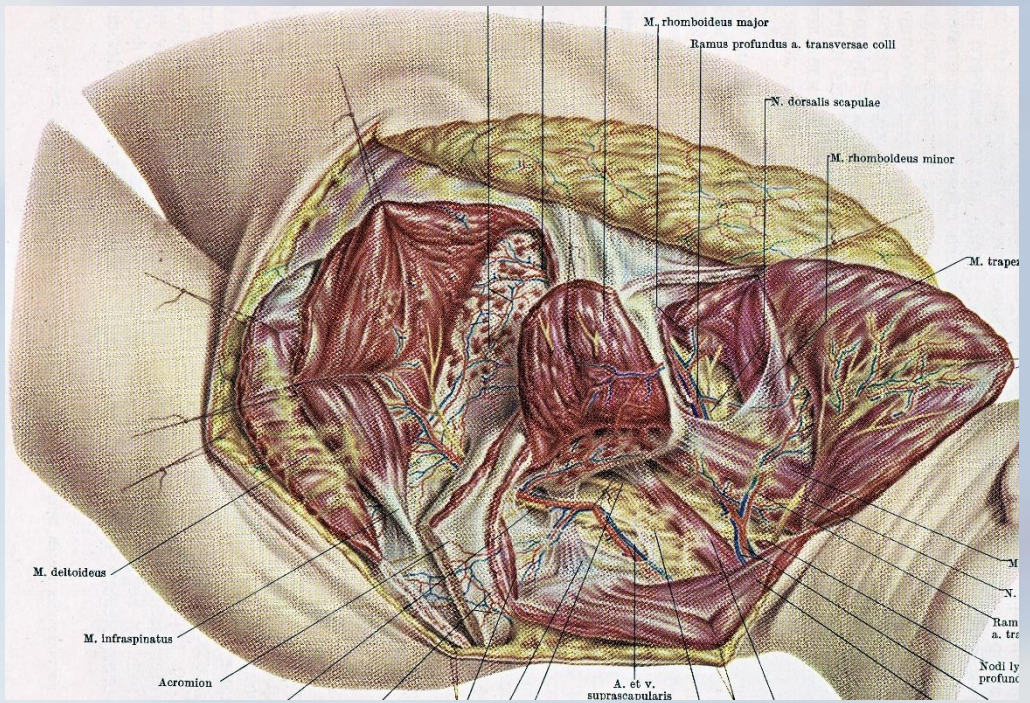
M. rhomboideus major
Ramus profundus a. transversae colli
N. dorsalis scapulae
M. rhomboideus minor
M. trapez
M. deltoideus
M. infraspinatus
Acromion
A. et v. suprascapularis
M
N.
Ram
a. tra
Nodi ly
profund

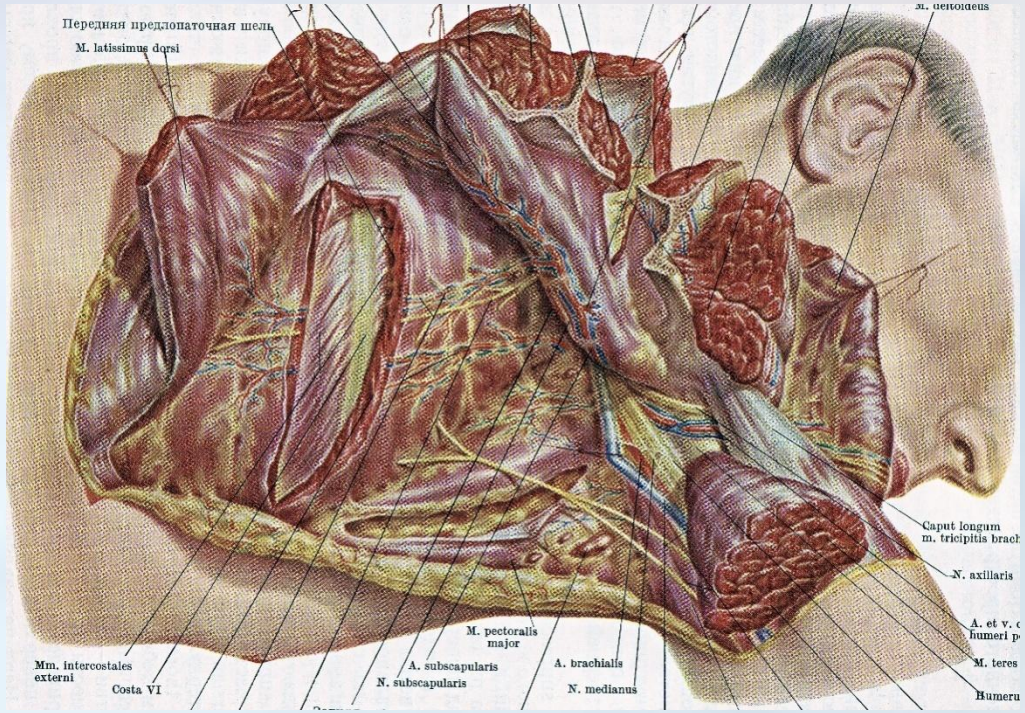
Передняя предлопаточная щель
M. latissimus dorsi
Mm. intercostales externi
Costa VI
N. subscapularis
A. subscapularis
M. pectoralis major
A. brachialis
N. medianus
Caput longum m. tricipitis brach
N. axillaris
M. teres

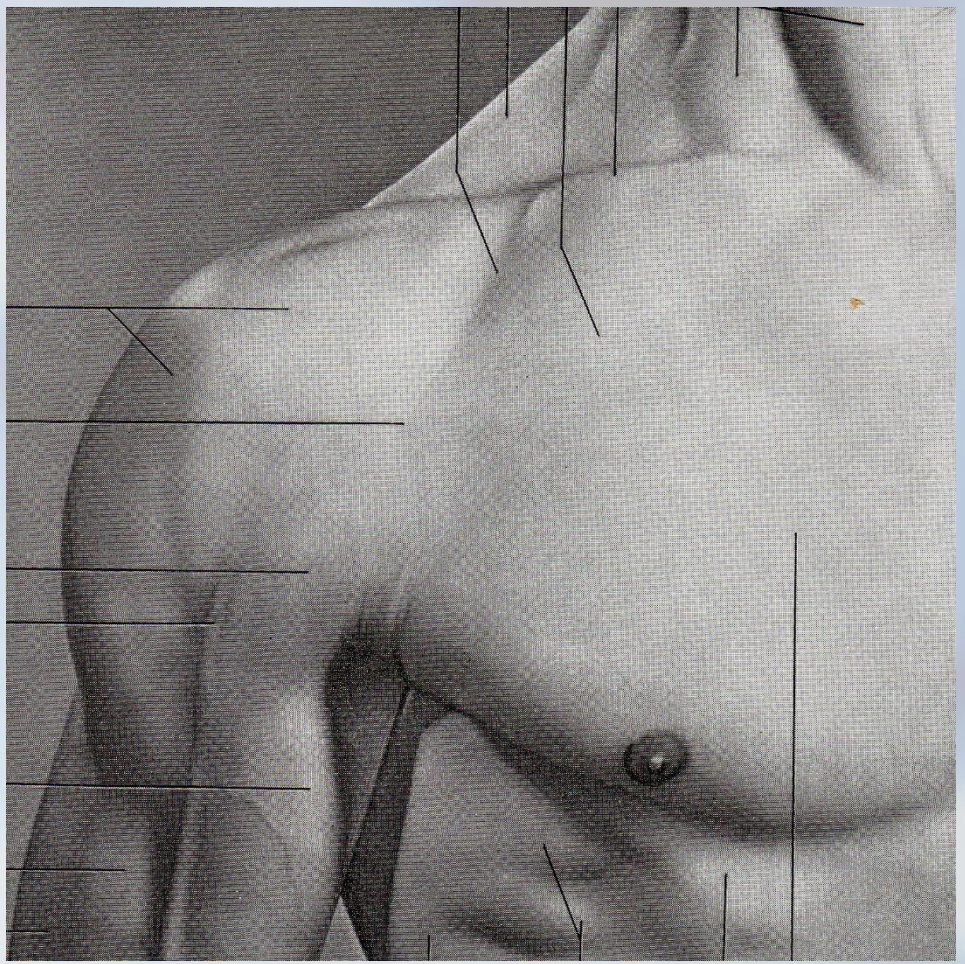

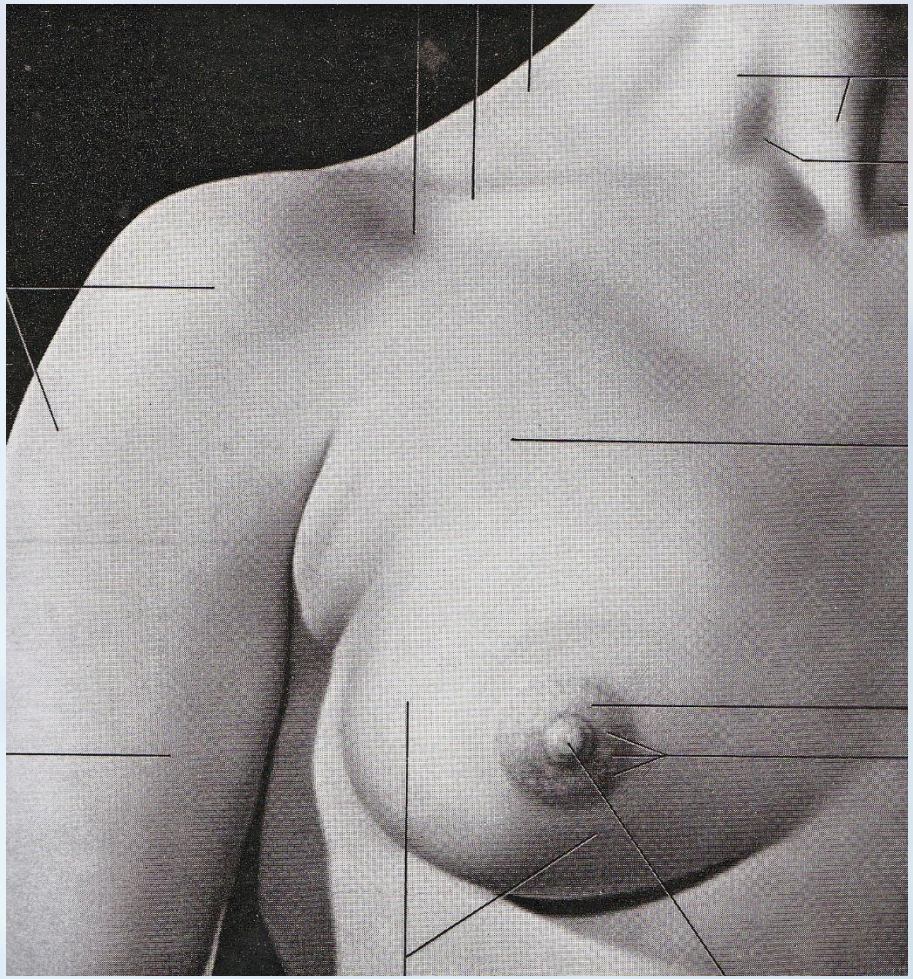

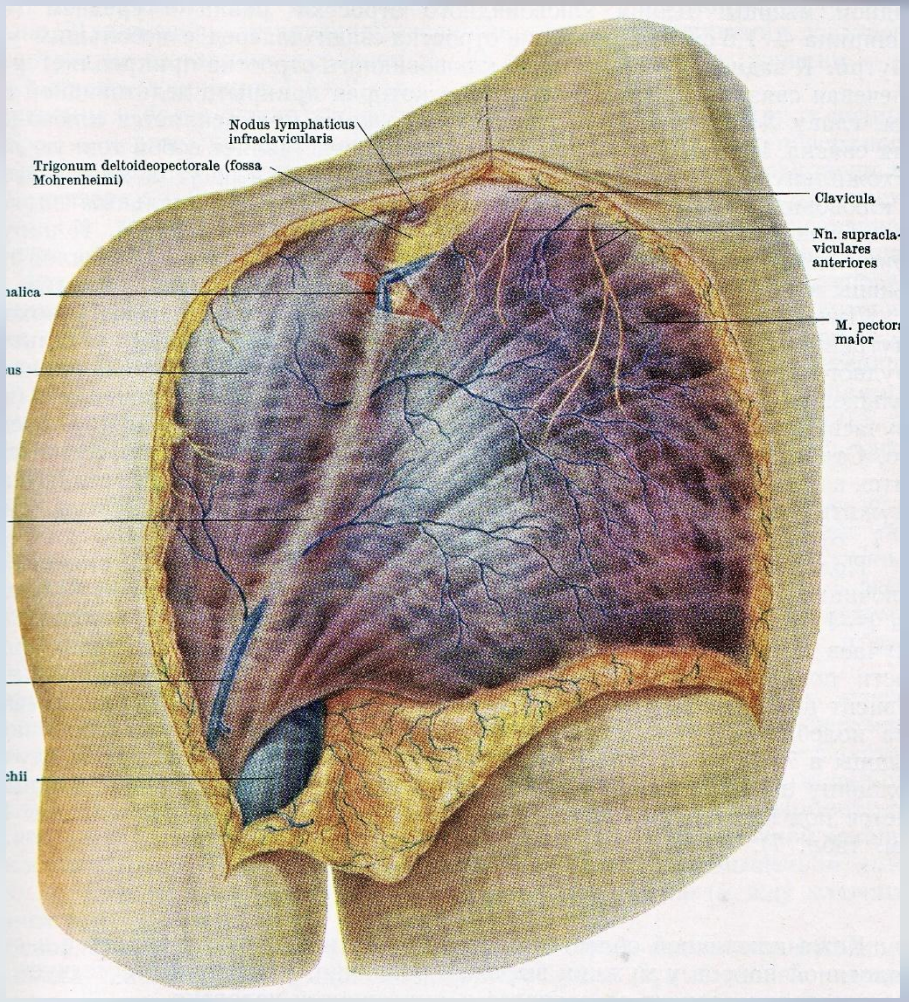
Nodus lymphaticus infraclavicularis
Trigonum deltoideopectorale (fossa Mohrenheimi)
Clavicula
Nn. supracla-viculares anteriores
M. pectora major

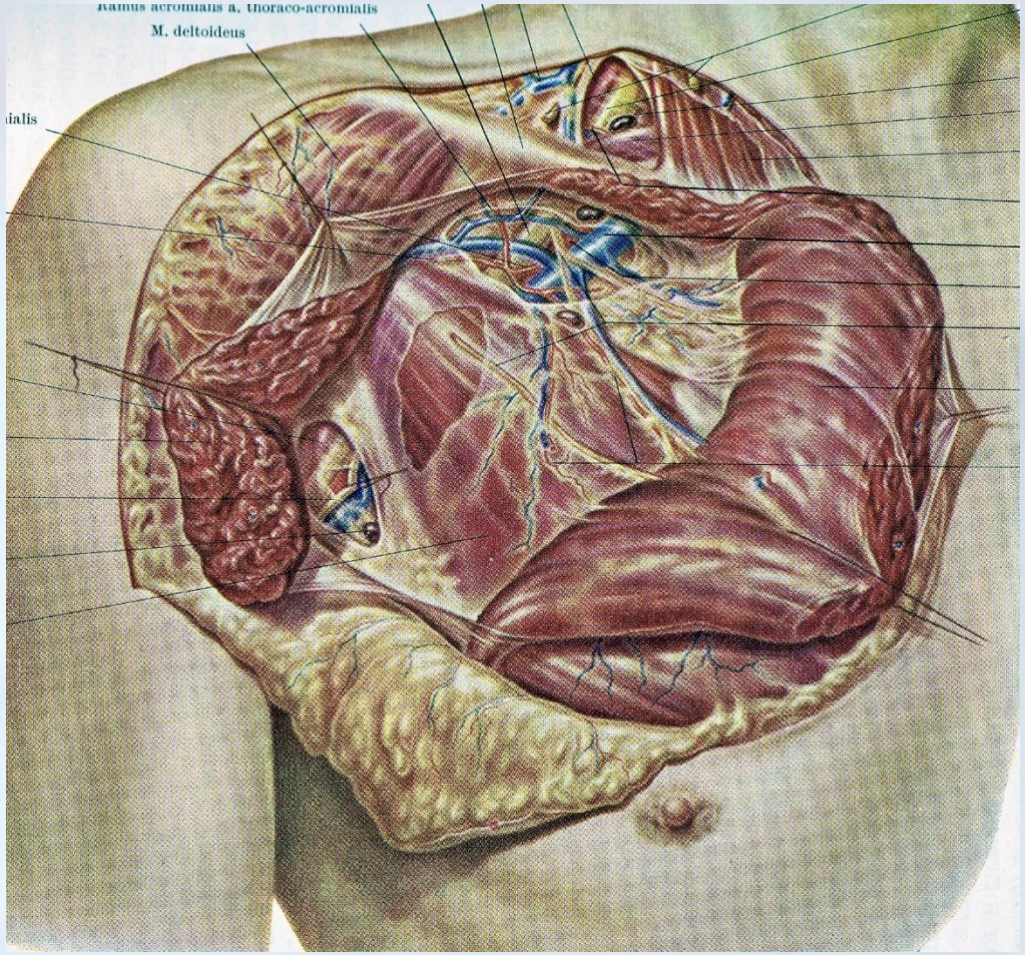
Ramus acromialis a. thoraco-acromialis
M. deltoideus

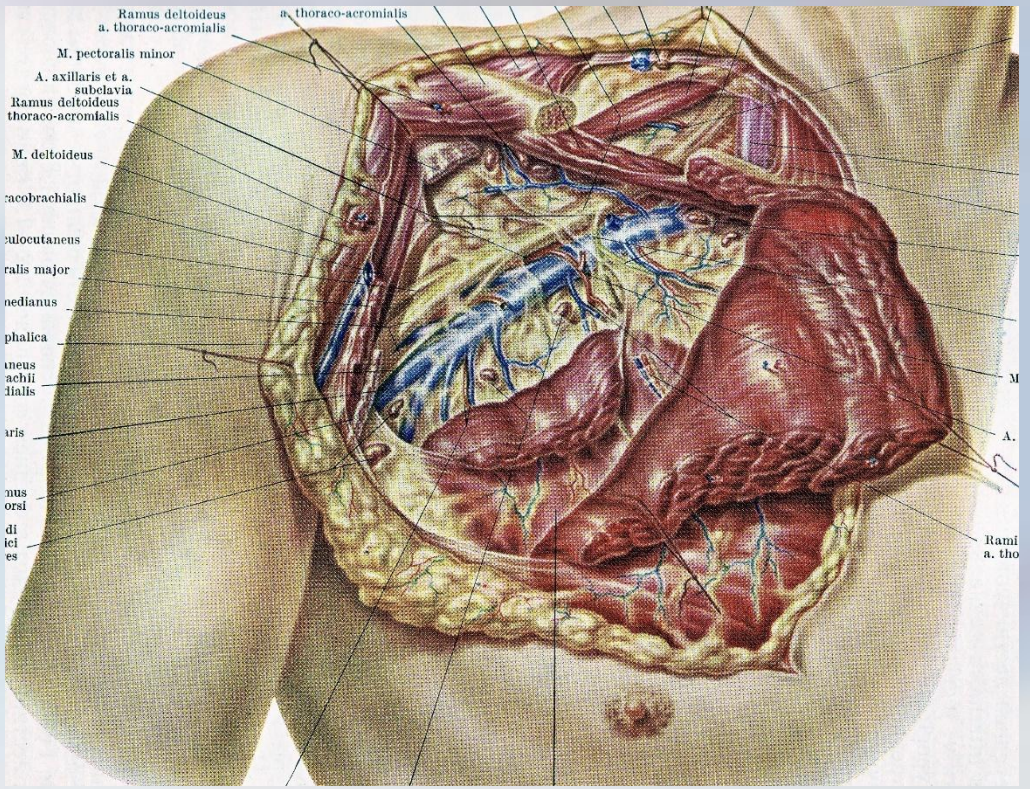
Ramus deltoideus
a. thoraco-acromialis
a. thoraco-acromialis
M. pectoralis minor
A. axillaris et a.
subclavia
Ramus deltoideus
thoraco-acromialis
M. deltoideus

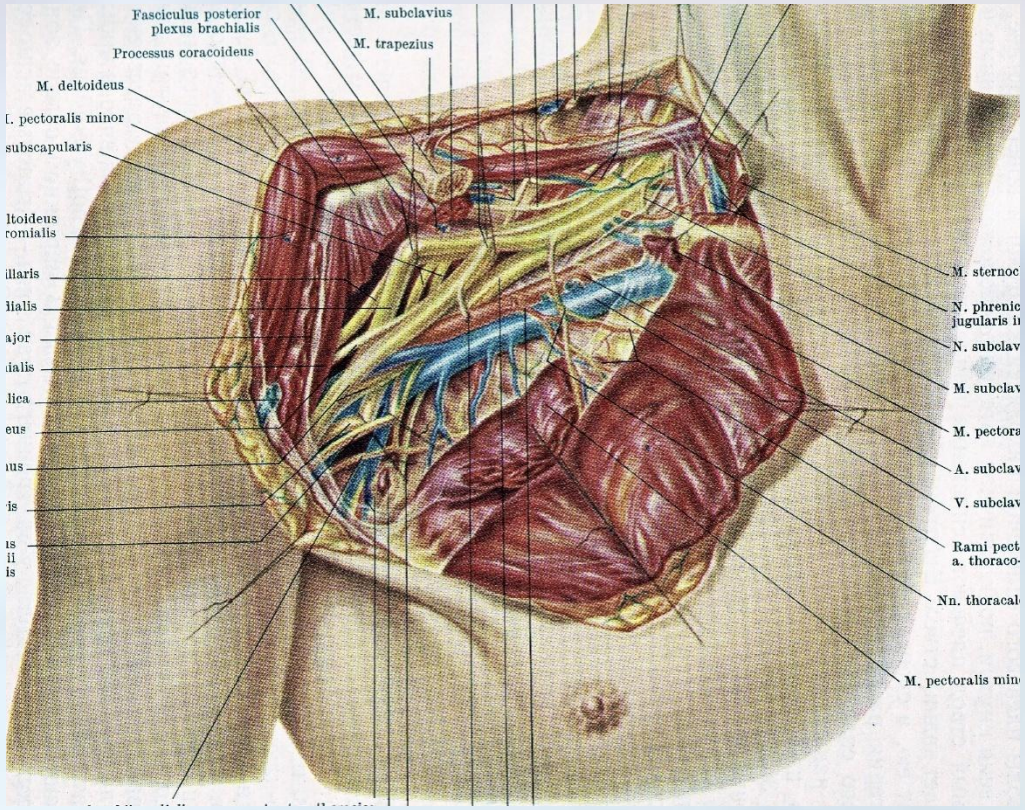
Fasciculus posterior plexus brachialis
M. subclavius
M. trapezius
Processus coracoideus
M. deltoideus
I. pectoralis minor
subscapularis
ltoideus
romialis
illaris
lialis
ajor
ialis
lica
eus
ius
is
is
ii
is
M. sternoc
N. phrenic
jugularis i
N. subclav
M. subclav
M. pectora
A. subclav
V. subclav
Rami pect
a. thoraco-
Nn. thoracal
M. pectoralis min

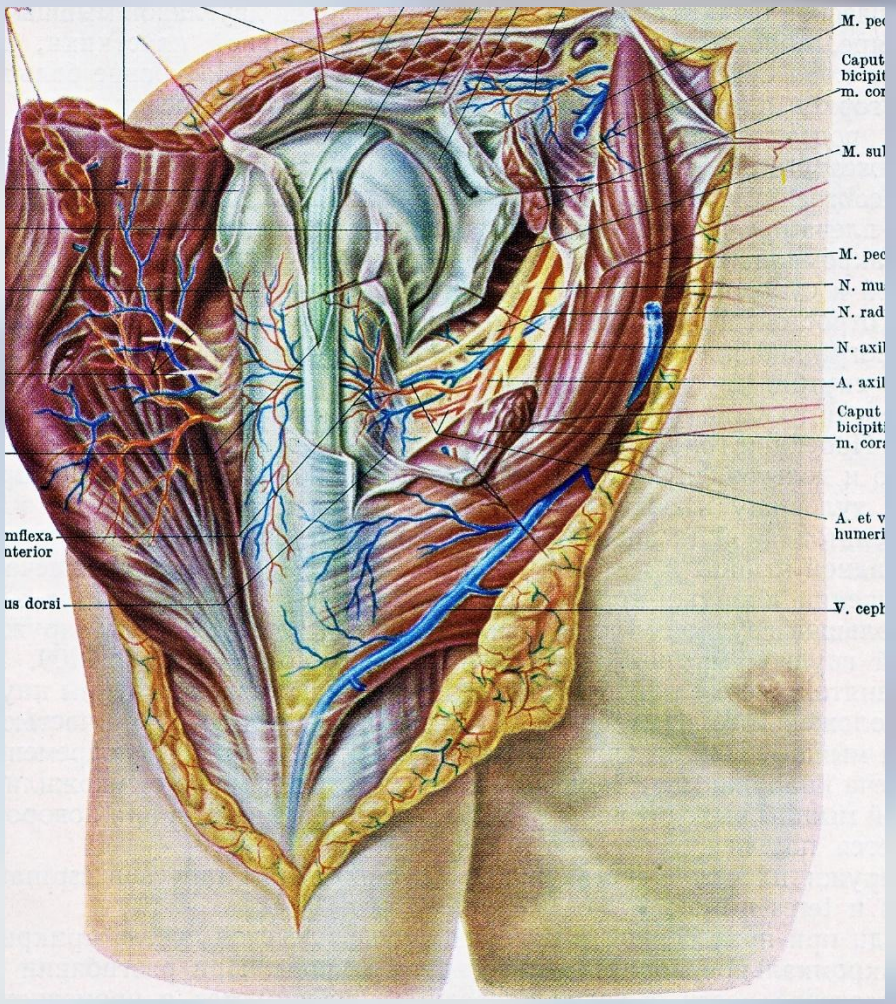
M. pec
Caput
bicipit
m. cor
M. sul
M. pec
N. mu
N. rad
N. axil
A. axil
Caput
bicipit
m. cora
A. et v
humeri
mflexa
nterior
us dorsi
V. ceph

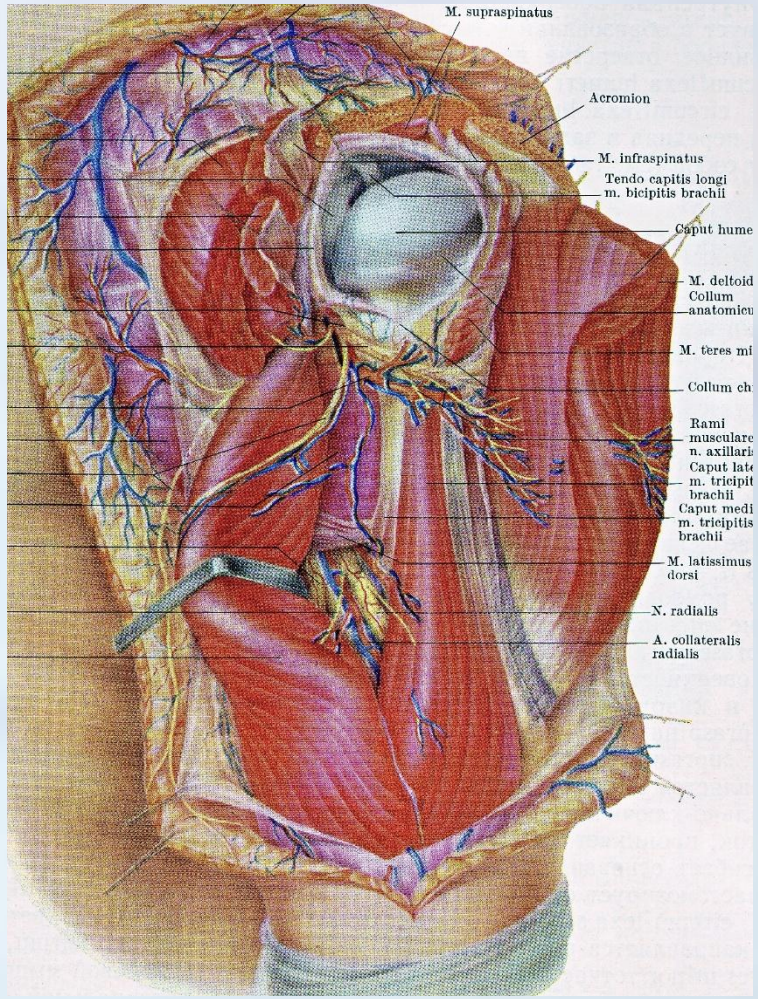
M. supraspinatus
Acromion
M. infraspinatus
Tendo capitis longi
m. bicipitis brachii
Caput hume
M. deltoid
Collum
anatomicu
M. teres mi
Collum ch
Rami
musculare
n. axillari
Caput lat
m. tricipit
brachii
Caput medi
m. tricipitis
brachii
M. latissimus
dorsi
N. radialis
A. collateralis
radialis

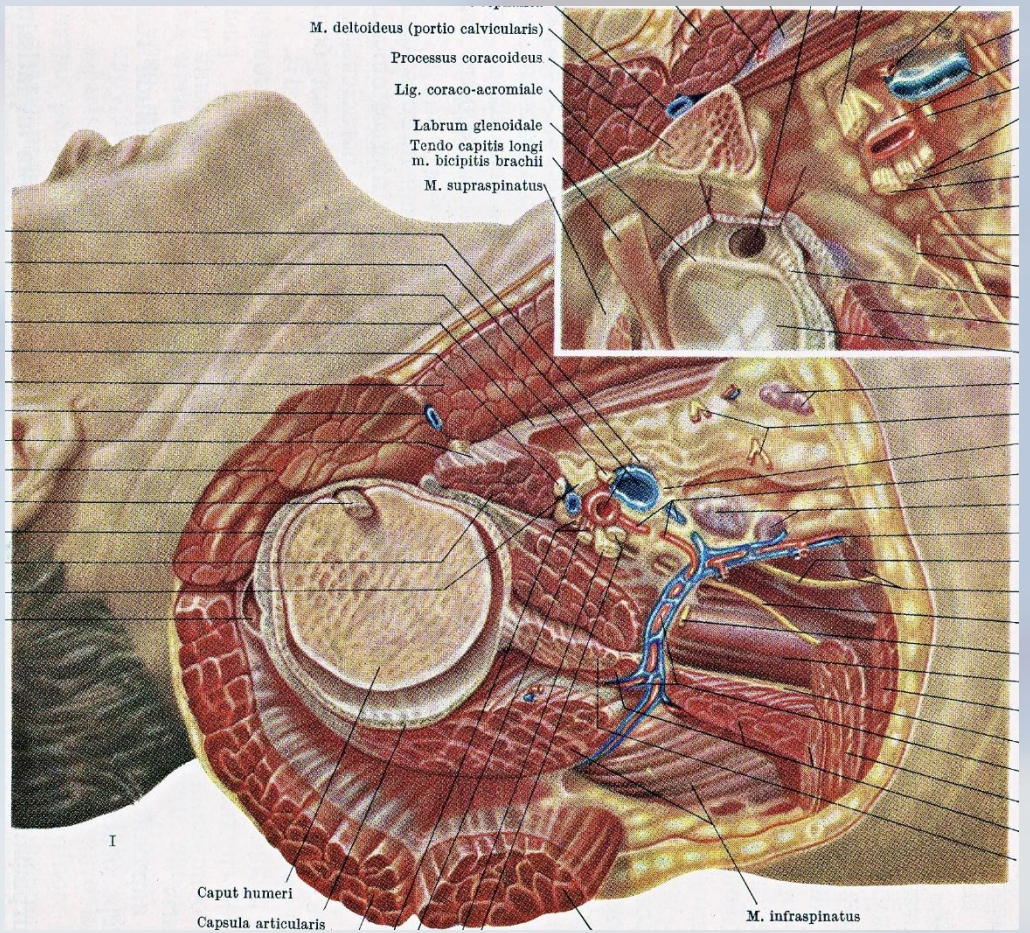
M. deltoideus (portio calvicularis)
Processus coracoideus
Lig. coraco-acromiale
Labrum glenoidale
Tendo capitis longi
m. bicipitis brachii
M. supraspinatus
I
Caput humeri
Capsula articularis
M. infraspinatus

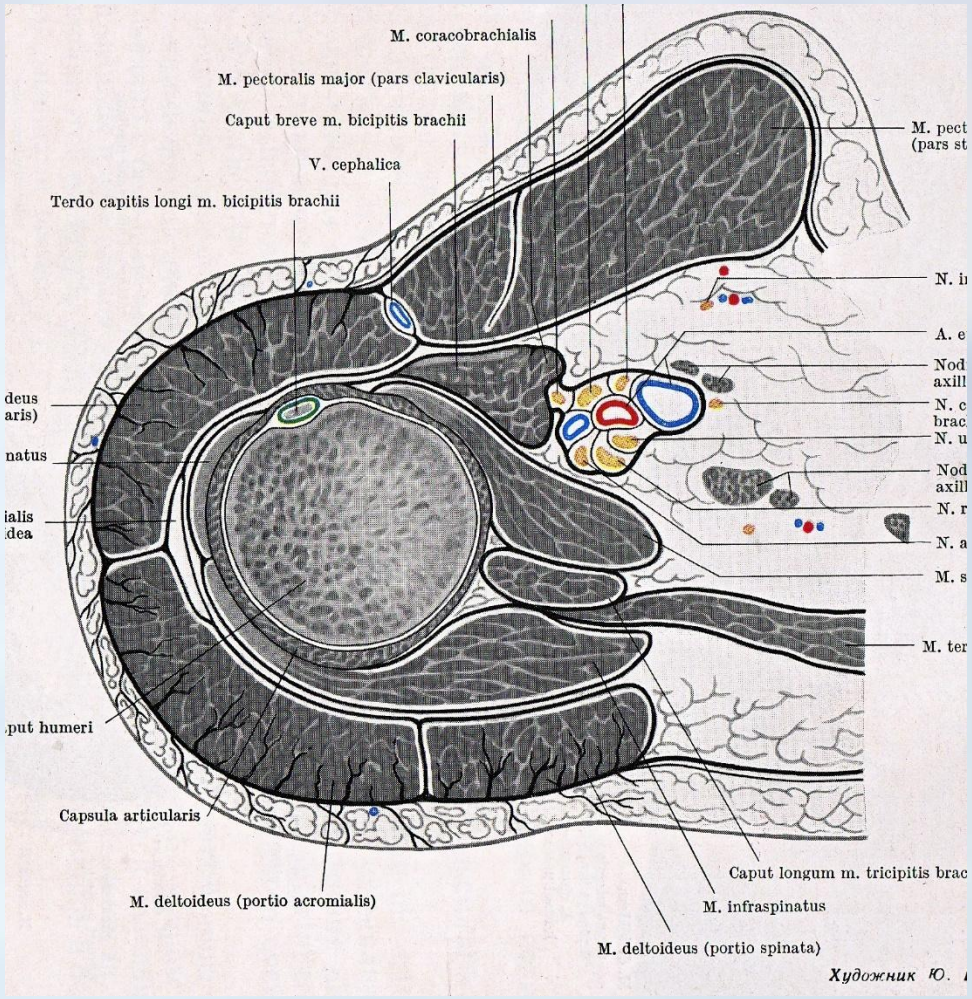
M. coracobrachialis
M. pectoralis major (pars clavicularis)
Caput breve m. bicipitis brachii
V. cephalica
Terdo capitis longi m. bicipitis brachii
M. pect
(pars st
N. i
A. e
Nod
axill
N. c
brac
N. u
Nod
axill
N. r
N. a
M. s
M. ter
deus
aris)
natus
ialis
idea
put humeri
Capsula articularis
M. deltoideus (portio acromialis)
Caput longum m. tricipitis brac
M. infraspinatus
M. deltoideus (portio spinata)
Художник Ю.

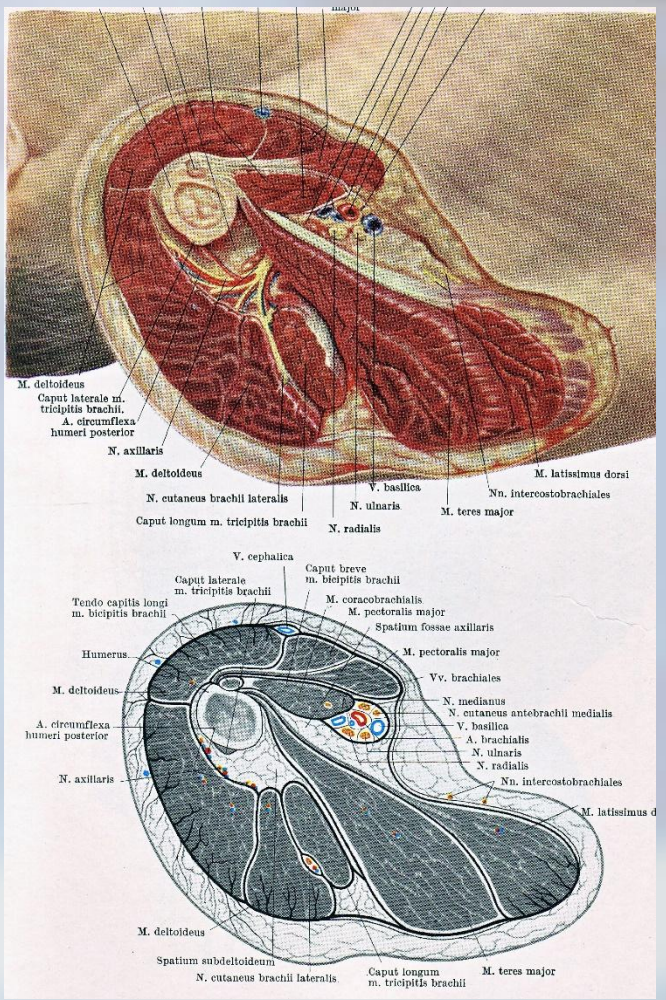
M. deltoideus
Caput laterale m. tricipitis brachii.
A. circumflexa humeri posterior
N. axillaris
M. deltoideus
N. cutaneus brachii lateralis
Caput longum m. tricipitis brachii
N. radialis
N. ulnaris
V. basilica
M. teres major
Nn. intercostobrachiales
M. latissimus dorsi
V. cephalica
Caput breve m. bicipitis brachii
Caput laterale m. tricipitis brachii
Tendo capitis longi m. bicipitis brachii
M. coracobrachialis
M. pectoralis major
Spatium fossae axillaris
Humerus
M. pectoralis major
Vv. brachiales
M. deltoideus
N. medianus
N. cutaneus antebrachii medialis
A. circumflexa humeri posterior
V. basilica
A. brachialis
N. ulnaris
N. radialis
N. axillaris
Nn. intercostobrachiales
M. latissimus d
M. deltoideus
Spatium subdeltoideum
N. cutaneus brachii lateralis
Caput longum m. tricipitis brachii
M. teres major

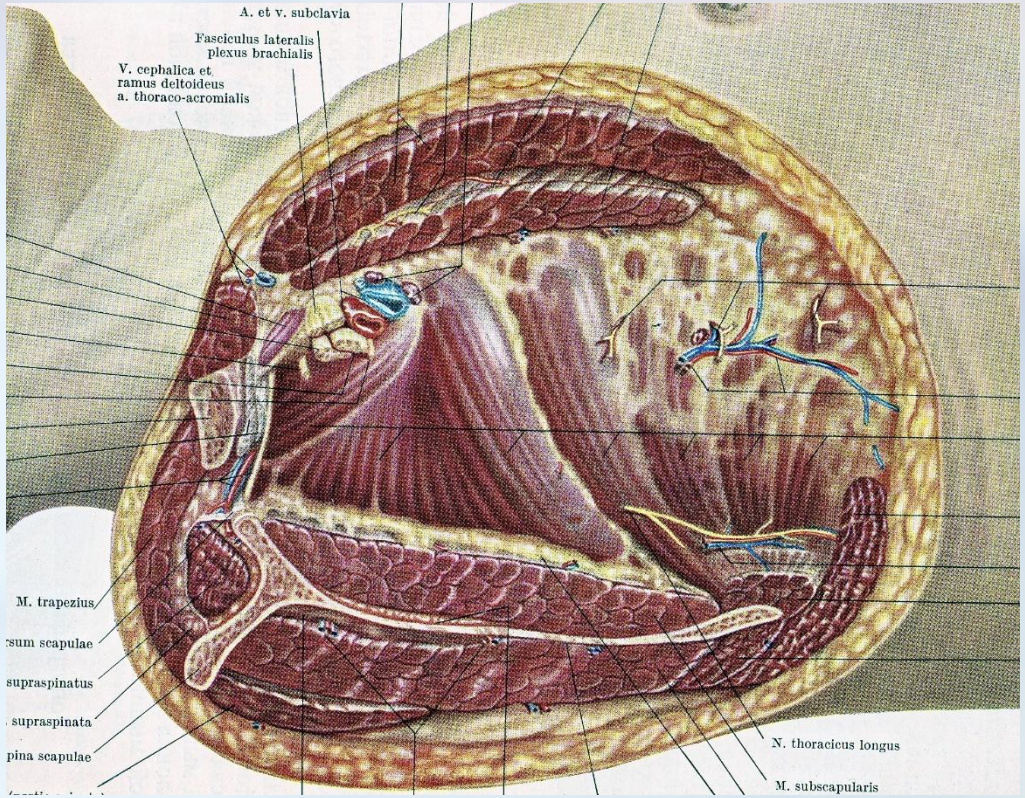
A. et v. subclavia
Fasciculus lateralis plexus brachialis
V. cephalica et ramus deltoideus a. thoraco-acromialis
M. trapezius
rsum scapulae
supraspinatus
supraspinata
pina scapulae
N. thoracicus longus
M. subscapularis

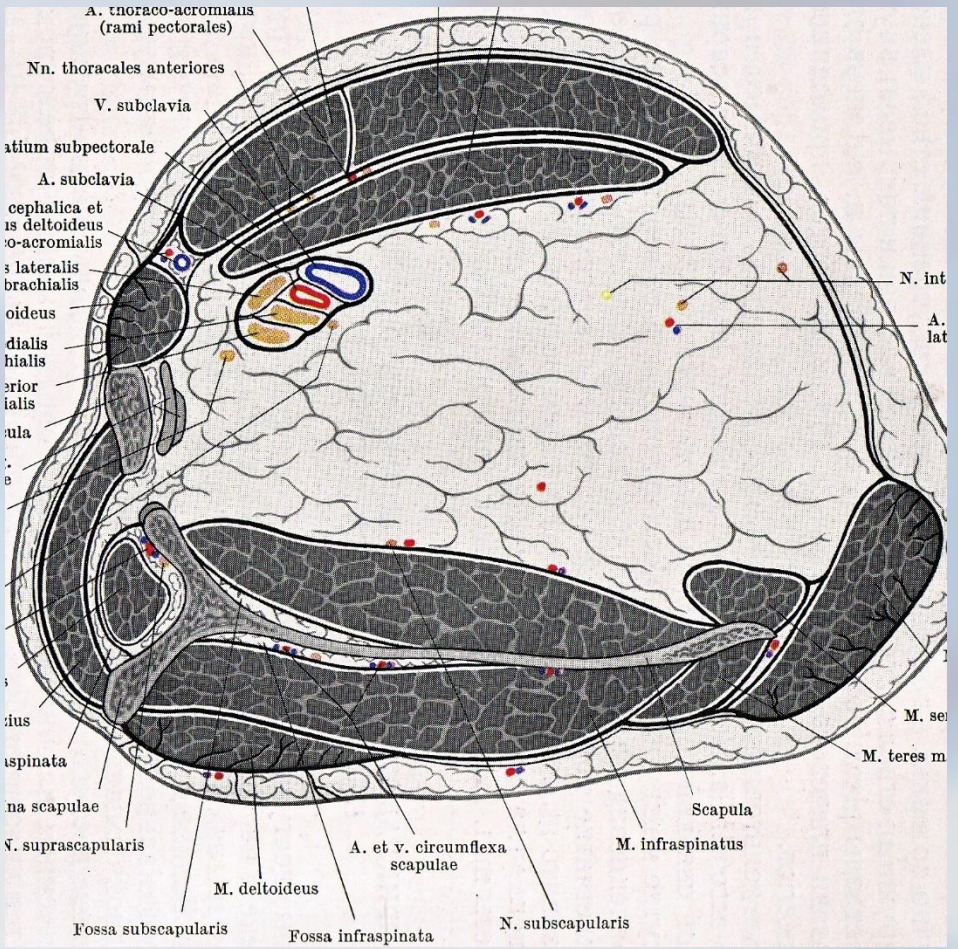
A. thoraco-acromialis (rami pectorales)
Nn. thoracales anteriores
V. subclavia
atium subpectorale
A. subclavia
cephalica et
ıs deltoideus
o-acromialis
s lateralis
brachialis
oideus
dialis
hialis
erior
ialis
ula
zius
aspinata
na scapulae
N. suprascapularis
N. int
A.
lat
M. se
M. teres m
Scapula
M. infraspinatus
A. et v. circumflexa scapulae
M. deltoideus
Fossa subscapularis
Fossa infraspinata
N. subscapularis

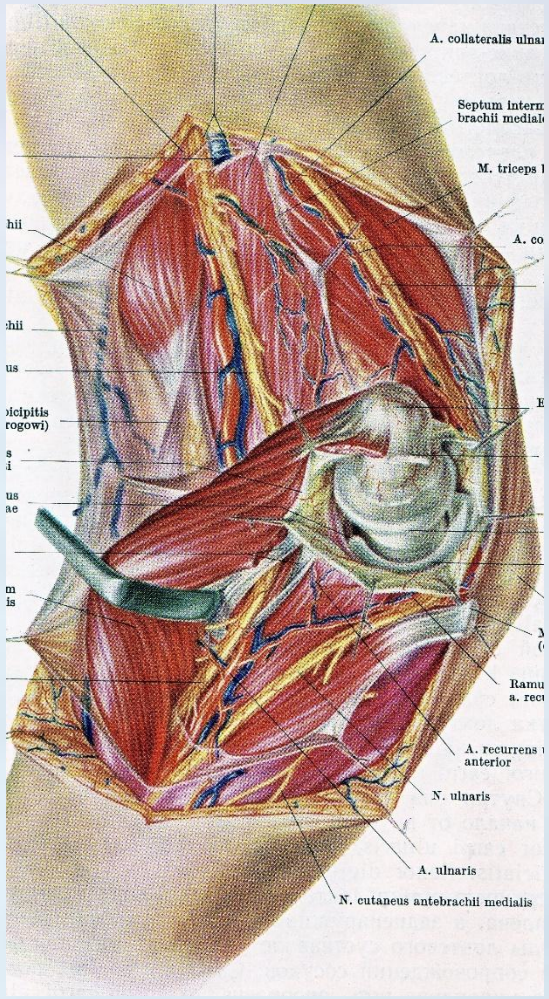
A. collateralis ulnar
Septum intern
brachii medial
M. triceps
A. co
Ramu
a. recu
A. recurrens
anterior
N. ulnaris
A. ulnaris
N. cutaneus antebrachii medialis

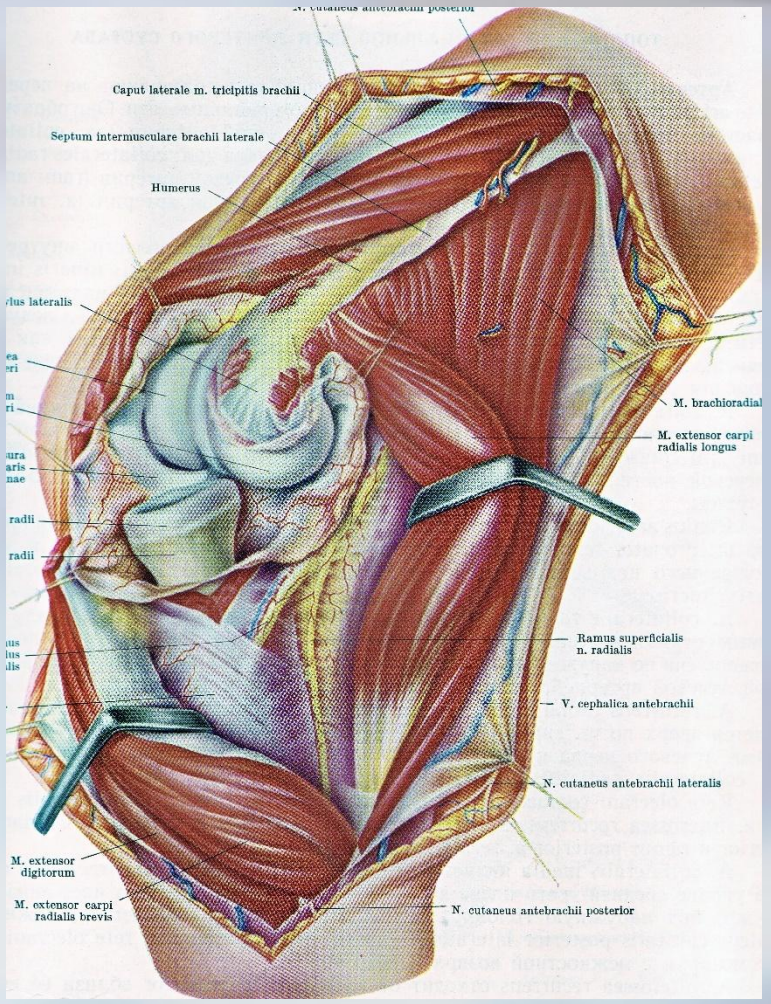
Caput laterale m. tricipitis brachii
Septum intermusculare brachii laterale
Humerus
M. brachioradial
M. extensor carpi
radialis longus
Ramus superficialis
n. radialis
V. cephalica antebrachii
N. cutaneus antebrachii lateralis
M. extensor
digitorum
M. extensor carpi
radialis brevis
N. cutaneus antebrachii posterior

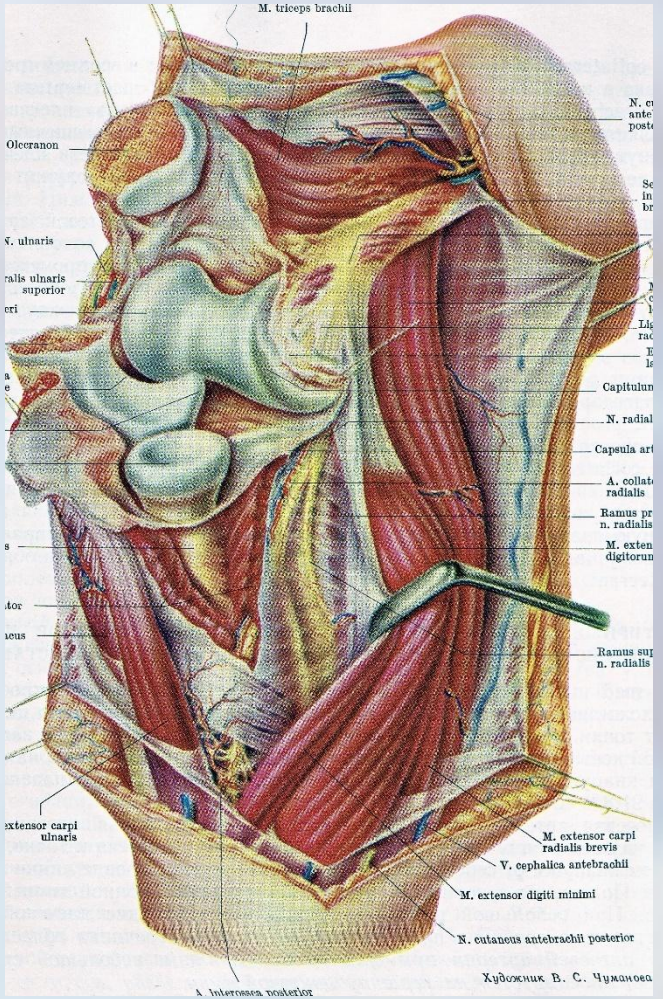
M. triceps brachii
Olecranon
N. ulnaris
superior
Capitulum
N. radial
Capsula art
A. collat
radialis
Ramus pr
n. radialis
M. exten
digitorum
Ramus sup
n. radialis
extensor carpi
ulnaris
M. extensor carpi
radialis brevis
V. cephalica antebrachii
M. extensor digiti minimi
N. cutaneus antebrachii posterior
Художник В. С. Чуманова