Введение в травматологию

Классификация переломов по этиологическому фактору:

- Травматические
- Нетравматические (патологические)

Классификация переломов в зависимости от повреждения кожных покровов:

1. Открытые
   - Первичнооткрытые
   - Вторичнооткрытые
2. Закрытые.
   - Неполные
   - Полные

По локализации

- Диафизарные
- Метафизарные
- Эпифизарные

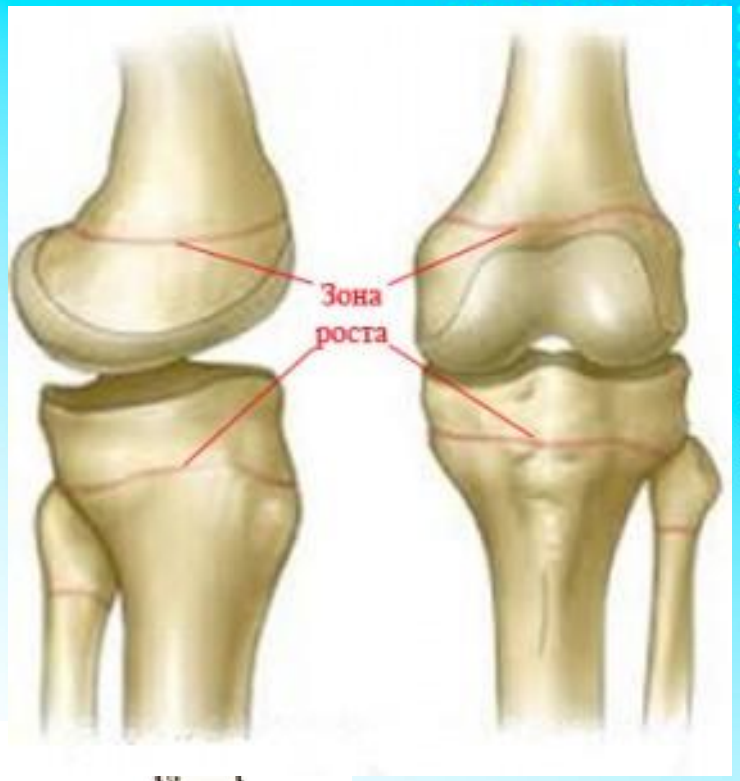

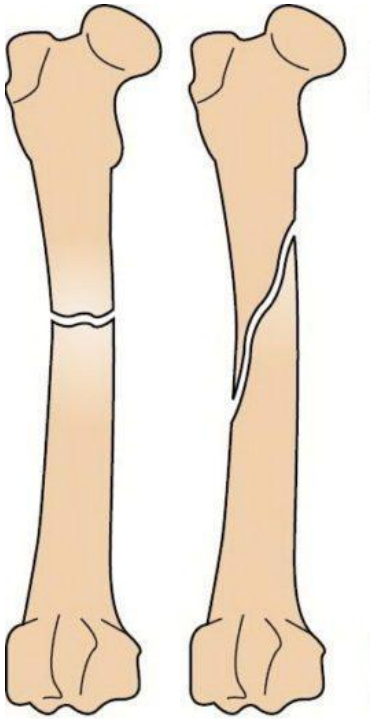

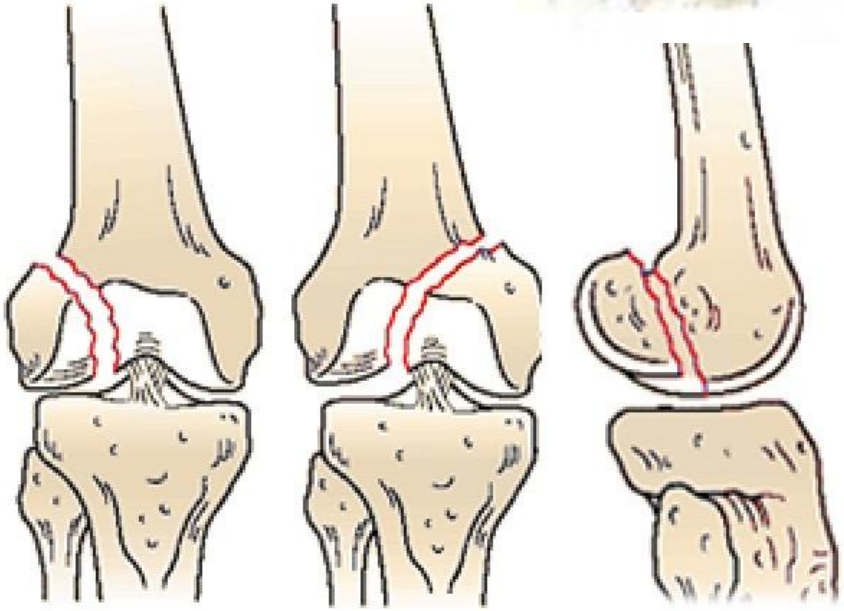

В зависимости от направления плоскости излома различают:

- Поперечные
- Косые
- Винтообразные
- Продольные
- Многооскольчатые

Виды смещения

- По длине
- По ширине
- Под углом
- Ротационные

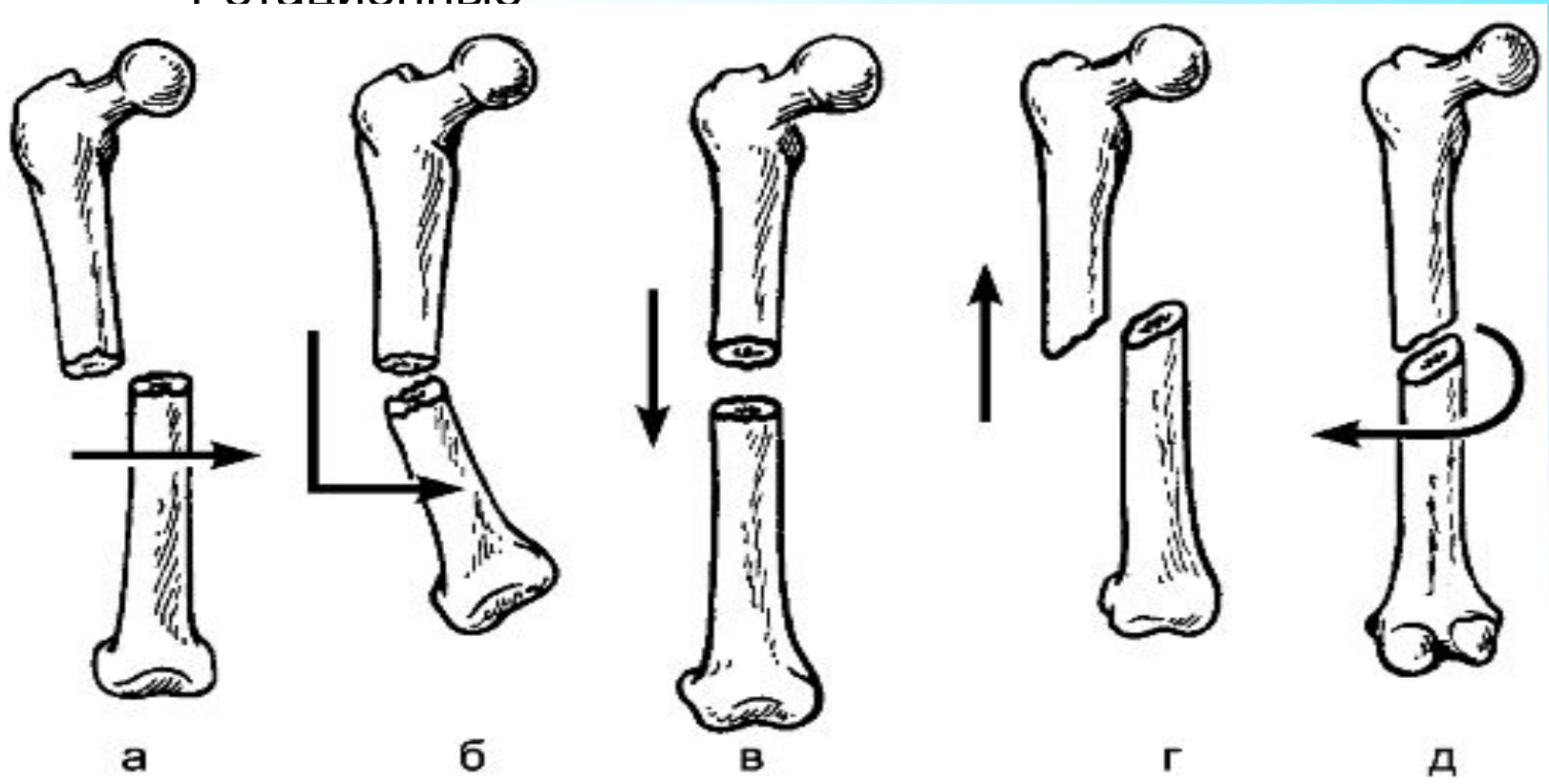

Классификация АО

32-B1

32-

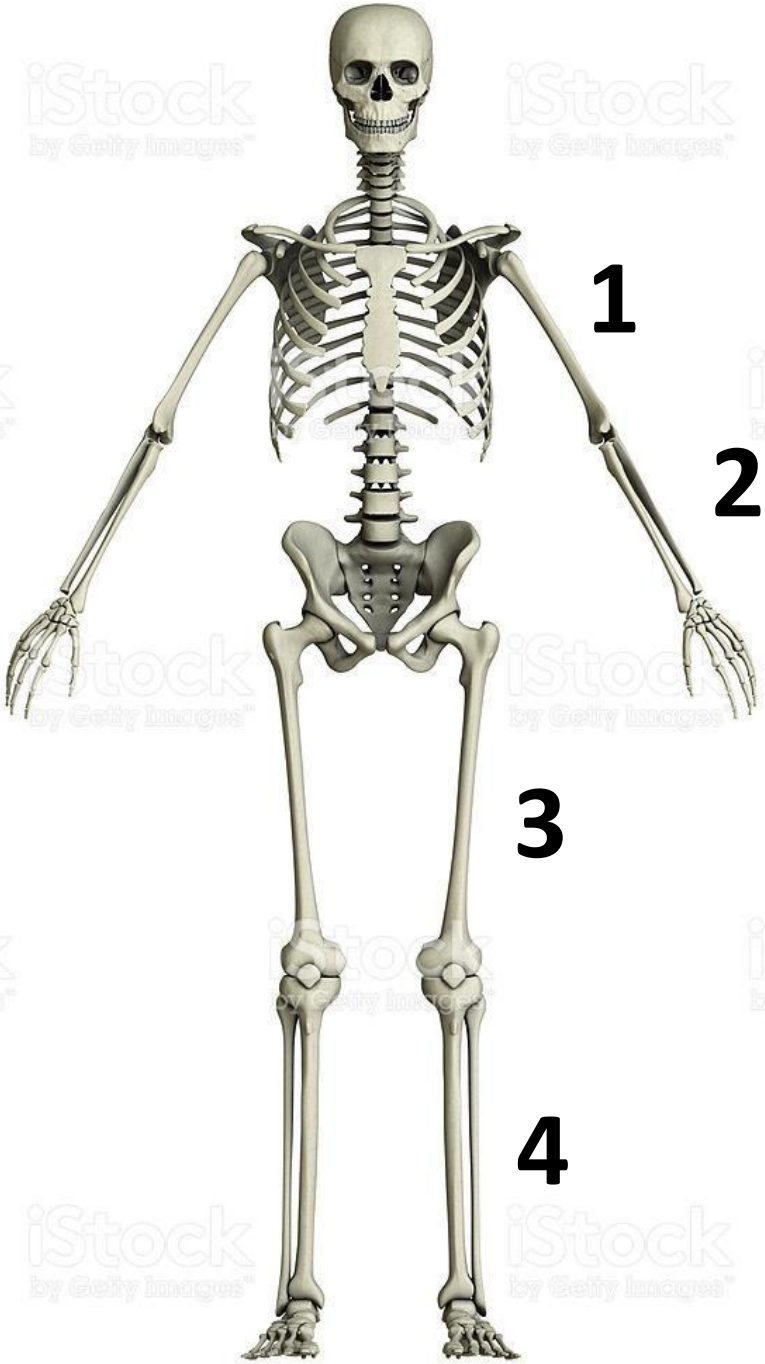

32-B1

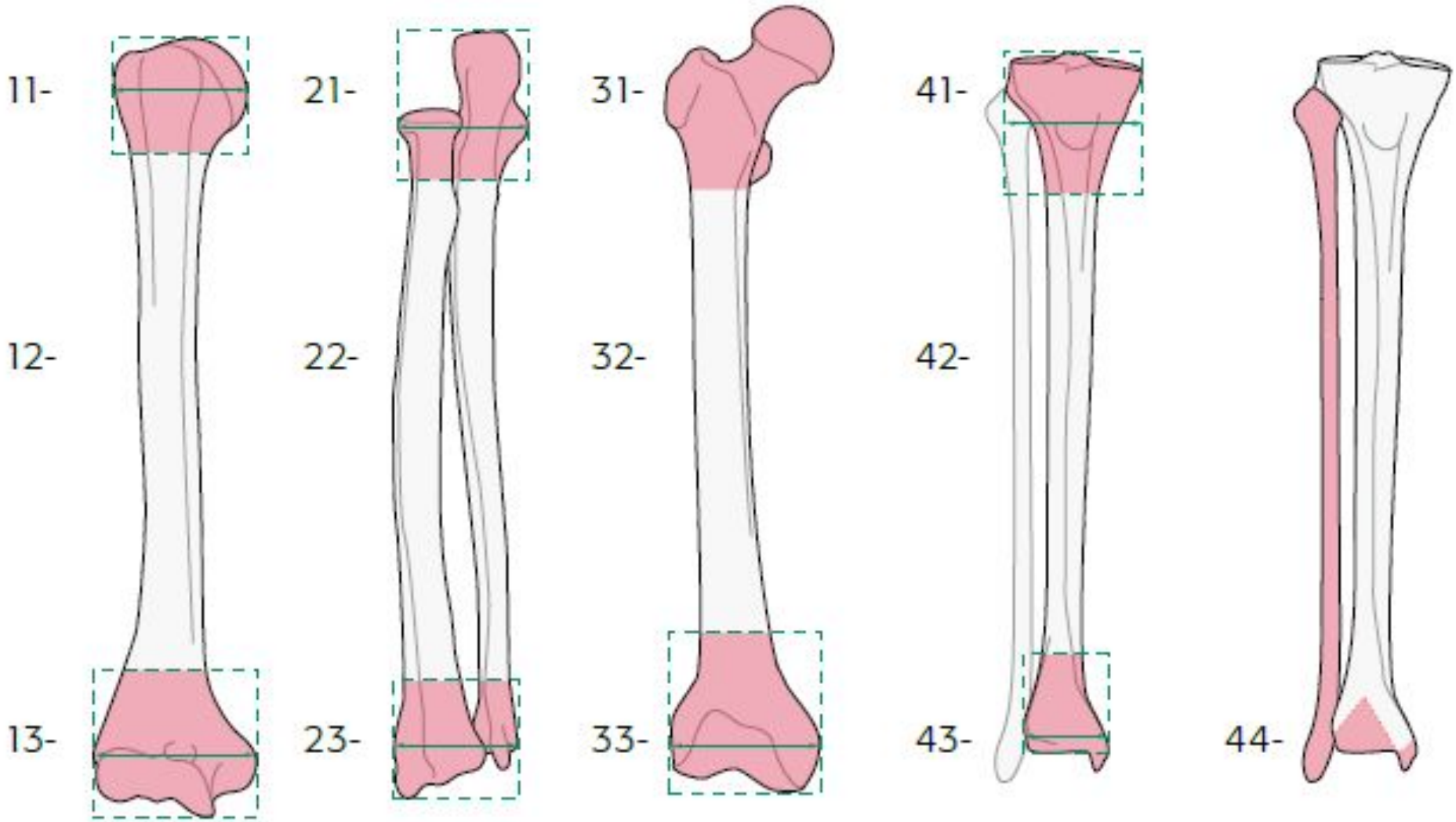

32-B1

	A	B	C
1 Proximal	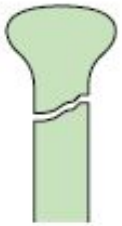	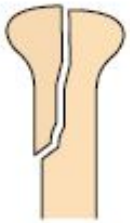	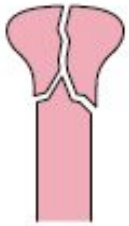
	Extraarticular No involvement of displaced fractures that extend into the articular surface	**Partial articular** Part of the articular component is involved, leaving the other part attached to the meta-/diaphysis	**Complete articular** Articular surface involved, metaphyseal fracture completely separates the articular component from the diaphysis
2 Diaphyseal		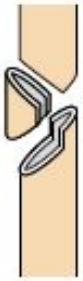	
	Simple One fracture line, cortical contact between fragments exceeds 90% after reduction	**Wedge** Three or more fragments, main fragments have contact after reduction	**Complex** Three or more fragments, main fragments have no contact after reduction
3 Distal	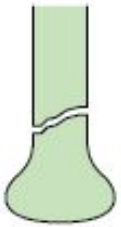	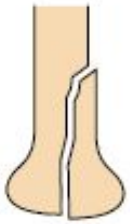	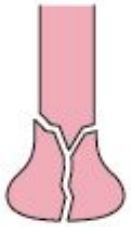
	Extraarticular	**Partial articular**	**Complete articular**

32-B1

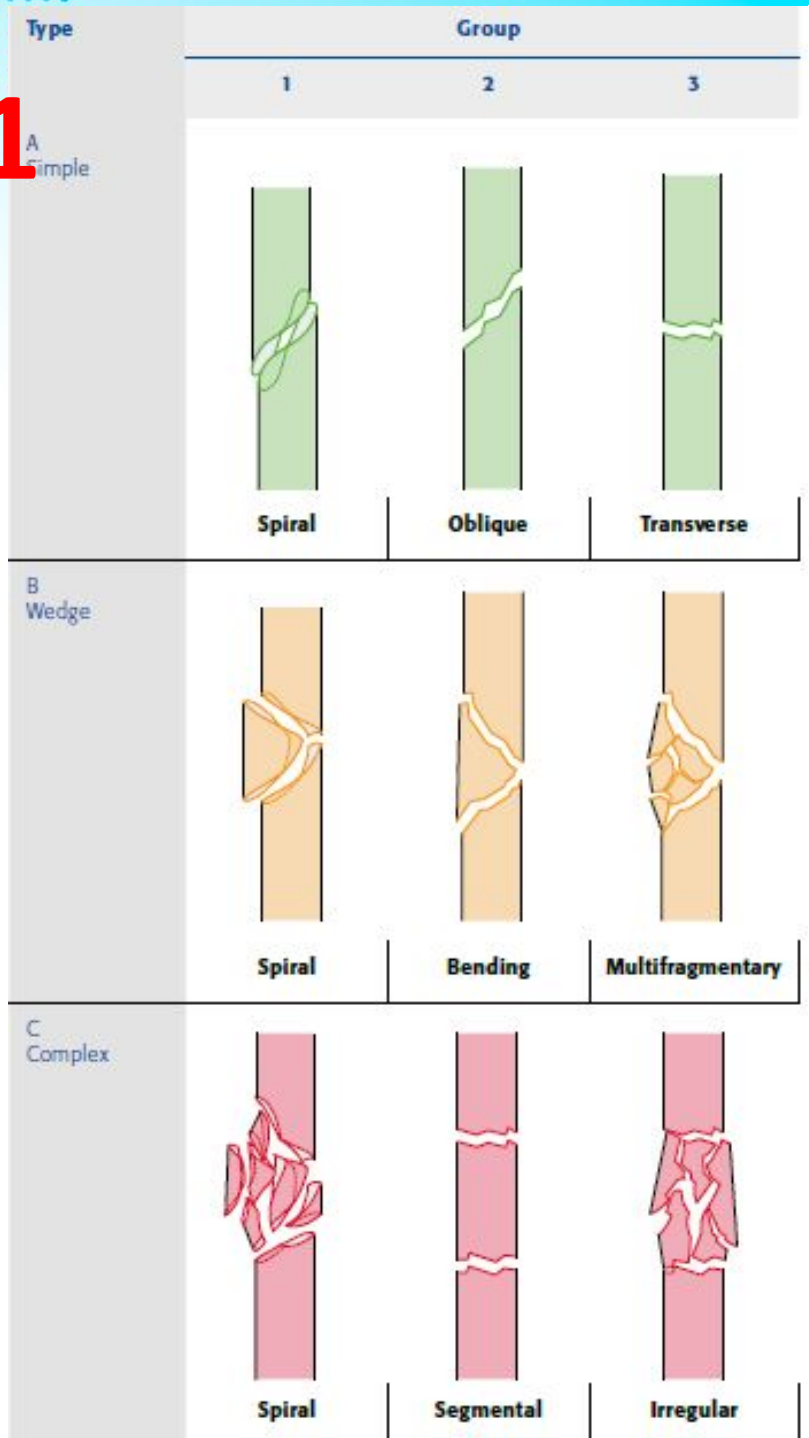
Type
Group
1
2
3
A
Simple
Spiral
Oblique
Transverse
B
Wedge
Spiral
Bending
Multifragmentary
C
Complex
Spiral
Segmental
Irregular

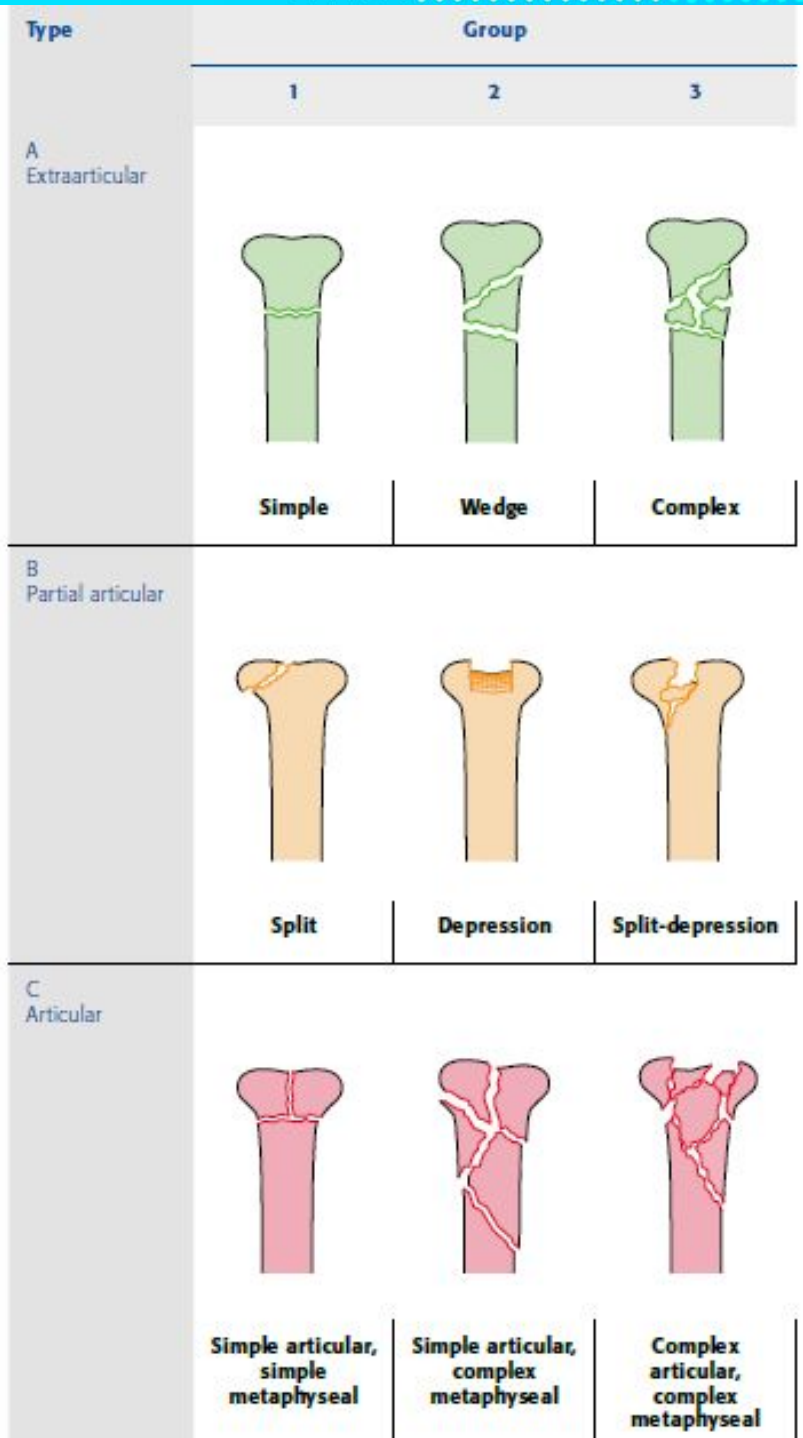
Type
Group
1
2
3
A
Extraarticular
Simple
Wedge
Complex
B
Partial articular
Split
Depression
Split-depression
C
Articular
Simple articular, simple metaphyseal
Simple articular, complex metaphyseal
Complex articular, complex metaphyseal

32-B1

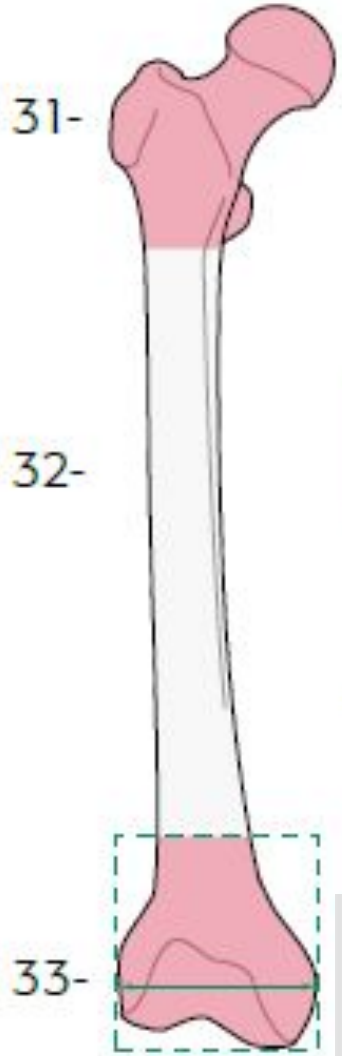
31-
32-
33-

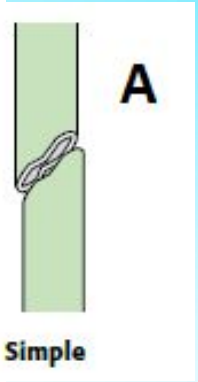
A
Simple

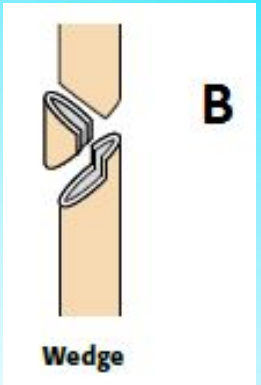
B
Wedge

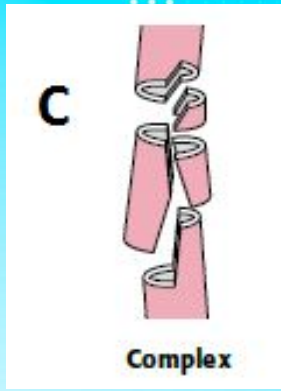
C
Complex

1
Spiral

2
Bending

3
Multifragmentary

Регенерация костной ткани

Лечение переломов

Консервативное

Оперативное

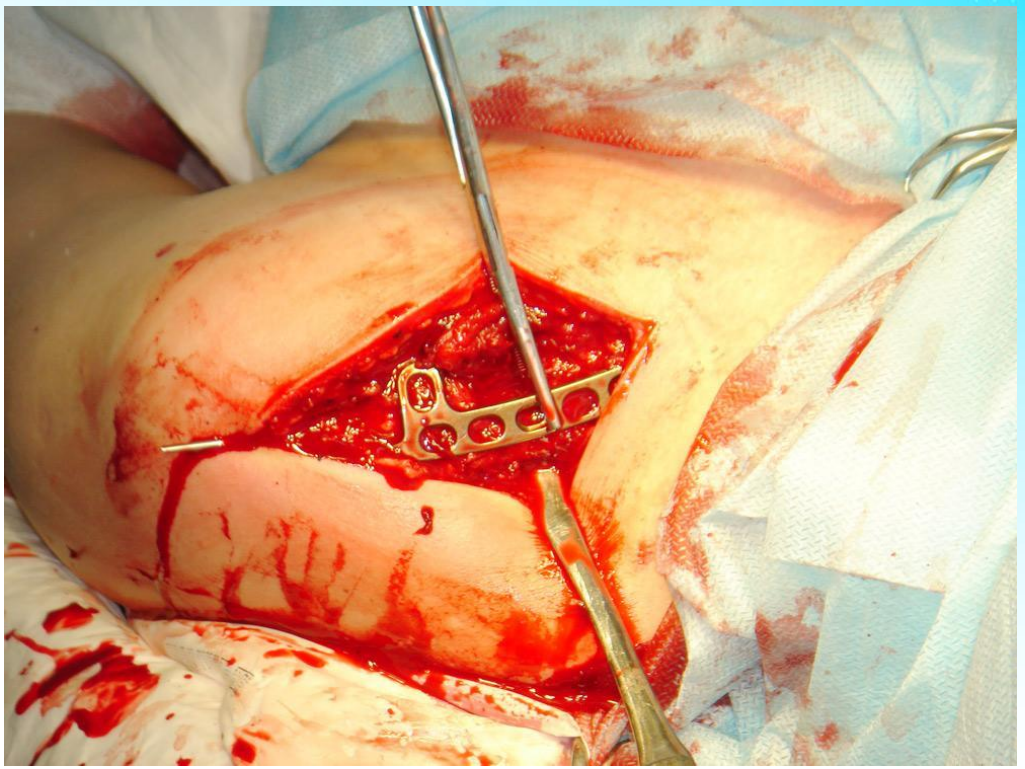

Гипсовые повязки

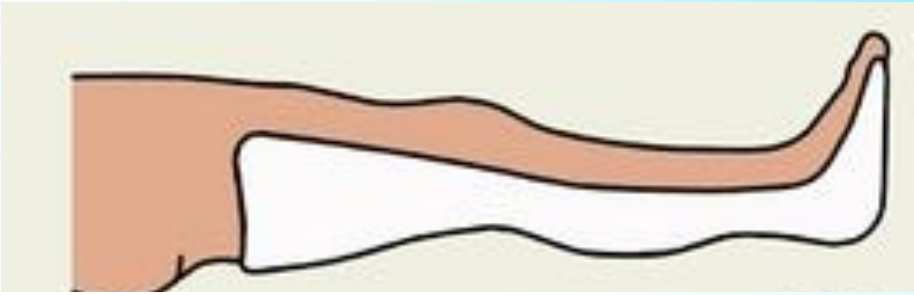

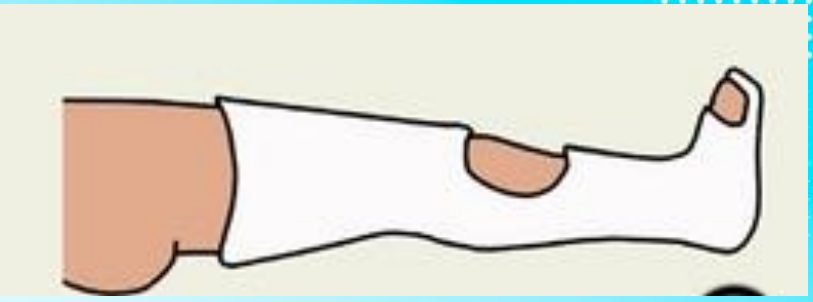

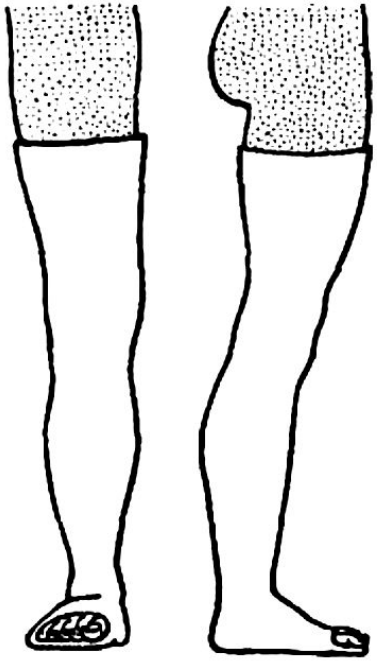

Целлакаст

Эластичкаст

Турбокаст

Скелетное вытяжение

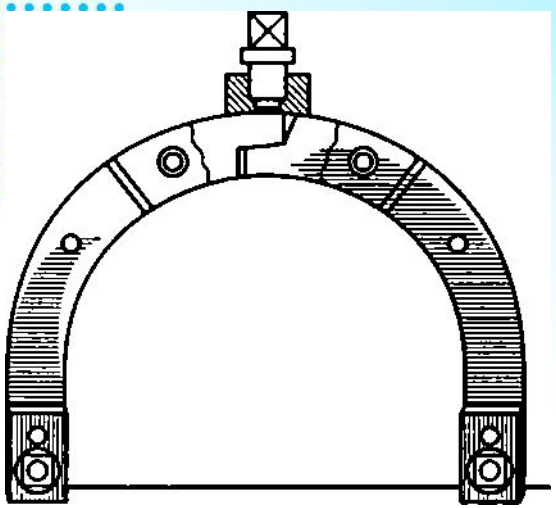

Скоба ЦИТО и спица Киршнера

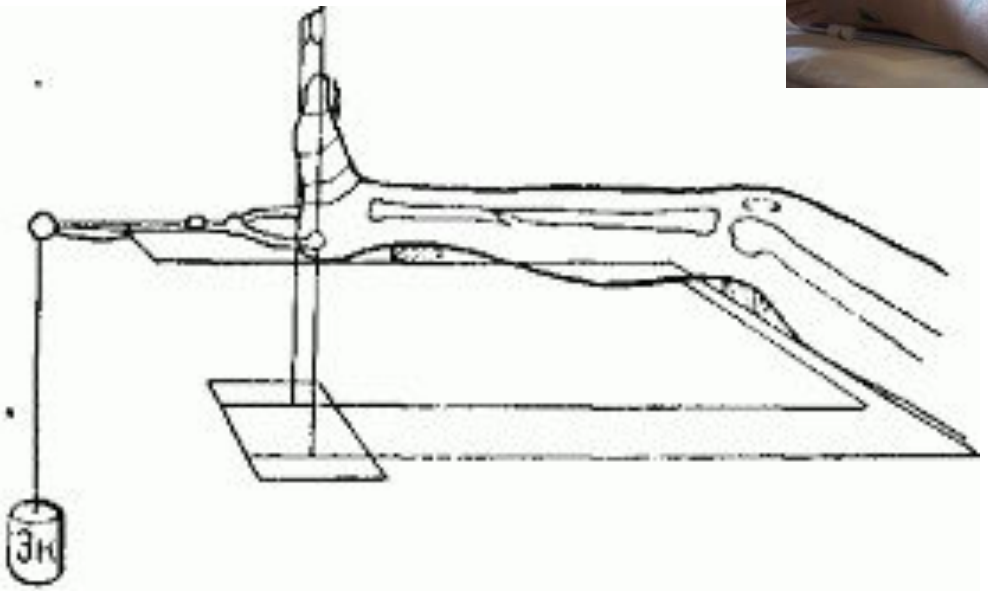

Длительная иммобилизация

Остеопороз

Мышцы не работают

Атрофия мышц

Слабое кровоснабжение

Нарушение трофики суставных тканей

Контрактура

Длительная реабилитация

Восстановление функции

?

Почему заживление перелома занимает 6-12 недель, а человек возвращается к работе только через 6-12 месяцев?

AO/ASIF

AO - Arbeitsgemeinschaft für **O**steosynthesefragen (1958)

ASIF - **A**ssociation for the **S**tudy of **I**nternal **F**ixation

Цель – обеспечить такое лечение, которое позволяет как можно раньше восстановить функцию.

AOTRAUMA

AOSPINE

AOCMF

AOVET

Принципы АО

1. Анатомическая репозиция и фиксация
2. Обеспечение абсолютной или относительной стабильности в зависимости от перелома
3. Сохранение кровоснабжения мягких тканей и кости путем бережной репозиции и осторожного обращения с тканями
4. Ранняя и безопасная мобилизация и реабилитация повреждённого участка и пациента в целом

Требования к репозиции

Обязательно устранить смещение:

- По длине
- Под углом
- Осевое

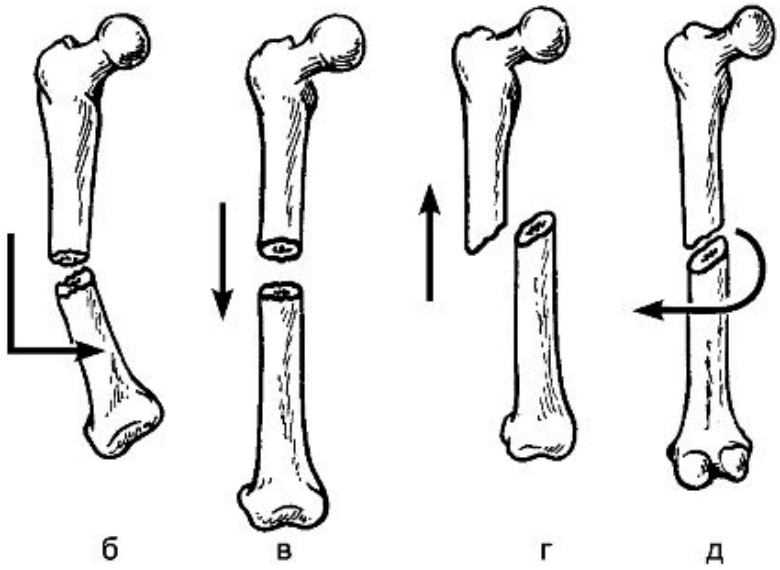

Допустимо:

- Смещение по ширине

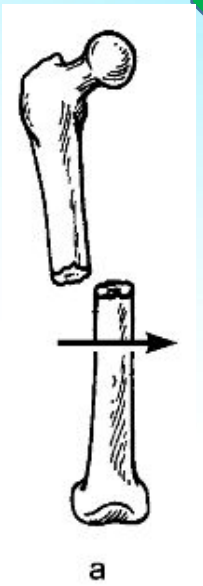

Остеосинтез

Внутренний

- Накостный

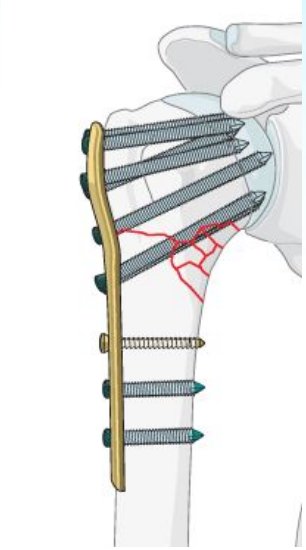

- Внутрикостный

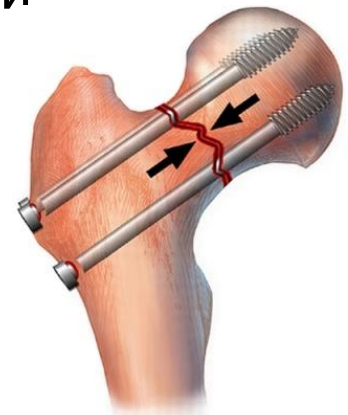

Наружный

- Спицевые аппараты

- Стержневые аппараты



Спицевые аппараты

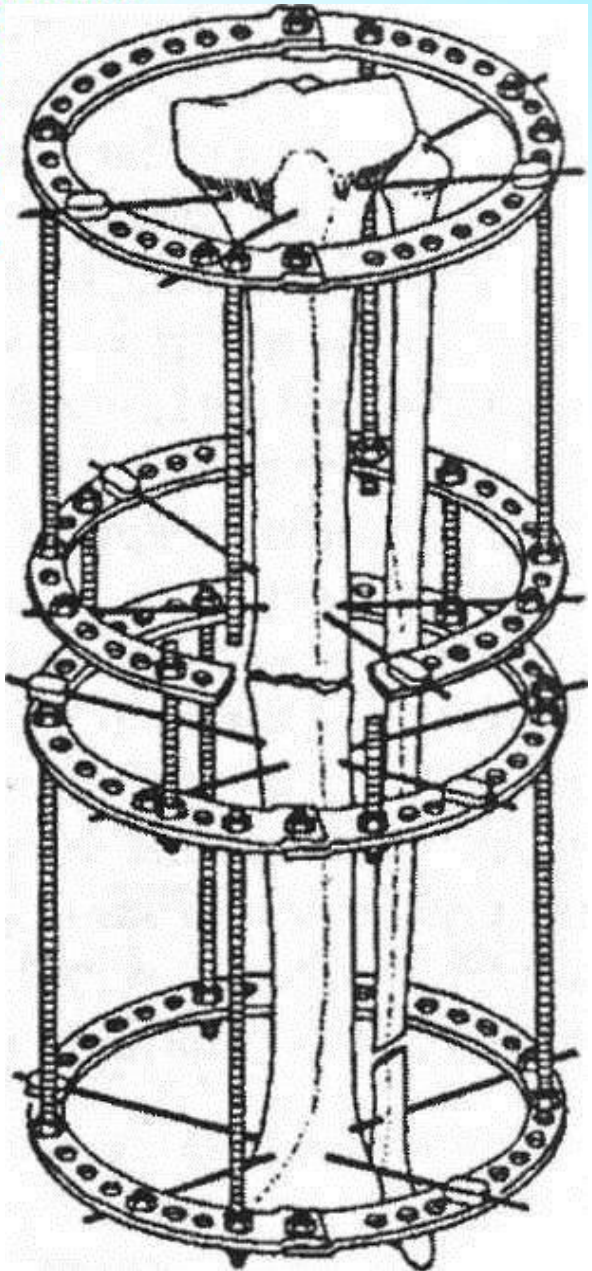

ЧКДО аппаратом Илизарова

Стержневые аппараты

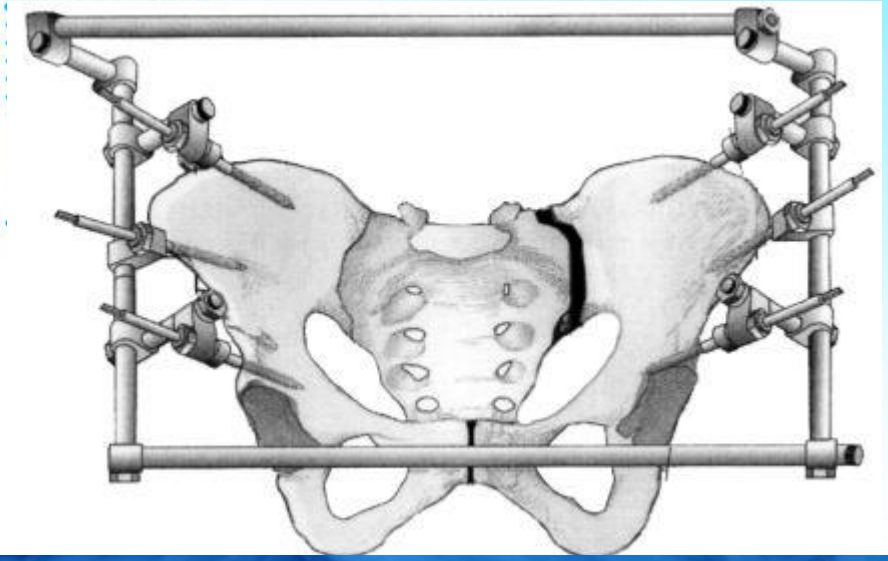

Показания к внешней фиксации

1. **Временная фиксация**

- Политравма
- Открытый перелом
- Невозможность проведения внутреннего остеосинтеза в данный момент
- Как метод репозиции

2. **Окончательная фиксация**

- Состояние больного не позволяет провести открытую операцию
- Некоторые ортопедические ситуации (лечение деформаций, удлинение костей)

Интрамедуллярный остеосинтез

Показания – диафизарные переломы

Интрамедуллярный остеосинтез

Non-locked

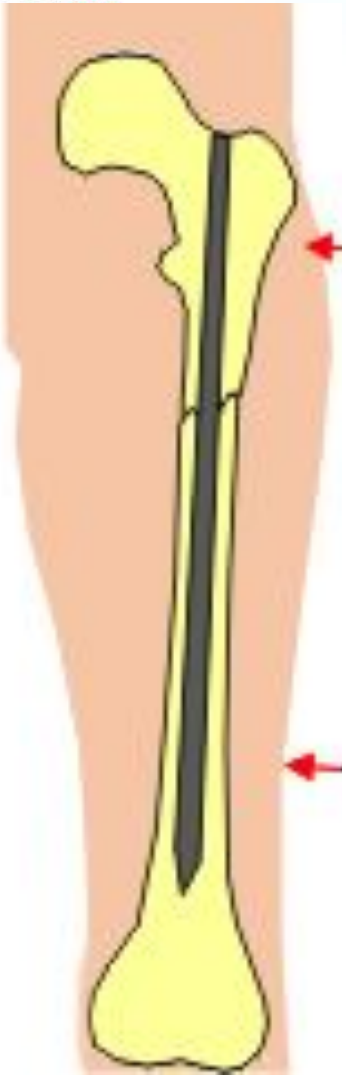

Locked

Reamed

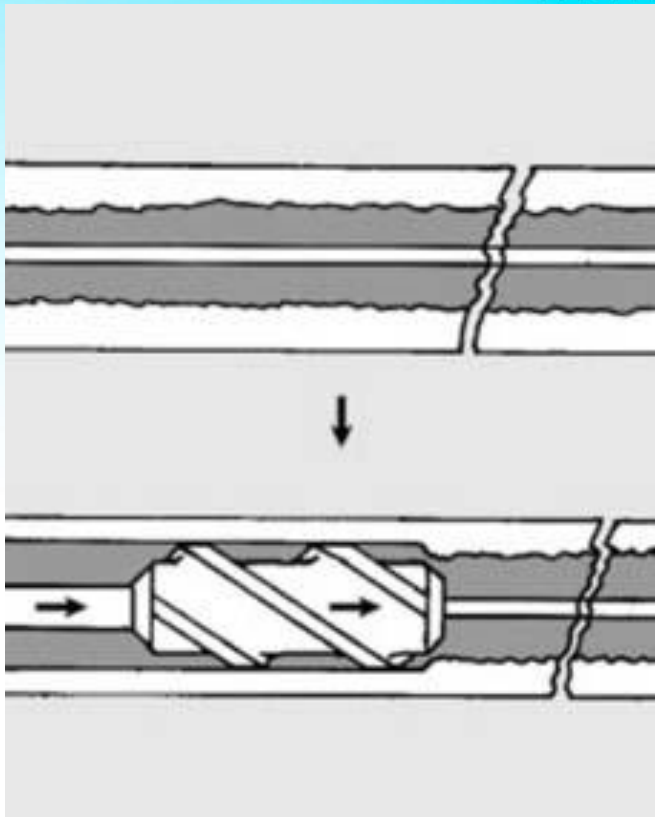

БИОС –блокированный интрамедуллярный остеосинтез

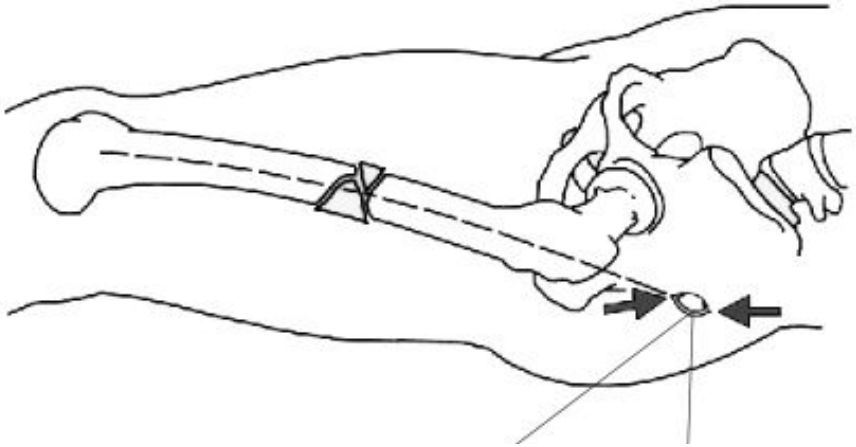

Введение направляющей спицы:

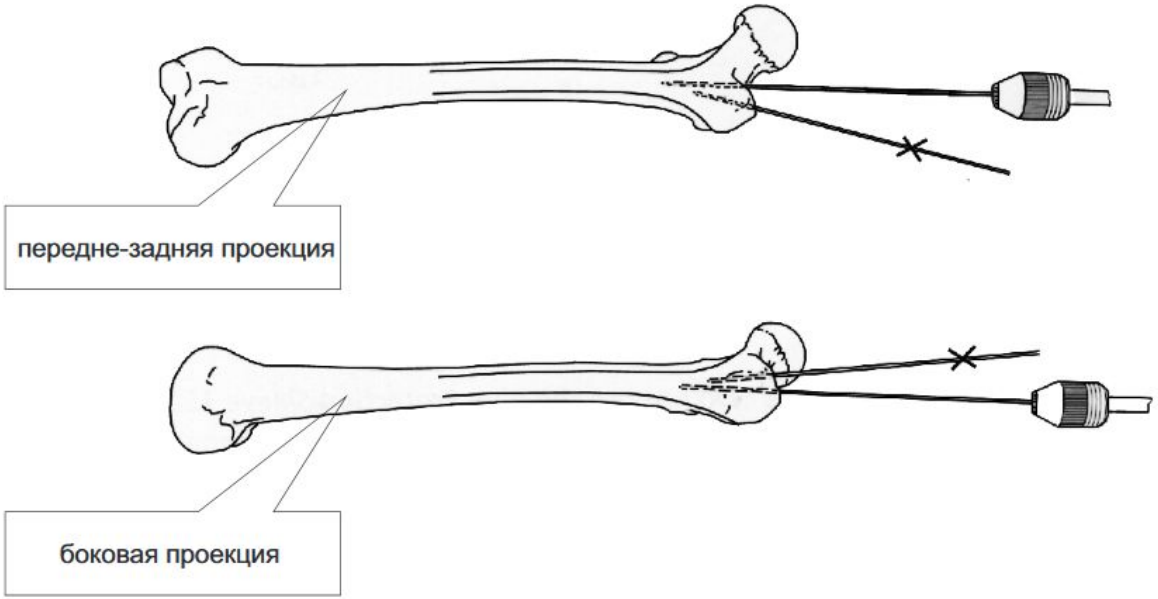

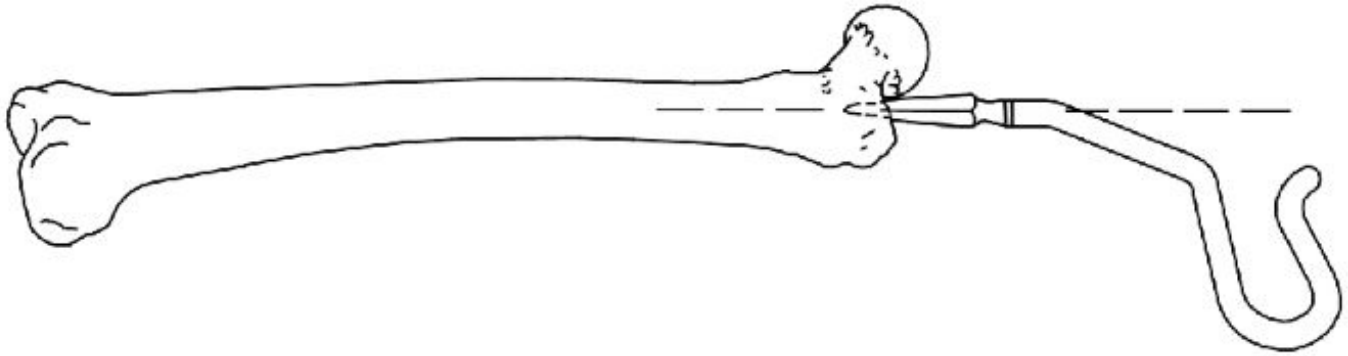

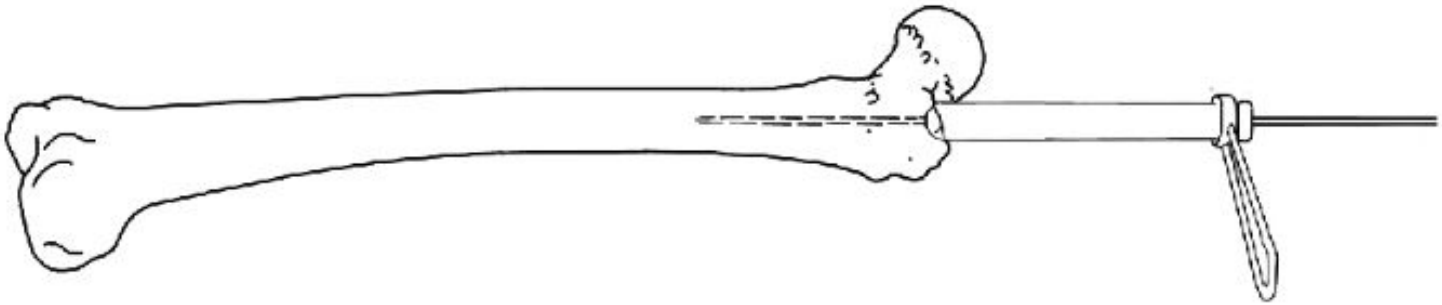

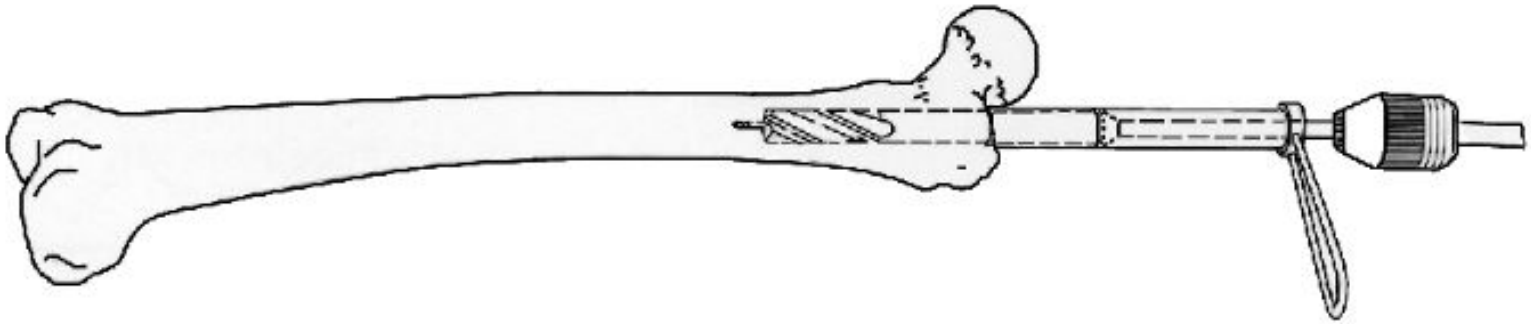

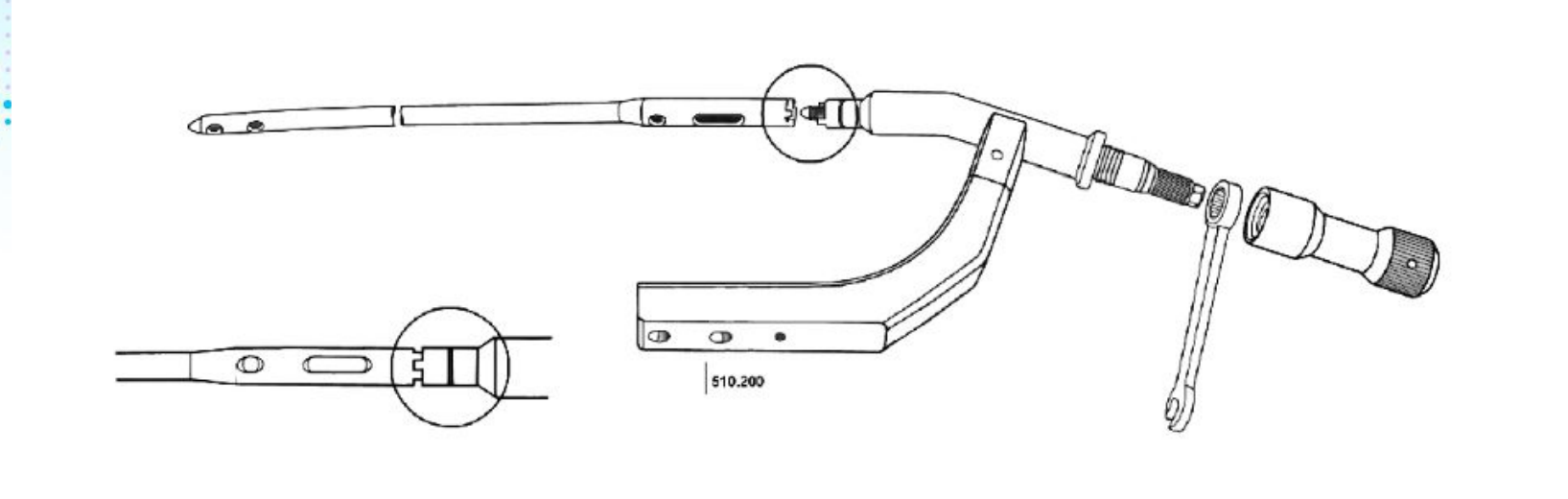
510.200

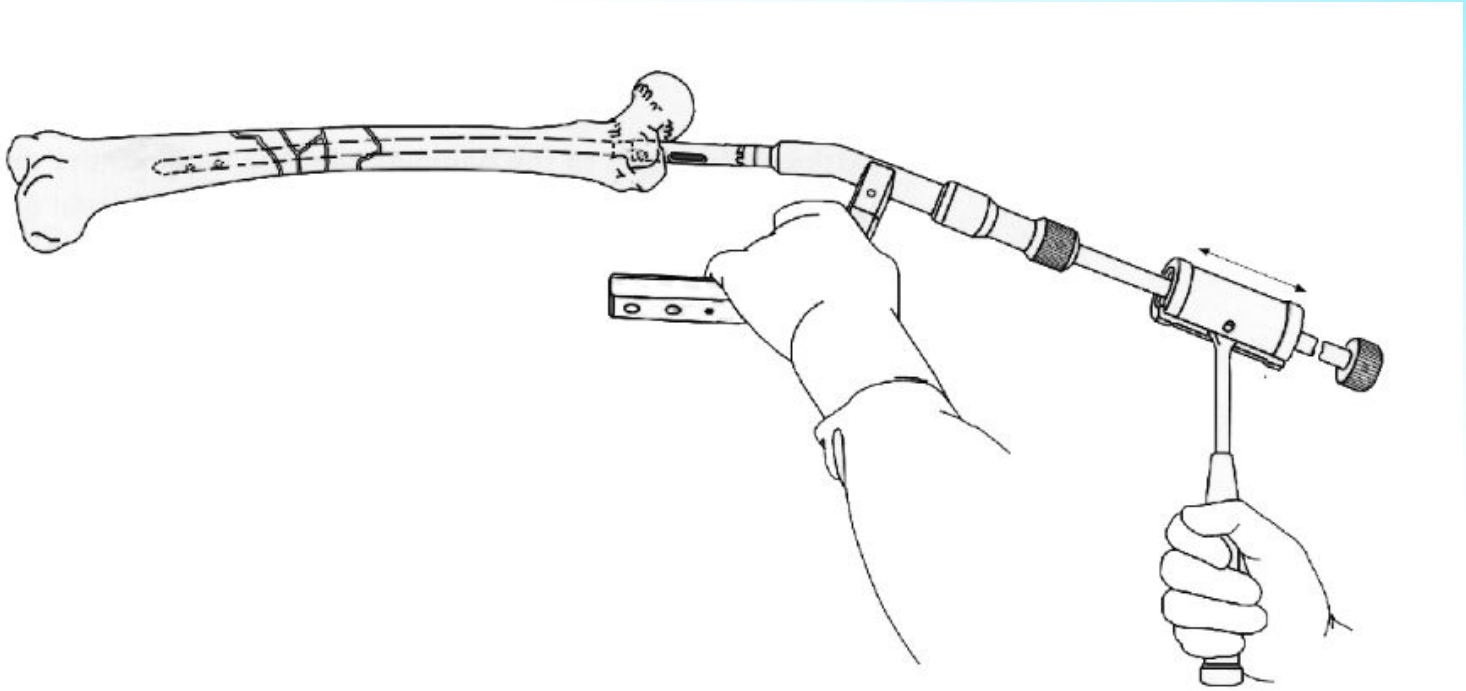

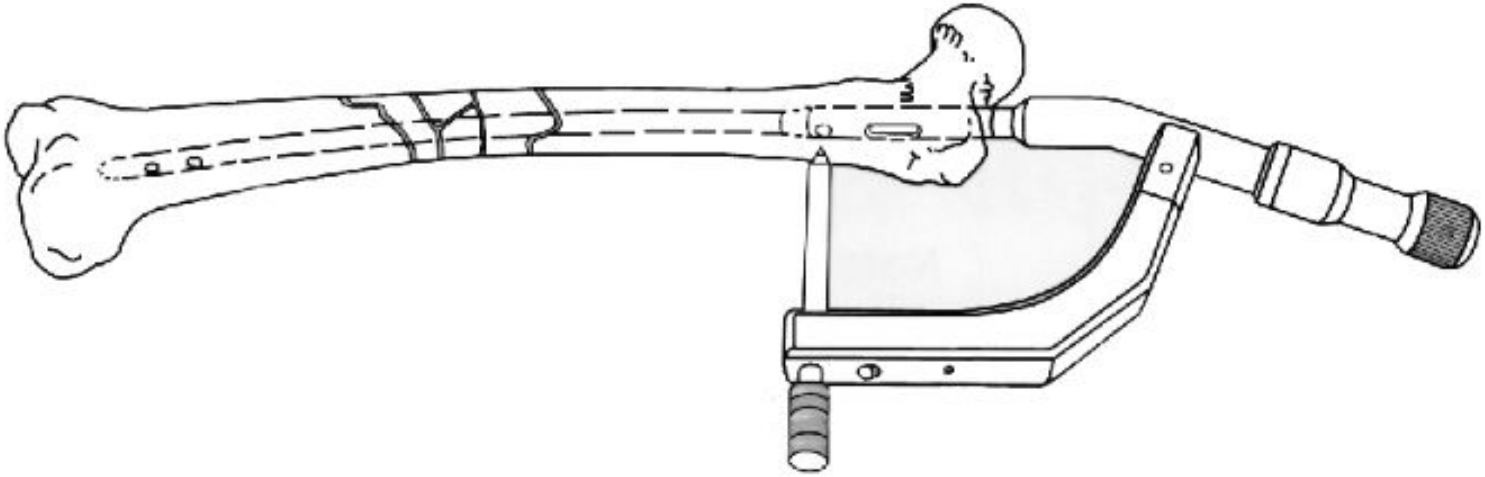

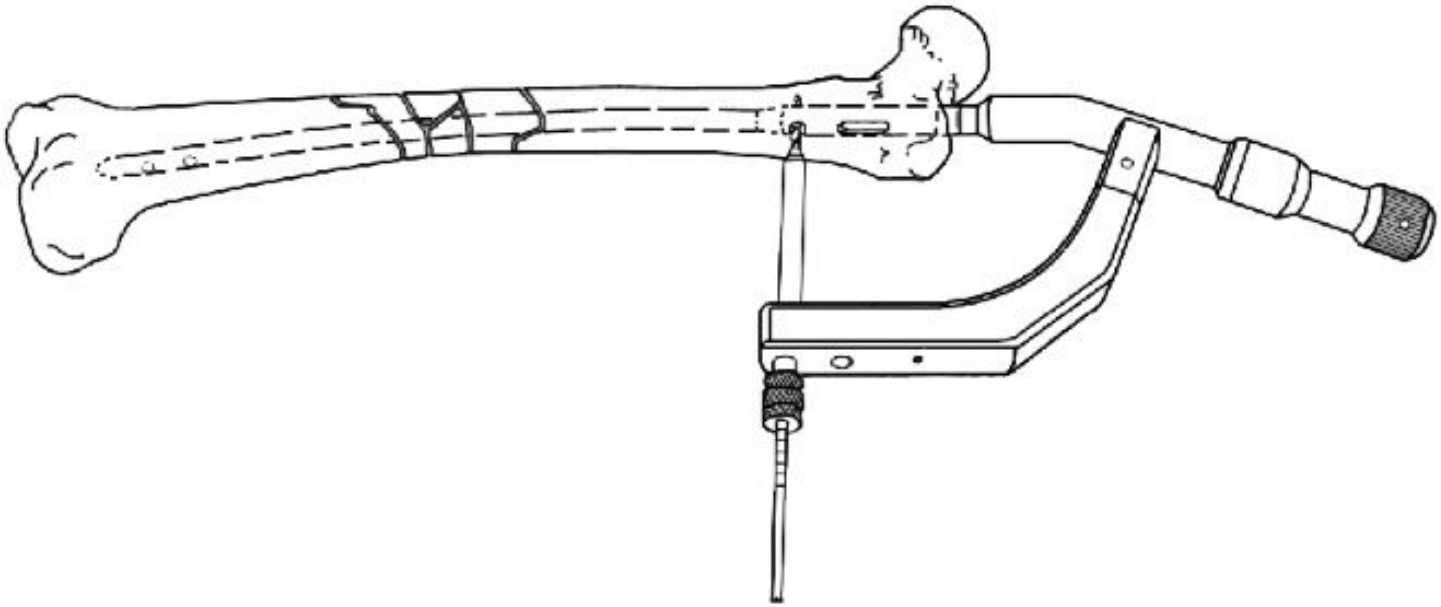

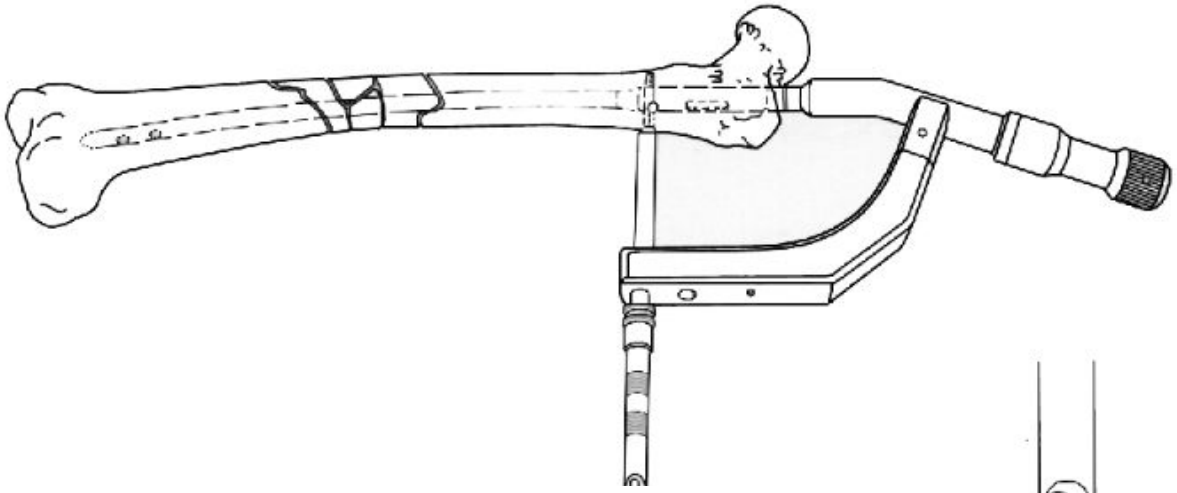

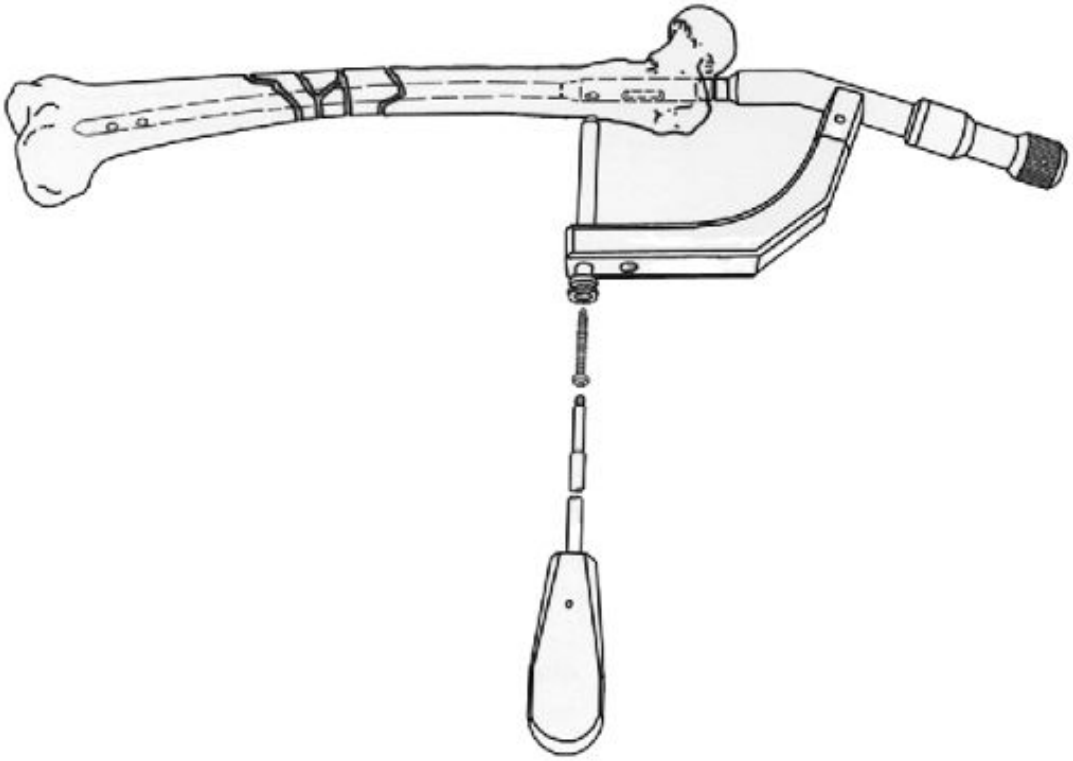

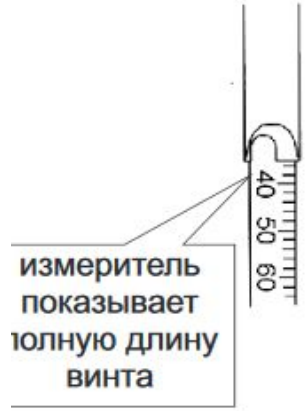
40 50 60
измеритель
показывает
полную длину
винта

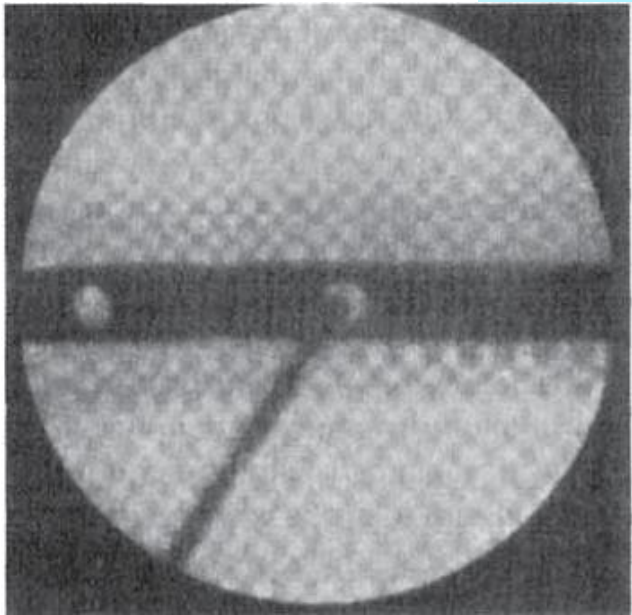

Накостный остеосинтез

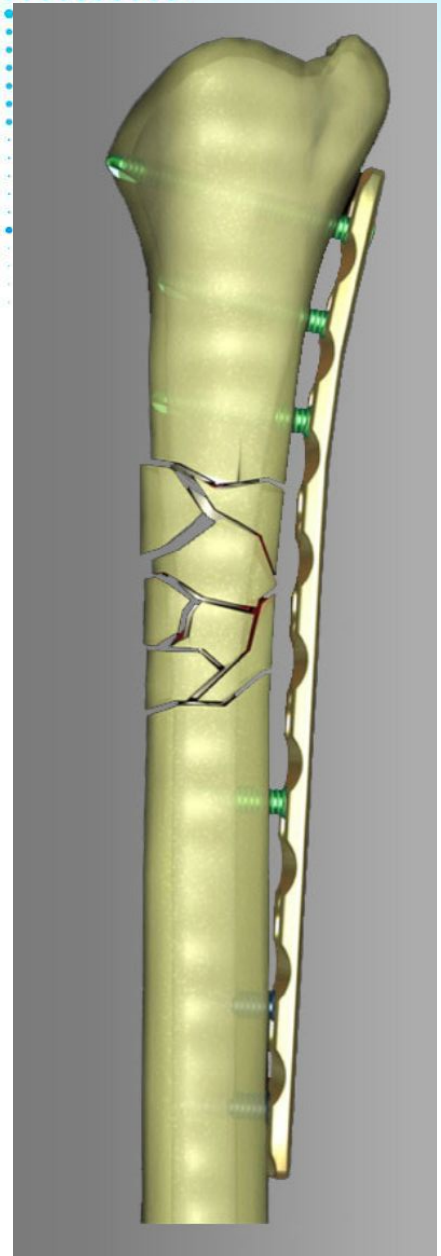

DCP – dynamic compression plate

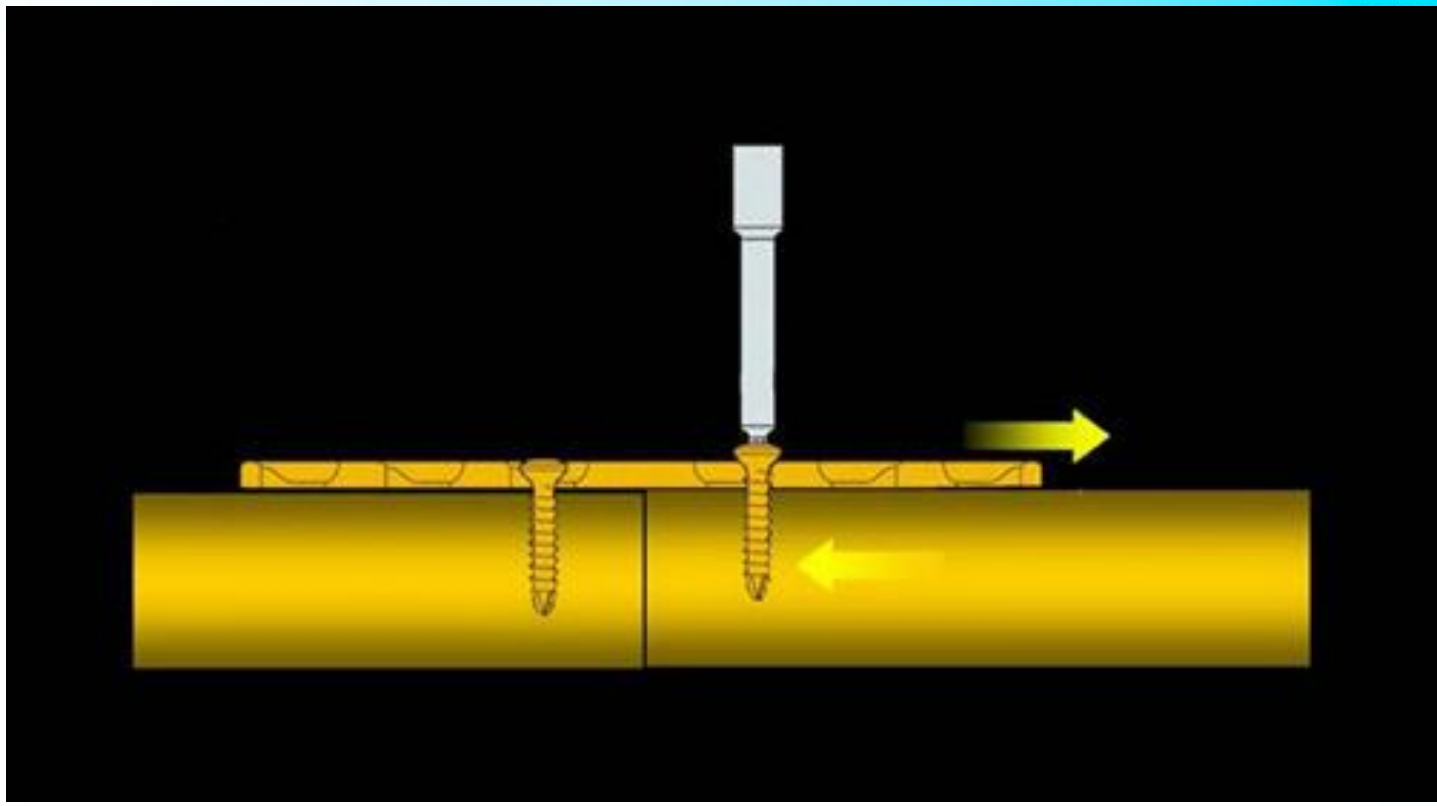

ynamic compression



LCP – locking compression plate

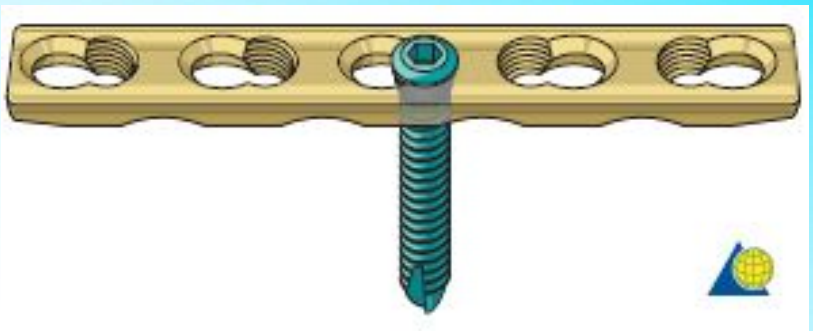

LISS – less invasive stabilisalion system

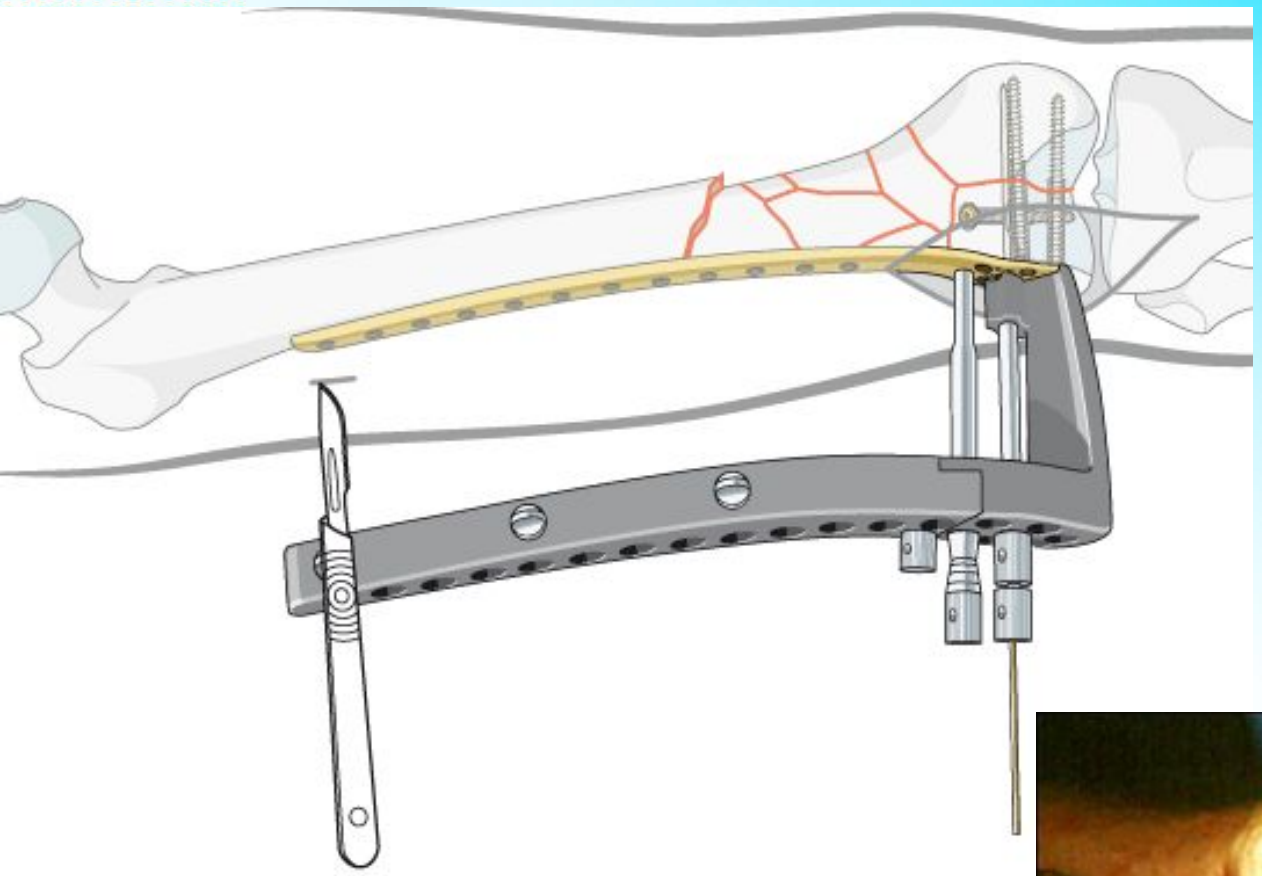

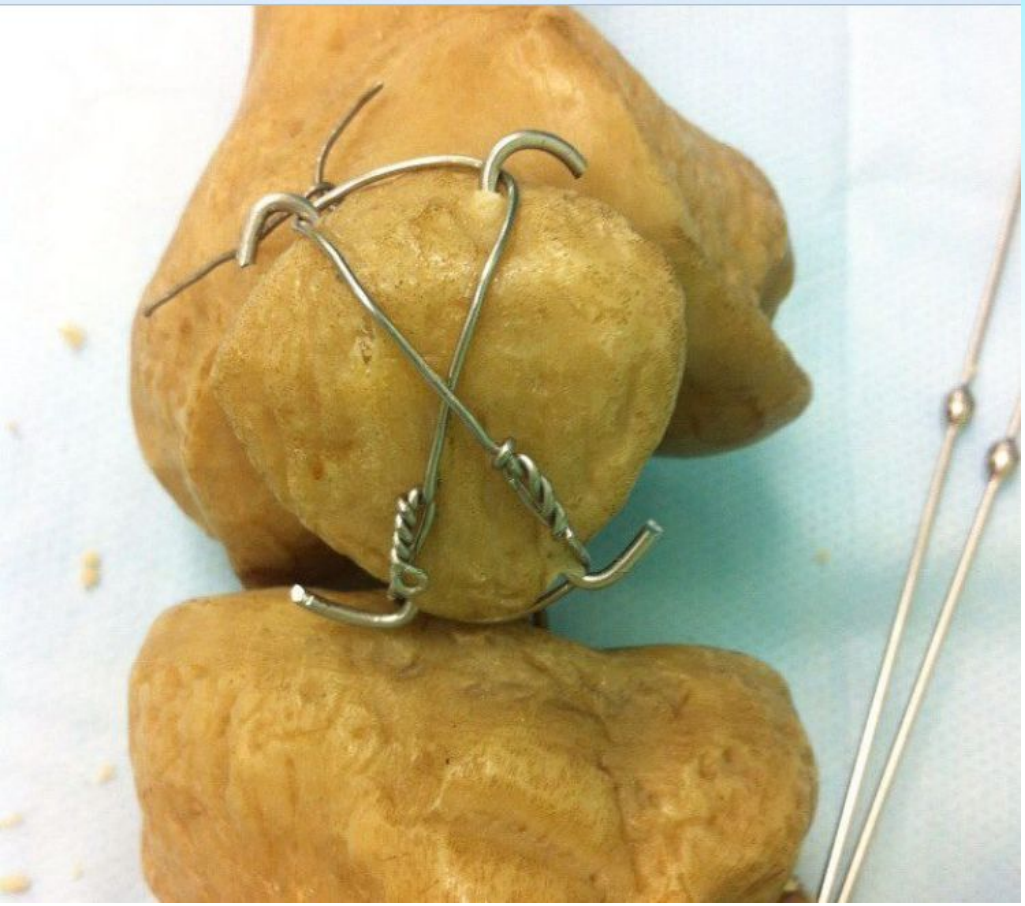

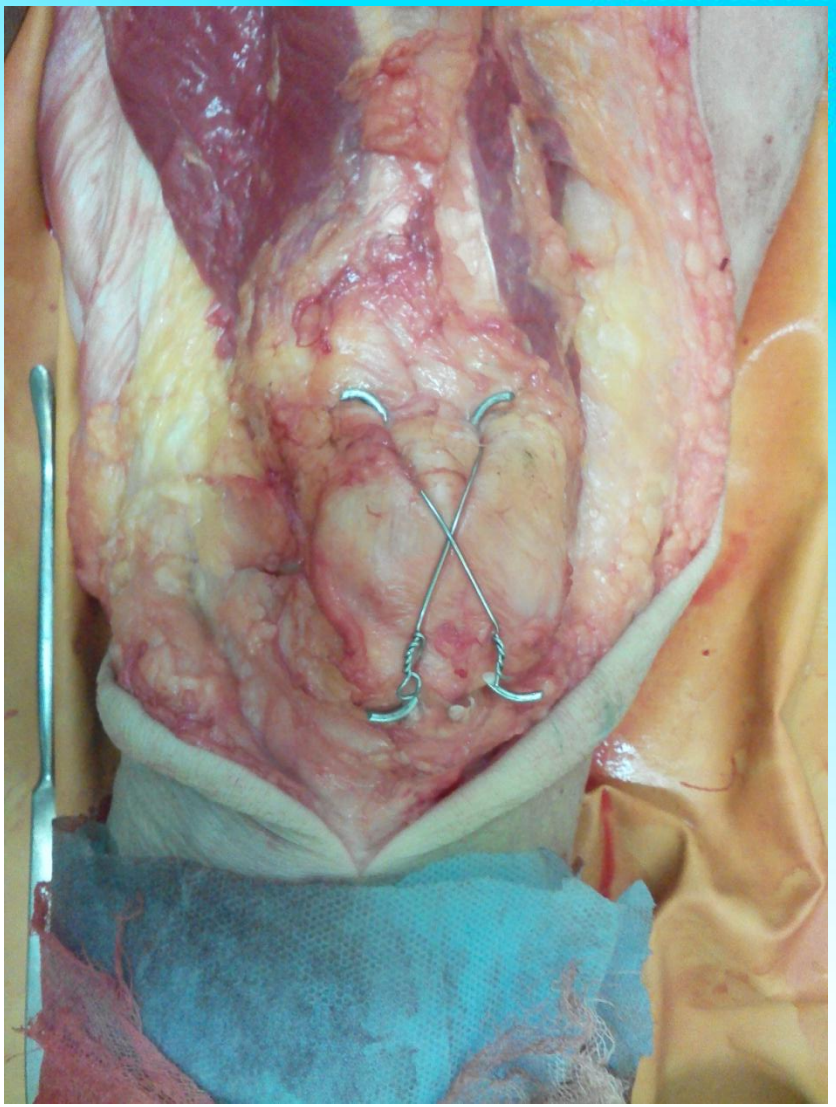

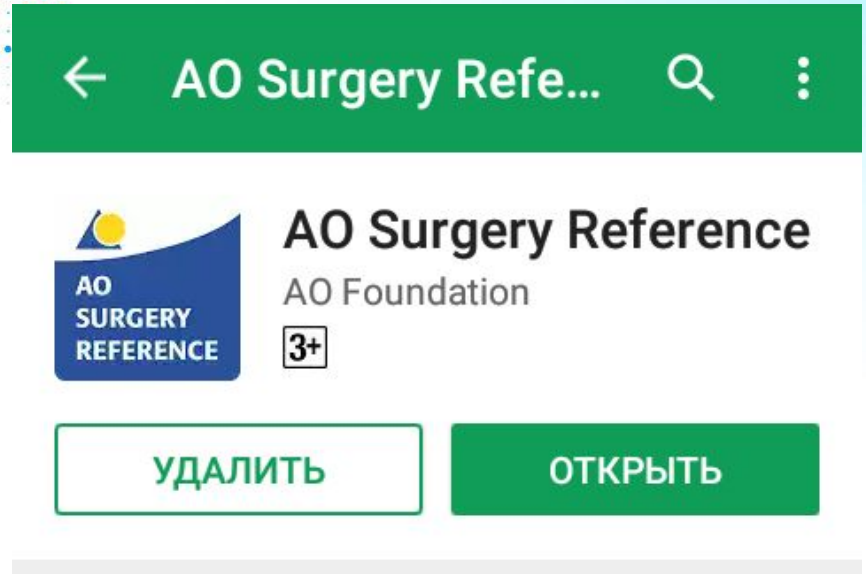
AO Surgery Refe...
AO SURGERY REFERENCE
AO Surgery Reference
AO Foundation
3+
УДАЛИТЬ
ОТКРЫТЬ

AO Foundation
Android
AO Surgery Reference

Overview | Diagnosis

AO Surgery Reference | Authors

Please select an anatomical area

AO Foundation

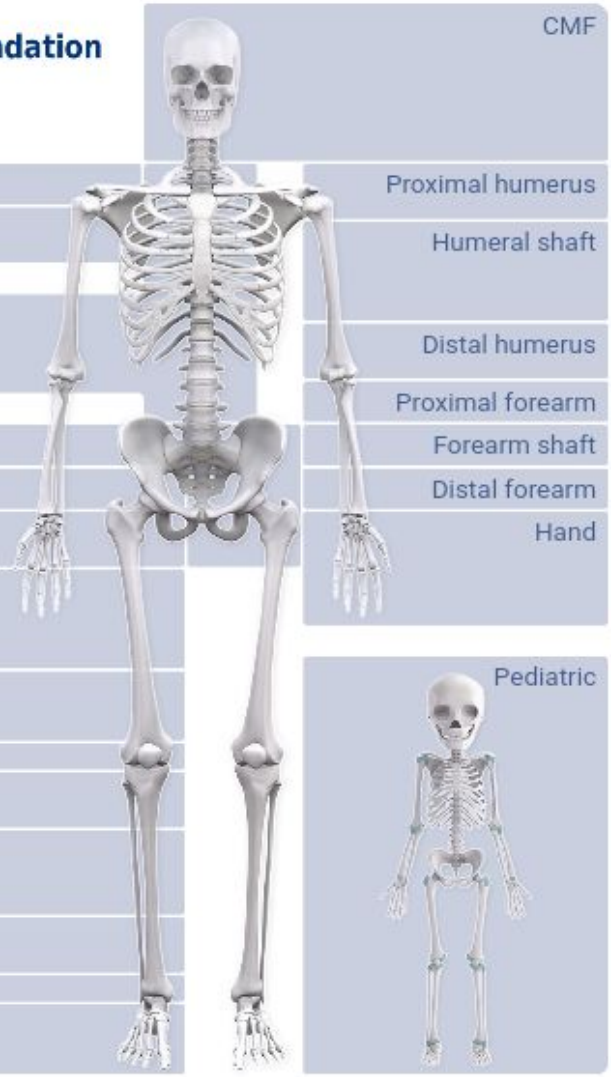

Overview | Diagnosis | Decision | Pr

Tibial shaft | Authors

Simple fractures

42-A1
Spiral

42-A2
Oblique (>30°)

42-A3
Transverse (<30°)

Wedge fractures

42-B1
Spiral wedge

42-B2
Bending wedge

Diagnosis | Decision | Preparation | Ap

Tibial shaft 42-A2 | Authors

Operative treatment

Casting

CREF: Closed reduction external fixation
External fixator (modular)

CREF: Closed reduction external fixation
External fixator (uniplanar)

CREF: Closed reduction external fixation
Ring fixator (Ilizarov)

CRIF: Closed reduction internal fixation
Nailing

CRIF: Closed reduction internal fixation
Nailing

CRIF: Closed reduction internal fixation
MIO - Compression plating

ORIF: Open reduction internal fixation
Lag screws with protection plate (screw through plate)

ORIF: Open reduction internal fixation
Lag screws with protection plate (screw outside plate)

ORIF: Open reduction internal fixation
Compression plate with lag screw

General considerations

Back

Decision - more detail

Tibial shaft 42-A3

Closed reduction; intramedullary nailing

CRIF - Intramedullary nailing

Main indication: Any diaphyseal fracture with a normal medullary canal

Skill: Equipment:

Indications

- Any tibial diaphyseal fracture with a normal medullary canal and sufficient length of end segments
- Need for surgical stabilization

Contraindications

- Deformed medullary canal (old fracture; hardware)
- Risks of surgery and anesthesia exceed

Approach | Reduction & Fixation | Aftercare

Tibial shaft 42-A2 CRIF

Authors

CRIF - Intramedullary nailing

1. Principles

Intramedullary nailing

Intramedullary fixation is valuable and appropriate for the majority of tibial fractures. It is well-suited for the mid diaphysis. With newer nail designs and attention to technique, nailing can be extended to both proximal and distal extraarticular fractures.

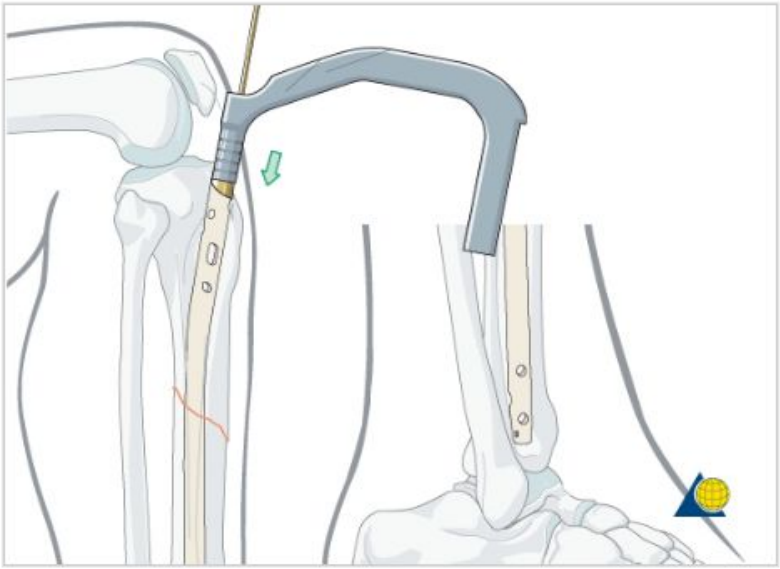

Спасибо за внимание!