Лекция №14

Филогенез нервной, сердечно-сосудистой, пищеварительной, дыхательной и мочеполовой систем хордовых

1. Рыбы

2. Амфибии (Земноводные)

3. Рептилии (Пресмыкающиеся)

4. Птицы

5. Млекопитающие

Эволюция органов у хордовых

1. Рыбы

2. Амфибии (Земноводные)

3. Рептилии (Пресмыкающиеся)

4. Птицы

5. Млекопитающие

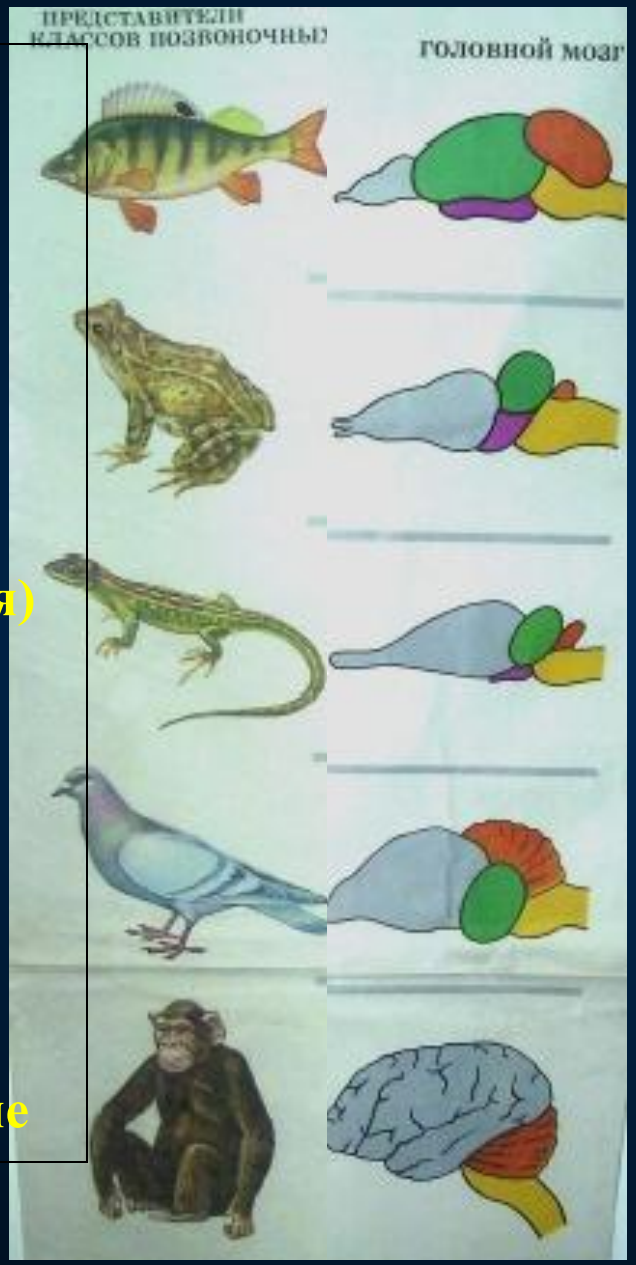

Филогенез нервной системы хордовых

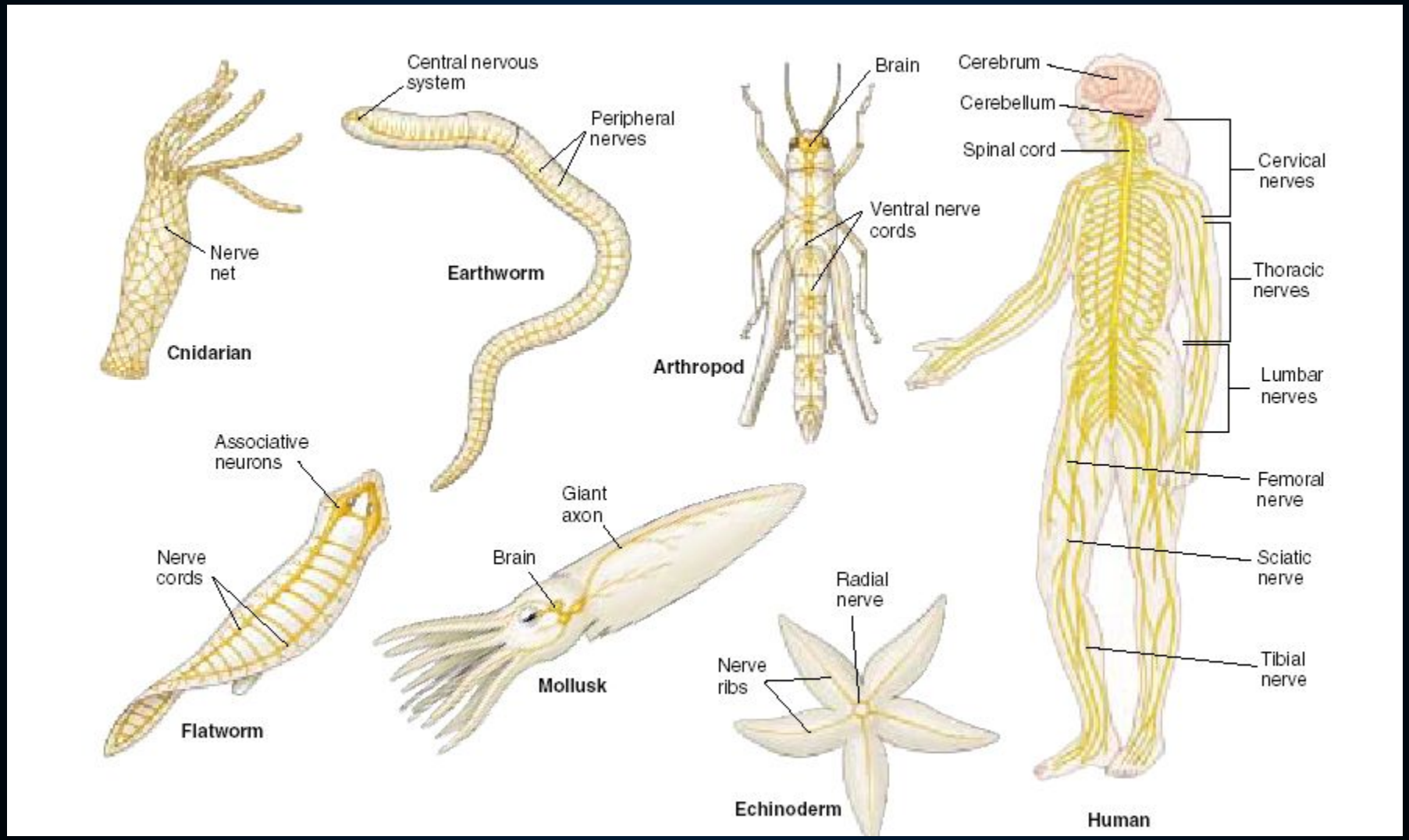

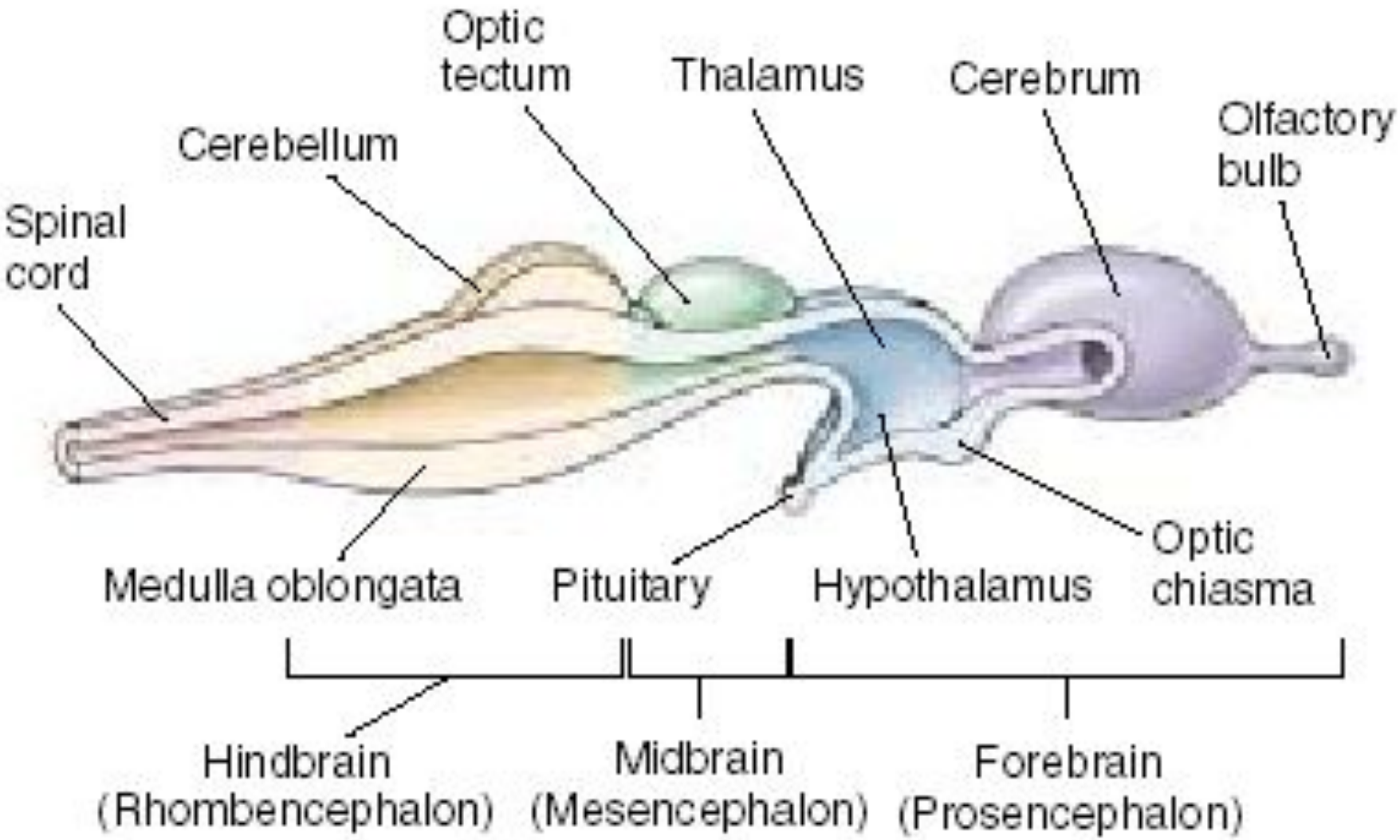
Optic tectum
Thalamus
Cerebrum
Olfactory bulb
Cerebellum
Spinal cord
Medulla oblongata
Pituitary
Hypothalamus
Optic chiasma
Hindbrain (Rhombencephalon)
Midbrain (Mesencephalon)
Forebrain (Prosencephalon)

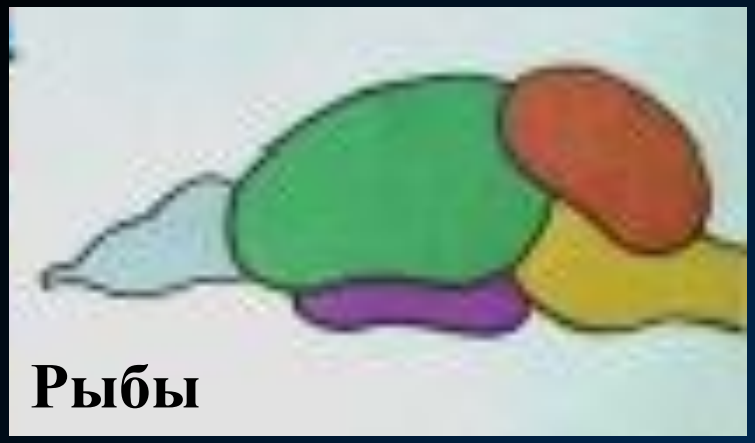

ихтиопсидный

зауропсидный

маммальный

Эволюция ЦНС хордовых

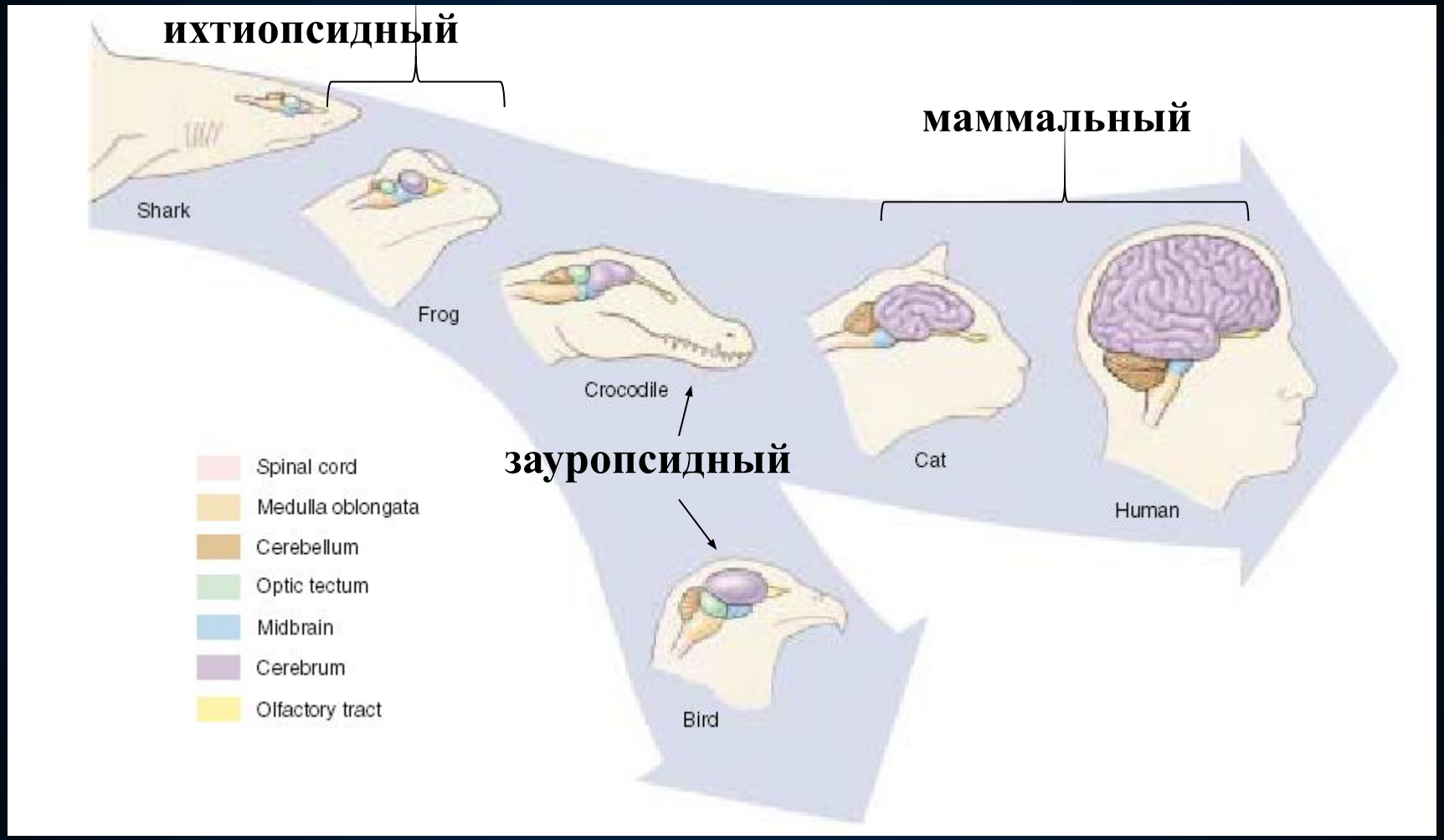

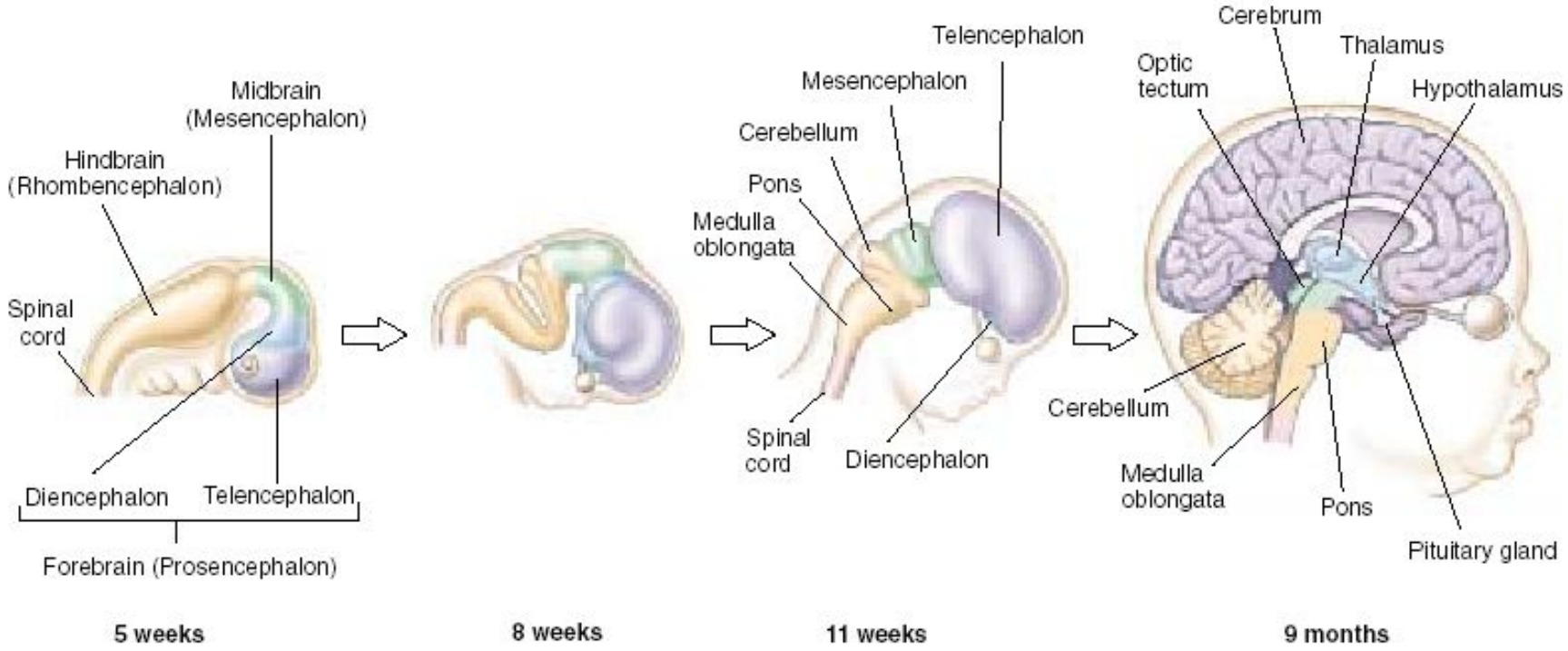
Midbrain
(Mesencephalon)
Hindbrain
(Rhombencephalon)
Spinal
cord
Diencephalon
Telencephalon
Forebrain (Prosencephalon)
5 weeks
8 weeks
Telencephalon
Mesencephalon
Cerebellum
Pons
Medulla
oblongata
Spinal
cord
Diencephalon
11 weeks
Cerebrum
Thalamus
Optic
tectum
Hypothalamus
Cerebellum
Medulla
oblongata
Pons
Pituitary gland
9 months

Филогенез сердечно-сосудистой системы хордовых

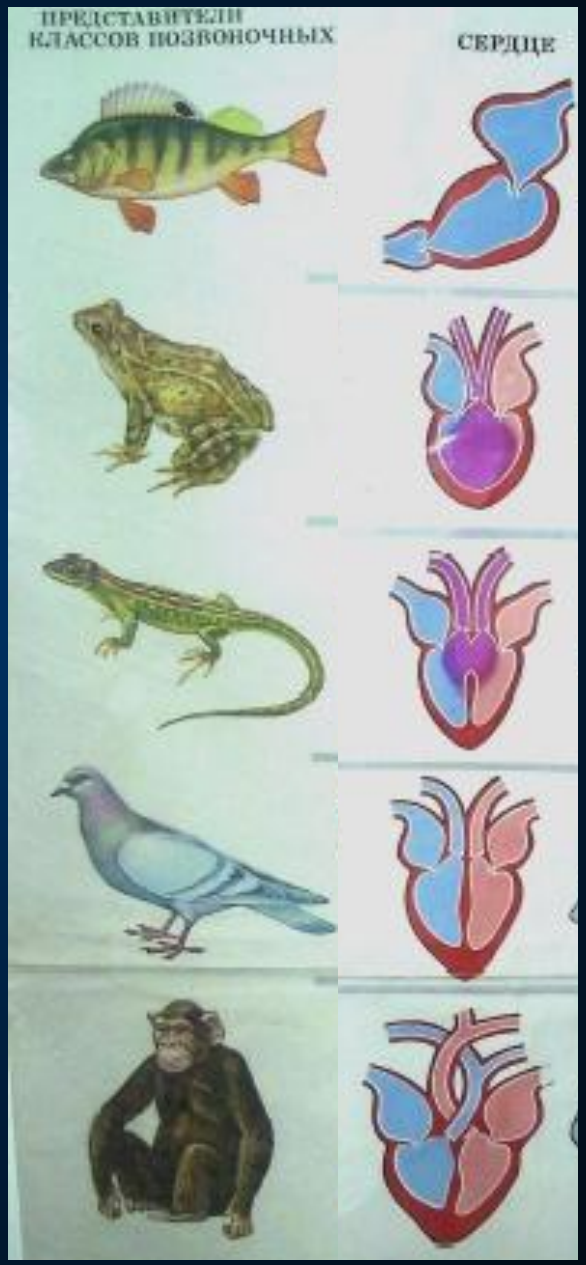

Сердечно-сосудистая система насекомых

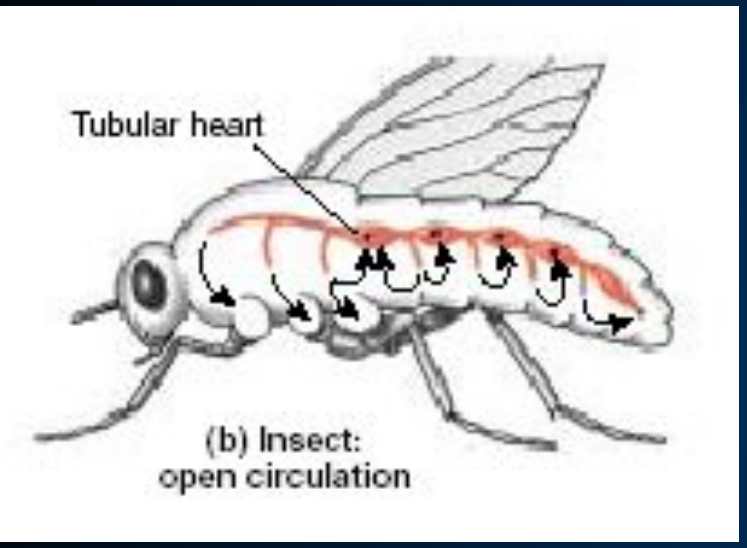

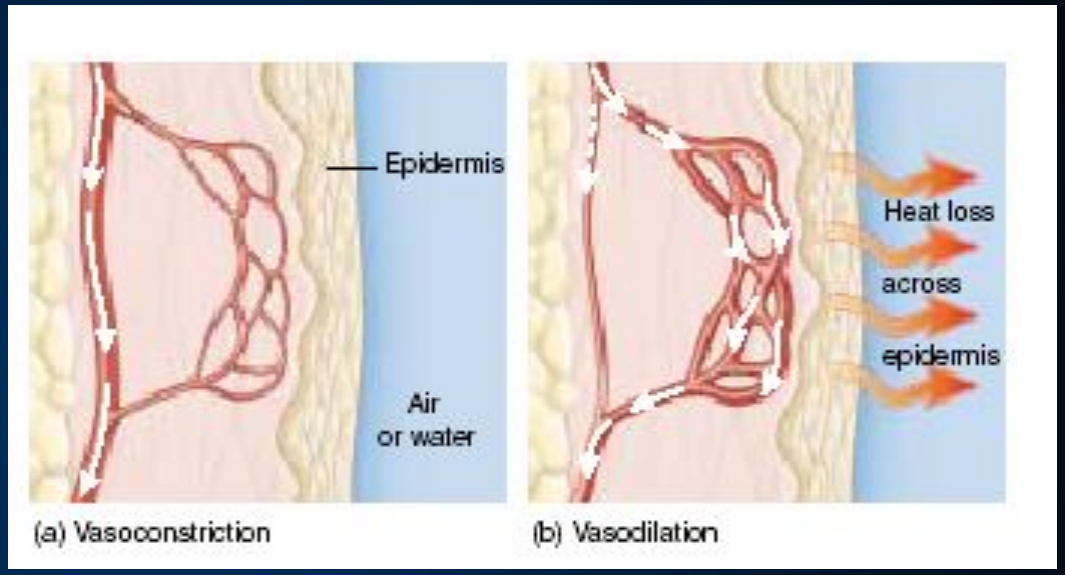

*** Кровеносная система незамкнутая**

*** на спинной стороне – пульсирующий сосуд – прообраз сердца.**

Ланцетник – низшее хордовое животное

Ланцетник – низшее хордовое животное

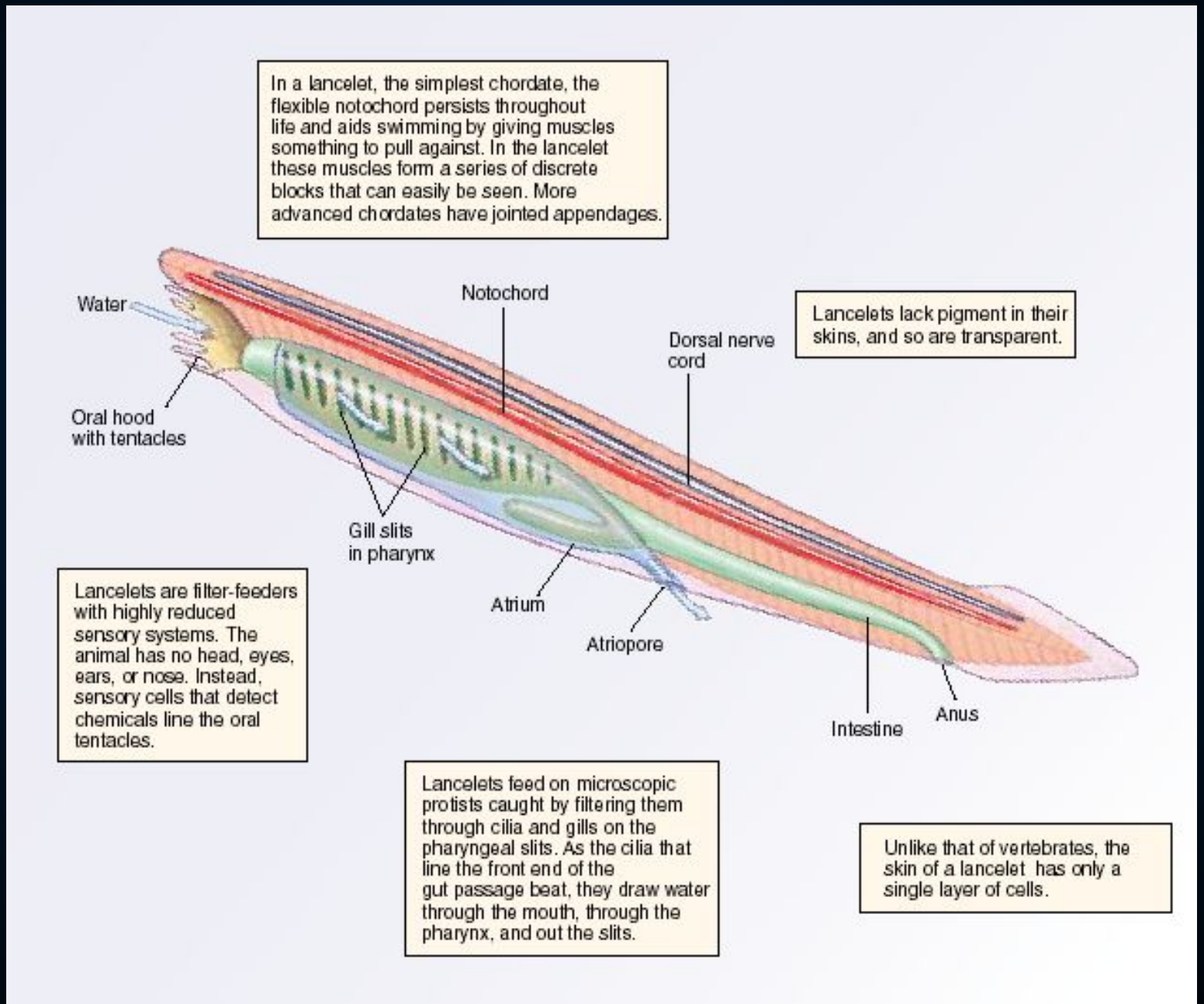

Филогенез сердечно-сосудистой системы хордовых

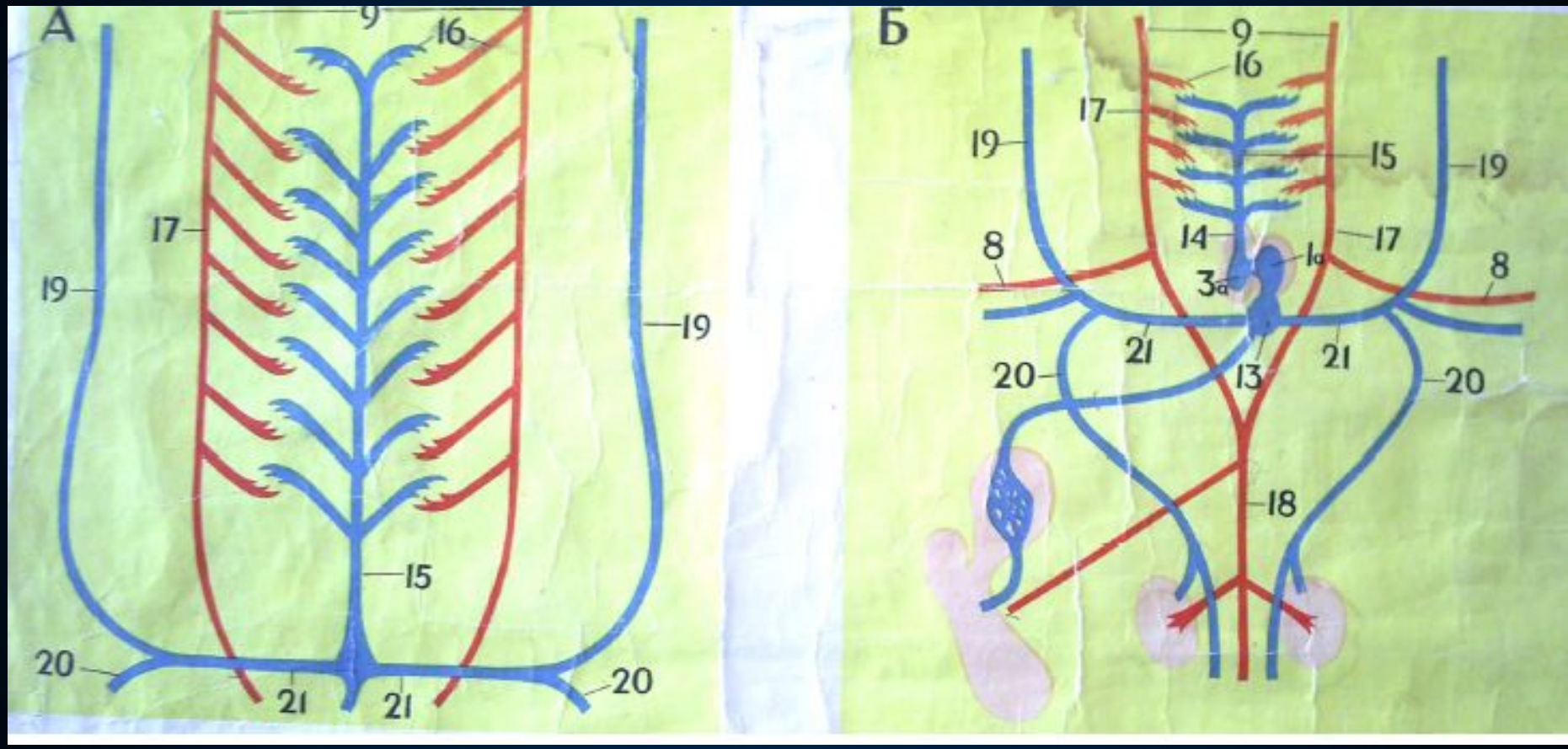

ланцетник

рыбы

Сердечно-сосудистая система рыб:

1. Замкнутая
2. 1 круг кровообращения
3. 2-х камерное сердце.

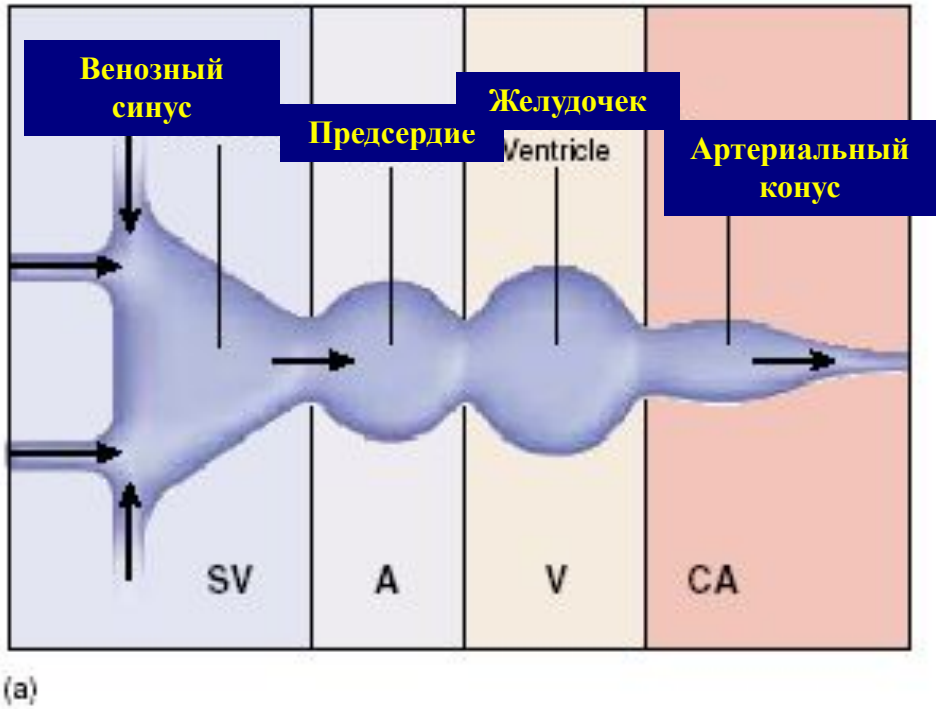



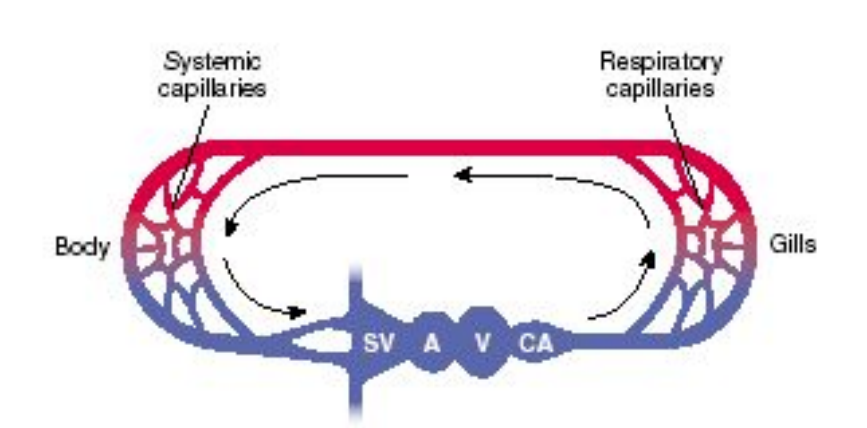

Сердечно-сосудистая система амфибий

2 круга кровообращения, 3-х камерное сердце

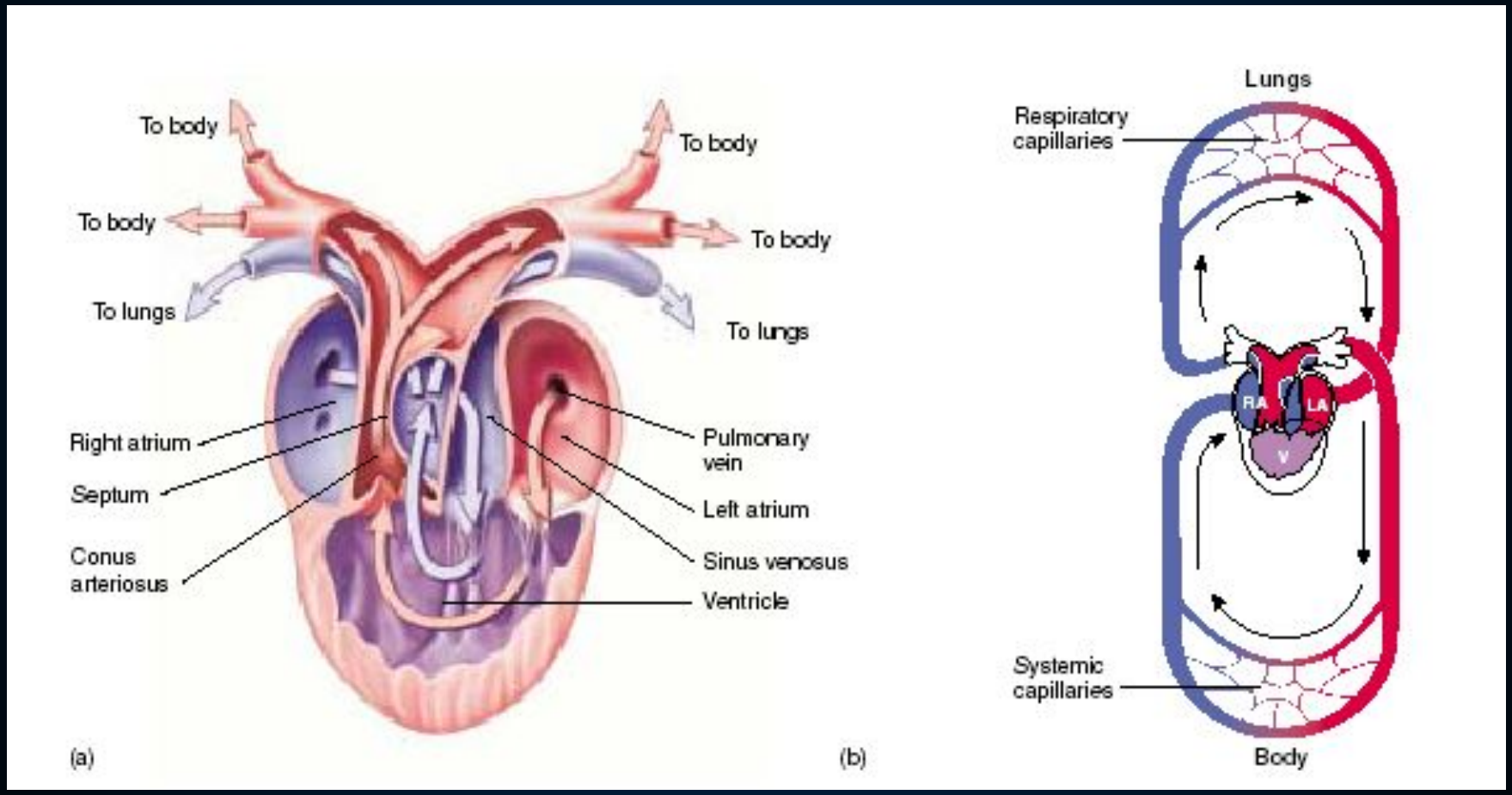

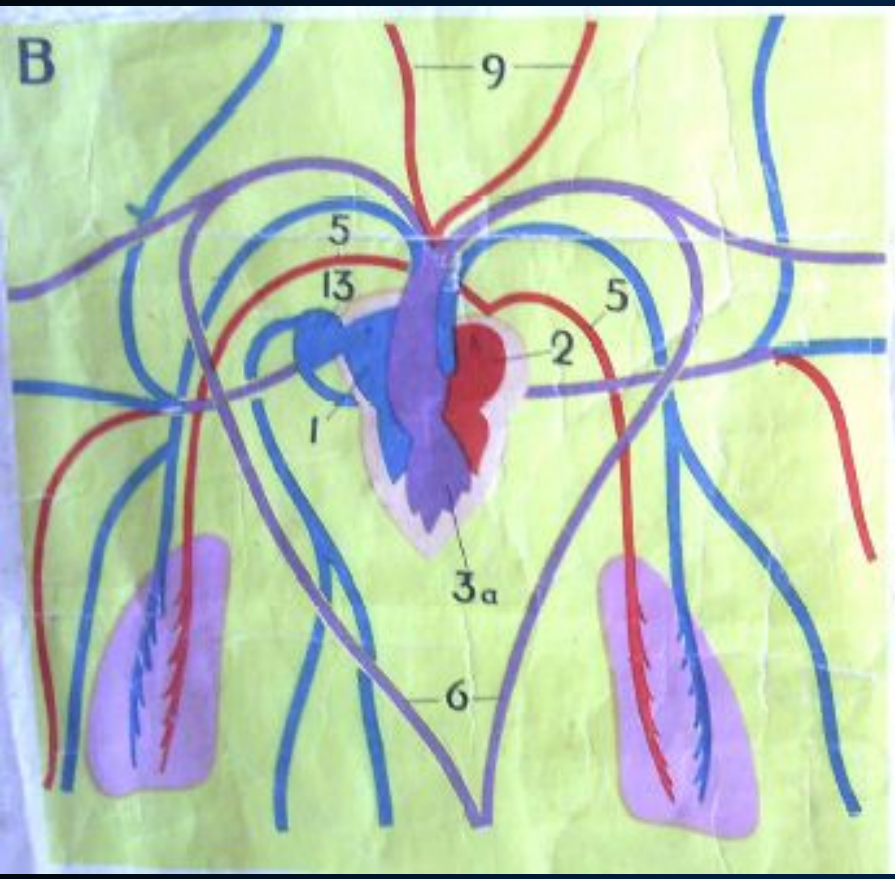

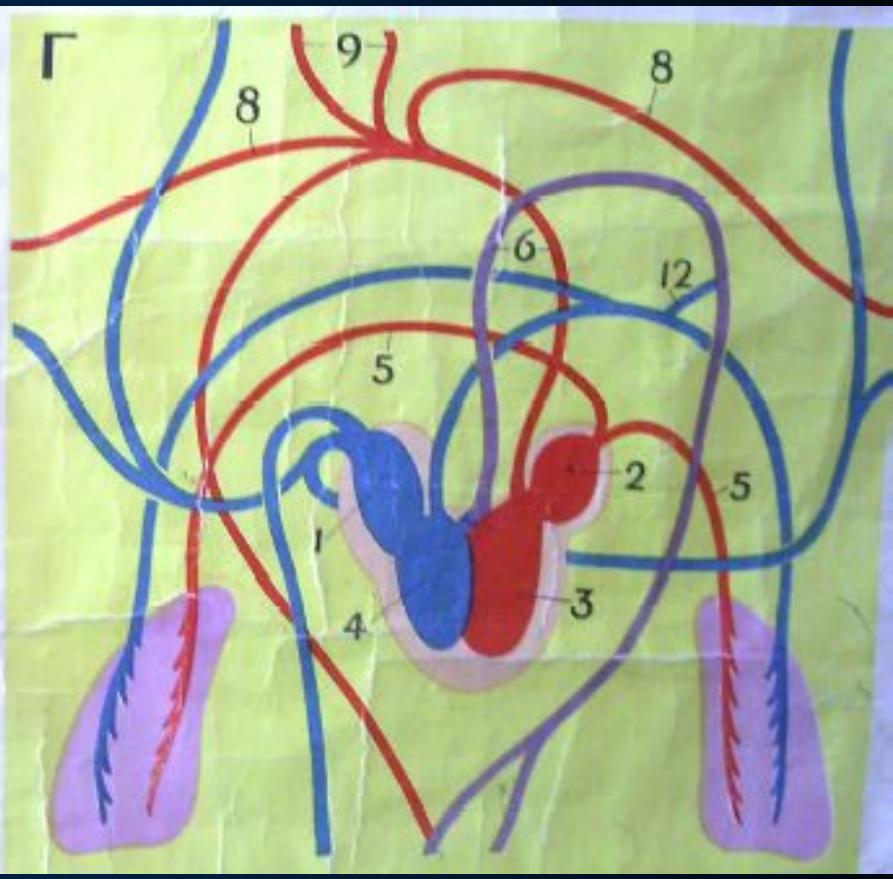

амфибии

пресмыкающиеся

Сердечно-сосудистая система млекопитающих и человека

2 круга кровообращения. 4-х камерное сердце

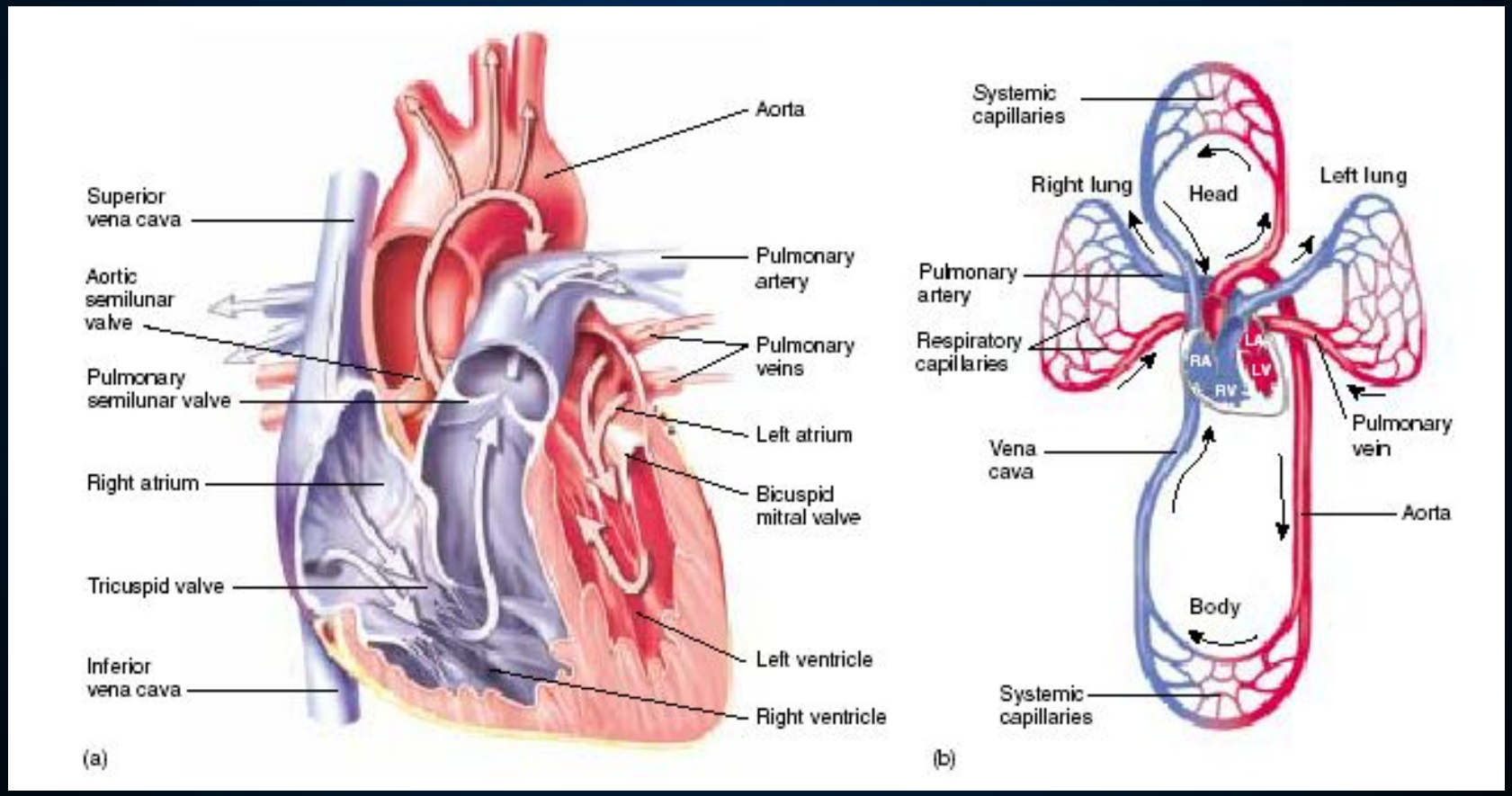

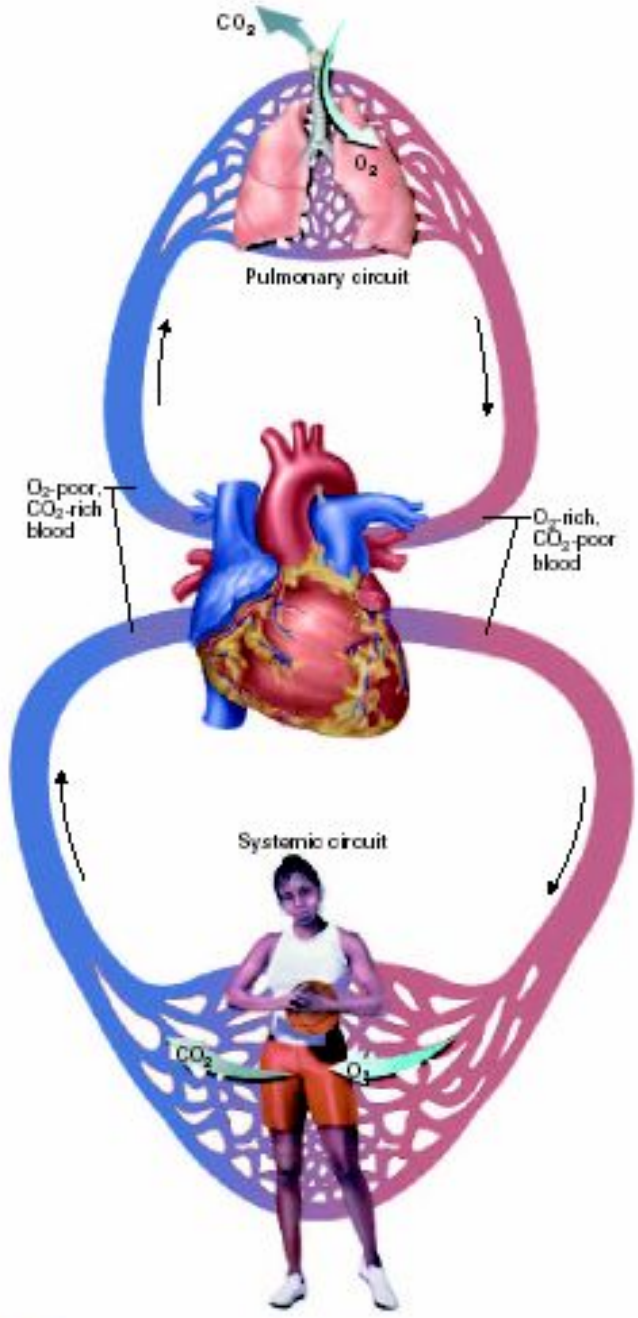

FIGURE 20.1
General Schematic of the Cardiovascular System.

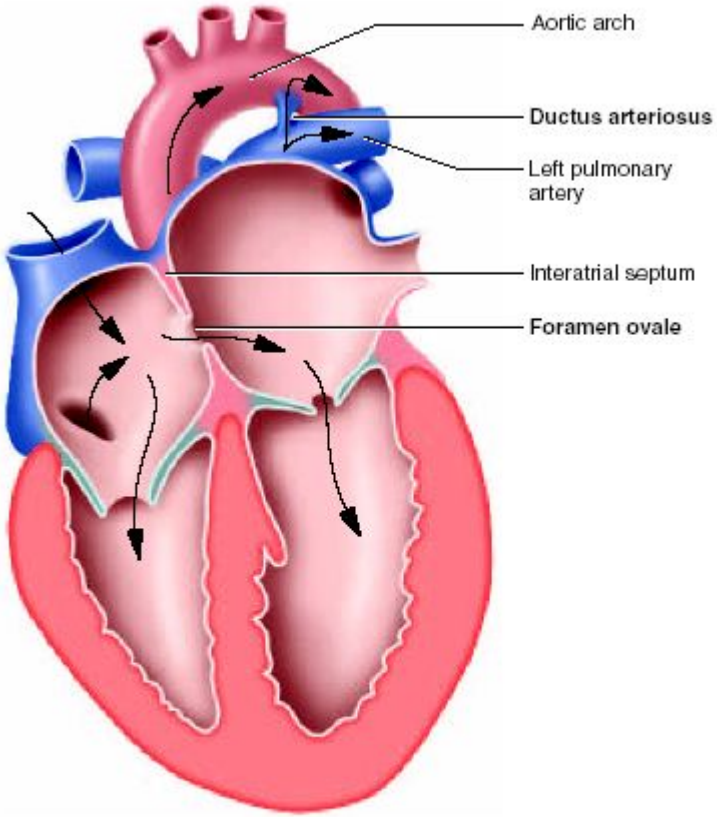

FIGURE 20.16
The Fetal Heart. Note the two shunts (foramen ovale and ductus arteriosus) that allow most blood to bypass the nonfunctional lungs.

Полное разделение большого и малого кругов кровообращений – одна из главных предпосылок возникновения теплокровности

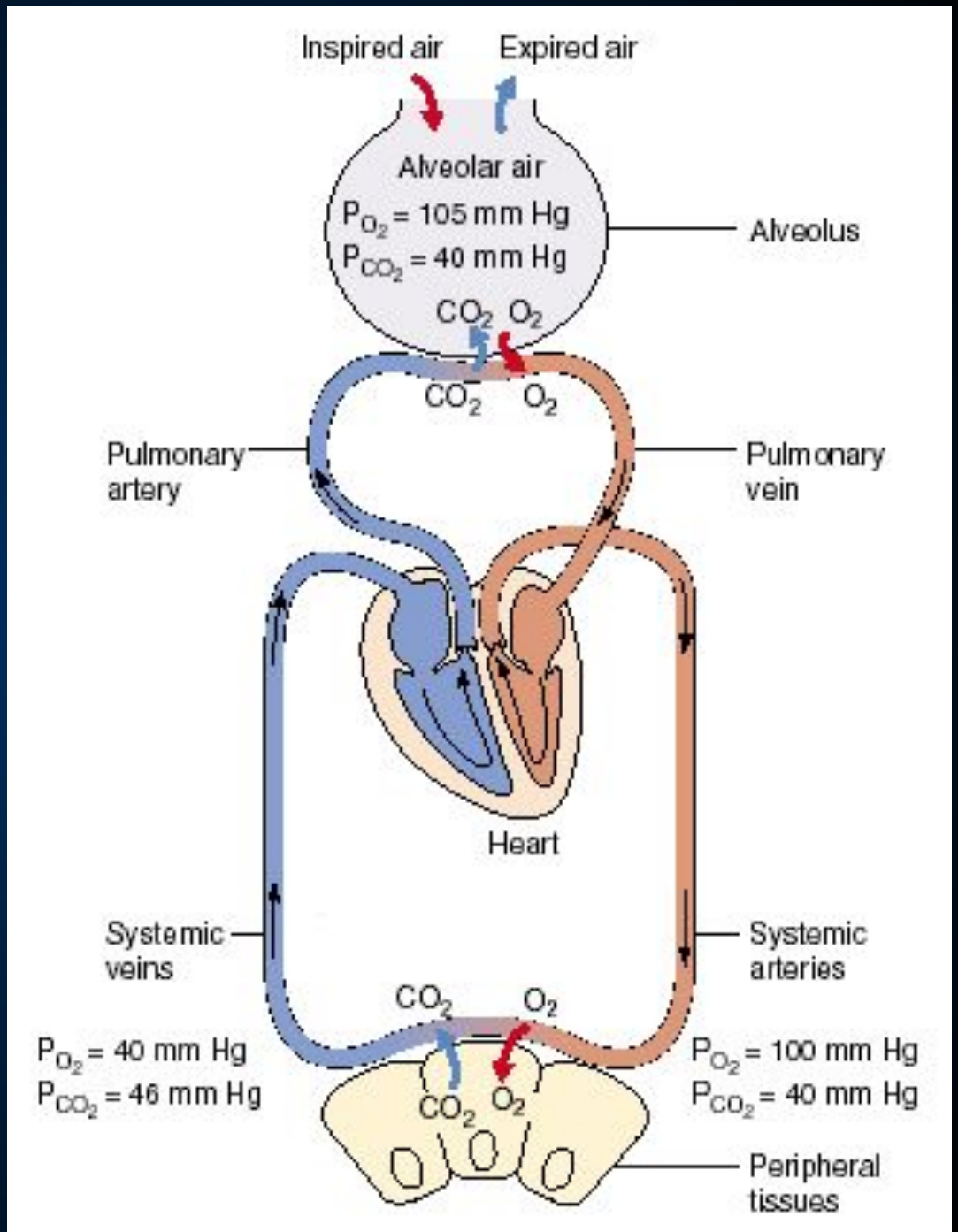

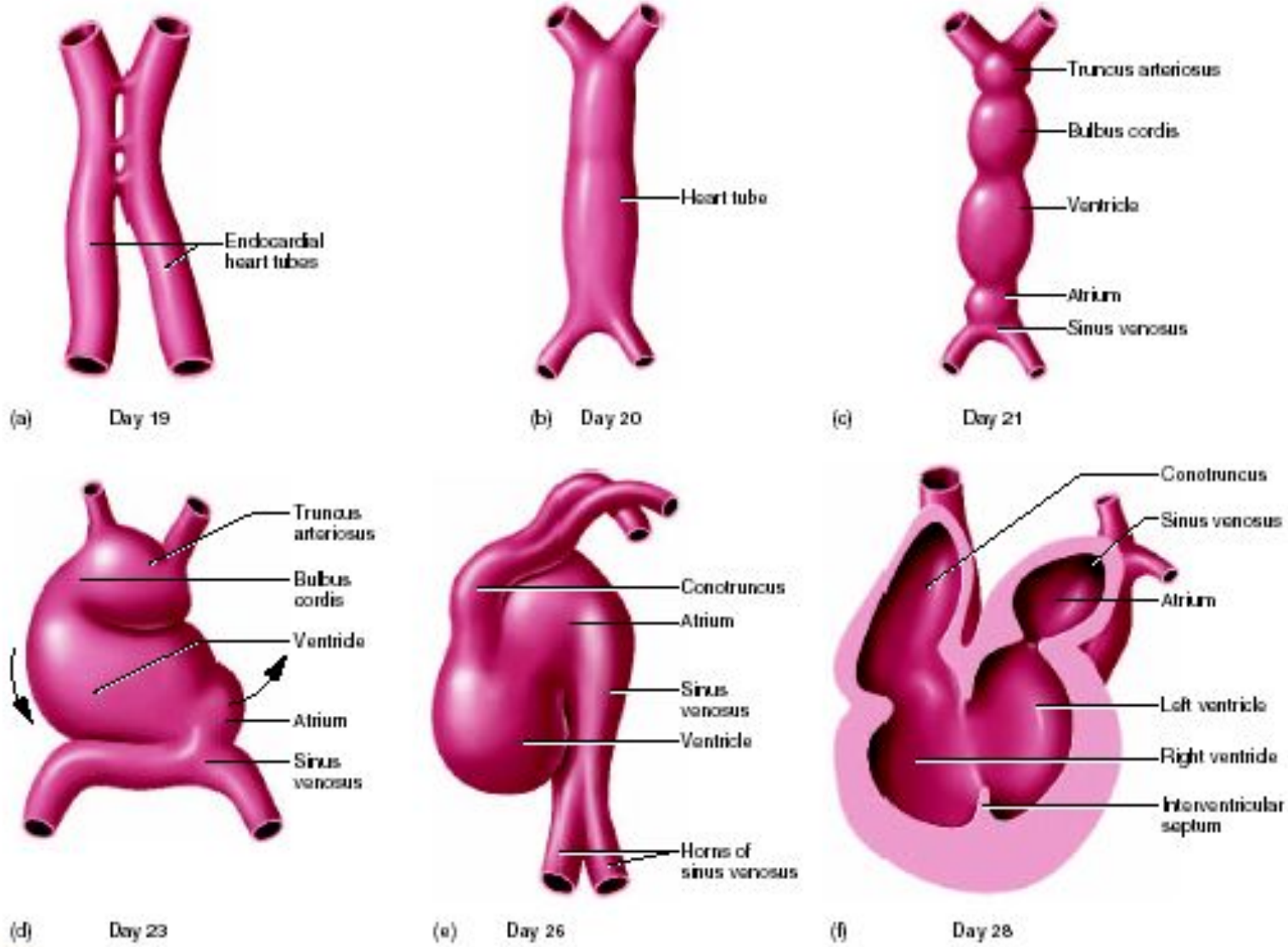

FIGURE 20.15

Embryonic Development of the Heart. (*a*) The endocardial heart tubes beginning to fuse at day 19. (*b*) Complete fusion by day 20, forming the heart tube. (*c*) Division of the heart tube into five dilated segments by day 21. The heart begins beating about a day later. (*d*) The heart begins looping around day 23, with the bulbus cordis migrating caudally *(left arrow)* and the atrium and sinus venosus migrating rostrally *(right arrow)*. Blood circulates throughout the embryo within a day of this stage. (*e*) Looping is nearly completed by day 26. (*f*) Frontal section of the heart at 28 days. As the interventricular septum develops, the conotruncus will divide longitudinally into the ascending aorta and pulmonary trunk, receiving blood from the left and right ventricles, respectively. The single atrium seen here divides into the right and left atria by day 33.

Филогенетическое преобразования жаберных дуг хордовых

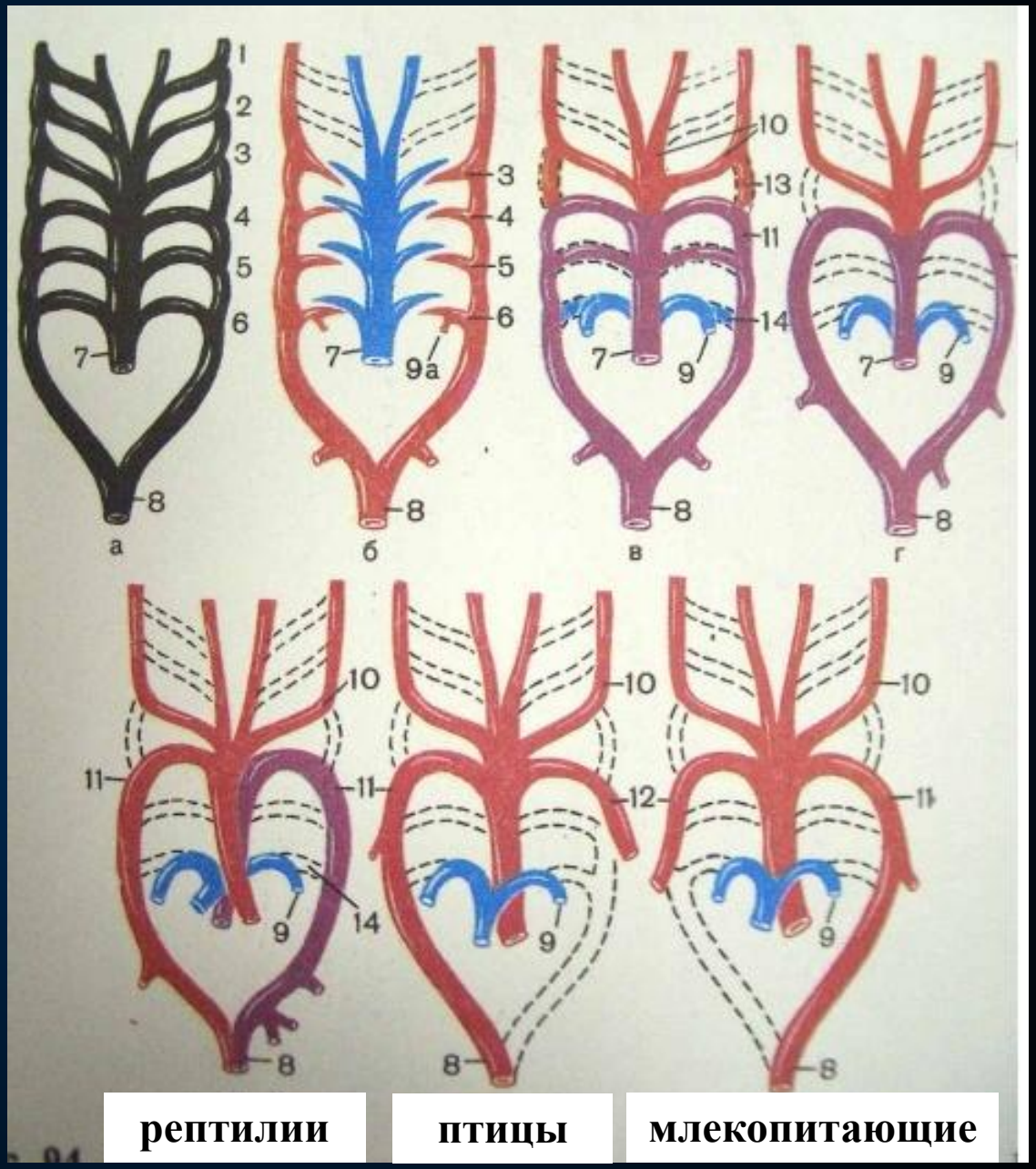

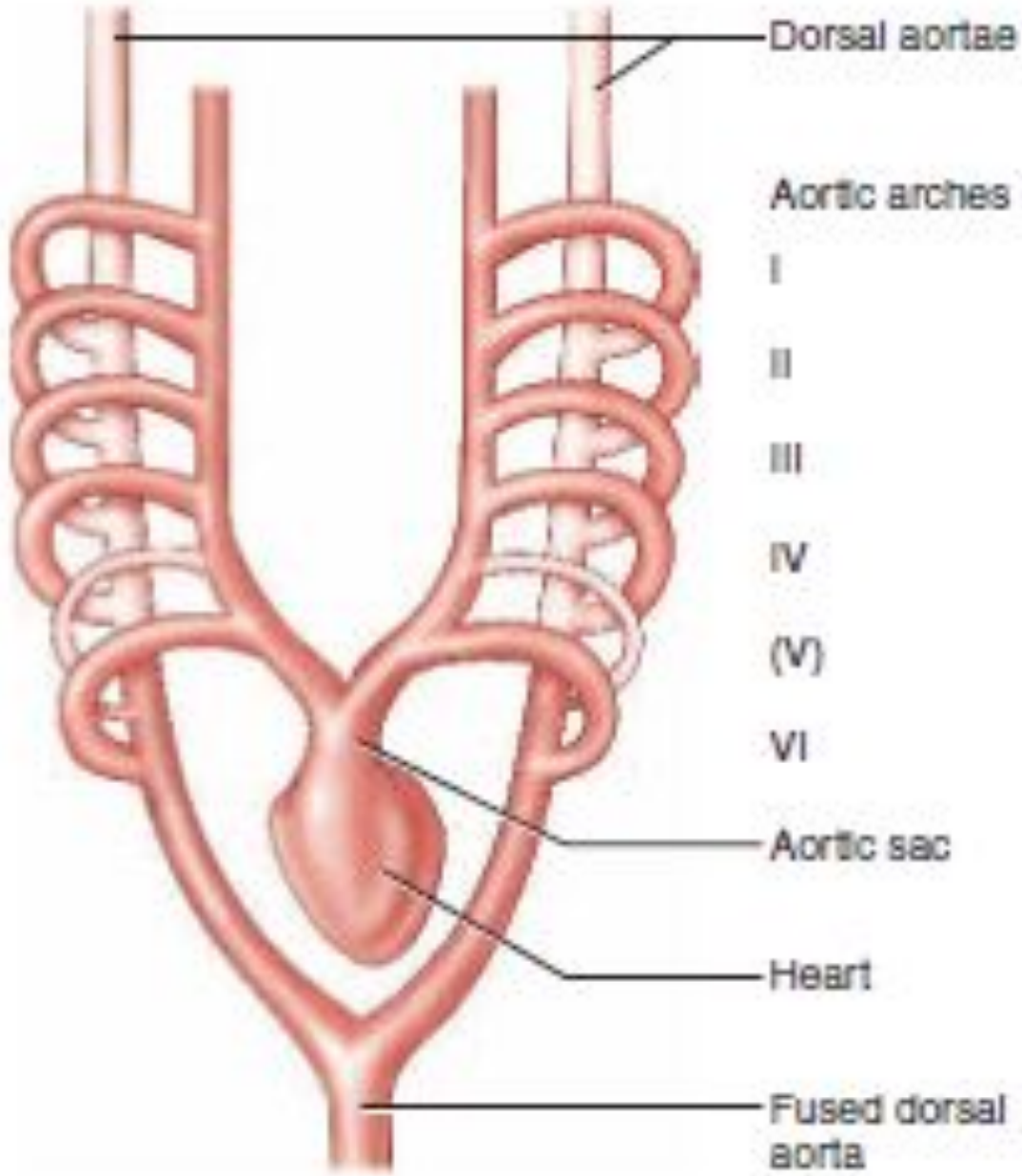
Dorsal aortae
Aortic arches
I
II
III
IV
(V)
VI
Aortic sac
Heart
Fused dorsal aorta

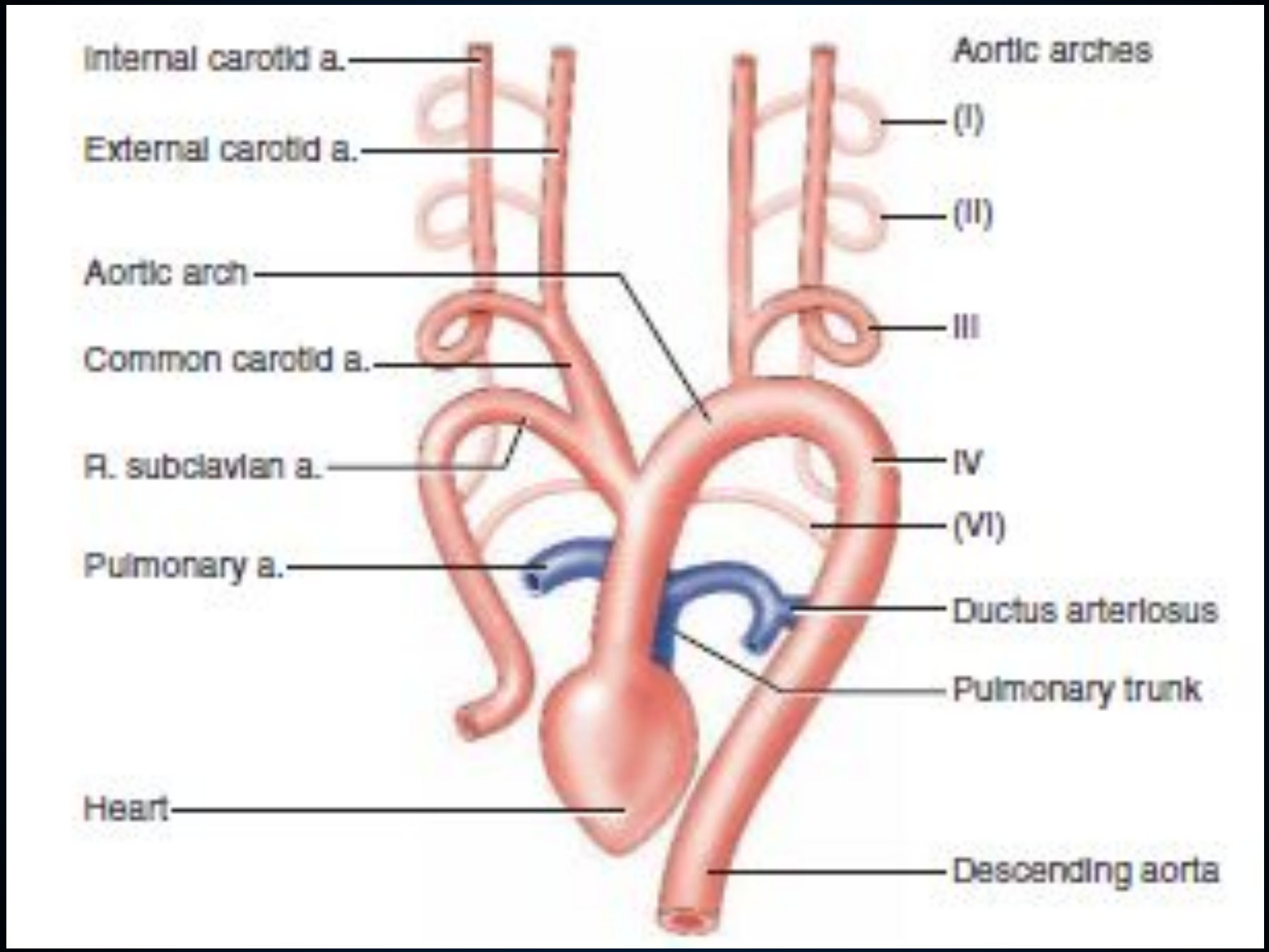
Internal carotid a.
External carotid a.
Aortic arch
Common carotid a.
R. subclavian a.
Pulmonary a.
Heart
Aortic arches
(I)
(II)
III
IV
(VI)
Ductus arteriosus
Pulmonary trunk
Descending aorta

Филогенез пищеварительной системы хордовых

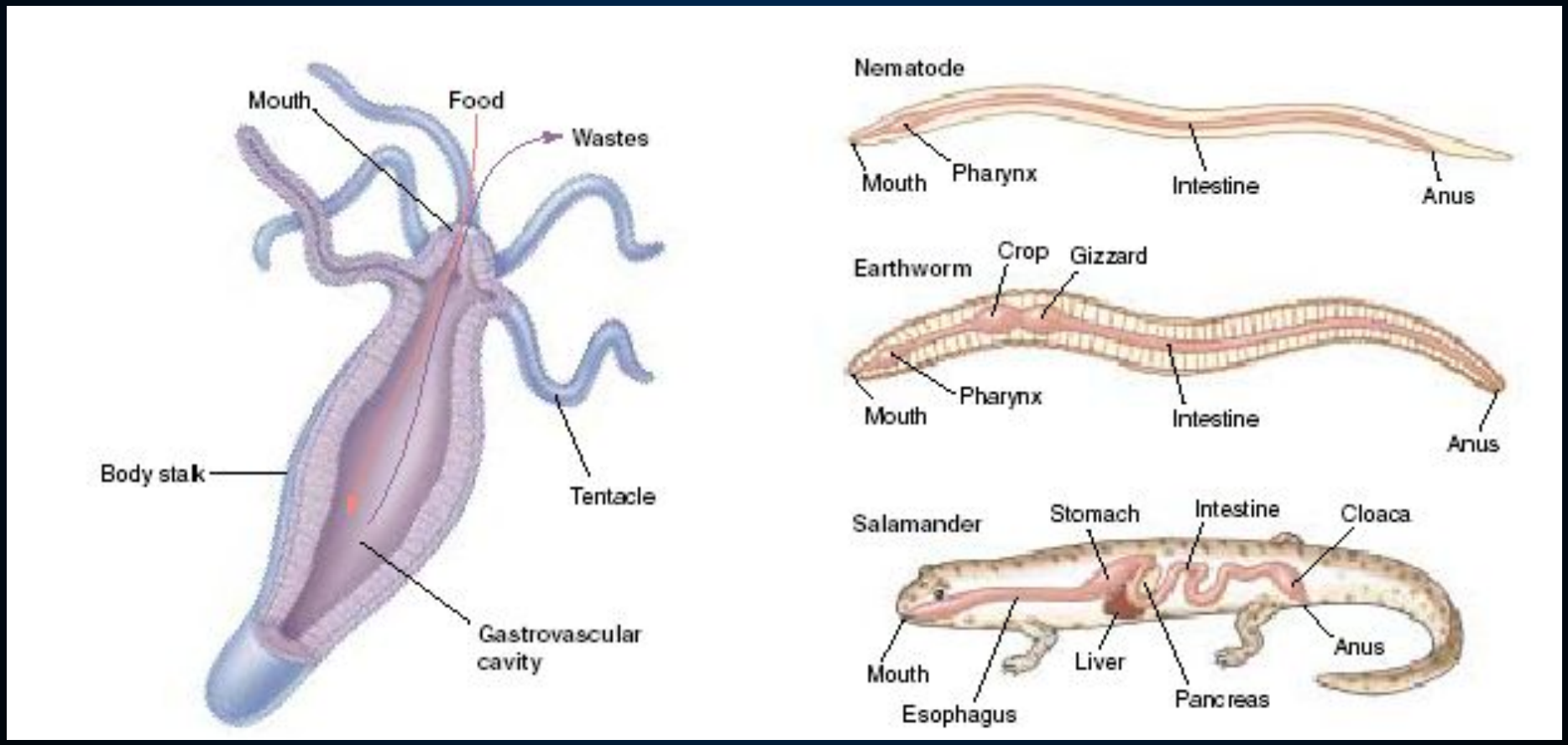

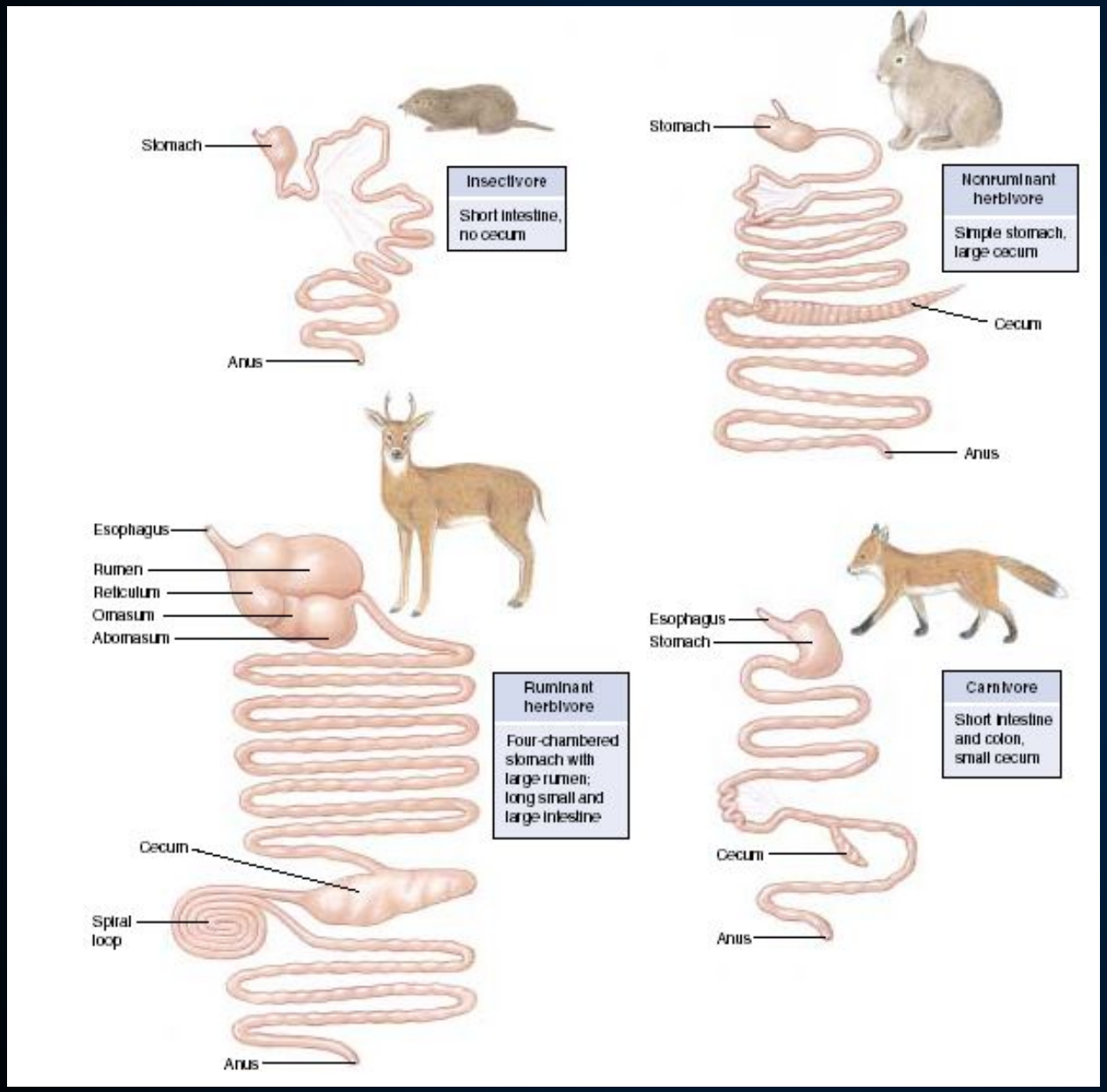
Stomach
Insectivore
Short intestine, no cecum
Anus
Stomach
Nonruminant herbivore
Simple stomach, large cecum
Cecum
Anus
Esophagus
Rumen
Reticulum
Omasum
Abomasum
Ruminant herbivore
Four-chambered stomach with large rumen; long small and large intestine
Cecum
Spiral loop
Anus
Esophagus
Stomach
Carnivore
Short intestine and colon, small cecum
Cecum
Anus

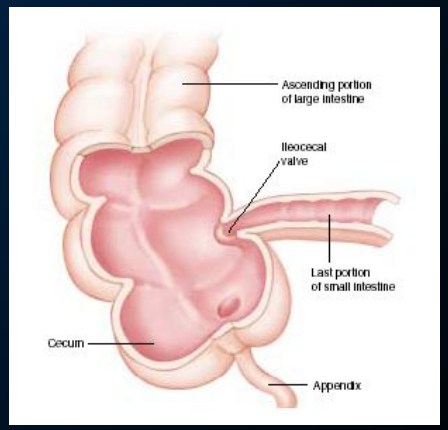
Ascending portion of large intestine
Ileocecal valve
Last portion of small intestine
Cecum
Appendix

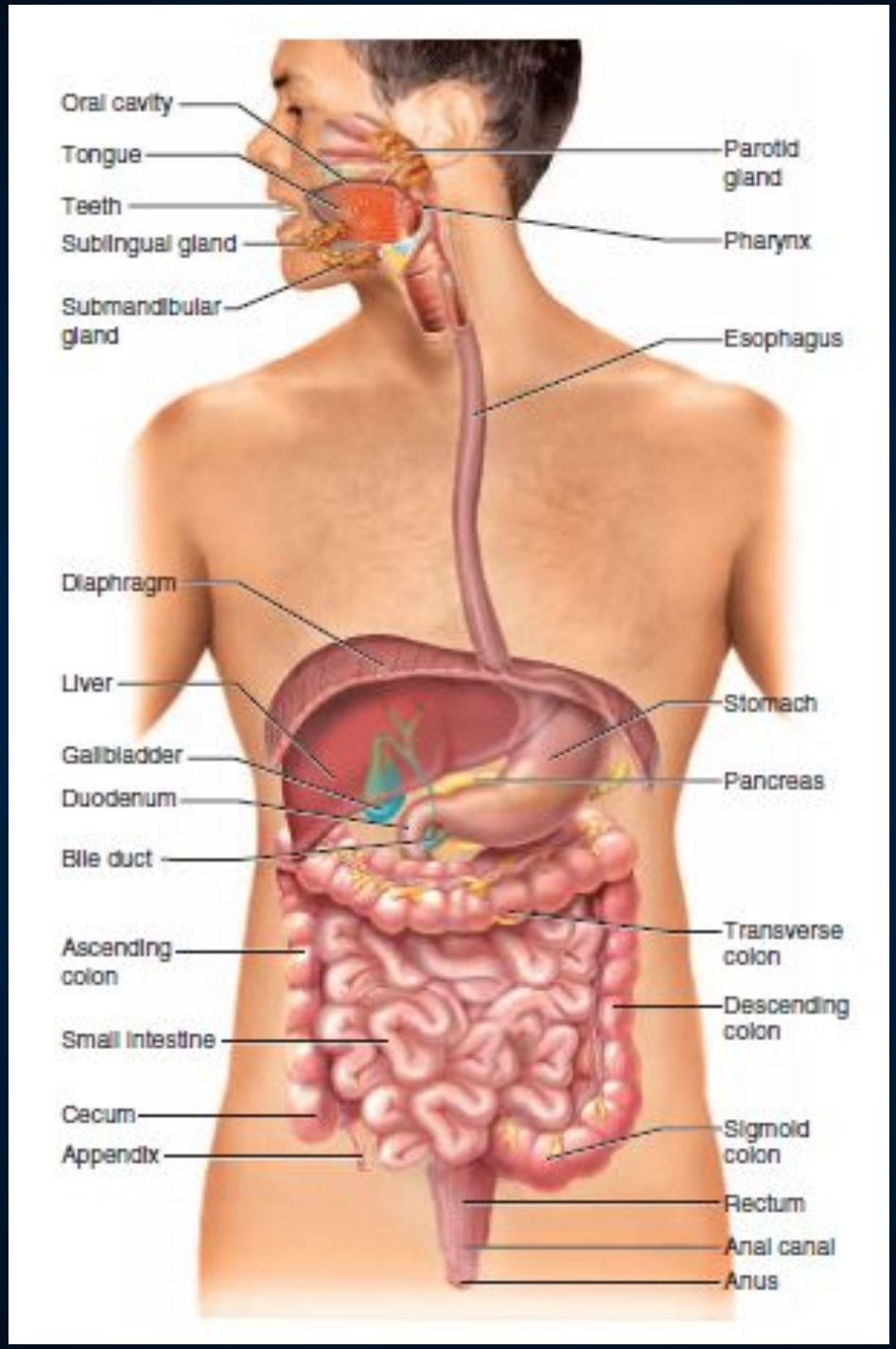
Oral cavity
Tongue
Teeth
Sublingual gland
Submandibular gland
Parotid gland
Pharynx
Esophagus
Diaphragm
Liver
Gallbladder
Duodenum
Bile duct
Stomach
Pancreas
Ascending colon
Small intestine
Cecum
Appendix
Transverse colon
Descending colon
Sigmoid colon
Rectum
Anal canal
Anus

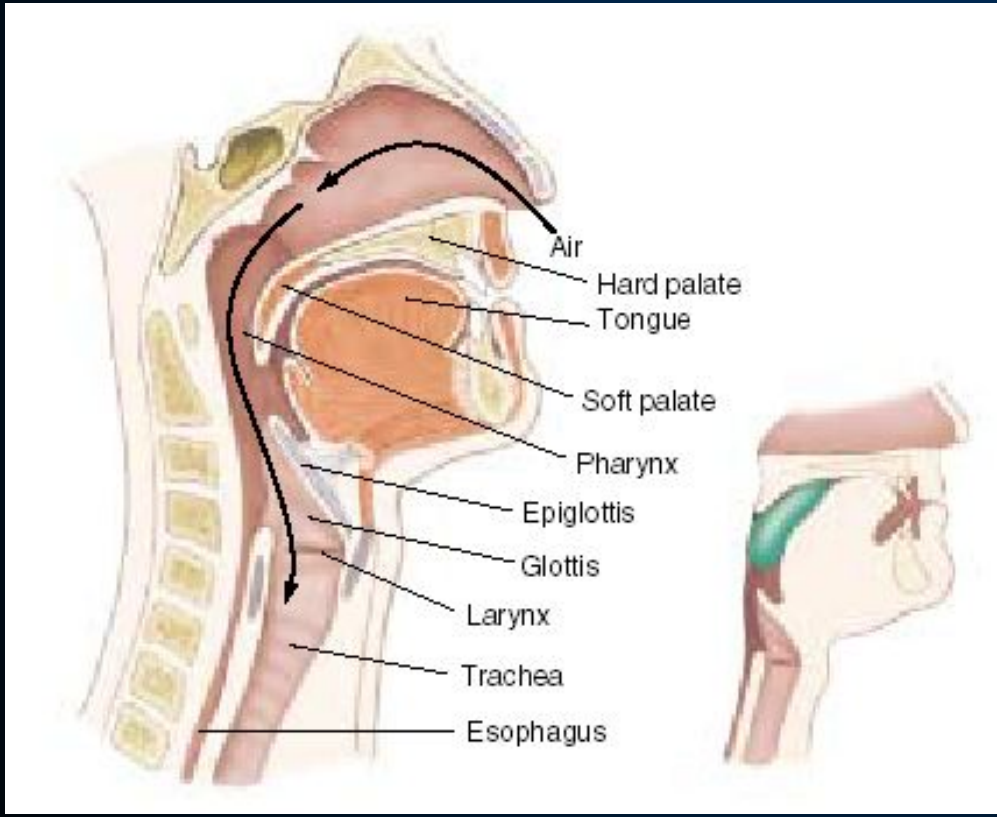
Air
Hard palate
Tongue
Soft palate
Pharynx
Epiglottis
Glottis
Larynx
Trachea
Esophagus

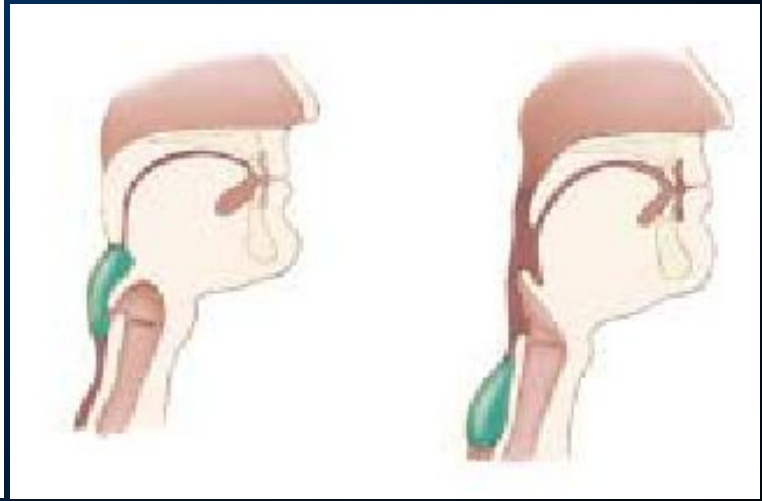

Филогенез дыхательной системы хордовых

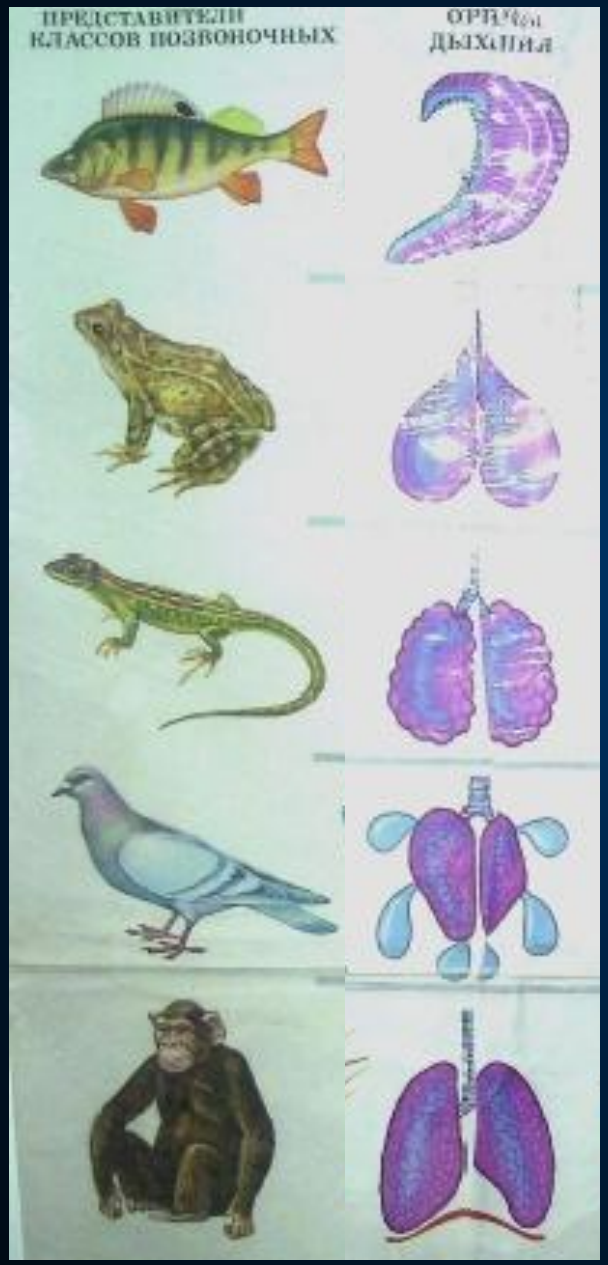

Жаберное дыхание у рыб

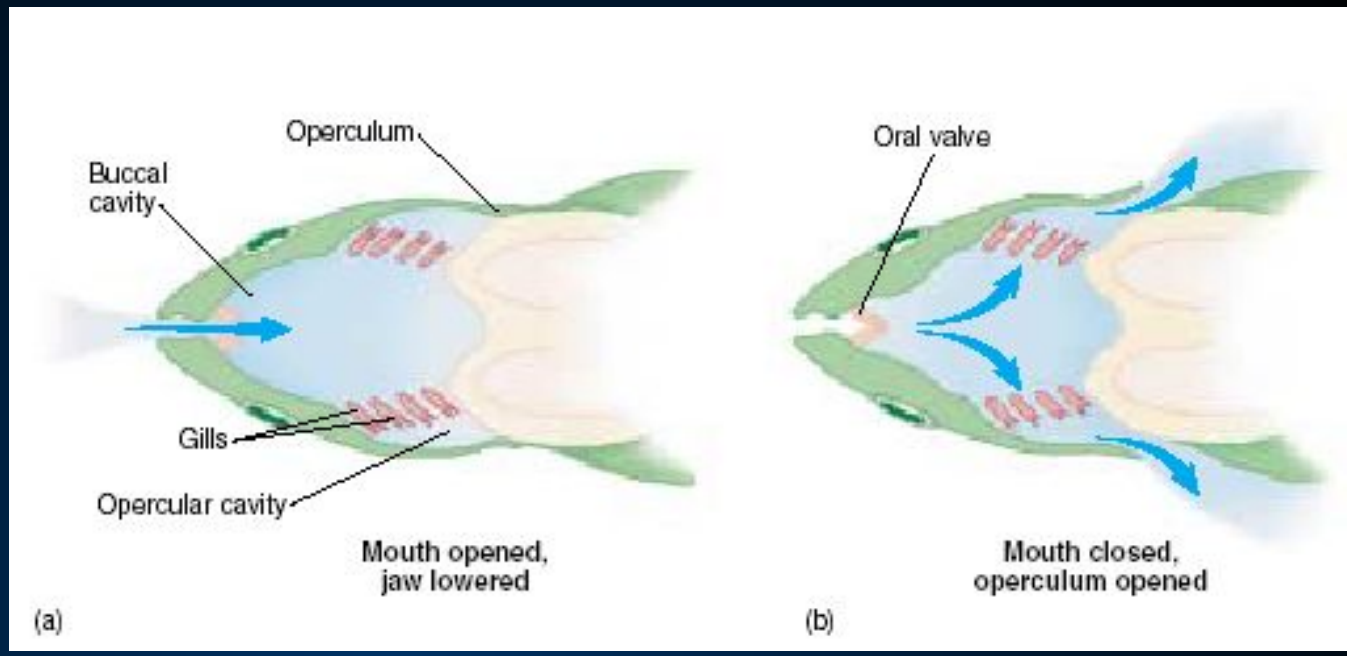

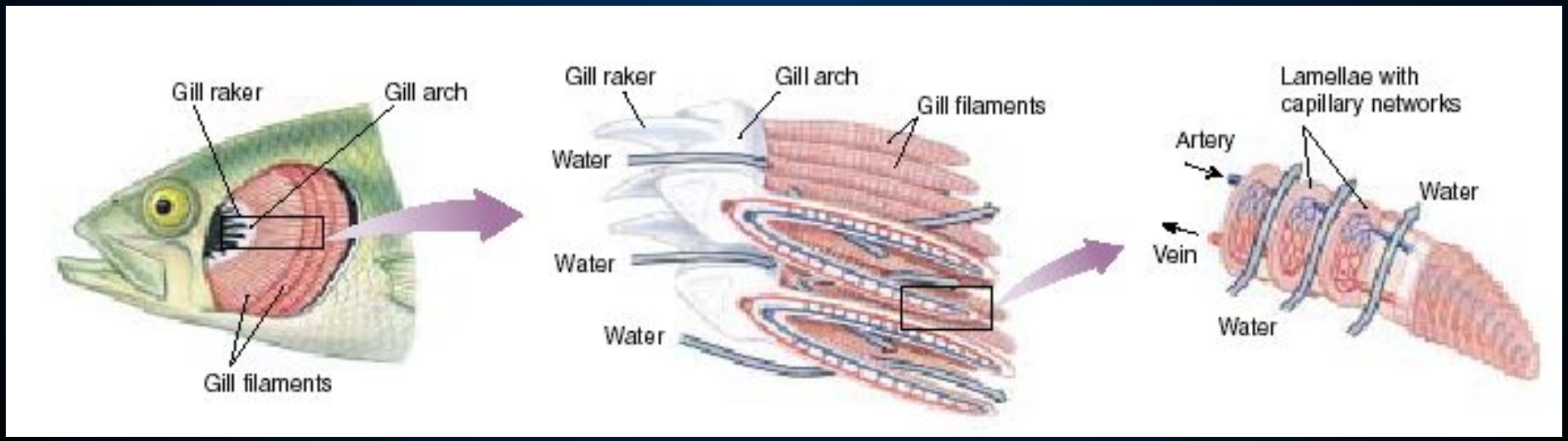

Появление легочных мешков у земноводных

(производные плавательного пузыря рыб)

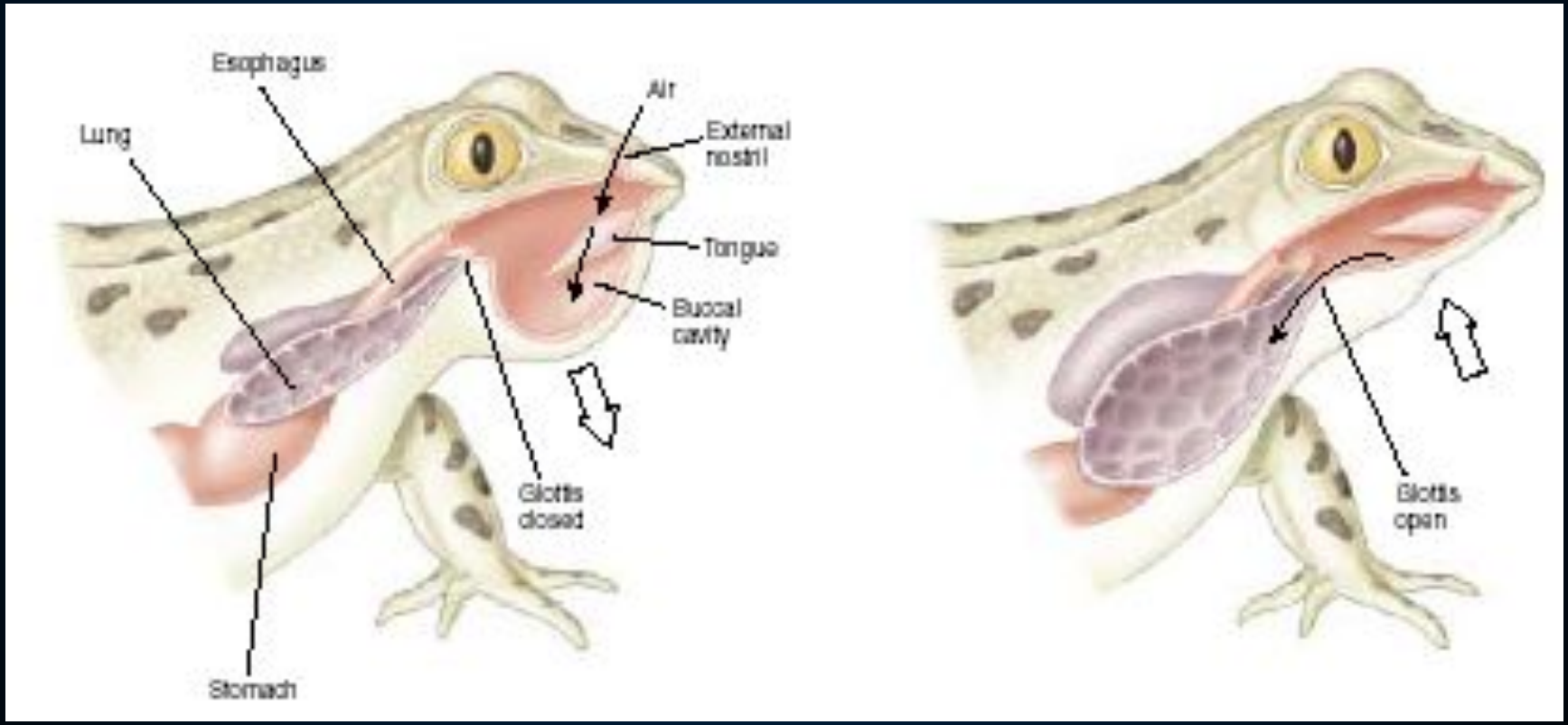

Крупноячеистые легкие у птиц

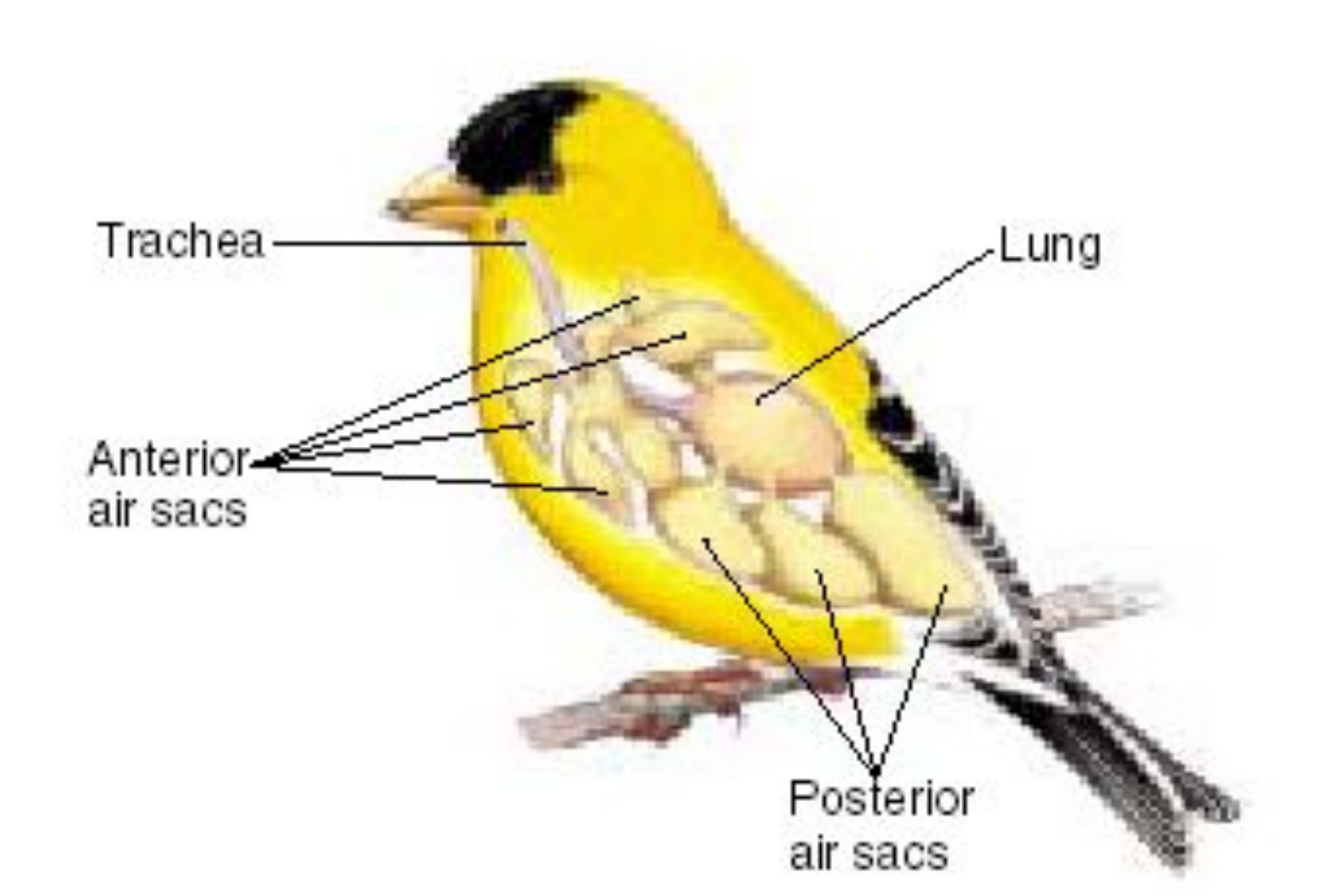

Органы дыхания у человека:

Нос носоглотка гортань трахея бронхи бронхиолы альвеолы

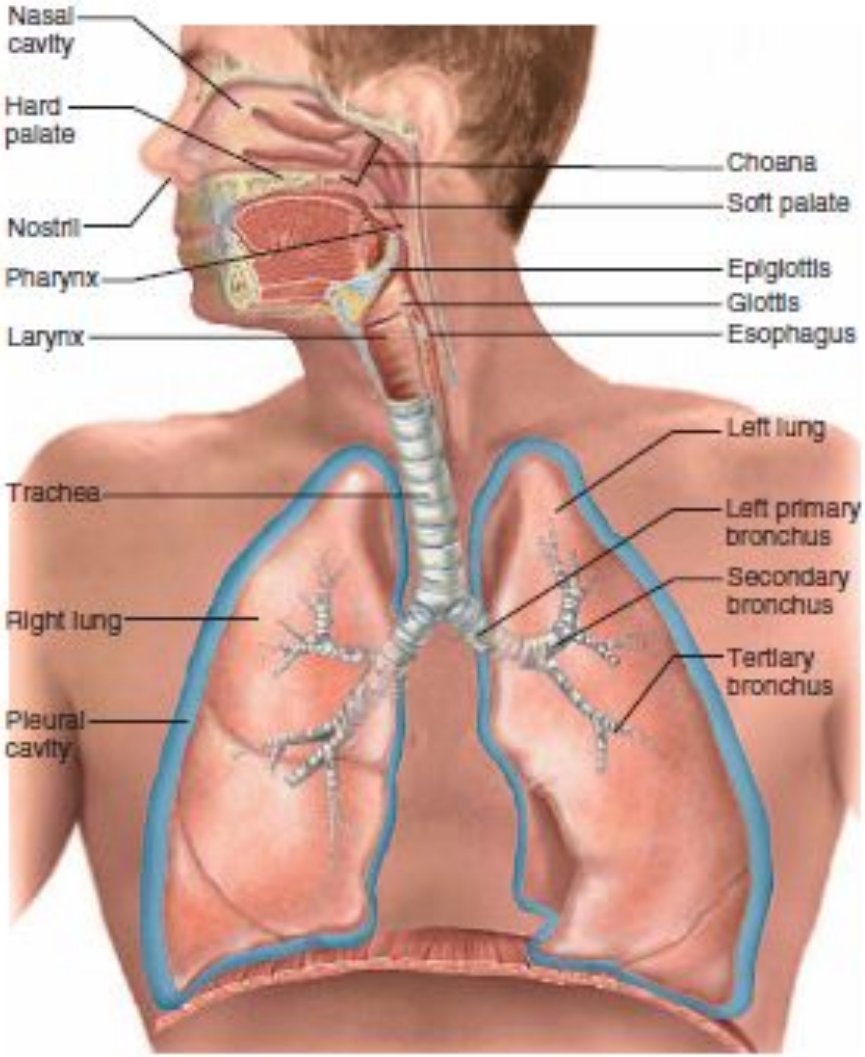

FIGURE 23.1
The Respiratory System.

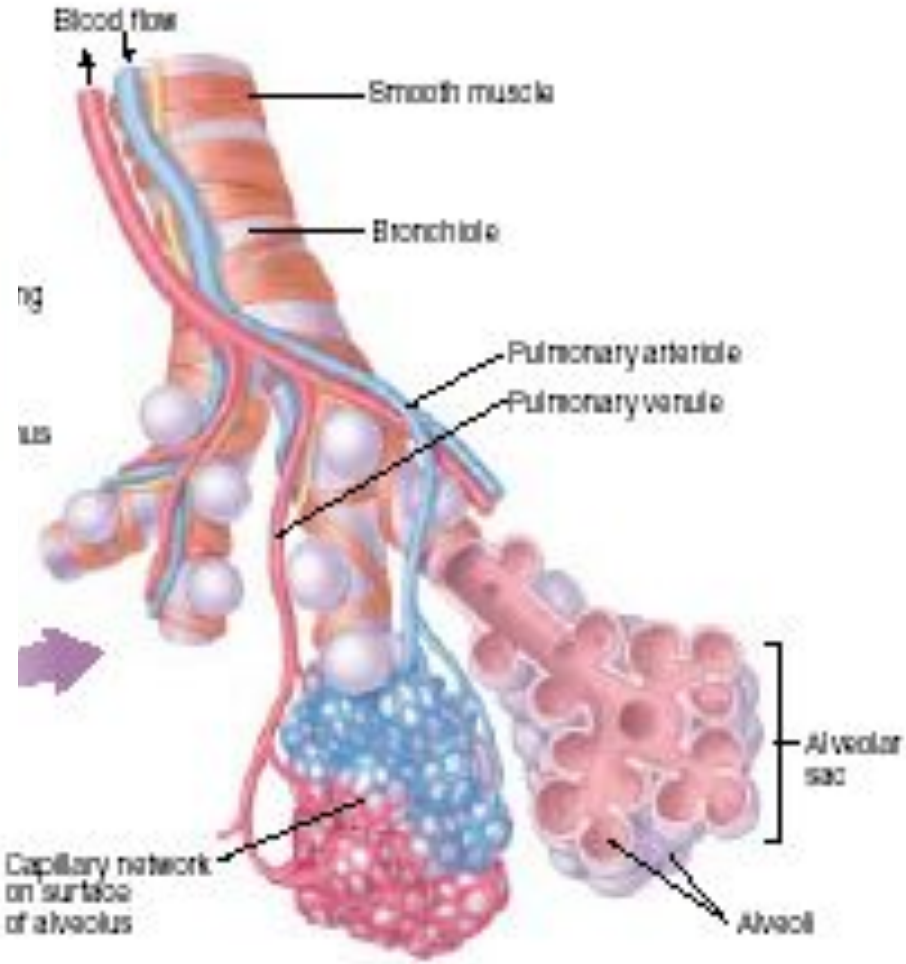

Онтогенез органов дыхания у млекопитающих

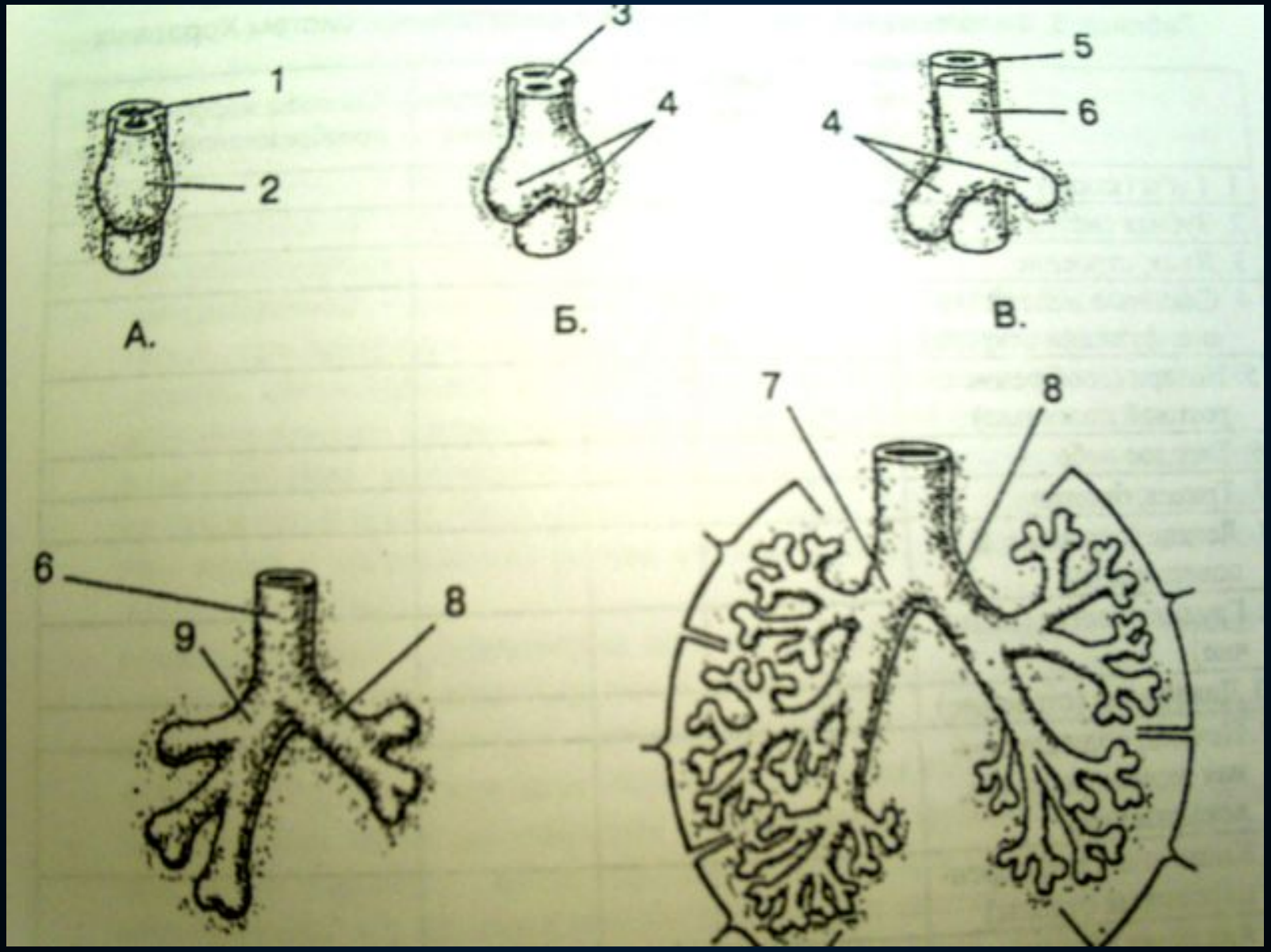

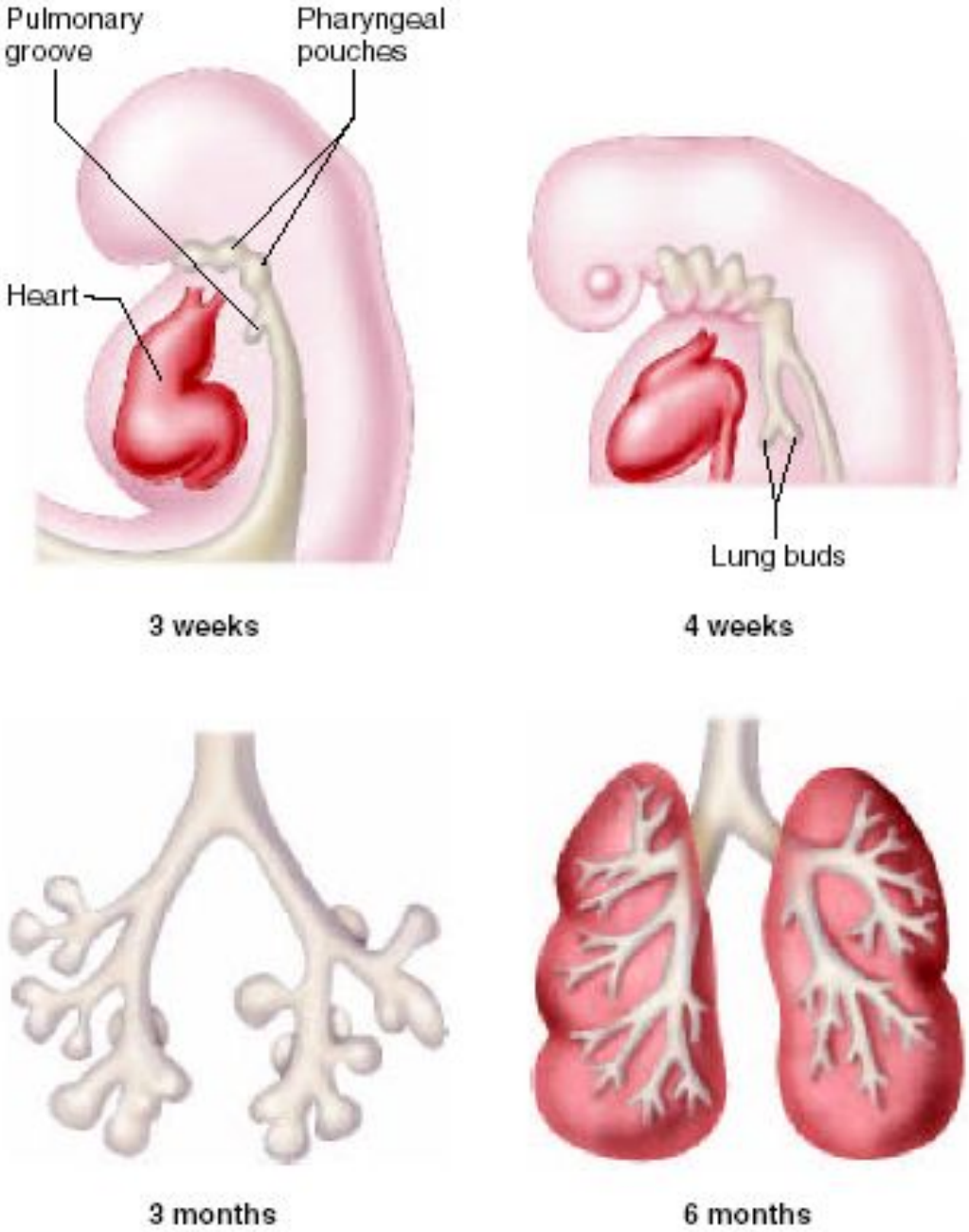

FIGURE 23.15

Embryonic Development of the Respiratory System.

Филогенез мочевыделительной системы хордовых

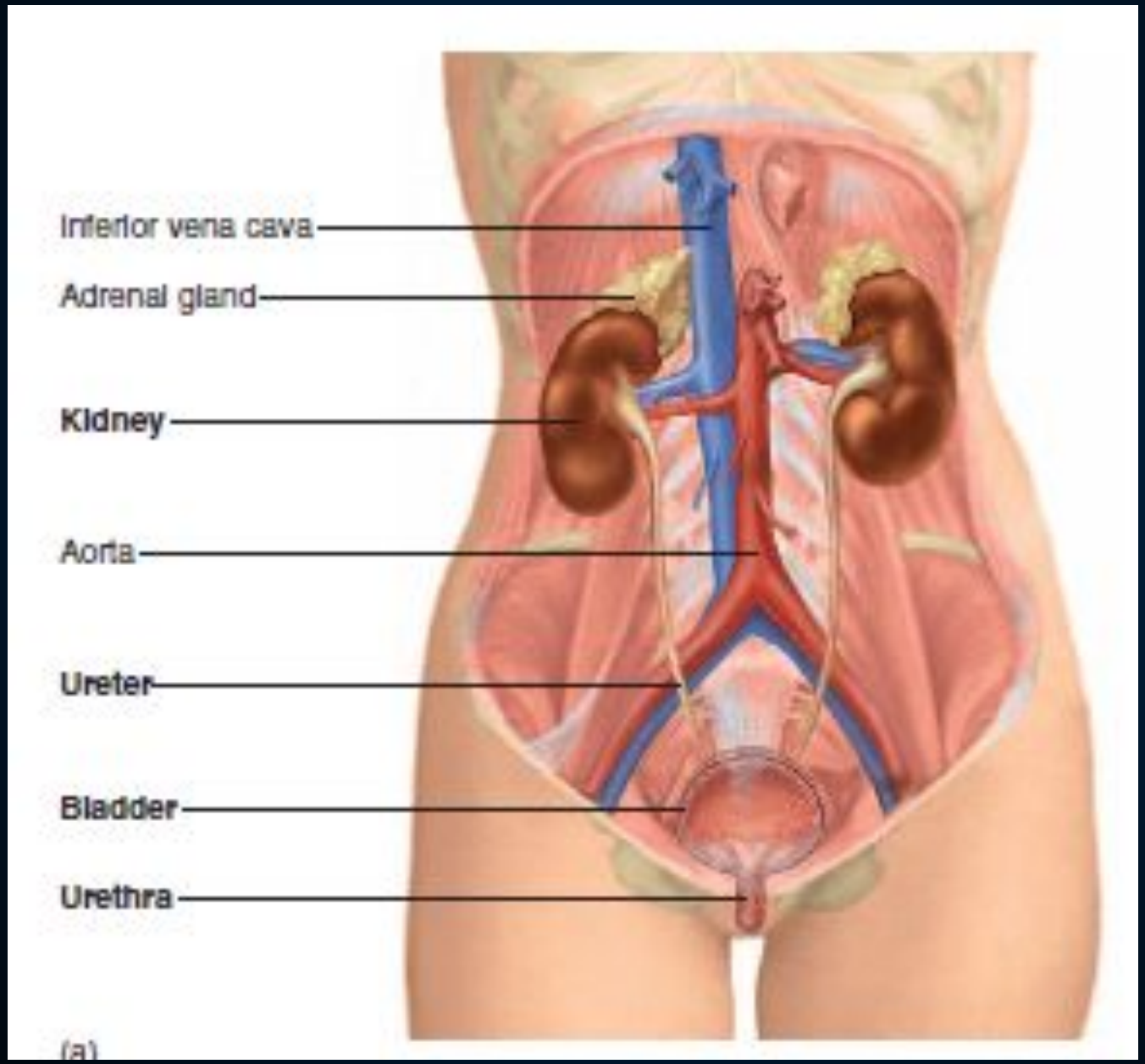

Филогенез мочевыделительной системы хордовых

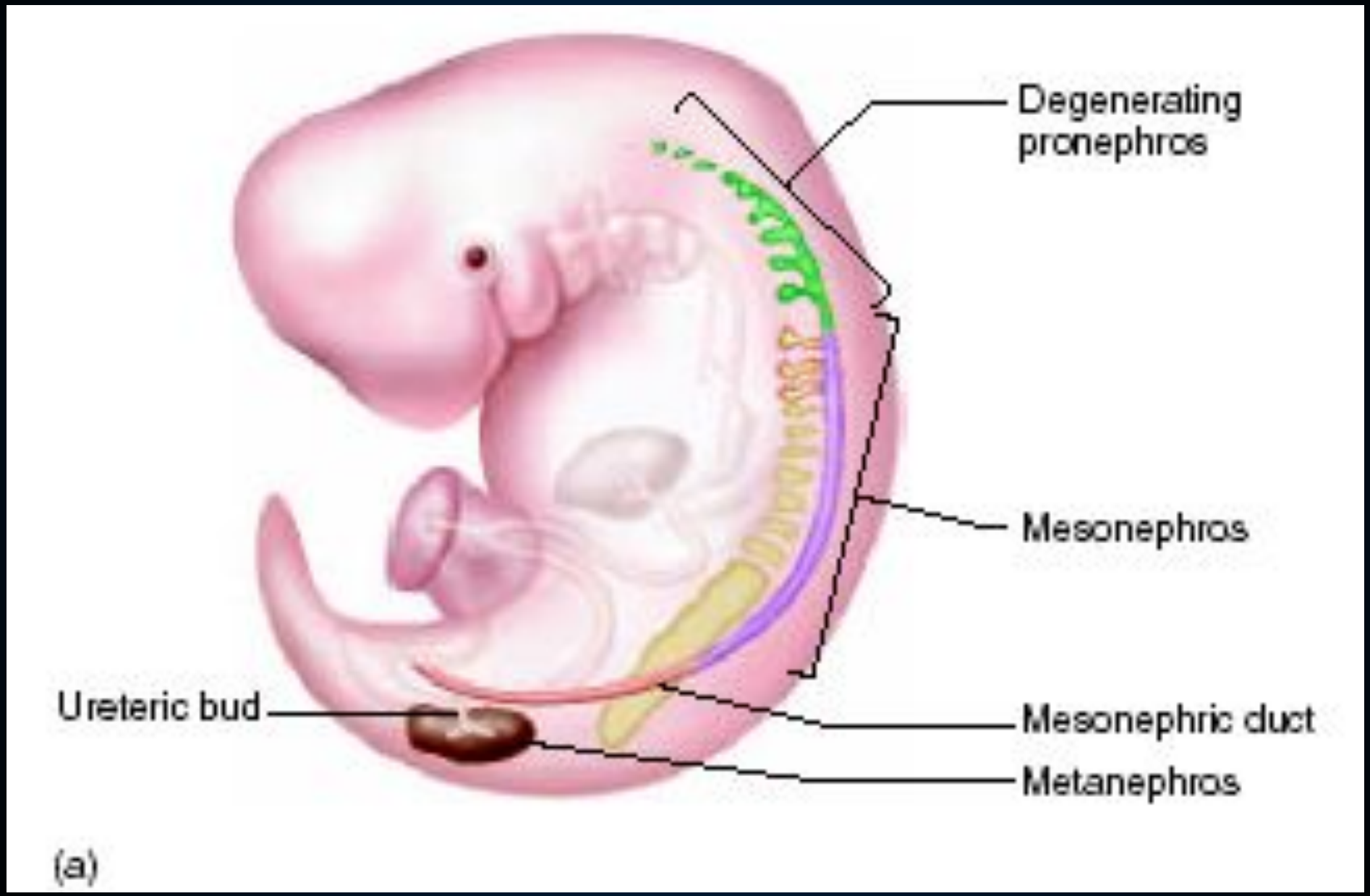

Филогенез мочеполовой системы хордовых:

предпочка у рыб

первичная почка у земноводных

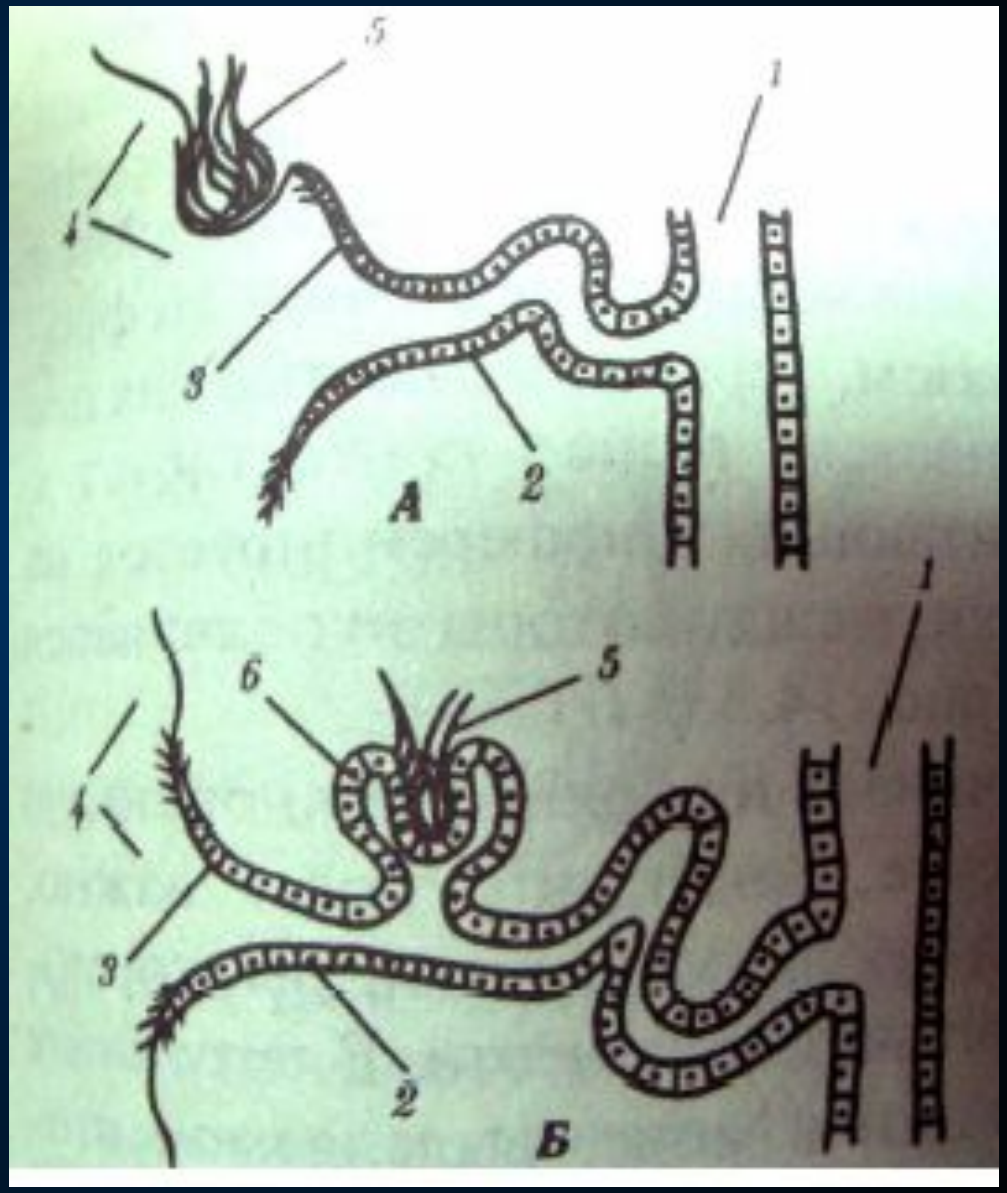

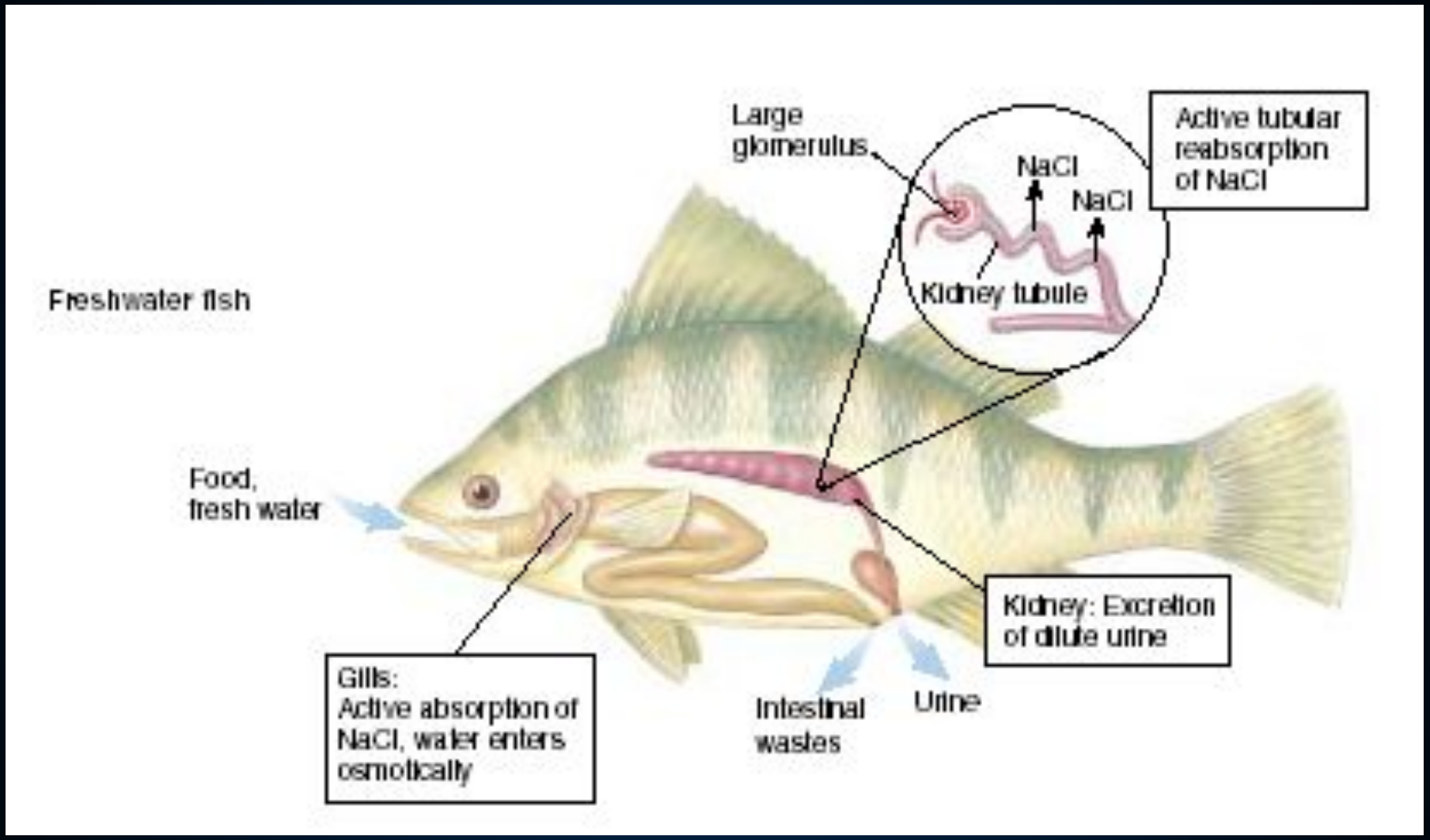
Freshwater fish
Large glomerulus
NaCl
NaCl
Kidney tubule
Active tubular reabsorption of NaCl
Food, fresh water
Kidney: Excretion of dilute urine
Gills: Active absorption of NaCl, water enters osmotically
Intestinal wastes
Urine

Филогенез мочеполовой системы хордовых: вторичная почка у млекопитающих

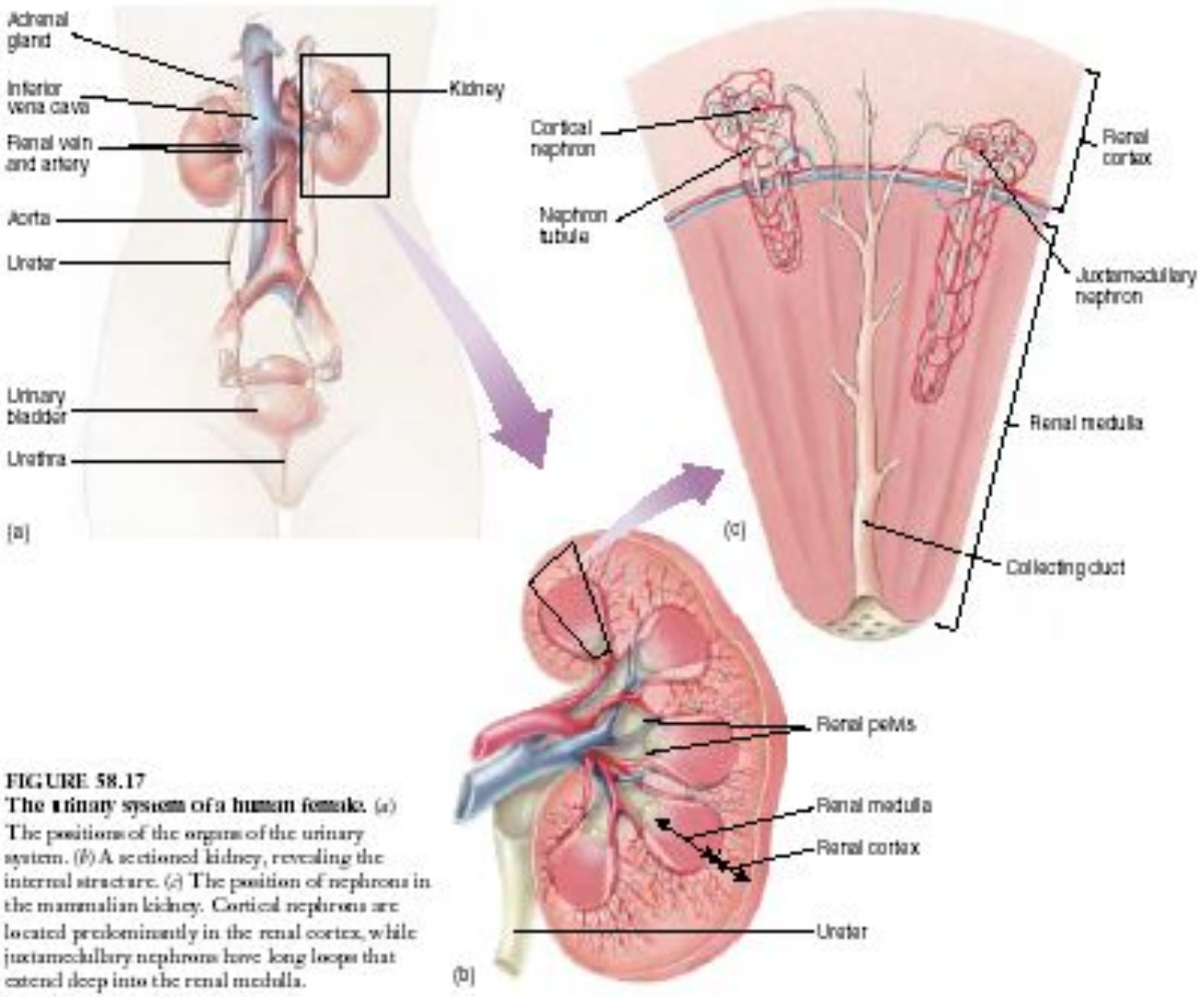

FIGURE 58.17
The urinary system of a human female. (*a*) The positions of the organs of the urinary system. (*b*) A sectioned kidney, revealing the internal structure. (*c*) The position of nephrons in the mammalian kidney. Cortical nephrons are located predominantly in the renal cortex, while juxtamedullary nephrons have long loops that extend deep into the renal medulla.

Филогенез мочеполовой системы хордовых:

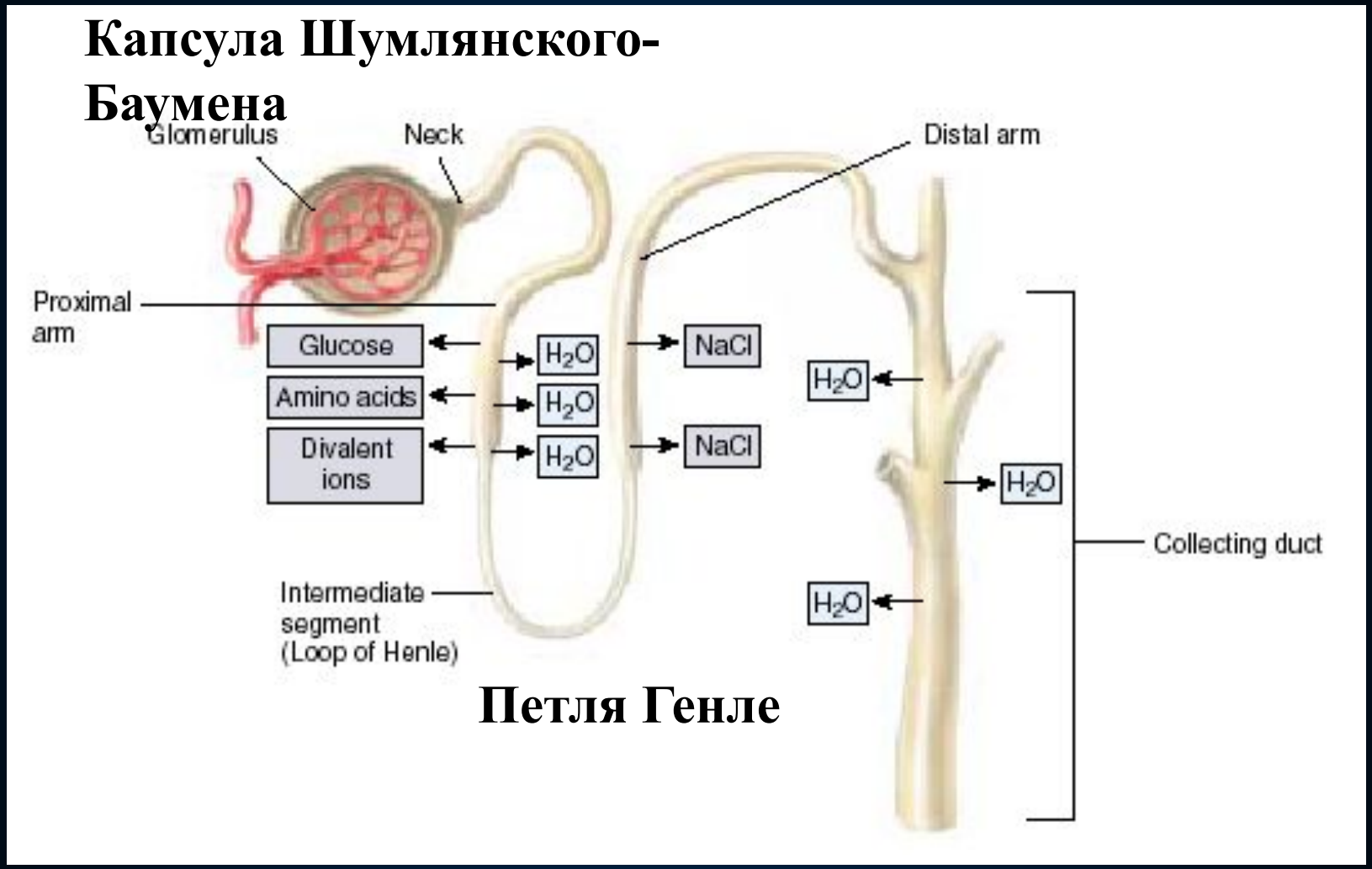

основные структурные элементы нефрона

Филогенез мочеполовой системы хордовых: вторичная почка у млекопитающих

Капсула Шумлянского-Баумена

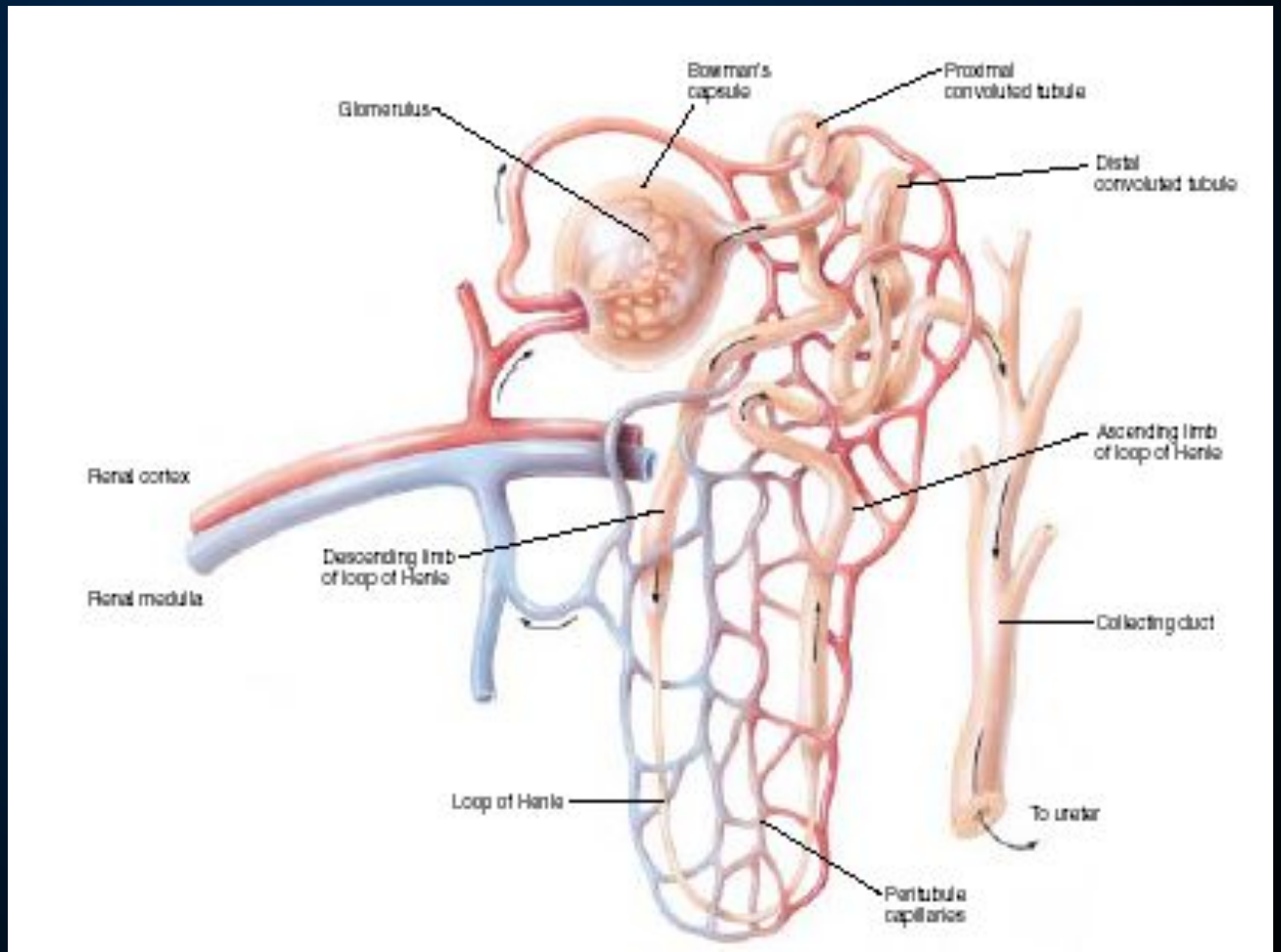

Петля Генле

Строение почечного тельца

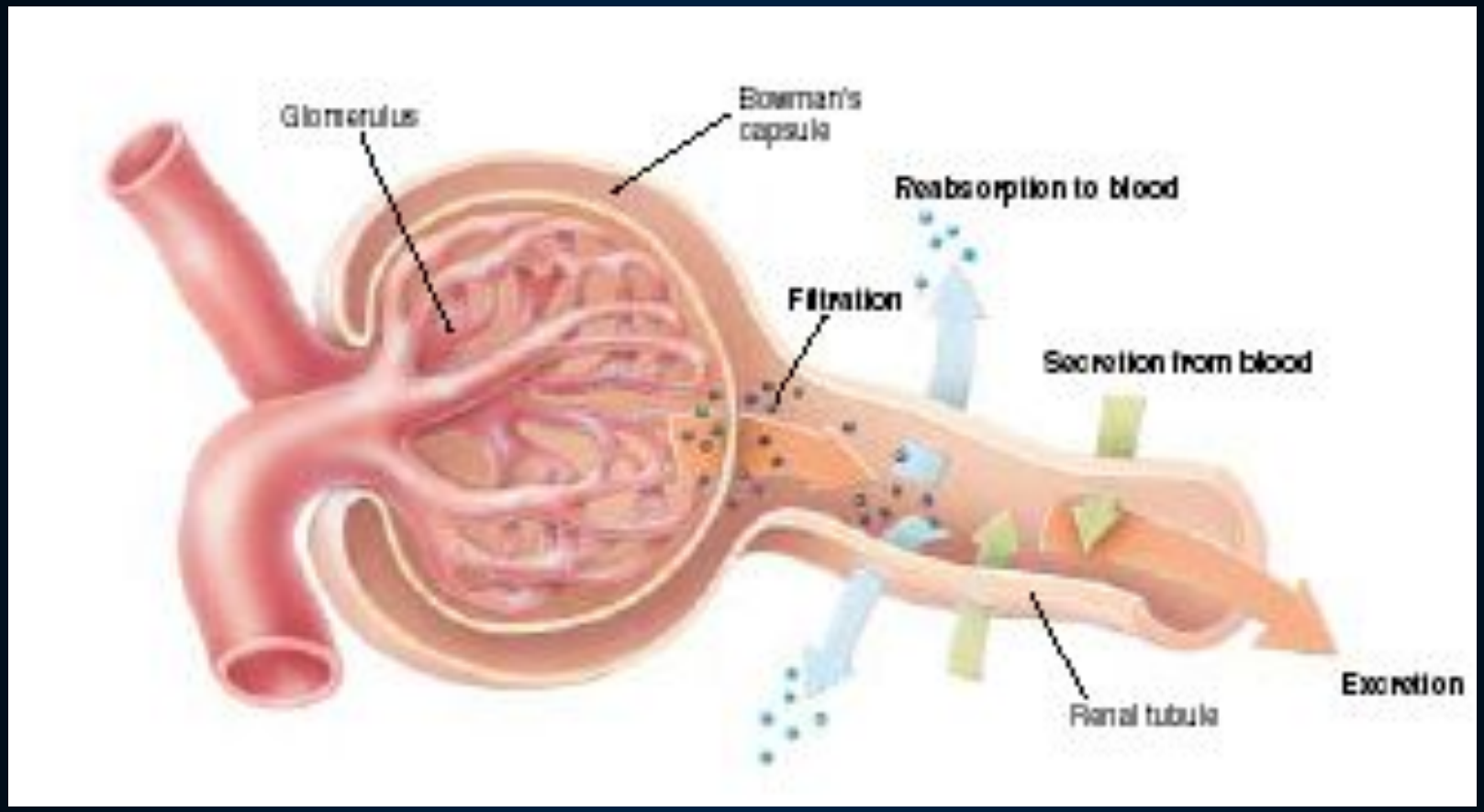

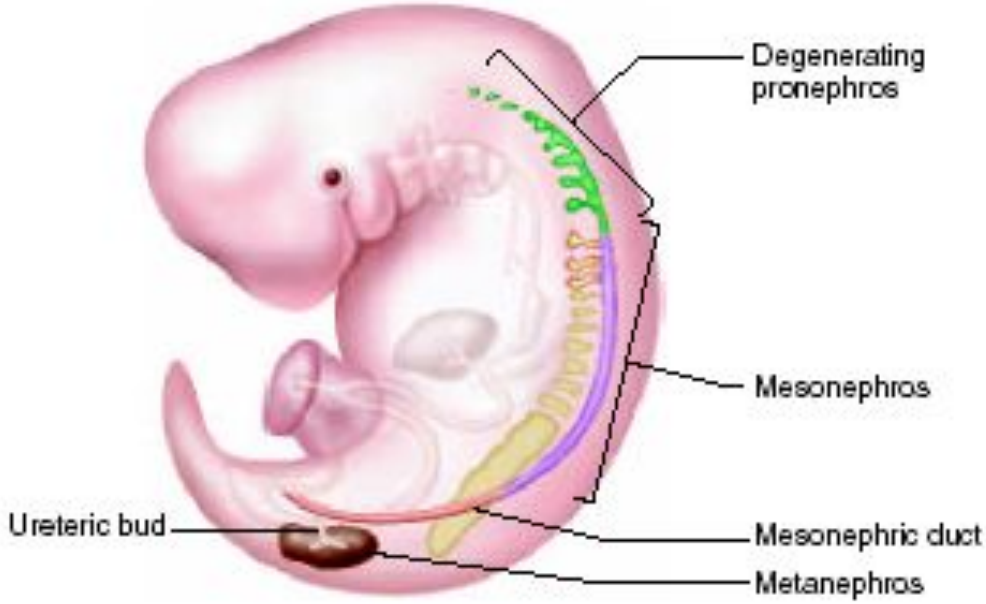
Degenerating pronephros
Mesonephros
Ureteric bud
Mesonephric duct
Metanephros

(a)

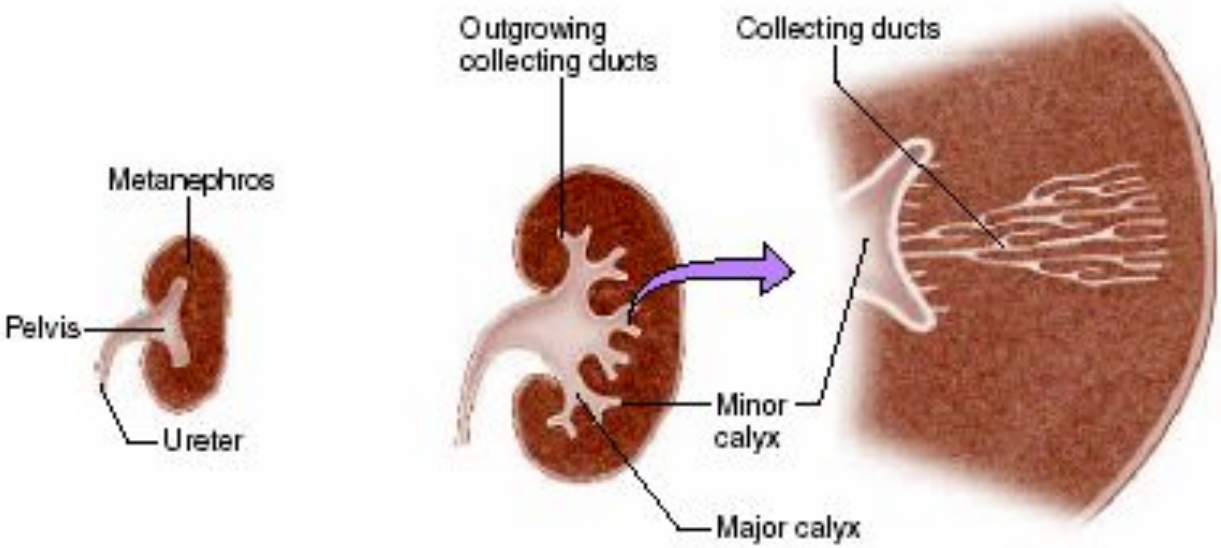
Metanephros
Pelvis
Ureter
Outgrowing collecting ducts
Collecting ducts
Minor calyx
Major calyx

(b)

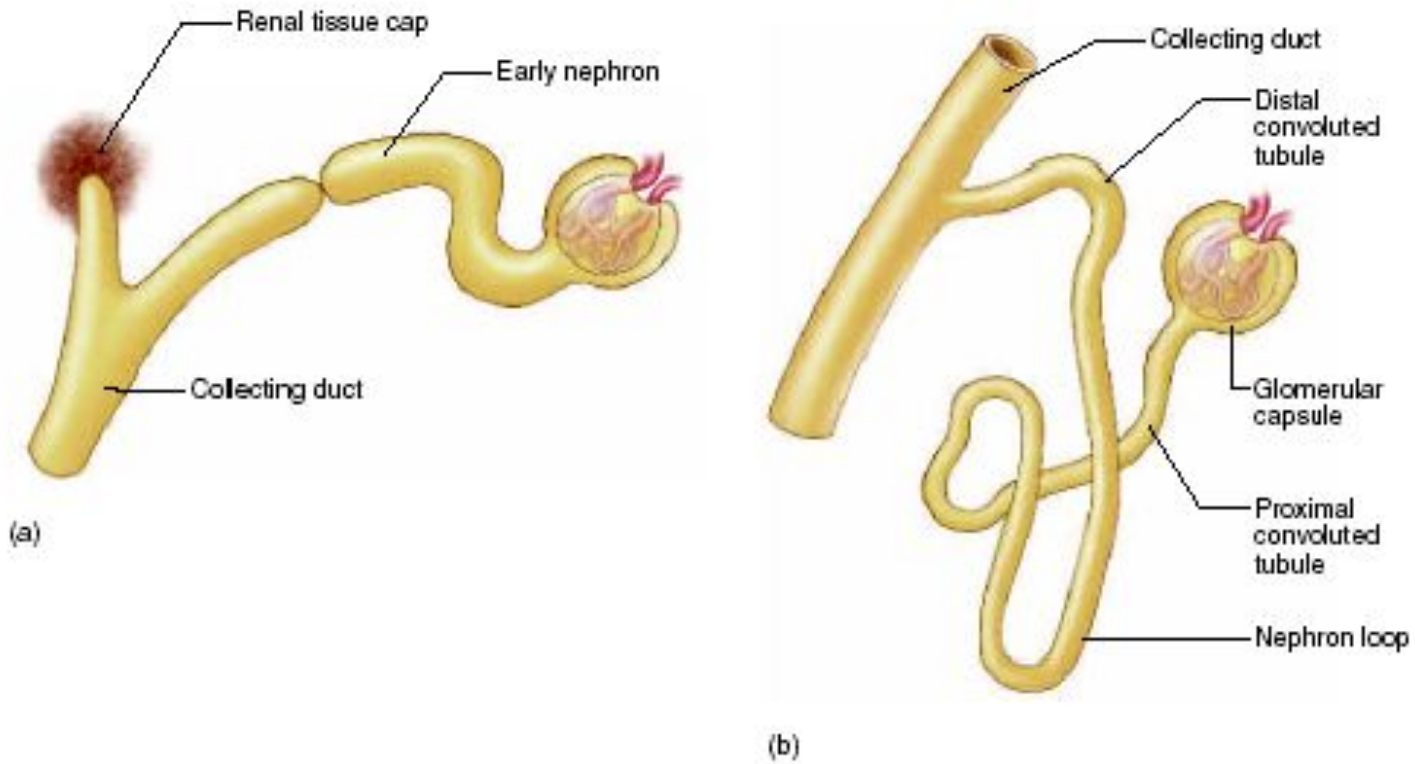

FIGURE 25.12

Embryonic Development of the Nephron. (*a*) The collecting duct induces mesoderm to differentiate into a renal (metanephric) tissue cap, as shown at the *far left*. This cap differentiates into an S-shaped tube that will become the nephron, as shown on the *right fork* of the duct (representing a later stage of development). (*b*) The renal tubule has begun to differentiate into proximal and distal convoluted tubules and nephron loop.

Филогенез половой системы хордовых

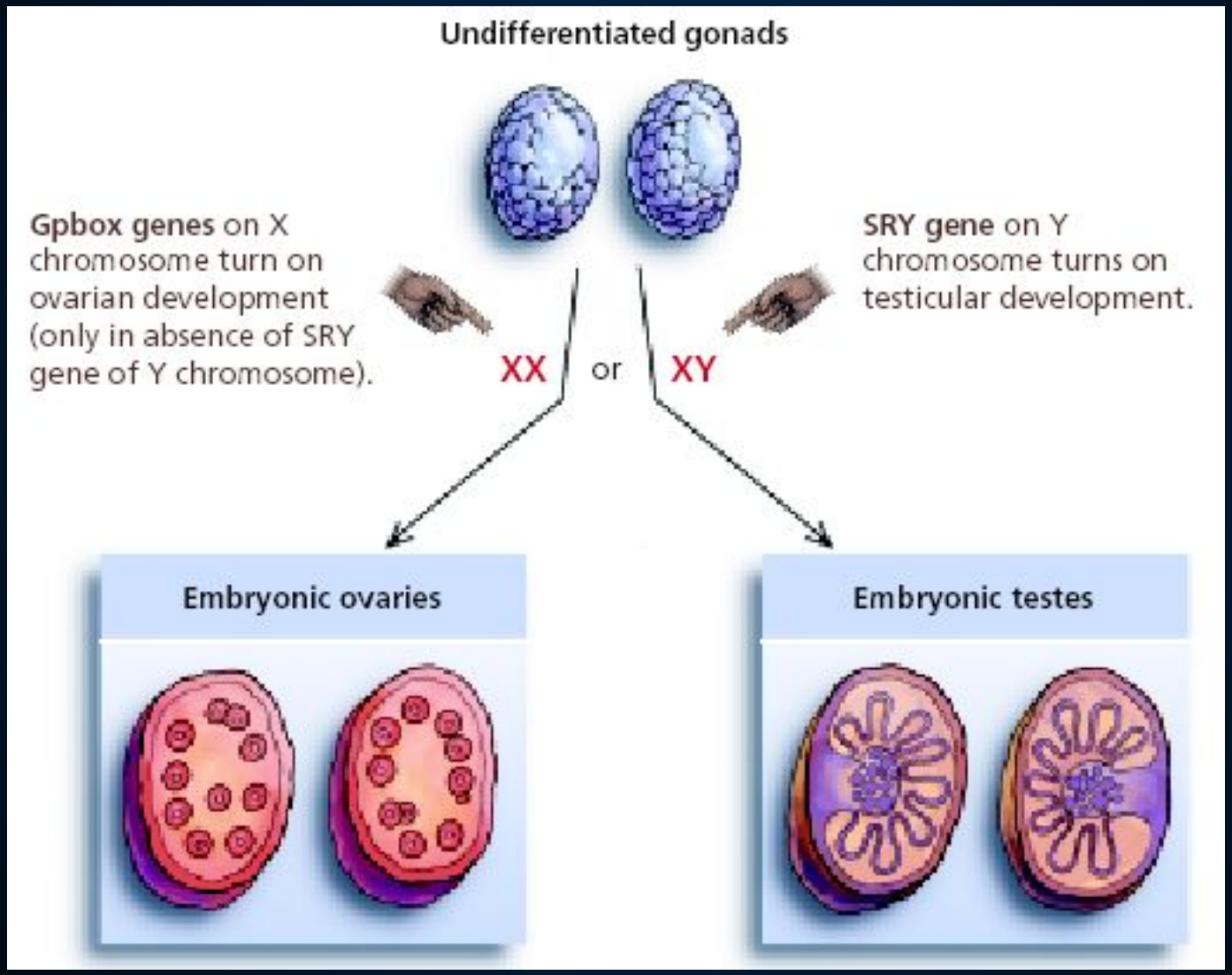

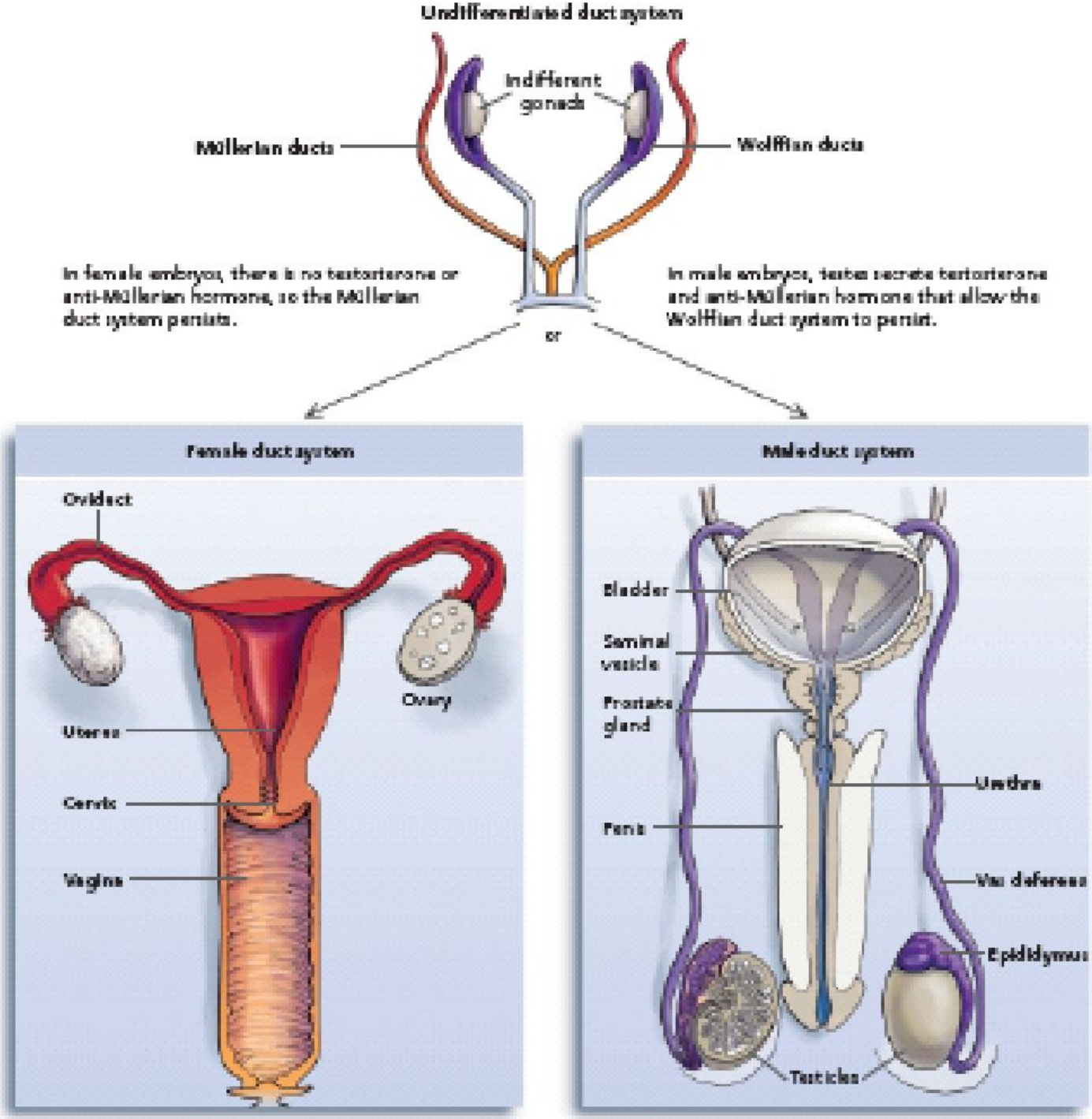
Undifferentiated duct system
Indifferent gonads
Müllerian ducts
Wolffian ducts
In female embryos, there is no testosterone or anti-Müllerian hormone, so the Müllerian duct system persists.
In male embryos, testes secrete testosterone and anti-Müllerian hormone that allow the Wolffian duct system to persist.
or
Female duct system
Oviduct
Ovary
Uterus
Cervix
Vagina
Male duct system
Bladder
Seminal vesicle
Prostate gland
Urethra
Penis
Vas deferens
Epididymus
Testicles

Филогенез половой системы хордовых

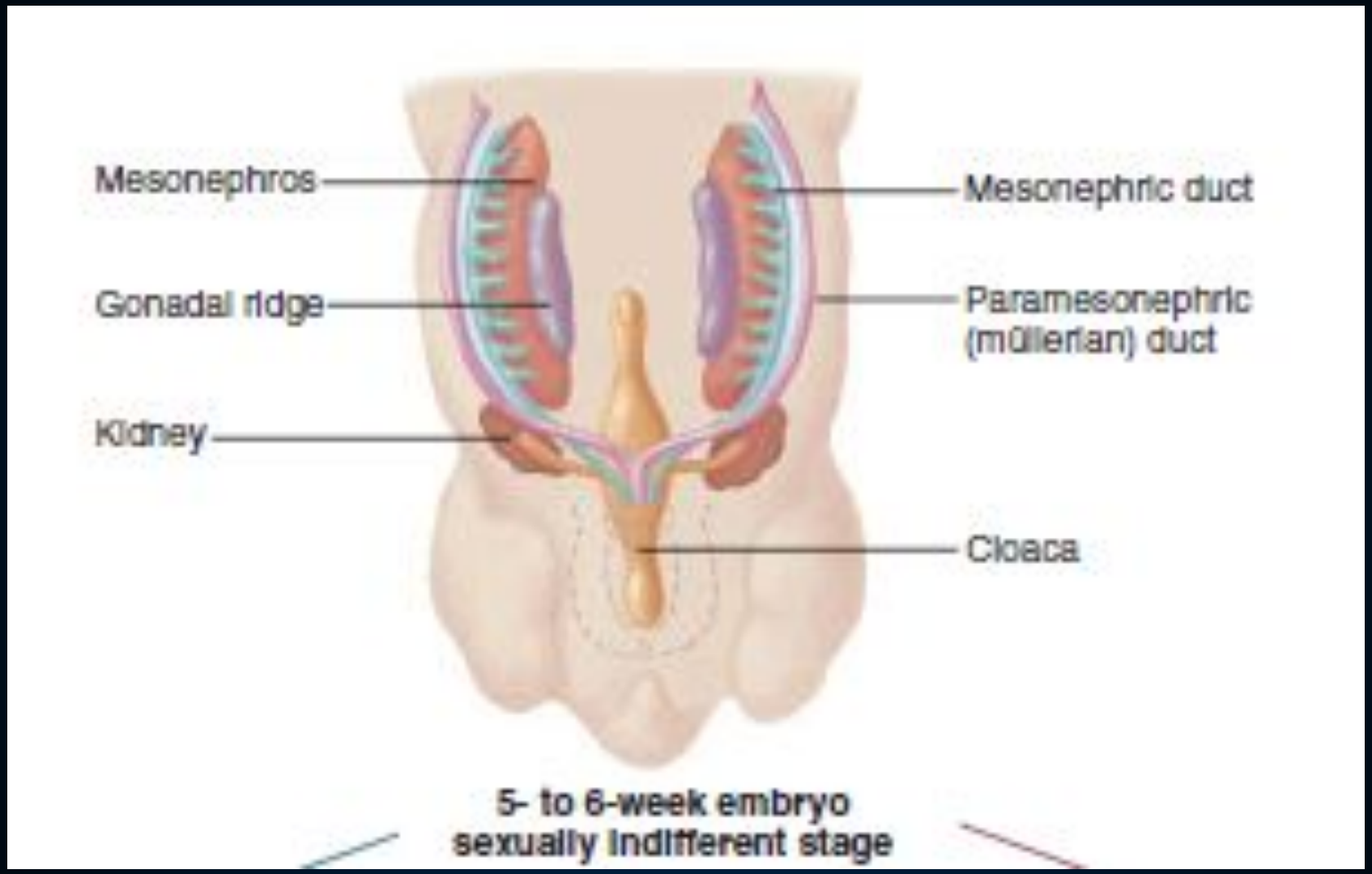

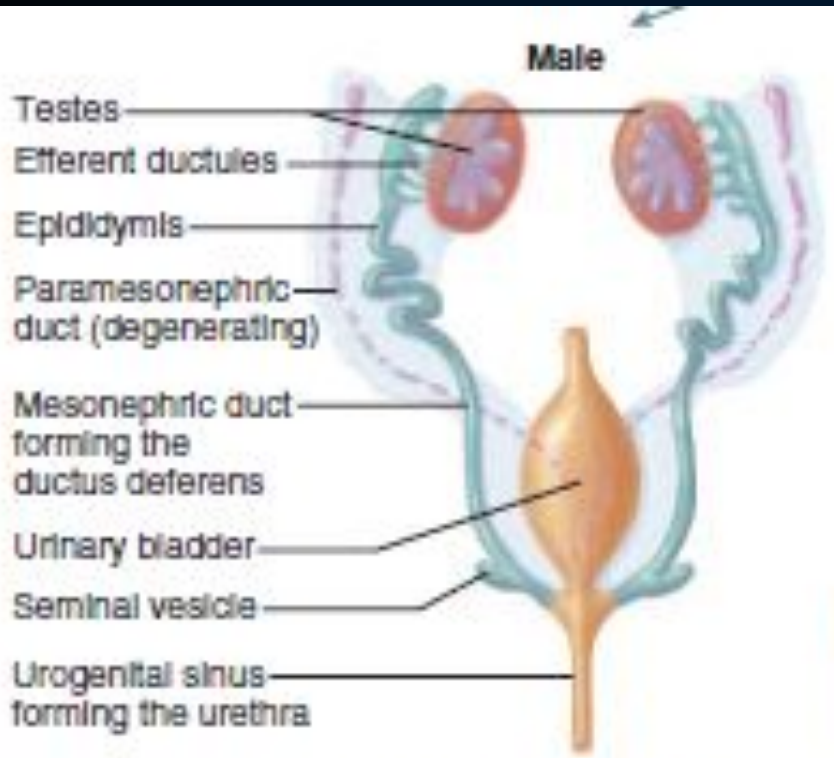

7- to 8-week male emb

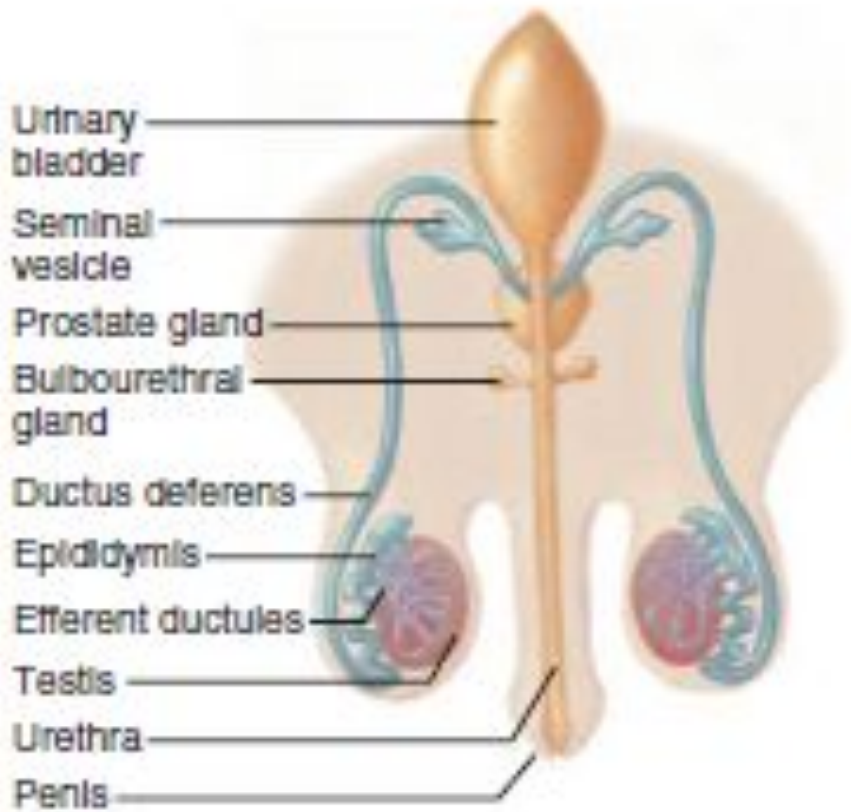

At birth

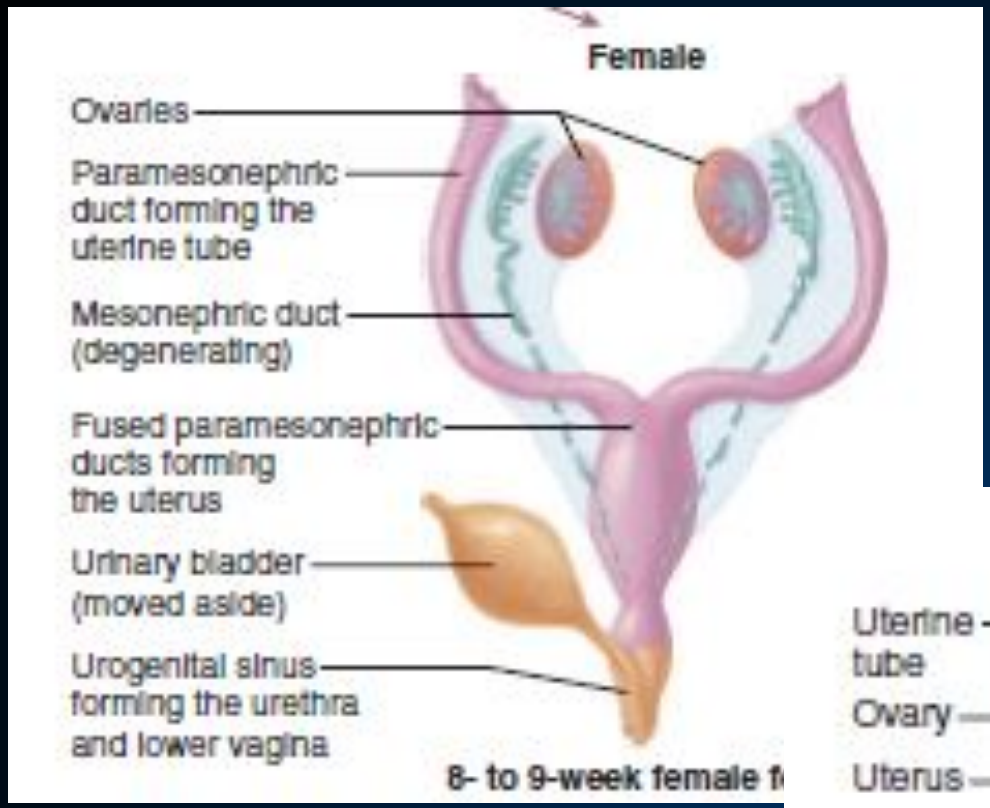
Female
Ovaries
Paramesonephric duct forming the uterine tube
Mesonephric duct (degenerating)
Fused paramesonephric ducts forming the uterus
Urinary bladder (moved aside)
Urogenital sinus forming the urethra and lower vagina
8- to 9-week female f

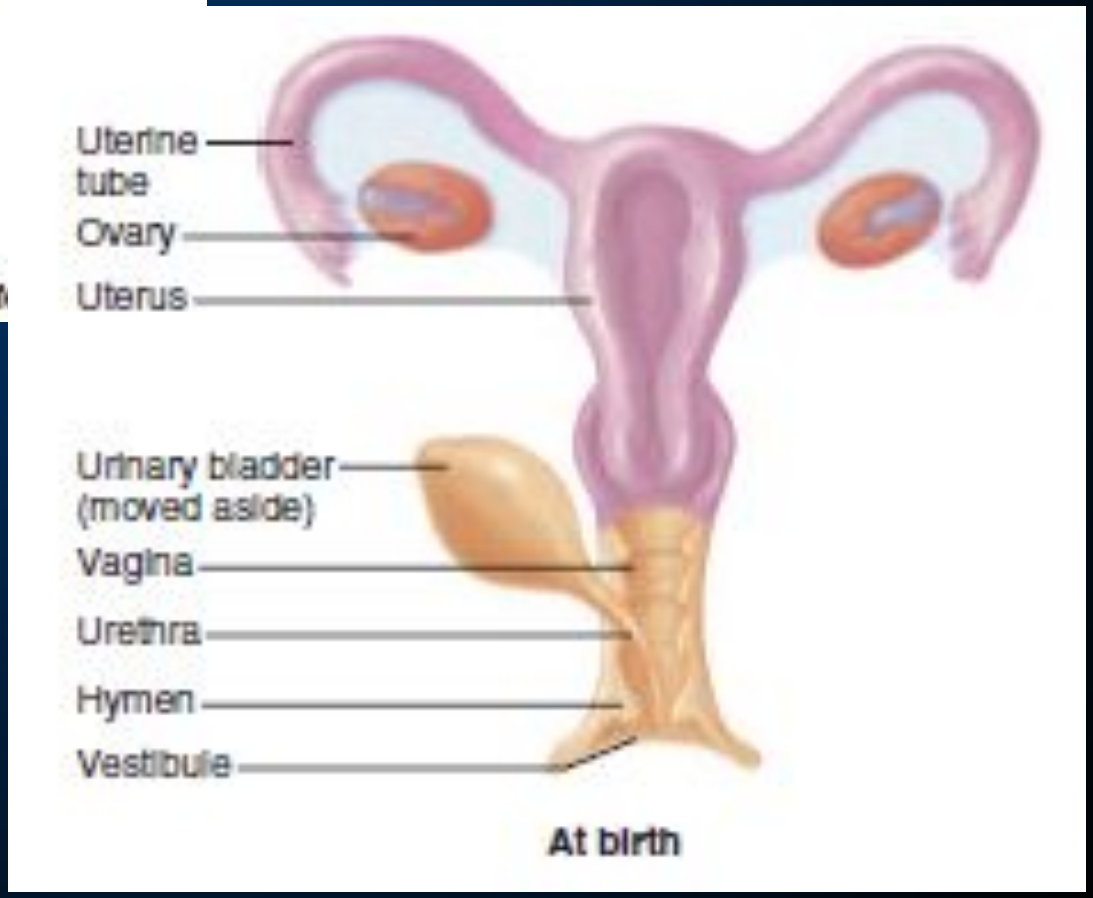
Uterine tube
Ovary
Uterus
Urinary bladder (moved aside)
Vagina
Urethra
Hymen
Vestibule
At birth

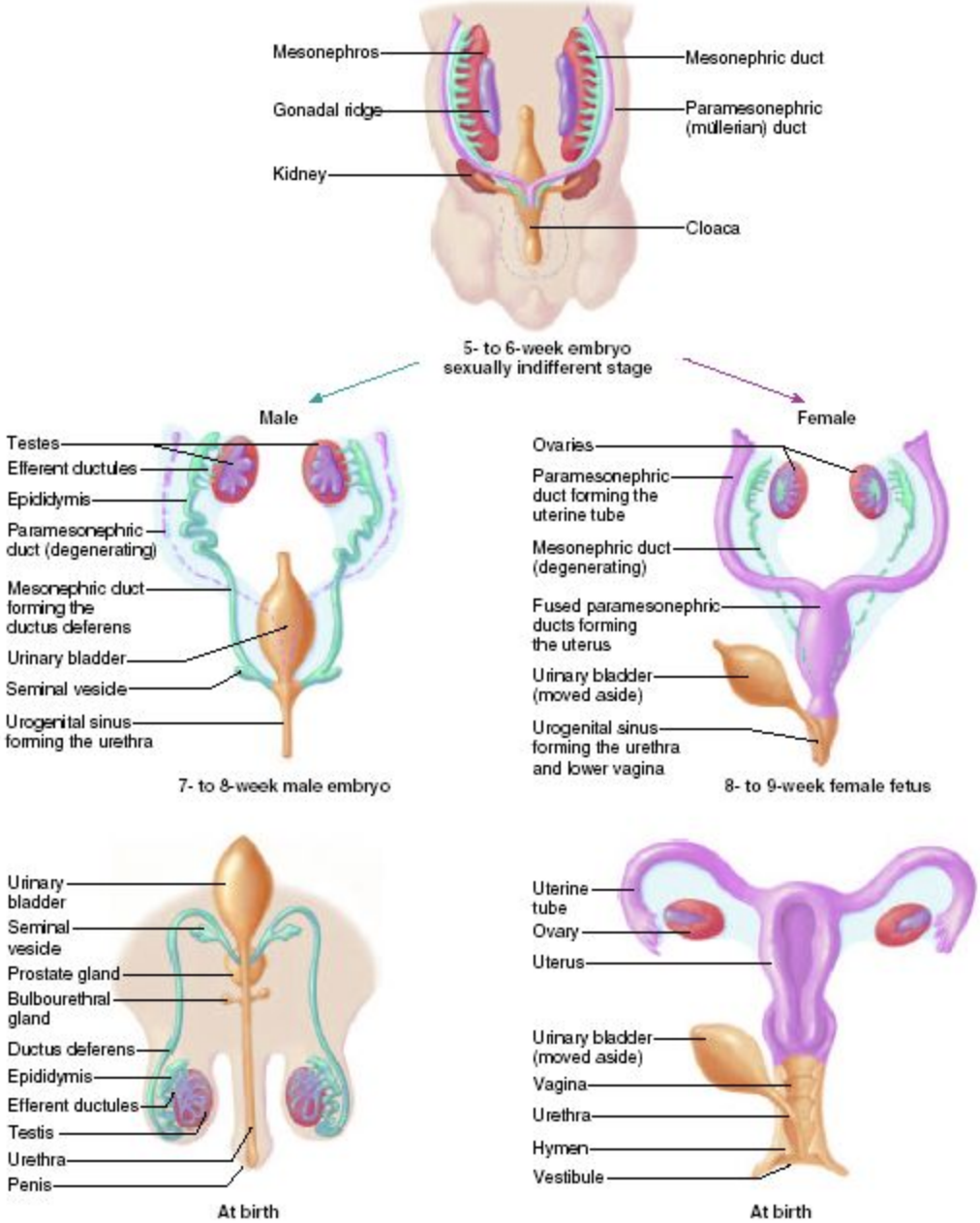

FIGURE 26.26

Embryonic Development of the Male and Female Reproductive Tracts. Note that the male tract develops from the mesonephric duct and the female tract from the paramesonephric duct, while the other duct in each sex degenerates.

Онтофилогенетические предпосылки формирования врожденных пороков развития у человека

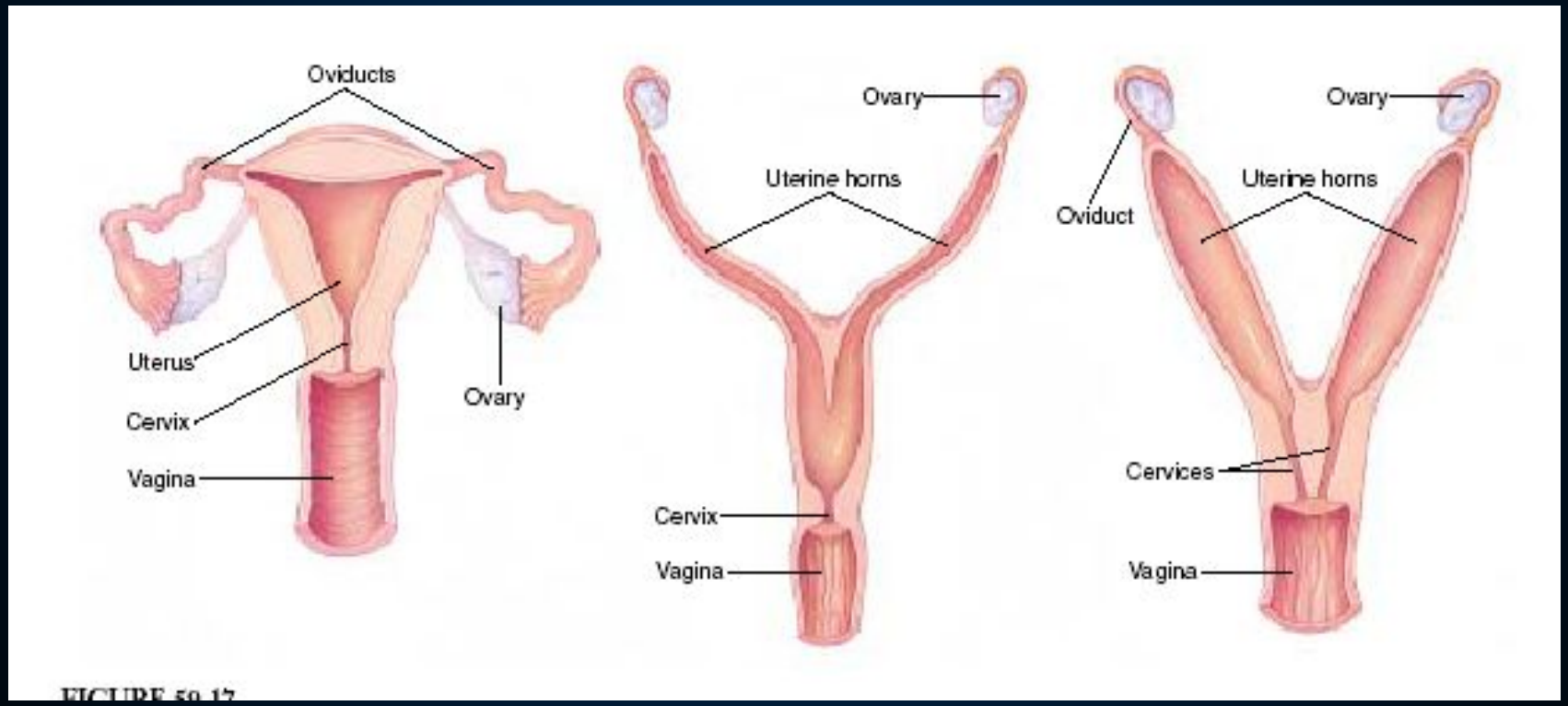

FIGURE 50.17