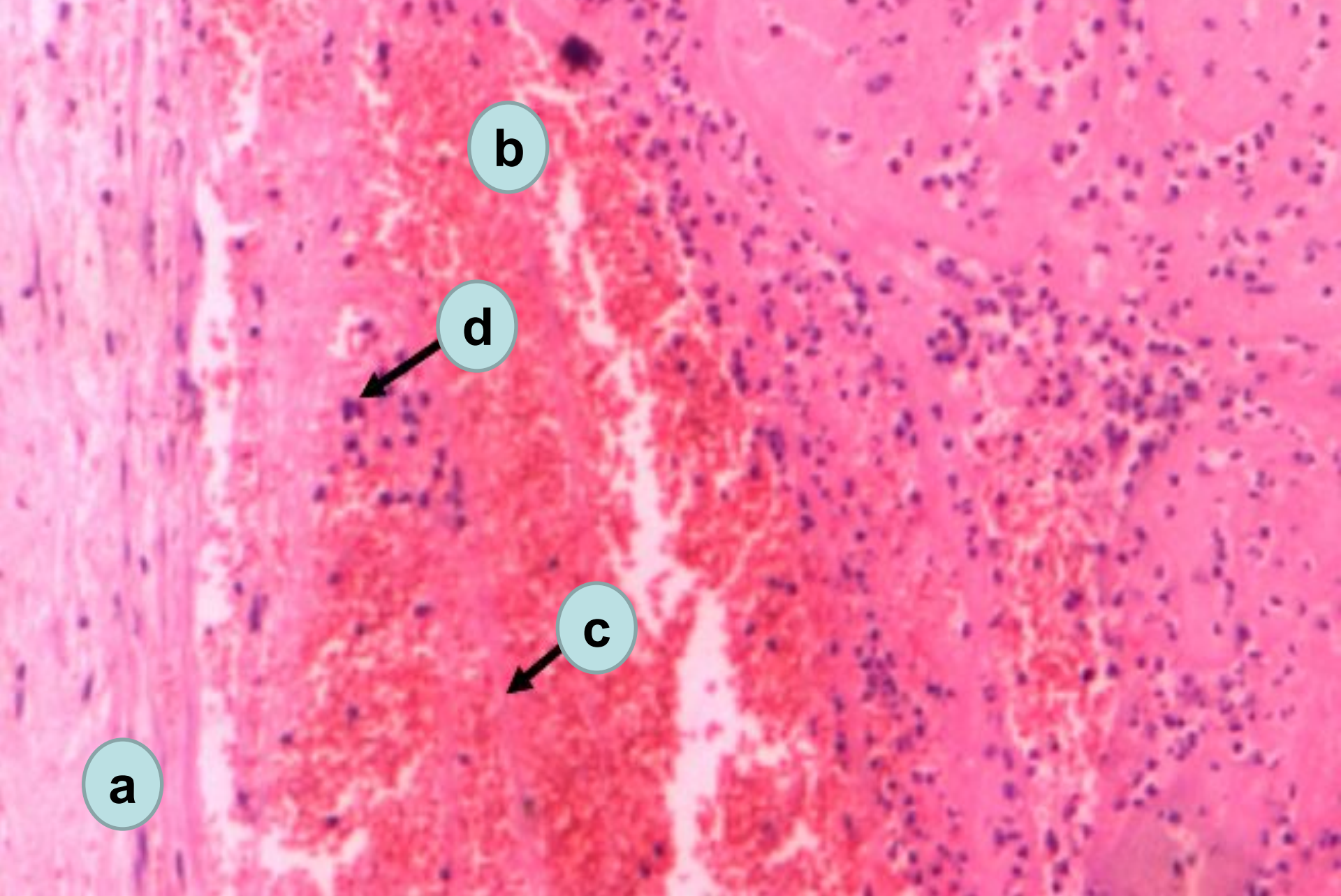


# **Topic № 8. Thrombosis. Embolism. Infarction.**

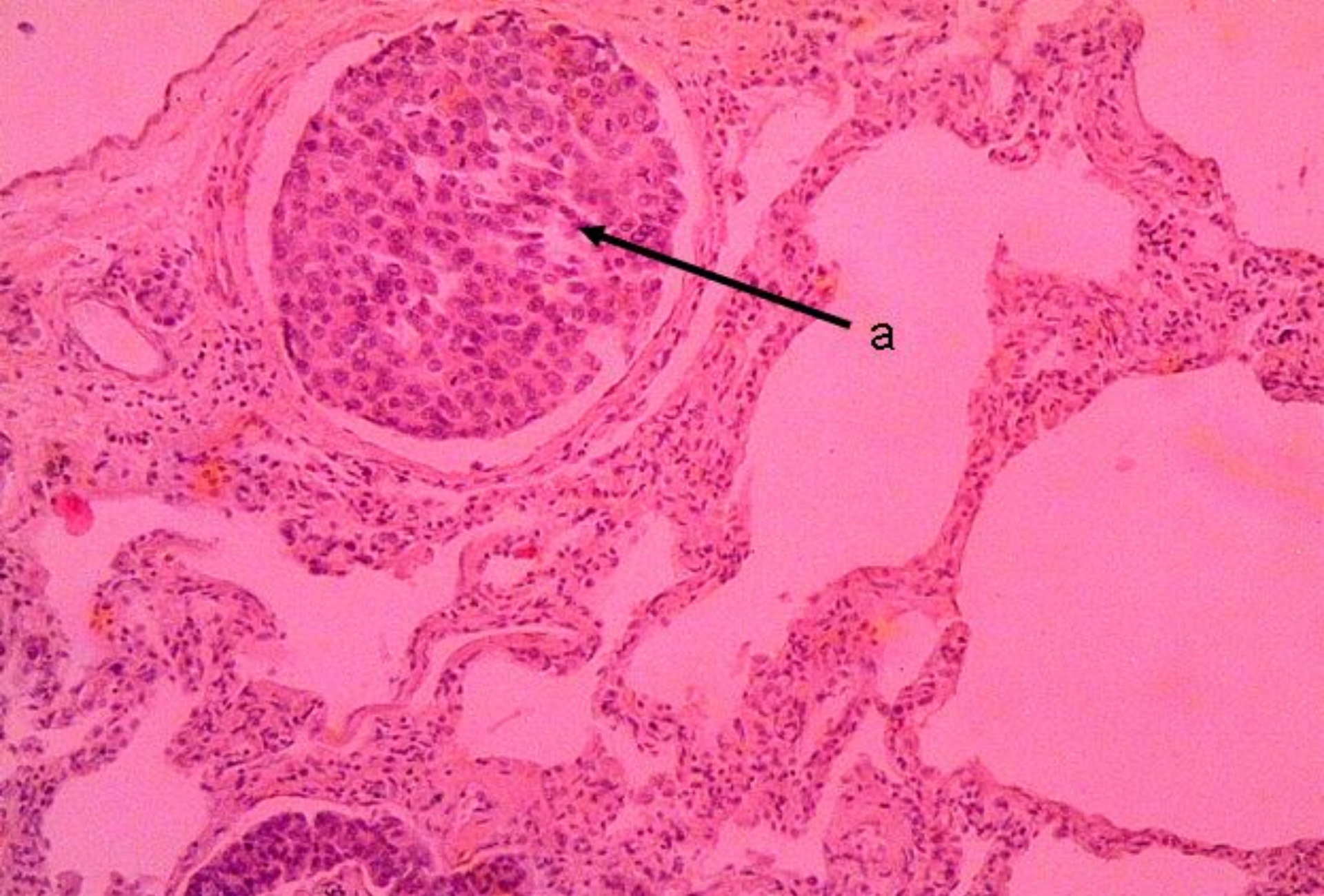
Prepared by  
d.m.s. Shabdarbaeva D.M.



Mixed thrombus in the vein

a – wall of the vein; b – erythrocytes; c – fibrin threads; d – leucocytes





Metastases of cancer in lungs  
a – embolism of the vessel of lung by neoplastic cells