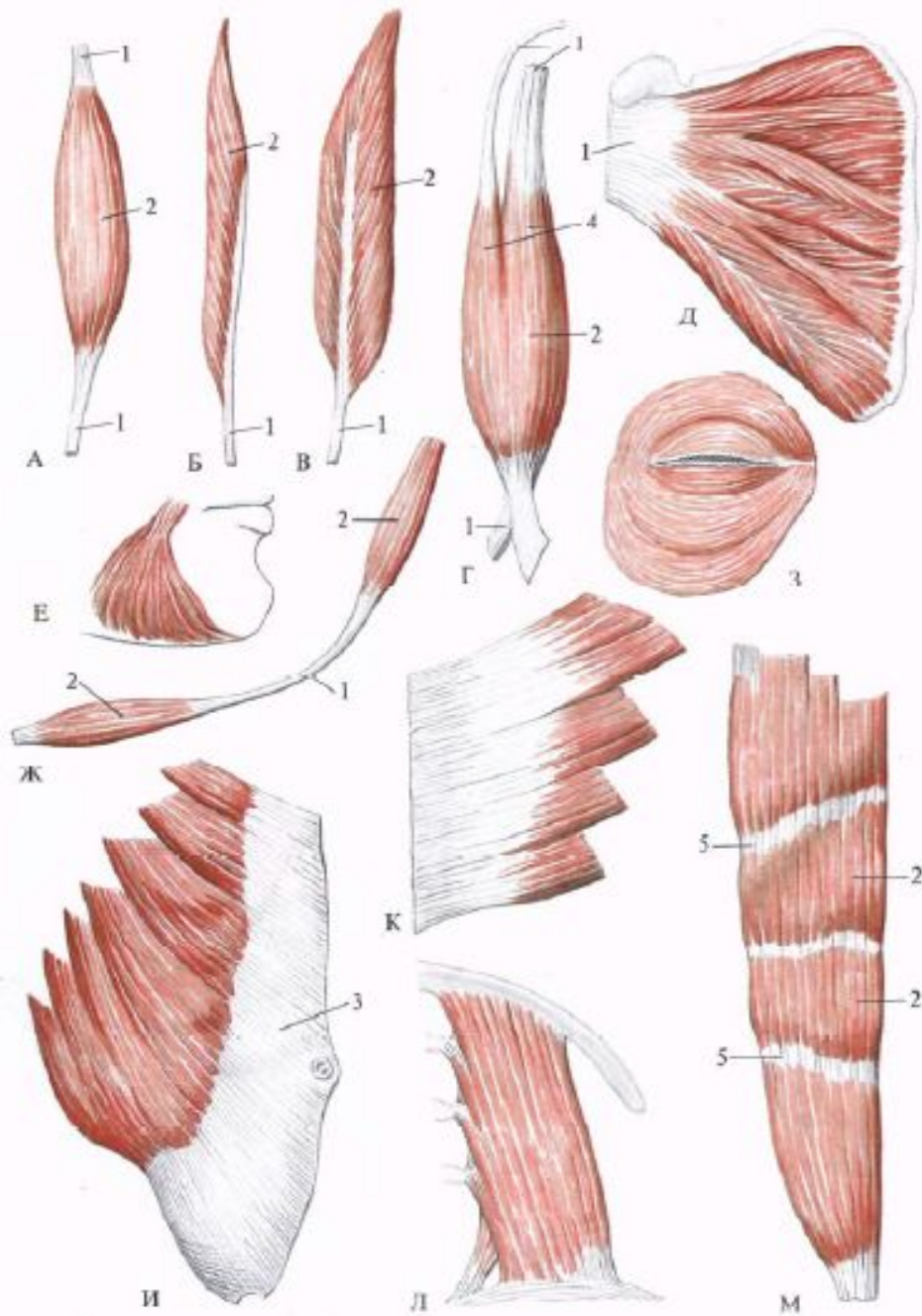
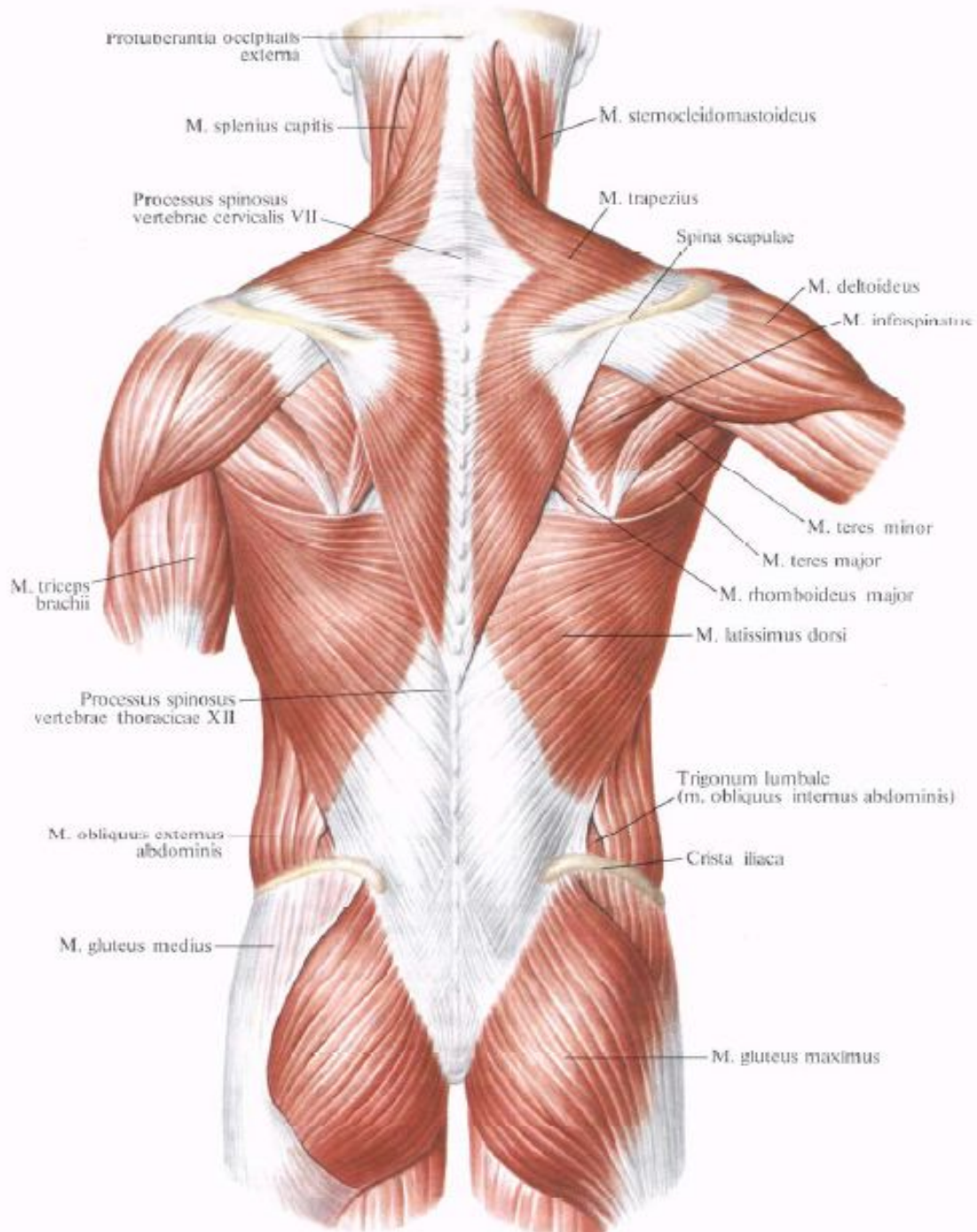
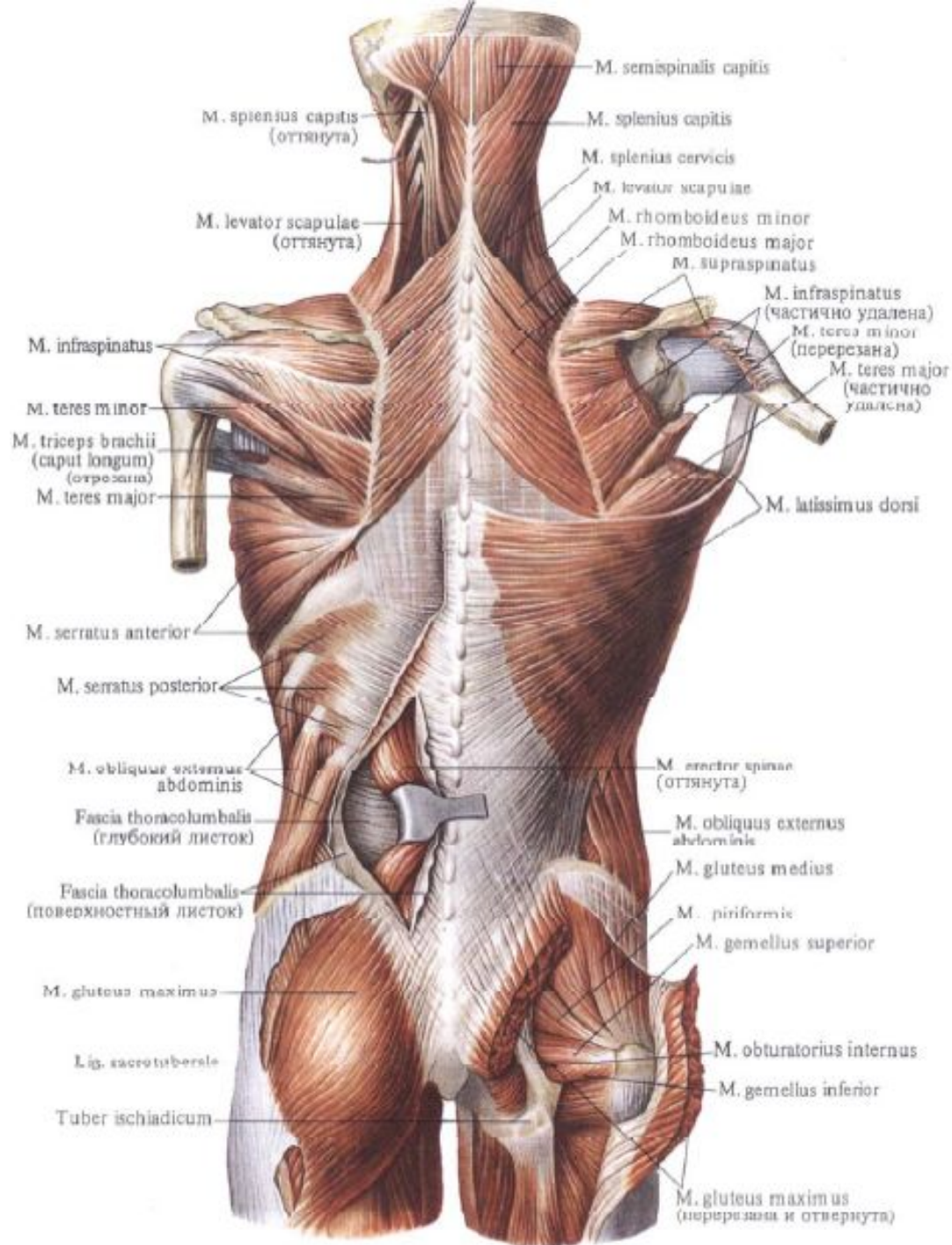
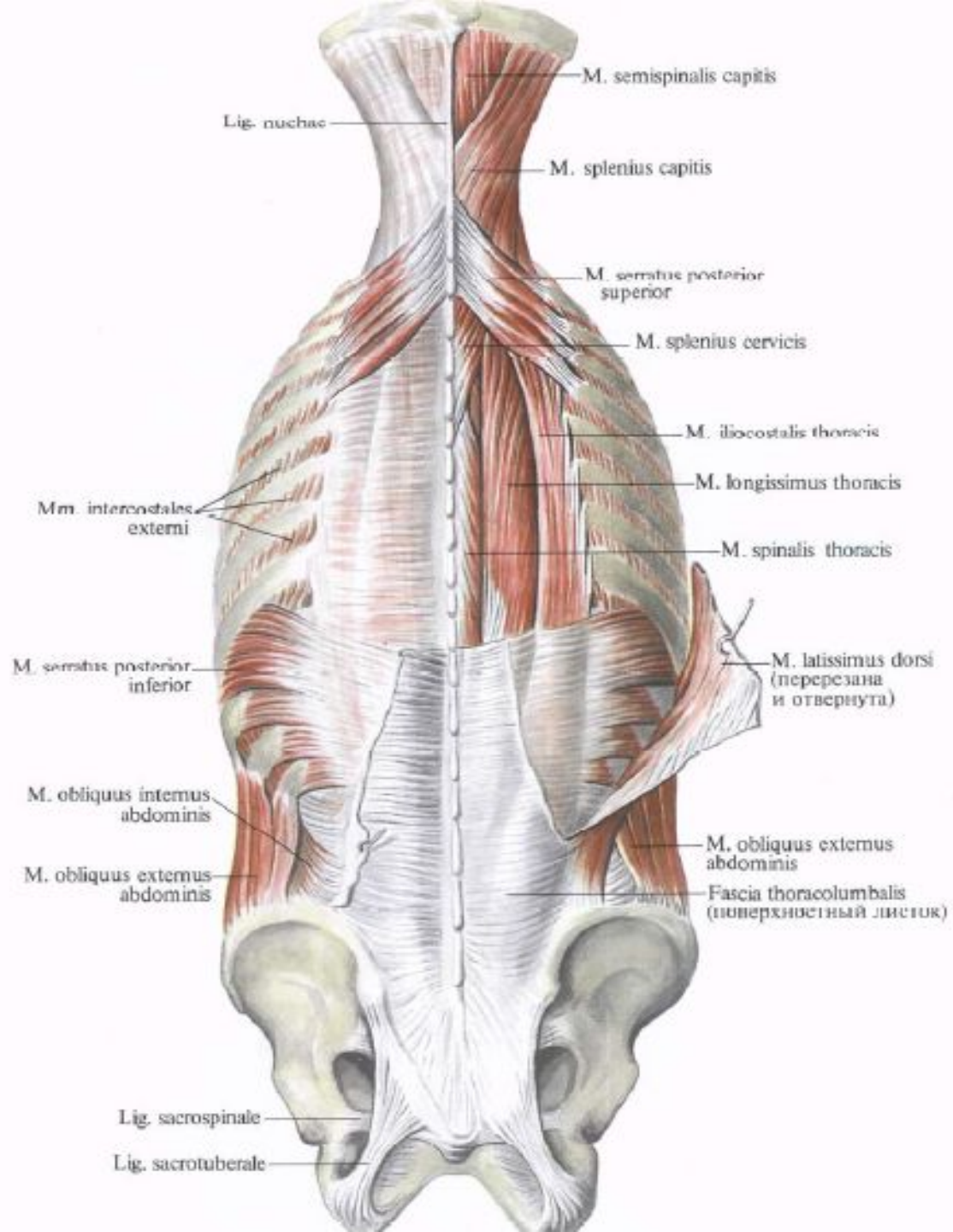


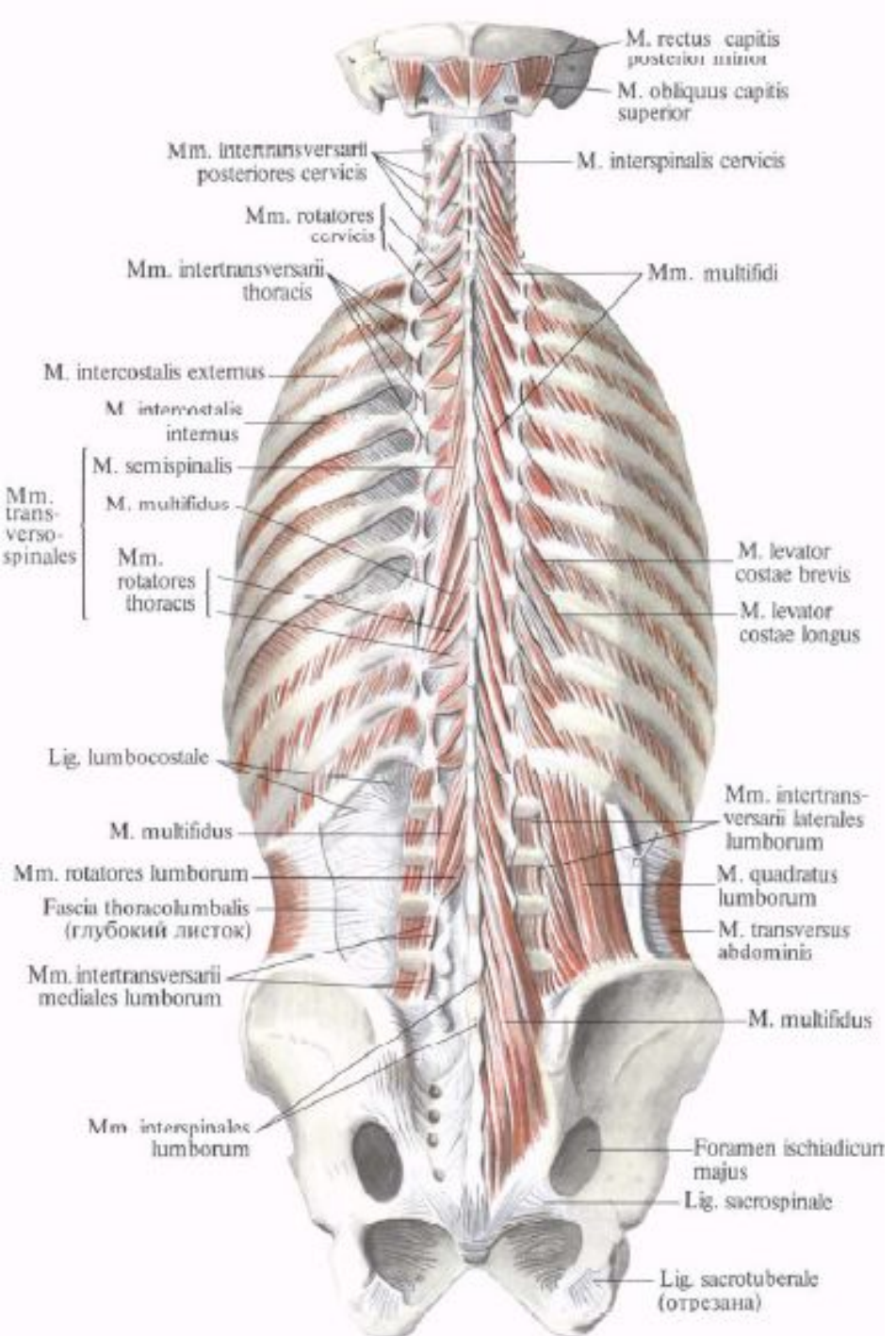
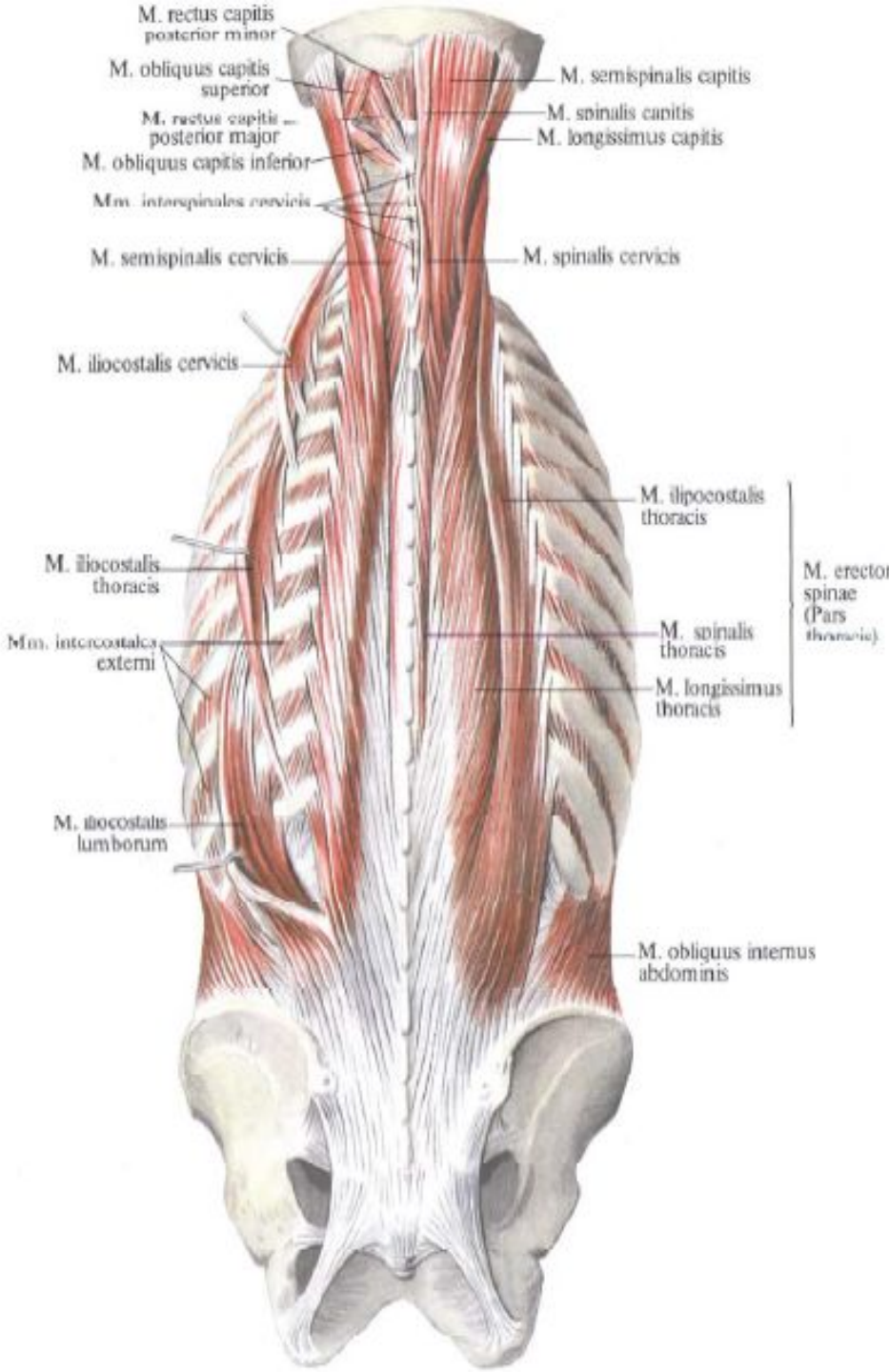
# Миология

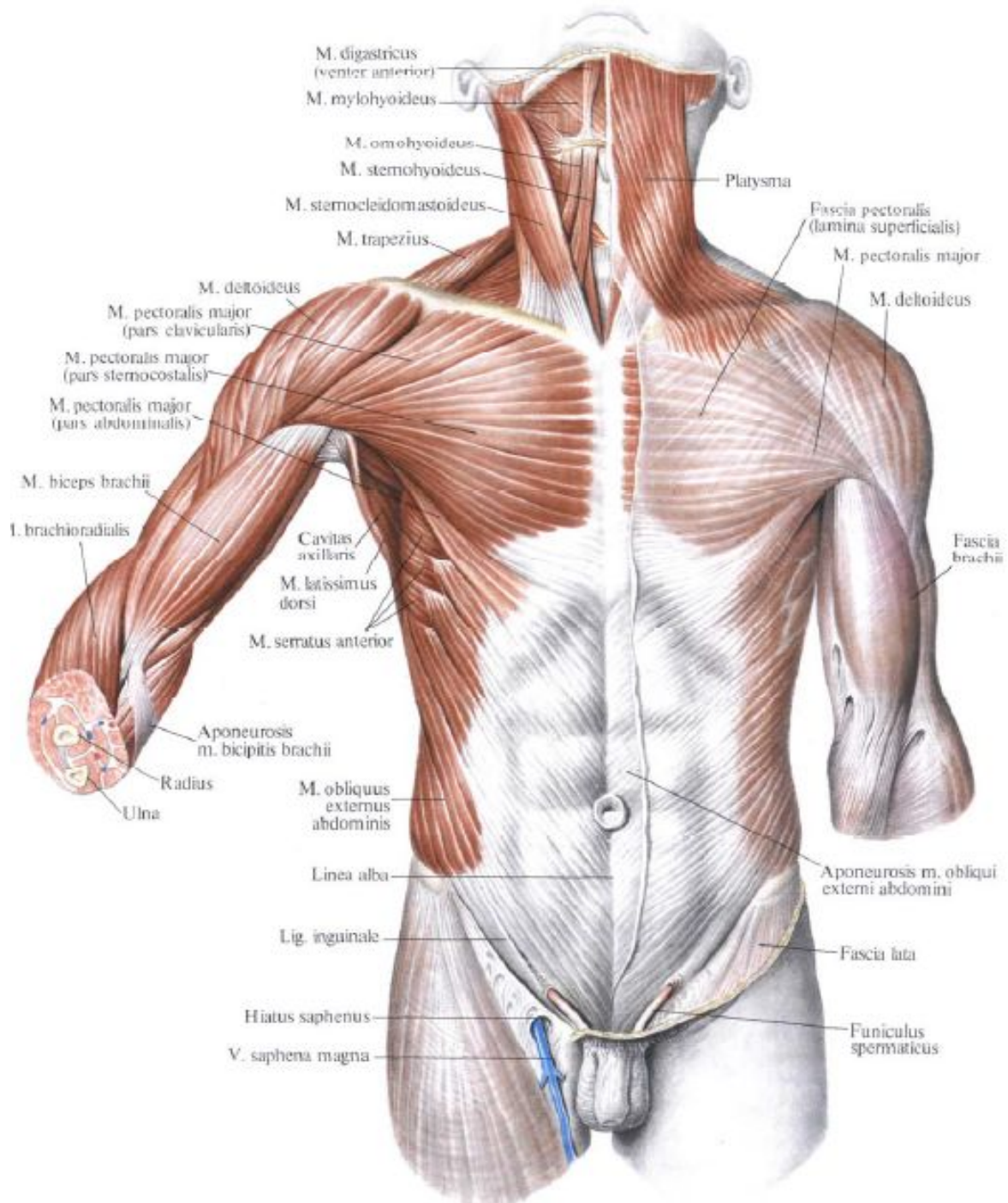


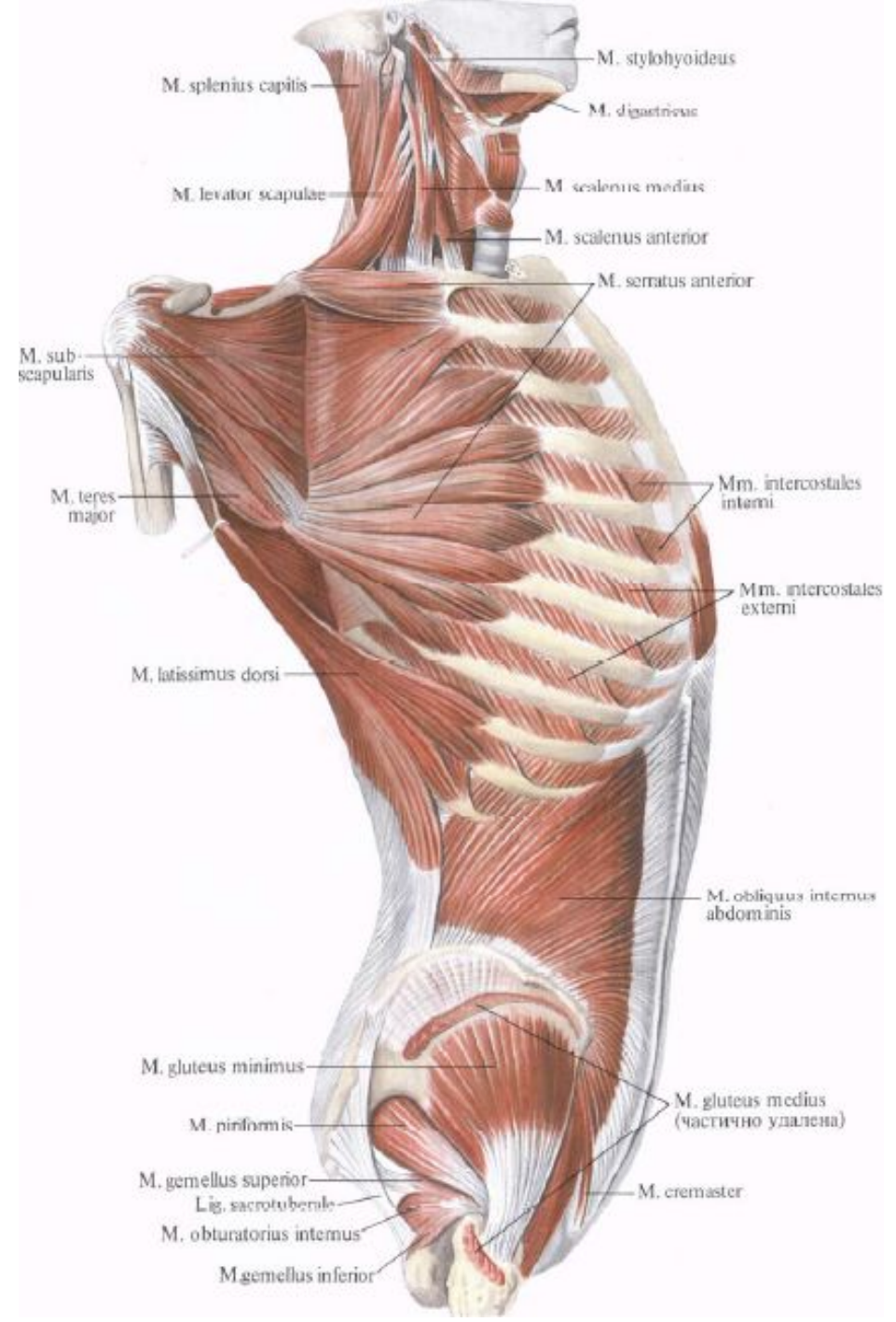
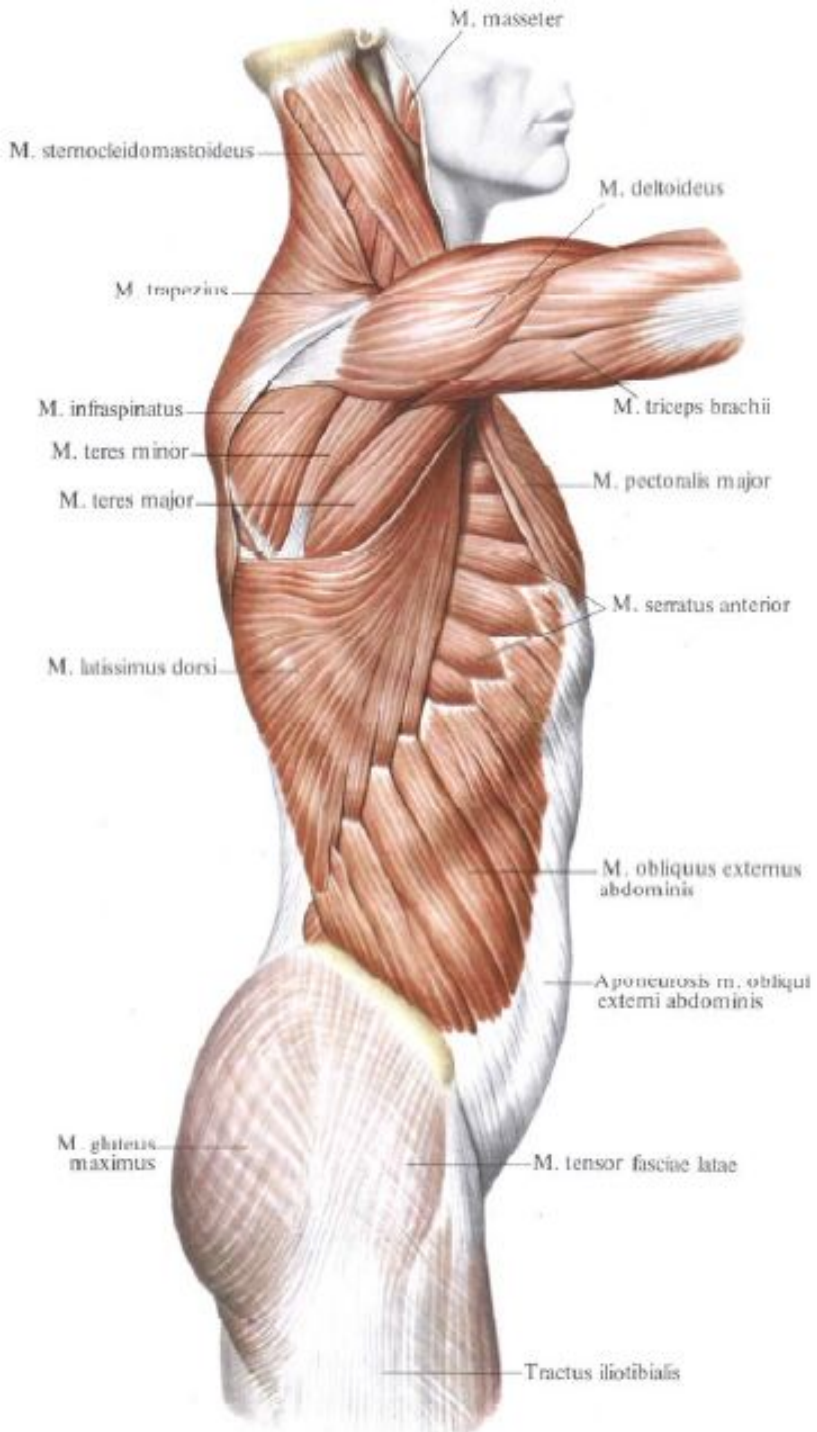




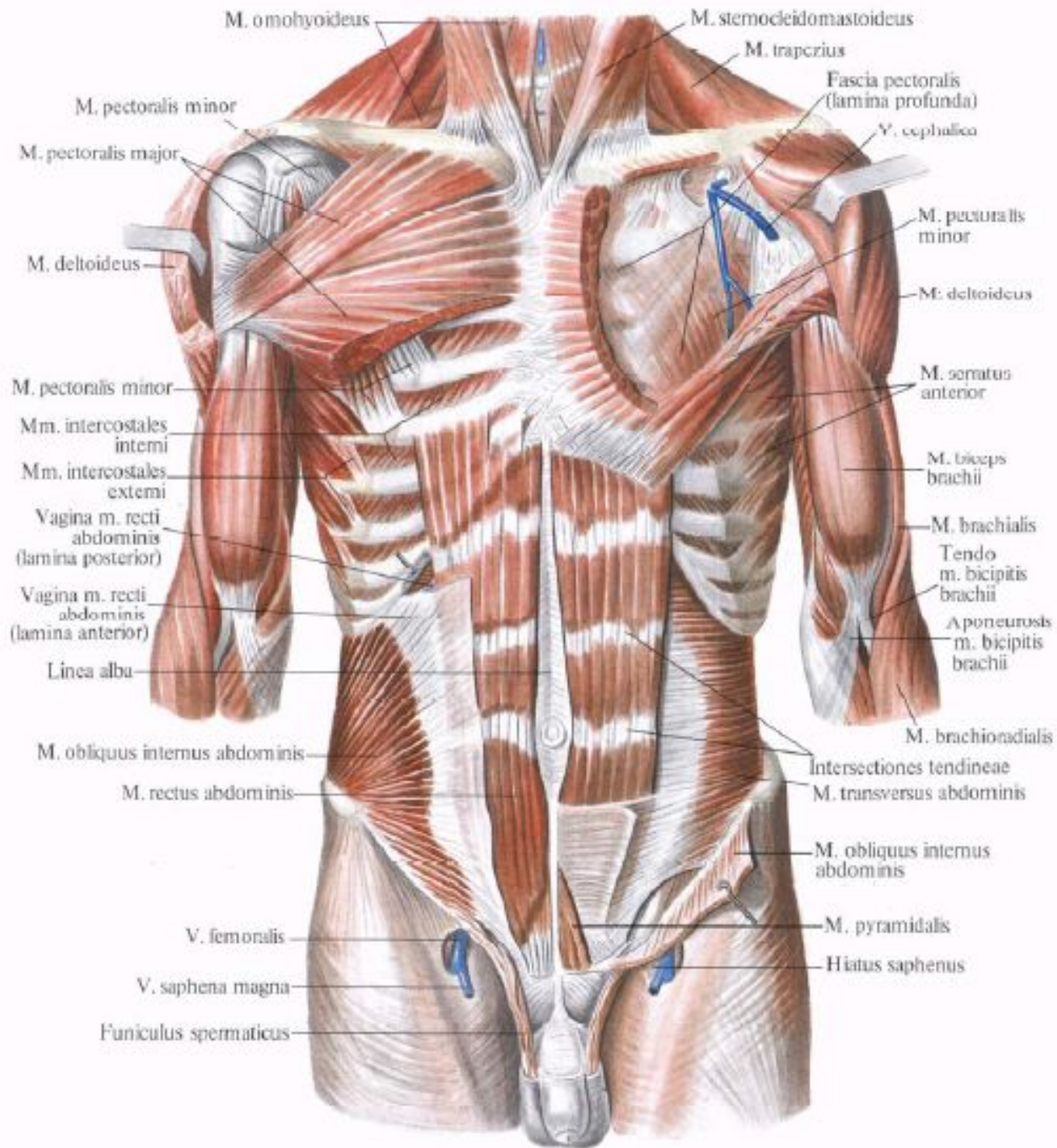


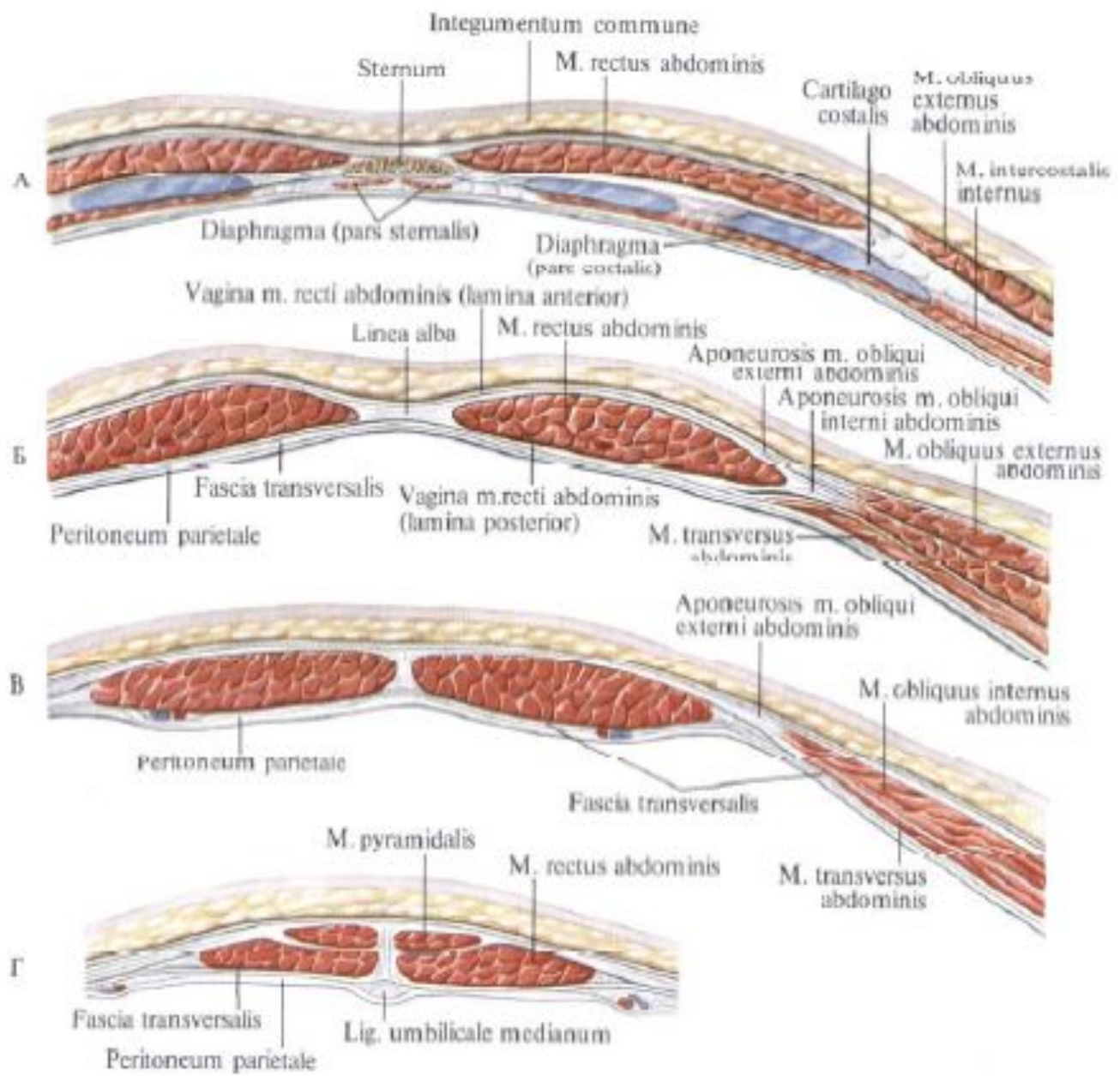


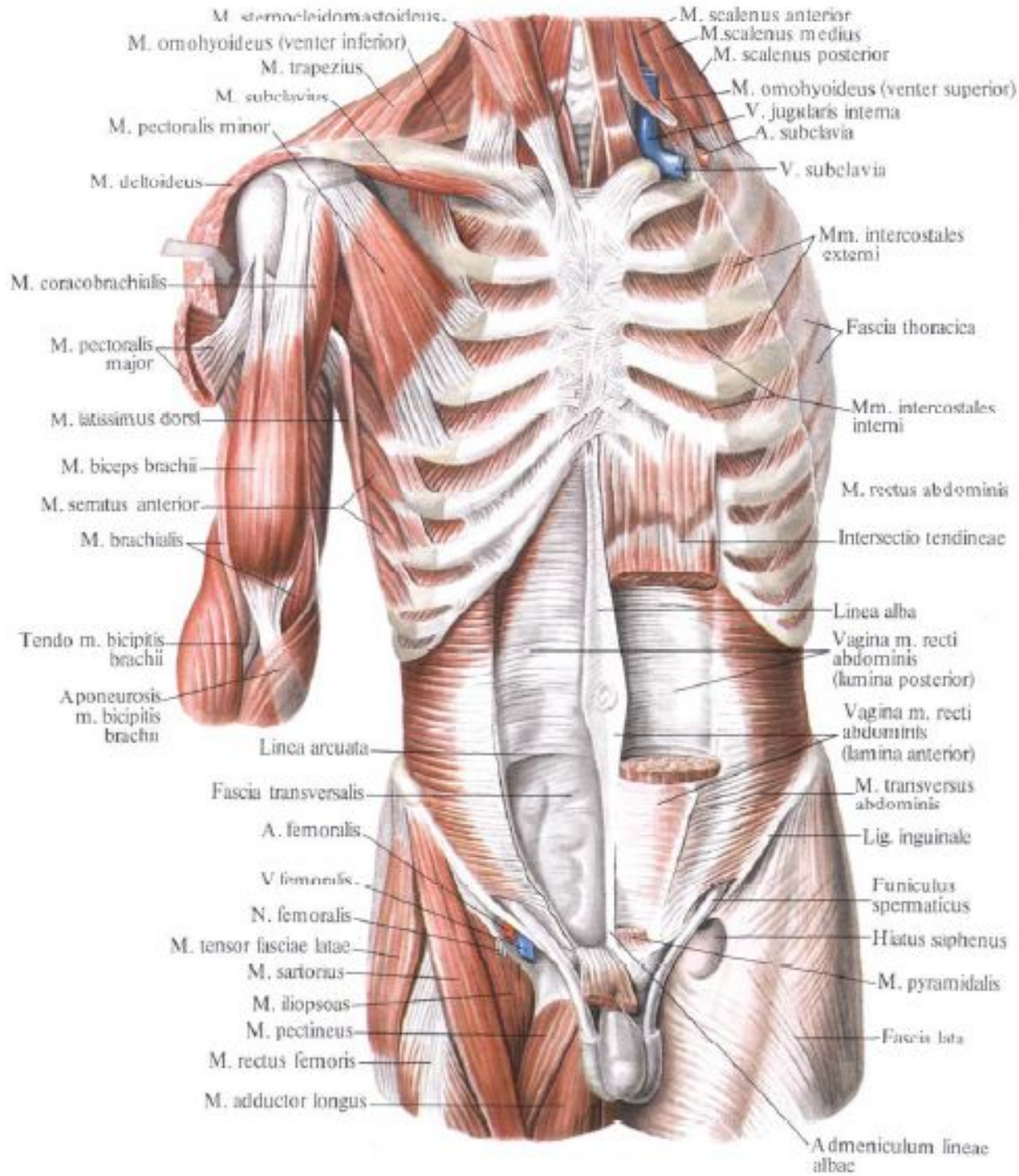








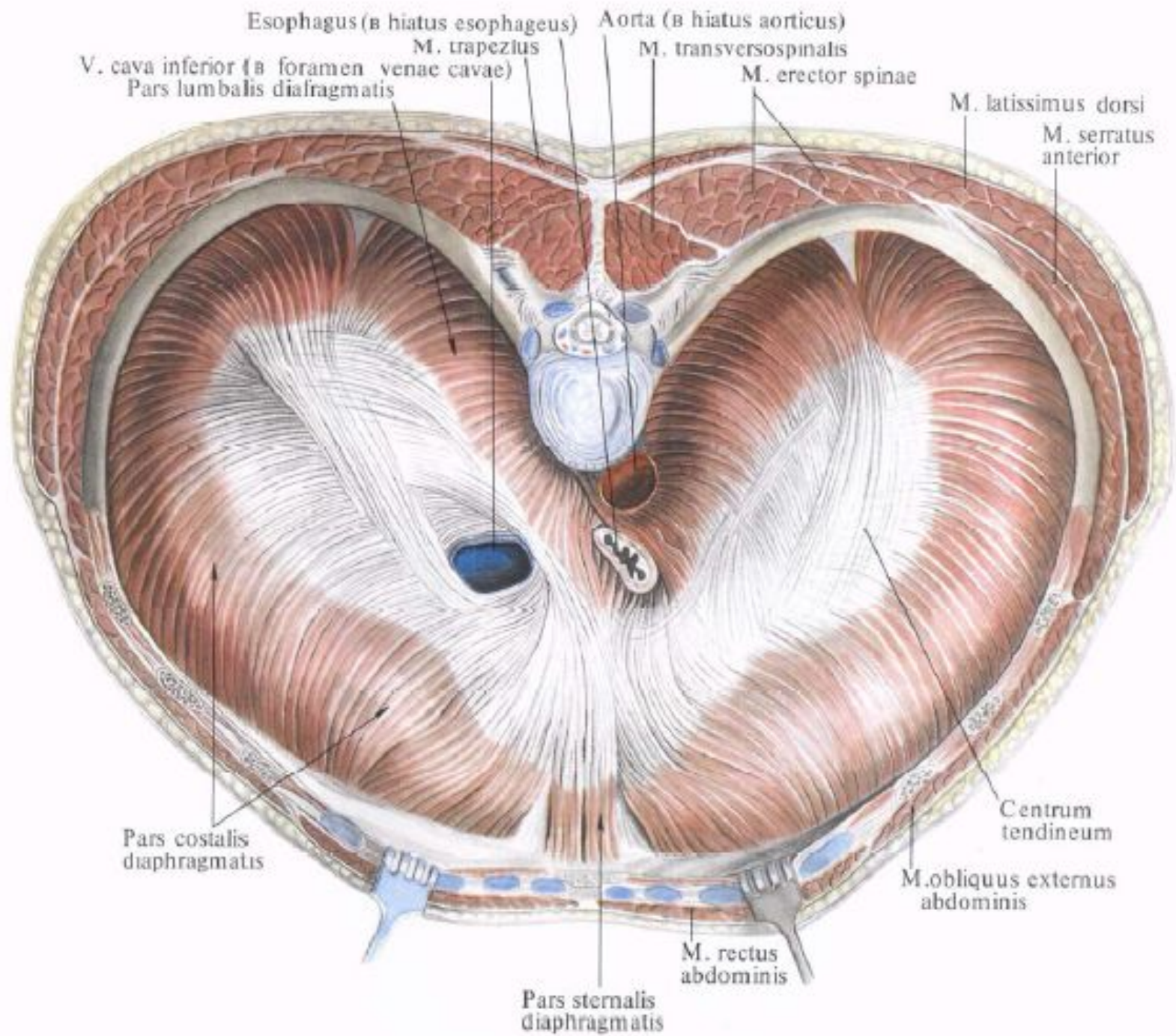


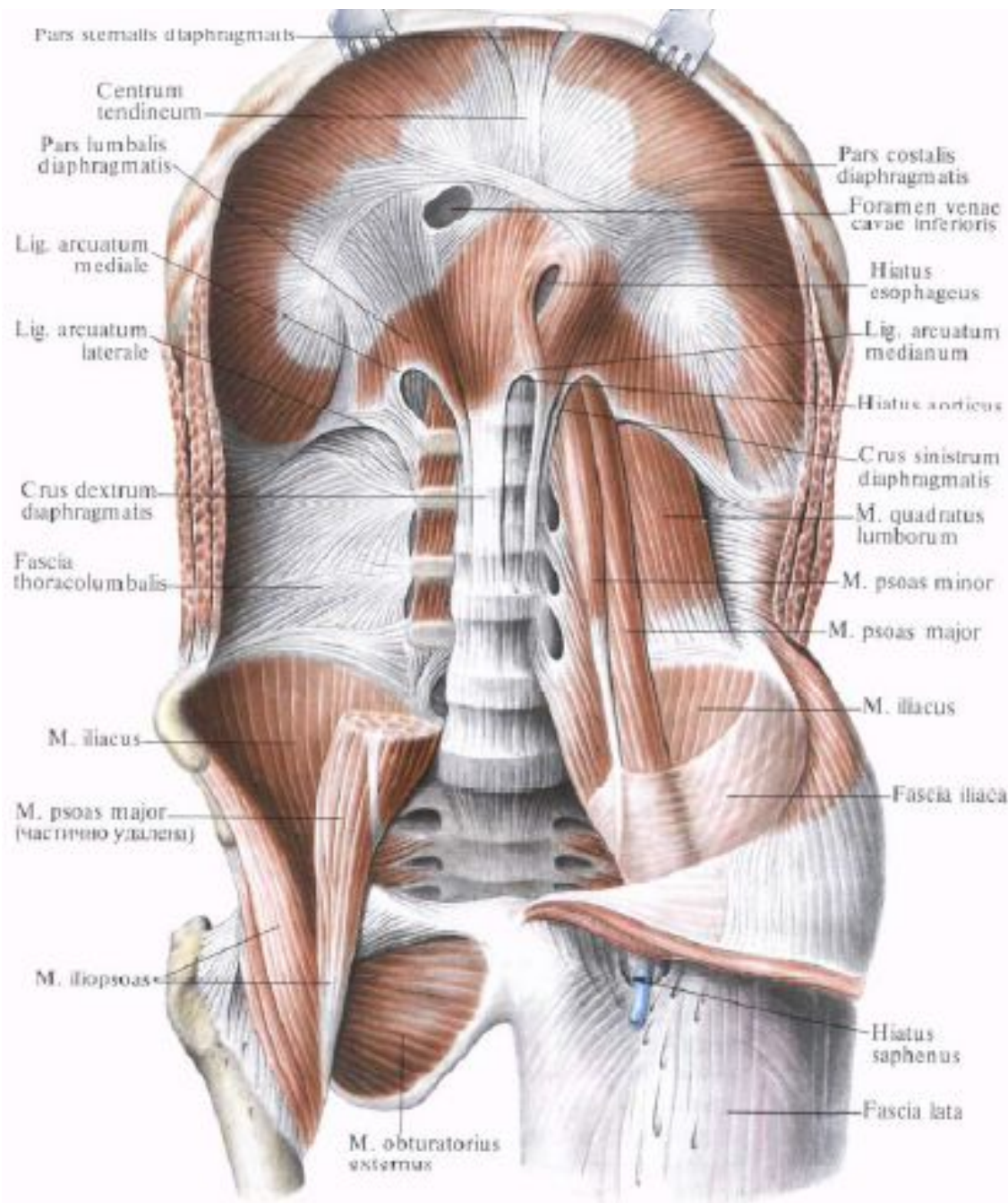


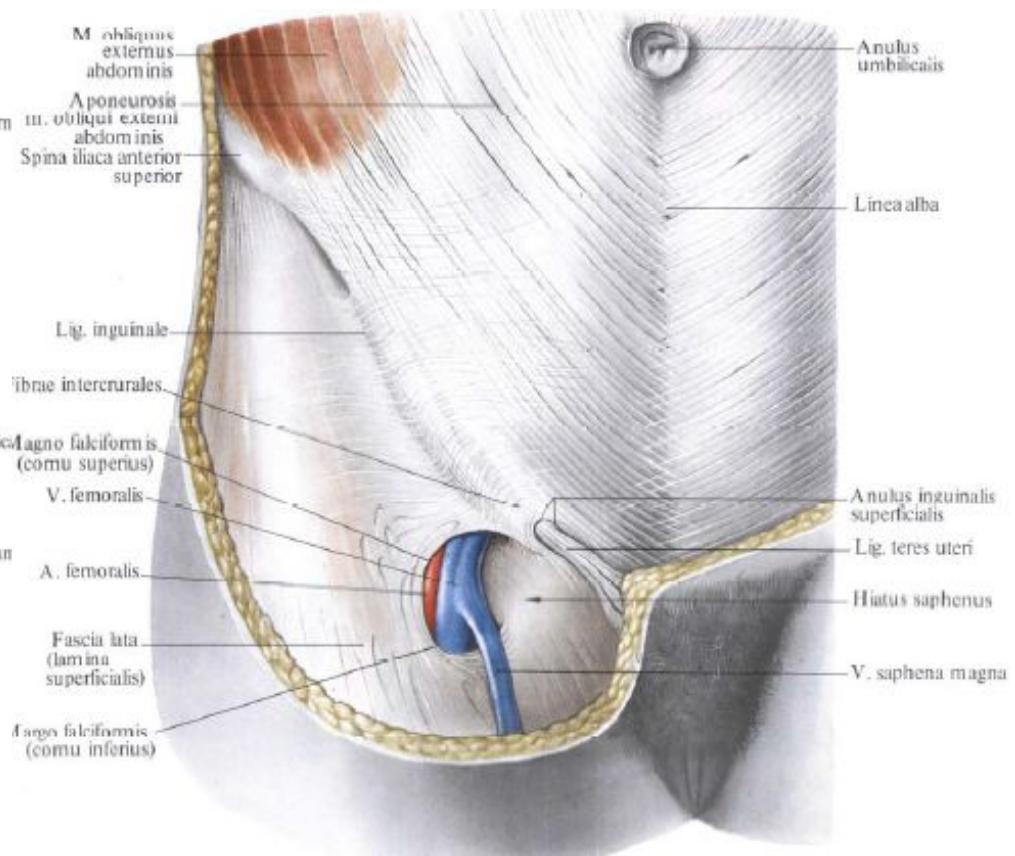
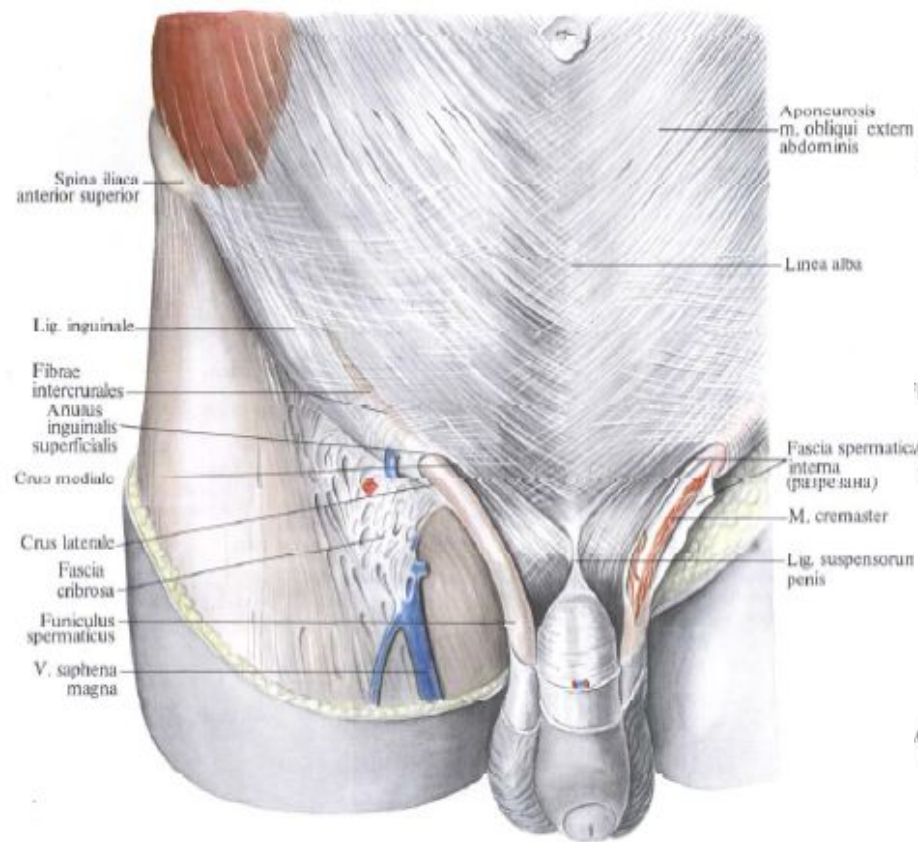
M. sternocleidomastoideus  
 M. omohyoideus (venter inferior)  
 M. trapezius  
 M. subclavius  
 M. pectoralis minor  
 M. deltoideus  
 M. coracobrachialis  
 M. pectoralis major  
 M. latissimus dorsi  
 M. biceps brachii  
 M. serratus anterior  
 M. brachialis  
 Tendo m. bicipitis brachii  
 Aponeuosis m. bicipitis brachii  
 Linea arcuata  
 Fascia transversalis  
 A. femoralis  
 V. femoralis  
 N. femoralis  
 M. tensor fasciae latae  
 M. sartorius  
 M. iliopsoas  
 M. pectineus  
 M. rectus femoris  
 M. adductor longus

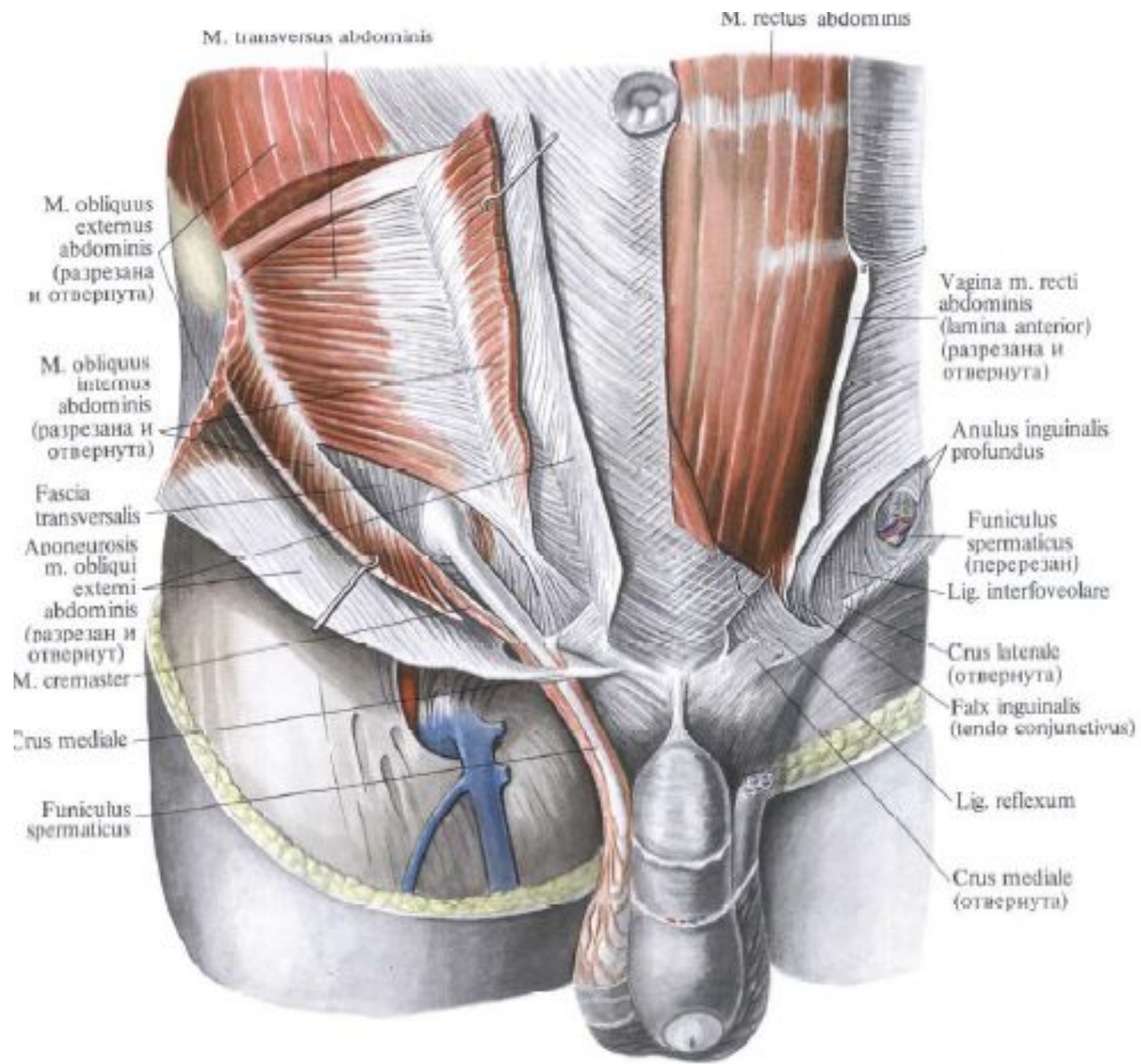
M. scalenus anterior  
 M. scalenus medius  
 M. scalenus posterior  
 M. omohyoideus (venter superior)  
 V. jugularis interna  
 A. subclavia  
 V. subclavia  
 Mm. intercostales externi  
 Fascia thoracica  
 Mm. intercostales interni  
 M. rectus abdominis  
 Intersectio tendineae  
 Linea alba  
 Vagina m. recti abdominis (lumina posterior)  
 Vagina m. recti abdominis (lumina anterior)  
 M. transversus abdominis  
 Lig. inguinale  
 Funiculus spermaticus  
 Hiatus saphenus  
 M. pyramidalis  
 Fascia lata  
 Admeniculum lineae albae











M. transversus abdominis

M. rectus abdominis

M. obliquus externus abdominis (разрезана и отвернута)

M. obliquus internus abdominis (разрезана и отвернута)

Fascia transversalis

Аponeurosis m. obliqui externi abdominis (разрезан и отвернут)

M. cremaster

Crus mediale

Funiculus spermaticus

Vagina m. recti abdominis (lamina anterior) (разрезана и отвернута)

Anulus inguinalis profundus

Funiculus spermaticus (перерезан)

Lig. interfoveolare

Crus laterale (отвернута)

Falx inguinalis (tendo conjunctivus)

Lig. reflexum

Crus mediale (отвернута)



