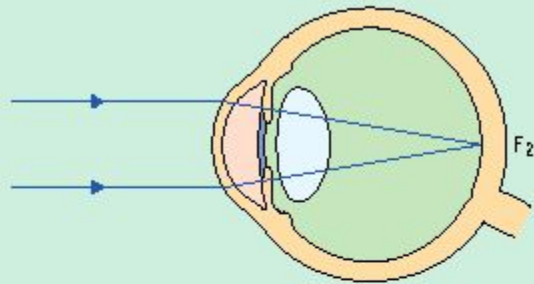


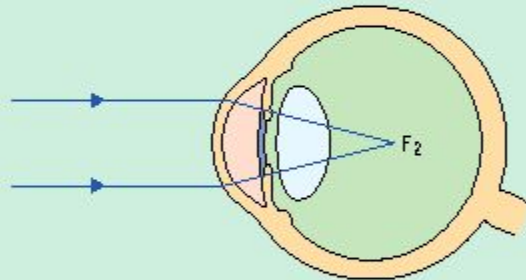
# РЕФРАКЦИЯ. АККОМОДАЦИЯ

# EMMETROPIA, MYOPIA, AND HYPEROPIA

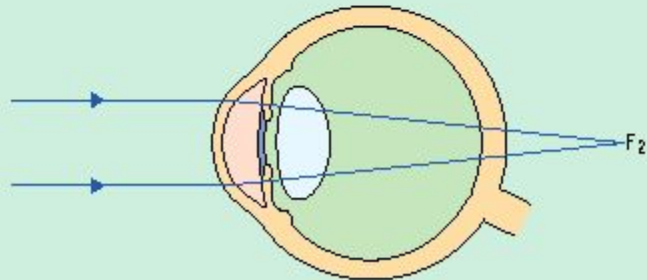
## Emmetropia

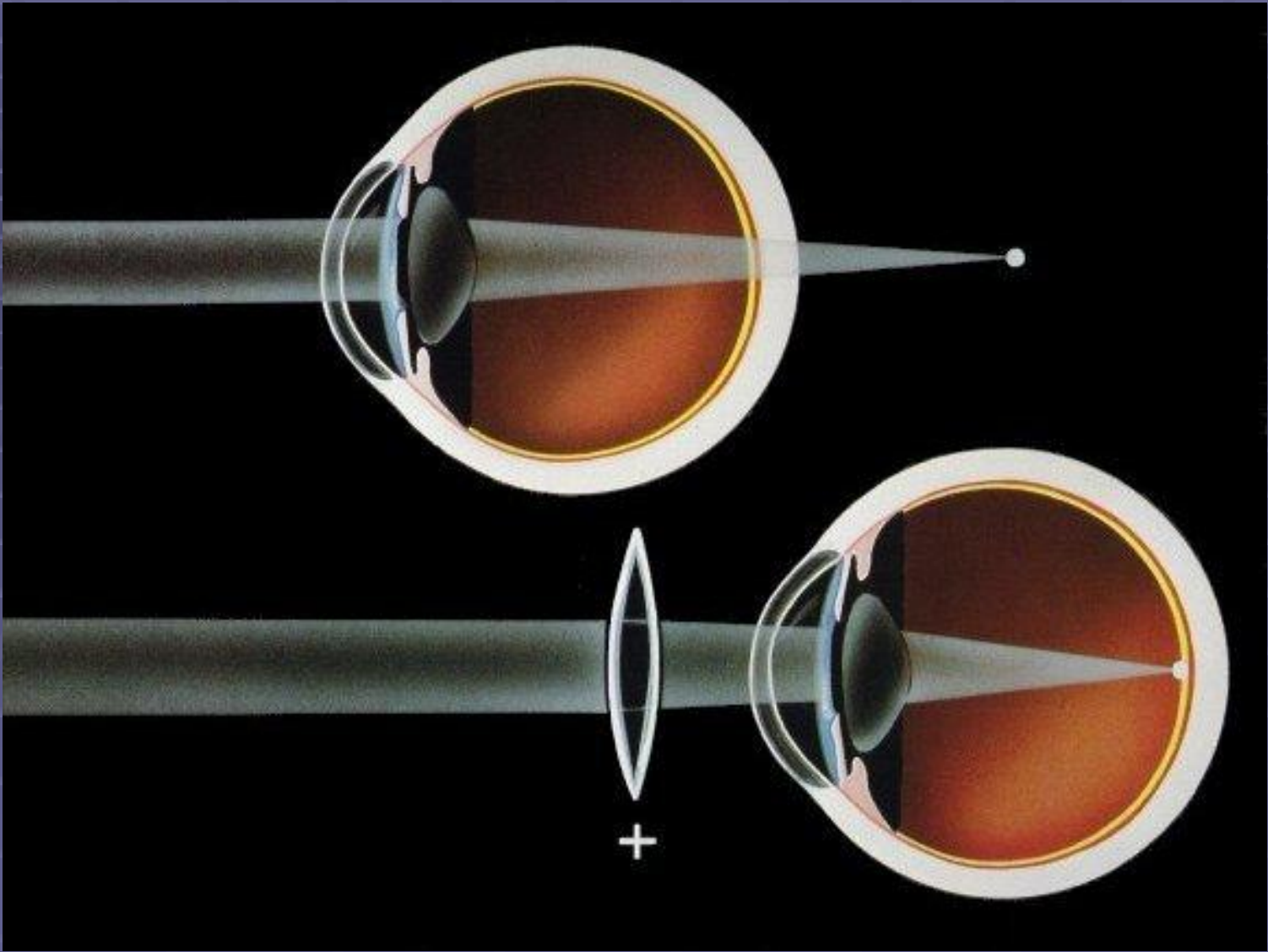


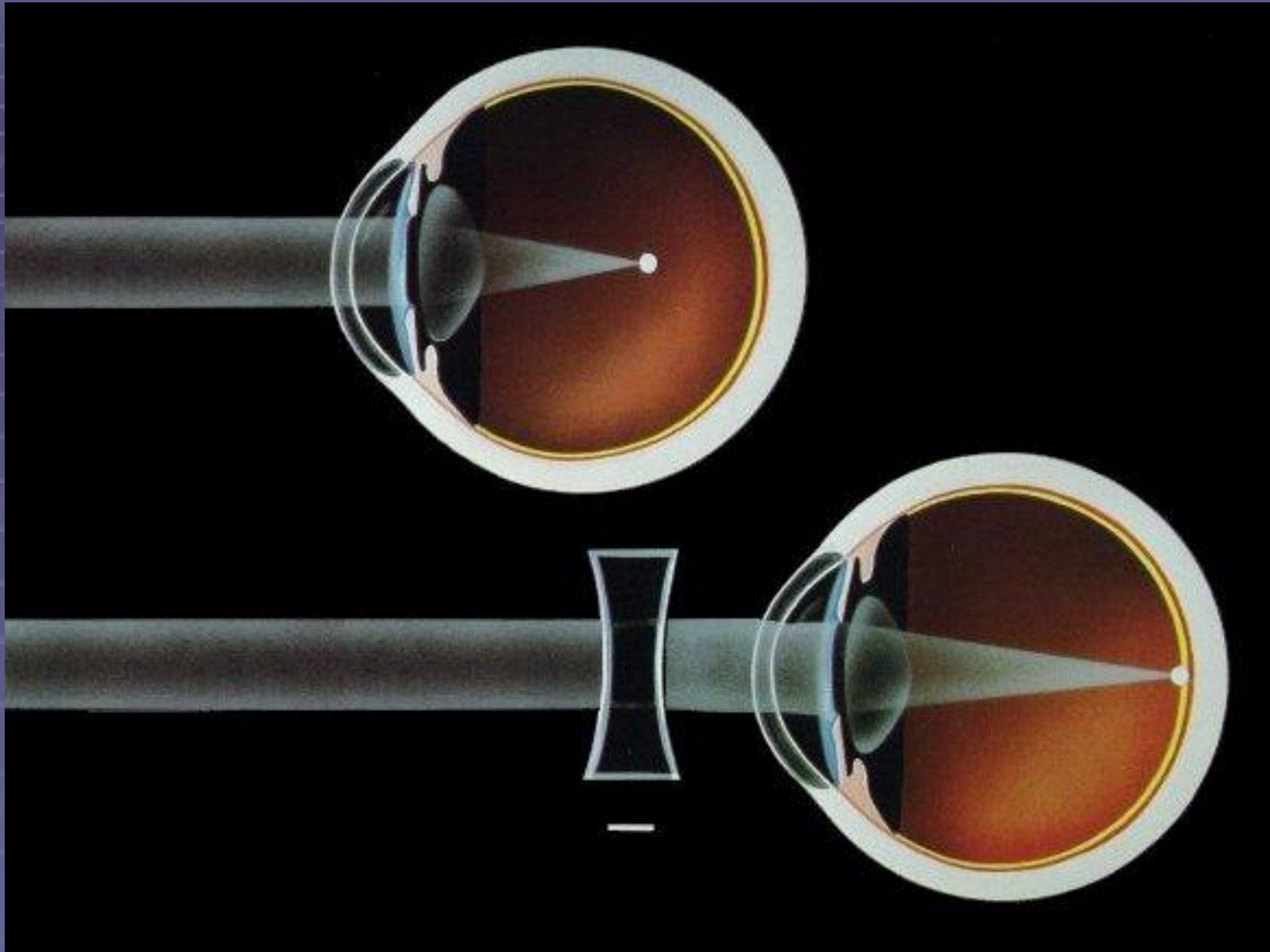
## Myopia

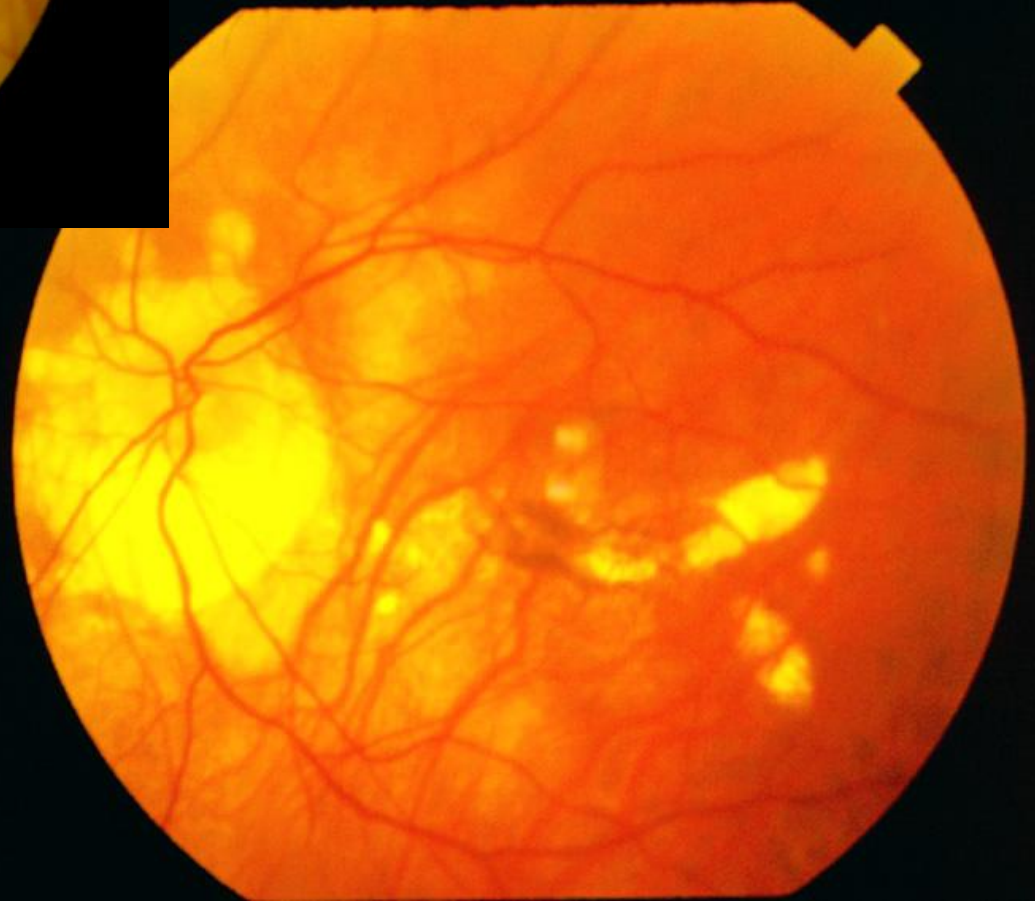
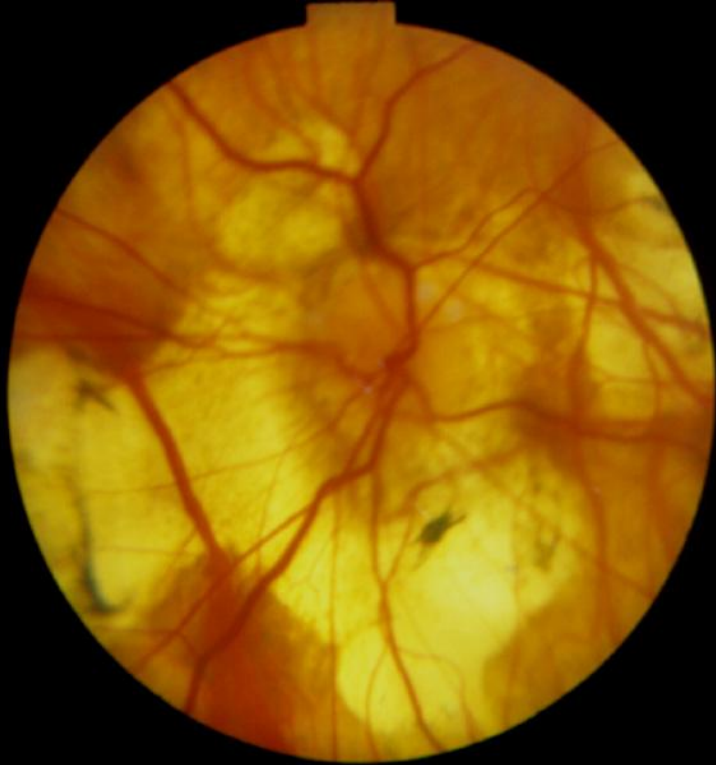
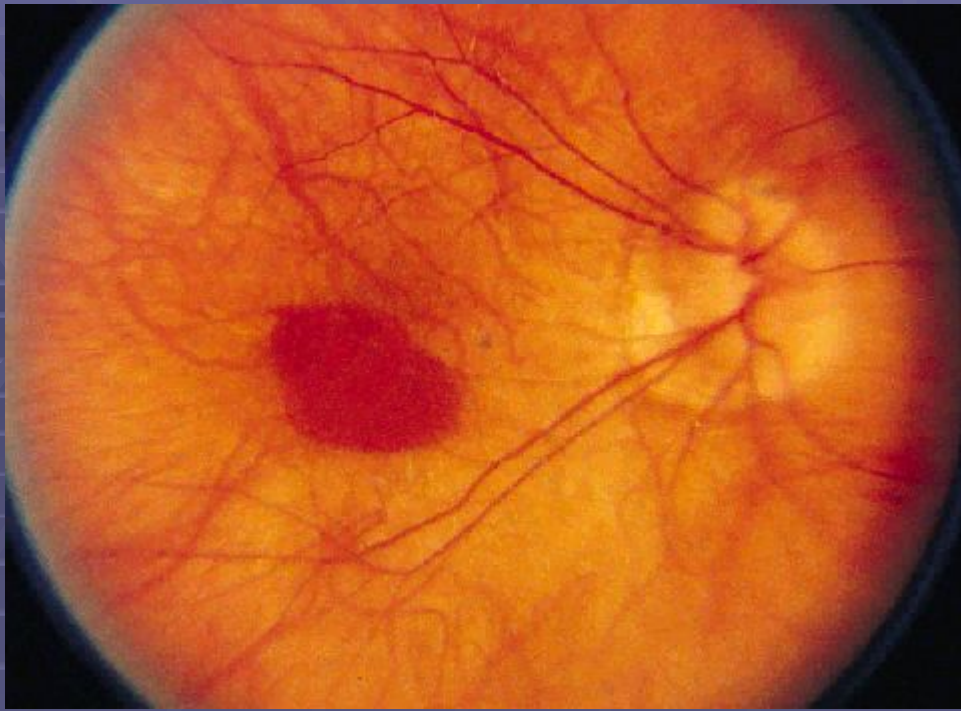
## Hyperopia



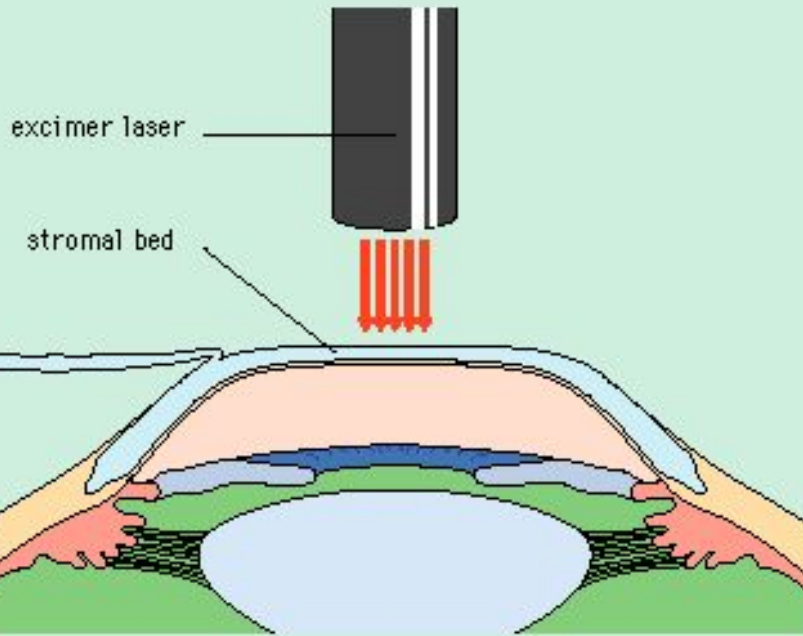






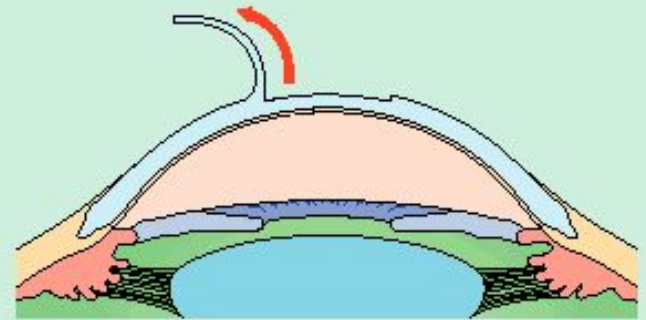


## LASER IN SITU KERATOMILEUSIS

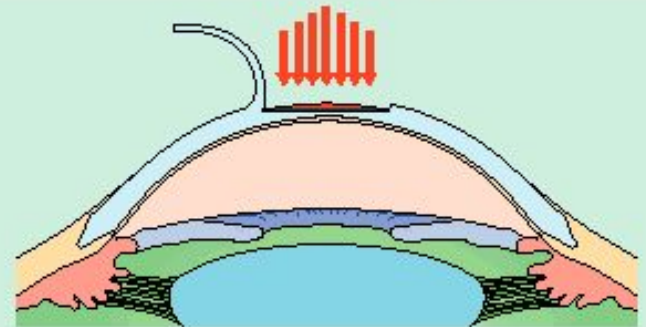


## LASER-ASSISTED STROMAL IN SITU KERATOMILEUSIS

Flap lifted from eye



Lenticle removed using laser light



Flap sewn back down

