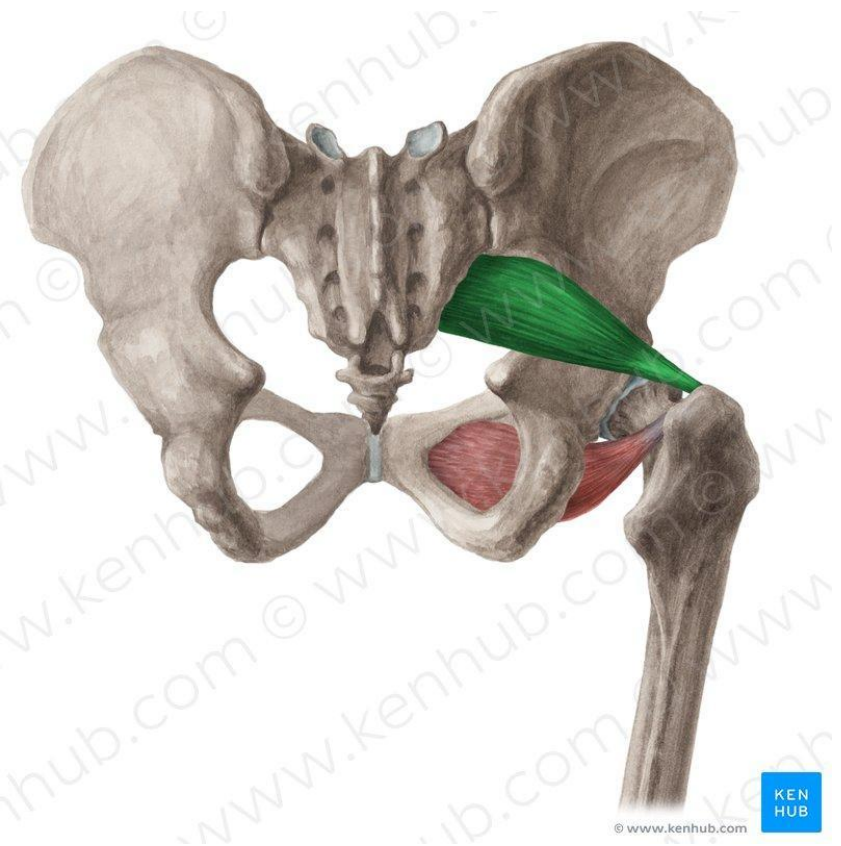
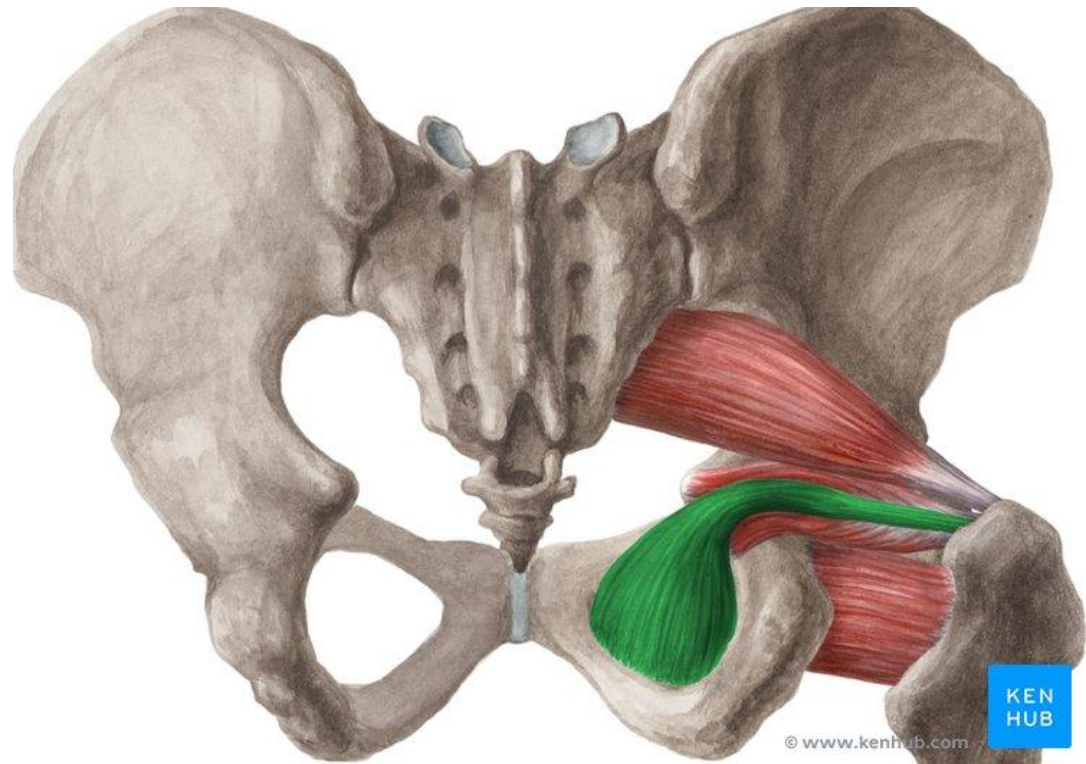




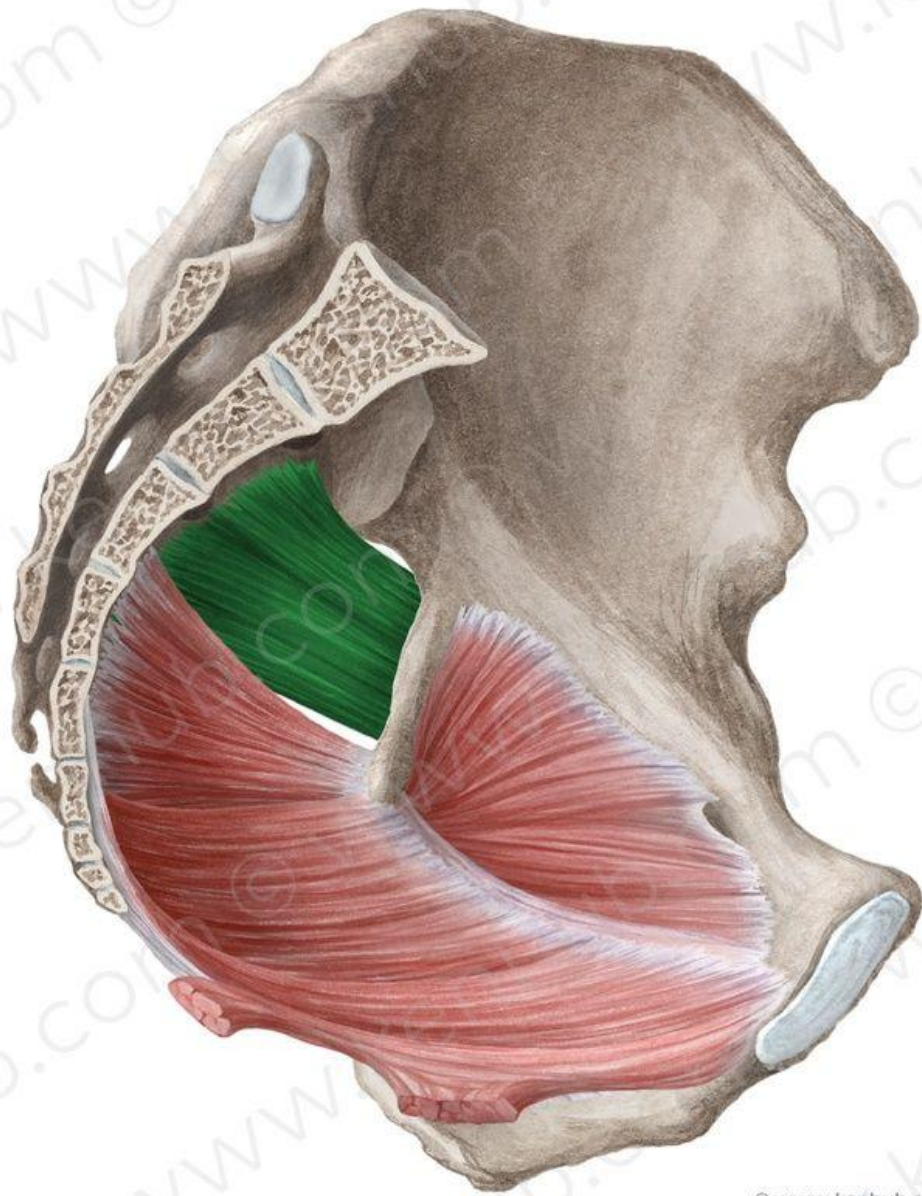
# Топографическая анатомия малого таза и промежности



m. piriformis



m. obturatorius  
internus

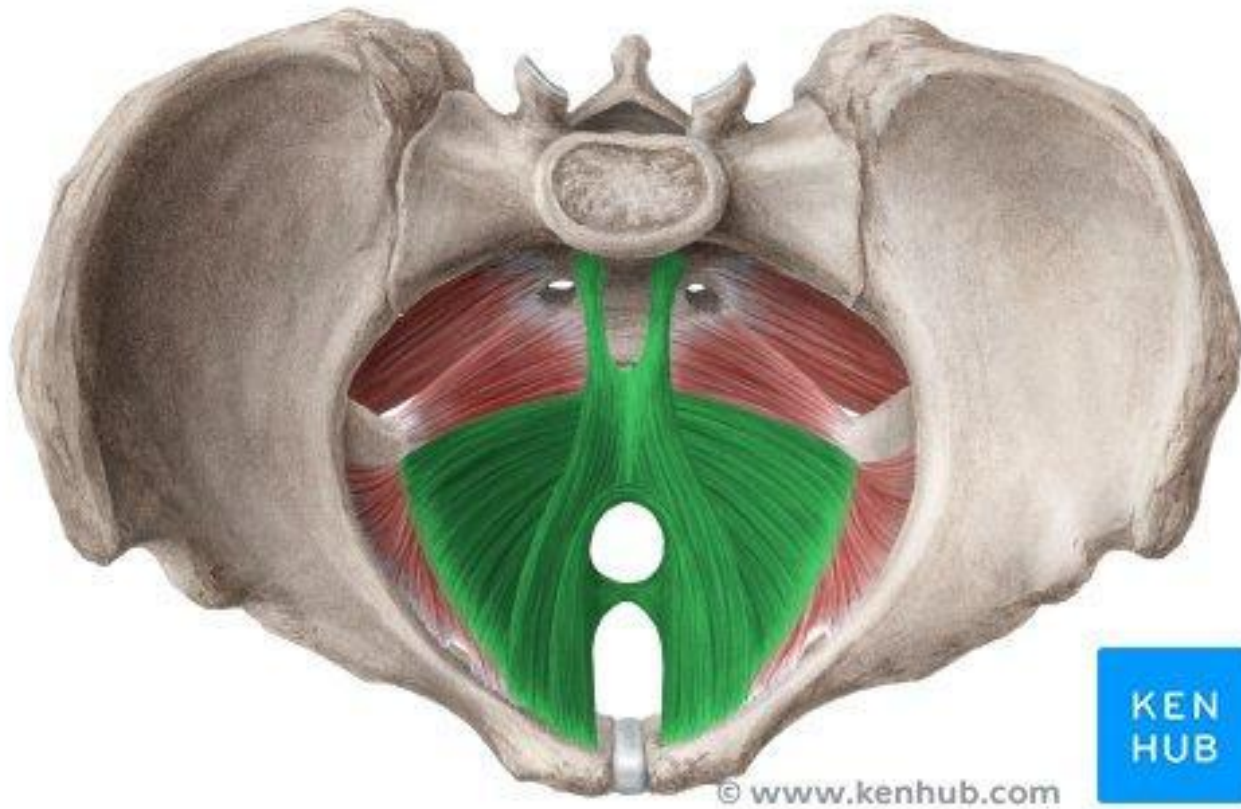


© www.kenhub.com



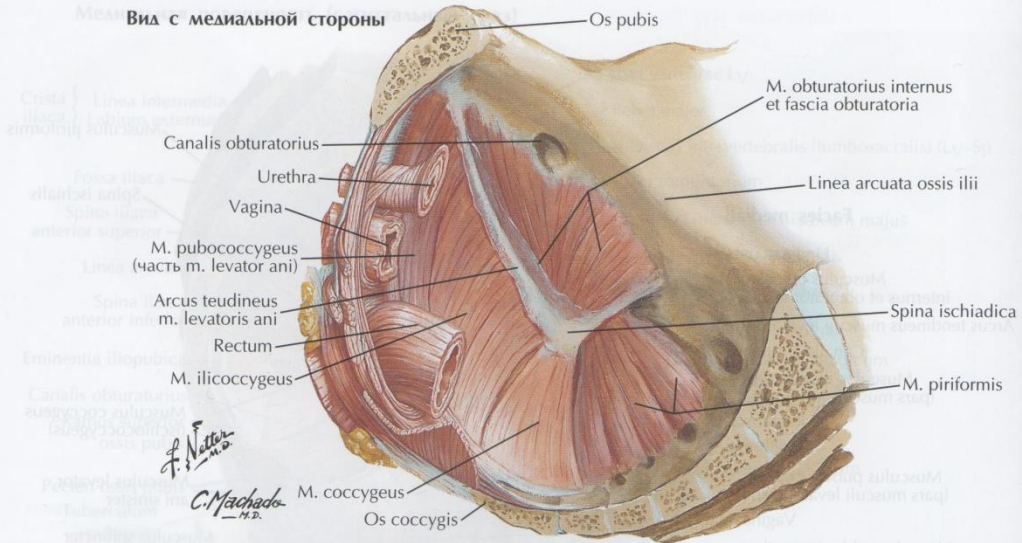
m. coccygeus

# Диафрагма таза

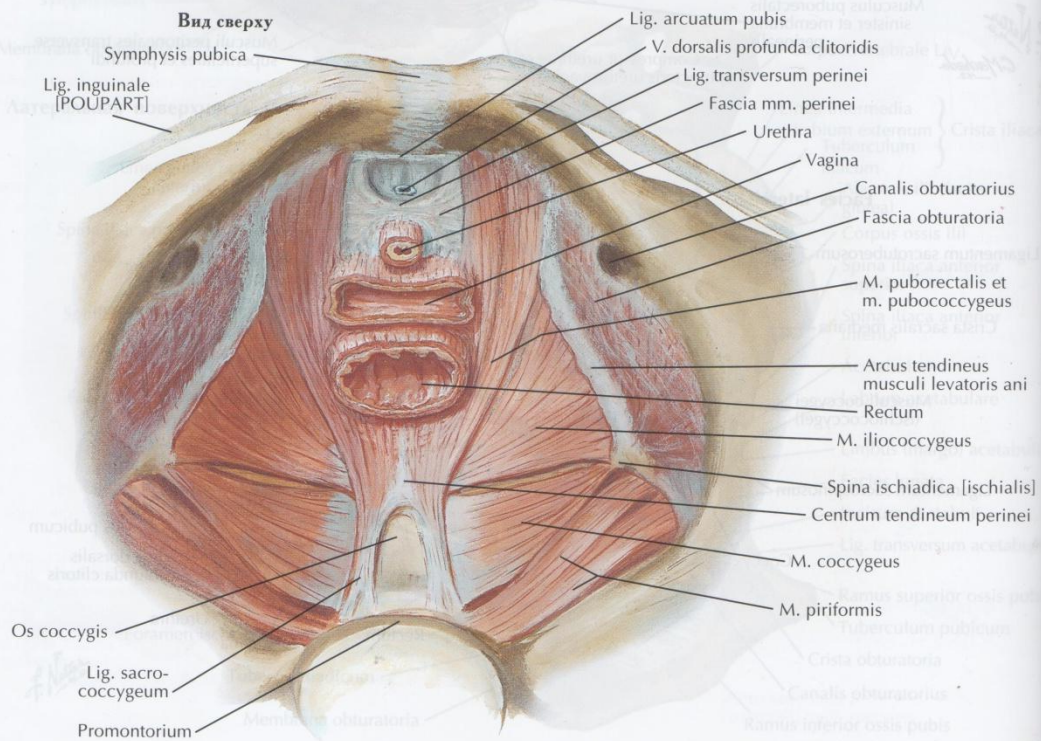


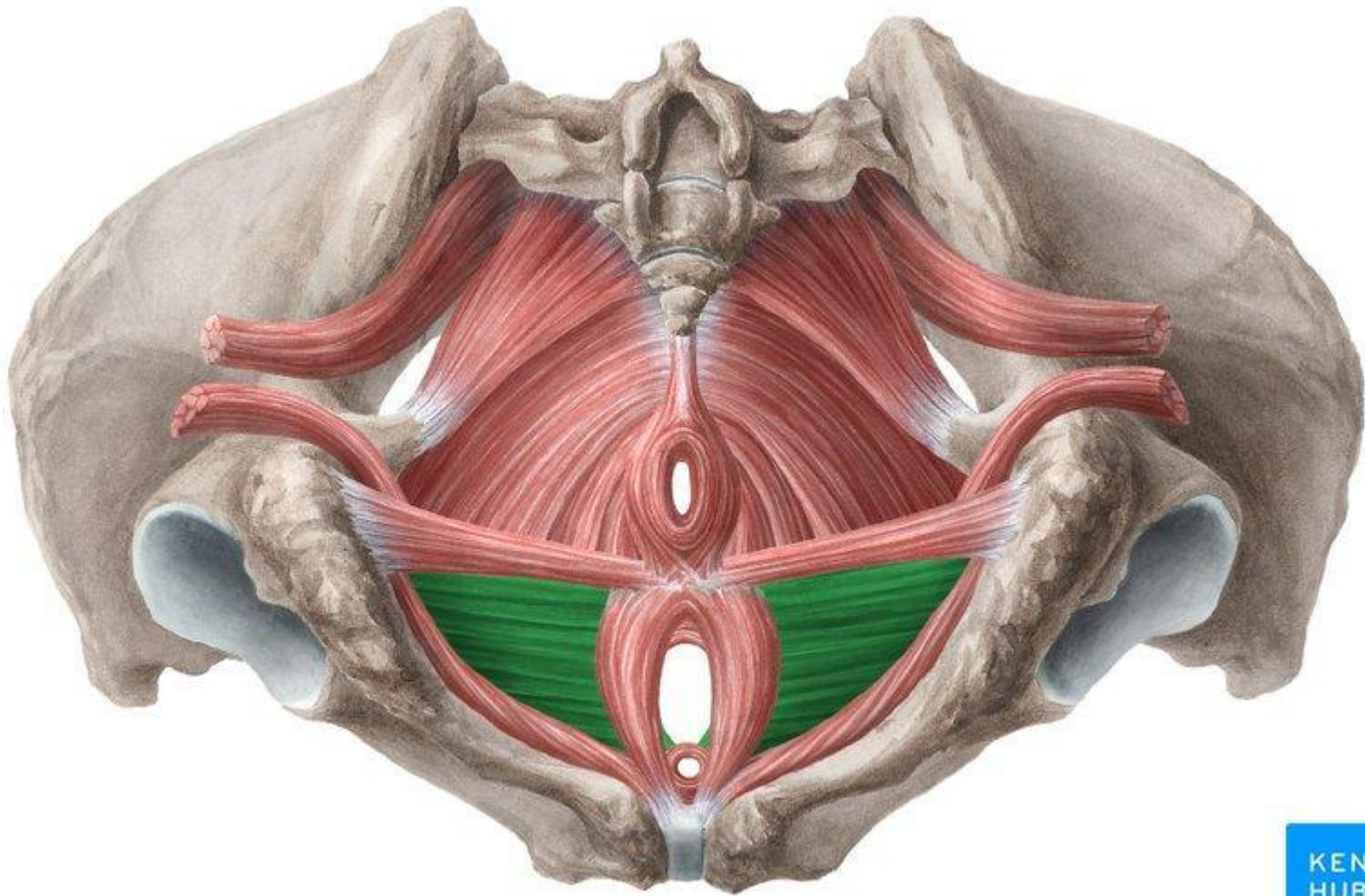
m.levator ani

**Вид с медиальной стороны**



**Вид сверху**



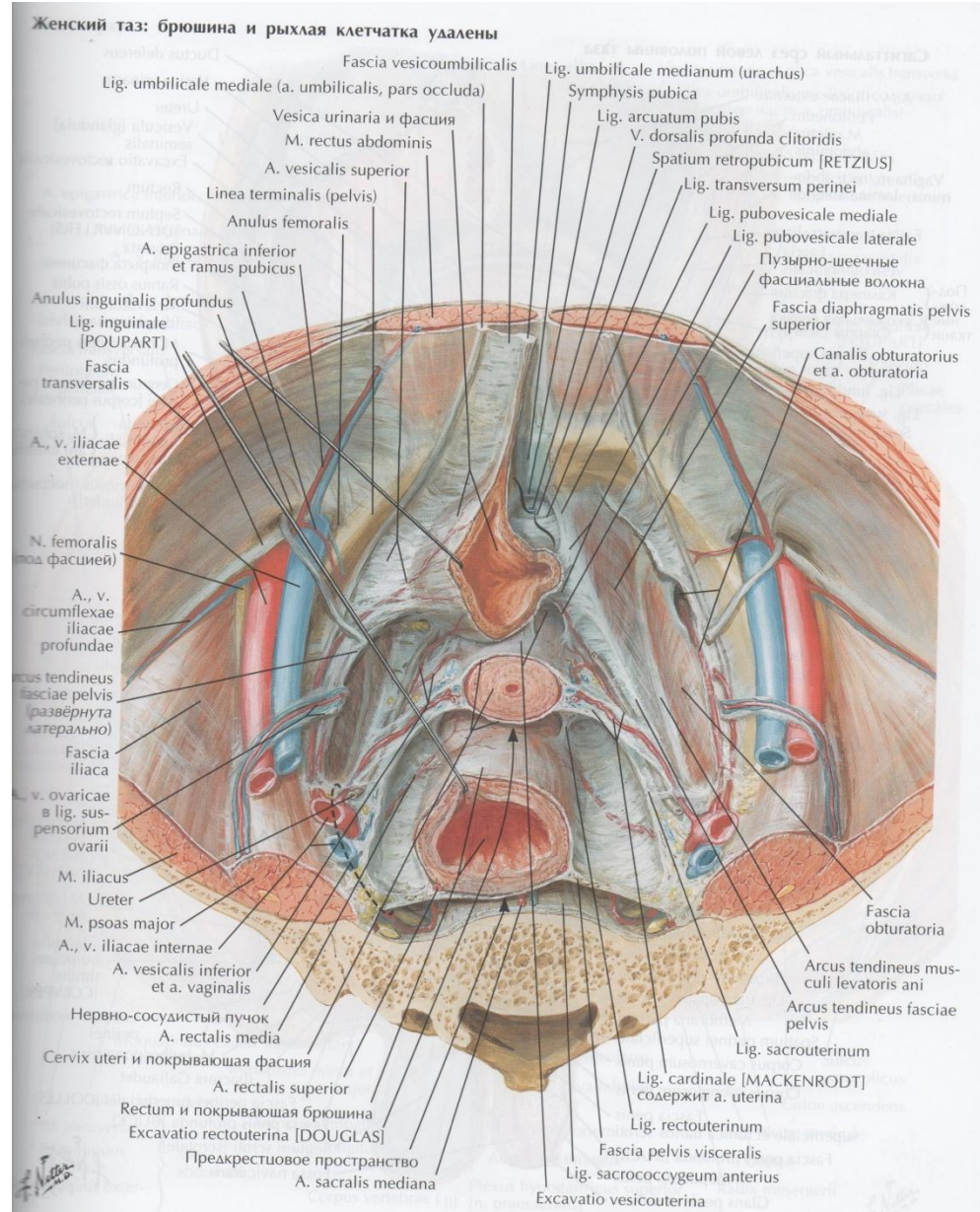


© www.kenhub.com

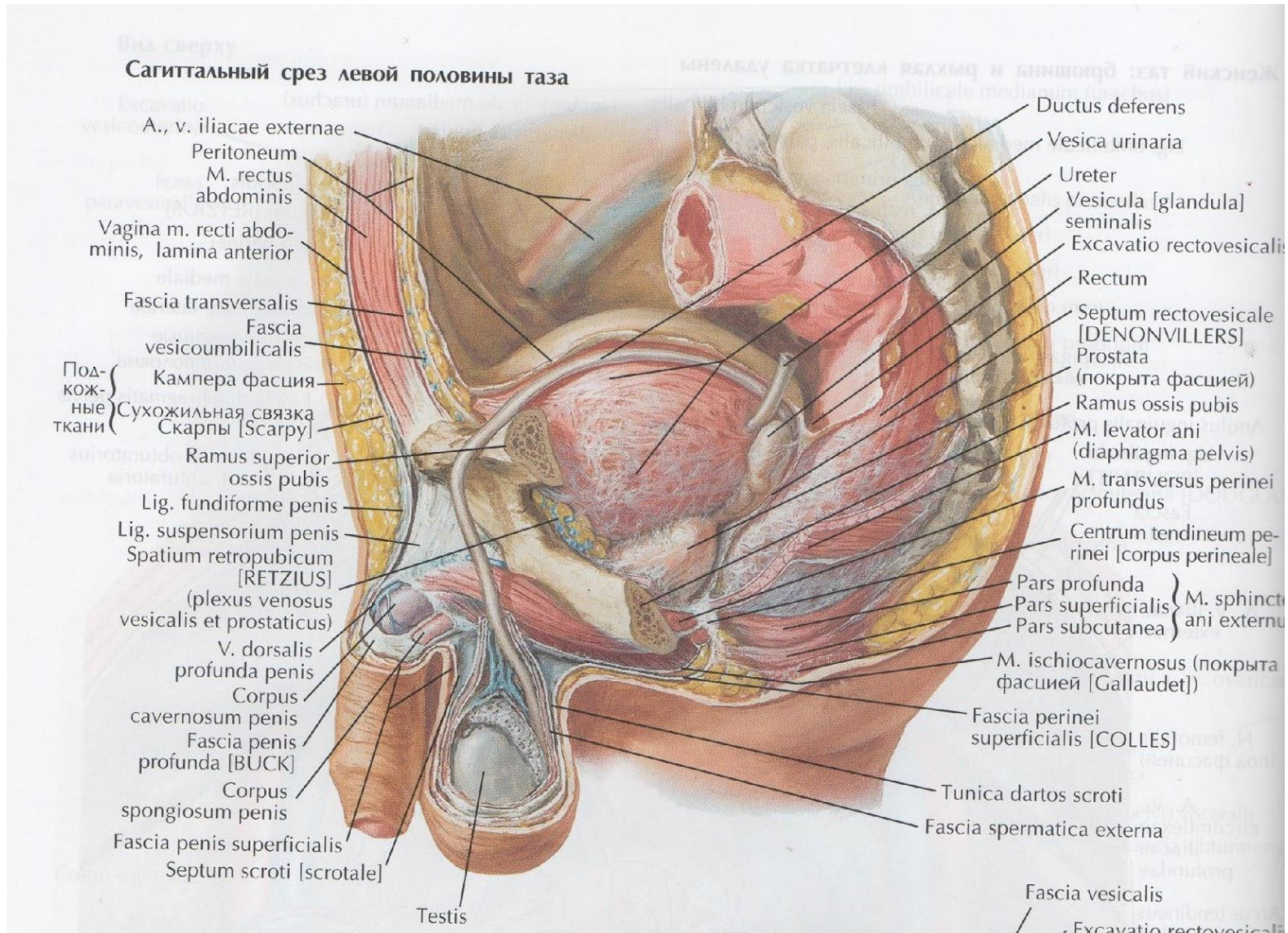


m. transversus perinei profundus

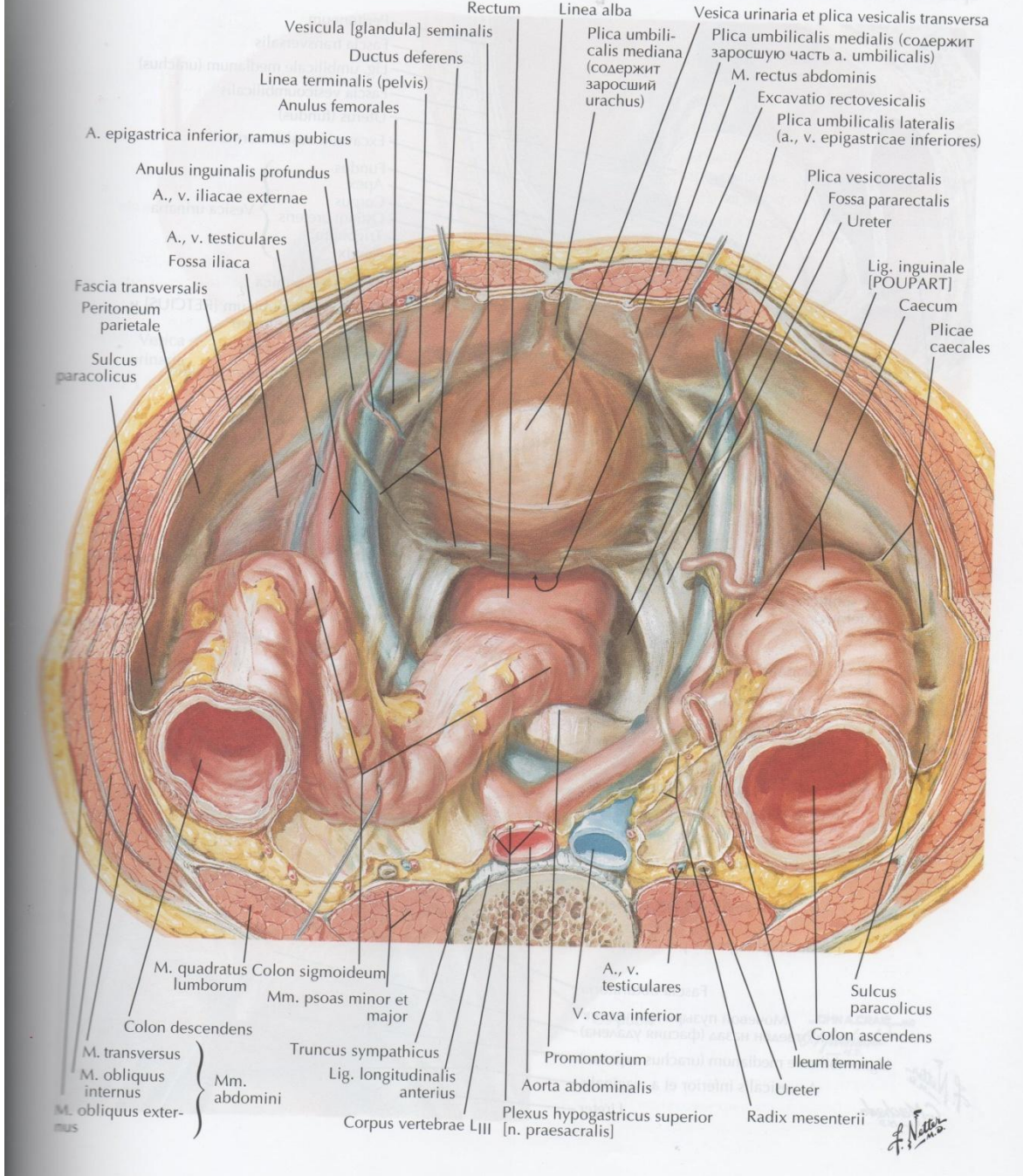
# Фасции таза



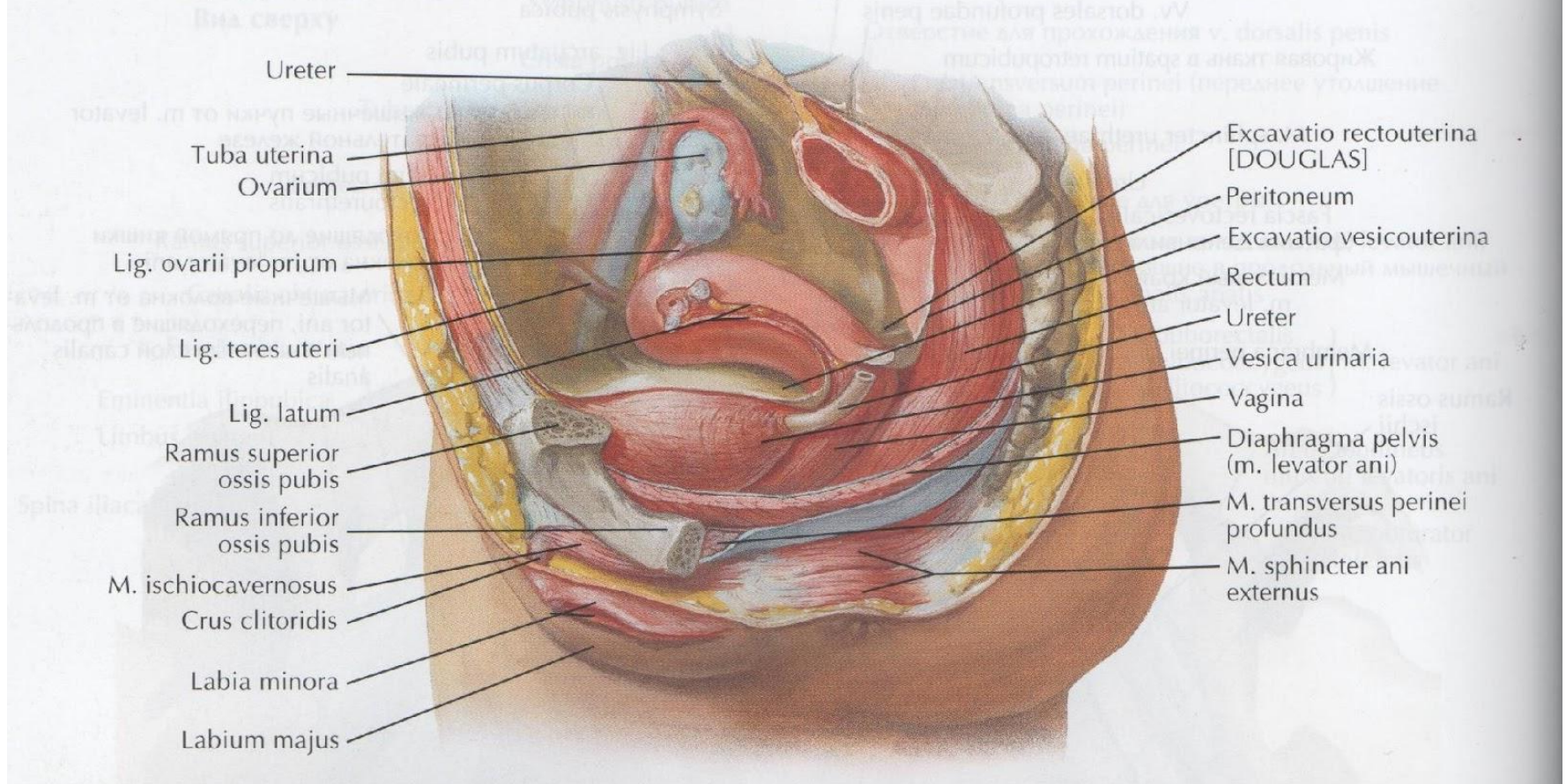
# Cavum pelvis peritoneale

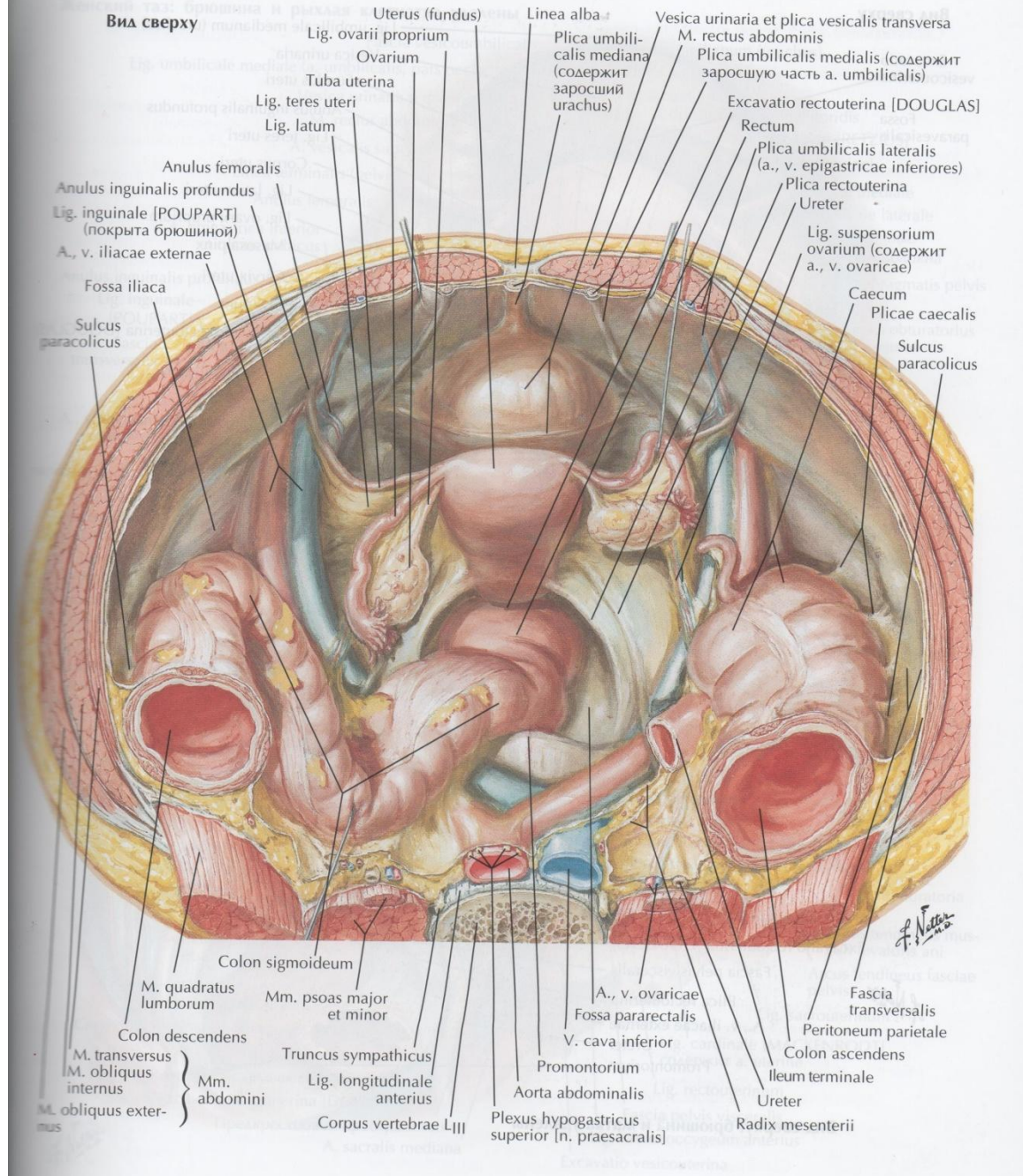




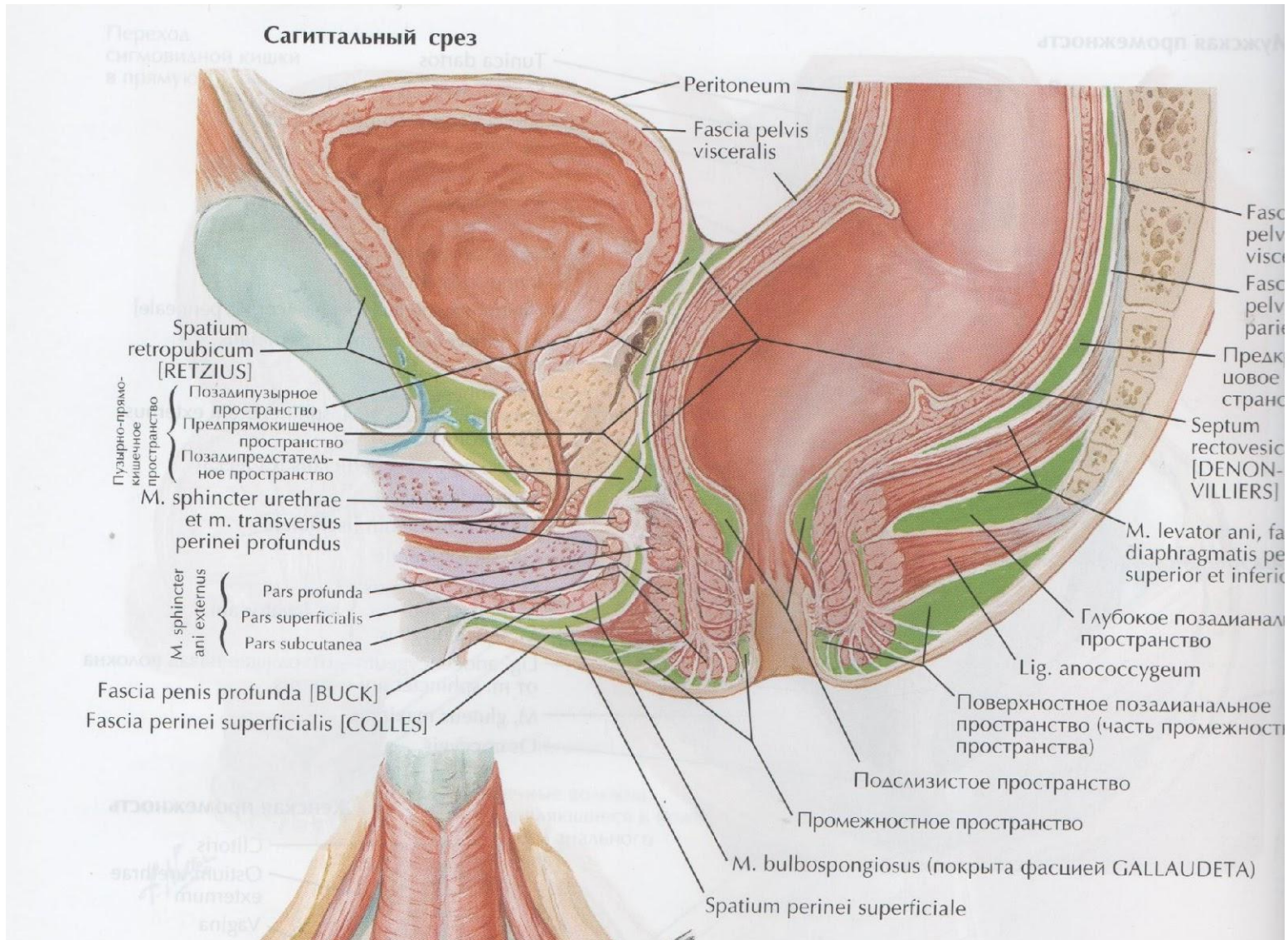


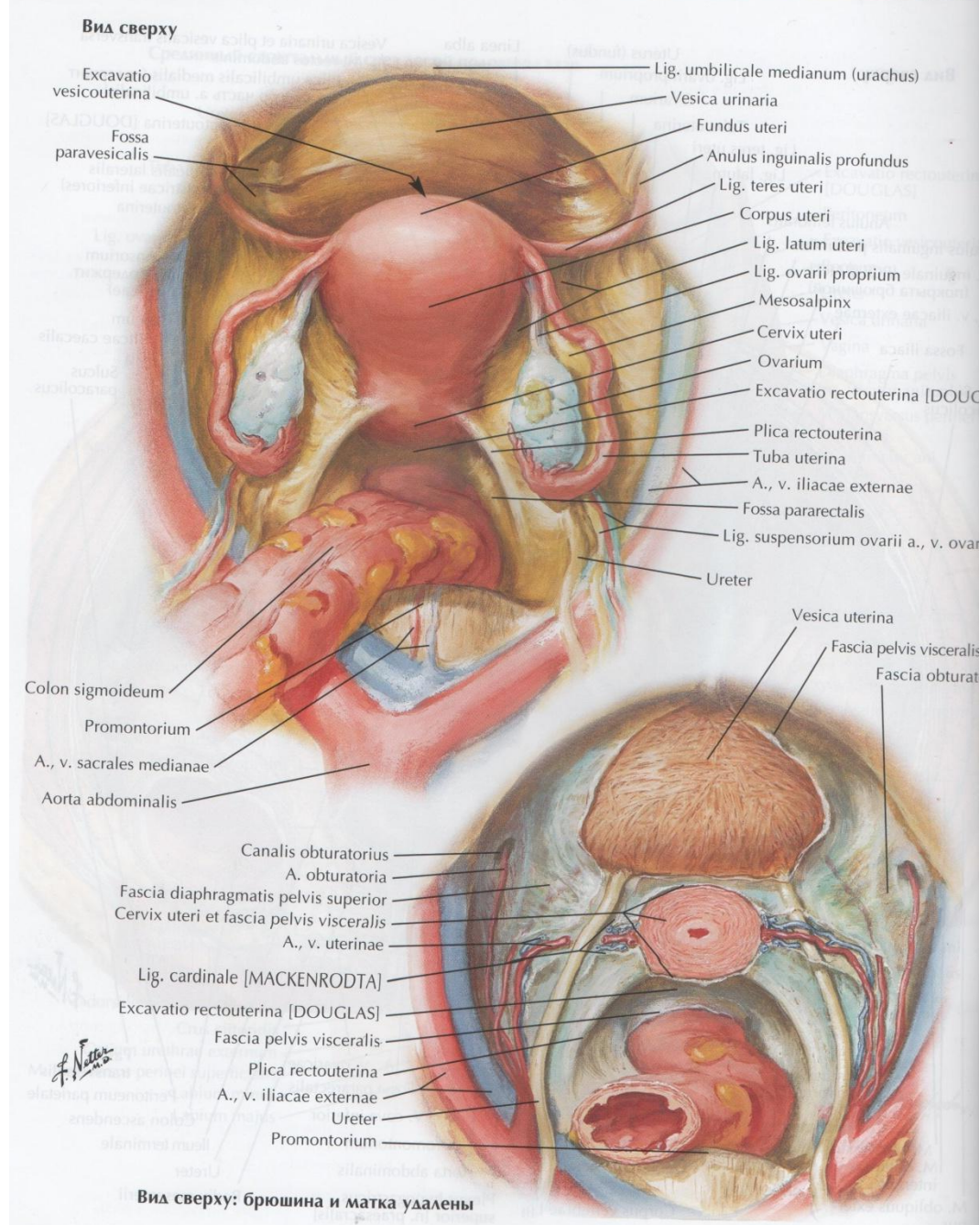
## Срединный сагиттальный срез левой половины таза



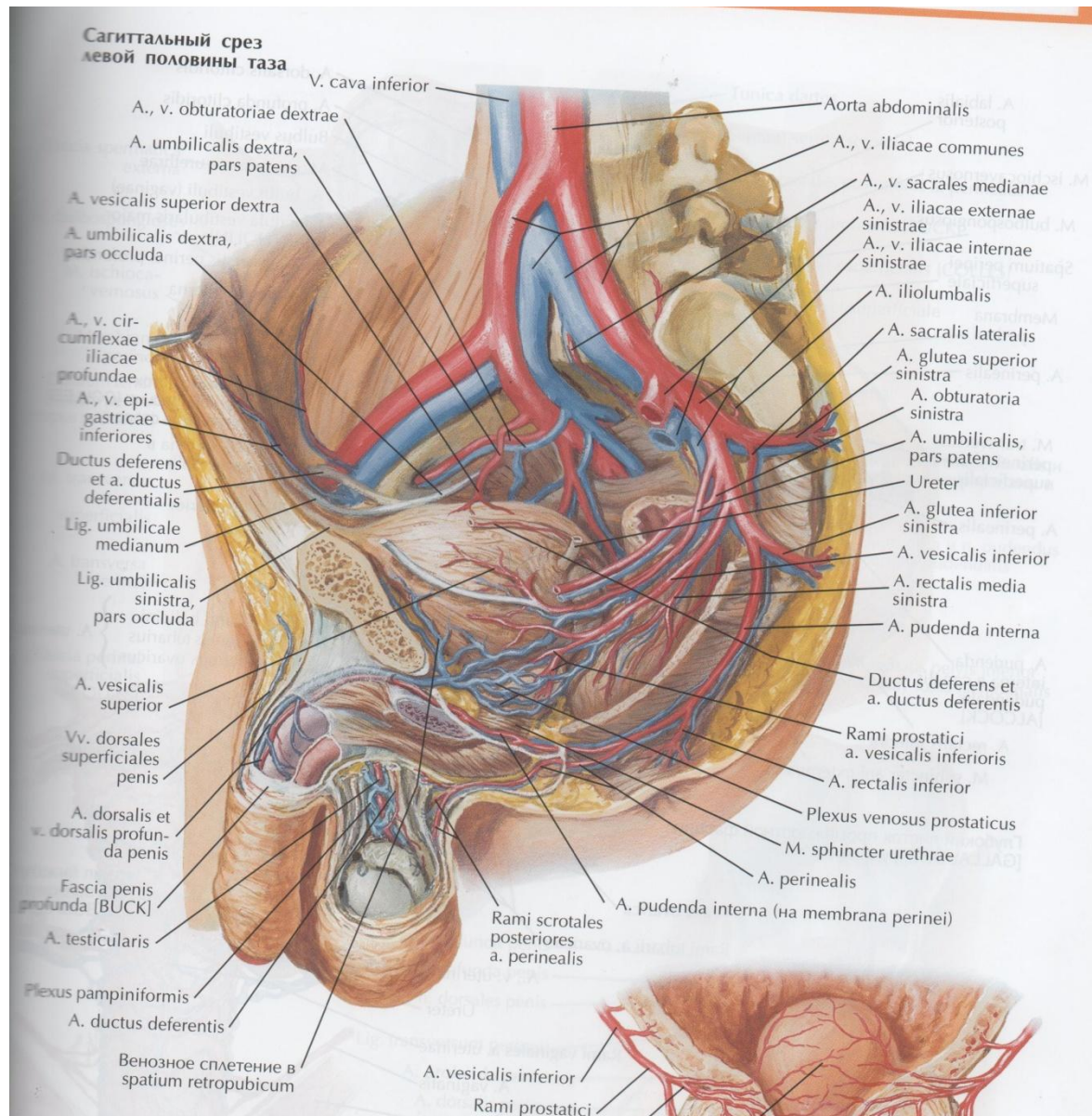


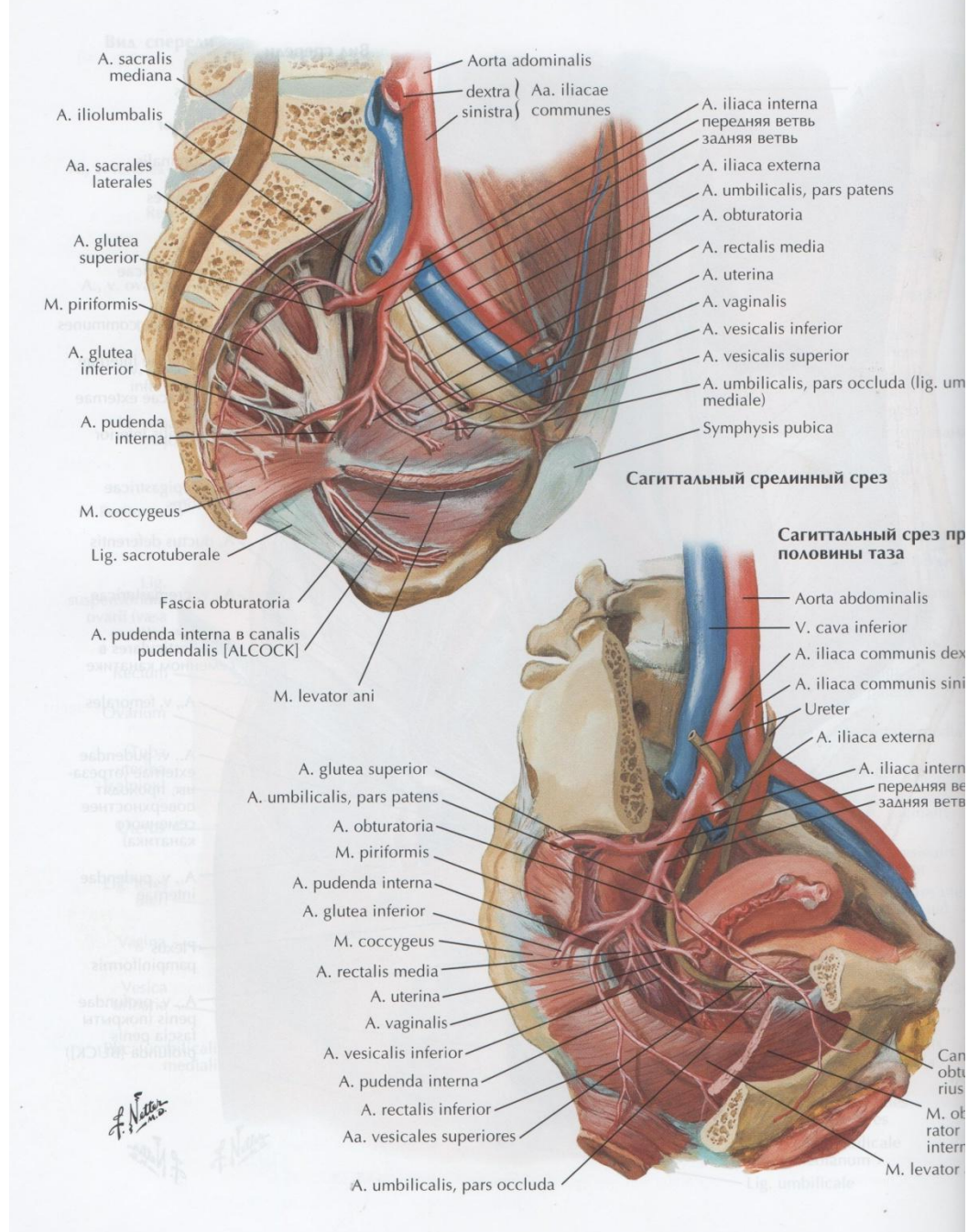
# Cavum pelvis subperitoneale



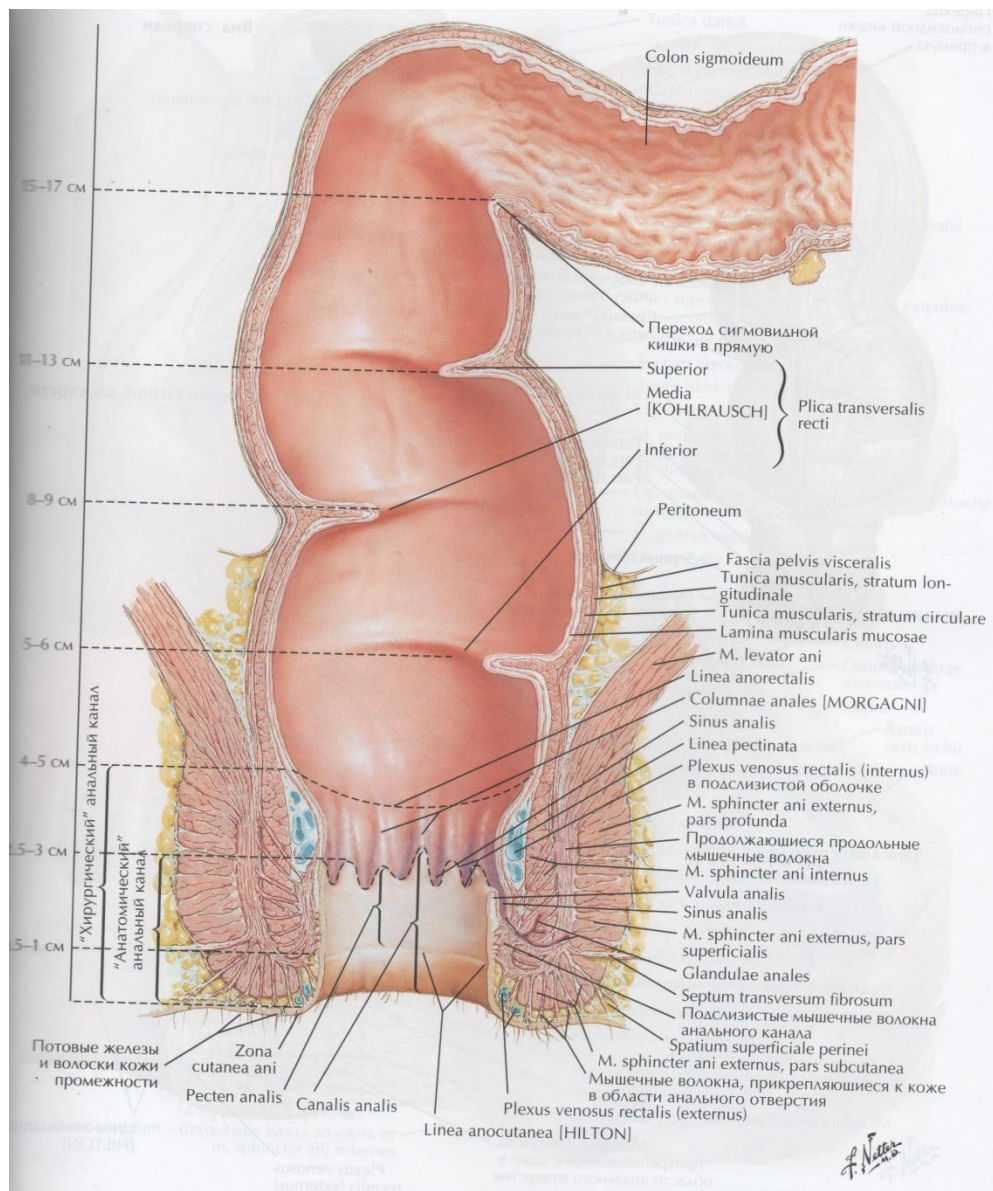


# A. iliaca interna



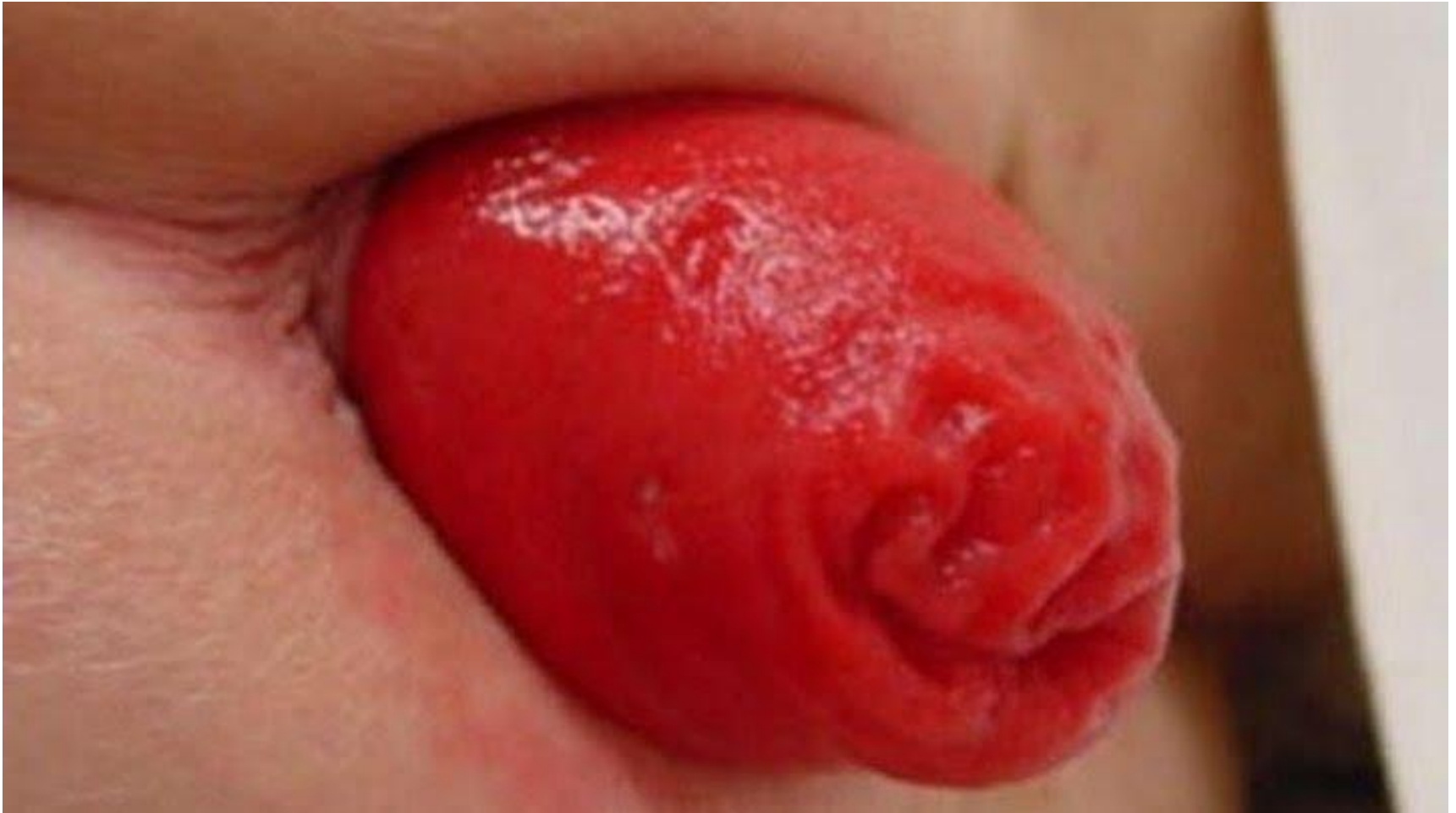

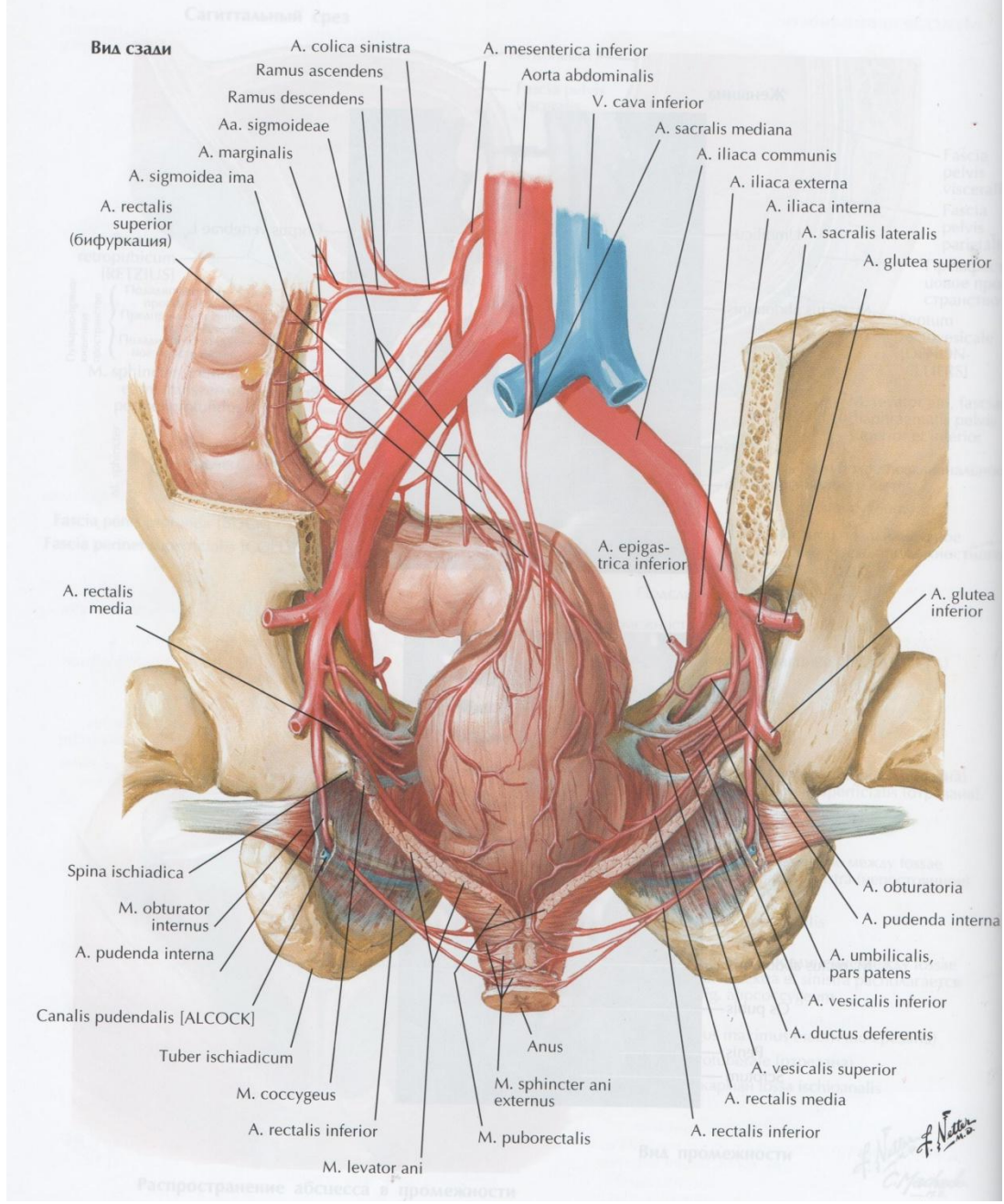
# Rectum

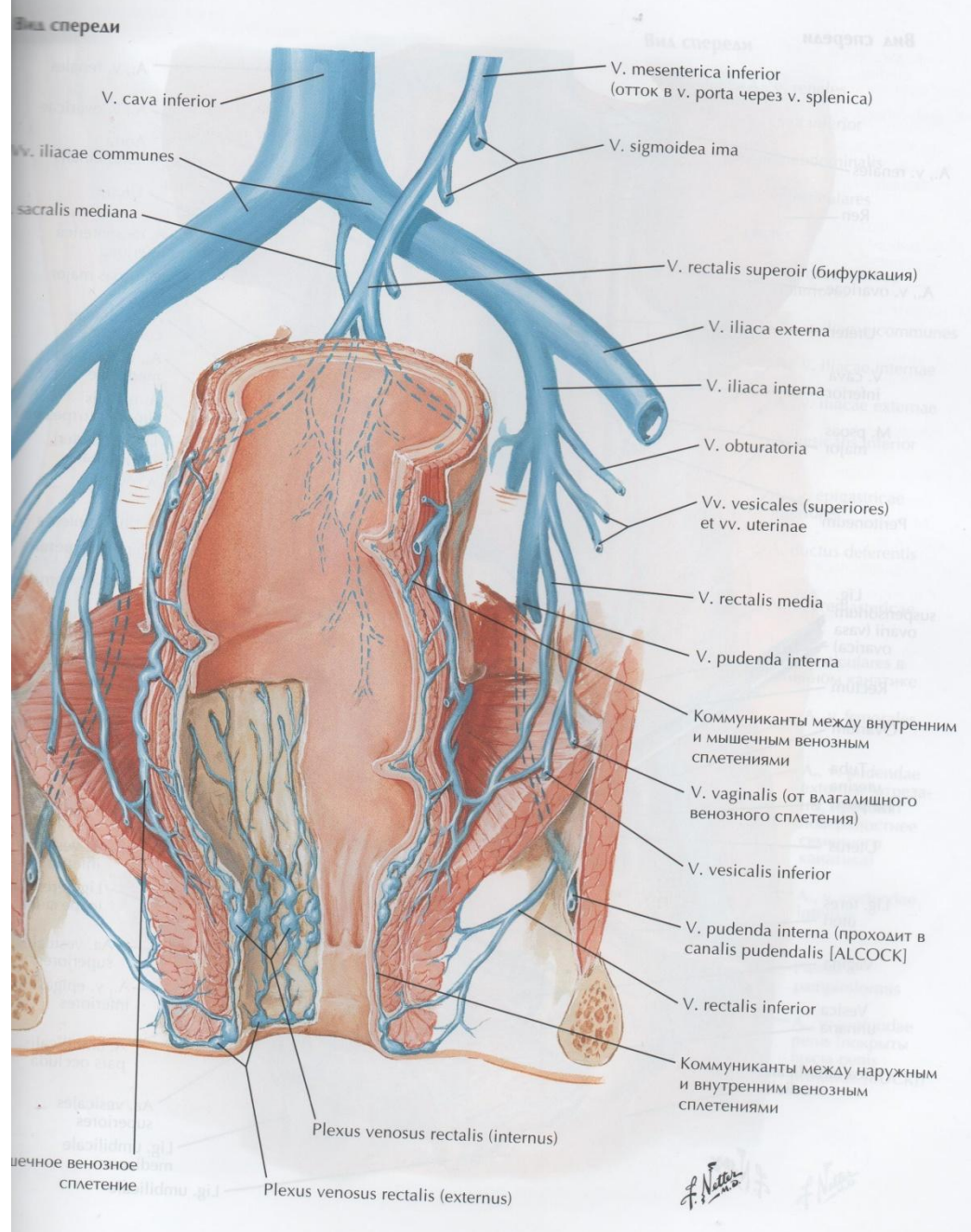


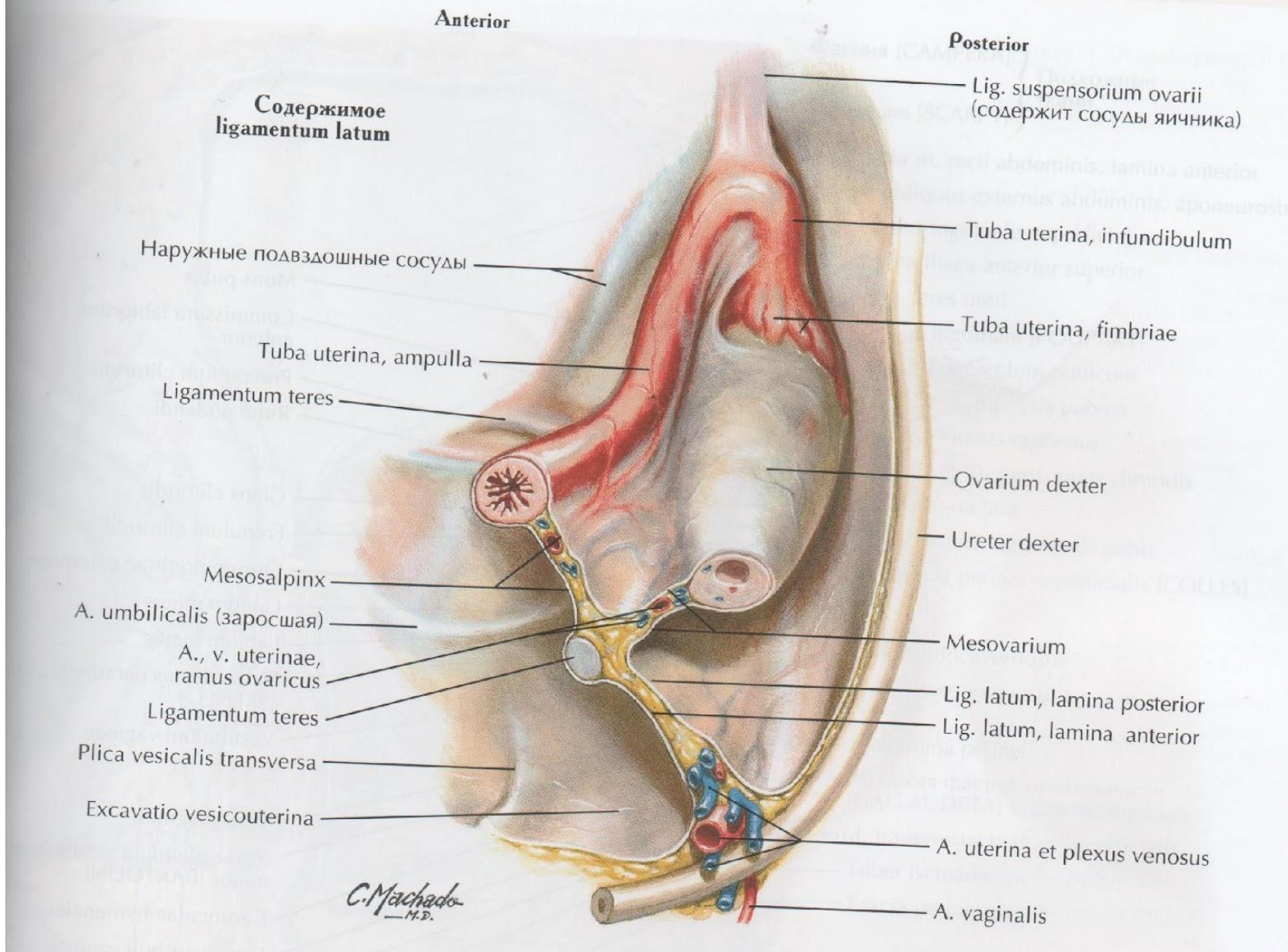


# Выпадение прямой кишки (МКБ—10: K62.3)

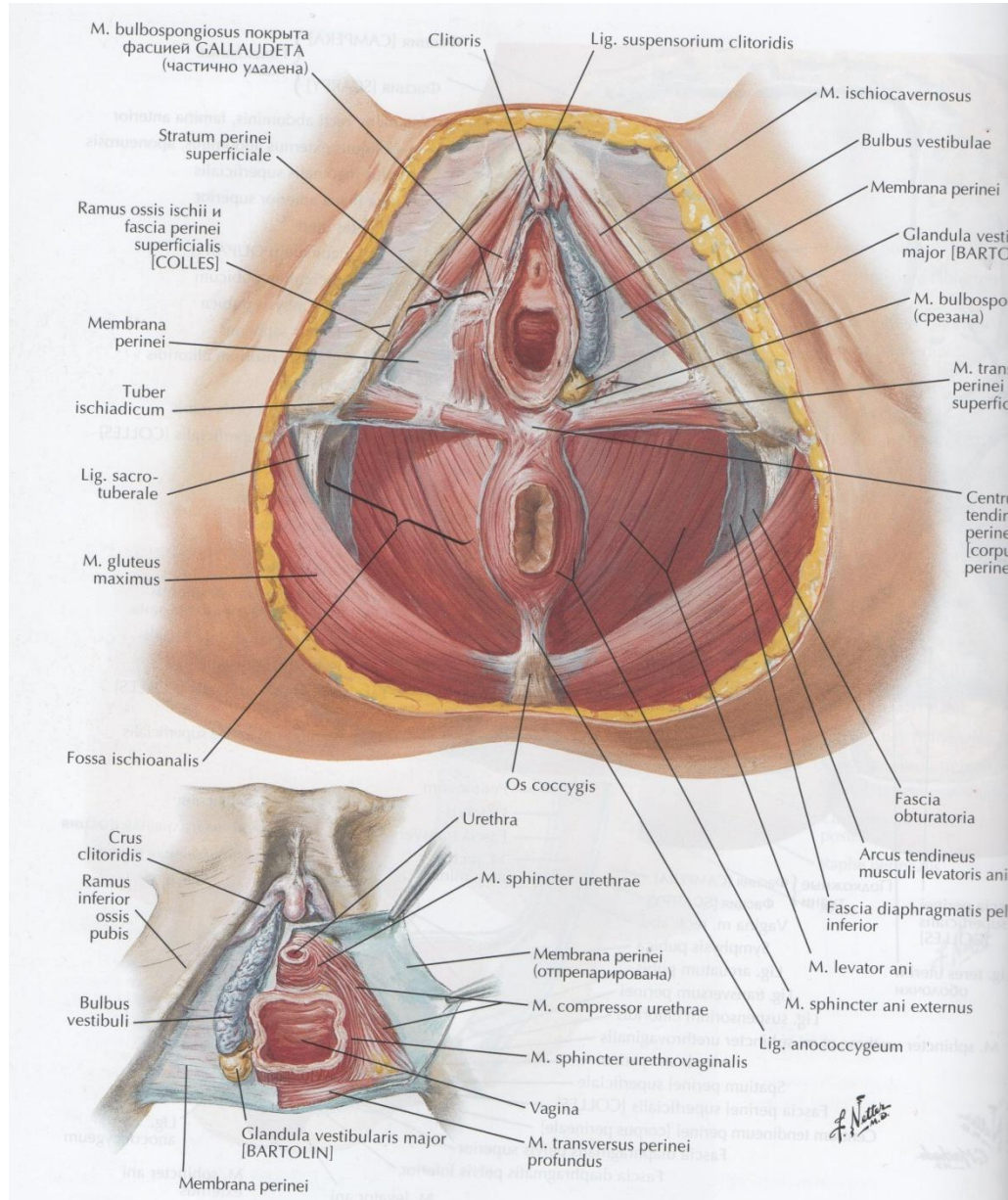


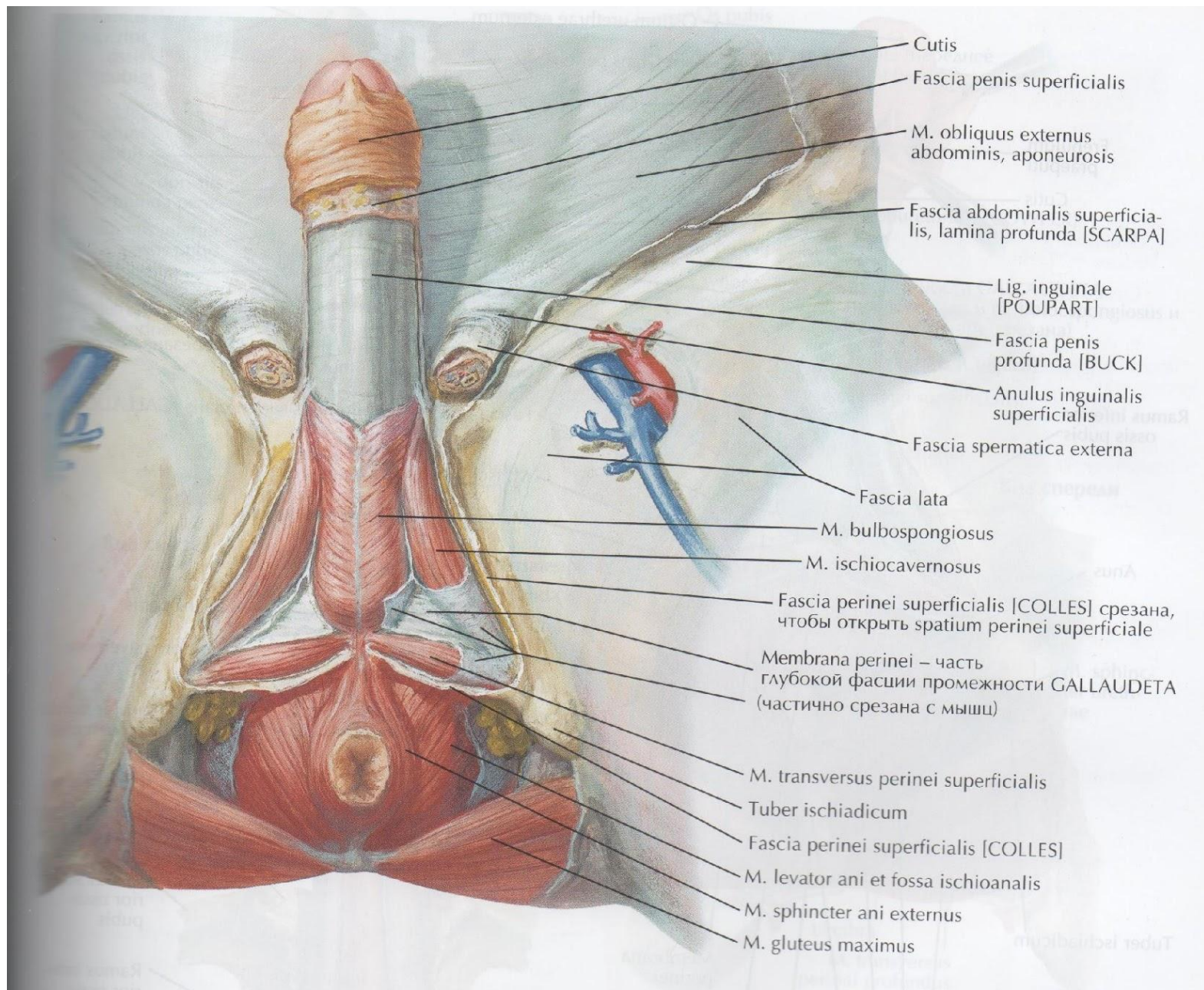




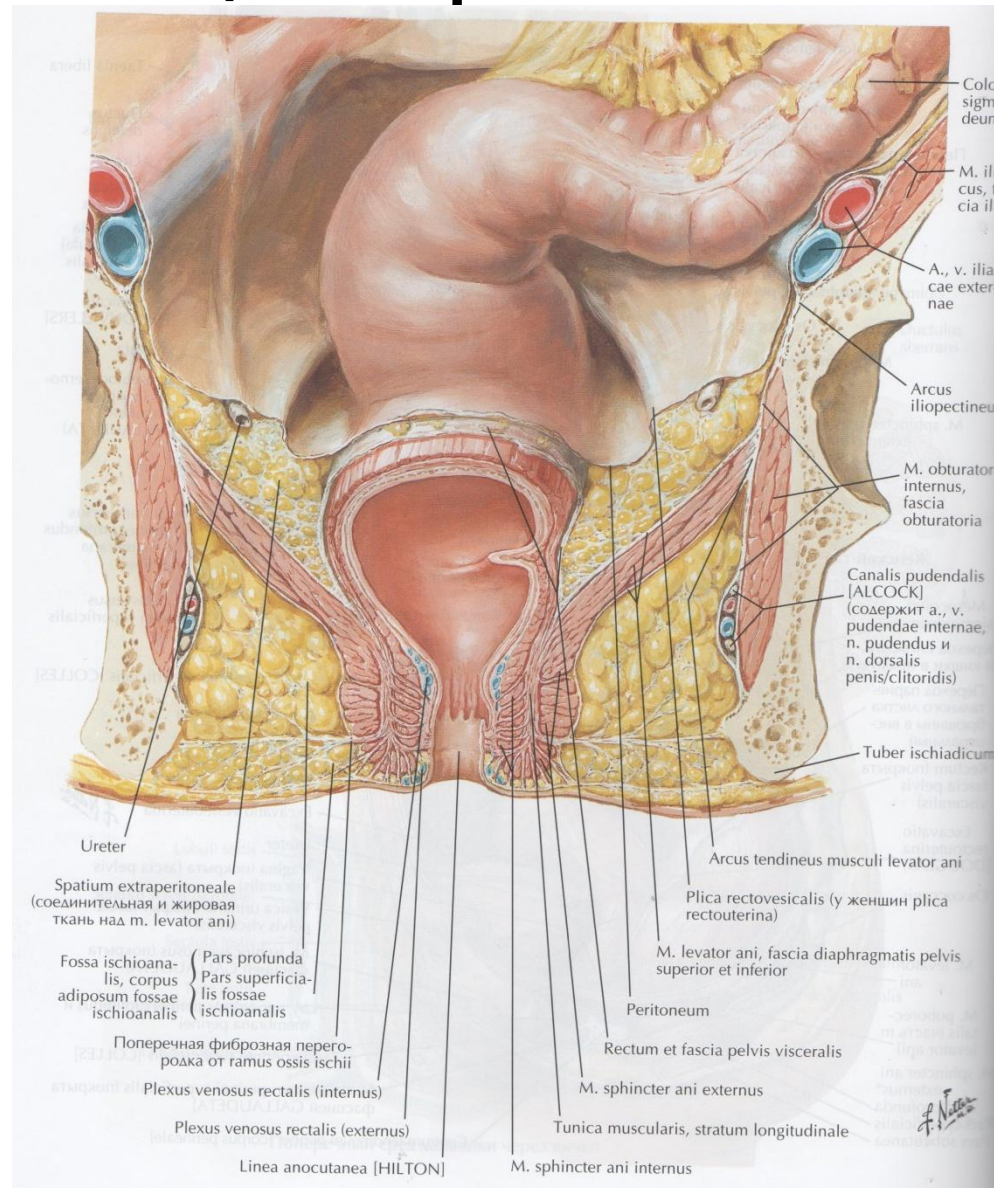


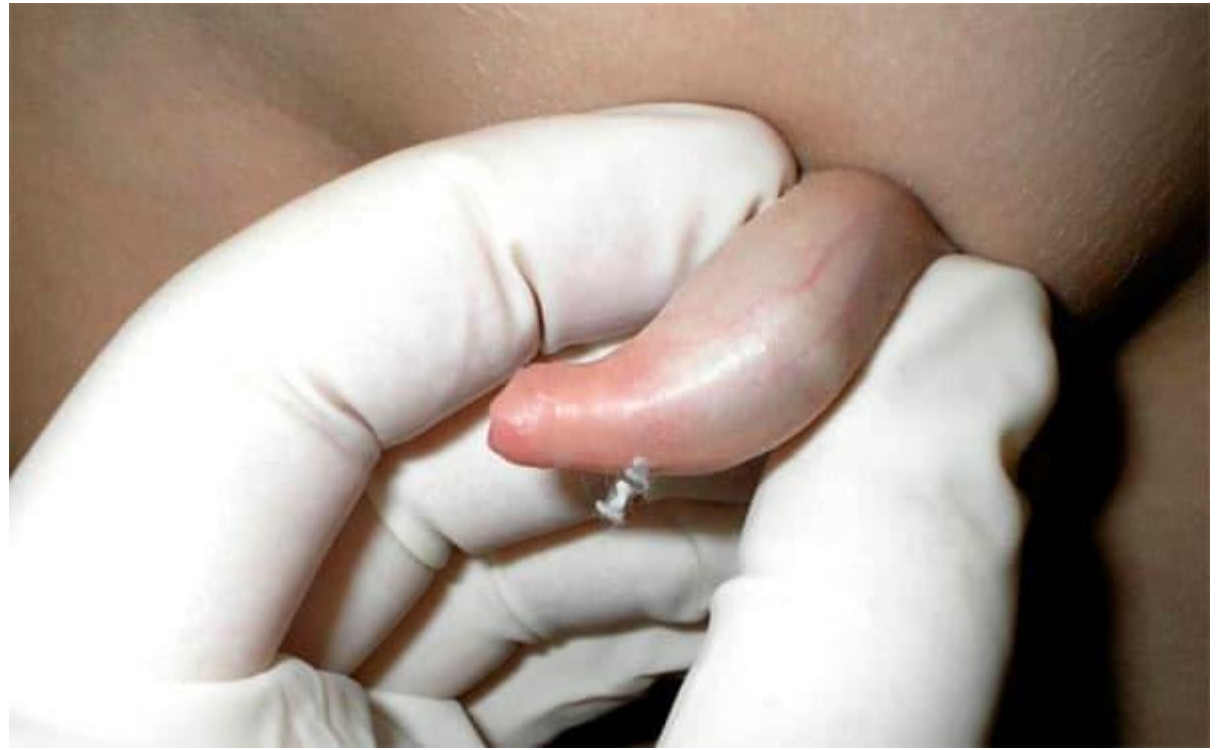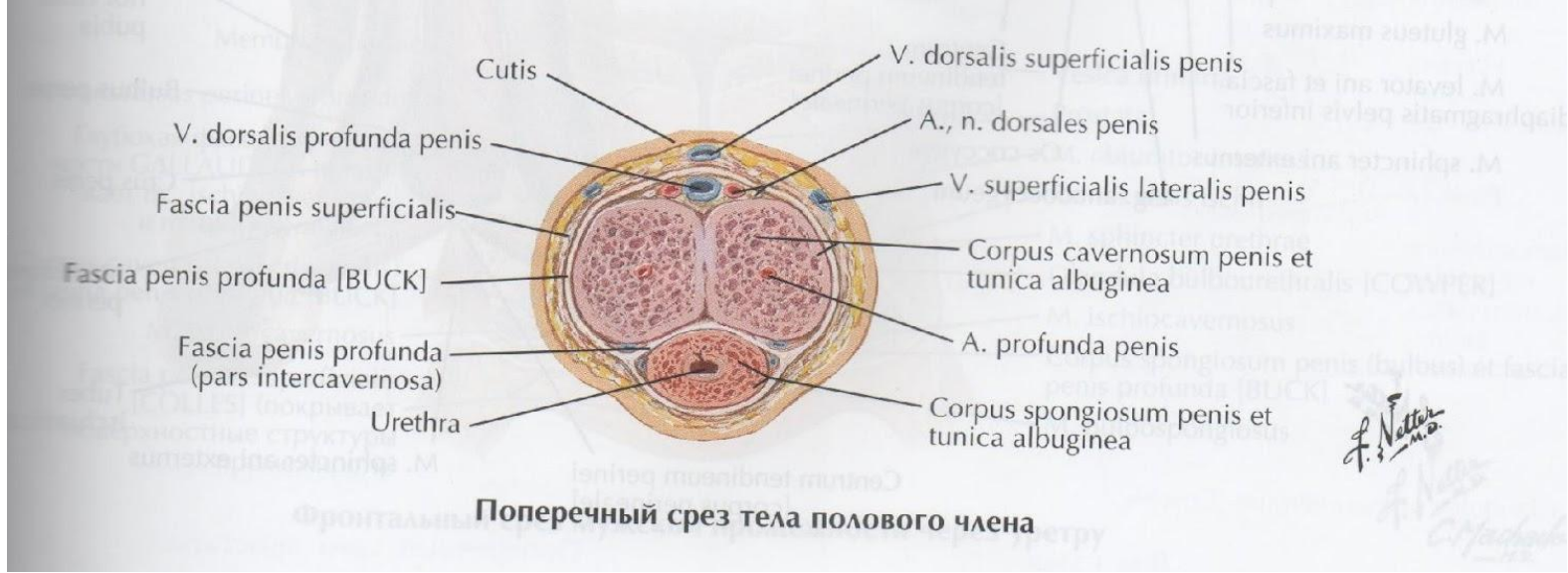
# Regio perinealis



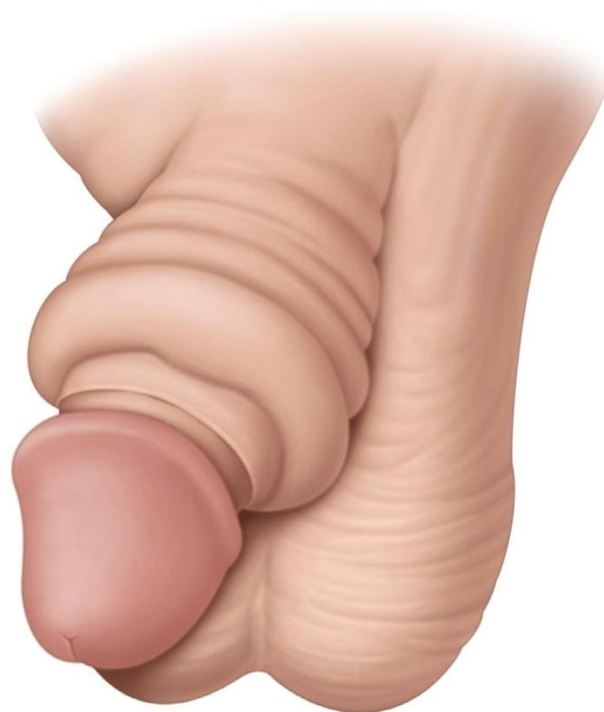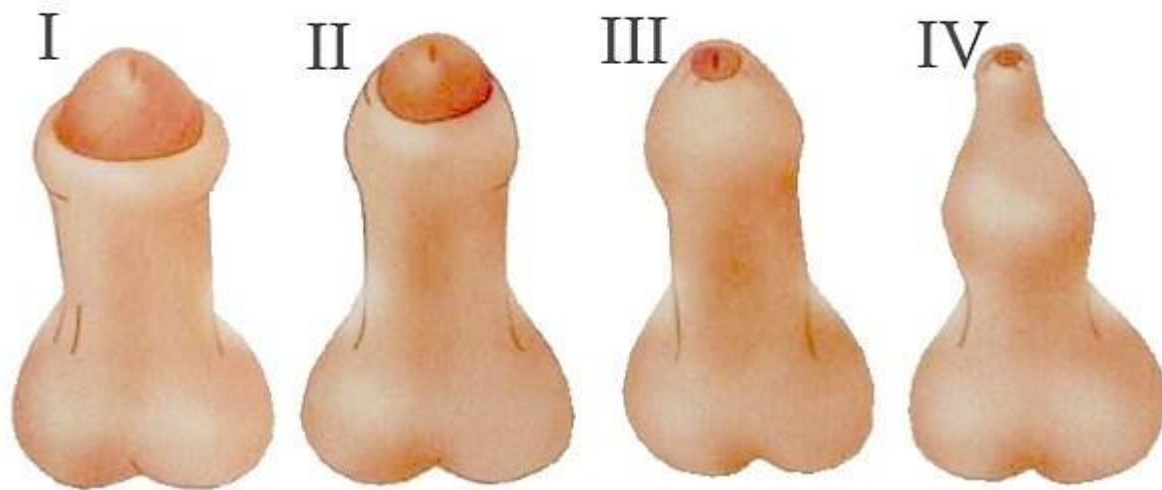


# Седлажно-прямокишечная ямка



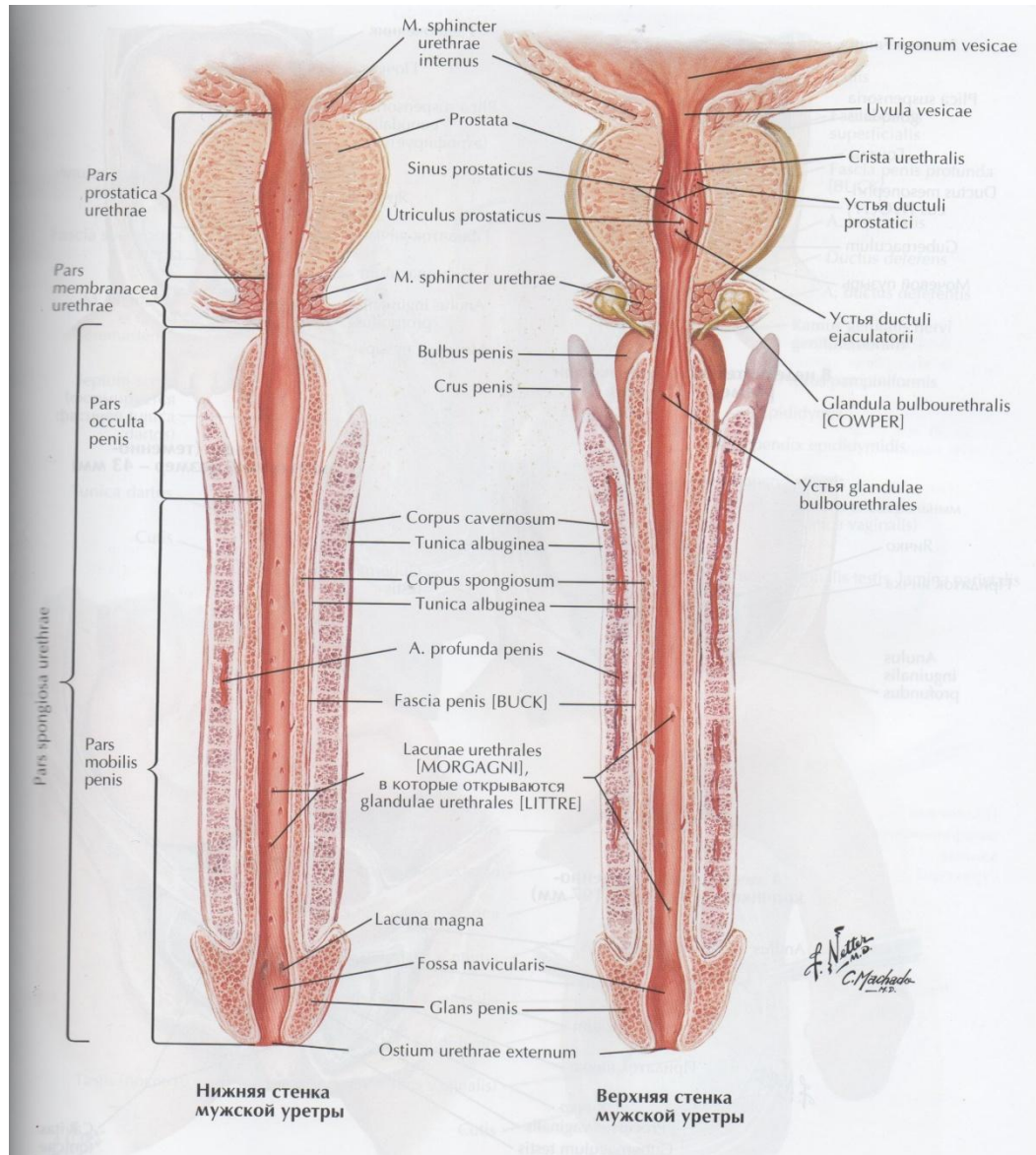


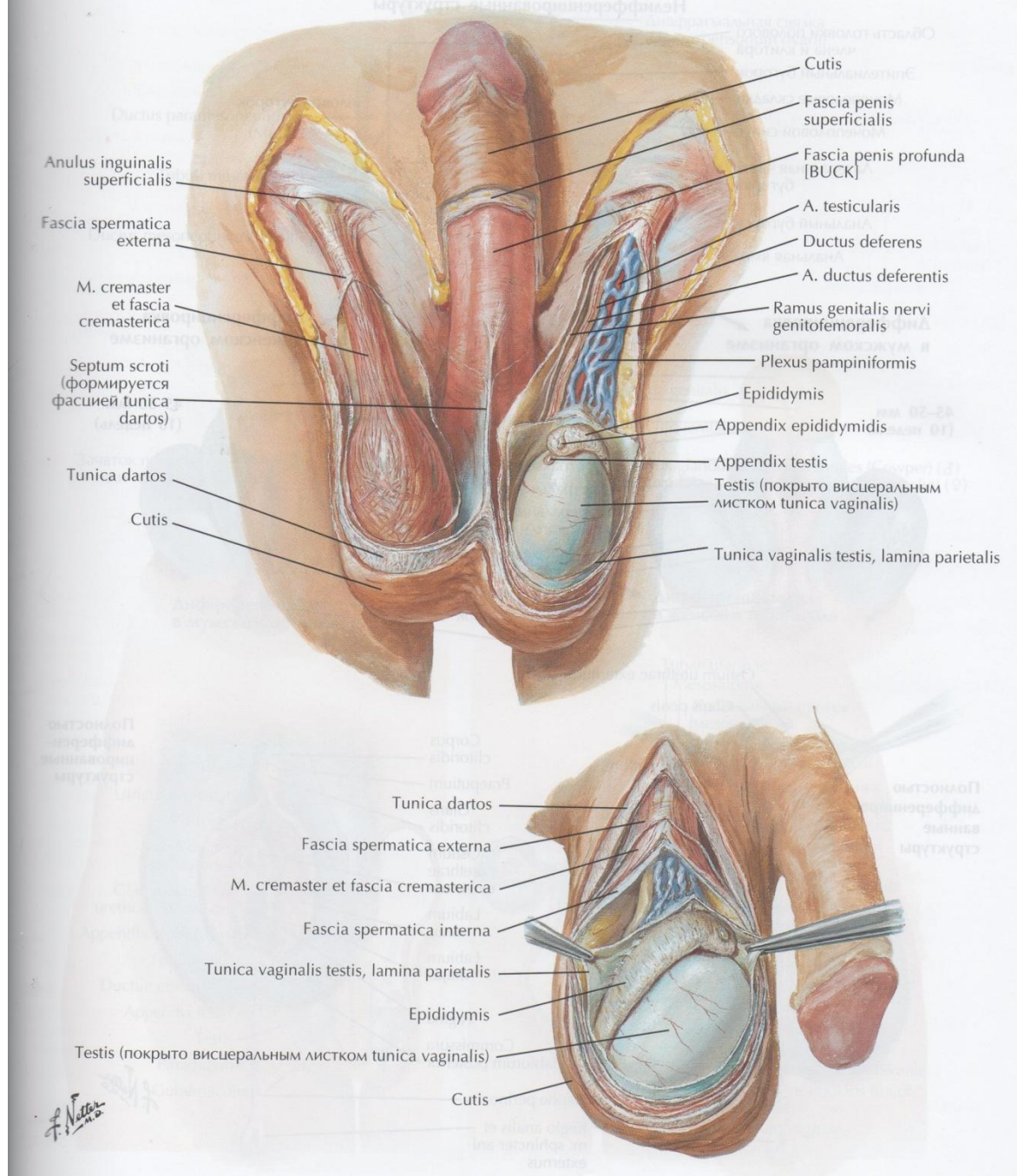




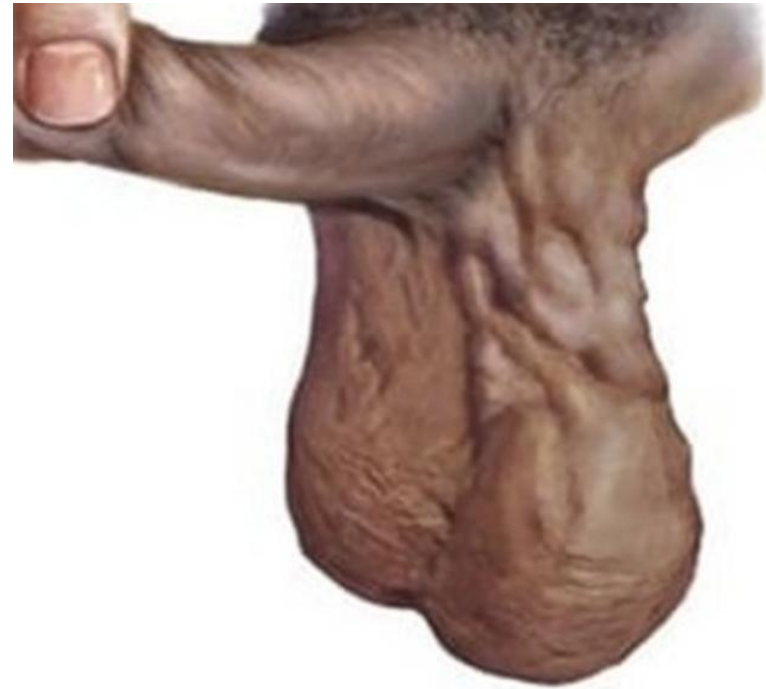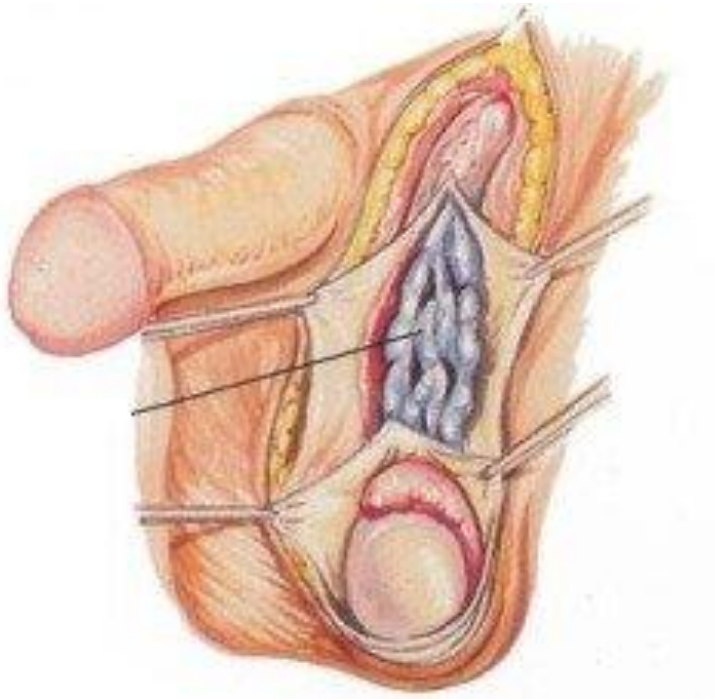
Парафимоз

# Мужская уретра





# Варикоцеле (МКБ-10: I86.1)

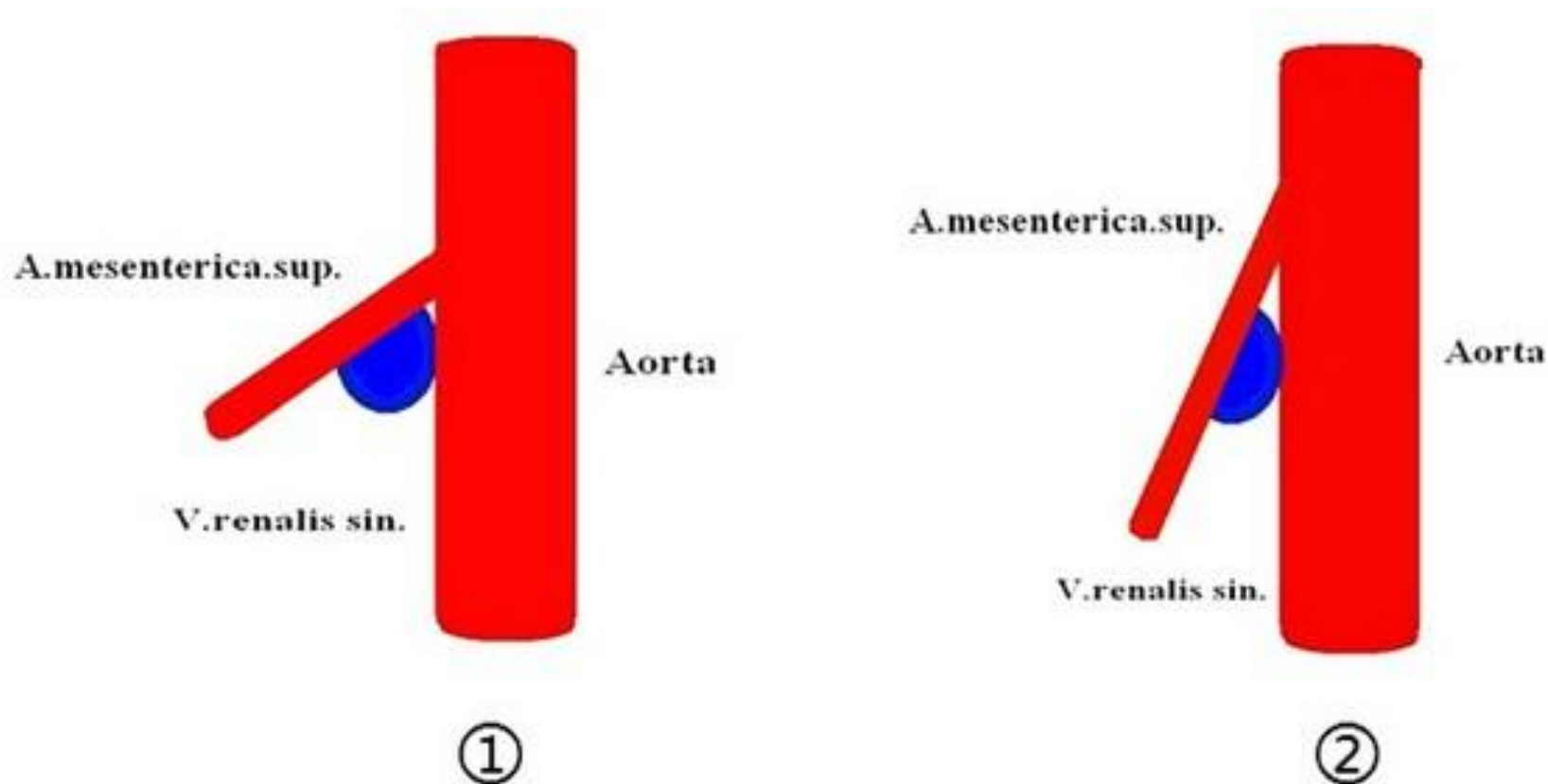


*Венозный отток от  
яичка:*

- v. testicularis
- v. cremasterica
- v. ductus deferens

—————> v. renalis/v. cava inferior  
} v. Iliaca externa et interna

# Варикоцеле (МКБ-10: I86.1)



Аорто-мезентериальный  
пинцет

# Перекрут подвеска придатка яичка (МКБ-10: N44)

