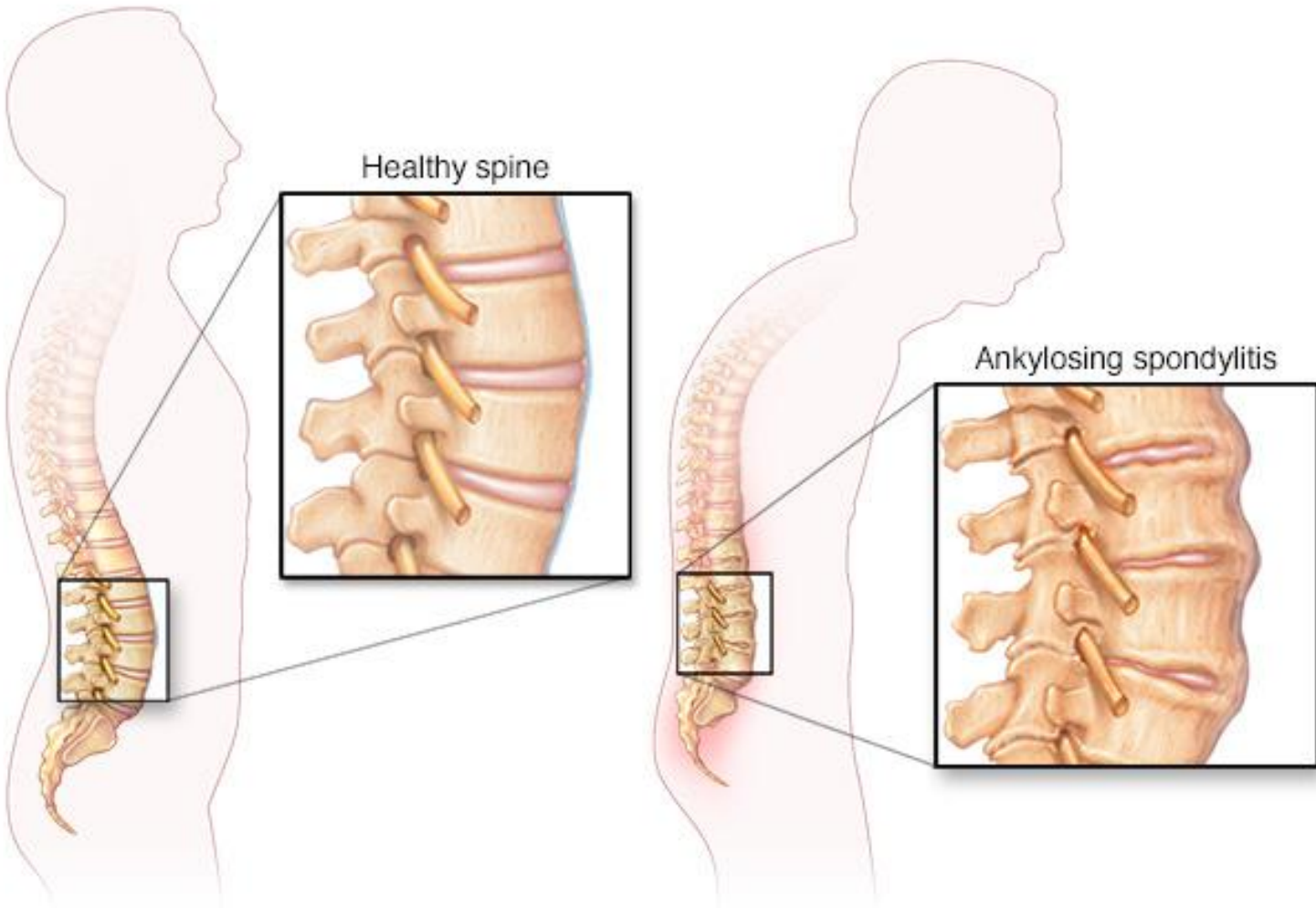
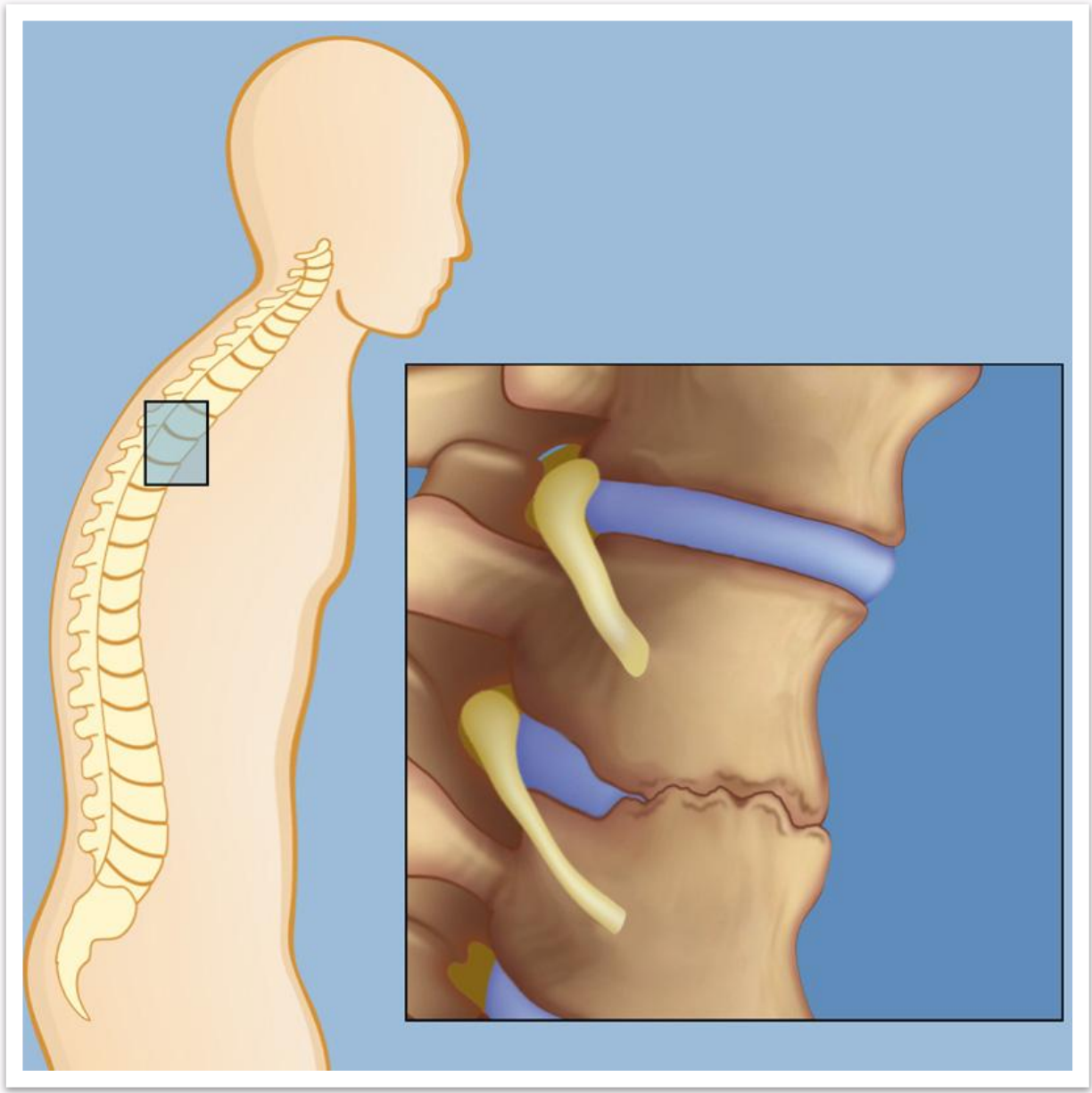
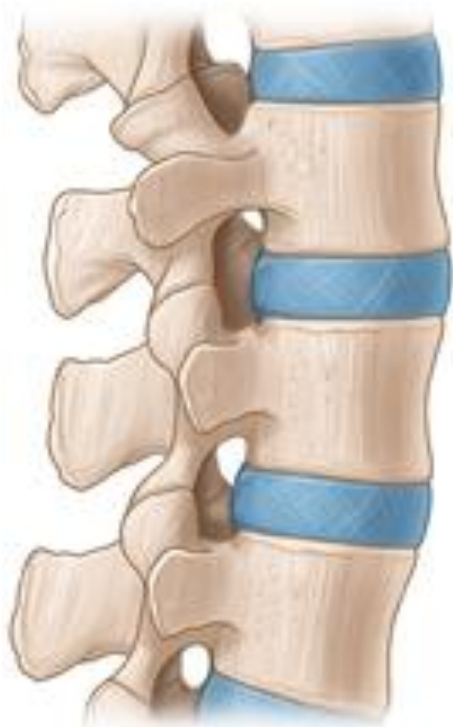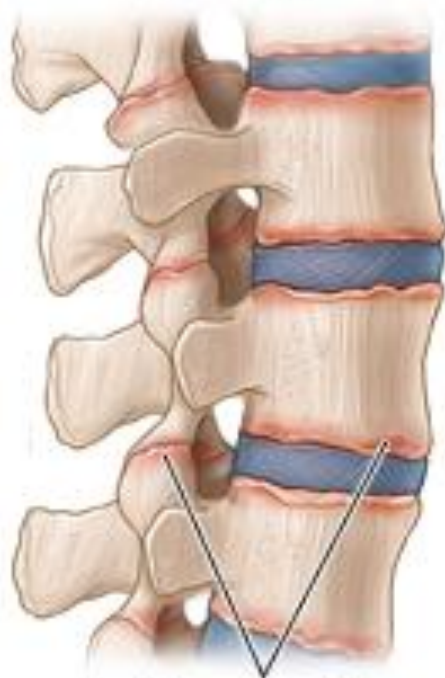Normal spine

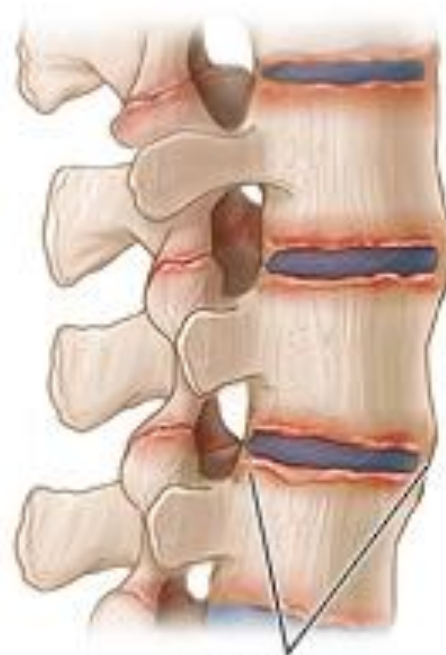

Early ankylosing  
spondylitis

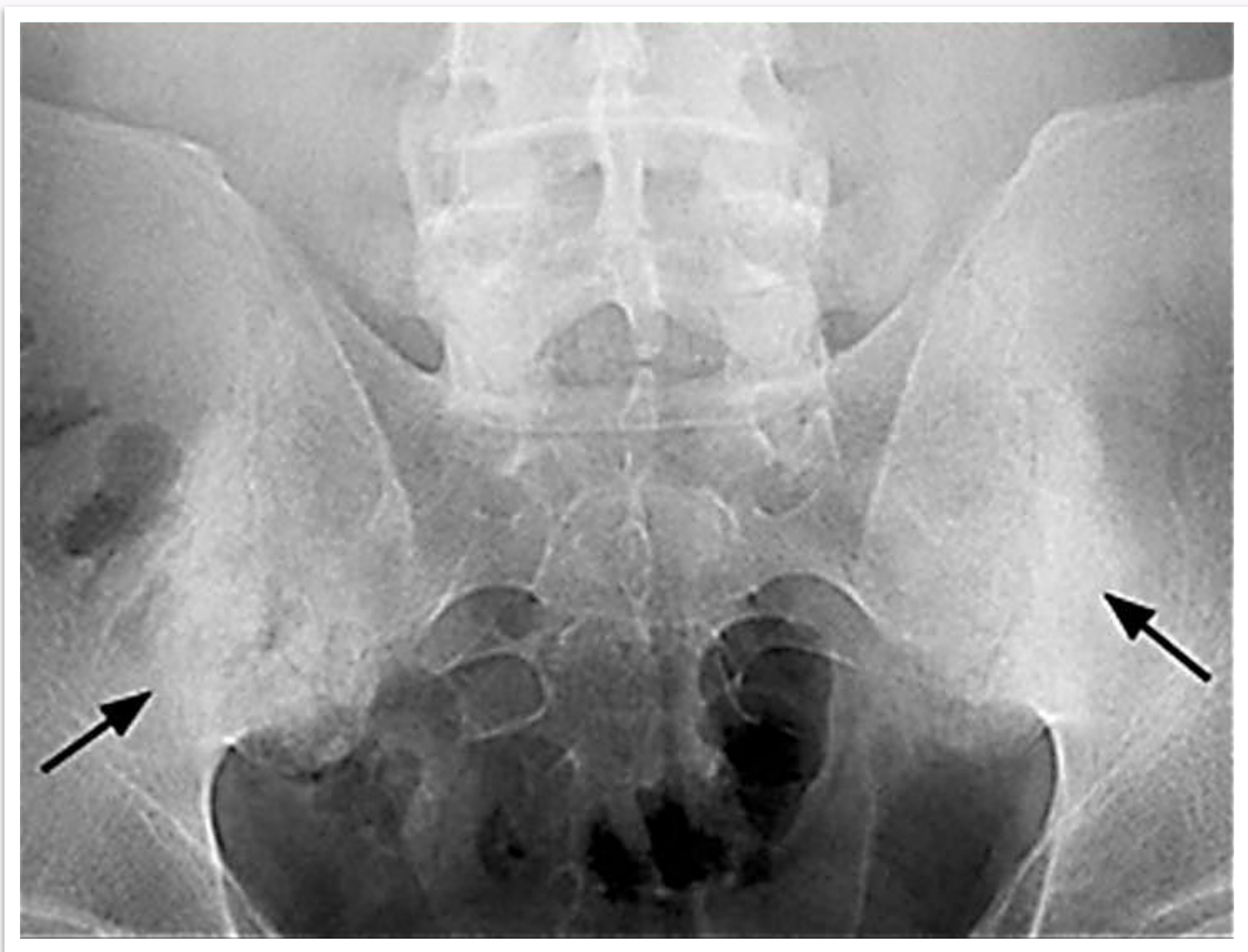

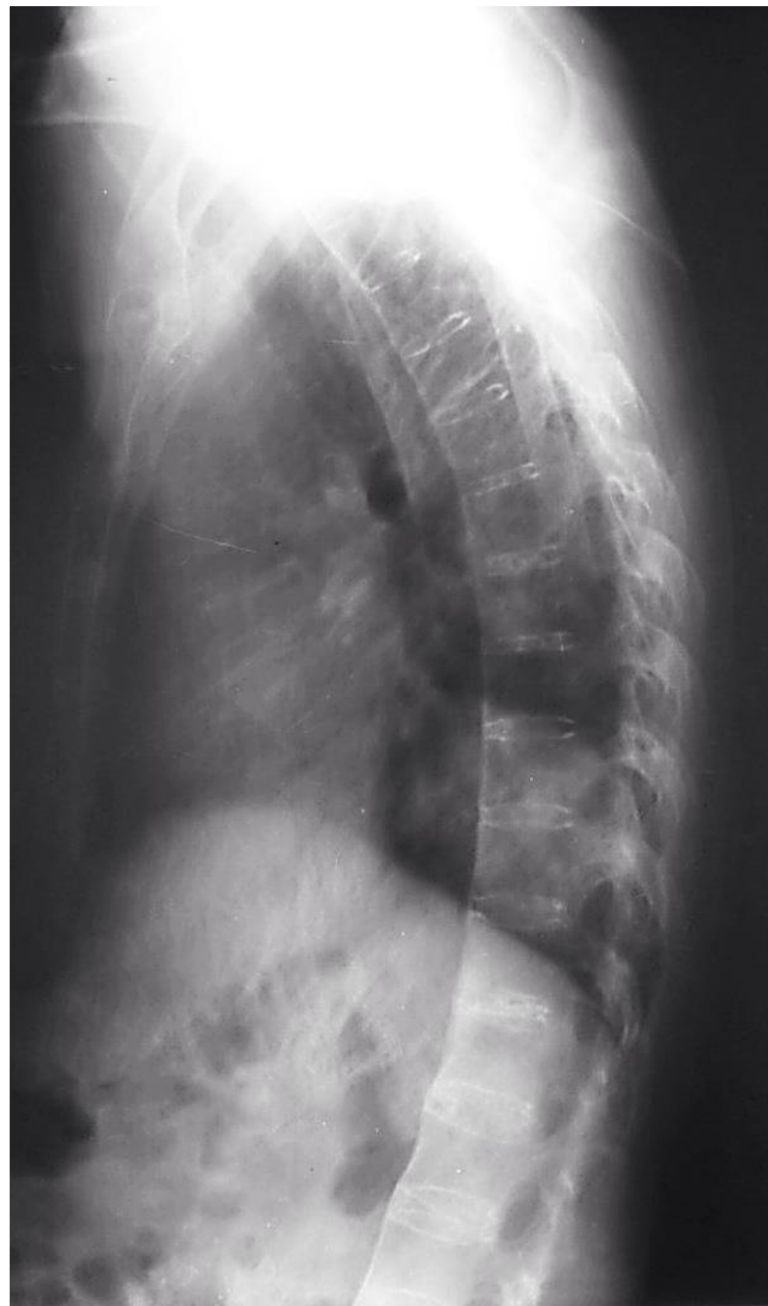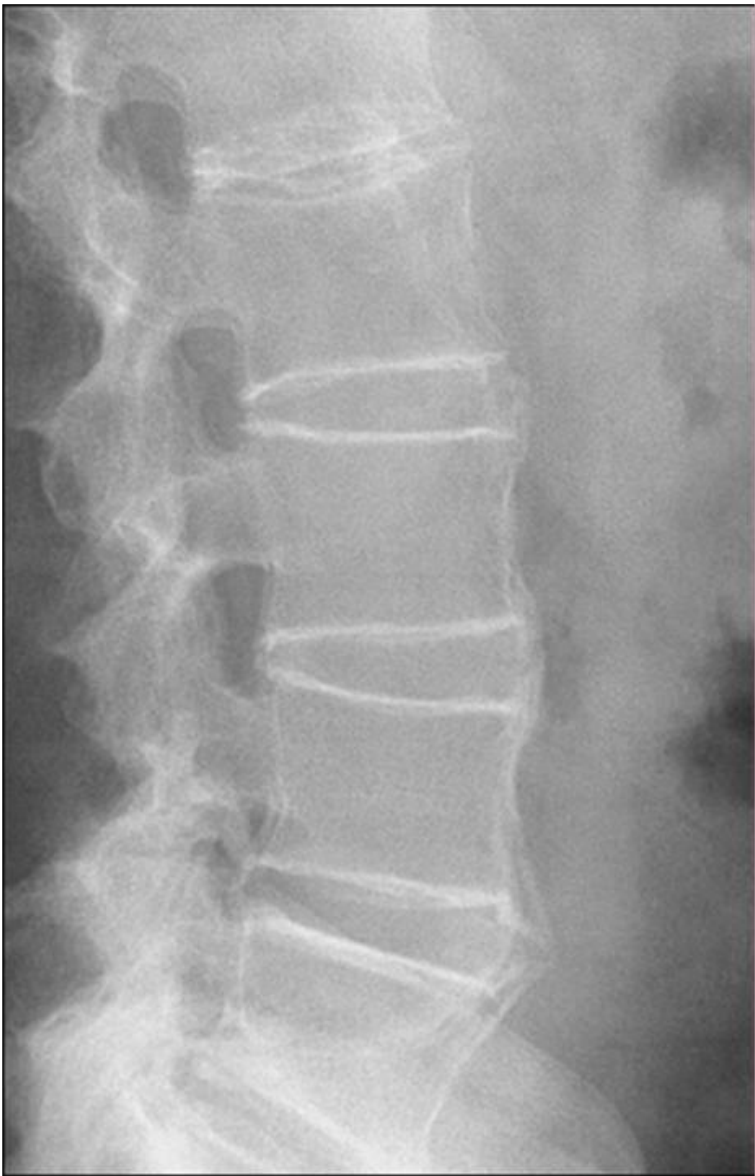Inflammation

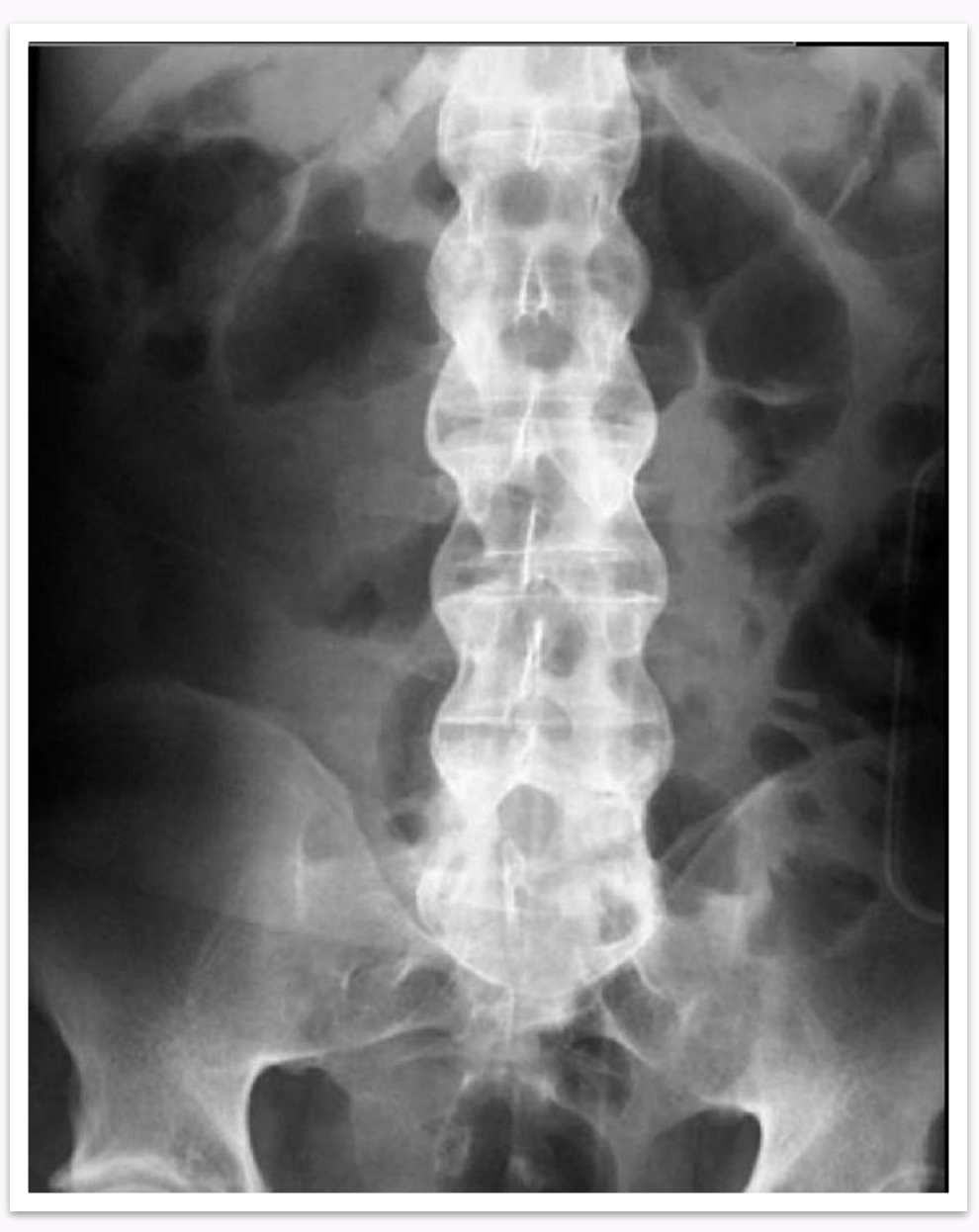Advanced  
ankylosing  
spondylitis

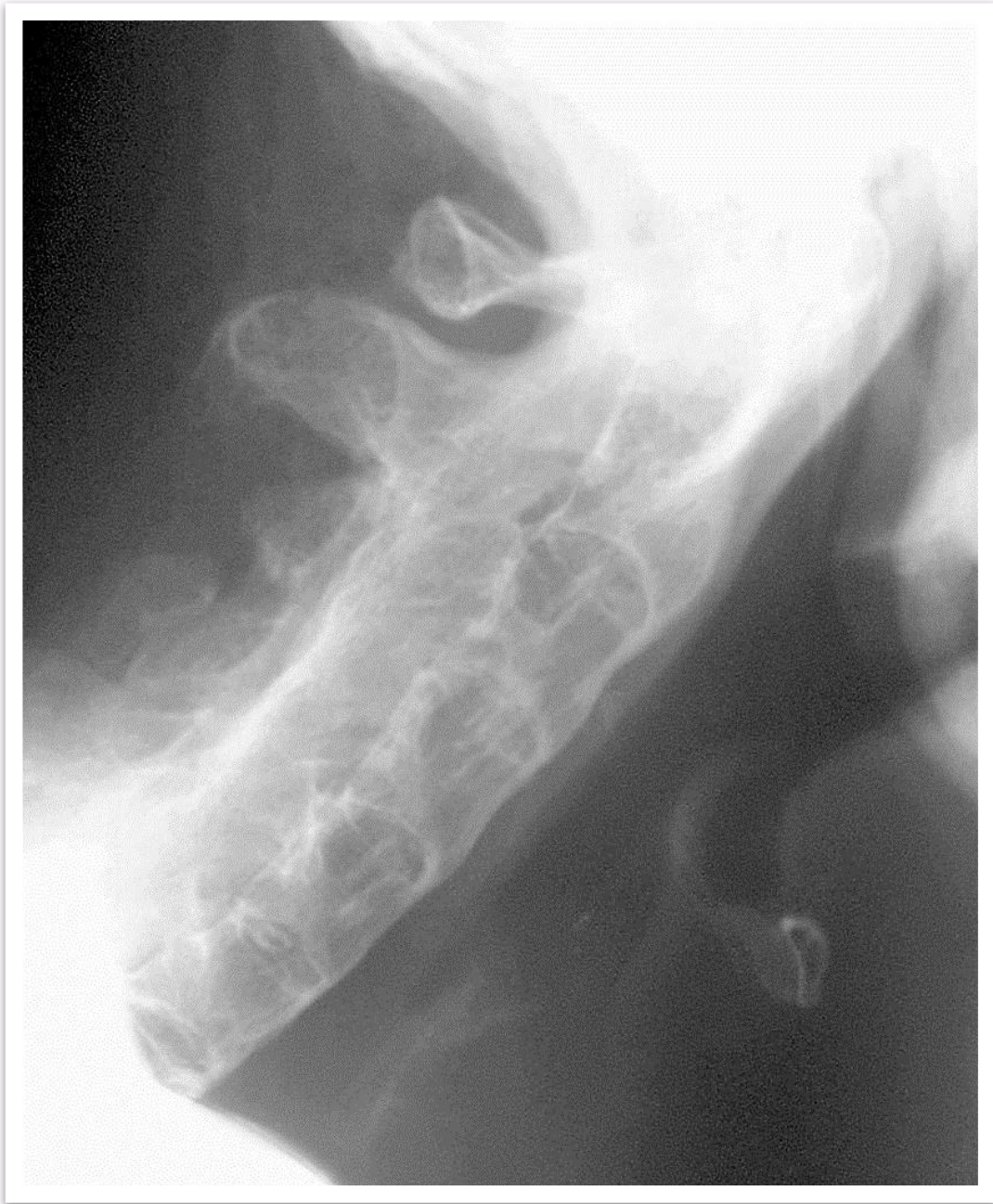

Fusion

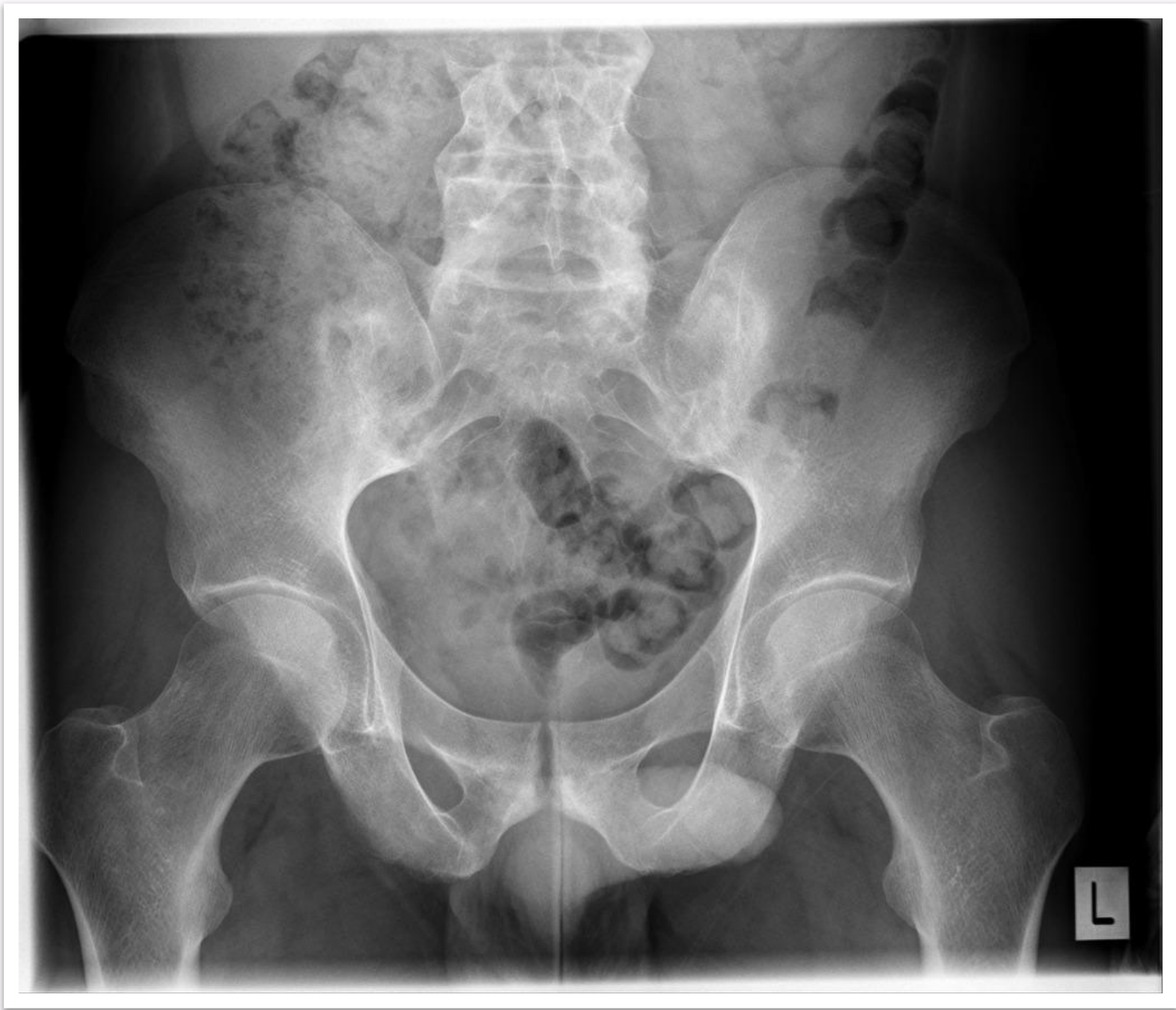


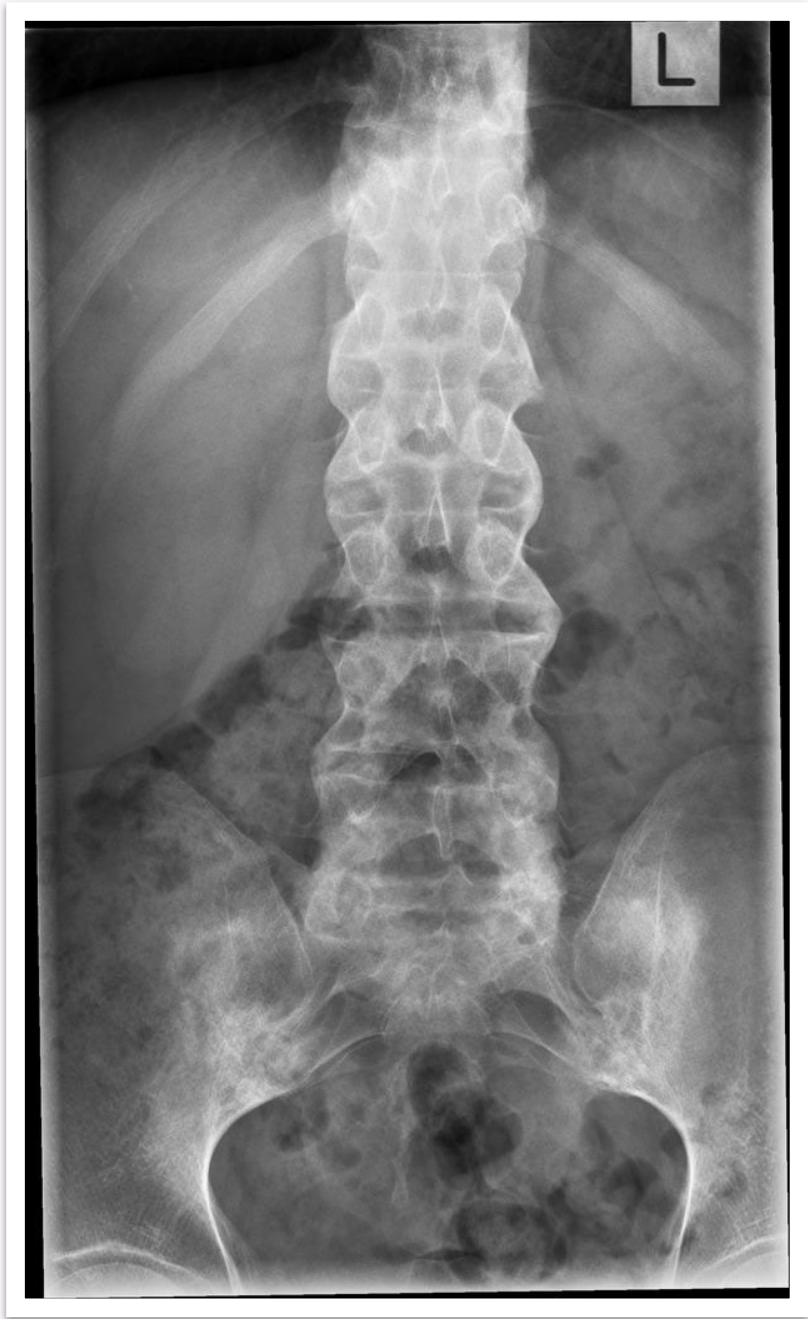
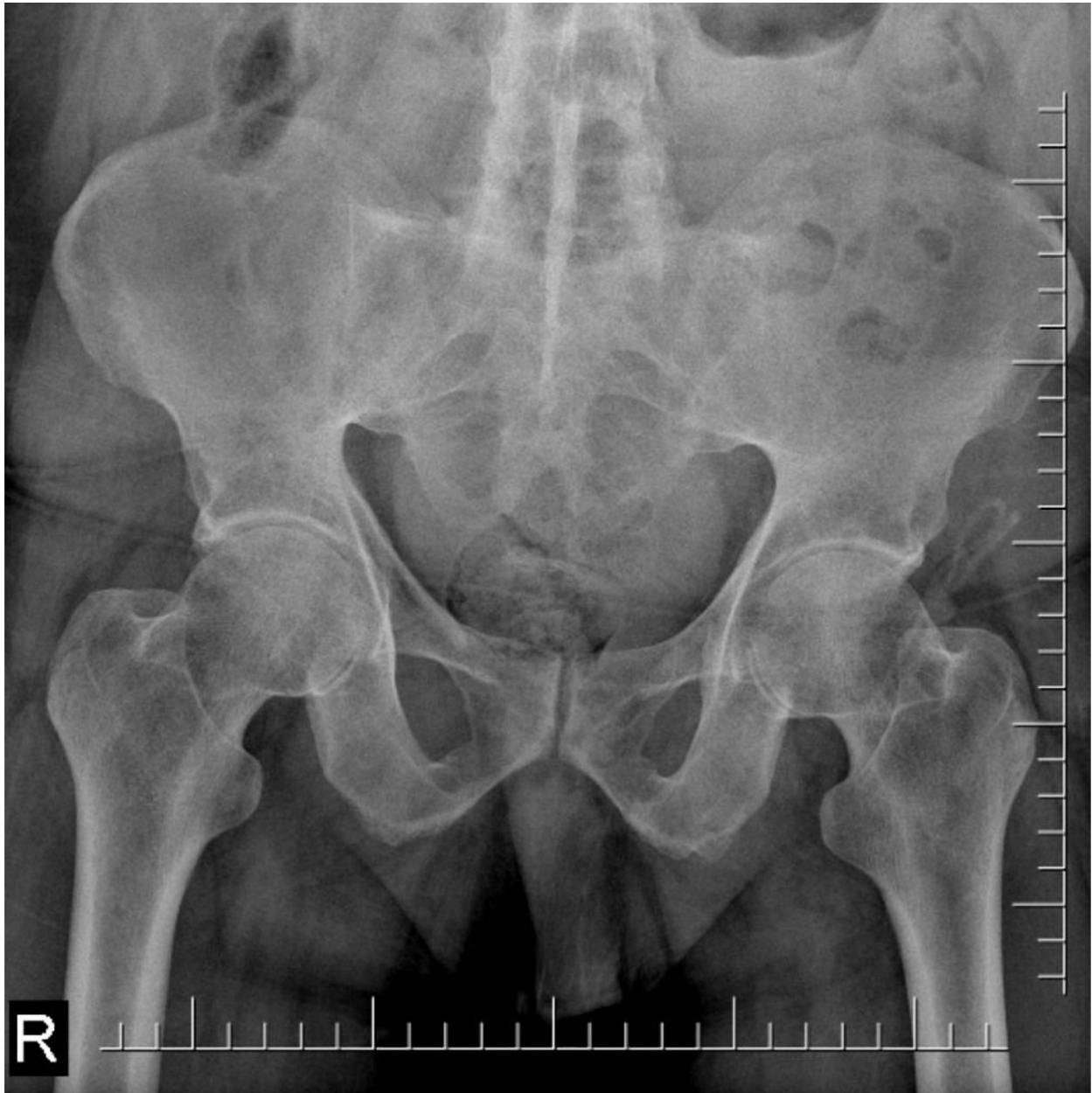












# Динамика за несколько лет





