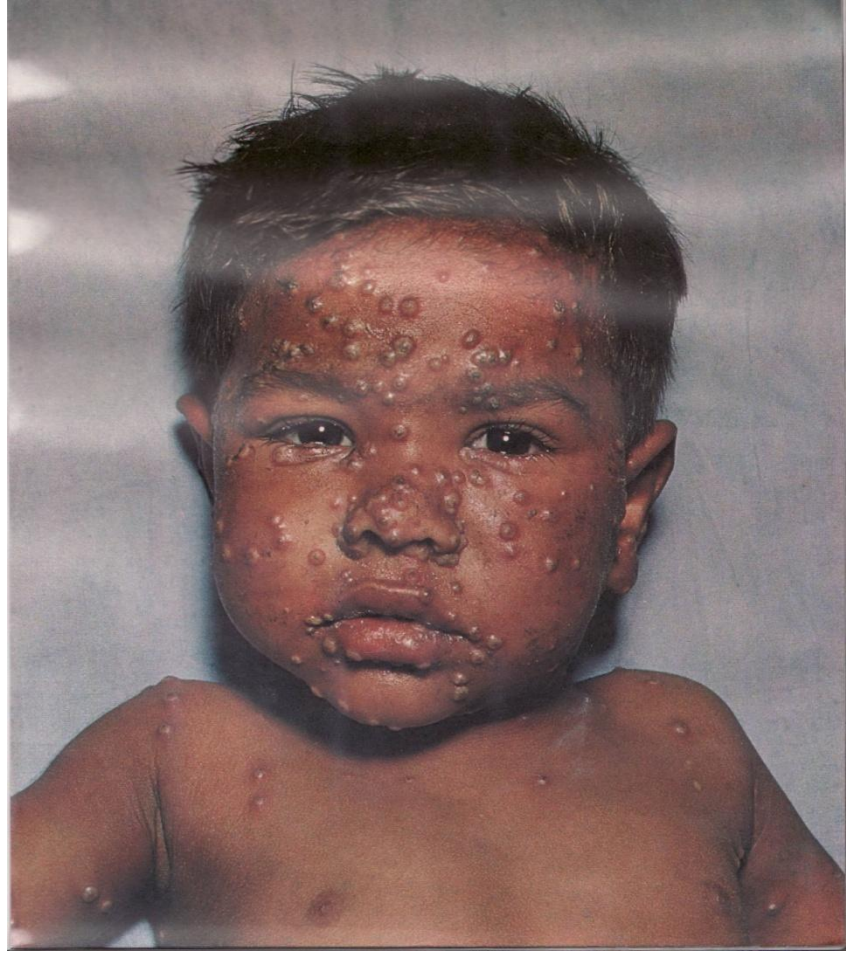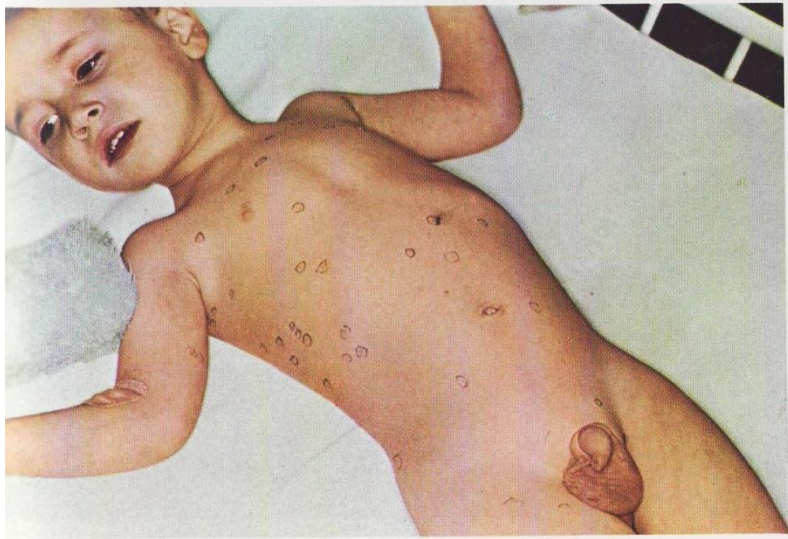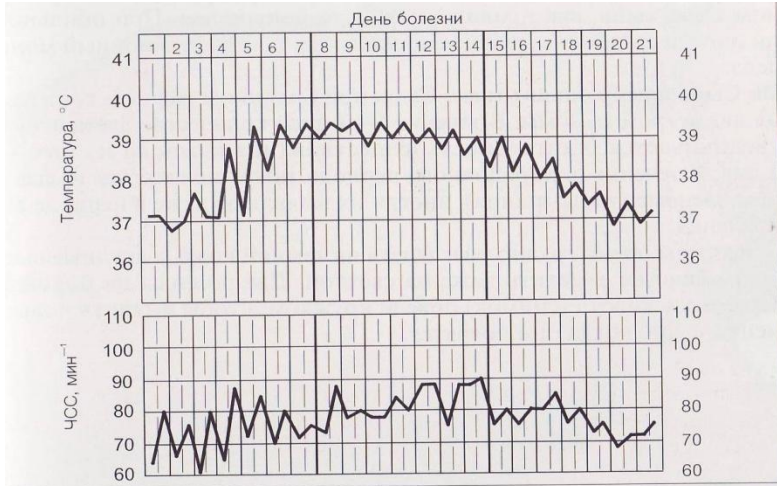
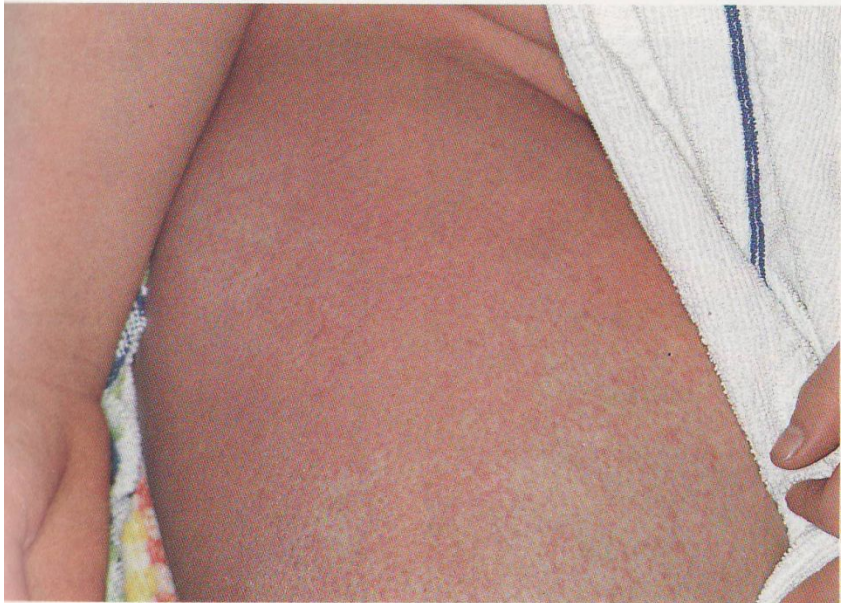


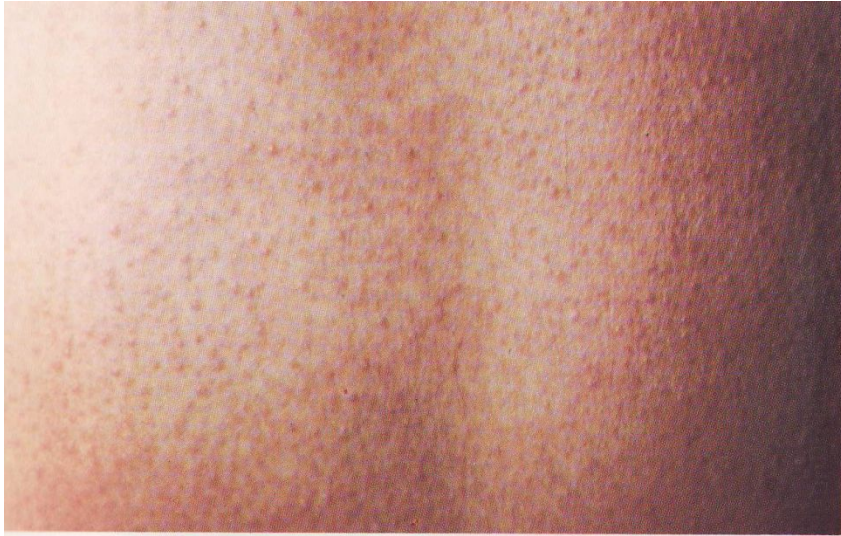
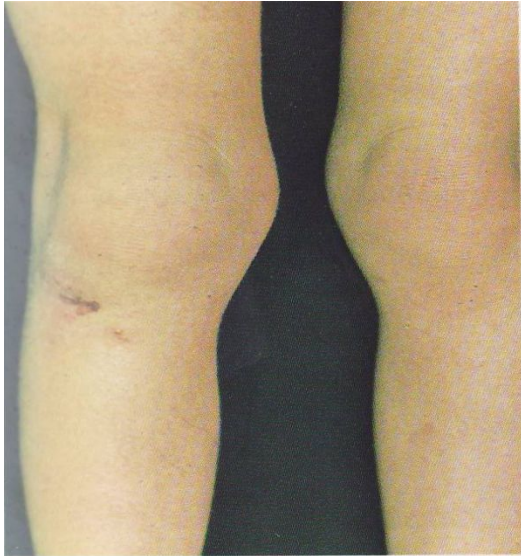
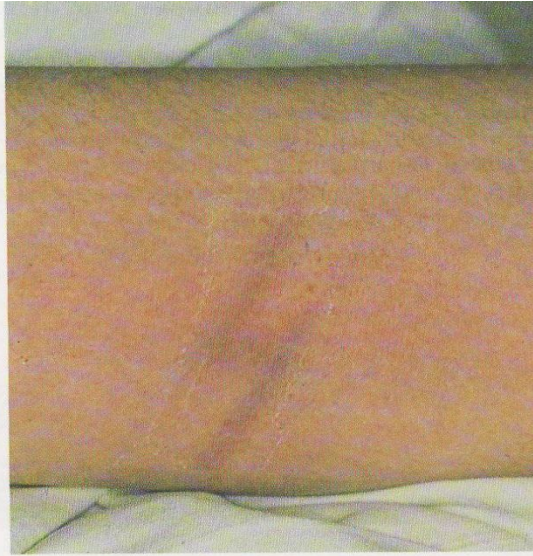Брюшной тиф



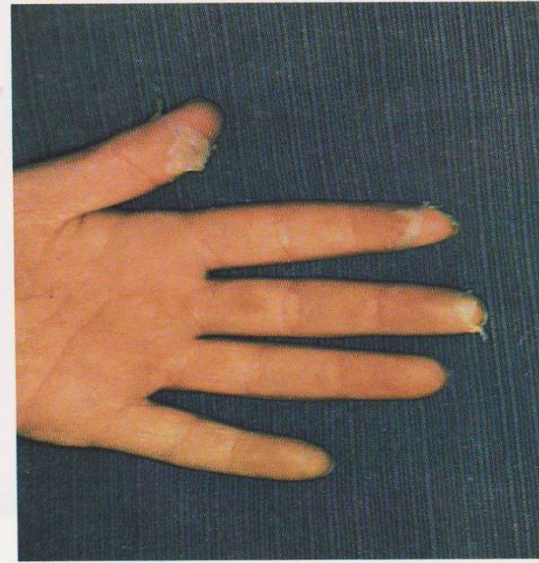
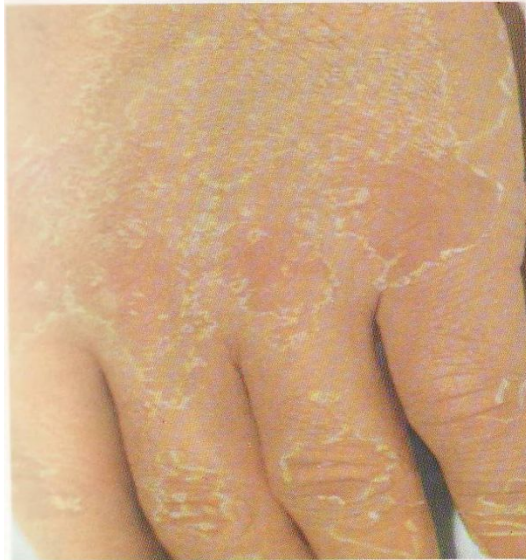

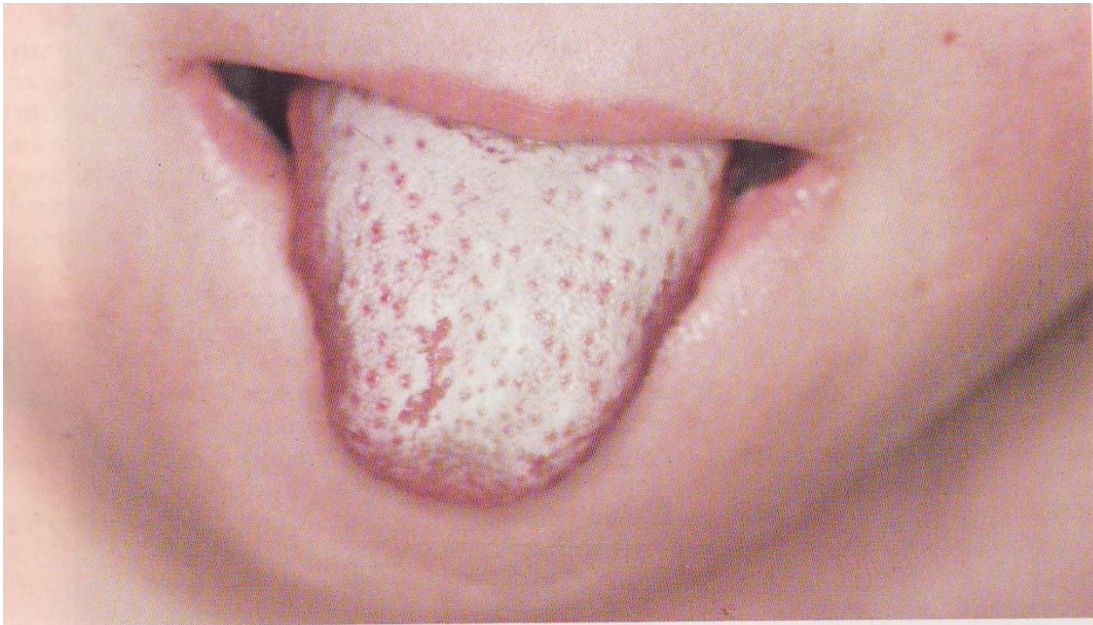


15

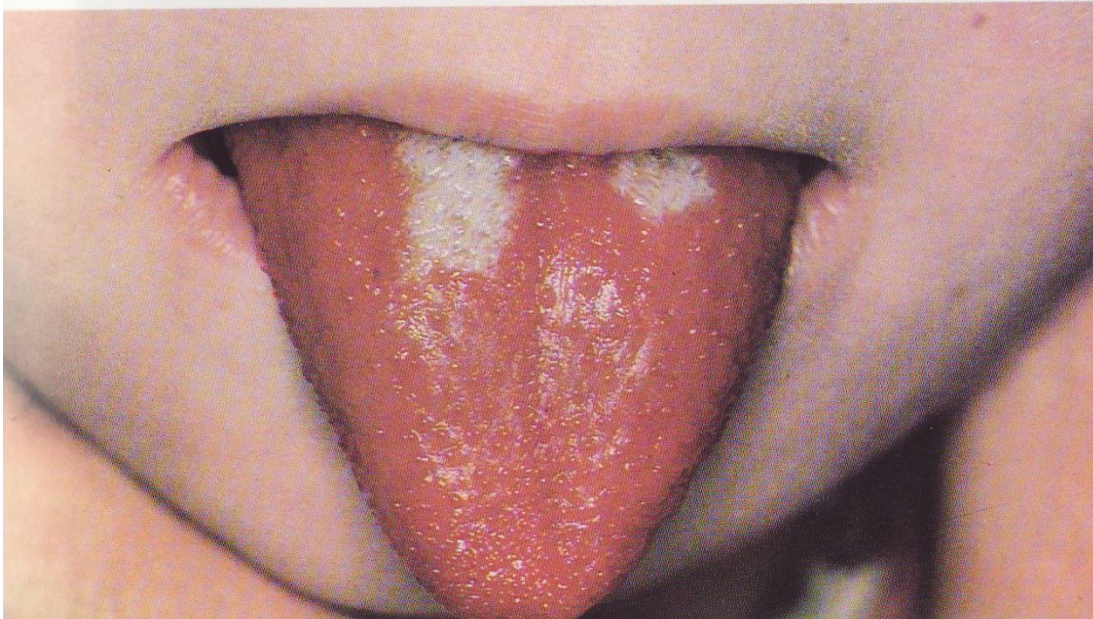

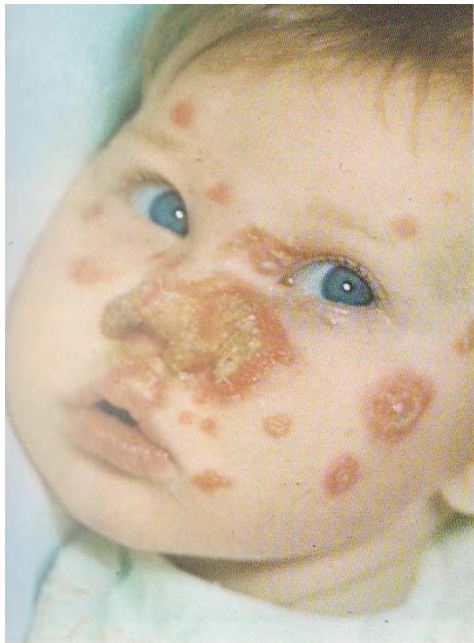16



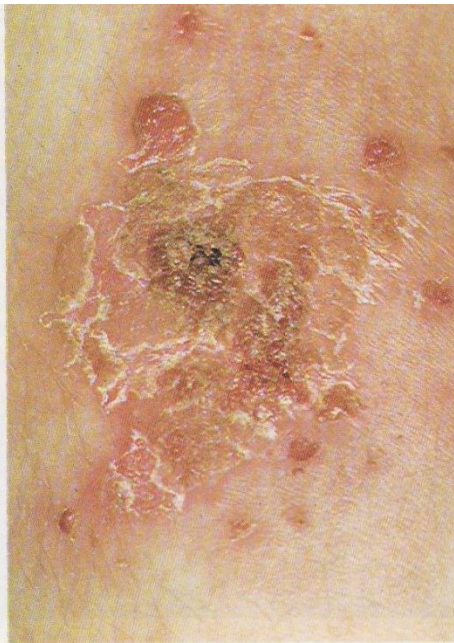

19



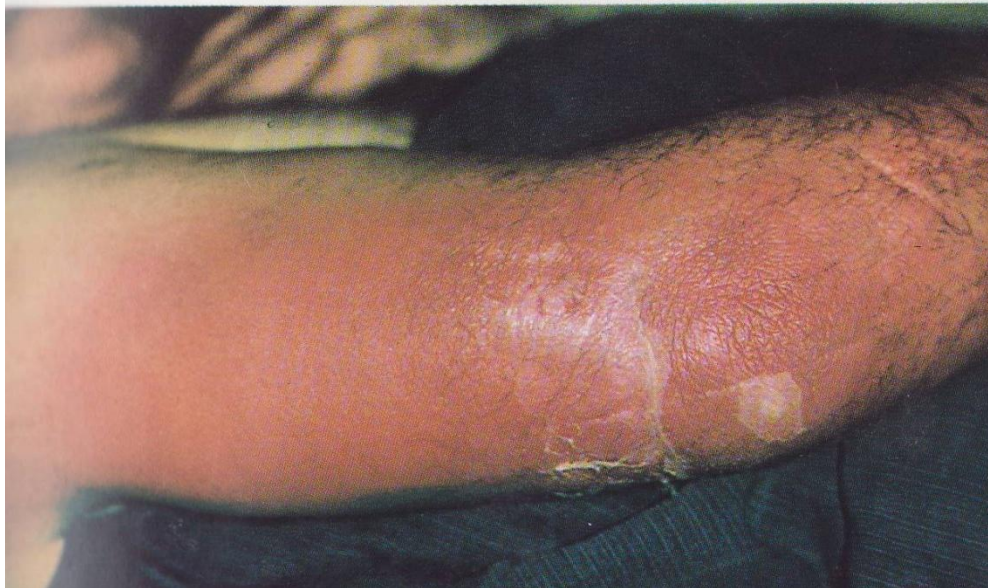

26

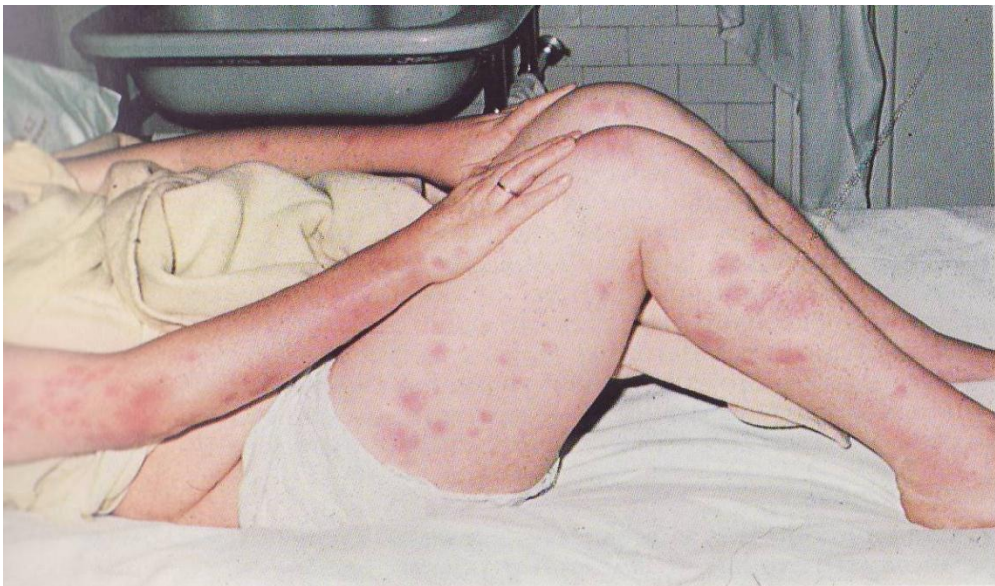

27

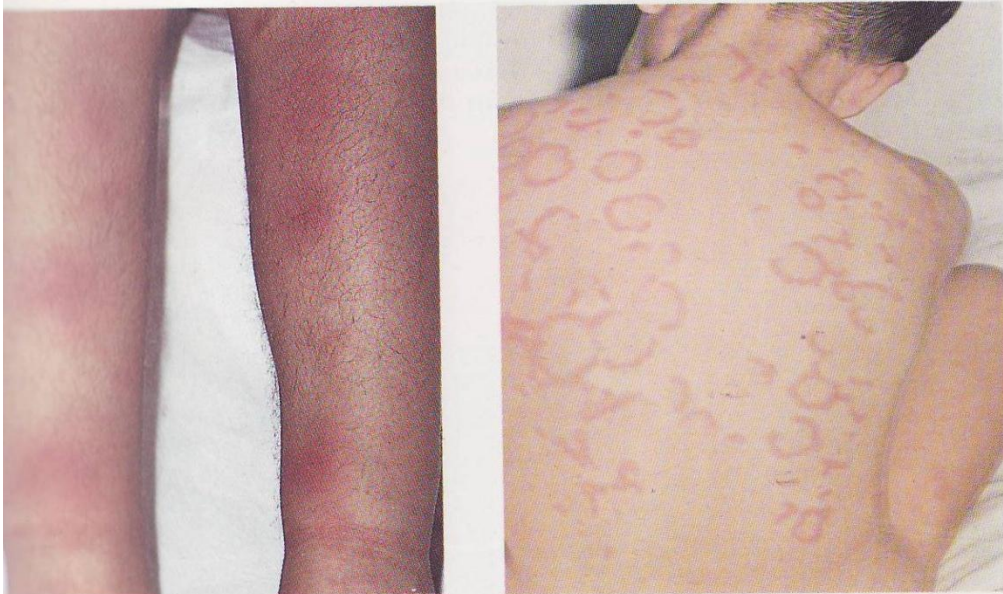Пиодермия



флегмона

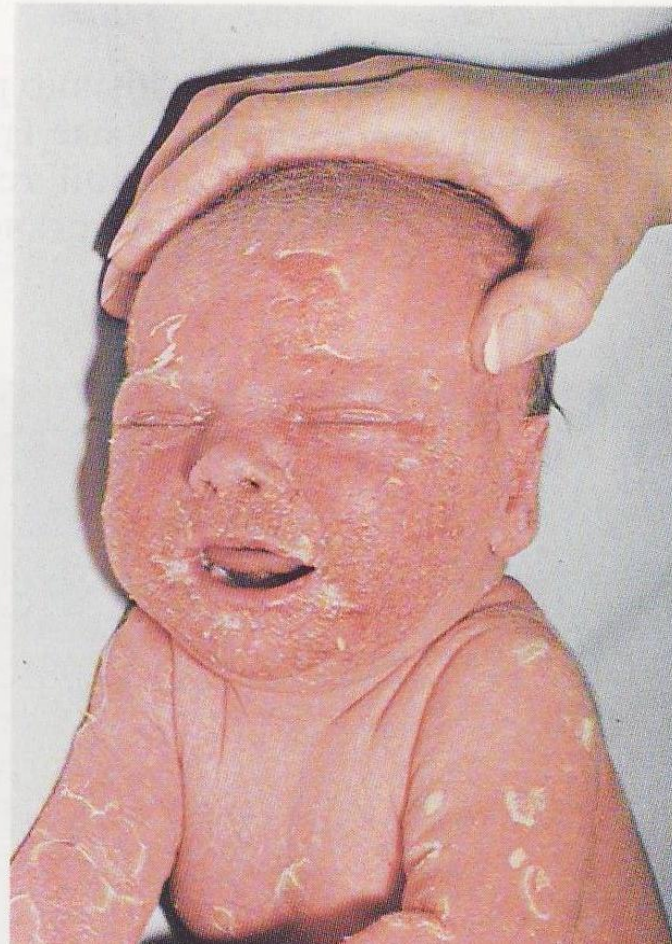
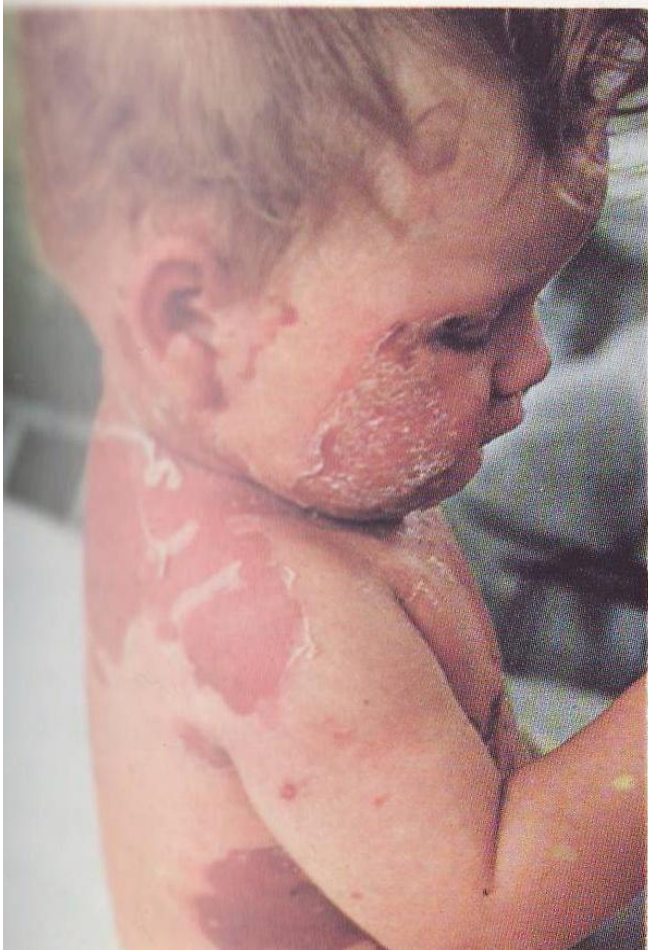
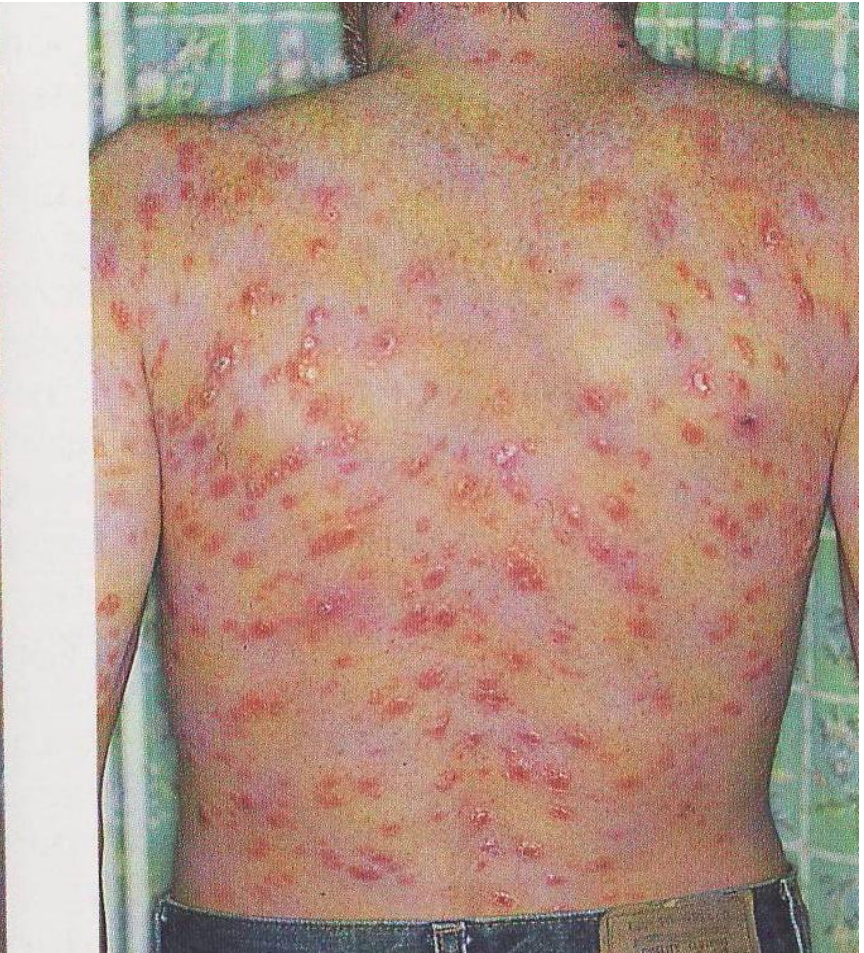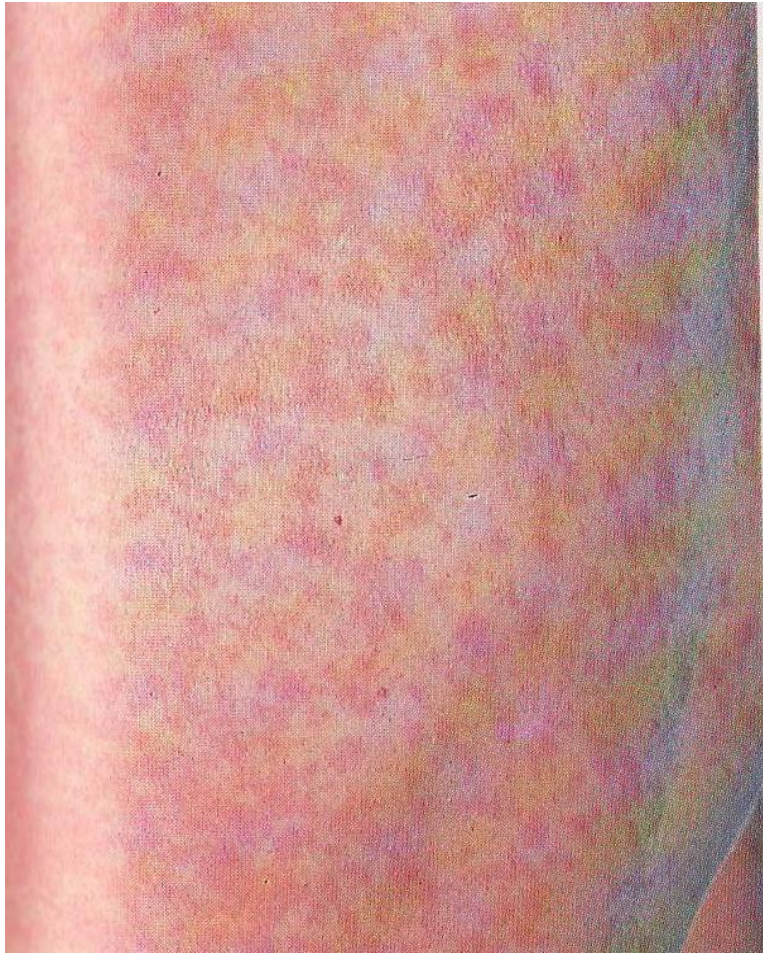
Узловатая эритема

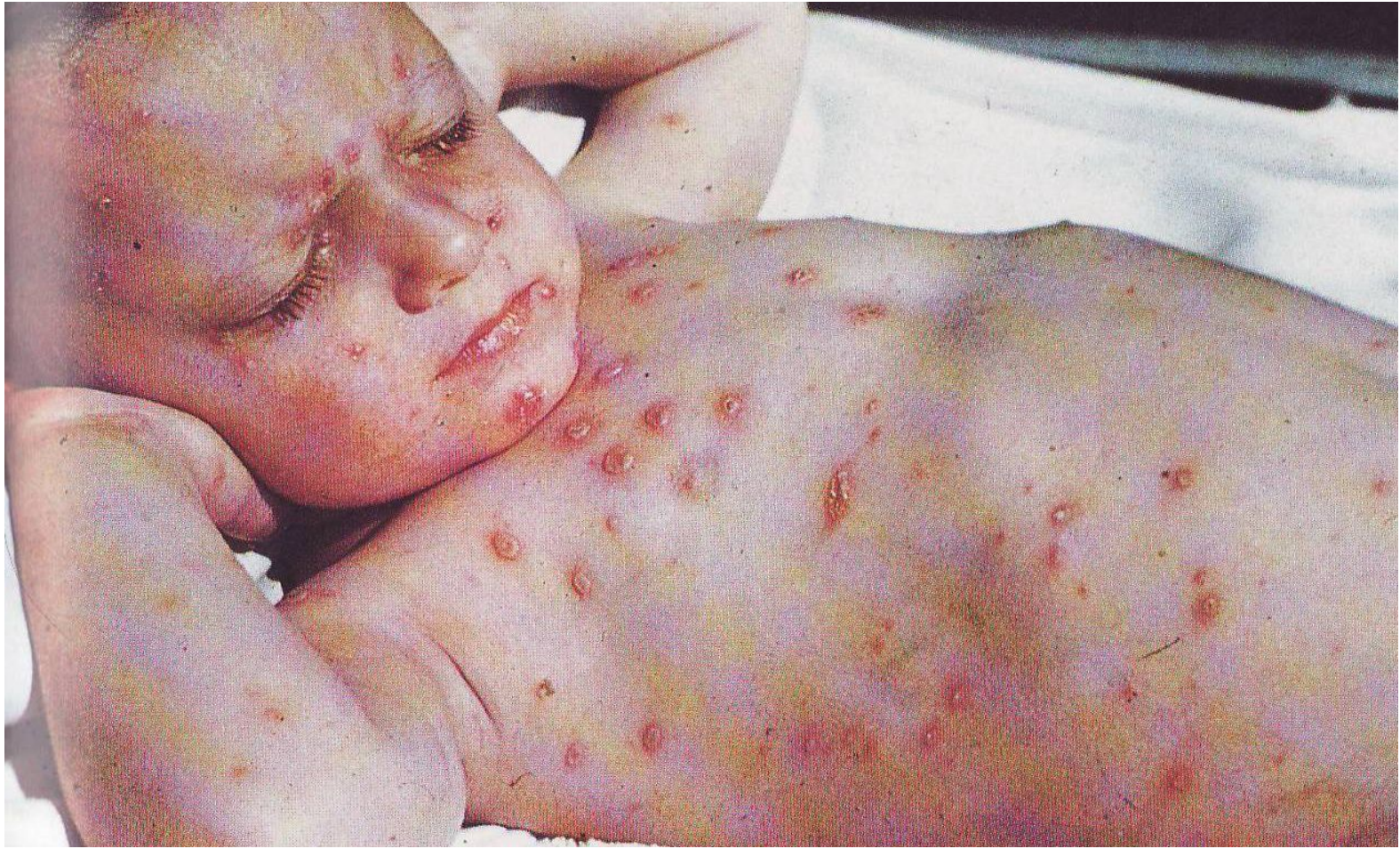

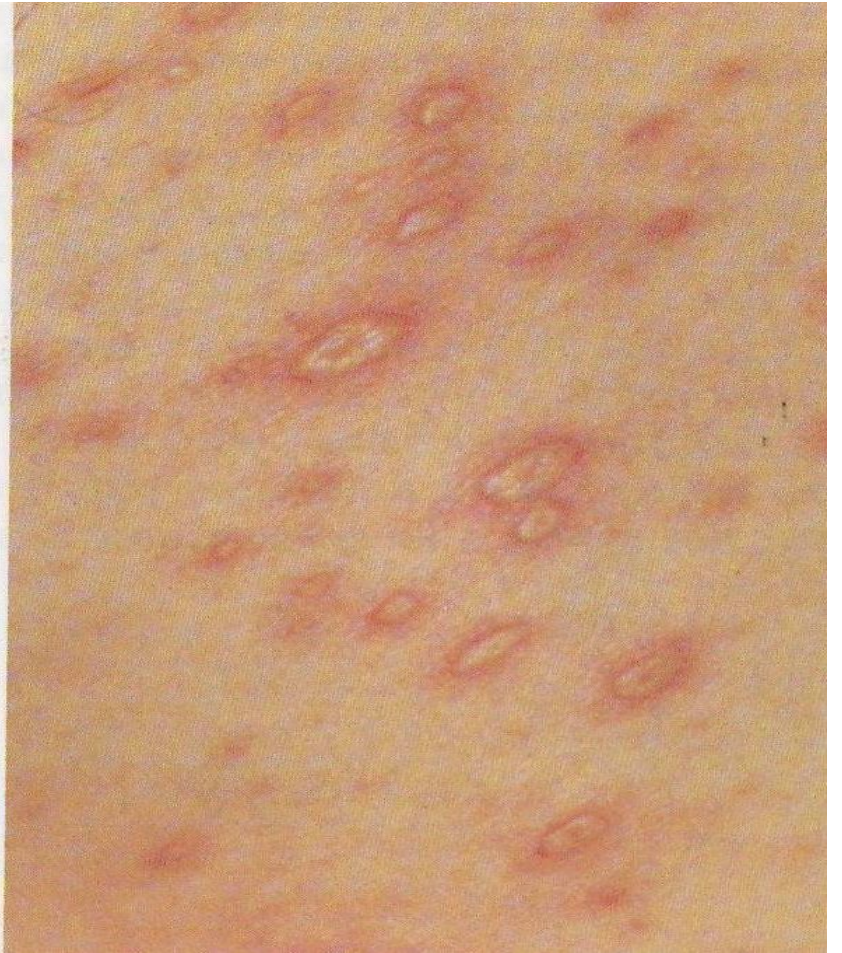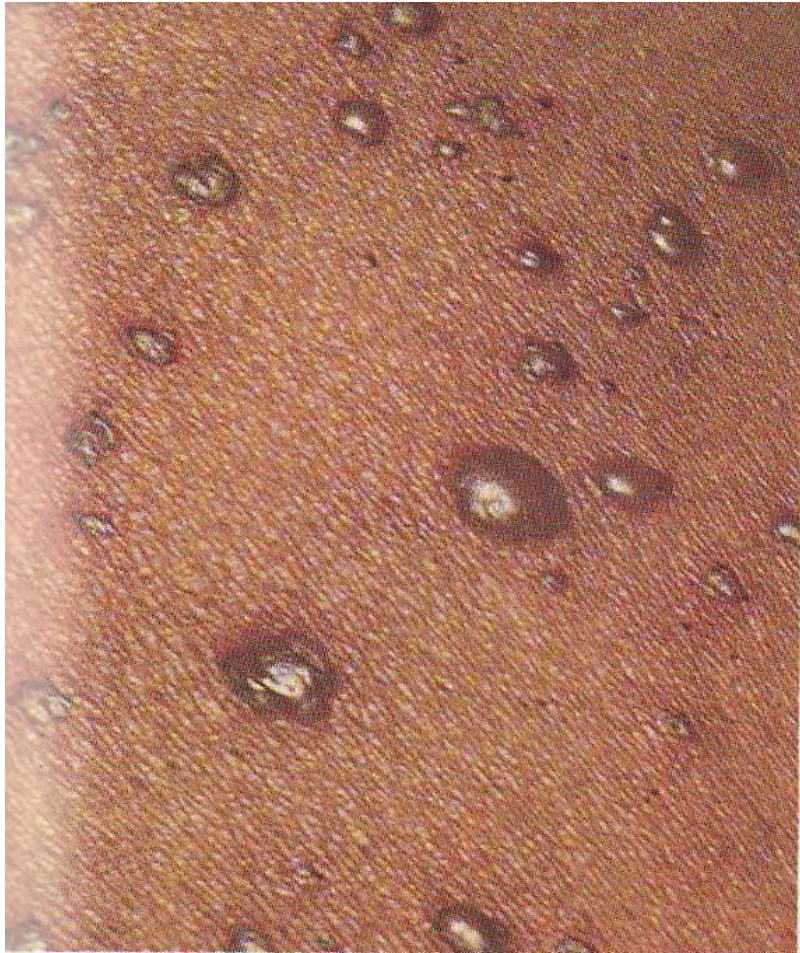
Кольцевидная эритема

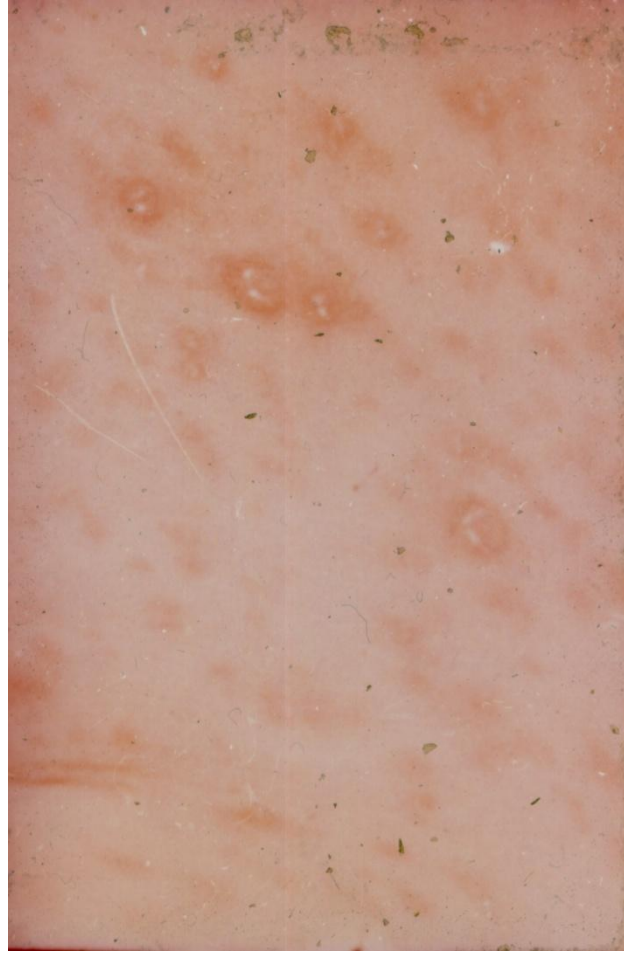
Синдром ошпаренной кожи



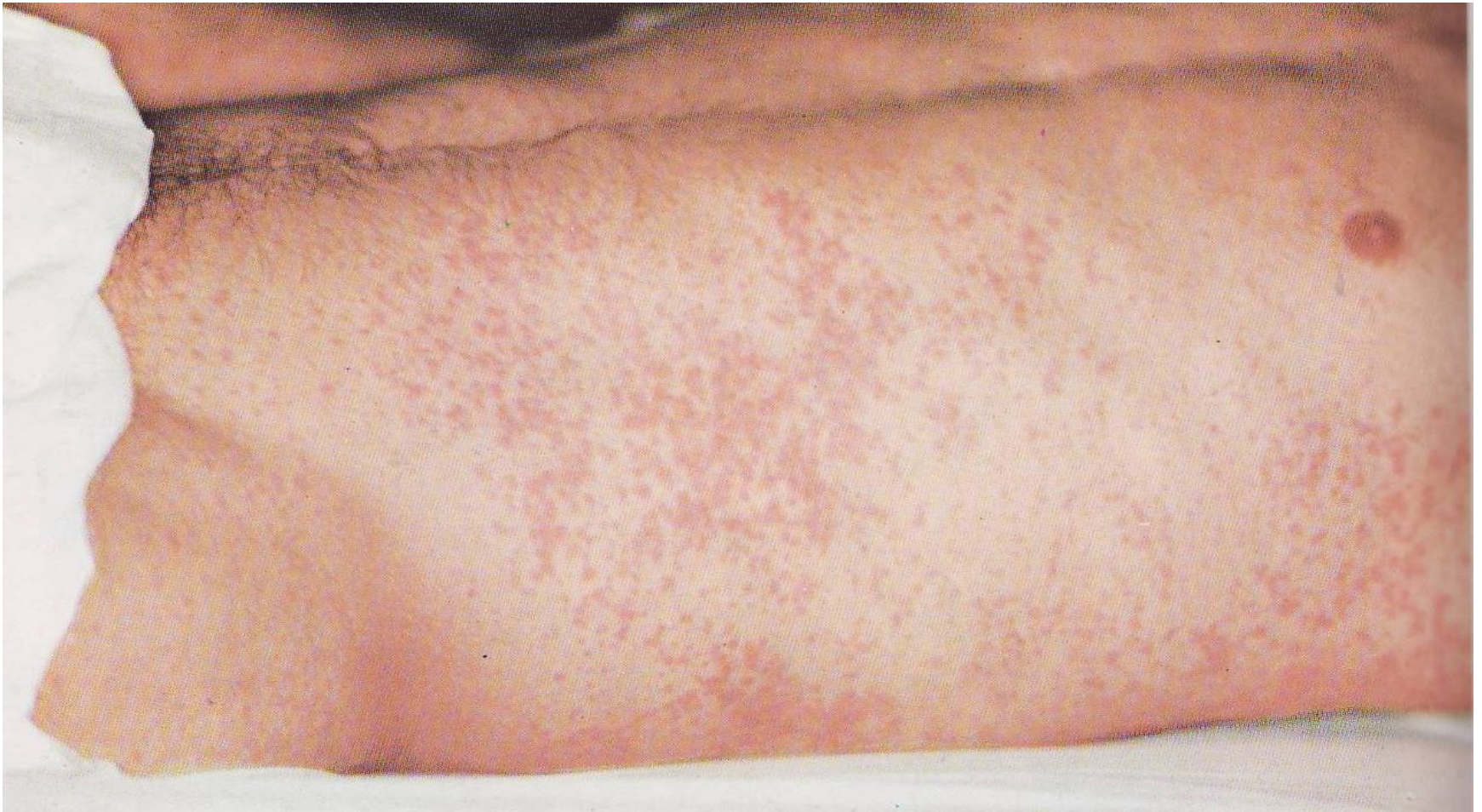

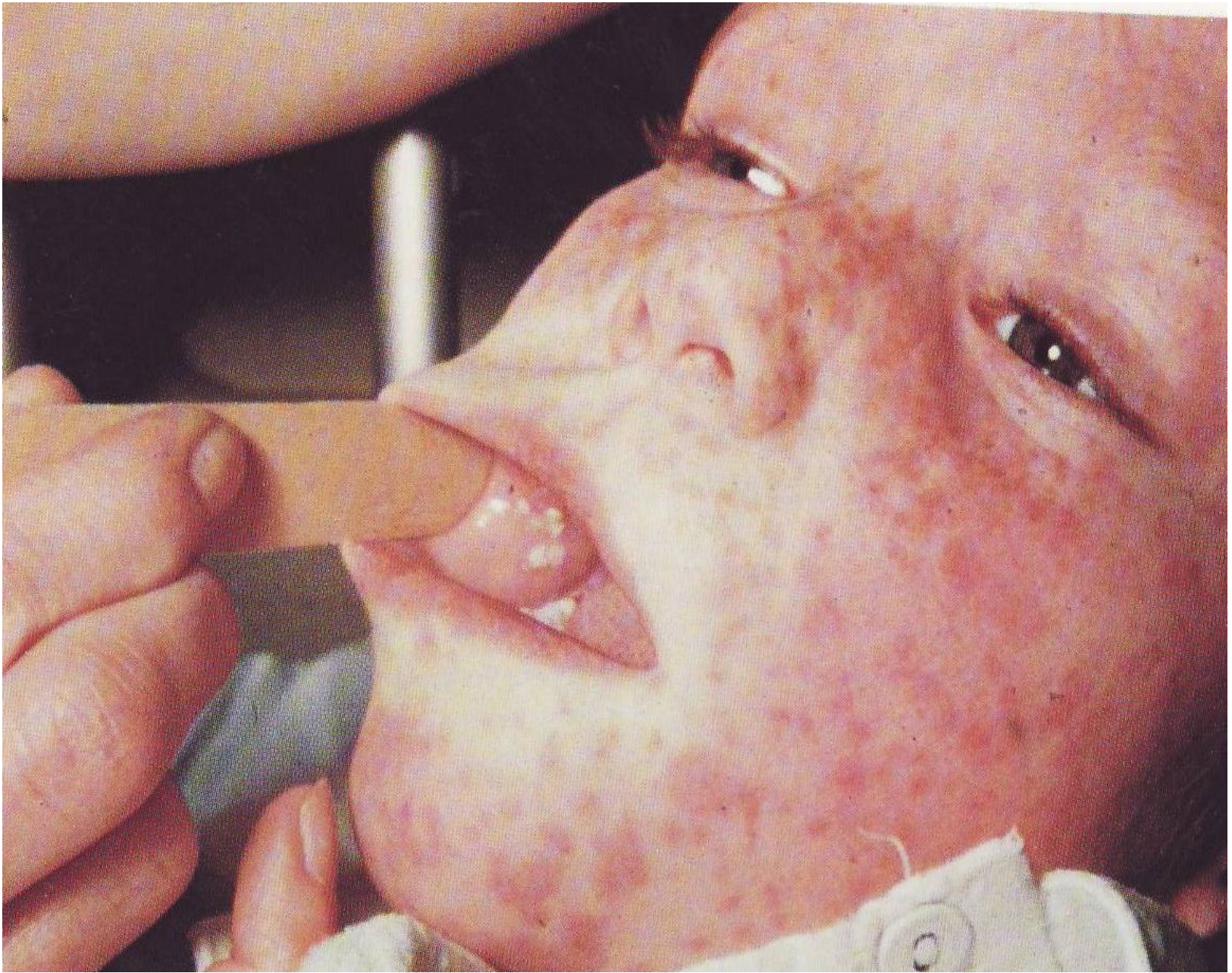


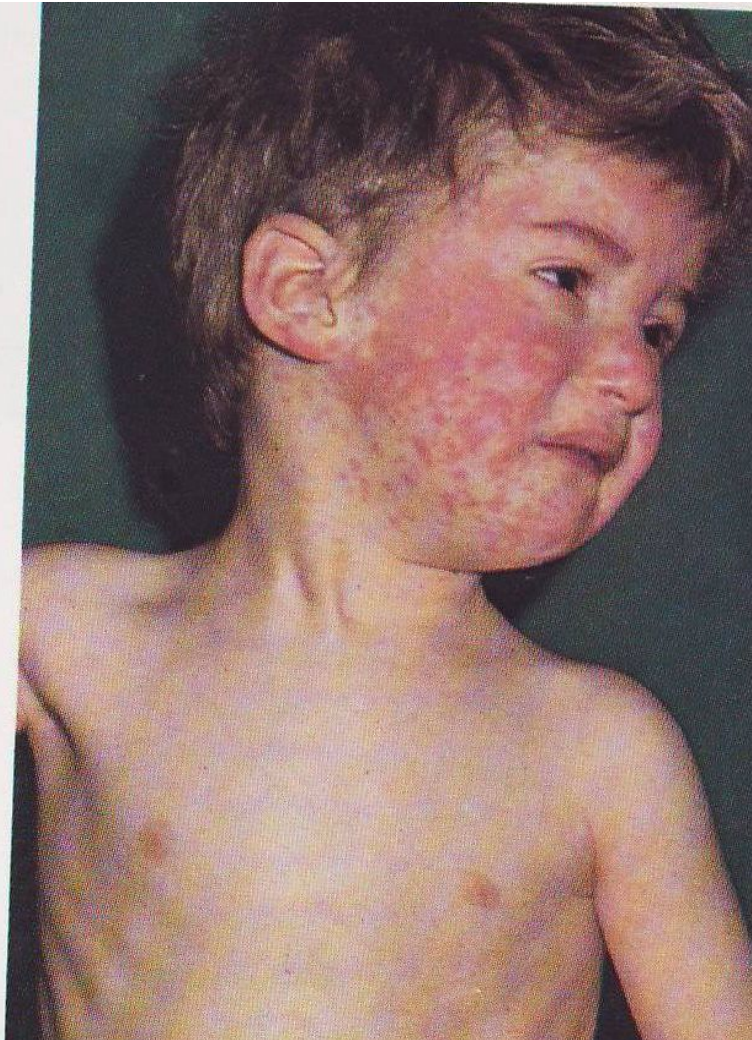
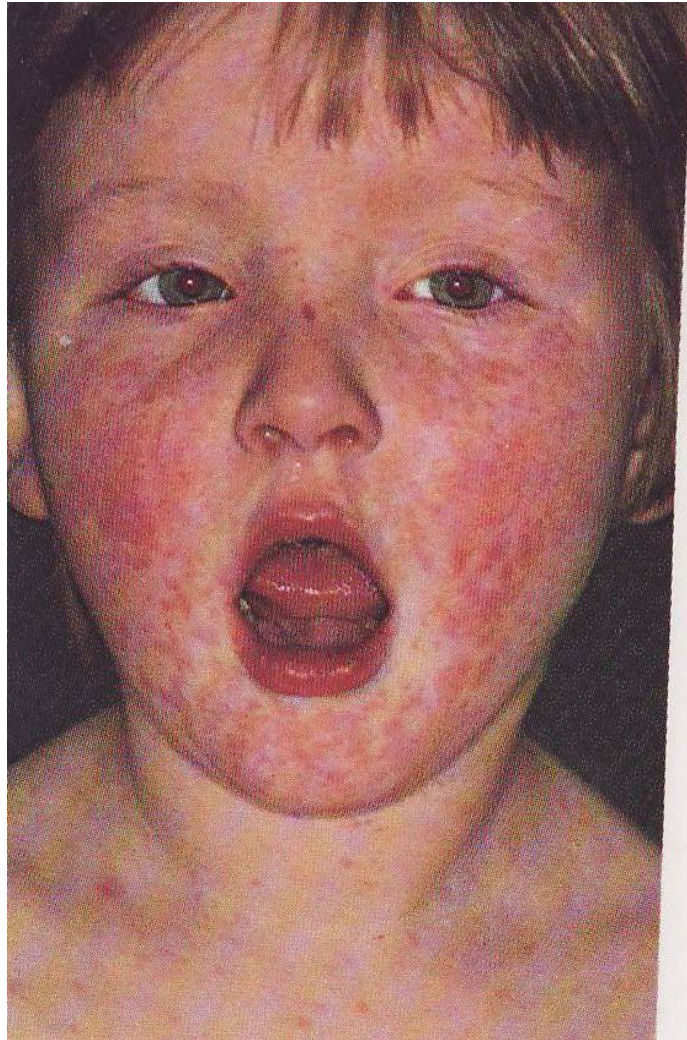



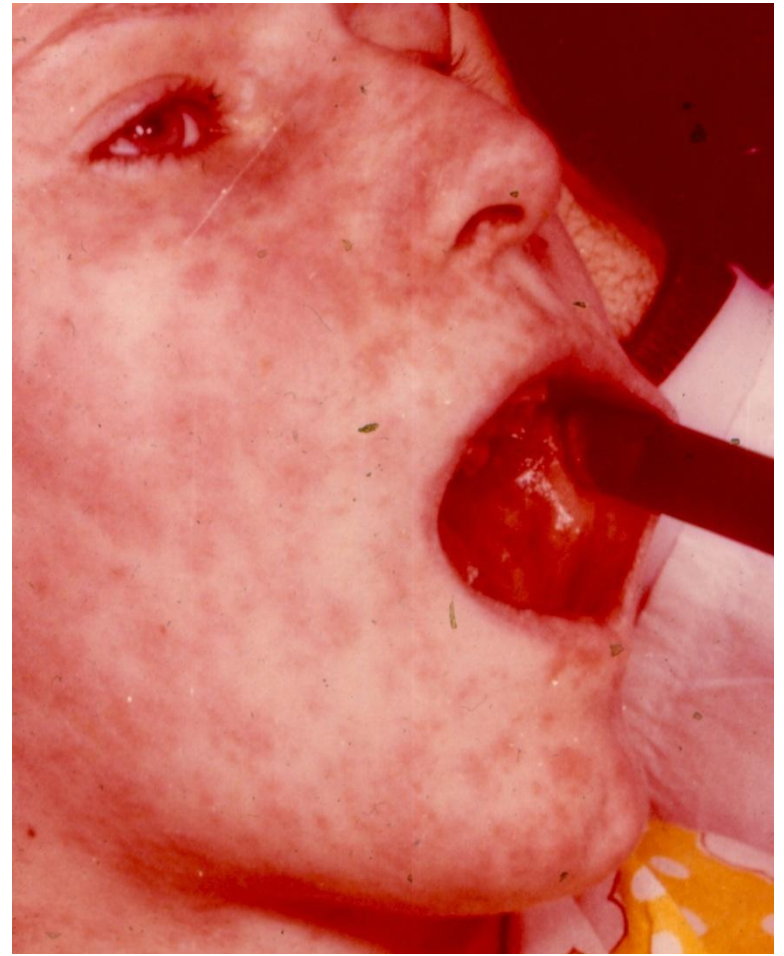
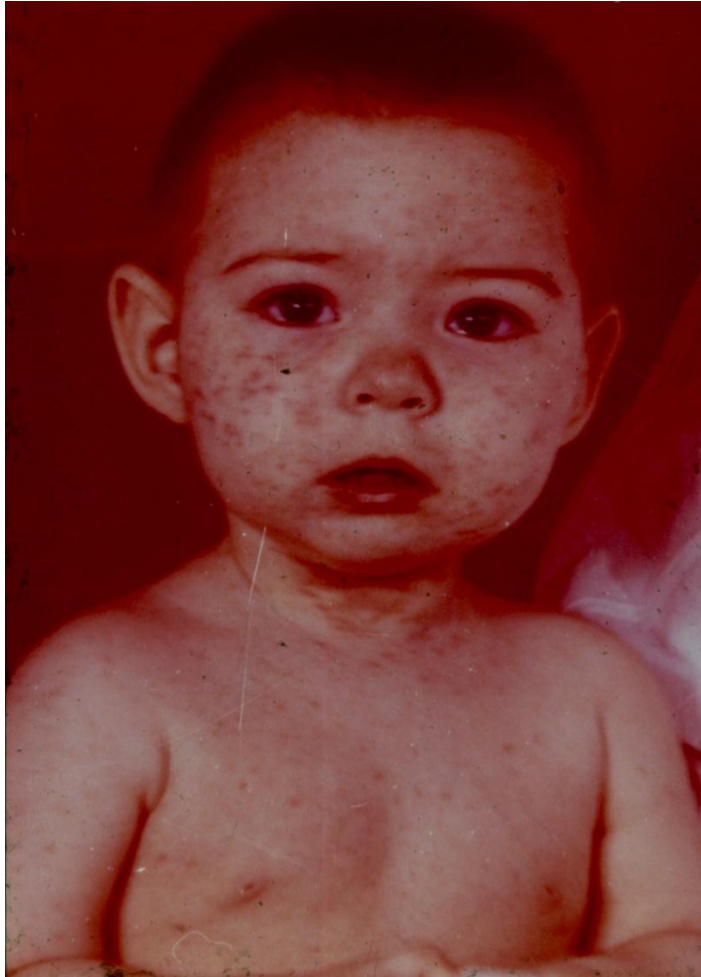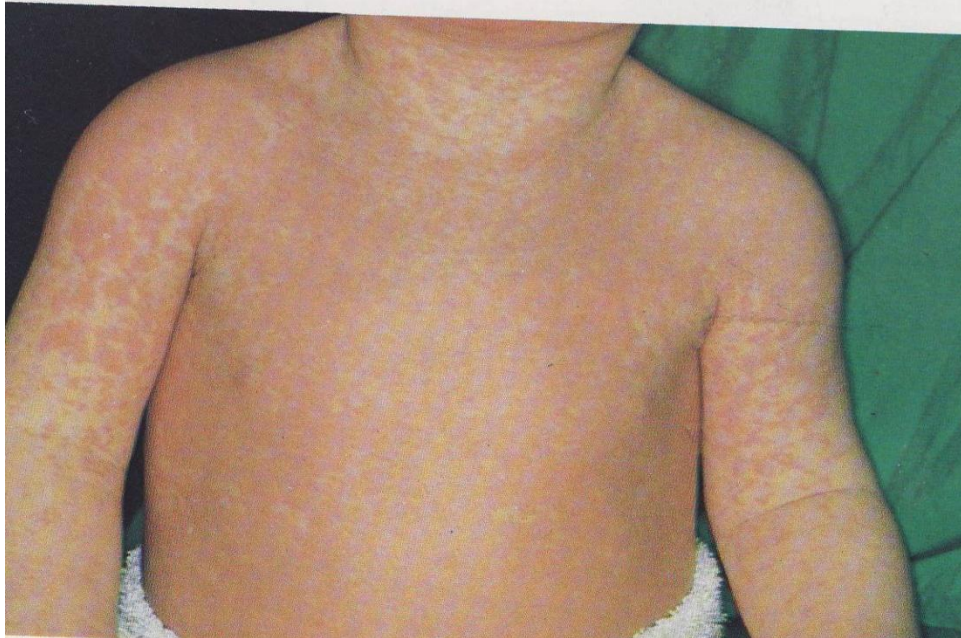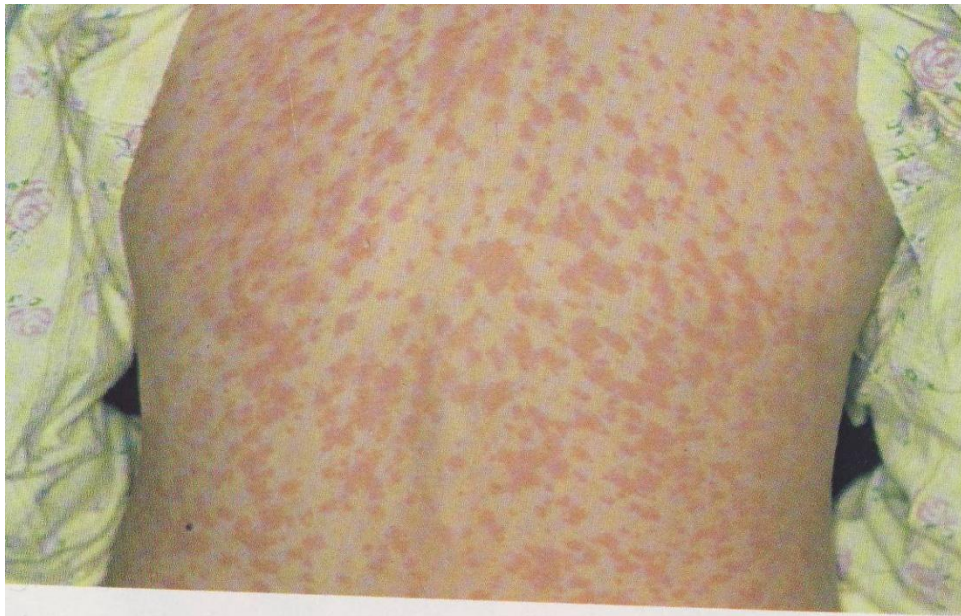
Инфекционный мононуклеоз

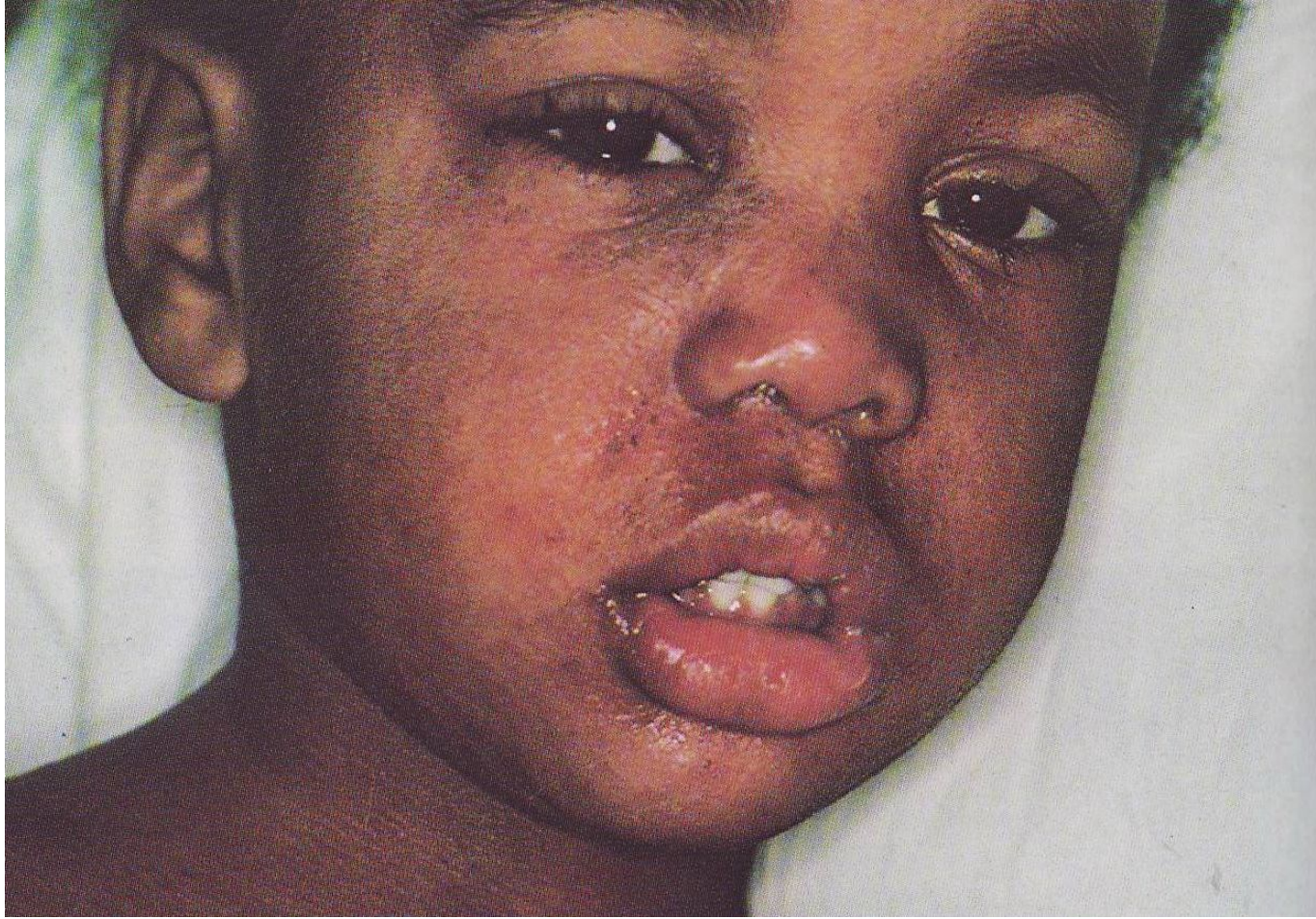


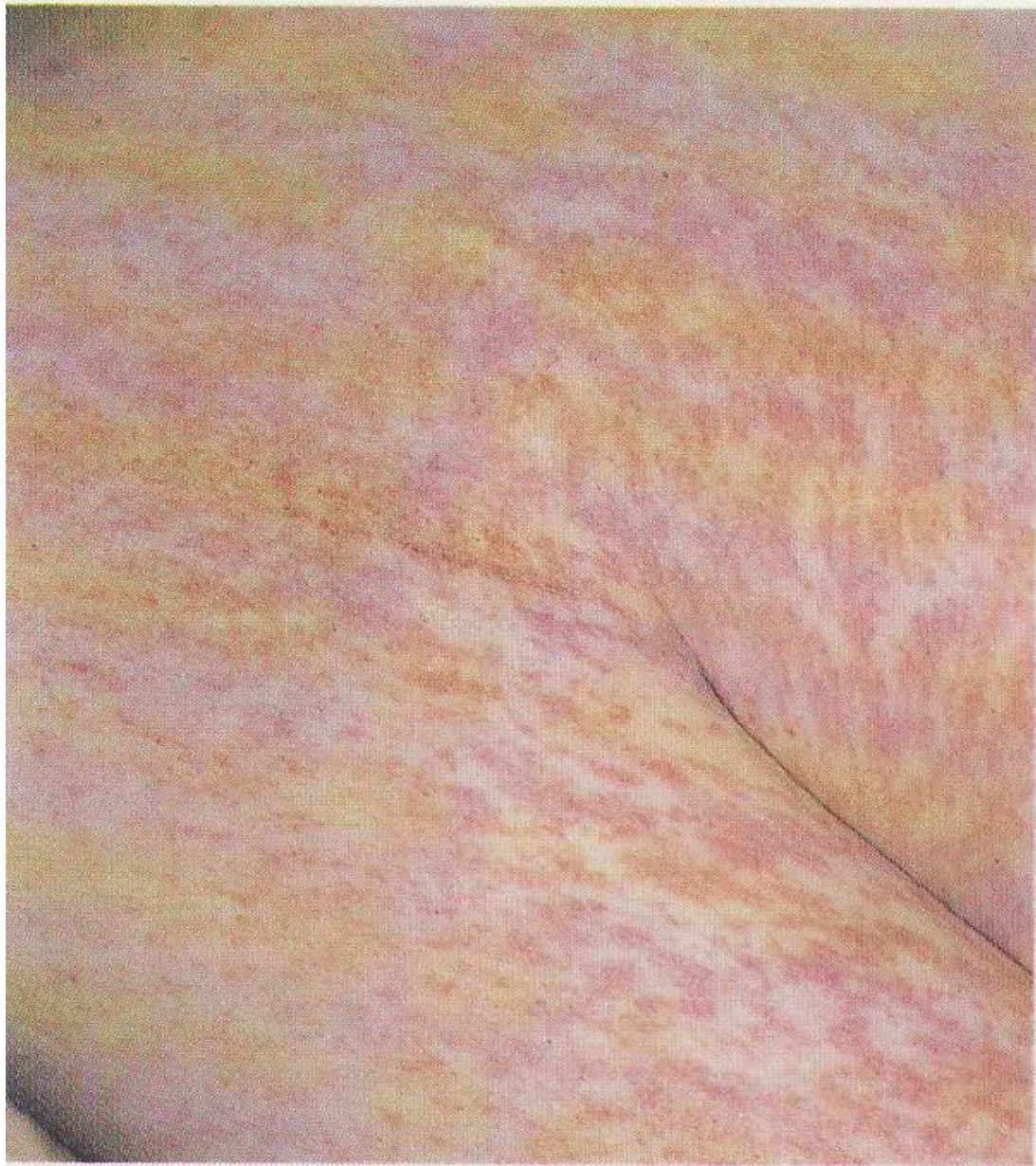


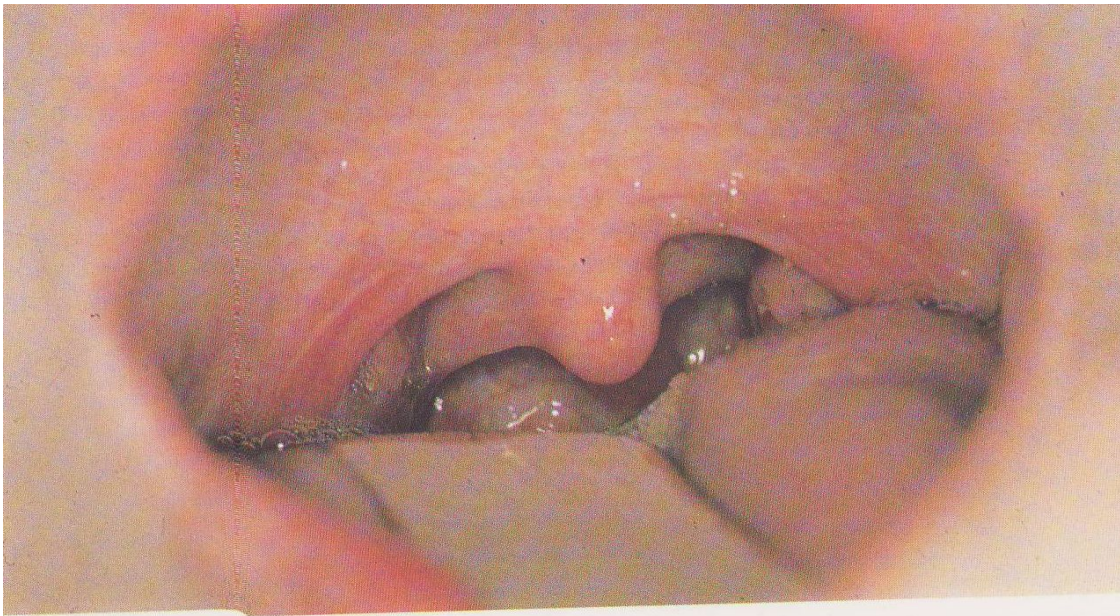

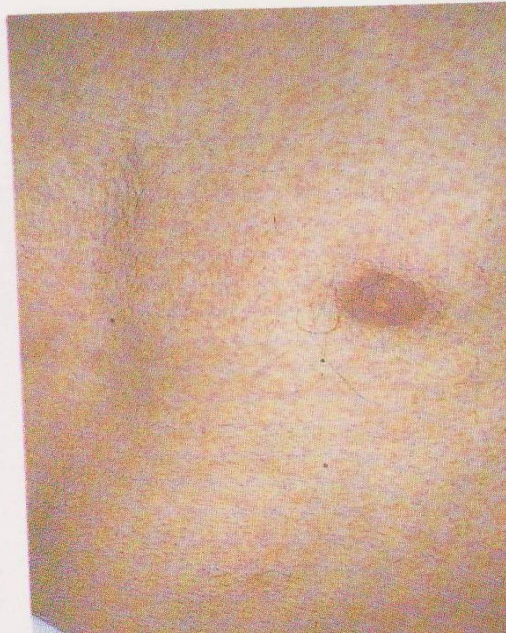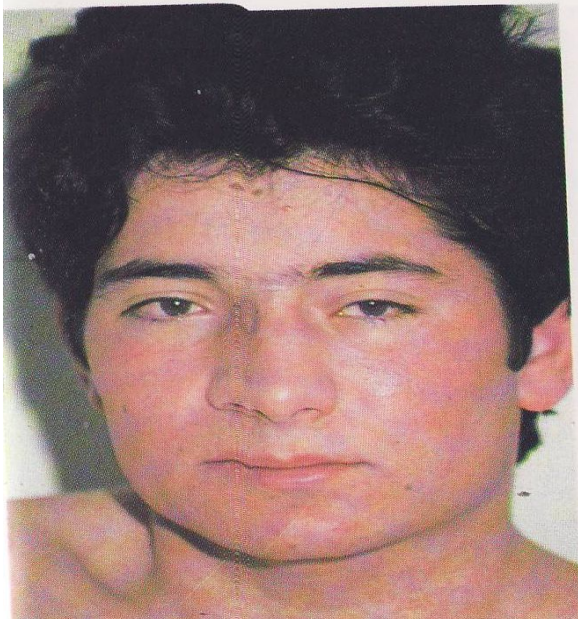


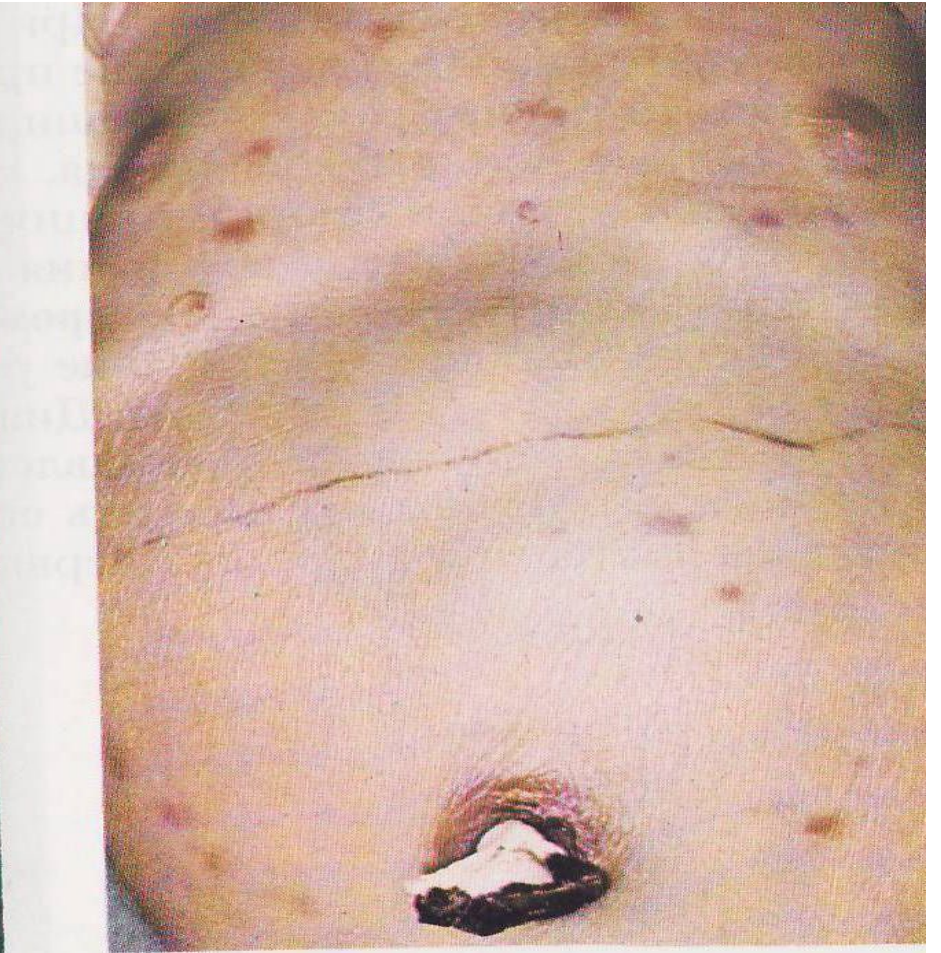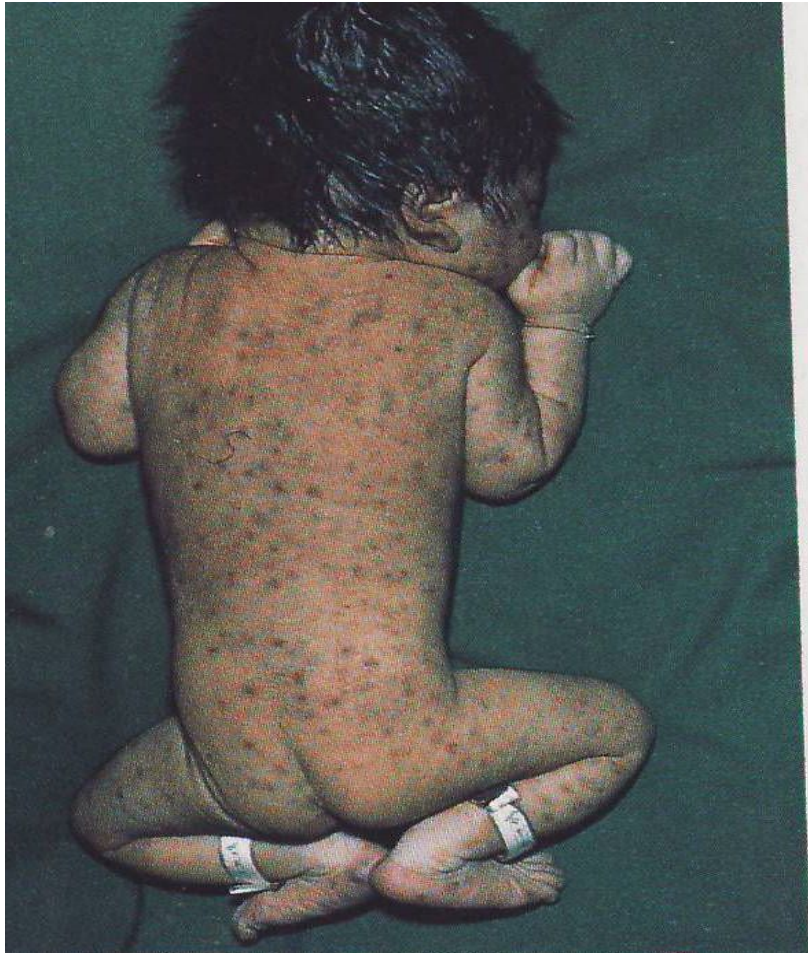






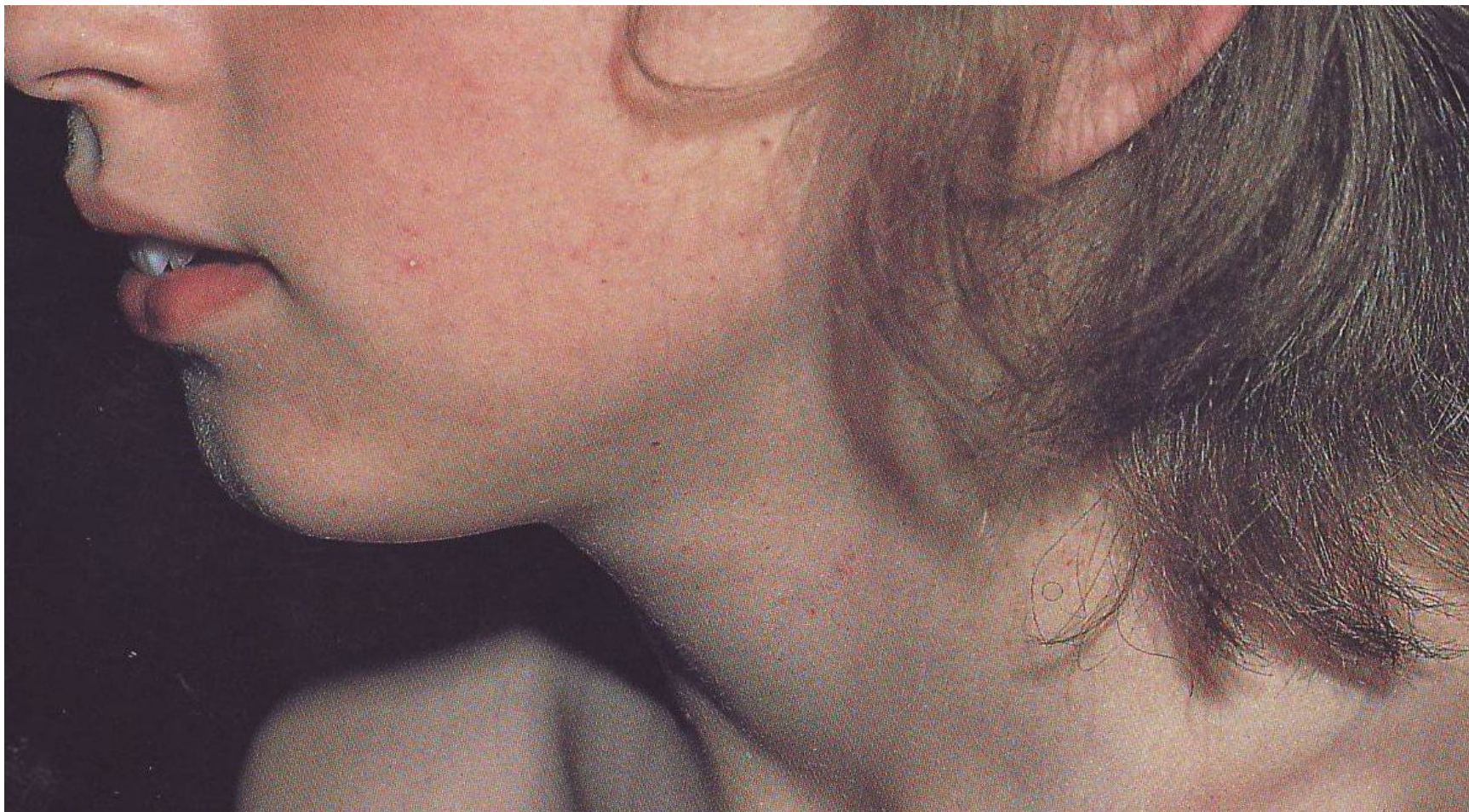100

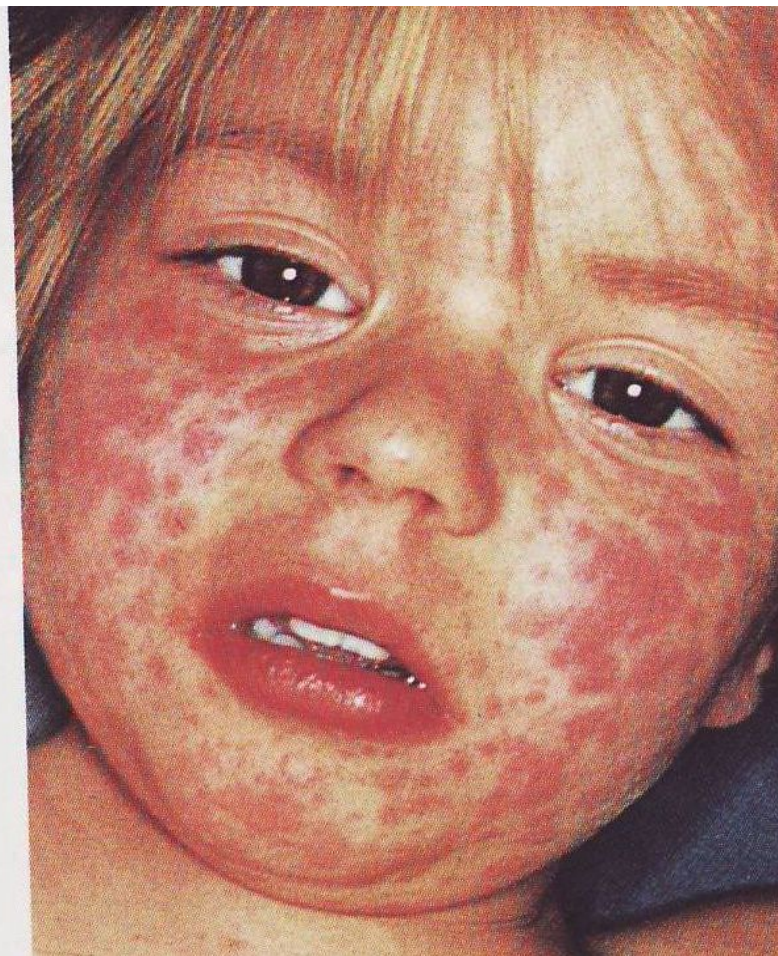
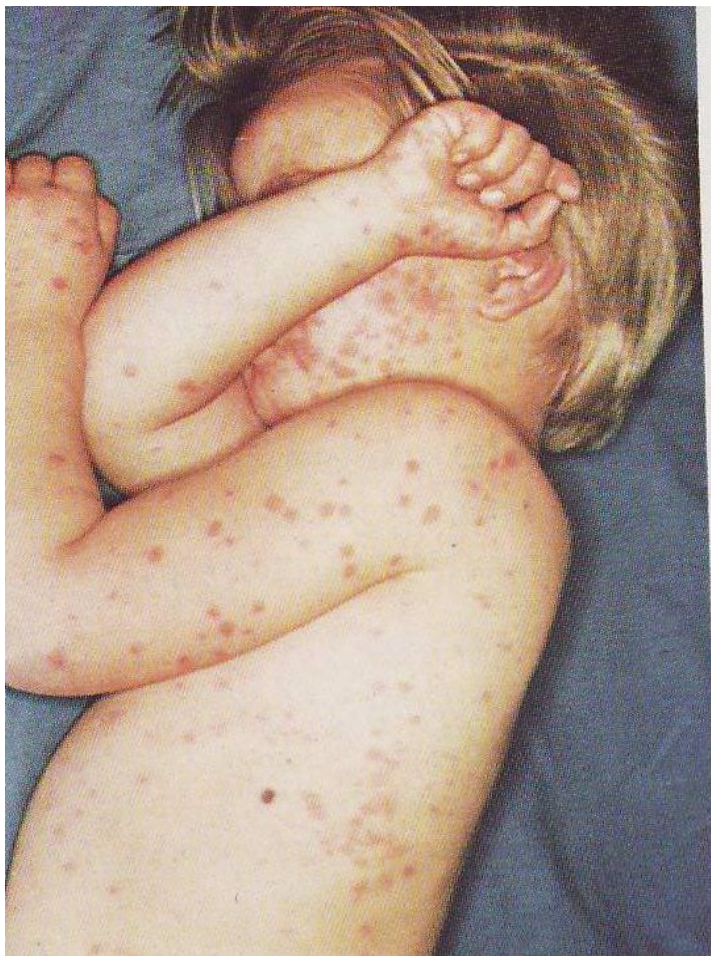



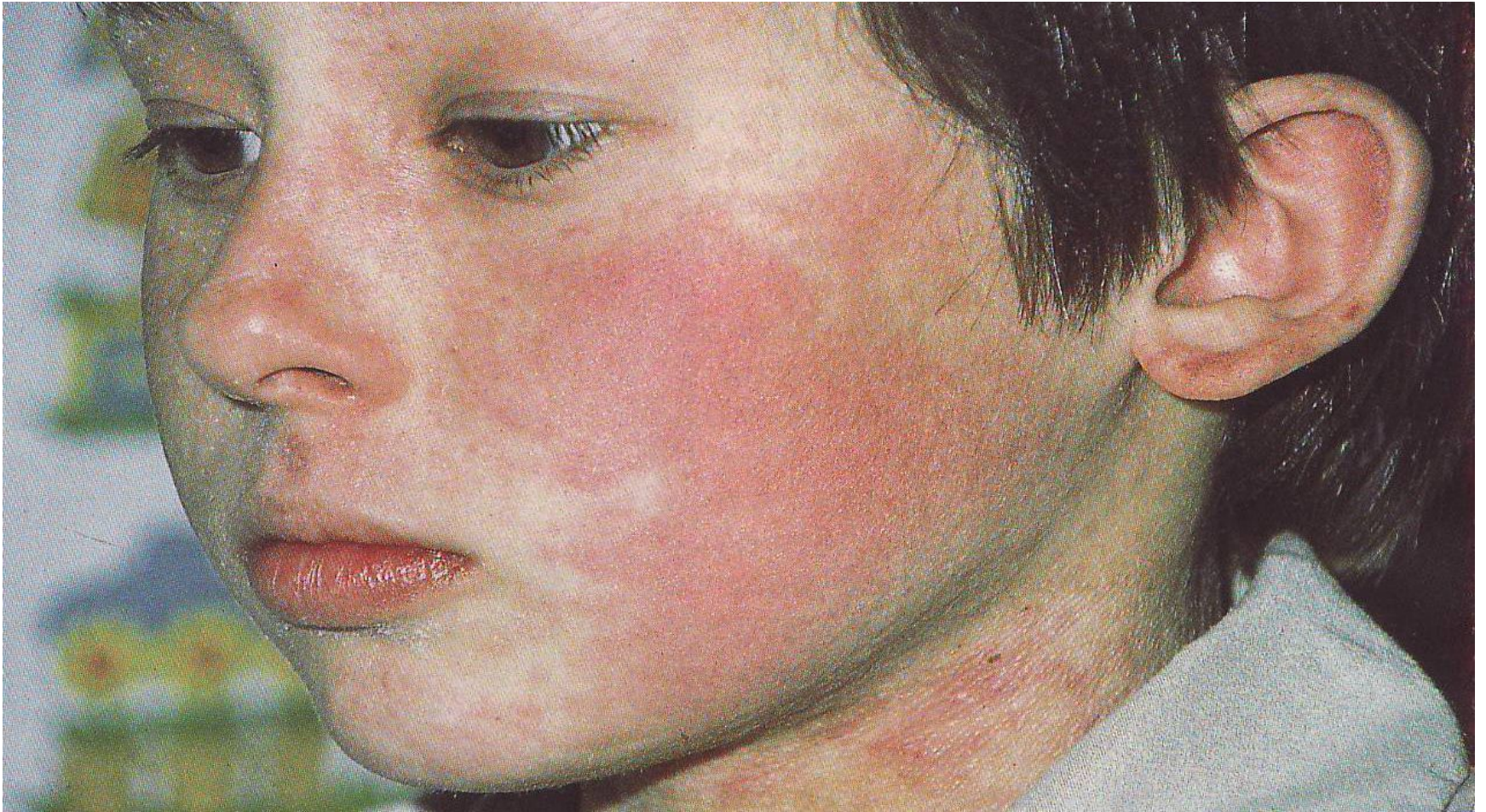Сыпь при энтеровирусной инфекции



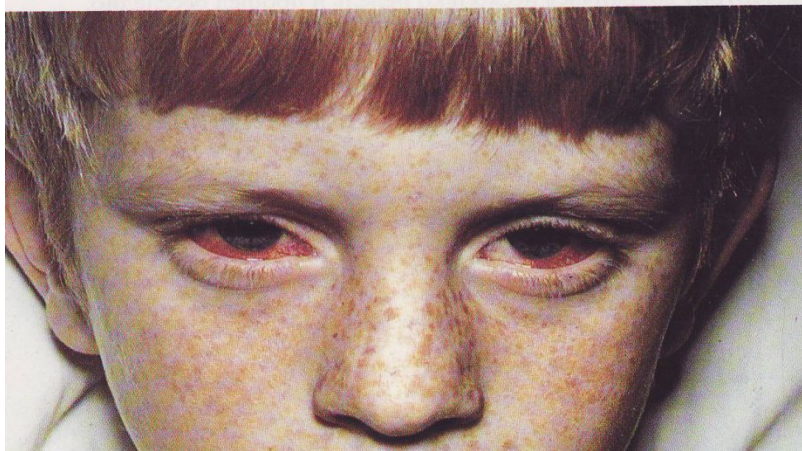
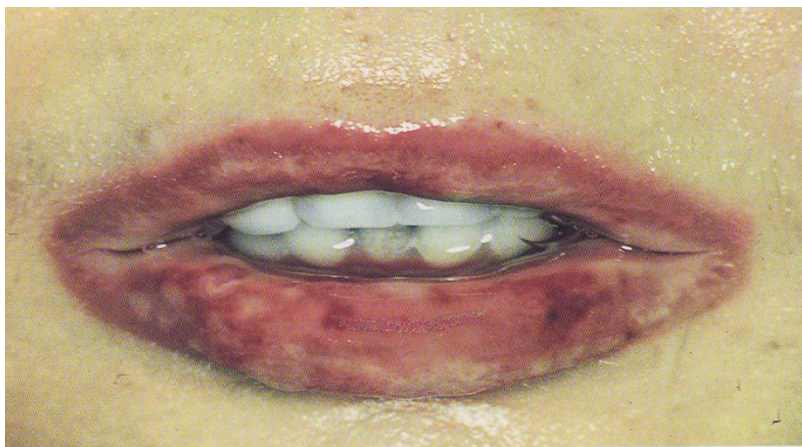Сыпь при энтеровирусной инфекции

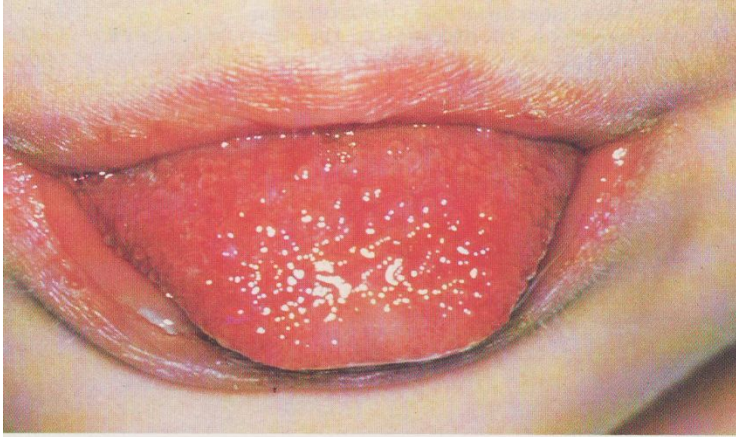

Инфекционная эритема (парвовирус)

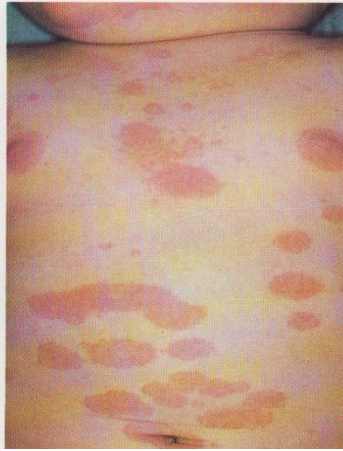
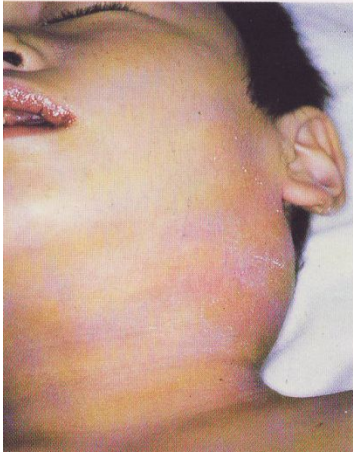

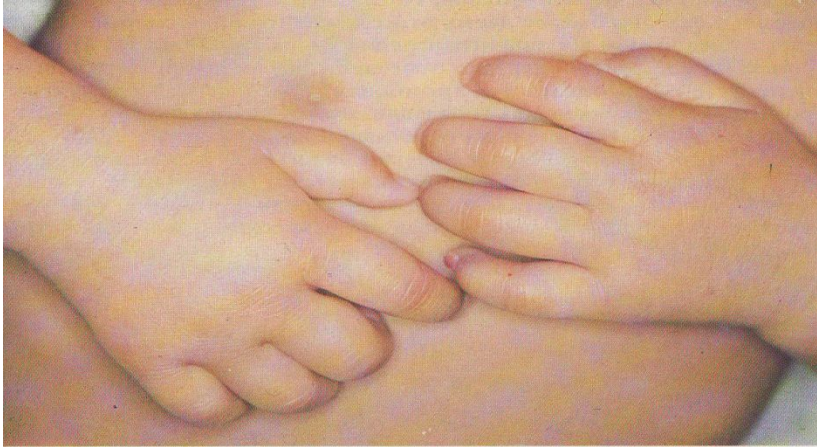Стивен-Джонс



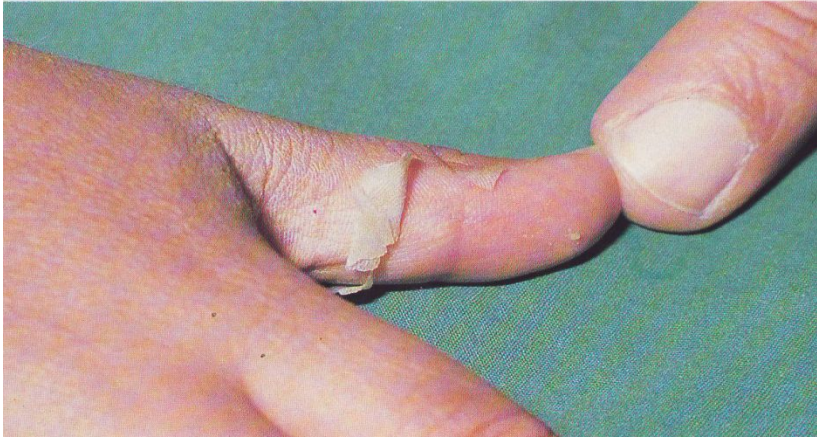


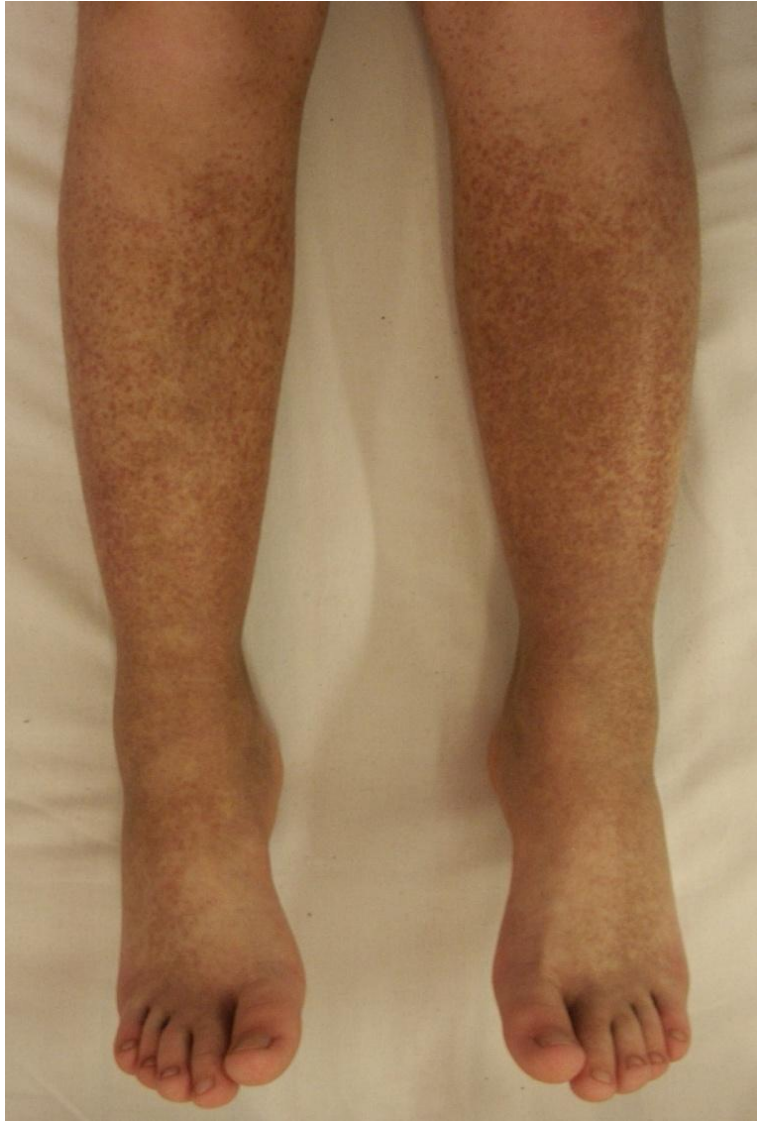3

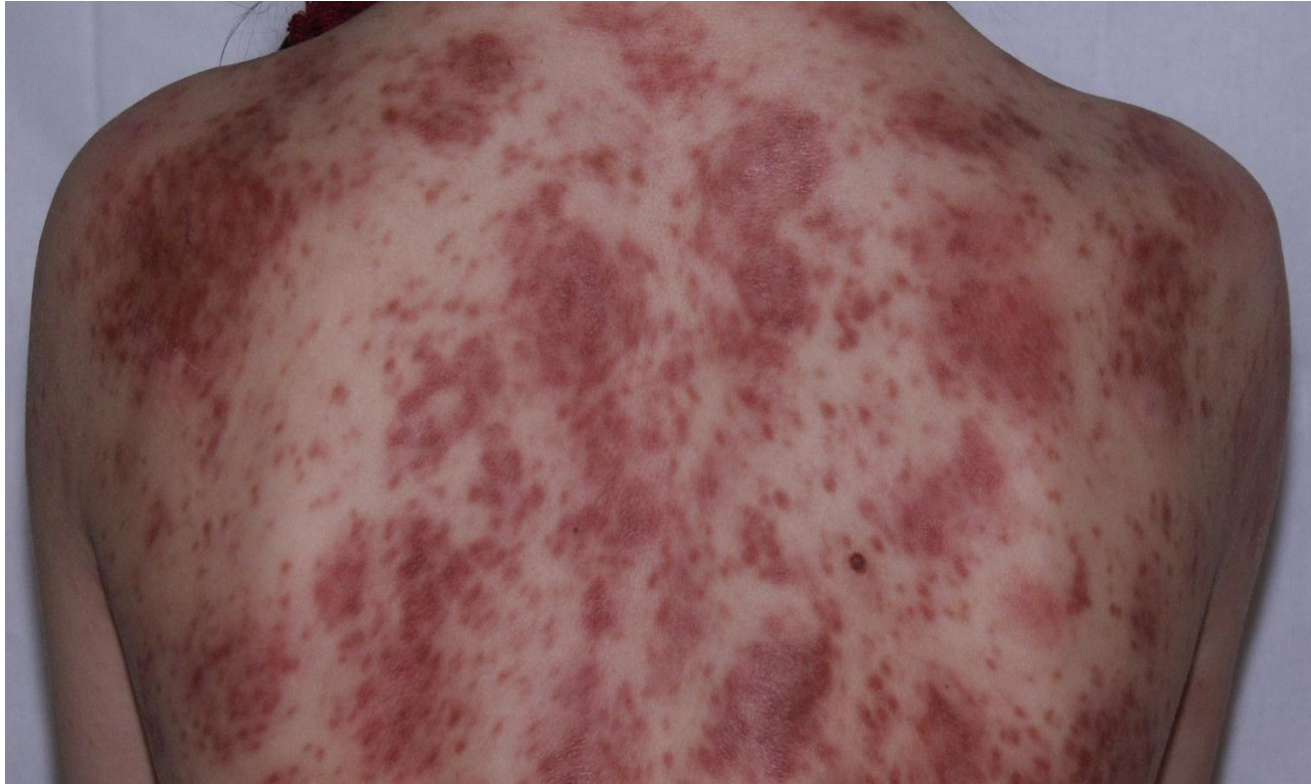



06







Мастоцитоз





