



СЕЧЕНОВСКИЙ УНИВЕРСИТЕТ

ПАТОЛОГИЯ ВОСХОДЯЩЕЙ АОРТЫ И ДУГИ АОРТЫ

Работу выполнила:
студентка ИКМ 6 курса 14 группы
Дорохина Елизавета Сергеевна

Москва - 2020

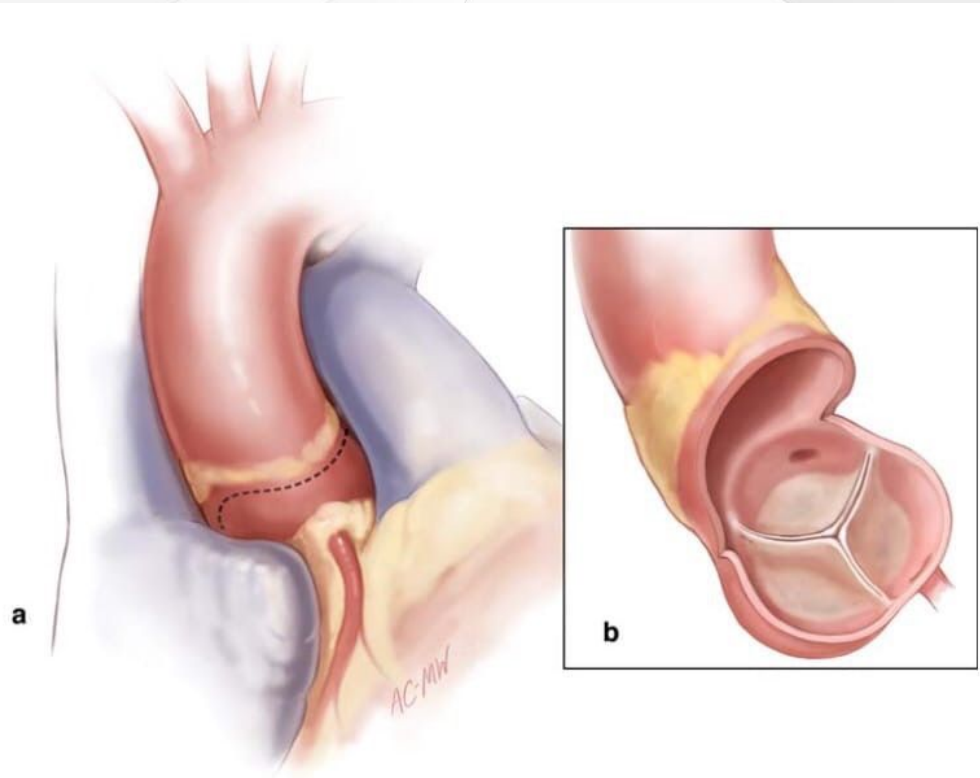
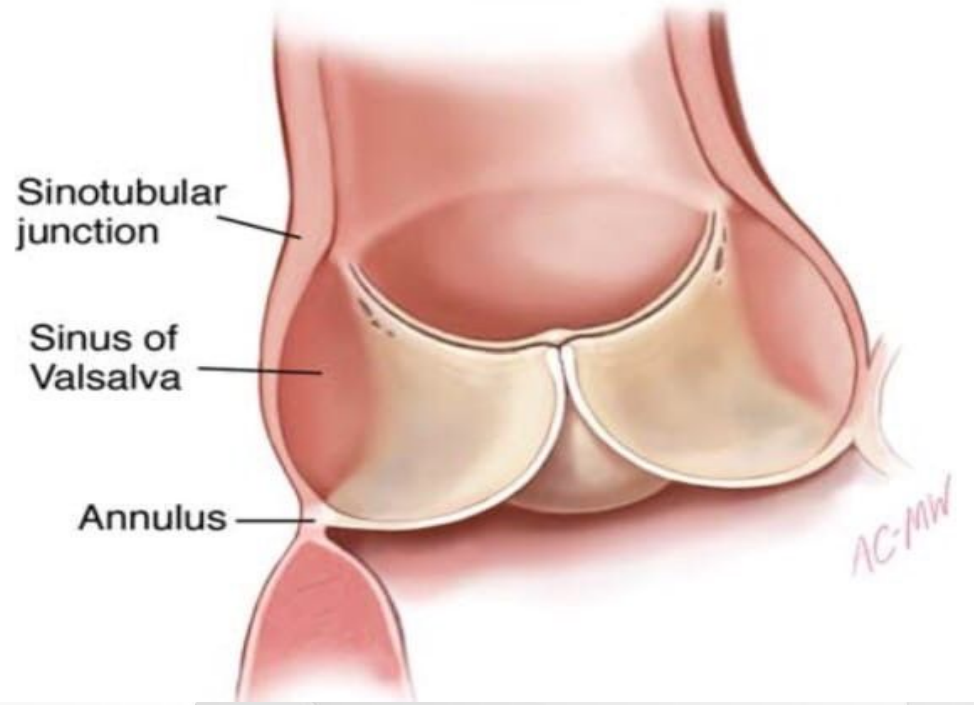
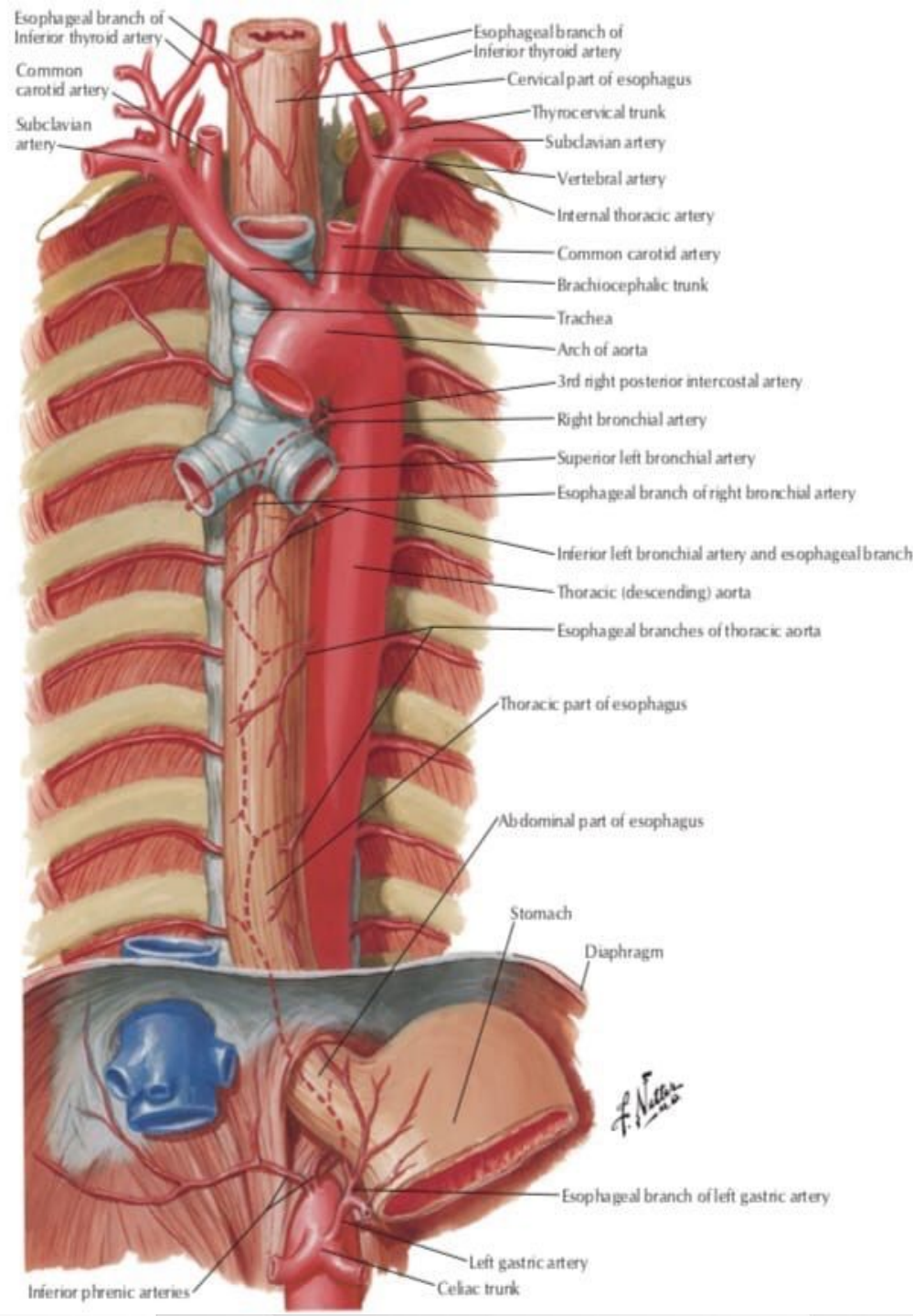
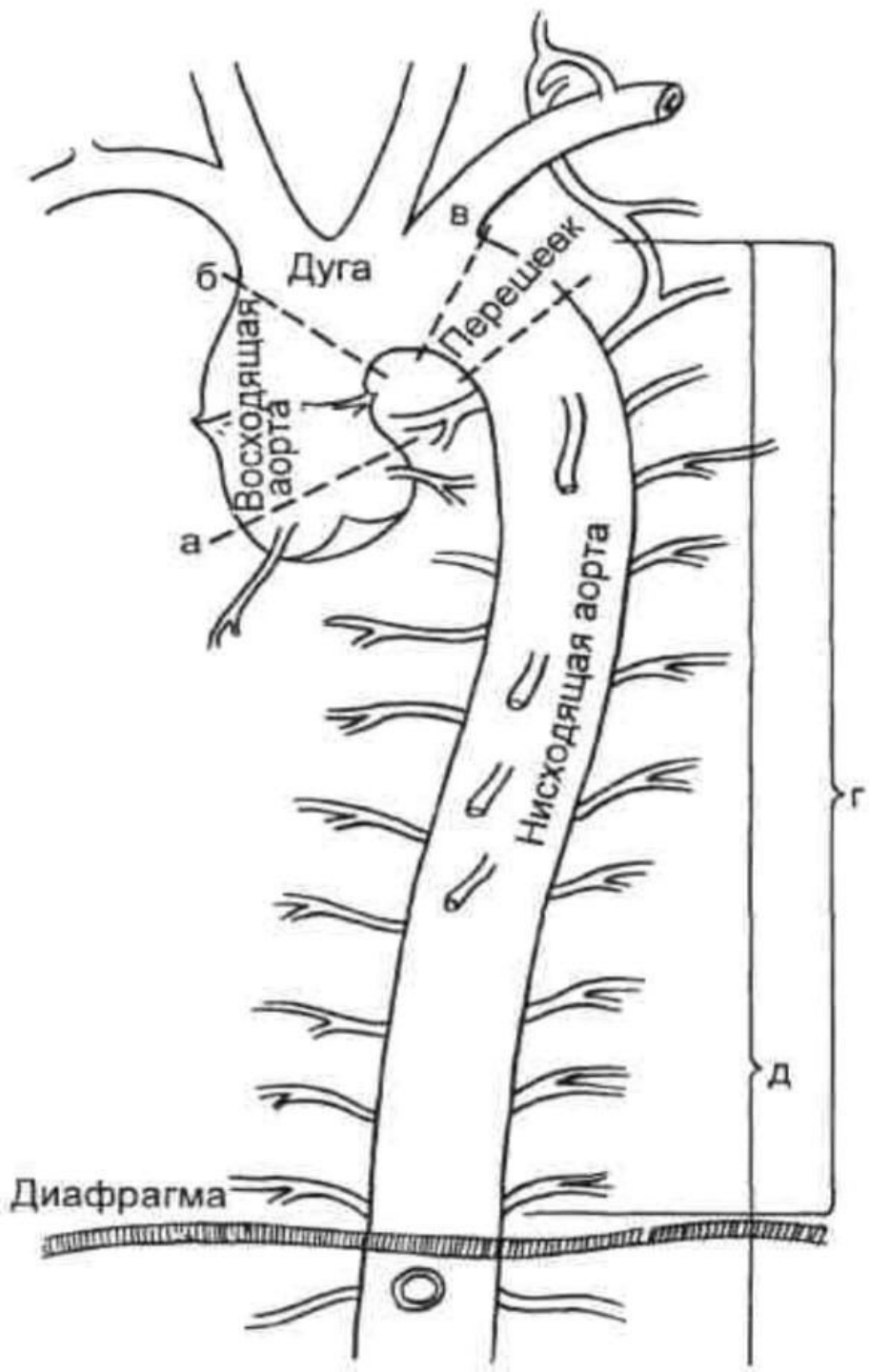


FIGURE 20-3





Этиология

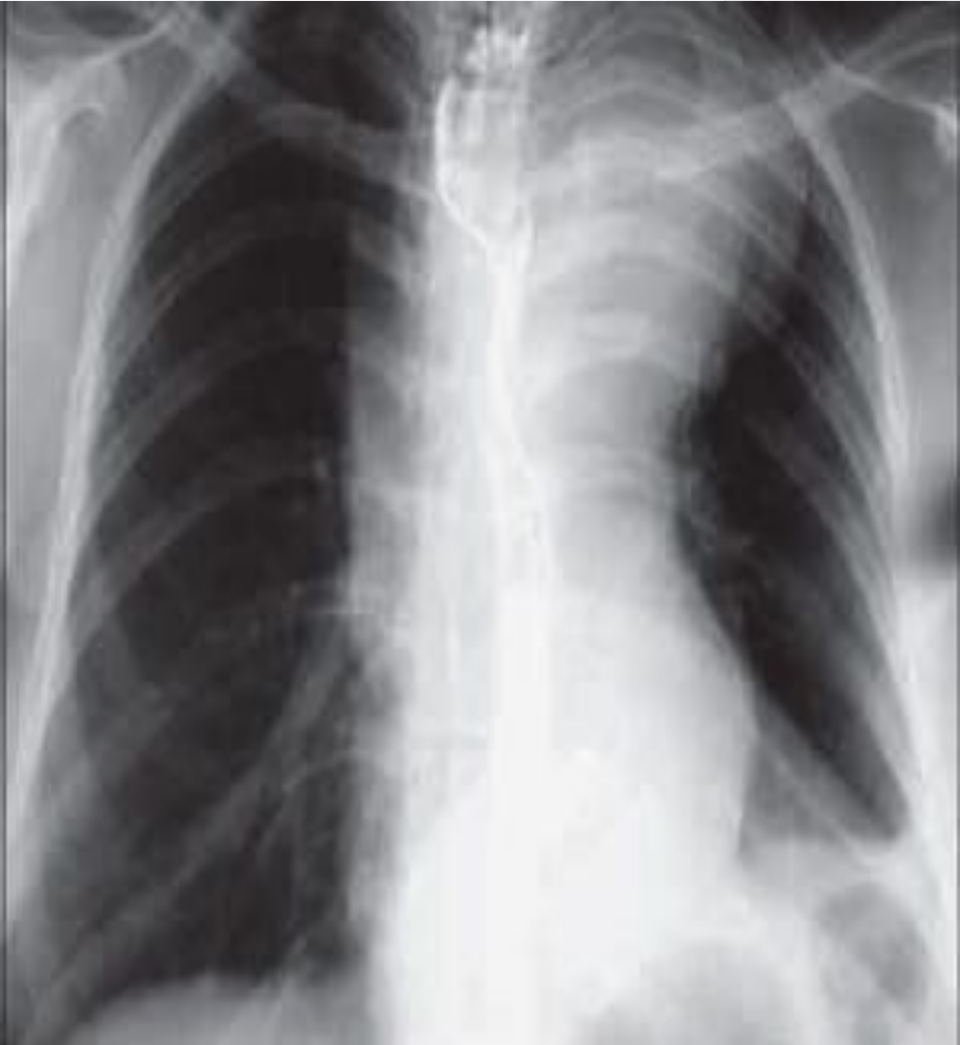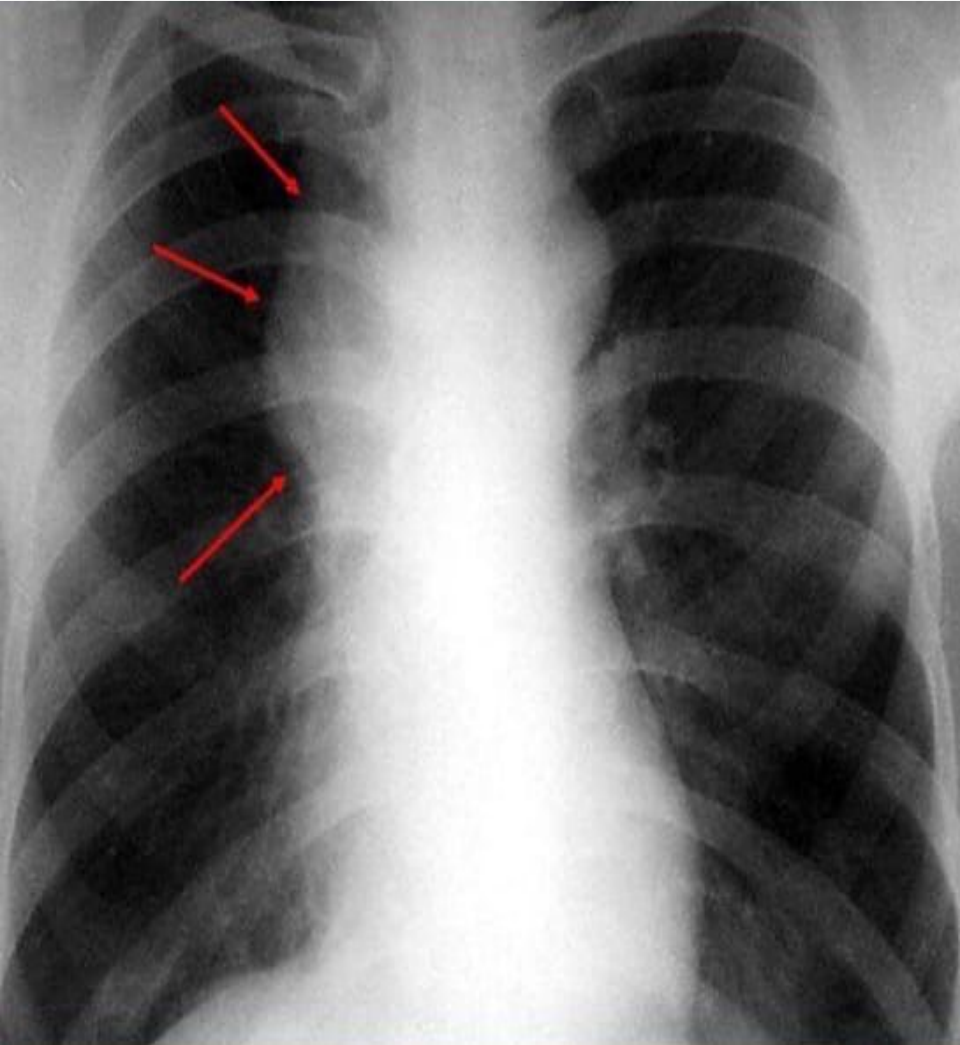
1. Врожденные заболевания:

- Сердечно-сосудистой системы: дву- или одностворчатый клапан, коарктация аорты
- Соединительной ткани: синдромы Марфана, Элерса-Данло, Лойса-Дитца

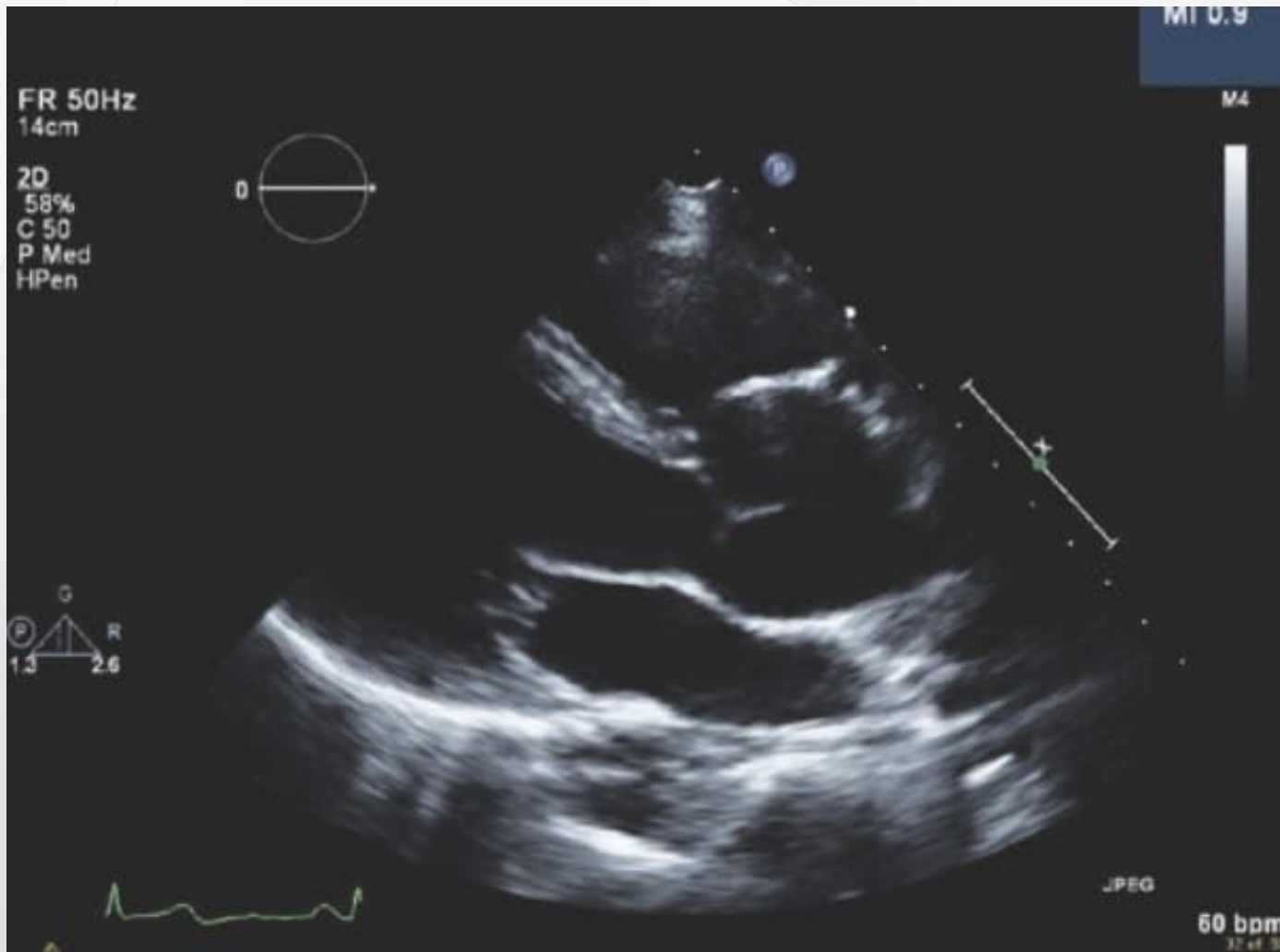
2. Приобретенные заболевания:

- Невоспалительные: атеросклероз, послеоперационные
- Воспалительные: инфекционные и неинфекционные аортиты, инфекция протеза аорты
- Посттравматические
- Ятрогенные
- Идиопатические – медионекроз Эрдгейма

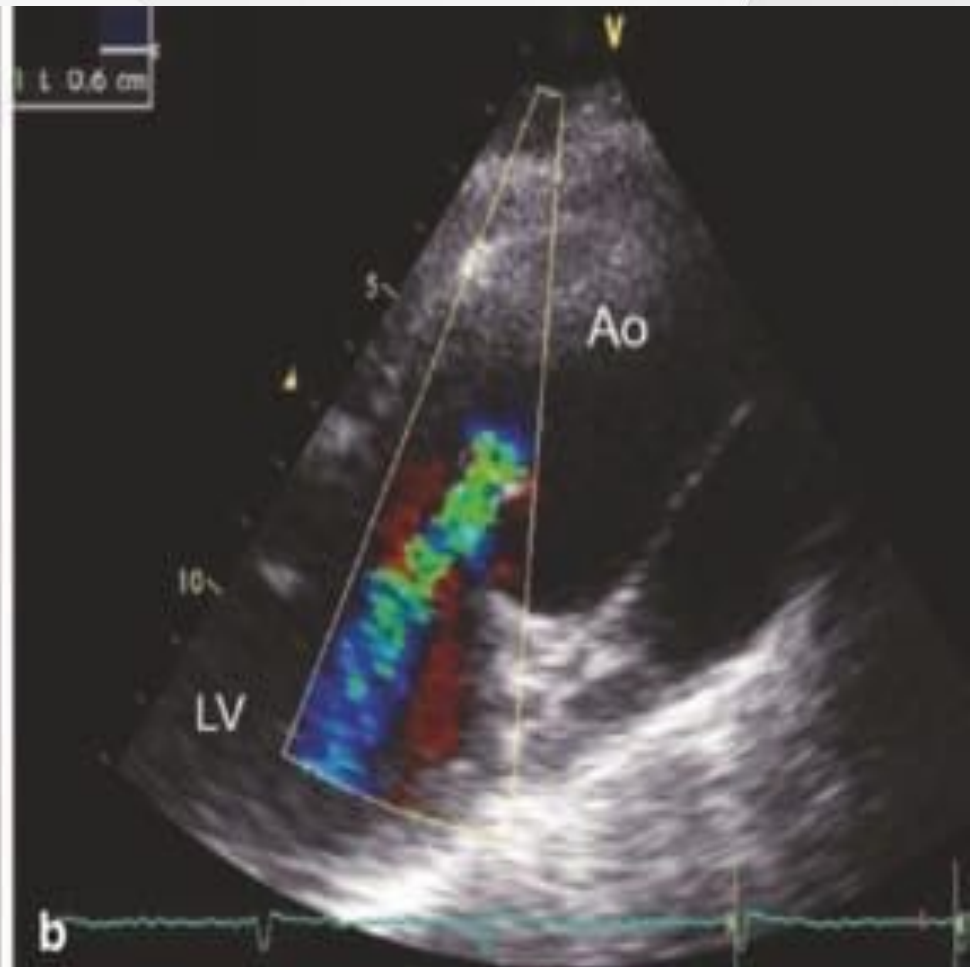
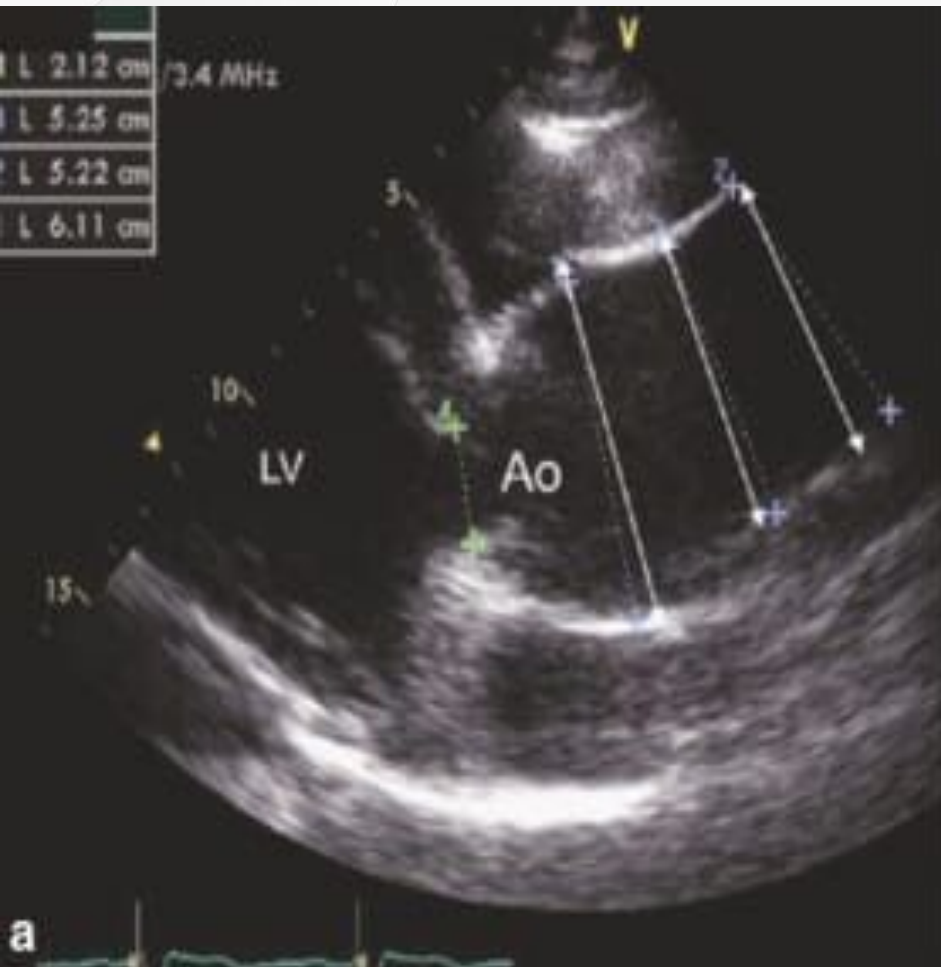Рентгенография



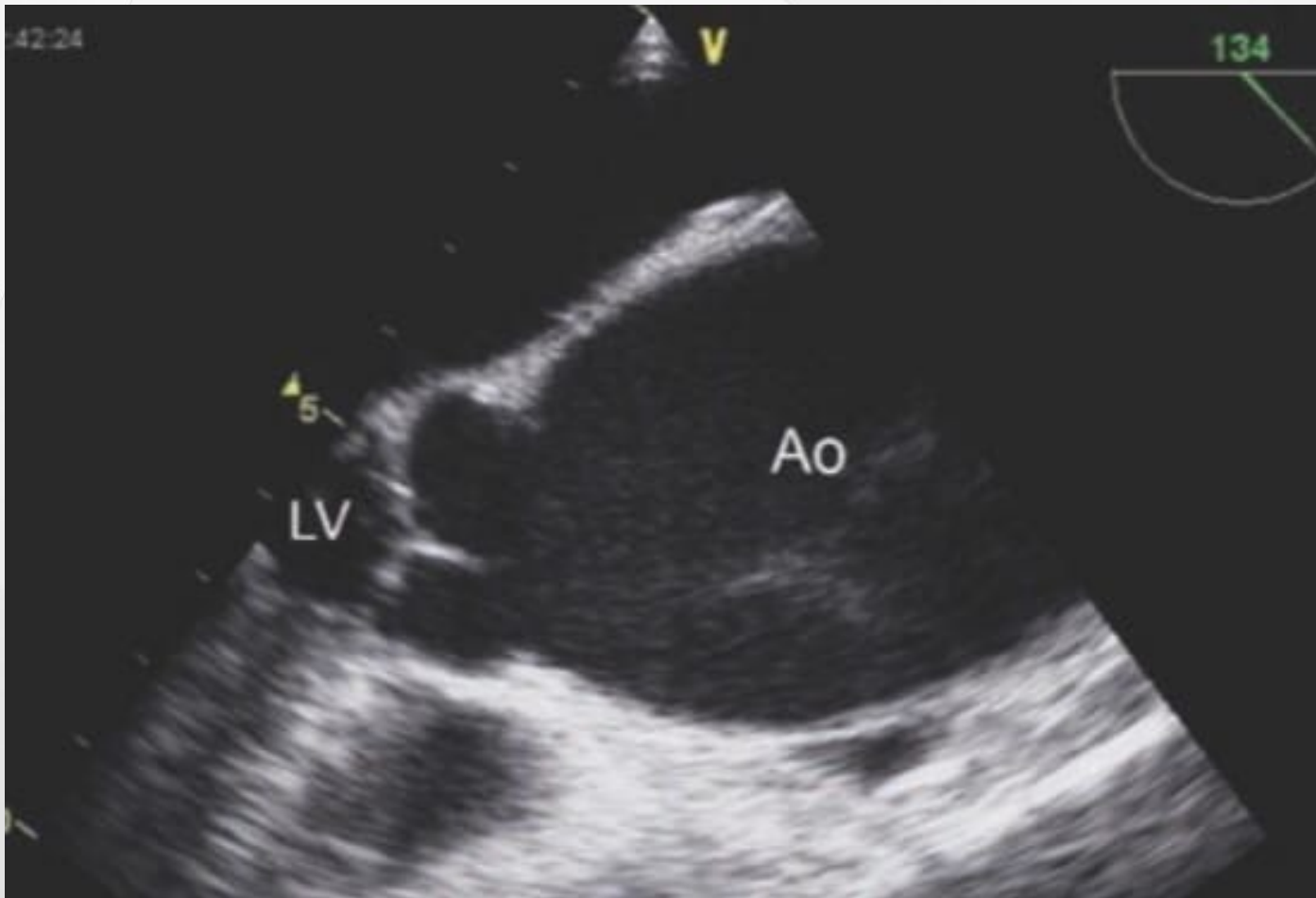
Трансторакальная и чреспищеводная Эхо-КГ



Dieter R.S., Dieter Jr. R.A., Dieter III R.A. Diseases of the Aorta, 2019

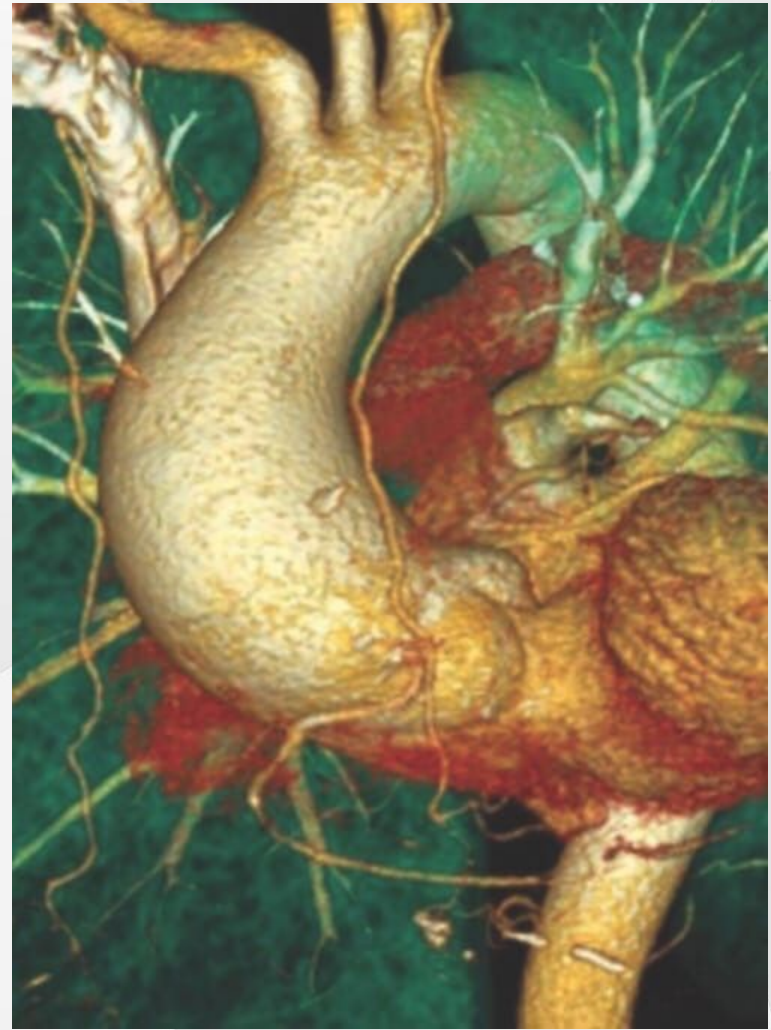
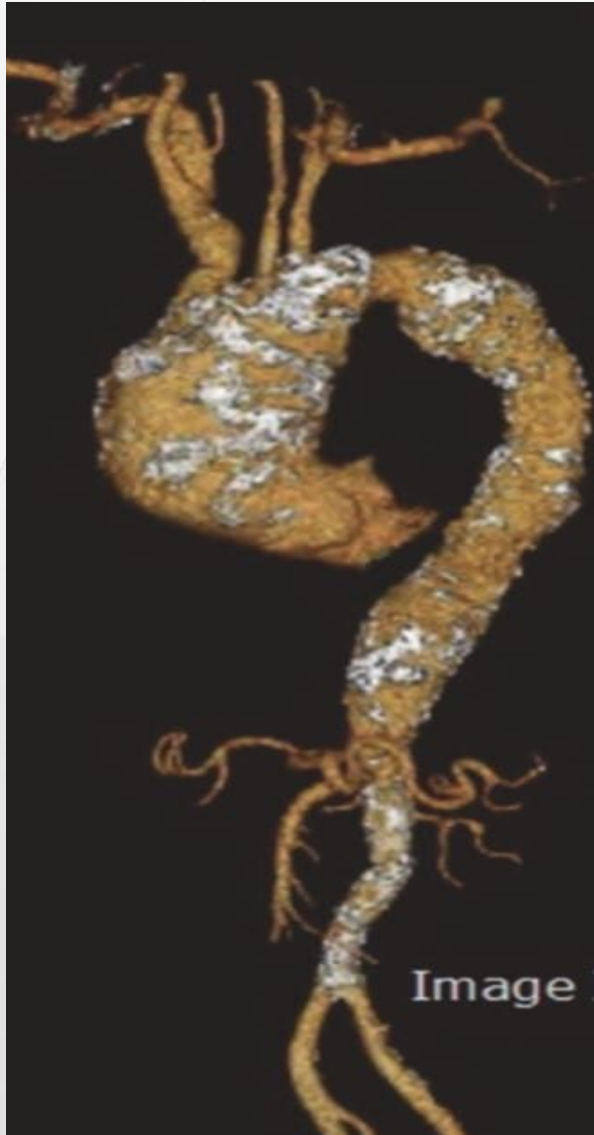

Stanger O.H., Pepper J.R., Svensson L.G. Surgical management of aortic pathology, 2019

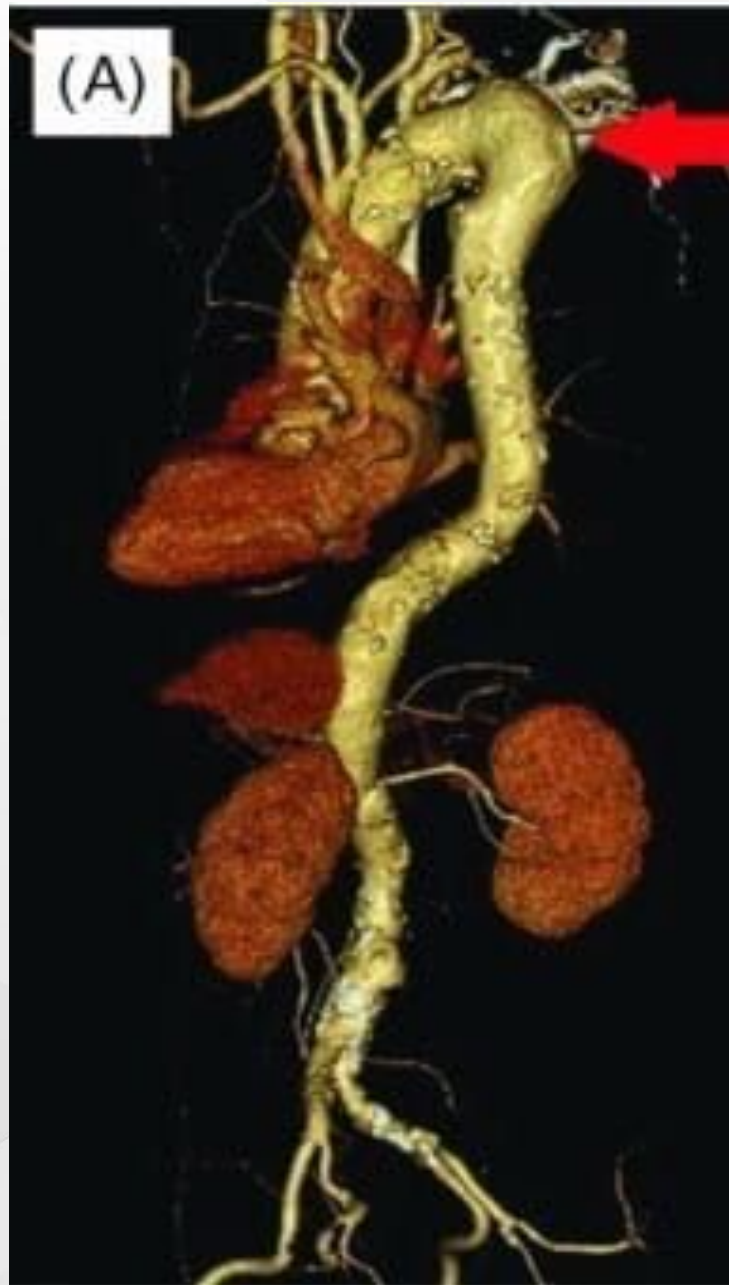

Stanger O.H., Pepper J.R., Svensson L.G. Surgical management of aortic pathology, 2019

КТ – ангиография

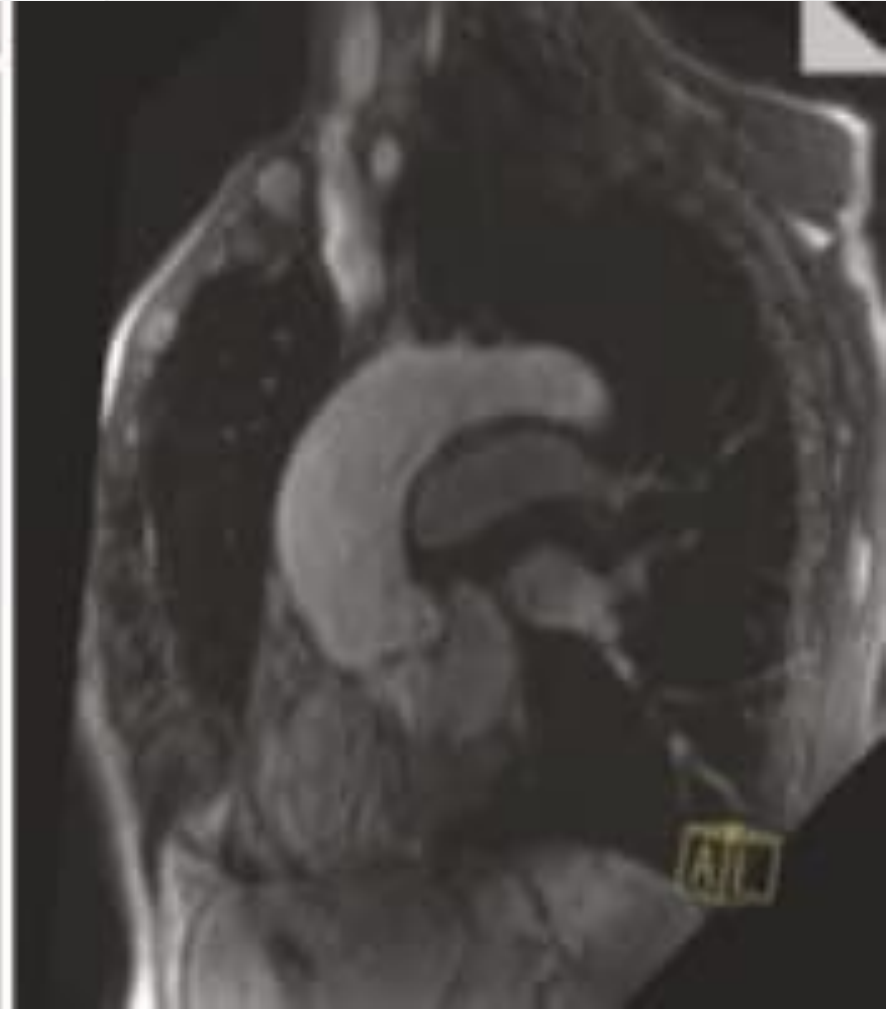
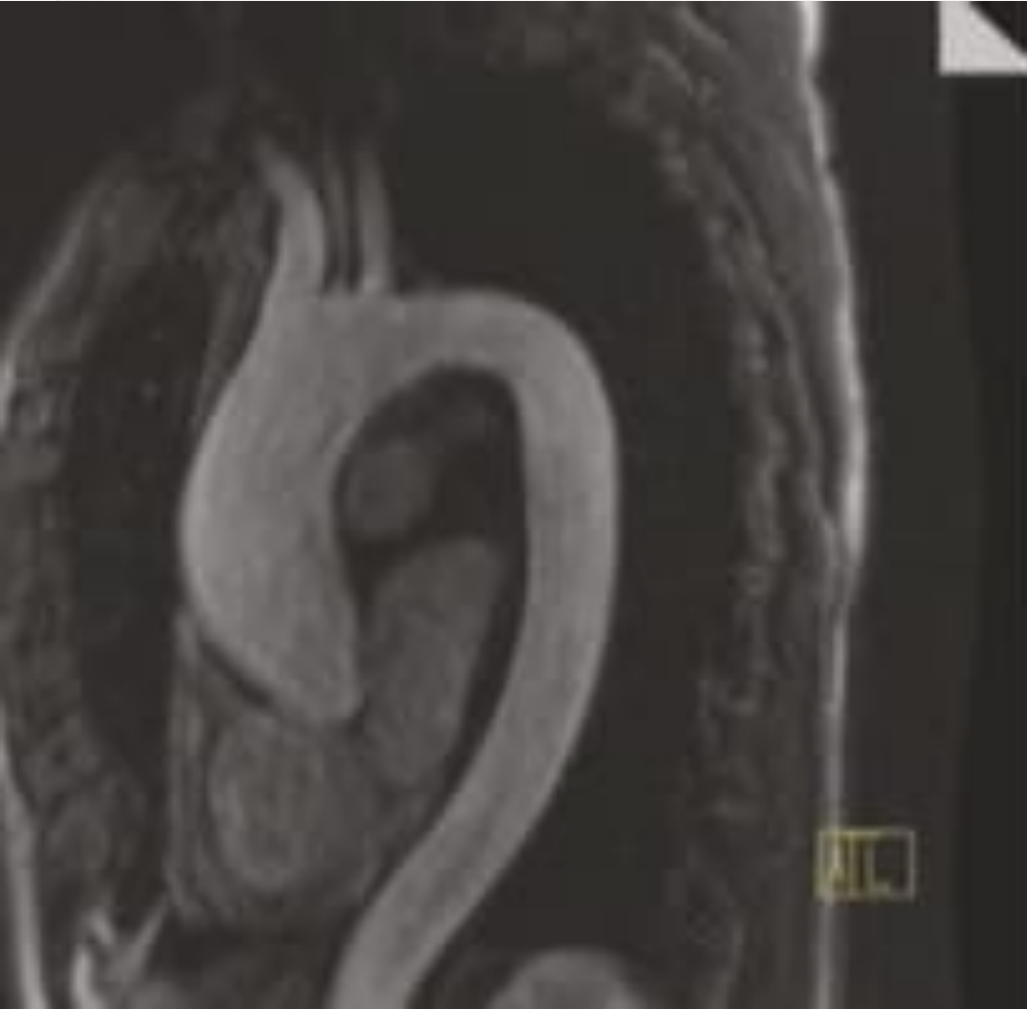

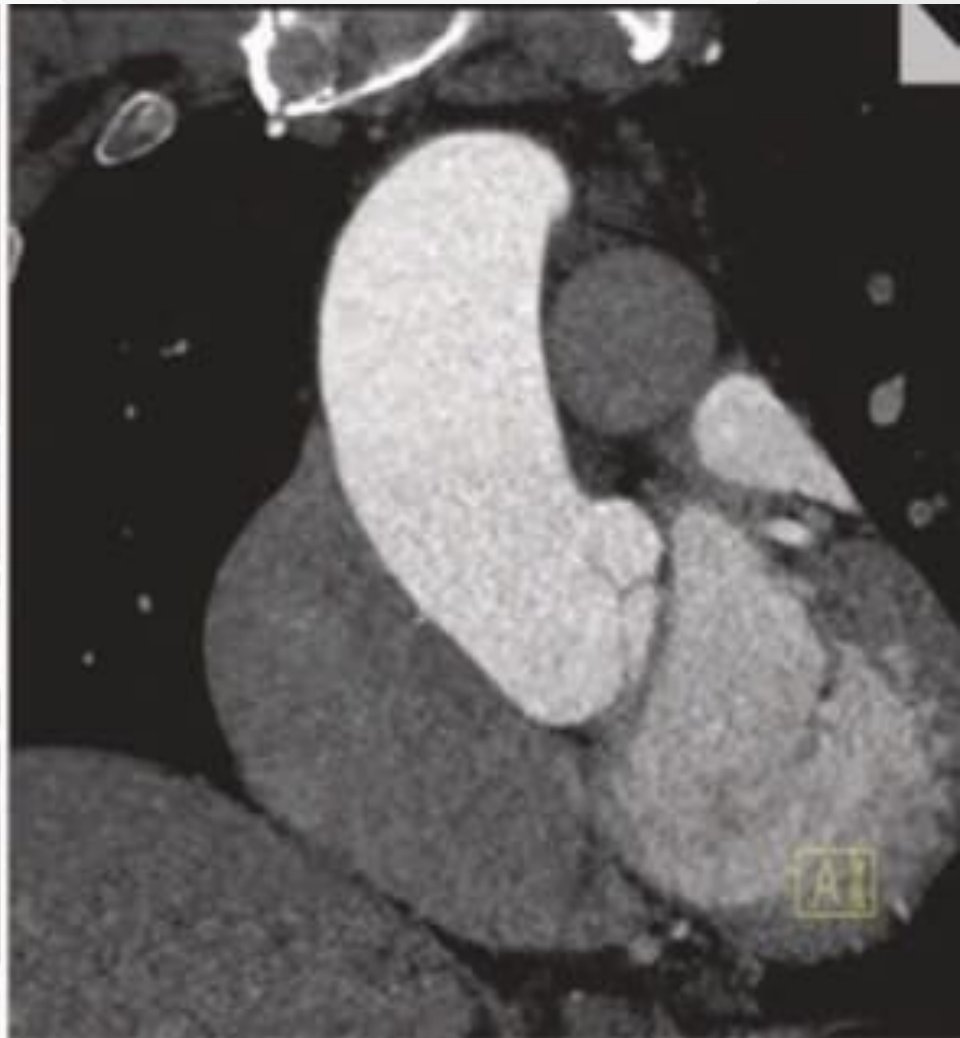
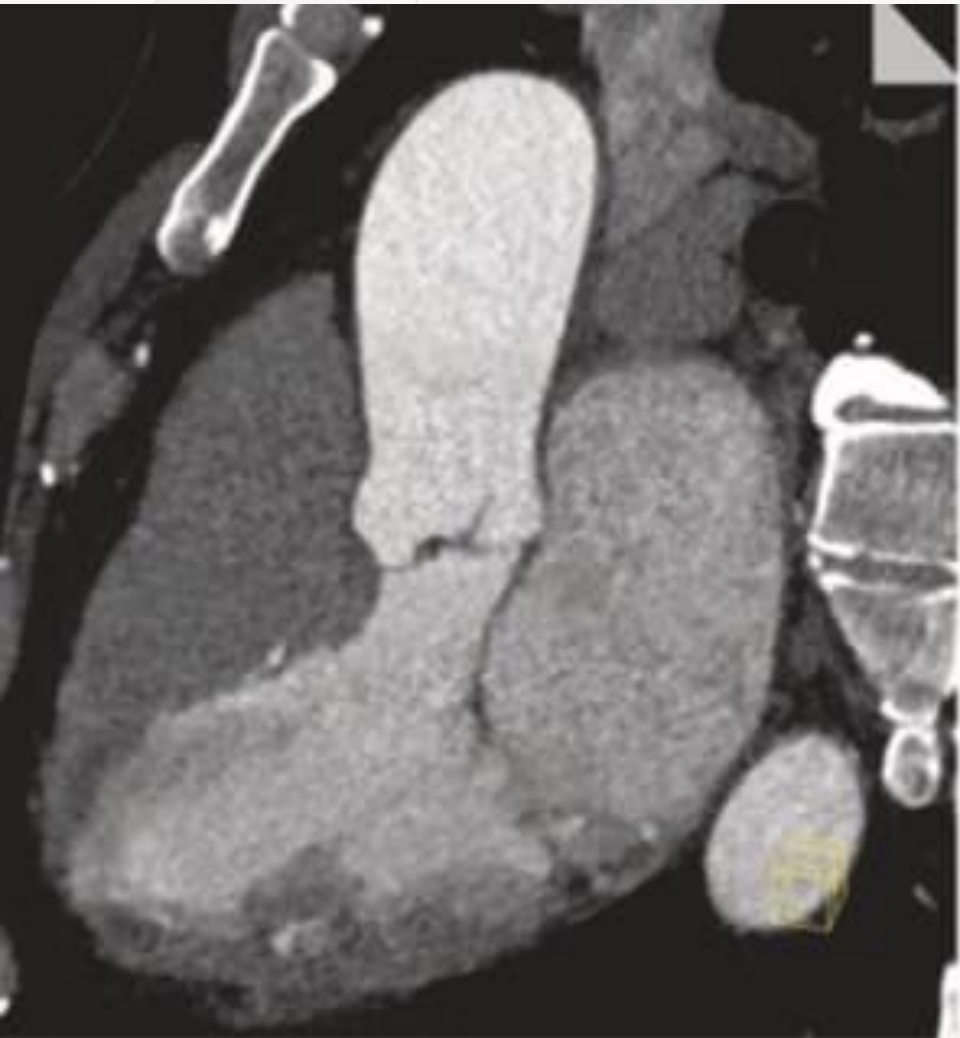Stanger O.H., Pepper J.R., Svensson L.G. Surgical management of aortic pathology, 2019

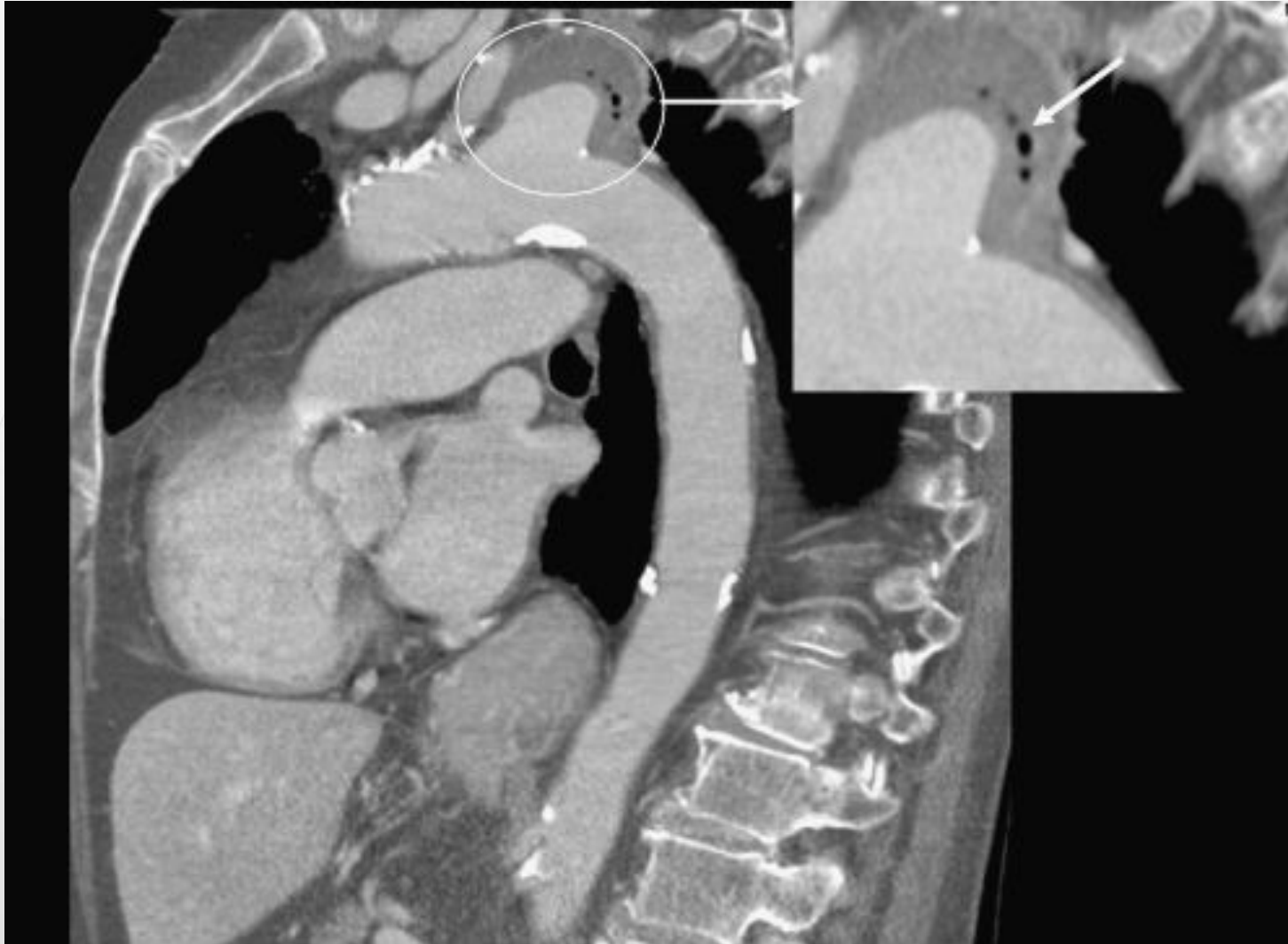

Onohara T., Nakamura Y., Kishimoto Y. Two Cases of Thoracic Aortic Aneurysm with Right Aortic Arch: Comparison of Two Operative Strategies for Hybrid Thoracic Endovascular Repair, 2014

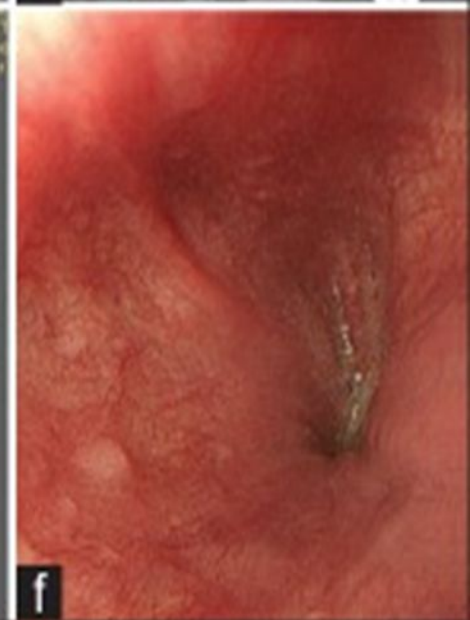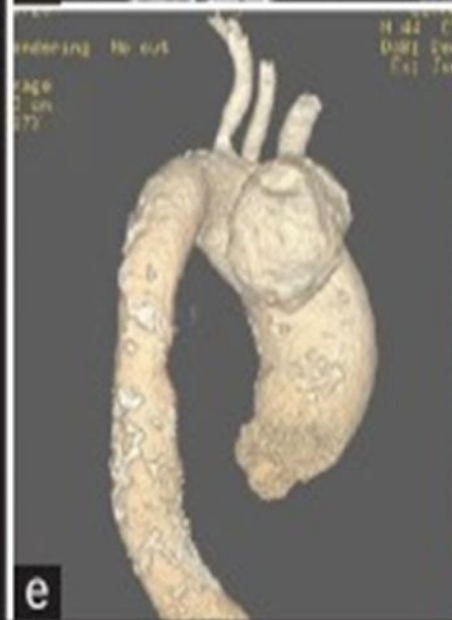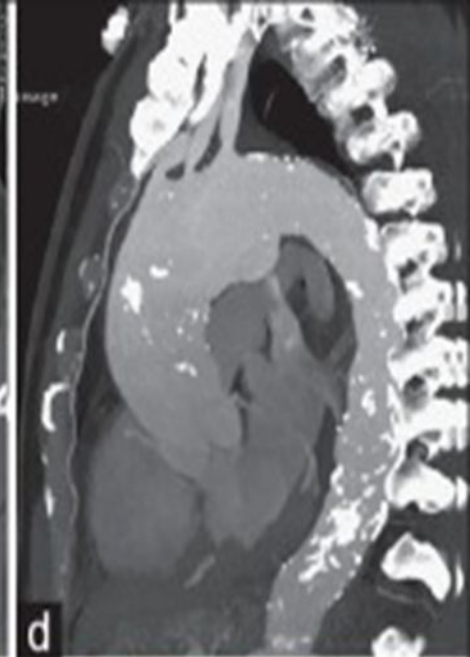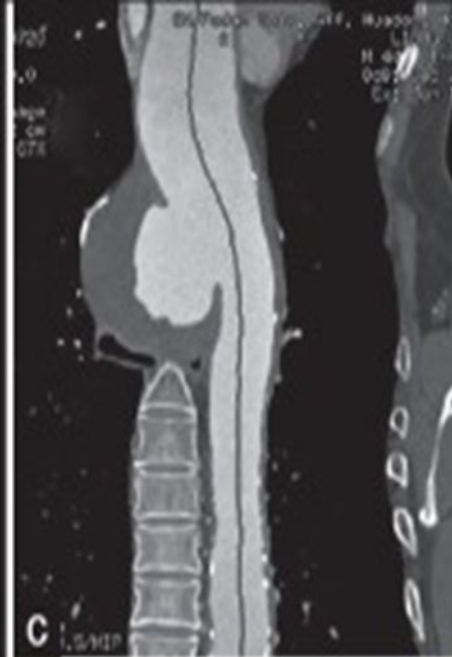
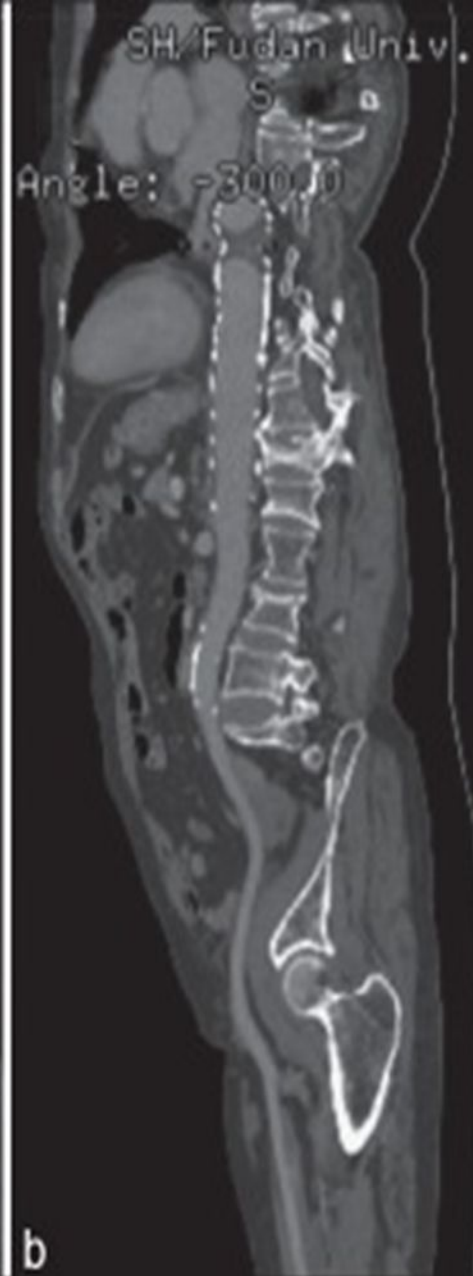
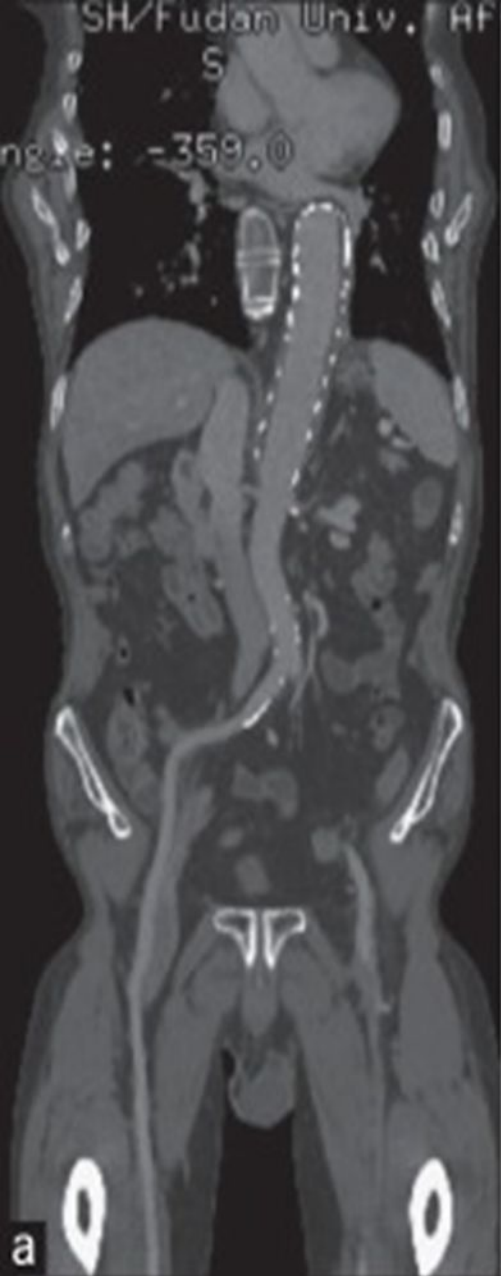
MPT





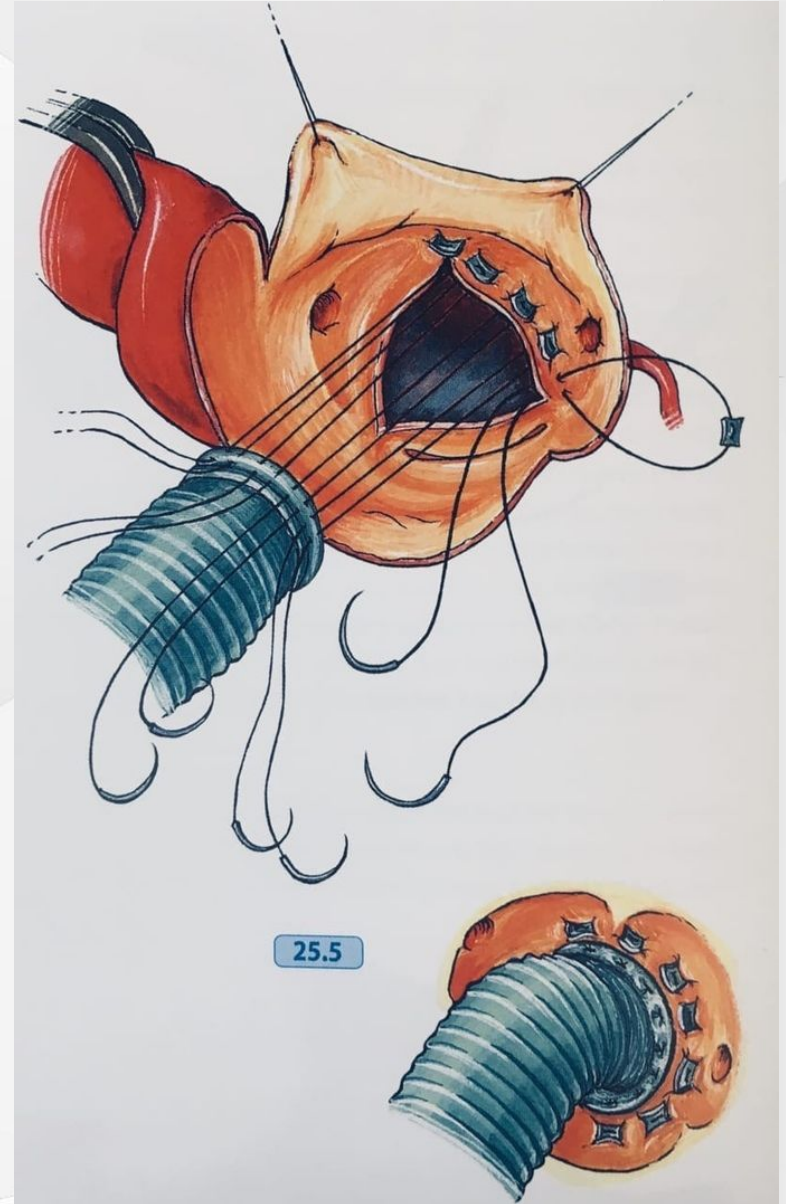
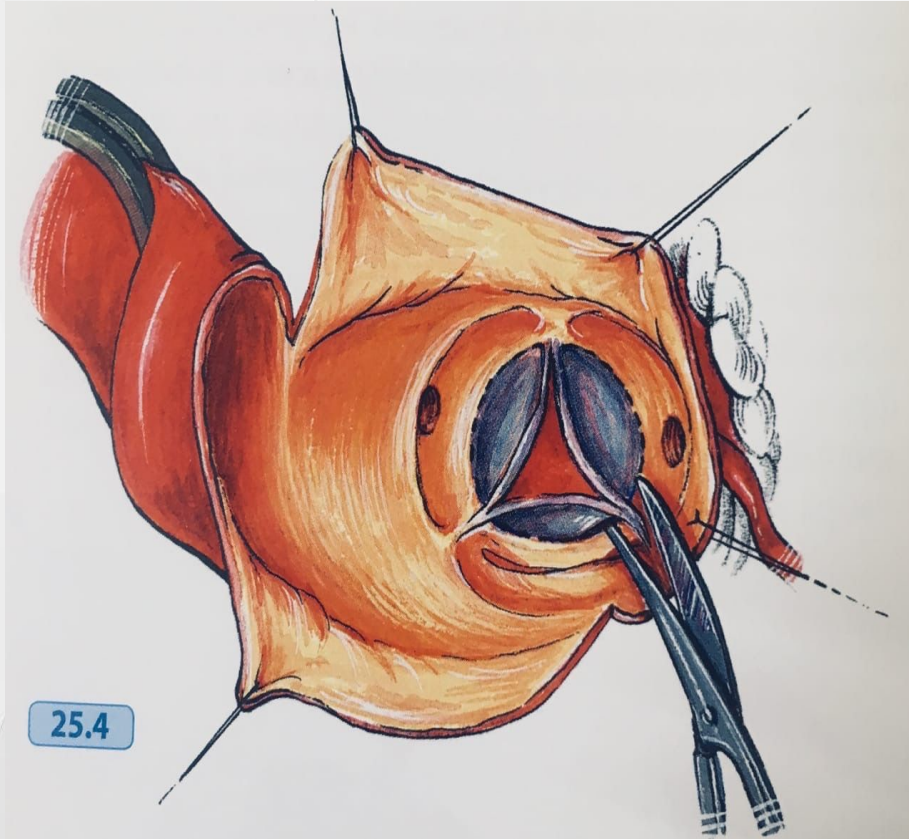


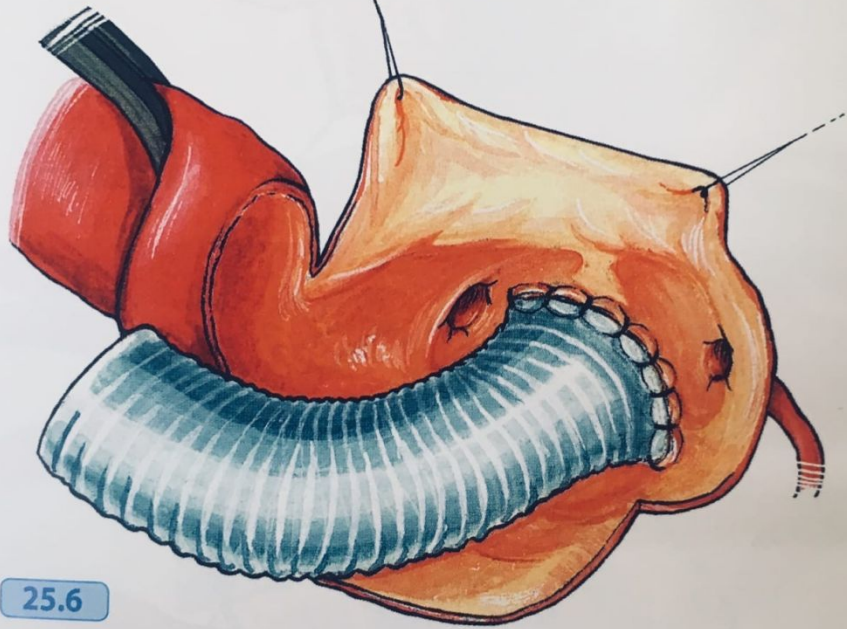
Jaspers M.N., Jr., van Wijngaarden J.J. Mycotic aneurysm of the aortic arch, 2011



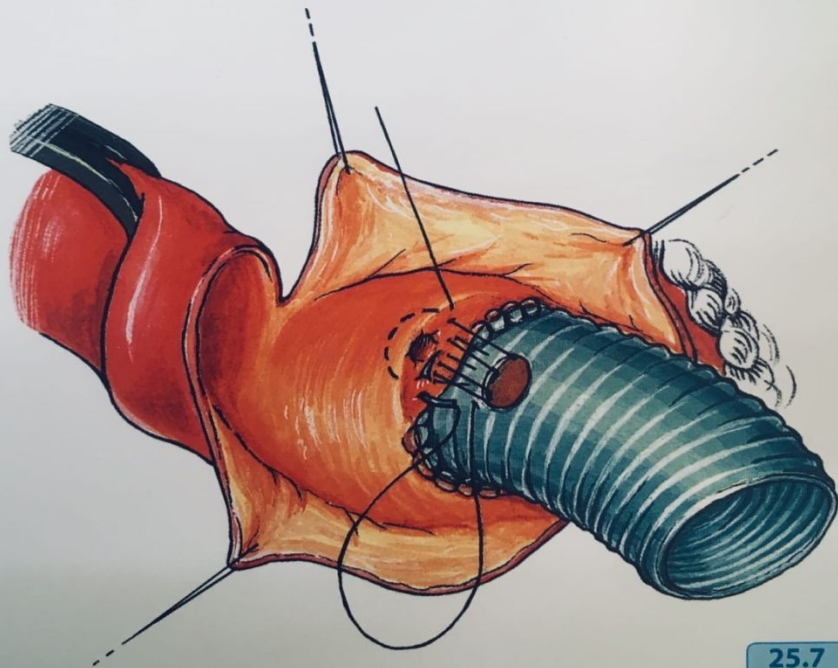
Surgical Intervention for Behcet's Disease with Aorta Aneurysm and Pseudoaneurysm: Opposite Outcomes in Two Cases. Yong Chen, Jia-Shen Cui, Jian-Fei Cai, Jun Zou, 2012.

Операция Bentall

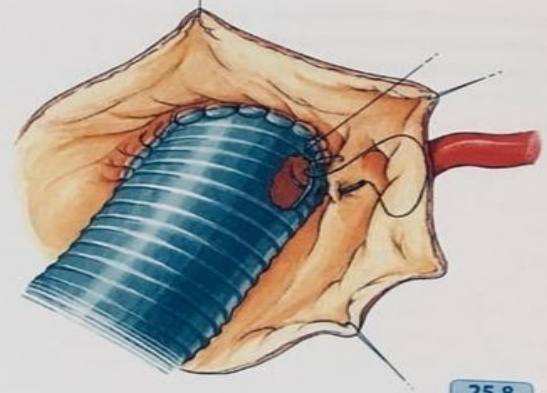




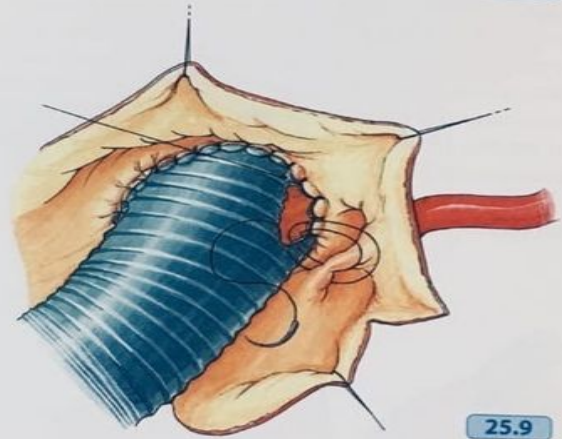
25.6



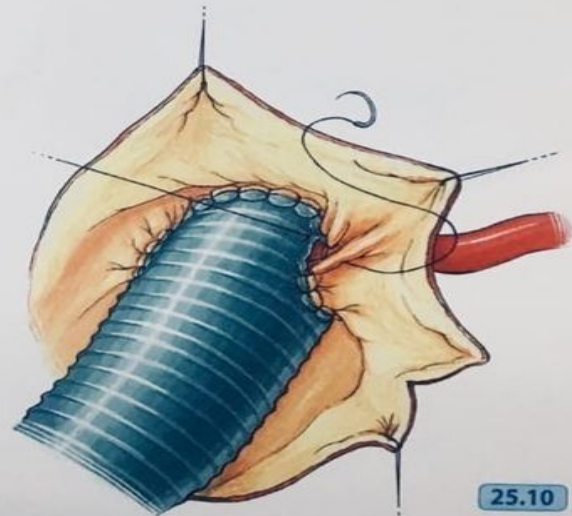
25.7



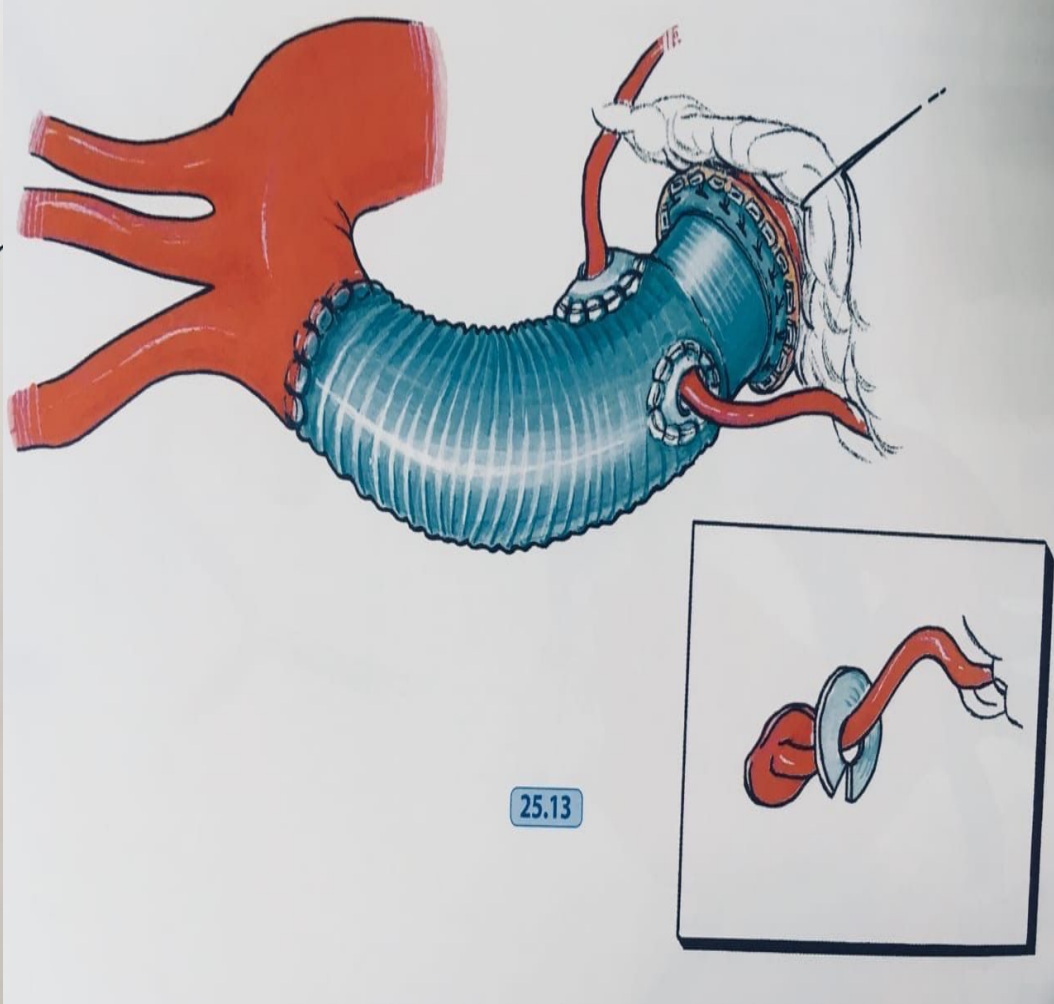
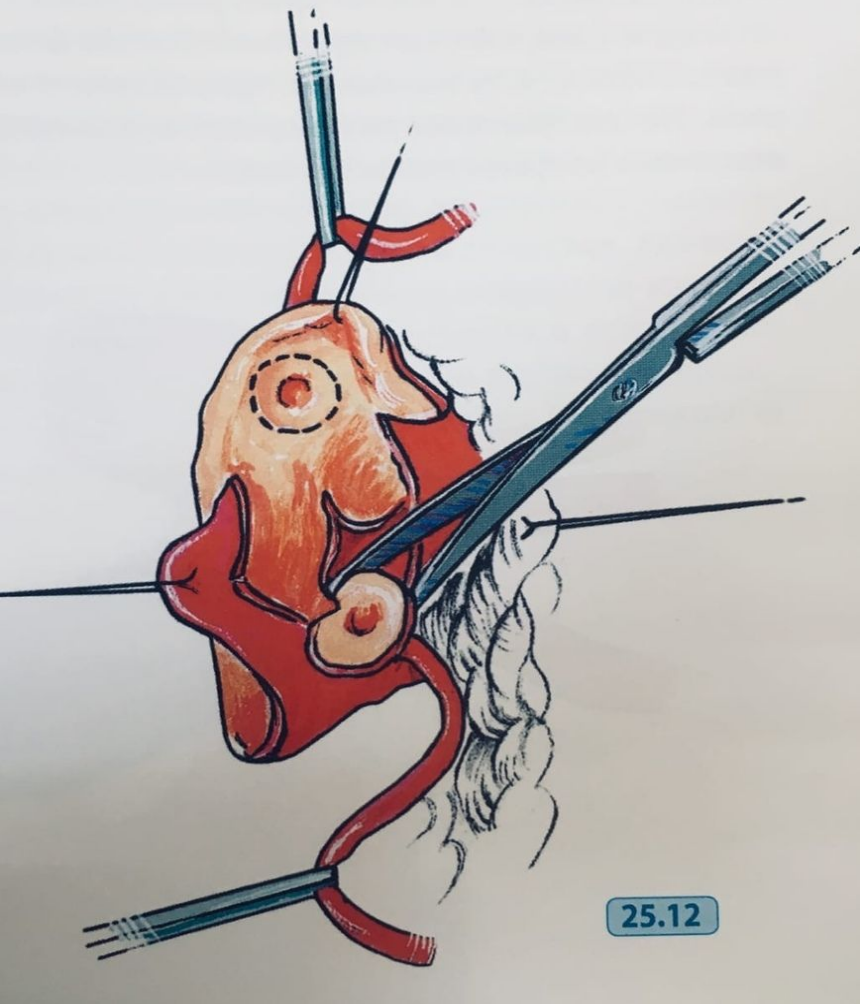25.8



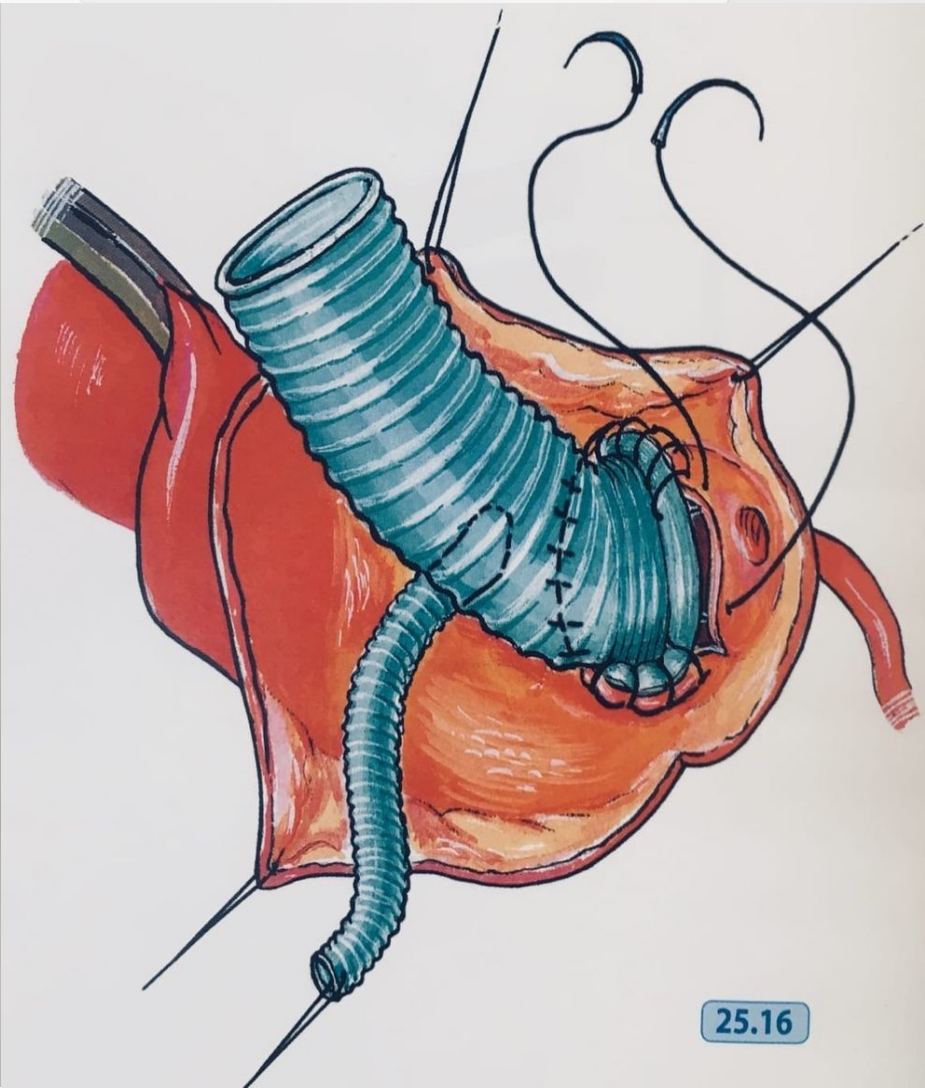
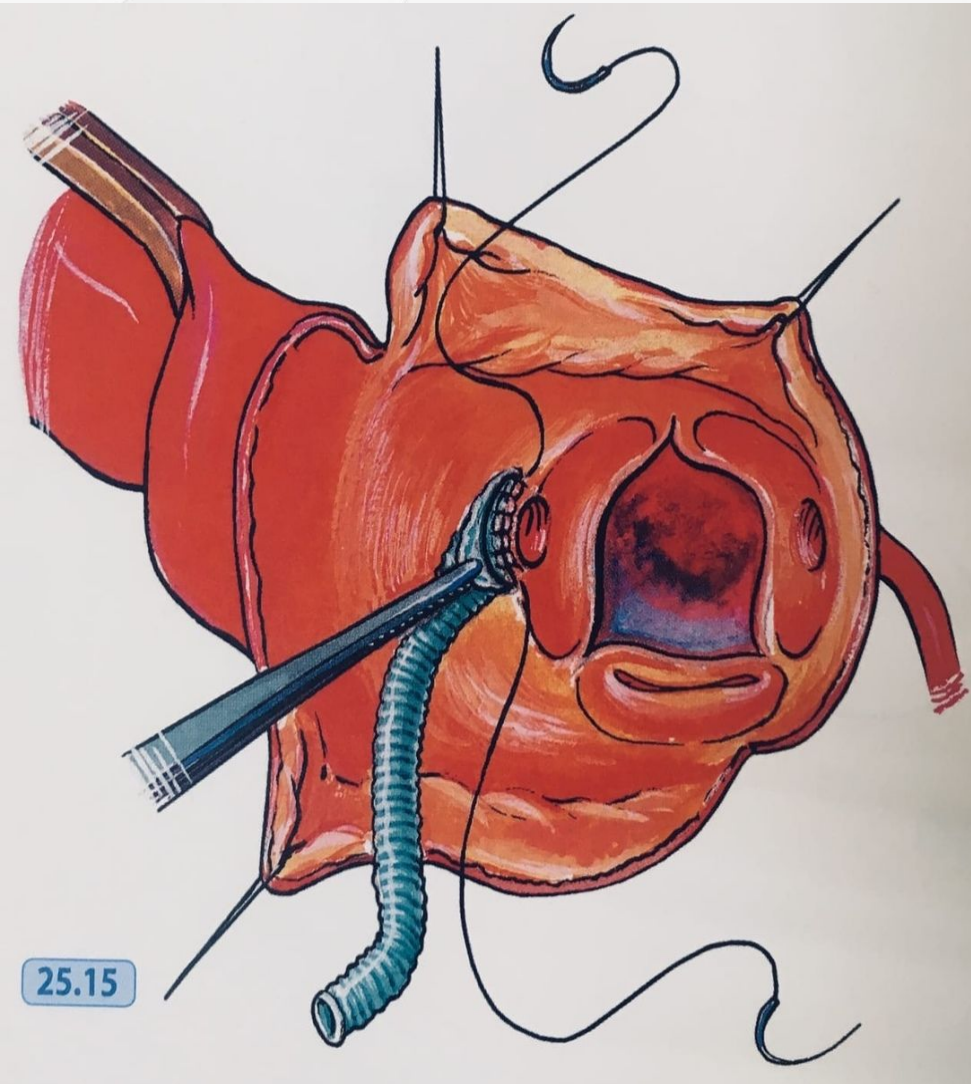
25.9

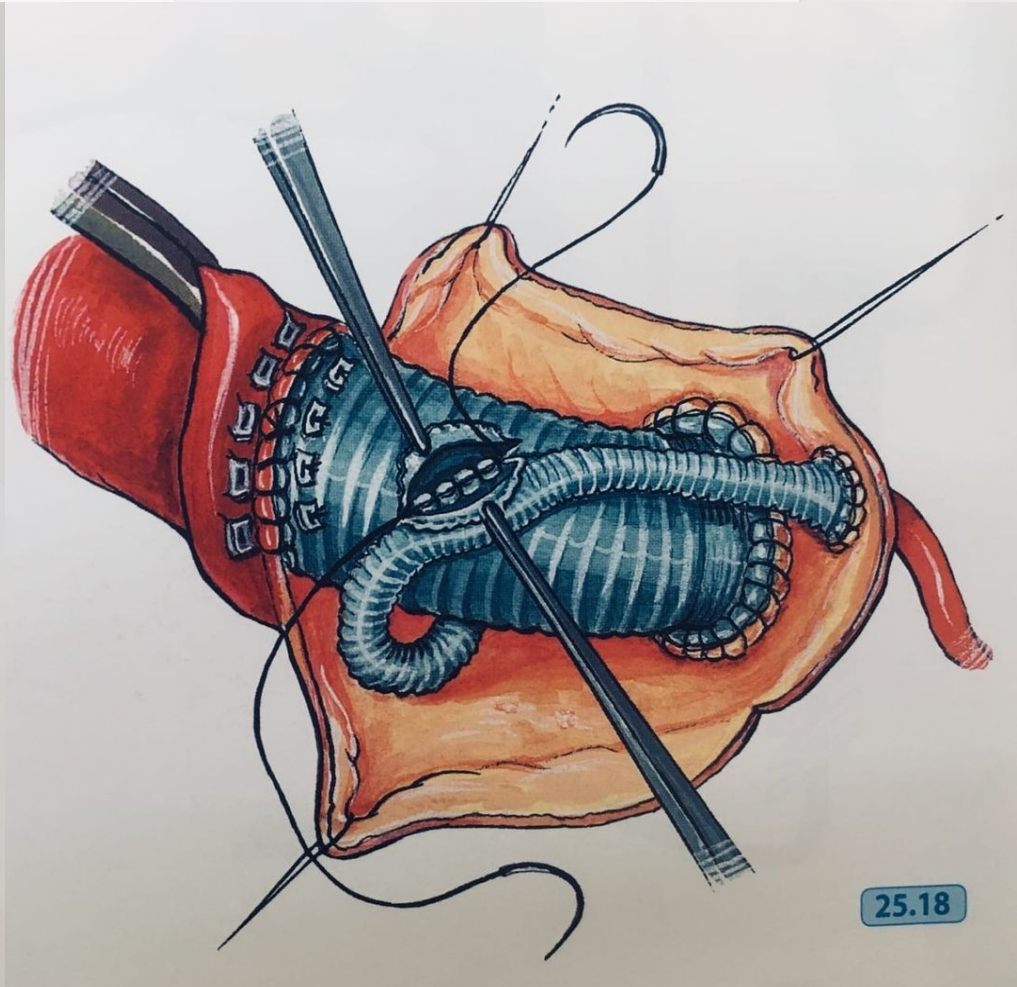
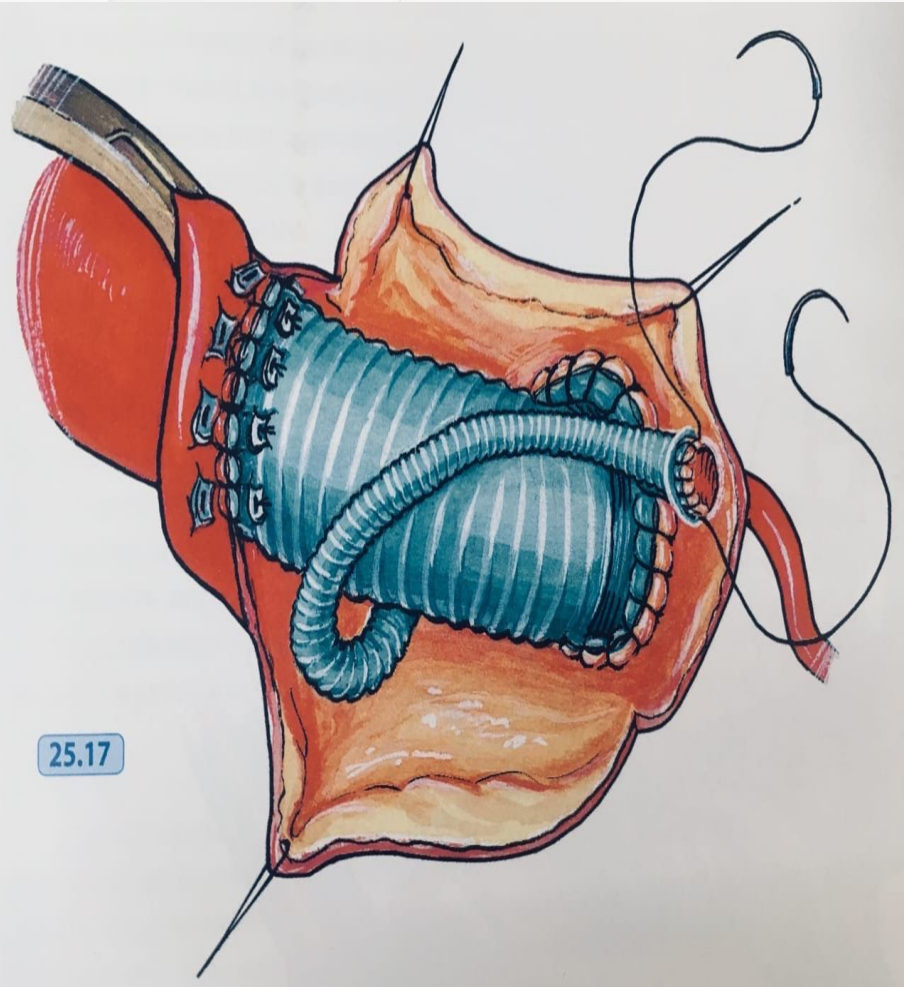


25.10

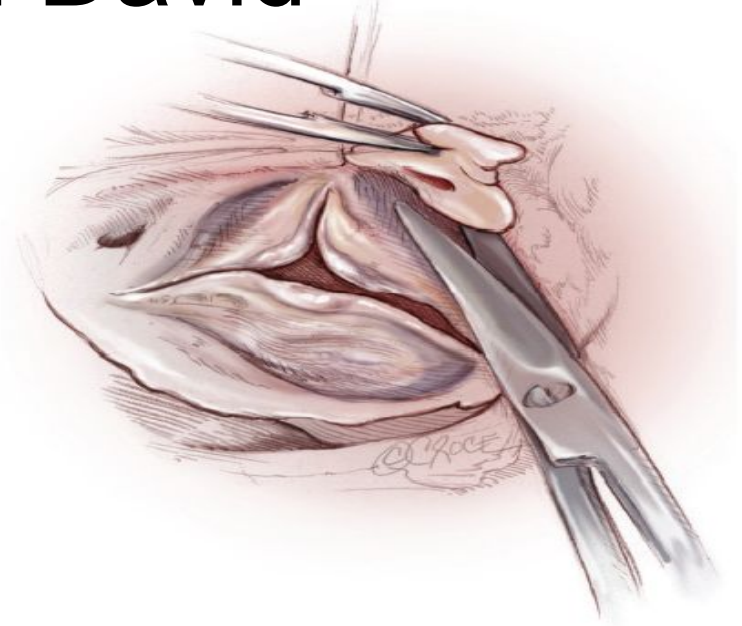
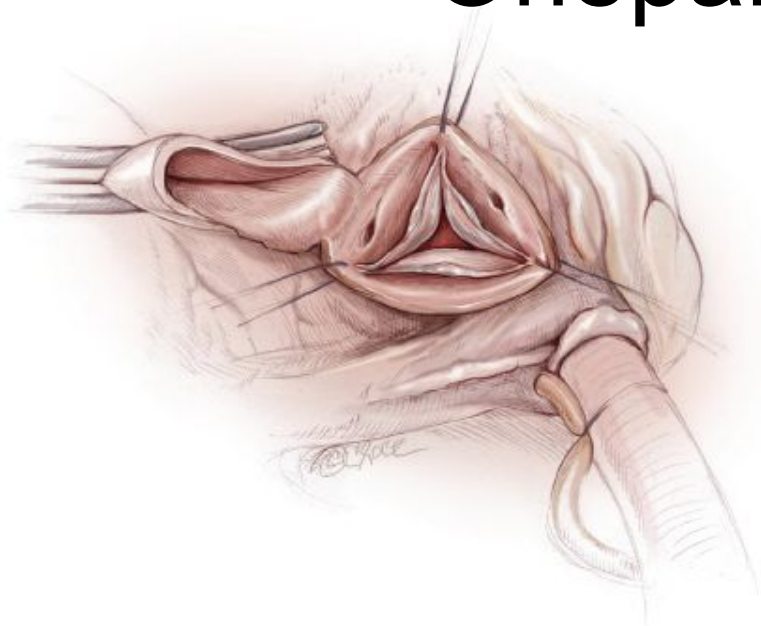


Операция Cabrol

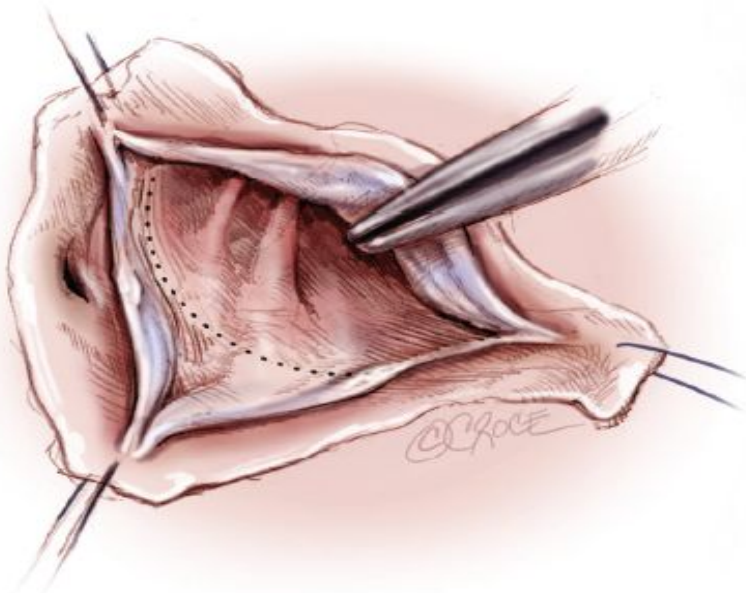




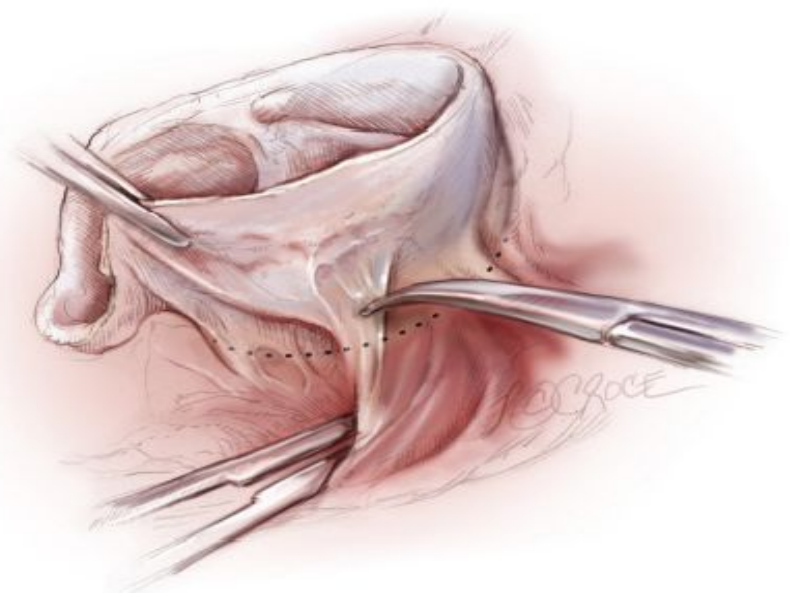
Операция David



A

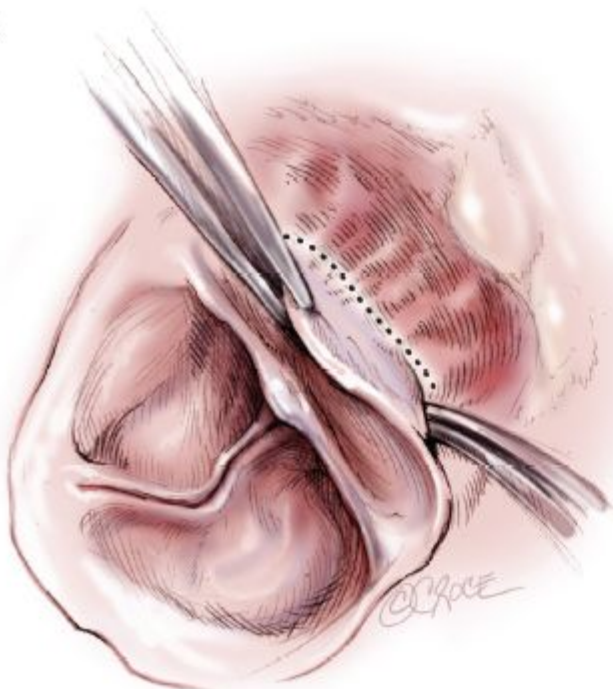


B

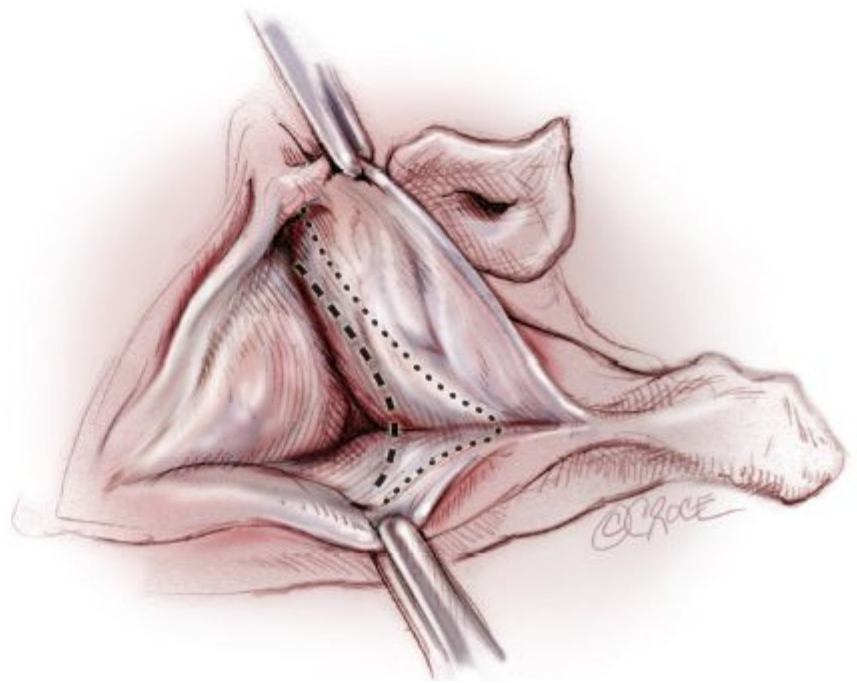


Kerchov L., Nezhad Z., Boodhwani M. How to perform valve sparing reimplantation in a tricuspid aortic valve, 2013

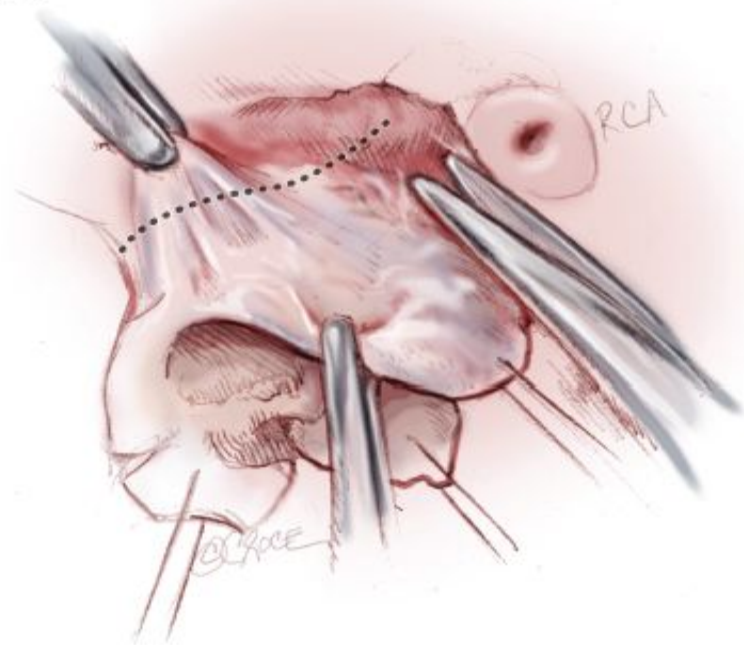
A



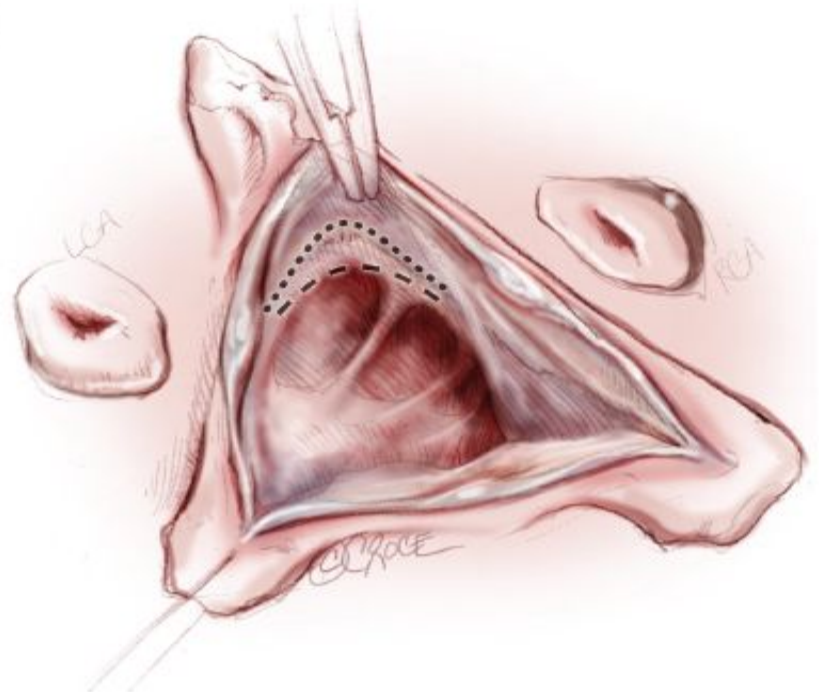
B

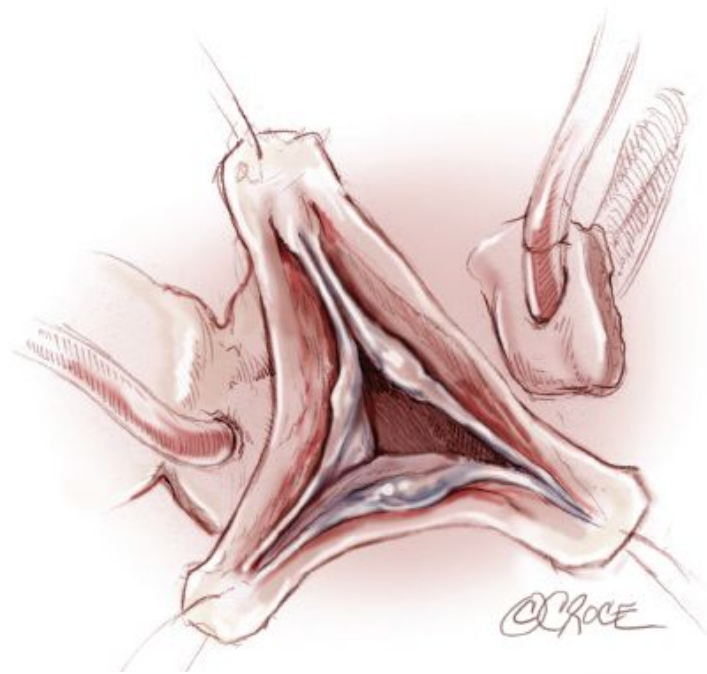


A

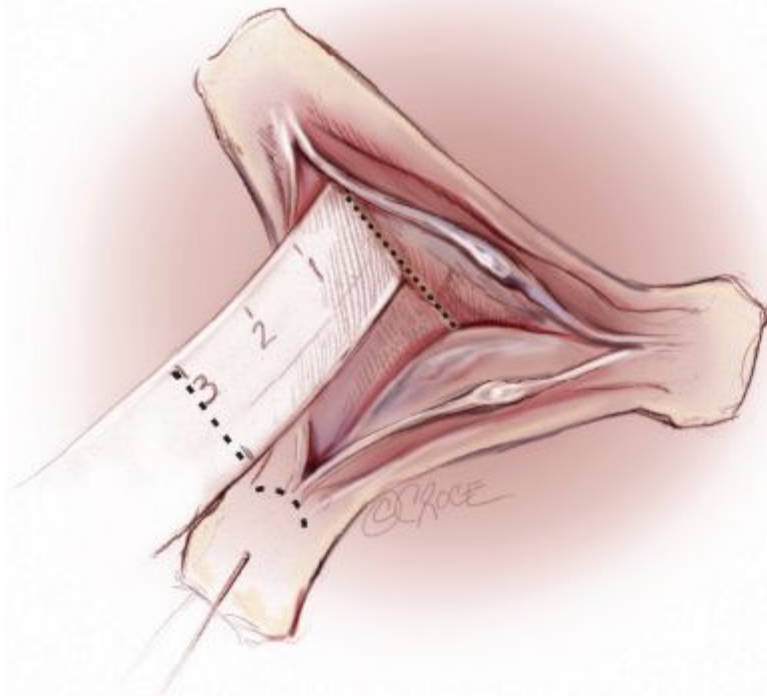


B

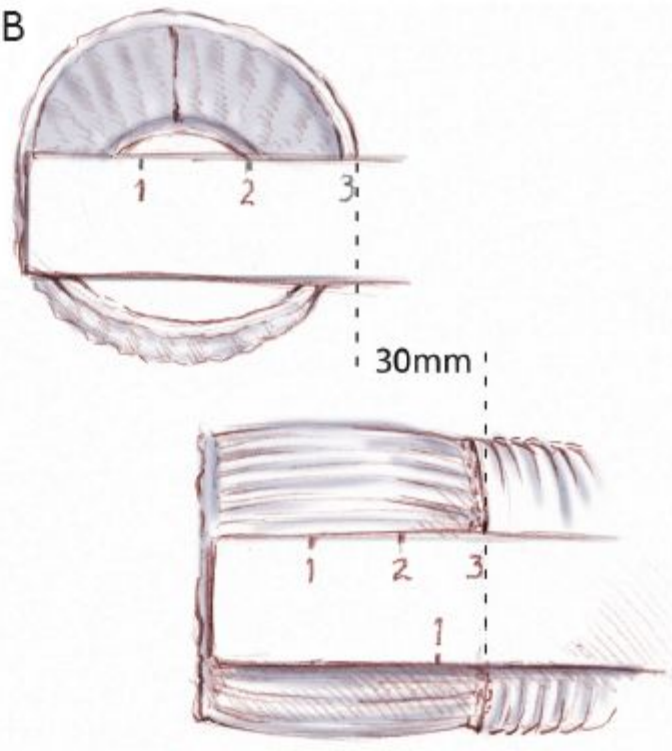


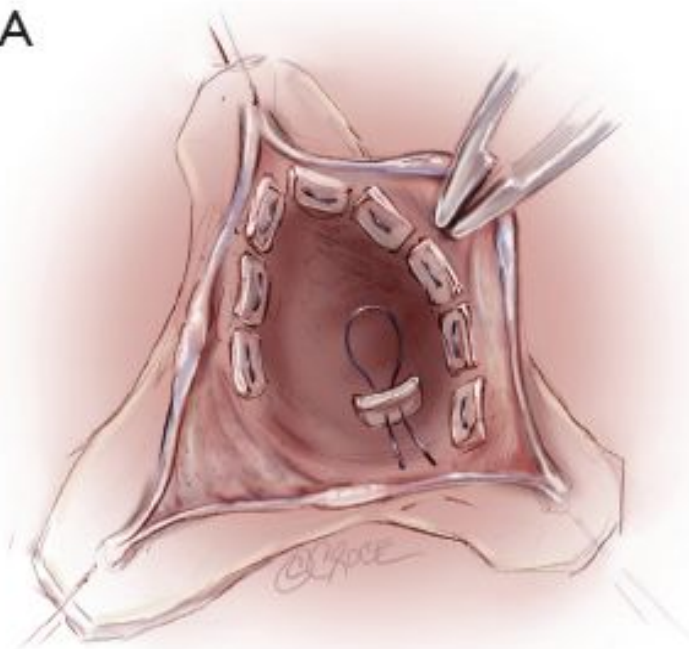
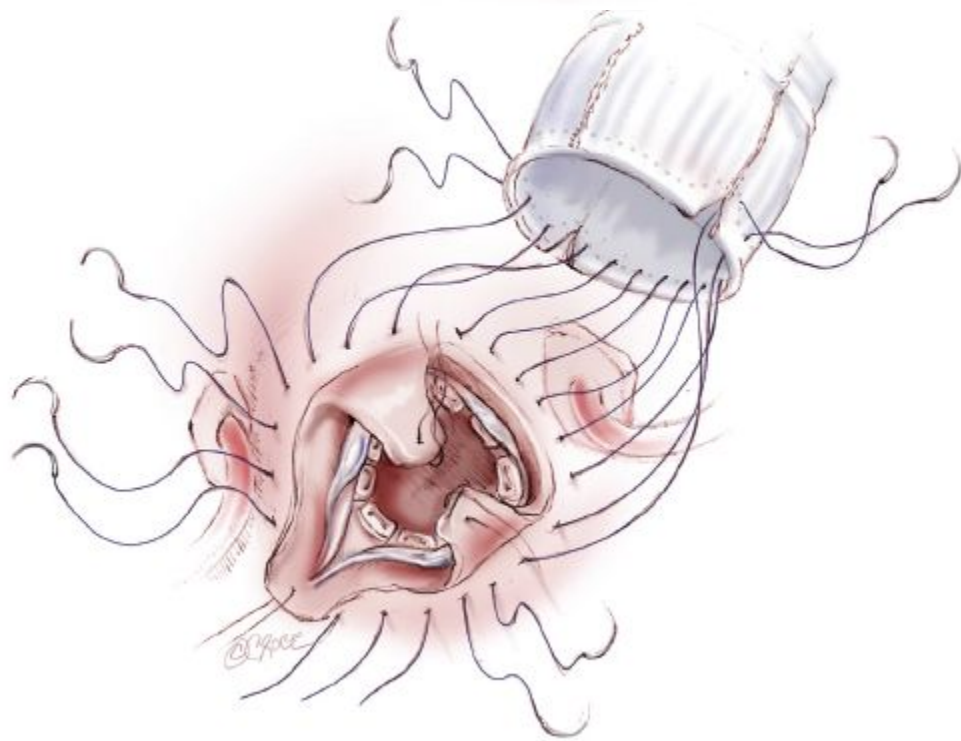
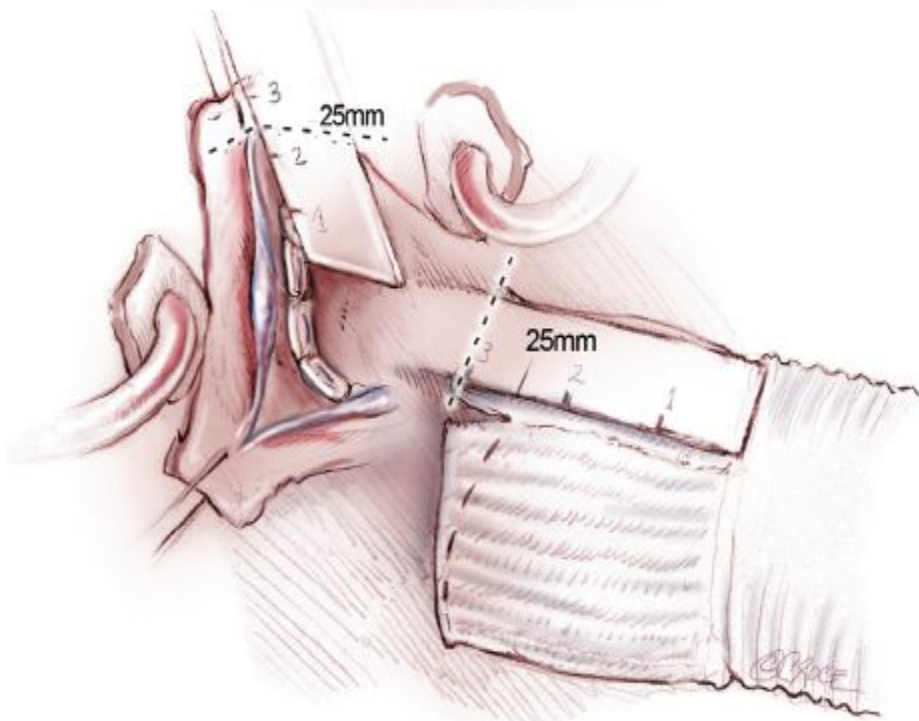
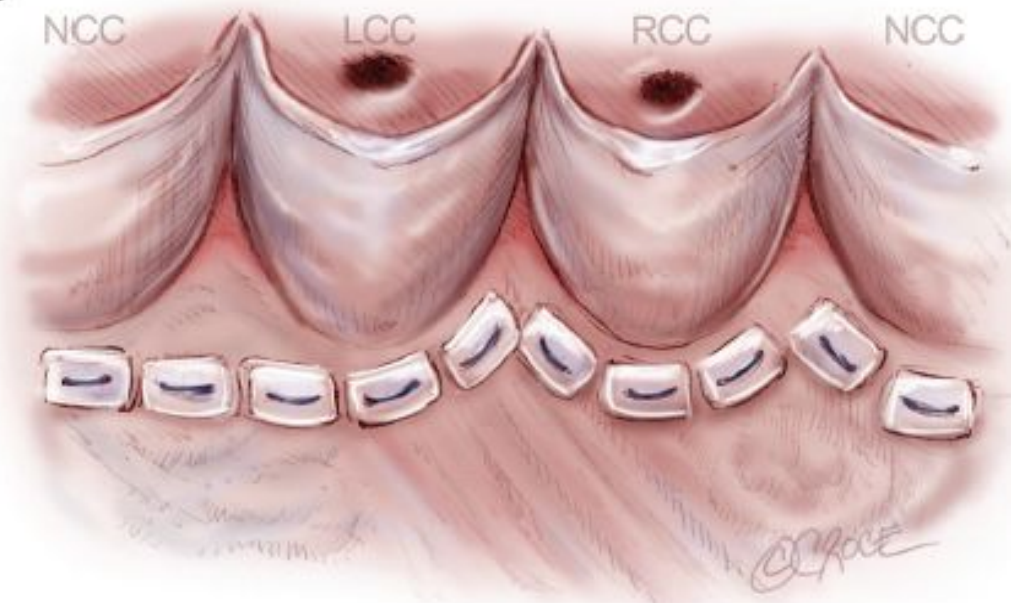

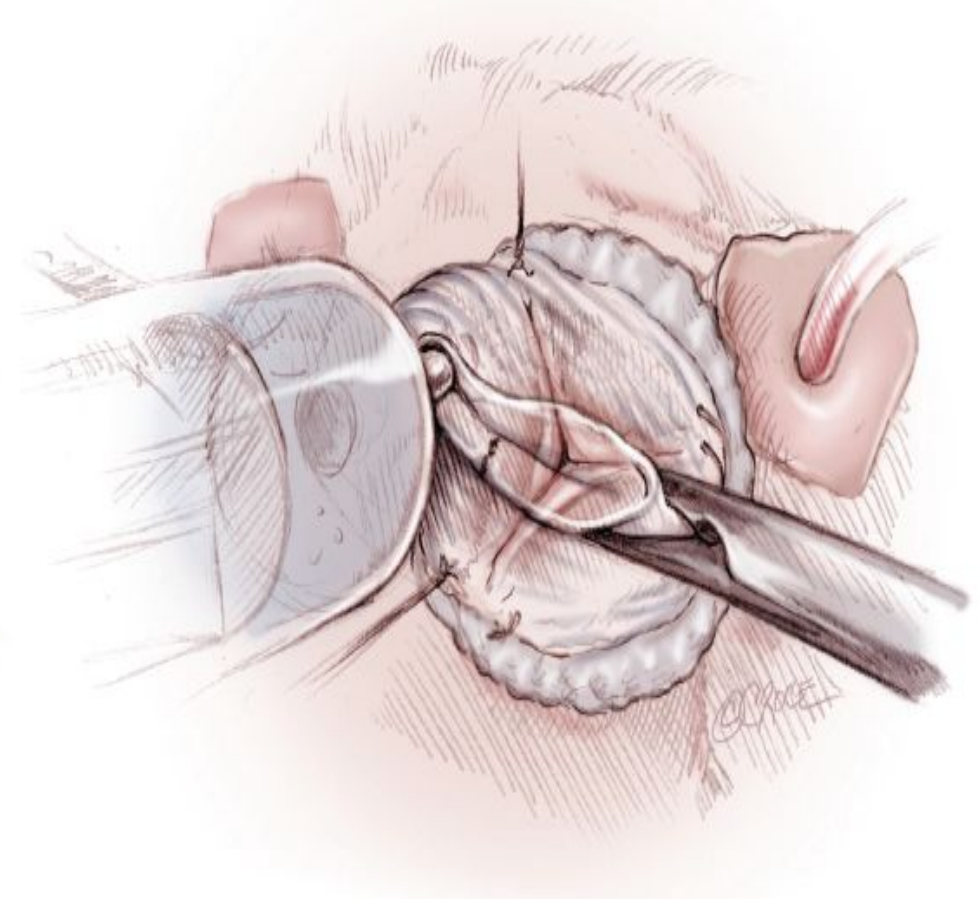
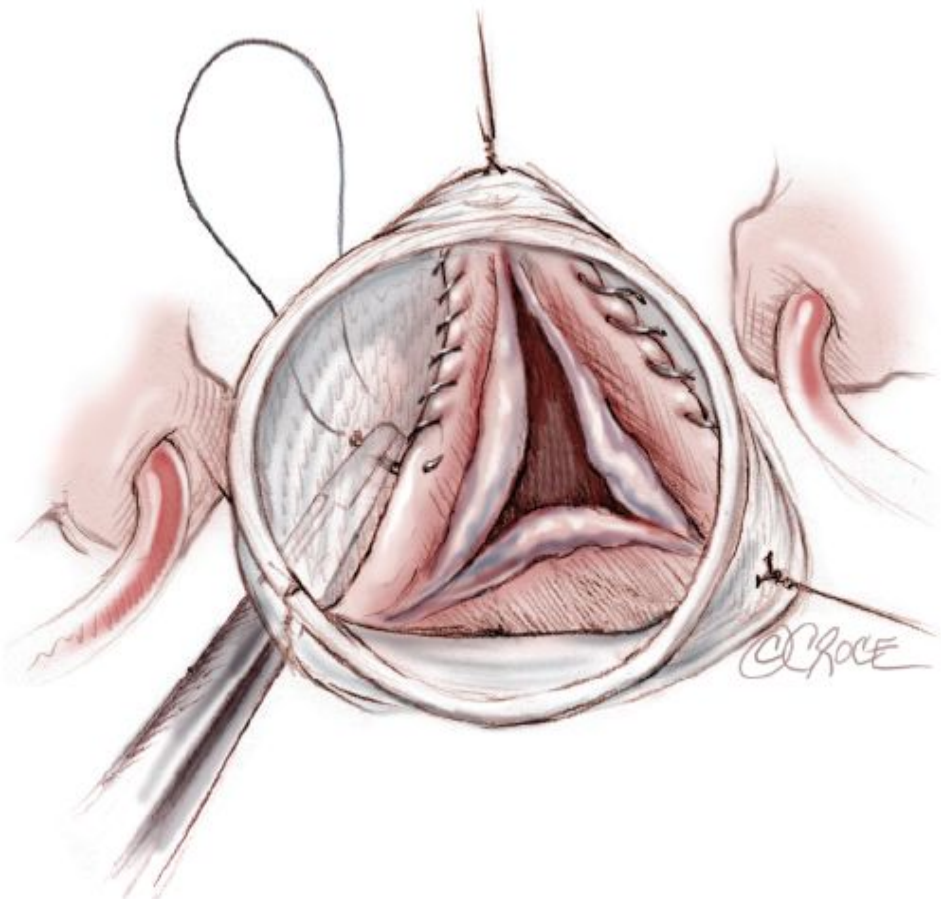
A



B

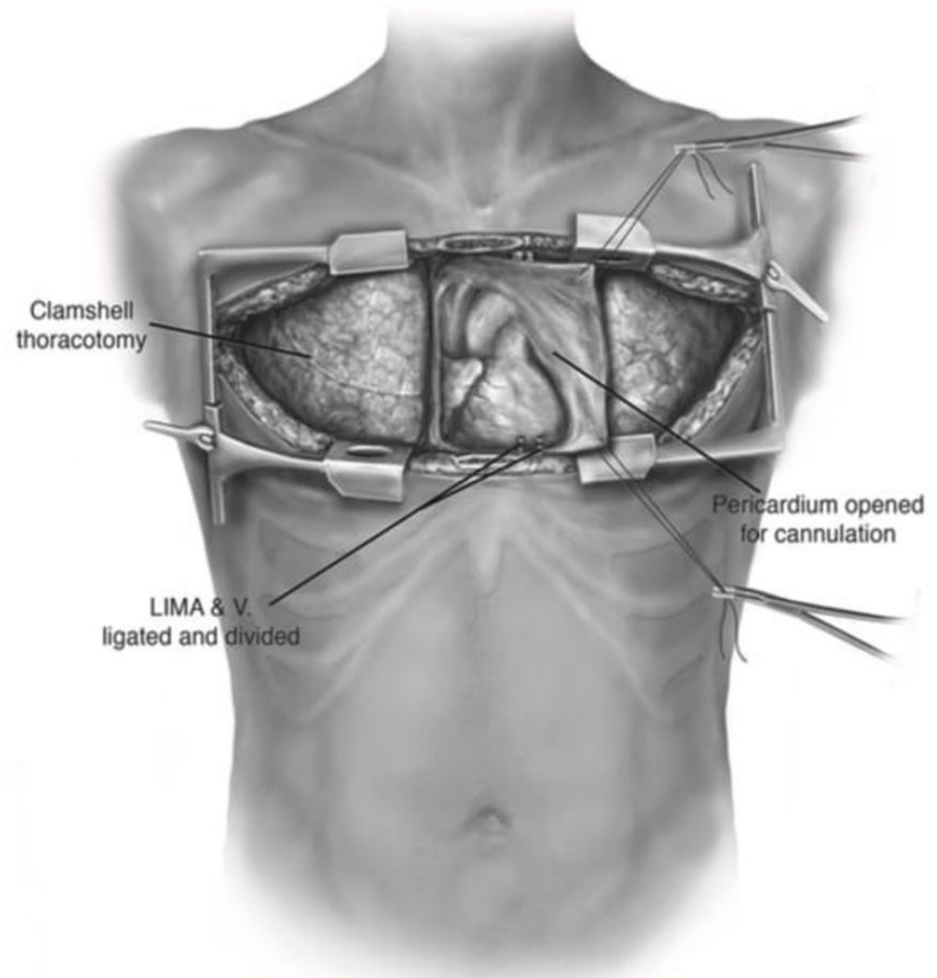
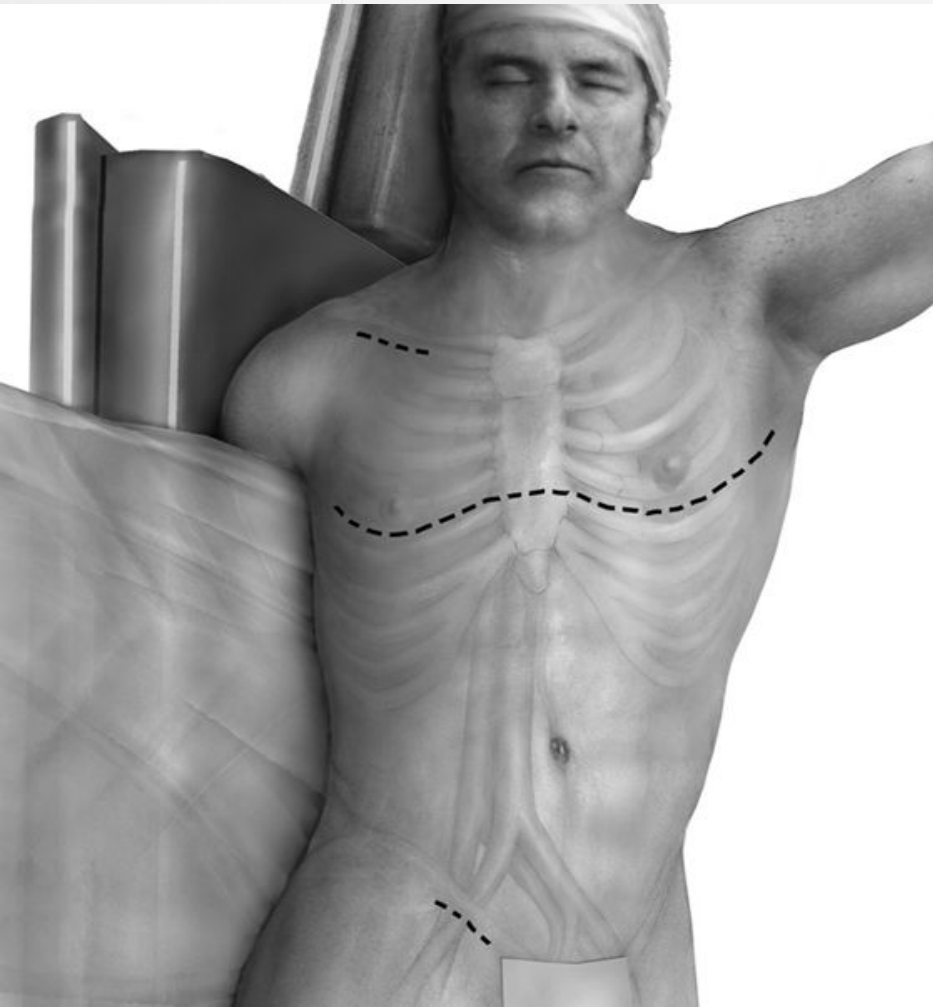

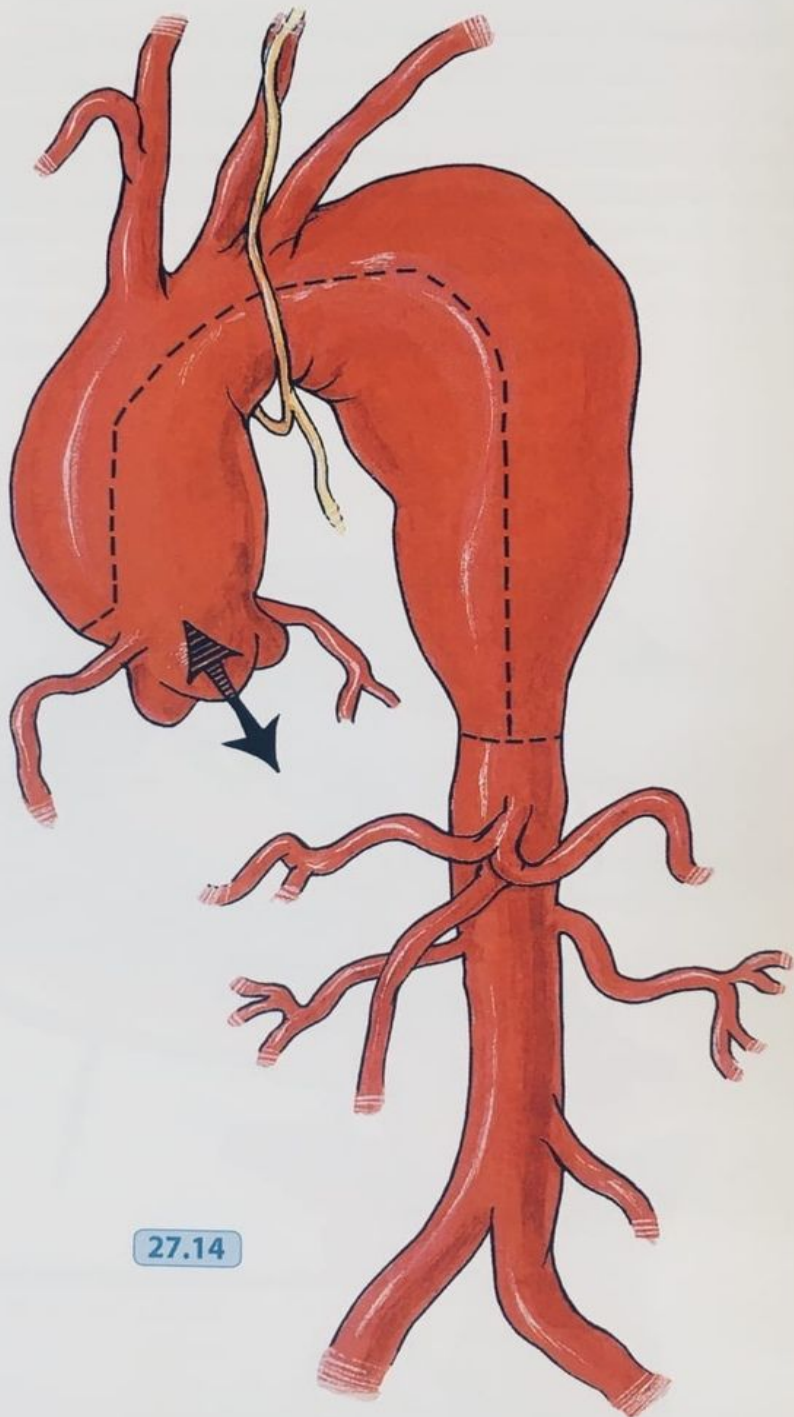
A**B**



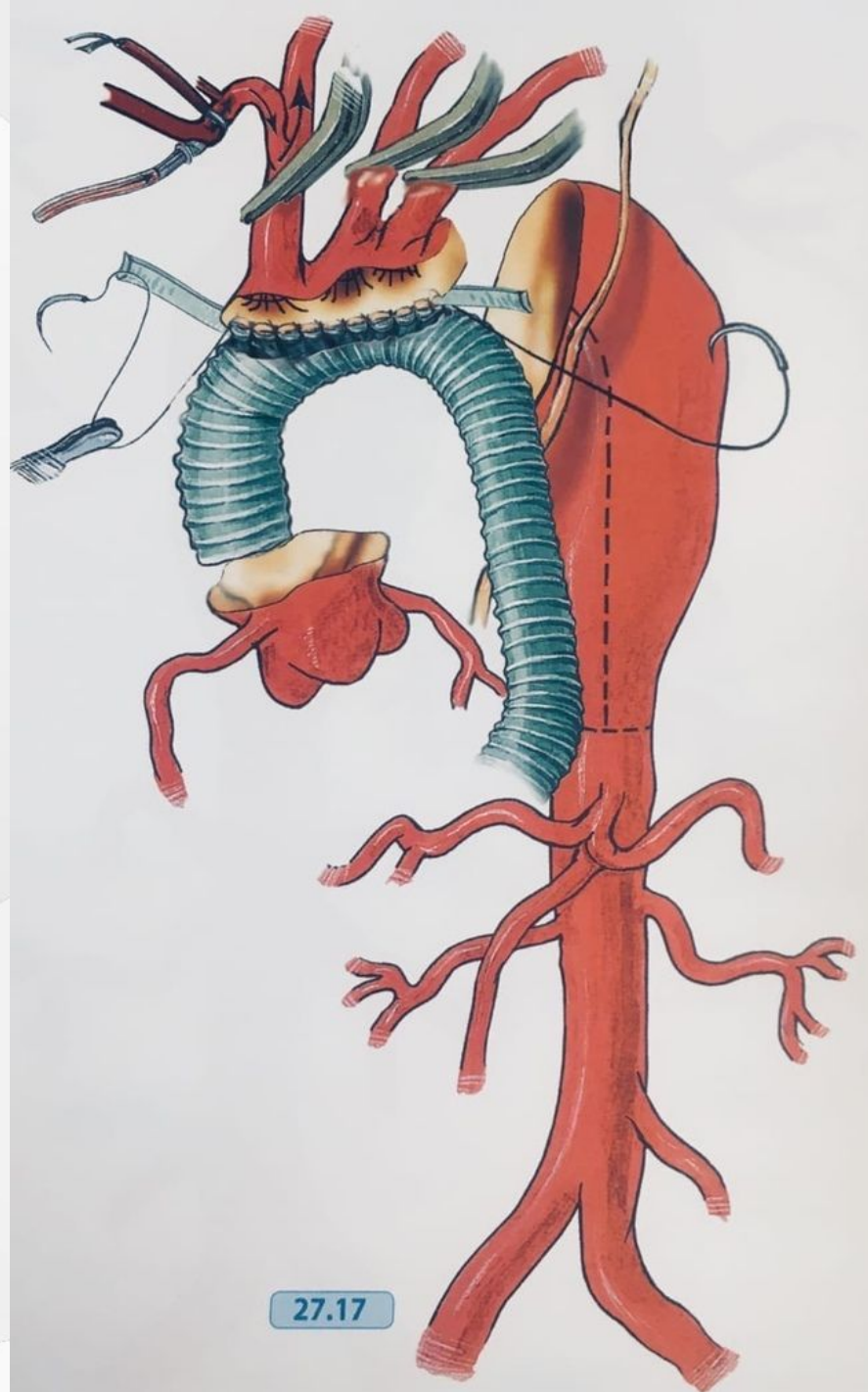
Операция Kouchoukos

Двусторонняя торакотомия с поперечной стернотомией
(clamshell)

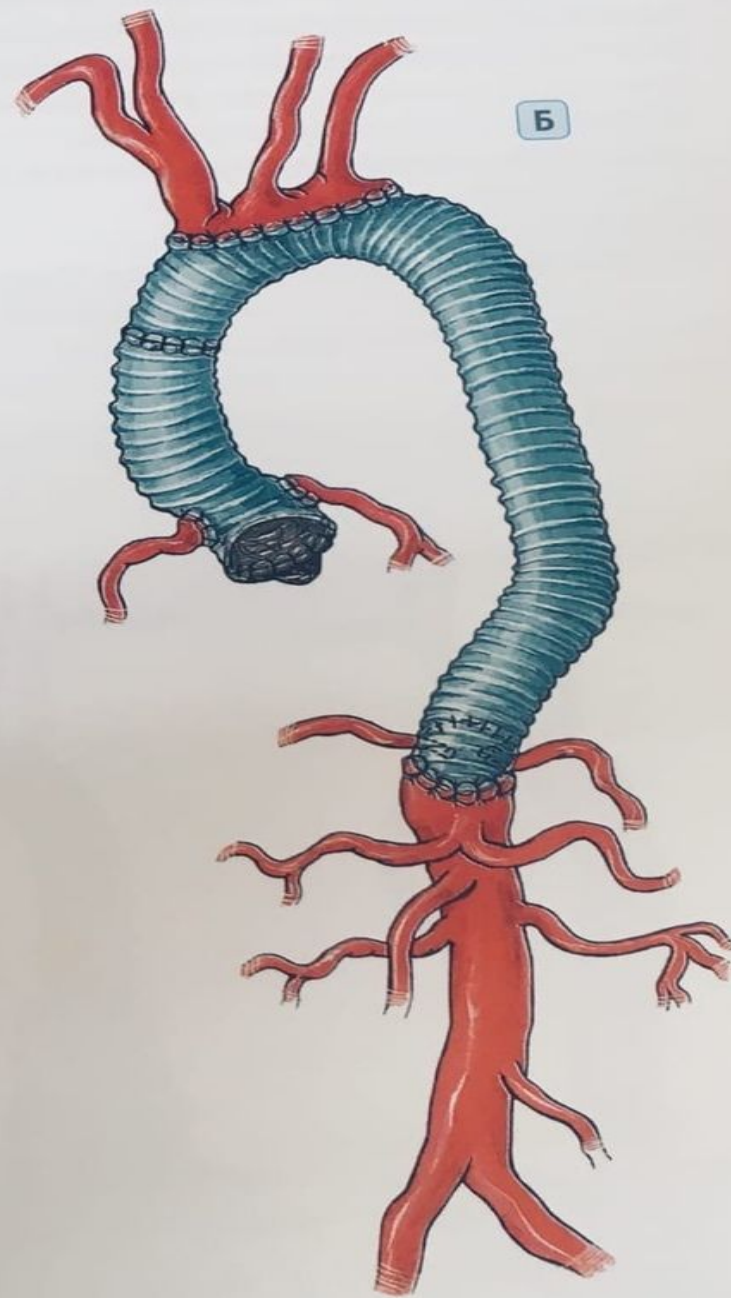
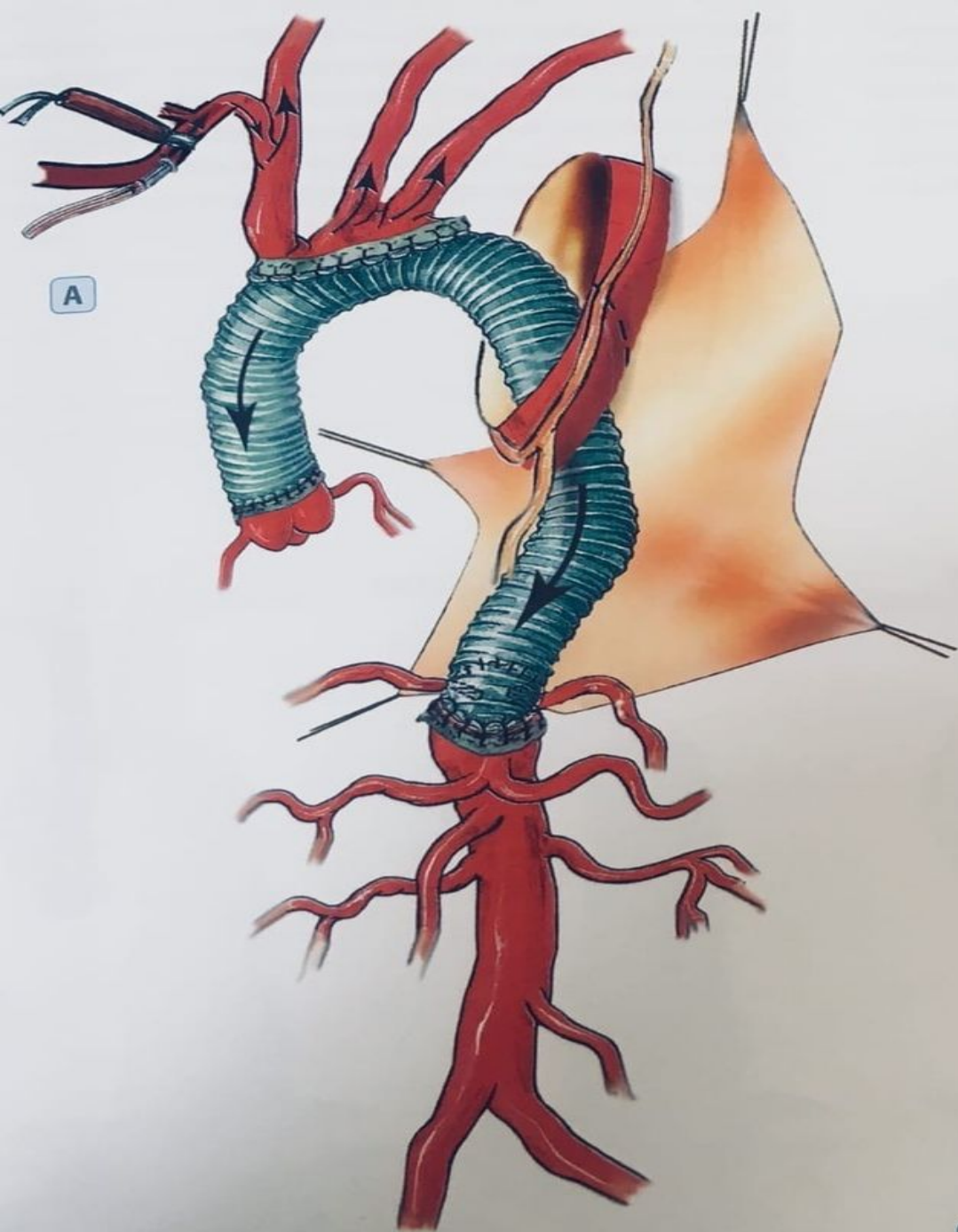




27.14

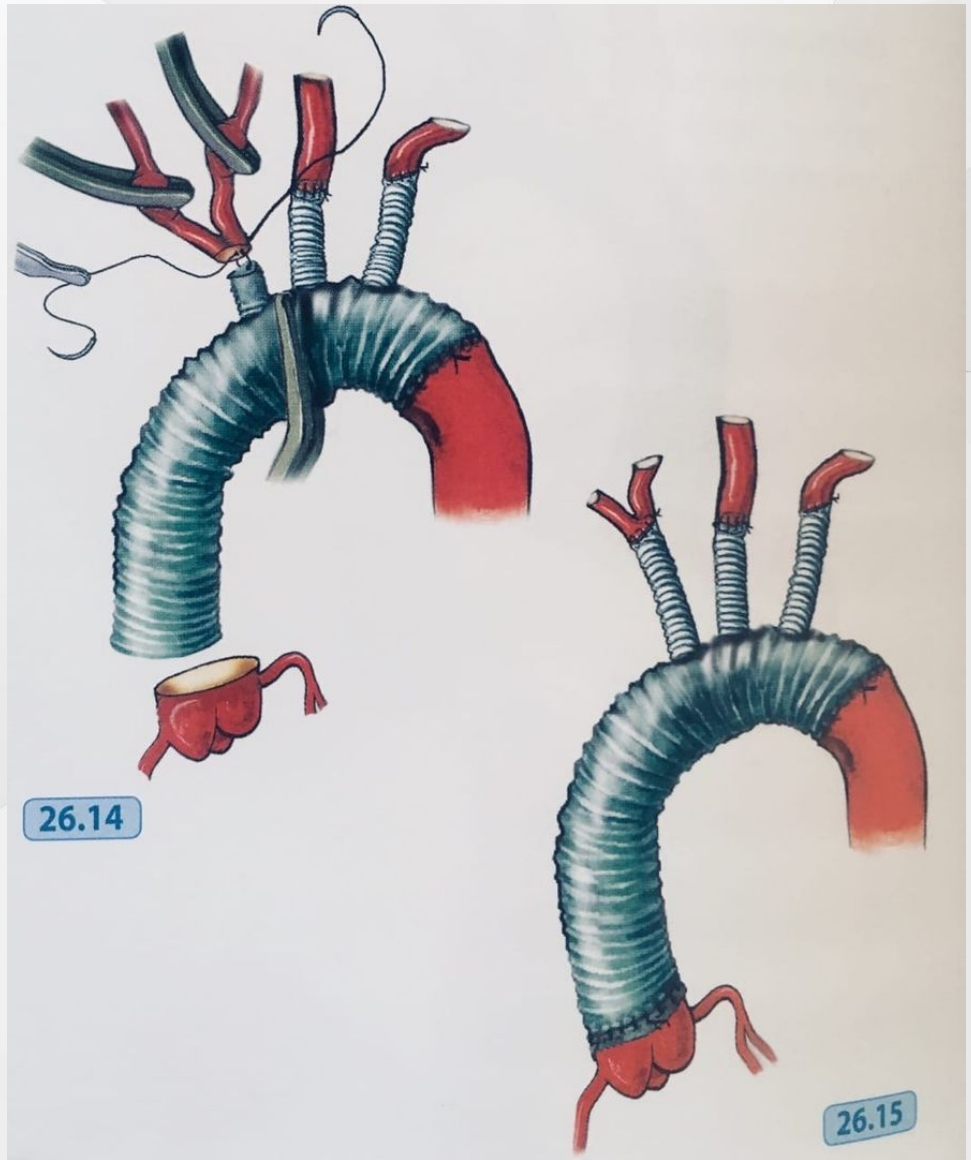


27.17





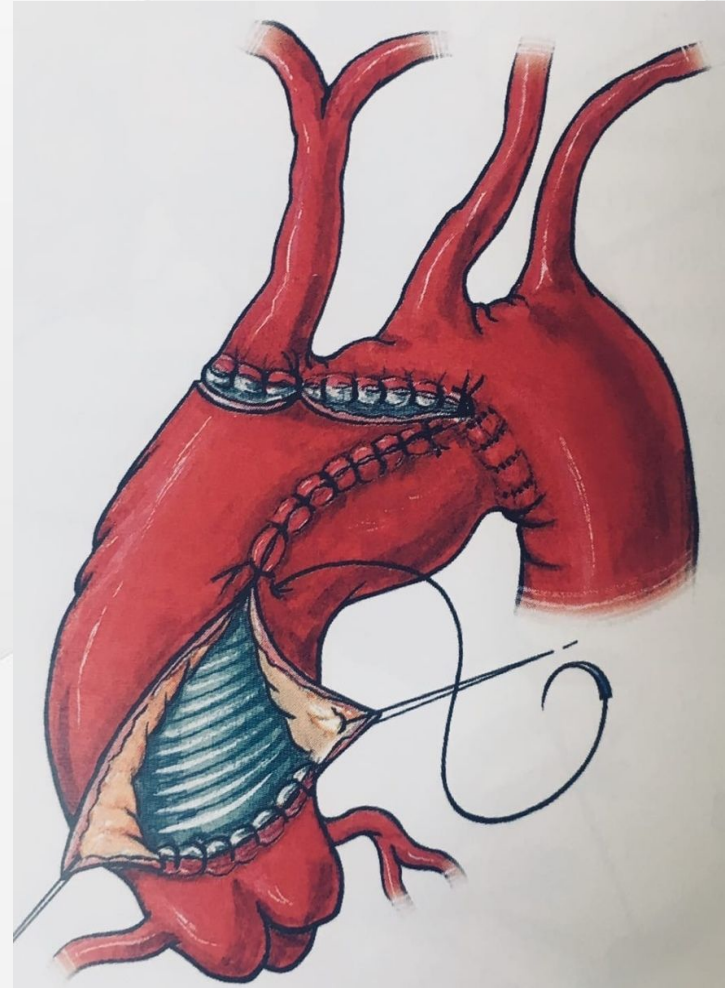
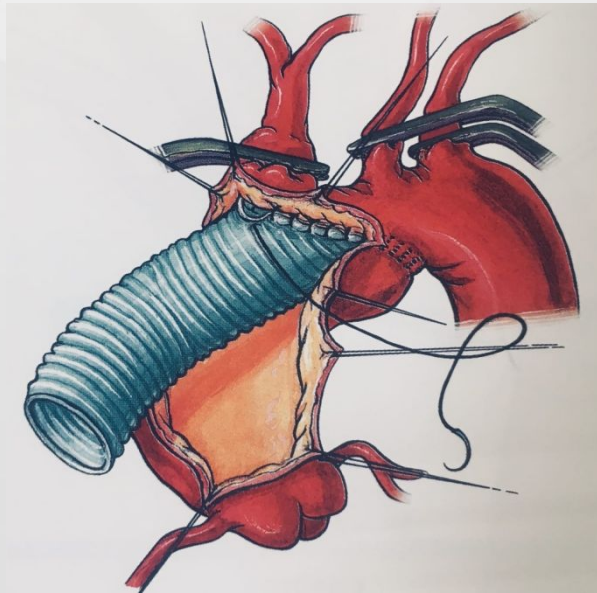
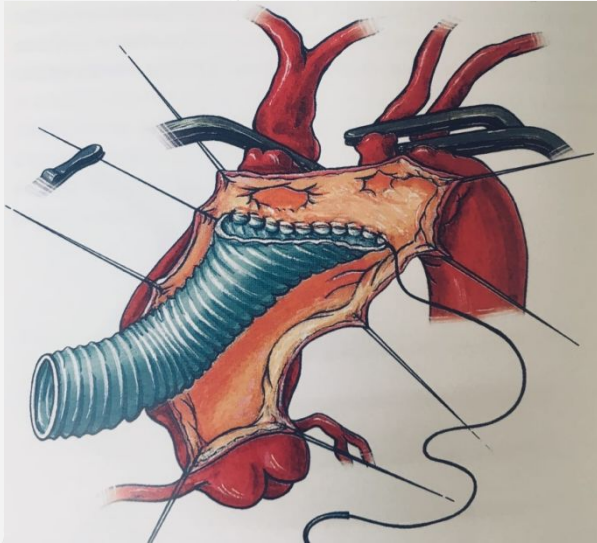
26.13



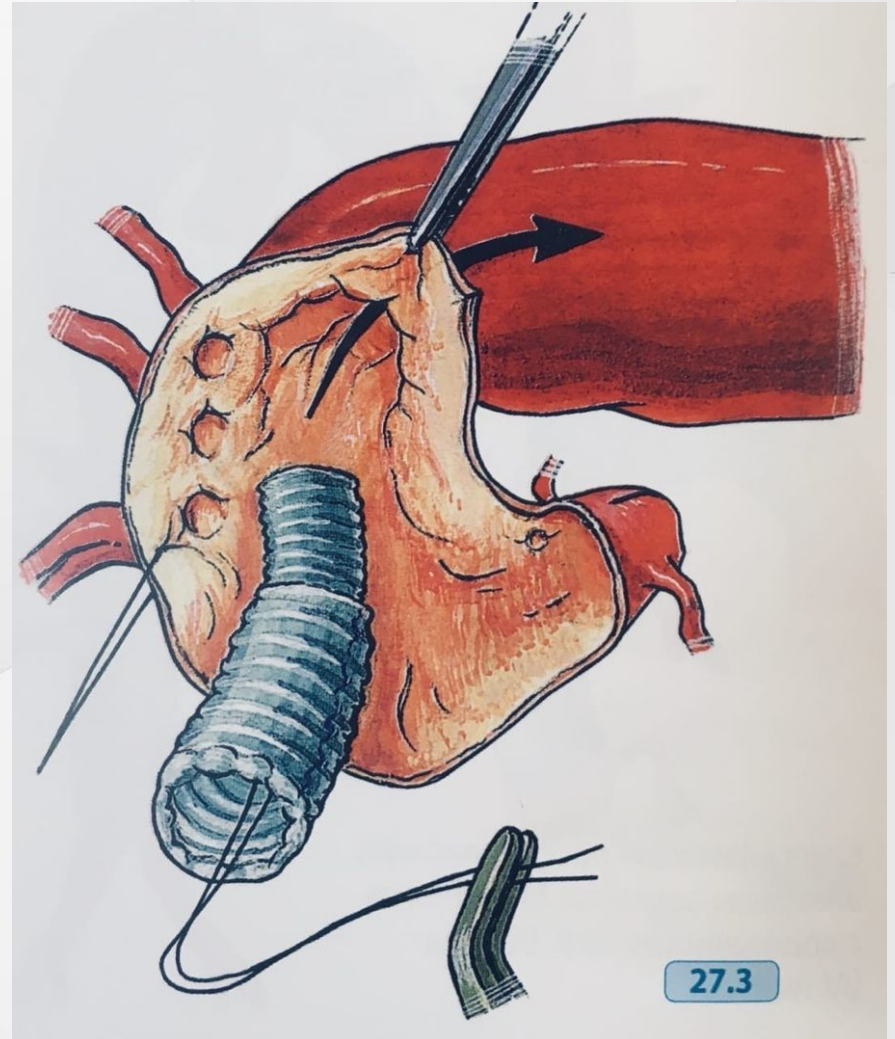
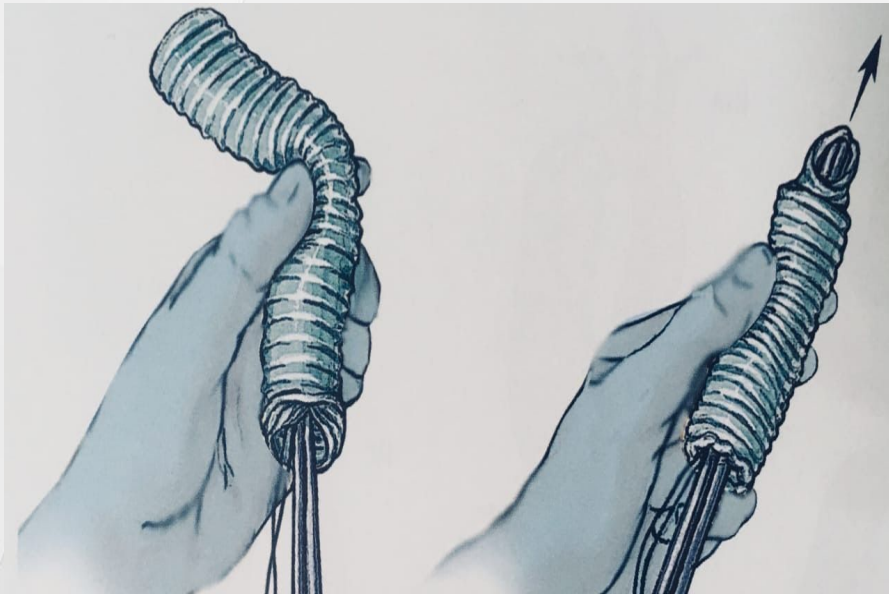
26.14

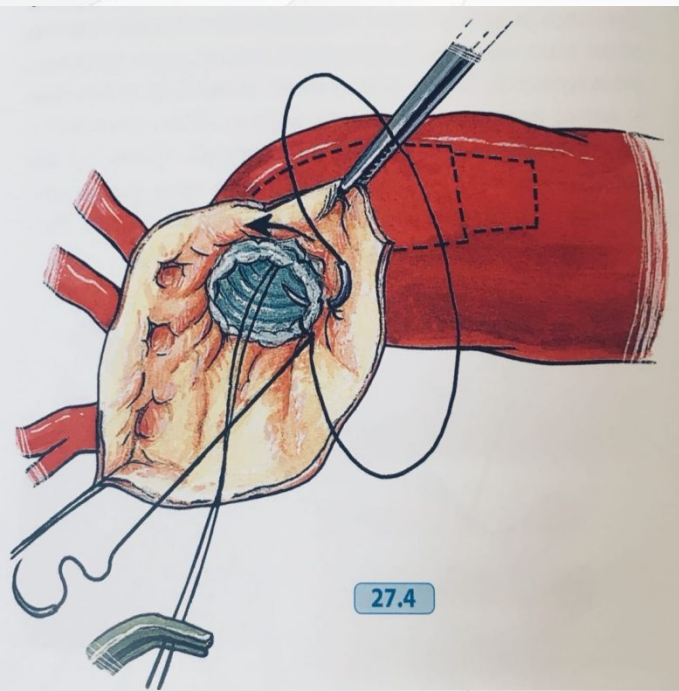
26.15

Операция hemiarch

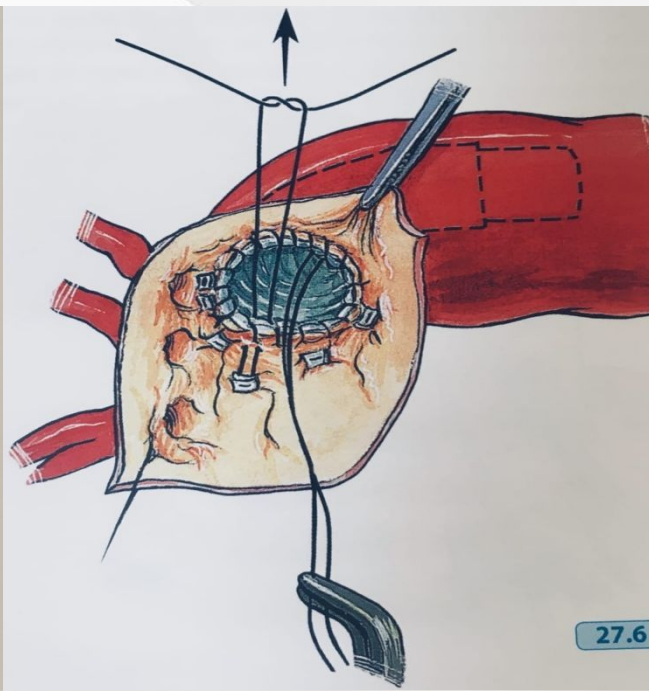


Операция Borst

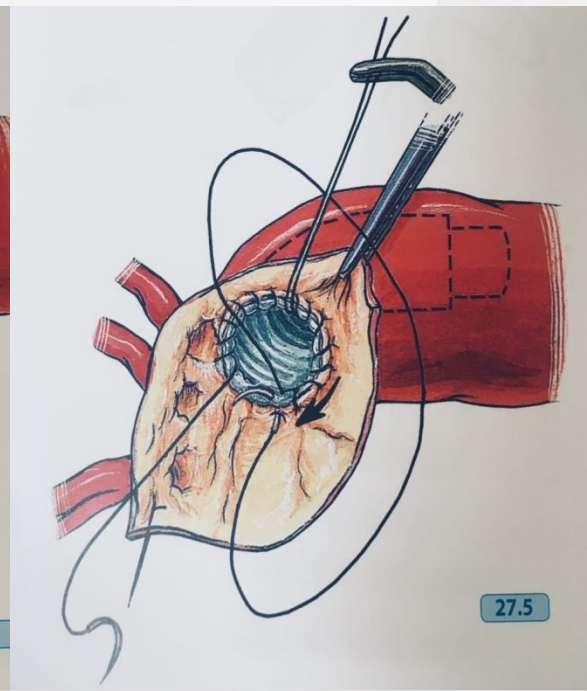




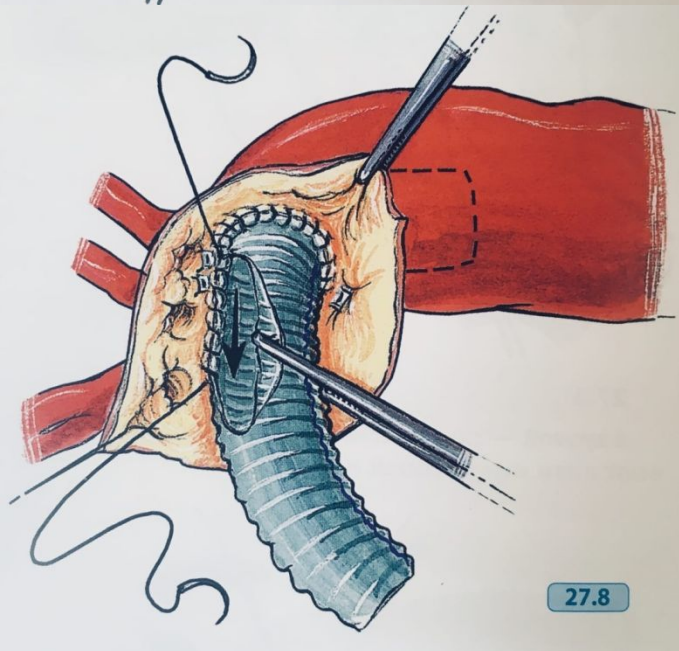
27.4



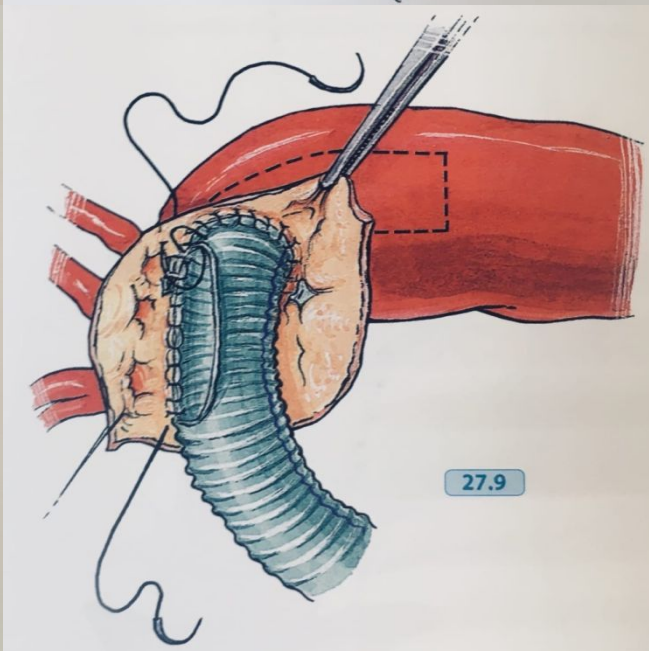
27.6



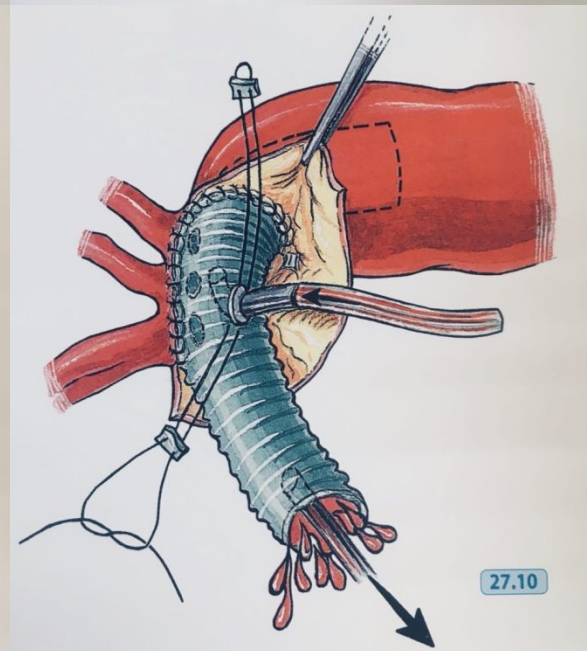
27.5



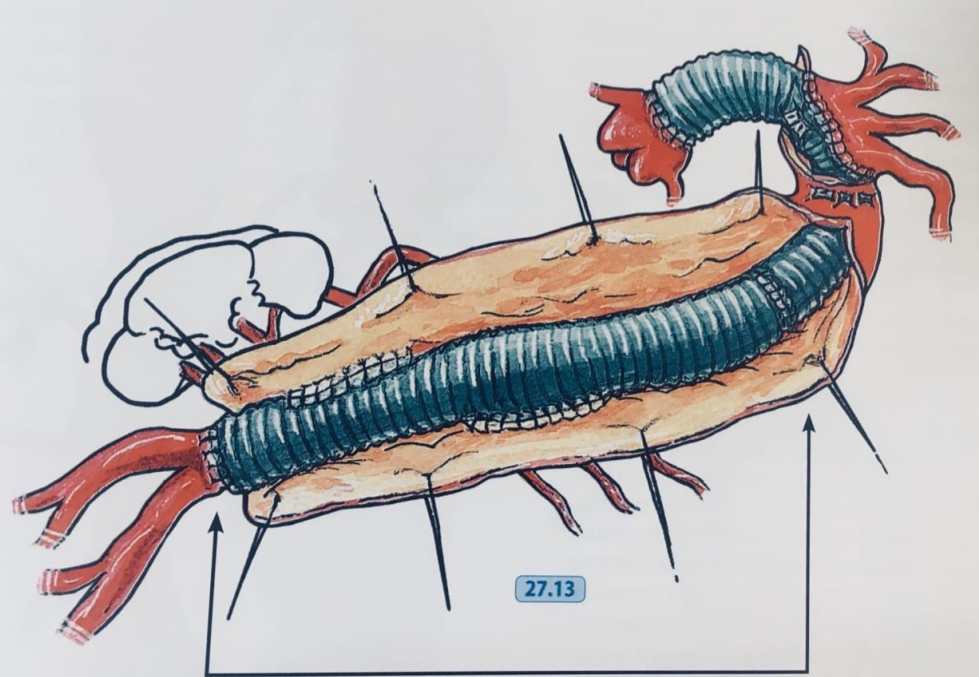
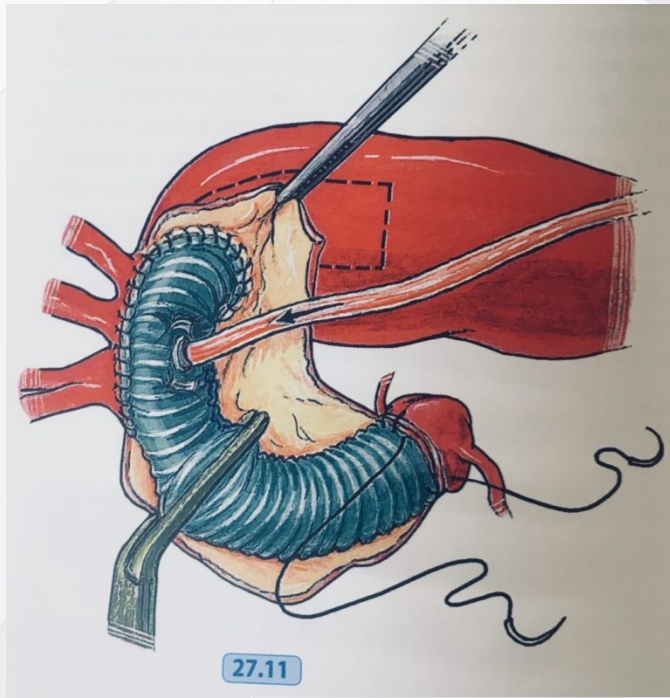
27.8



27.9



27.10



Благодарю за внимание!