

СВИНОВОДСТВО

- Болезни свиней.
Патологоанатомические изменения.











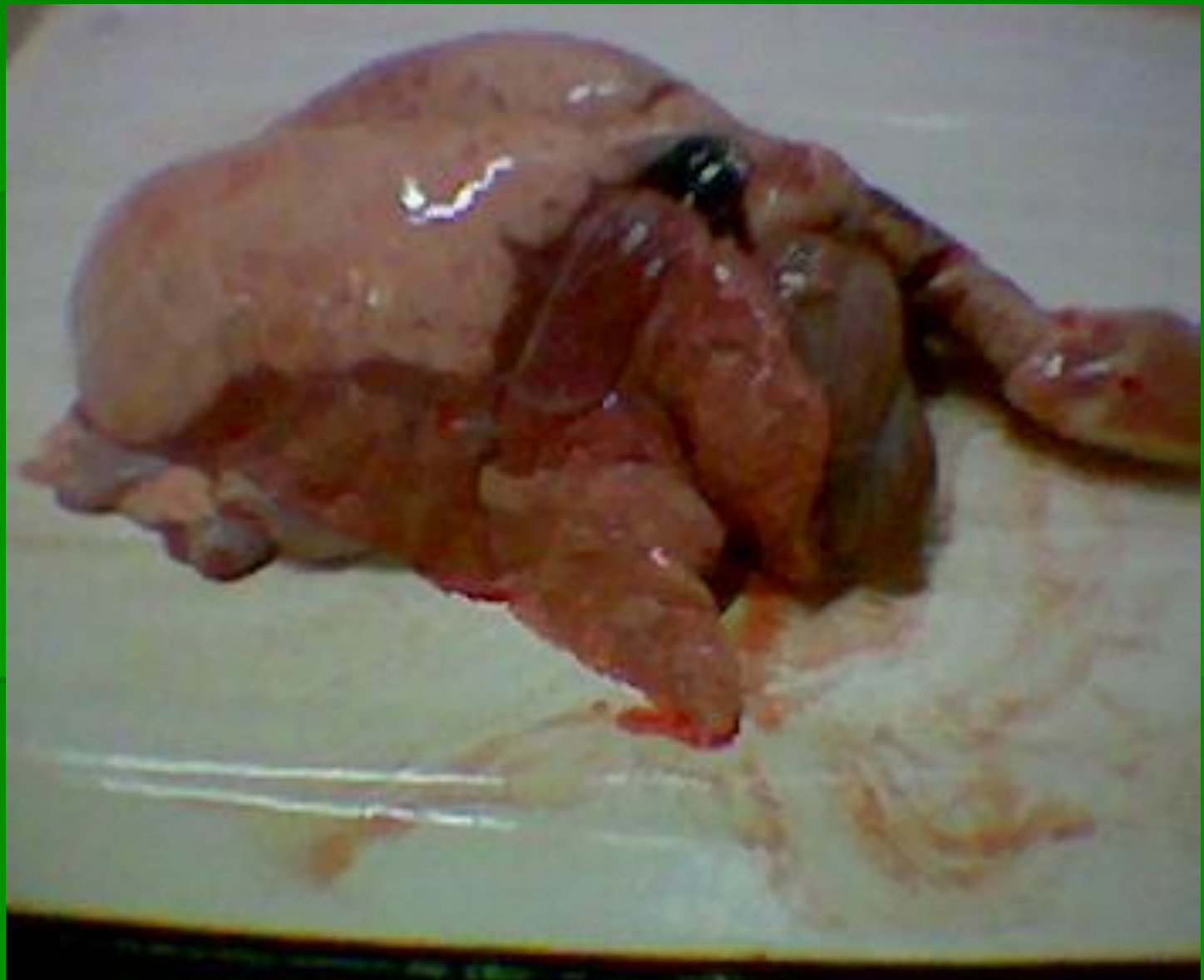

МИКОПЛАЗМО

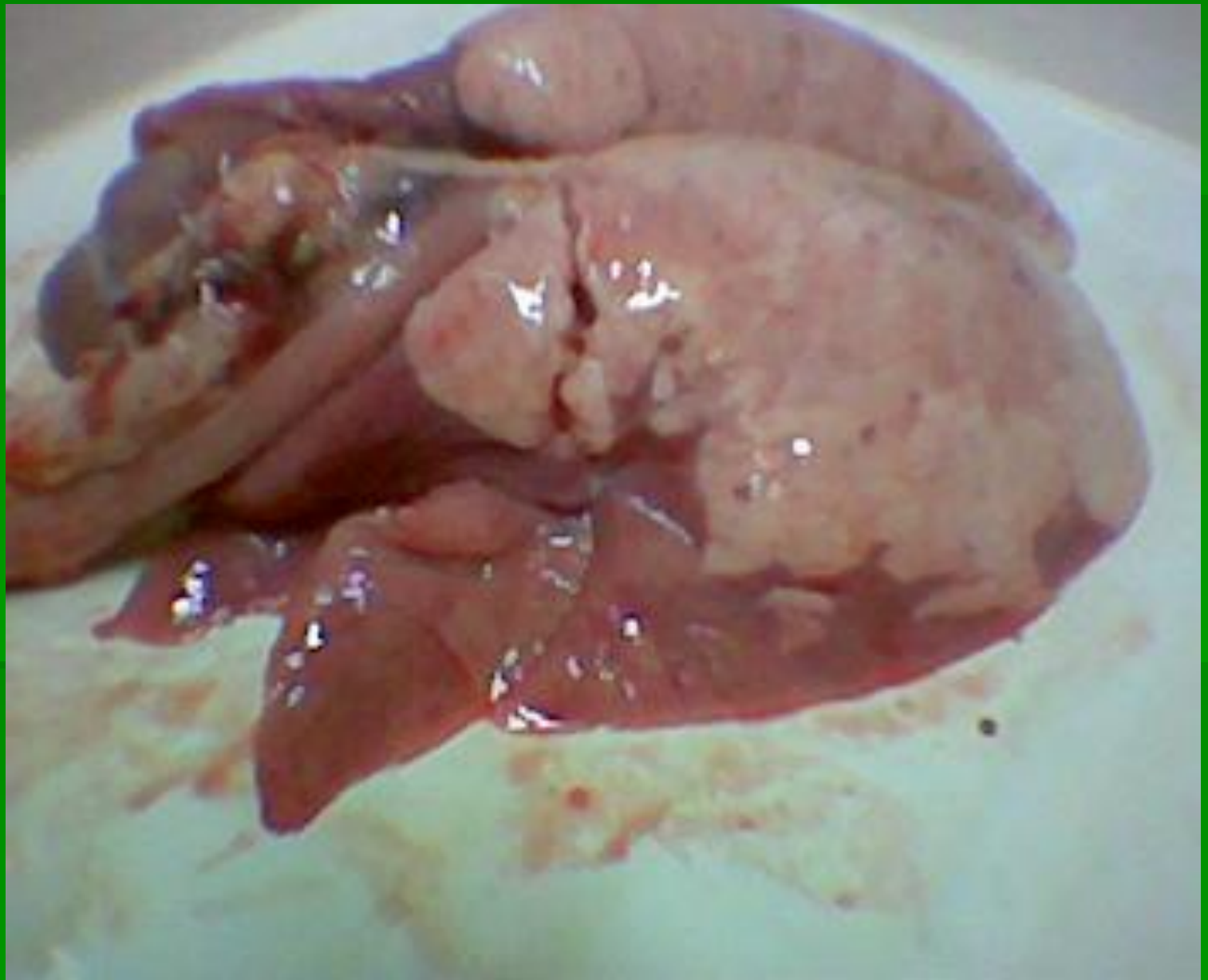
3

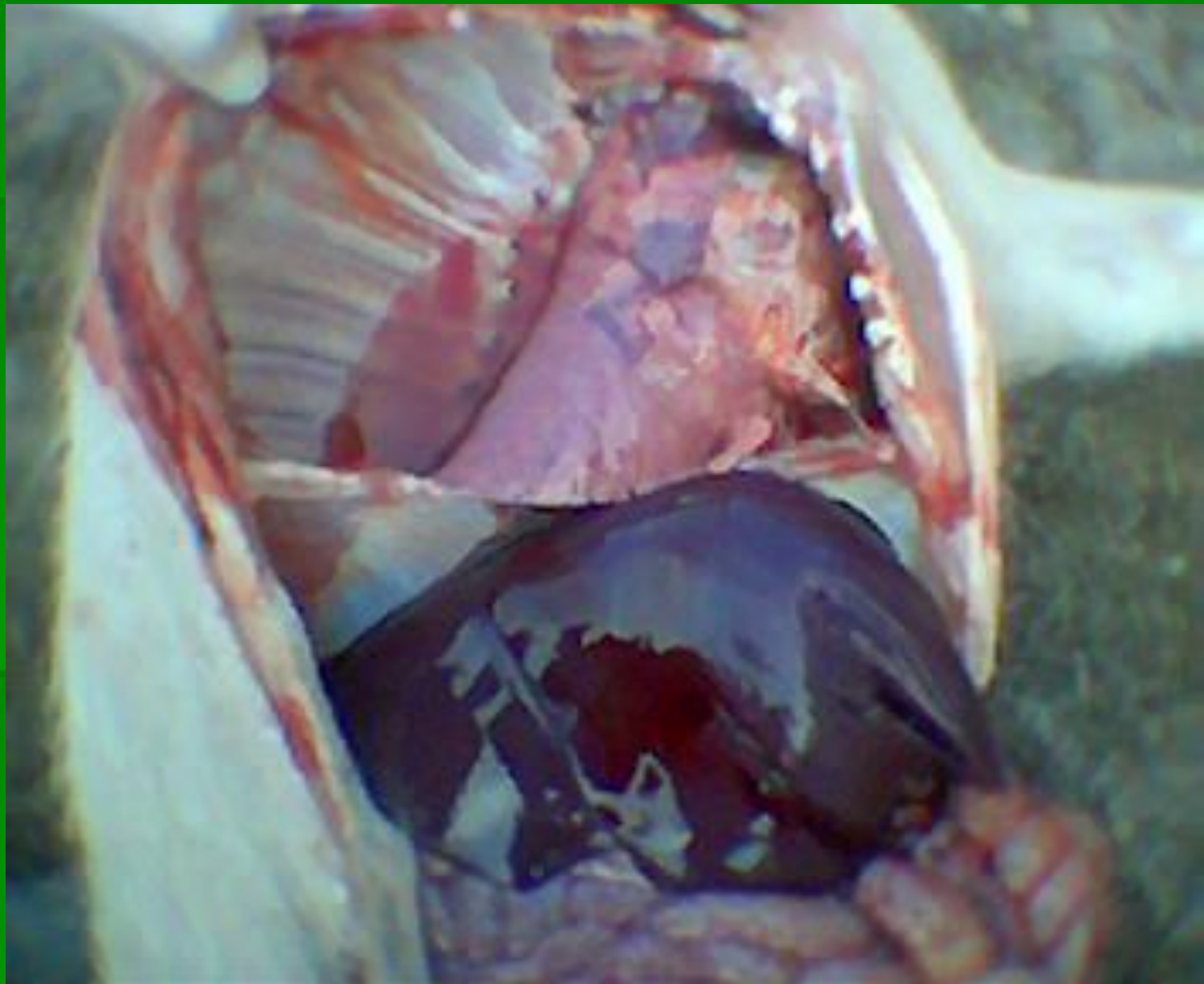


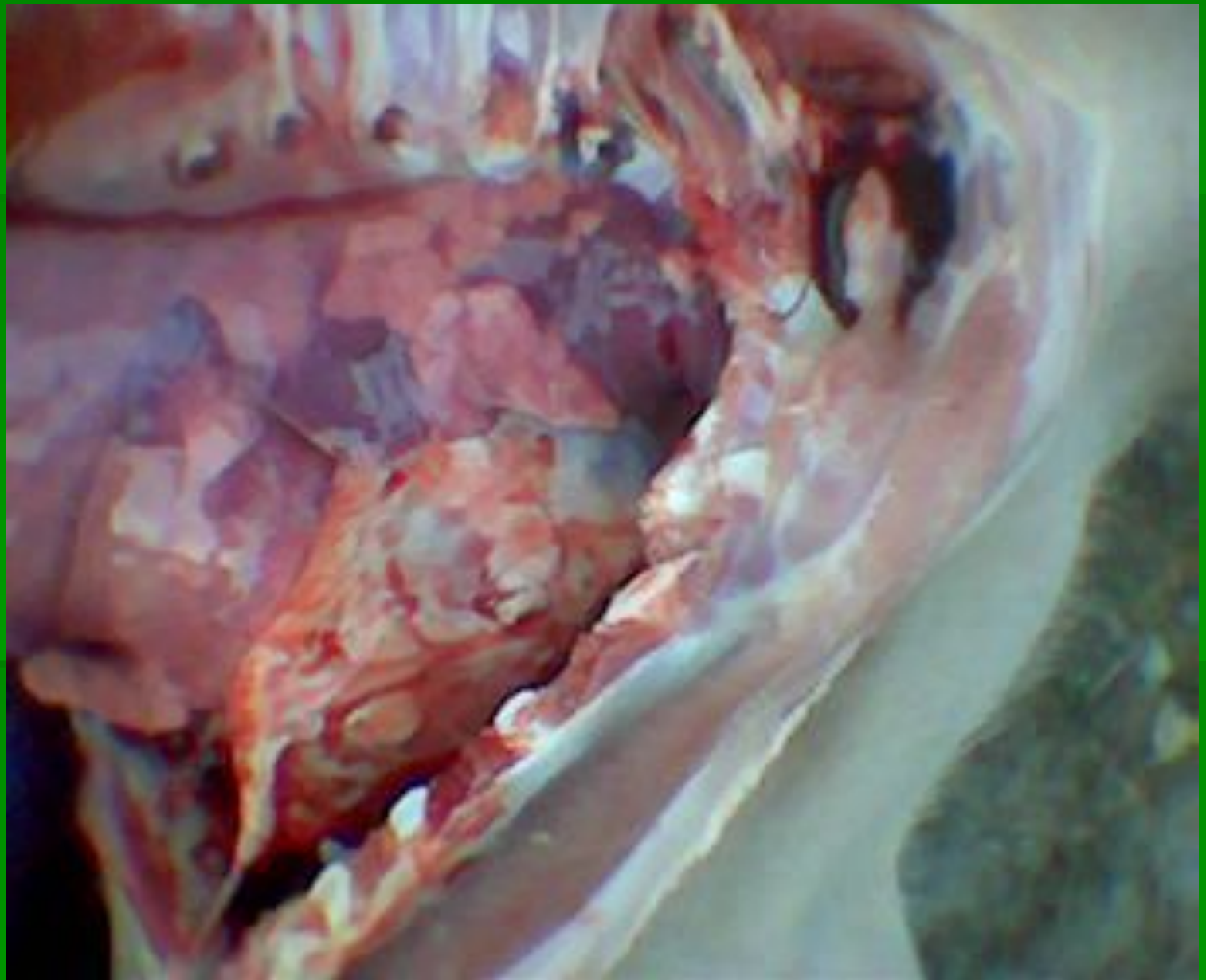


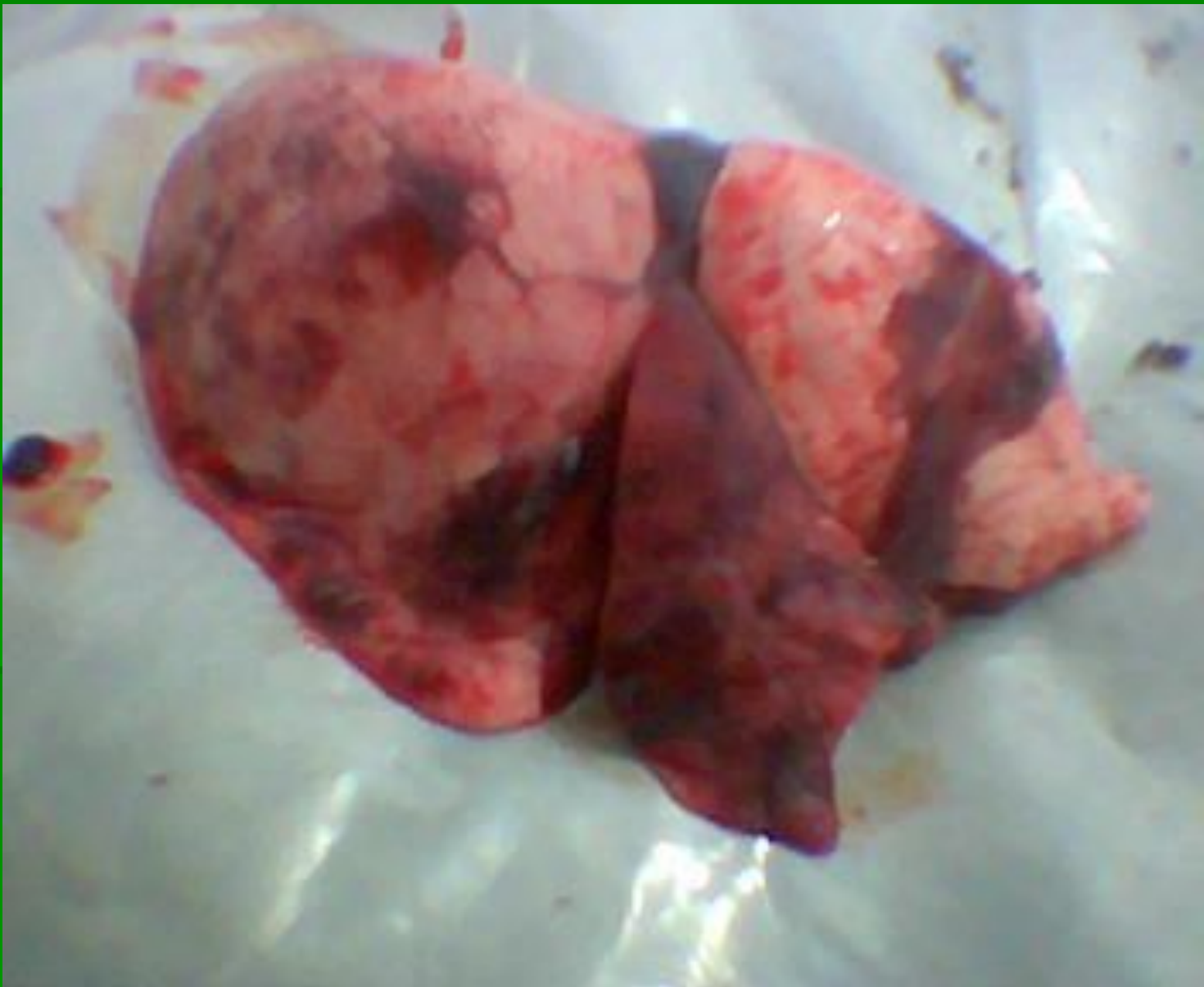


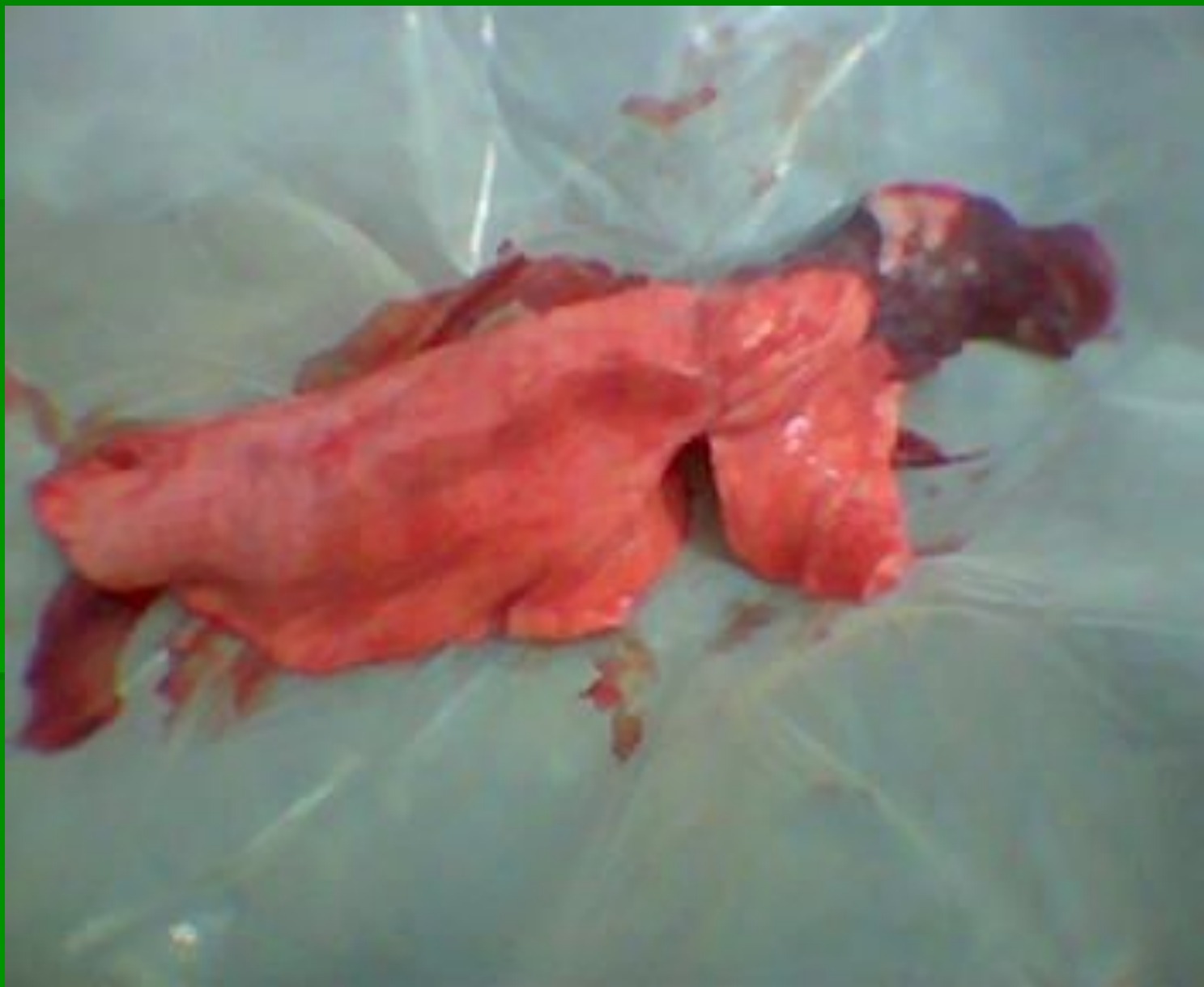
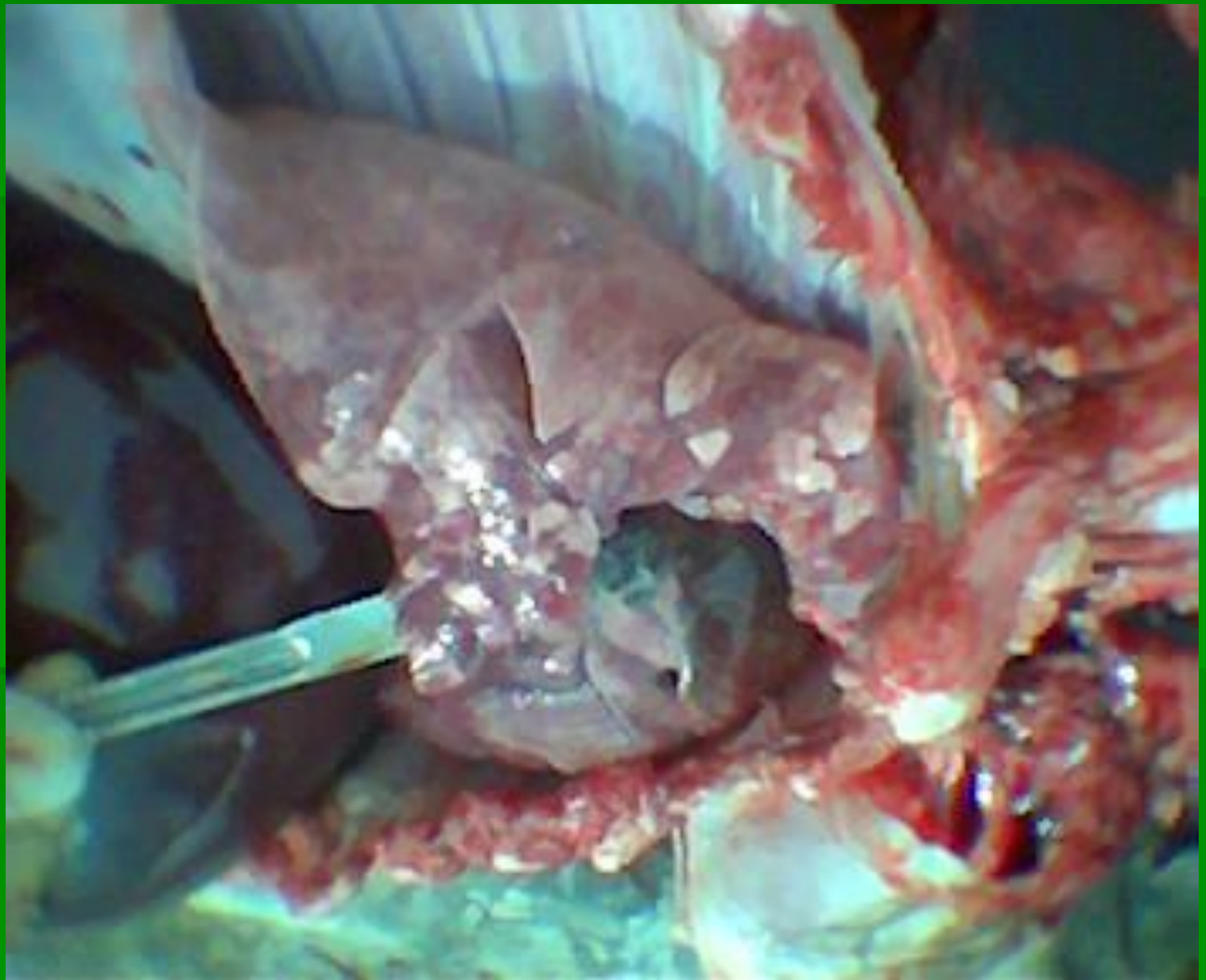




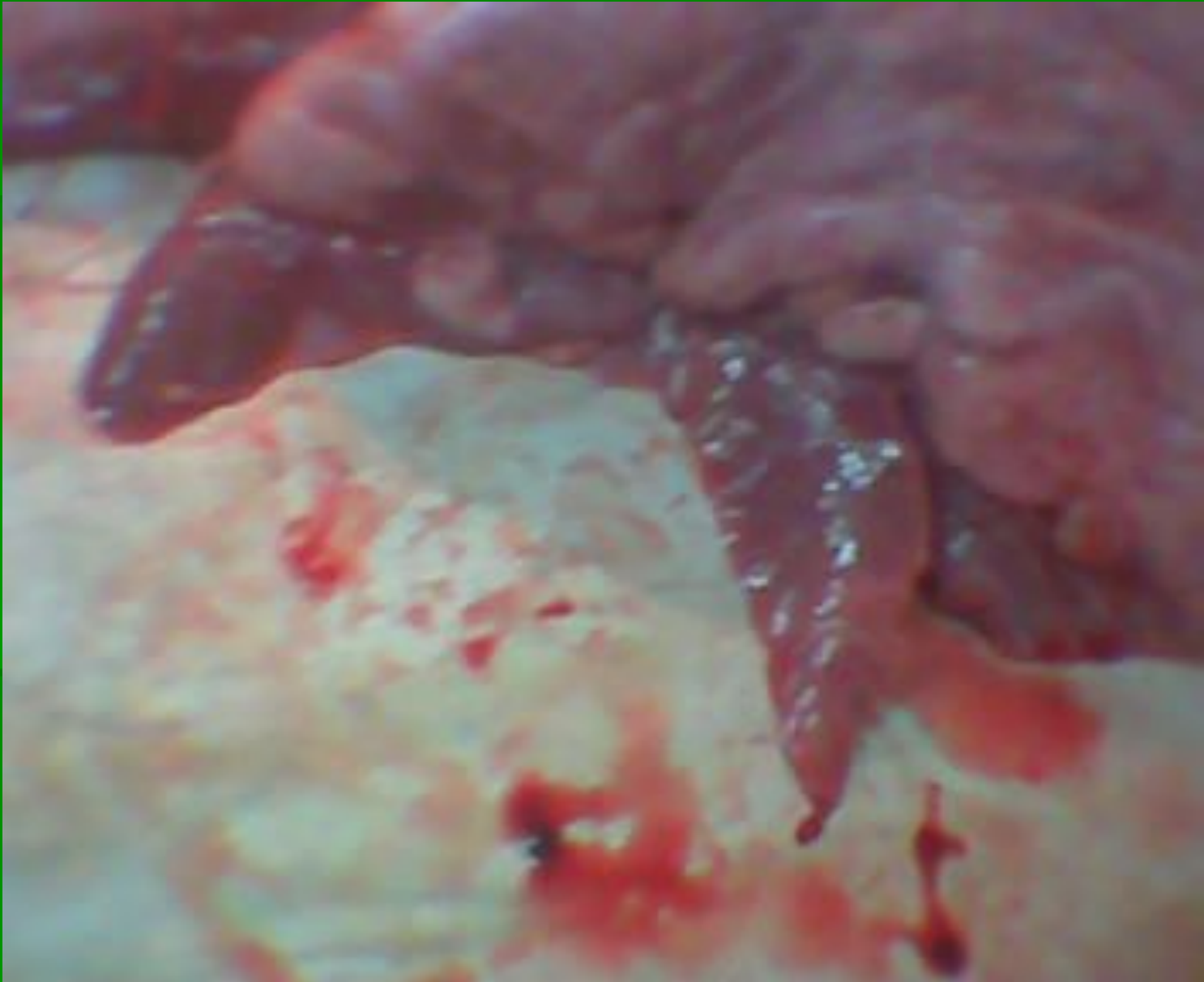


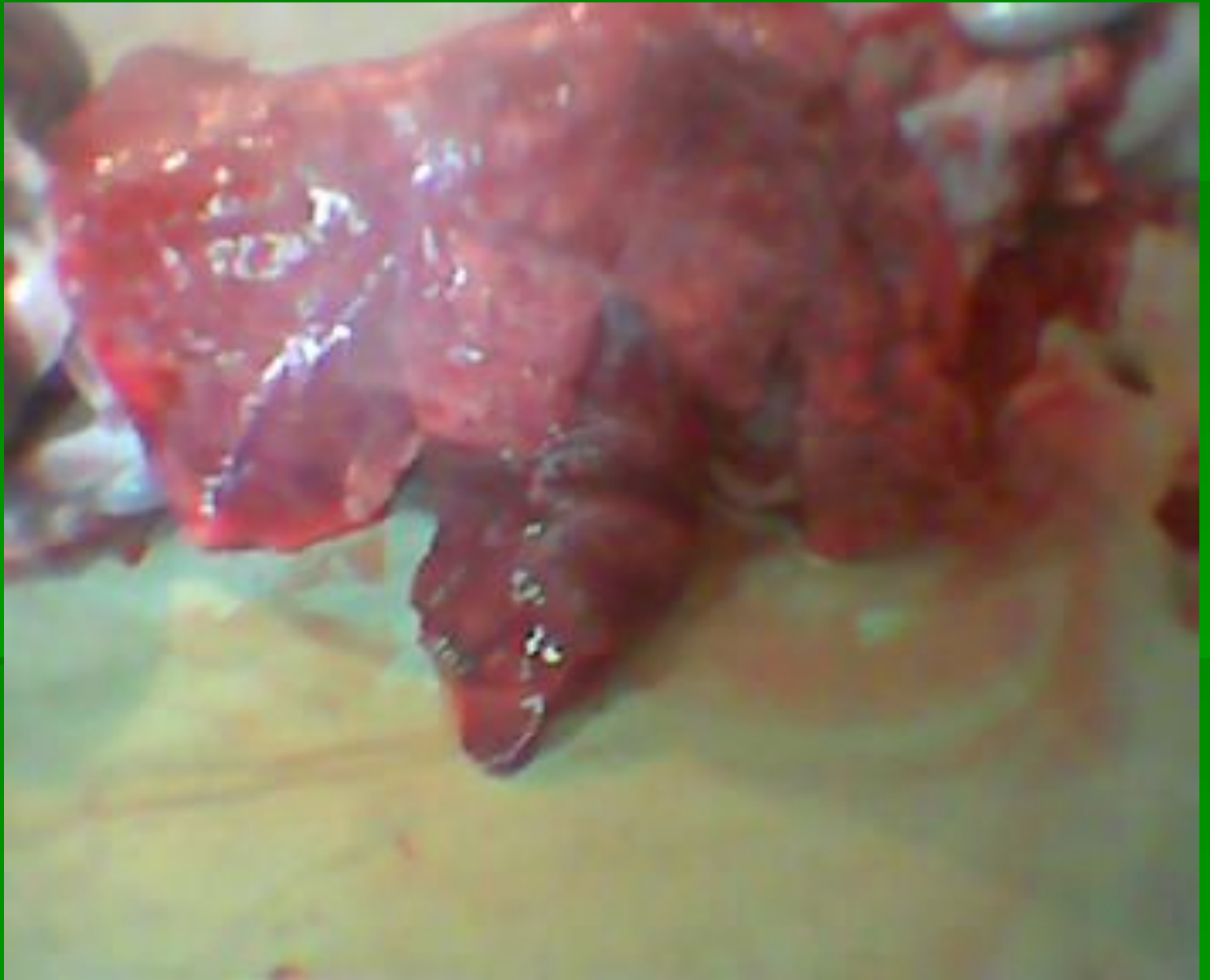
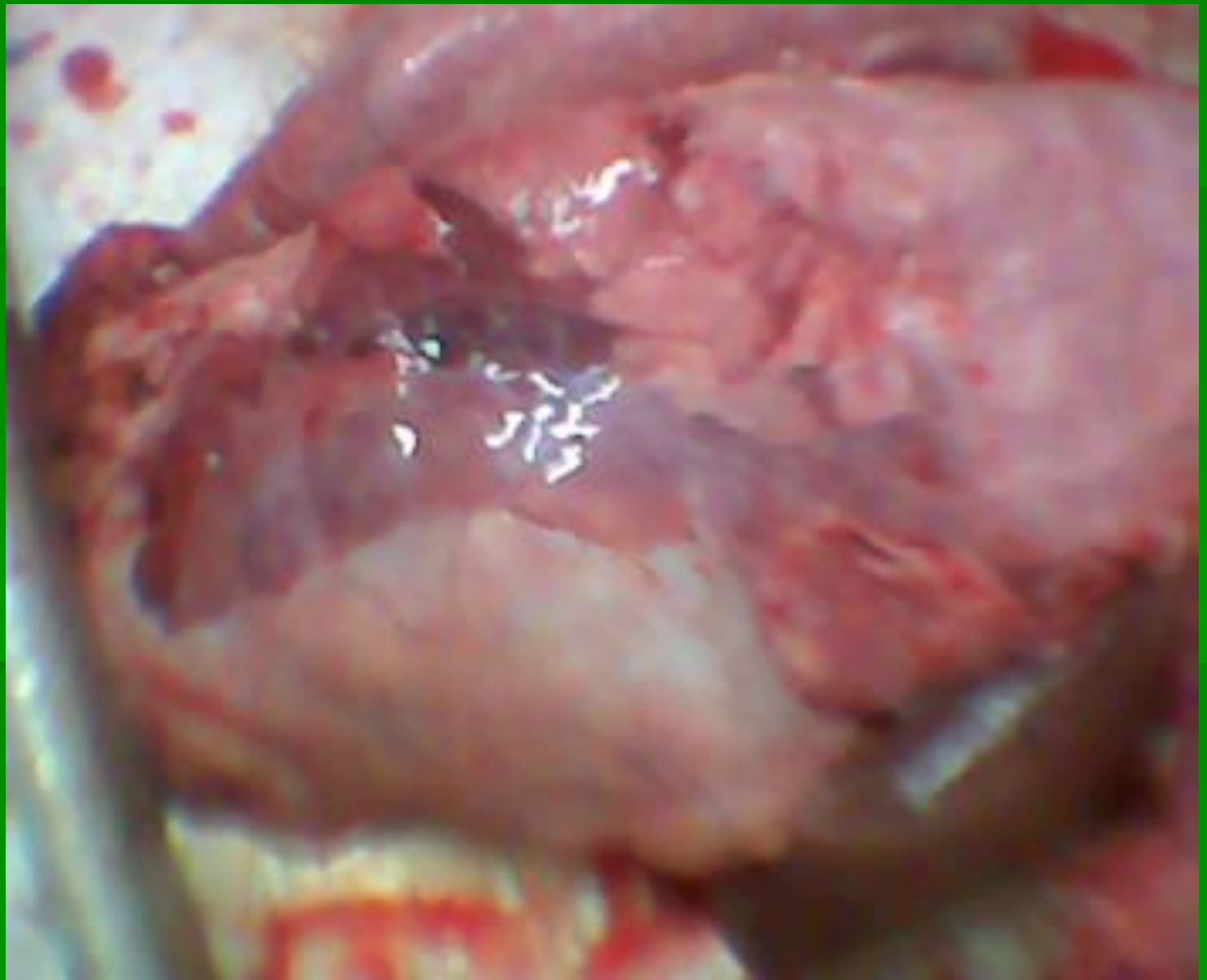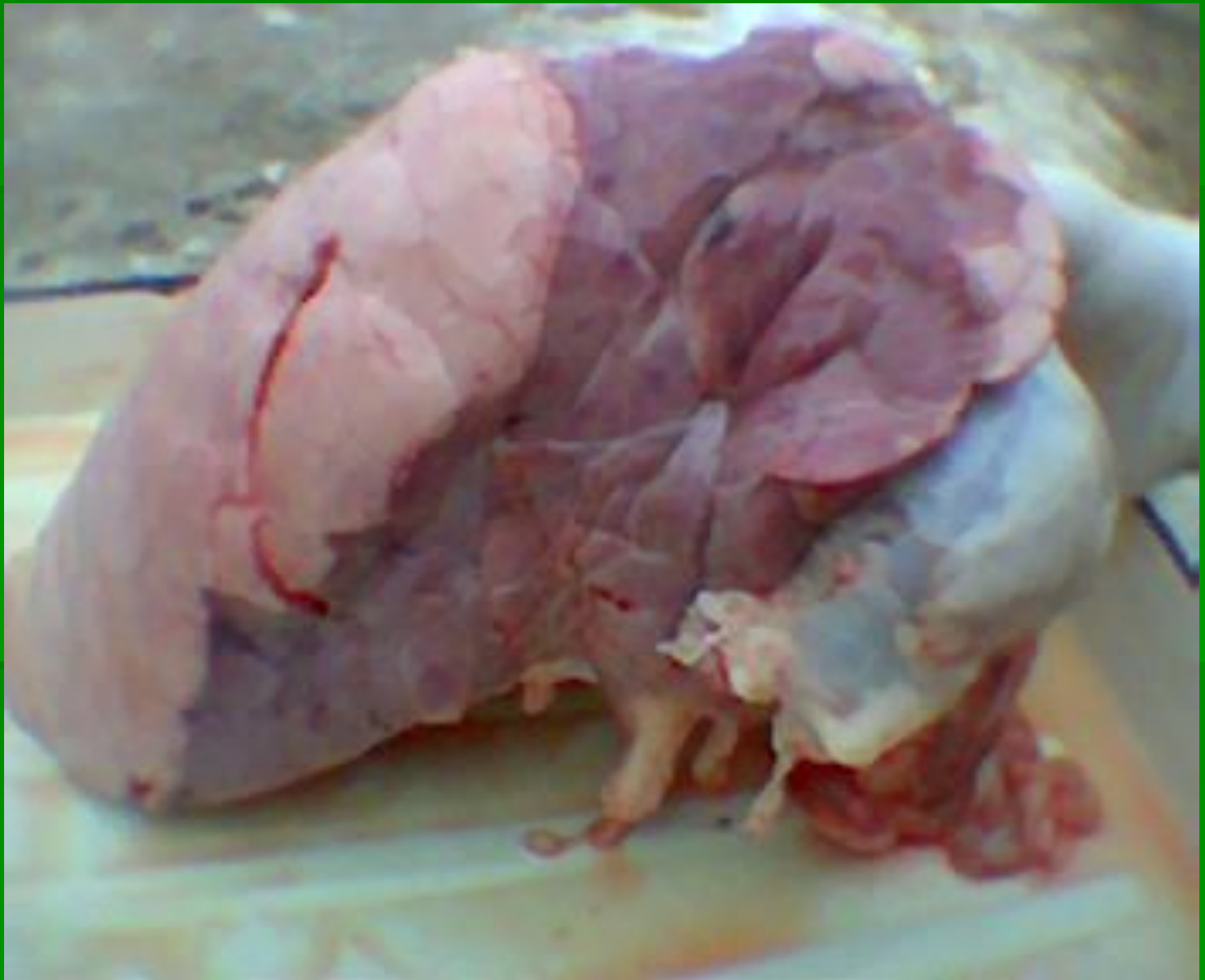




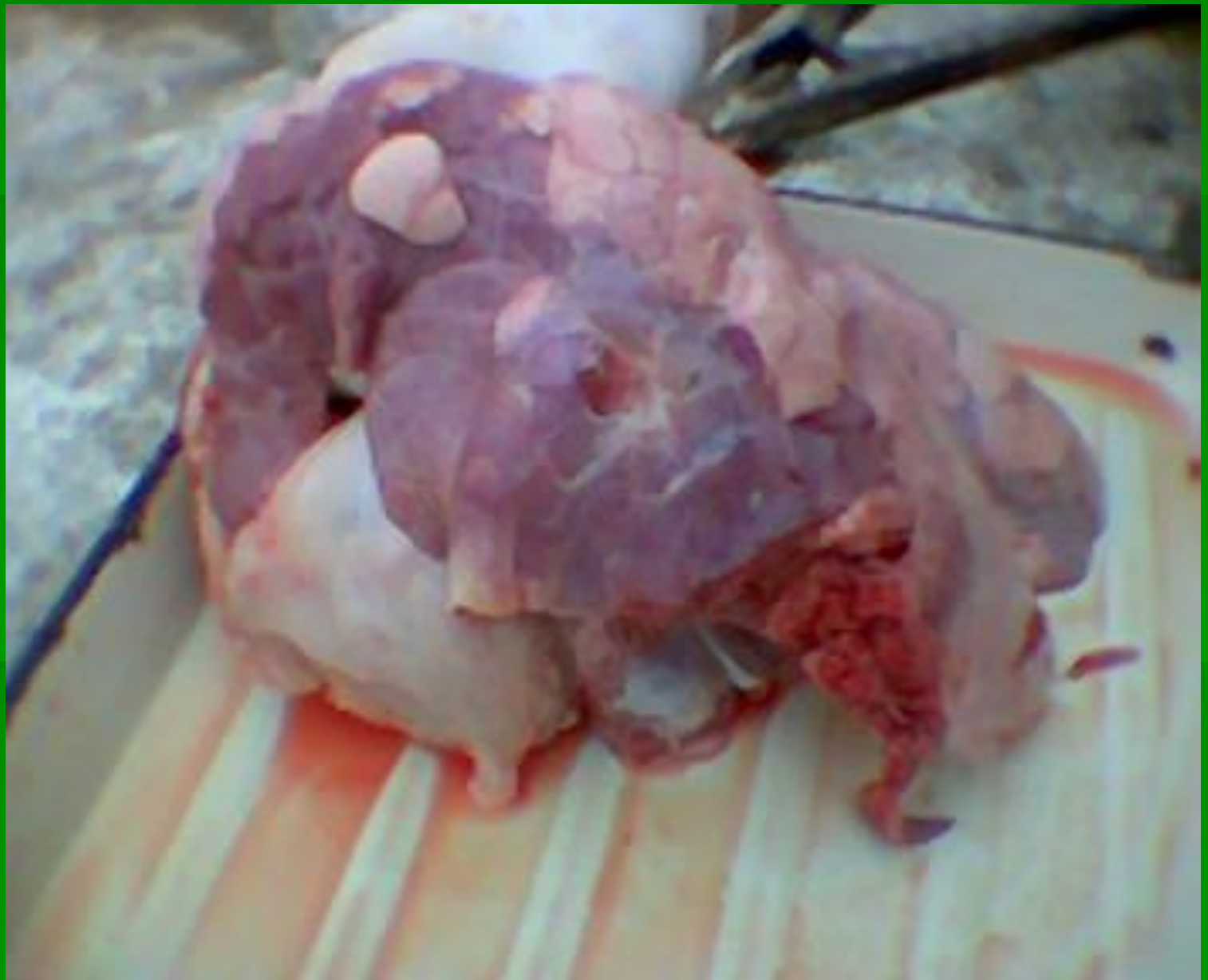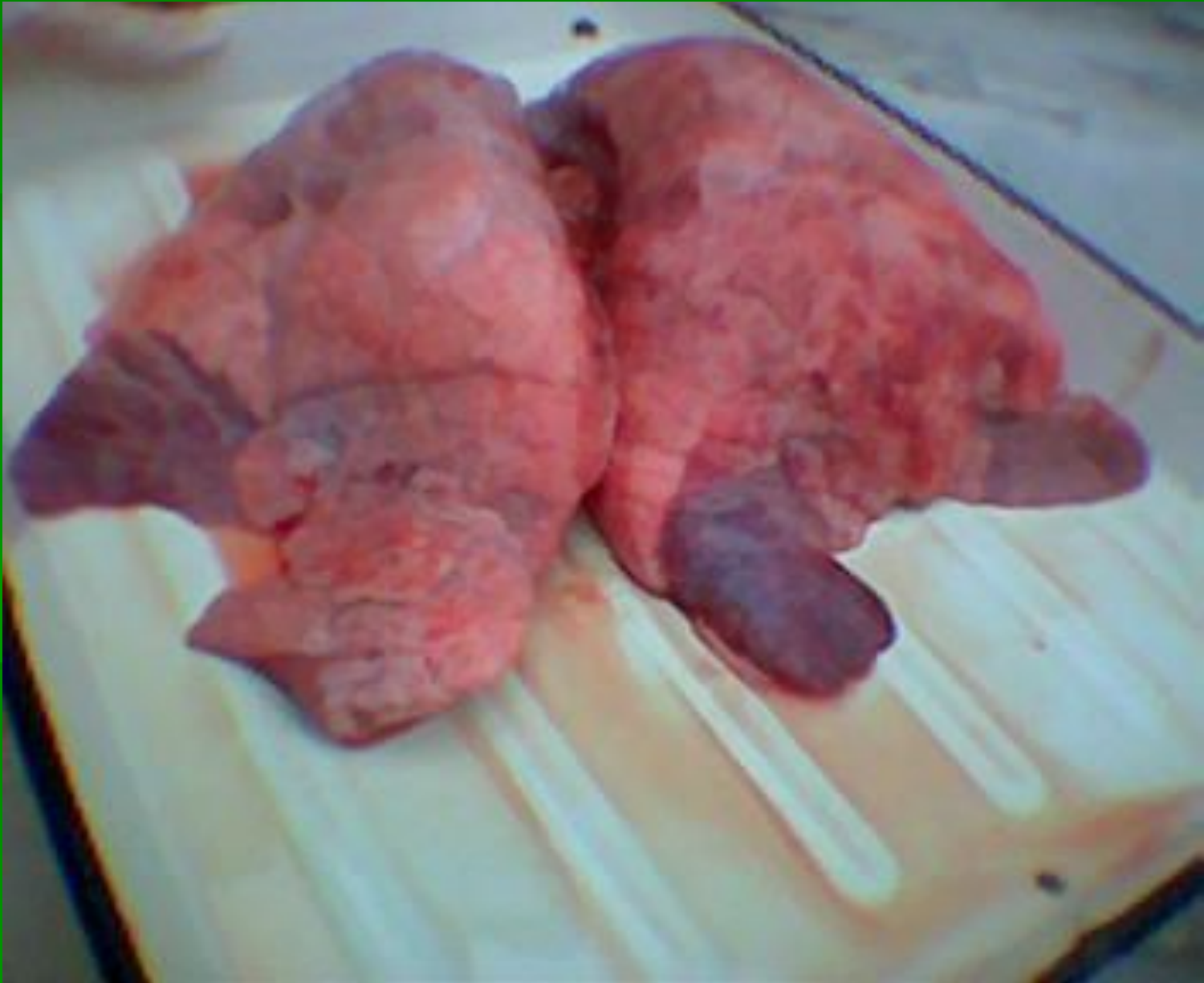




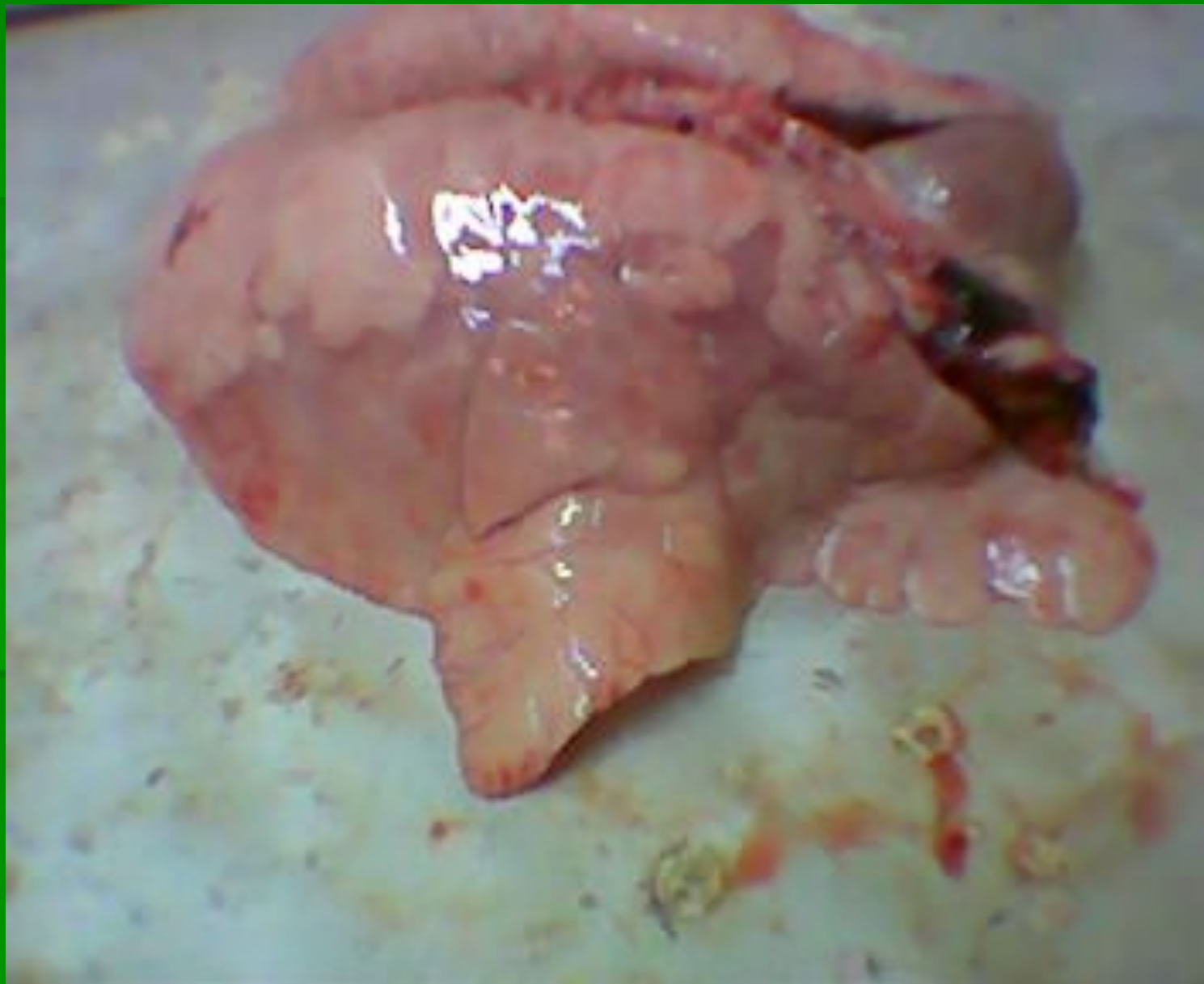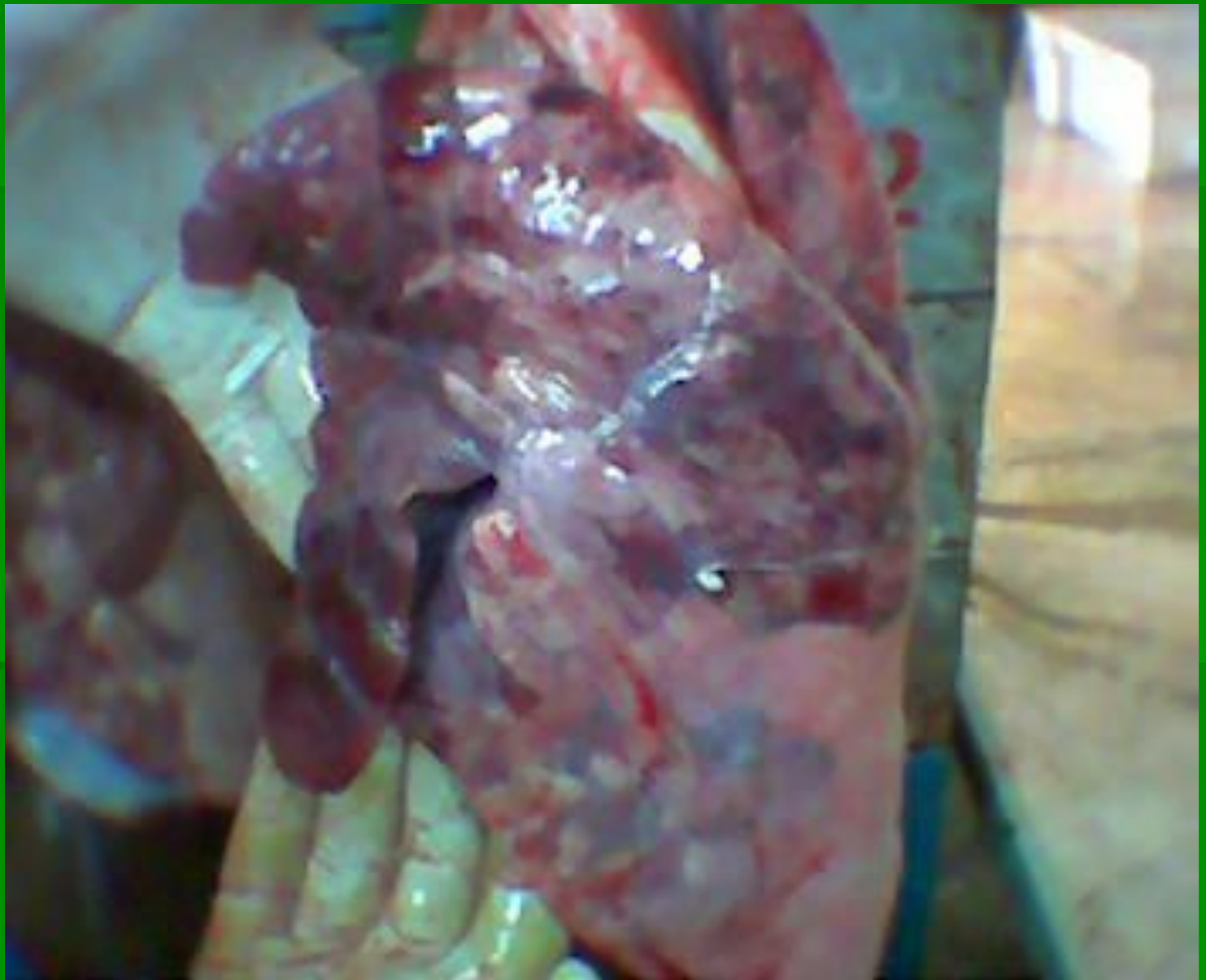








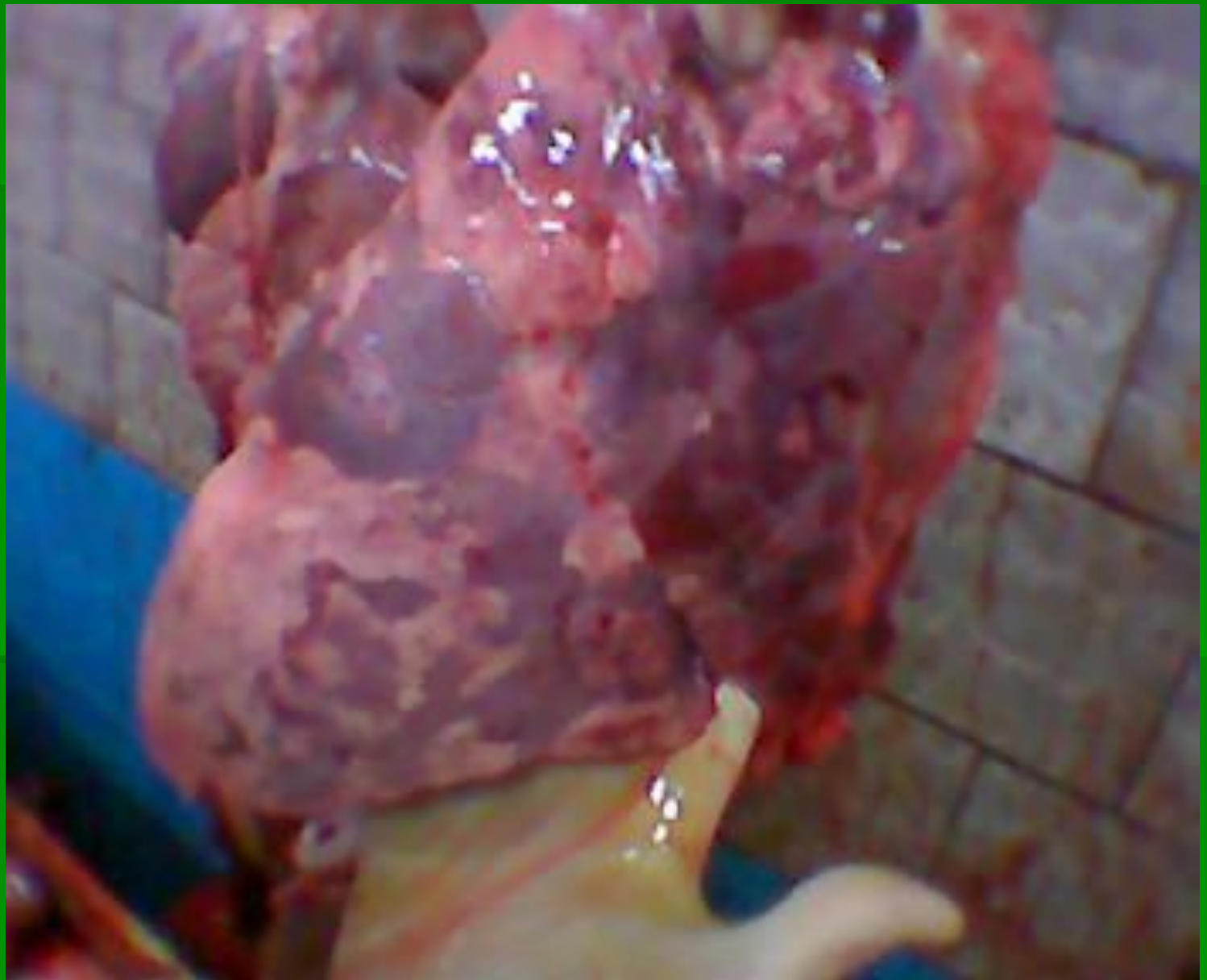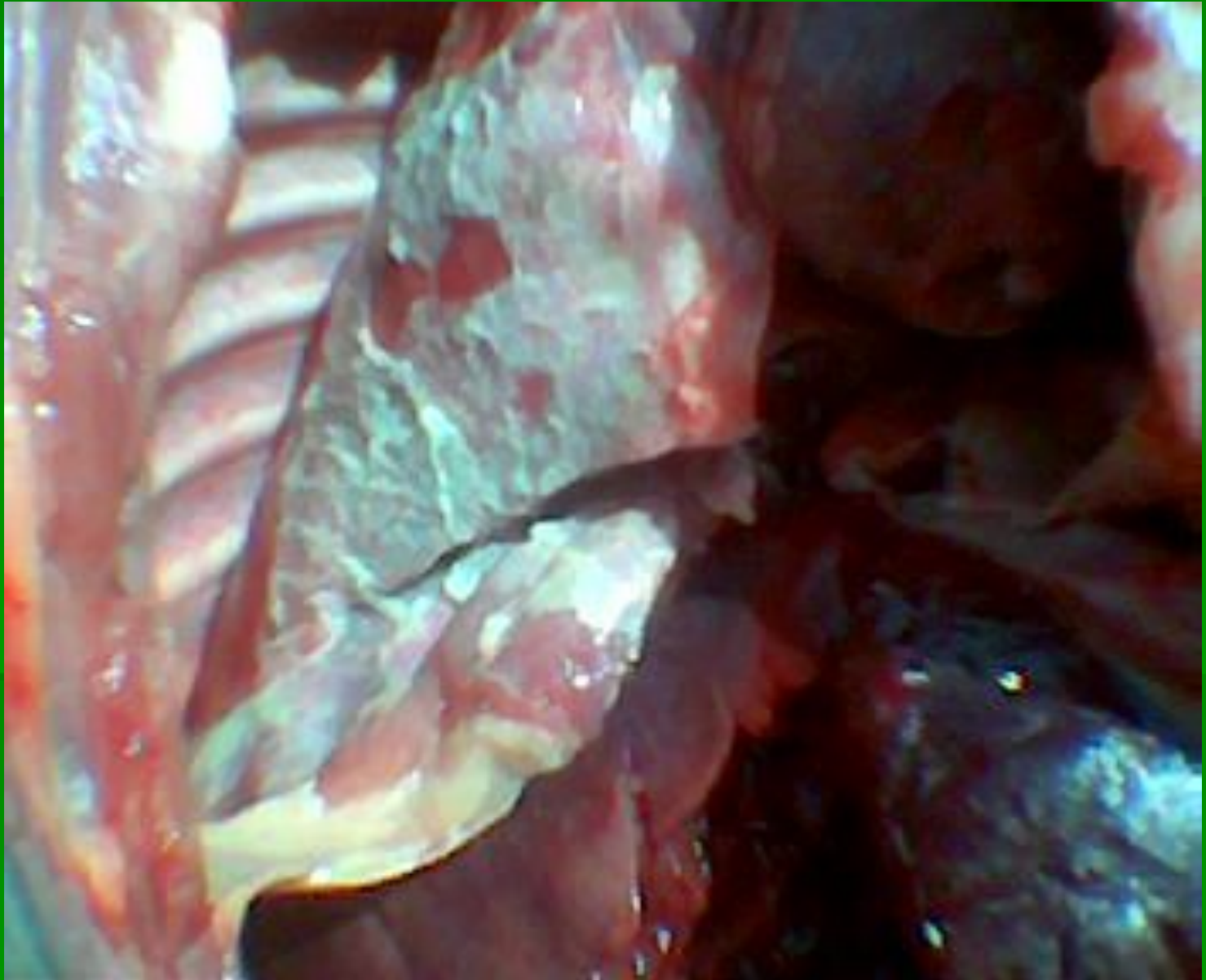


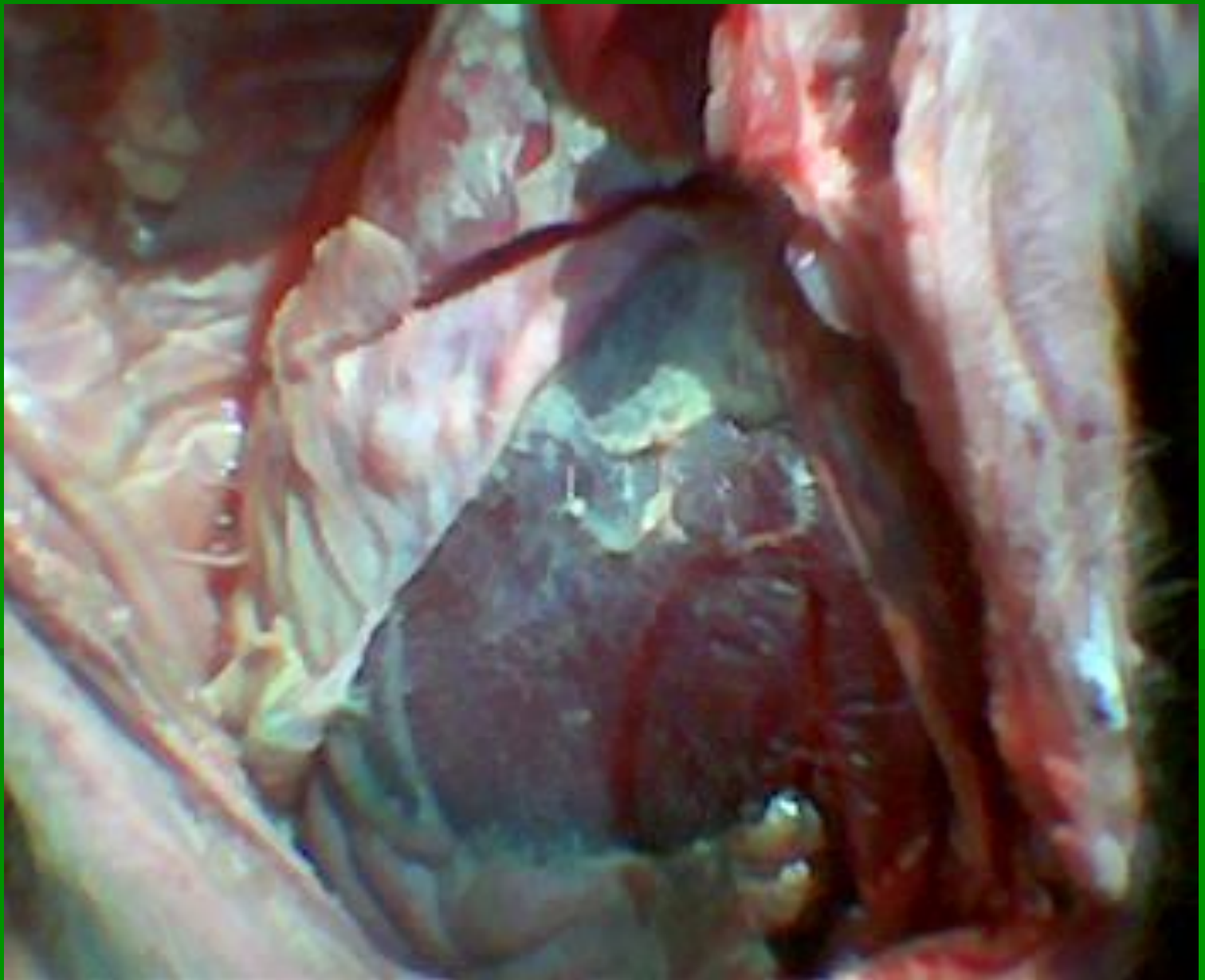




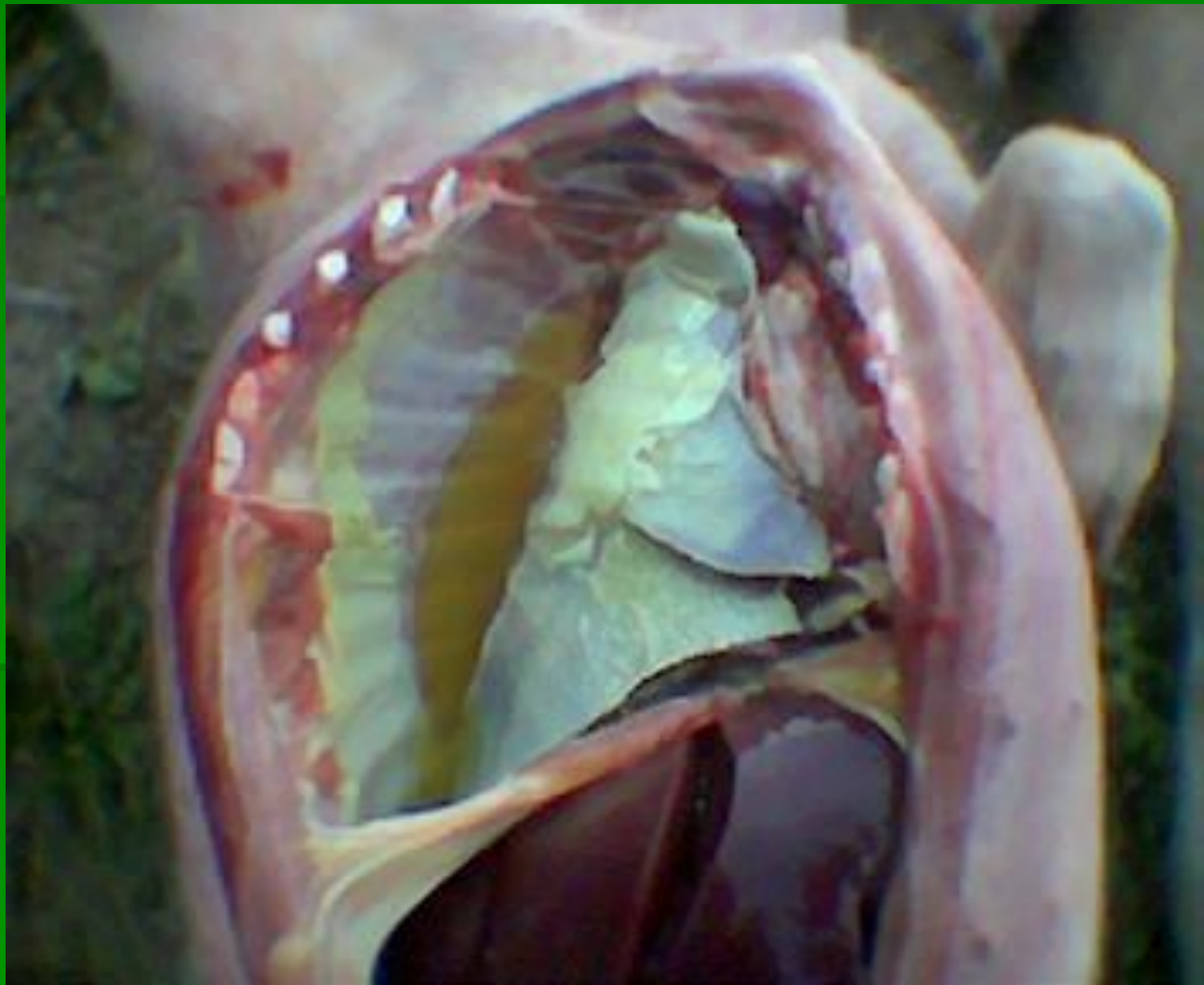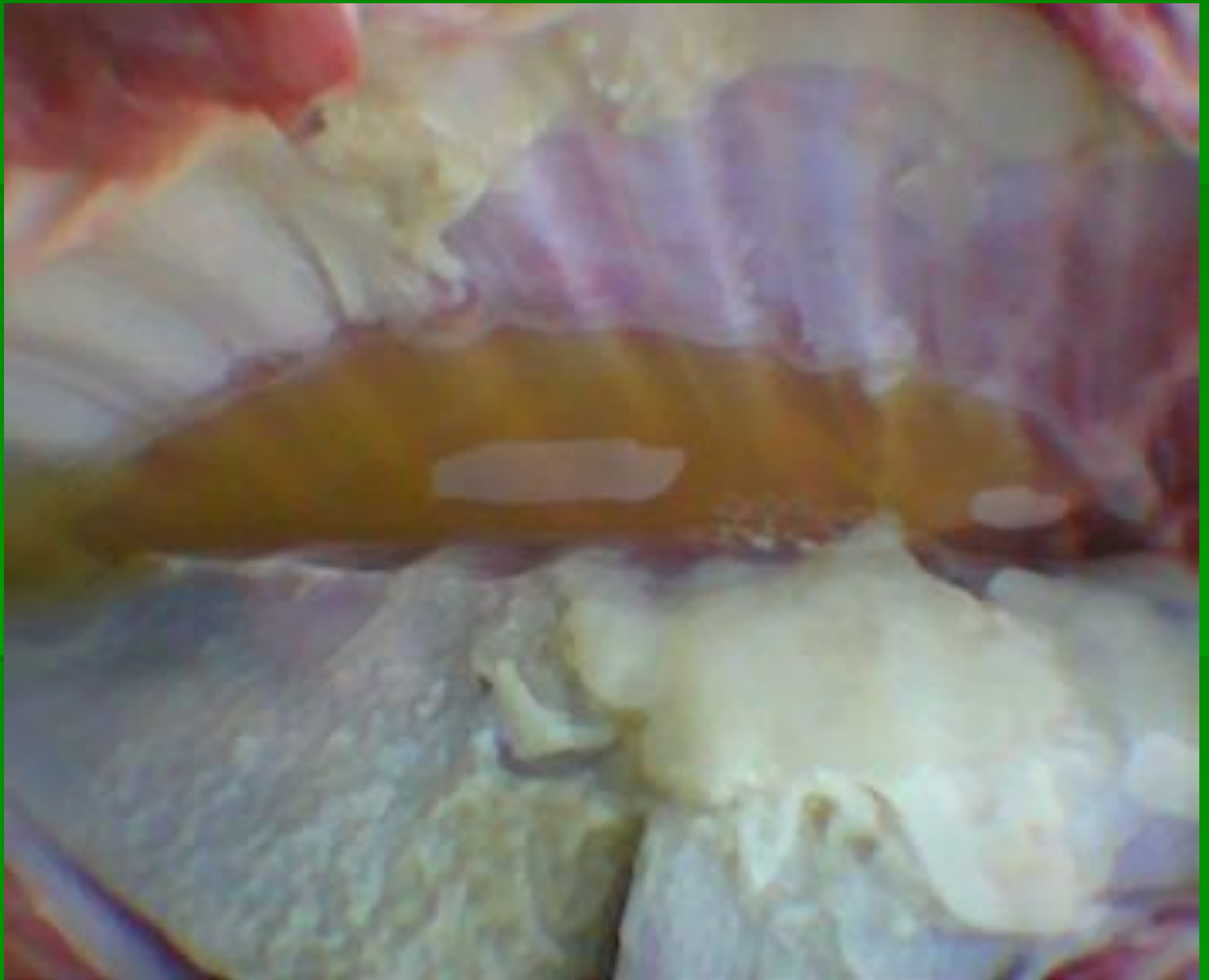ГЕМОФИЛИЕ

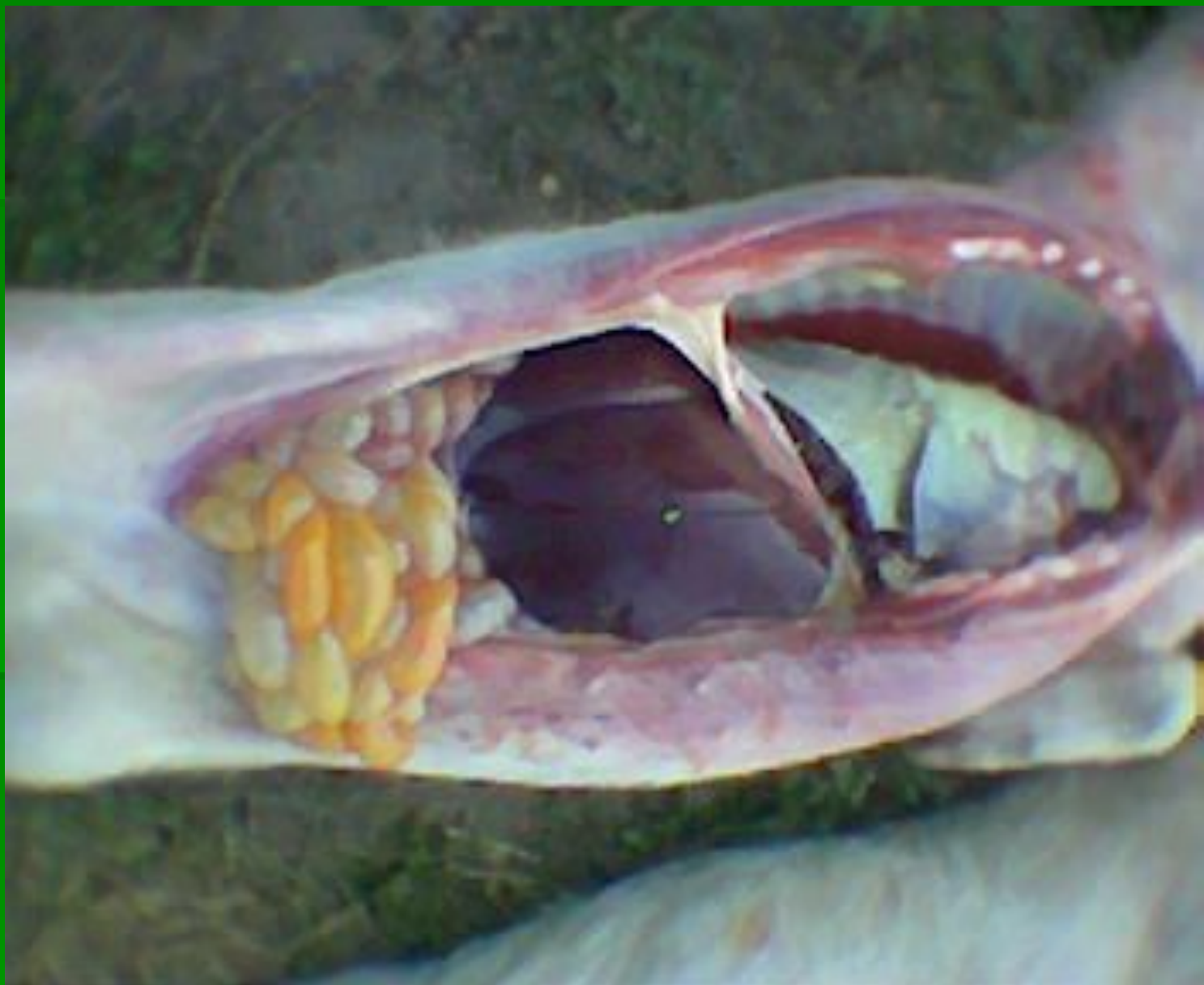3

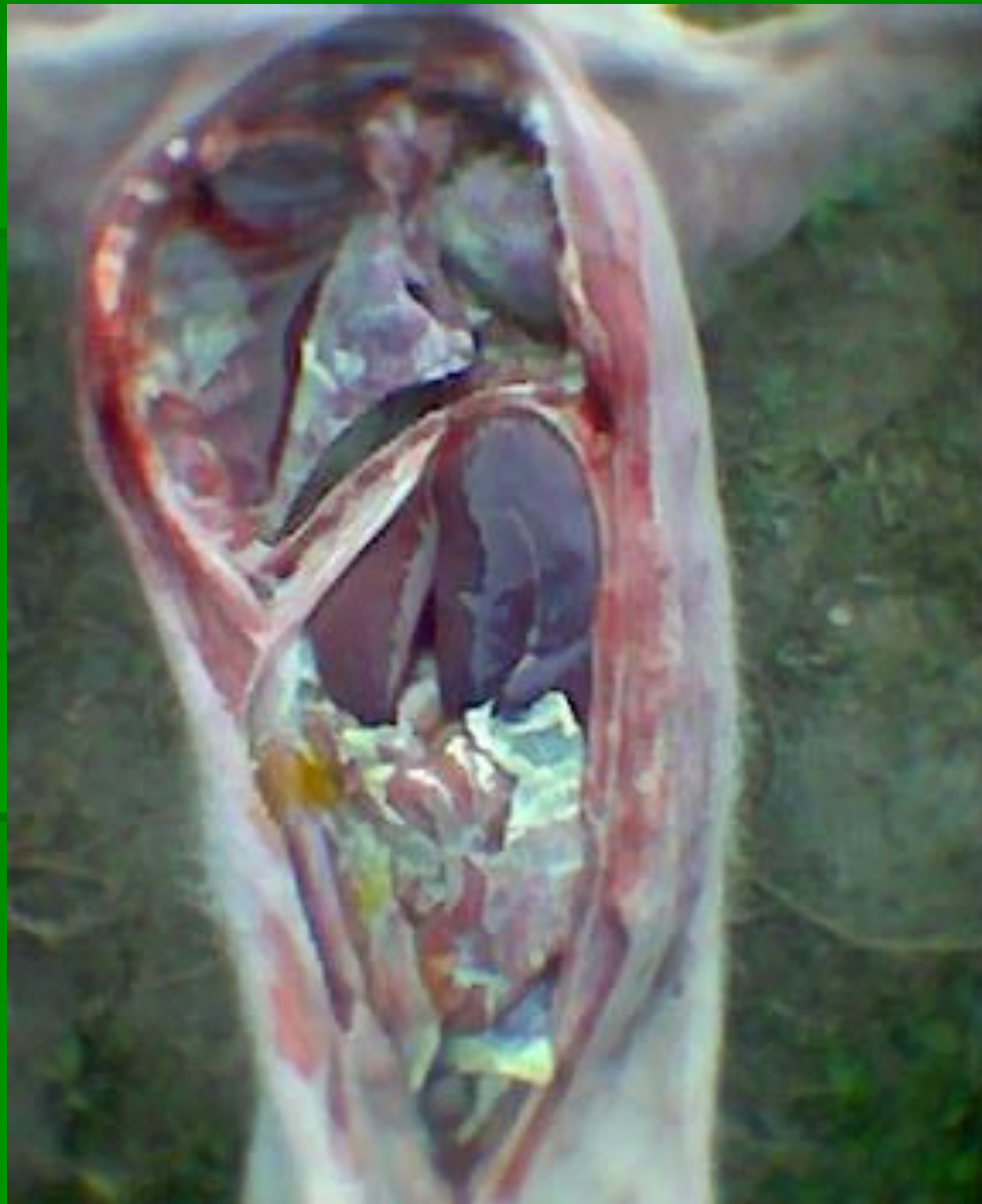

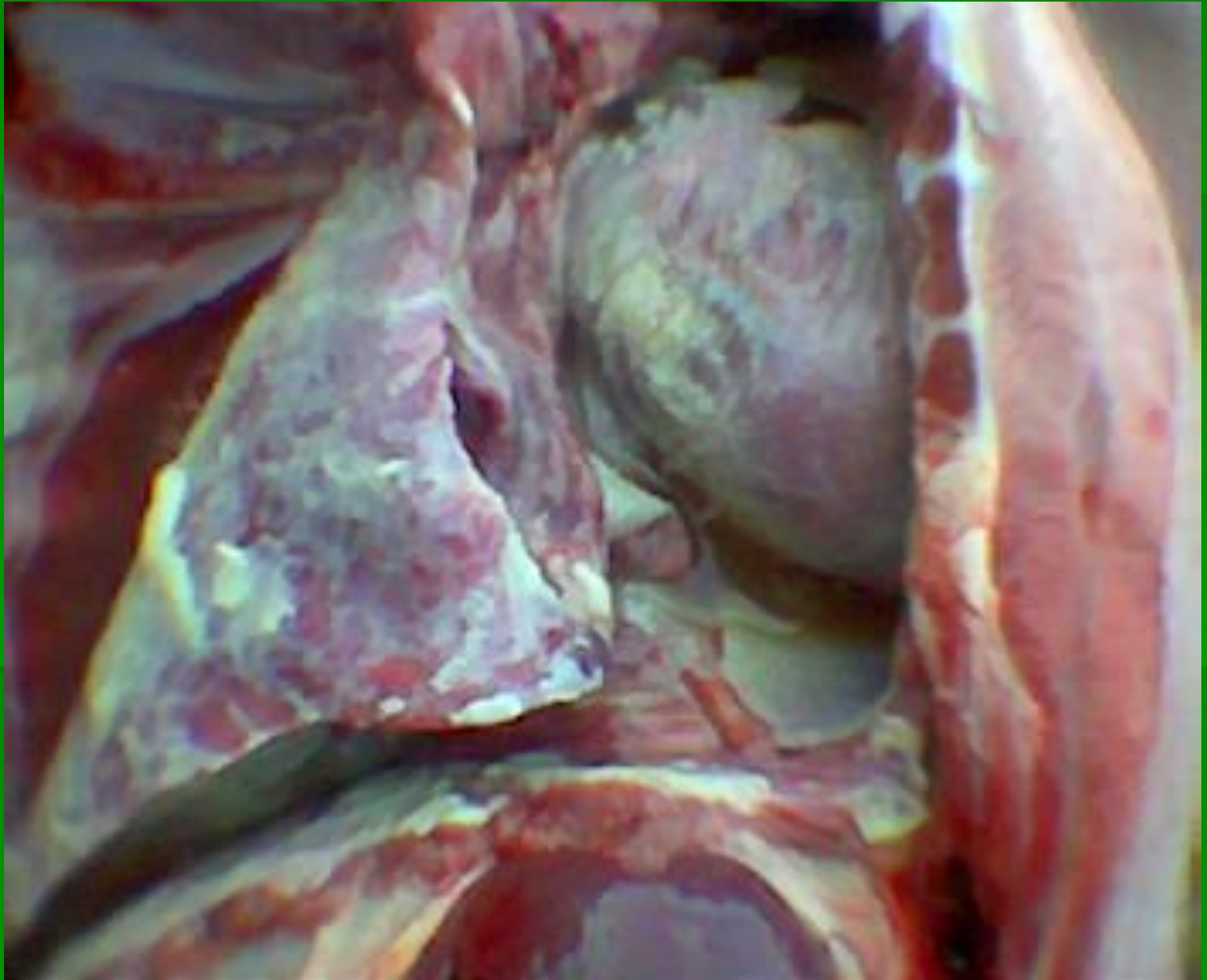





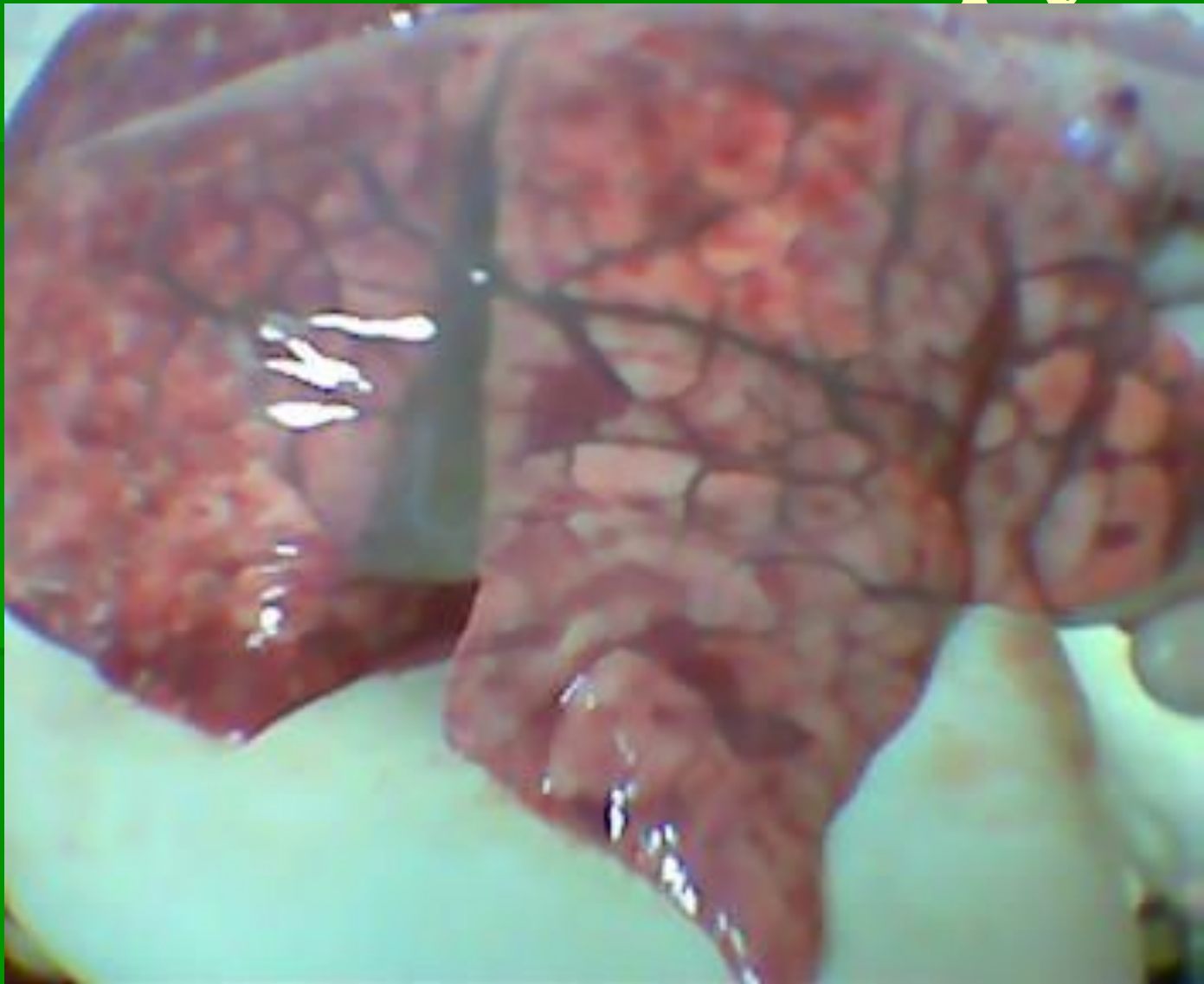


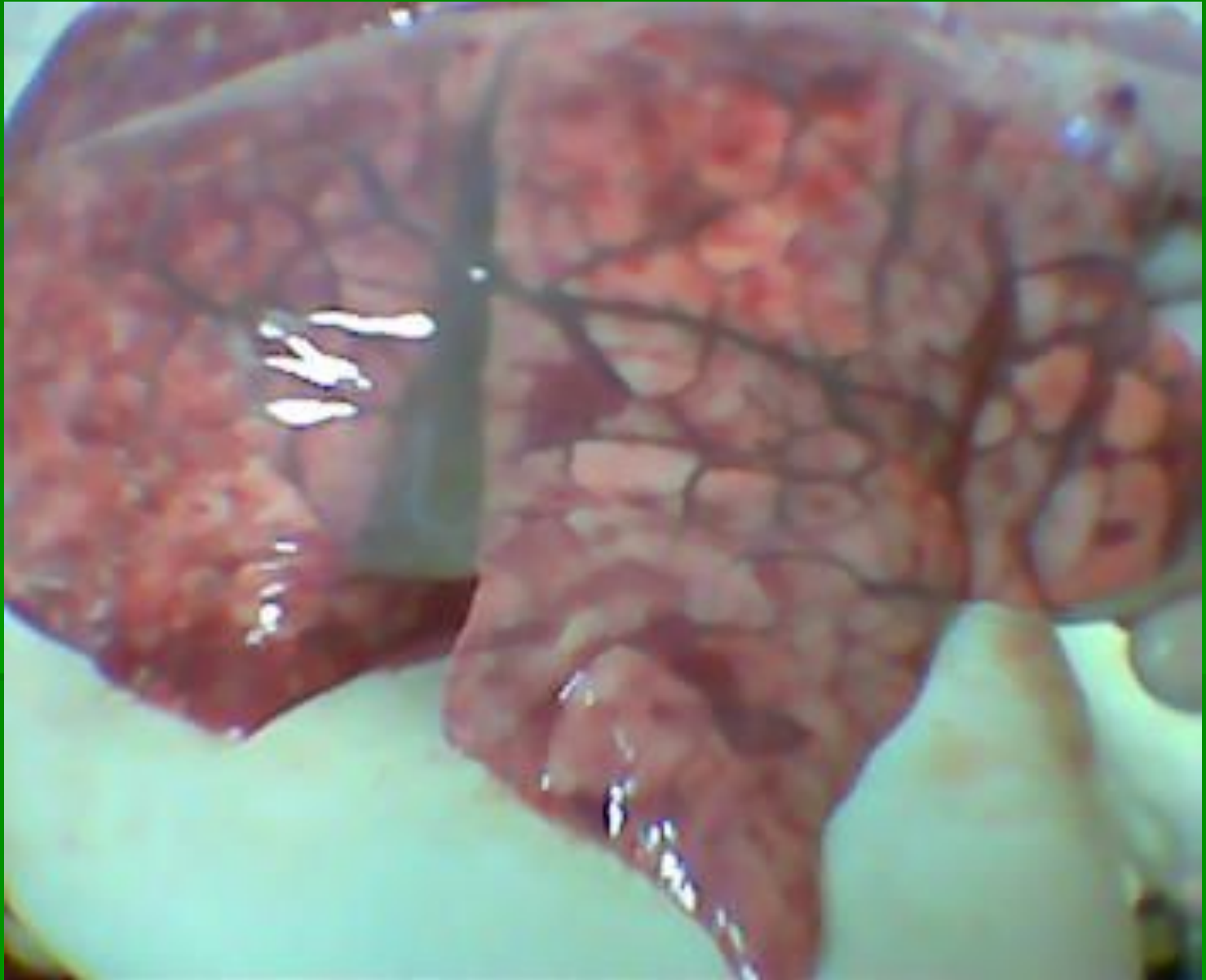


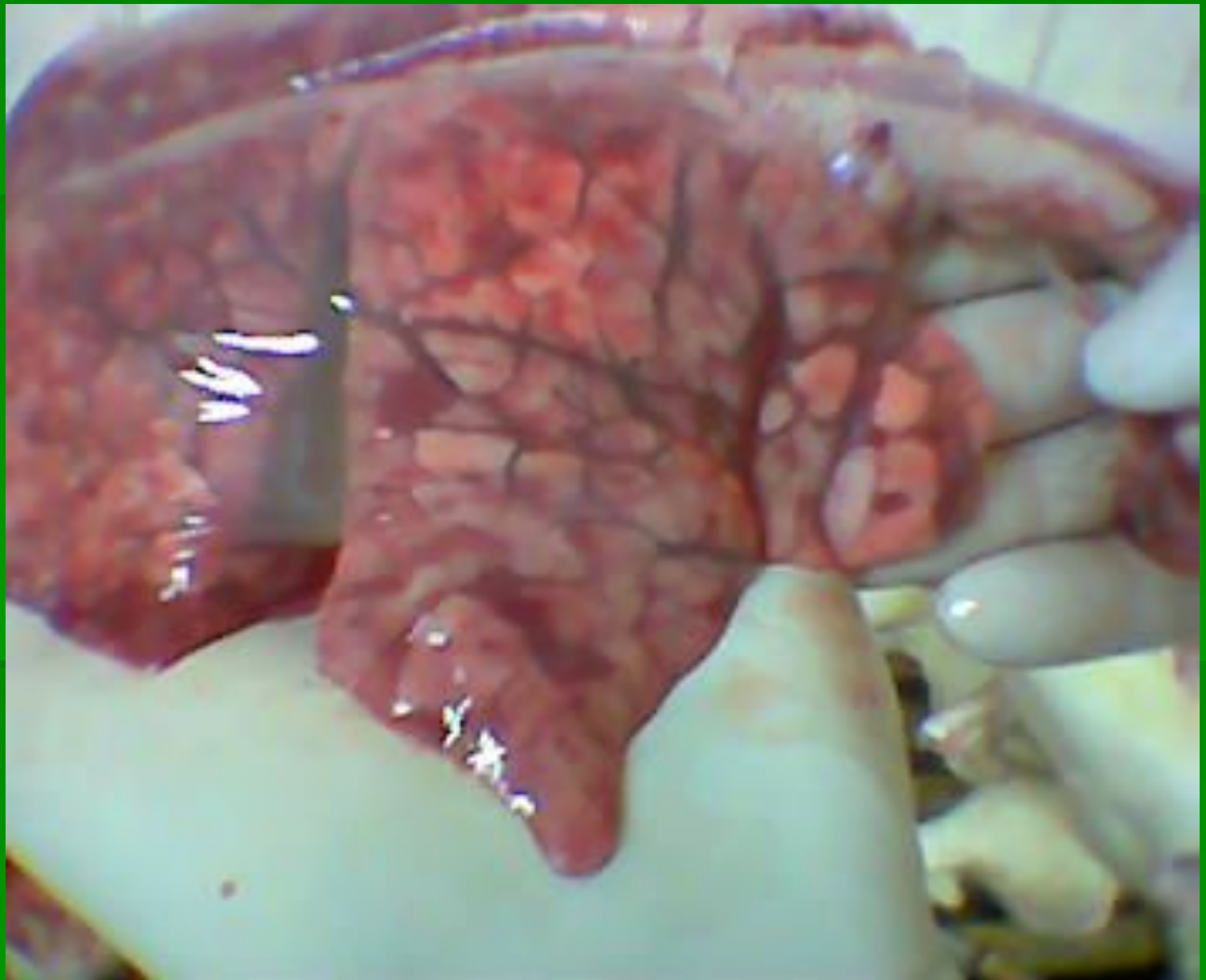
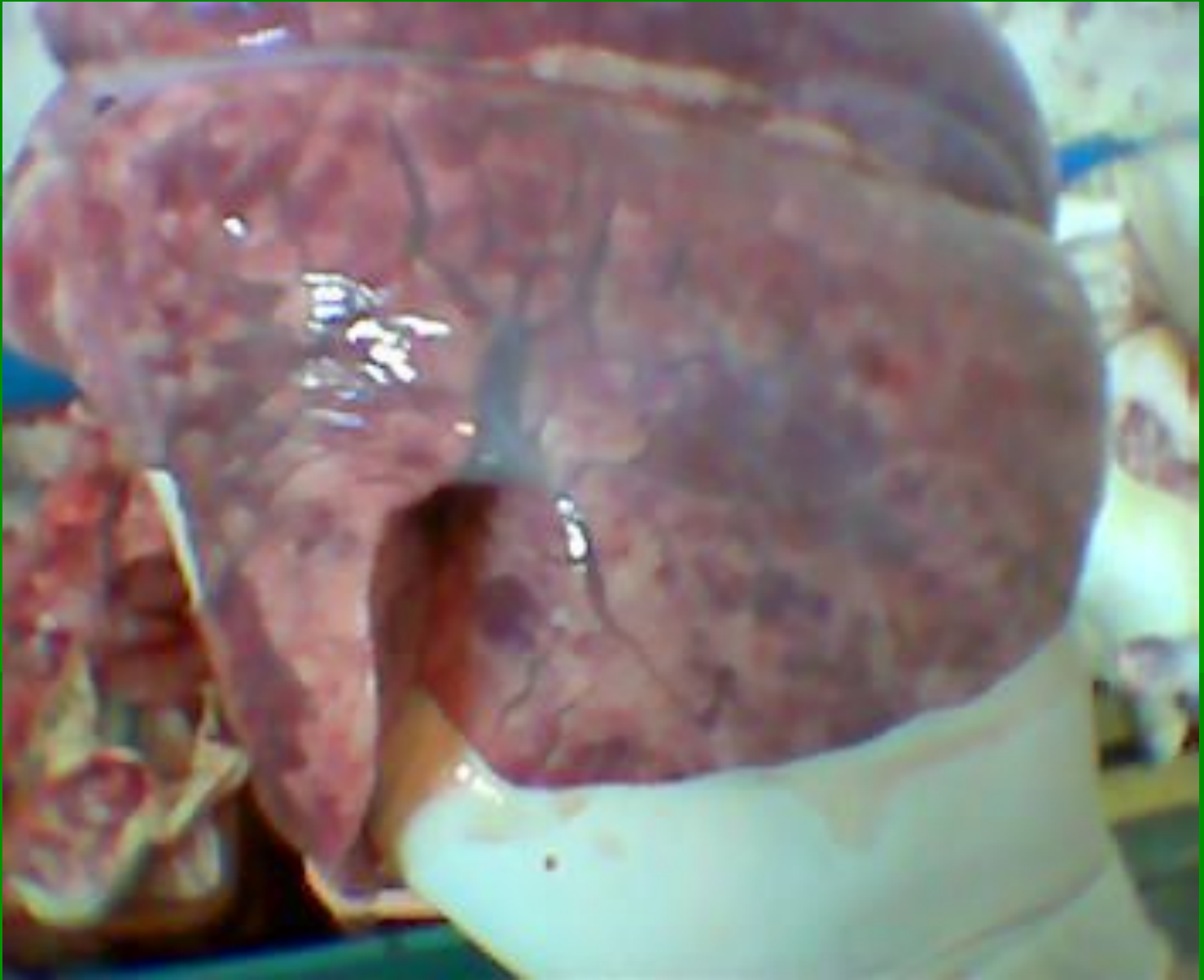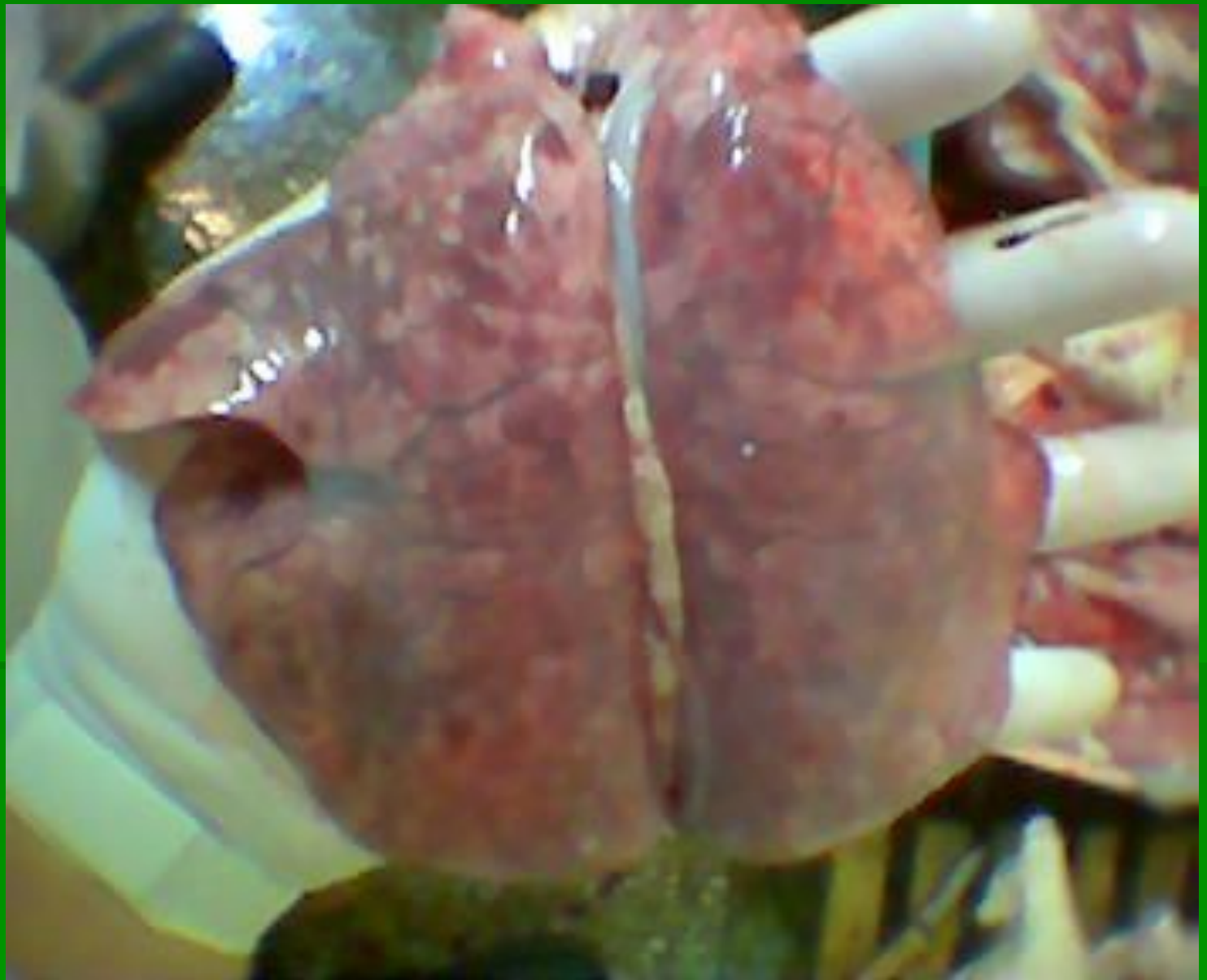Цитомегаловирус

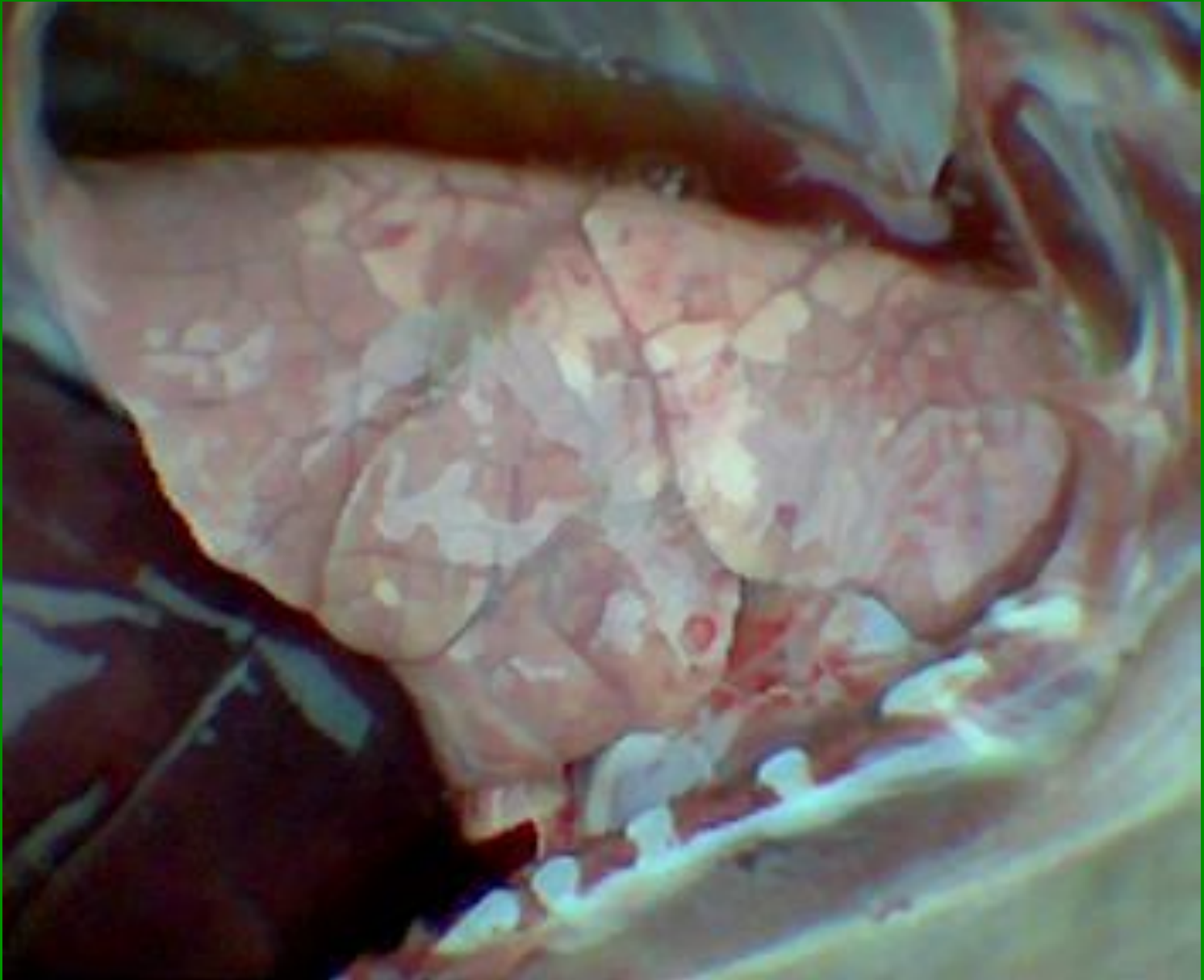


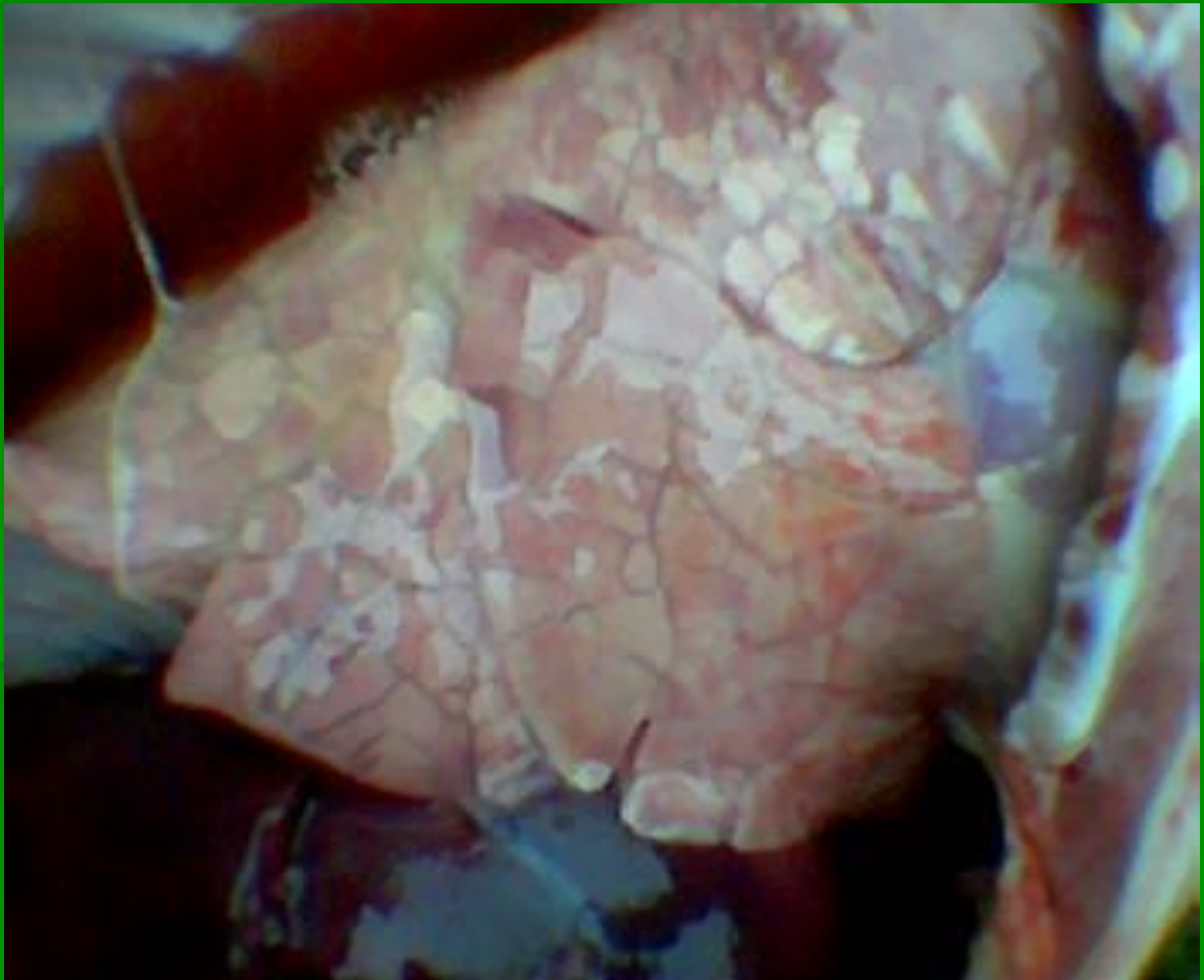


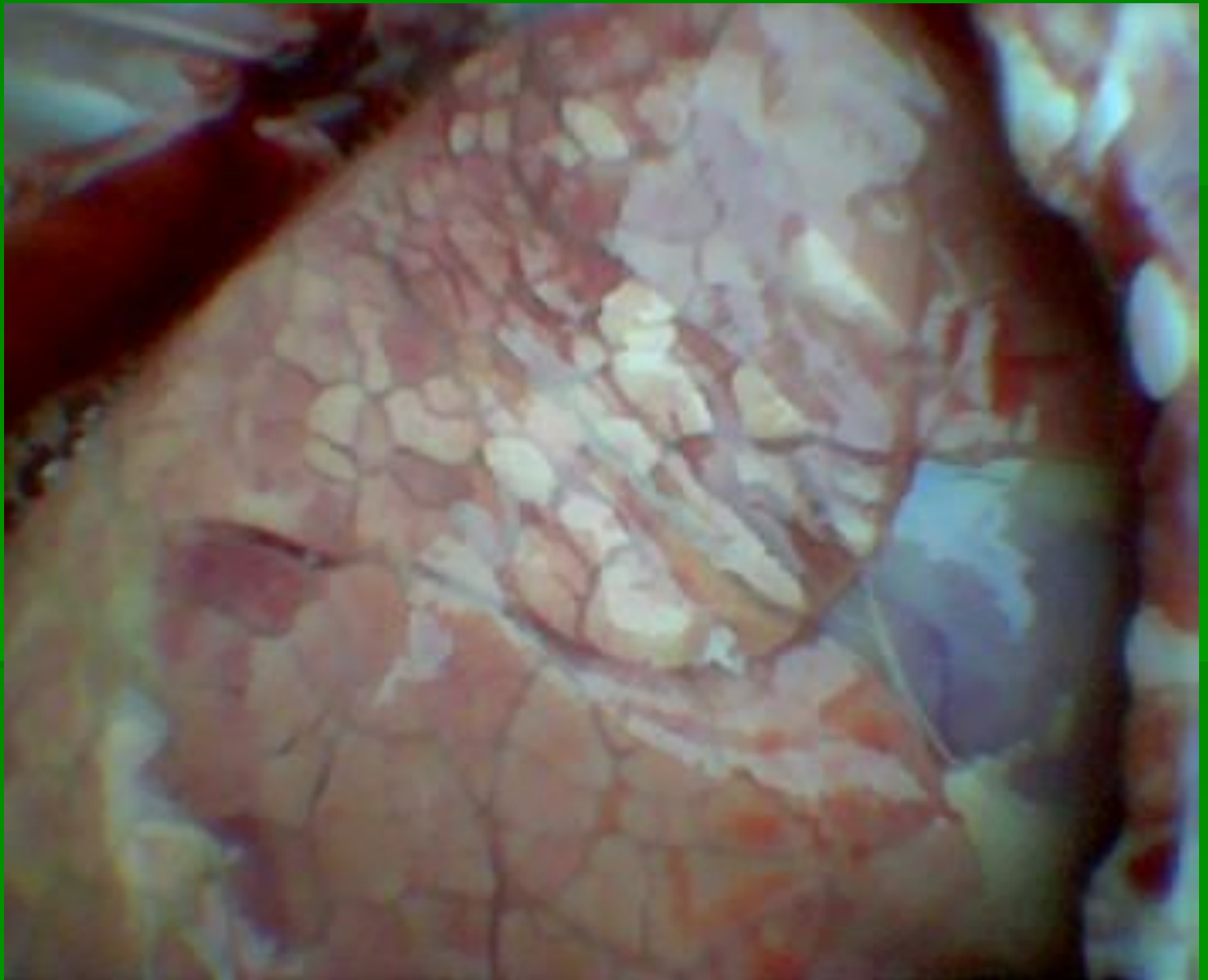




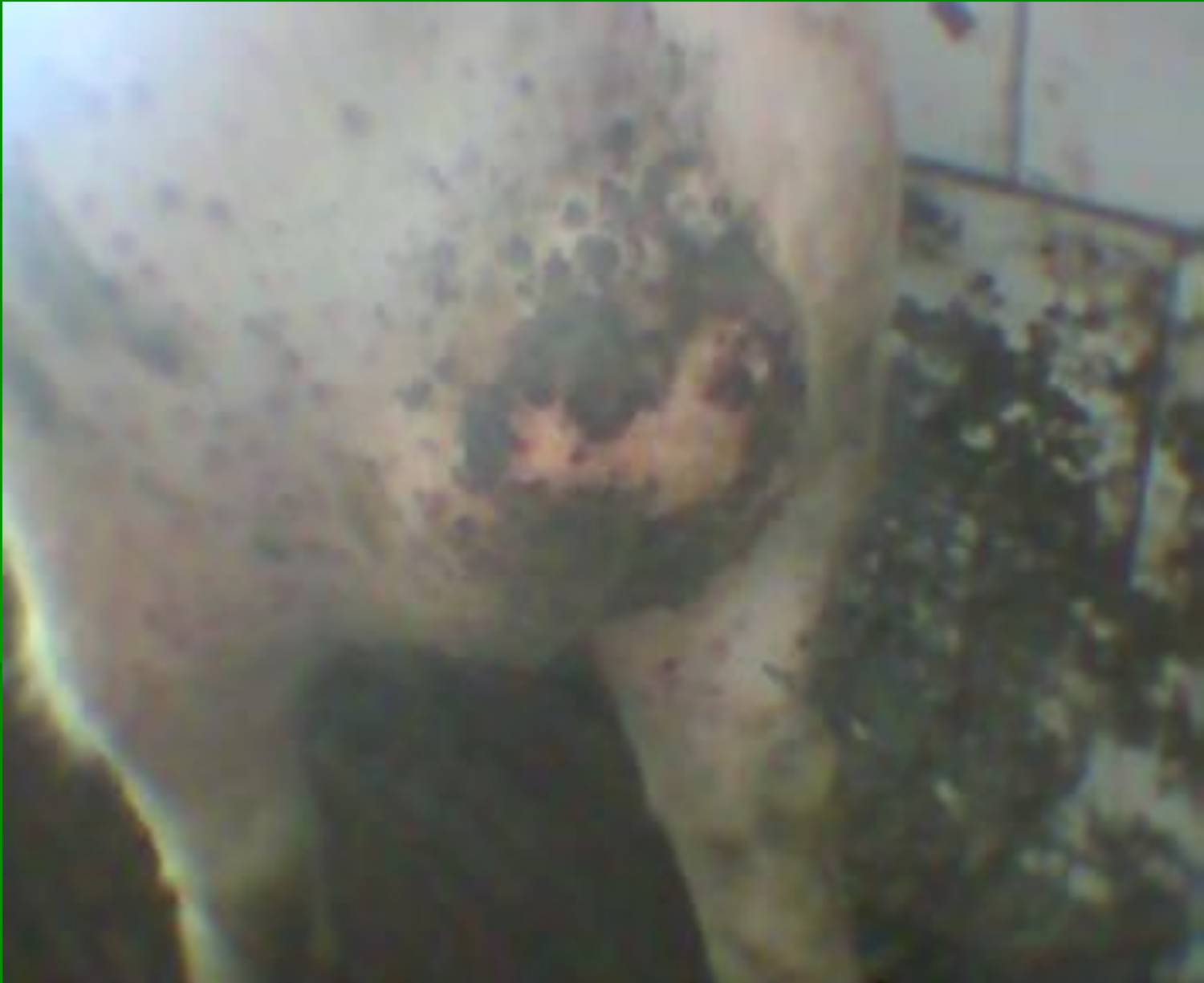


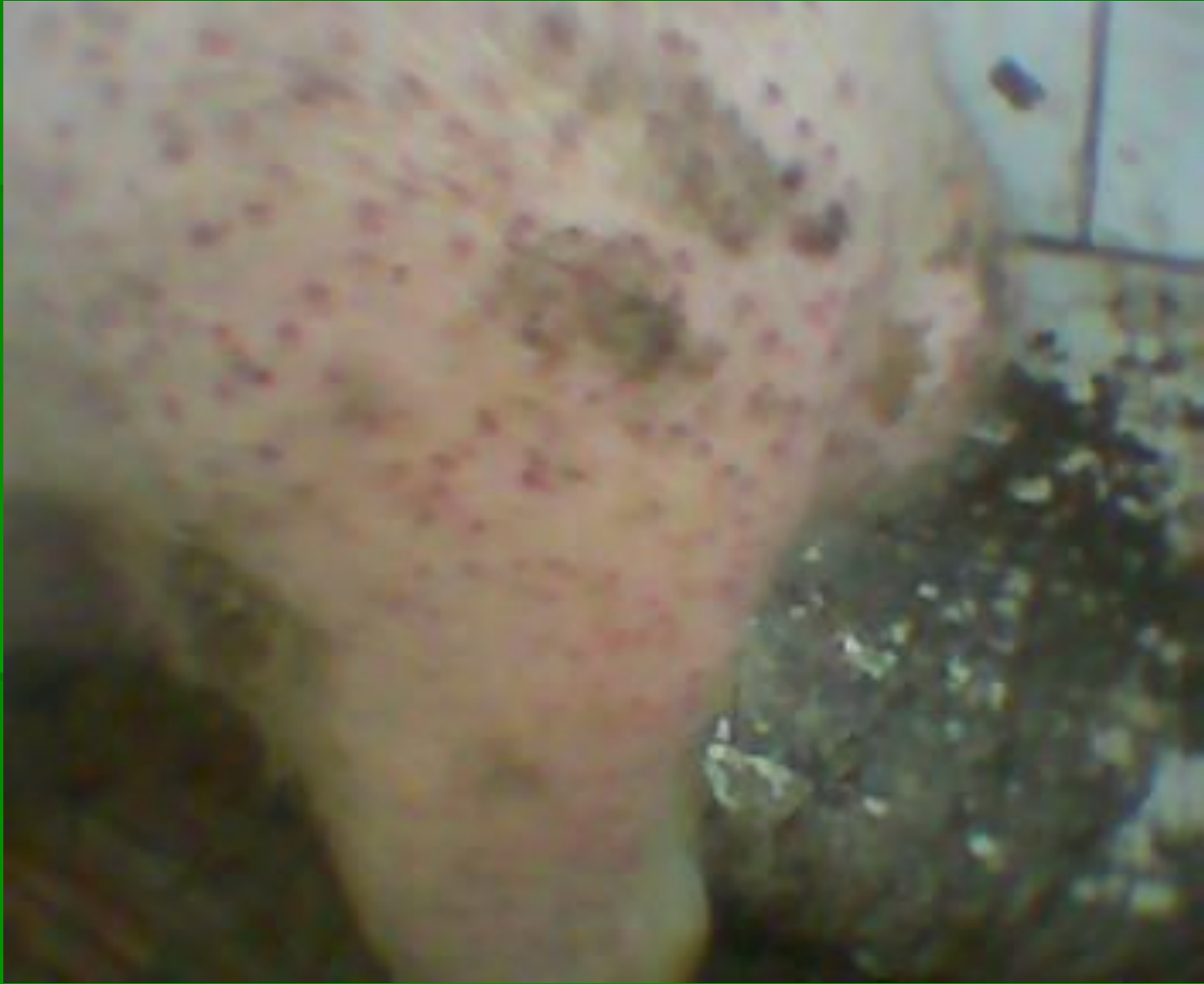


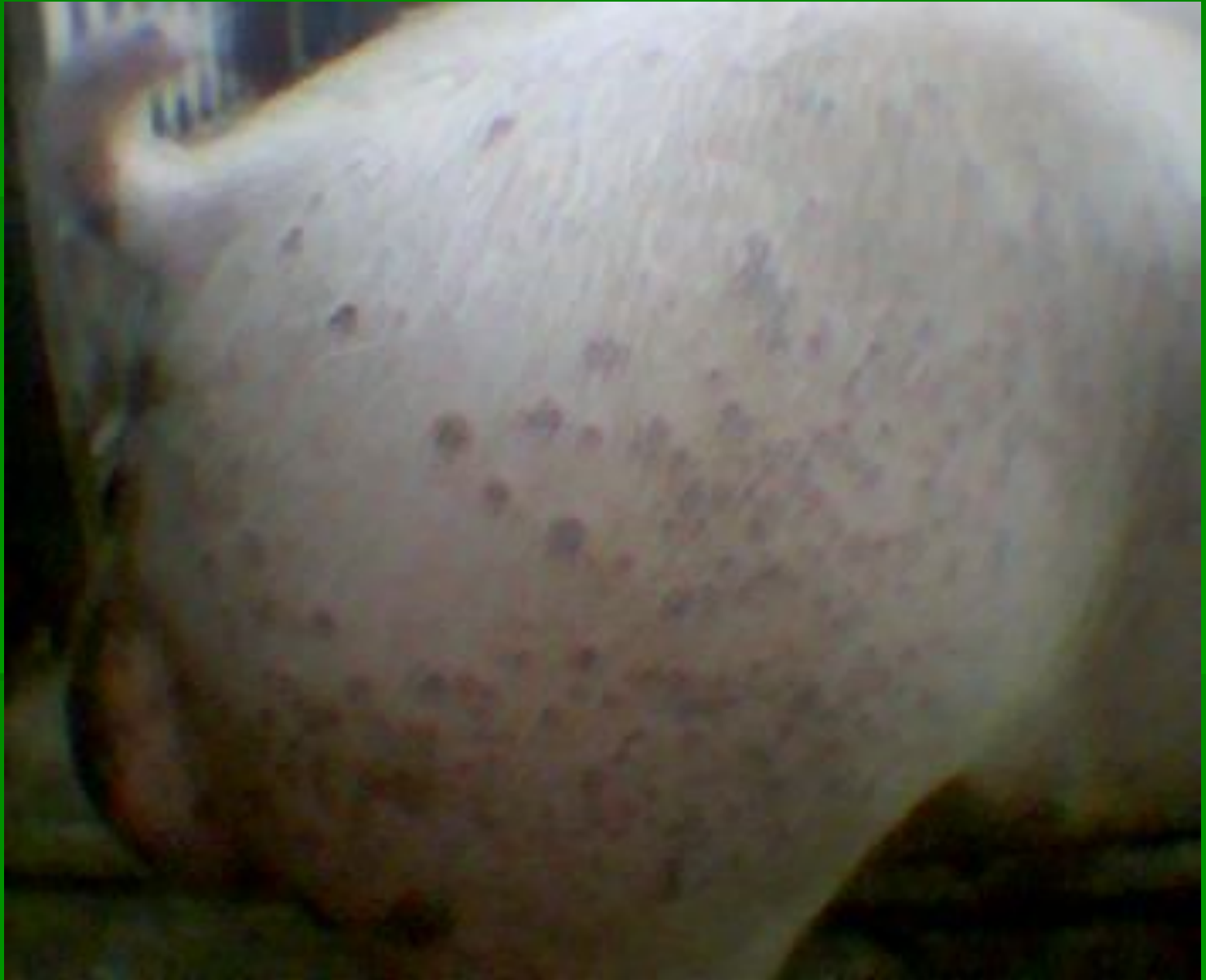

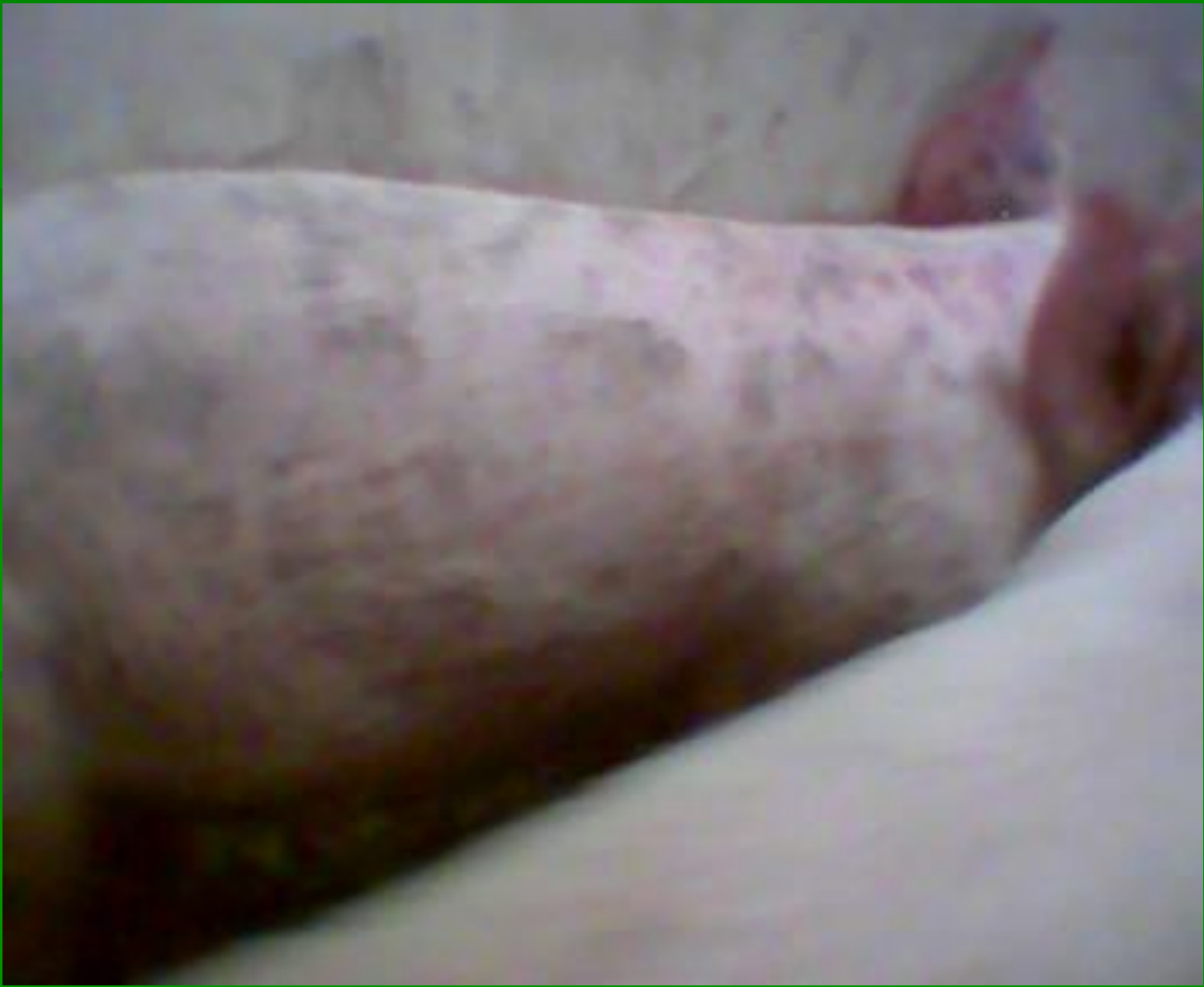Кожно- почечный синдром

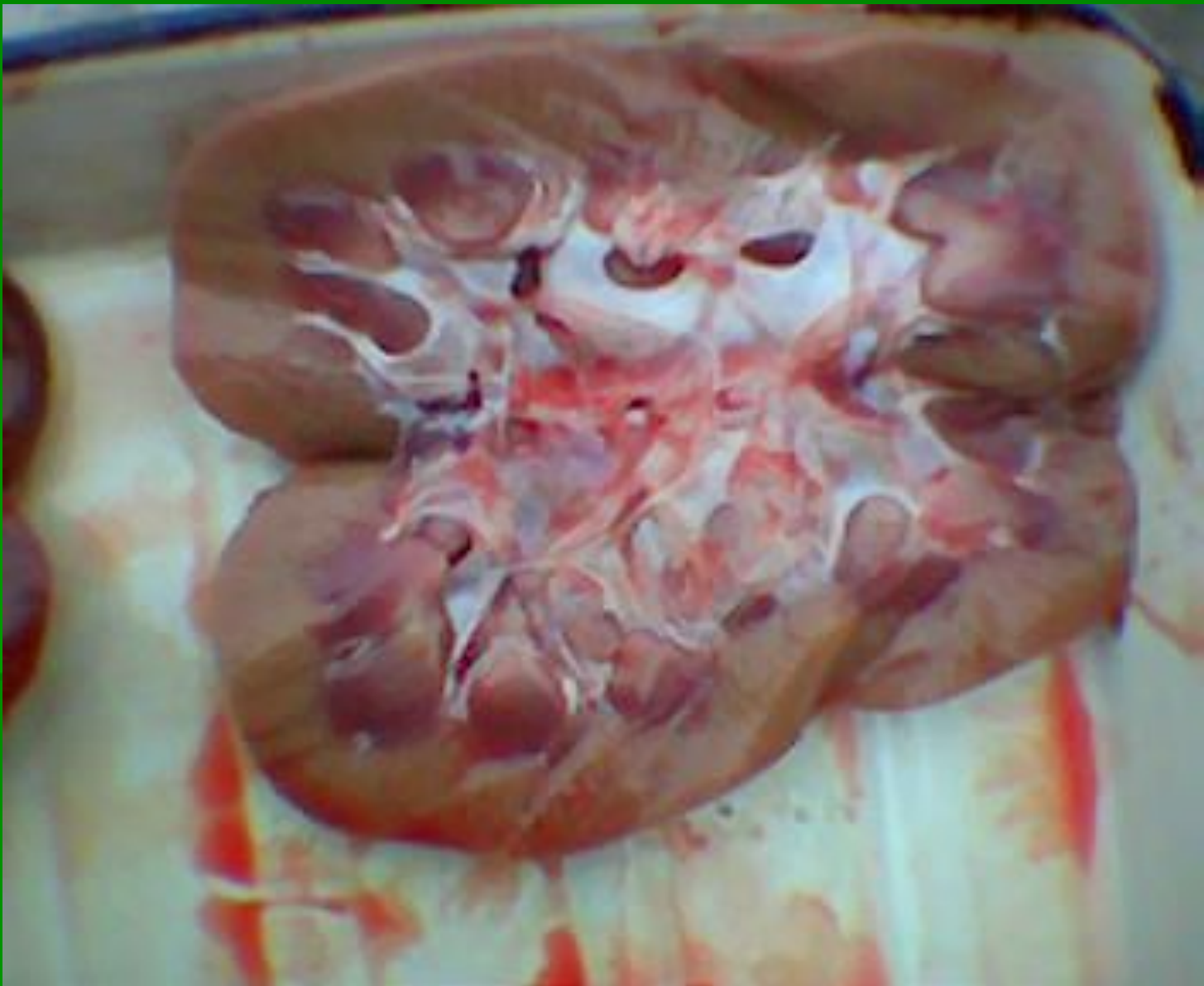


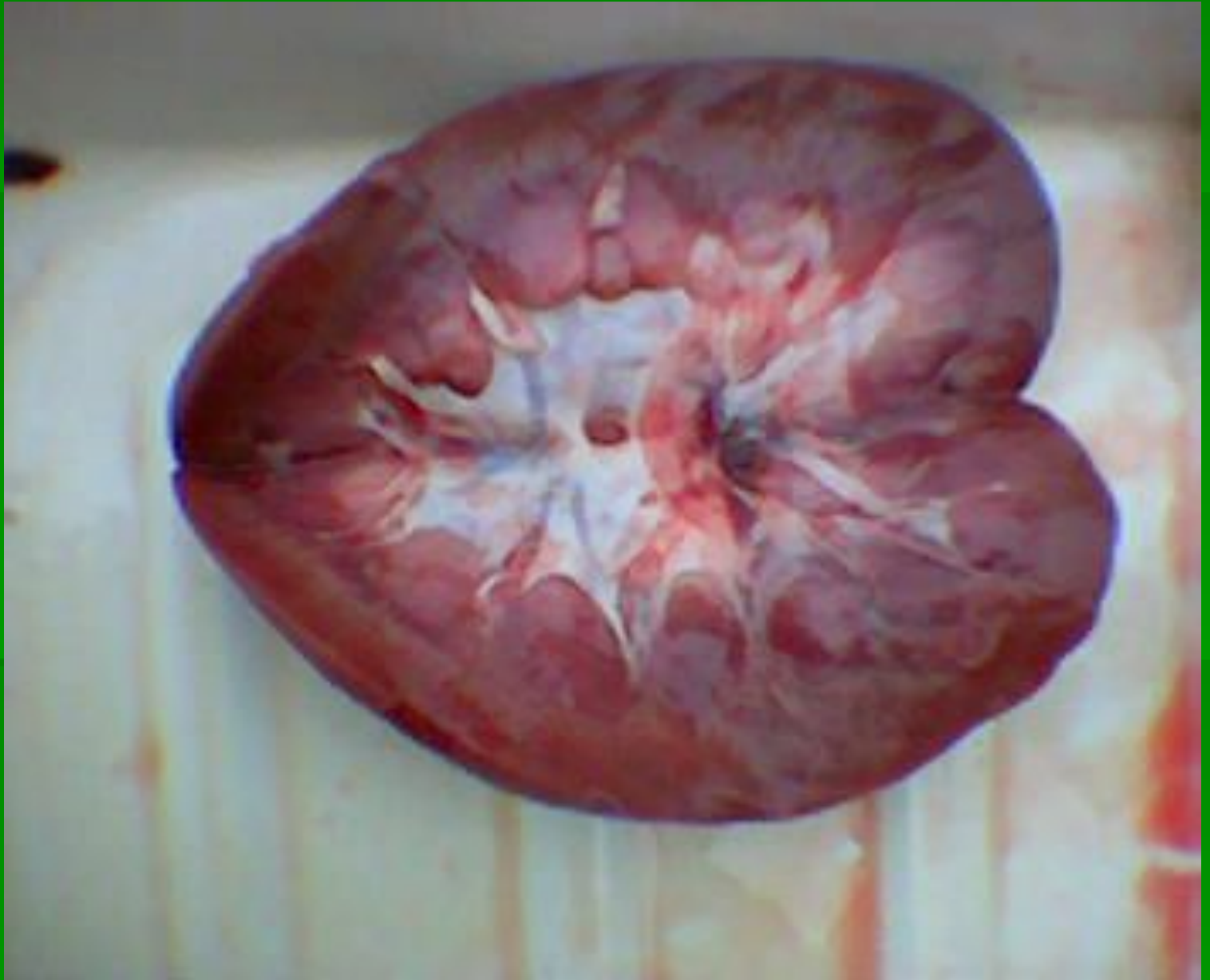






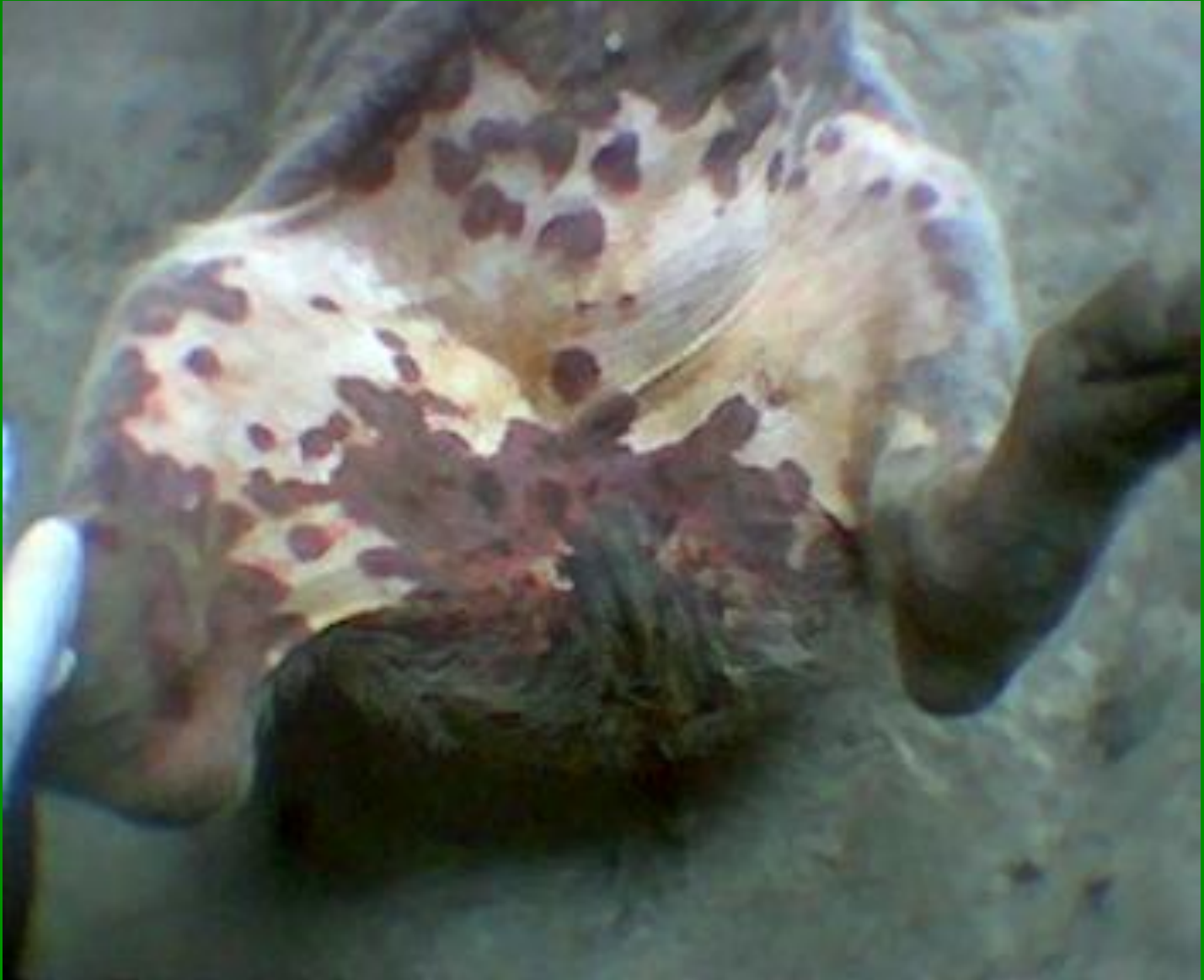


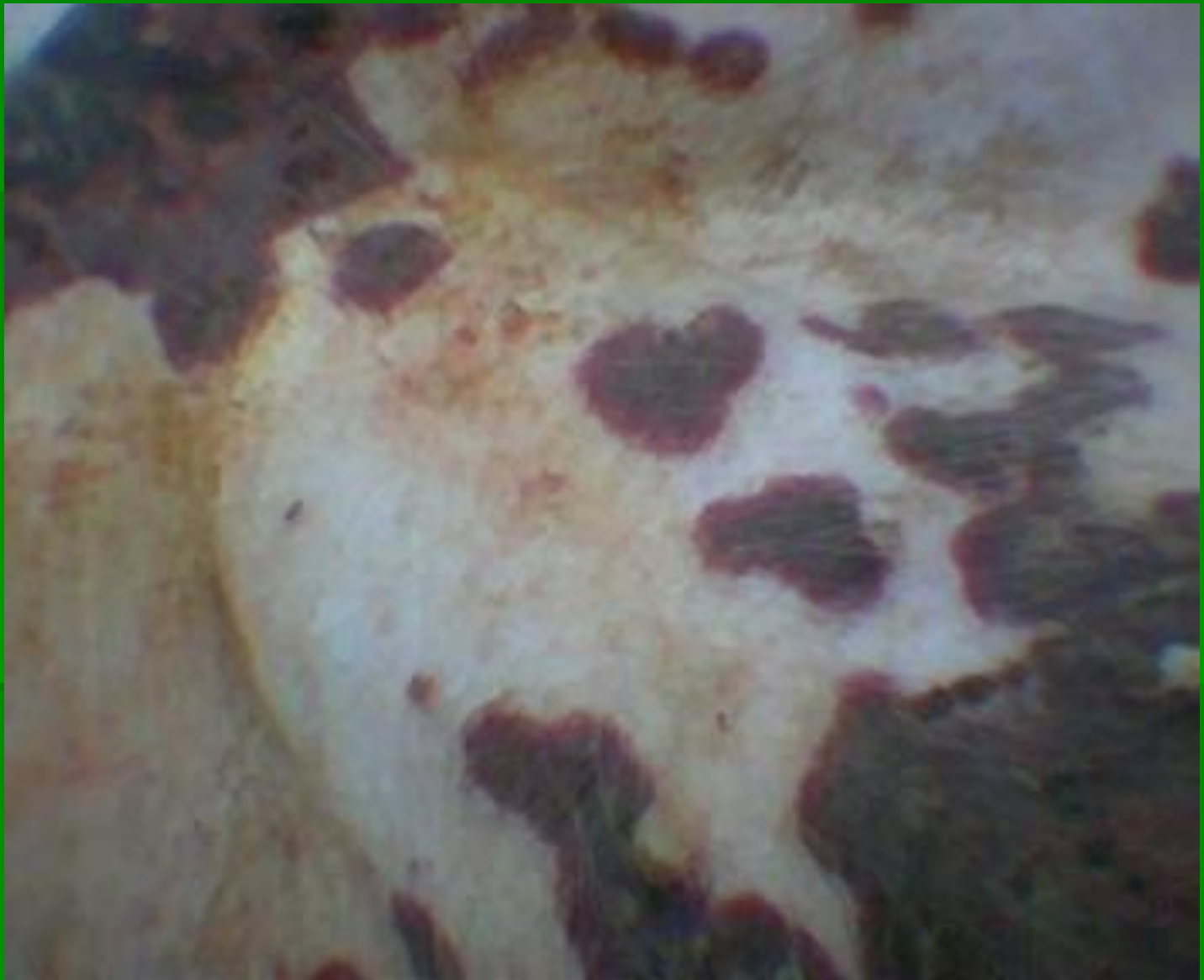


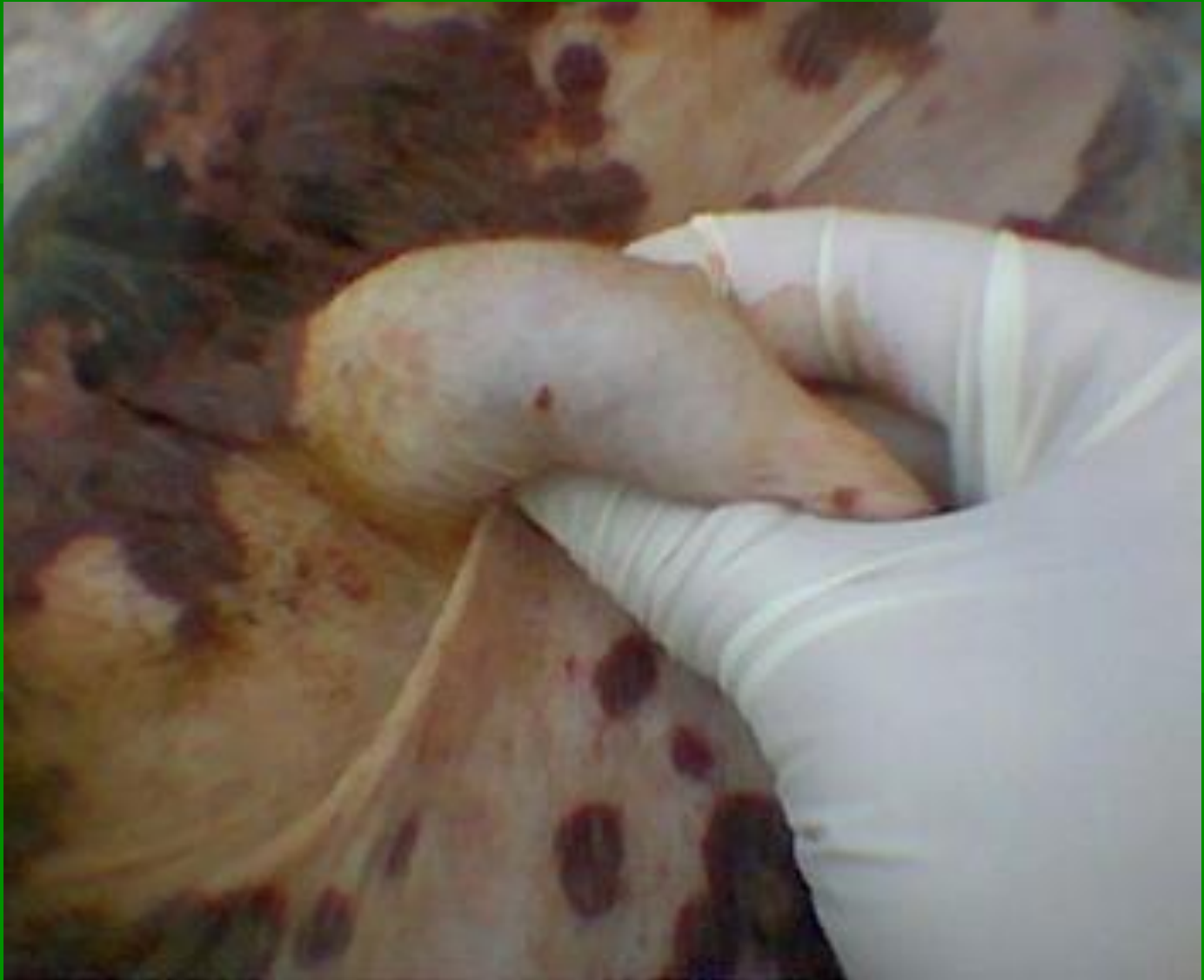


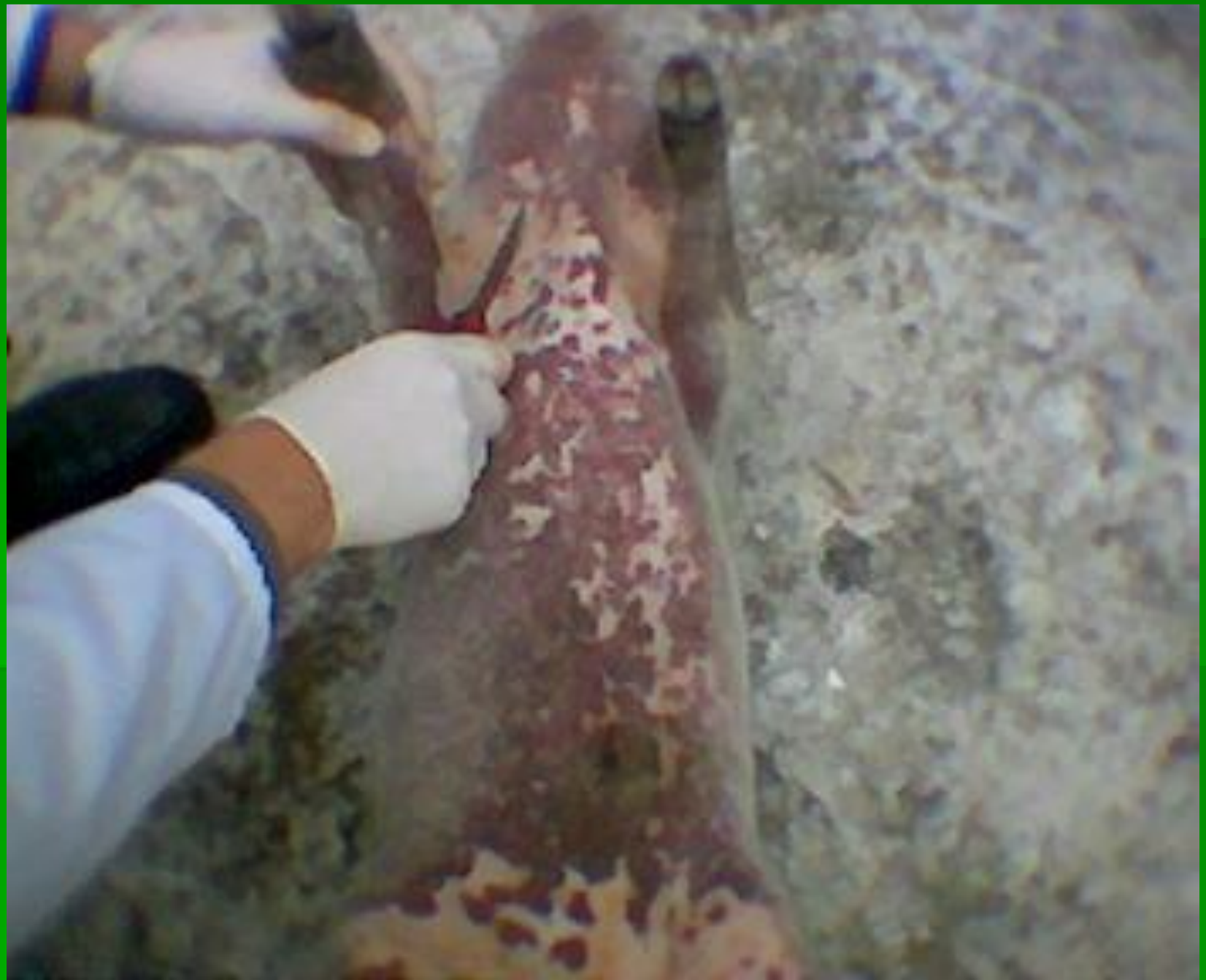


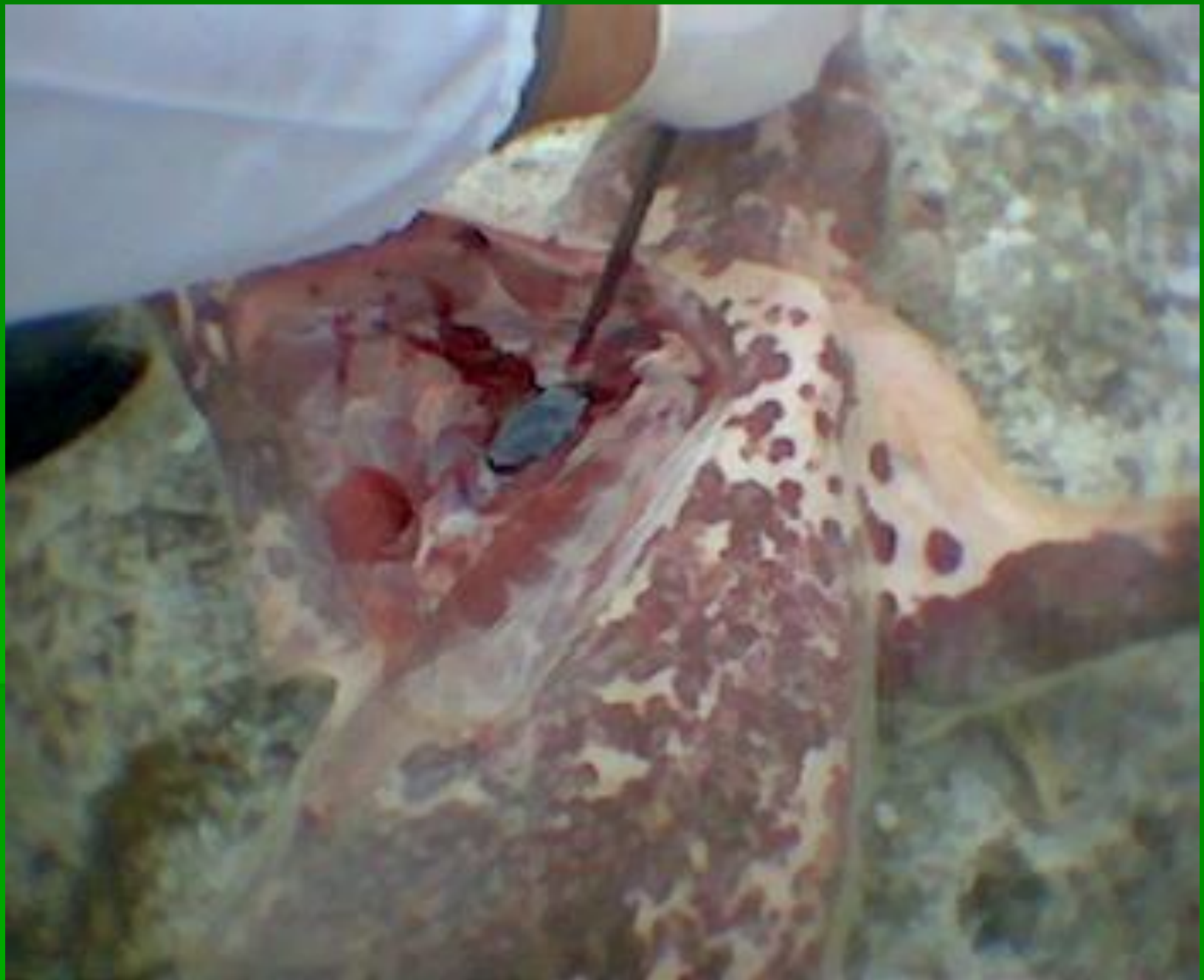


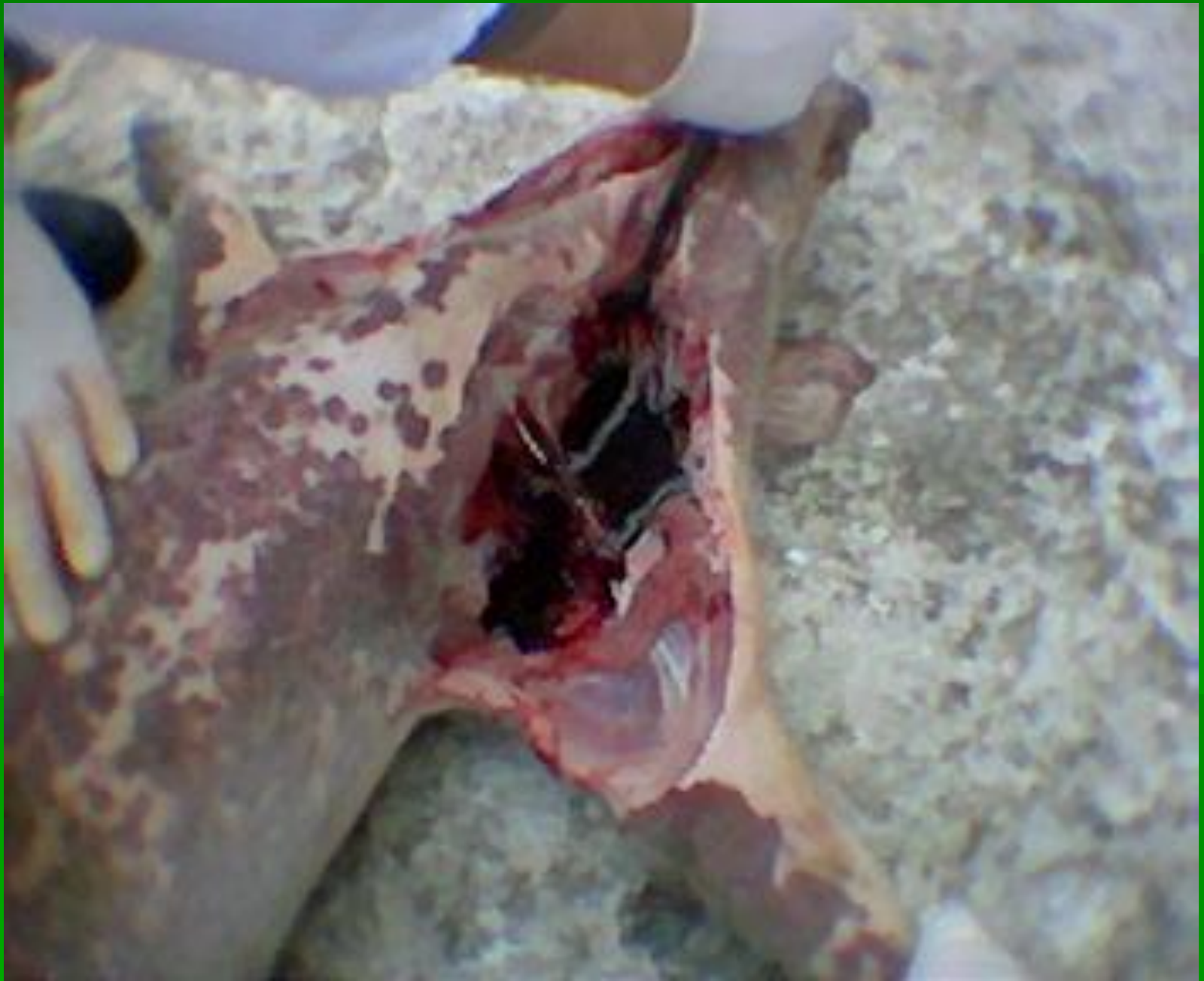
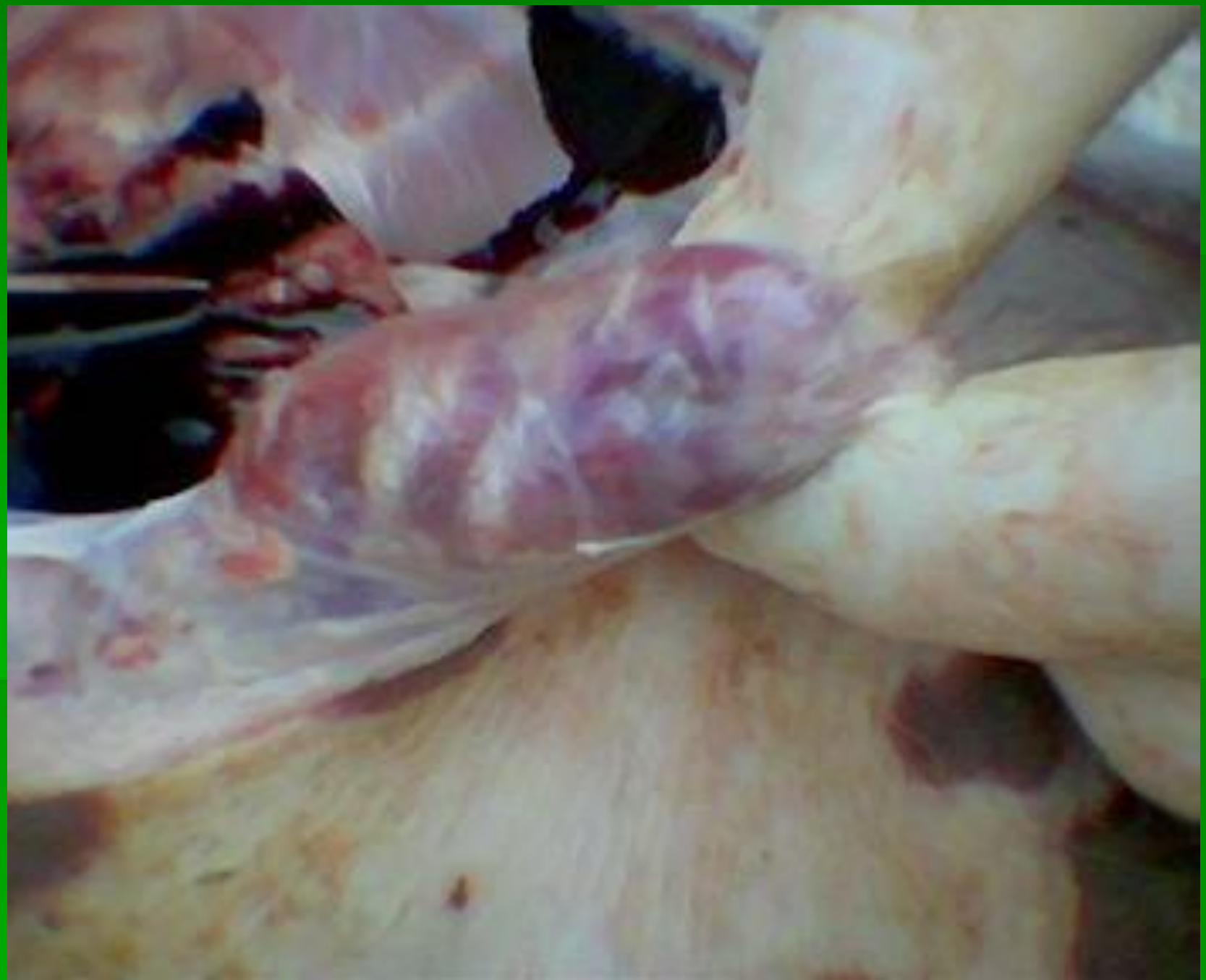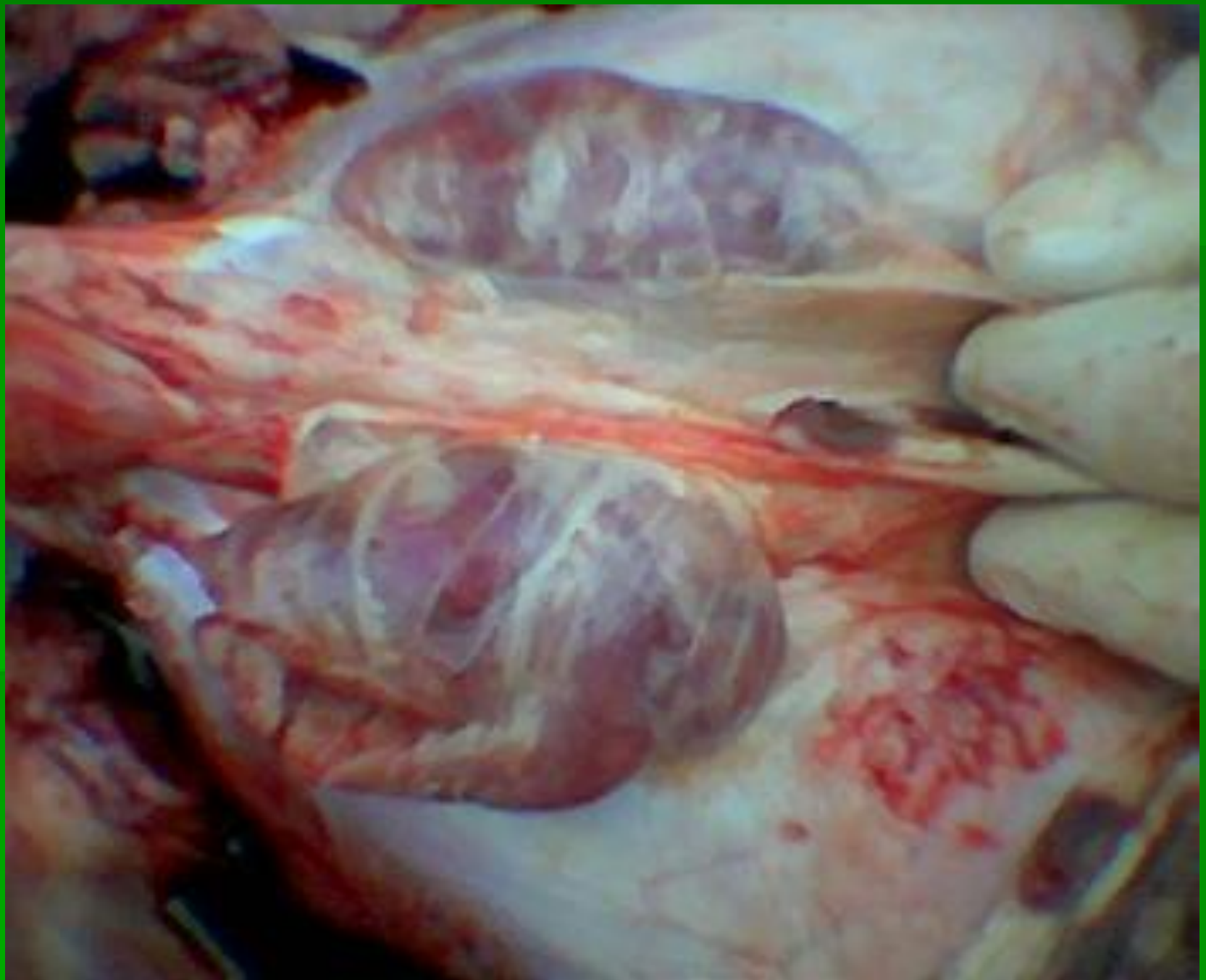






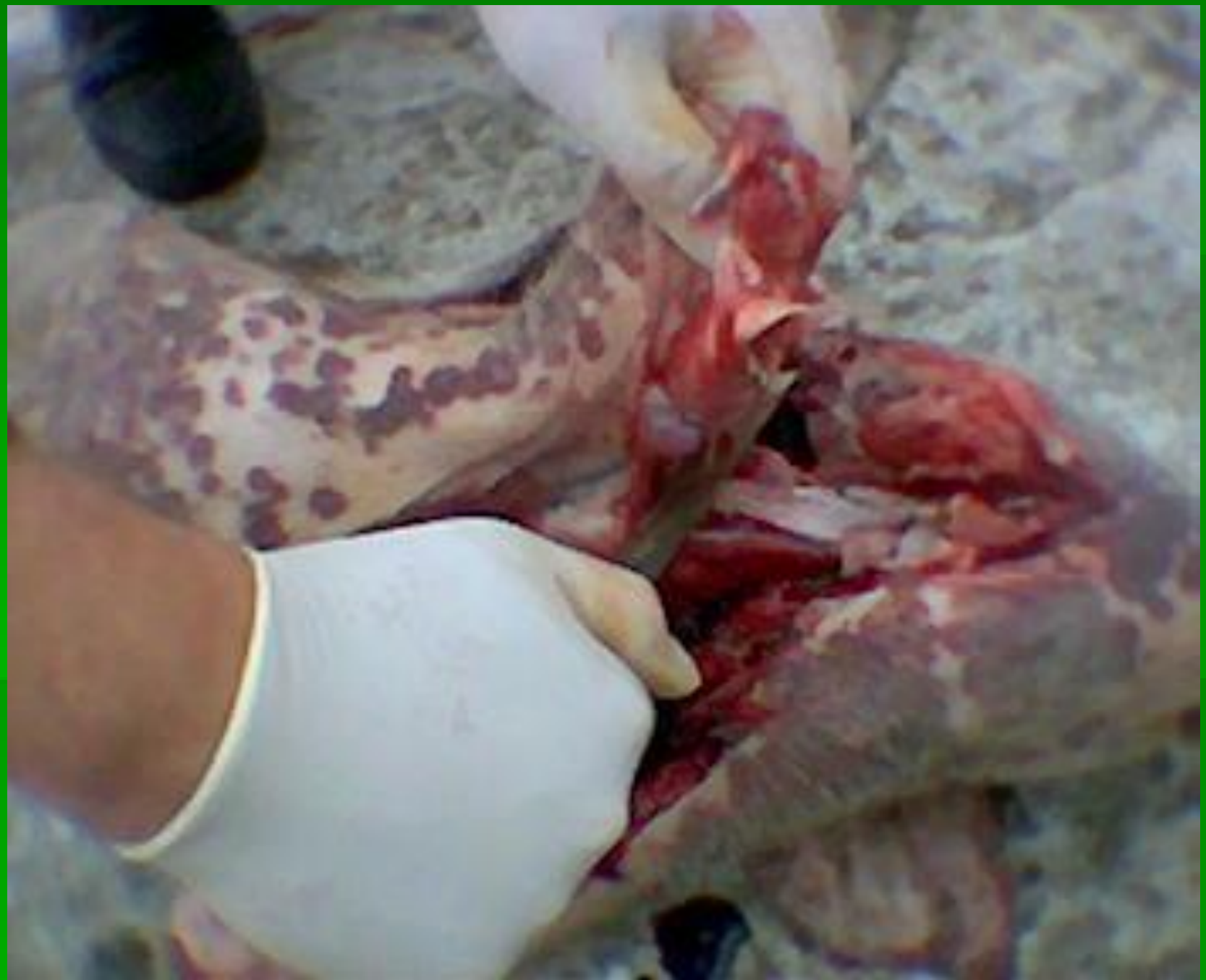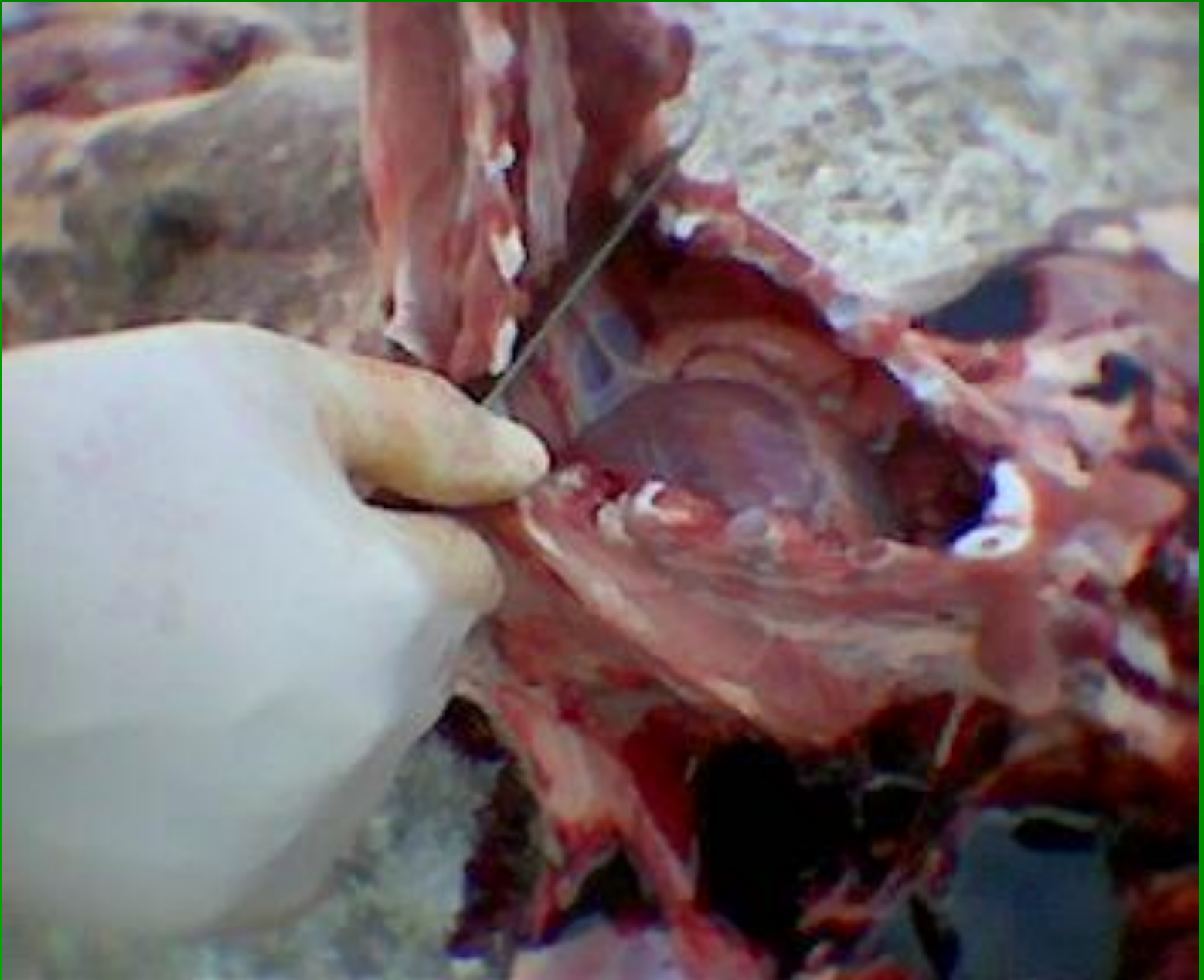




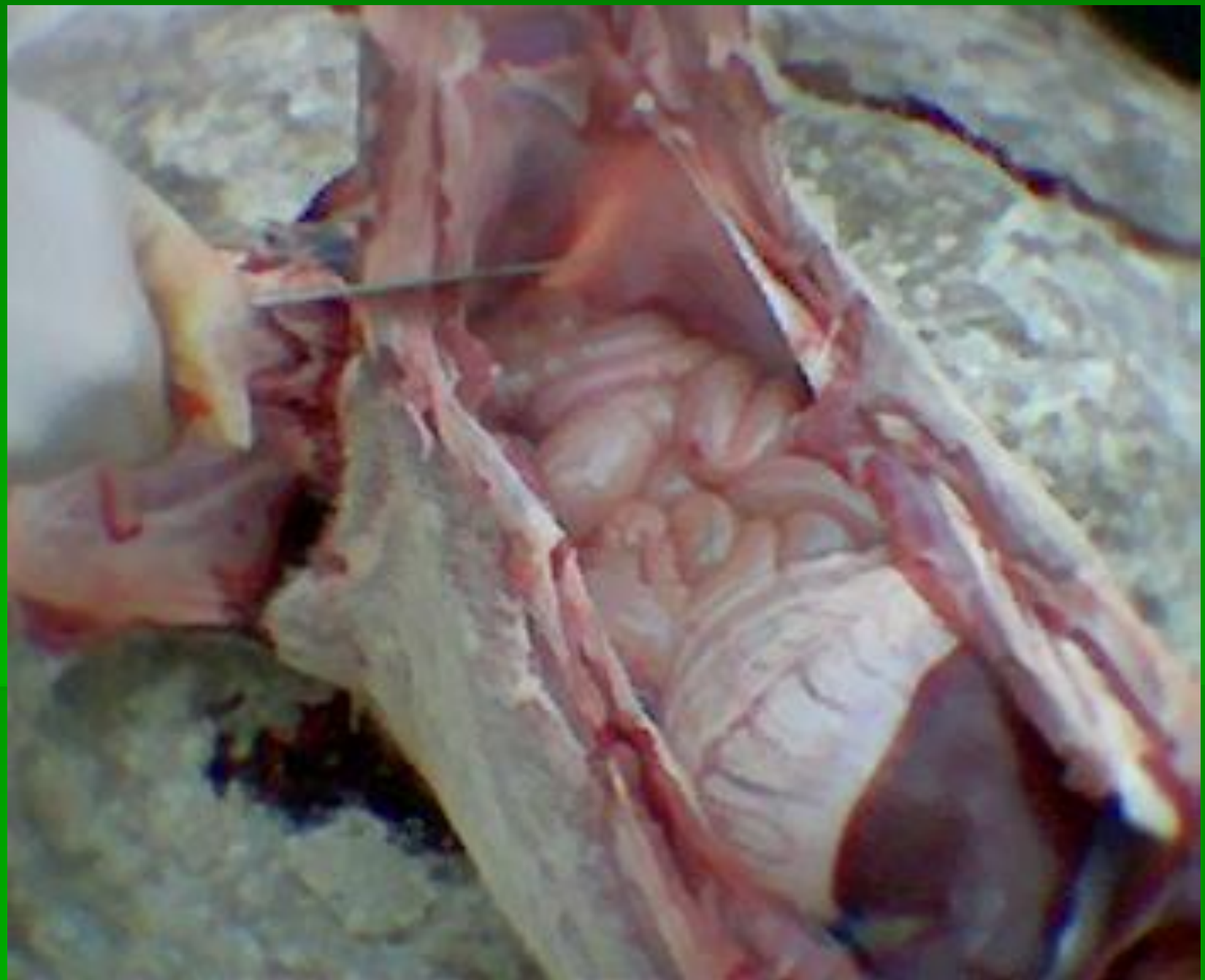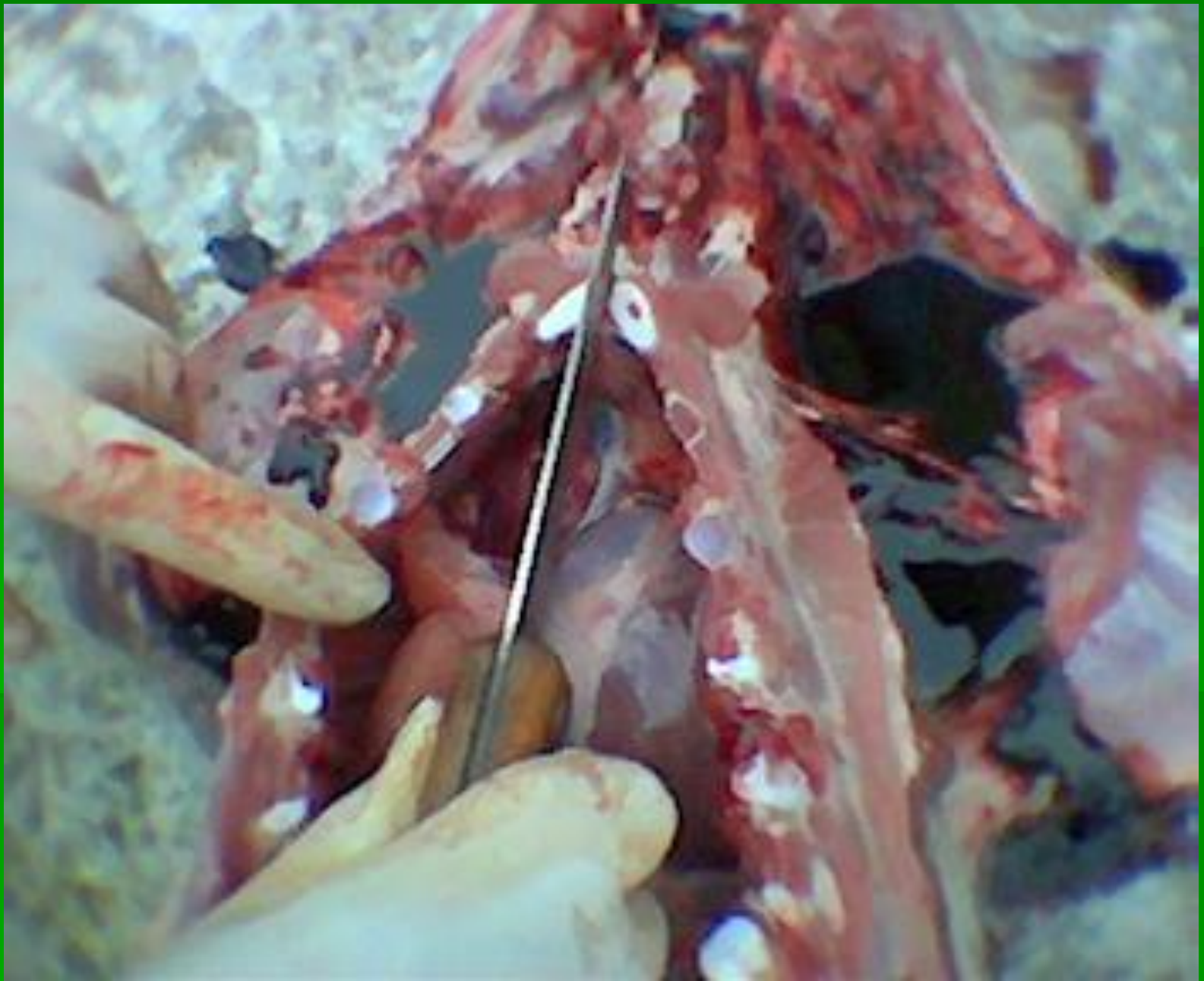




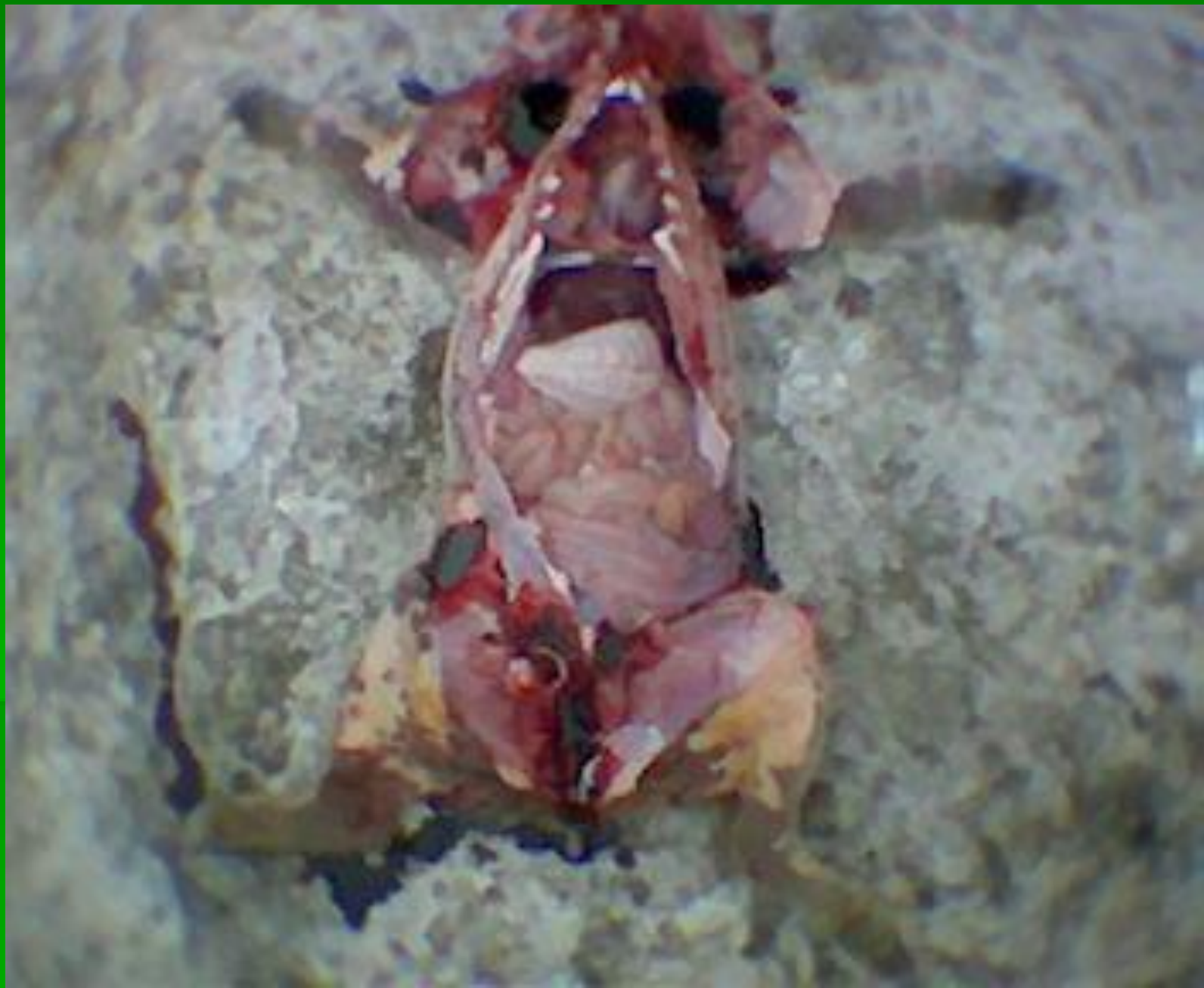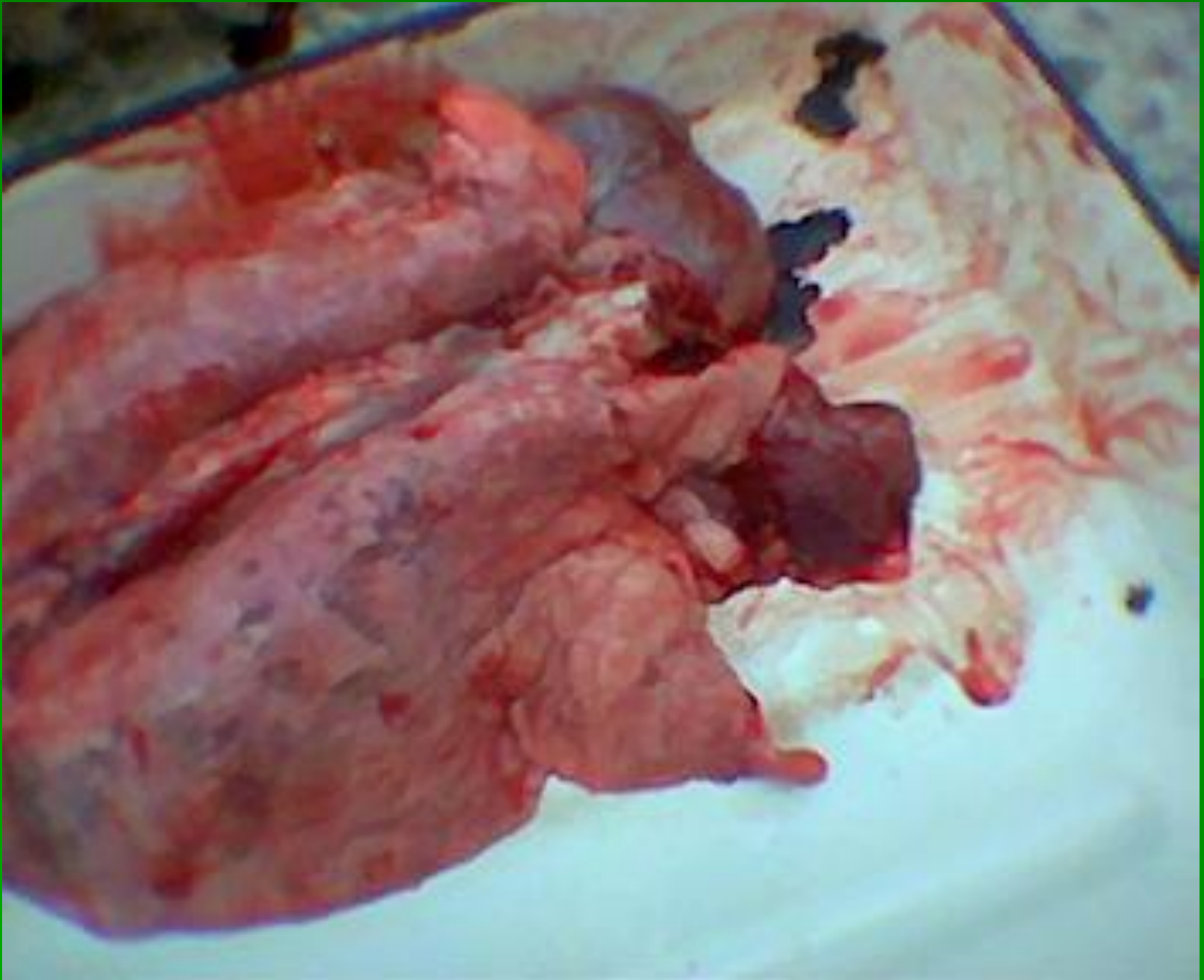


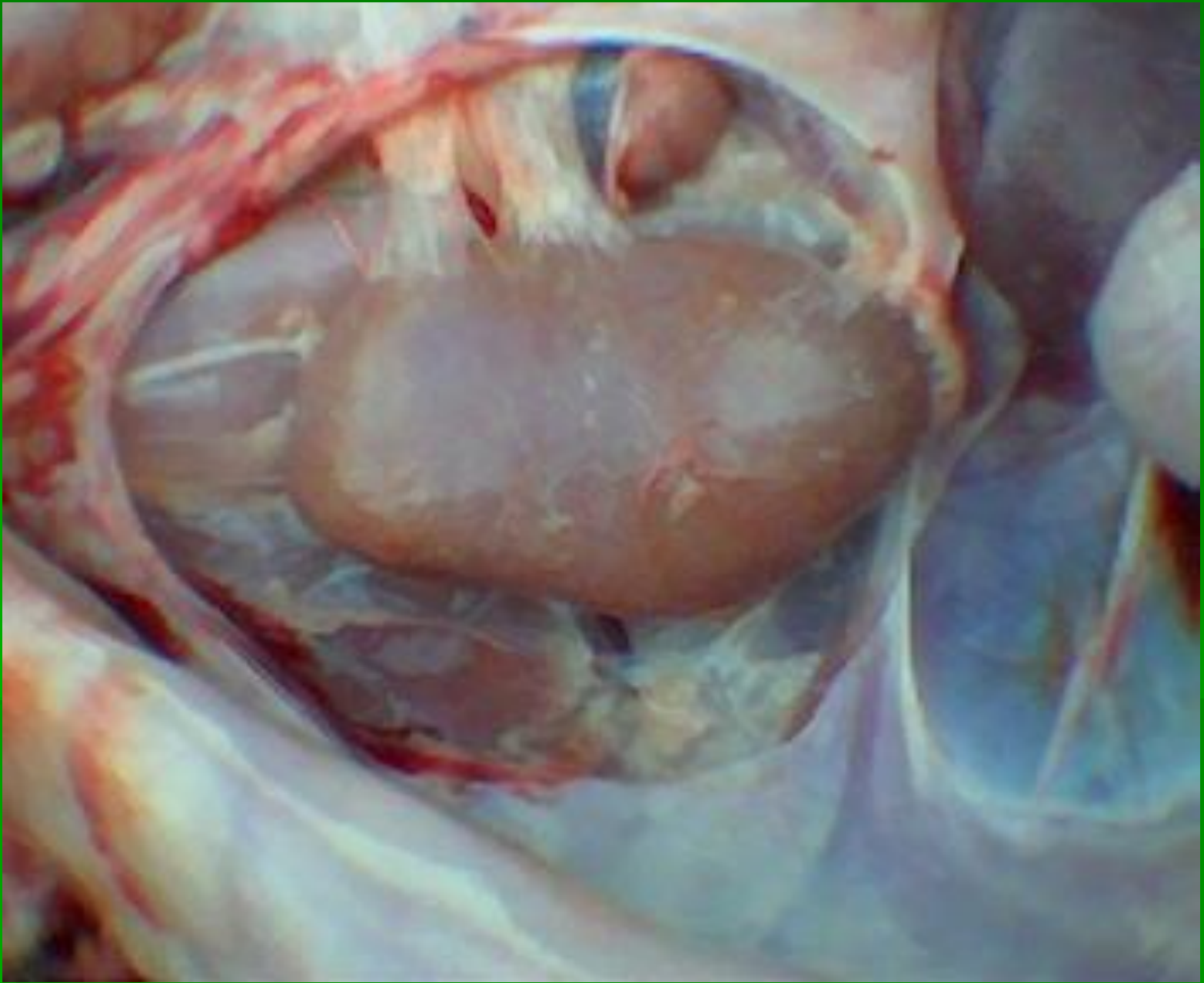












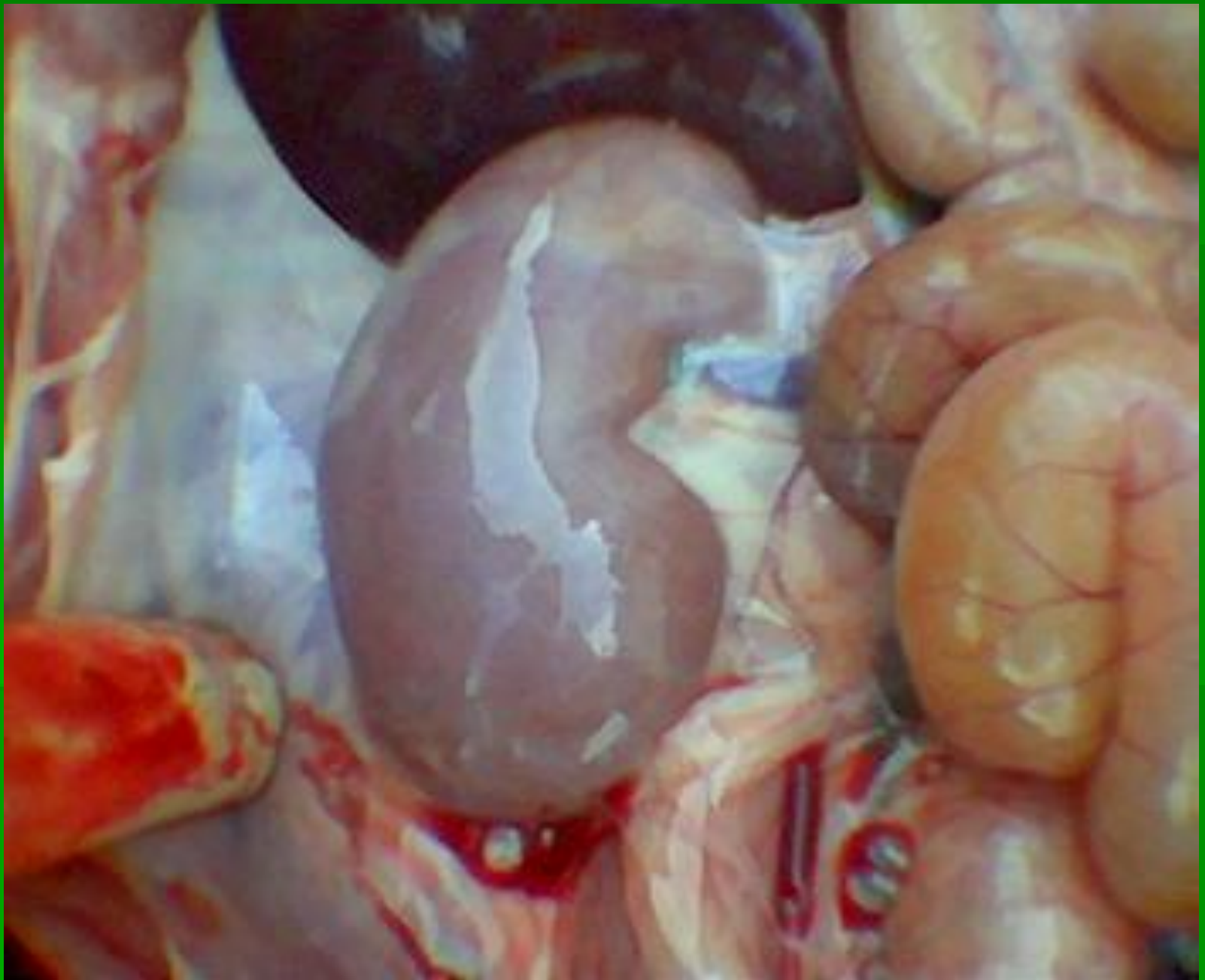


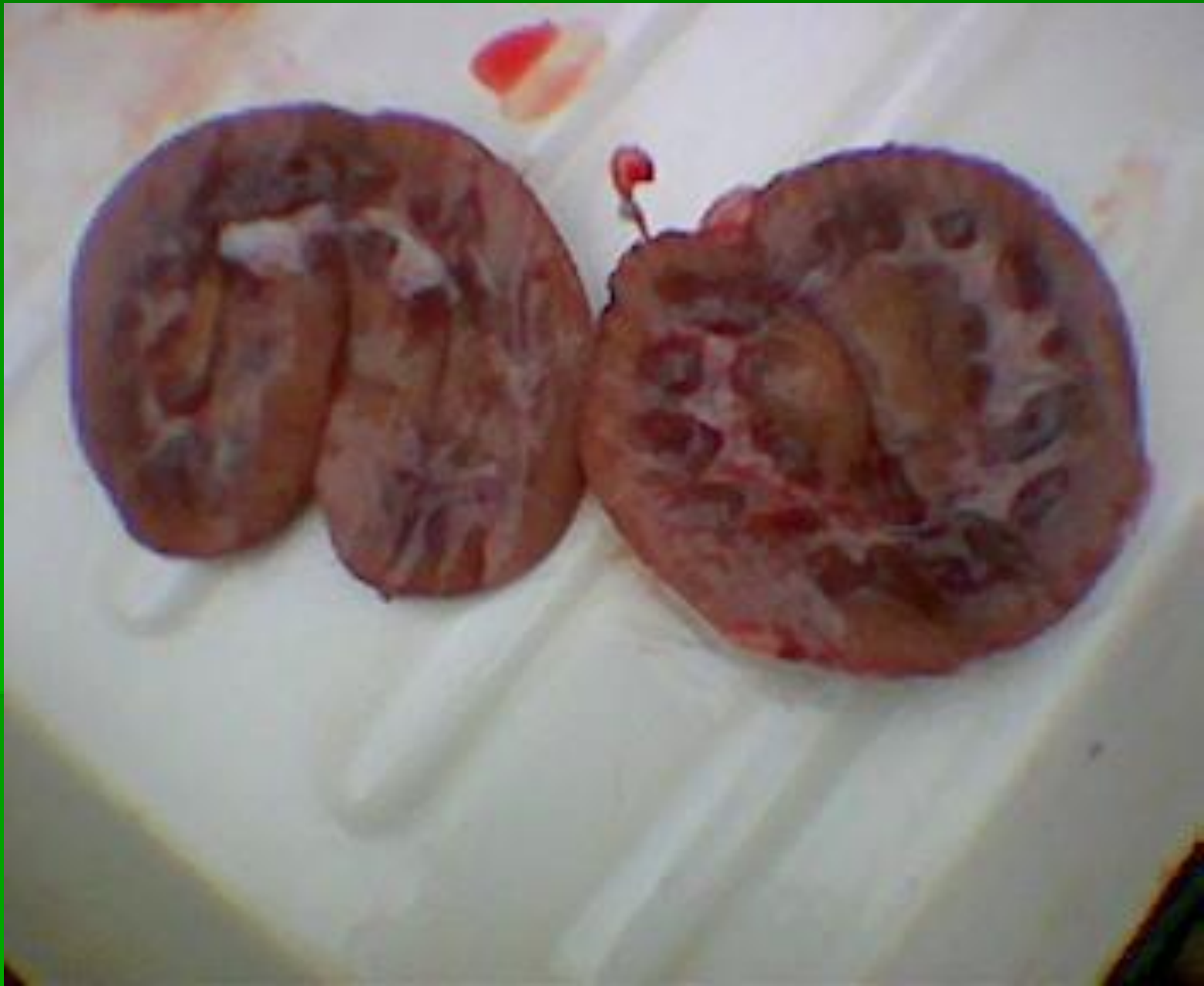
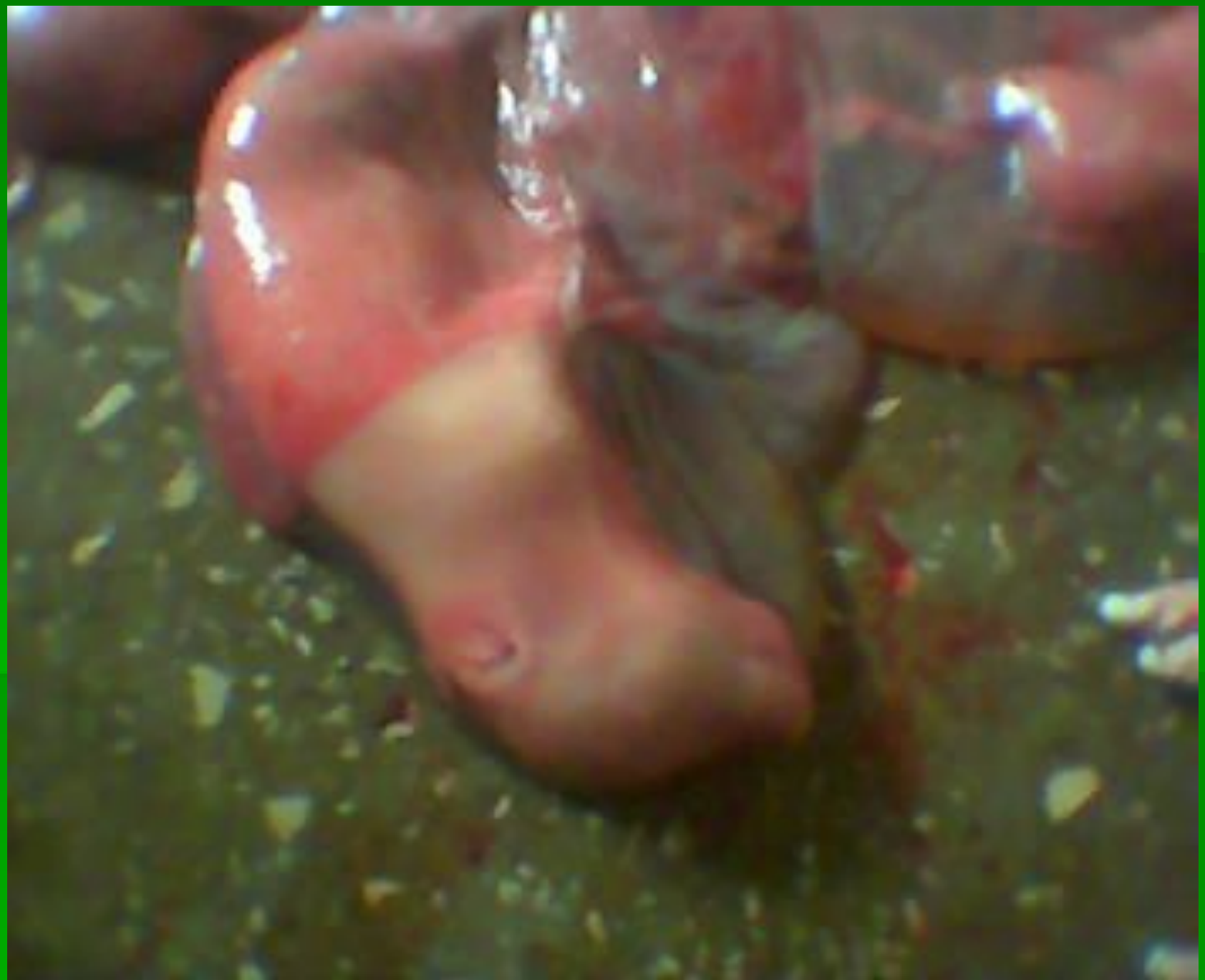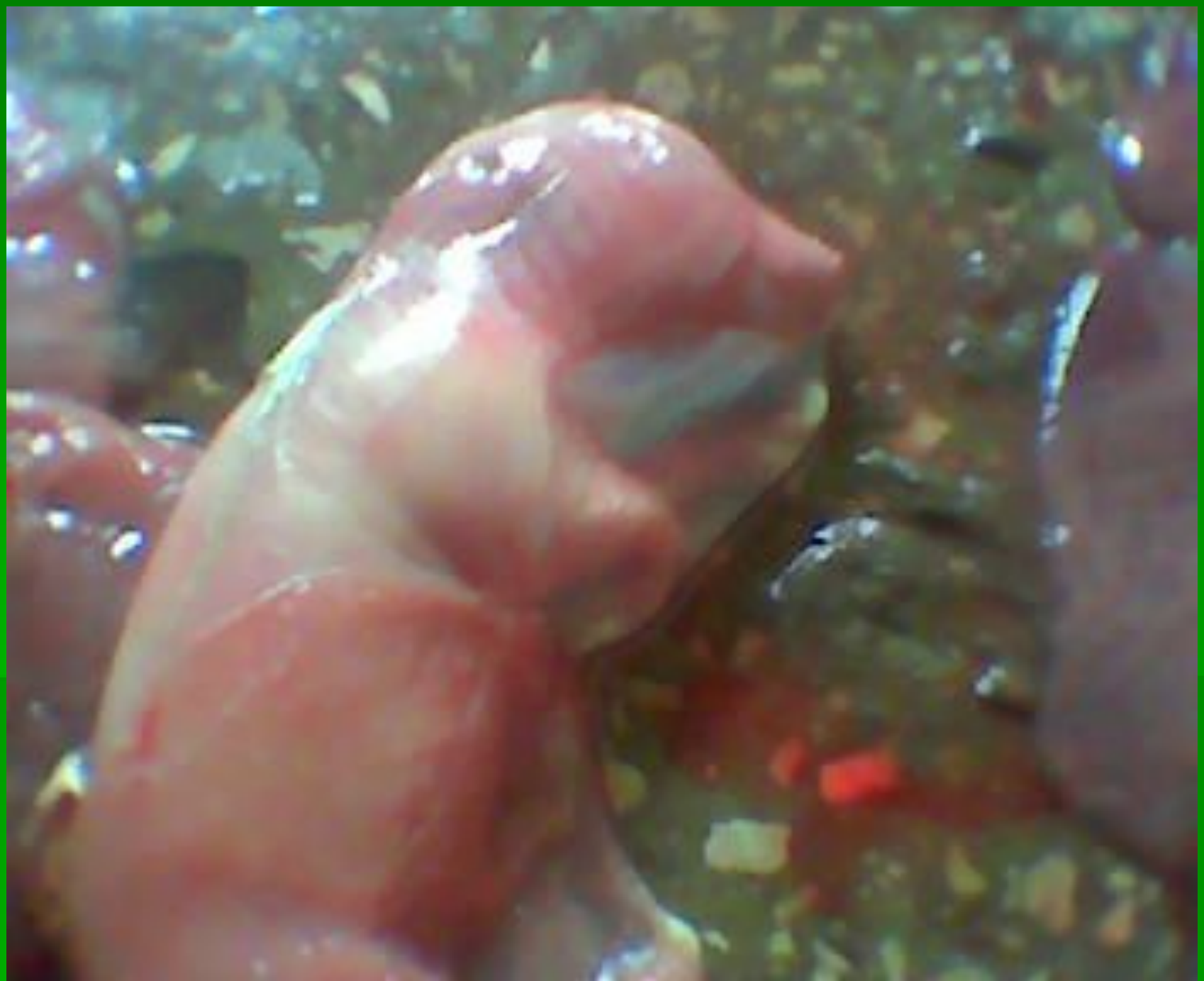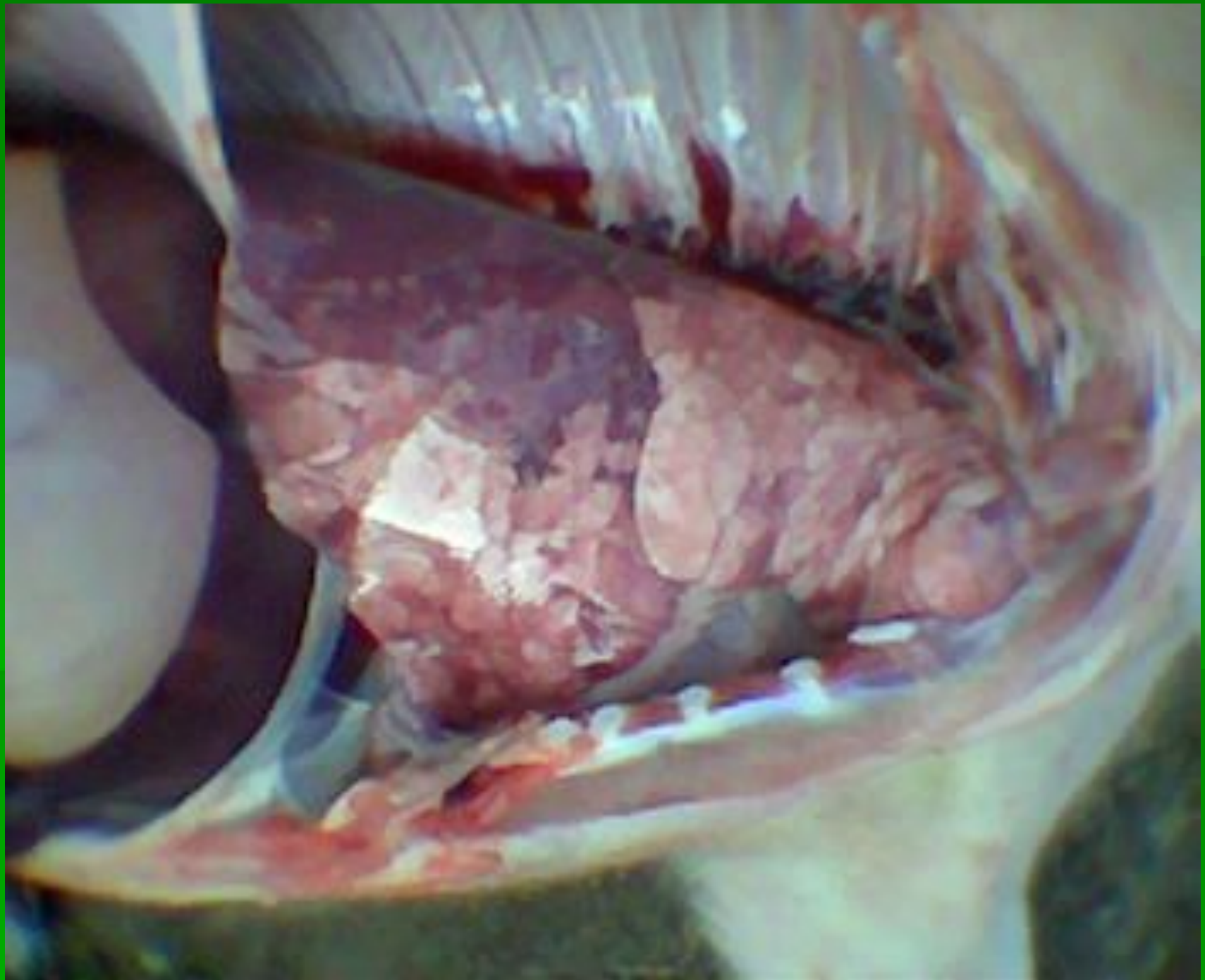
РРСС (синее ухо)

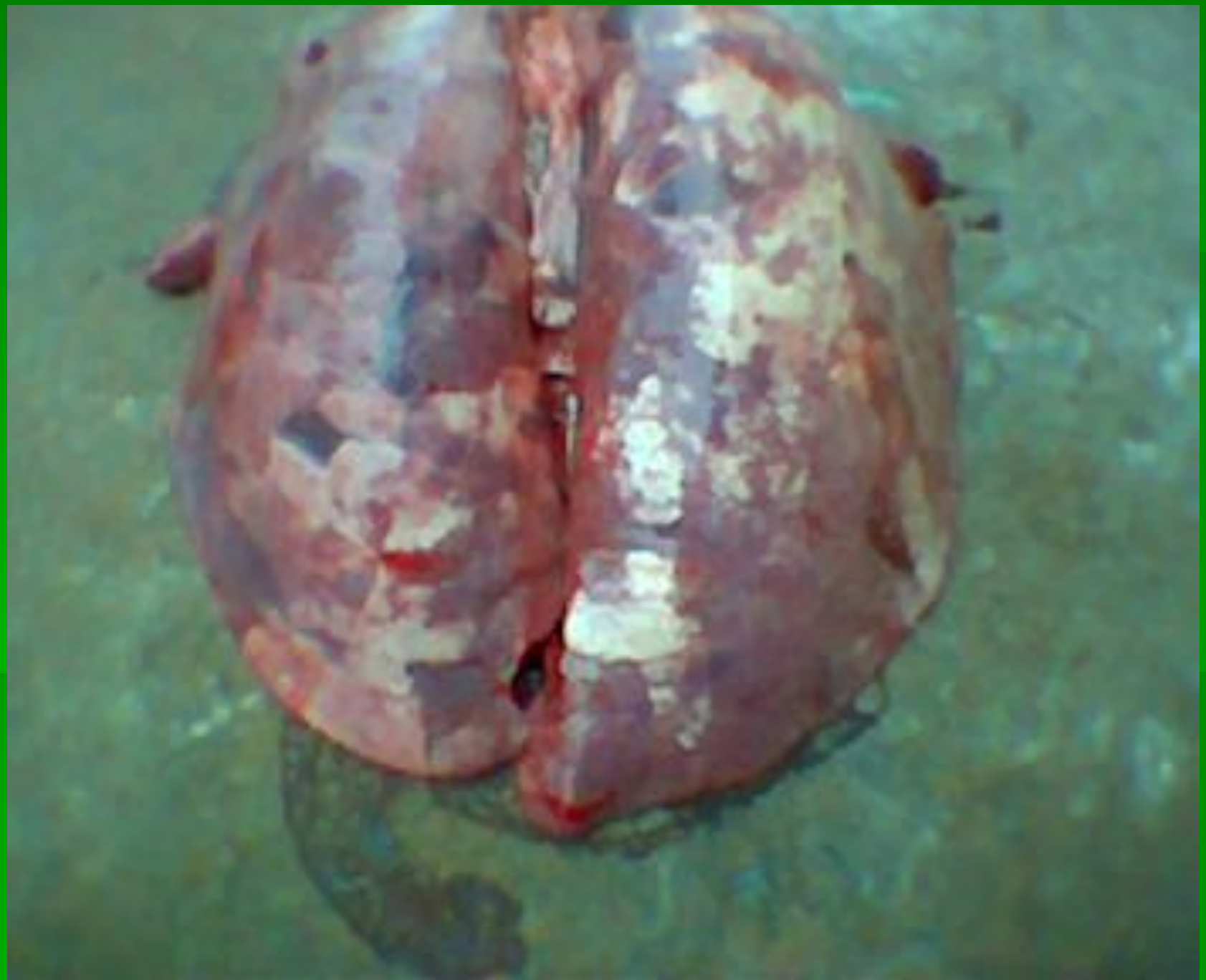


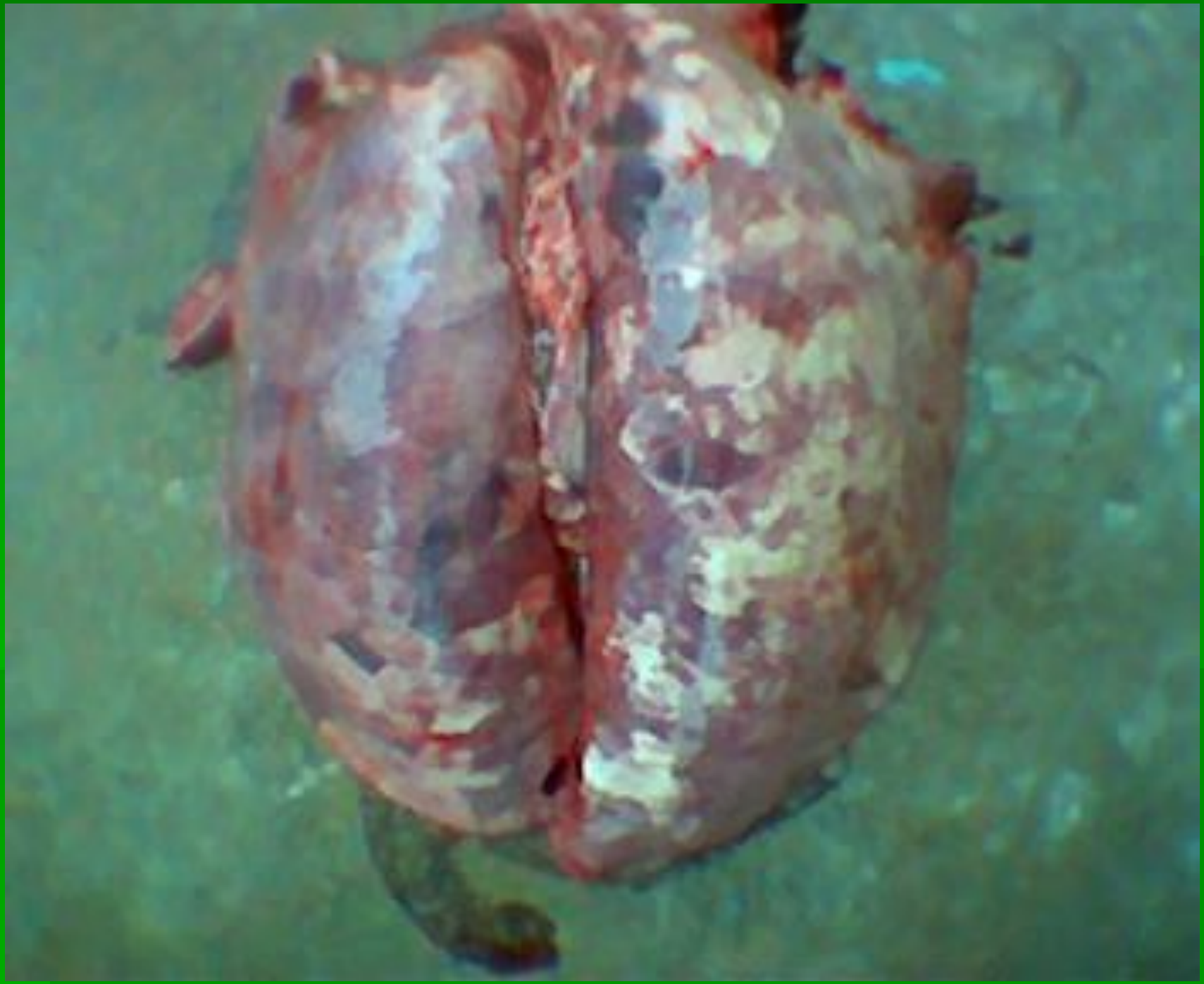


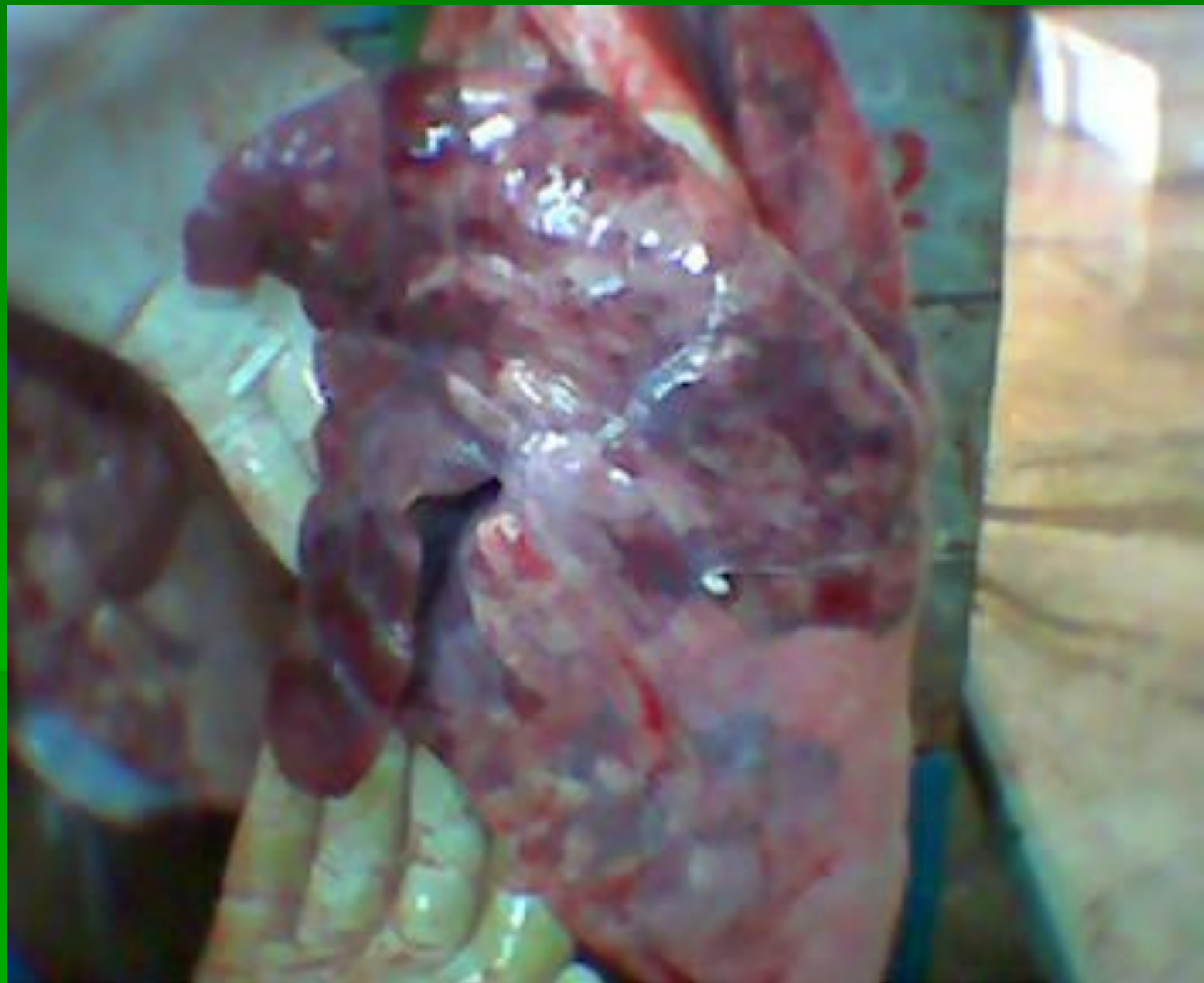


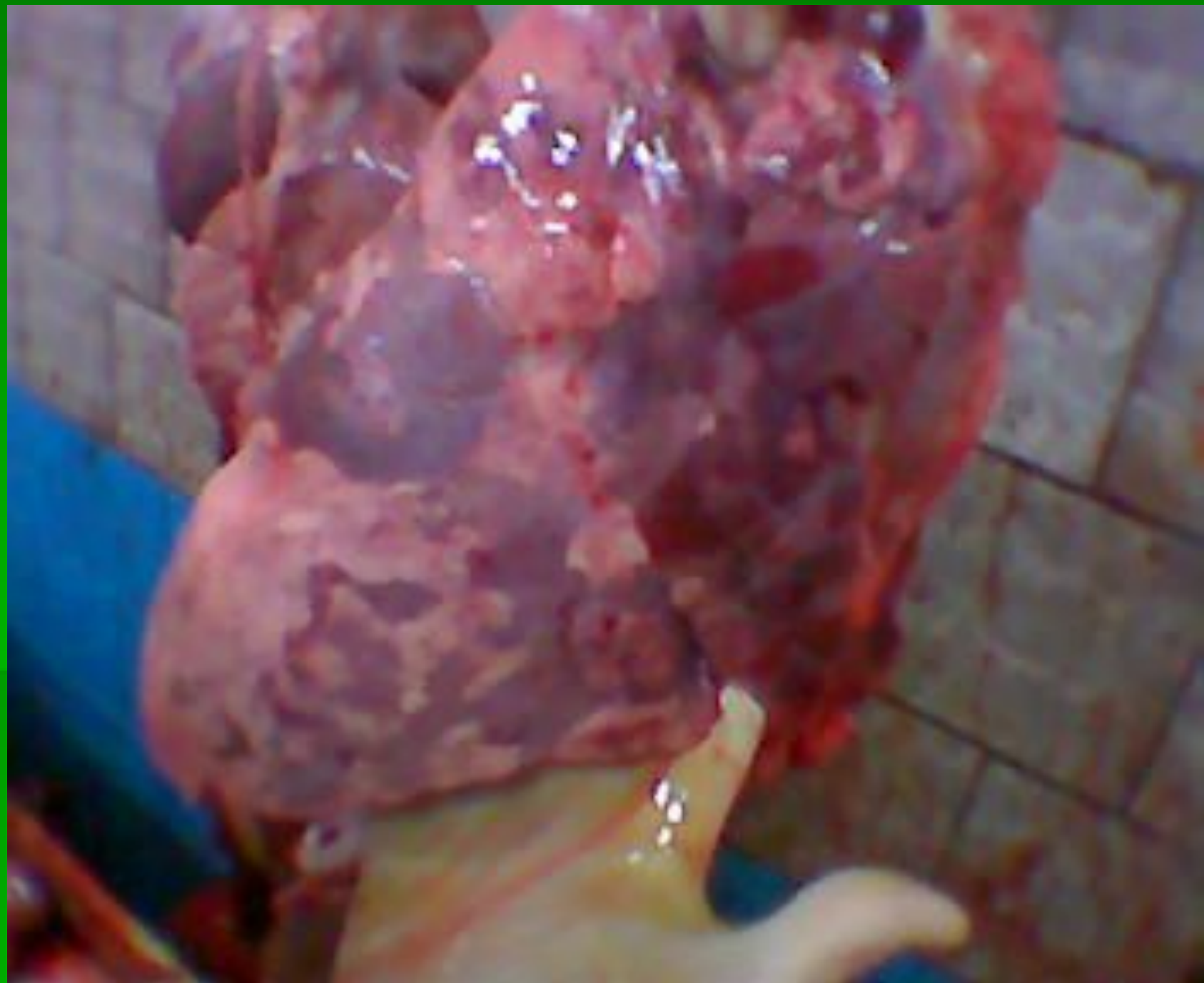
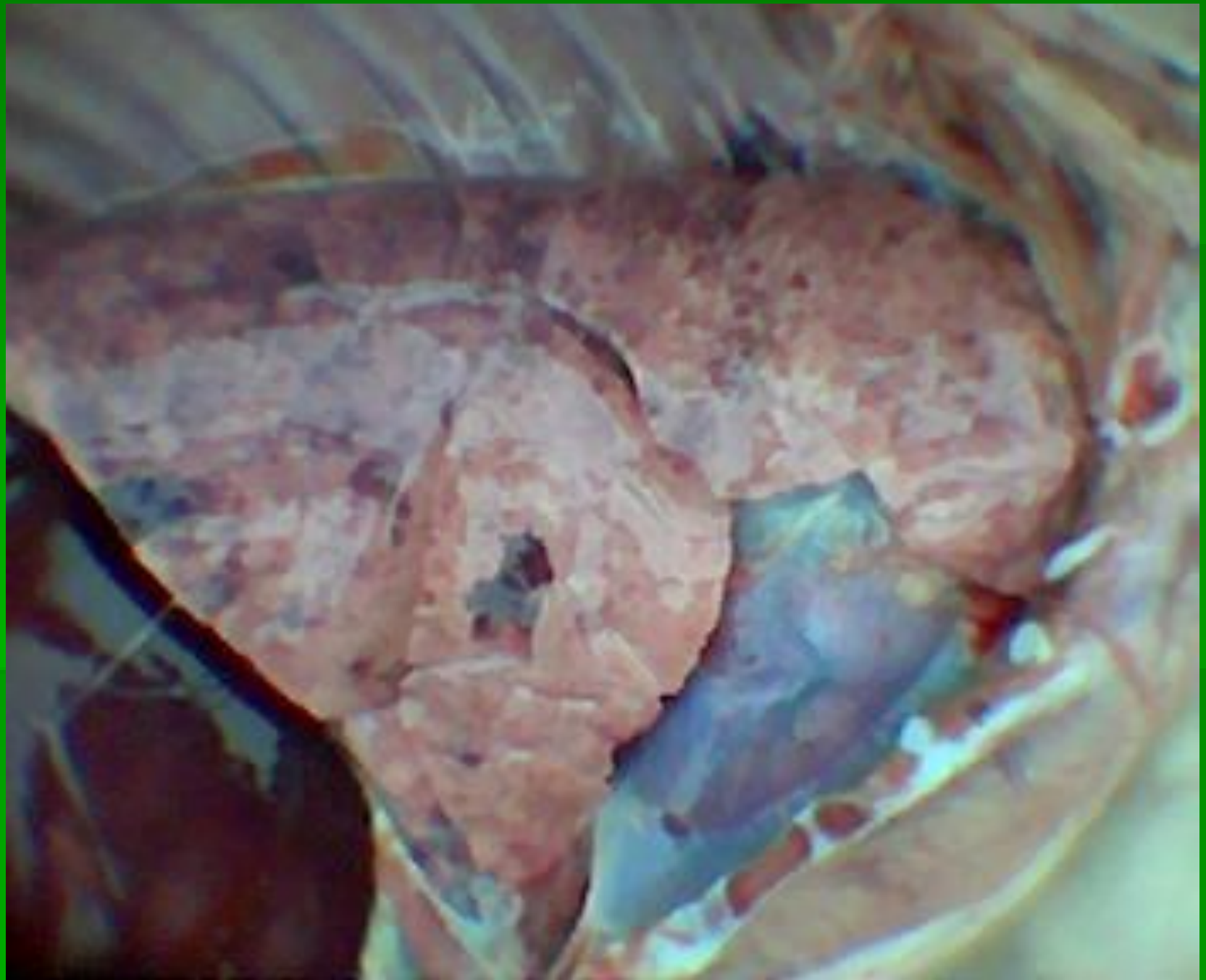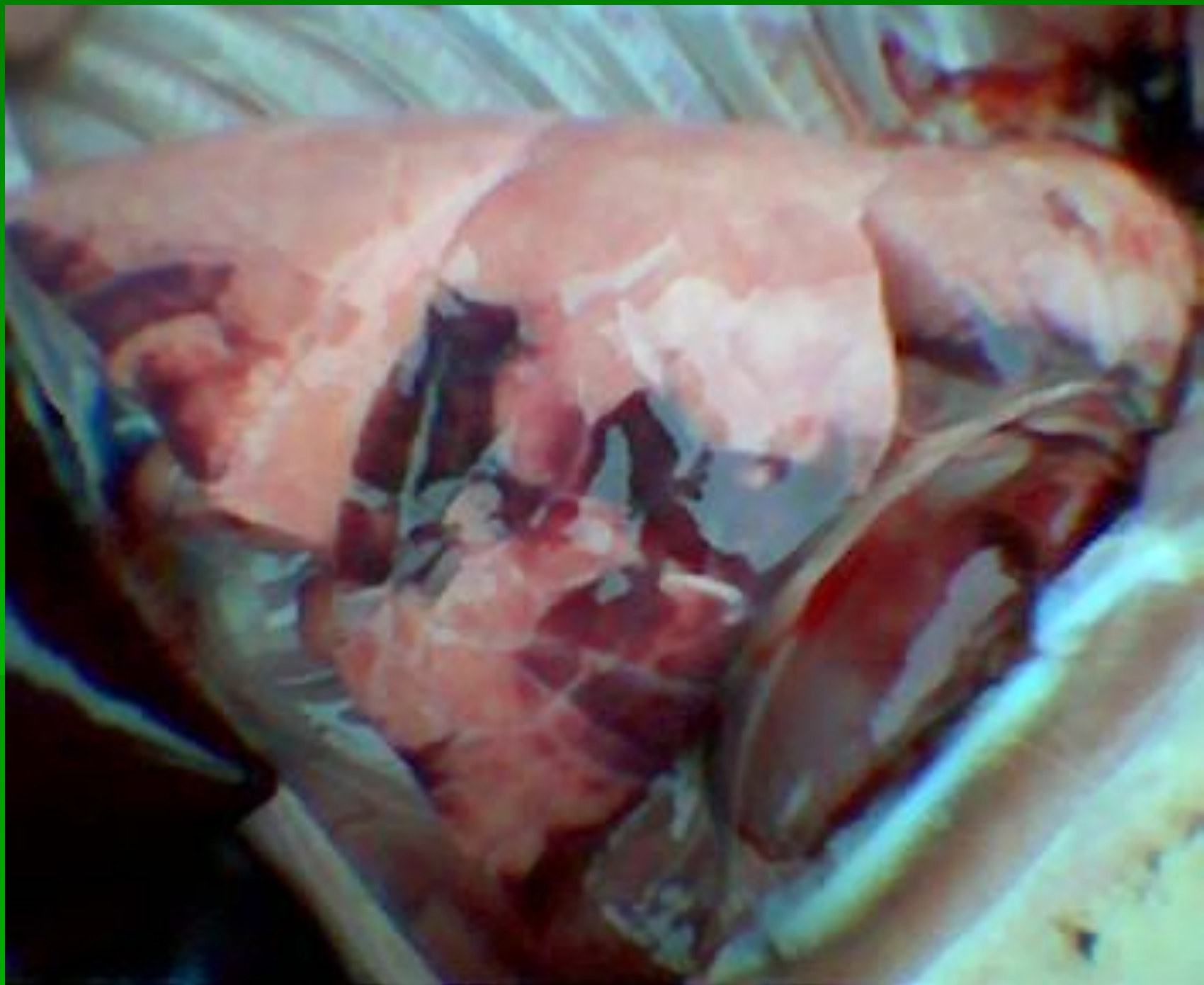












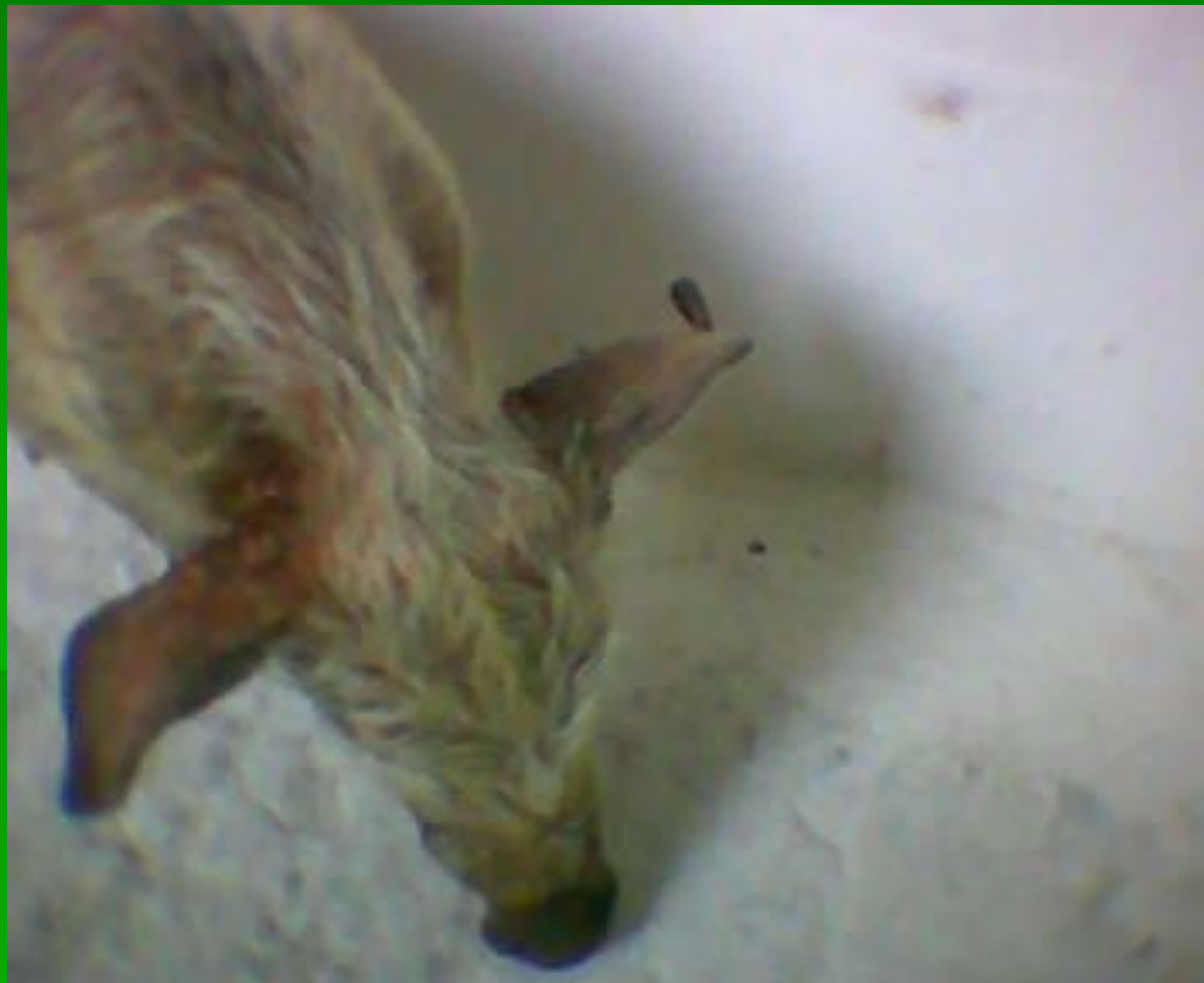Инфекционный

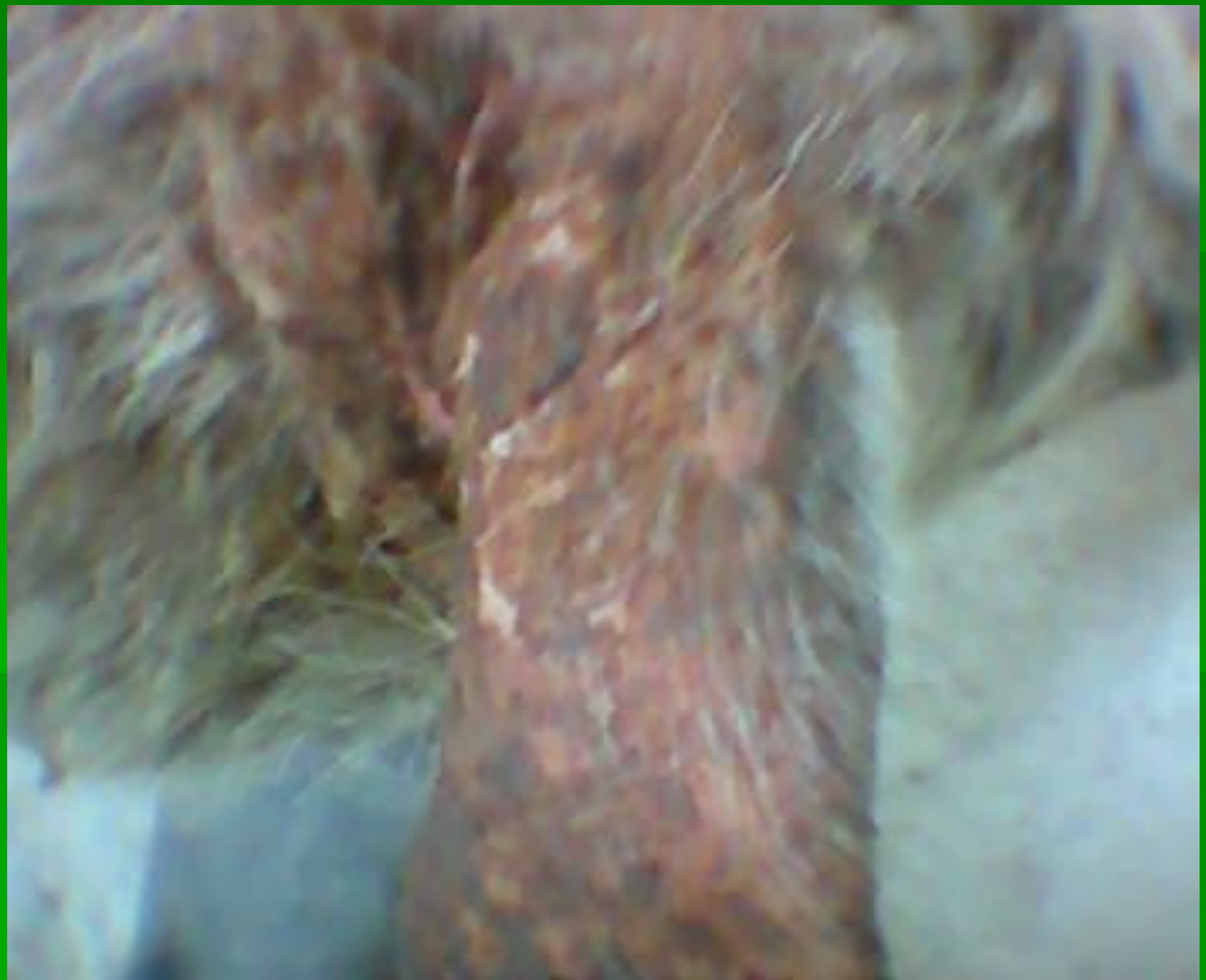эпидермит

(стафилококкоз)





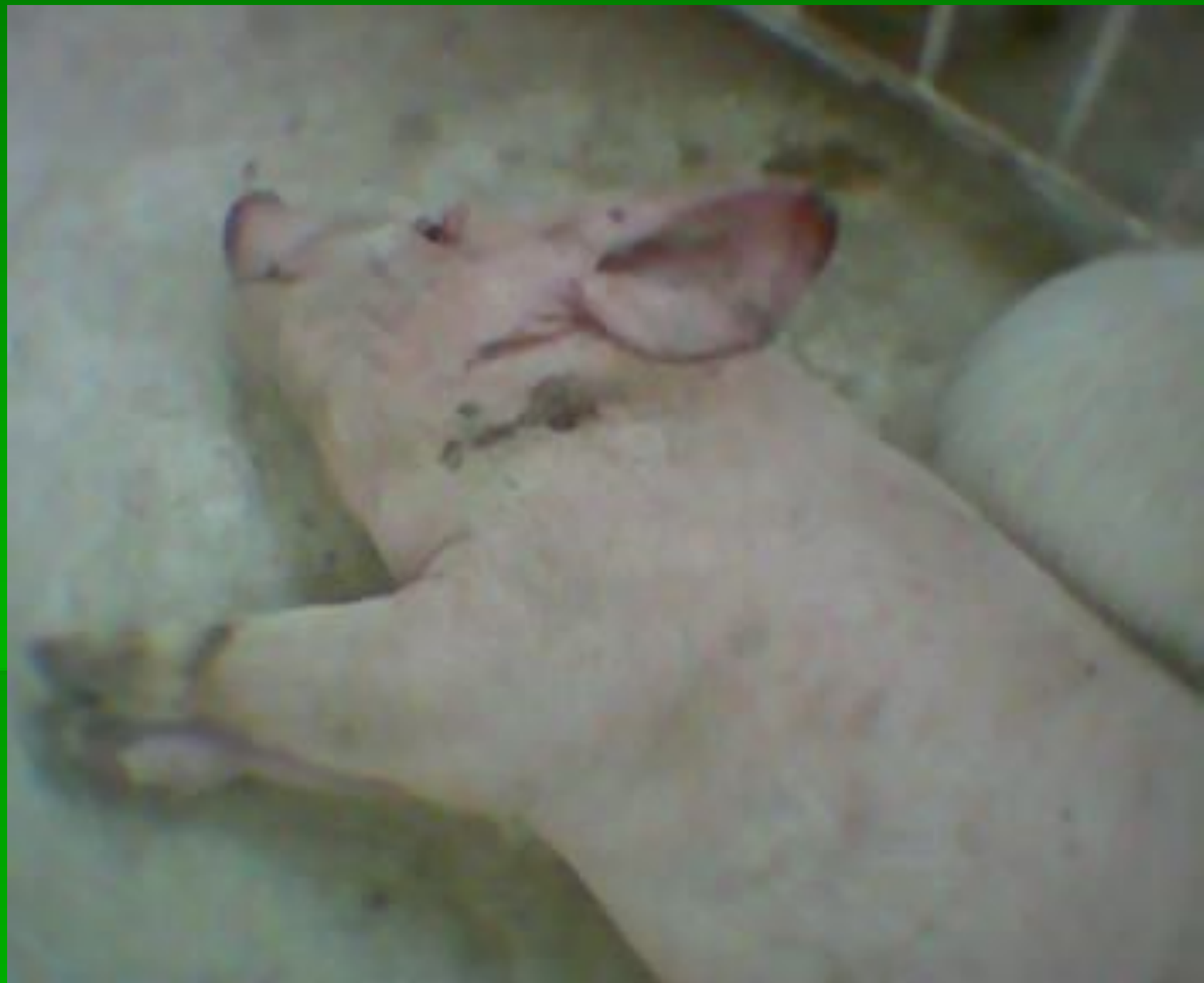


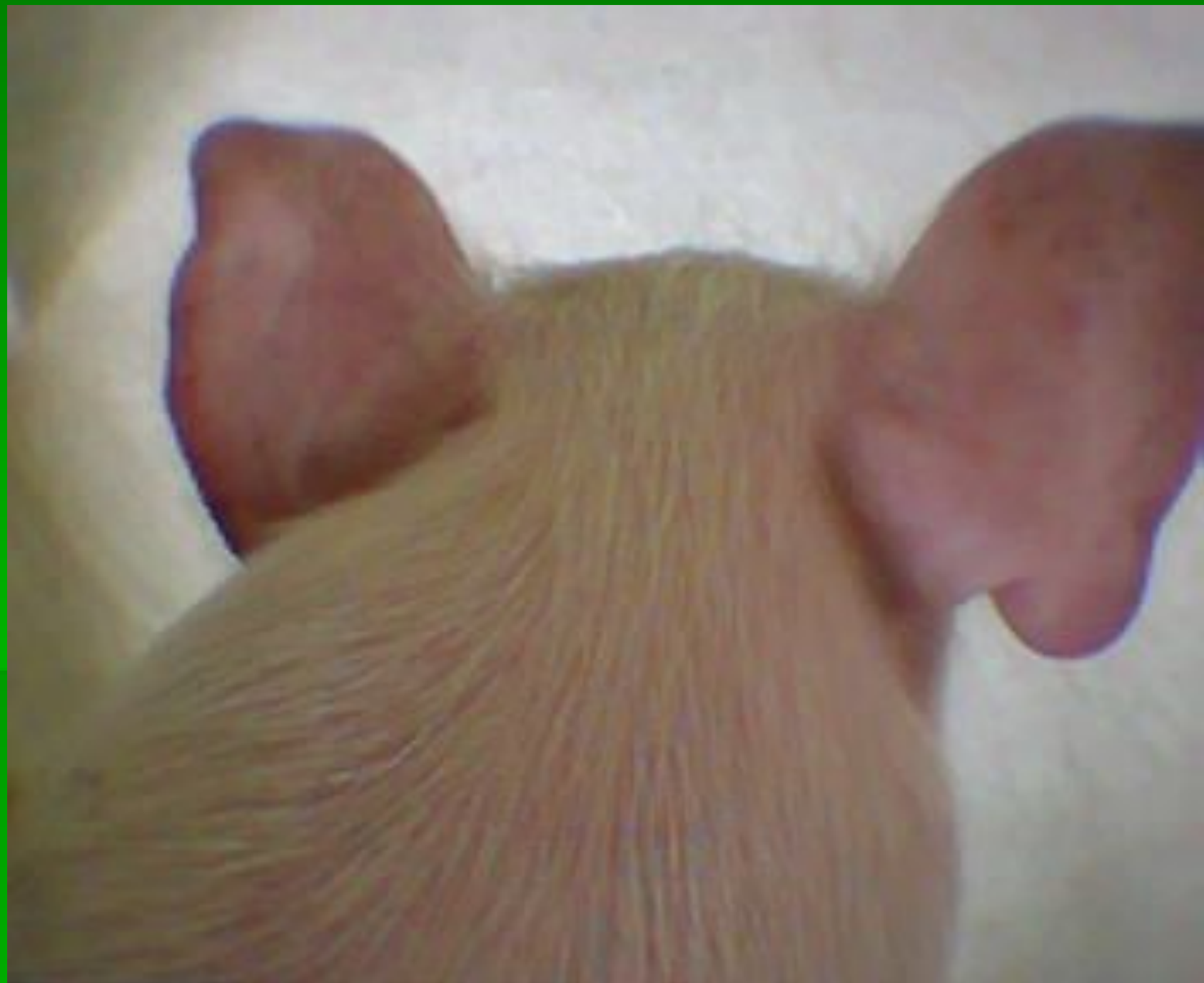
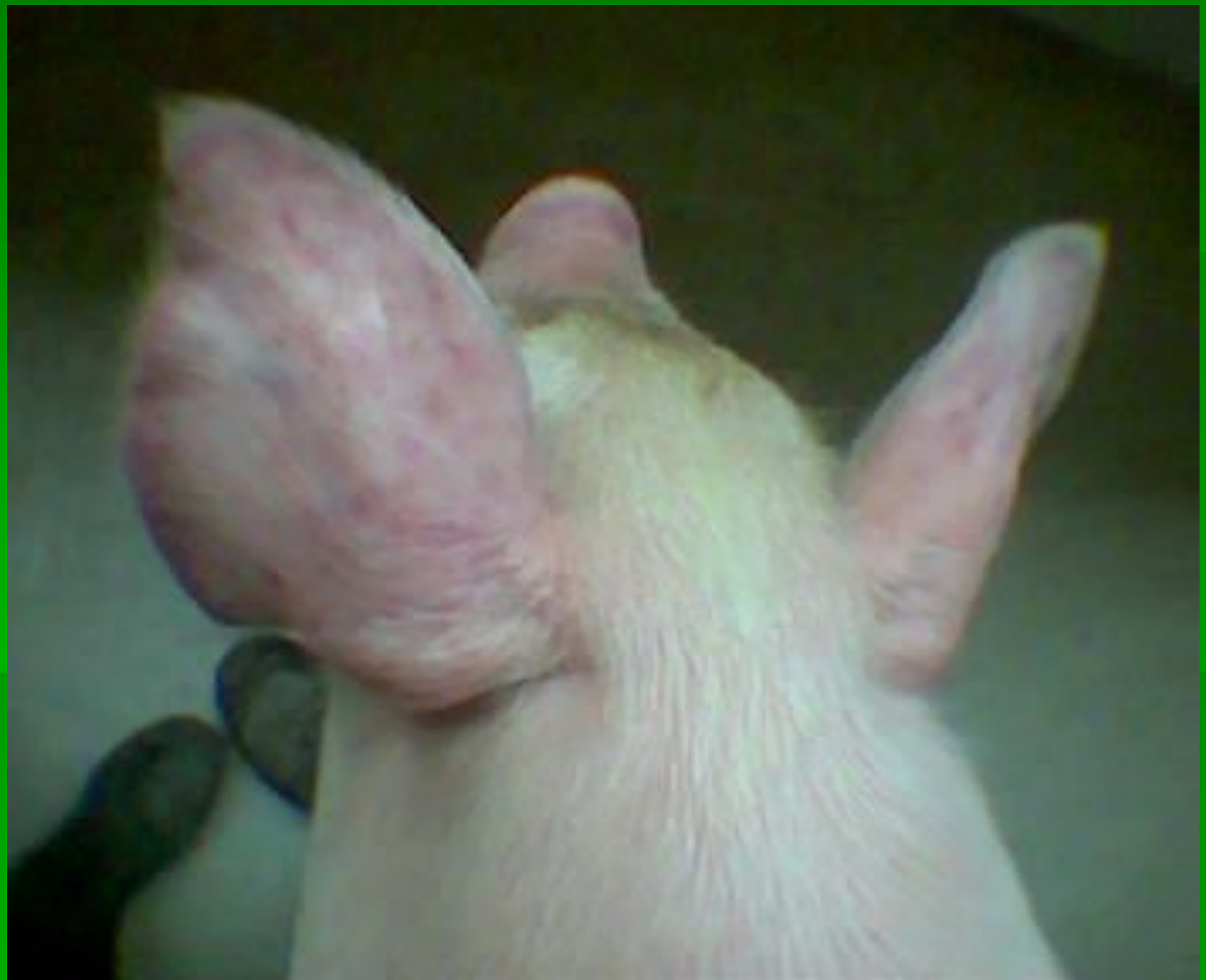Стрептококко

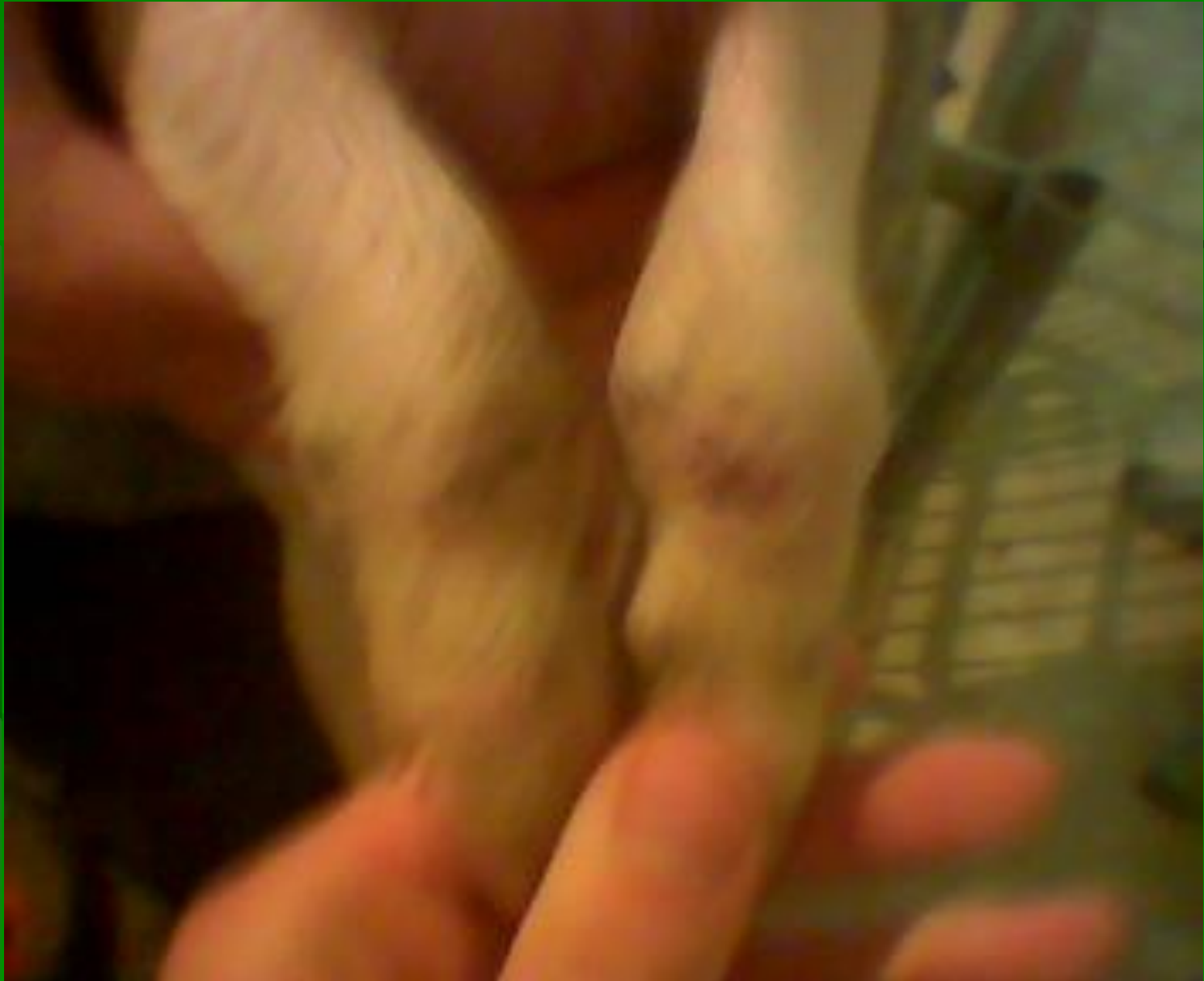3

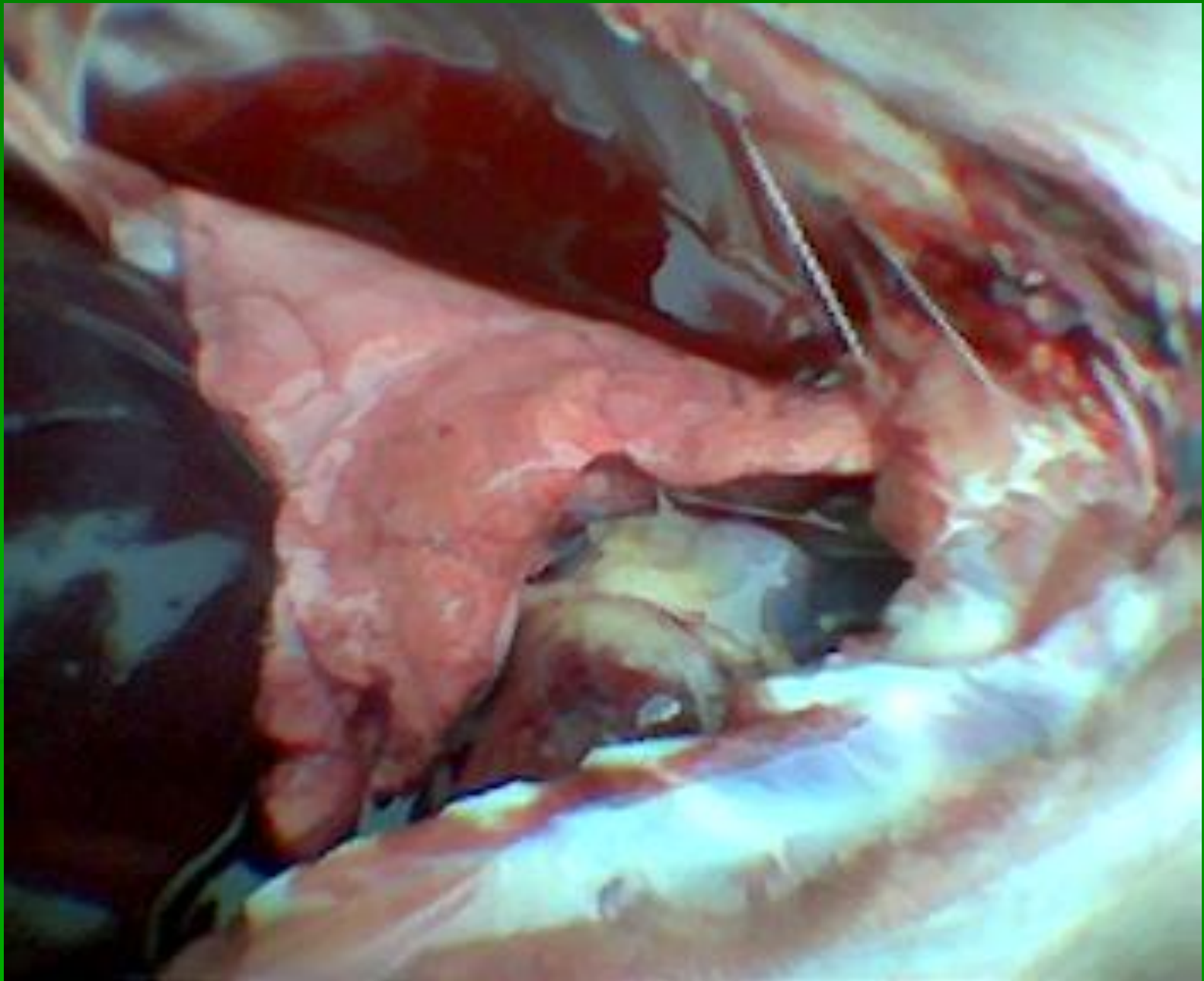


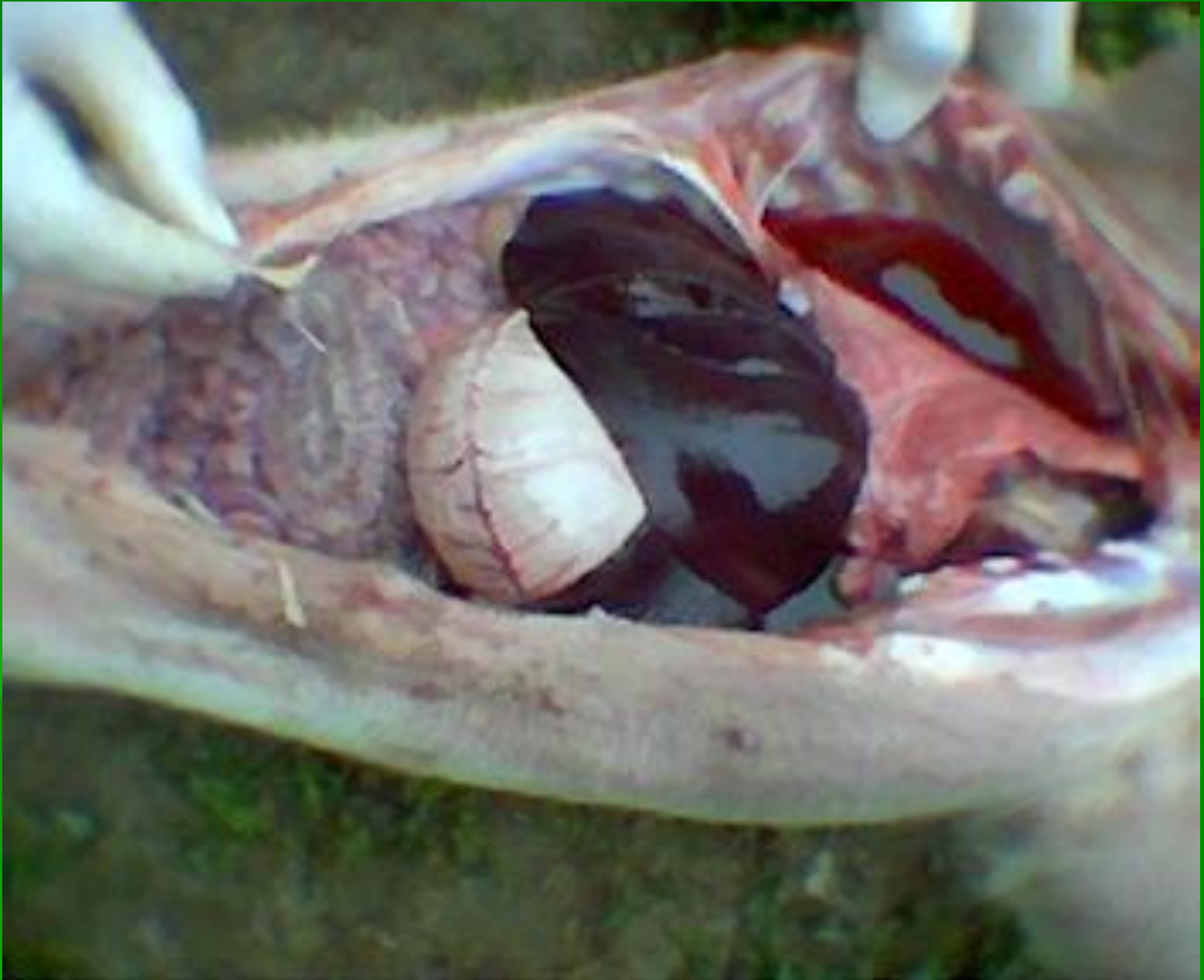

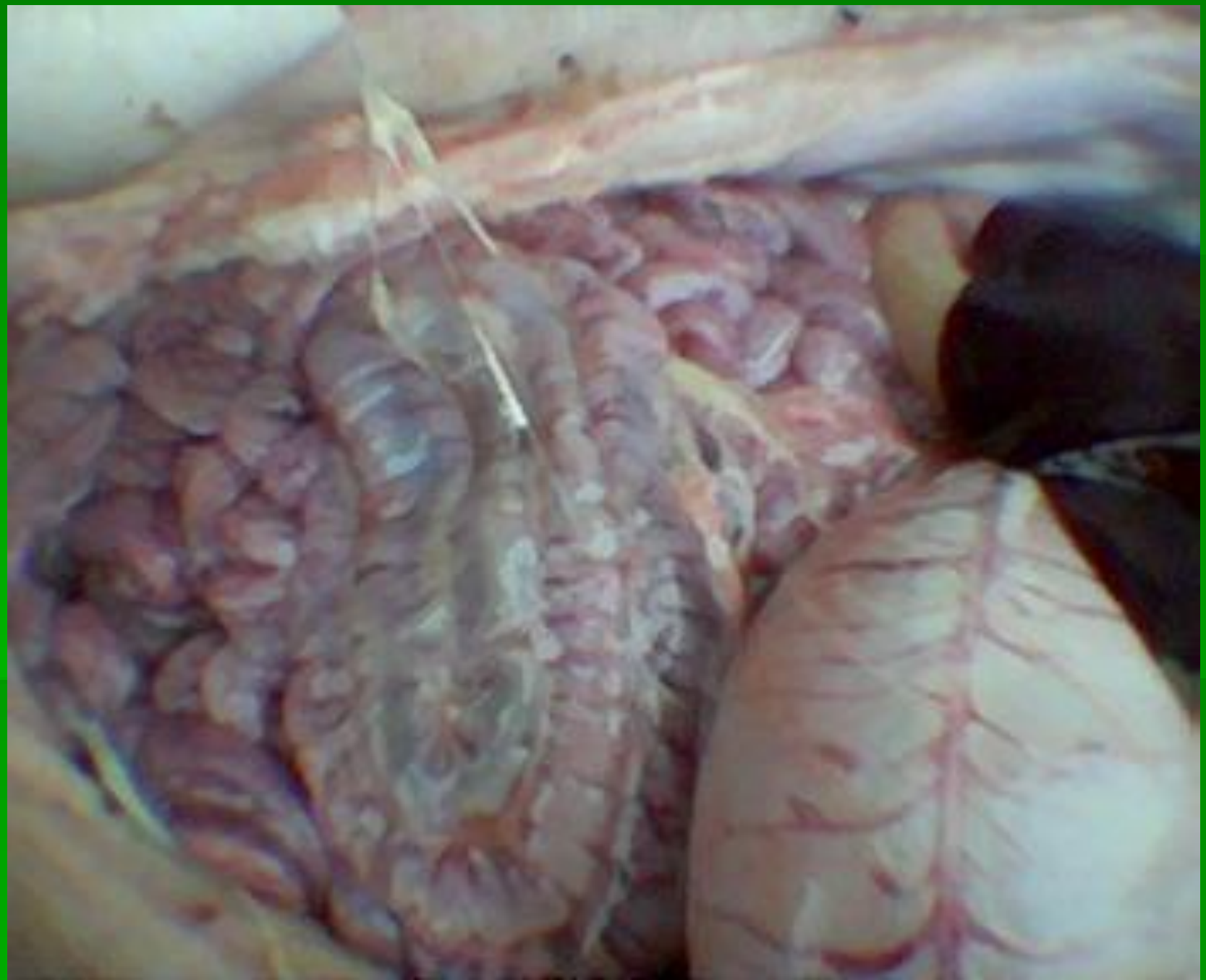





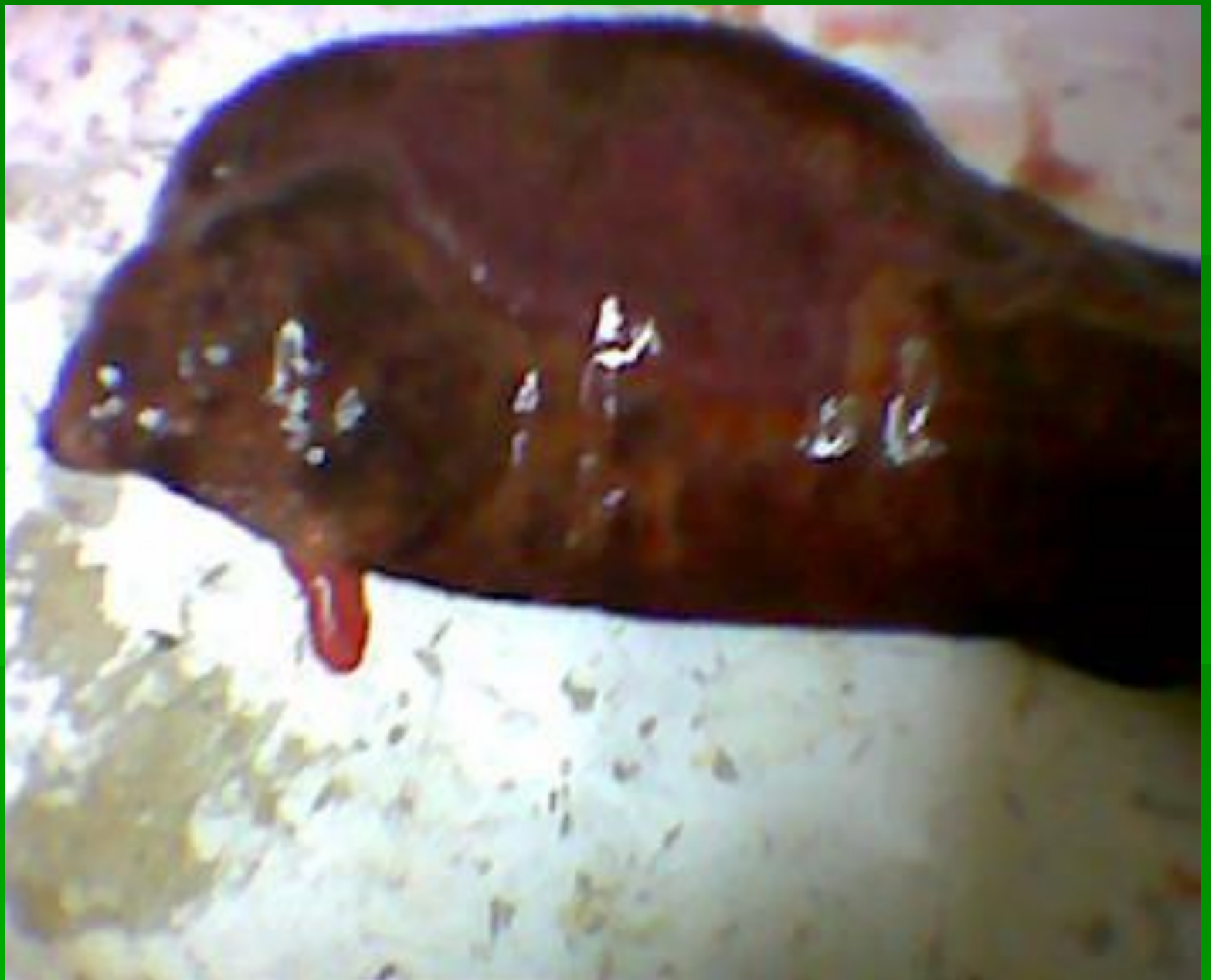


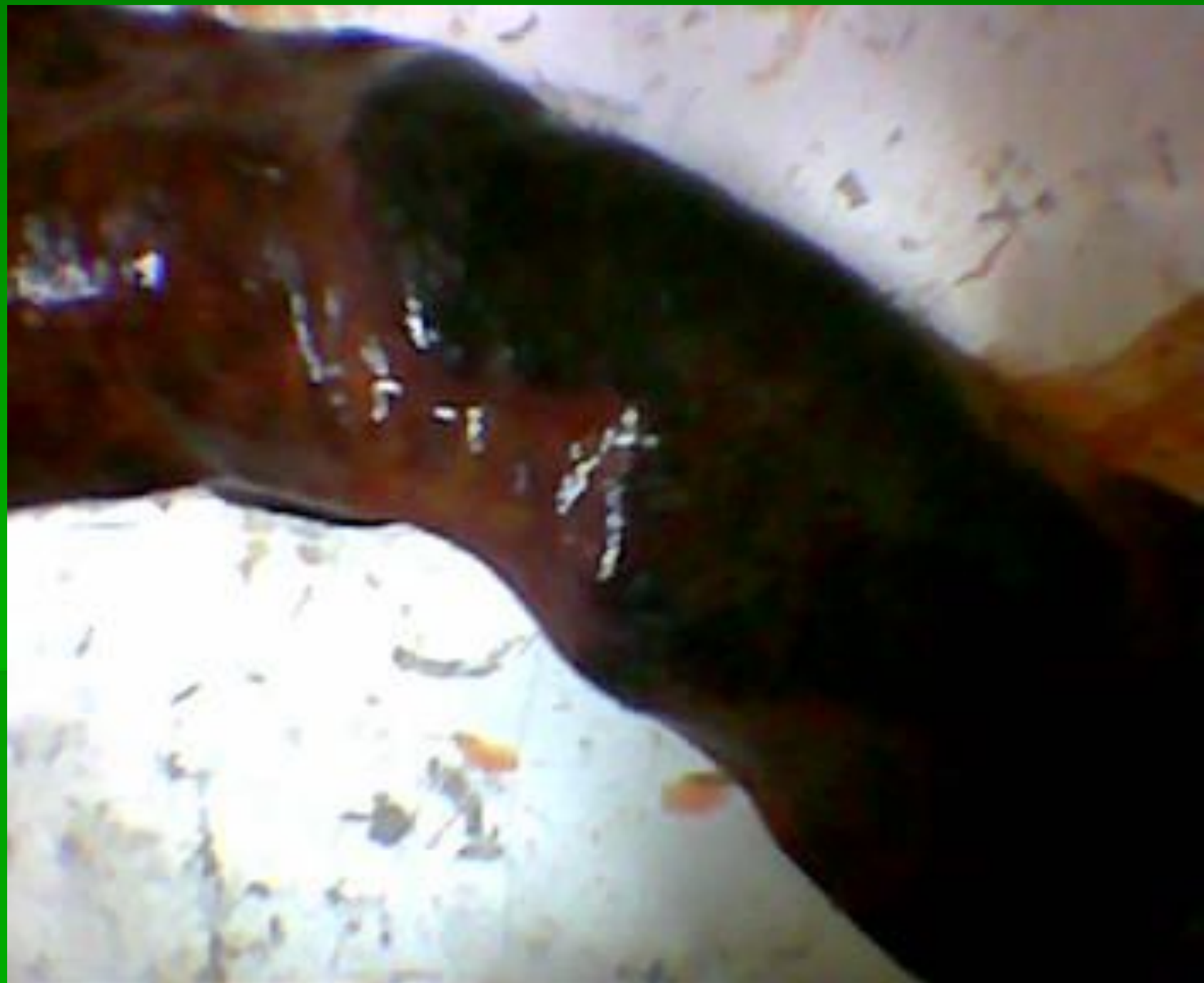


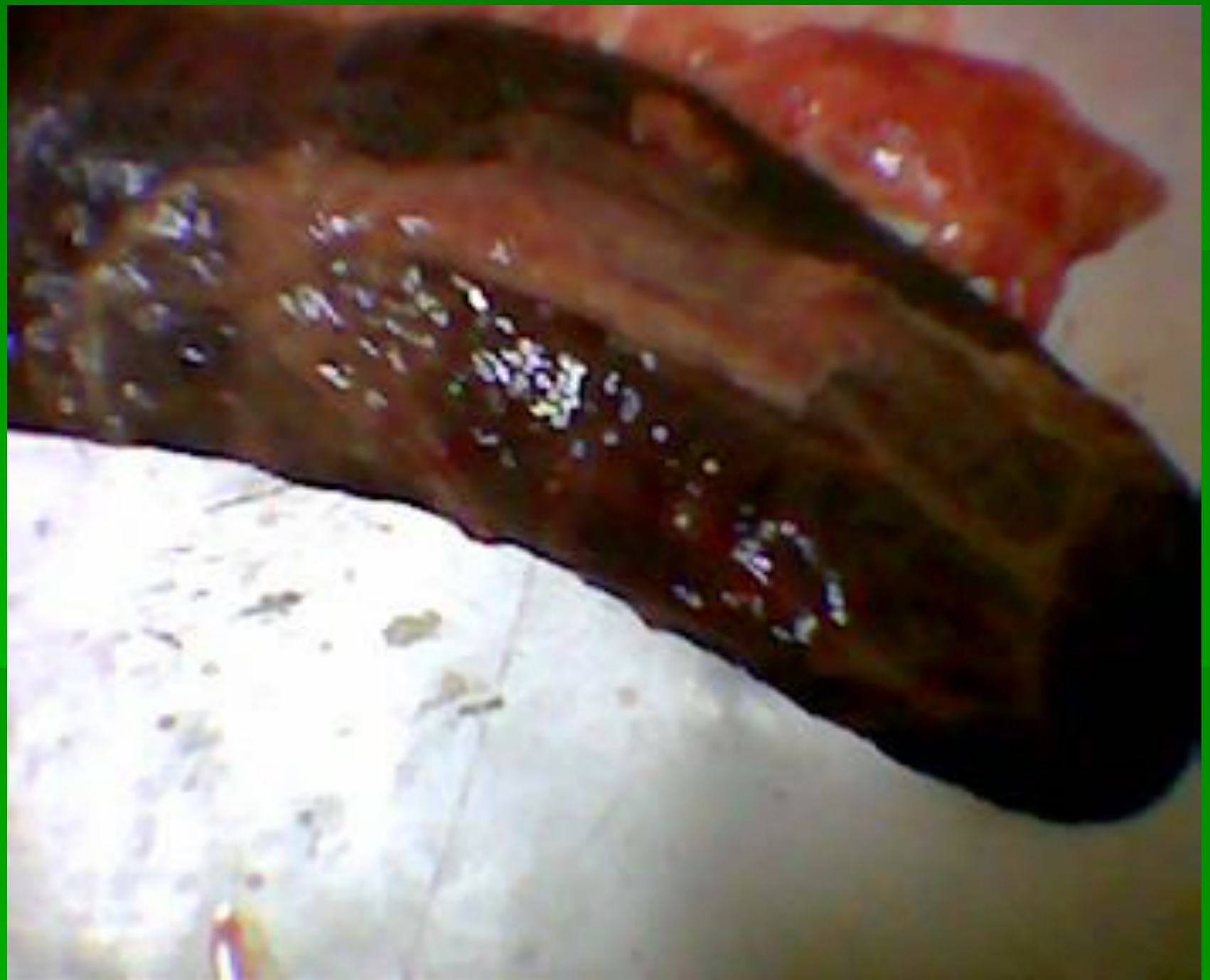


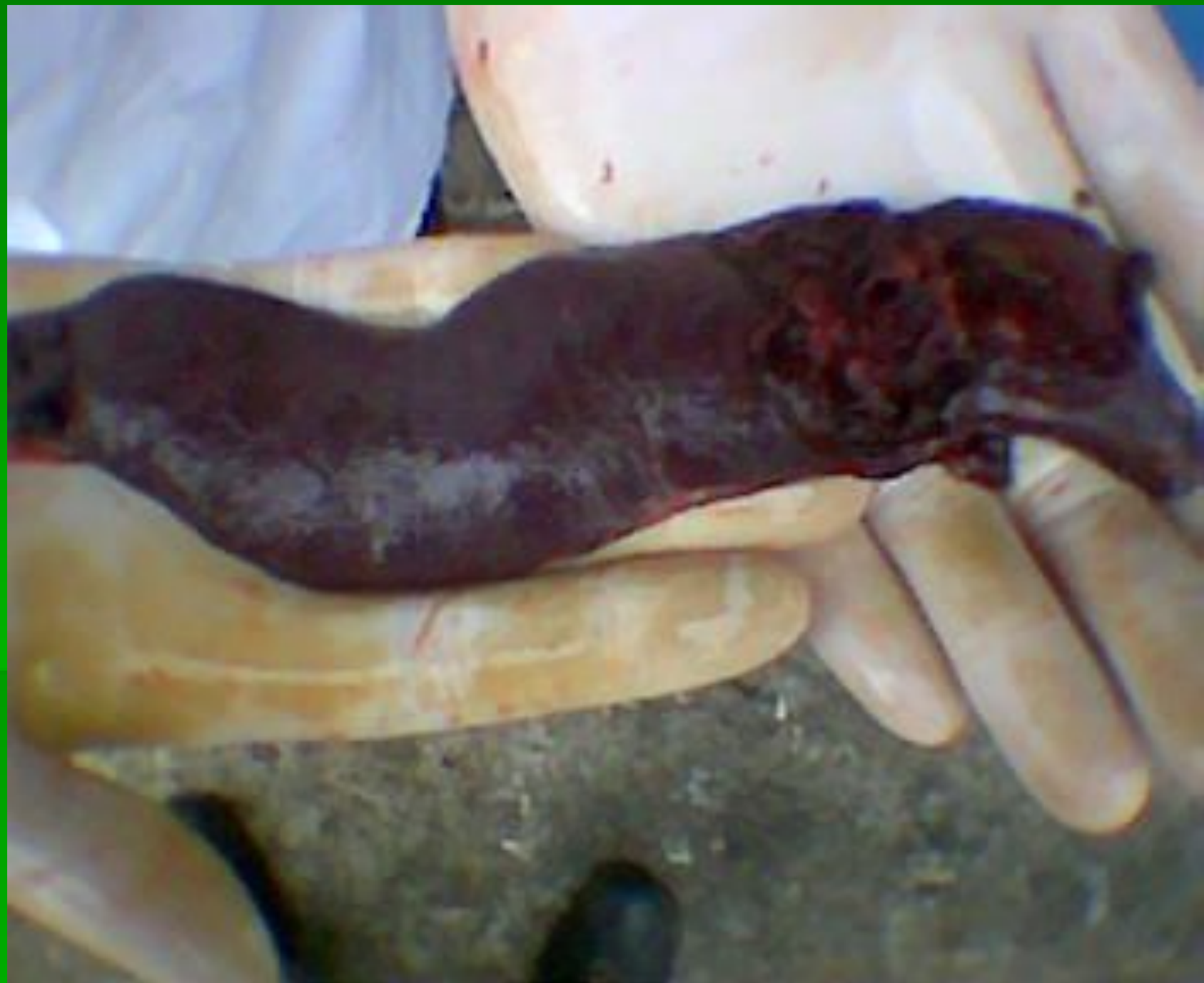

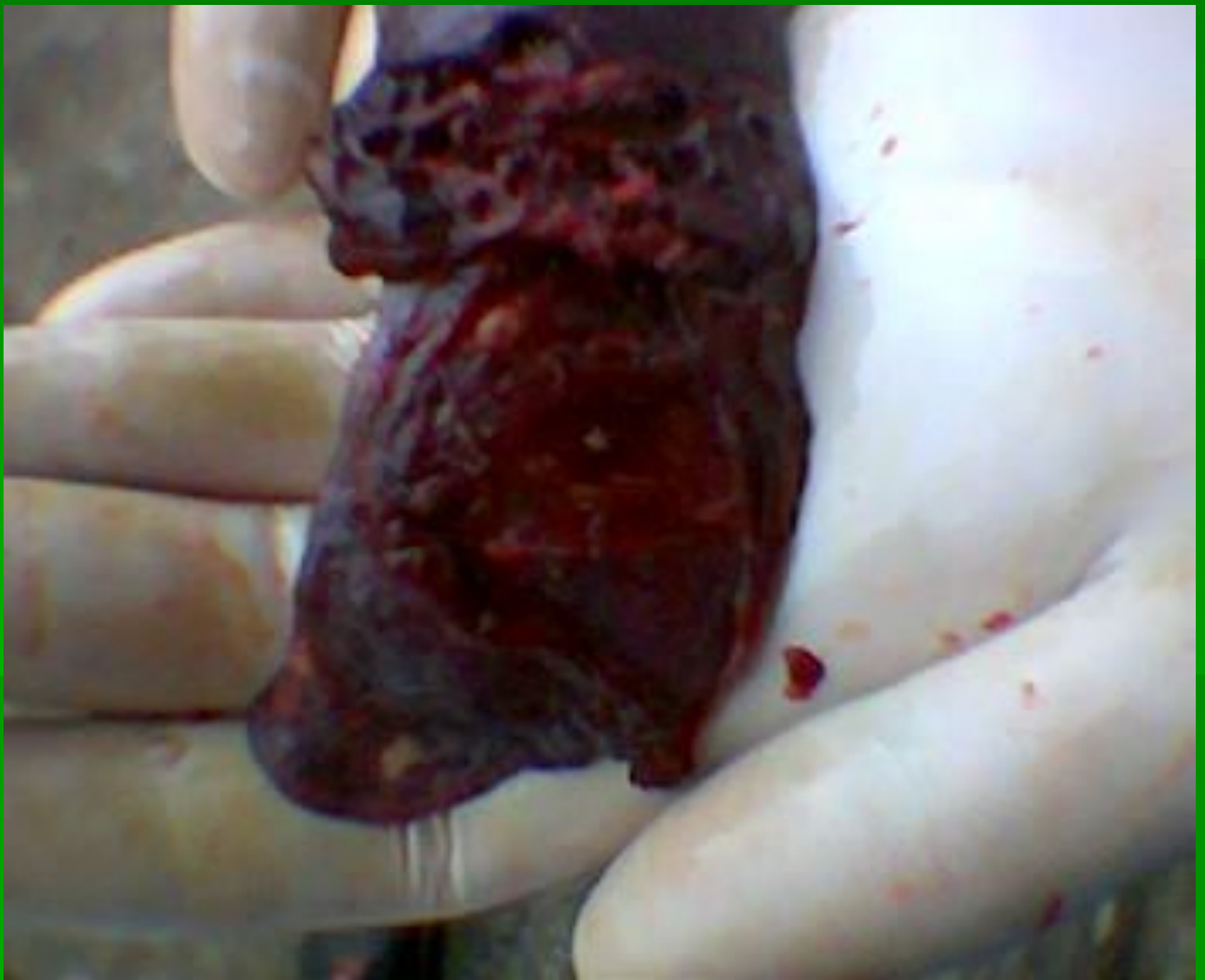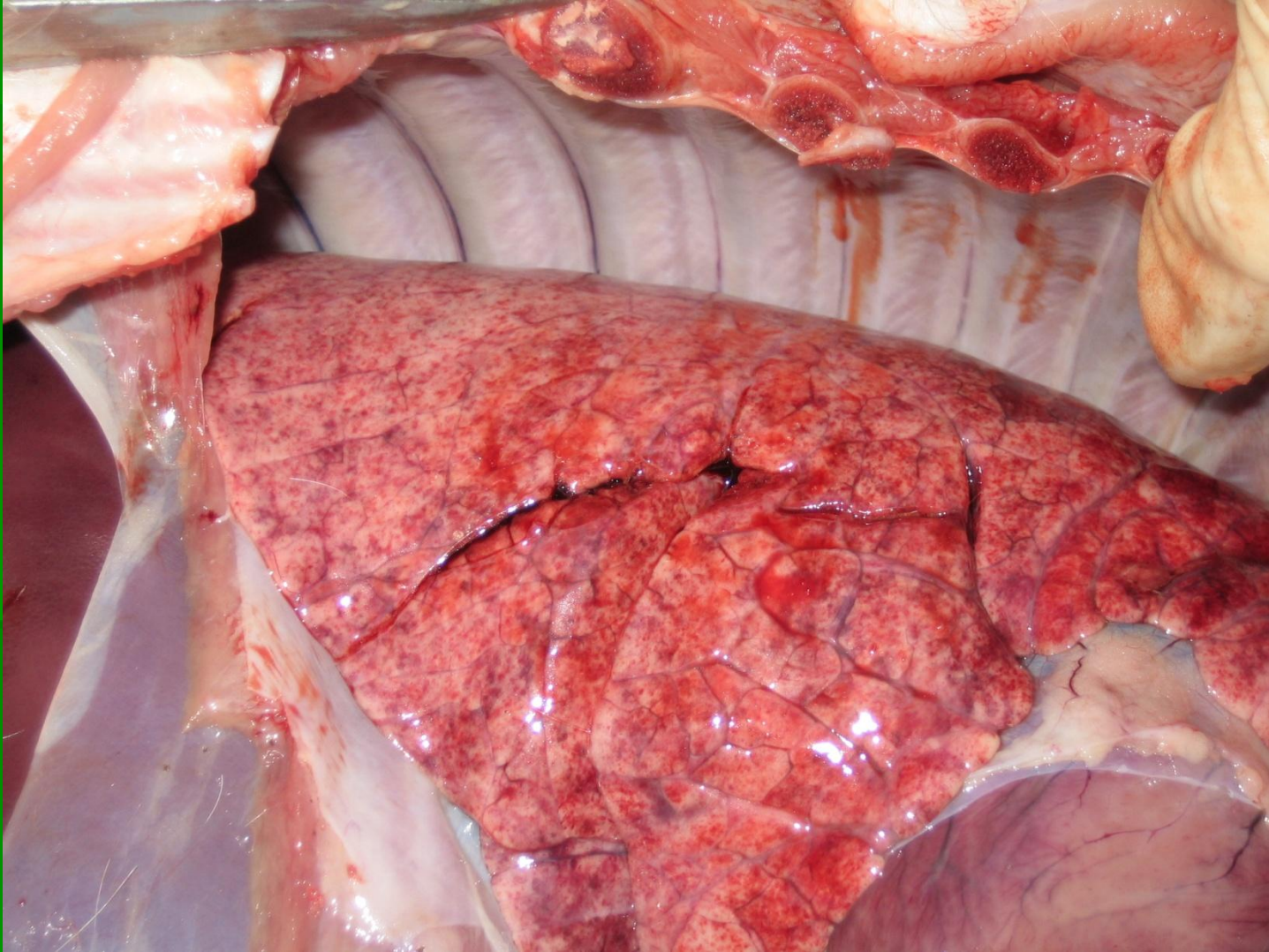








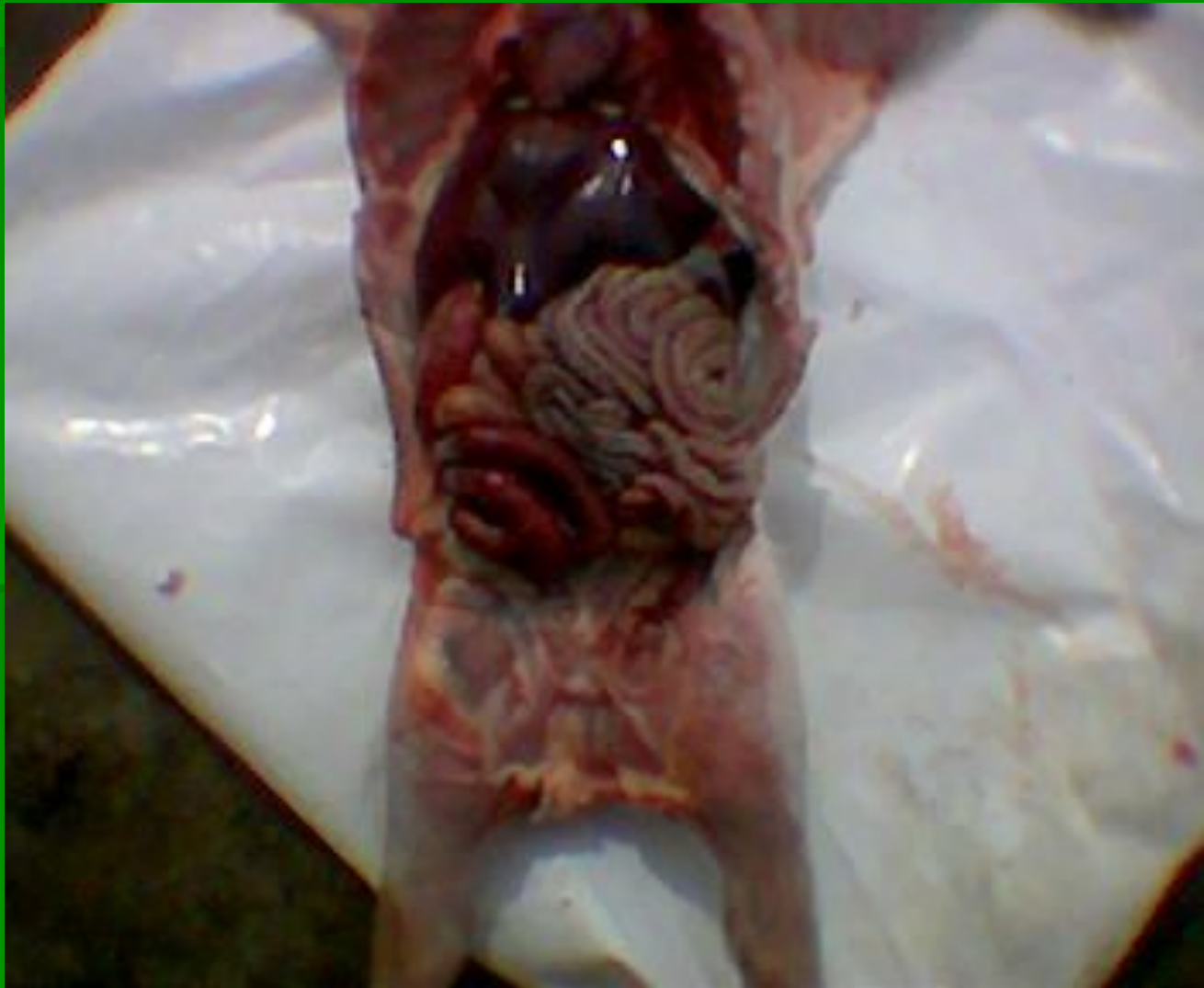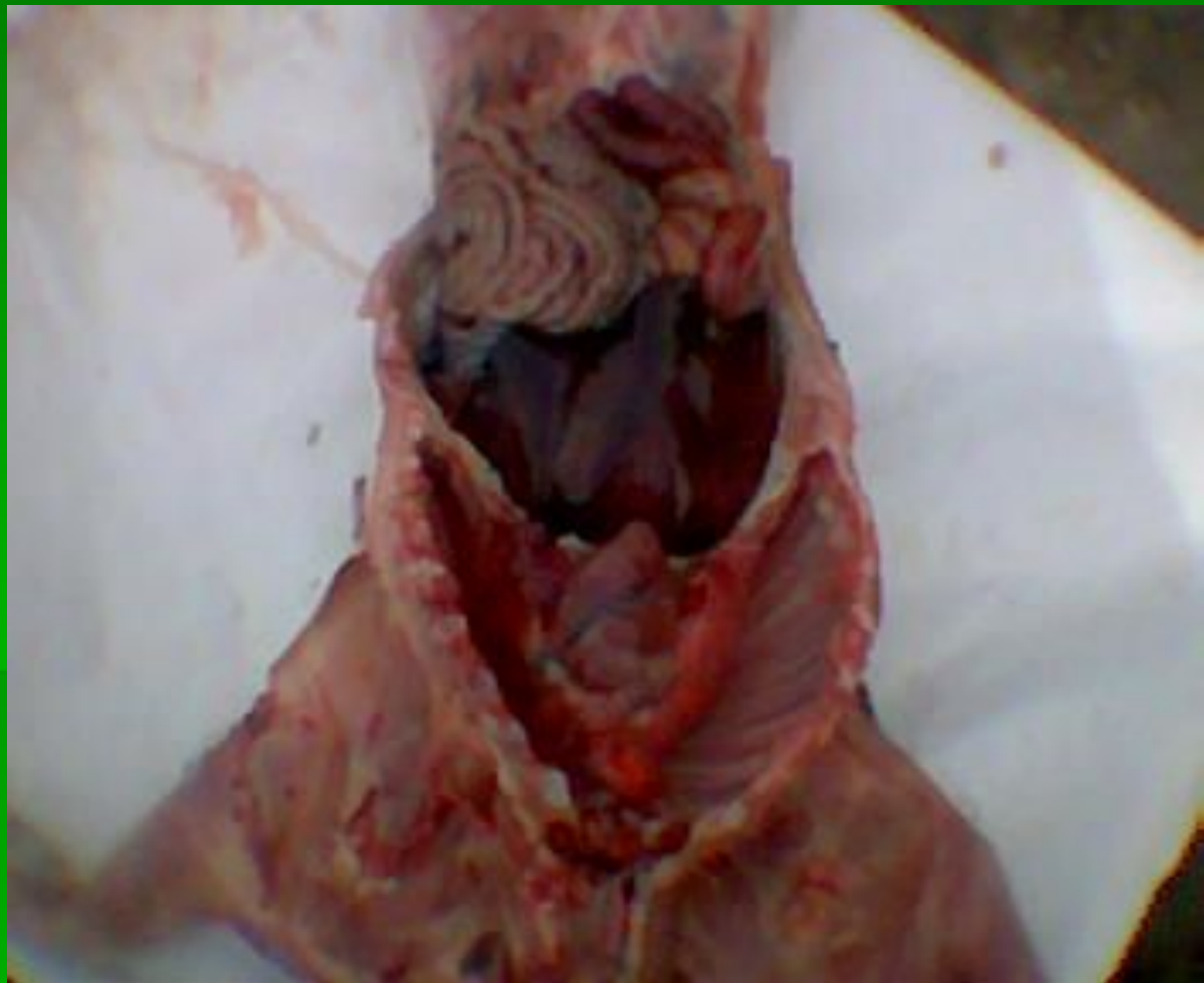Грипп свиней

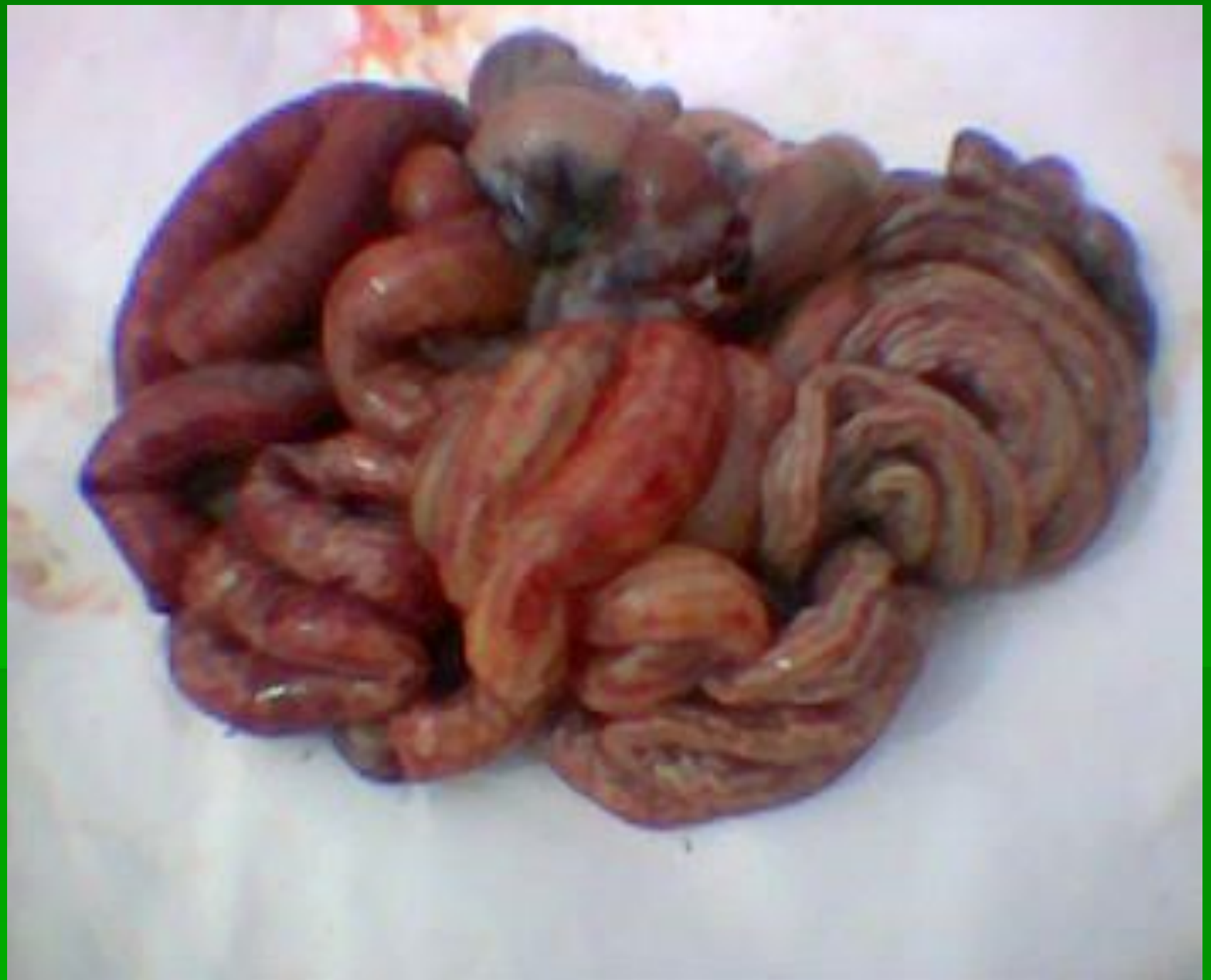

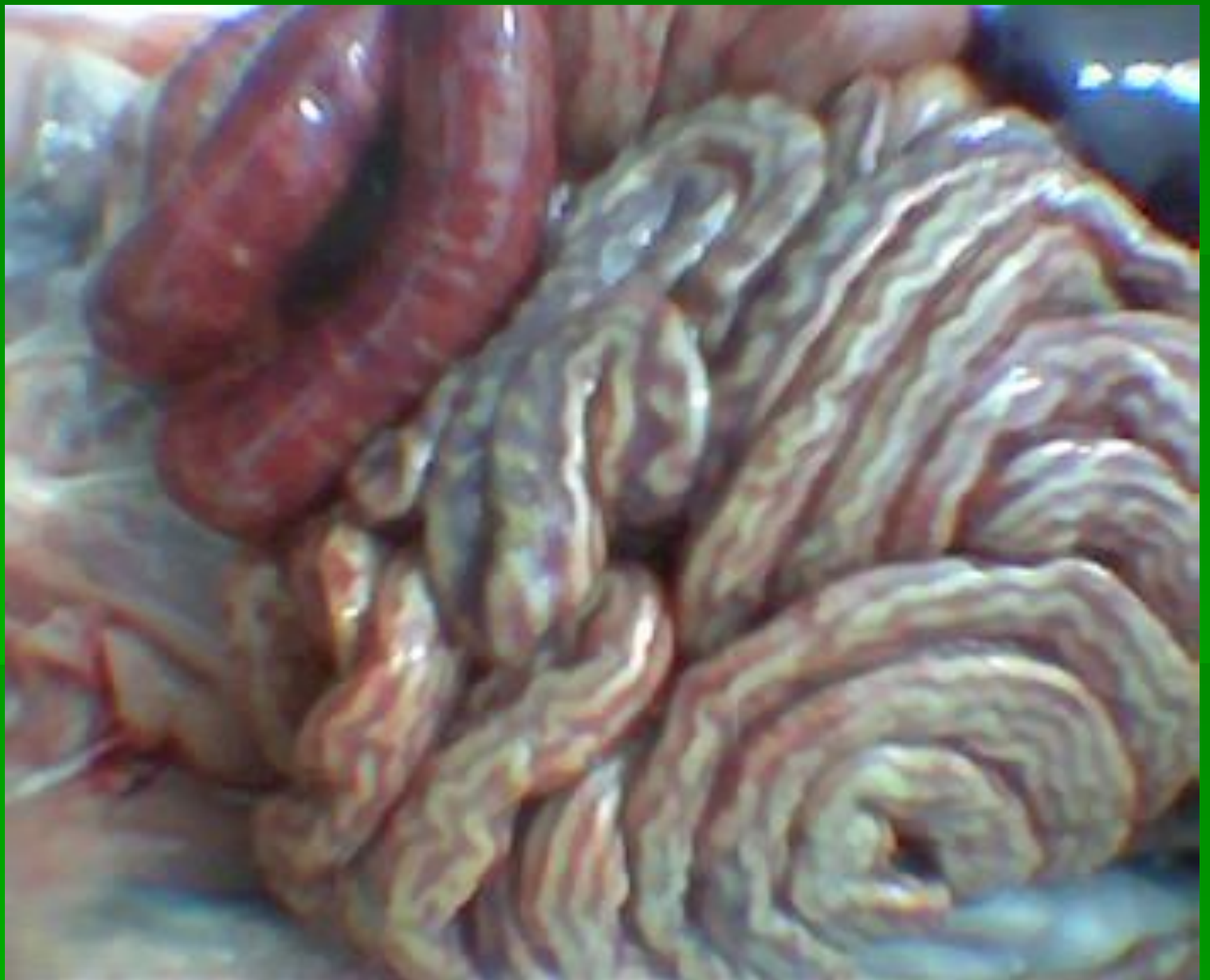
Заболевания ЖКТ

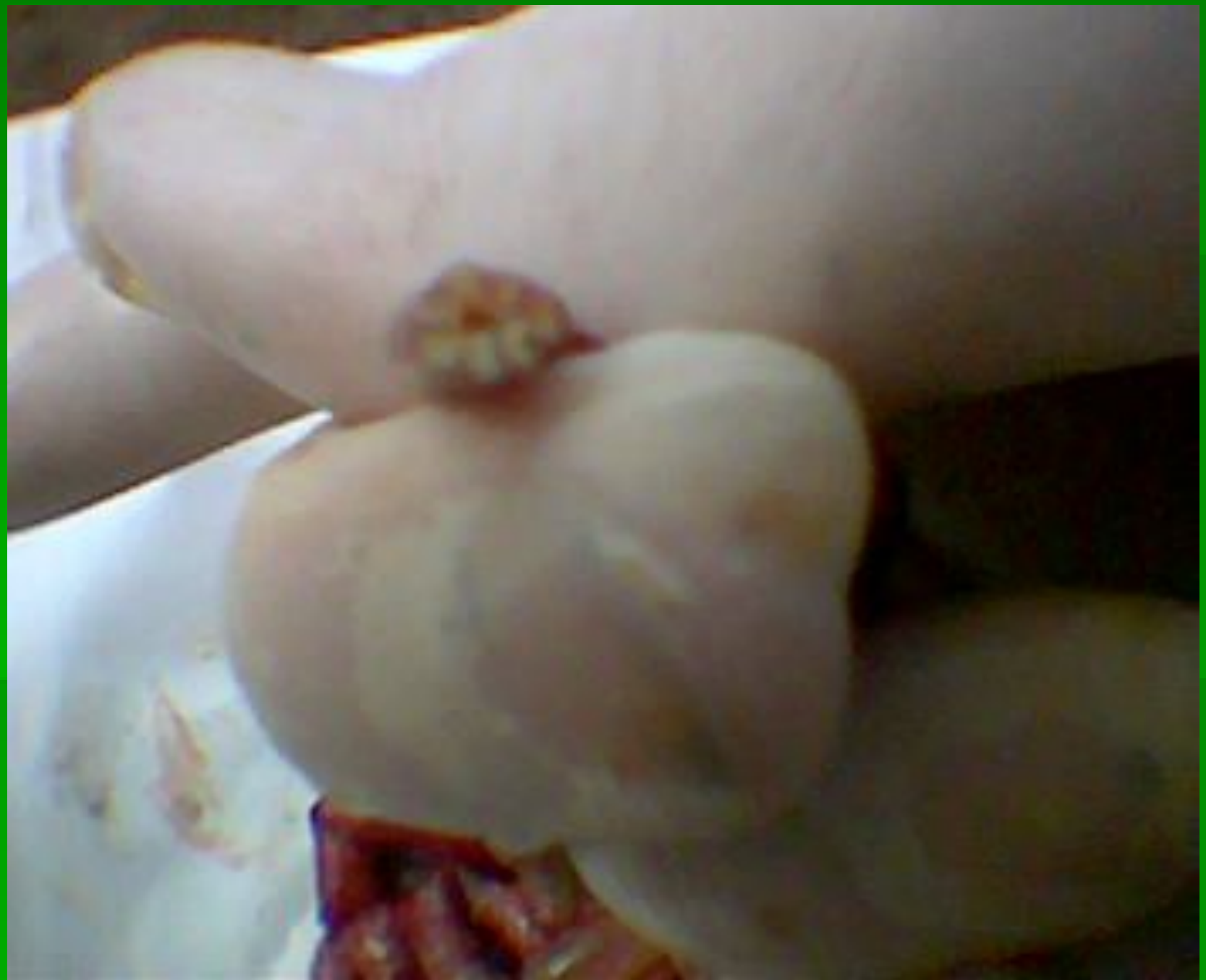Анаэробная энтеротоксемия

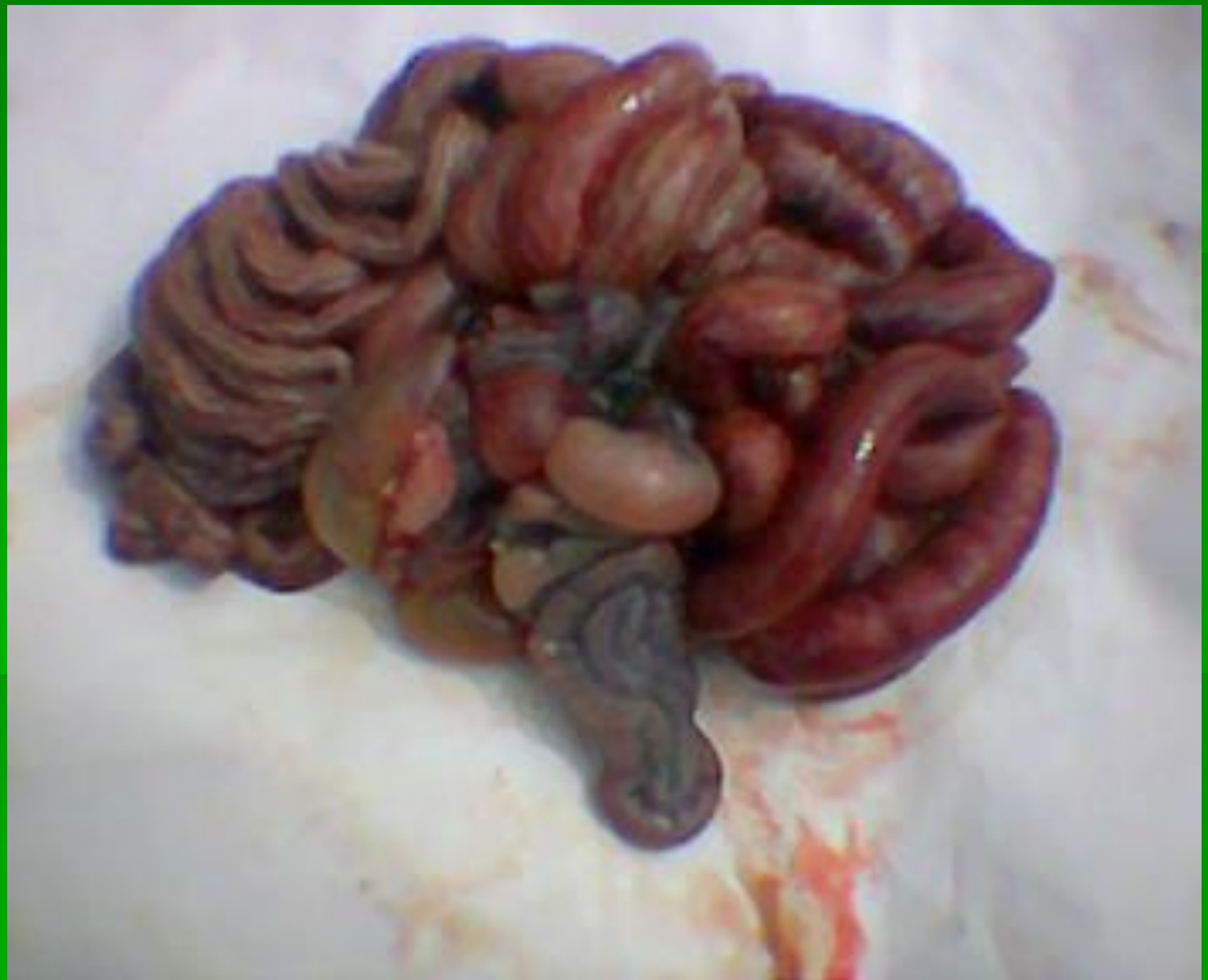


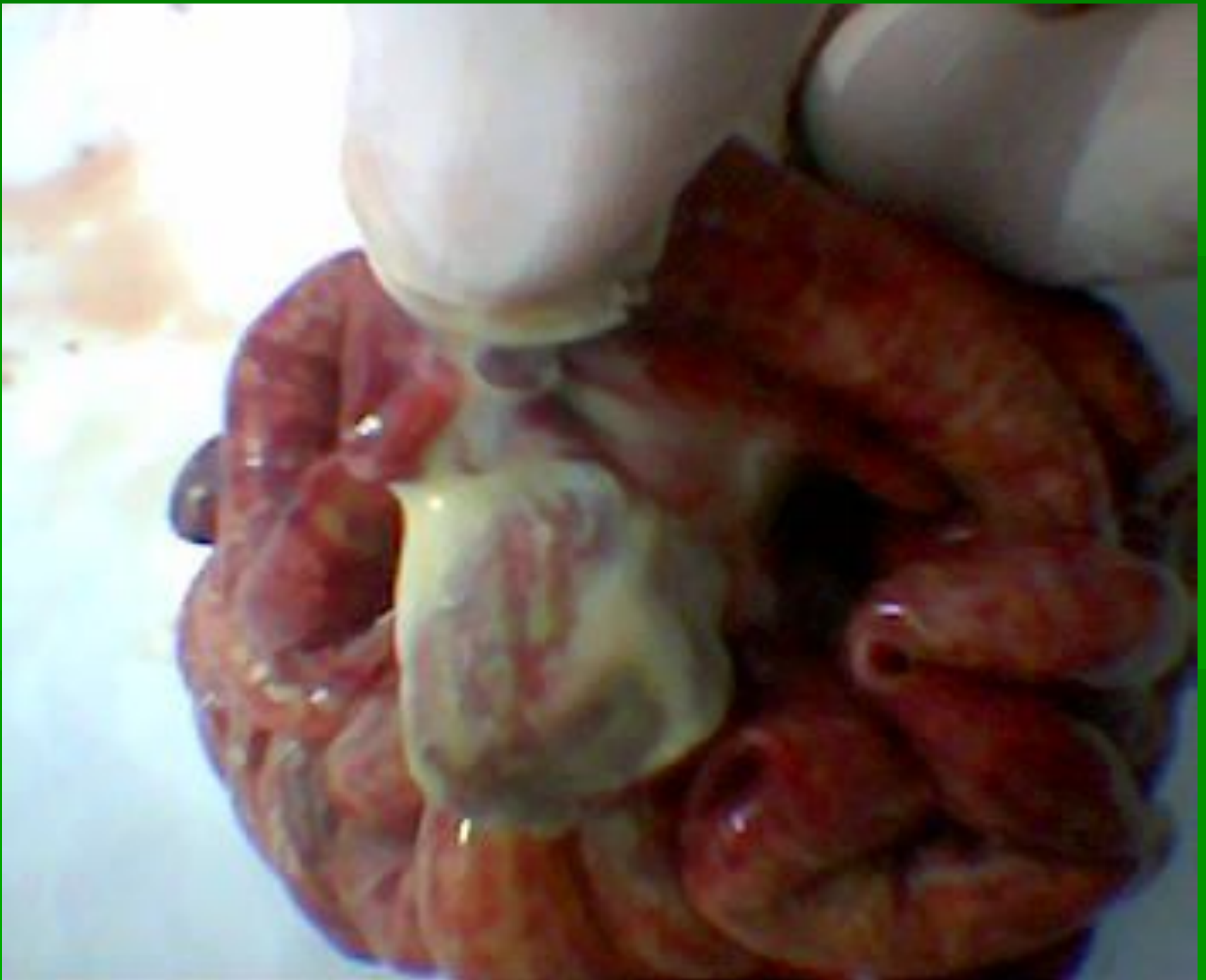






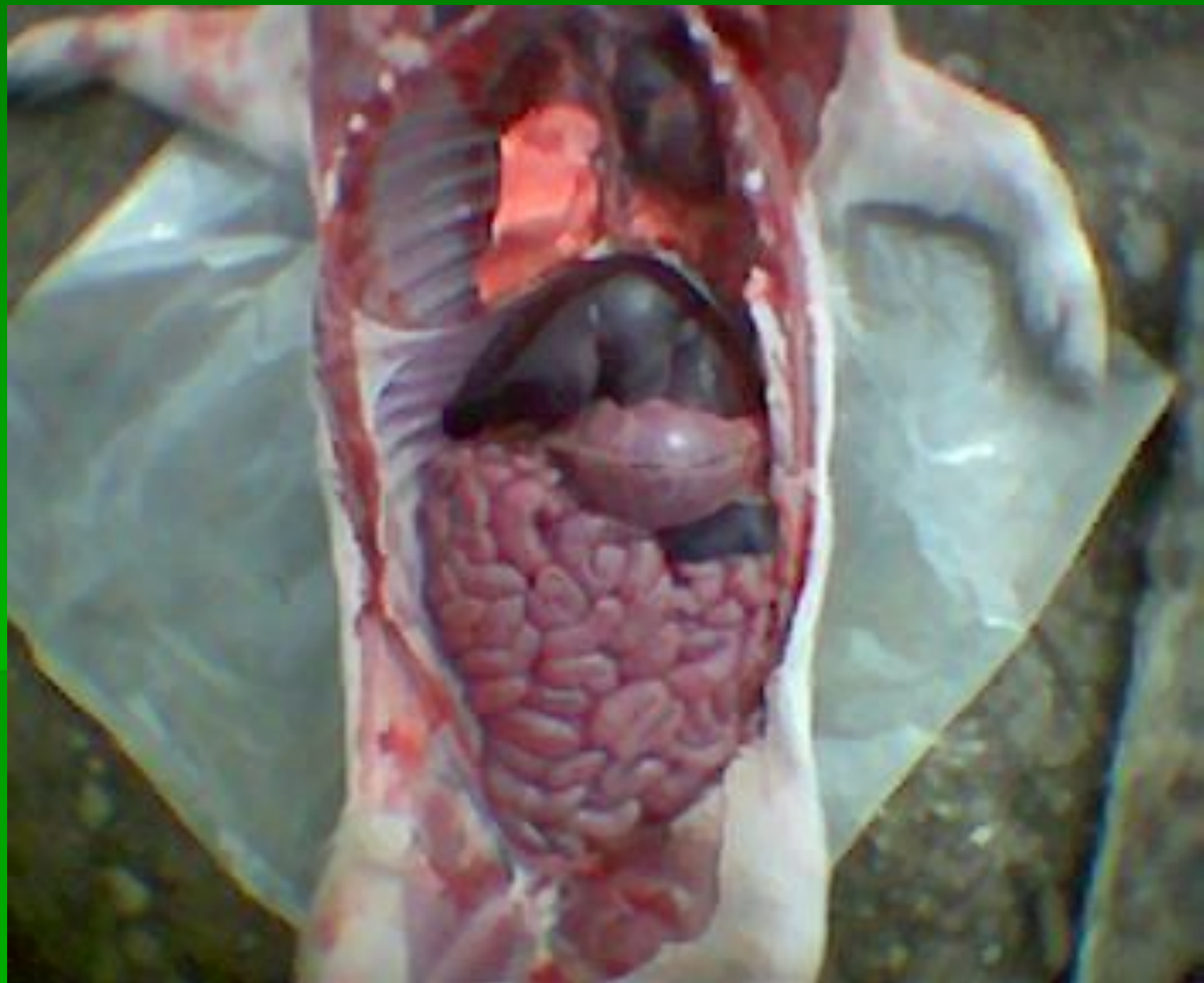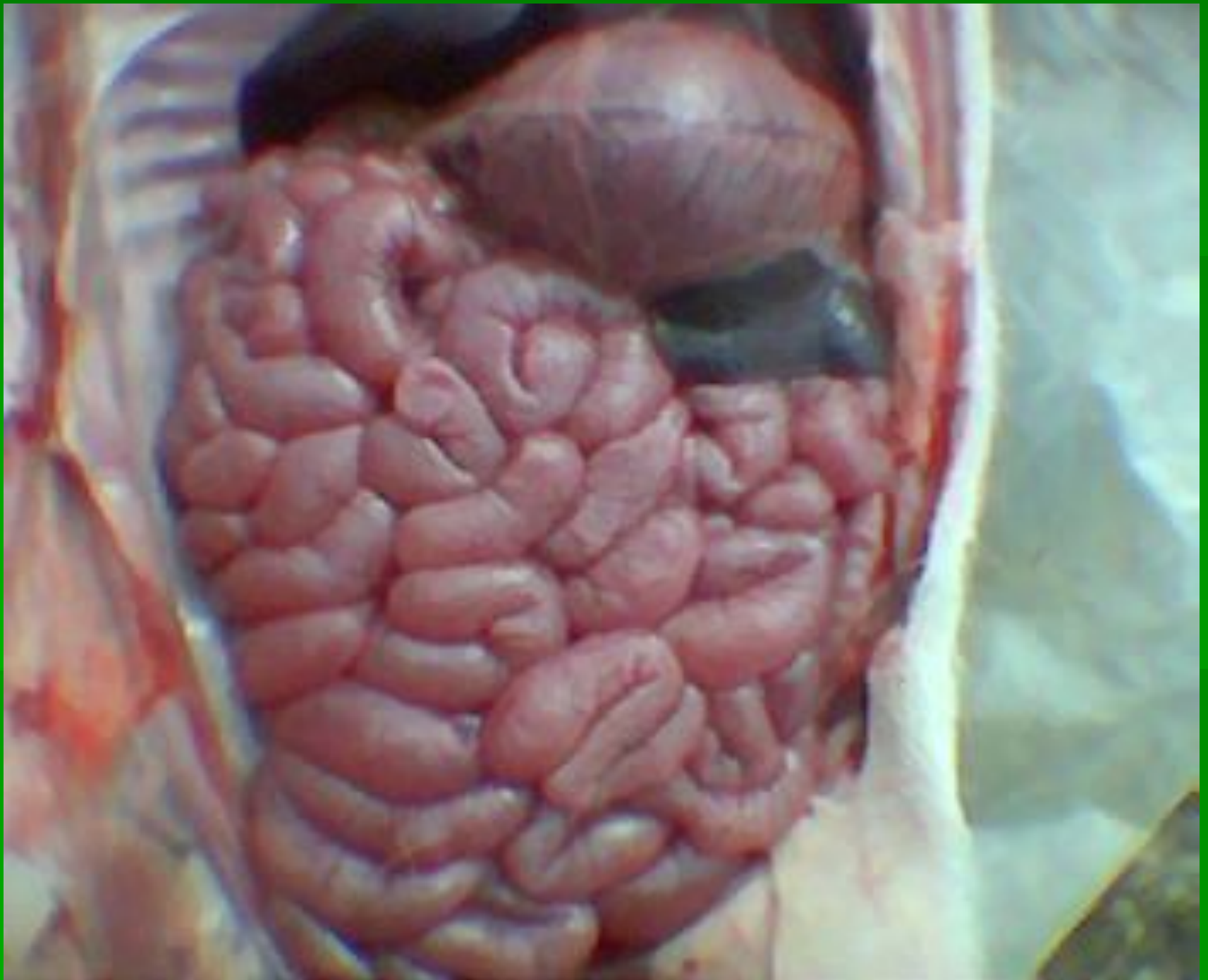




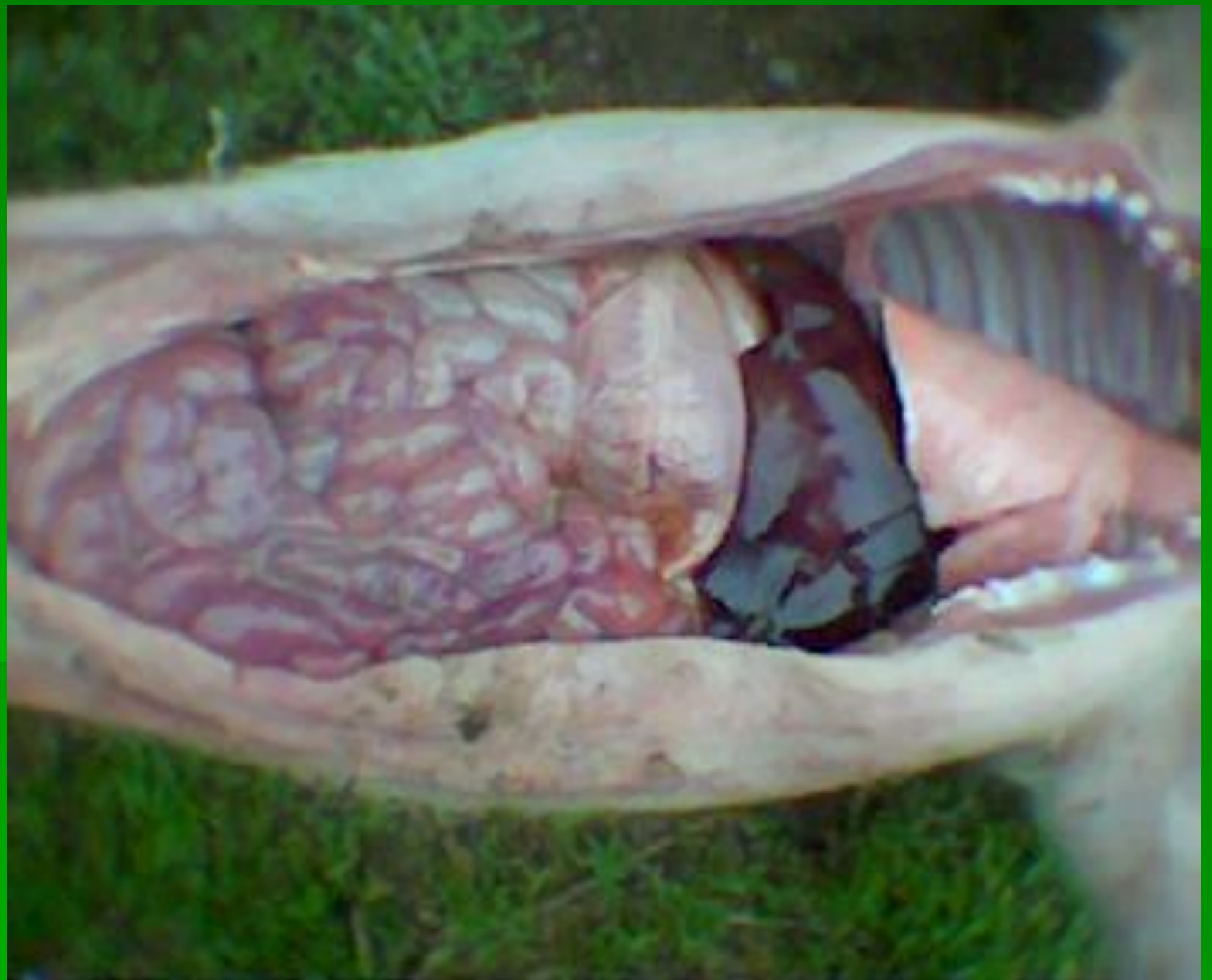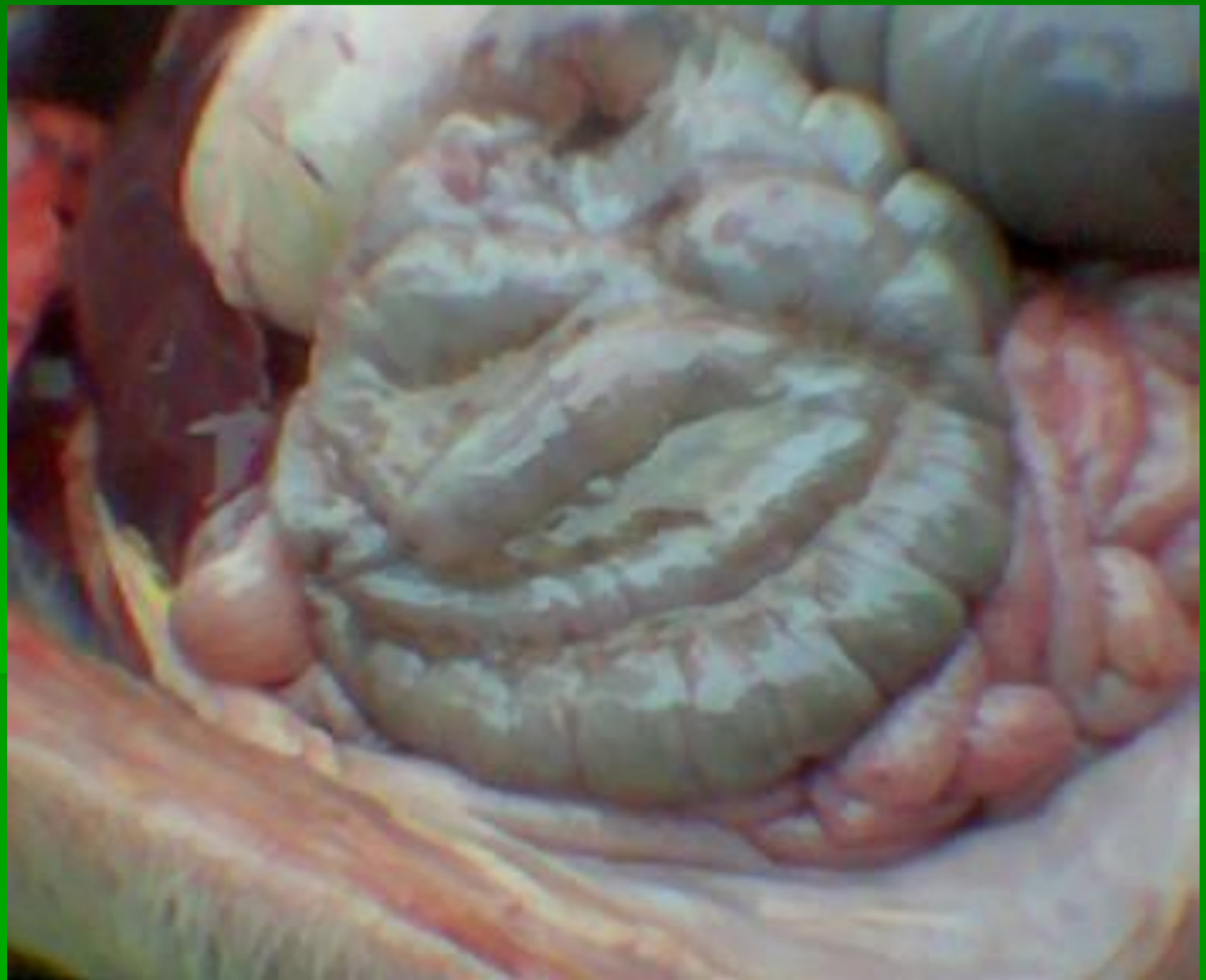Колібактеріо

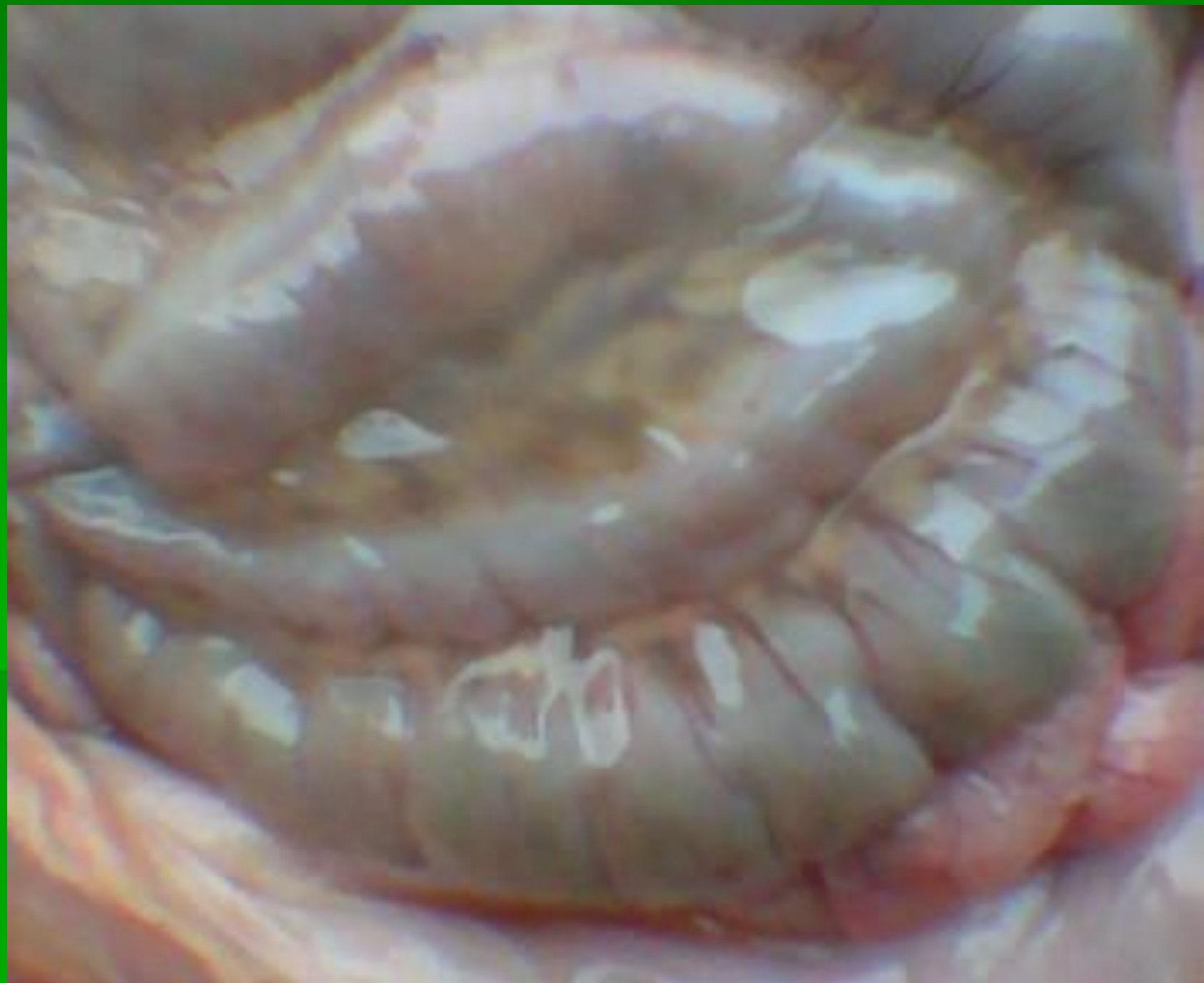з





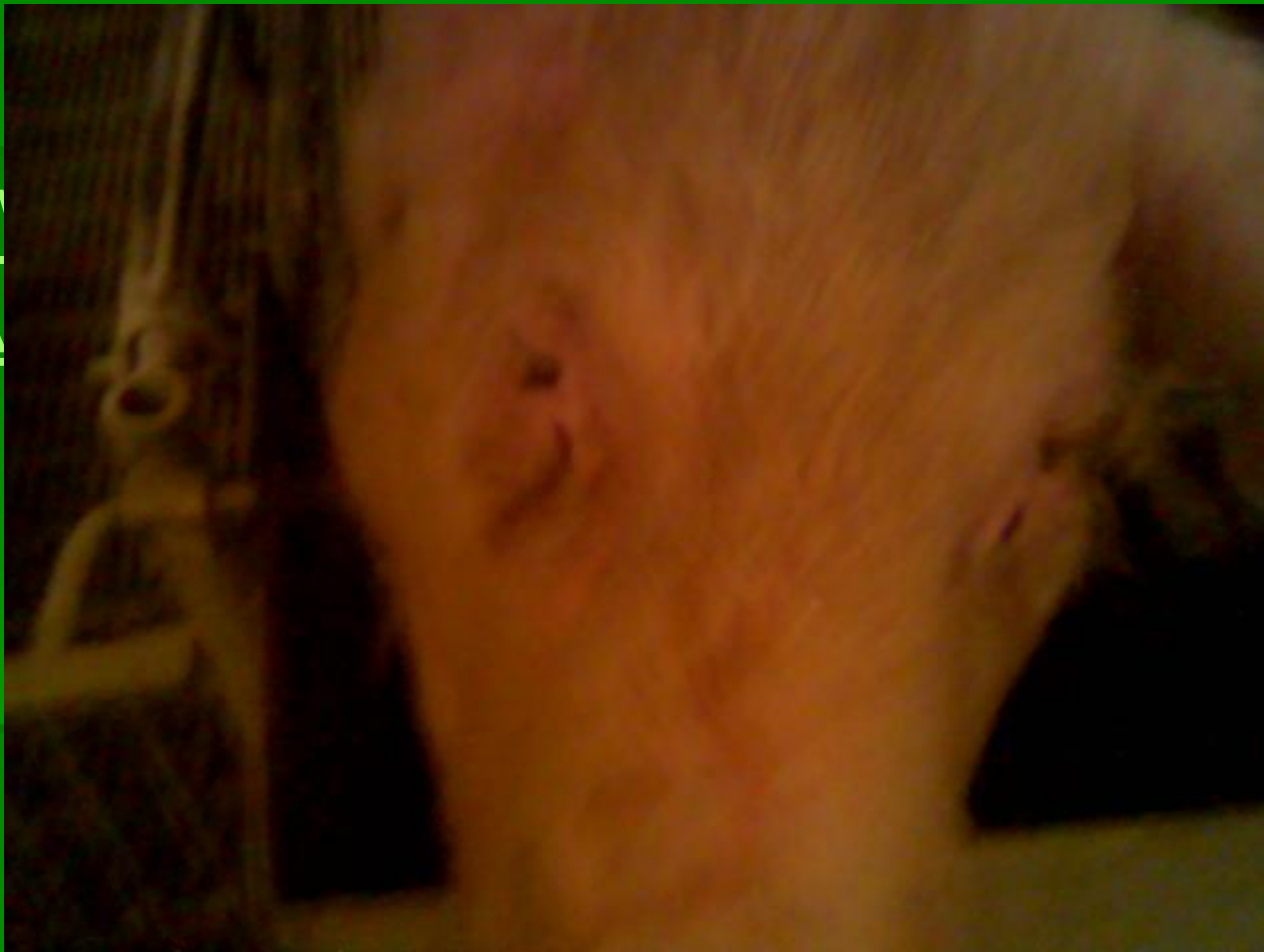




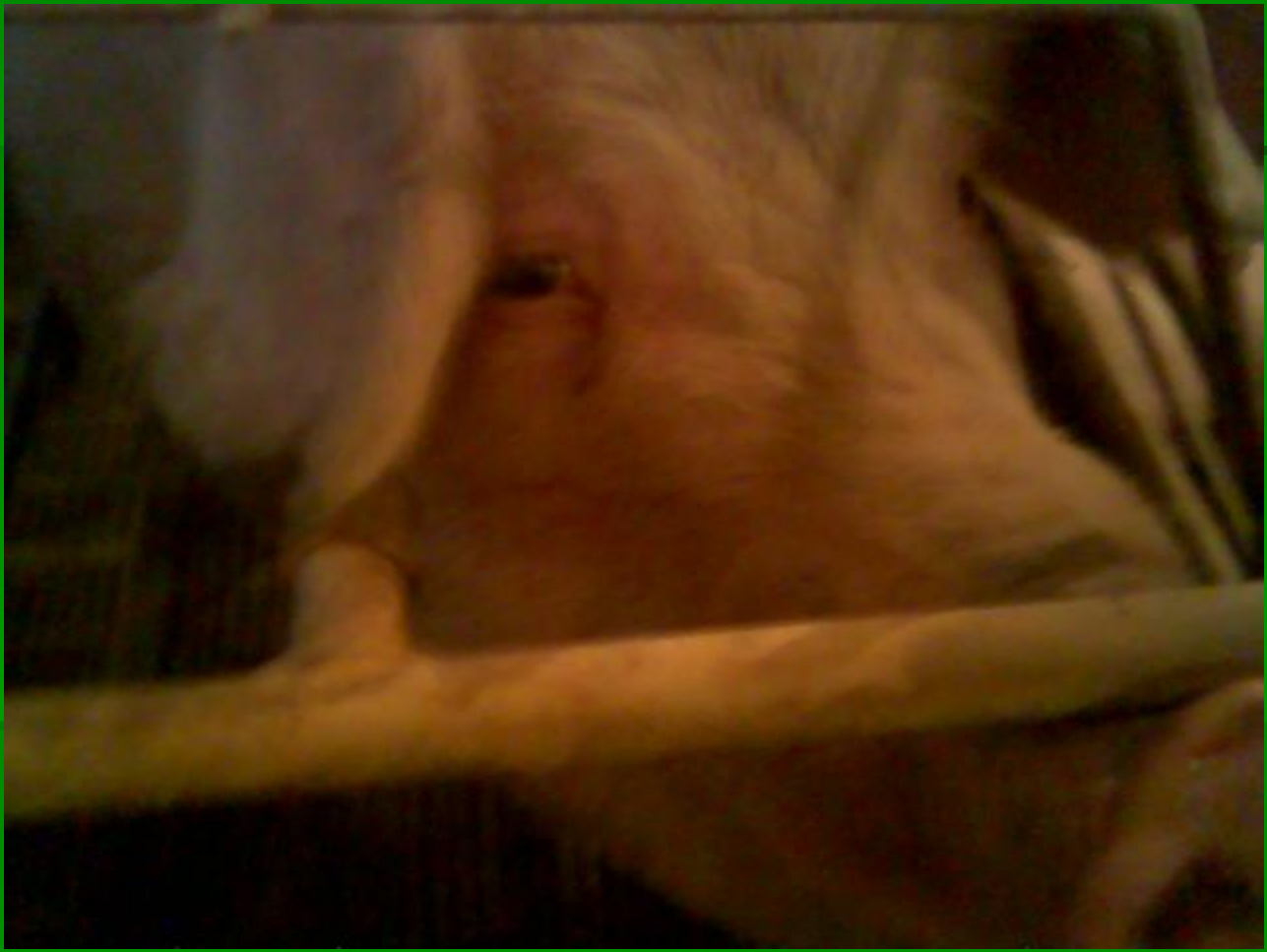
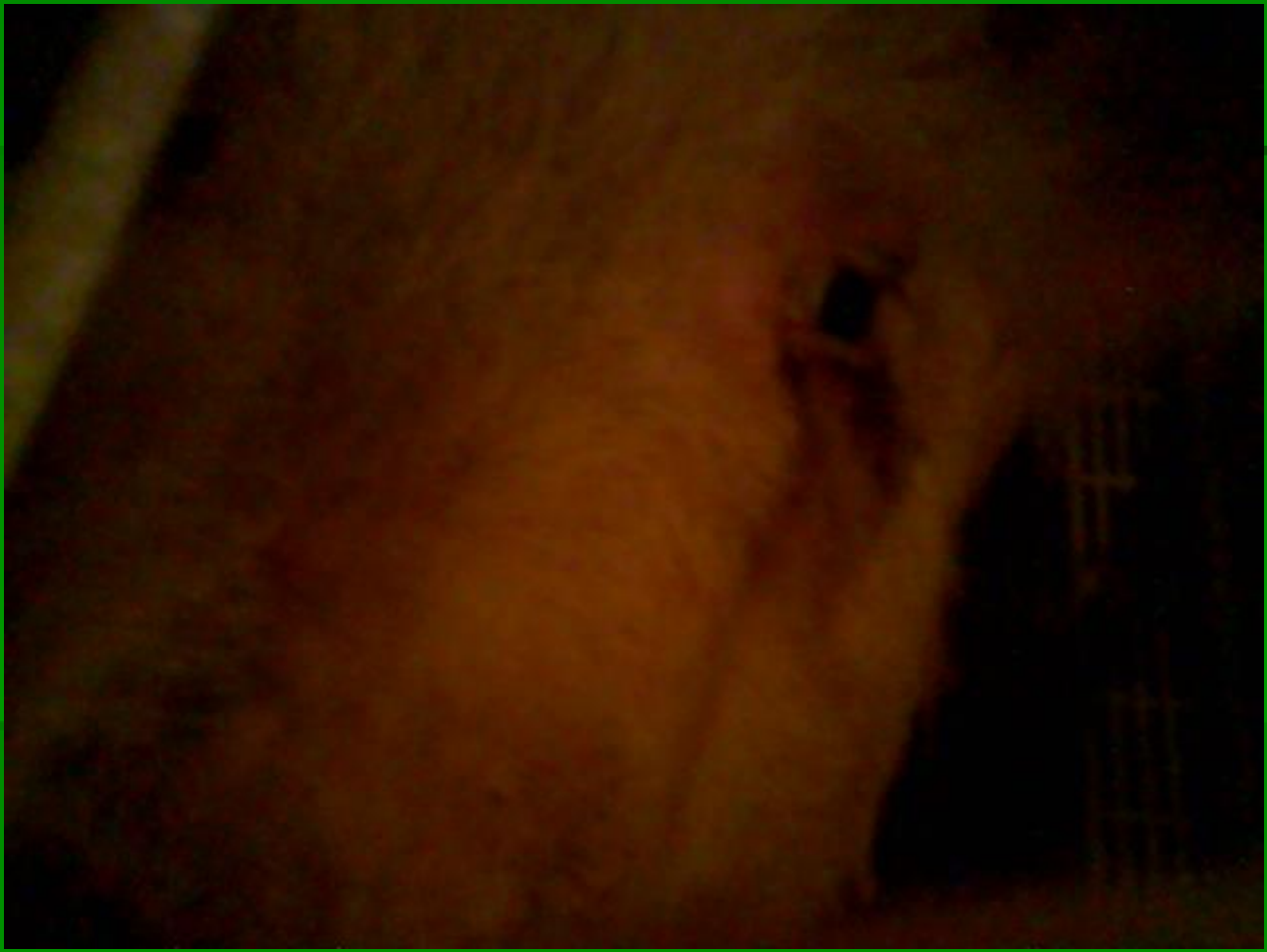КОНЬЮНКТИВИТ

■ А



ТОГР





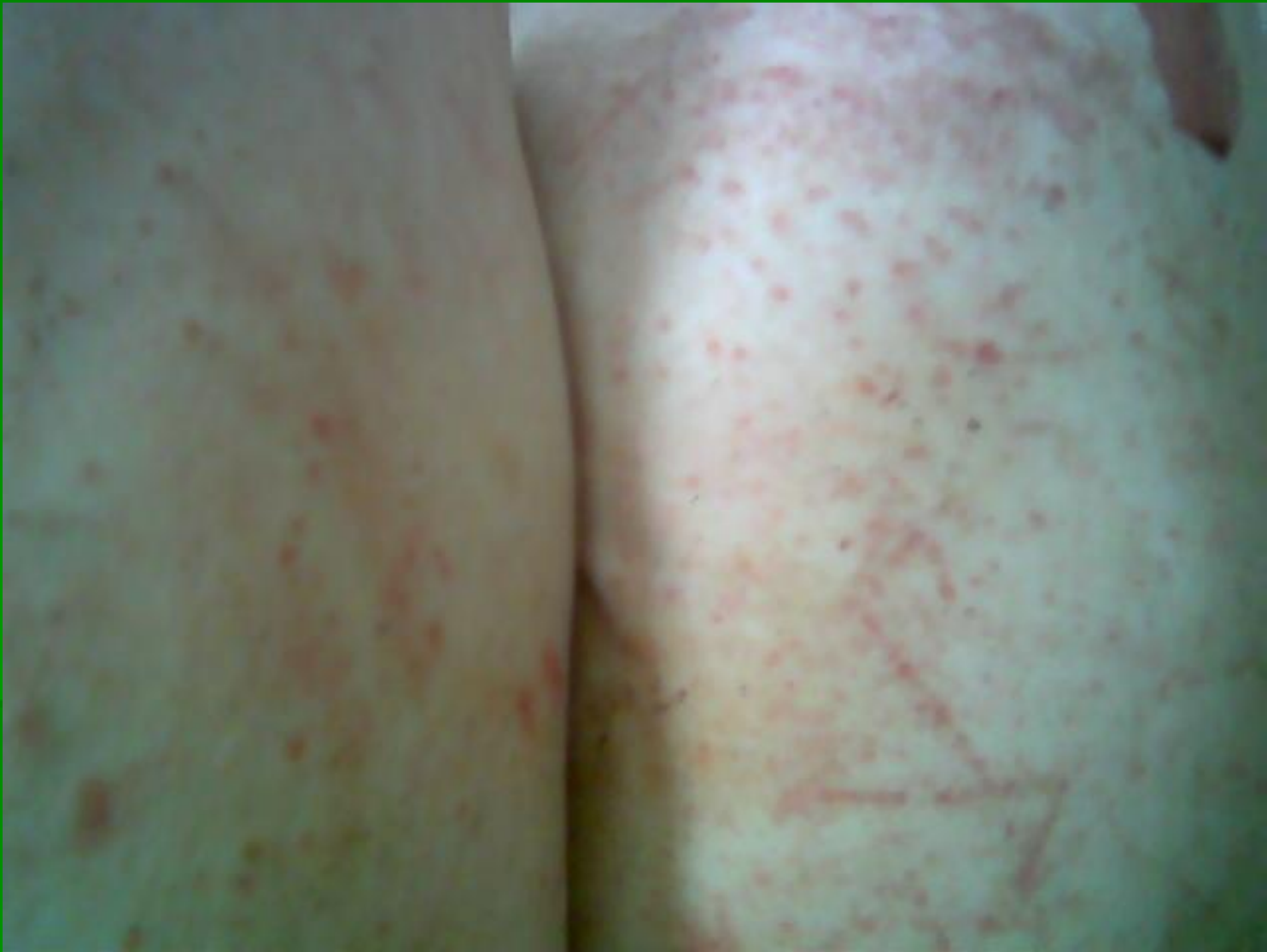


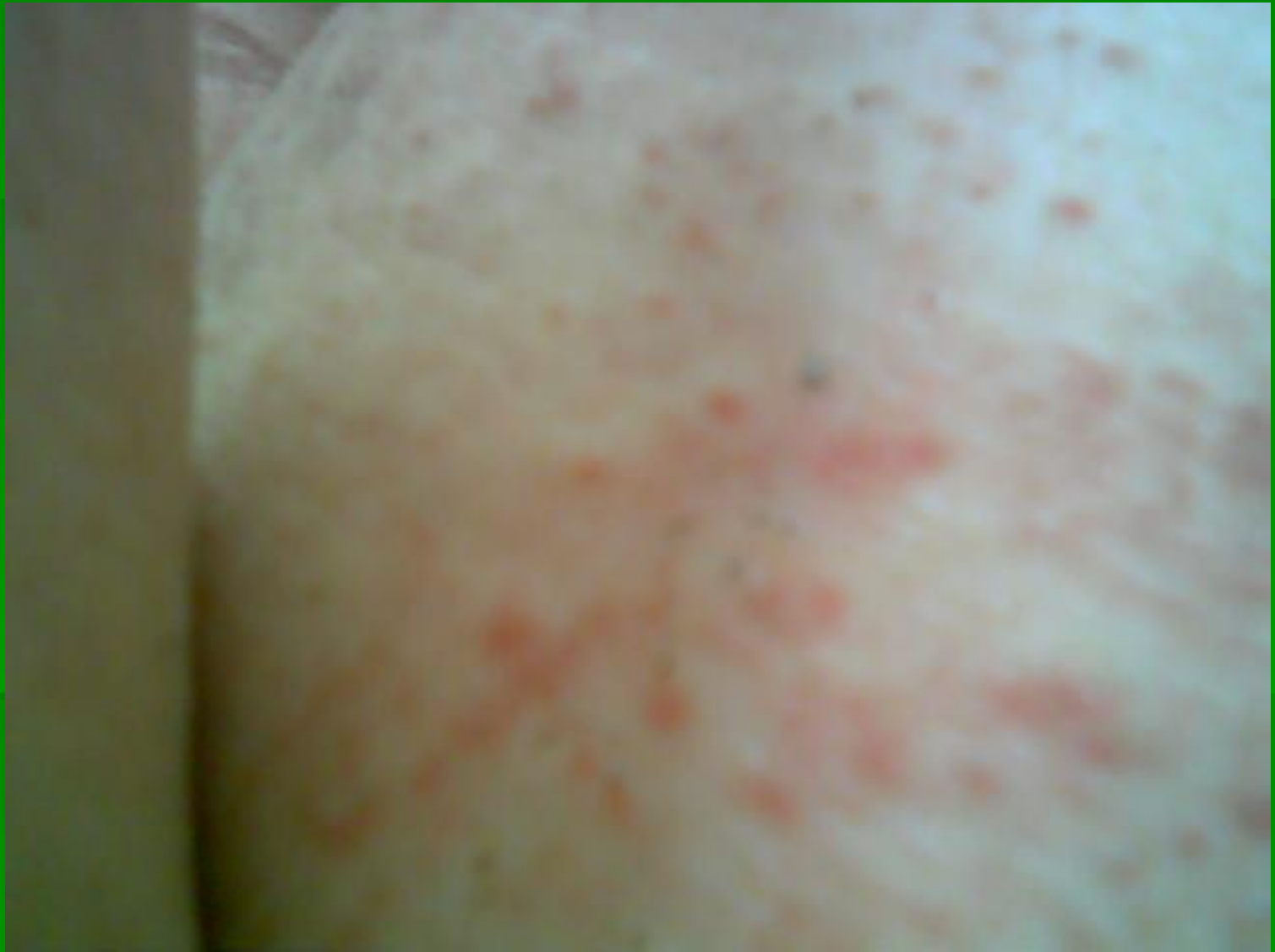


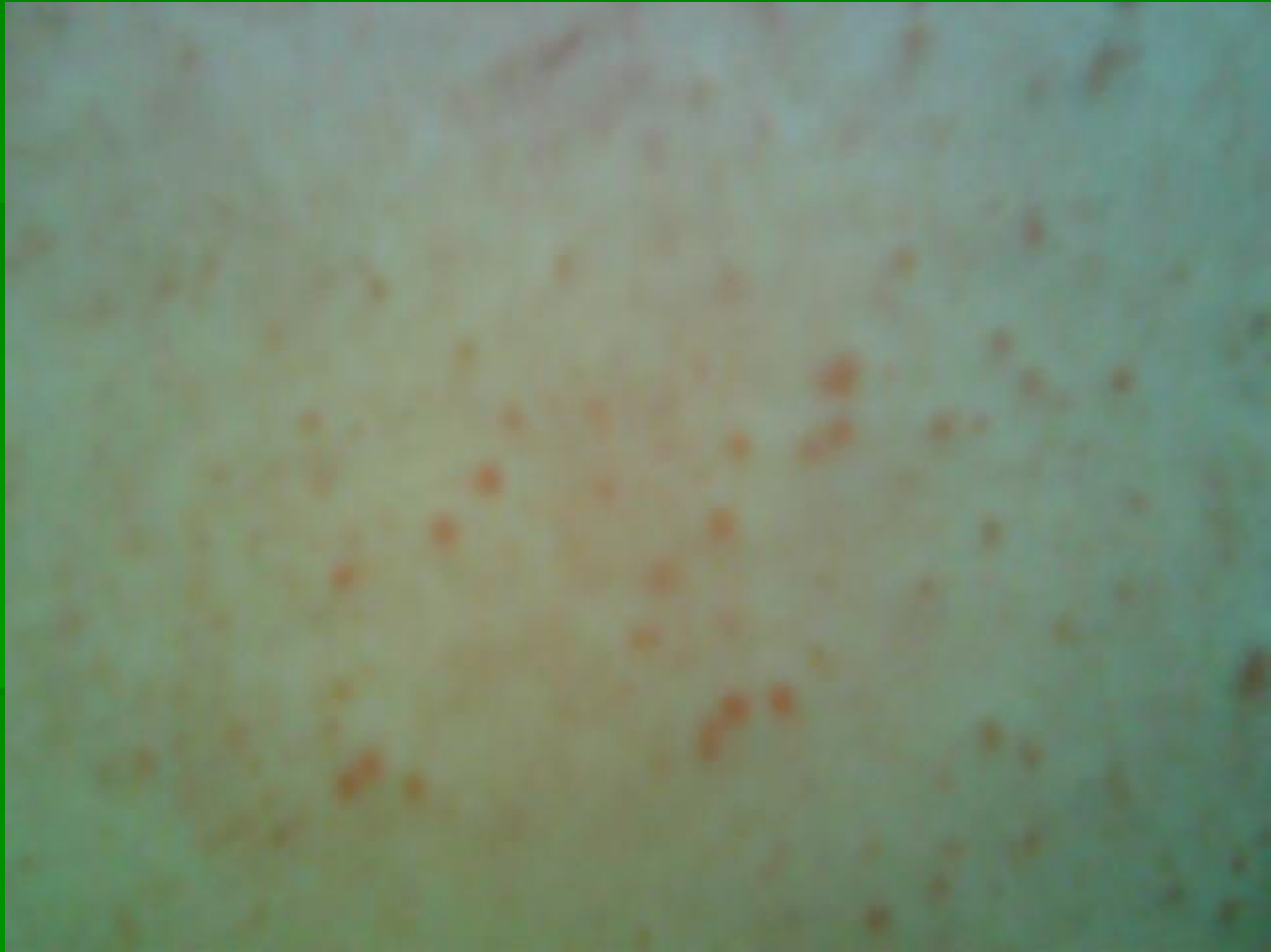

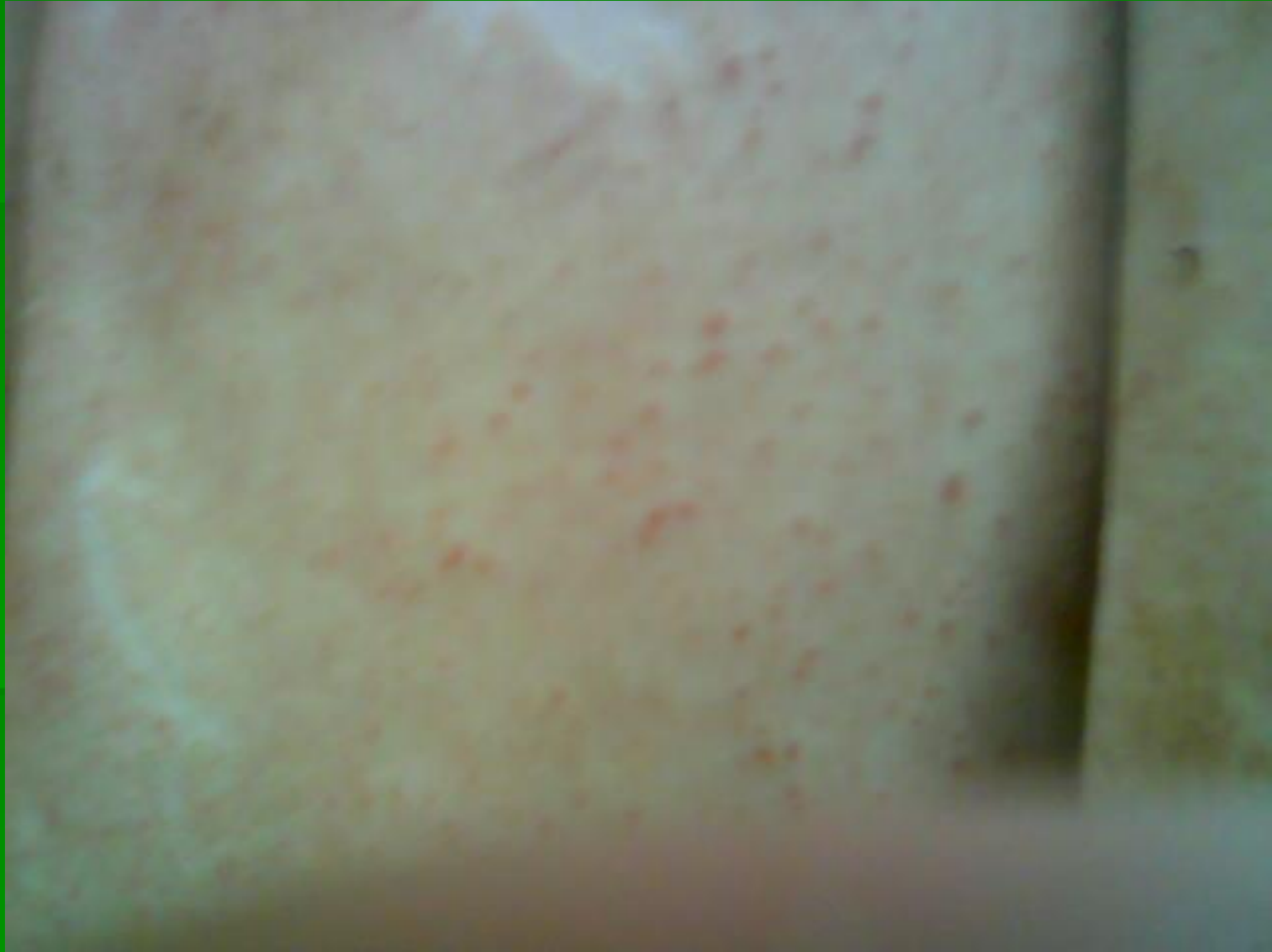САРКОПТОЗ

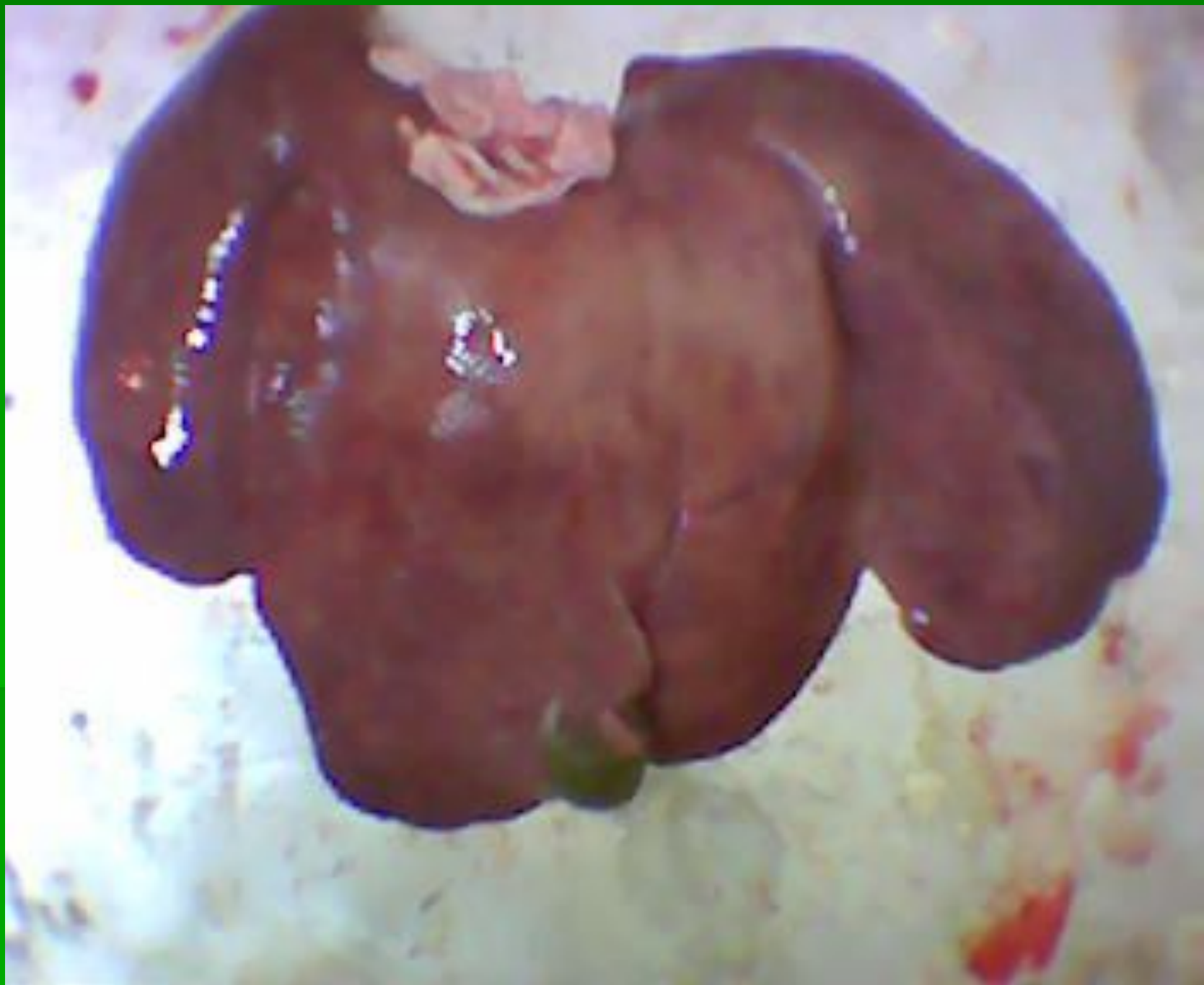

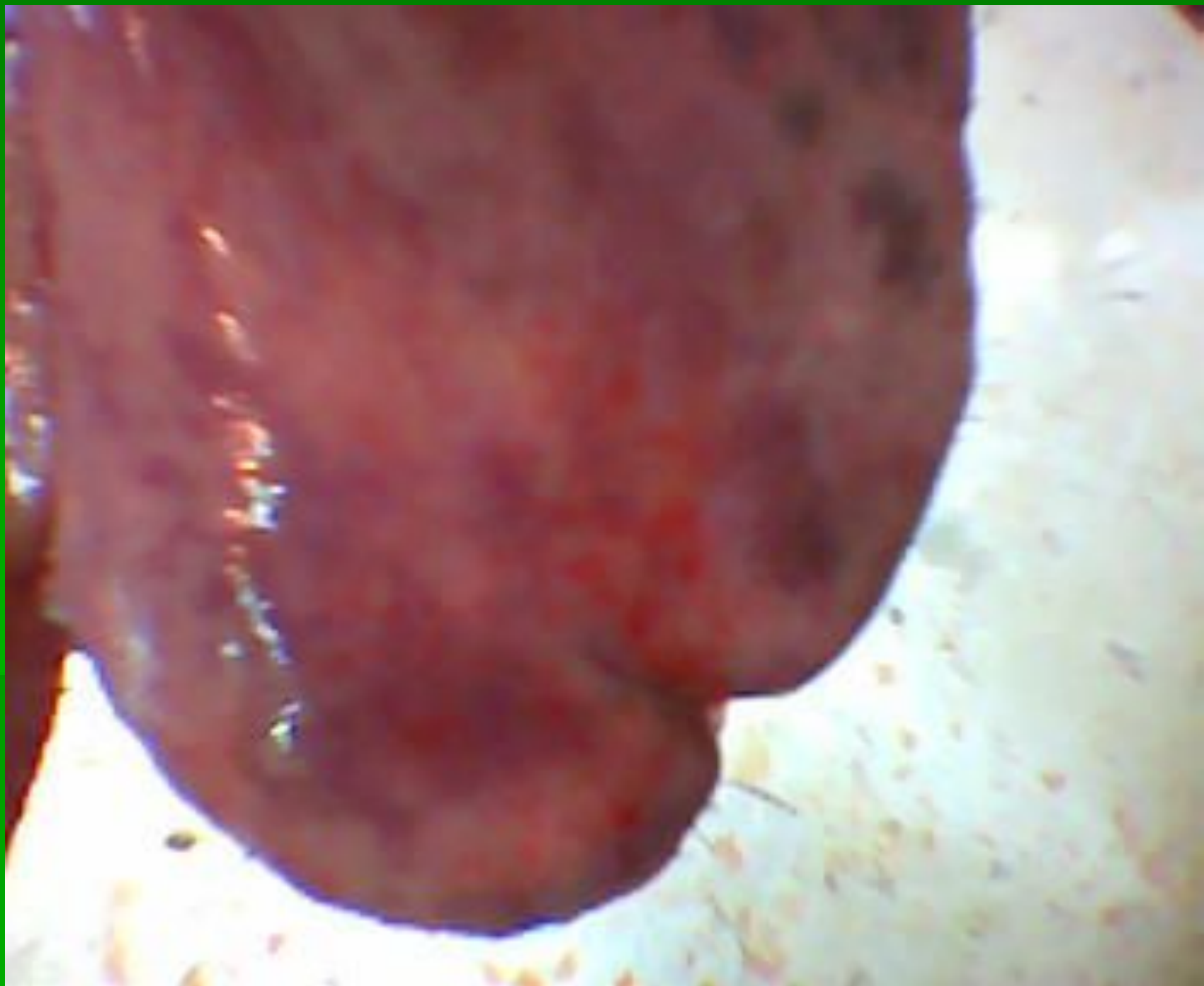



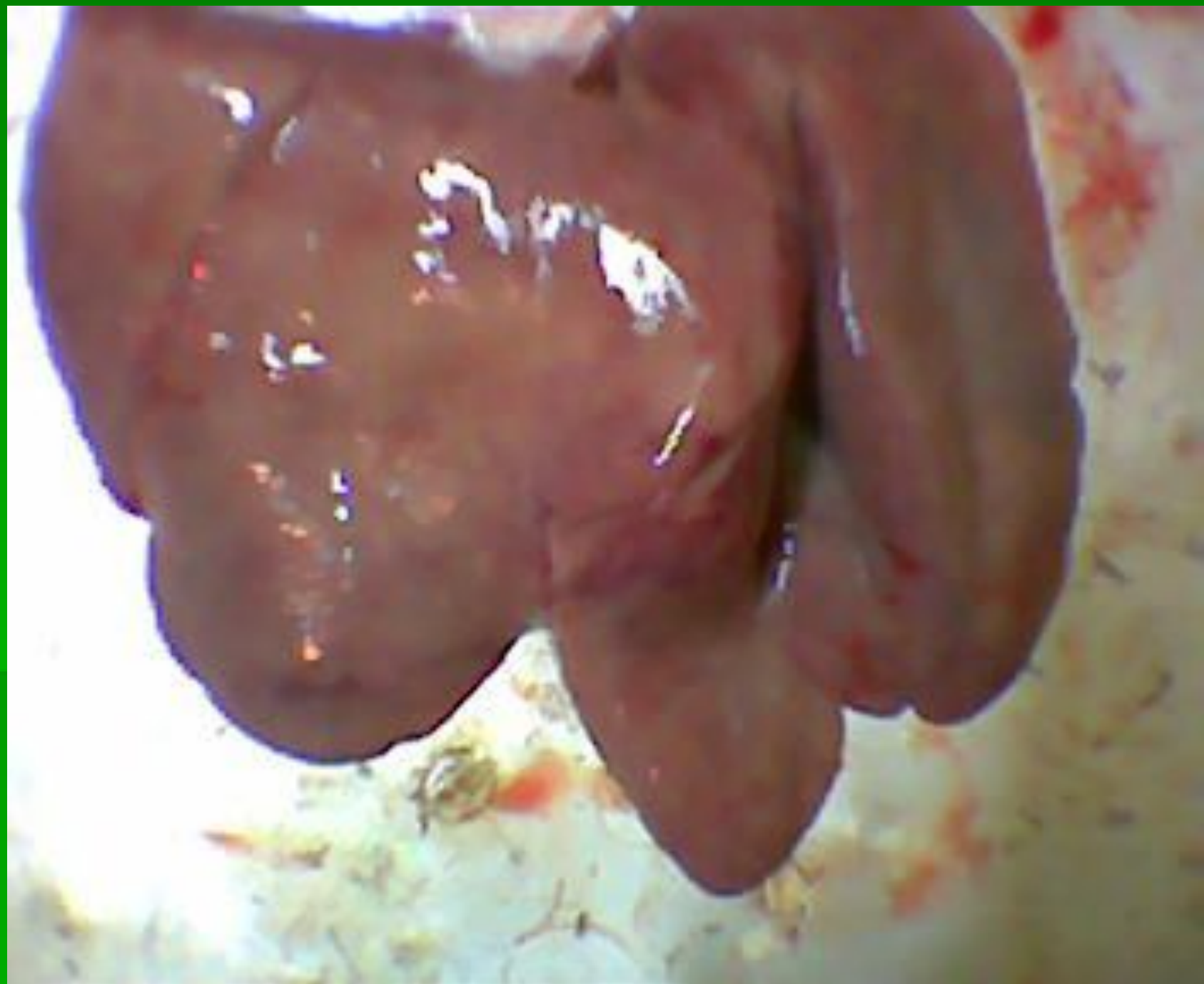


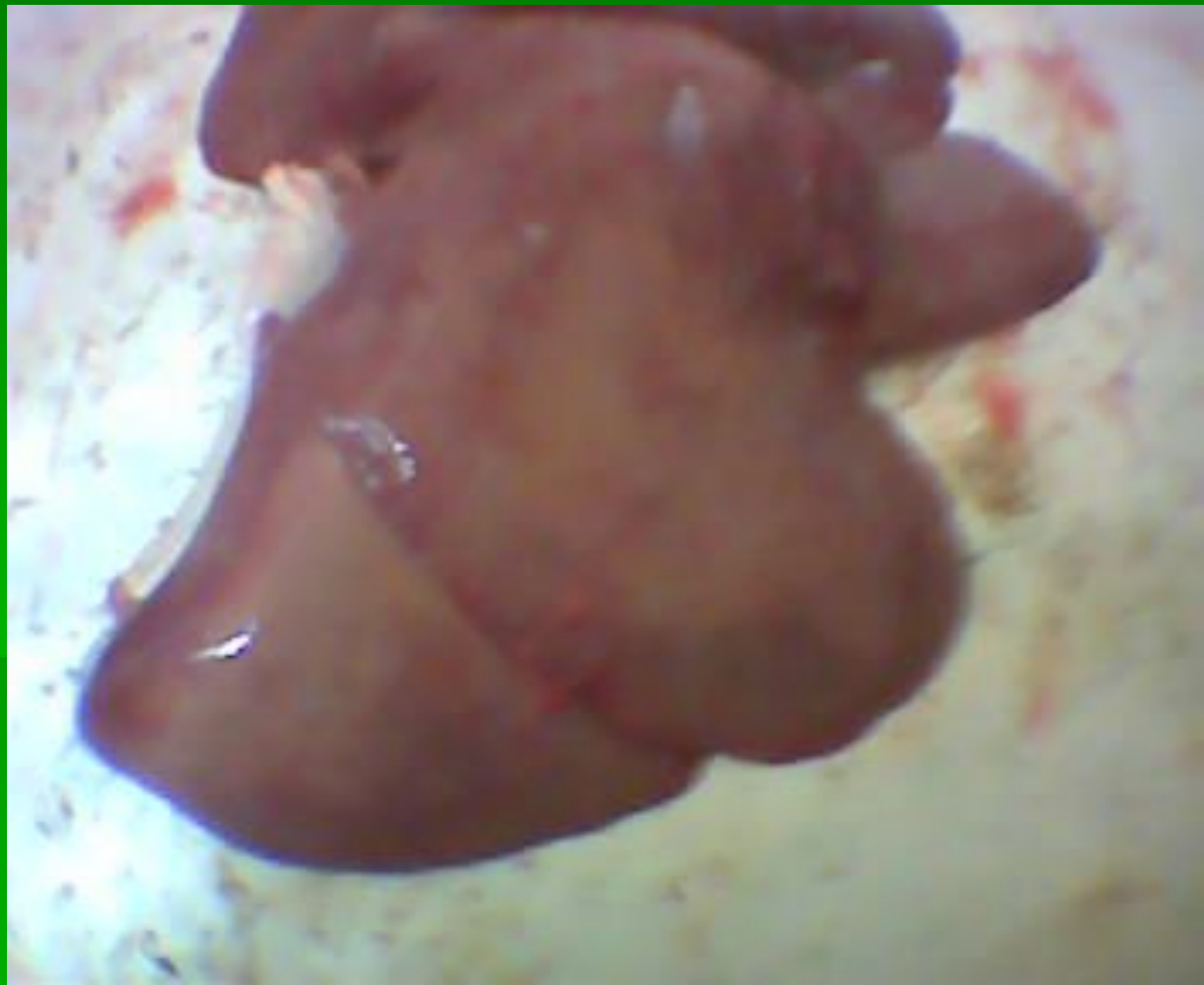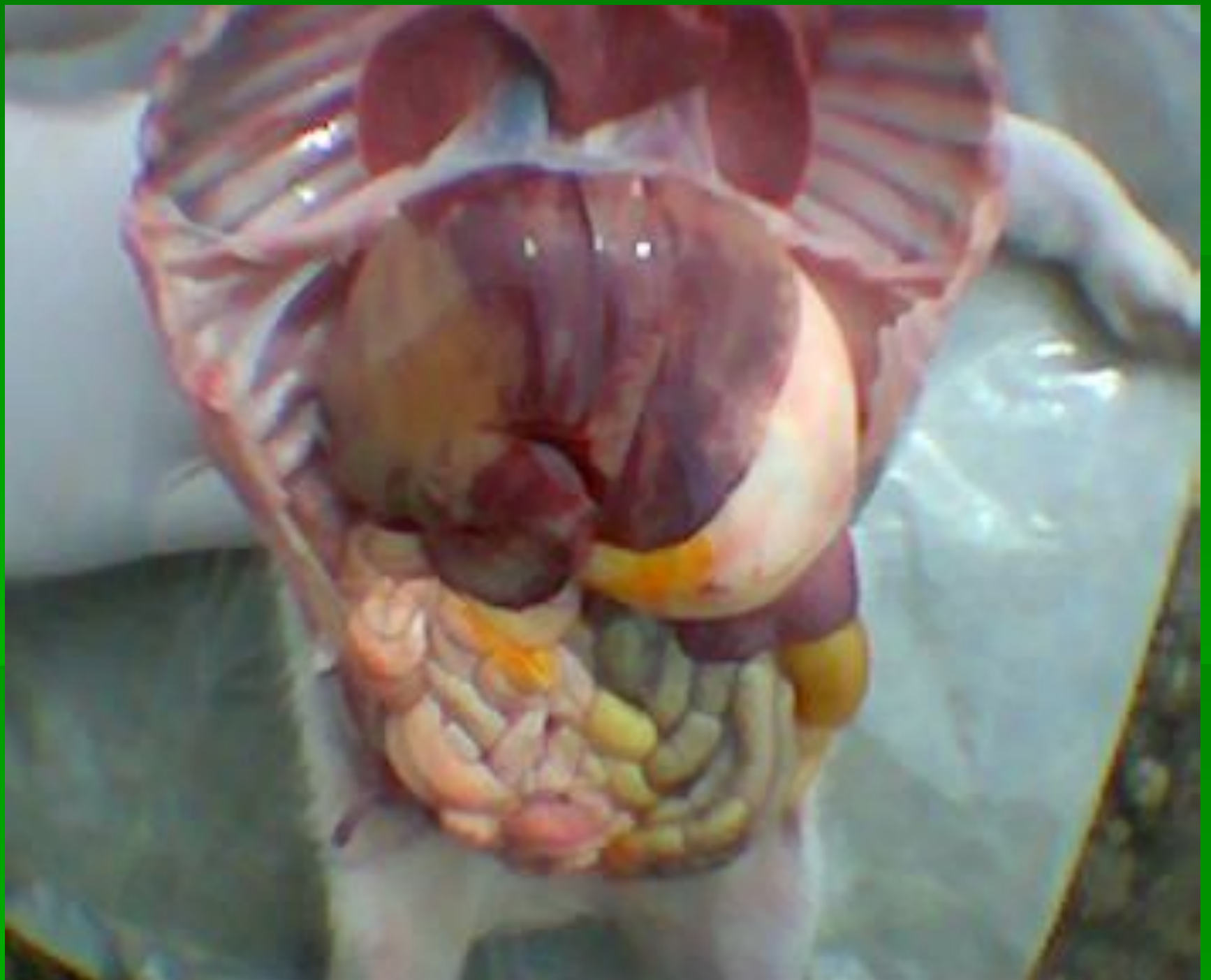Токсическая дистрофия печени











Организационно- технологические проблемы

















