# ВВЕДЕНИЕ В НЕЙРОХИРУРГИЮ

**Нейрохирургия — раздел хирургии, занимающийся вопросами оперативного лечения заболеваний нервной системы включая**

**головной мозг, спинной мозг и периферическую нервную систему**

# Спинальная нейрохирургия

# Спинальная нейрохирургия

A
IM:
B
C

**Extradural tumors**

Lymphoma invading spinal canal via intervertebral foramen, compressing dura mater and spinal cord

**Intradural extramedullary tumors**

Meningioma compressing spinal cord and distorting nerve roots

**Intramedullary tumors**

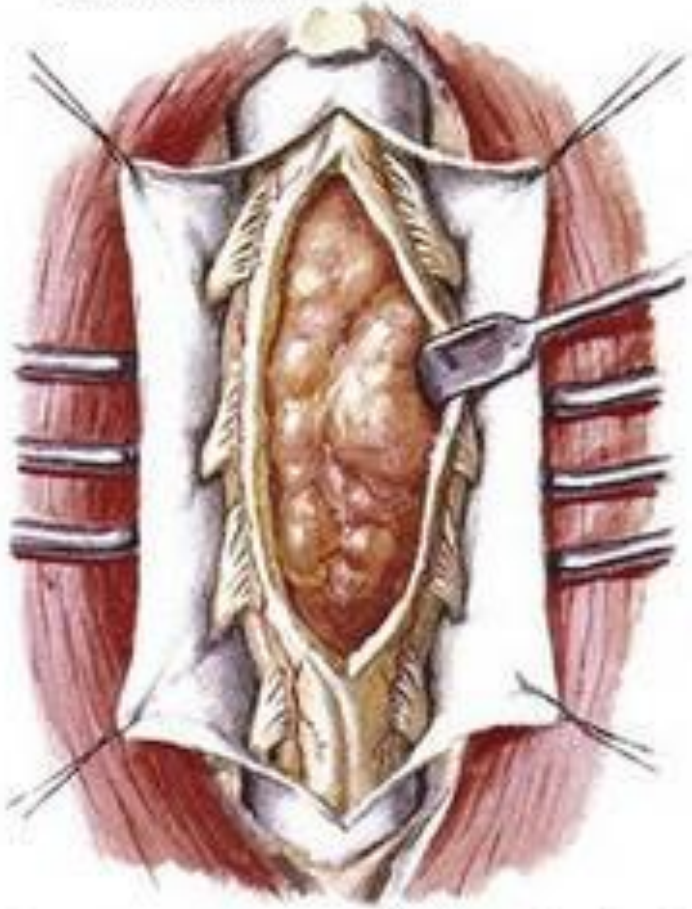

Astrocytoma exposed by longitudinal incision in bulging spinal cord

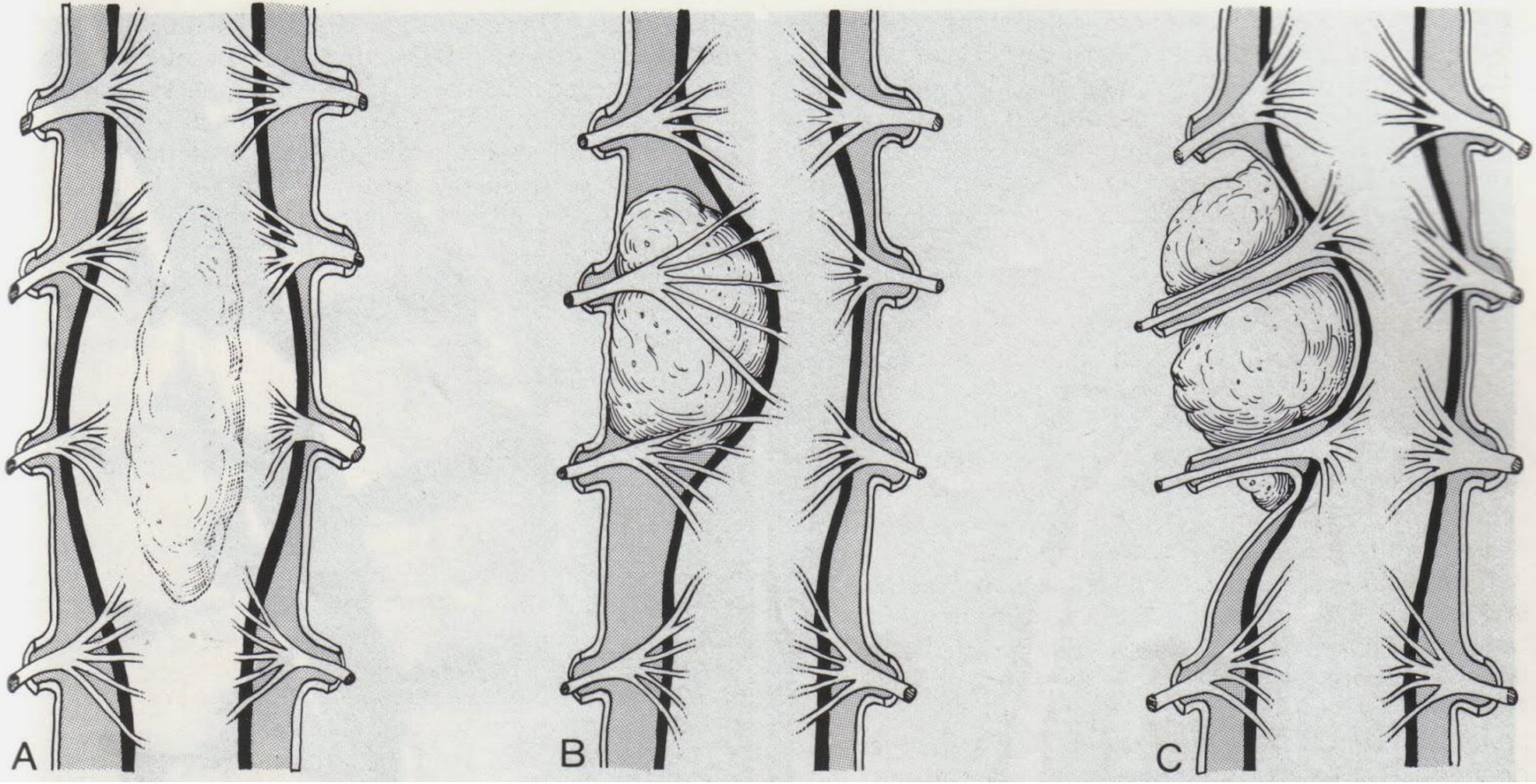
A
B
C

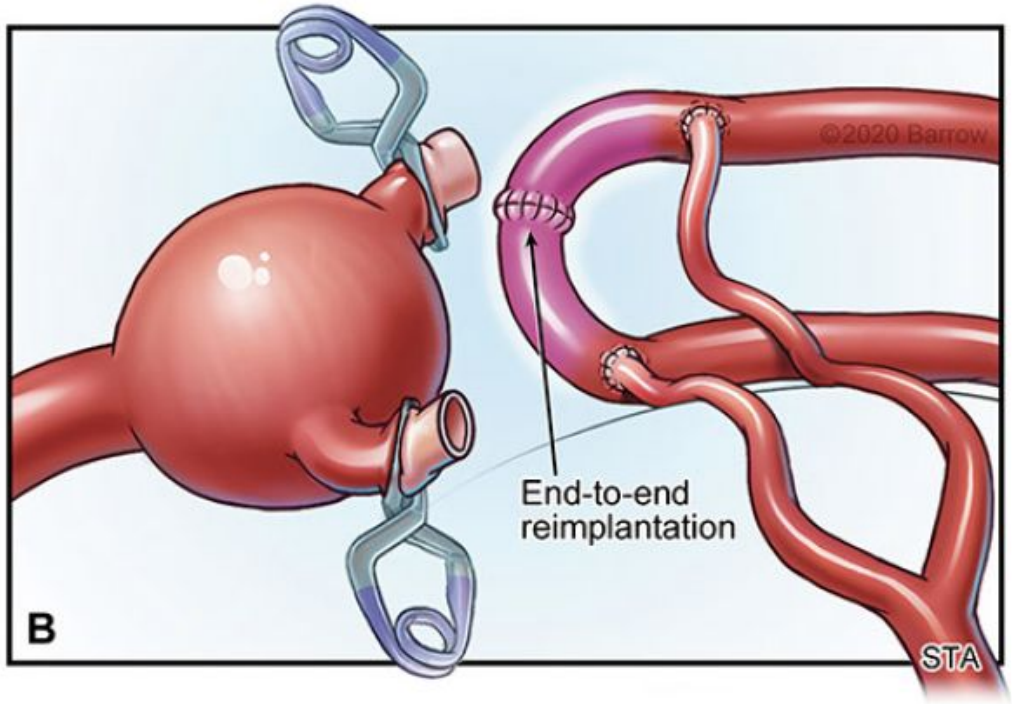


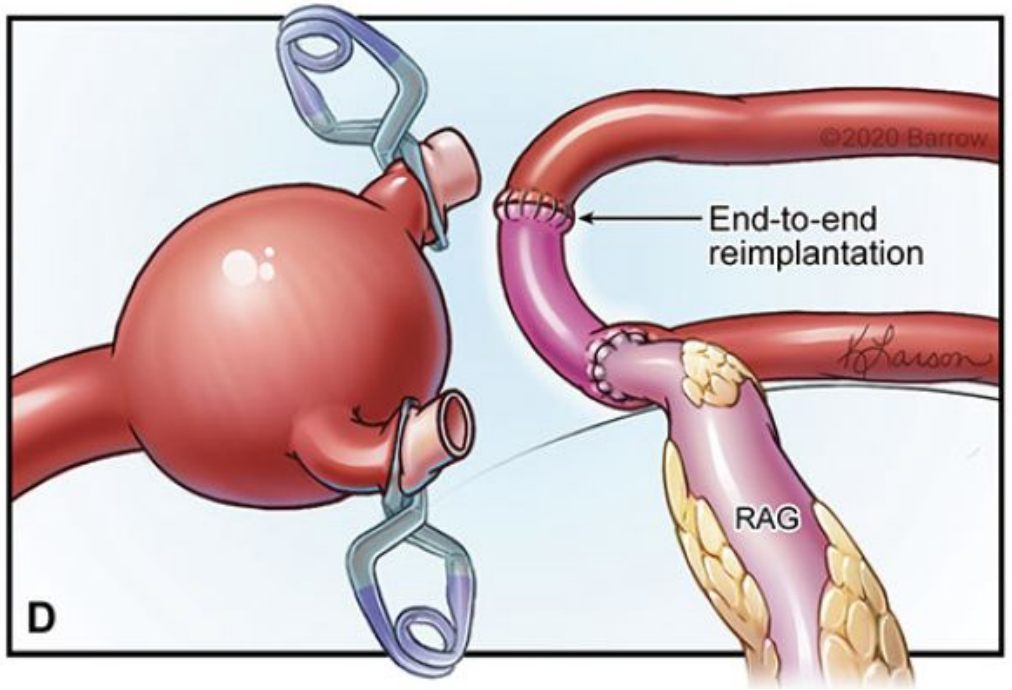


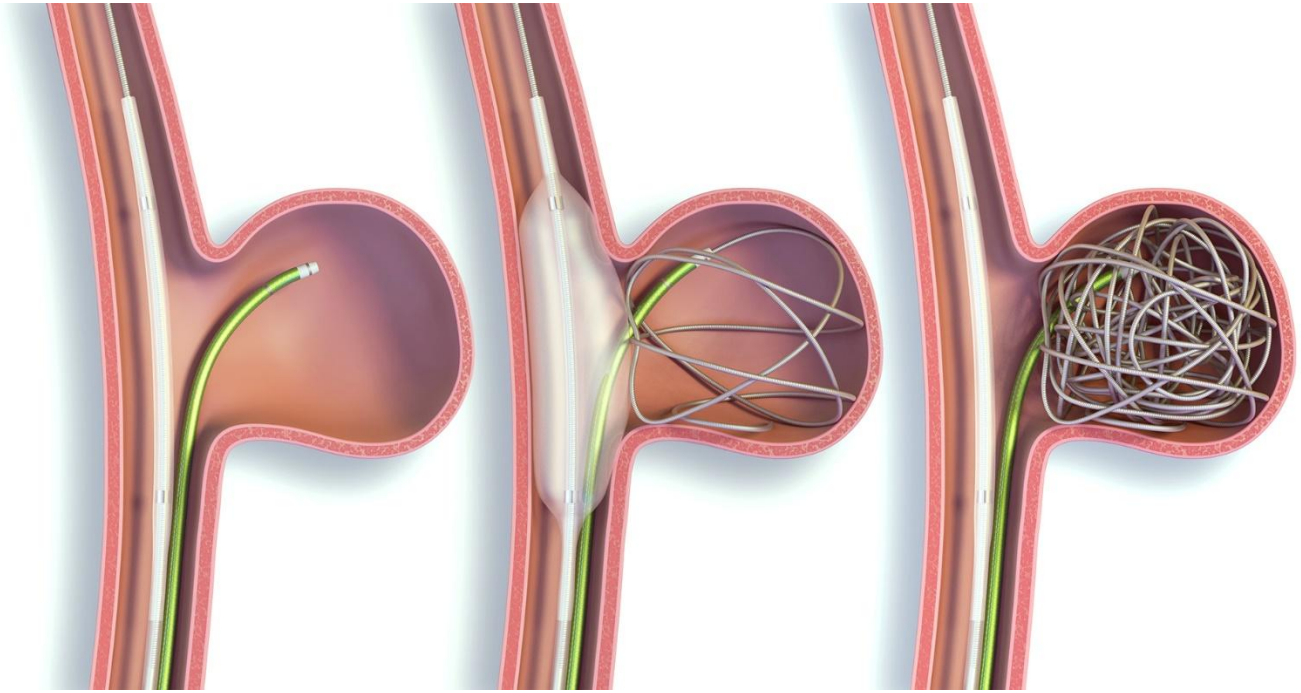

# Сосудистая нейрохирургия

# Нейроонкология

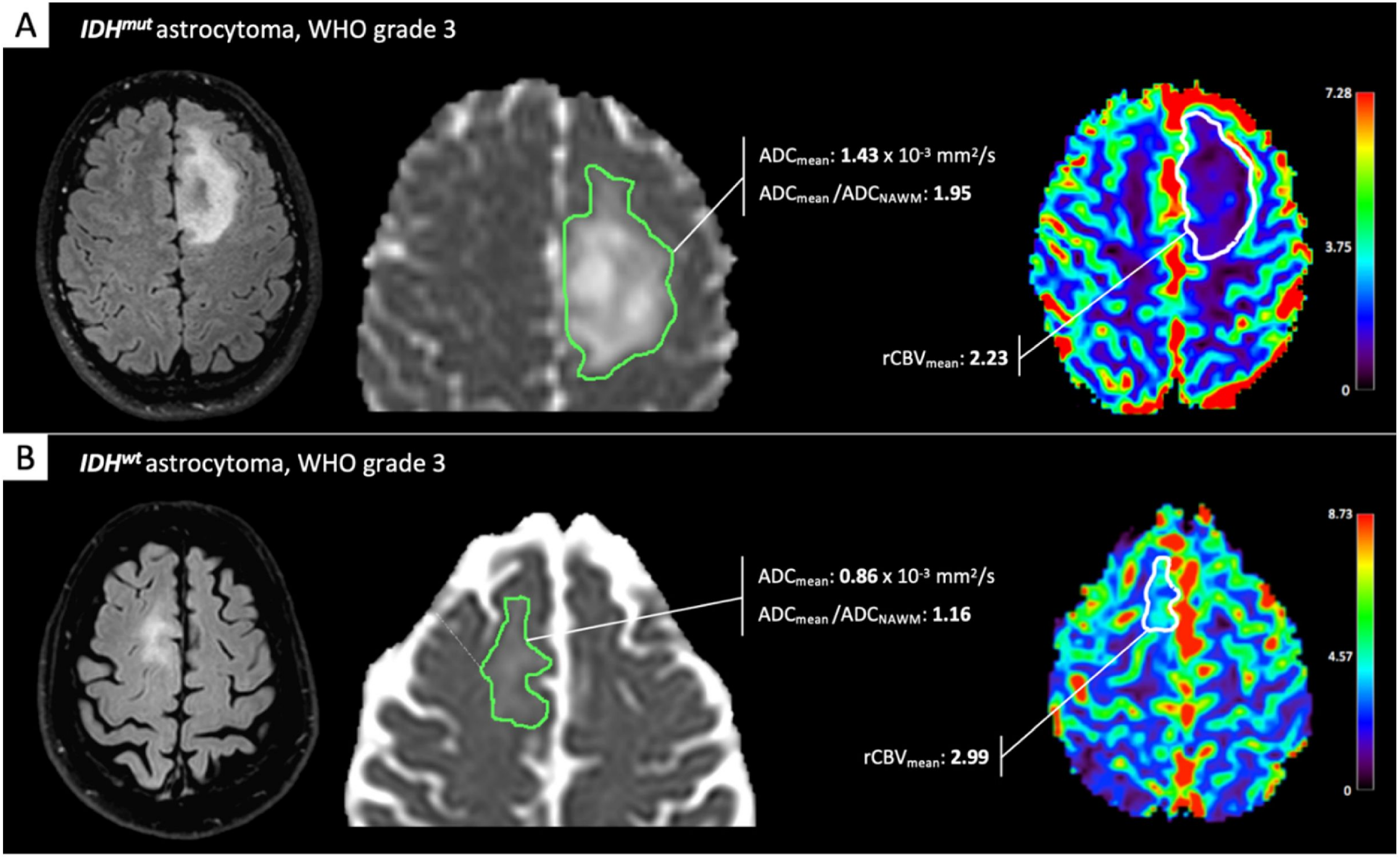
A
IDHmut astrocytoma, WHO grade 3
ADCmean: 1.43 x 10-3 mm2/s
ADCmean /ADCNAWM: 1.95
rCBVmean: 2.23
7.28
3.75
0
B
IDHwt astrocytoma, WHO grade 3
ADCmean: 0.86 x 10-3 mm2/s
ADCmean /ADCNAWM: 1.16
rCBVmean: 2.99
8.73
4.57
0

Нейроэндокринология

Функциональная нейрохирургия

Детская нейрохирургия

Хирургия периферических нервов

# немного о хирургии периферических нервов

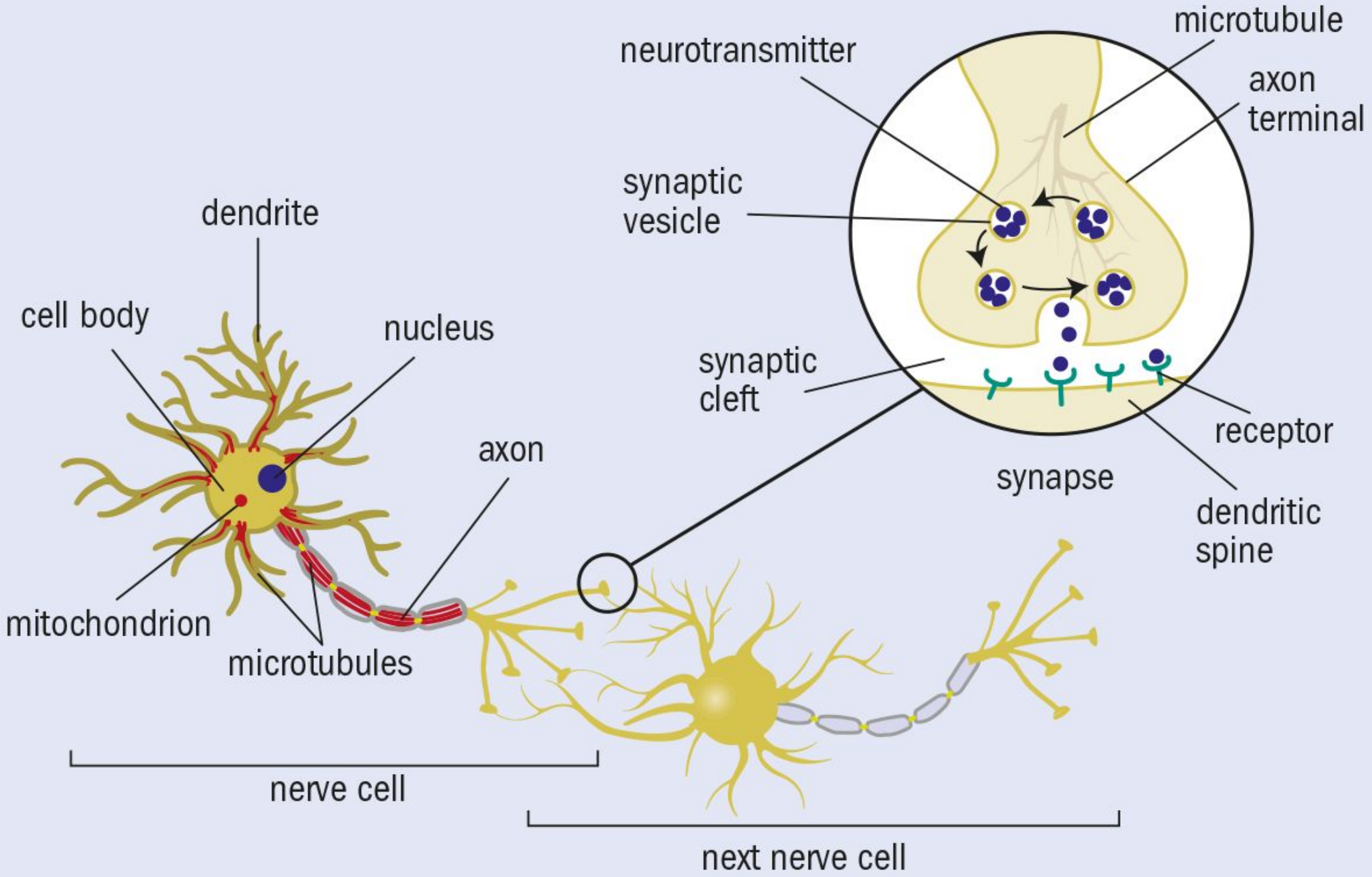
microtubule
neurotransmitter
axon
terminal
synaptic
vesicle
dendrite
cell body
nucleus
synaptic
cleft
receptor
axon
synapse
dendritic
spine
mitochondrion
microtubules
nerve cell
next nerve cell

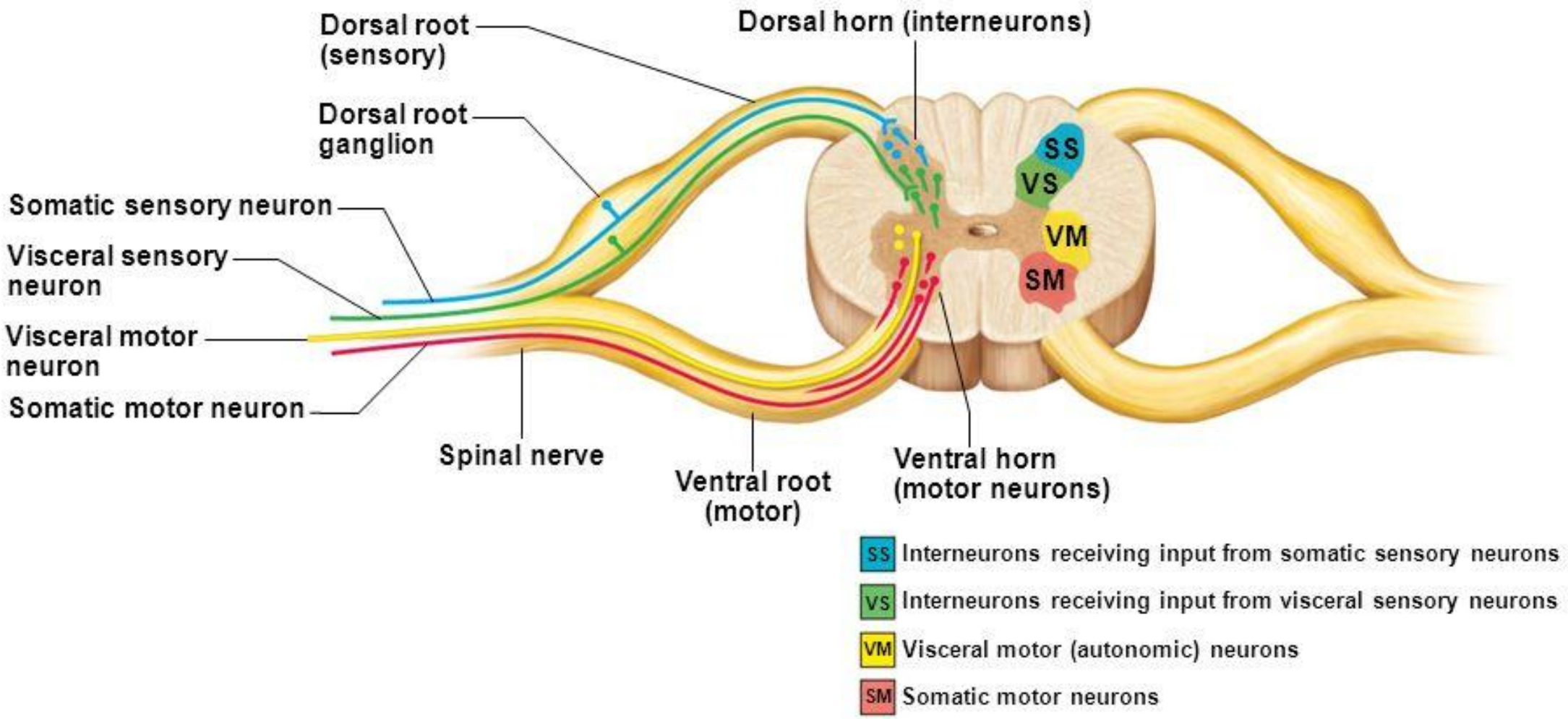
Dorsal root (sensory)
Dorsal horn (interneurons)
Dorsal root ganglion
Somatic sensory neuron
Visceral sensory neuron
Visceral motor neuron
Somatic motor neuron
Spinal nerve
Ventral root (motor)
Ventral horn (motor neurons)
SS
VS
VM
SM
SS Interneurons receiving input from somatic sensory neurons
VS Interneurons receiving input from visceral sensory neurons
VM Visceral motor (autonomic) neurons
SM Somatic motor neurons

# Anatomy of sympathetic chain

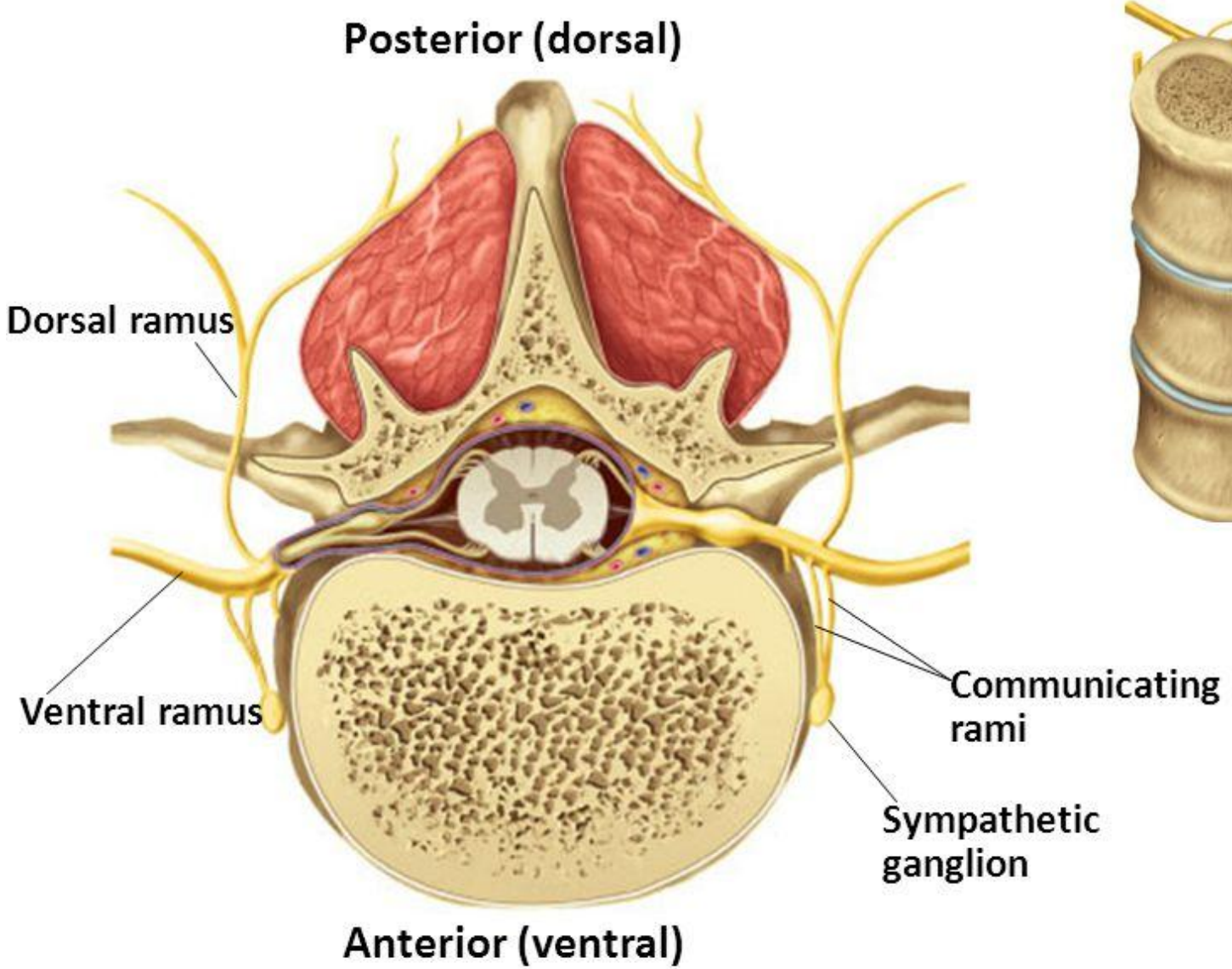


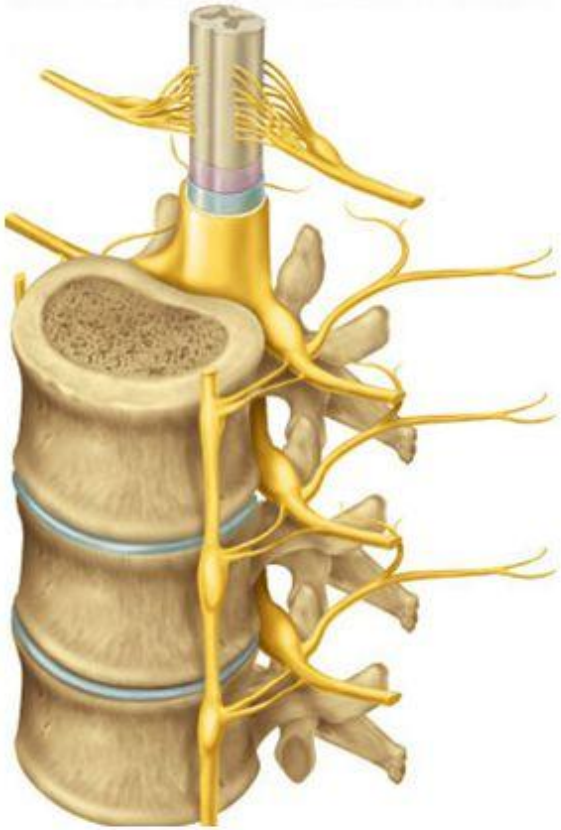

WARNSON

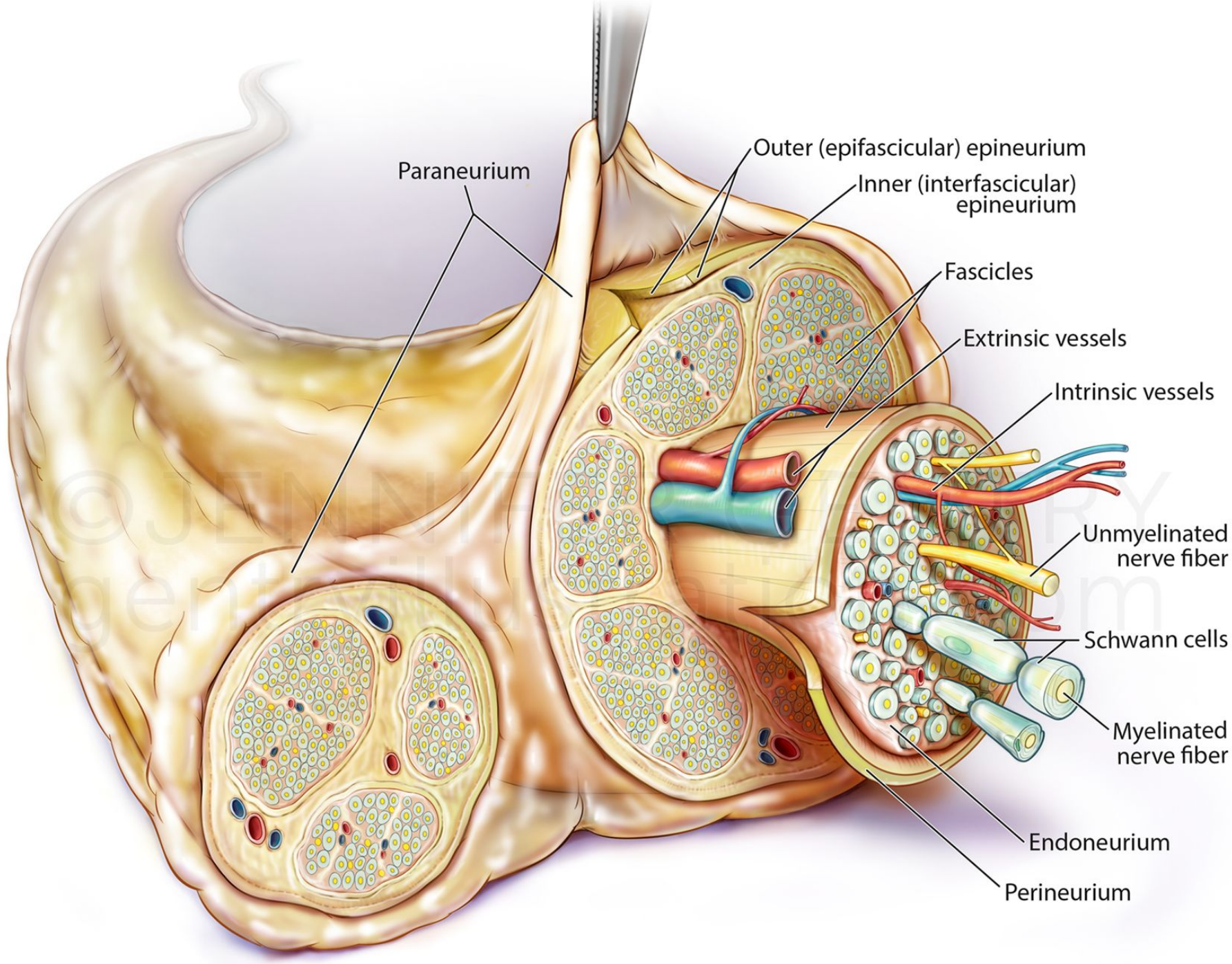
Paraneurium
Outer (epifascicular) epineurium
Inner (interfascicular) epineurium
Fascicles
Extrinsic vessels
Intrinsic vessels
Unmyelinated nerve fiber
Schwann cells
Myelinated nerve fiber
Endoneurium
Perineurium

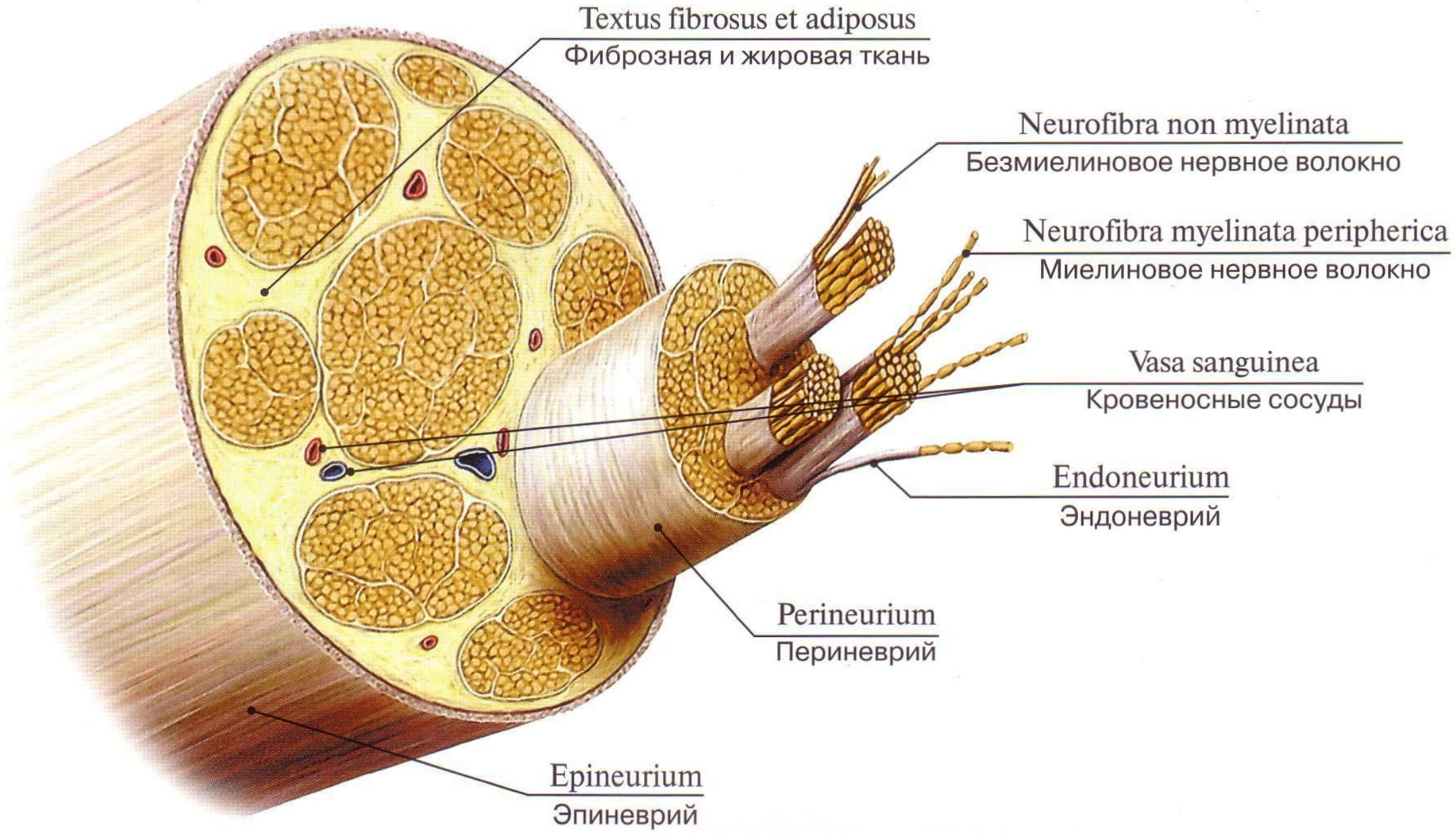
Textus fibrosus et adiposus
Фиброзная и жировая ткань
Neurofibra non myelinata
Безмиелиновое нервное волокно
Neurofibra myelinata peripherica
Миелиновое нервное волокно
Vasa sanguinea
Кровеносные сосуды
Endoneurium
Эндоневрий
Perineurium
Периневрий
Epineurium
Эпиневрий

# Normal Nerve

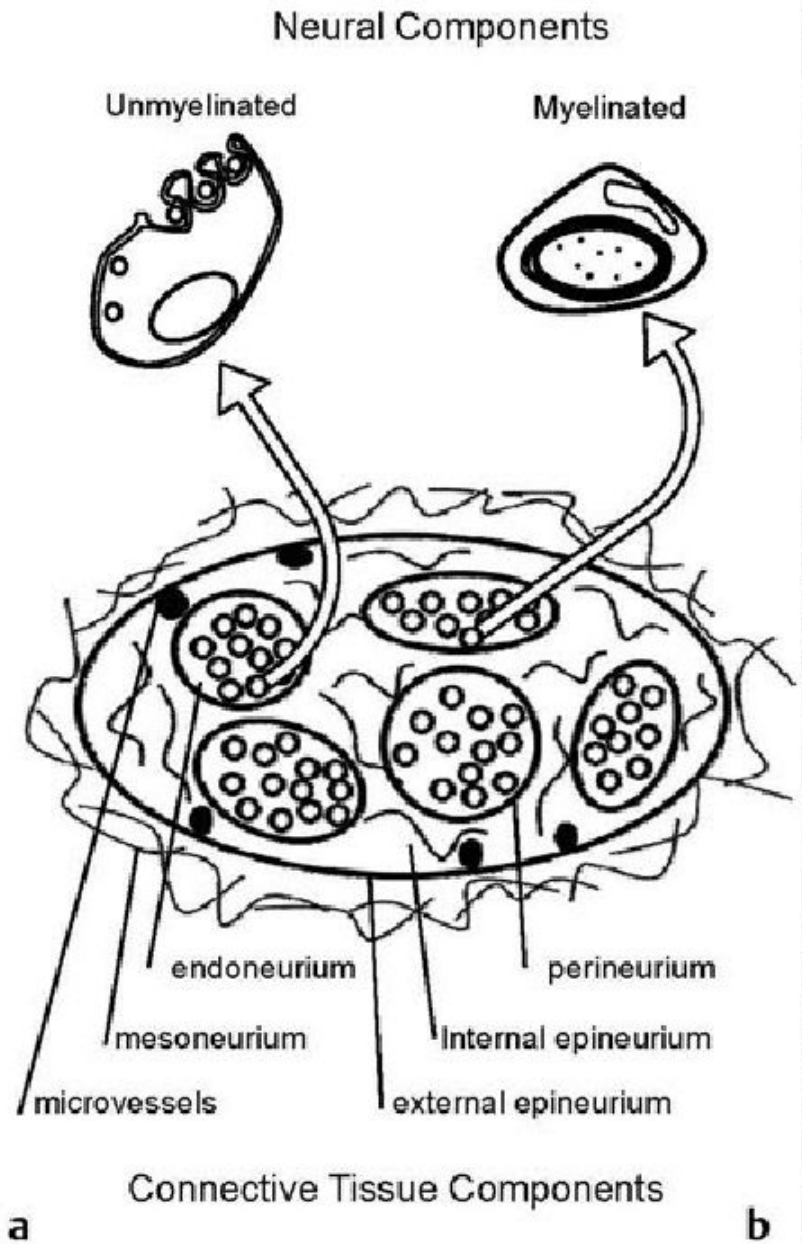


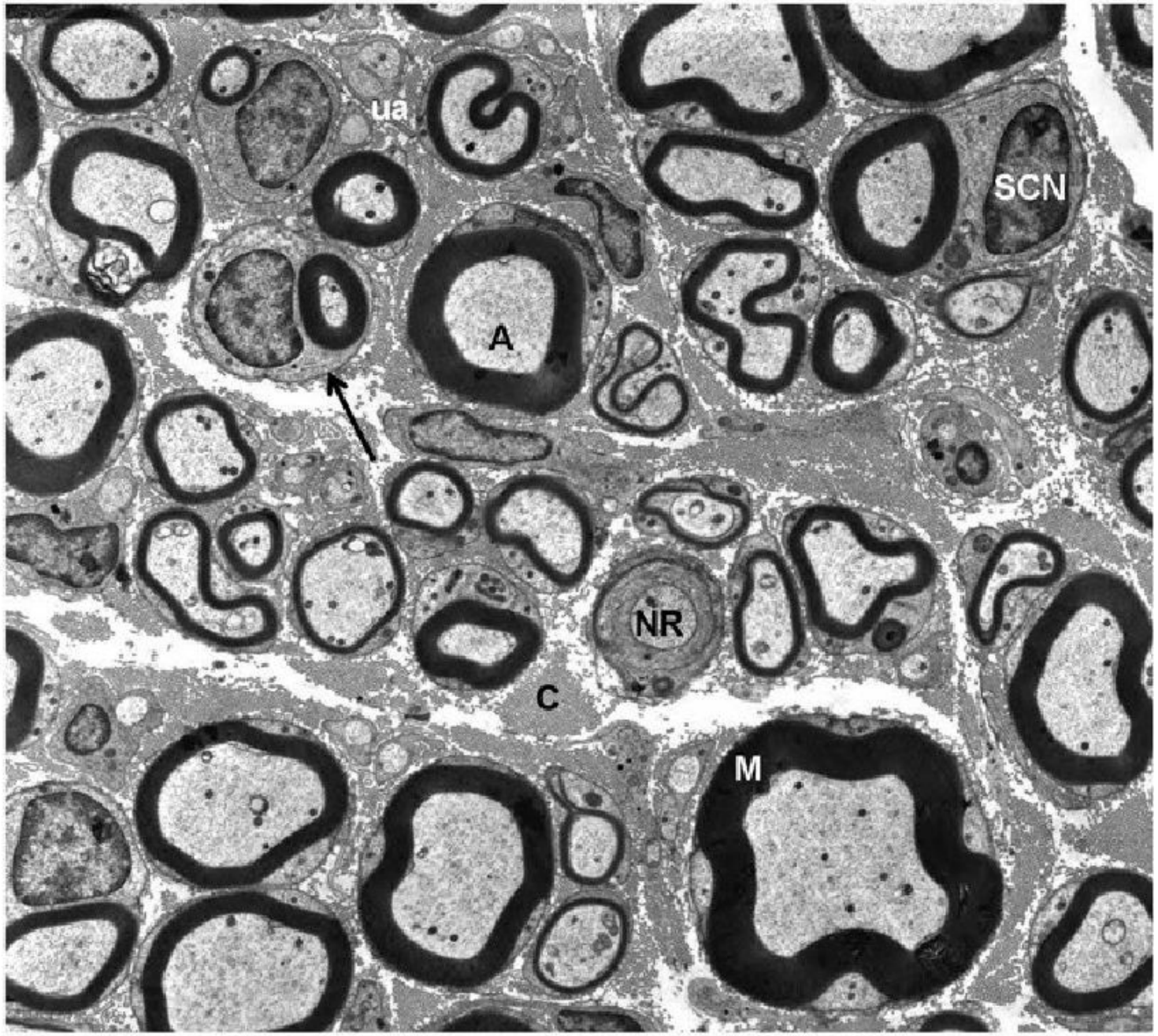

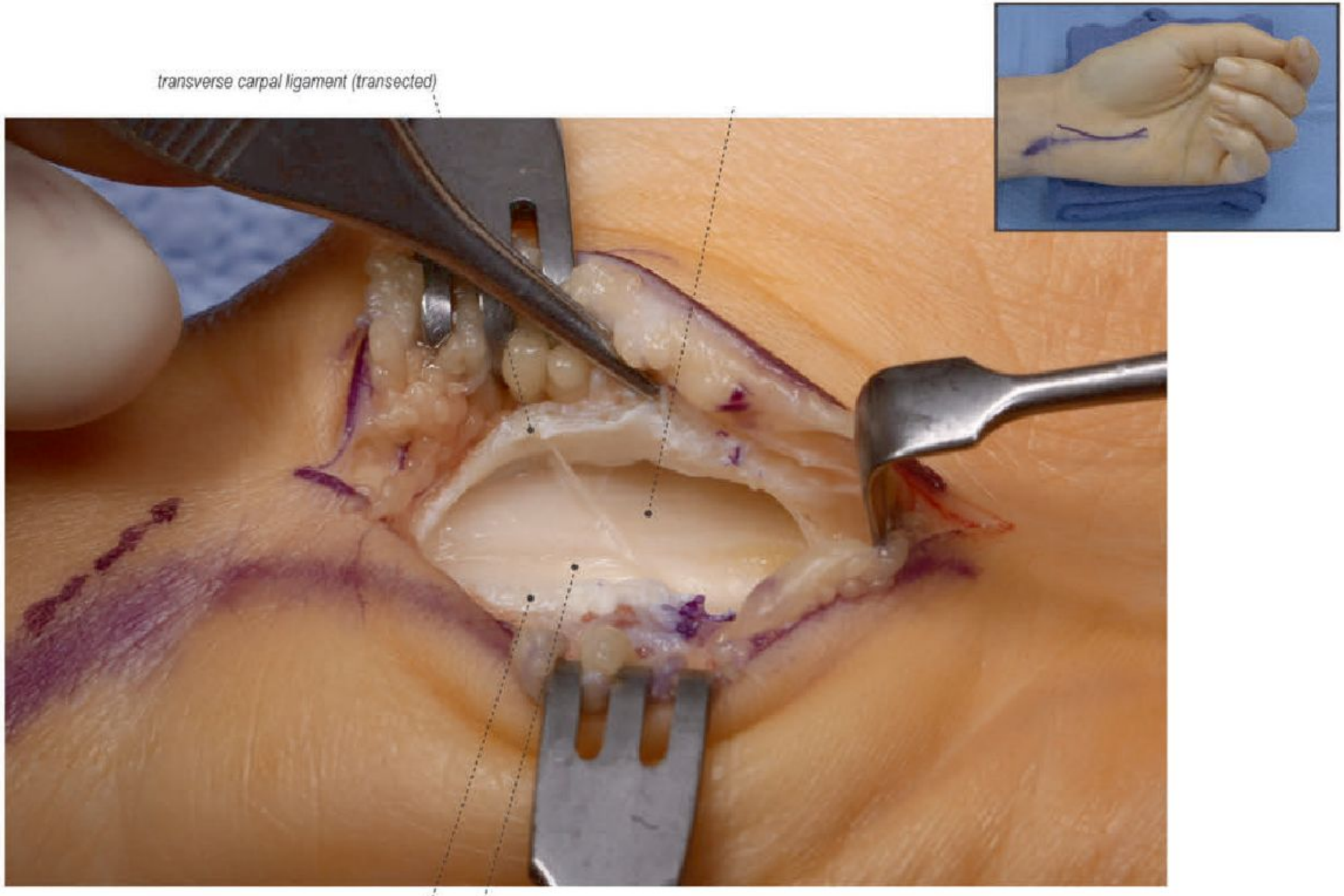
transverse carpal ligament (transected)
transverse carpal ligament (transected)
(M) tendons of flexor digitorum superficialis

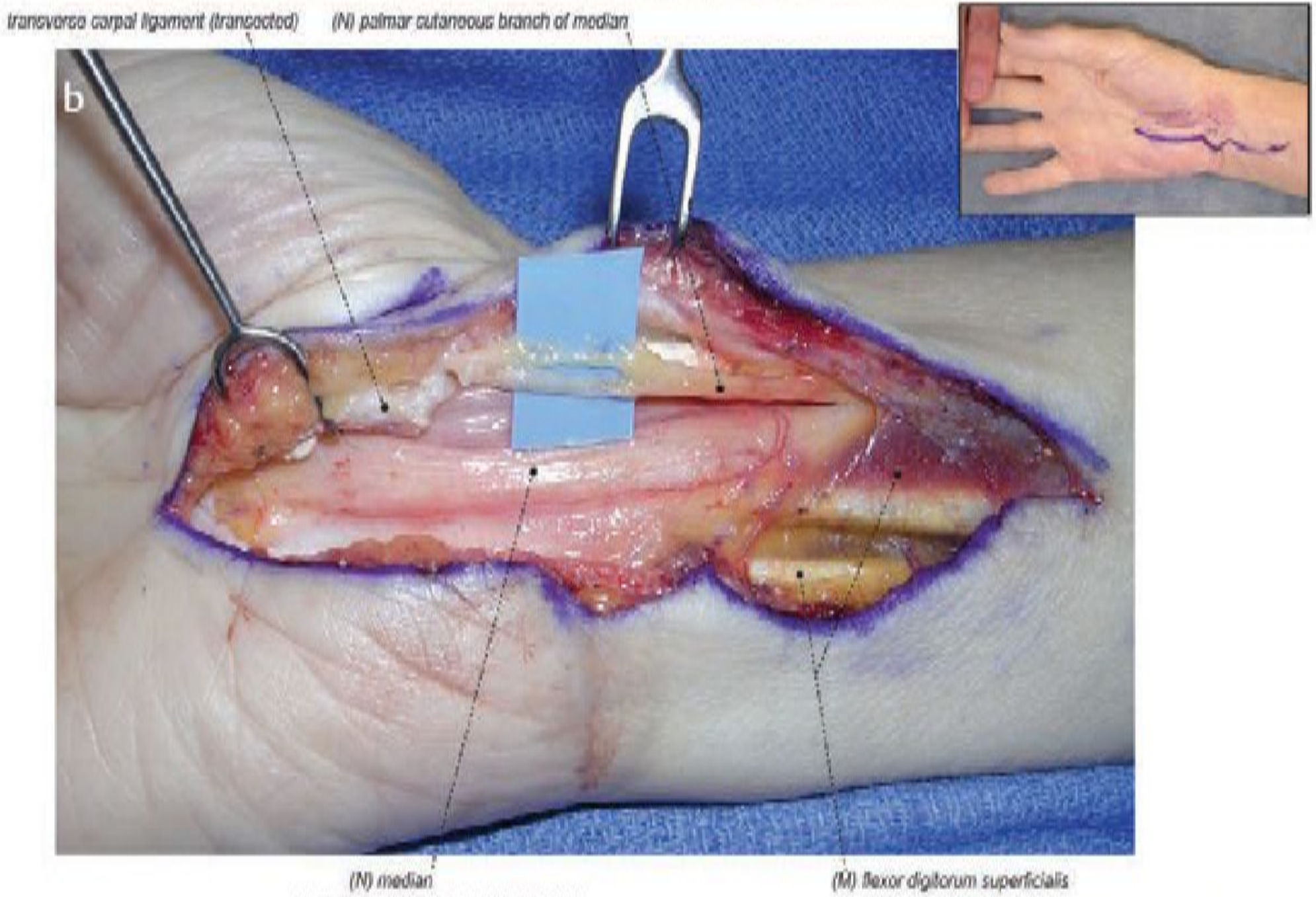
transverse carpal ligament (transected)
(N) palmar cutaneous branch of median
b
(N) median
(M) flexor digitorum superficialis

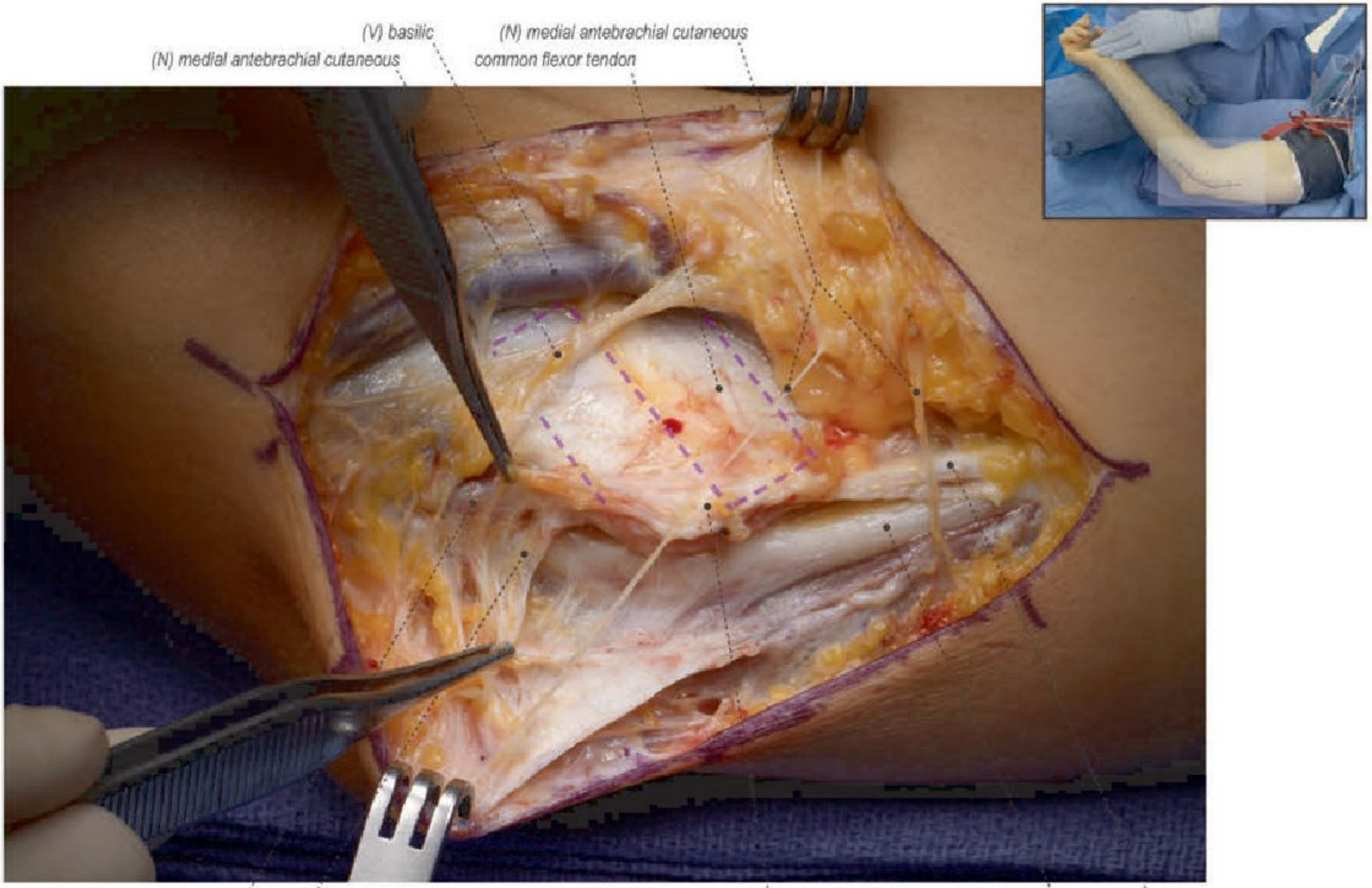
(V) basilic
(N) medial antebrachial cutaneous
(N) medial antebrachial cutaneous
common flexor tendon
(M) flexor carpi ulnaris
Osborne's ligament
(tendinous leading-edge of flexor carpi ulnaris)
(B) medial epicondyle of humerus
medial intermuscular septum

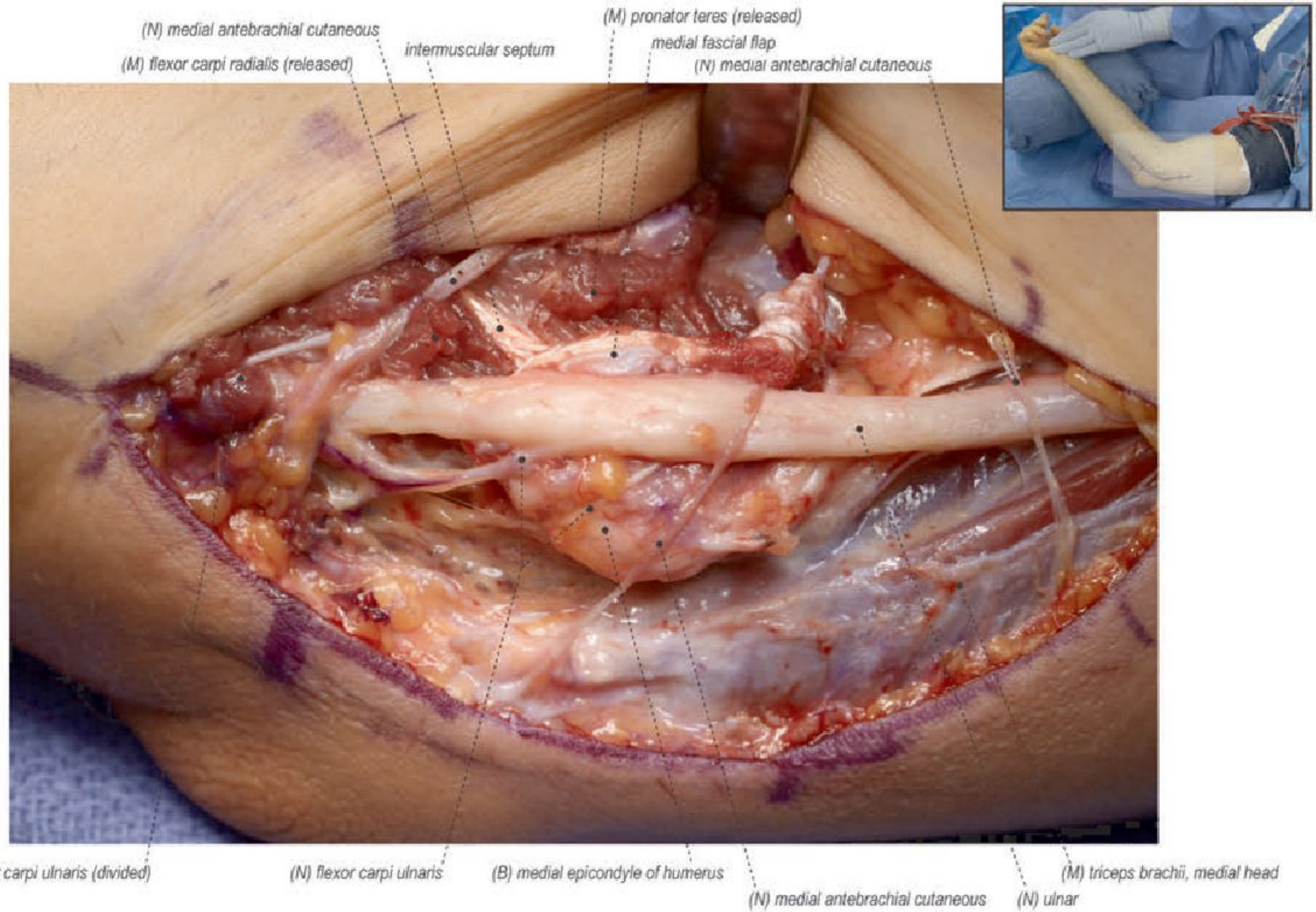
(N) medial antebrachial cutaneous
(M) flexor carpi radialis (released)
intermuscular septum
(M) pronator teres (released)
medial fascial flap
(N) medial antebrachial cutaneous
(M) flexor carpi ulnaris (divided)
(N) flexor carpi ulnaris
(B) medial epicondyle of humerus
(N) medial antebrachial cutaneous
(N) ulnar
(M) triceps brachii, medial head

Под **туннельным синдромом** принято обозначать комплекс клинических проявлений (чувствительных, двигательных и трофических) обусловленных сдавлением, ущемлением нерва в узких анатомических пространствах (анатомический туннель). Стенки анатомического туннеля являются естественными анатомическими структурами (кости, сухожилия, мышцы), и в норме через туннель свободно проходят периферические нервы и сосуды. Но при определенных патологических условиях канал сужается, возникает нервно–канальный конфликт.

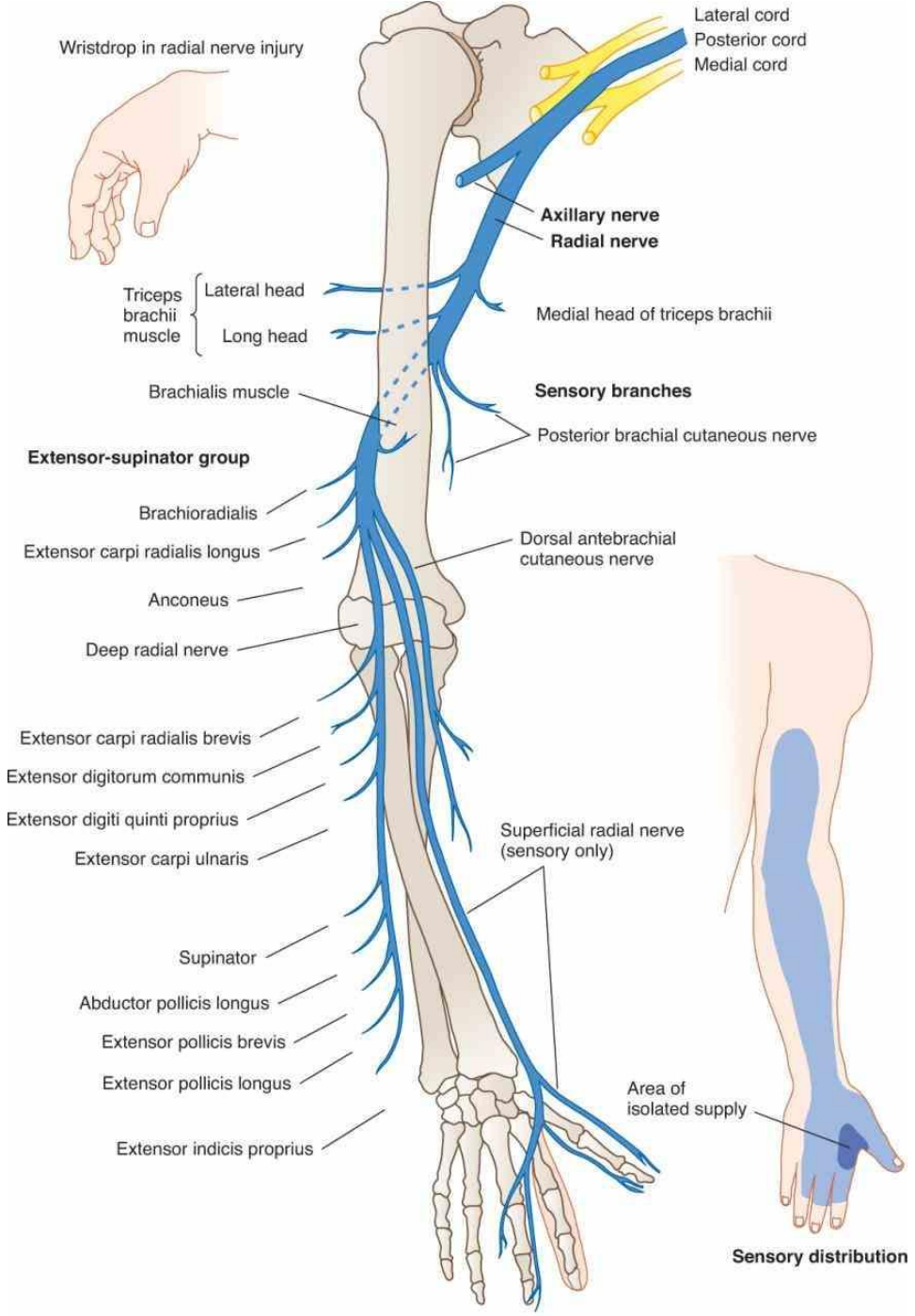


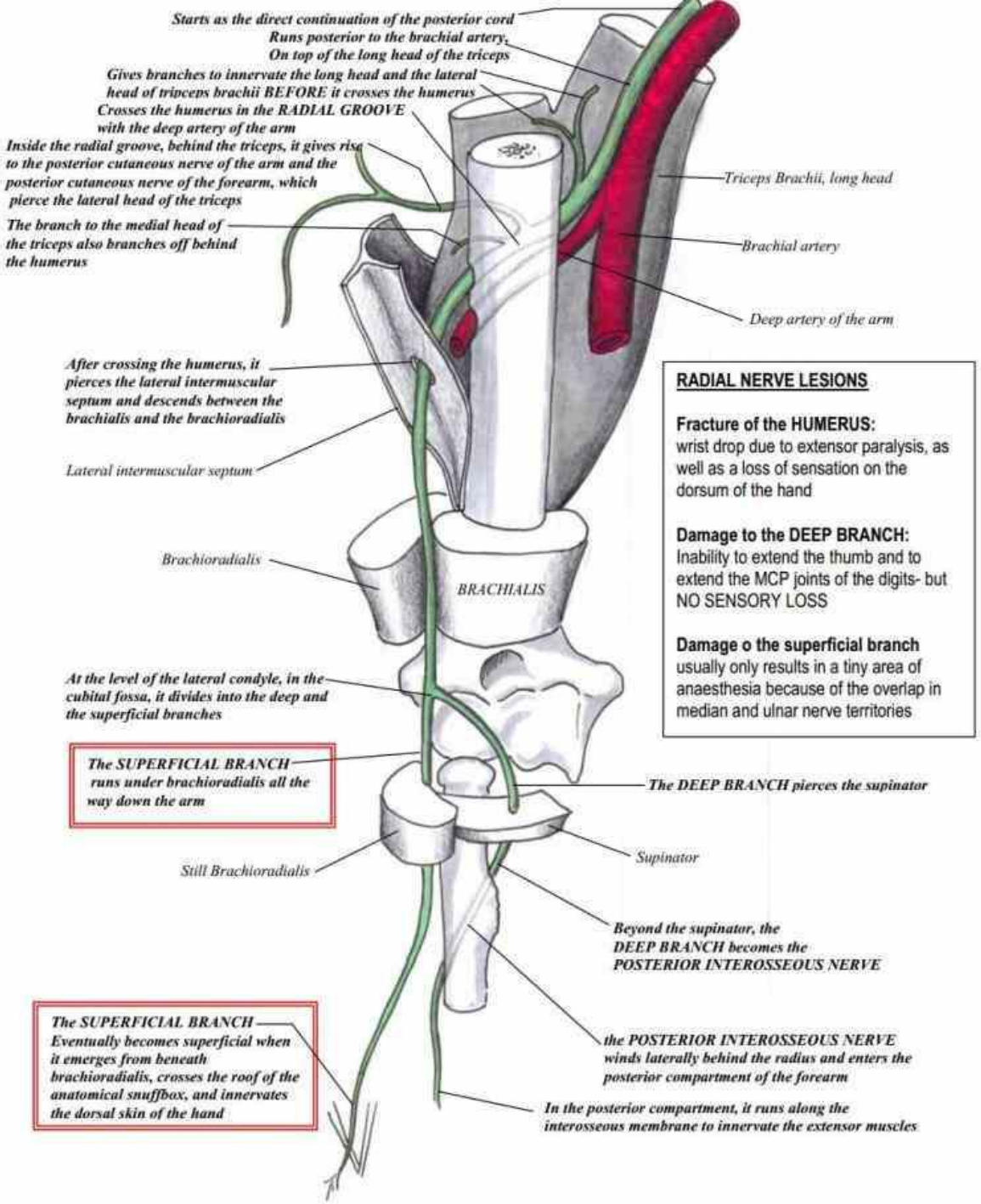


**RADIAL NERVE LESIONS**

**Fracture of the HUMERUS:**
wrist drop due to extensor paralysis, as well as a loss of sensation on the dorsum of the hand

**Damage to the DEEP BRANCH:**
Inability to extend the thumb and to extend the MCP joints of the digits- but NO SENSORY LOSS

**Damage o the superficial branch**
usually only results in a tiny area of anaesthesia because of the overlap in median and ulnar nerve territories

Source: Waxman SG: Clinical Neuroanatomy: Twenty-Seventh Edition: www.accessmedicine.com
Copyright © The McGraw-Hill Companies, Inc. All rights reserved.

# Ulnar Nerve Injury

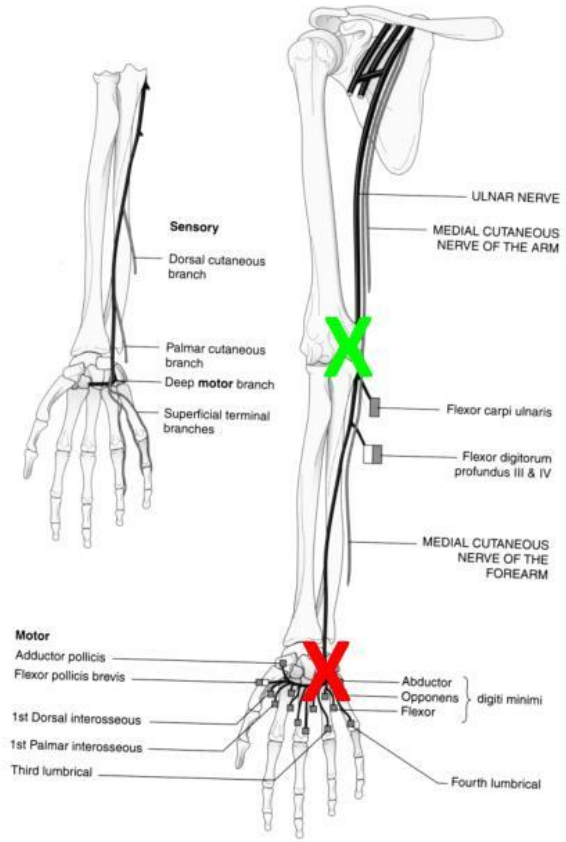


R G Tunstall 2014

**Damage at the elbow or proximal**

No flexion of distal IP joint of Digits 4 & 5 = Lack of FDP

Wrist abducts on flexion = Lack of FCU

No digit ab-or adduction (except thumb abduction)

Some clawing of digits 4 & 5 at rest = loss of lumbricals & interossei

No clawing of digits 2 & 3 as lumbricals 1 & 2 OK

**Damage at the wrist**

Loss of most intrinsic hand muscles

Hypothenar & interosseous wasting

Clawing of digits 4 & 5 worse in low lesion as FDP remains innervated and exacerbates IP joint flexion

Warwick Medical School

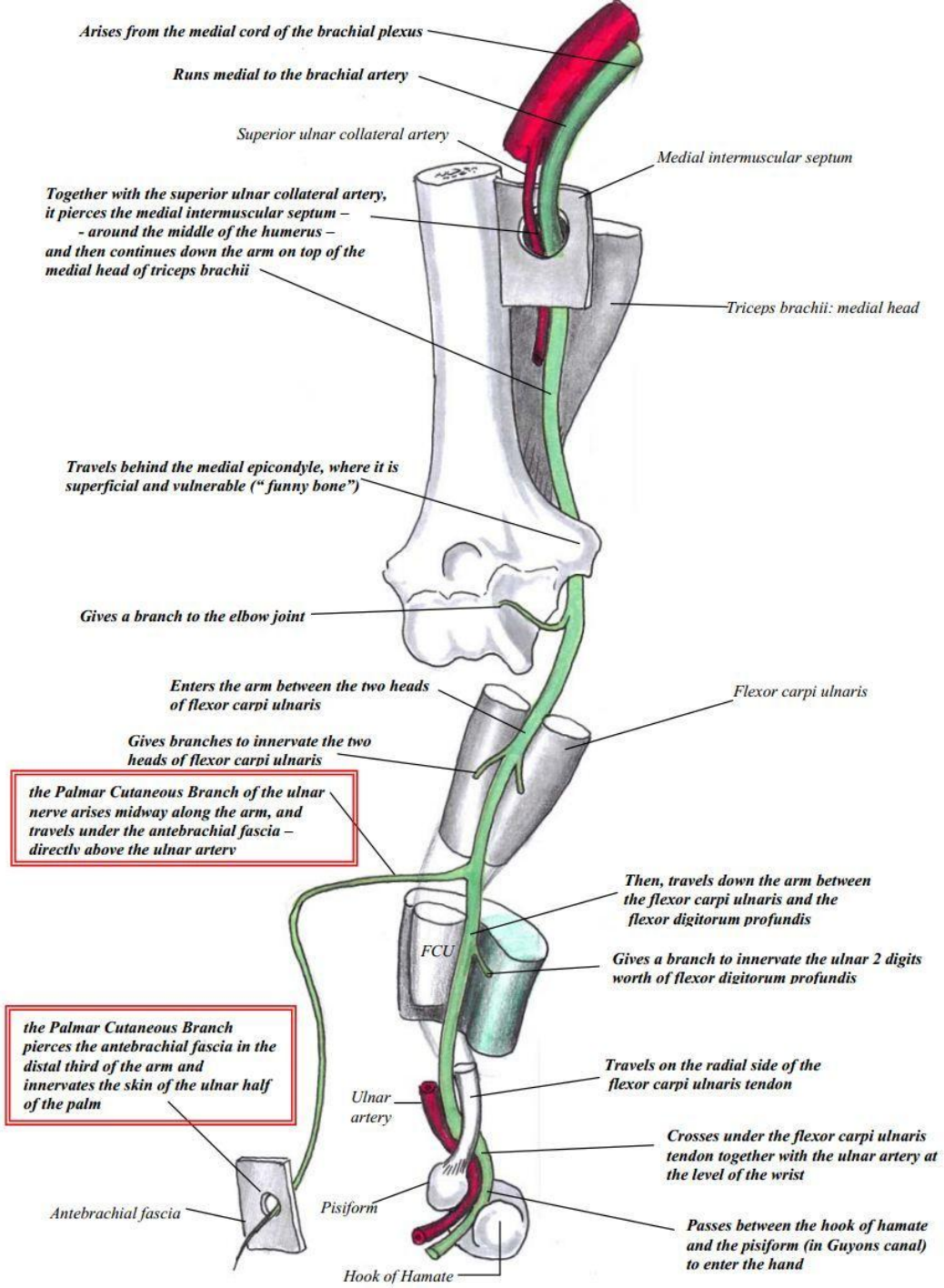

# MEDIAN NERVE

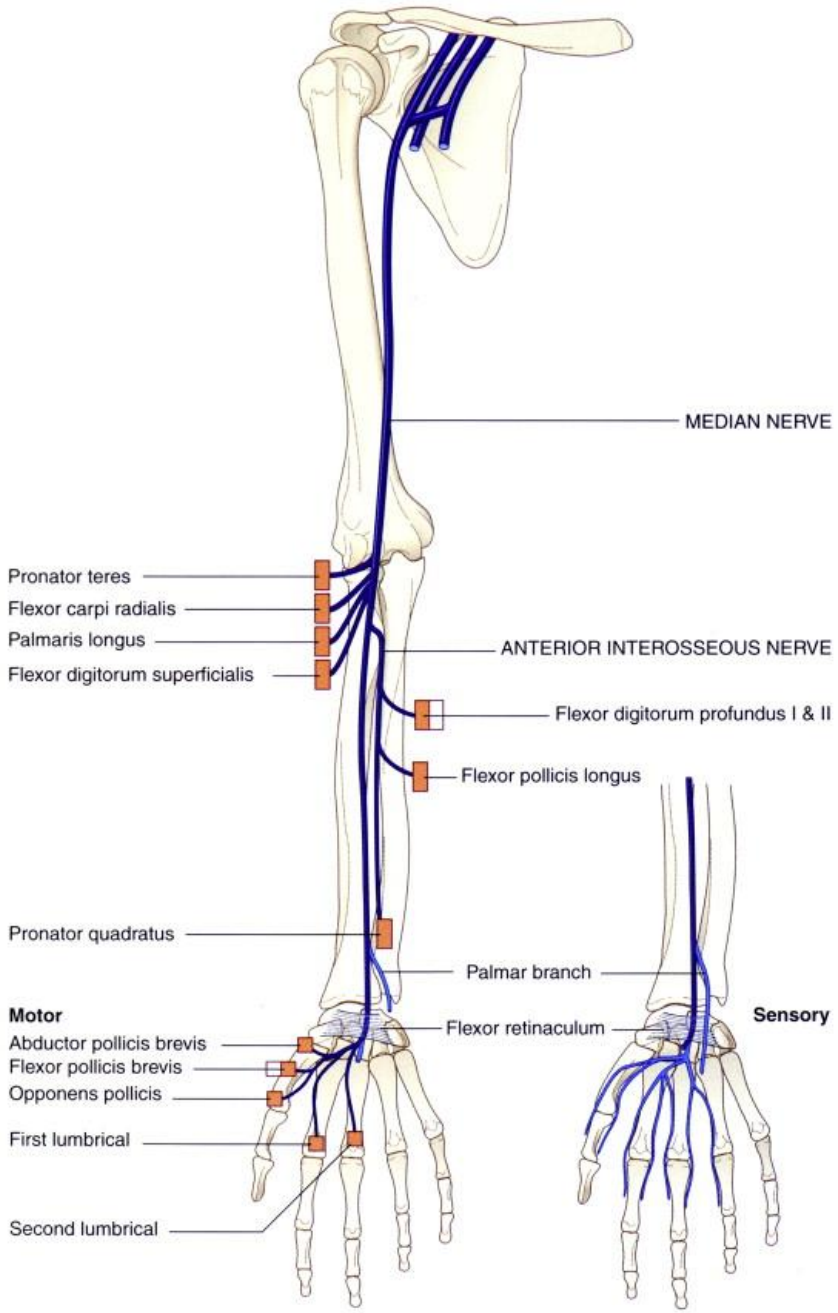


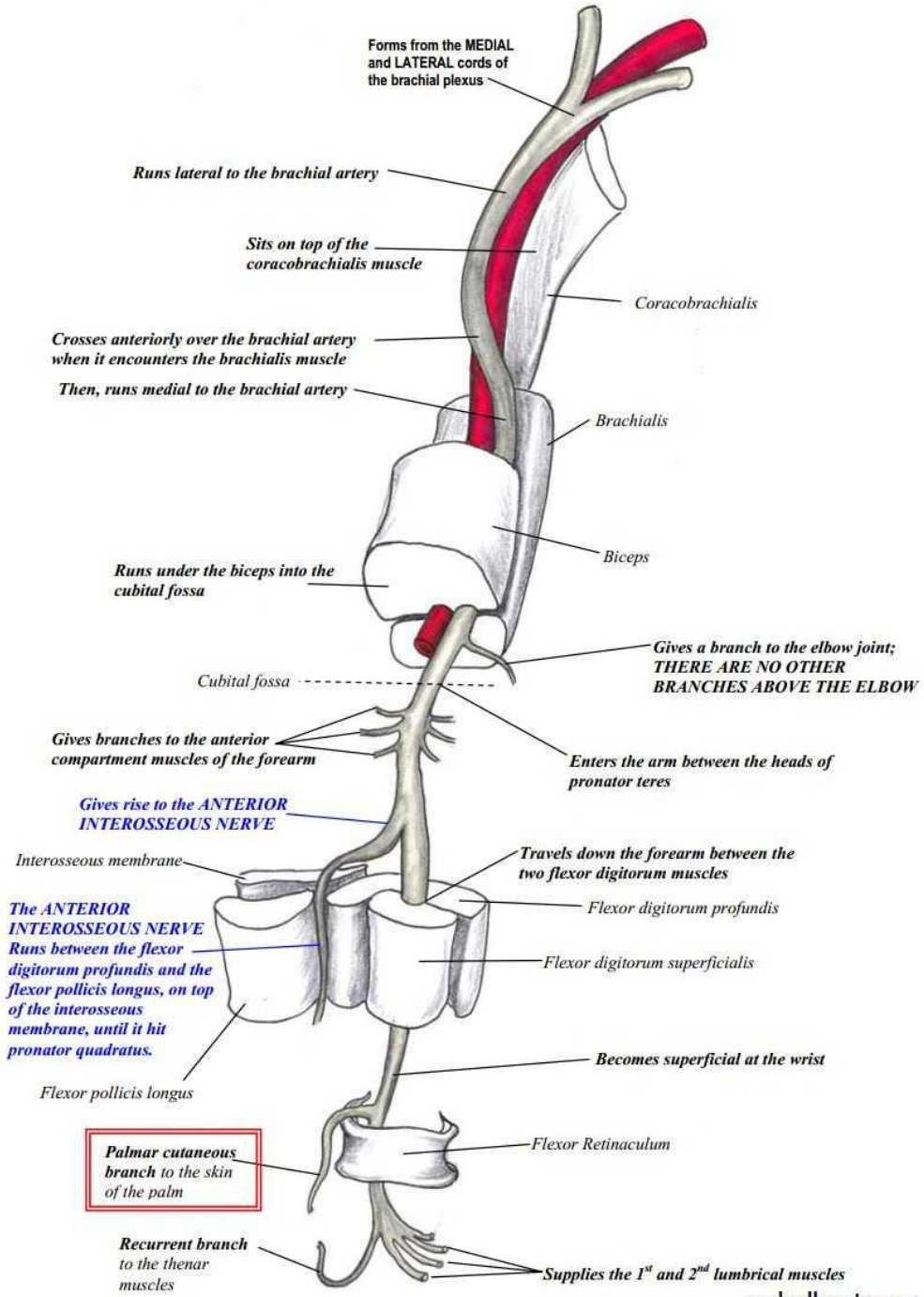


muhadharaty.com

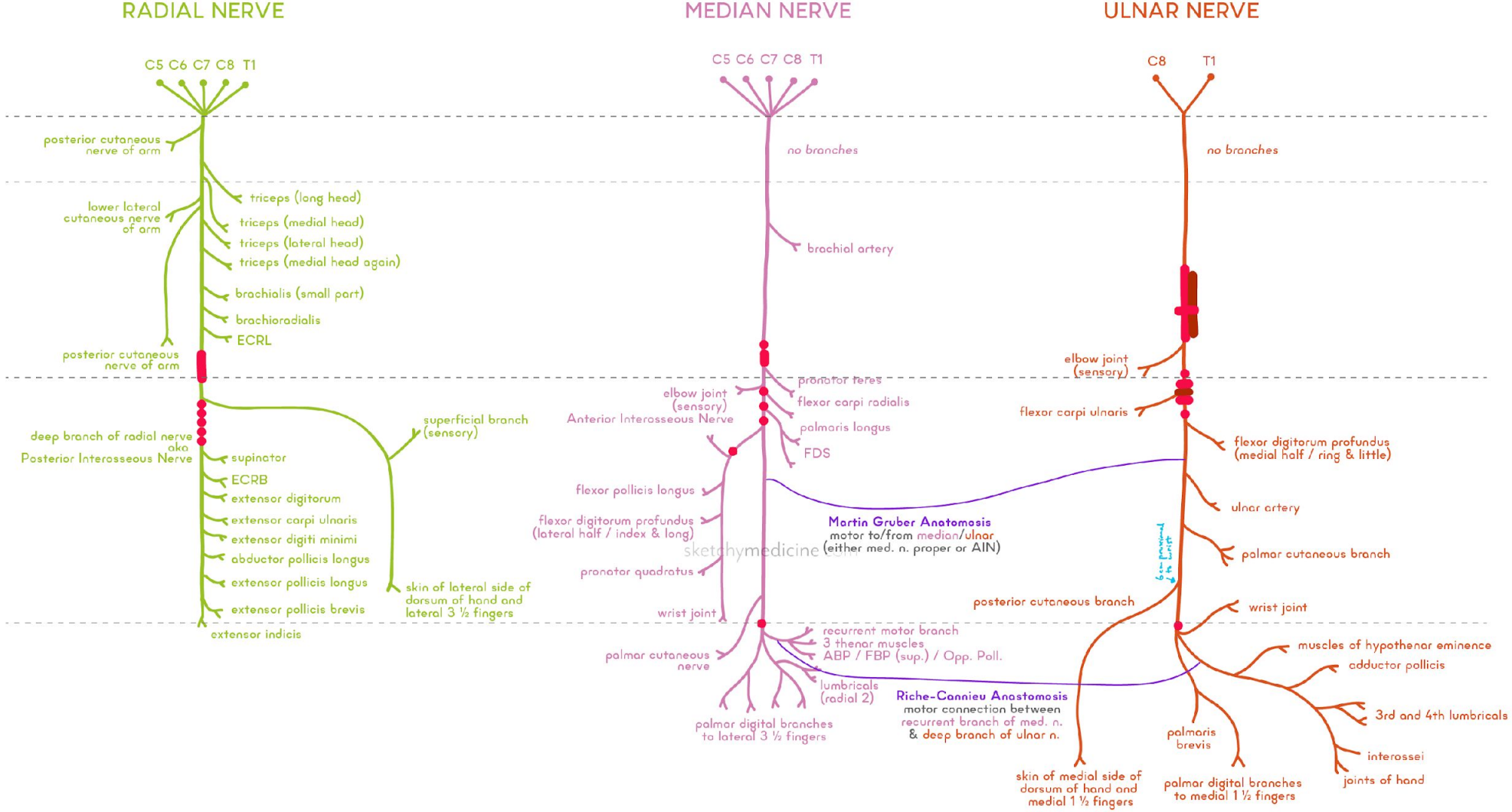


**Points of Compression *(proximal to distal)***

**Proximal**

1. Spiral groove / fibrous arch from lateral head of triceps

**Radial Tunnel Syndrome aka Early PIN Syndrome**

2. Fibrous bands of radiocapitellar joint (attached to and superficial to the joint)
3. Leash of Henry (radial recurrent artery and venae comitantes)
4. Tendinous margin of ECRB
5. Arcade of Frohse (most common) aka proximal fibrous edge of supinator muscle
6. Fascial border at distal edge of supinator

**Points of Compression *(proximal to distal)***

**Pronator Syndrome**

1. Supracondylar process of humerus (only present in 1% of population)
2. Ligament of Struthers (supracondylar process to medial epicondyle)
3. Bicipital aponeurosis aka lacertus fibrosis (biceps tendon to the fascia of the flexors)
4. Between ulnar and humeral heads of pronator teres
5. FDS aponeurotic arch (6.5 cm distal to elbow)

**AIN Syndrome - pronator syndrome points *plus*:**

6. Accessory head of FPL aka Gantzer's muscle

*AIN is often affected in Parsonage Turner Syndrome*

**Carpal Tunnel Syndrome**

7. Carpal tunnel +/- local tumors, persistent median artery, low-lying muscle bellies (FDS most common), accessory muscles (manus) or lumbricals, lysosomal storage diseases

**Points of Compression *(proximal to distal)***

**Cubital Tunnel Syndrome**

1. Medial intermuscular septum
2. Medial head of triceps
3. Arcade of Struthers aka aponeurosis from medial head of triceps to medial intermuscular septum (not to be confused with ligament of Struthers)
4. Medial epicondyle (wall of tunnel with olecranon laterally)
5. Osborne's ligament (roof of cubital tunnel)
6. Anconeus epitrochlearis (accessory muscle)
7. Aponeurosis of FCU (between two heads, part of roof of tunnel)
8. Ligament of Spinner (between FCU and FDS D4)
9. Elbow joint pathology

**Guyon's Canal**

10. Zone I - proximal to bifurcation of motor and sensory
11. Zone II - after division, along deep motor branch (motor only)
12. Zone III - after division, along superficial sensory branch (sensory only)

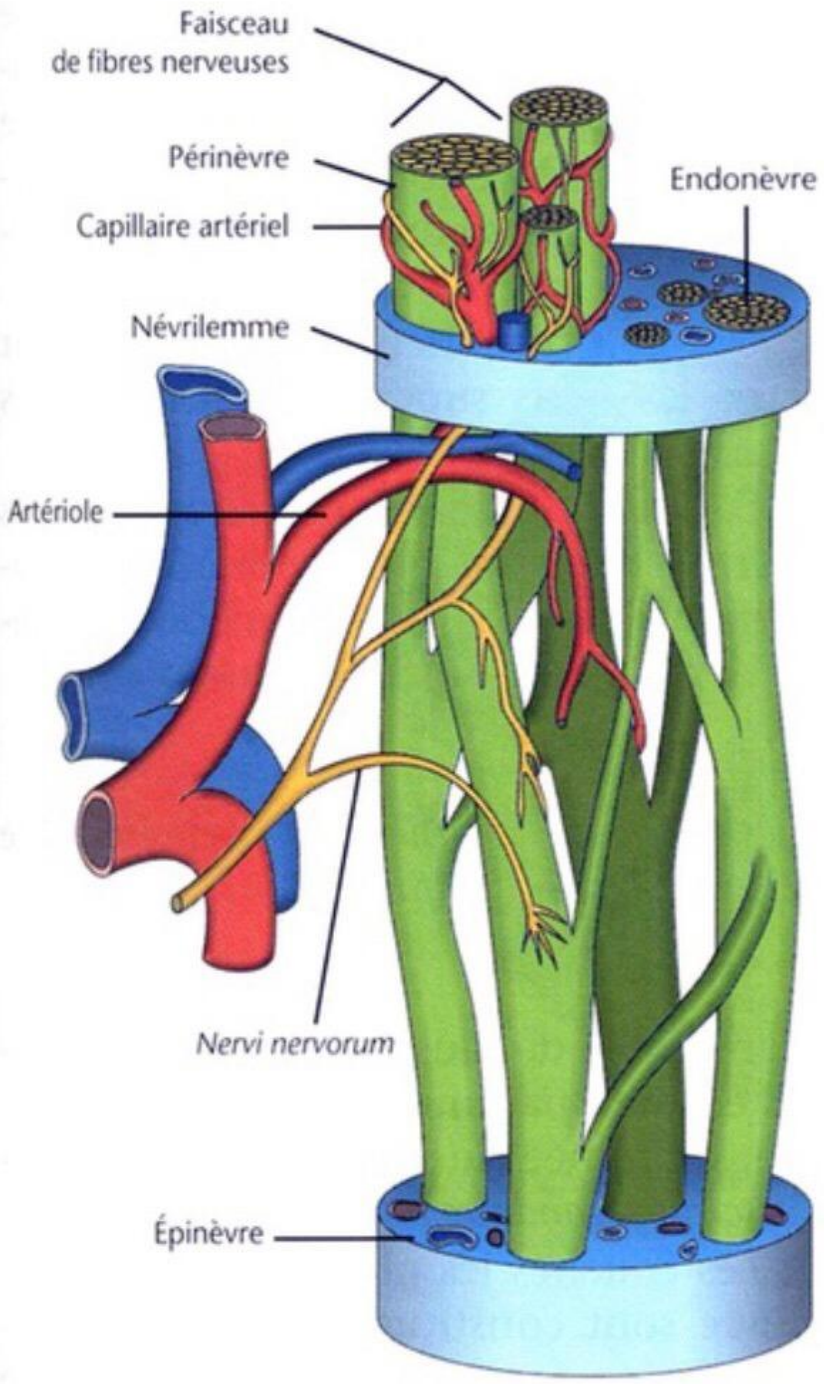
Faisceau
de fibres nerveuses
Périnèvre
Capillaire artériel
Endonèvre
Névrilemme
Artériole
Nervi nervorum
Épinèvre

# MEDIAN NERVE - Forearm and Hand

Revision Date: 120803

KEY:
FDS - flexor digitorum superficialis
FDP - flexor digitorum profundus
FPL - flexor pollicis longus
FCR - flexor carpi radialis
PL - palmaris longus
PQ - pronator quadratus

- Motor
- Sensory
- Thenar fasicicle
- Articular fasicicle

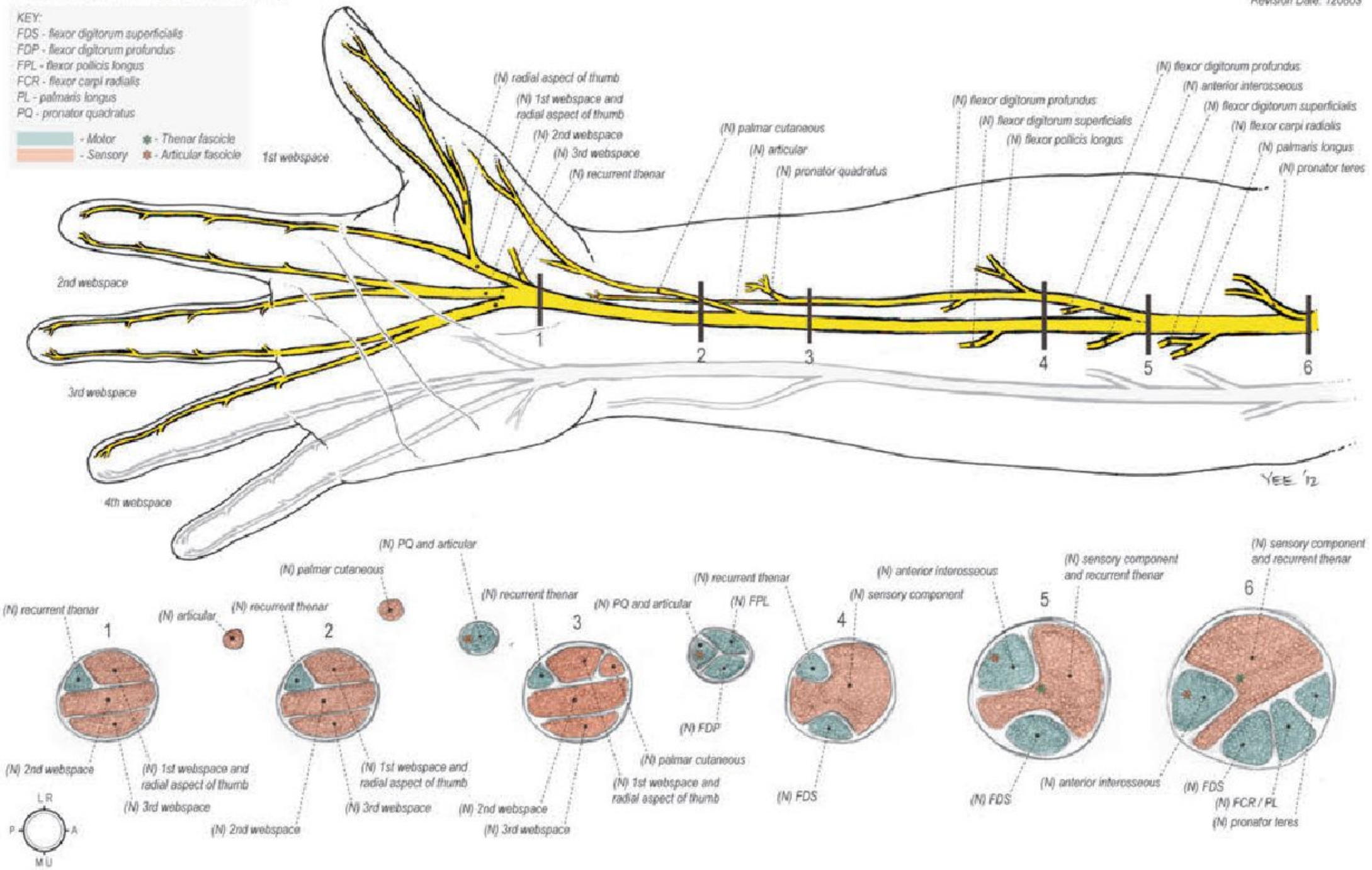

# MEDIAN NERVE - Arm and Forearm

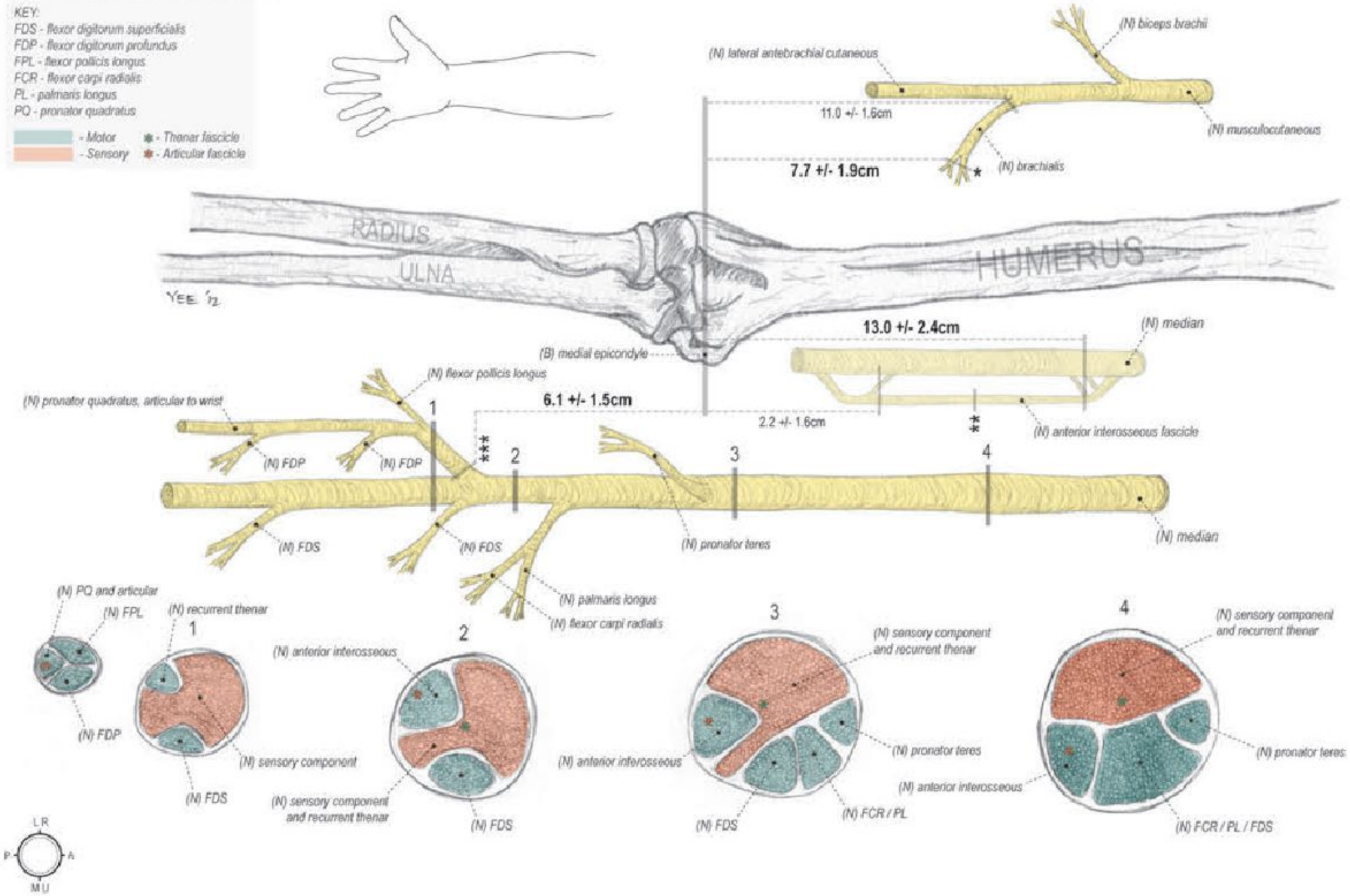

# Martin-Gruber Anastomosis

KEY:
AIN - anterior interosseous nerve
FDS - flexor digitorum superficialis
FDP - flexor digitorum profundus
FPL - flexor pollicis longus
FCR - flexor carpi radialis
FCU - flexor carpi ulnaris
PL - palmaris longus
MGA - Martin-Gruber anastomosis

- MGA #1
- MGA #3

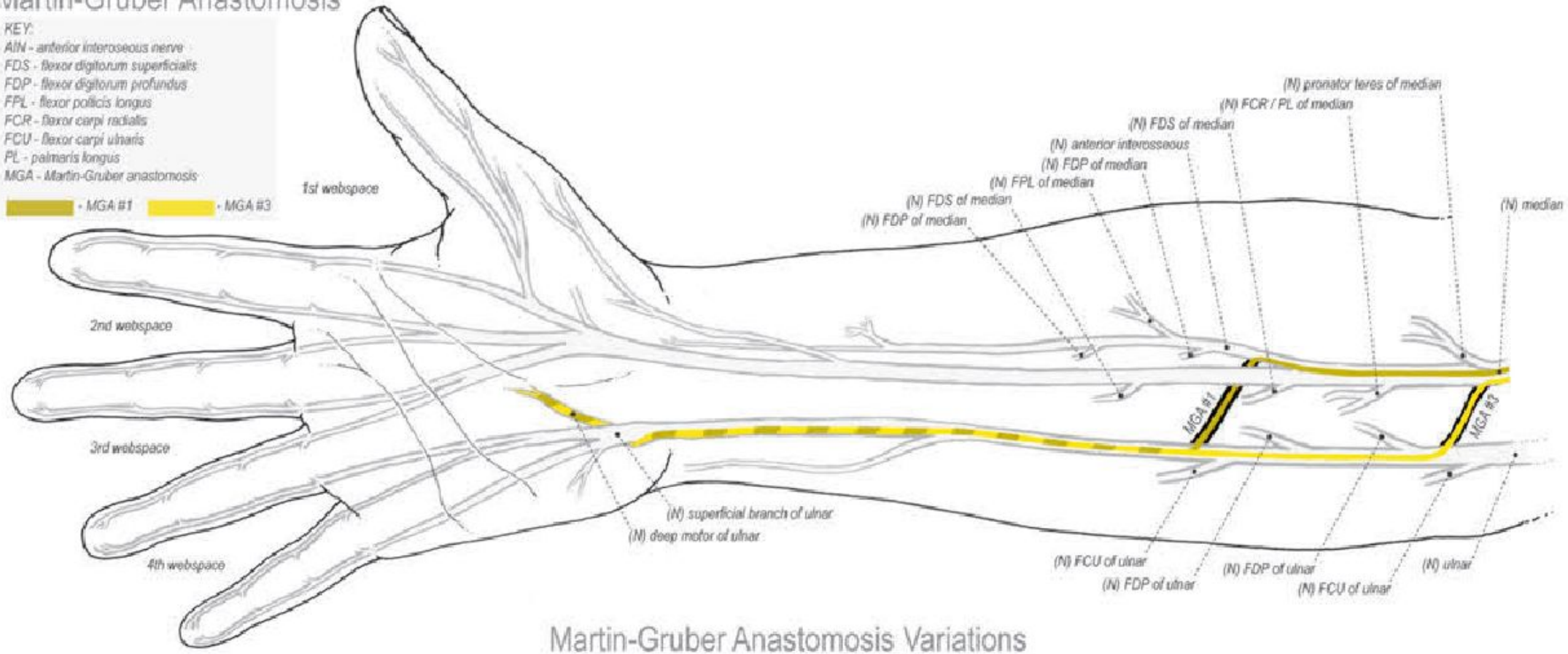


## Martin-Gruber Anastomosis Variations

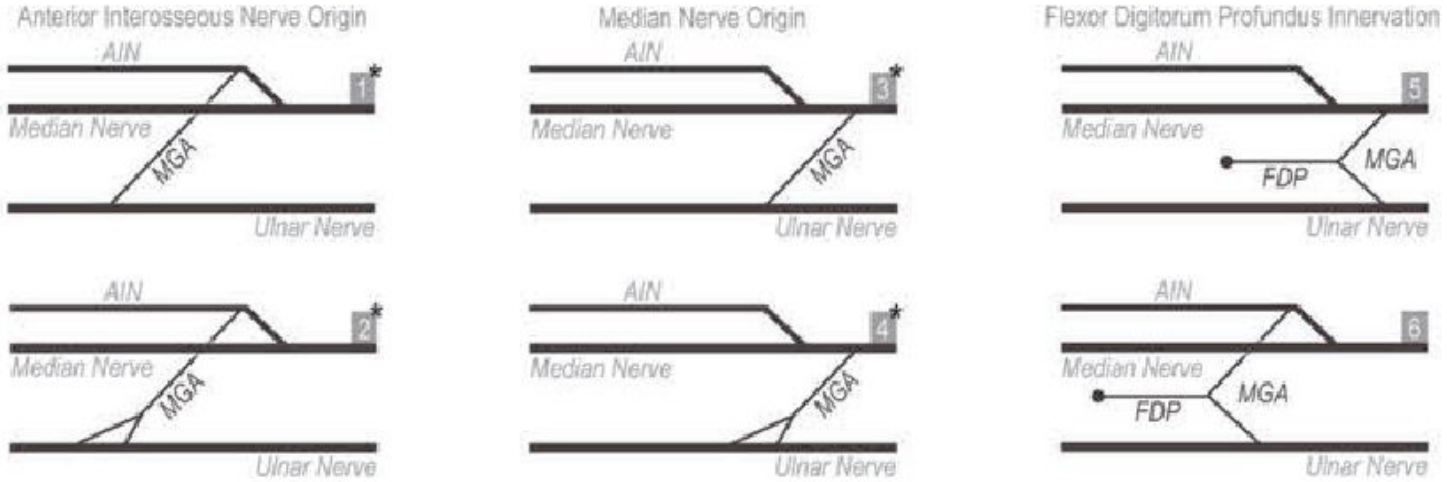

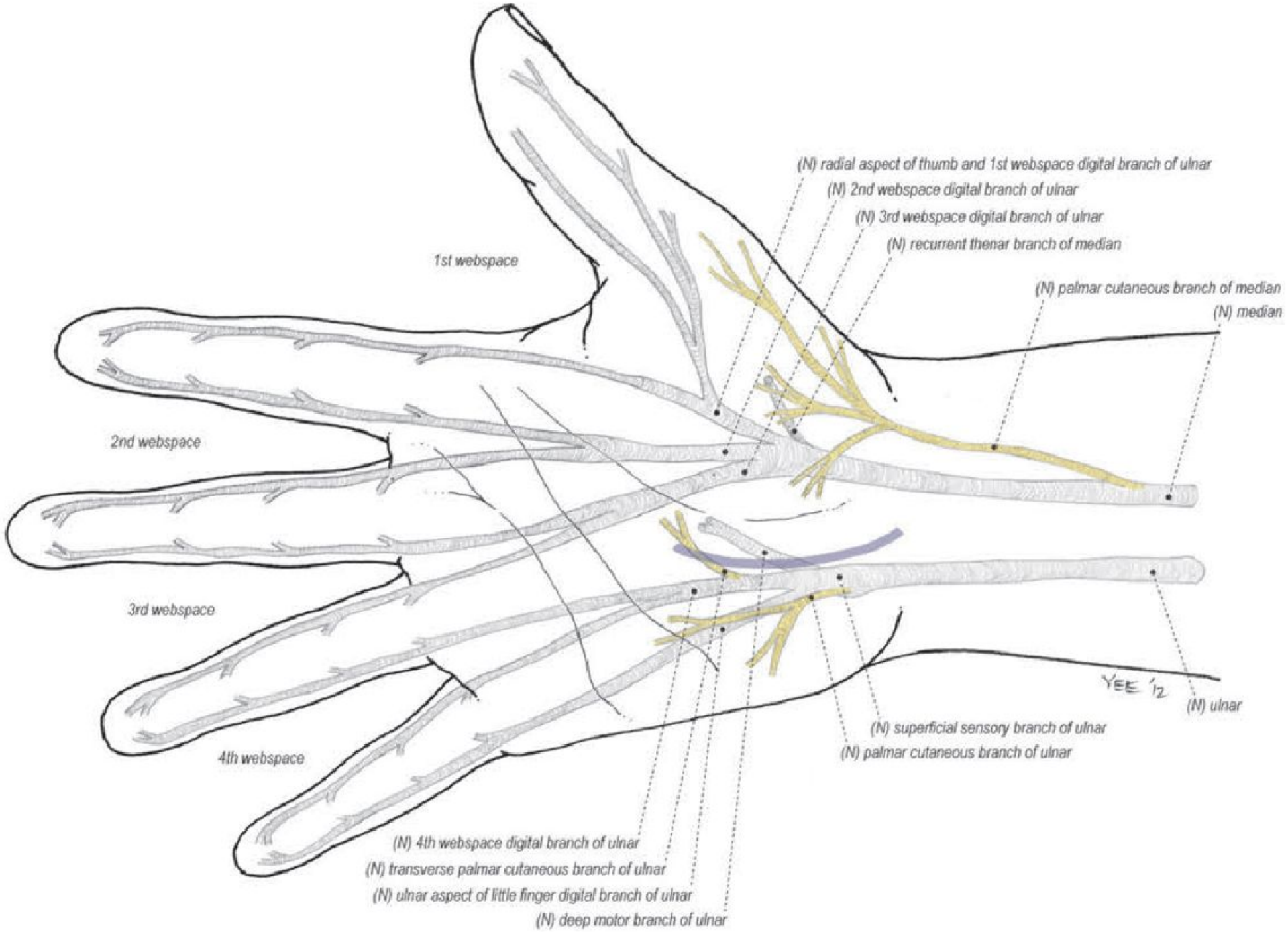
(N) radial aspect of thumb and 1st webspace digital branch of ulnar
(N) 2nd webspace digital branch of ulnar
(N) 3rd webspace digital branch of ulnar
(N) recurrent thenar branch of median
(N) palmar cutaneous branch of median
(N) median
1st webspace
2nd webspace
3rd webspace
4th webspace
YEE '12
(N) ulnar
(N) superficial sensory branch of ulnar
(N) palmar cutaneous branch of ulnar
(N) 4th webspace digital branch of ulnar
(N) transverse palmar cutaneous branch of ulnar
(N) ulnar aspect of little finger digital branch of ulnar
(N) deep motor branch of ulnar

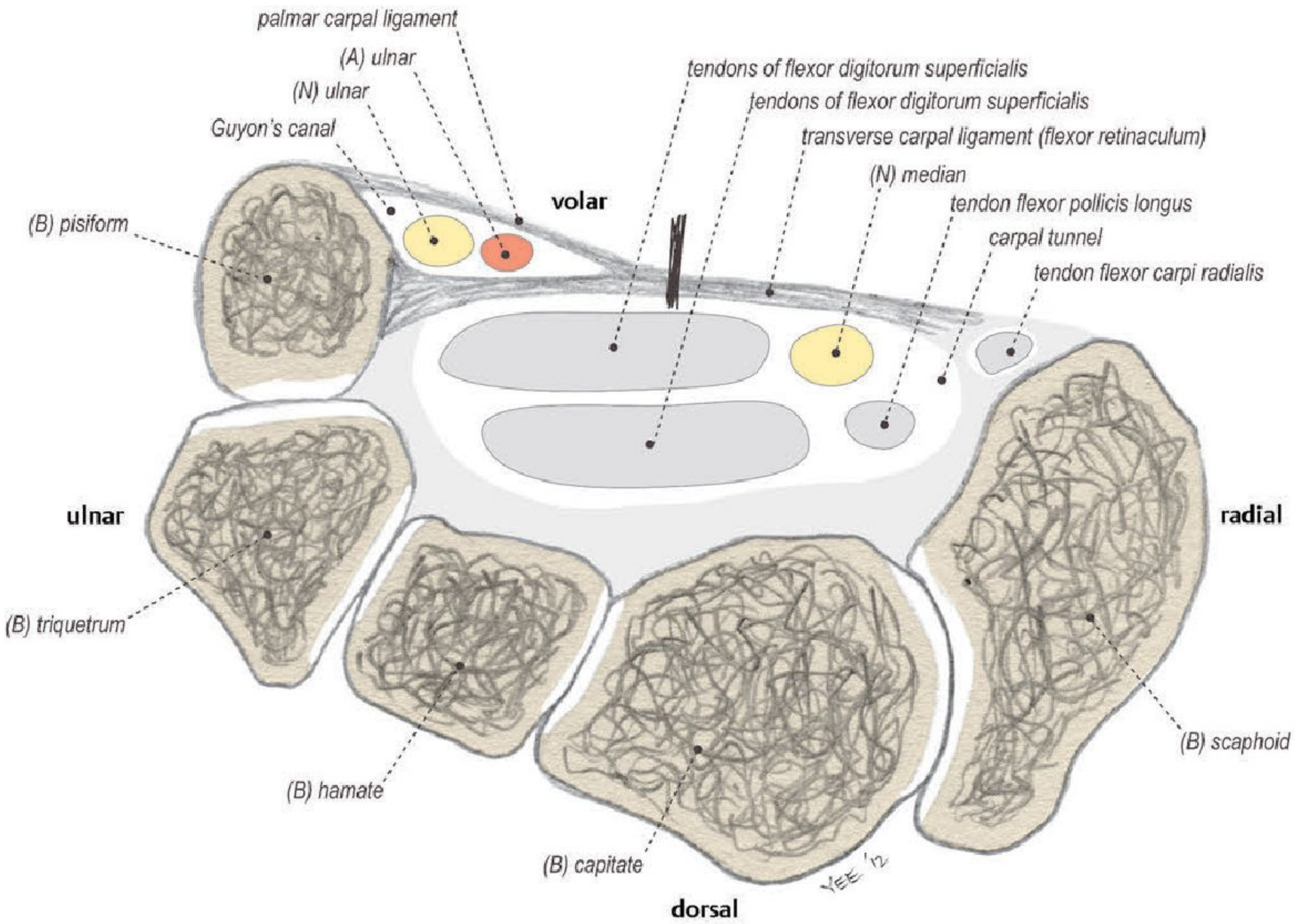
palmar carpal ligament
(A) ulnar
(N) ulnar
Guyon's canal
tendons of flexor digitorum superficialis
tendons of flexor digitorum superficialis
transverse carpal ligament (flexor retinaculum)
(N) median
tendon flexor pollicis longus
carpal tunnel
tendon flexor carpi radialis
volar
(B) pisiform
ulnar
radial
(B) triquetrum
(B) hamate
(B) capitate
(B) scaphoid
dorsal
YEE '12

# Направления хирургического лечения

- Травмы нервов
- Туннельные синдромы
- Опухоли периферических нервов
- Болевые синдромы

## Виды оперативных вмешательств:

- Невролиз
- Нейроррафия
- Пластика нерва
- Невротизация

# Виды травмы периферических нервов

**Открытые повреждения:**

- Резаные, колотые, рубленые, рваные, разможенные
- Огнестрельные
- Ранения нервов в сочетании с повреждением костей, суставов, сухожилий

**Закрытые повреждения:**

- Сотрясение, ушиб, сдавление, тракция
- Повреждения нервов в сочетании: с переломом, вывихом, повреждением сосудов, массивным размозжением мышц
- Жгутовые повреждения
- Ишемические
- Холодовые

# Формы повреждения нерва

**Анатомический перерыв нервного ствола:**

- Полный
- Частичный

**Внутриствольные повреждения нерва:**

- Гематома
- Инородные тела
- Разрывы пучков

**22.** Формы повреждения нерва:

а — полный анатомический перерыв нерва, неврома центрального конца; б — частичный перерыв нерва, образование боковой невромы; в — почти полный анатомический перерыв нерва; г — внутриствольное повреждение нерва, рубцовые изменения нерва на месте повреждения

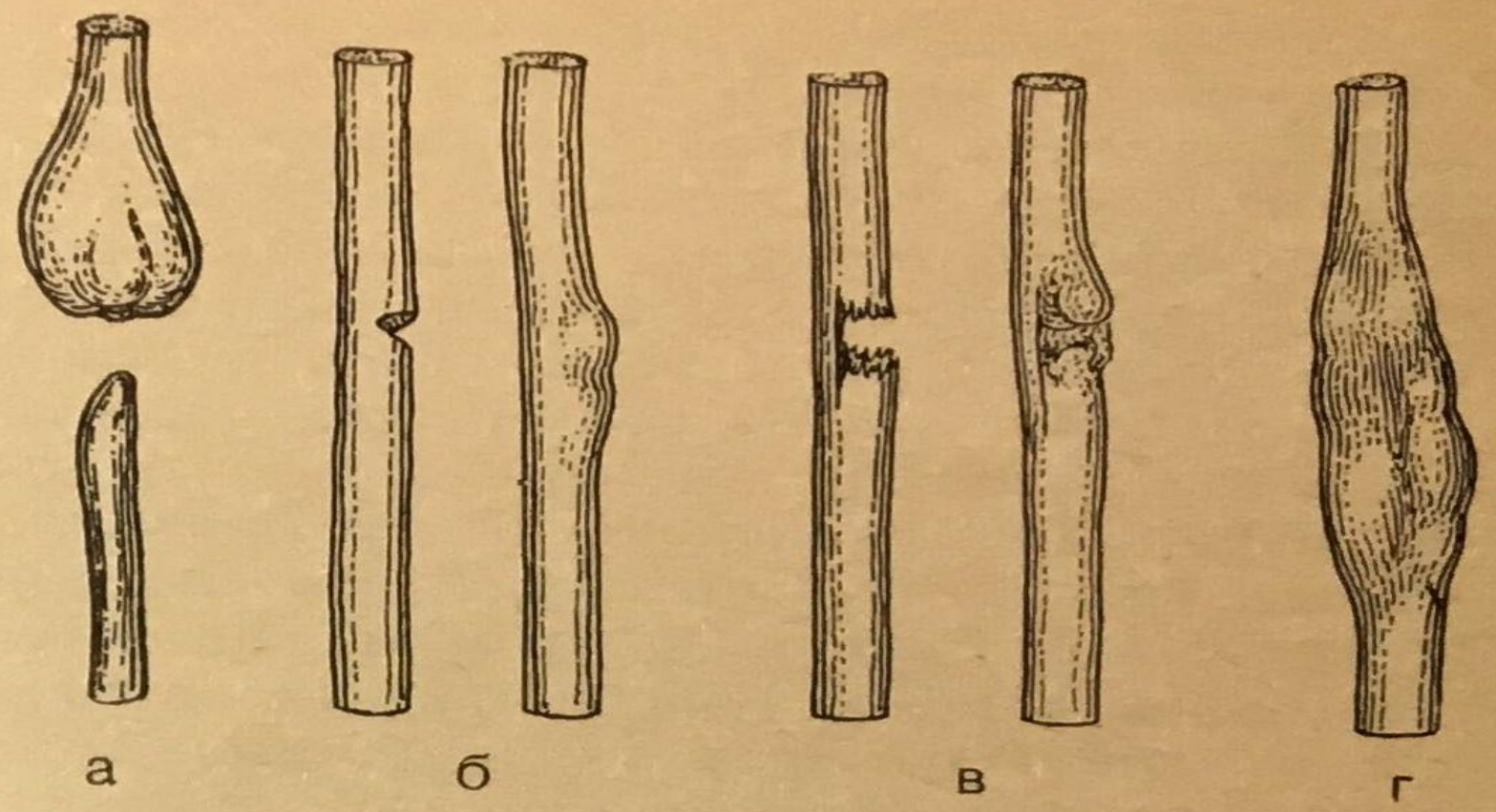

# Классификация повреждений периферической нервной системы

| Seddon | Sunderland (Degree) | favorable | recovery rate |
|---|---|---|---|
| Neurapraxia | I | + | quick |
| Axonotmesis | II | + | slow |
| | III | + | partial slow |
| | IV | - | - |
| Neurotmesis | V | - | - |
| | VI (combination of any of Sunderland (I-V) | + / - | + / - |

| Классификация | Классификация | Патология | Восстановление |
|---|---|---|---|
| Нейропраксия | 1 | Блок проведения, лёгкое повреждение с чувствительными и двигательными нарушениями. Анатомически страдают миелиновые оболочки | Полное |
| Аксонотмезис | 2 | Разрушение аксонов и миелиновых оболочек. Эндоневрий интактный. ВД. Последующий рост аксонов вдоль интактных эндоневральных трубок. | Полное |
| Аксонотмезис | 3 | Повреждение эндоневрия, его рубцевание. Регенерация затруднена | Вариабельно, неполное. |
| Аксонотмезис | 4 | Повреждены аксоны, пери- и эндоневрий. Целостность поддерживается рубцовой тканью и эпиневрием | Вариабельно, неполное. |
| Нейротмезис | 5 | Полный перерыв нерва или значительная его дезорганизация рубцовой тканью | Отсутствует |

**Table 1.2** Classification of Nerve Injury

| | Histopathologic Changes | | | | | Tinel Sign | |
|---|---|---|---|---|---|---|---|
| Degree of Injury | Myelin | Axon | Endoneurium | Perineurium | Epineurium | Present | Progresses Distally |
| I Neurapraxia | + /- | | | | | - | - |
| II Axonotmesis | + | + | | | | + | + |
| III | + | + | + | | | + | + |
| IV | + | + | + | + | | + | - |
| V Neurotmesis | + | + | + | + | + | + | - |
| VI | Various fibers and fascicles demonstrate various pathologic changes | | | | | + | + /- |

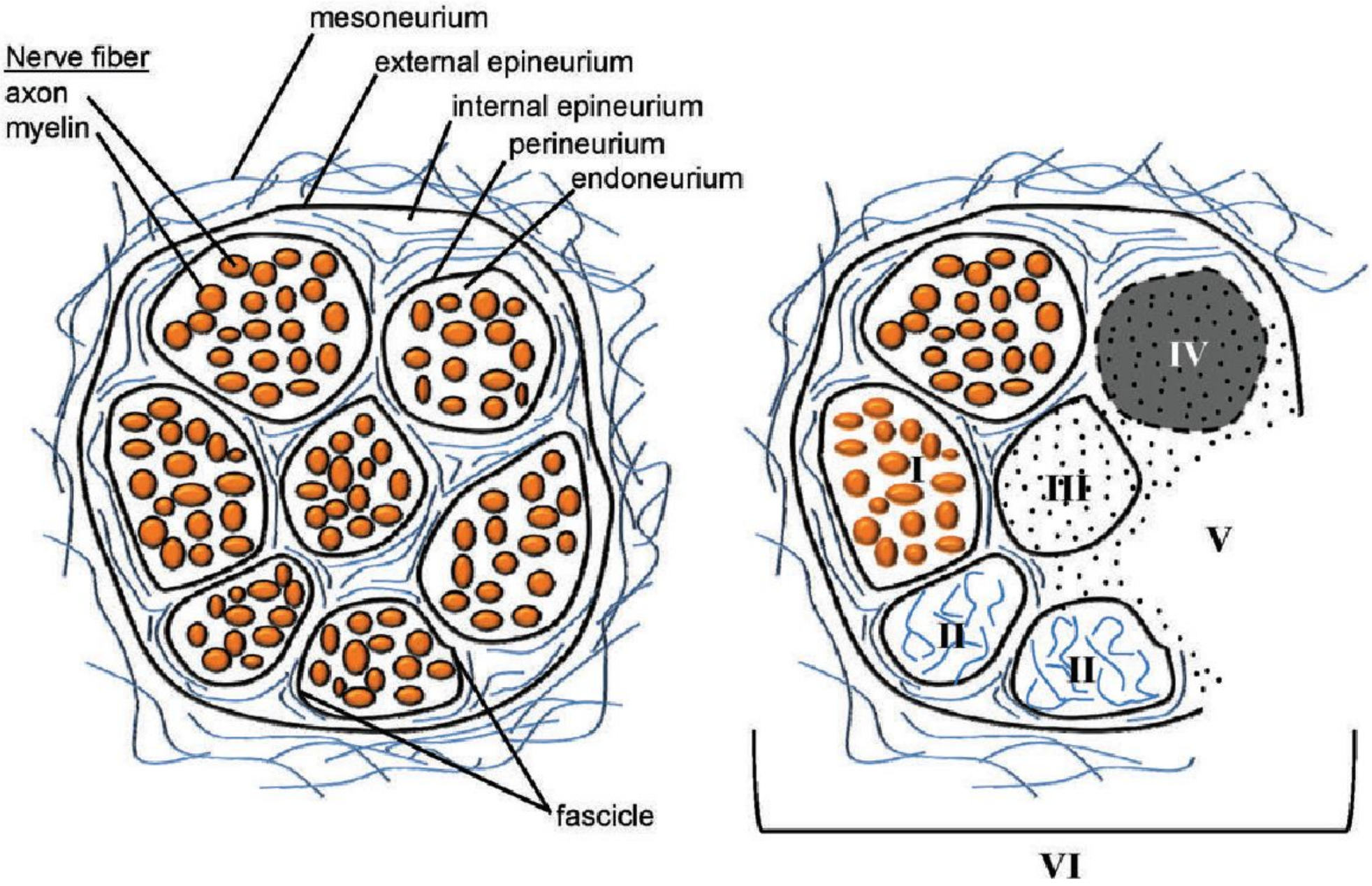


a Normal Nerve

b Classification of Nerve Injury

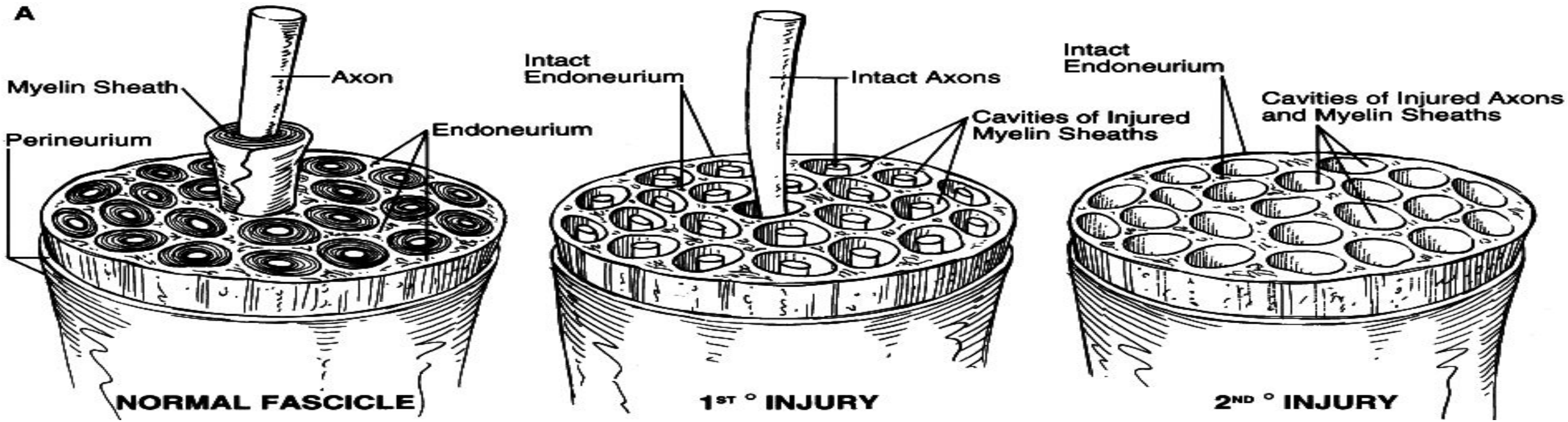
A
Myelin Sheath
Axon
Perineurium
Endoneurium
NORMAL FASCICLE
Intact Endoneurium
Intact Axons
Cavities of Injured Myelin Sheaths
1ST ° INJURY
Intact Endoneurium
Cavities of Injured Axons and Myelin Sheaths
2ND ° INJURY

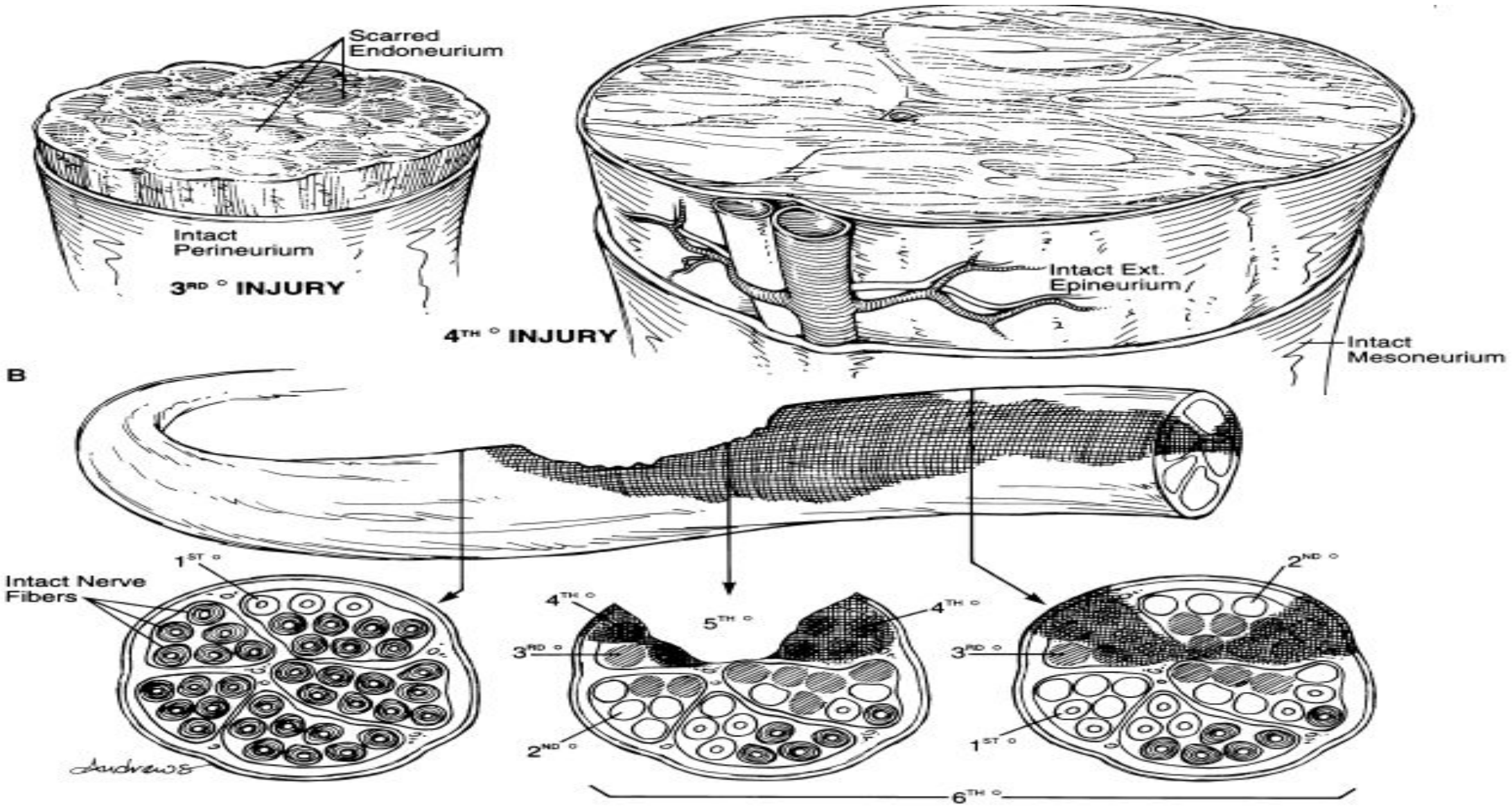
Scarred Endoneurium
Intact Perineurium
3RD ° INJURY
4TH ° INJURY
Intact Ext. Epineurium
Intact Mesoneurium
B
Intact Nerve Fibers
1ST °
2ND °
3RD °
4TH °
5TH °
6TH °

# Normal Nerve

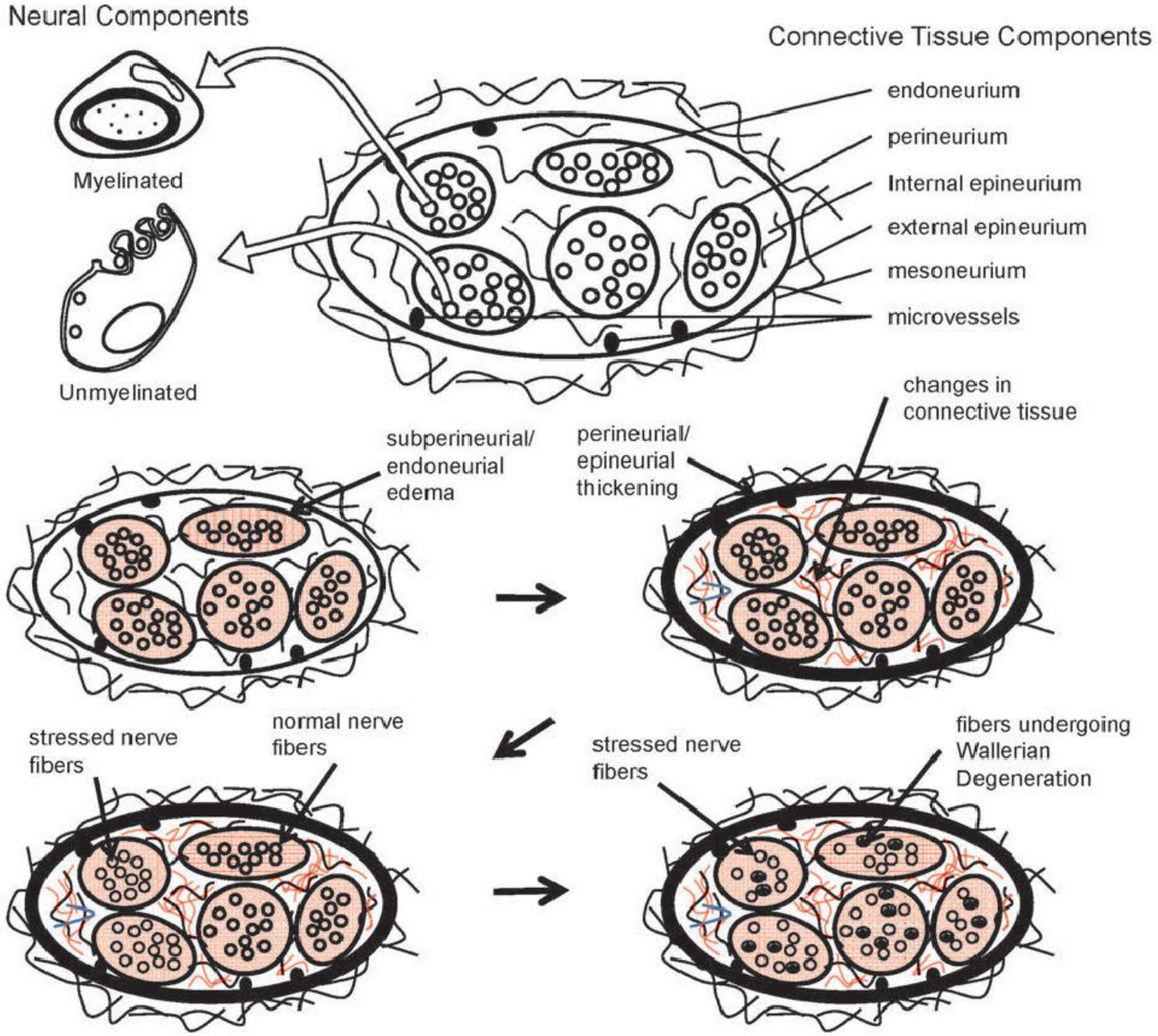

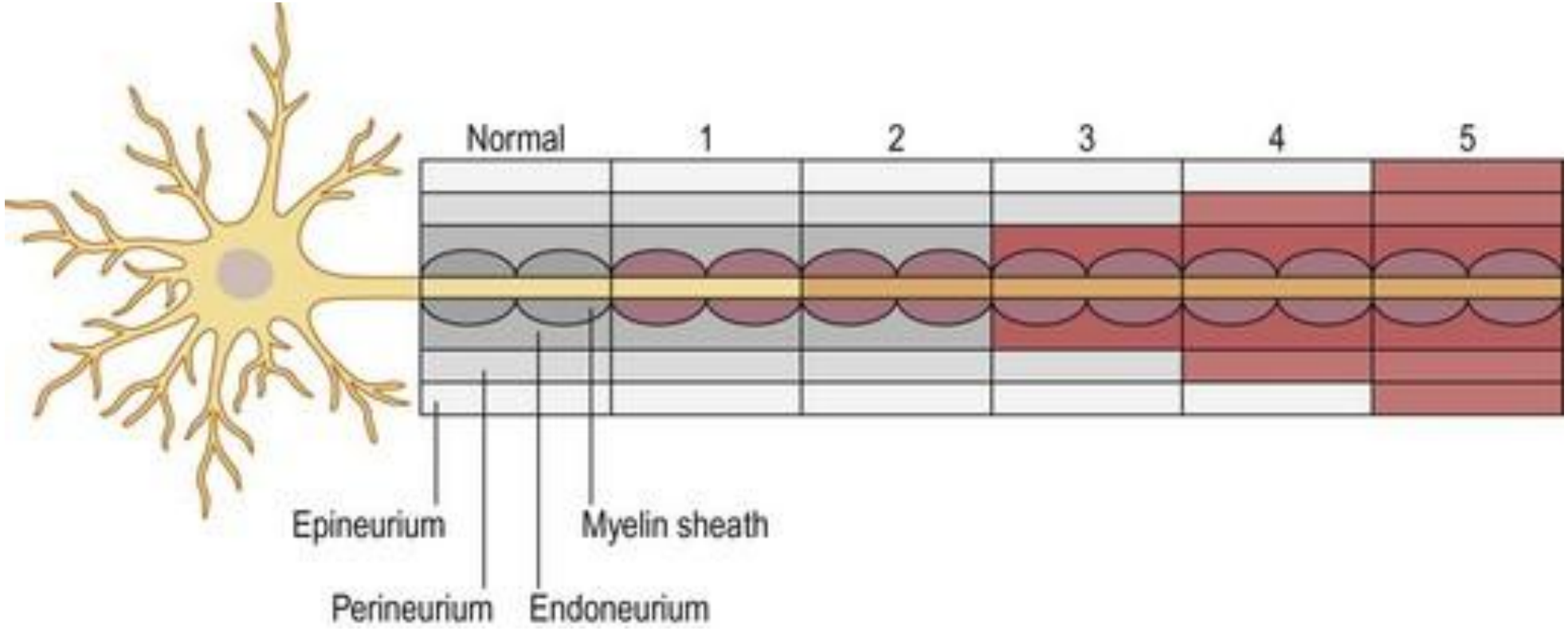
Normal
1
2
3
4
5
Epineurium
Myelin sheath
Perineurium
Endoneurium

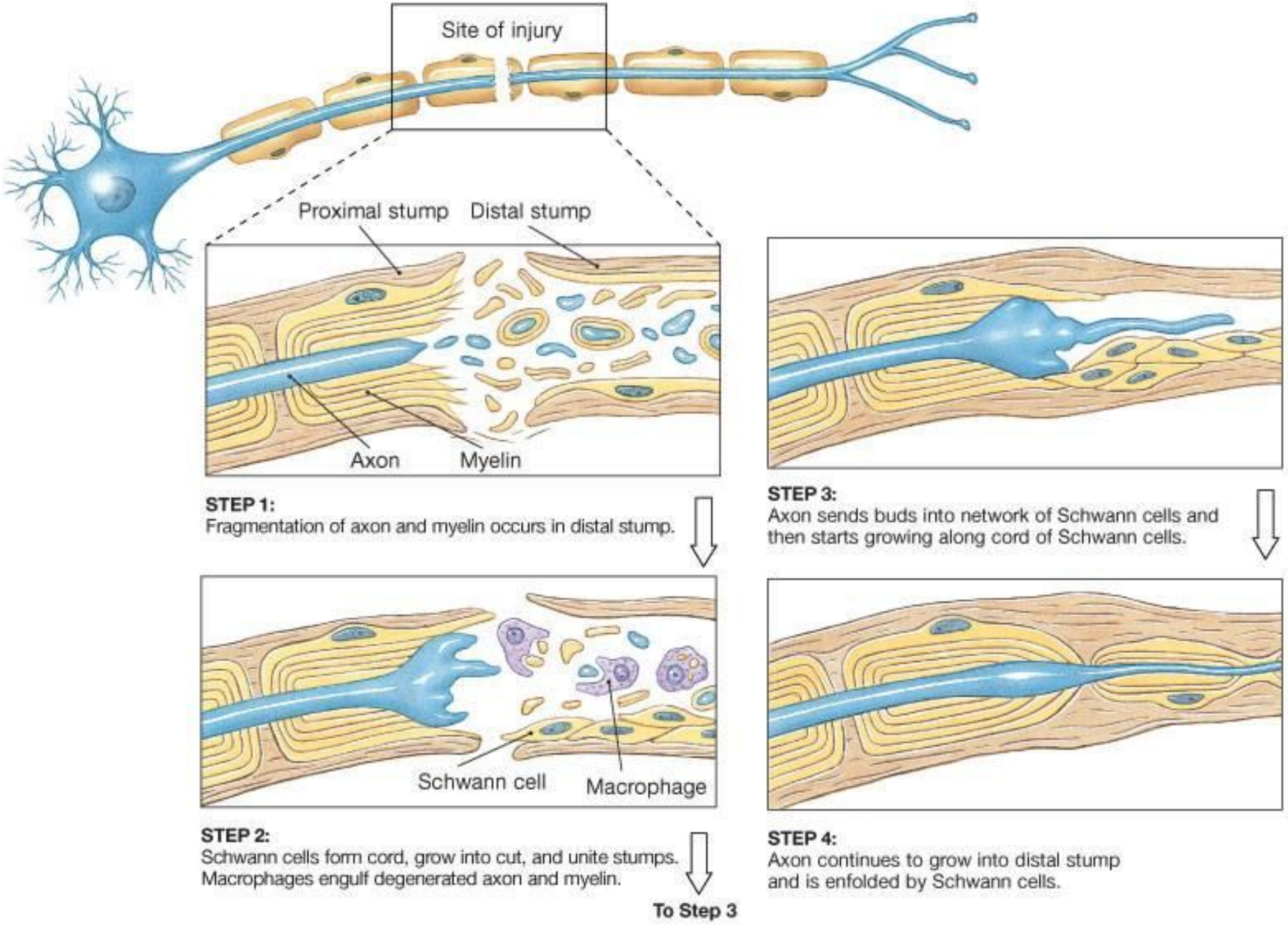


Copyright © 2003 Pearson Education, Inc., publishing as Benjamin Cummings.

# Принципы хирургического лечения:

1. **Количественная до- и послеоперационная оценка чувствительности и двигательной функции**
2. **Микрохирургия**
3. **Отсутствие натяжения**
4. **Если без натяжения невозможно – устанавливают межпучковый трансплантат**
5. **Нейтральное положение конечности**
6. **Сопоставление групп пучков нервных волокон**
7. **Послеоперационный курс реабилитации**

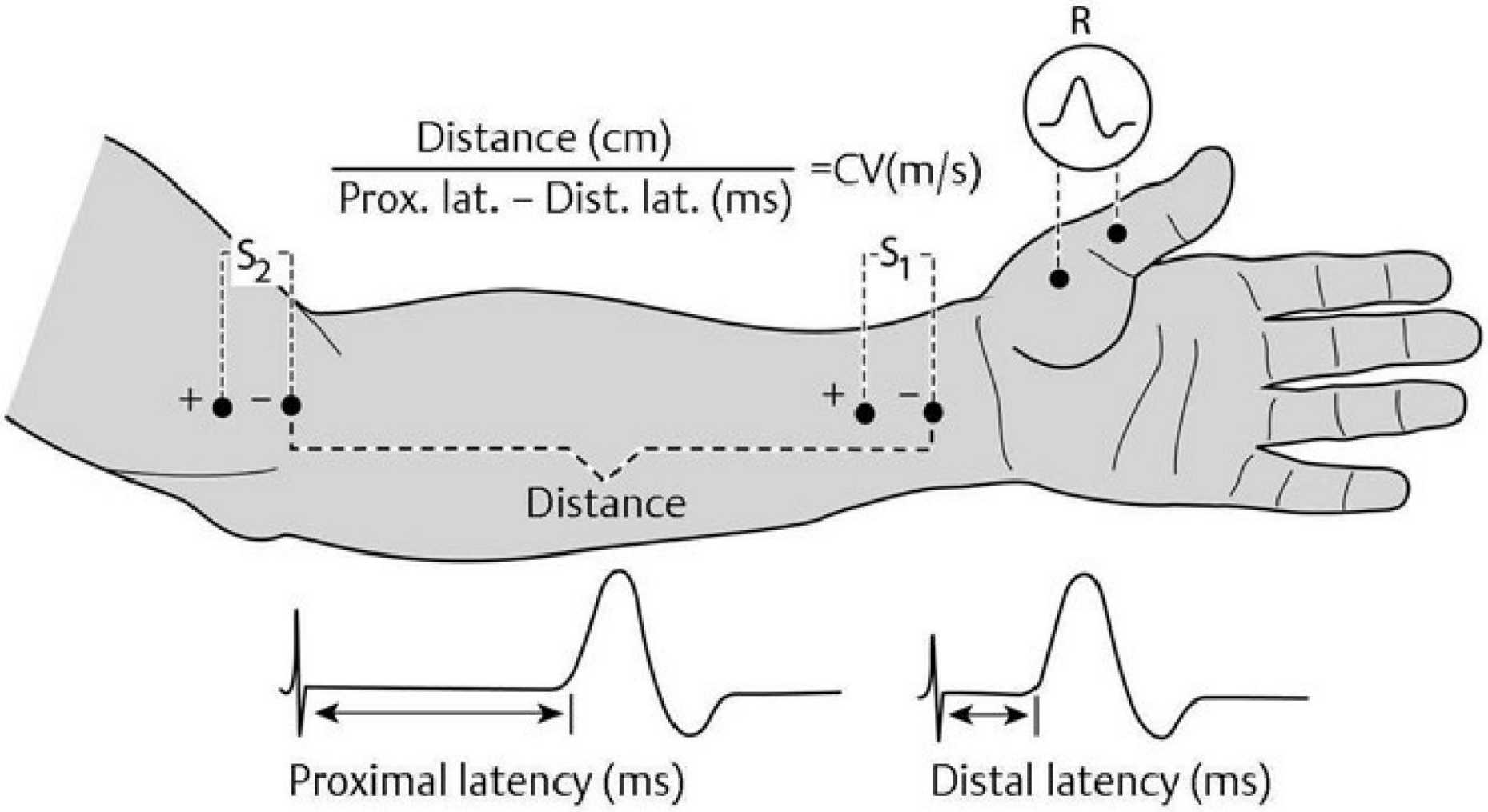
R
Distance (cm)
Prox. lat. – Dist. lat. (ms)
=CV(m/s)
S2
S1
+
–
+
–
Distance
Proximal latency (ms)
Distal latency (ms)

ЭНМГ

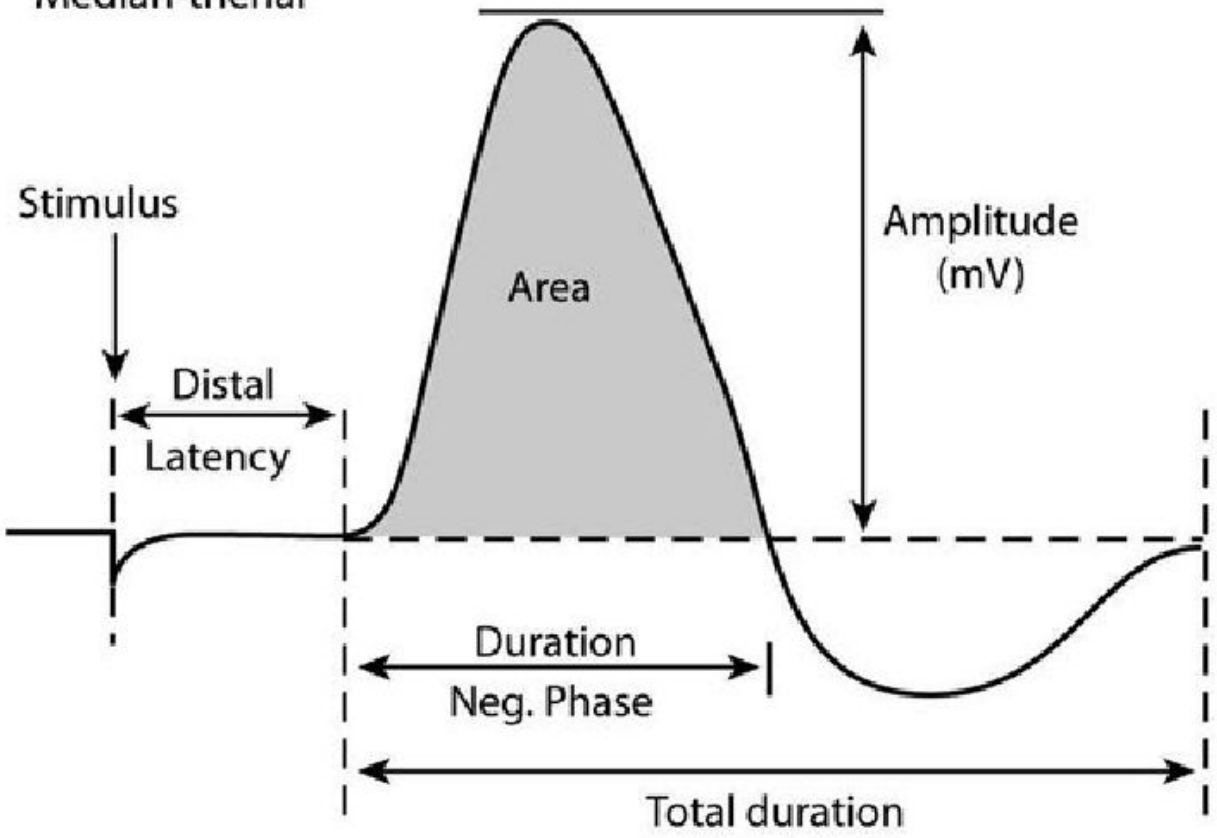
Motor
Median-thenar
Stimulus
Distal
Latency
Area
Amplitude
(mV)
Duration
Neg. Phase
Total duration

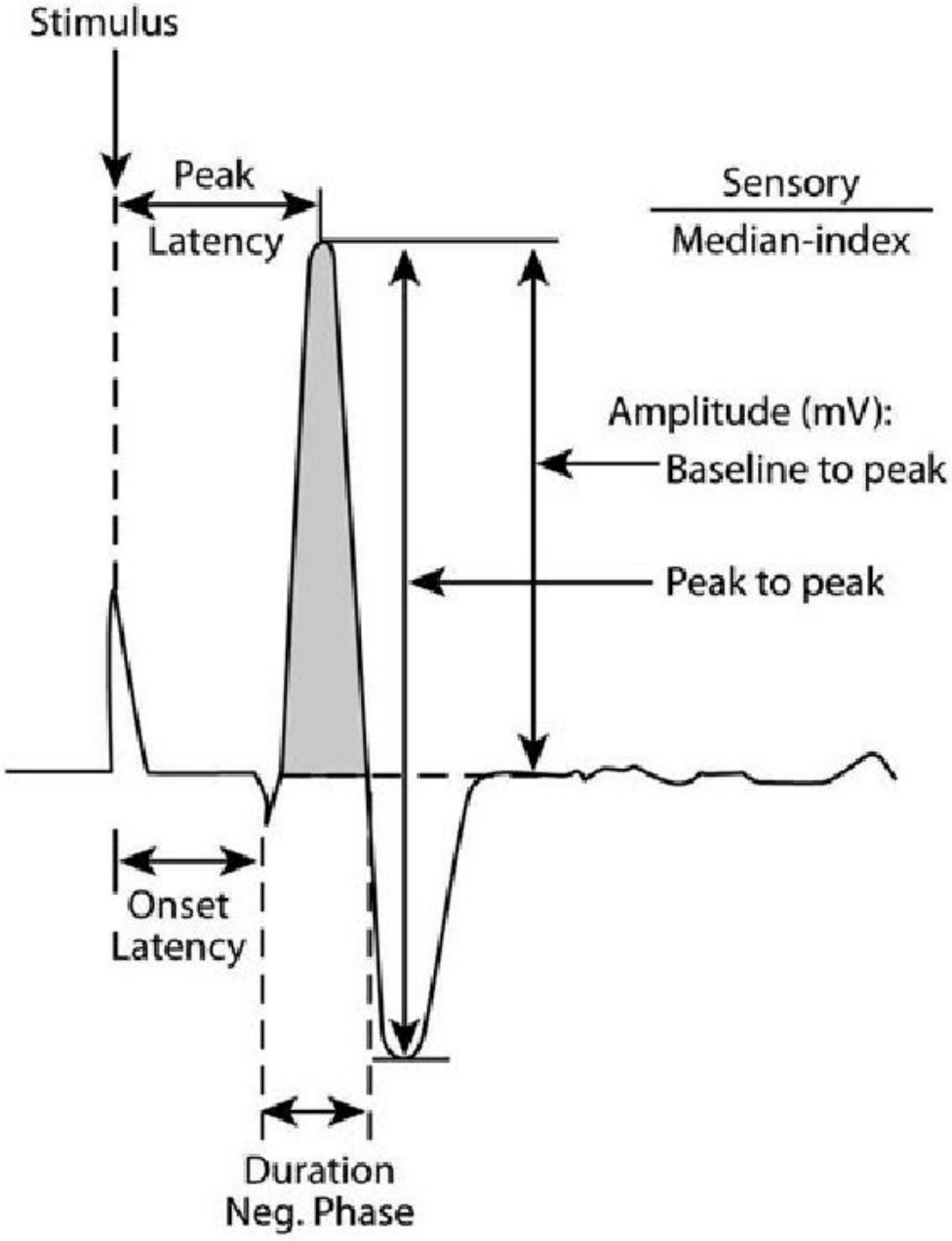
Stimulus
Peak
Latency
Sensory
Median-index
Amplitude (mV):
Baseline to peak
Peak to peak
Onset
Latency
Duration
Neg. Phase

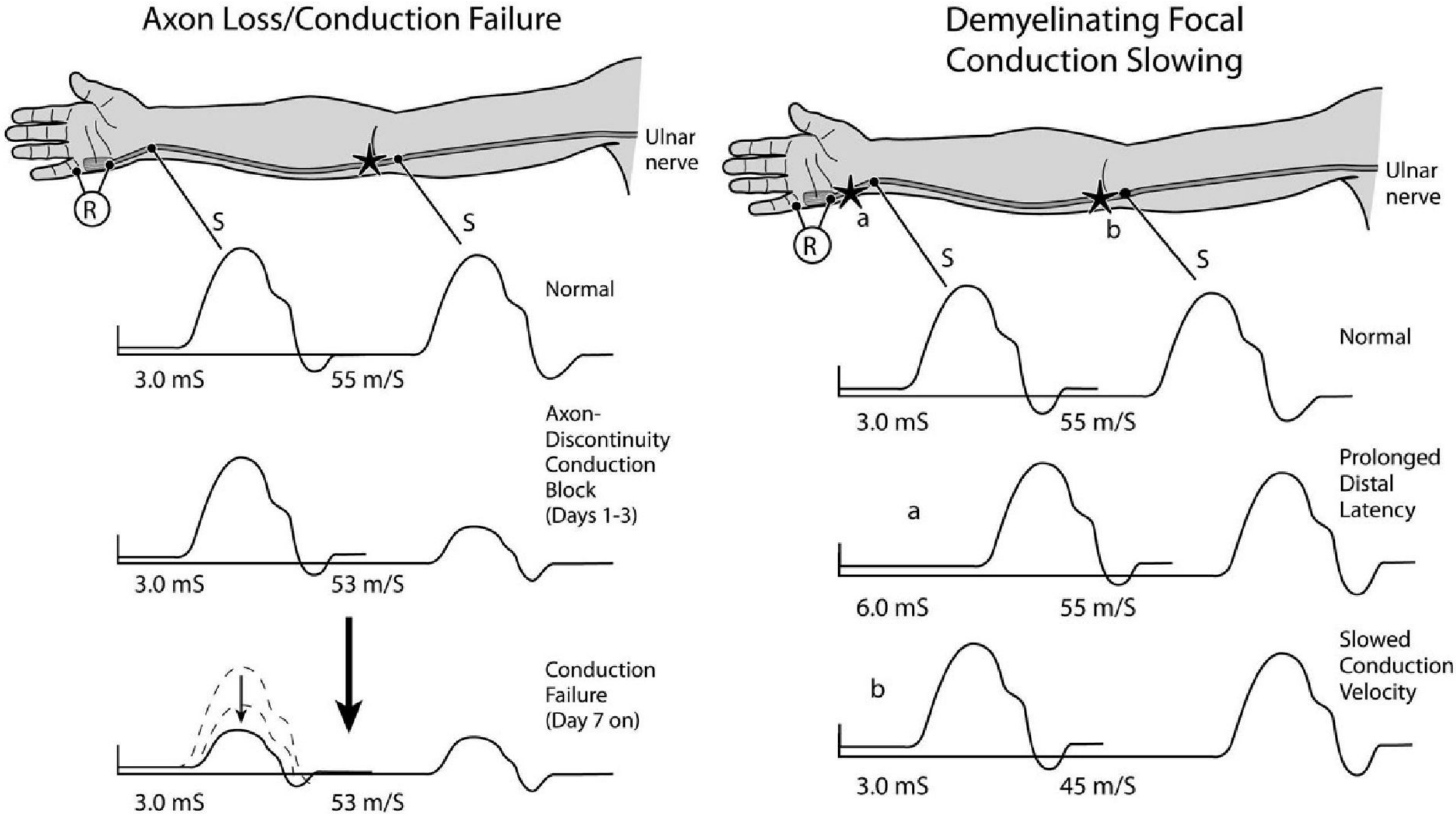
Axon Loss/Conduction Failure
Ulnar nerve
R
S
S
Normal
3.0 mS
55 m/S
Axon-Discontinuity Conduction Block (Days 1-3)
3.0 mS
53 m/S
Conduction Failure (Day 7 on)
3.0 mS
53 m/S
Demyelinating Focal Conduction Slowing
Ulnar nerve
a
b
R
S
S
Normal
3.0 mS
55 m/S
Prolonged Distal Latency
a
6.0 mS
55 m/S
Slowed Conduction Velocity
b
3.0 mS
45 m/S

## Demyelinating Differential Slowing

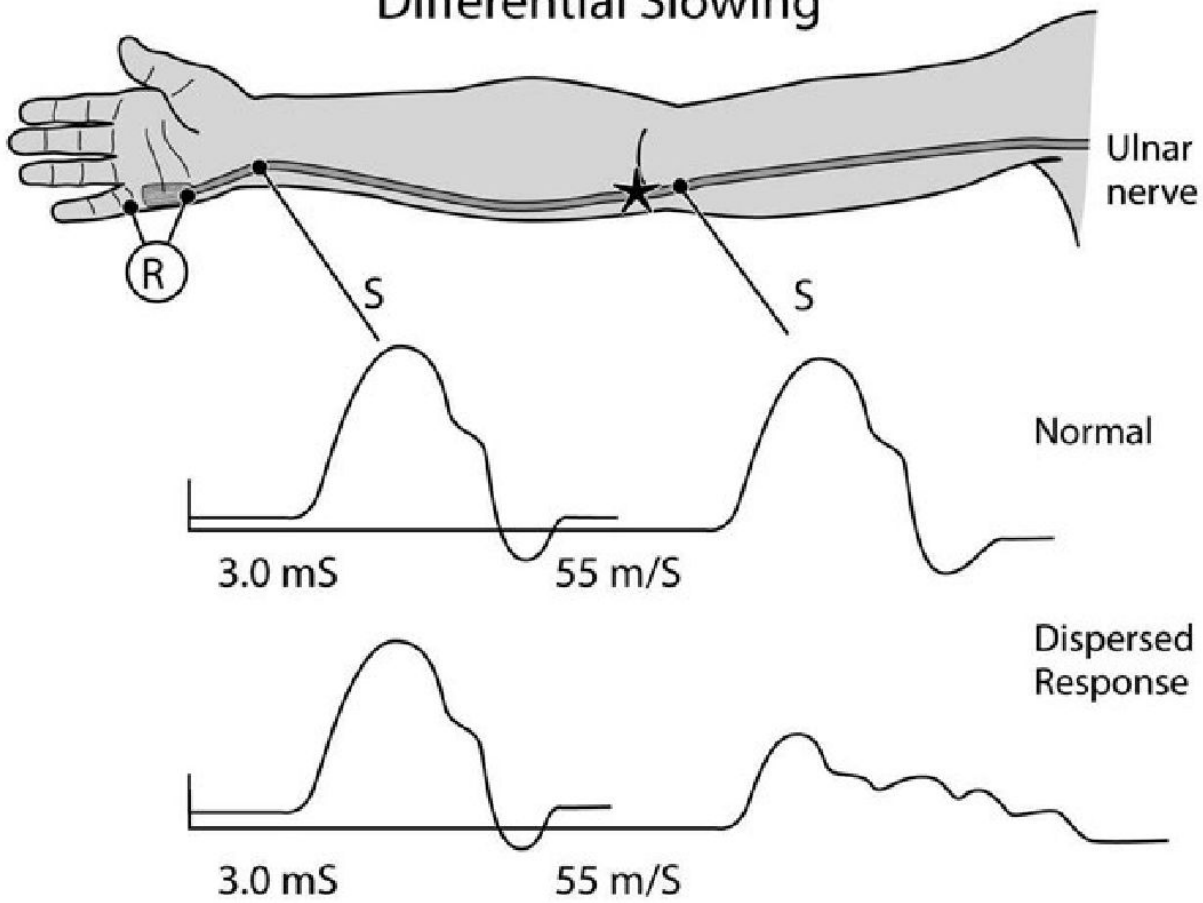


## Demyelinating Conduction Block

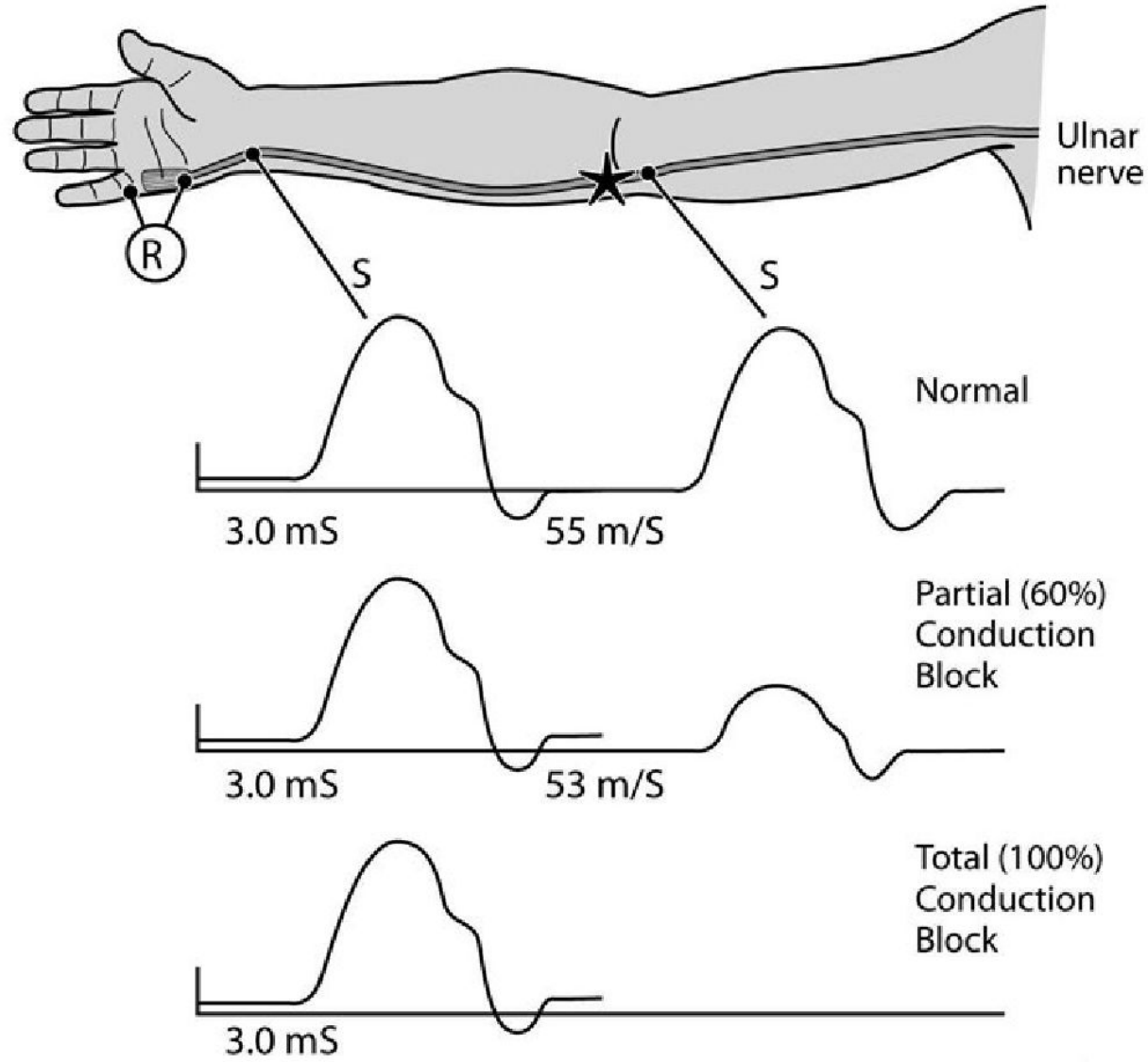

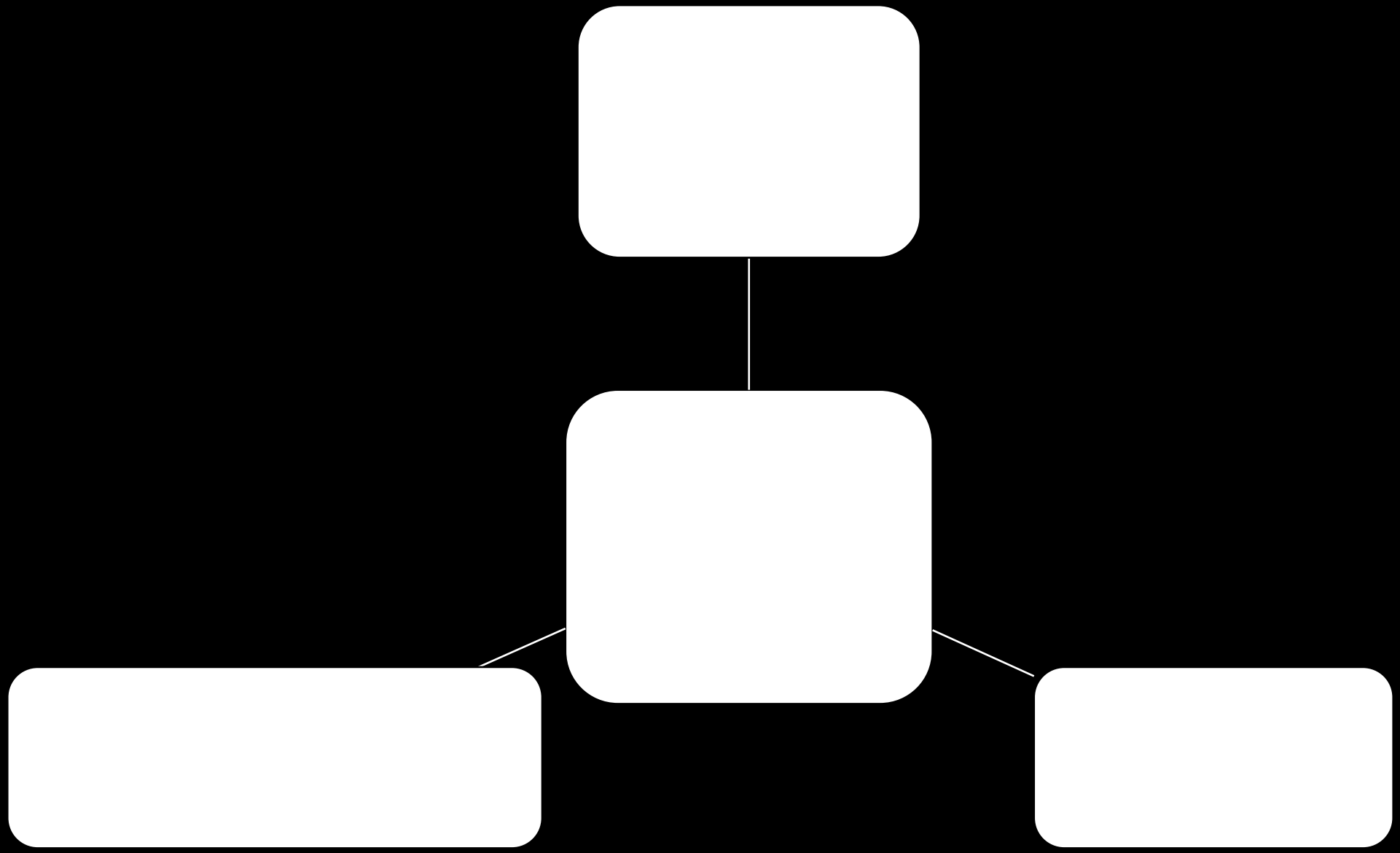

# Сроки сопоставления нерва при утрате им непрерывности:

- Первичный шов нерва: до 72 часов ?
- Первично-отсроченный шов нерва: 72 часа – 7 суток
- Вторичный шов нерва: после 7 суток.

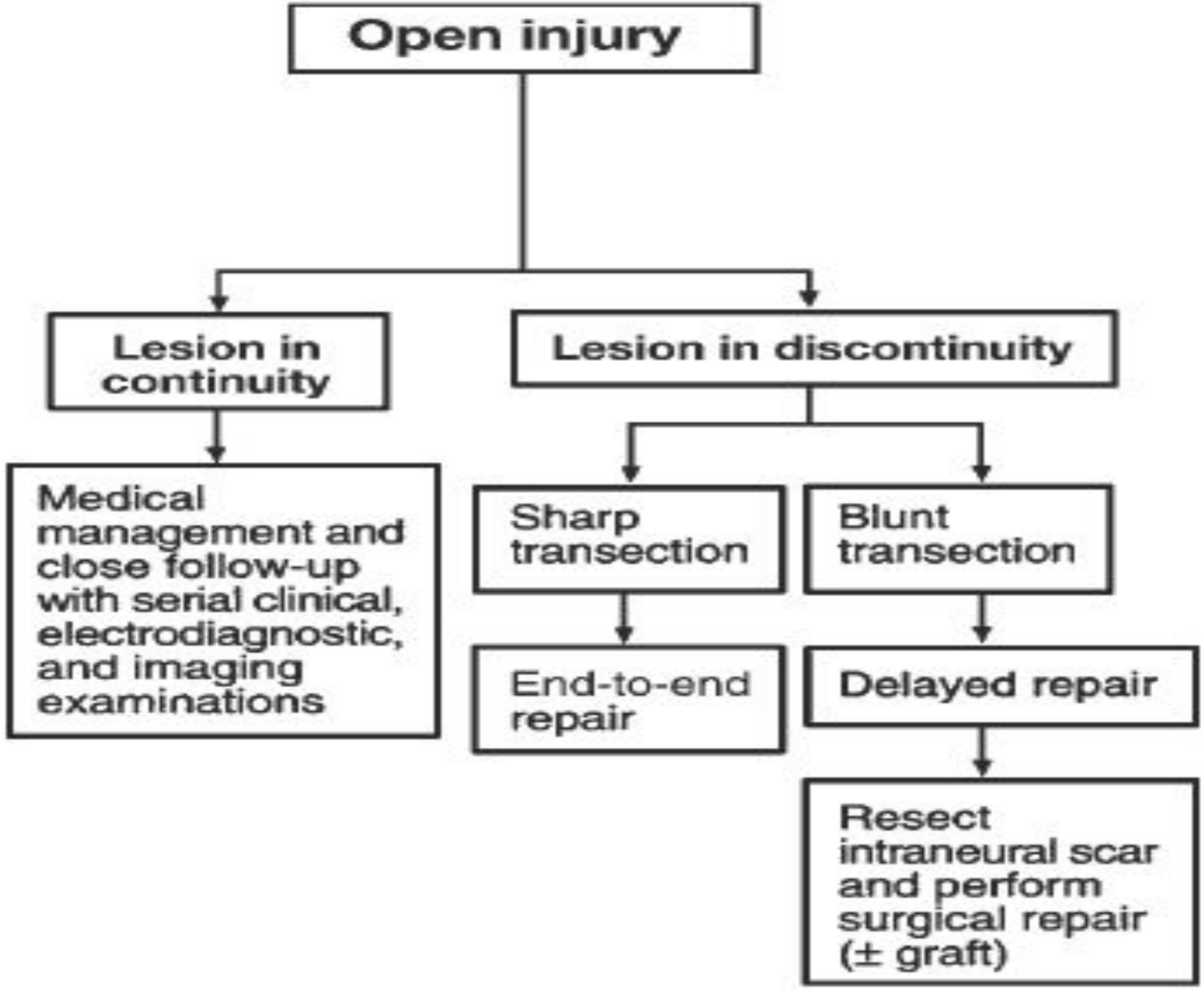
Open injury
Lesion in continuity
Lesion in discontinuity
Medical management and close follow-up with serial clinical, electrodiagnostic, and imaging examinations
Sharp transection
Blunt transection
End-to-end repair
Delayed repair
Resect intraneural scar and perform surgical repair (± graft)

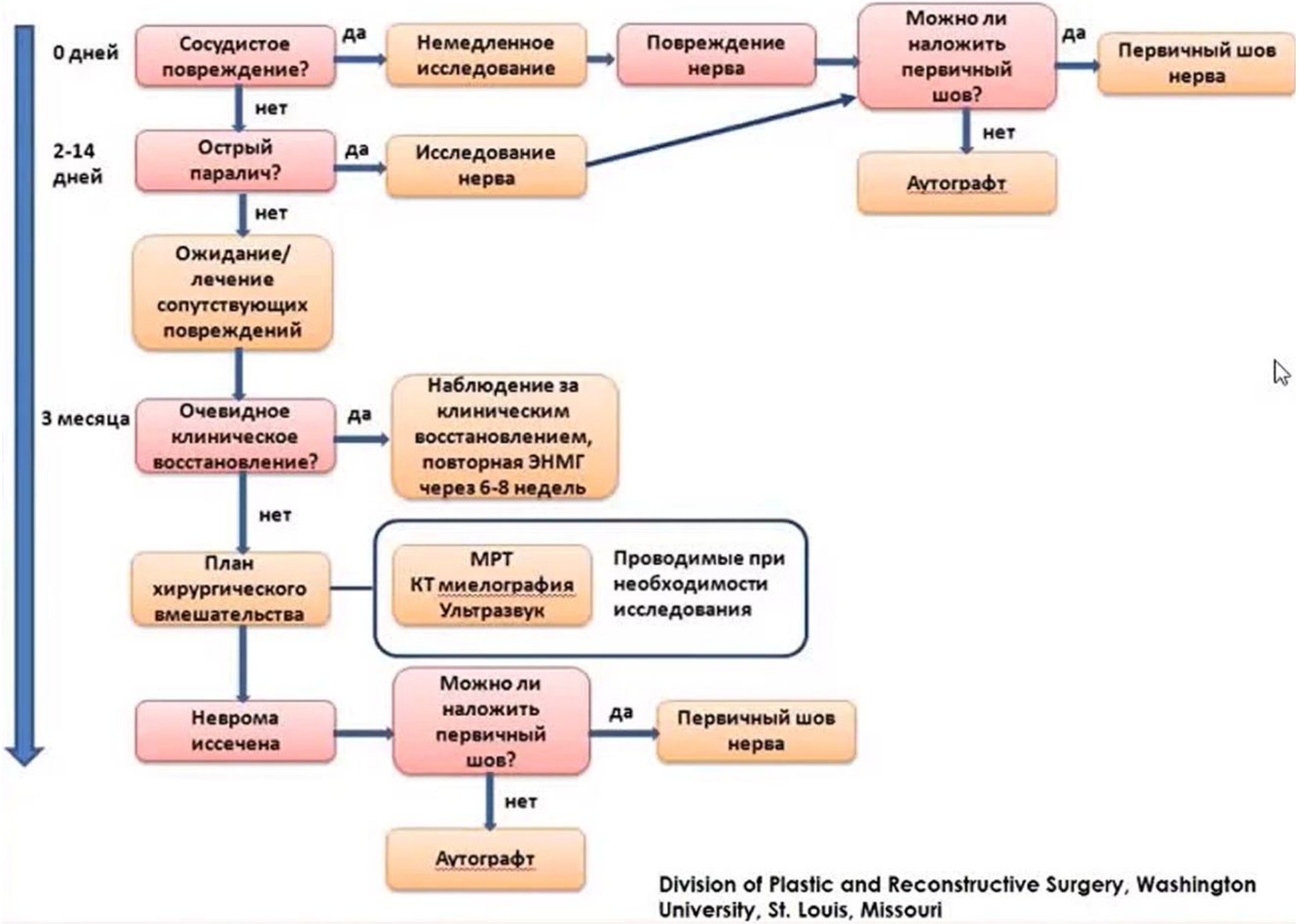
0 дней
Сосудистое повреждение?
да
Немедленное исследование
Повреждение нерва
Можно ли наложить первичный шов?
да
Первичный шов нерва
нет
Аутографт
2-14 дней
Острый паралич?
да
Исследование нерва
нет
Ожидание/ лечение сопутствующих повреждений
3 месяца
Очевидное клиническое восстановление?
да
Наблюдение за клиническим восстановлением, повторная ЭНМГ через 6-8 недель
нет
План хирургического вмешательства
МРТ
КТ миелография
Ультразвук
Проводимые при необходимости исследования
Неврома иссечена
Можно ли наложить первичный шов?
да
Первичный шов нерва
нет
Аутографт
Division of Plastic and Reconstructive Surgery, Washington University, St. Louis, Missouri

# Strategies for Nerve Reconstruction

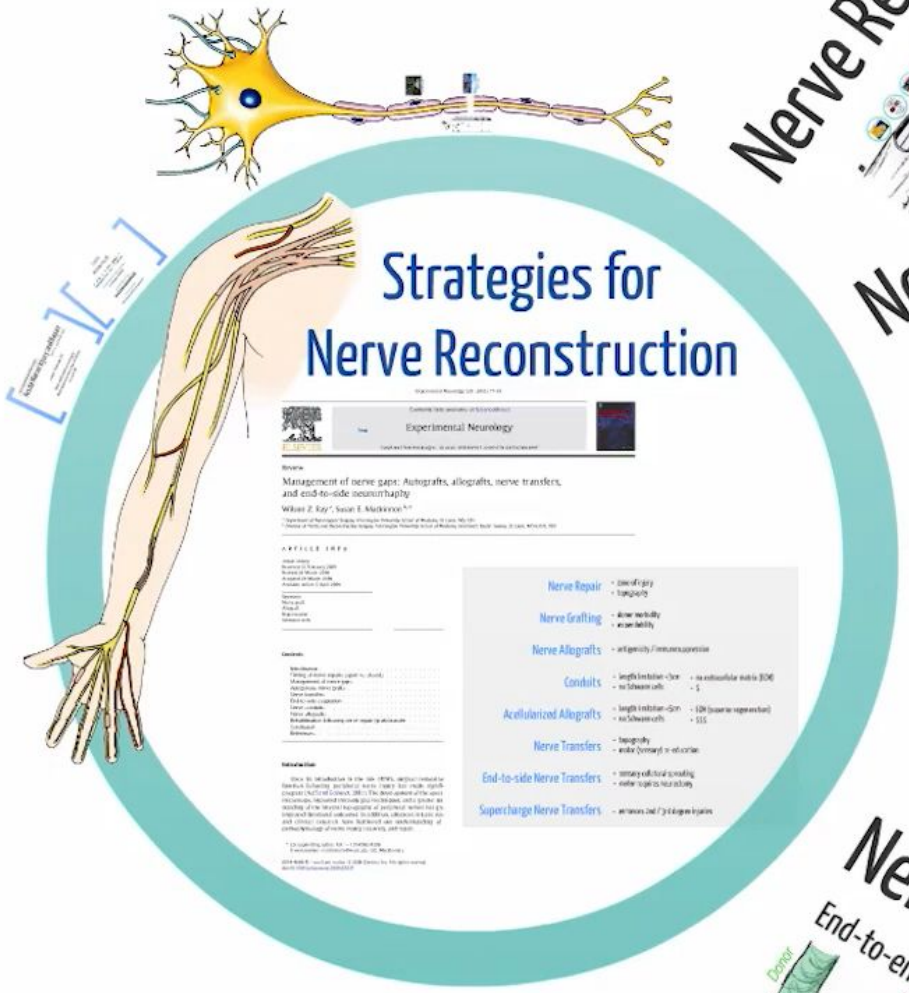


## Nerve Repair

## Nerve Grafting

## Nerve Allograft

## Conduit and Acellularized Allograft

Conduits < Allografts ≤ Grafts

## Nerve Transfers

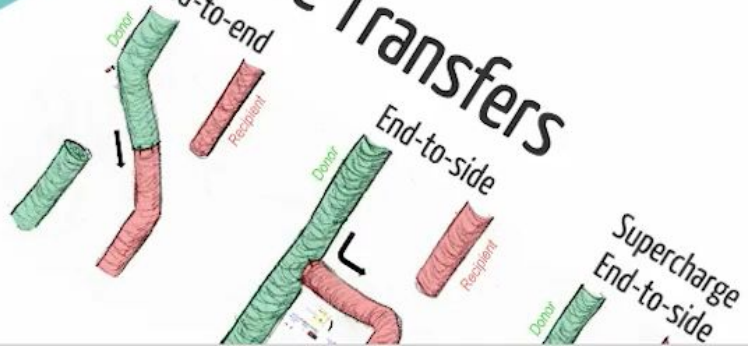

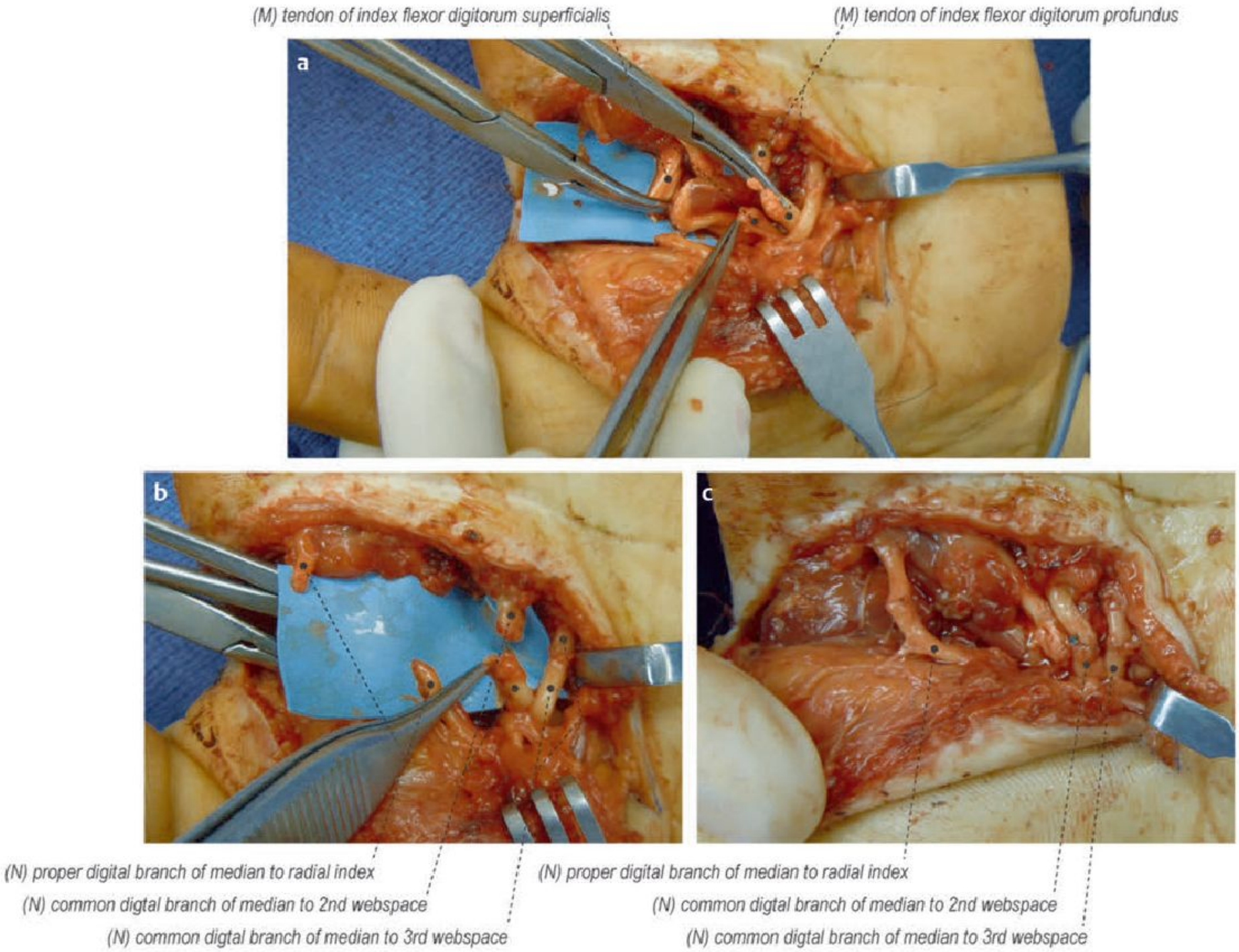
(M) tendon of index flexor digitorum superficialis
(M) tendon of index flexor digitorum profundus
a
b
c
(N) proper digital branch of median to radial index
(N) common digtal branch of median to 2nd webspace
(N) common digtal branch of median to 3rd webspace
(N) proper digital branch of median to radial index
(N) common digtal branch of median to 2nd webspace
(N) common digtal branch of median to 3rd webspace

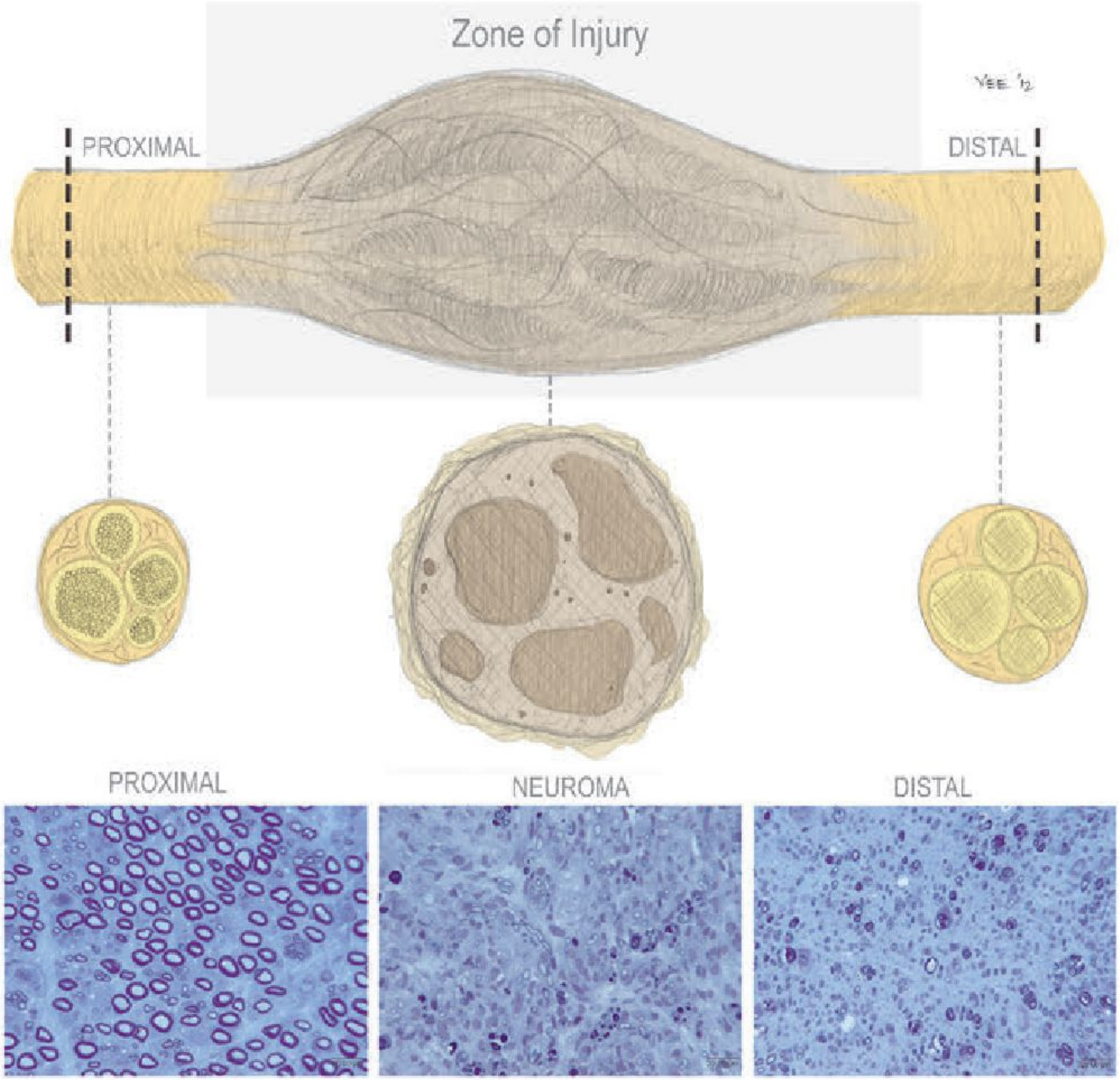
Zone of Injury
PROXIMAL
DISTAL
PROXIMAL
NEUROMA
DISTAL

**Как узнать, что дошли до живого нерва?**

1) **Красивые чёткие пучки**
2) **Кровотечение**

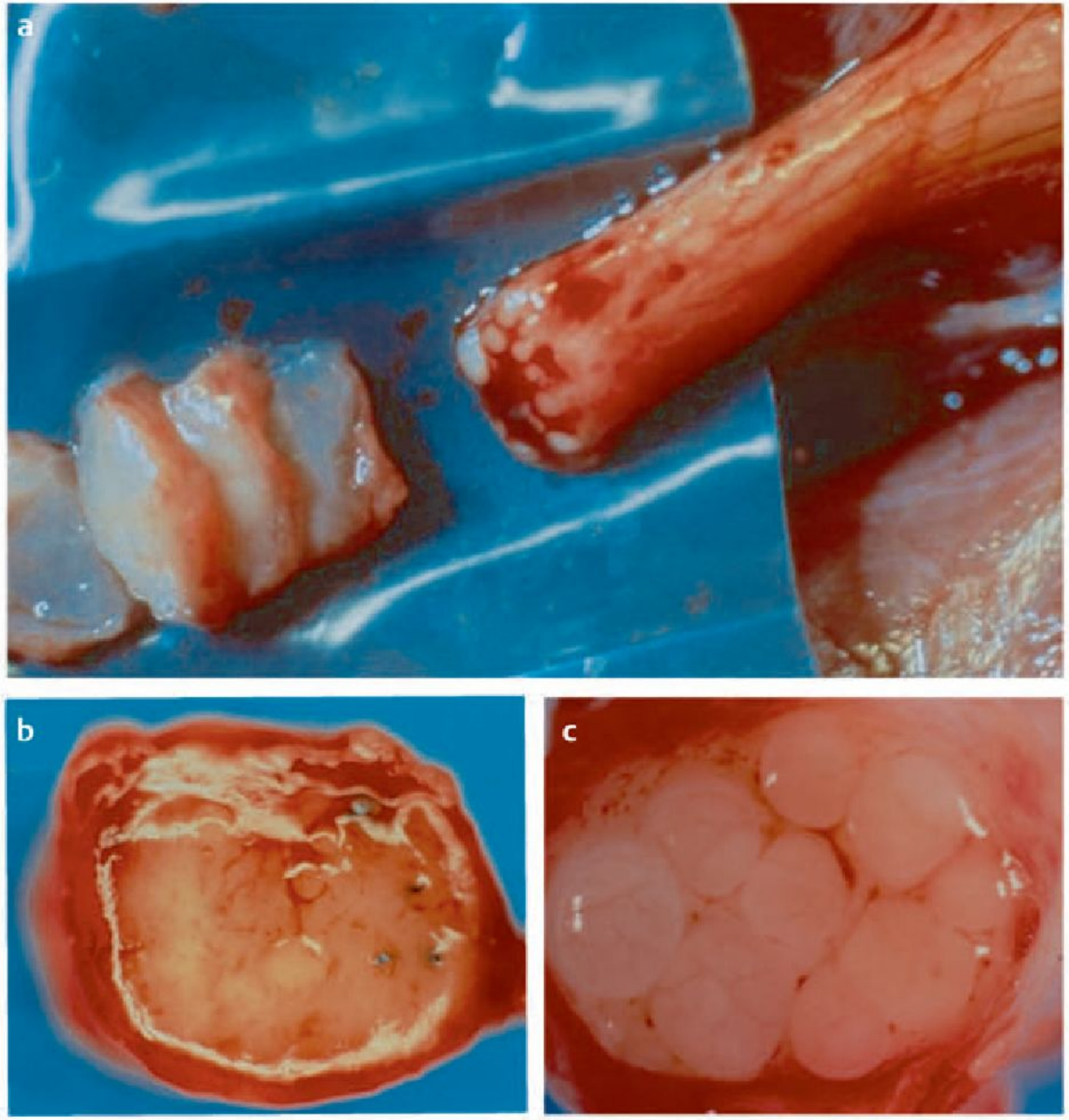

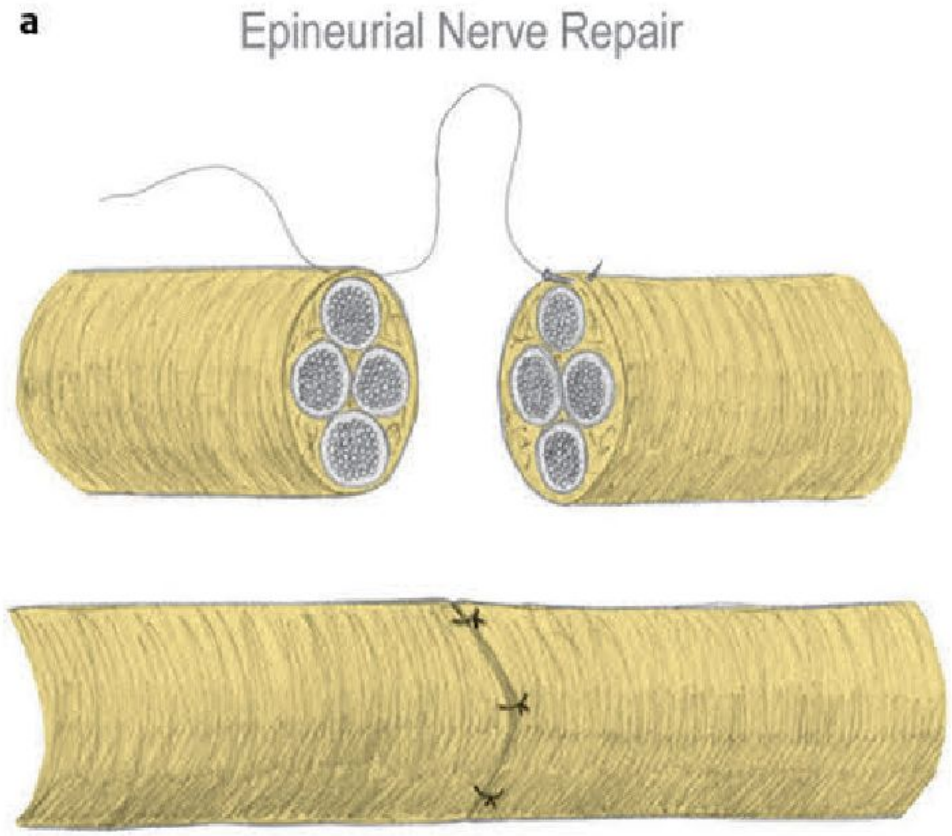


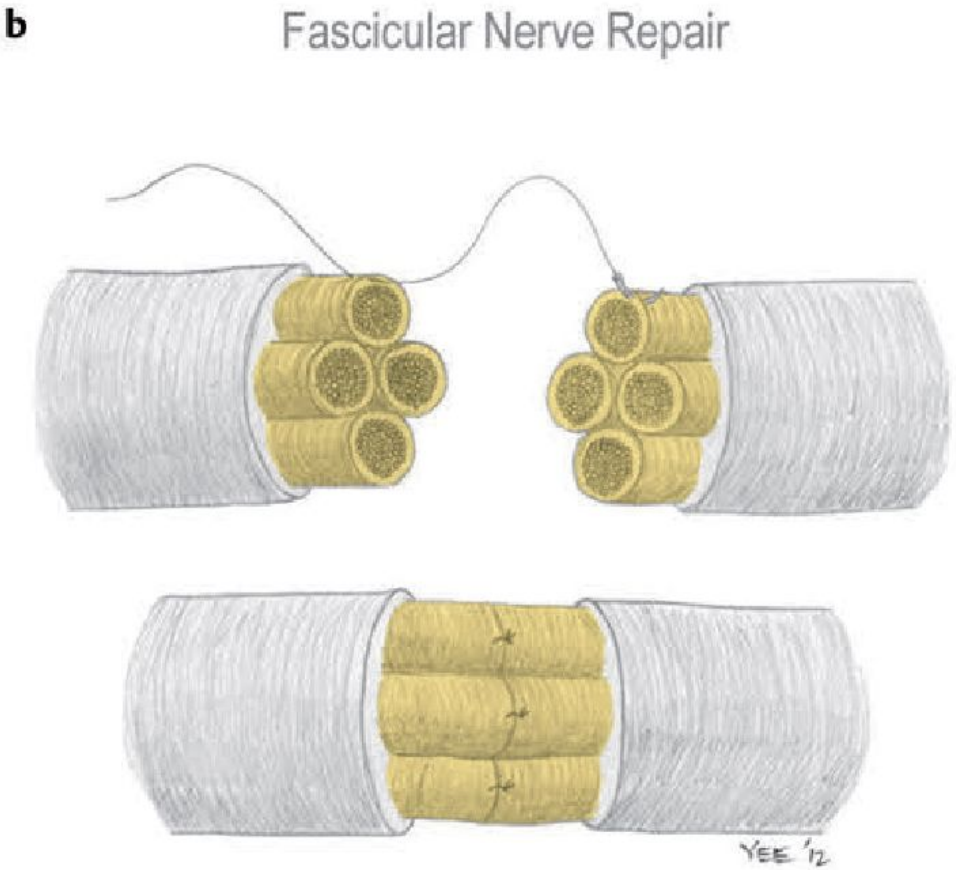


**Эпиневральный шов**

**Периневральный шов**

# Можно так

- **Эпиневральный**
- **Периневральный**
- **Эпипериневральный**
- **Межпучковый**
- **Внутрипучковый**

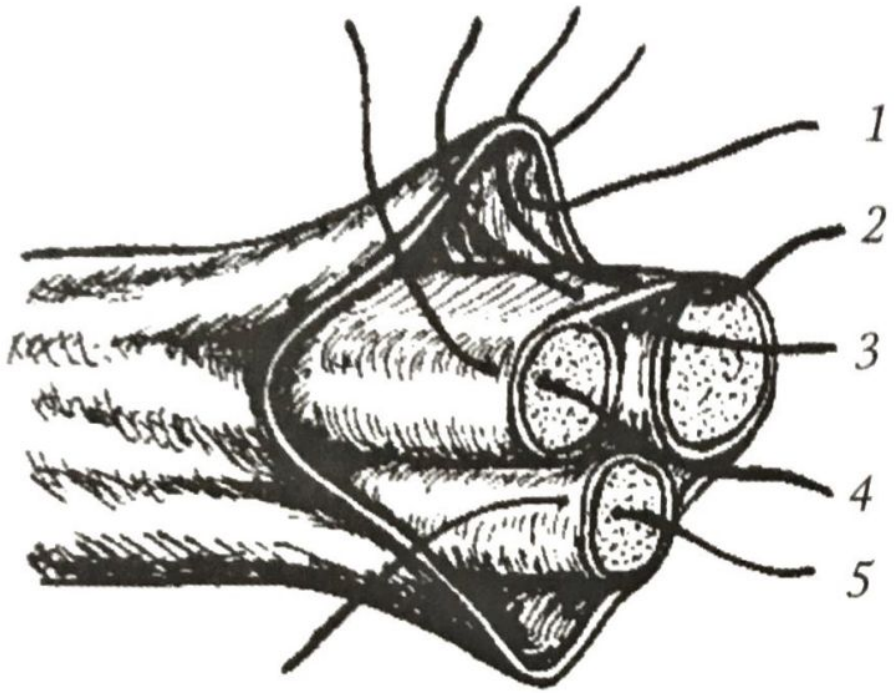


Рис. 58. Виды микрохирургических швов в зависимости от расположения шовной нити:

*1* – эпиневральный; *2* – эпипериневральный; *3* – межпучковый; *4* – периневральный; *5* – интраневральный (по: Белоусов А. Е., 1984)

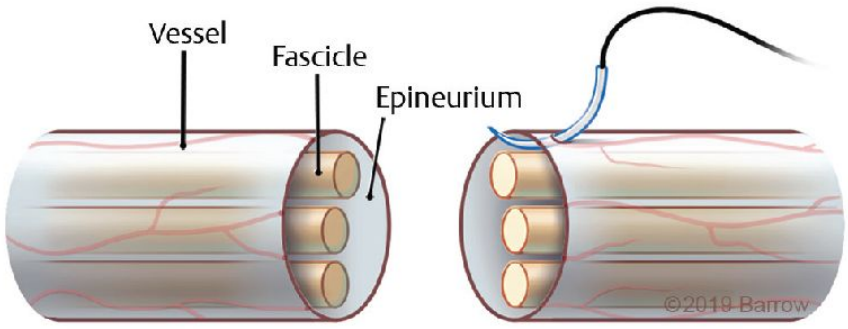
Vessel
Fascicle
Epineurium
©2019 Barrow

a

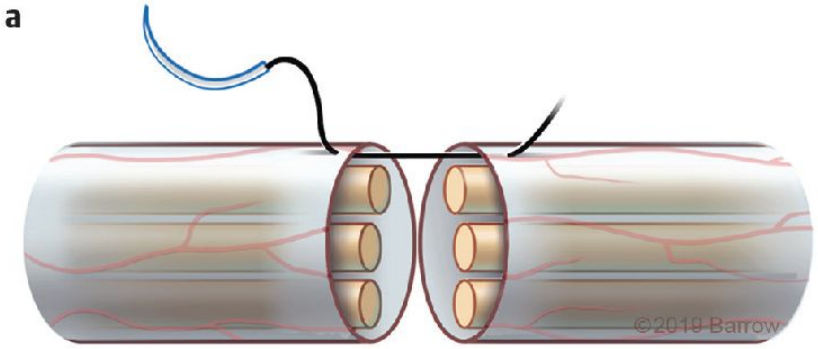
©2019 Barrow

b

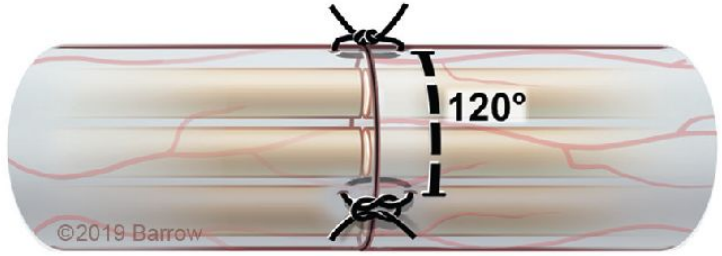
120°
©2019 Barrow

c

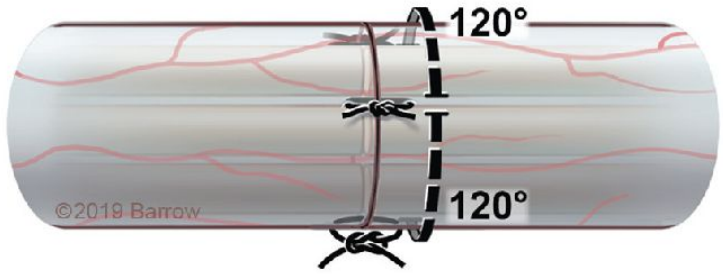
120°
120°
©2019 Barrow

d

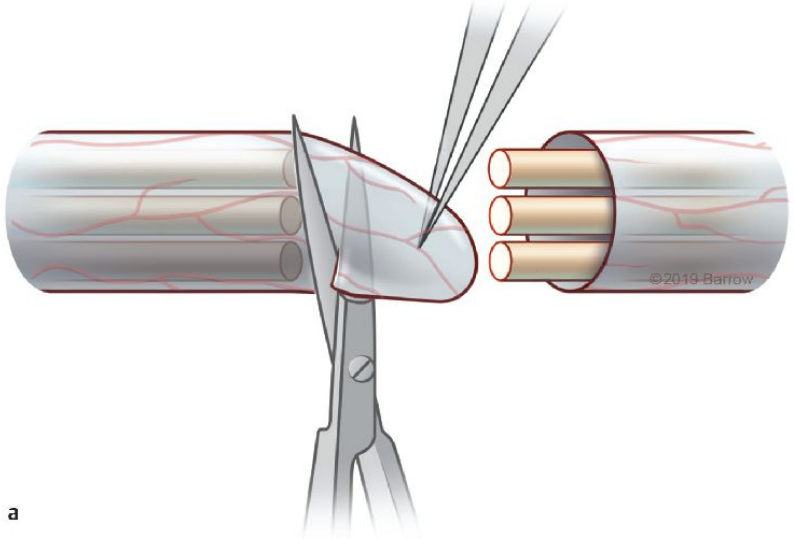
©2019 Barrow

a

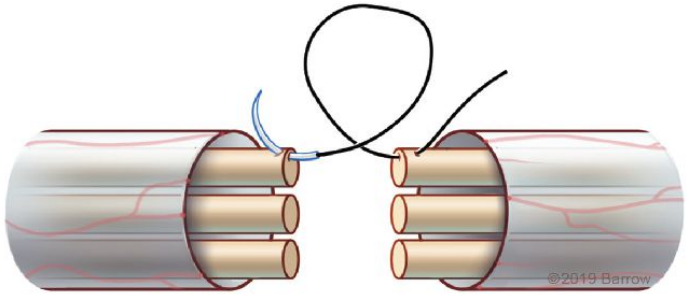
©2019 Barrow

b

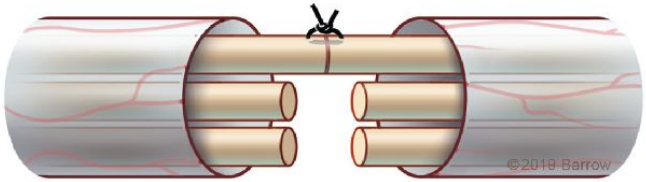
©2019 Barrow

c

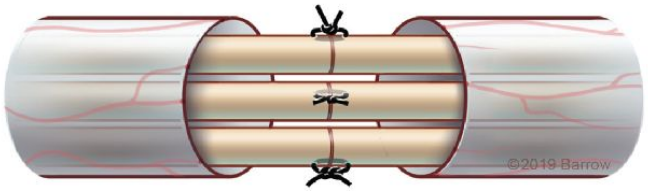
©2019 Barrow

d

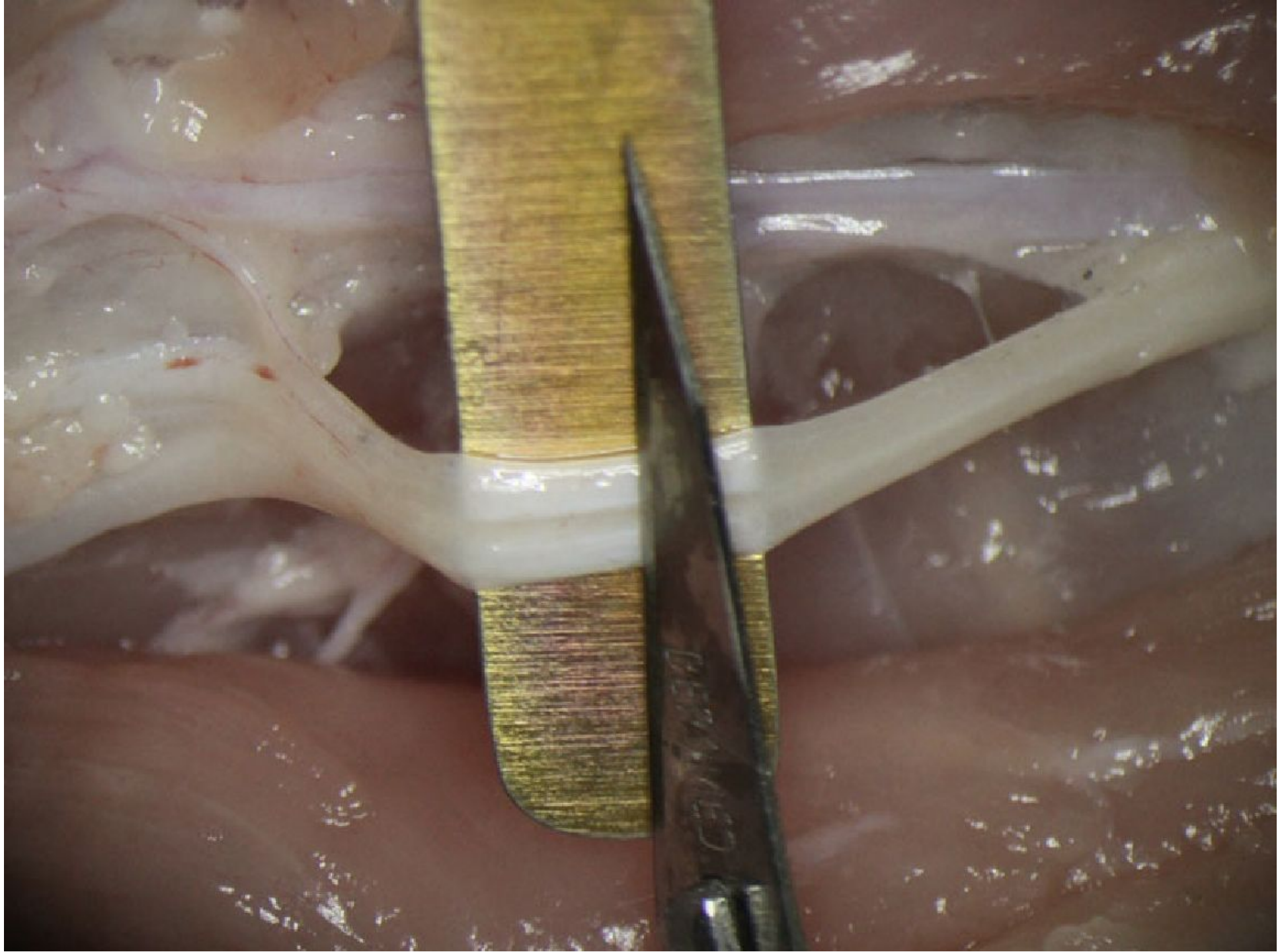

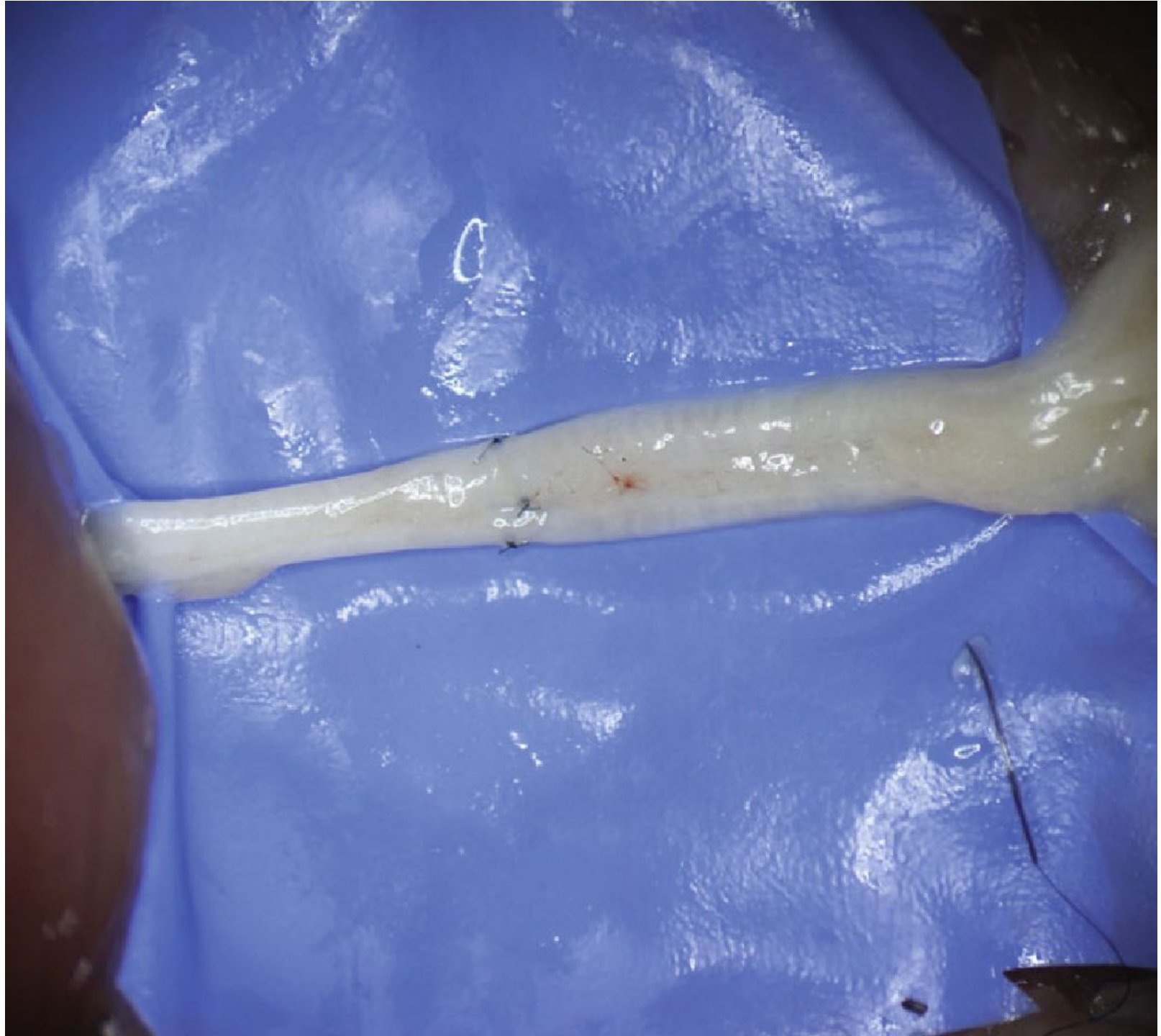

## Как избежать натяжения:

Хорошее выделение нерва (мобилизация)
Транспозиция нерва
Пластика нерва

# Strategies for Nerve Reconstruction

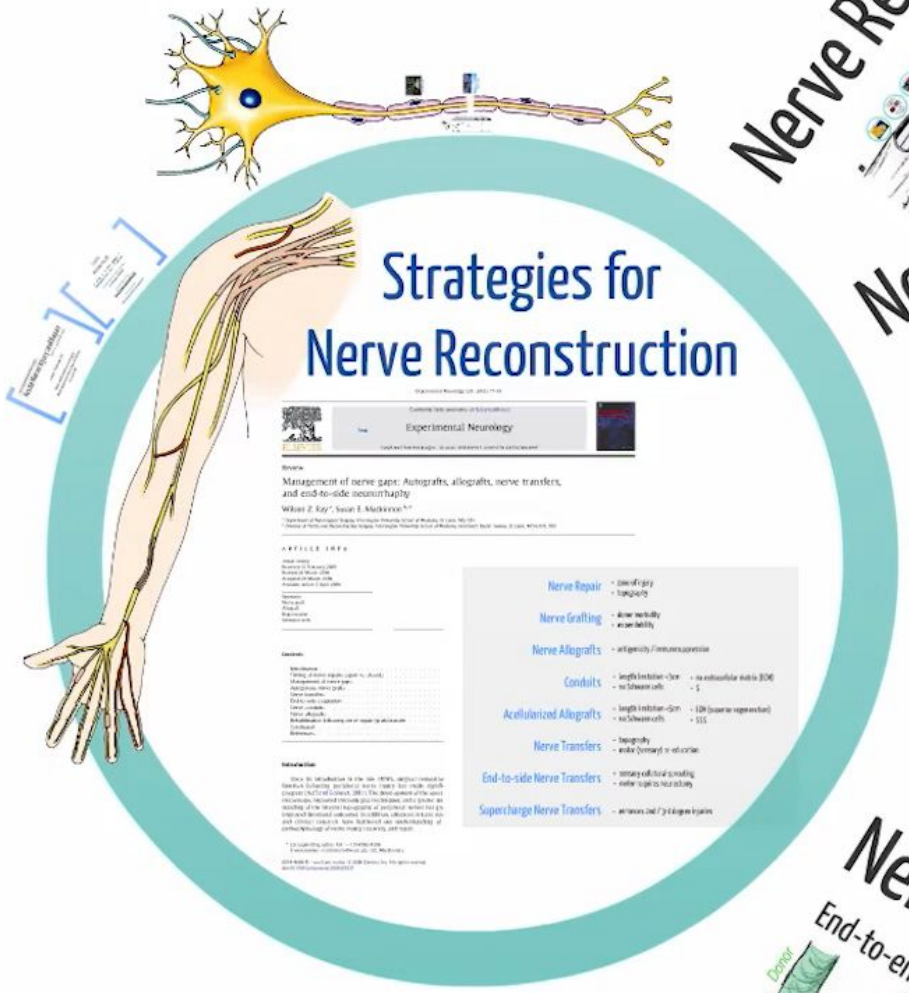


## Nerve Repair

## Nerve Grafting

## Nerve Allograft

## Conduit and Acellularized Allograft

Conduits < Allografts ≤ Grafts

## Nerve Transfers

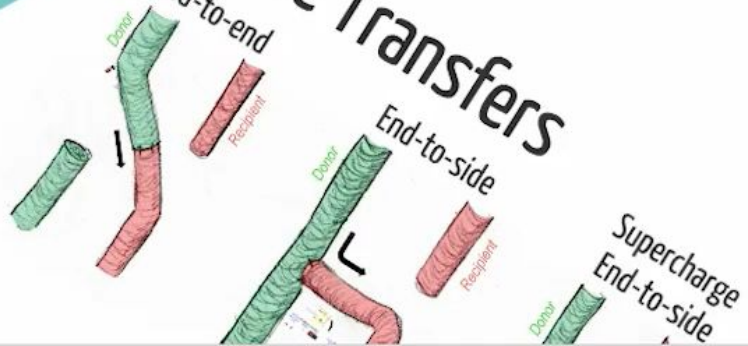

# Nerve Repair

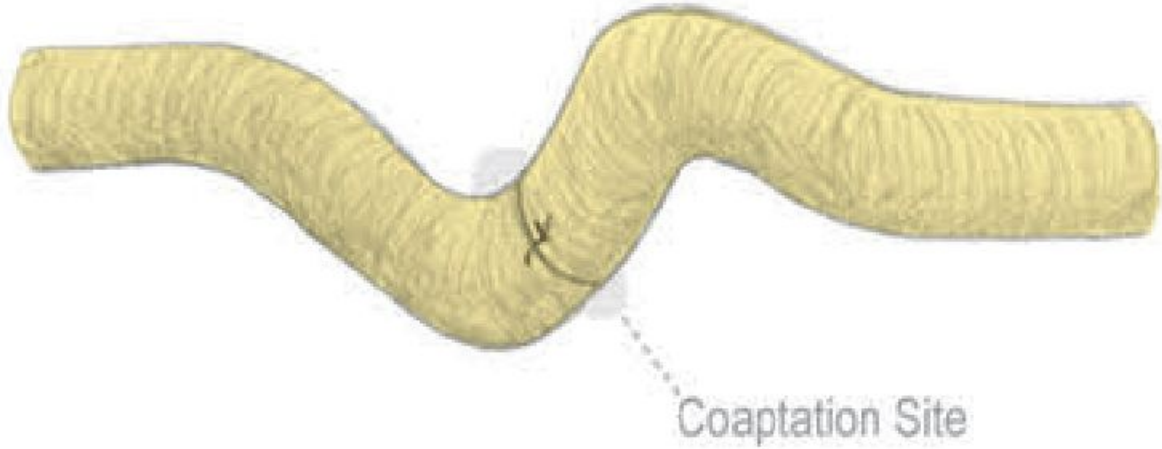


# Nerve Grafting

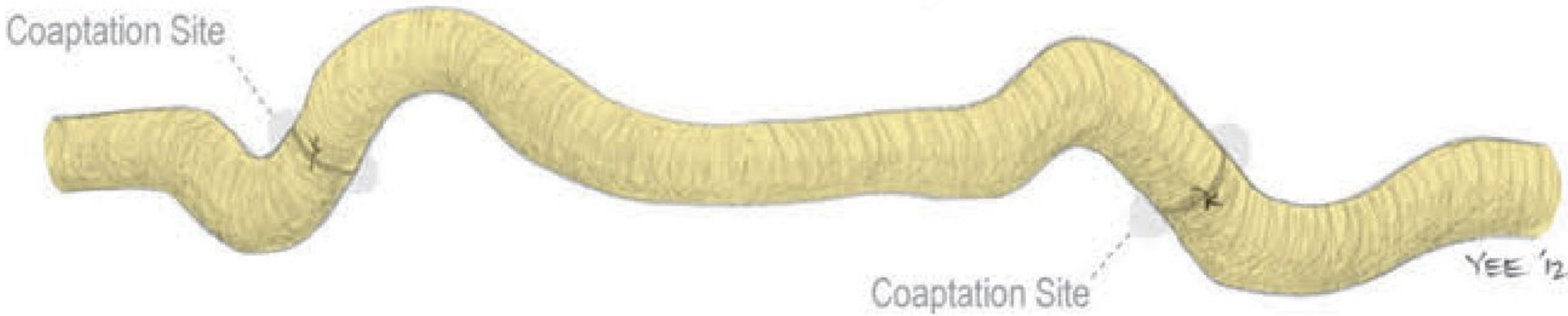

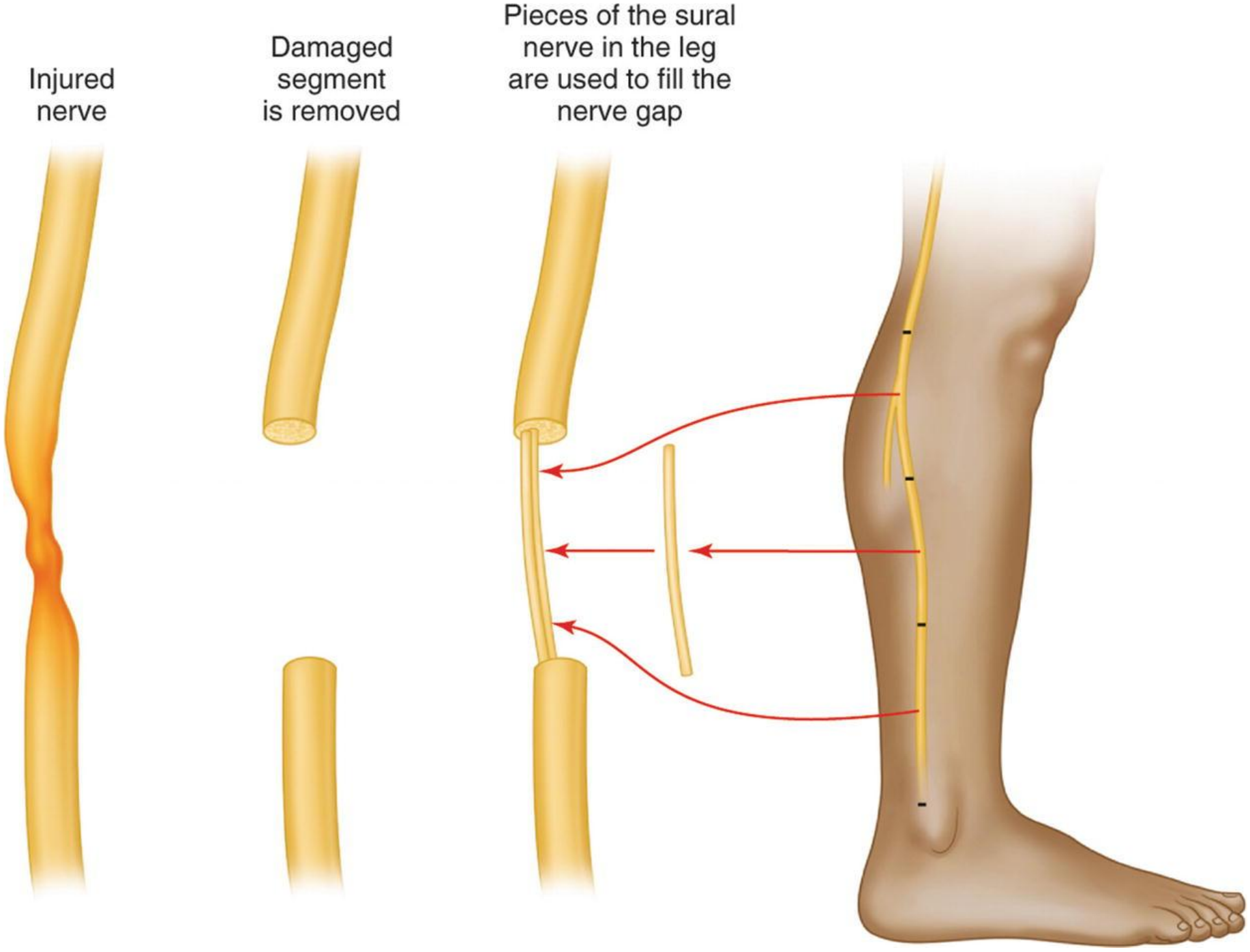
Injured nerve
Damaged segment is removed
Pieces of the sural nerve in the leg are used to fill the nerve gap

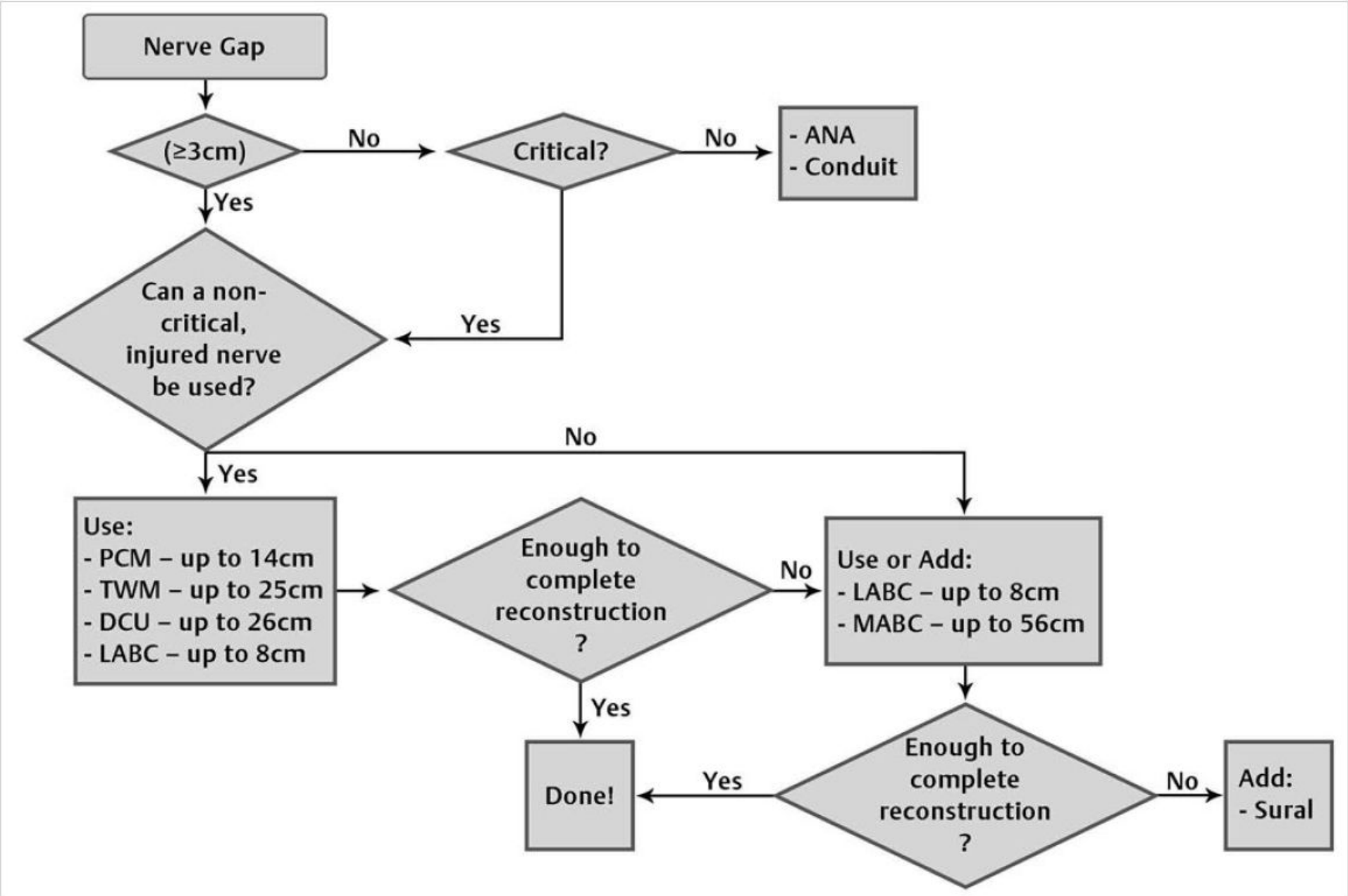


Fig. 4.14 Algorithm for sural alternatives. ANA, acellular nerve allograft; DCU, dorsal cutaneous branch of ulnar nerve; LABC, lateral antebrachial cutaneous nerve; MABC, medial antebrachial cutaneous nerve; PCM, palmar cutaneous branch of median nerve; TWM, Third webspace branch of median nerve.

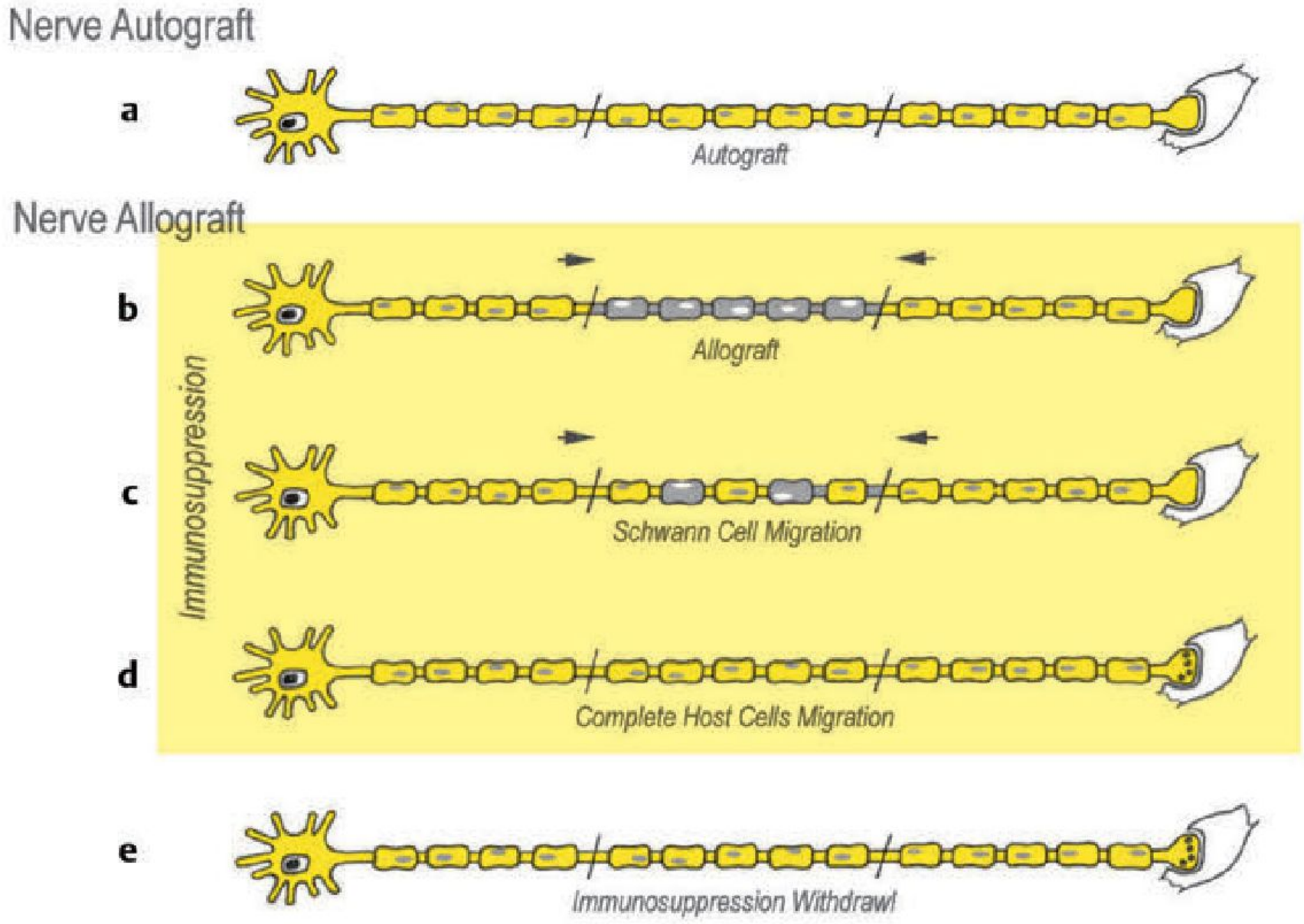
Nerve Autograft
a
Autograft
Nerve Allograft
b
Allograft
Immunosuppression
c
Schwann Cell Migration
d
Complete Host Cells Migration
e
Immunosuppression Withdrawl

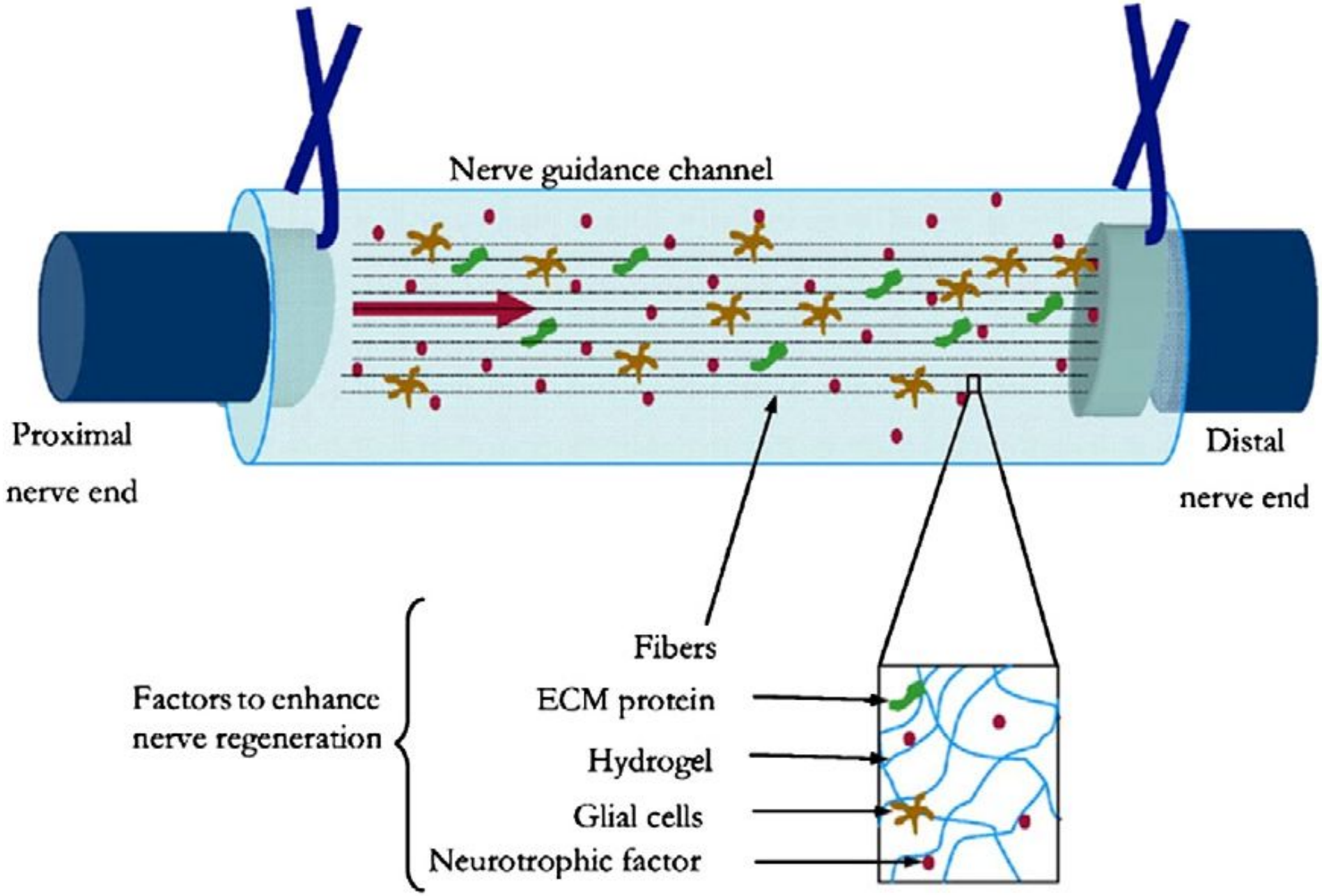
Nerve guidance channel
Proximal
nerve end
Distal
nerve end
Fibers
Factors to enhance
nerve regeneration
ECM protein
Hydrogel
Glial cells
Neurotrophic factor

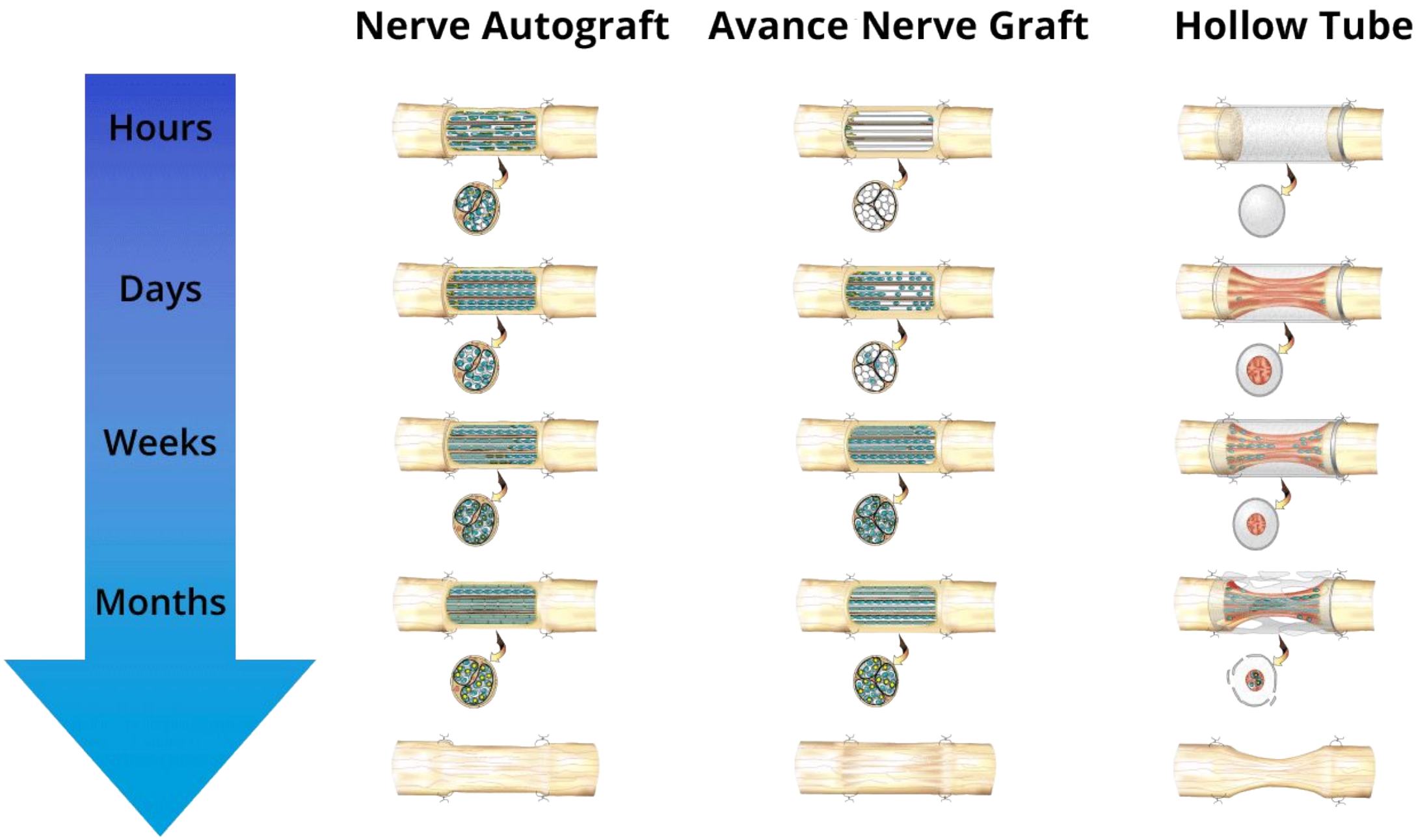
Nerve Autograft
Avance Nerve Graft
Hollow Tube
Hours
Days
Weeks
Months

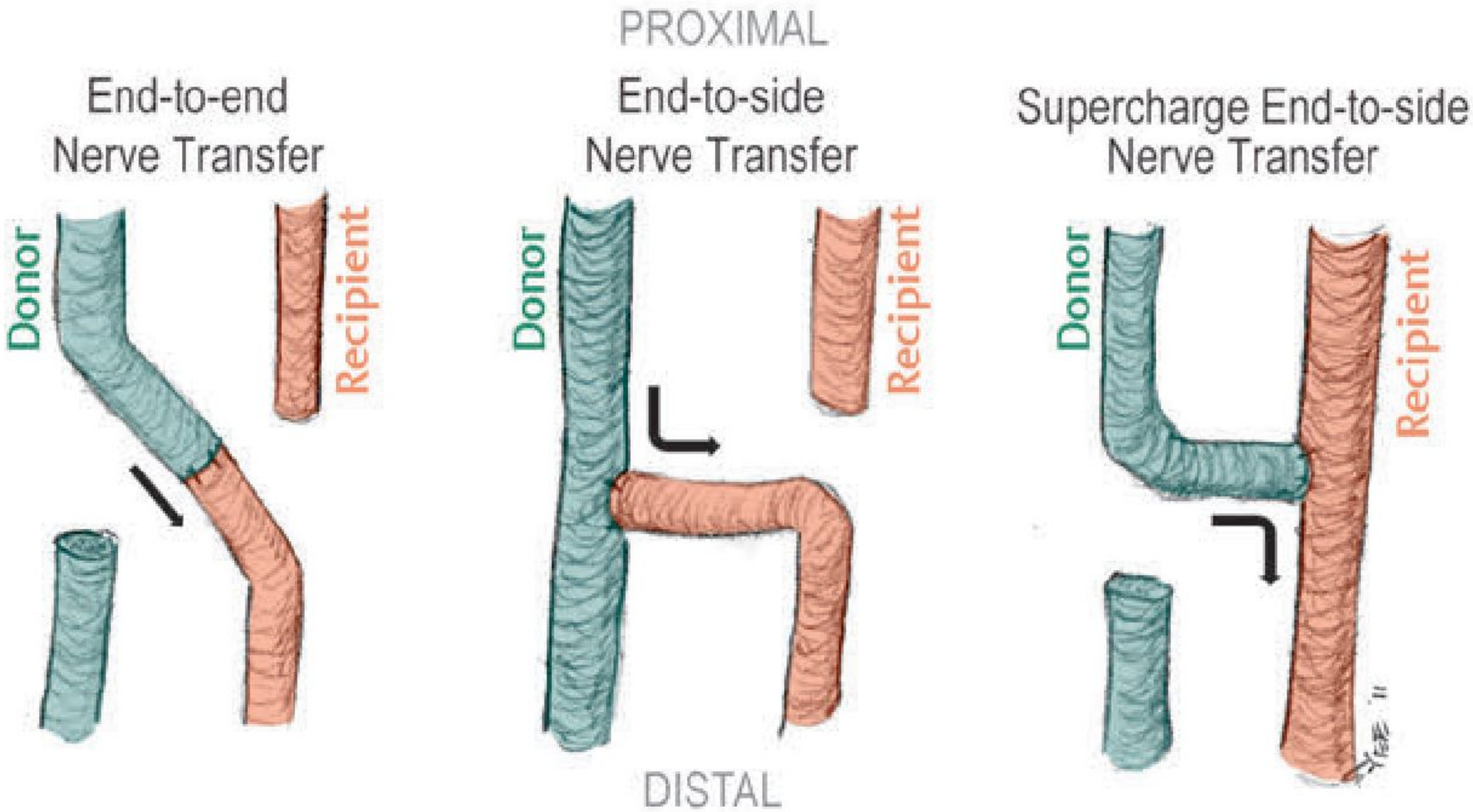
PROXIMAL
End-to-end
Nerve Transfer
Donor
Recipient
End-to-side
Nerve Transfer
Donor
Recipient
DISTAL
Supercharge End-to-side
Nerve Transfer
Donor
Recipient

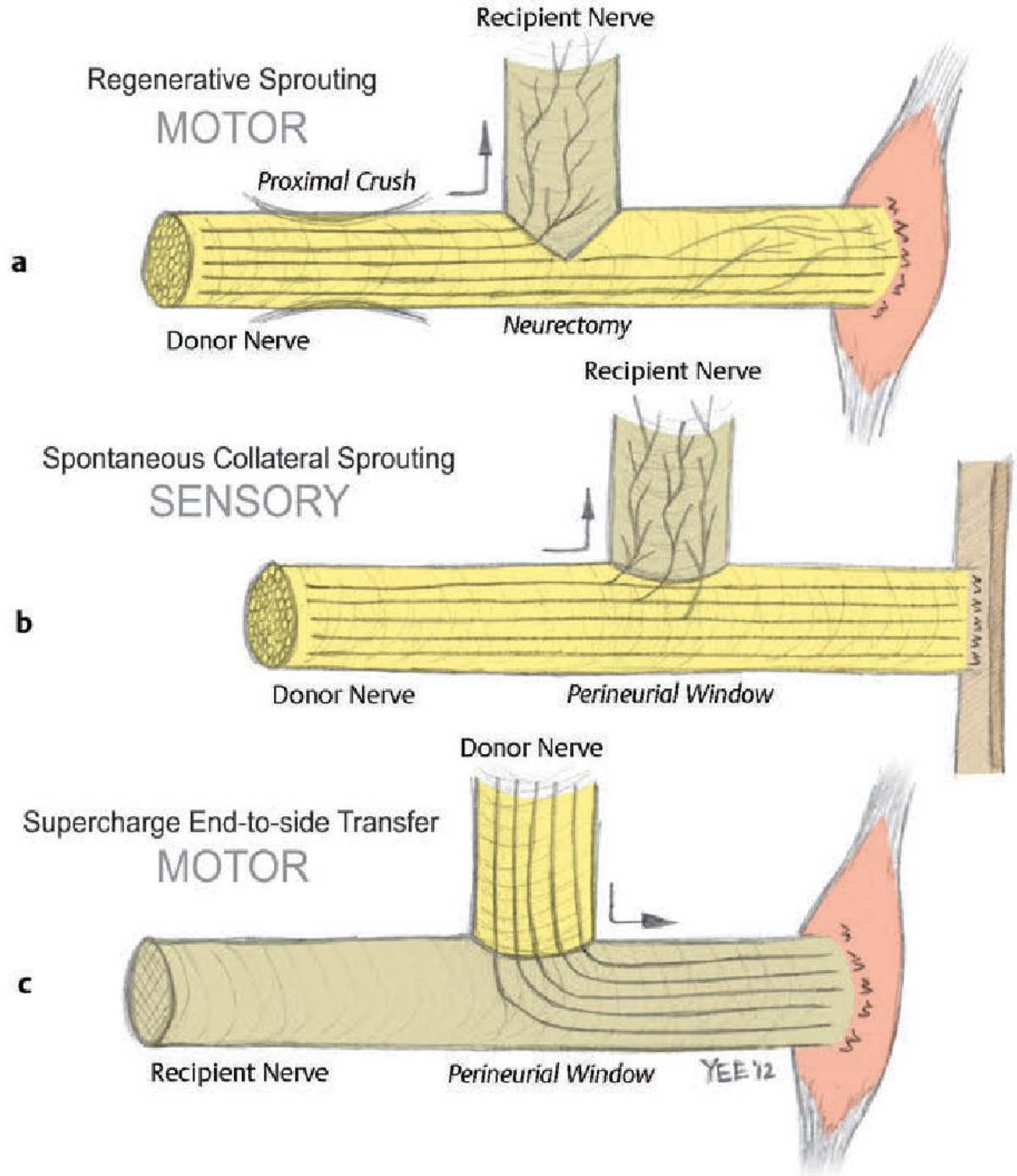
Recipient Nerve
Regenerative Sprouting
MOTOR
Proximal Crush
a
Donor Nerve
Neurectomy
Recipient Nerve
Spontaneous Collateral Sprouting
SENSORY
b
Donor Nerve
Perineurial Window
Donor Nerve
Supercharge End-to-side Transfer
MOTOR
c
Recipient Nerve
Perineurial Window
YEE '12

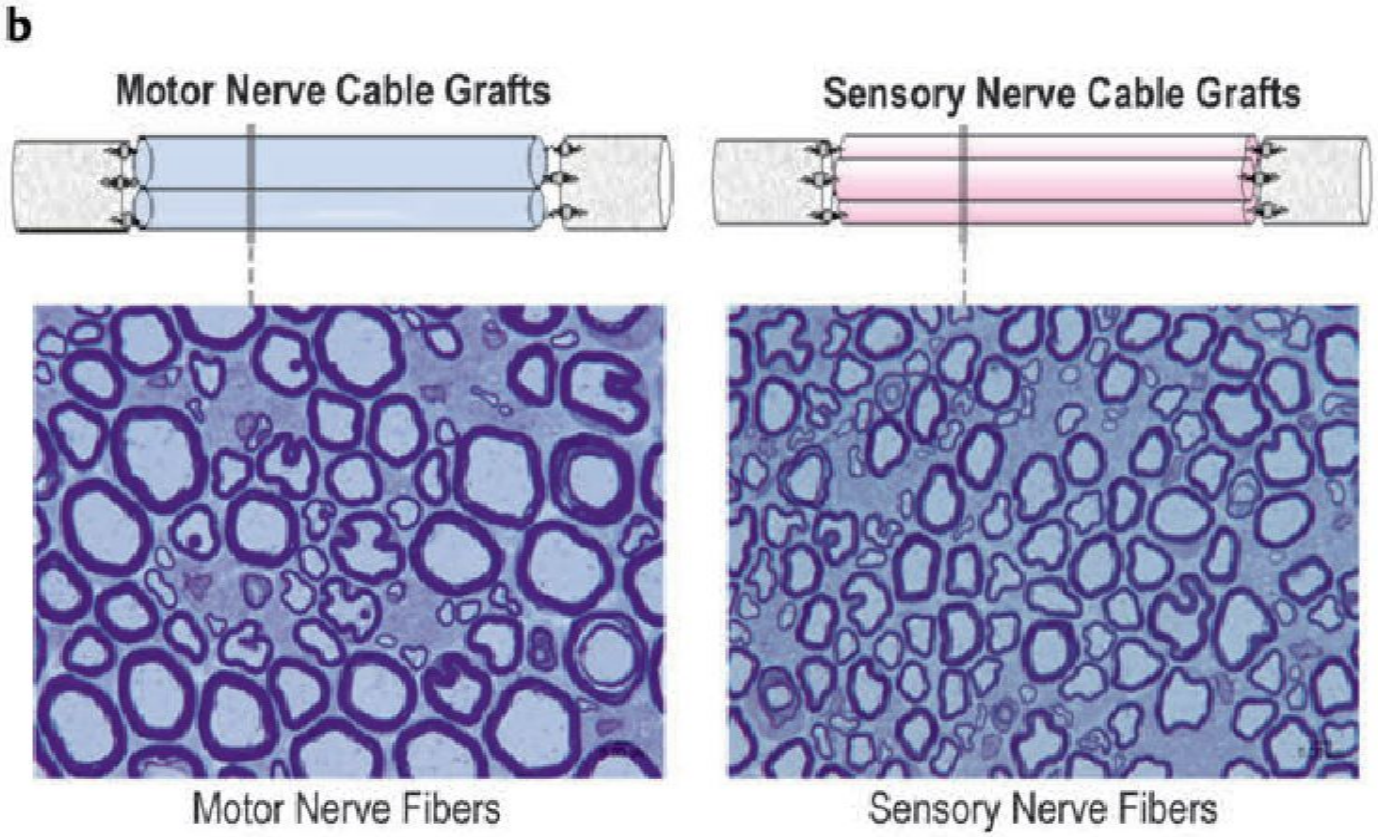
b
Motor Nerve Cable Grafts
Sensory Nerve Cable Grafts
Motor Nerve Fibers
Sensory Nerve Fibers

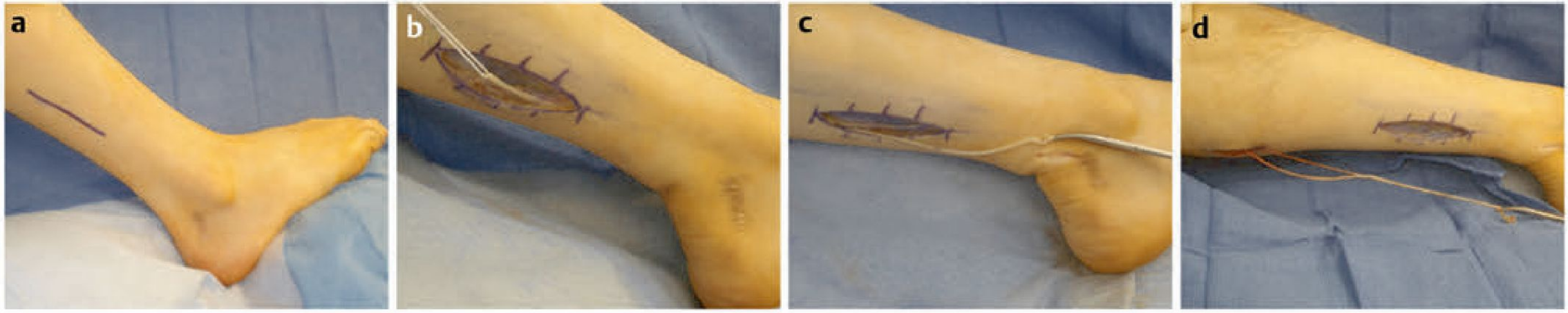
a
b
c
d

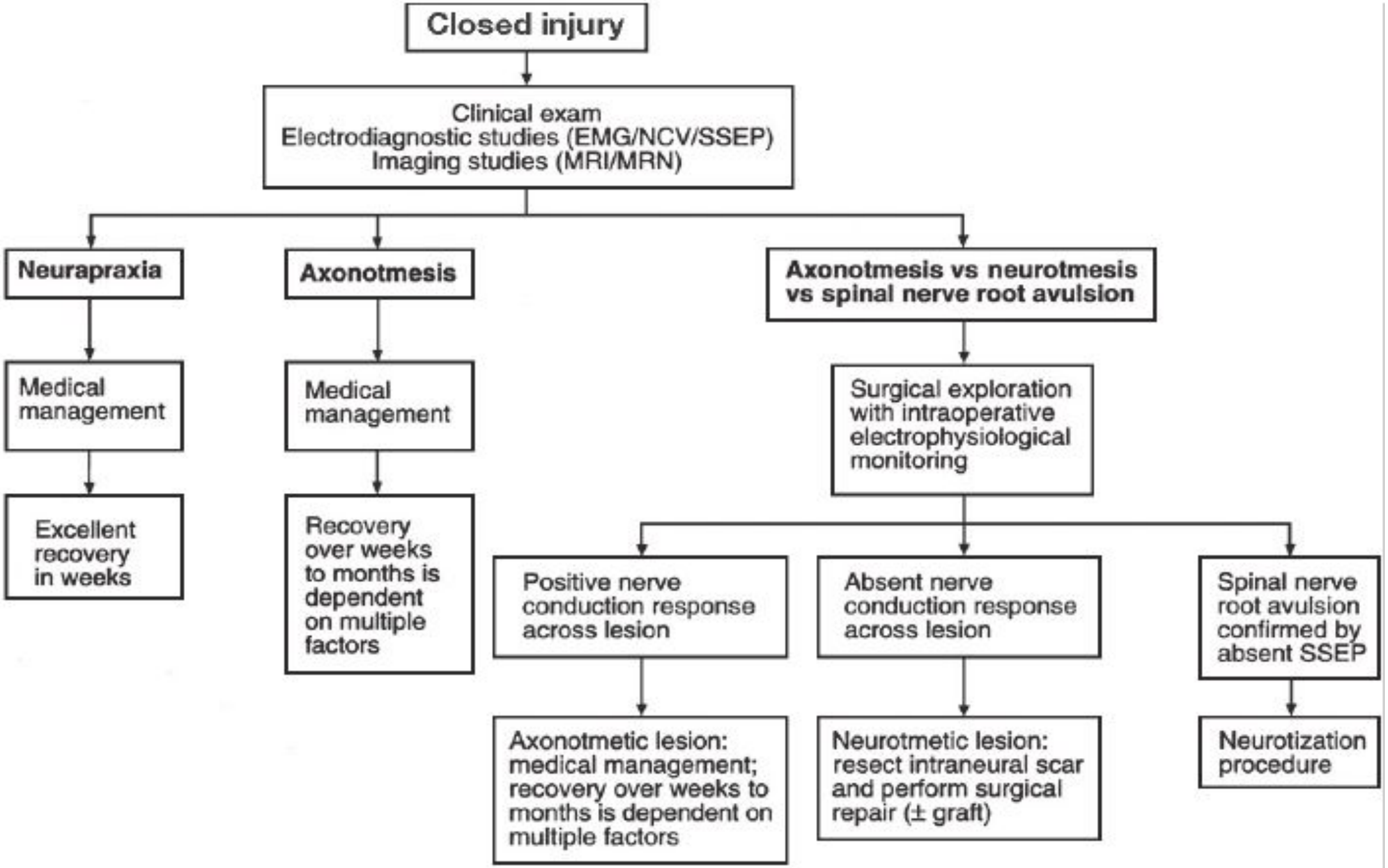
Closed injury
Clinical exam
Electrodiagnostic studies (EMG/NCV/SSEP)
Imaging studies (MRI/MRN)
Neurapraxia
Axonotmesis
Axonotmesis vs neurotmesis vs spinal nerve root avulsion
Medical management
Medical management
Surgical exploration with intraoperative electrophysiological monitoring
Excellent recovery in weeks
Recovery over weeks to months is dependent on multiple factors
Positive nerve conduction response across lesion
Absent nerve conduction response across lesion
Spinal nerve root avulsion confirmed by absent SSEP
Axonotmetic lesion: medical management; recovery over weeks to months is dependent on multiple factors
Neurotmetic lesion: resect intraneural scar and perform surgical repair (± graft)
Neurotization procedure

| Тип опухоли |
| --- |
| I. Нейрогенные опухоли<br>А. Доброкачественные опухоли оболочки нерва<br>Шваннома (невринома), в одном случае при Б.Р. (Болезнь Реклингаузера).<br>Нейрофиброма (в одном при Б.Р.).<br>Б. Злокачественные опухоли оболочки нерва<br>злокачественная шваннома<br>фибросаркома<br>нейрофиброссаркома |
| II. Опухоль из периферического нейрона<br>Ганглионеврома<br>Нейробластома |
| III. Опухоли не из оболочки нерва (доброкачественные)<br>фиброма<br>хондромиксоидная фиброма<br>фибролипома<br>фибромиолипома<br>хемодектома<br>В эту группу также входят десмоидная опухоль, миобластома, лимфангиома, гемангиома и сосудистые опухоли. |
| IV. Метастазы в периферические нервы<br>Лучевой фиброз после хирургического и лучевого лечения<br>рака молочной железы<br>Лимфома Карцинома |

# Опухоли ПНС

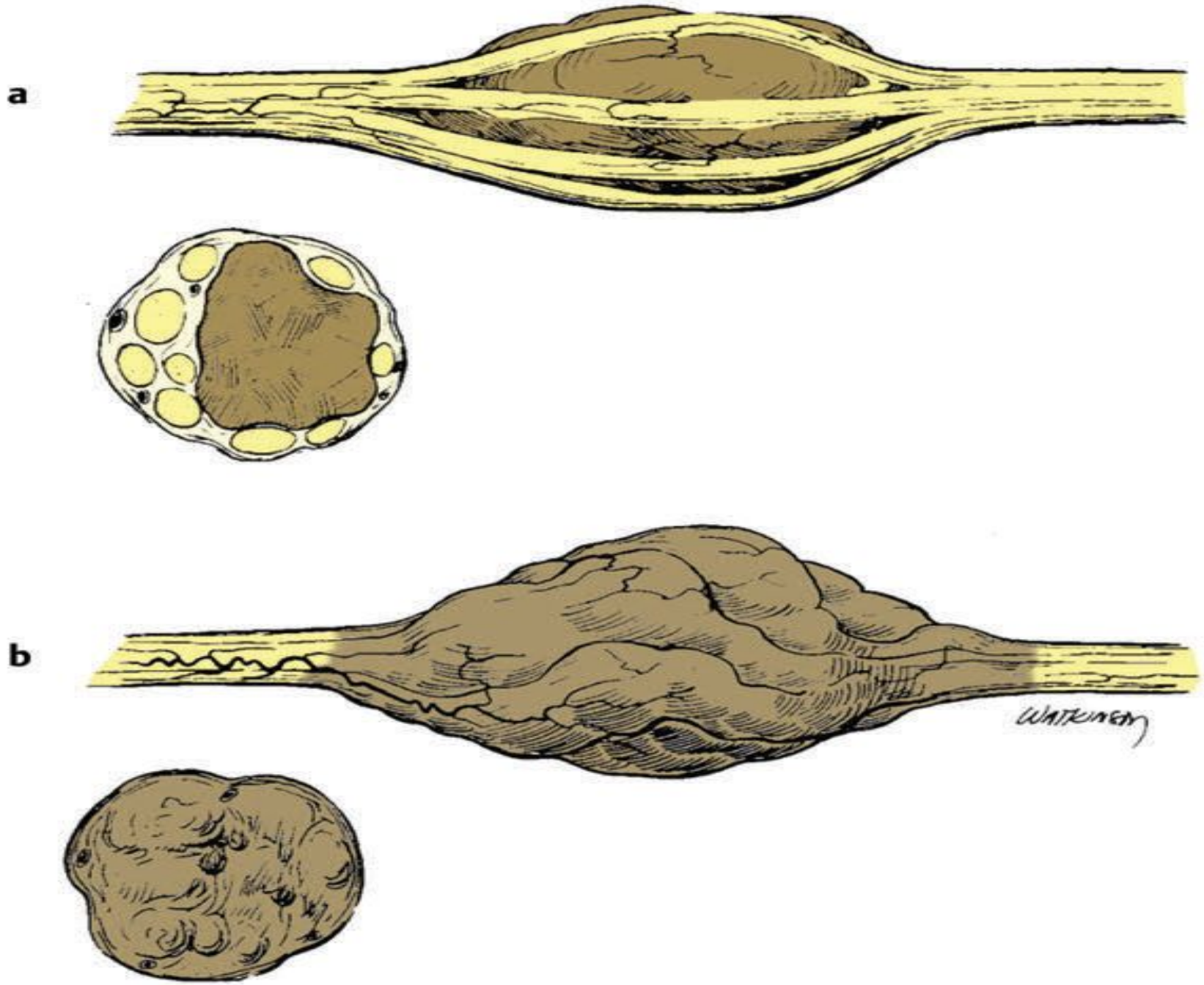
a
b

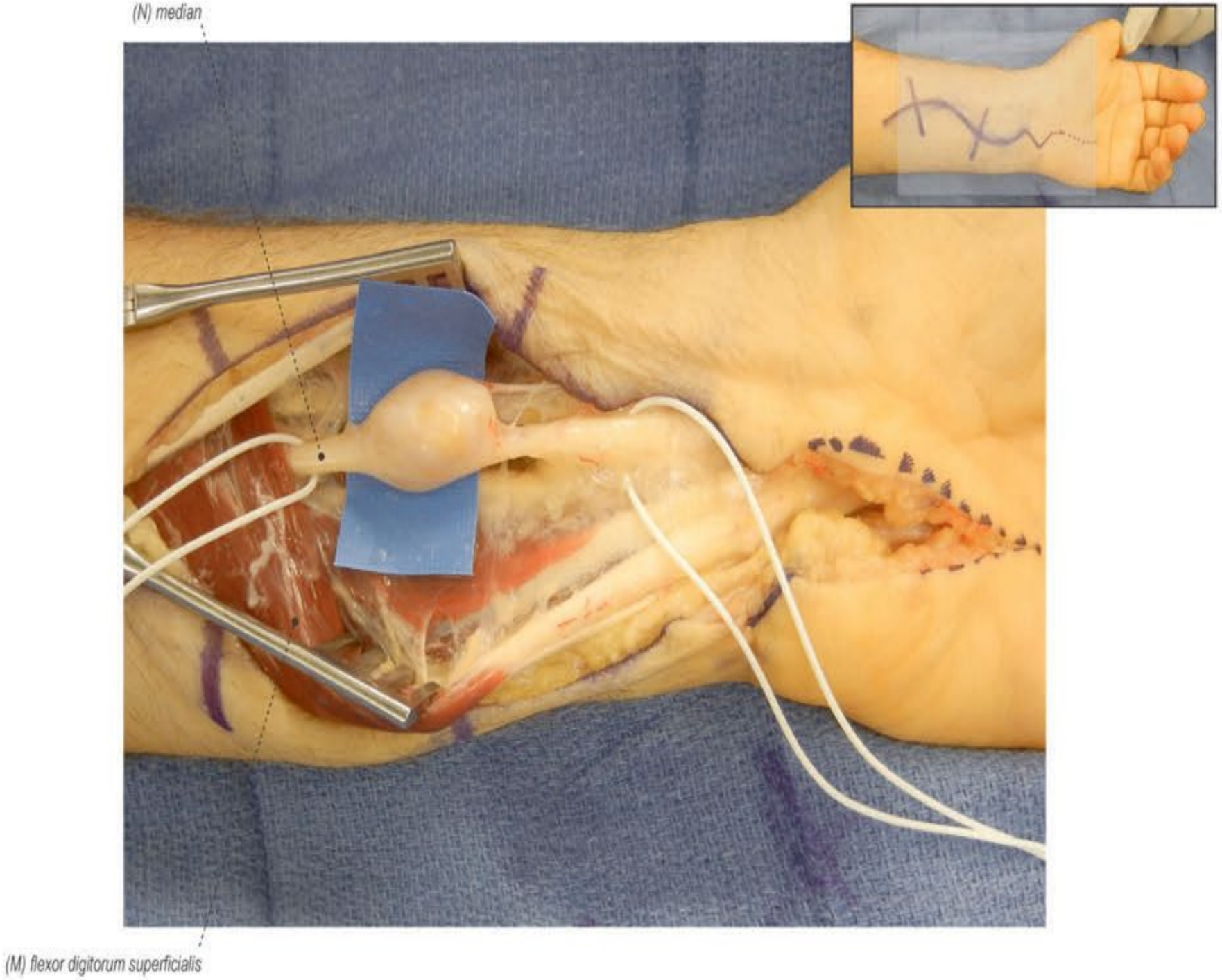
(N) median
(M) flexor digitorum superficialis

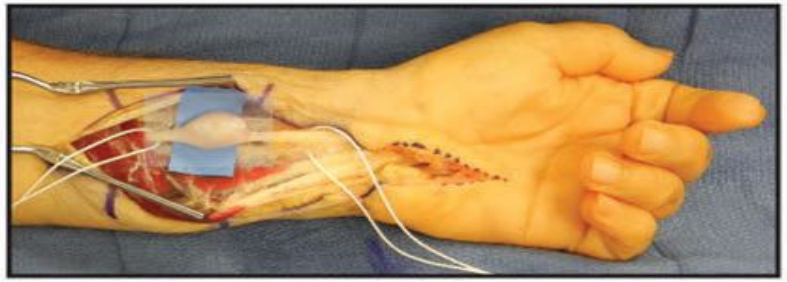

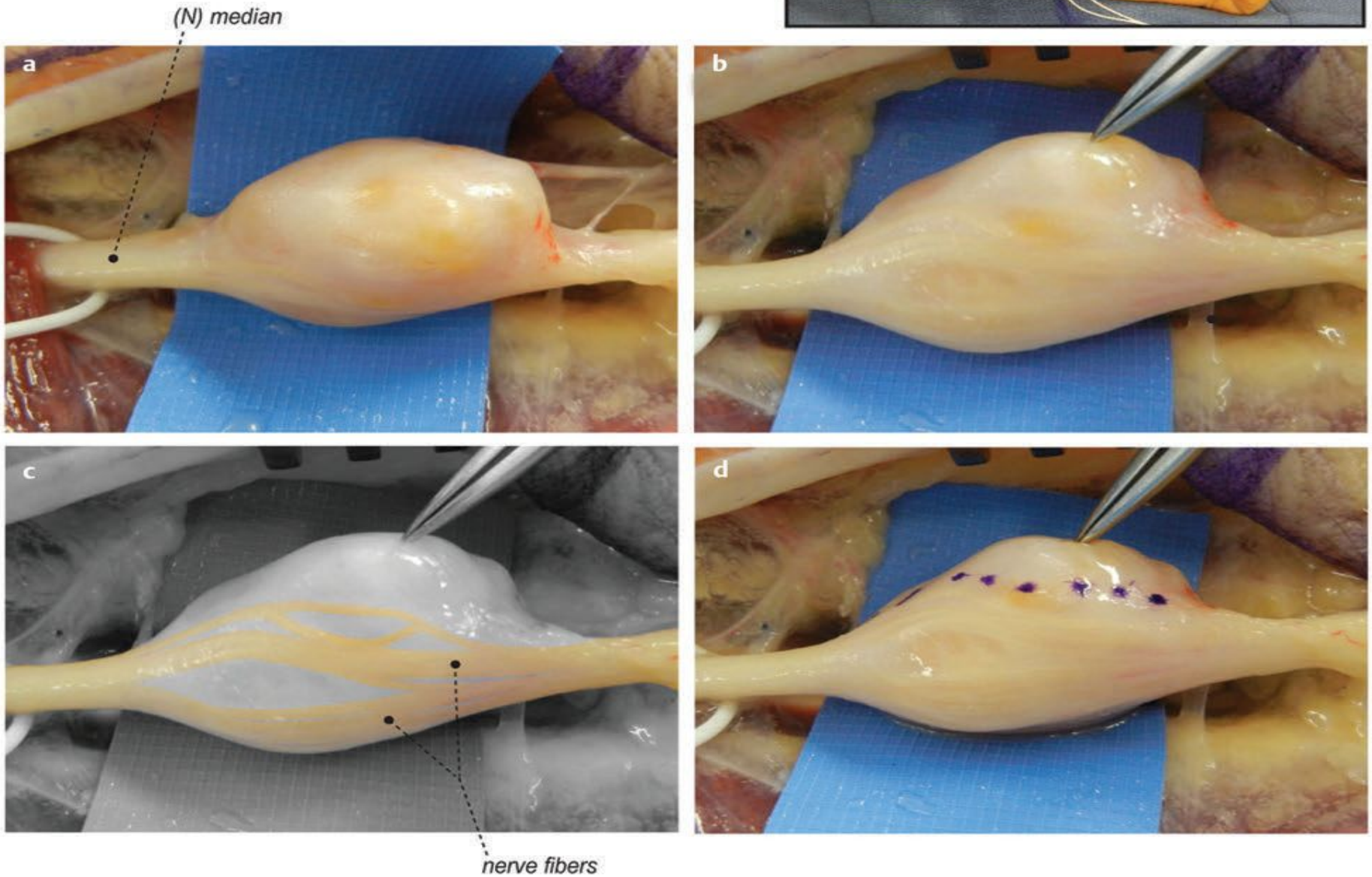
(N) median
a
b
c
d
nerve fibers

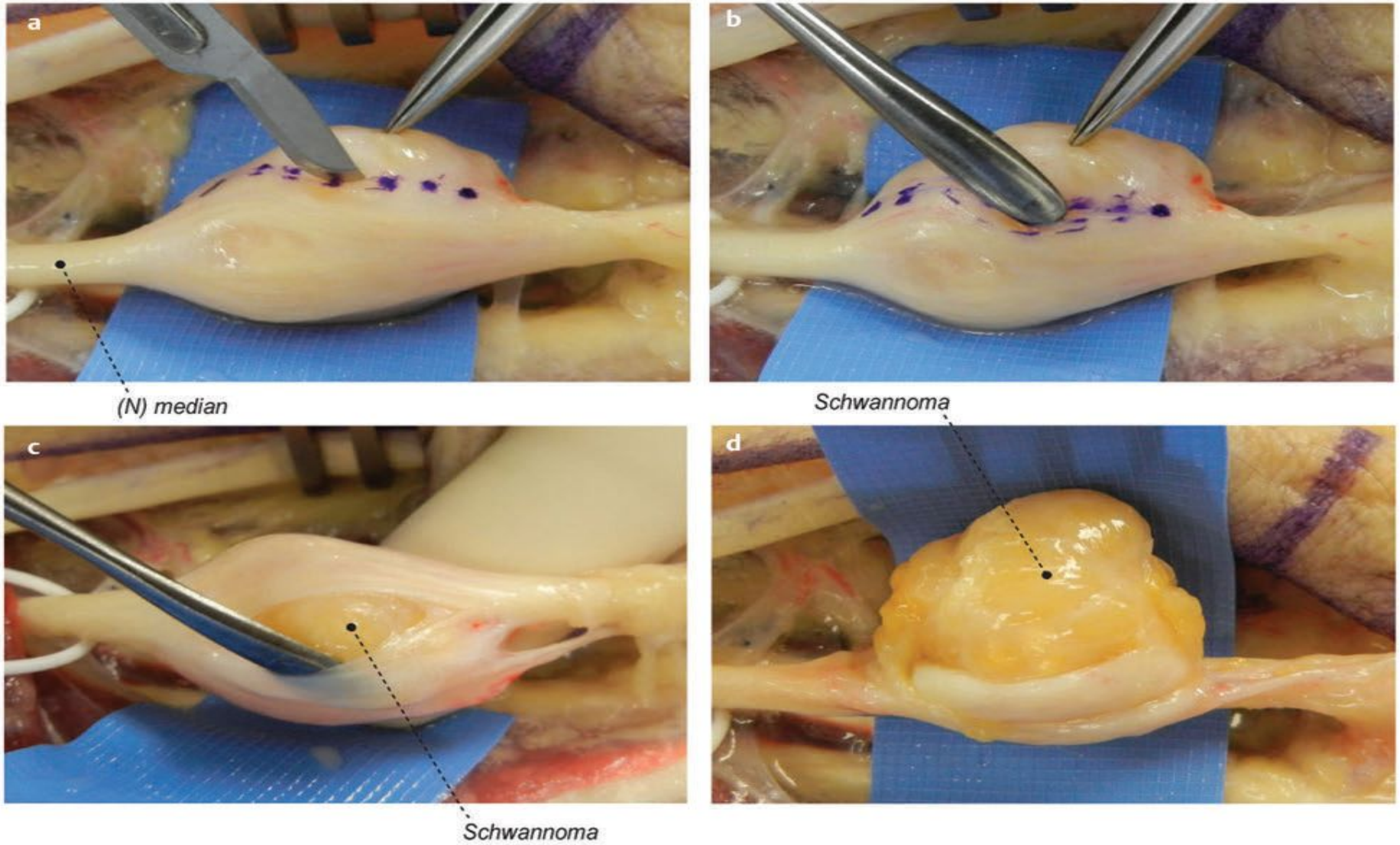
a
(N) median
b
Schwannoma
c
Schwannoma
d

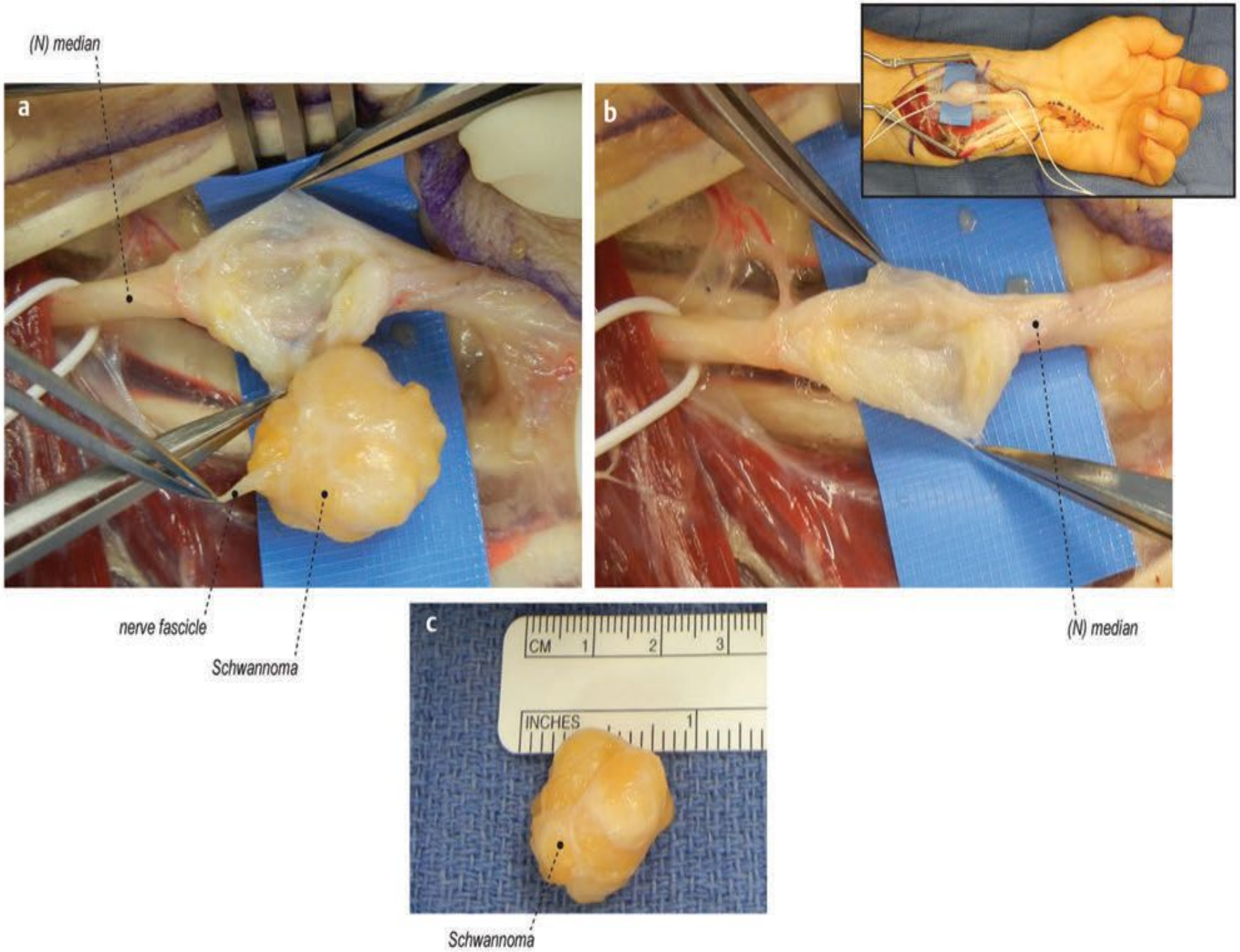
(N) median
a
b
nerve fascicle
Schwannoma
(N) median
c
CM 1 2 3
INCHES 1
Schwannoma

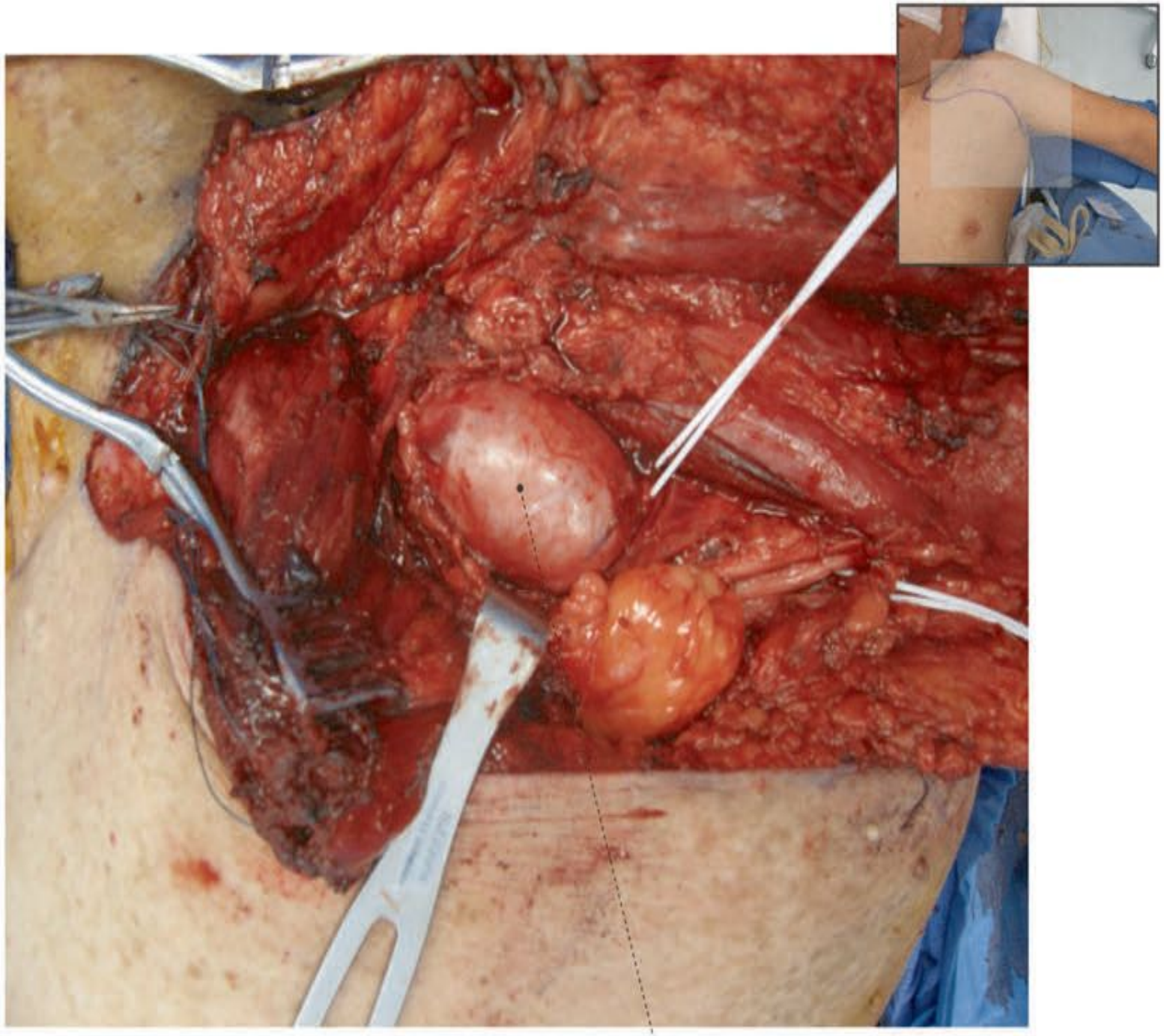
benign neurofibroma

# Спасибо за внимание!