Функциональная анатомия головного мозга.

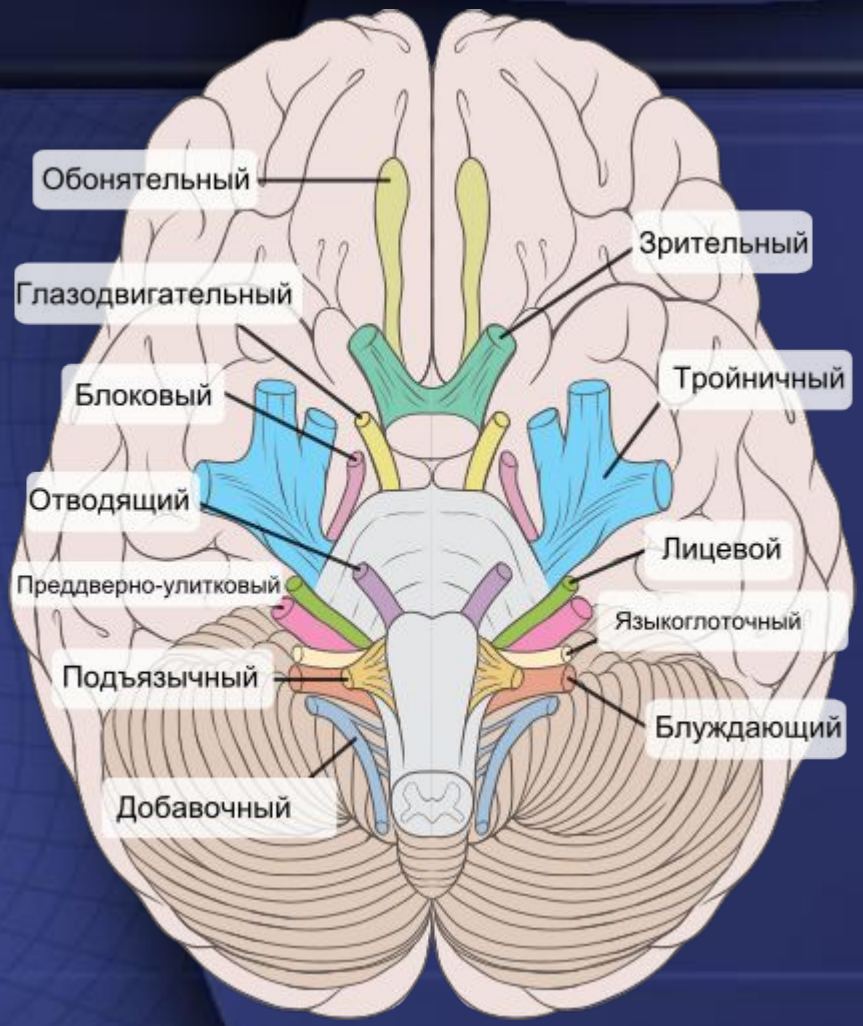
Обонятельный
Зрительный
Глазодвигательный
Блоковый
Тройничный
Отводящий
Лицевой
Преддверно-улитковый
Языкоглоточный
Подъязычный
Блуждающий
Добавочный

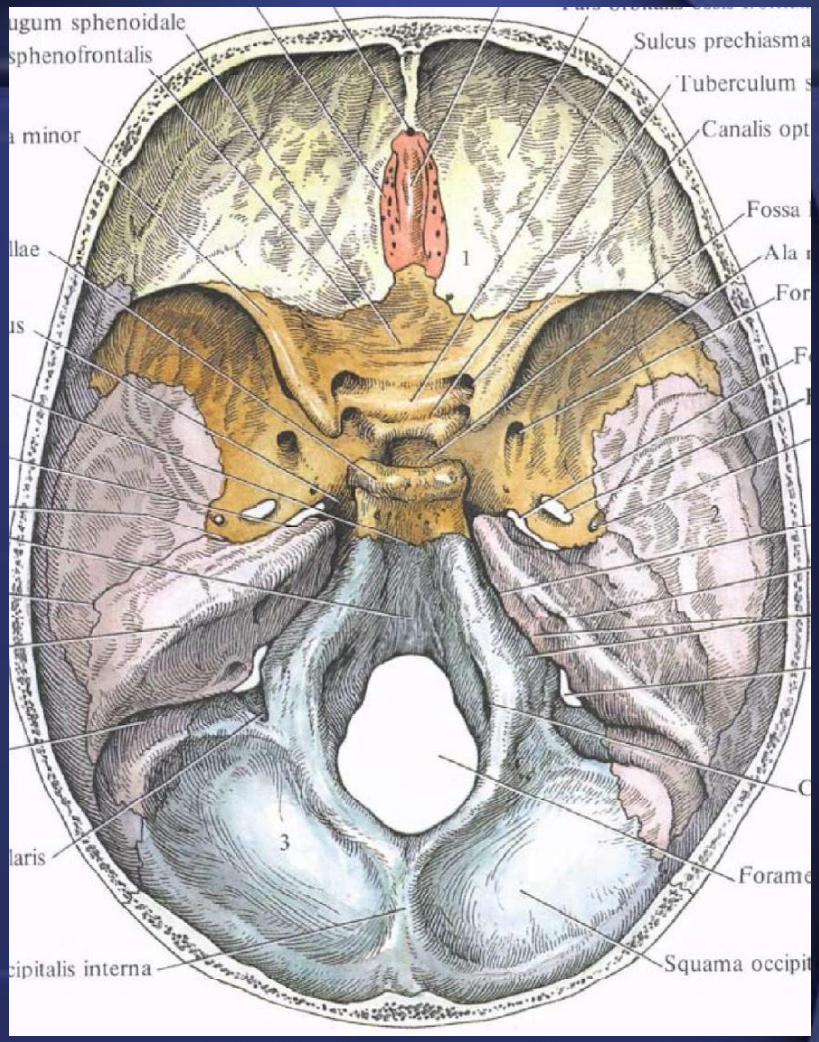
ugum sphenoidale
sphenofrontalis
Sulcus prechiasma
Tuberculum s
a minor
Canalis opt
Fossa
llae
Ala
For
us
1
2
3
laris
Forame
cipitalis interna
Squama occipit

Головной мозг эмбриона человека на стадиях трех (А) и пяти (Б) мозговых пузырей.

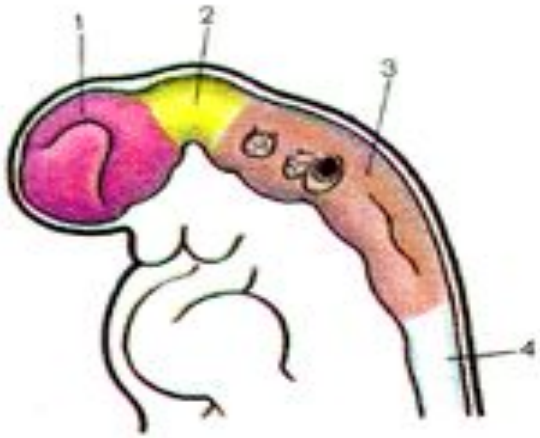

А

А — 3 1/2 нед:
1 — prosencephalon;
2 — mesencephalon;
3 — rhombencephalon;
4 — medulla spinalis.

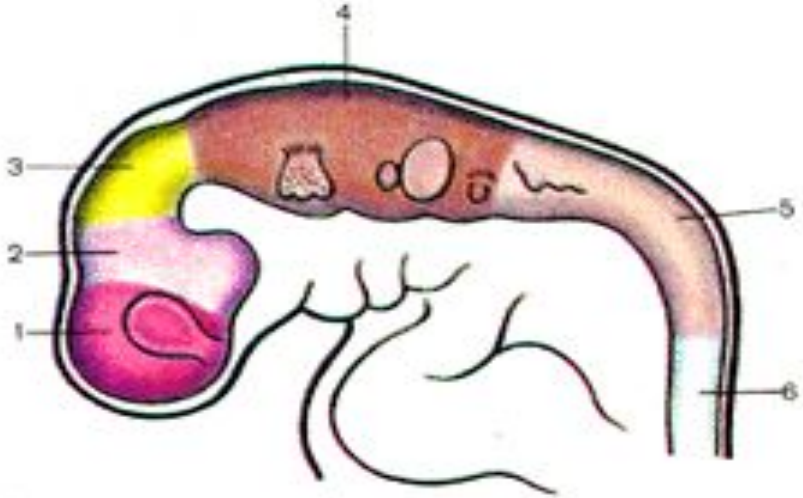

Б

Б — 4 нед:
1 — telencephalon;
2 — diencephalon;
3 — mesencephalon;
4 — metencephalon;
5 — myelencephalon;
6— medulla spinalis.

Головной мозг эмбриона человека, 8 нед.

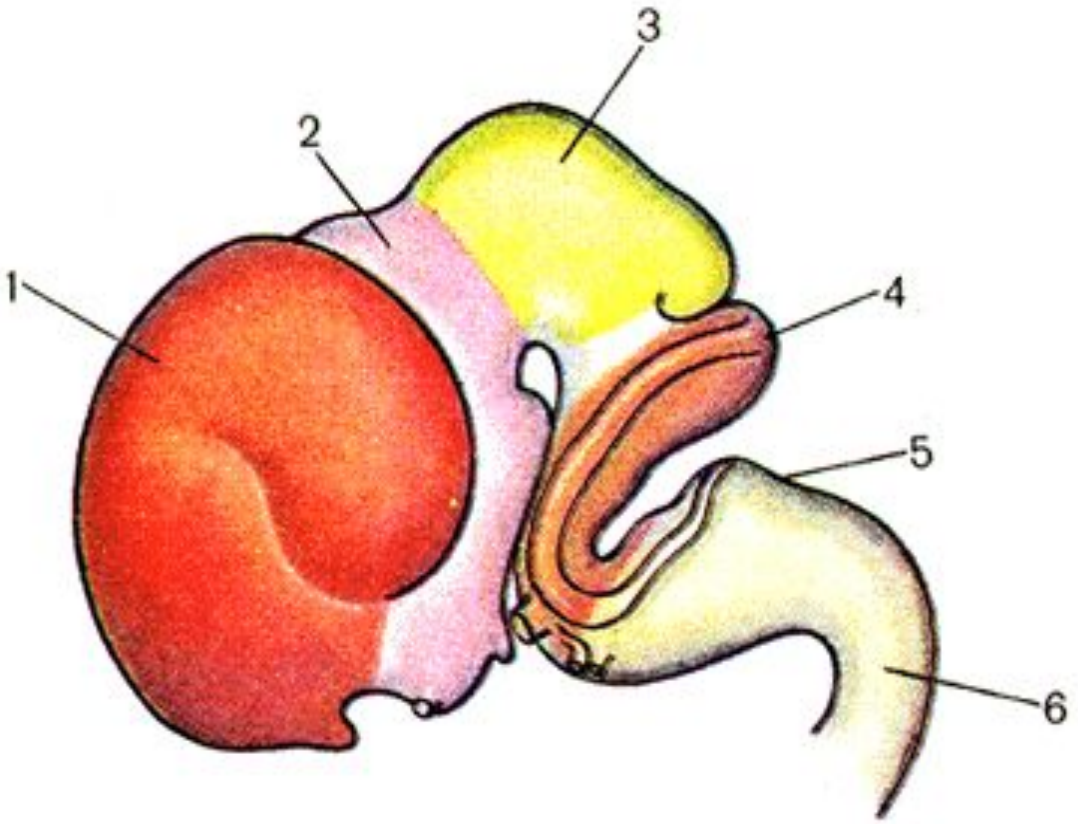

1 – telencephalon;
2 – diencephalon;
3 – mesencephalon;
4 – metencephalon;
5 – myelencephalon;
6 – medulla spinalis.

Стадия трех мозговых пузырей	Стадия пяти мозговых пузырей	Полость мозгового пузыря
Ромбовидный мозг	1. Продолговатый мозг 2. Задний мозг: Мост; мозжечок, перешеек ромбовидного мозга	Четвертый желудочек
Средний мозг	3. Средний мозг: пластинка крыши (четверохолмие), ножки мозга	Водопровод мозга (Сильвиев)
Передний мозг	4. Промежуточный мозг : таламический мозг; эпиталамус, гипоталамус, метаталамус 5. Конечный мозг: полушария мозга; базальные ядра, обонятельный мозг, мозолистое тело, свод	Третий желудочек Боковые желудочки (левый – первый)

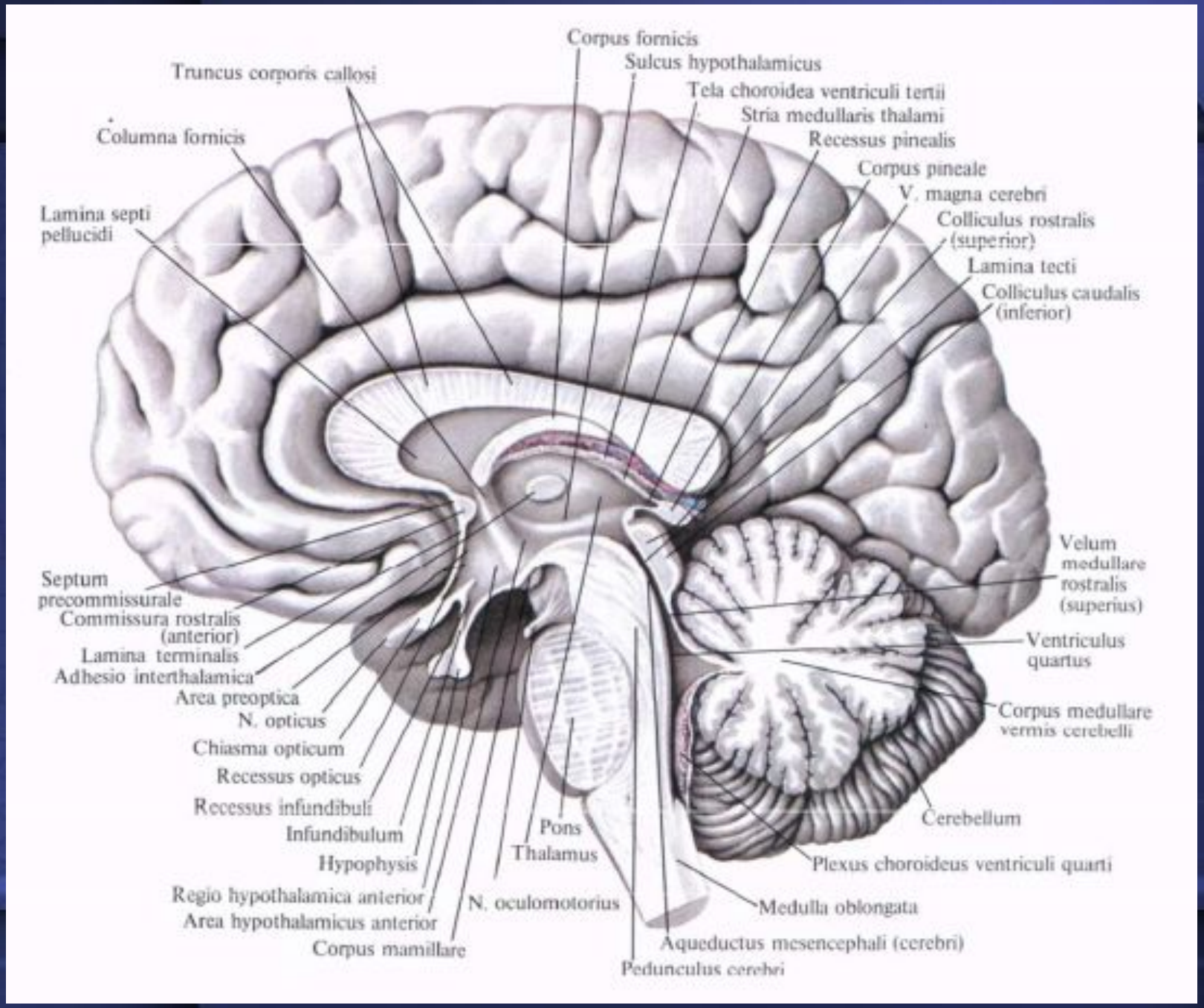
Corpus fornicis
Sulcus hypothalamicus
Truncus corporis callosi
Tela choroidea ventriculi tertii
Stria medullaris thalami
Columna fornicis
Recessus pinealis
Corpus pineale
V. magna cerebri
Lamina septi pellucidi
Colliculus rostralis (superior)
Lamina tecti
Colliculus caudalis (inferior)
Velum medullare rostralis (superius)
Septum precommissurale
Commissura rostralis (anterior)
Ventriculus quartus
Lamina terminalis
Adhesio interthalamica
Area preoptica
Corpus medullare vermis cerebelli
N. opticus
Chiasma opticum
Recessus opticus
Recessus infundibuli
Cerebellum
Infundibulum
Pons
Thalamus
Hypophysis
Plexus choroideus ventriculi quarti
Regio hypothalamica anterior
N. oculomotorius
Medulla oblongata
Area hypothalamicus anterior
Aqueductus mesencephali (cerebri)
Corpus mamillare
Pedunculus cerebri

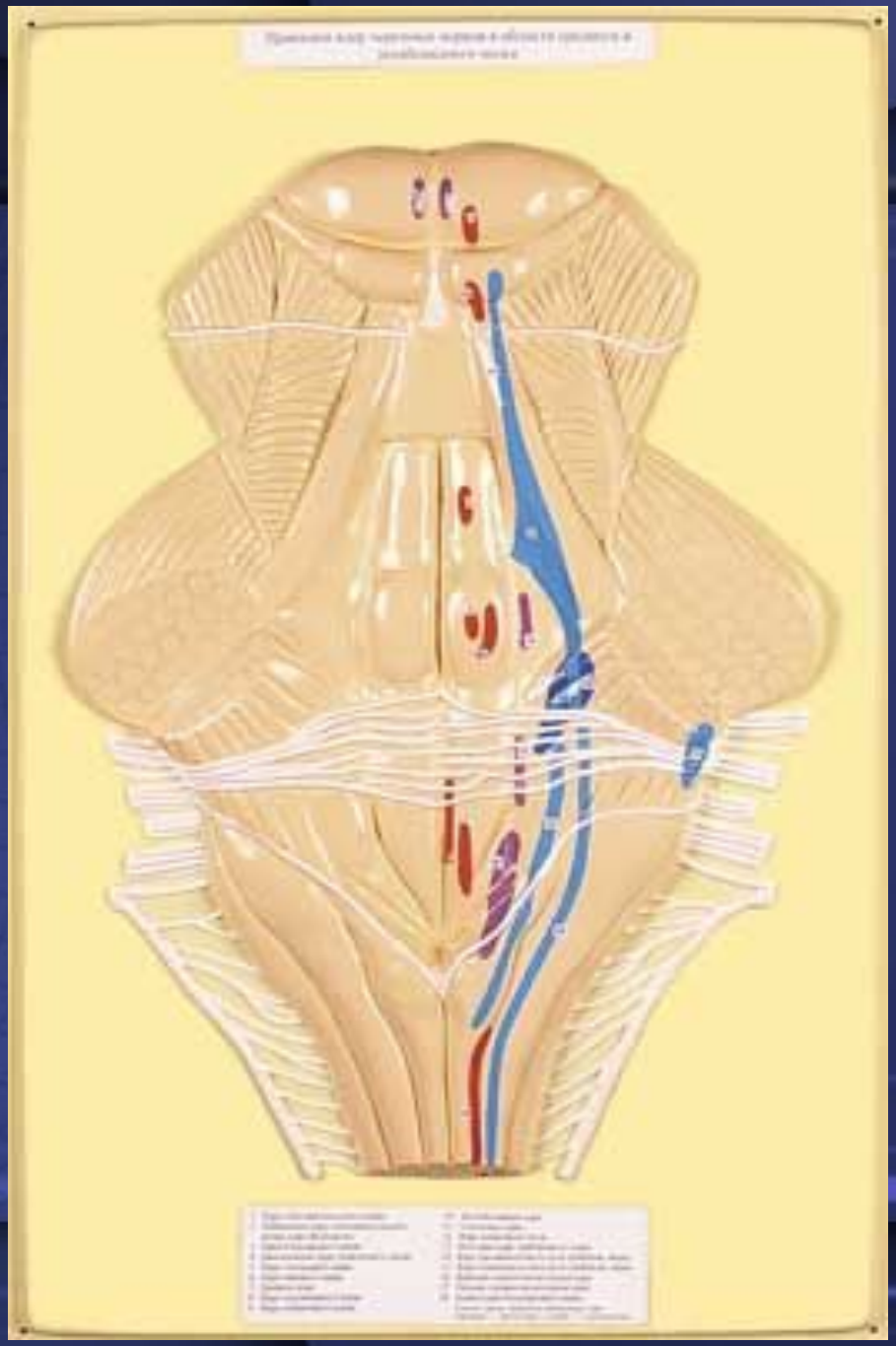

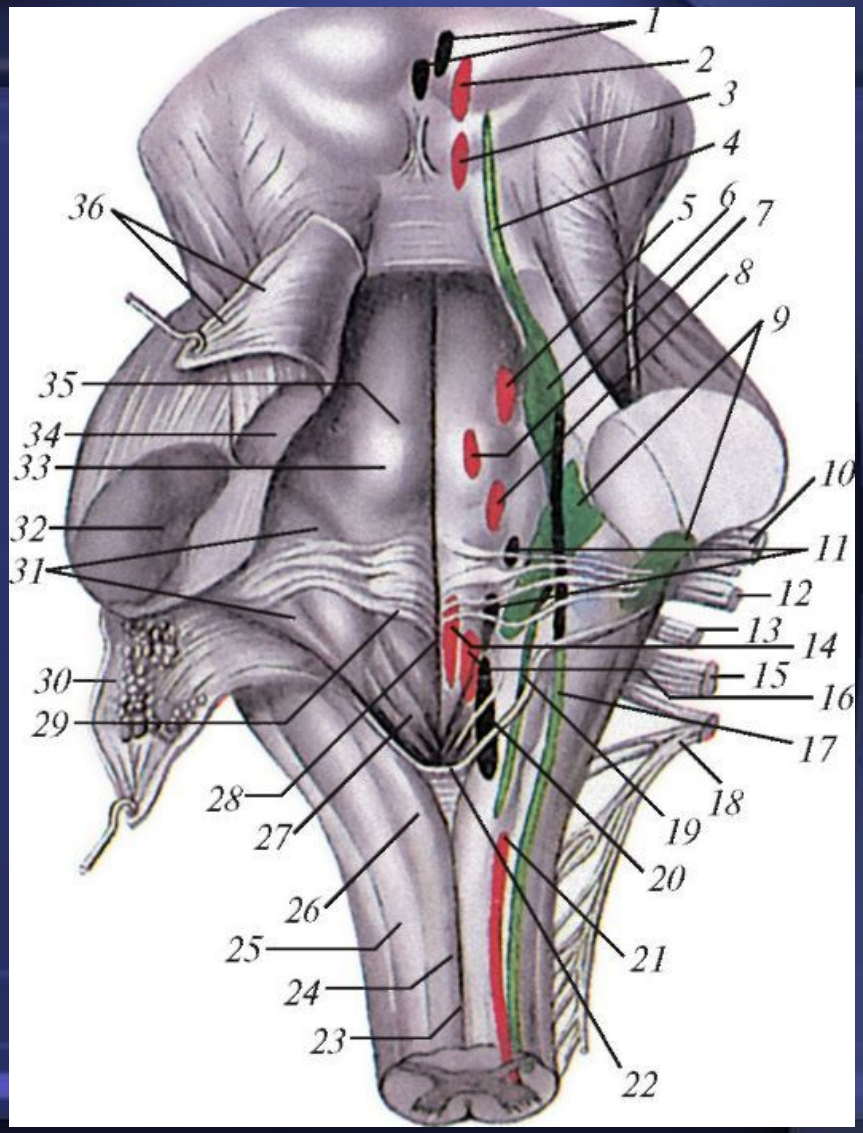
1
2
3
4
5
6
7
8
9
10
11
12
13
14
15
16
17
18
19
20
21
22
23
24
25
26
27
28
29
30
31
32
33
34
35
36

VIII

- nucl. cochlear is dorsalis et ventralis

- nucll. vestibulares medialis (Швальба),
- lateralis (Дейтерса),
- superior (Бехтерева),
- inferior (Роллера)

	Двигательные	Чувствительные	Парасимпатич.
V	*nucl.motorius*	nucl. pontinus, nucl. spinalis n. mesencephalicus	----------
VI	*nucl.motorius*	----------	----------
VII	*nucl.motorius*	nucl. solitarius	nucl.salivatorius superior (VII)
IX	*nucl.ambiguus*		nucl.salivatorius inferior (IX)
X			nucl.dorsalis (X).
XI		----------	----------
XI	*nucl.motorius*	----------	----------

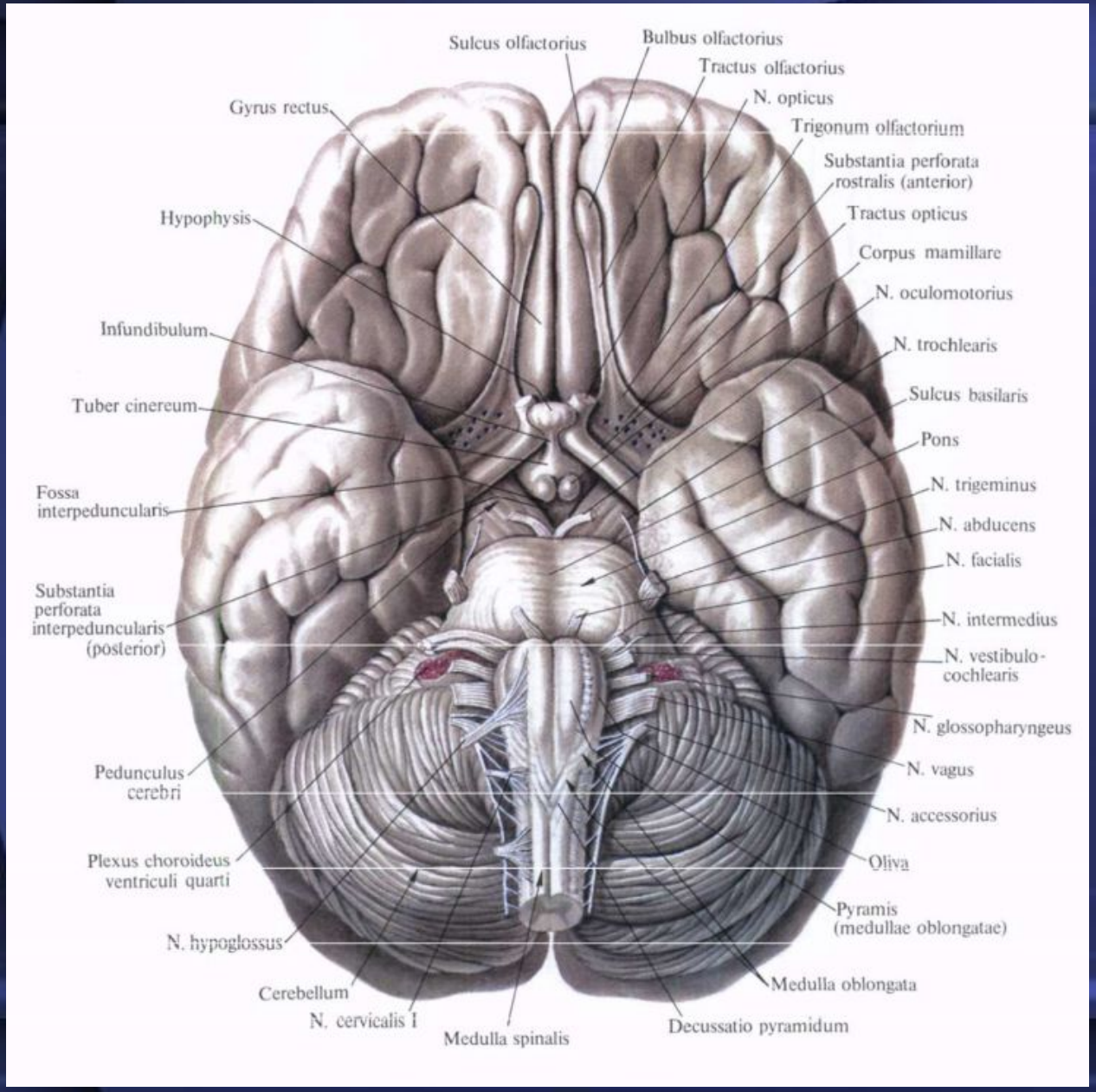
Sulcus olfactorius
Bulbus olfactorius
Tractus olfactorius
N. opticus
Trigonum olfactorium
Substantia perforata rostralis (anterior)
Tractus opticus
Corpus mamillare
N. oculomotorius
N. trochlearis
Sulcus basilaris
Pons
N. trigeminus
N. abducens
N. facialis
N. intermedius
N. vestibulo-cochlearis
N. glossopharyngeus
N. vagus
N. accessorius
Oliva
Pyramis (medullae oblongatae)
Medulla oblongata
Decussatio pyramidum
Medulla spinalis
N. cervicalis I
Cerebellum
N. hypoglossus
Plexus choroideus ventriculi quarti
Pedunculus cerebri
Substantia perforata interpeduncularis (posterior)
Fossa interpeduncularis
Tuber cinereum
Infundibulum
Hypophysis
Gyrus rectus

- Продолговатый мозг

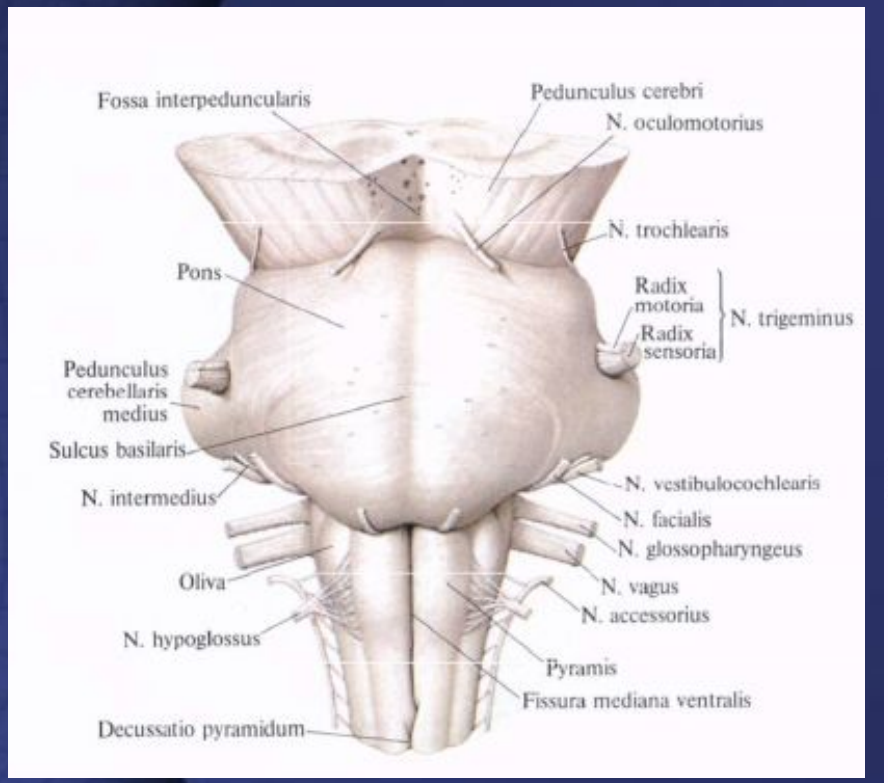

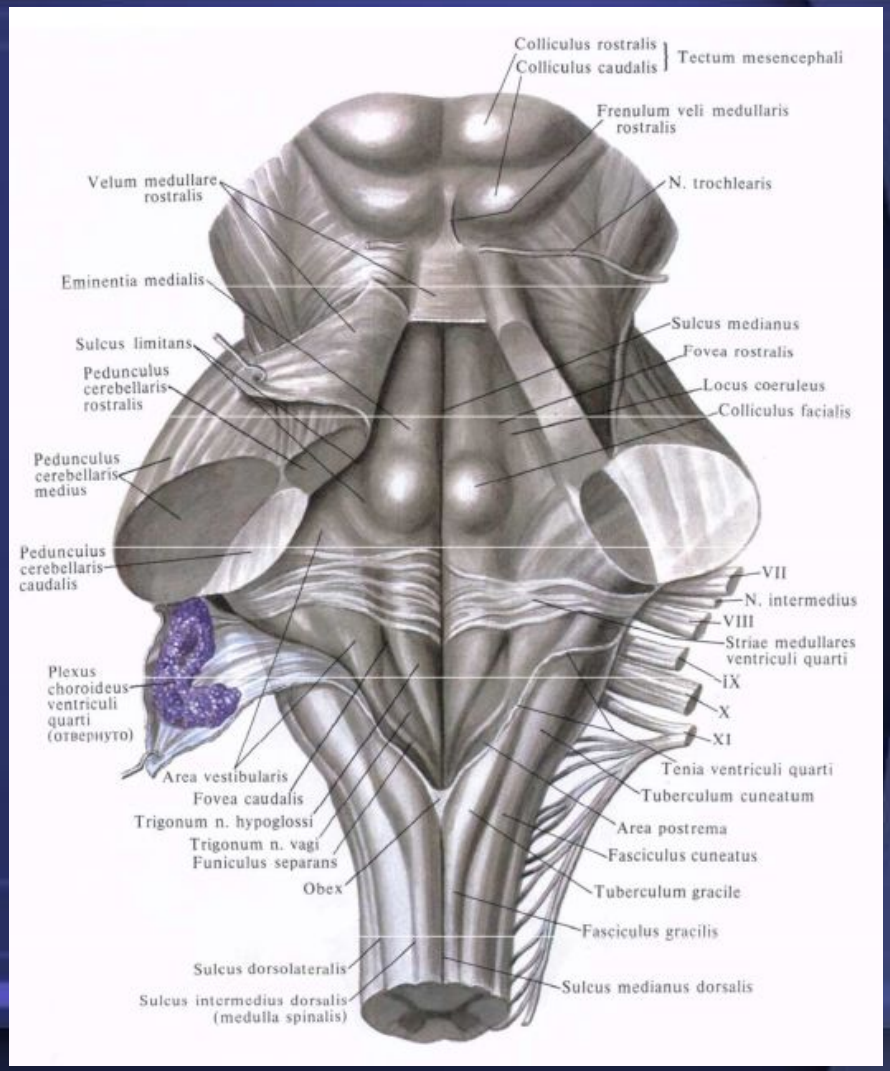

Поперечный разрез продолговатого мозга на уровне олив.

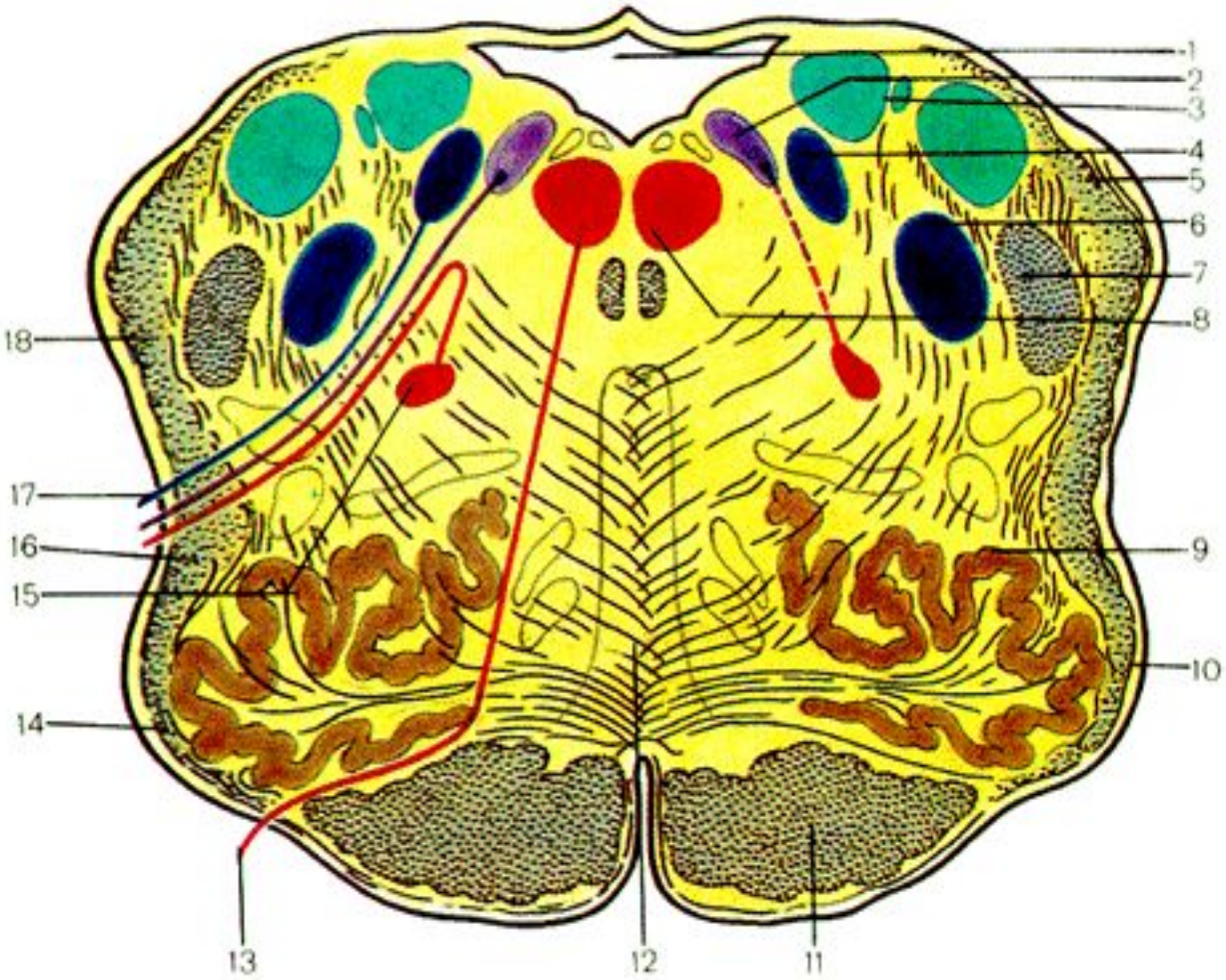

1 – ventriculus quartus;
2 – nucl. dorsalis n. vagi;
3 – nucl. n. vestibularis;
4 – nucl. solitarius;
5 – tr. spinocerebellaris dorsalis [posterior];
6 – nucl. spinalis (inferior) n. trigeminalis;
7 – tr. spinalis n. trigeminalis;
8 – nucl. n. hypoglossi;
9 – nucl. olivaris;
10 – oliva;
11 – tr. corticospinalis (pyramidalis);
12 – lemniscus medialis;
13 – n. hypoglossus;
14 – fibrae arcuatae externae ventrales;
15 – nucl. ambiguus;
16 – tr. spinothalamicus et spinotectalis;
17 – n. vagus;
18 – tr. spinocerebellaris ventralis [anterior] .

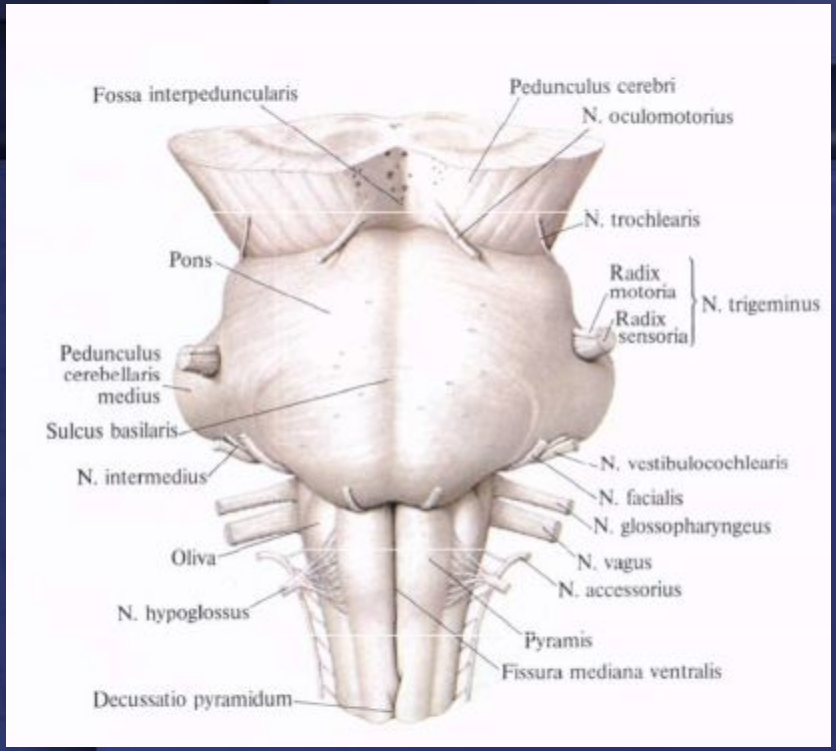

- Задний мозг:
- Мост
- Мозжечок
- 4 желудочек

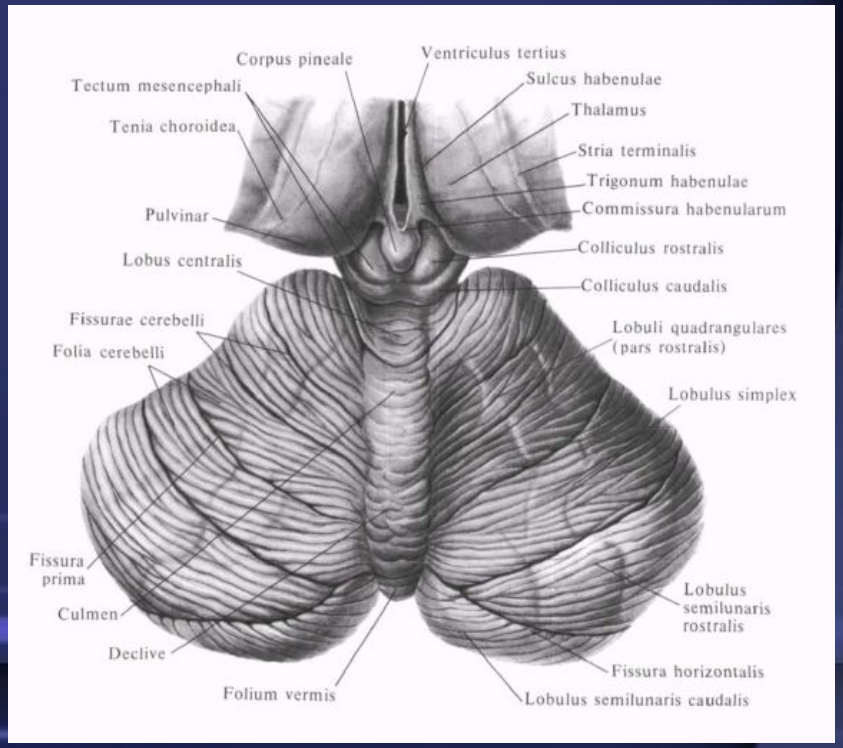

Мост, образования в плоскости разреза

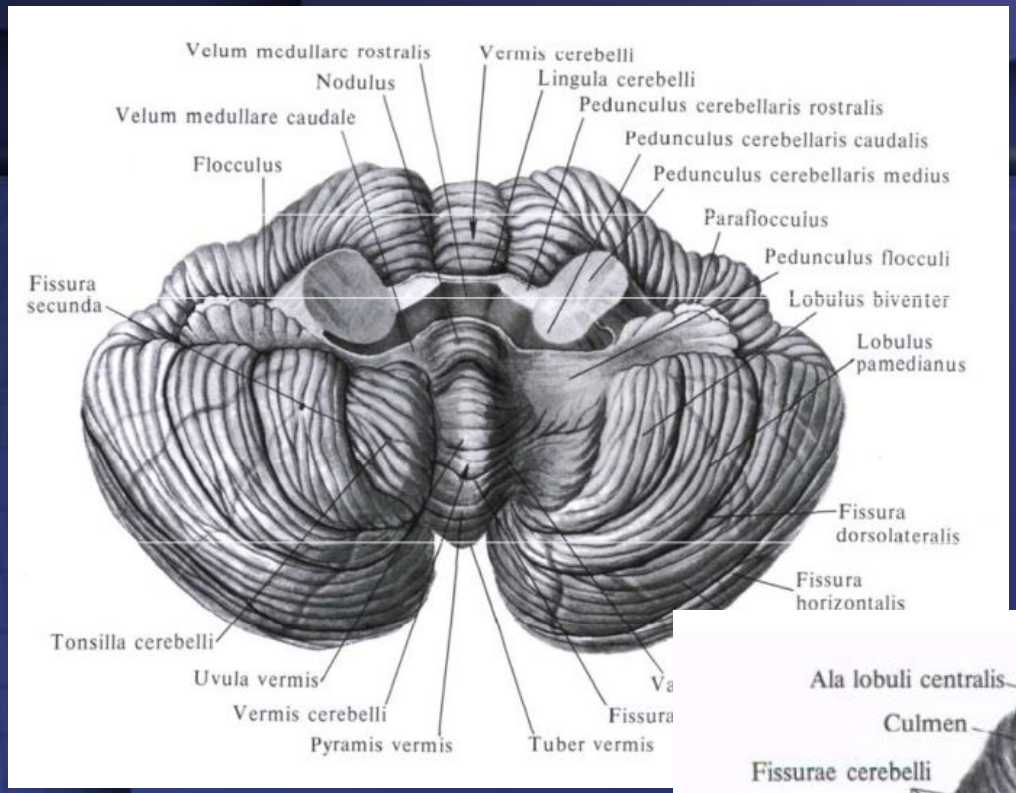
Velum medullare rostralis
Vermis cerebelli
Nodulus
Lingula cerebelli
Pedunculus cerebellaris rostralis
Velum medullare caudale
Pedunculus cerebellaris caudalis
Flocculus
Pedunculus cerebellaris medius
Paraflocculus
Pedunculus flocculi
Fissura secunda
Lobulus biventer
Lobulus pamedianus
Fissura dorsolateralis
Fissura horizontalis
Tonsilla cerebelli
Uvula vermis
Vermis cerebelli
Pyramis vermis
Tuber vermis

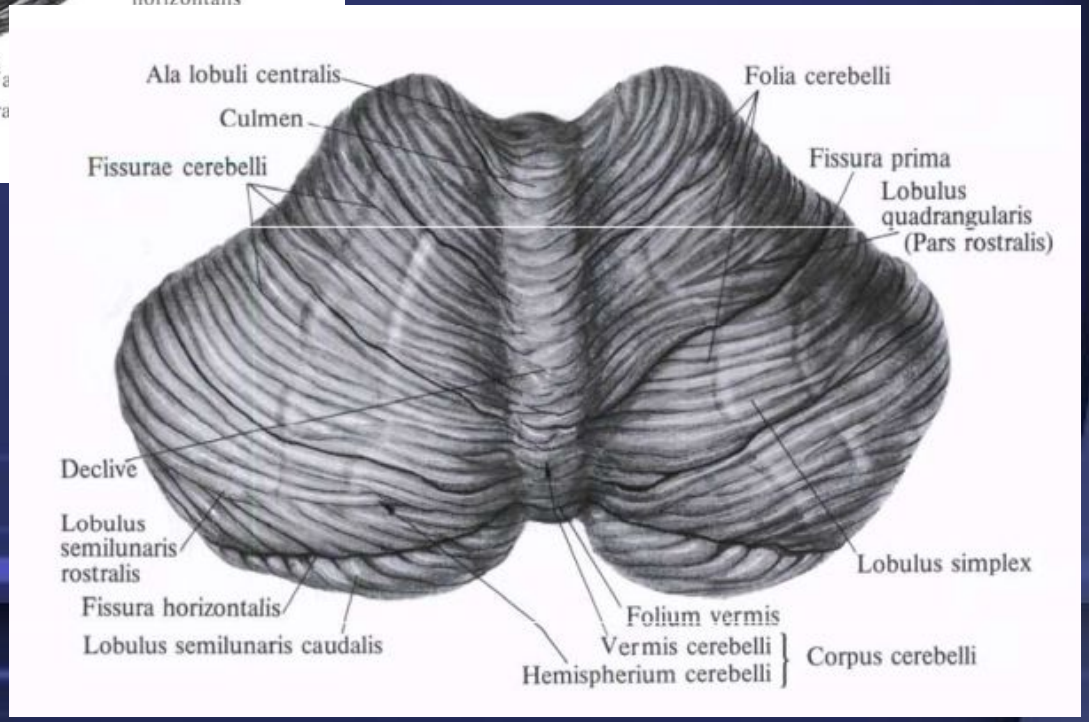
Ala lobuli centralis
Folia cerebelli
Culmen
Fissurae cerebelli
Fissura prima
Lobulus quadrangularis (Pars rostralis)
Declive
Lobulus semilunaris rostralis
Lobulus simplex
Fissura horizontalis
Folium vermis
Lobulus semilunaris caudalis
Vermis cerebelli
Hemispherium cerebelli
Corpus cerebelli

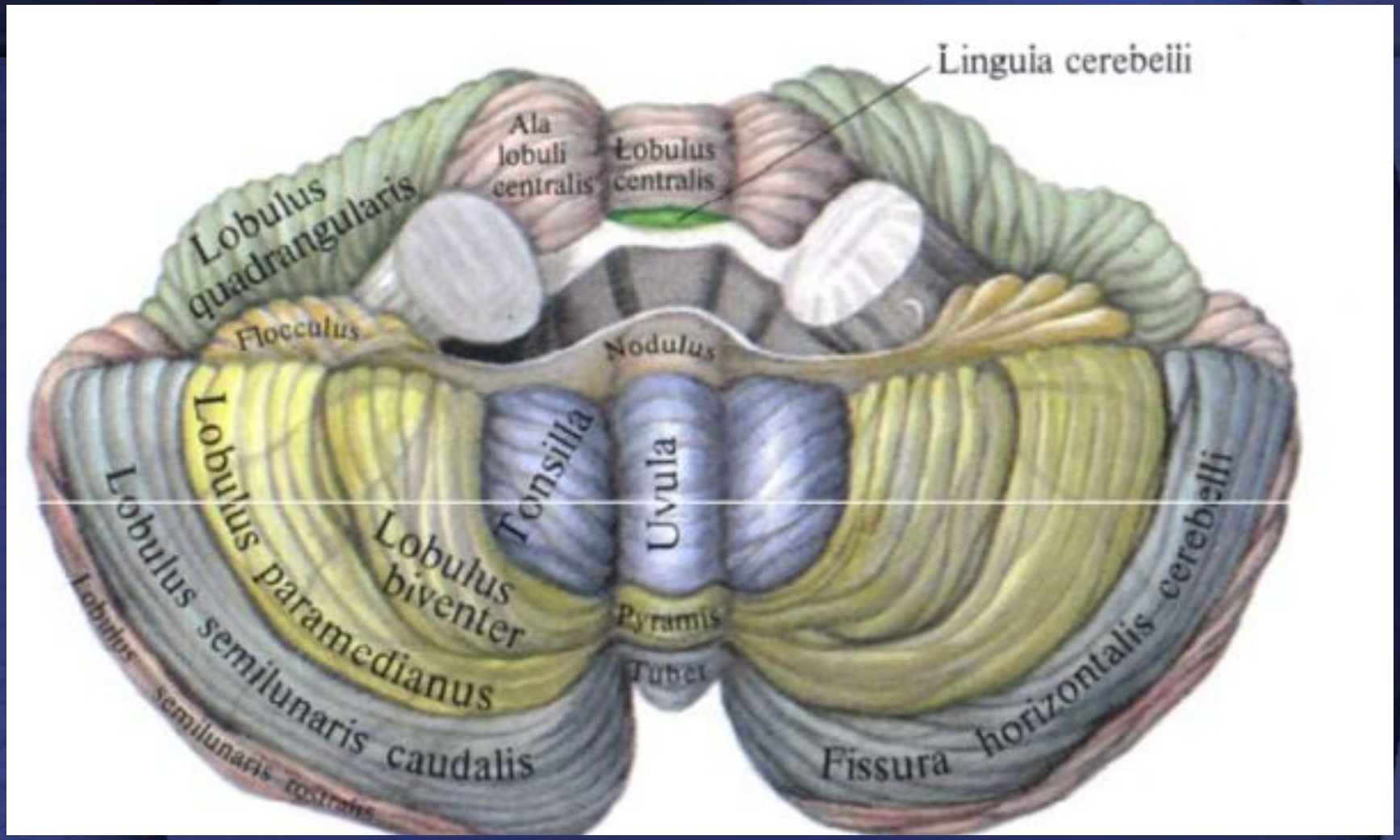
Lingula cerebelli
Ala lobuli centralis
Lobulus centralis
Lobulus quadrangularis
Flocculus
Nodulus
Tonsilla
Uvula
Lobulus paramedianus
Lobulus biventer
Lobulus semilunaris caudalis
Lobulus semilunaris rostralis
Pyramis
Tuber
Fissura horizontalis cerebelli

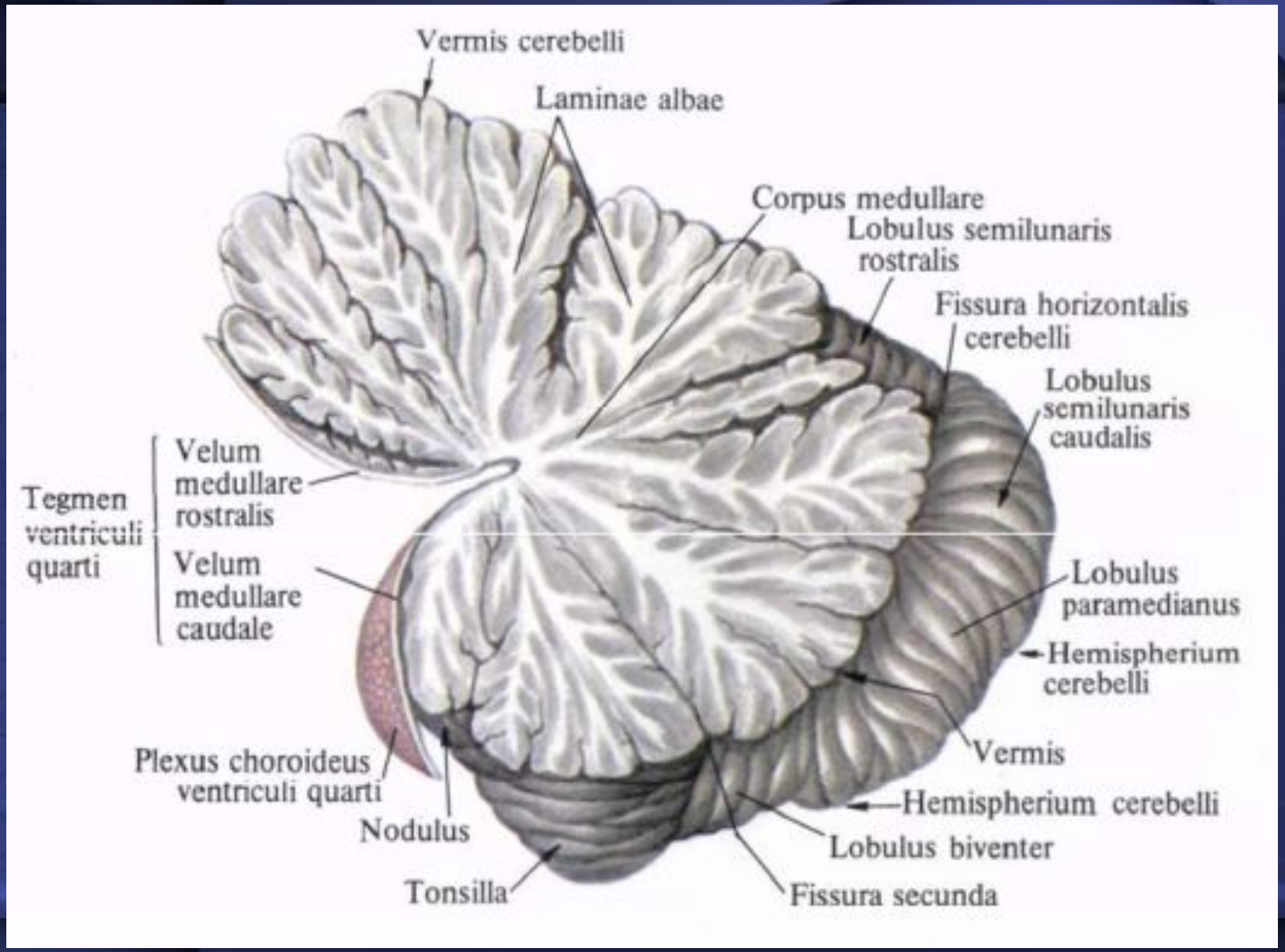
Vermis cerebelli
Laminae albae
Corpus medullare
Lobulus semilunaris rostralis
Fissura horizontalis cerebelli
Lobulus semilunaris caudalis
Tegmen ventriculi quarti
Velum medullare rostralis
Velum medullare caudale
Lobulus paramedianus
Hemispherium cerebelli
Vermis
Plexus choroideus ventriculi quarti
Nodulus
Hemispherium cerebelli
Lobulus biventer
Tonsilla
Fissura secunda

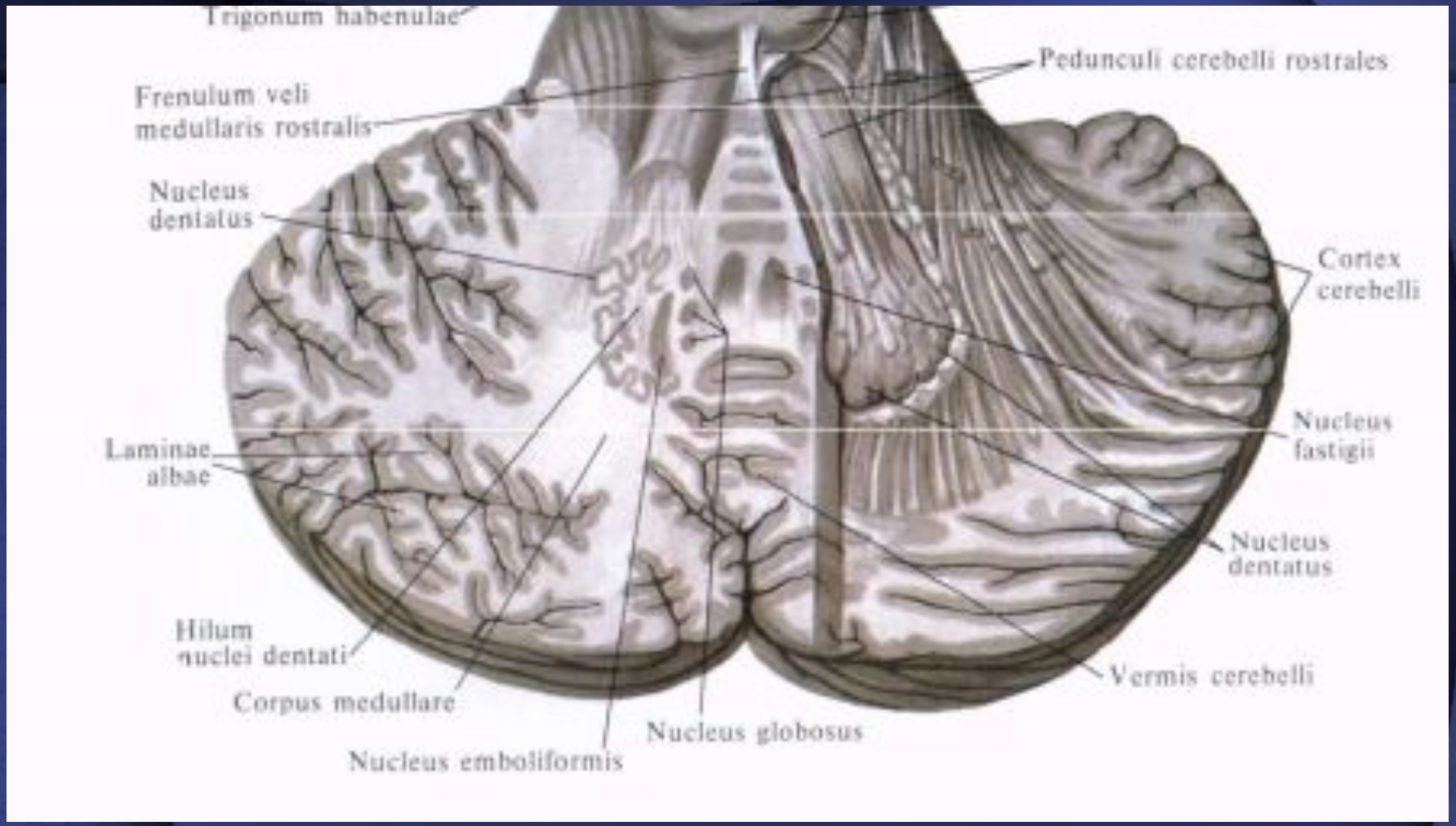
Trigonum habenulae
Pedunculi cerebelli rostrales
Frenulum veli
medullaris rostralis
Nucleus
dentatus
Cortex
cerebelli
Nucleus
fastigii
Laminae
albae
Nucleus
dentatus
Hilum
nuclei dentati
Vermis cerebelli
Corpus medullare
Nucleus globosus
Nucleus emboliformis

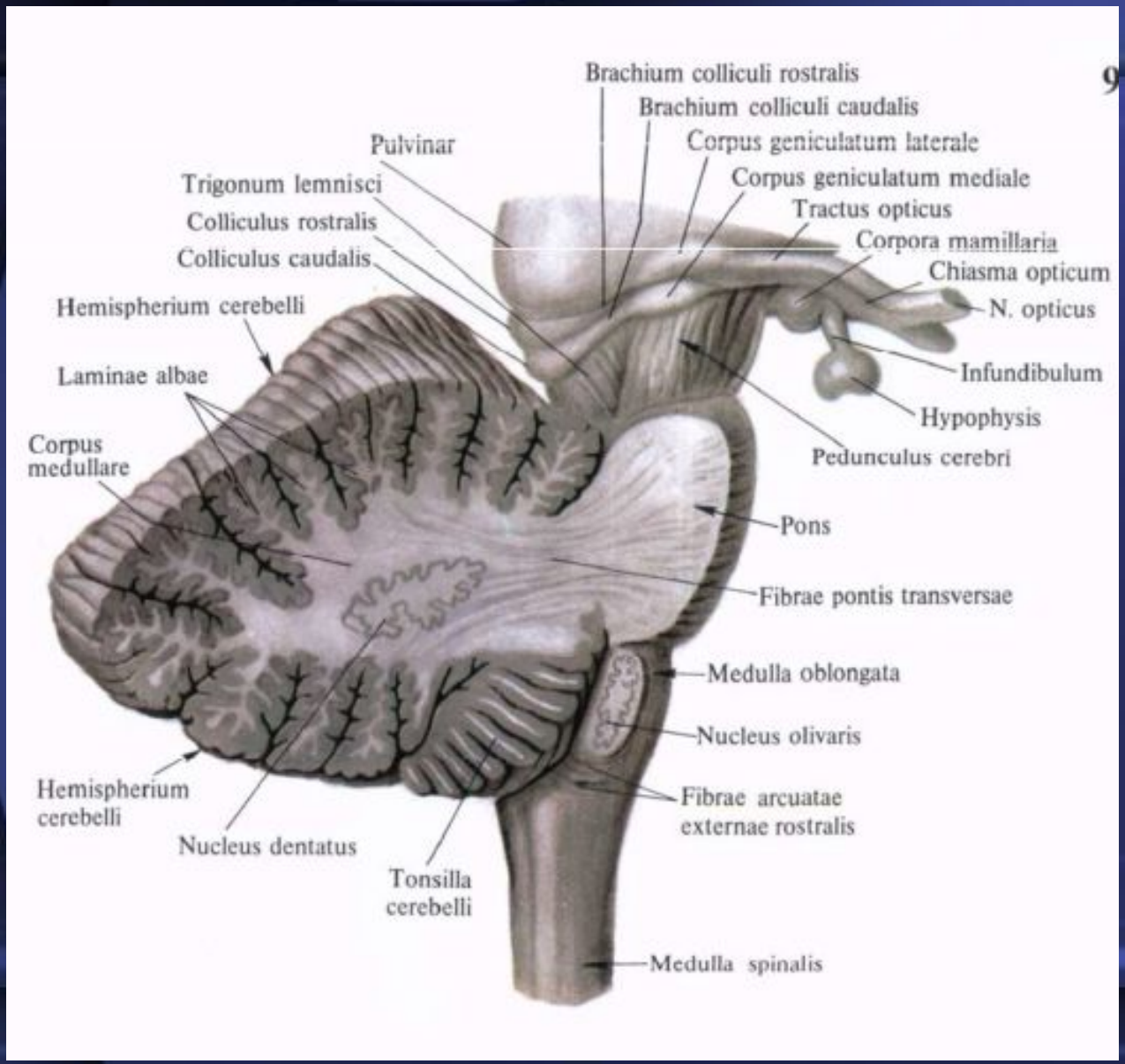
9
Brachium colliculi rostralis
Brachium colliculi caudalis
Corpus geniculatum laterale
Corpus geniculatum mediale
Tractus opticus
Corpora mamillaria
Chiasma opticum
N. opticus
Infundibulum
Hypophysis
Pedunculus cerebri
Pulvinar
Trigonum lemnisci
Colliculus rostralis
Colliculus caudalis
Hemispherium cerebelli
Laminae albae
Corpus medullare
Pons
Fibrae pontis transversae
Medulla oblongata
Nucleus olivaris
Fibrae arcuatae externae rostralis
Hemispherium cerebelli
Nucleus dentatus
Tonsilla cerebelli
Medulla spinalis

Средний мозг

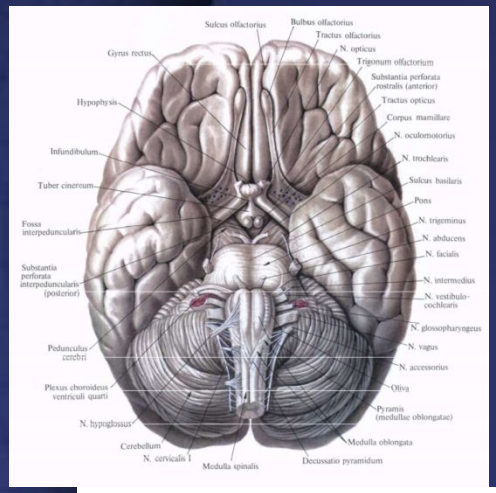

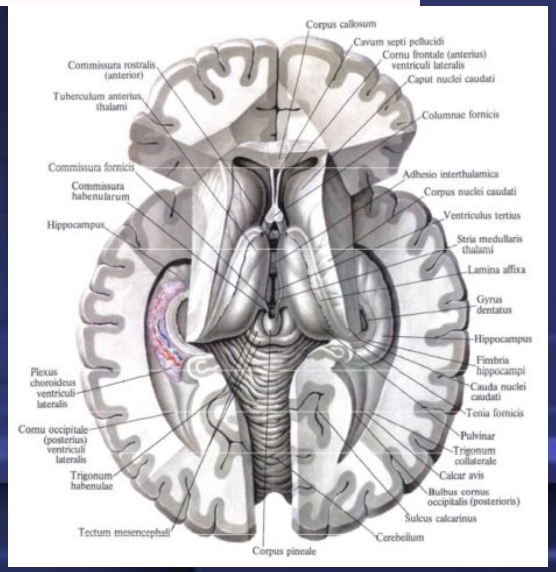

- Ножки мозга
- Пластинка крыши (четверохолмие)
- Полость – водопровод мозга – Сильвиев водопровод

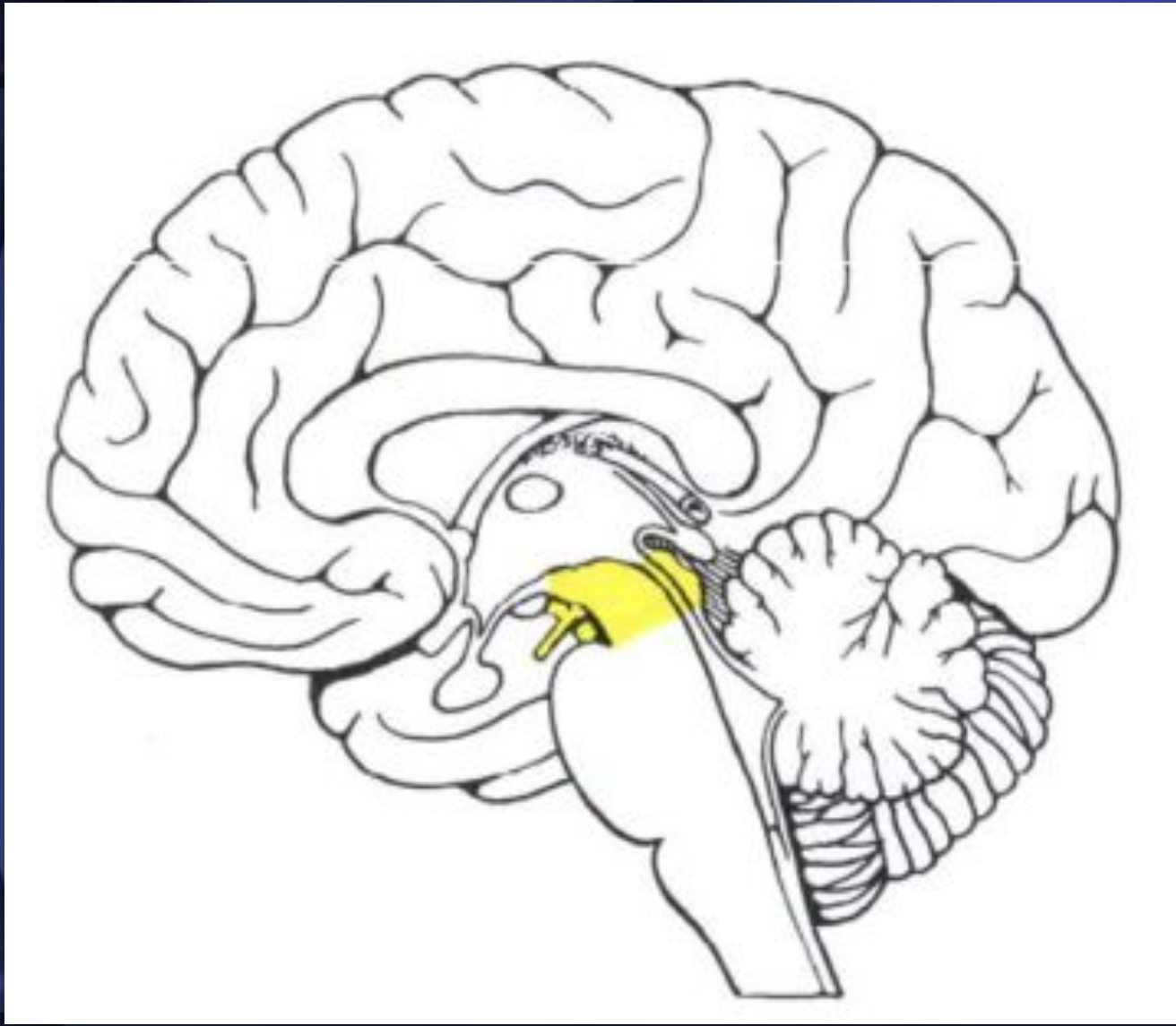

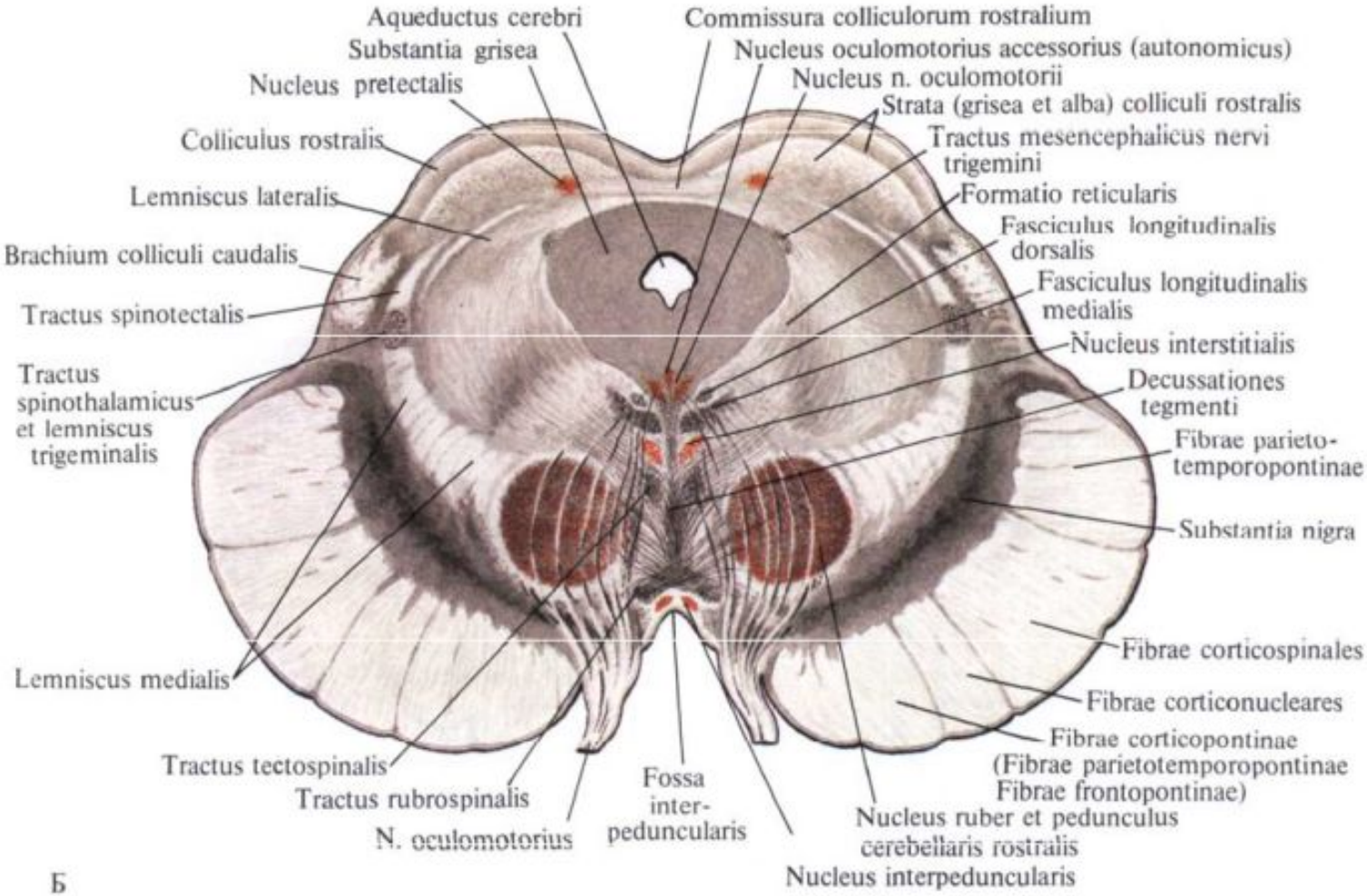
Aqueductus cerebri
Substantia grisea
Nucleus pretectalis
Colliculus rostralis
Lemniscus lateralis
Brachium colliculi caudalis
Tractus spinotectalis
Tractus spinothalamicus et lemniscus trigeminalis
Lemniscus medialis
Tractus tectospinalis
Tractus rubrospinalis
N. oculomotorius
Fossa inter-peduncularis
Commissura colliculorum rostralium
Nucleus oculomotorius accessorius (autonomicus)
Nucleus n. oculomotorii
Strata (grisea et alba) colliculi rostralis
Tractus mesencephalicus nervi trigemini
Formatio reticularis
Fasciculus longitudinalis dorsalis
Fasciculus longitudinalis medialis
Nucleus interstitialis
Decussationes tegmenti
Fibrae parieto-temporopontinae
Substantia nigra
Fibrae corticospinales
Fibrae corticonucleares
Fibrae corticopontinae
(Fibrae parietotemporopontinae
Fibrae frontopontinae)
Nucleus ruber et pedunculus cerebellaris rostralis
Nucleus interpeduncularis
Б

Промежуточный мозг

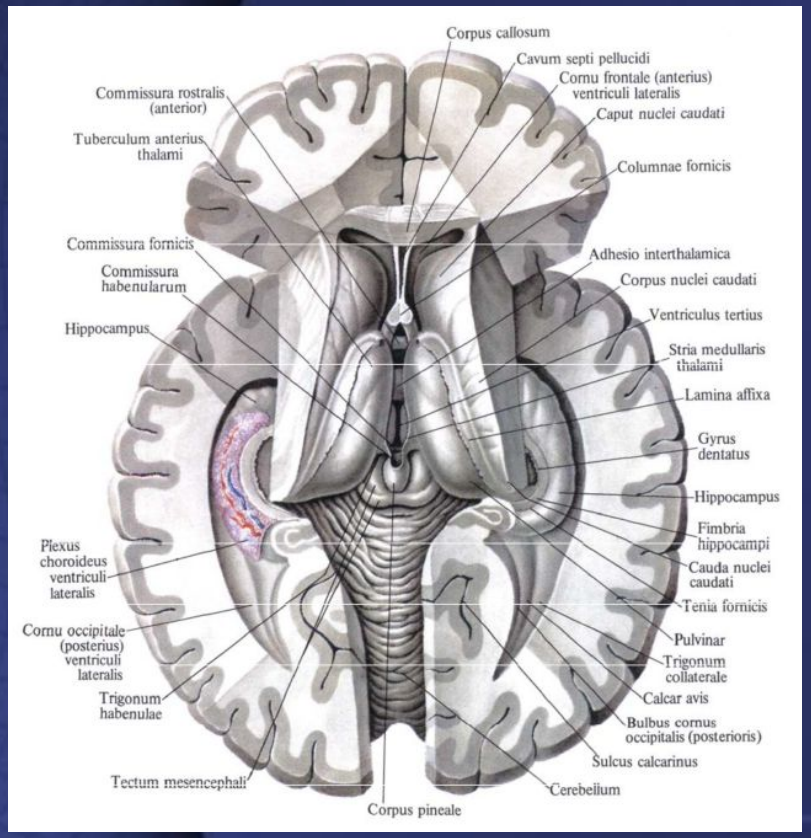

- Таламический мозг
  таламус
  эпиталамус (эпифиз, поводки)
  метаталамус (латеральное и медиальное коленчатые тела
- Гипоталамус или подталамическая область
- Зрительный перекрест, зрительный тракт, серый бугор с воронкой, гипофиз
- Полость – 3 желудочек

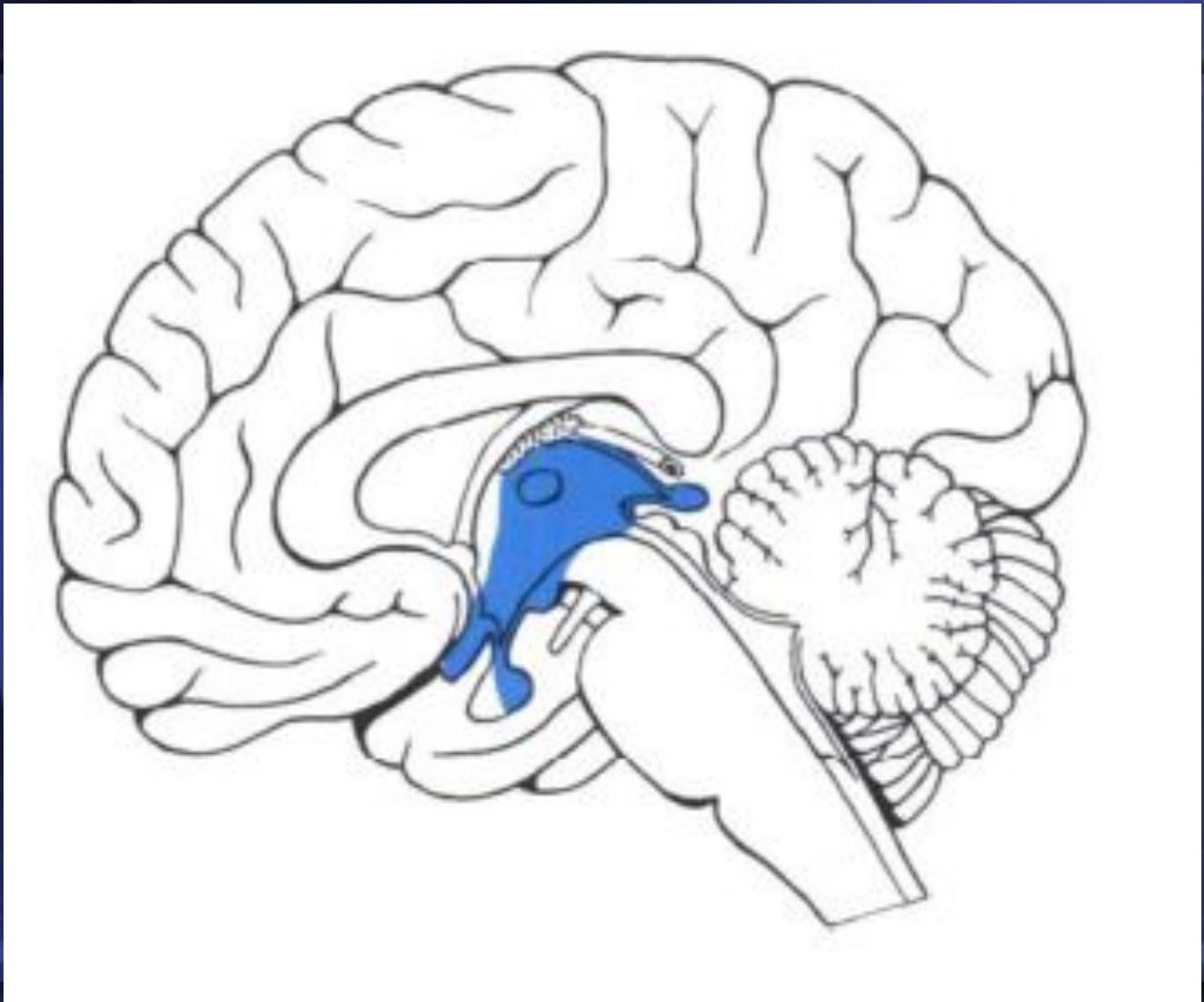

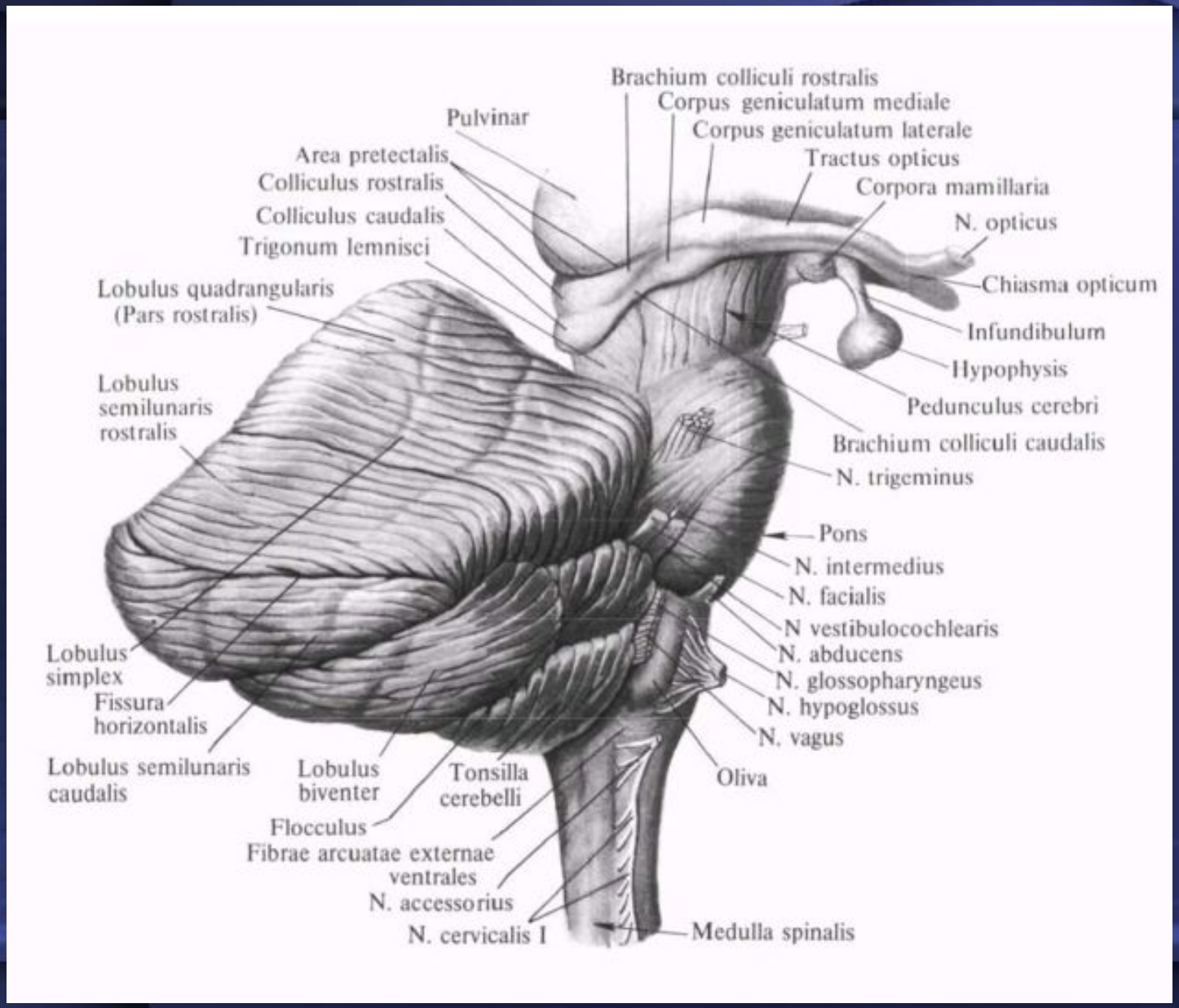
Brachium colliculi rostralis
Corpus geniculatum mediale
Corpus geniculatum laterale
Pulvinar
Tractus opticus
Area pretectalis
Corpora mamillaria
Colliculus rostralis
N. opticus
Colliculus caudalis
Trigonum lemnisci
Chiasma opticum
Lobulus quadrangularis
(Pars rostralis)
Infundibulum
Hypophysis
Lobulus
semilunaris
rostralis
Pedunculus cerebri
Brachium colliculi caudalis
N. trigeminus
Pons
N. intermedius
N. facialis
N vestibulocochlearis
N. abducens
N. glossopharyngeus
N. hypoglossus
N. vagus
Lobulus
simplex
Fissura
horizontalis
Lobulus semilunaris
caudalis
Lobulus
biventer
Tonsilla
cerebelli
Oliva
Flocculus
Fibrae arcuatae externae
ventrales
N. accessorius
N. cervicalis I
Medulla spinalis

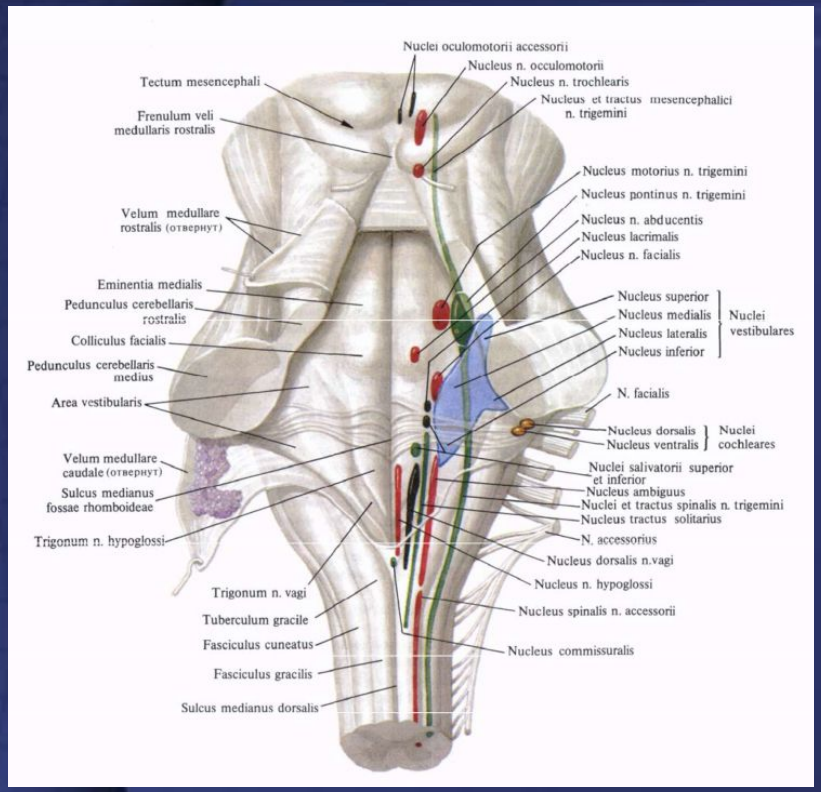
Nuclei oculomotorii accessorii
Nucleus n. occulomotorii
Nucleus n. trochlearis
Nucleus et tractus mesencephalici n. trigemini
Tectum mesencephali
Frenulum veli medullaris rostralis
Nucleus motorius n. trigemini
Nucleus pontinus n. trigemini
Velum medullare rostralis (отвернут)
Nucleus n. abducentis
Nucleus lacrimalis
Nucleus n. facialis
Eminentia medialis
Pedunculus cerebellaris rostralis
Nucleus superior
Nucleus medialis
Nucleus lateralis
Nucleus inferior
Nuclei vestibulares
Colliculus facialis
Pedunculus cerebellaris medius
Area vestibularis
N. facialis
Nucleus dorsalis
Nucleus ventralis
Nuclei cochleares
Velum medullare caudale (отвернут)
Nuclei salivatorii superior et inferior
Sulcus medianus fossae rhomboideae
Nucleus ambiguus
Nuclei et tractus spinalis n. trigemini
Nucleus tractus solitarius
Trigonum n. hypoglossi
N. accessorius
Nucleus dorsalis n.vagi
Nucleus n. hypoglossi
Trigonum n. vagi
Nucleus spinalis n. accessorii
Tuberculum gracile
Fasciculus cuneatus
Nucleus commissuralis
Fasciculus gracilis
Sulcus medianus dorsalis

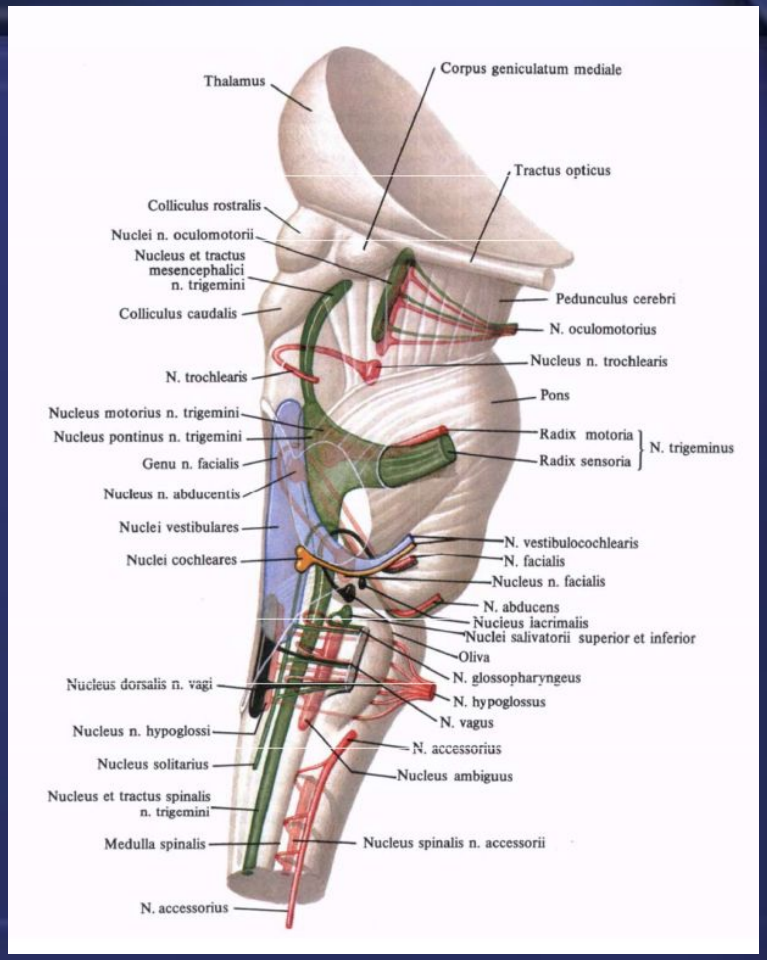
Thalamus
Corpus geniculatum mediale
Tractus opticus
Colliculus rostralis
Nuclei n. oculomotorii
Nucleus et tractus mesencephalici n. trigemini
Pedunculus cerebri
Colliculus caudalis
N. oculomotorius
Nucleus n. trochlearis
N. trochlearis
Pons
Nucleus motorius n. trigemini
Nucleus pontinus n. trigemini
Radix motoria
Radix sensoria
N. trigeminus
Genu n. facialis
Nucleus n. abducentis
Nuclei vestibulares
N. vestibulocochlearis
Nuclei cochleares
N. facialis
Nucleus n. facialis
N. abducens
Nucleus lacrimalis
Nuclei salivatorii superior et inferior
Oliva
N. glossopharyngeus
Nucleus dorsalis n. vagi
N. hypoglossus
N. vagus
Nucleus n. hypoglossi
N. accessorius
Nucleus solitarius
Nucleus ambiguus
Nucleus et tractus spinalis n. trigemini
Medulla spinalis
Nucleus spinalis n. accessorii
N. accessorius

Конечный мозг : полушария
Мозолистое тело , свод

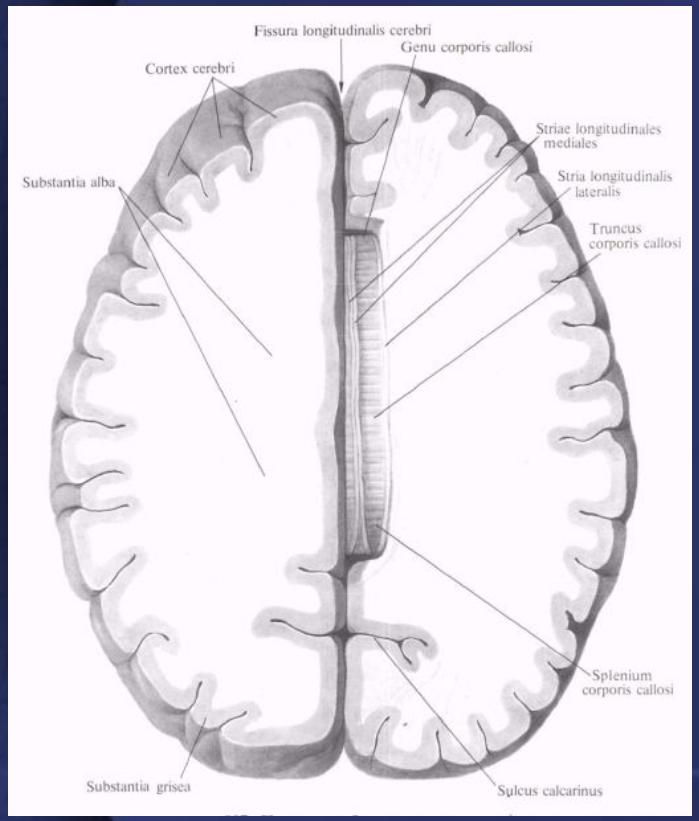

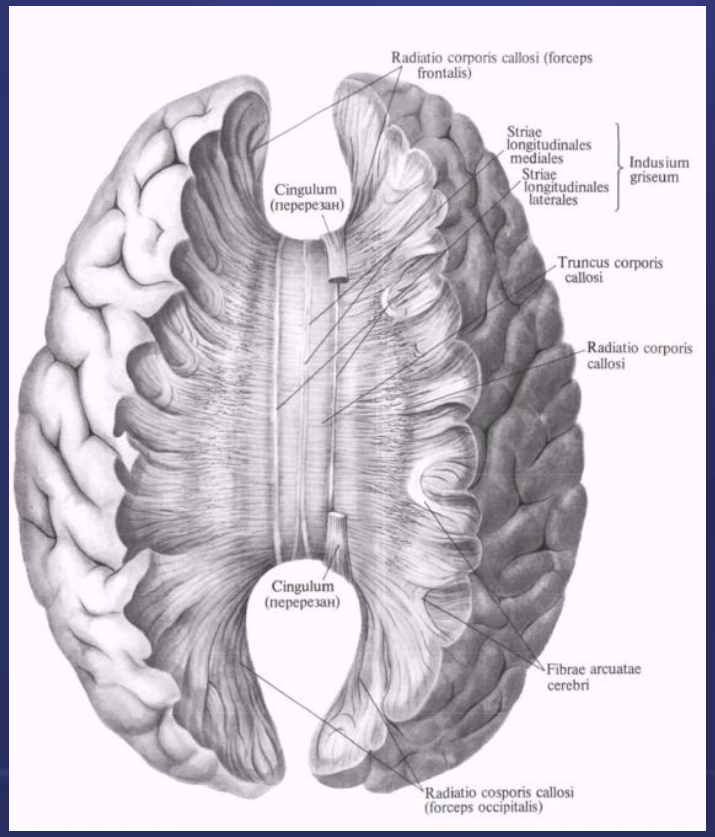

Комиссуральные волокна: Свод

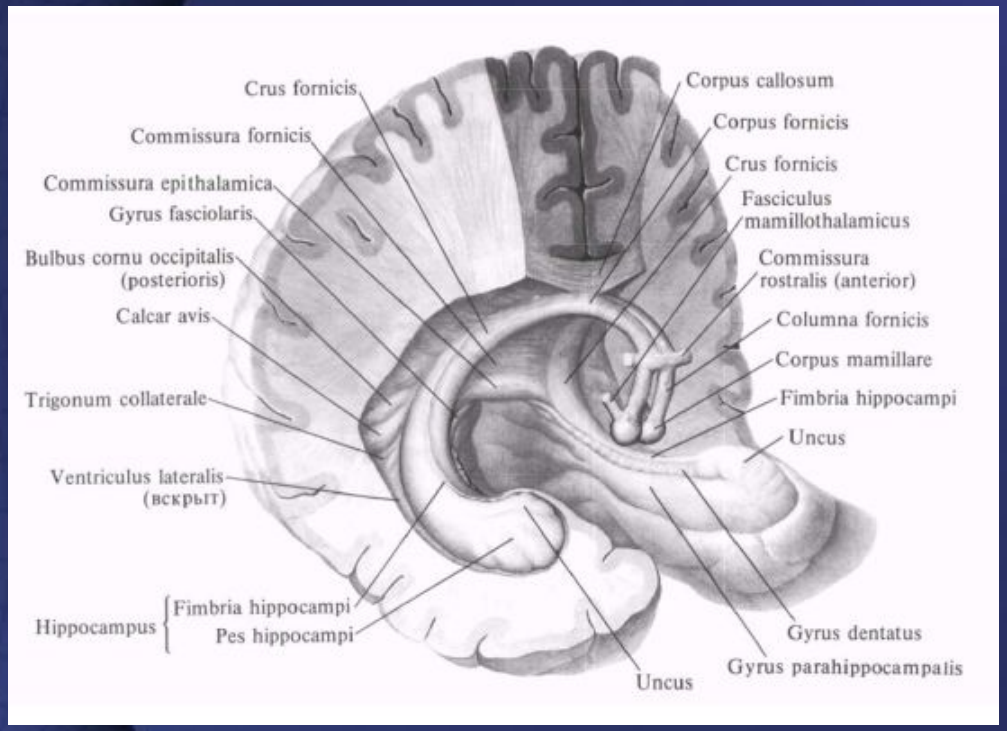

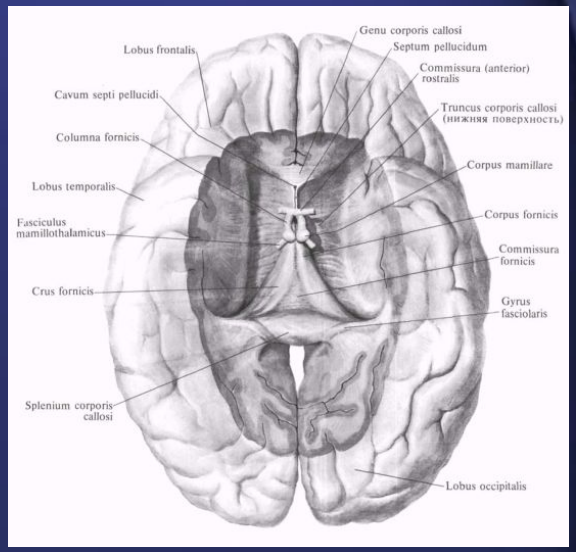

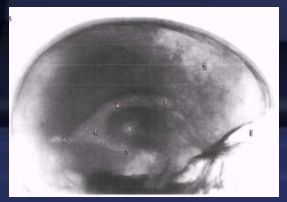

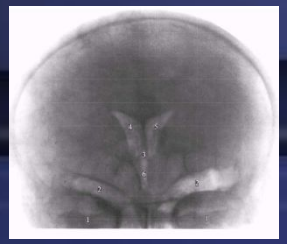

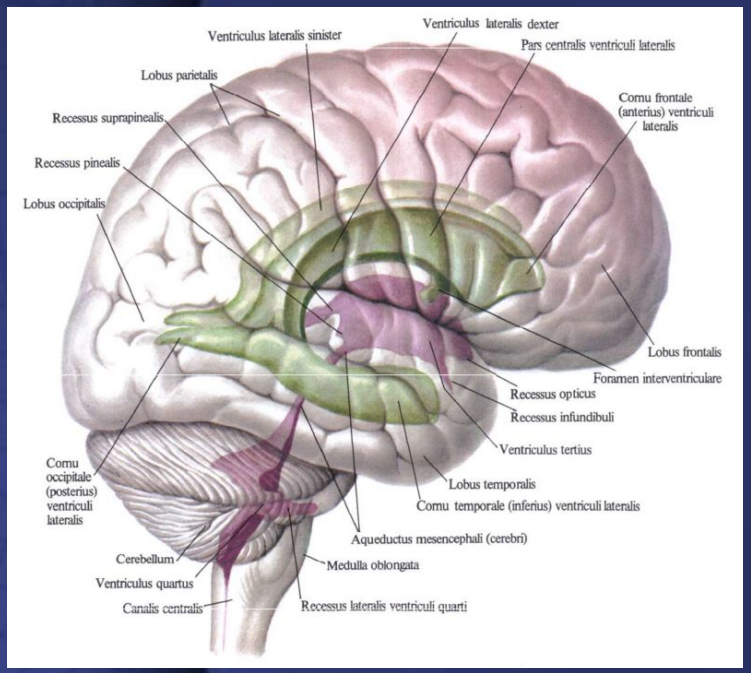
Ventriculus lateralis sinister
Ventriculus lateralis dexter
Pars centralis ventriculi lateralis
Lobus parietalis
Cornu frontale (anterius) ventriculi lateralis
Recessus suprapinealis
Recessus pinealis
Lobus occipitalis
Lobus frontalis
Foramen interventriculare
Recessus opticus
Recessus infundibuli
Ventriculus tertius
Cornu occipitale (posterius) ventriculi lateralis
Lobus temporalis
Cornu temporale (inferius) ventriculi lateralis
Aqueductus mesencephali (cerebri)
Cerebellum
Medulla oblongata
Ventriculus quartus
Canalis centralis
Recessus lateralis ventriculi quarti

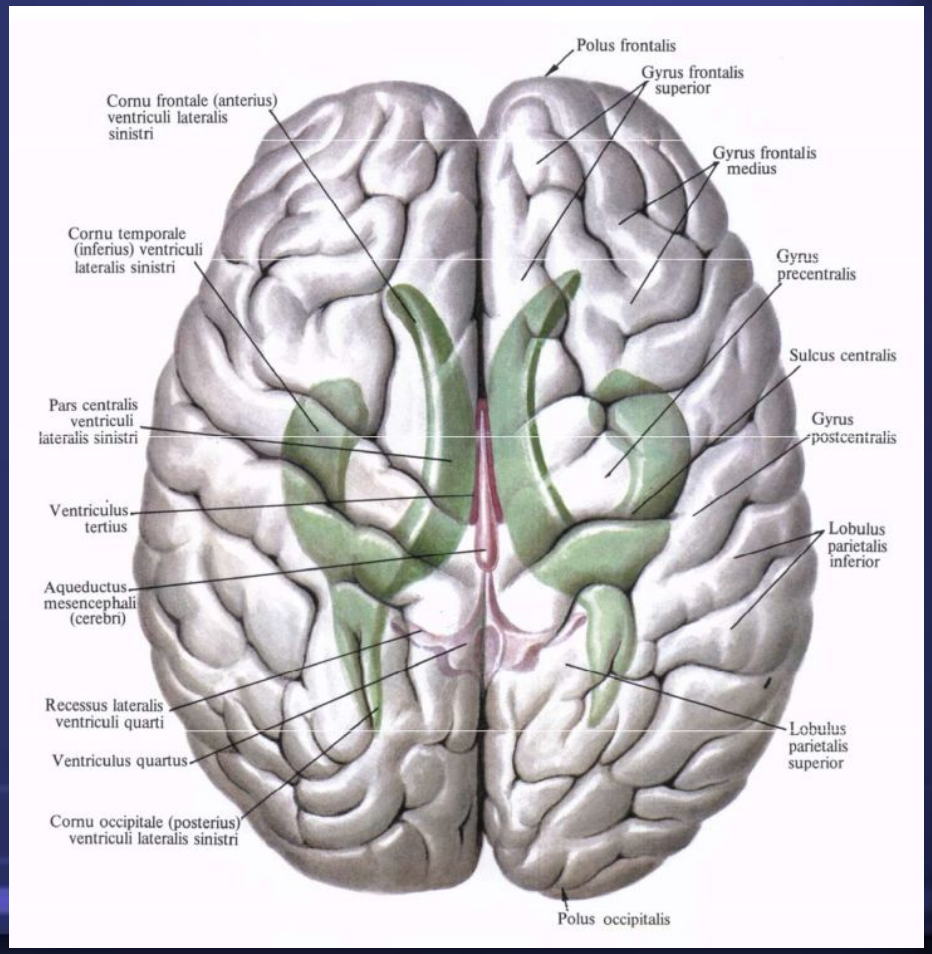
Polus frontalis
Gyrus frontalis superior
Cornu frontale (anterius) ventriculi lateralis sinistri
Gyrus frontalis medius
Cornu temporale (inferius) ventriculi lateralis sinistri
Gyrus precentralis
Sulcus centralis
Pars centralis ventriculi lateralis sinistri
Gyrus postcentralis
Ventriculus tertius
Lobulus parietalis inferior
Aqueductus mesencephali (cerebri)
Recessus lateralis ventriculi quarti
Lobulus parietalis superior
Ventriculus quartus
Cornu occipitale (posterius) ventriculi lateralis sinistri
Polus occipitalis

Ventriculus lateralis sinister
Ventriculus lateralis dexter
Pars centralis ventriculi lateralis
Lobus parietalis
Cornu frontale (anterius) ventriculi lateralis
Recessus suprapinealis
Recessus pinealis
Lobus occipitalis
Foramen in
Recessus opticus
Recessus infundibuli
Ventriculus tertius
Cornu occipitale (posterius) ventriculi lateralis
Lobus temporalis
Cornu temporale (inferius) ventriculi lateralis
Aqueductus mesencephali (cerebri)
Cerebellum
Medulla oblongata
Ventriculus quartus
Canalis centralis
Recessus lateralis ventriculi quarti

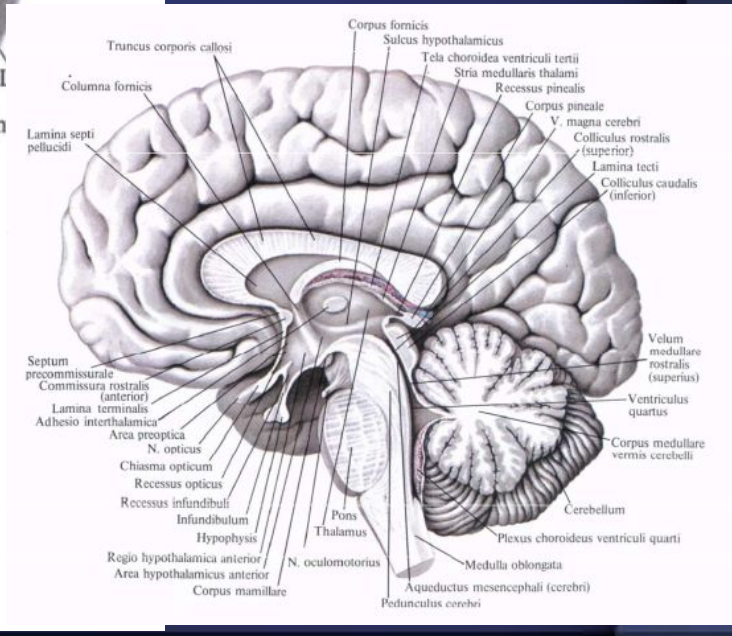

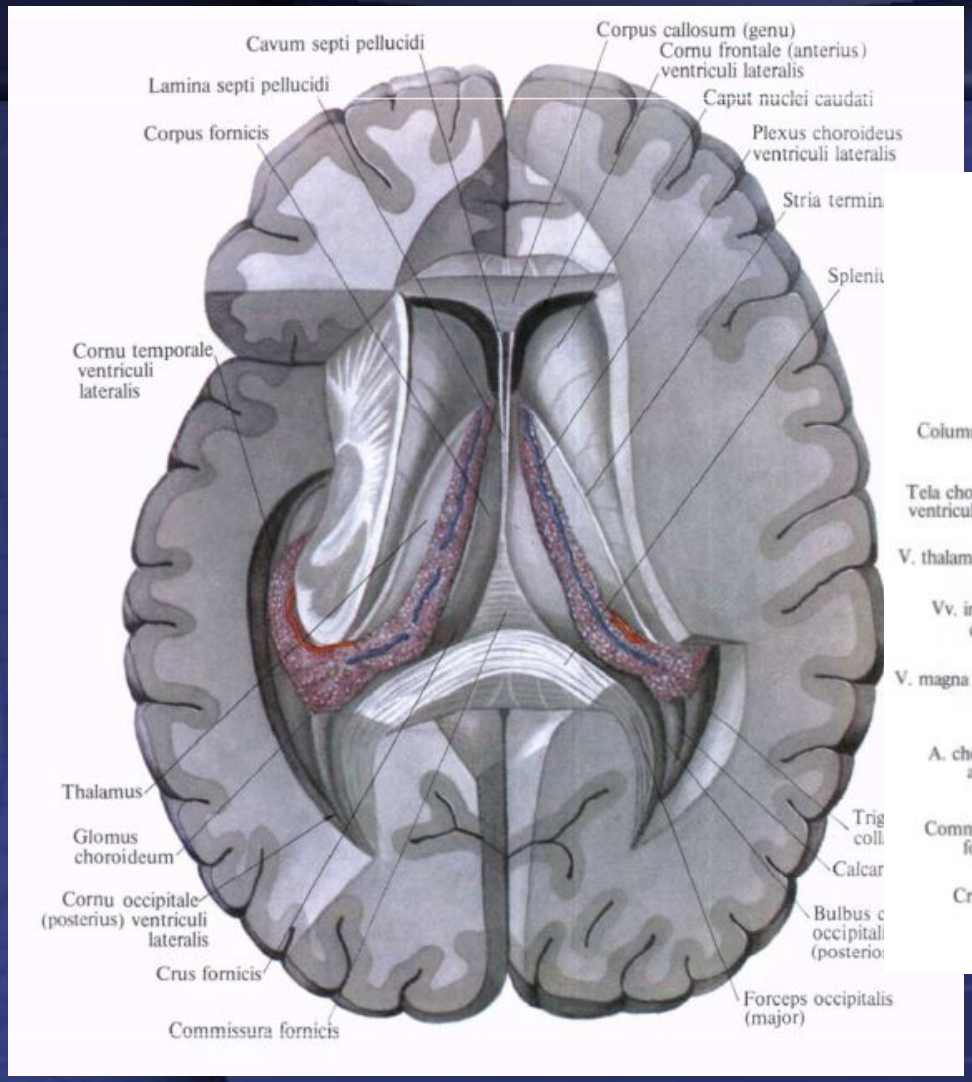
Cavum septi pellucidi
Corpus callosum (genu)
Cornu frontale (anterius) ventriculi lateralis
Lamina septi pellucidi
Caput nuclei caudati
Corpus fornicis
Plexus choroideus ventriculi lateralis
Stria termin
Splenit
Cornu temporale ventriculi lateralis
Thalamus
Glomus choroideum
Cornu occipitale (posterius) ventriculi lateralis
Crus fornicis
Commissura fornicis
Trig coll
Calcar
Bulbus occipitali (posterio
Forceps occipitalis (major)

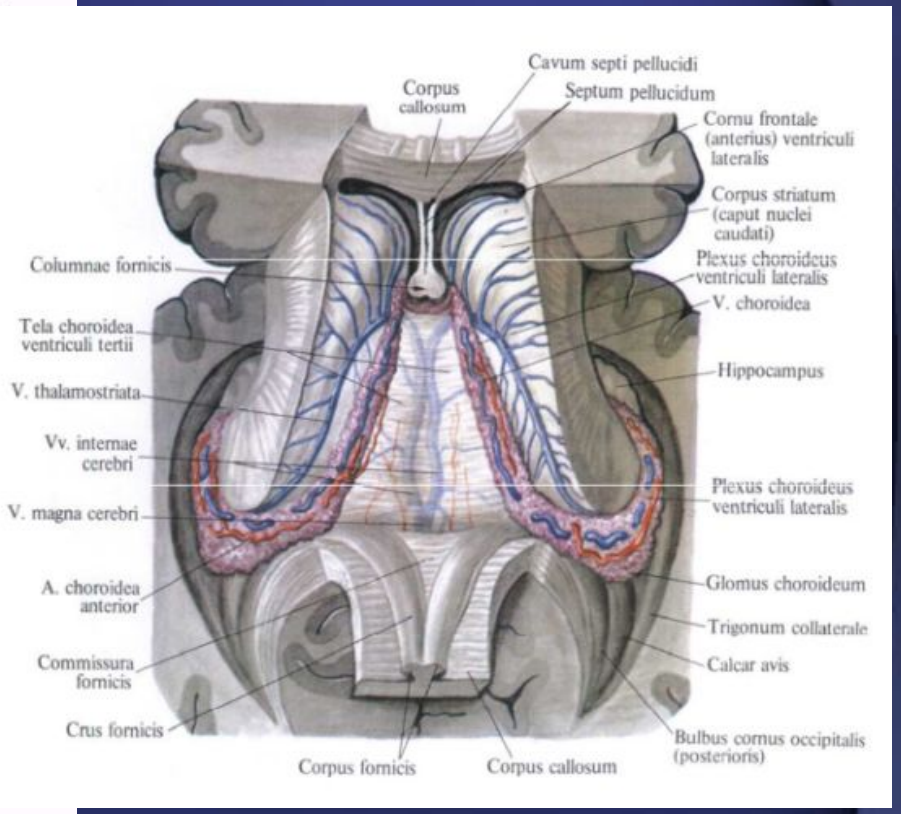
Cavum septi pellucidi
Corpus callosum
Septum pellucidum
Cornu frontale (anterius) ventriculi lateralis
Corpus striatum (caput nuclei caudati)
Columnae fornicis
Plexus choroideus ventriculi lateralis
V. choroidea
Tela choroidea ventriculi tertii
Hippocampus
V. thalamostriata
Vv. internae cerebri
Plexus choroideus ventriculi lateralis
V. magna cerebri
Glomus choroideum
A. choroidea anterior
Trigonum collaterale
Commissura fornicis
Calcar avis
Crus fornicis
Bulbus cornus occipitalis (posterioris)
Corpus fornicis
Corpus callosum

Базальные ядра полушарий

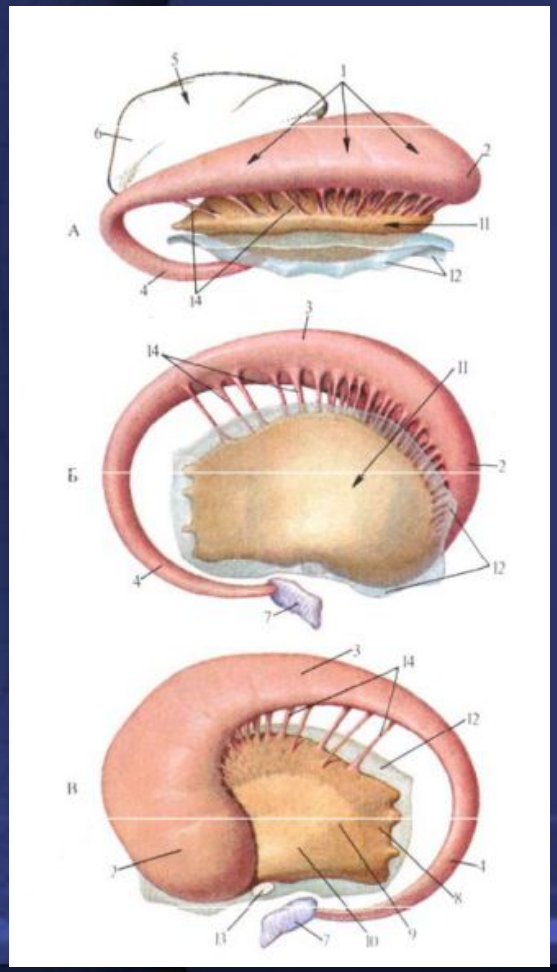

- Хвостатое ядро (nucleus caudatus): головка, тело, хвост
- Чечевицеобразное ядро (nucleus lentiformis): бледный шар (медиальный и латеральный), скорлупа
- Ограда
- Миндалевидное тело

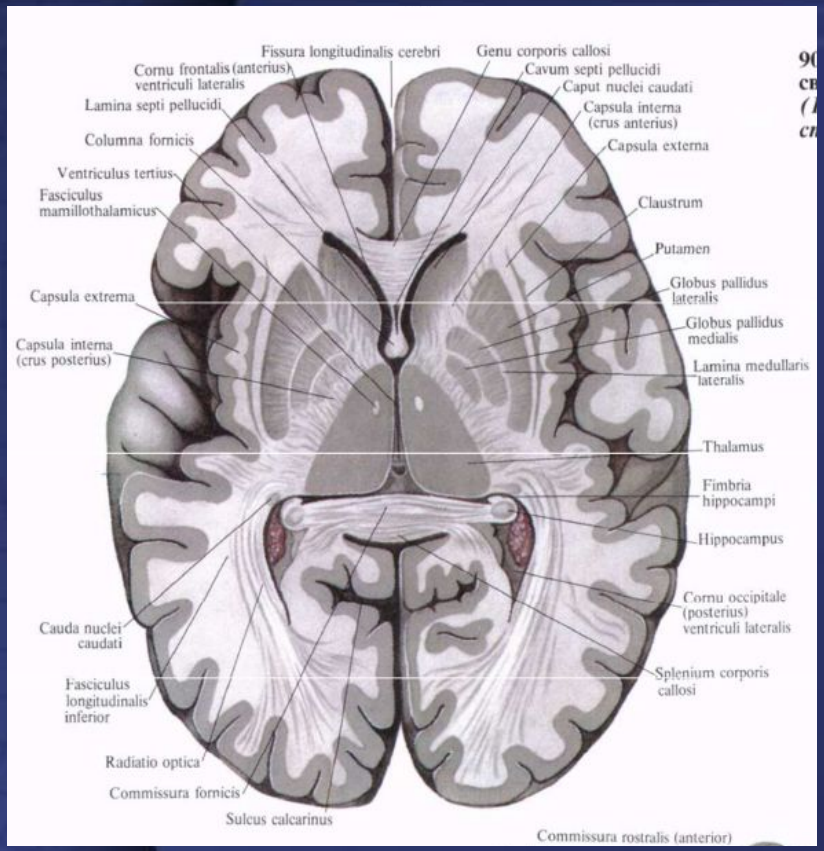
Fissura longitudinalis cerebri
Genu corporis callosi
Cornu frontalis (anterius) ventriculi lateralis
Cavum septi pellucidi
Caput nuclei caudati
Lamina septi pellucidi
Capsula interna (crus anterius)
Columna fornicis
Capsula externa
Ventriculus tertius
Fasciculus mamillothalamicus
Claustrum
Putamen
Globus pallidus lateralis
Capsula extrema
Globus pallidus medialis
Capsula interna (crus posterius)
Lamina medullaris lateralis
Thalamus
Fimbria hippocampi
Hippocampus
Cornu occipitale (posterius) ventriculi lateralis
Cauda nuclei caudati
Splenium corporis callosi
Fasciculus longitudinalis inferior
Radiatio optica
Commissura fornicis
Sulcus calcarinus
Commissura rostralis (anterior)

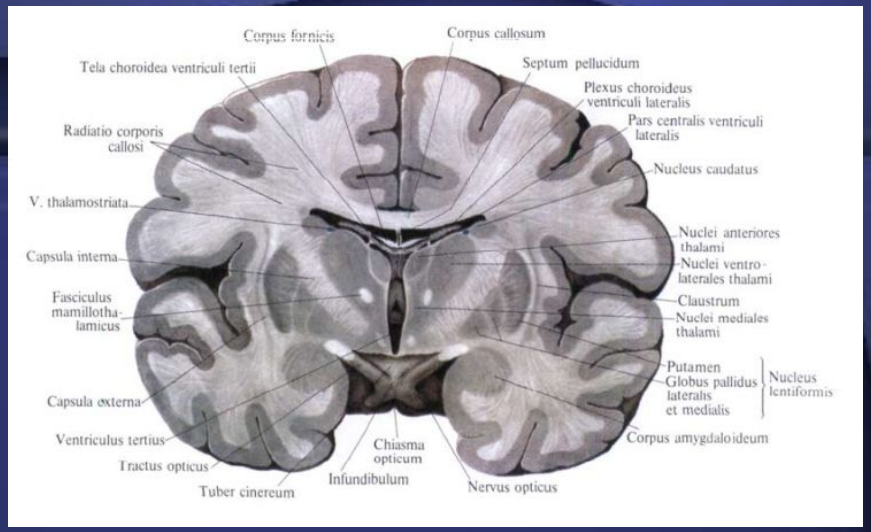
Corpus fornicis
Corpus callosum
Tela choroidea ventriculi tertii
Septum pellucidum
Plexus choroideus ventriculi lateralis
Pars centralis ventriculi lateralis
Radiatio corporis callosi
Nucleus caudatus
V. thalamostriata
Nuclei anteriores thalami
Capsula interna
Nuclei ventro-laterales thalami
Fasciculus mamillotha-lamicus
Claustrum
Nuclei mediales thalami
Putamen
Globus pallidus lateralis et medialis
Nucleus lentiformis
Capsula externa
Corpus amygdaloideum
Ventriculus tertius
Chiasma opticum
Tractus opticus
Infundibulum
Tuber cinereum
Nervus opticus

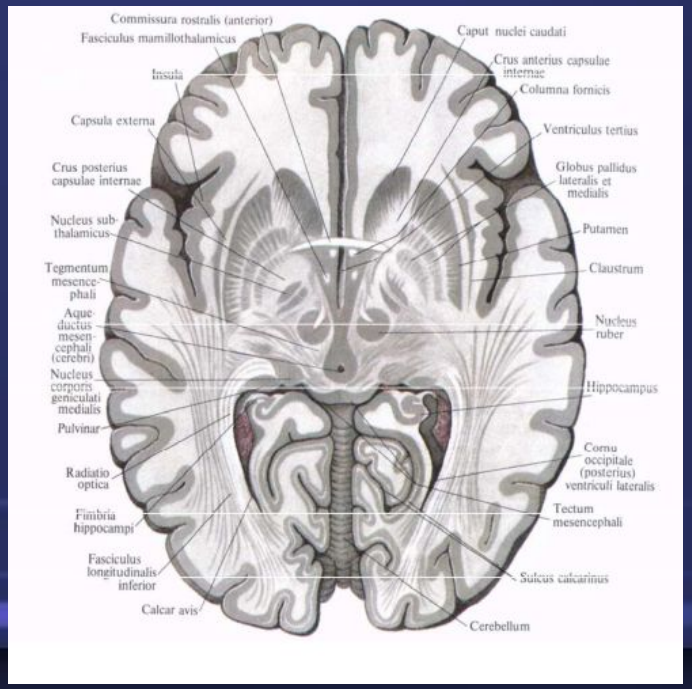
Commissura rostralis (anterior)
Fasciculus mamillothalamicus
Caput nuclei caudati
Crus anterius capsulae internae
Insula
Columna fornicis
Capsula externa
Ventriculus tertius
Crus posterius capsulae internae
Globus pallidus lateralis et medialis
Nucleus sub-thalamicus
Putamen
Tegmentum mesence-phali
Claustrum
Aque-ductus mesen-cephali (cerebri)
Nucleus ruber
Nucleus corporis geniculati medialis
Hippocampus
Pulvinar
Cornu occipitale (posterius) ventriculi lateralis
Radiatio optica
Tectum mesencephali
Fimbria hippocampi
Fasciculus longitudinalis inferior
Sulcus calcarinus
Calcar avis
Cerebellum

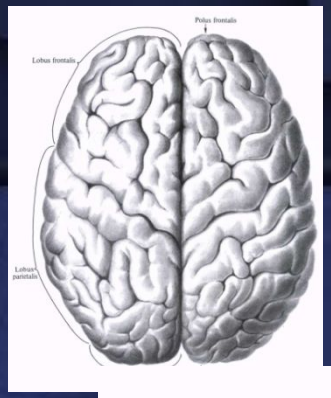
Polus frontalis
Lobus frontalis
Lobus parietalis

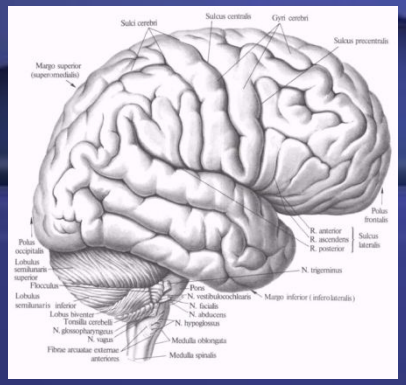
Sulci cerebri
Sulcus centralis
Gyri cerebri
Sulcus precentralis
Margo superior (superomedialis)
Polus frontalis
R. anterior
R. ascendens
R. posterior
Sulcus lateralis
Polus occipitalis
Lobulus semilunaris superior
N. trigeminus
Flocculus
Pons
N. vestibulocochlearis
Margo inferior (inferolateralis)
Lobulus semilunaris inferior
N. facialis
Lobus biventer
N. abducens
Tonsilla cerebelli
N. hypoglossus
N. glossopharyngeus
N. vagus
Medulla oblongata
Fibrae arcuatae externae anteriores
Medulla spinalis

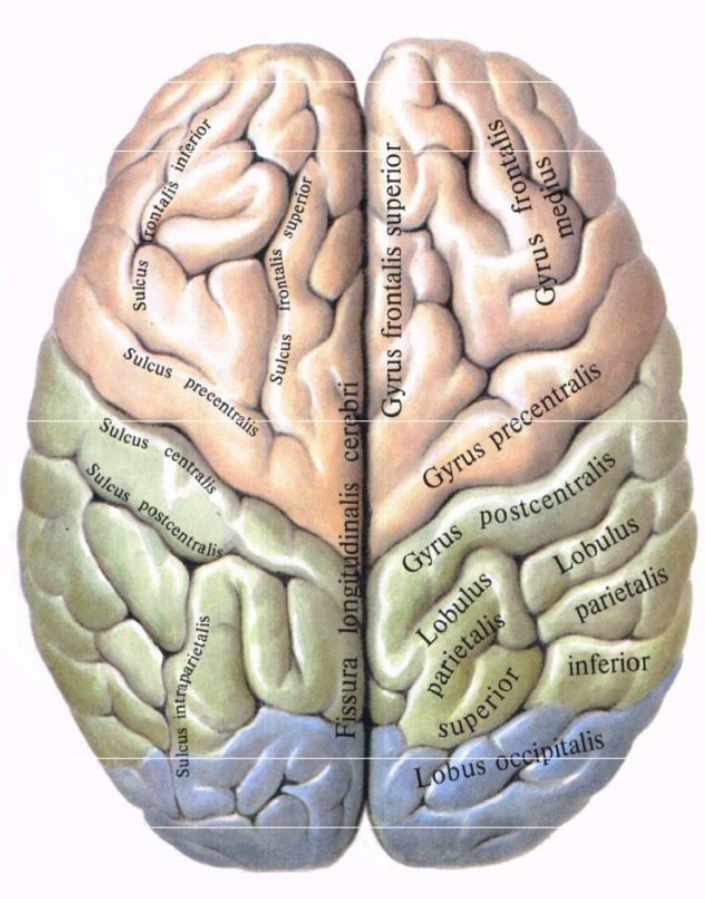
Sulcus frontalis inferior
Sulcus frontalis superior
Gyrus frontalis superior
Gyrus frontalis medius
Sulcus precentralis
Gyrus precentralis
Sulcus centralis
Sulcus postcentralis
Gyrus postcentralis
Fissura longitudinalis cerebri
Lobulus parietalis inferior
Lobulus parietalis superior
Sulcus intraparietalis
Lobus occipitalis

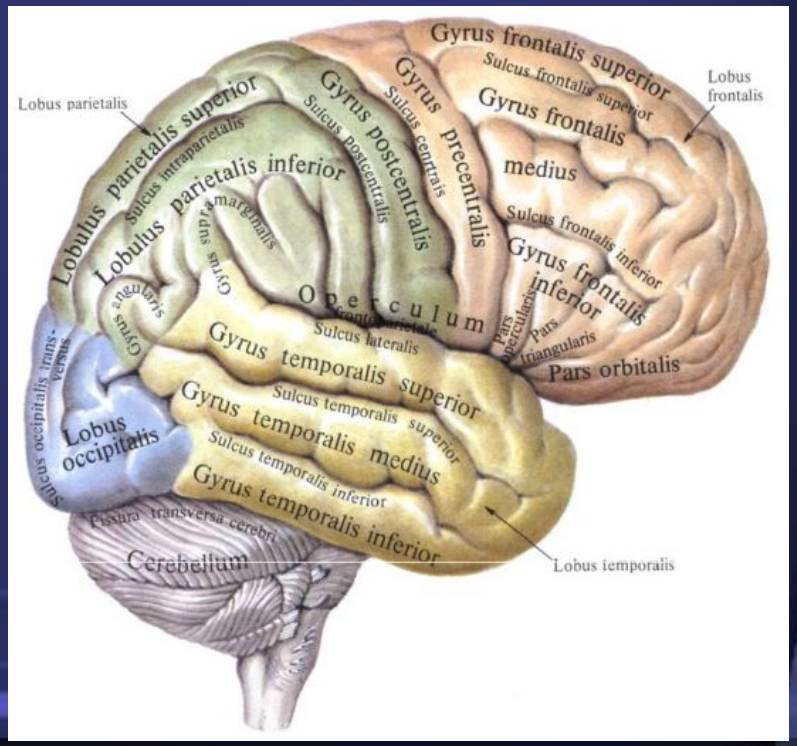
Gyrus frontalis superior
Sulcus frontalis superior
Lobus frontalis
Lobus parietalis
Lobulus parietalis superior
Sulcus intraparietalis
Gyrus postcentralis
Sulcus postcentralis
Sulcus centralis
Gyrus precentralis
Gyrus frontalis medius
Lobulus parietalis inferior
Gyrus supramarginalis
Sulcus frontalis inferior
Gyrus frontalis inferior
Gyrus angularis
Operculum
Pars opercularis
Pars triangularis
Pars orbitalis
Sulcus lateralis
Gyrus temporalis superior
Sulcus temporalis superior
Sulcus occipitalis transversus
Lobus occipitalis
Gyrus temporalis medius
Sulcus temporalis inferior
Gyrus temporalis inferior
Fissura transversa cerebri
Cerebellum
Lobus temporalis

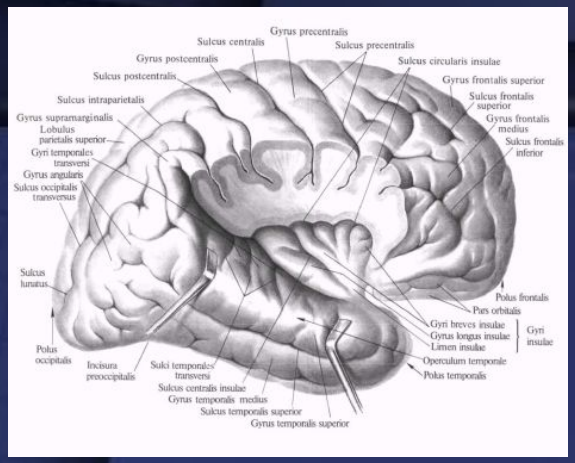
Gyrus precentralis
Sulcus centralis
Sulcus precentralis
Gyrus postcentralis
Sulcus circularis insulae
Sulcus postcentralis
Gyrus frontalis superior
Sulcus intraparietalis
Sulcus frontalis superior
Gyrus supramarginalis
Gyrus frontalis medius
Lobulus parietalis superior
Sulcus frontalis inferior
Gyri temporales transversi
Gyrus angularis
Sulcus occipitalis transversus
Sulcus lunatus
Polus frontalis
Pars orbitalis
Gyri breves insulae
Gyrus longus insulae
Gyri insulae
Limen insulae
Operculum temporale
Polus temporalis
Polus occipitalis
Incisura preoccipitalis
Suki temporales transversi
Sulcus centralis insulae
Gyrus temporalis medius
Sulcus temporalis superior
Gyrus temporalis superior

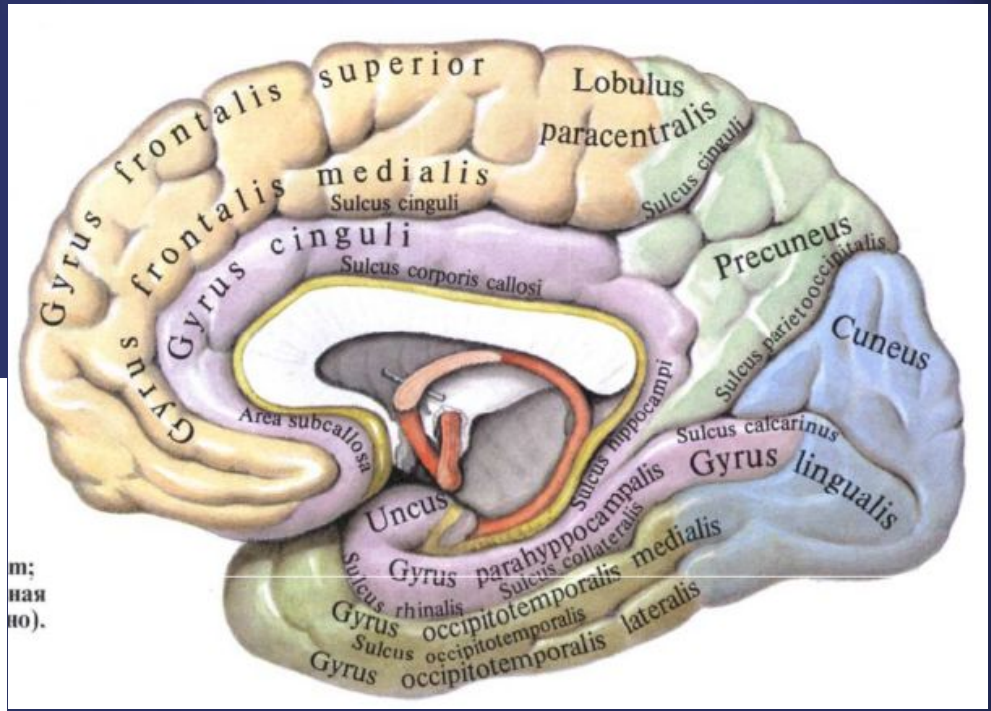
Gyrus frontalis superior
Lobulus paracentralis
Gyrus frontalis medialis
Sulcus cinguli
Sulcus cinguli
Gyrus cinguli
Sulcus corporis callosi
Precuneus
Sulcus parietooccipitalis
Cuneus
Gyrus hippocampi
Area subcallosa
Sulcus calcarinus
Gyrus lingualis
Uncus
Sulcus hippocampalis
Sulcus collateralis
Gyrus parahyppocampalis medialis
Sulcus rhinalis
Gyrus occipitotemporalis
Sulcus occipitotemporalis
Gyrus occipitotemporalis lateralis

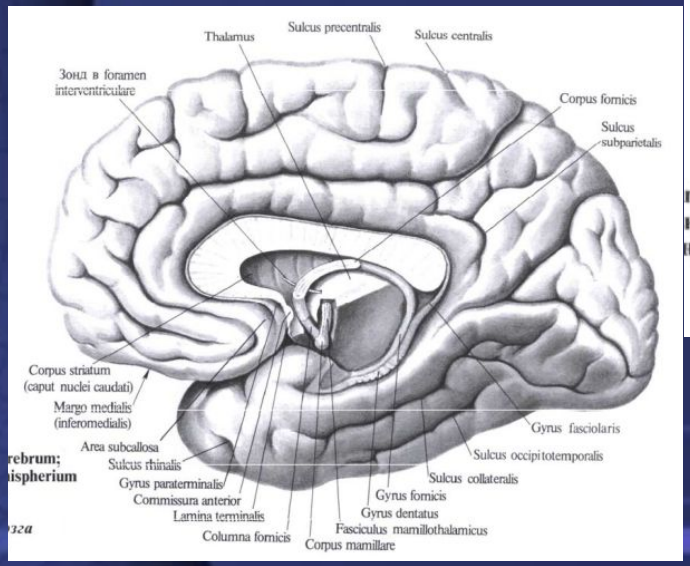
Thalamus
Sulcus precentralis
Sulcus centralis
Зонд в foramen interventriculare
Corpus fornicis
Sulcus subparietalis
Corpus striatum (caput nuclei caudati)
Margo medialis (inferomedialis)
Gyrus fasciolaris
Area subcallosa
Sulcus rhinalis
Sulcus occipitotemporalis
Gyrus paraterminalis
Sulcus collateralis
Commissura anterior
Gyrus fornicis
Lamina terminalis
Gyrus dentatus
Columna fornicis
Fasciculus mamillothalamicus
Corpus mamillare

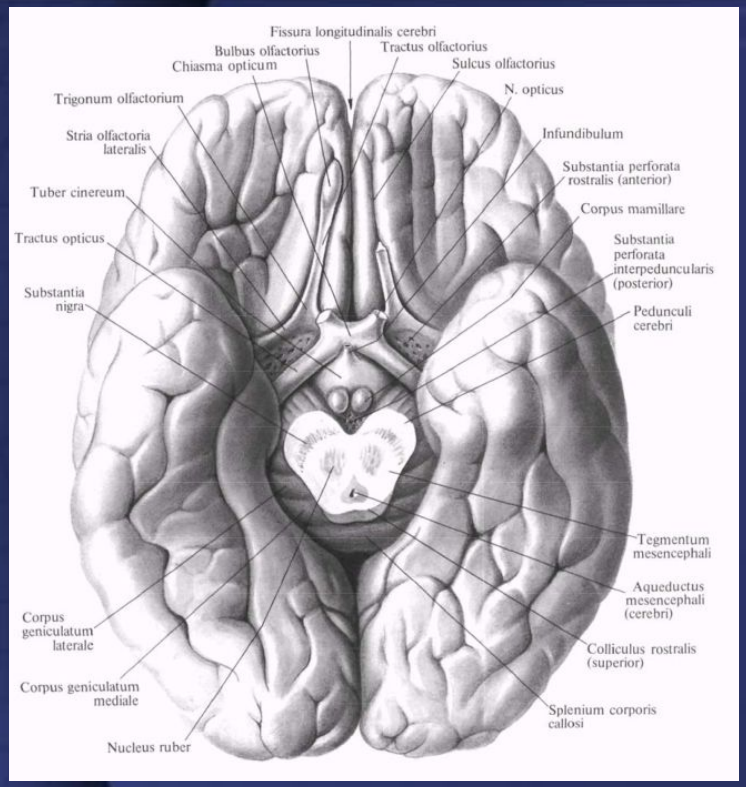
Fissura longitudinalis cerebri
Bulbus olfactorius
Tractus olfactorius
Chiasma opticum
Sulcus olfactorius
N. opticus
Trigonum olfactorium
Infundibulum
Stria olfactoria lateralis
Substantia perforata rostralis (anterior)
Tuber cinereum
Corpus mamillare
Tractus opticus
Substantia perforata interpeduncularis (posterior)
Substantia nigra
Pedunculi cerebri
Tegmentum mesencephali
Aqueductus mesencephali (cerebri)
Corpus geniculatum laterale
Colliculus rostralis (superior)
Corpus geniculatum mediale
Splenium corporis callosi
Nucleus ruber

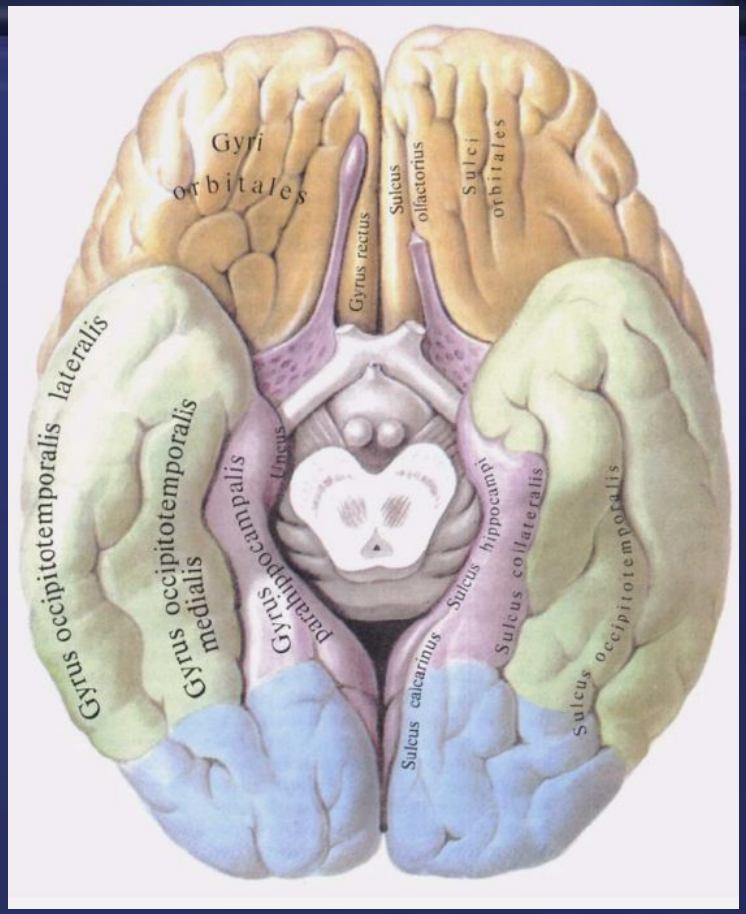
Gyri orbitales
Gyrus rectus
Sulcus olfactorius
Sulci orbitales
Gyrus occipitotemporalis lateralis
Gyrus occipitotemporalis medialis
Gyrus parahippocampalis
Uncus
Sulcus hippocampi
Sulcus collateralis
Sulcus occipitotemporalis
Sulcus calcarinus

Строение коры головного мозга

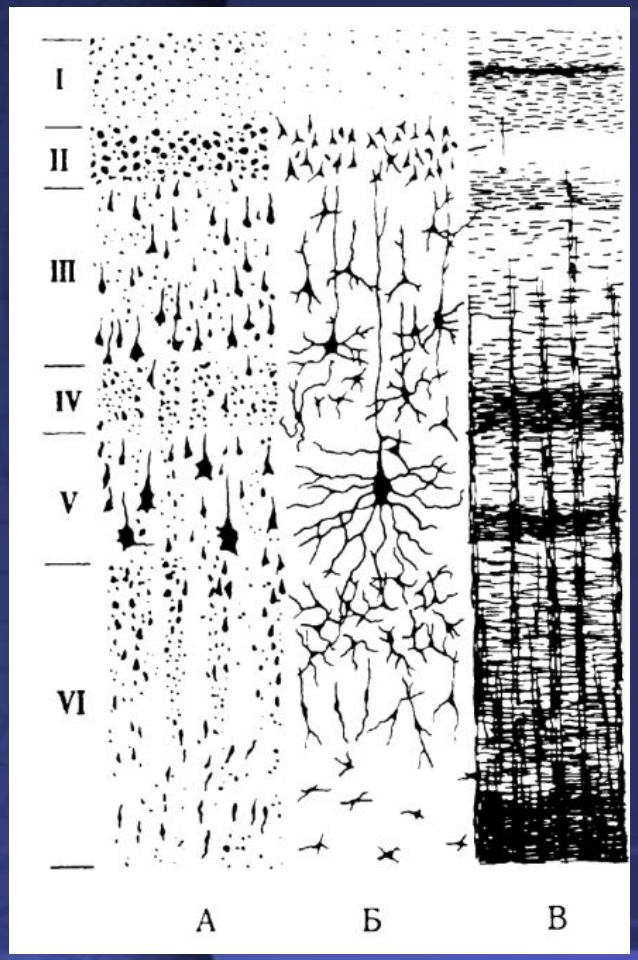

- Слои коры:

1. Молекулярная пластинка
2. Наружная зернистая пластинка
3. Наружная пирамидная пластинка
4. Внутренняя зернистая пластинка
5. Внутренняя пирамидная пластинка
6. Полиморфный слой (мультиформные клетки)

1-3 – ассоциативные нейроны;

4 – проекционные волокна от ядер таламуса и коленчатых тел;

5 – начинаются корково-спинномозговые и корково-ядерные тракты

6- ассоциативные и комиссуральные волокна

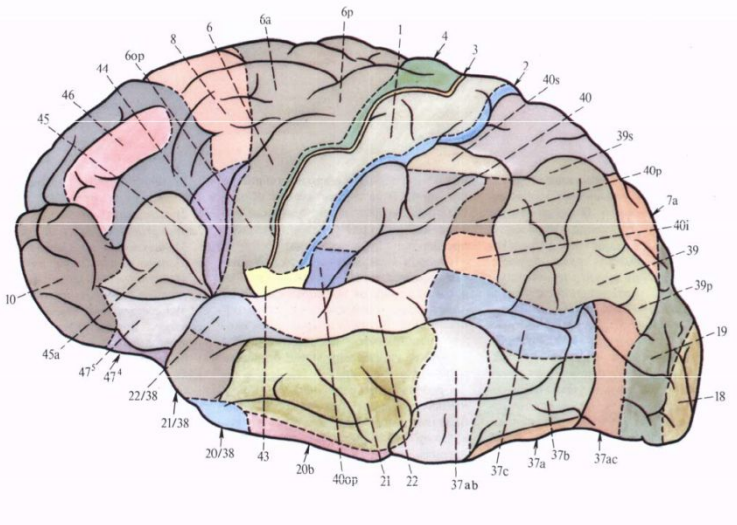

896. Цитоархитектонические поля коры полушарий большого мозга. (Верхнелатеральная поверхность. По данным Института мозга РАМН.)

1 — area postcentralis intermedia; 4 — area gigantopyramidalis; 3 — area postcentralis oralis; 2 — area postcentralis caudalis; 40s — subarea supramarginalis; 40 — area supramarginalis; 39s — subarea angularis superior; 40p — subarea supramarginalis posterior; 7a — subarea parietooccipitalis; 40i — subarea supramarginalis inferior; 39 — area angularis; 39p — subarea angularis posterior; 19 — area preoccipitalis; 18 — area occipitalis; 37ac — area temporoparietooccipitalis posterior; 37b — area temporoparietooccipitalis centralis; 37a — area temporoparietooccipitalis inferior; 37c — area temporoparietooccipitalis superior; 37ab — area temporoparietooccipitalis anterior; 22 — area temporalis superior; 21 — area temporalis media; 40op — subarea supramarginalis opercularis; 20b — area temporalis basalis; 43 — area postcentralis subcentralis; 20/38 — area temporalis basalis polaris; 21/38 — area temporalis media polaris; 22/38 — area temporalis superior polaris; 47^4 — subarea orbitalis; 47^5 — subarea orbitalis; 45a — subarea triangularis; 10 — area frontopolaris; 45 — area triangularis; 46 — area frontalis media; 44 — area opercularis; 6op — subarea opercularis; 8 — area frontalis intermedia; 6 — area frontalis agranularis; 6a — subarea anterior; 6p — subarea posterior.

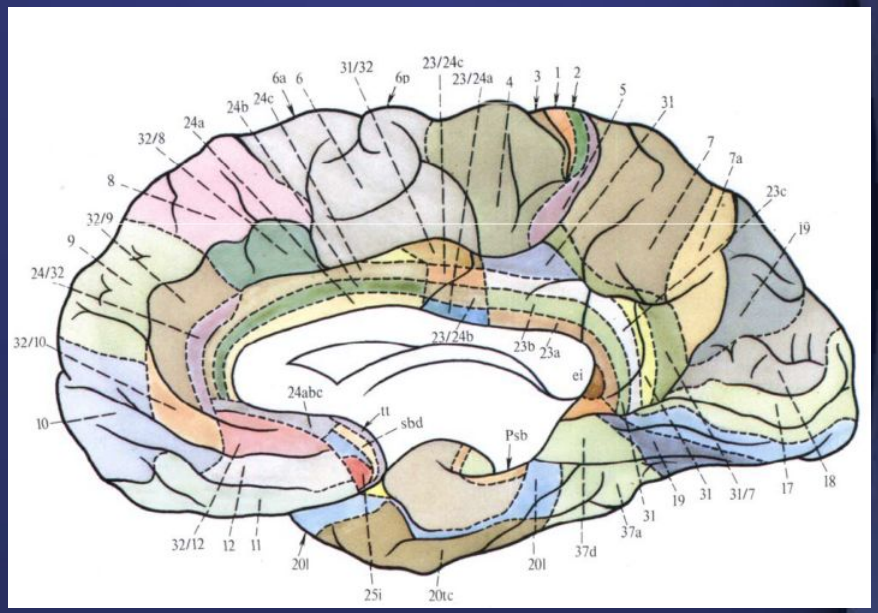

Чувствительный гомункулус. Показаны проекции частей тела человека на область коркового конца анализатора общей чувствительности, локализующегося в коре постцентральной извилины большого мозга; разрез полушария во фронтальной плоскости (схема).

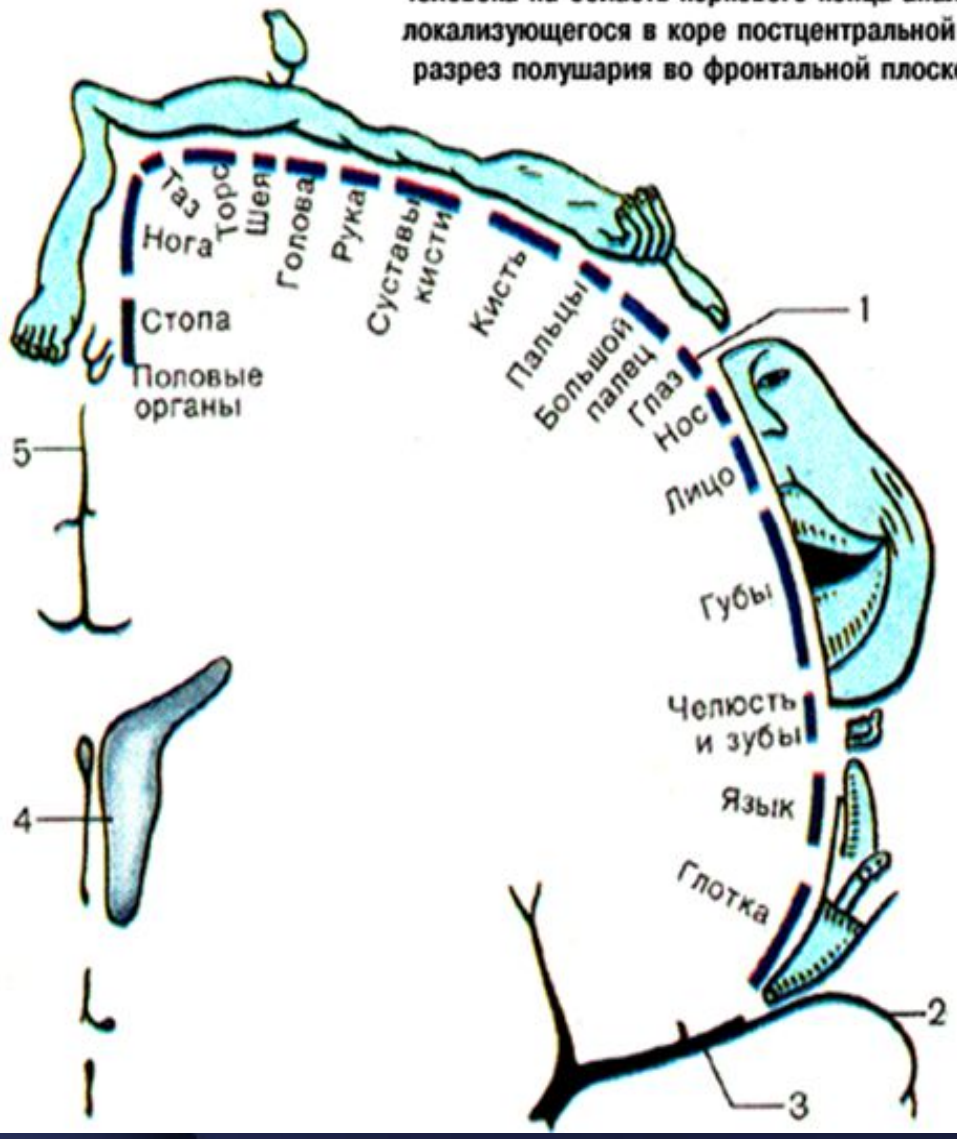

1 – facies superolateralis hemispherii (gyrus postcentralis);
2 – lobus temporalis;
3 – sul. lateralis;
4 – ventriculus lateralis;
5 – fissura longitudinalis cerebri.

Двигательный гомункулус. Показаны проекции частей тела человека на область коркового конца двигательного анализатора, локализующегося в коре предцентральной извилины большого мозга; разрез полушария во фронтальной плоскости (схема).

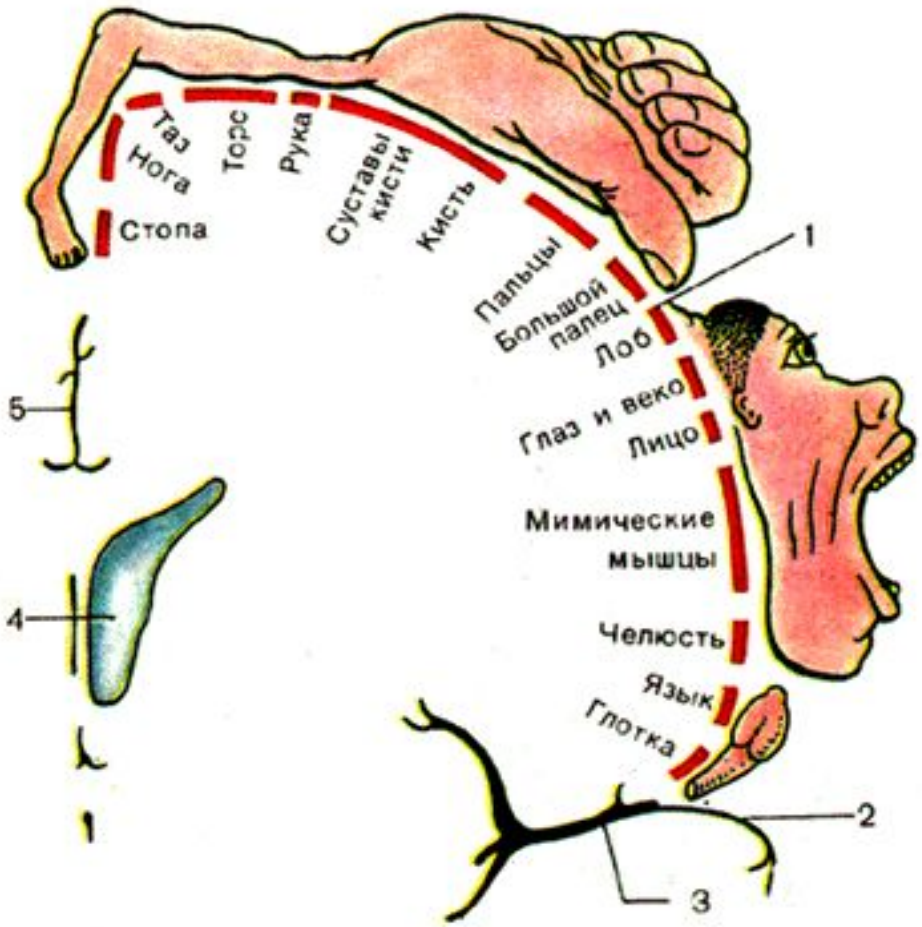

1 — facies superolateralis hernispherii (gyrus precentralis);
2 — lobus temporalis;
3 — sul. lateralis;
4 — ventriculi lateralis;
5 — fissura longitudinalis cerebri.

Основание головного мозга; выход корешков черепных нервов.

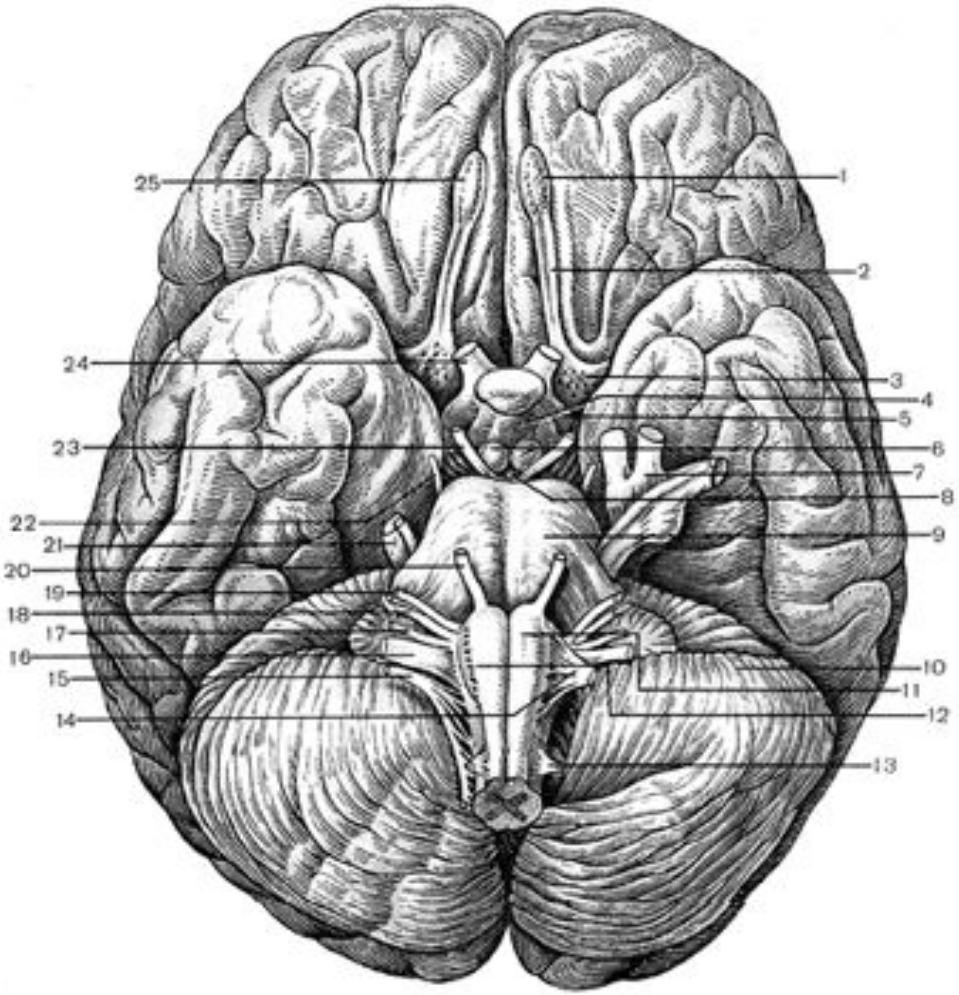

1 — bulbus olfactorius;
2 — tr. olfactorius;
3 — substantia perforata rostralis [anterior];
4 — tuber cinereum;
5 — tr. opticus;
6 — corpora mamillaris;
7 — gangi. trigeminale;
8 — substantia perforata interpeduncularis (posterior);
9 — pons;
10 — cerebellum;
11 — pyramis;
12 — oliva;
13 — nn.spinales;
14 — n. hypoglossus;
15 — n. accessorius;
16 — n.vagus;
17 — n. glossopharyngeus;
18 — n. vestibulocochlearis;
19 — n. facialis;
20 — n. abducens;
21 — n. trigeminus;
22 — n. trochlearis;
23 — n. oculomotorius;
24 — n. opticus;
25 — n. olfactorii.

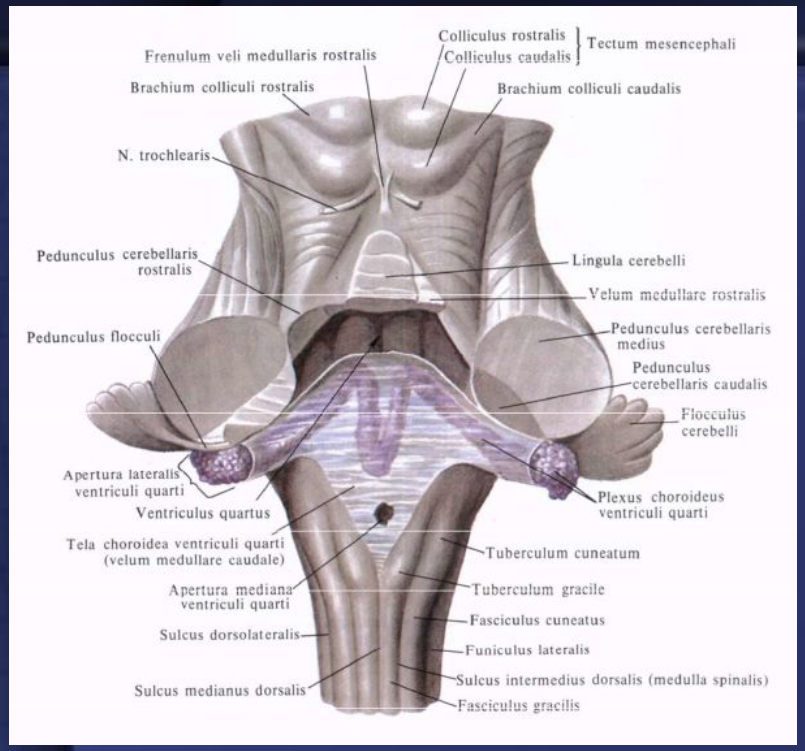
Colliculus rostralis
Colliculus caudalis
Tectum mesencephali
Frenulum veli medullaris rostralis
Brachium colliculi rostralis
Brachium colliculi caudalis
N. trochlearis
Pedunculus cerebellaris rostralis
Lingula cerebelli
Velum medullare rostralis
Pedunculus cerebellaris medius
Pedunculus flocculi
Pedunculus cerebellaris caudalis
Flocculus cerebelli
Apertura lateralis ventriculi quarti
Plexus choroideus ventriculi quarti
Ventriculus quartus
Tela choroidea ventriculi quarti (velum medullare caudale)
Tuberculum cuneatum
Apertura mediana ventriculi quarti
Tuberculum gracile
Fasciculus cuneatus
Sulcus dorsolateralis
Funiculus lateralis
Sulcus intermedius dorsalis (medulla spinalis)
Sulcus medianus dorsalis
Fasciculus gracilis

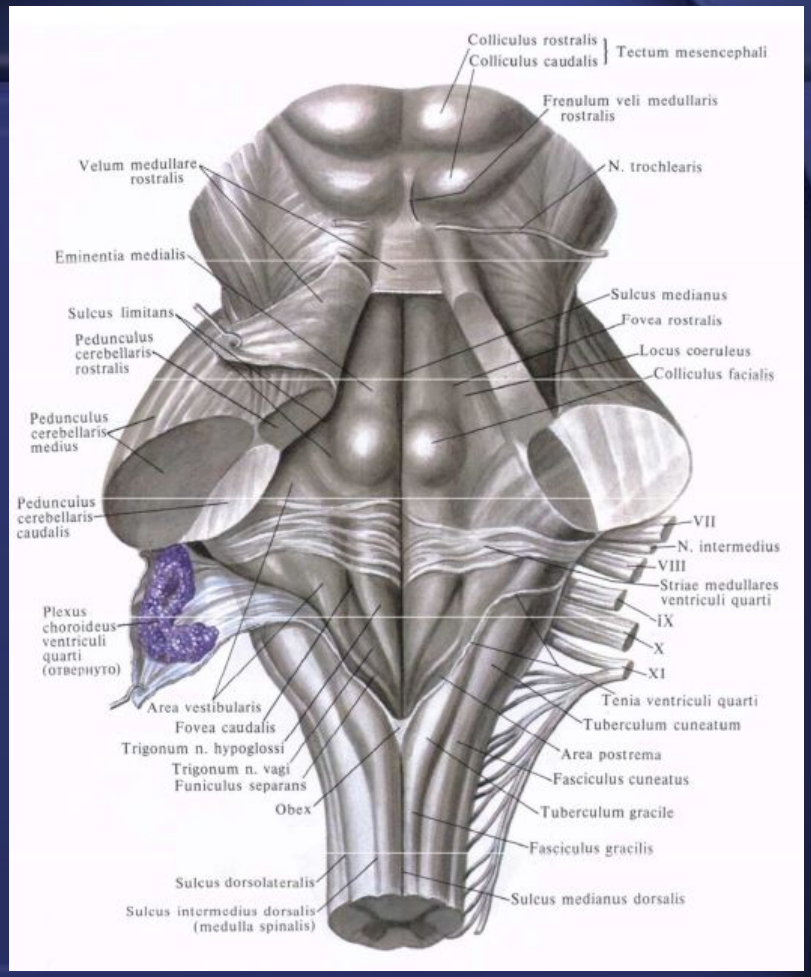
Colliculus rostralis
Colliculus caudalis
Tectum mesencephali
Frenulum veli medullaris rostralis
Velum medullare rostralis
N. trochlearis
Eminentia medialis
Sulcus medianus
Fovea rostralis
Sulcus limitans
Pedunculus cerebellaris rostralis
Locus coeruleus
Colliculus facialis
Pedunculus cerebellaris medius
Pedunculus cerebellaris caudalis
VII
N. intermedius
VIII
Striae medullares ventriculi quarti
Plexus choroideus ventriculi quarti (отвернуто)
IX
X
XI
Tenia ventriculi quarti
Area vestibularis
Tuberculum cuneatum
Fovea caudalis
Trigonum n. hypoglossi
Area postrema
Trigonum n. vagi
Fasciculus cuneatus
Funiculus separans
Obex
Tuberculum gracile
Fasciculus gracilis
Sulcus dorsolateralis
Sulcus medianus dorsalis
Sulcus intermedius dorsalis (medulla spinalis)

Glebova N V
26-Dec-1974
9678
08-Nov-2006 08:56
Intera 1.0T
ADC

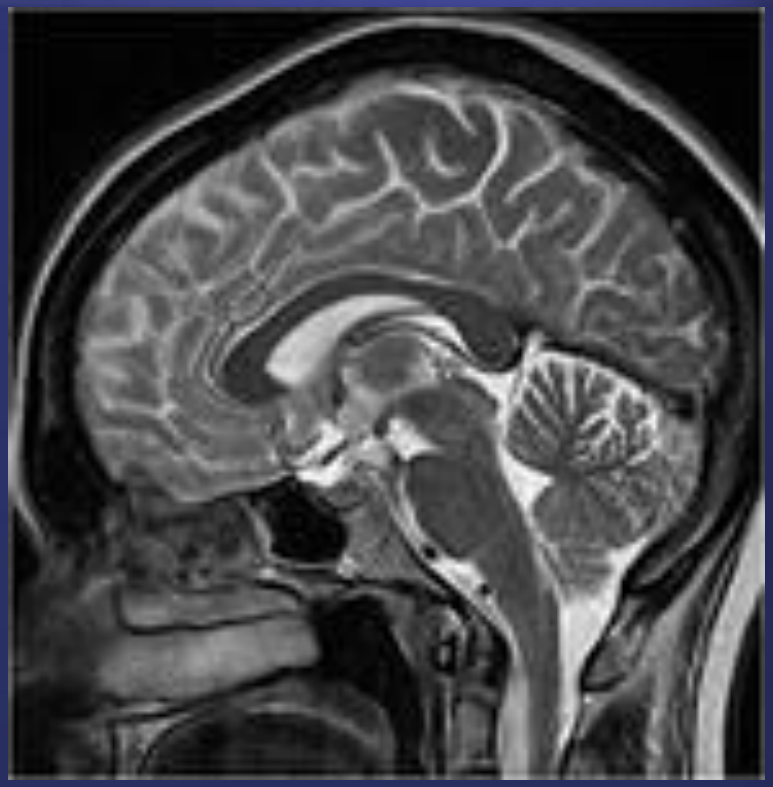

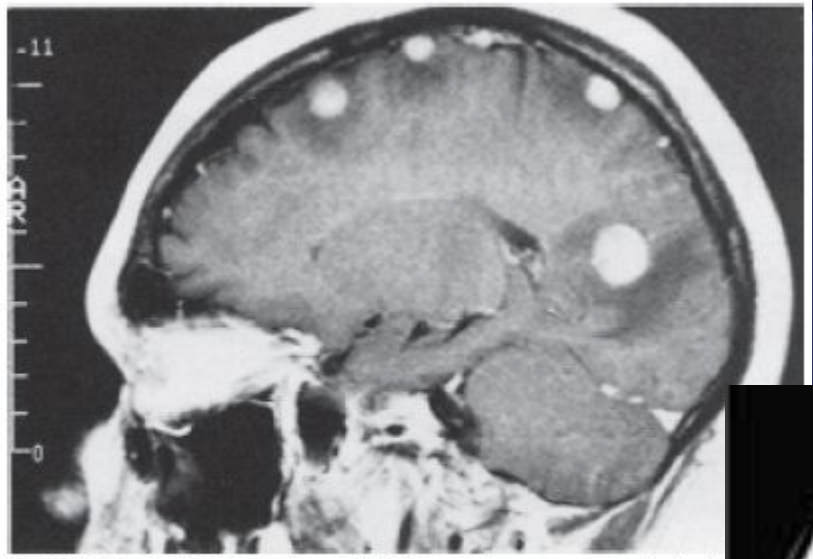

FIGURE 1: Gadolinium-enhanced MRI scan demonstrating multiple br
tastases. Note the edema surrounding each lesion.

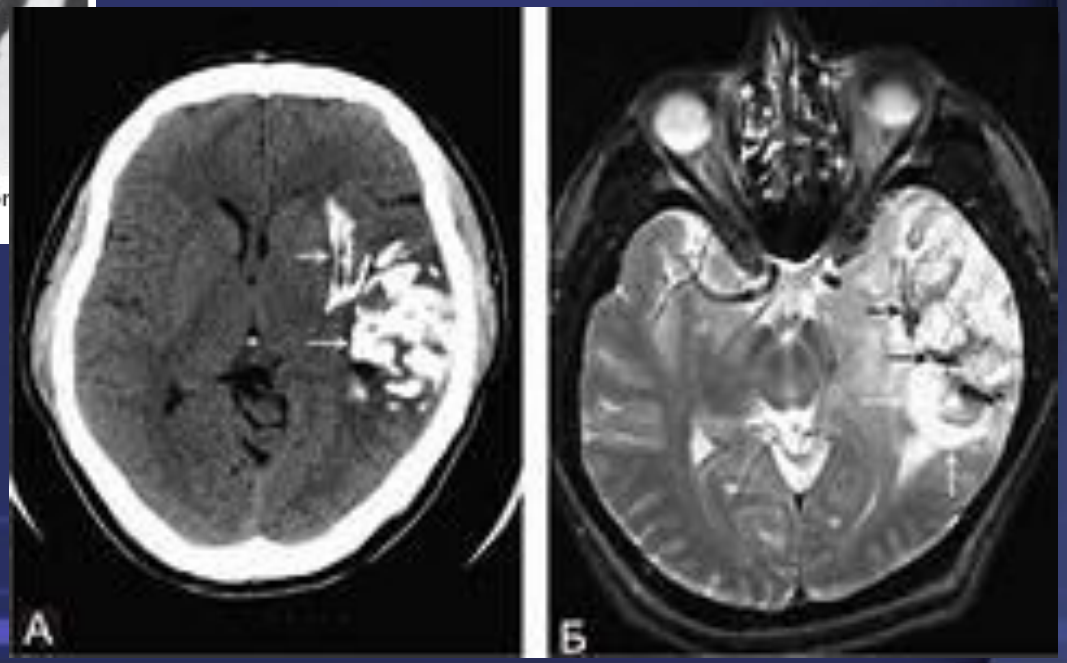

Благодарю за внимание!