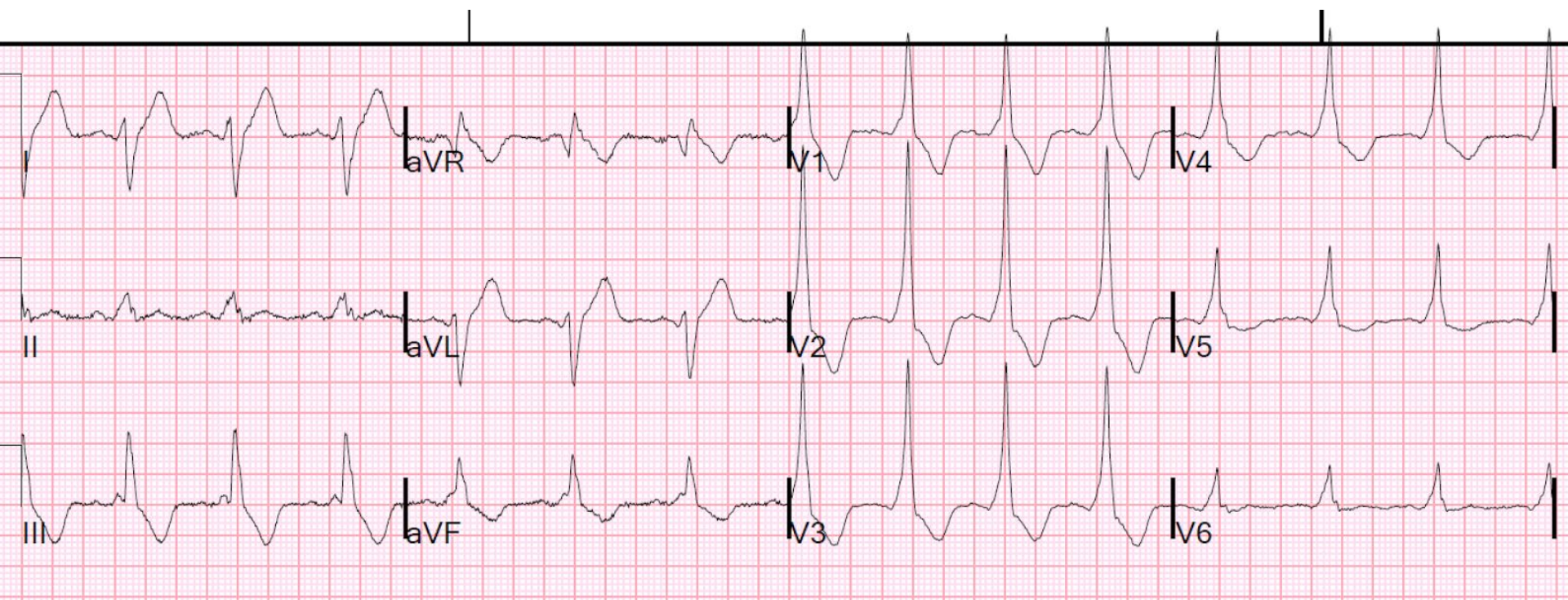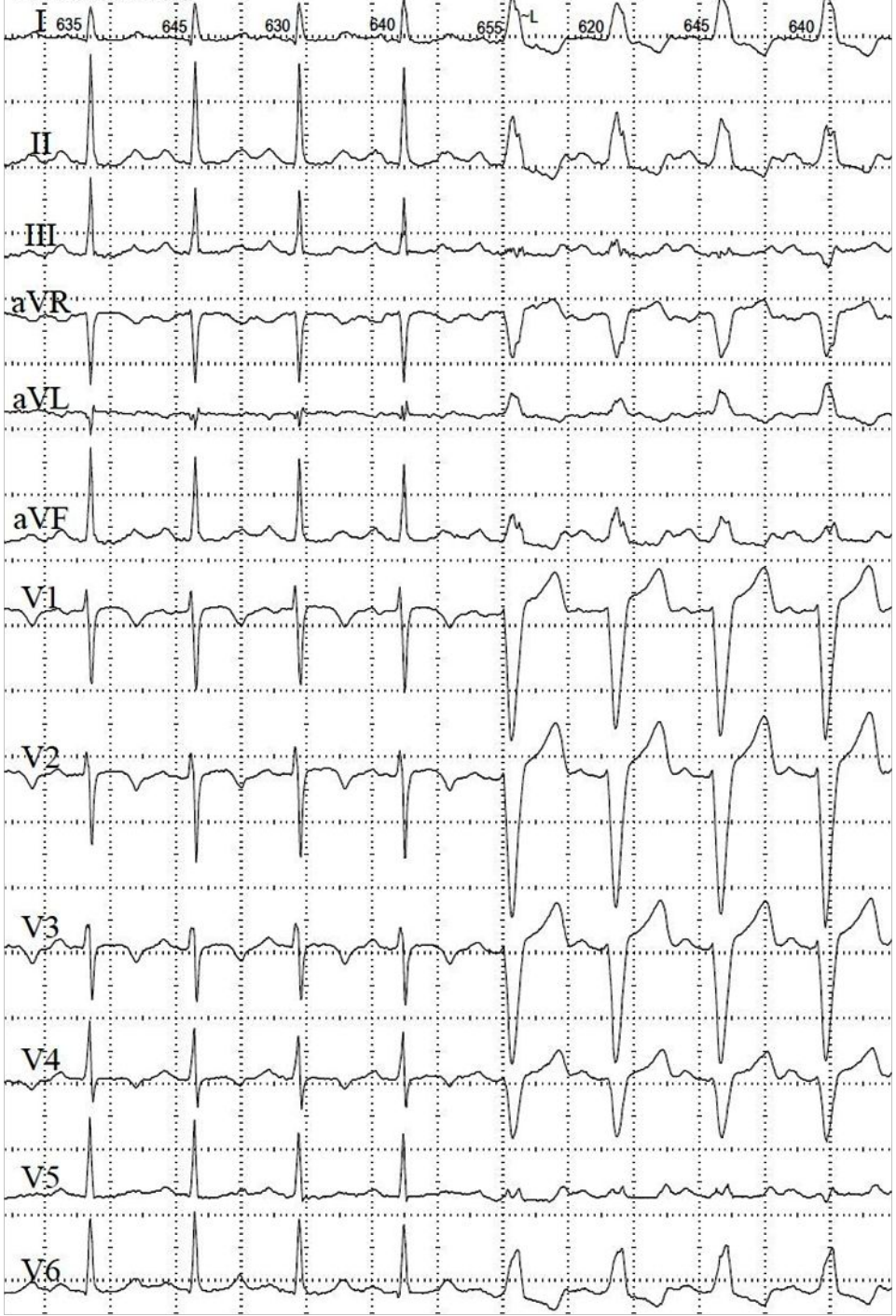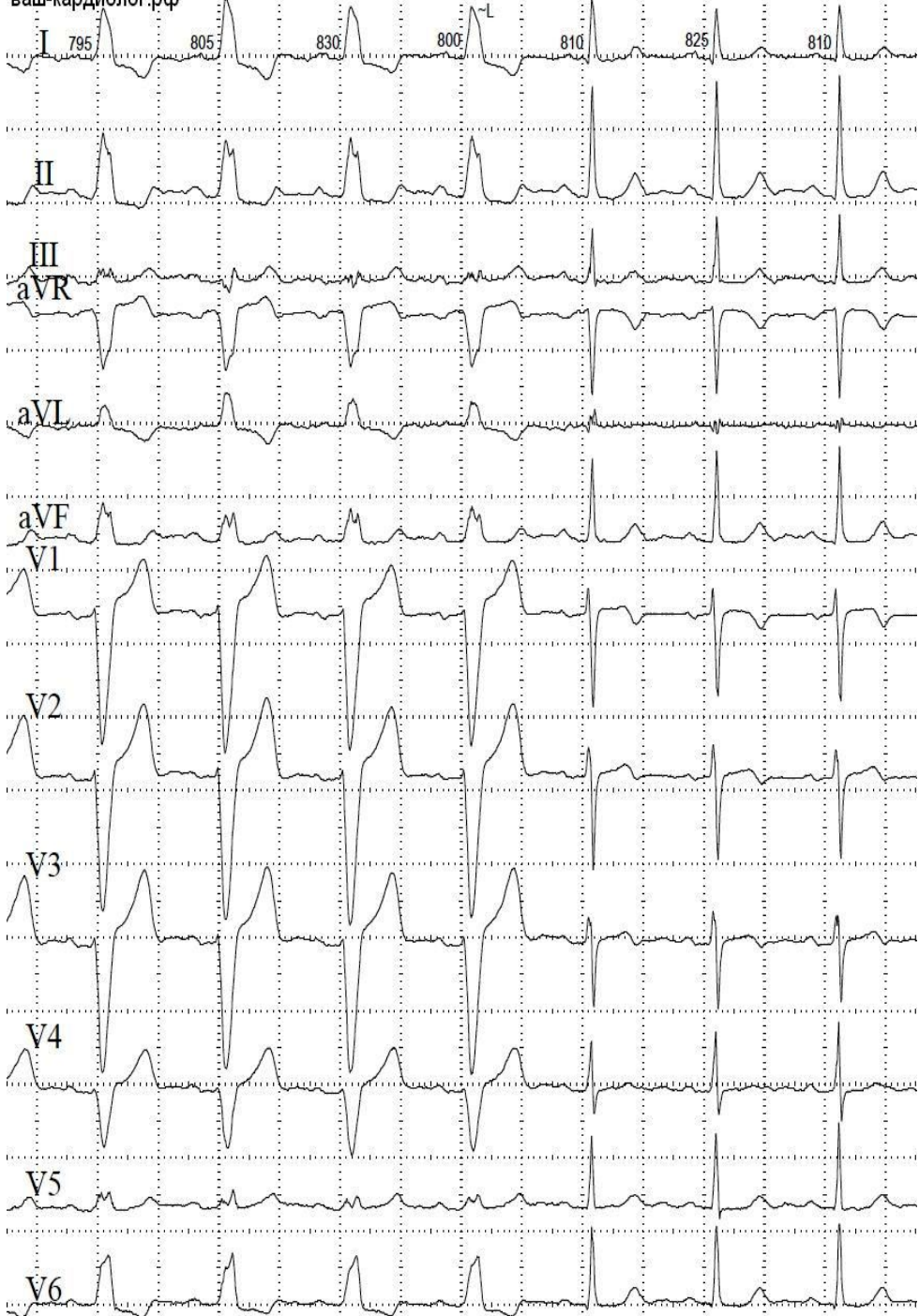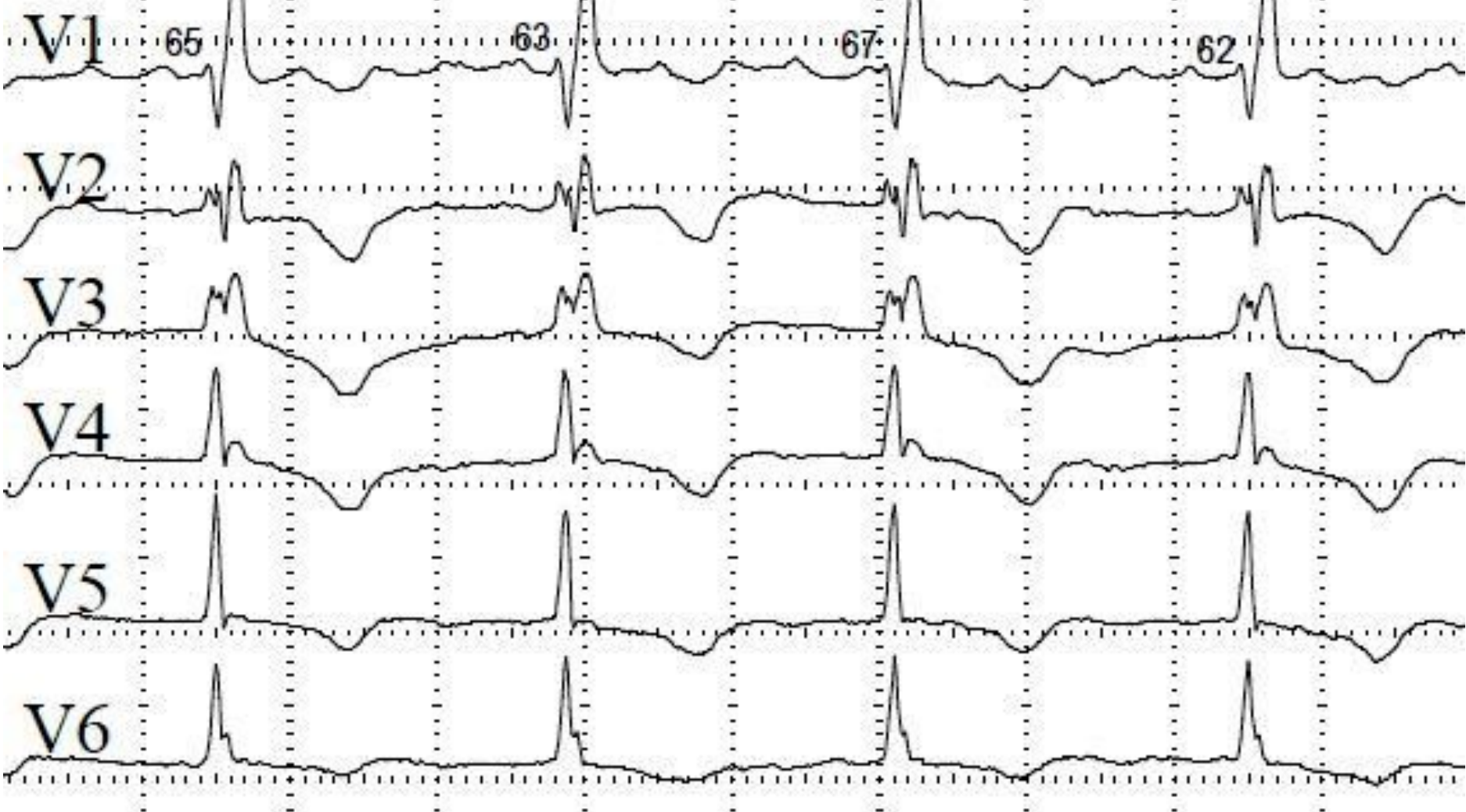
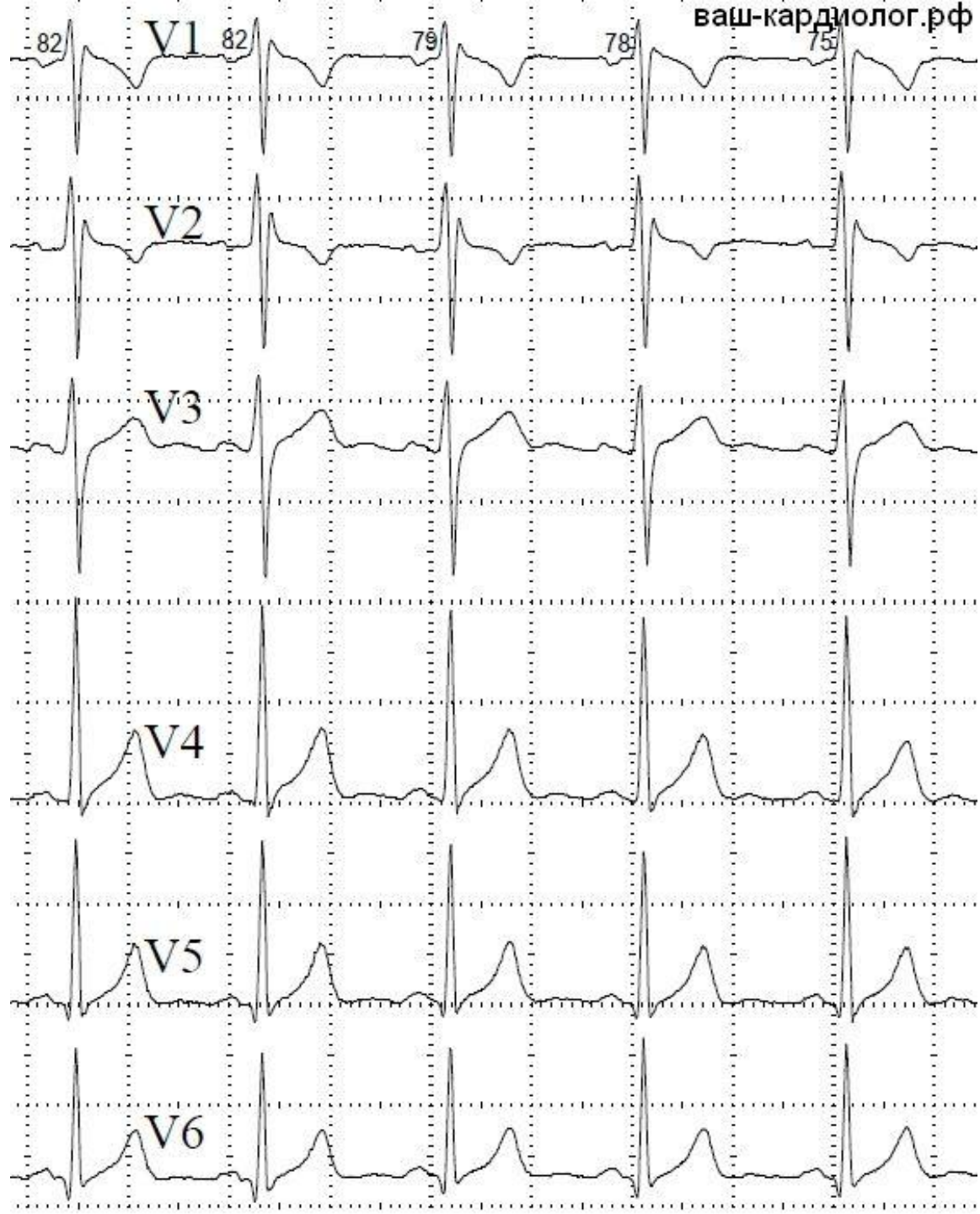
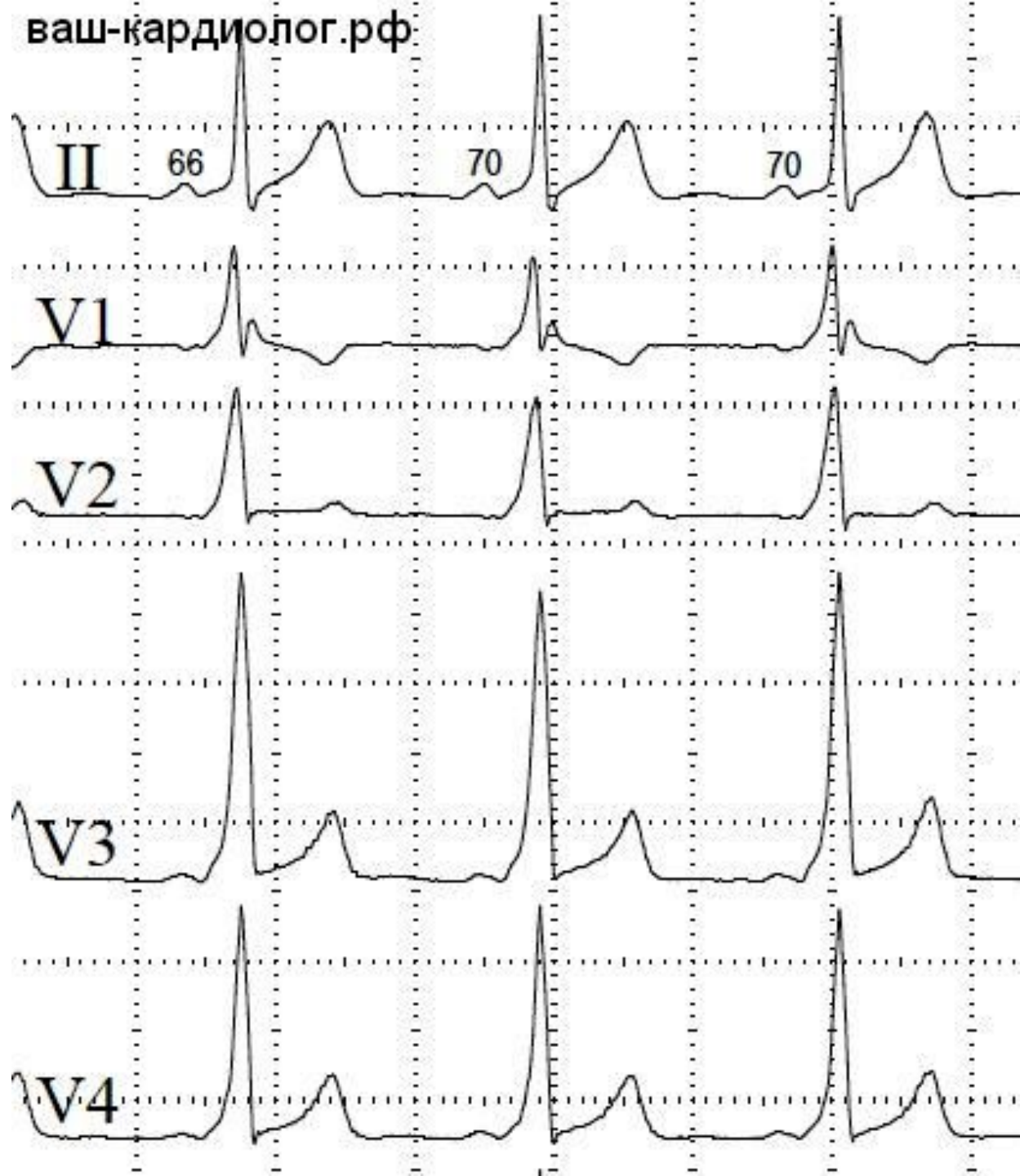


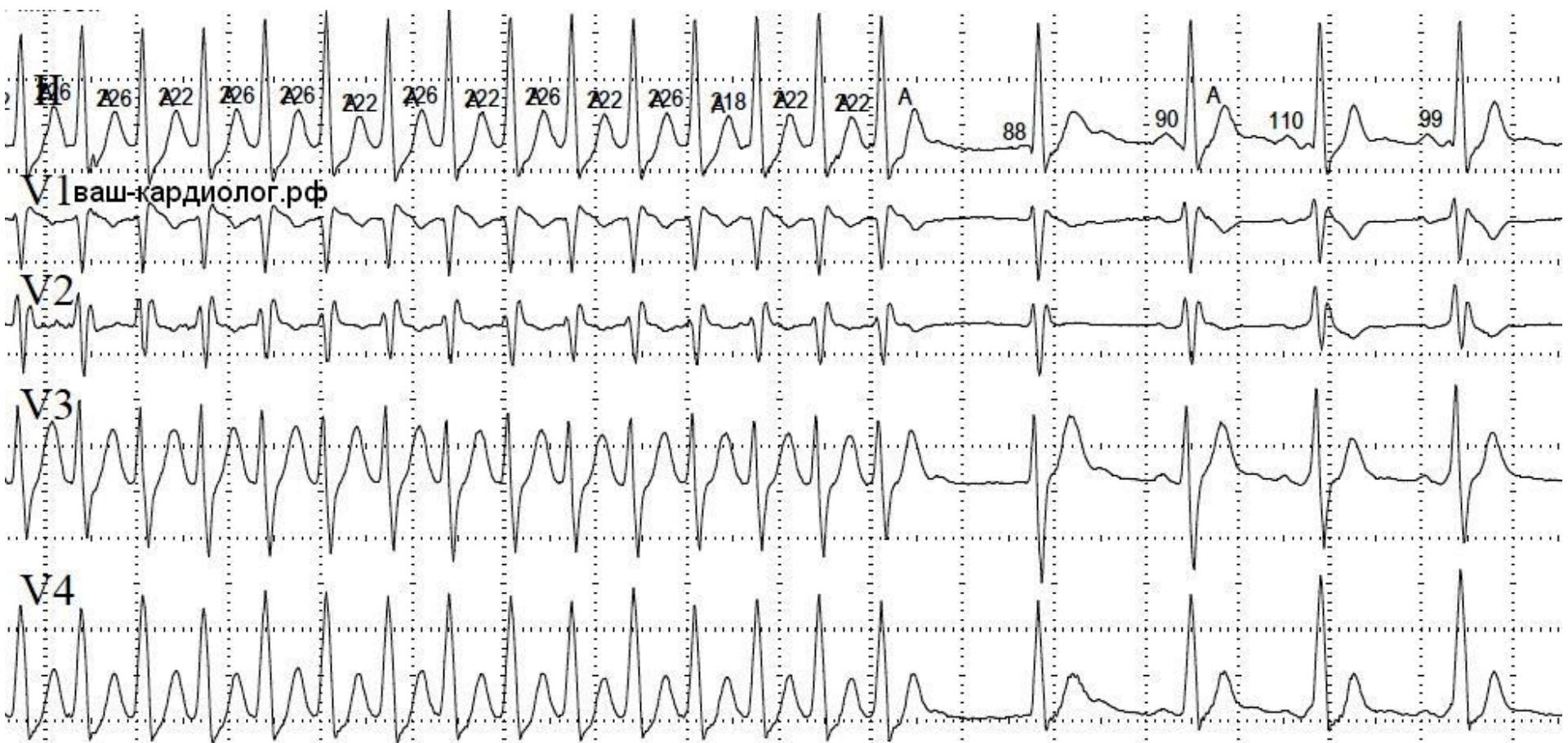
ваш-кардиолог.рф



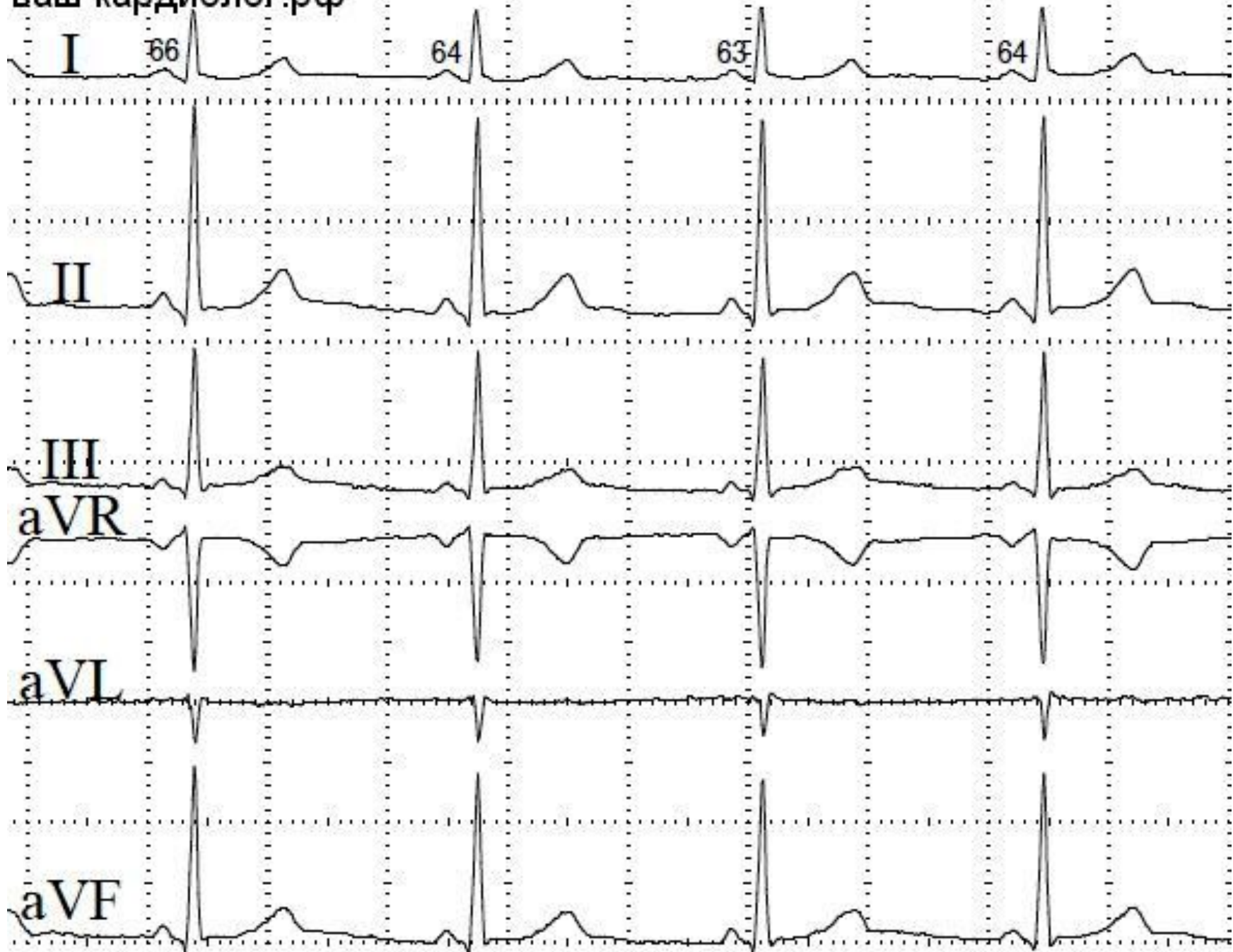

ваш-кардиолог.рф

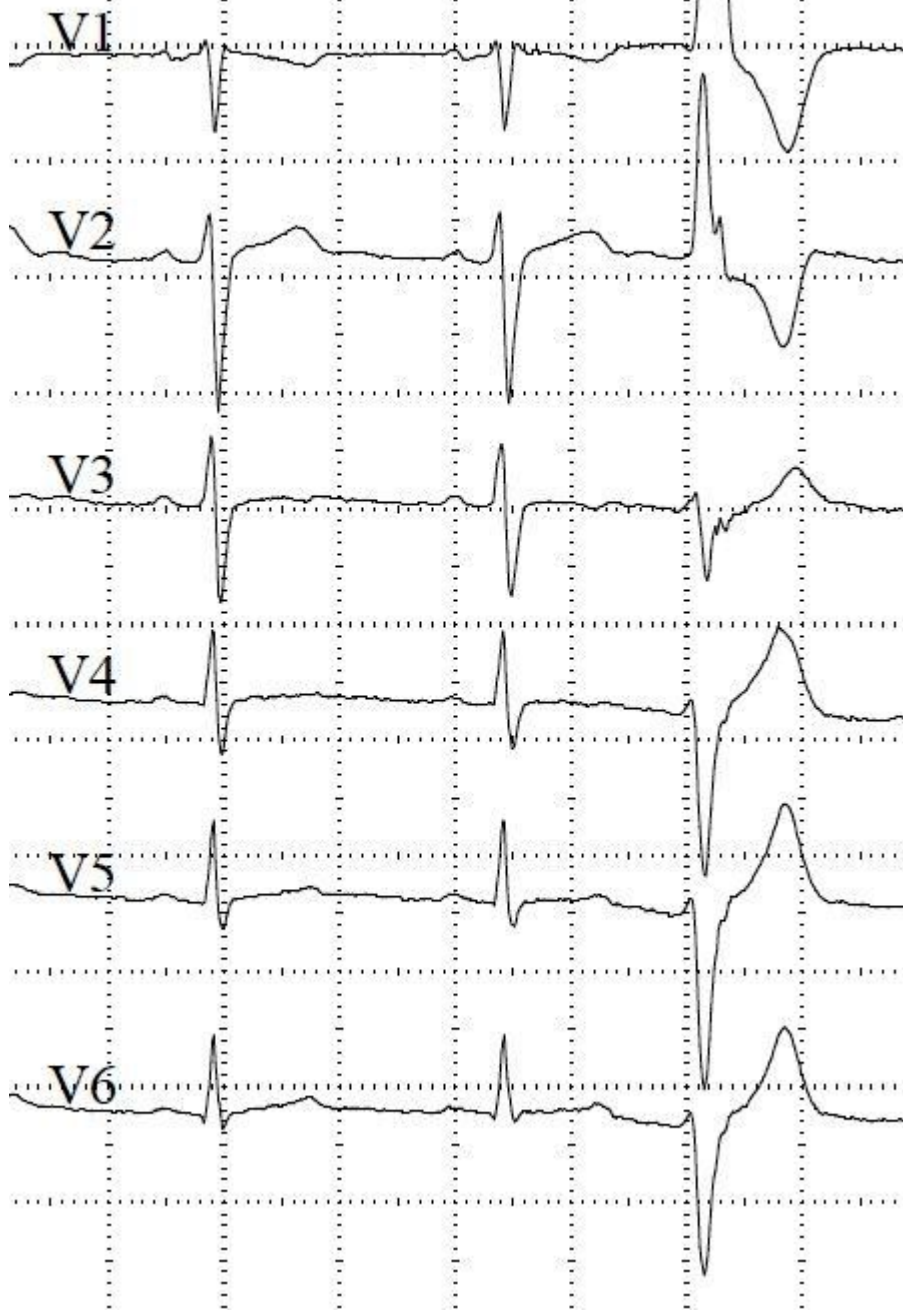


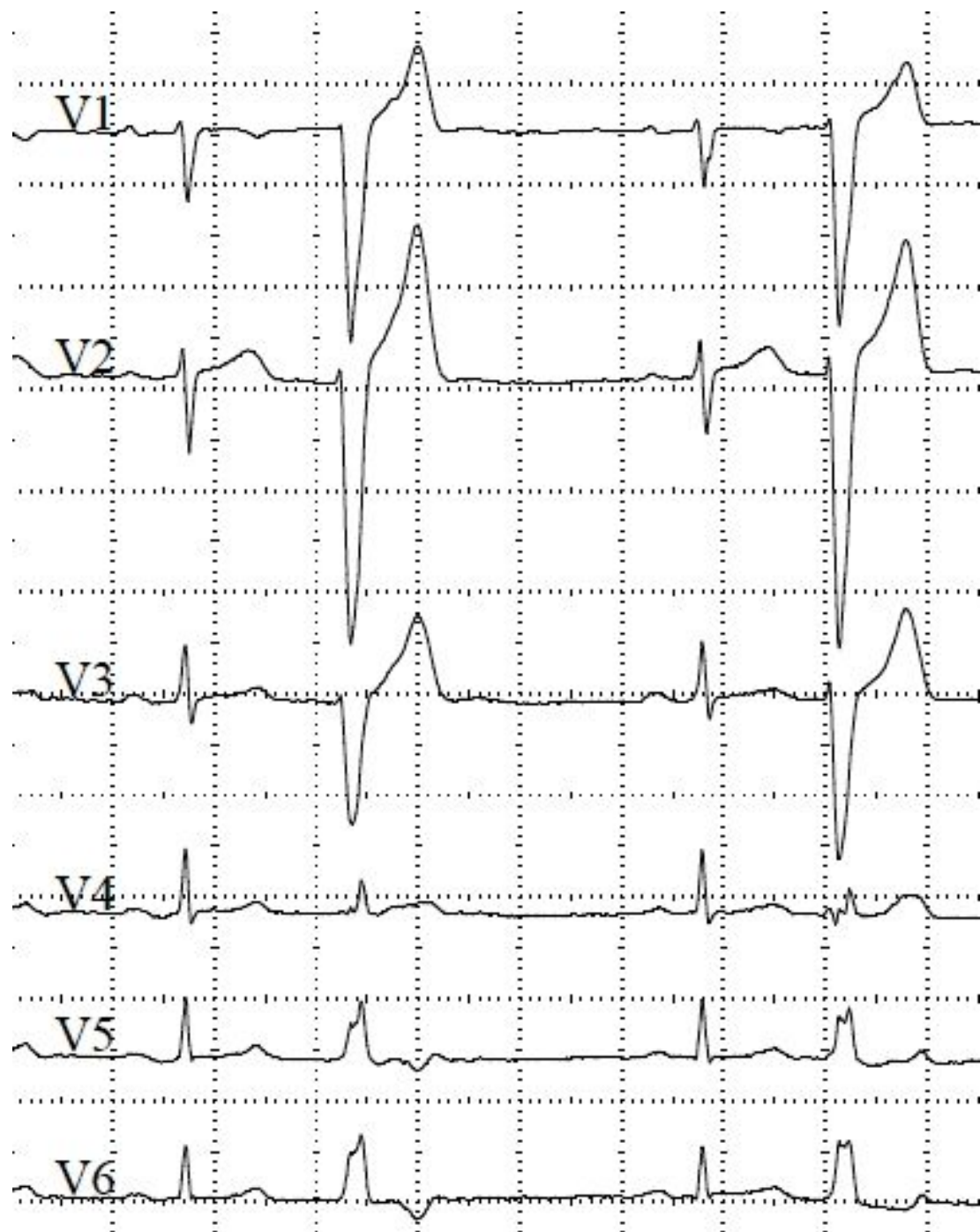


ваш-кардиолог.рф

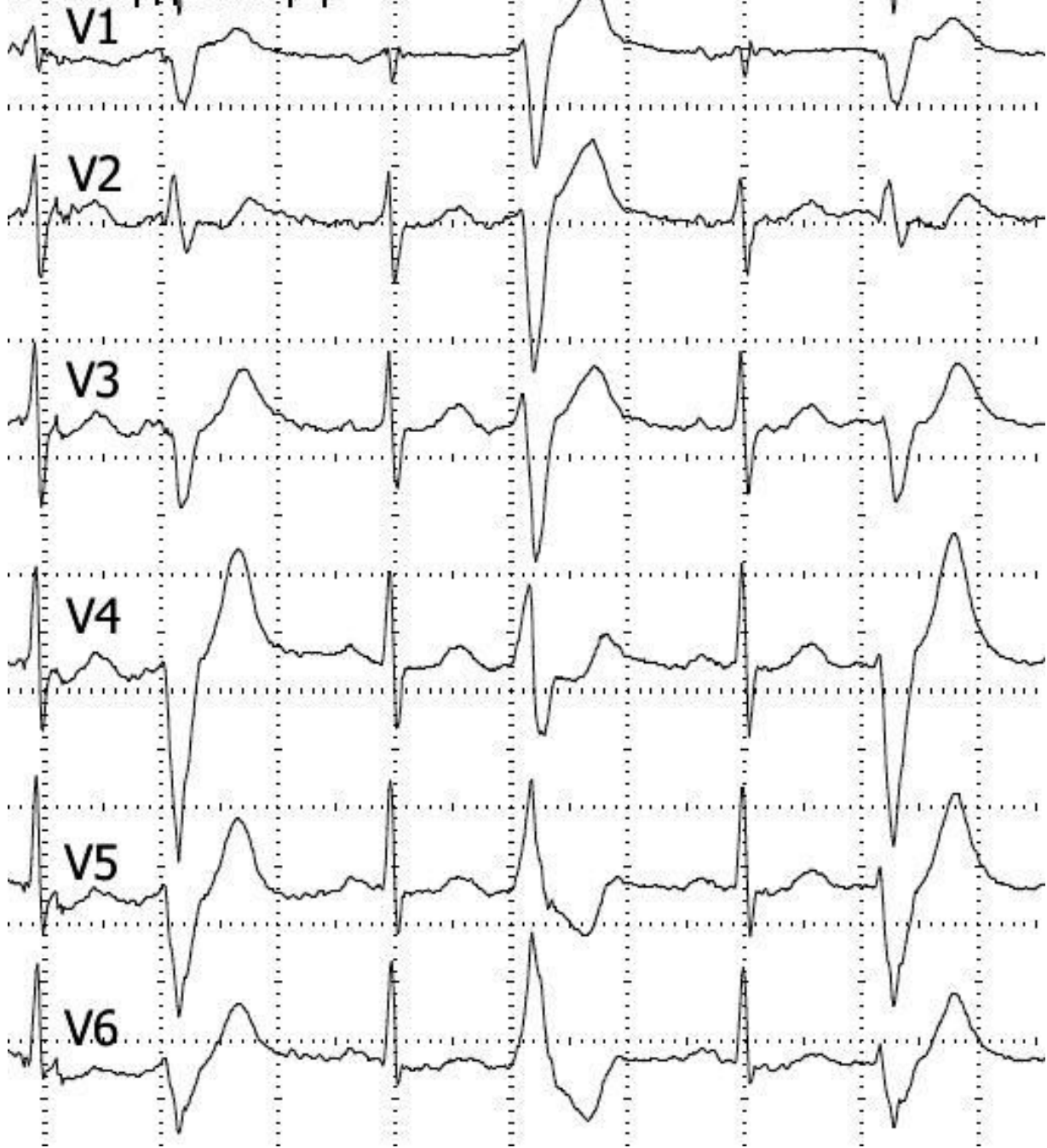


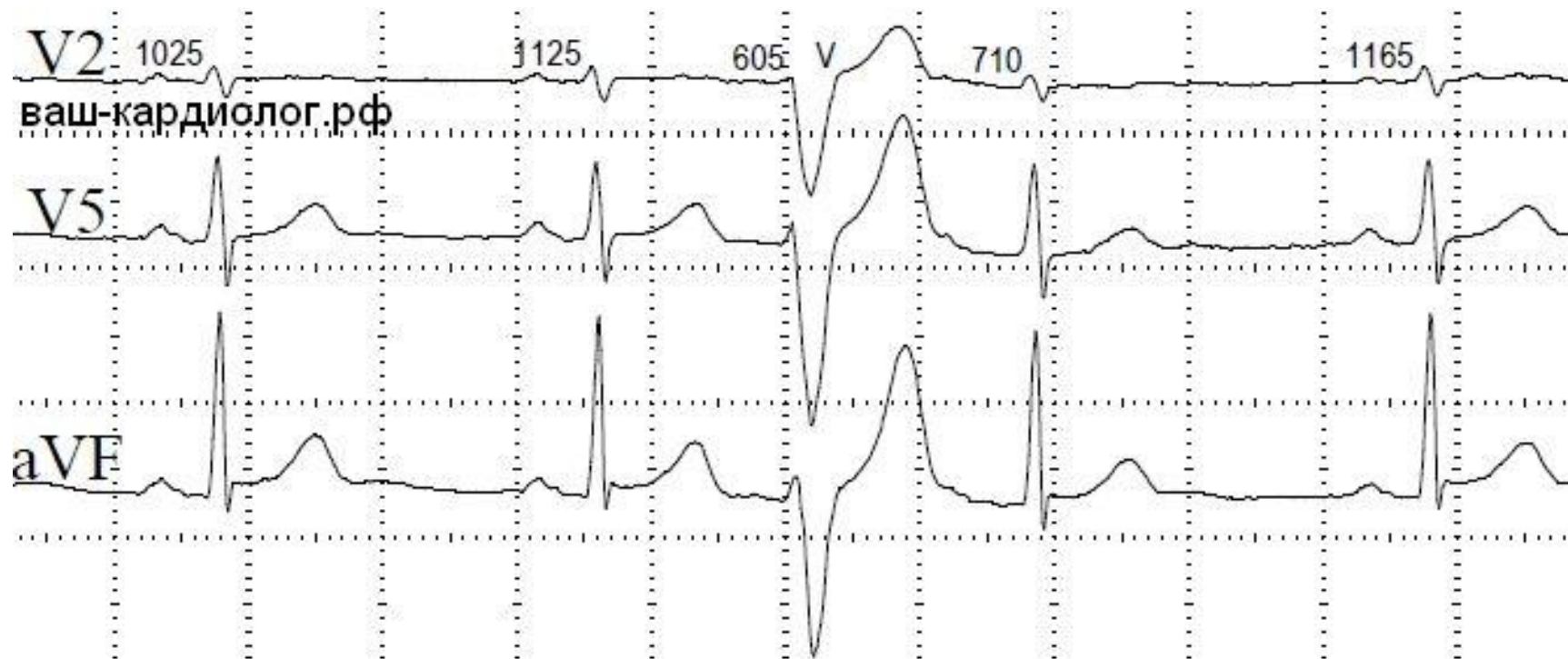
ваш-кардиолог.рф



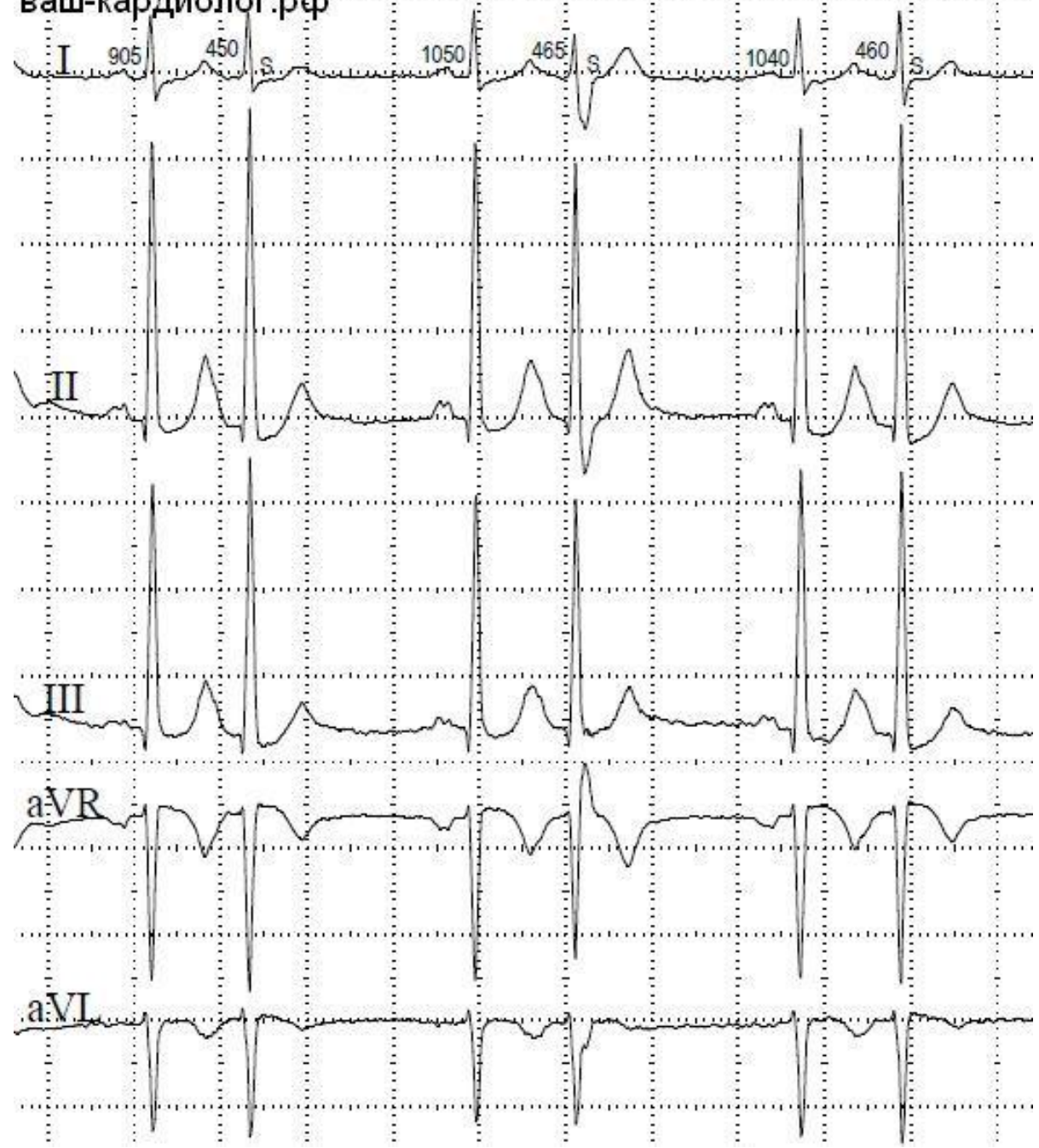


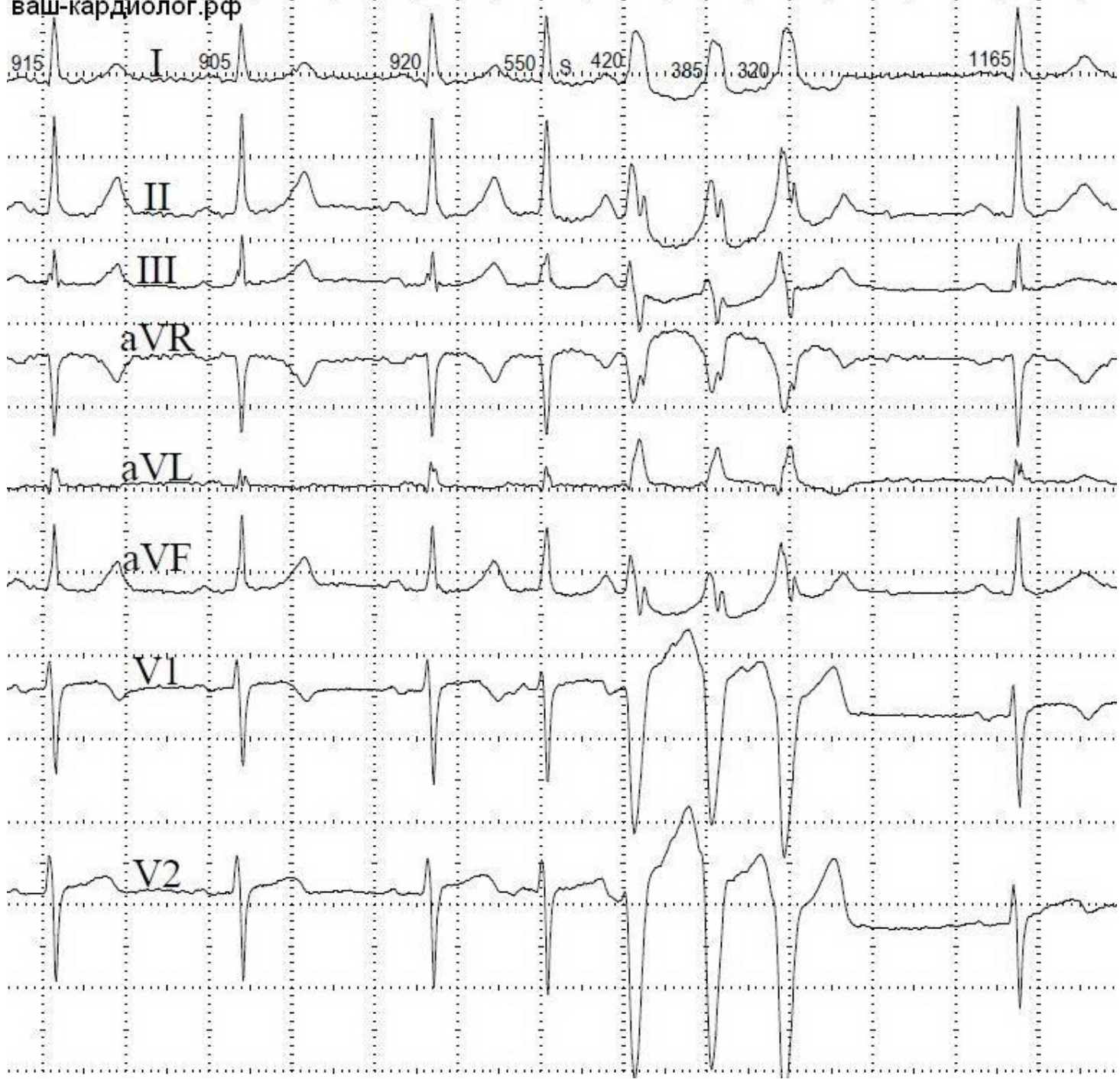
ваш-кардиолог.рф





ваш-кардиолог.рф





ваш-кардиолог.рф

V1

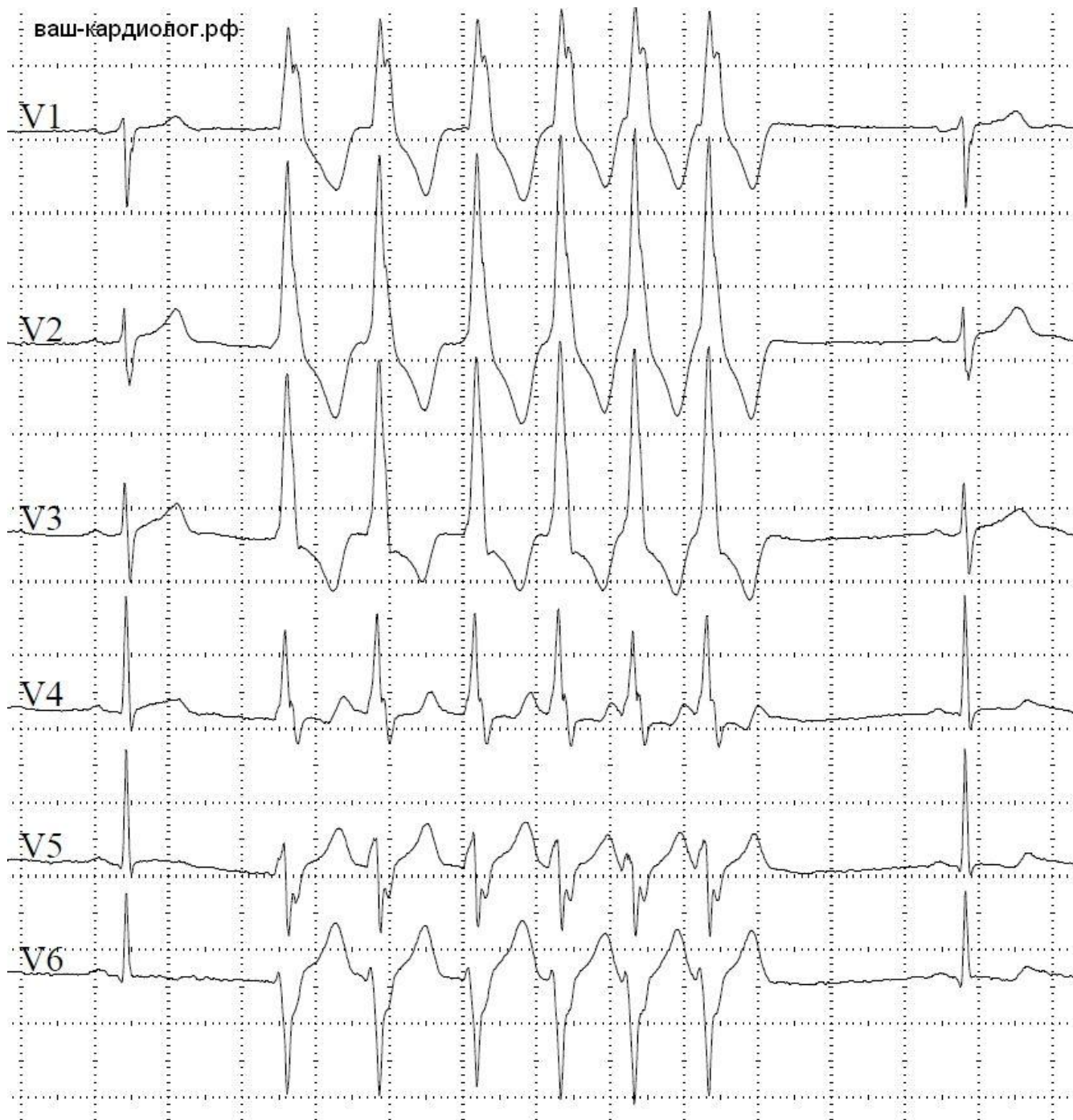
V2

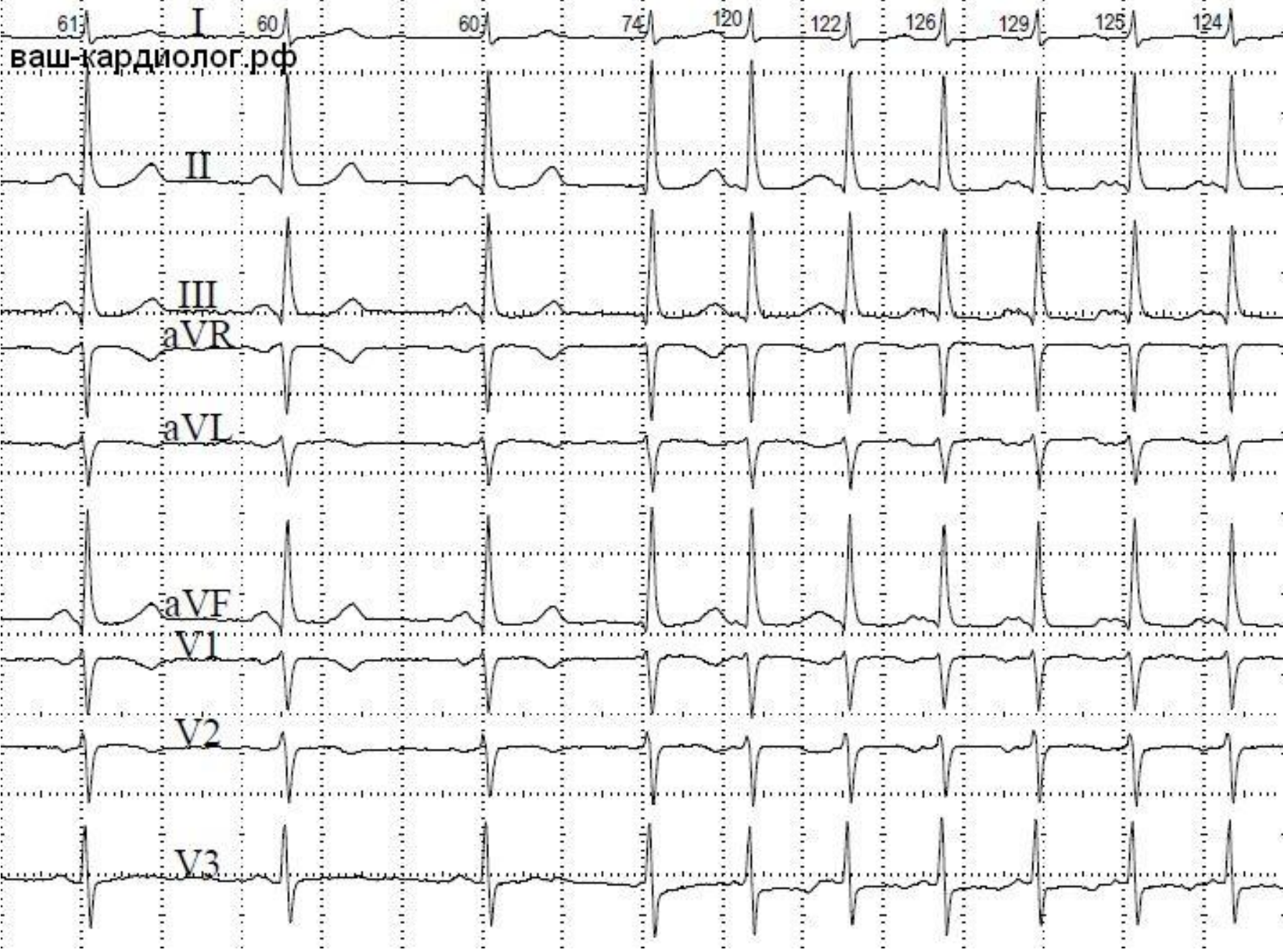
V3

V4

V5

V6

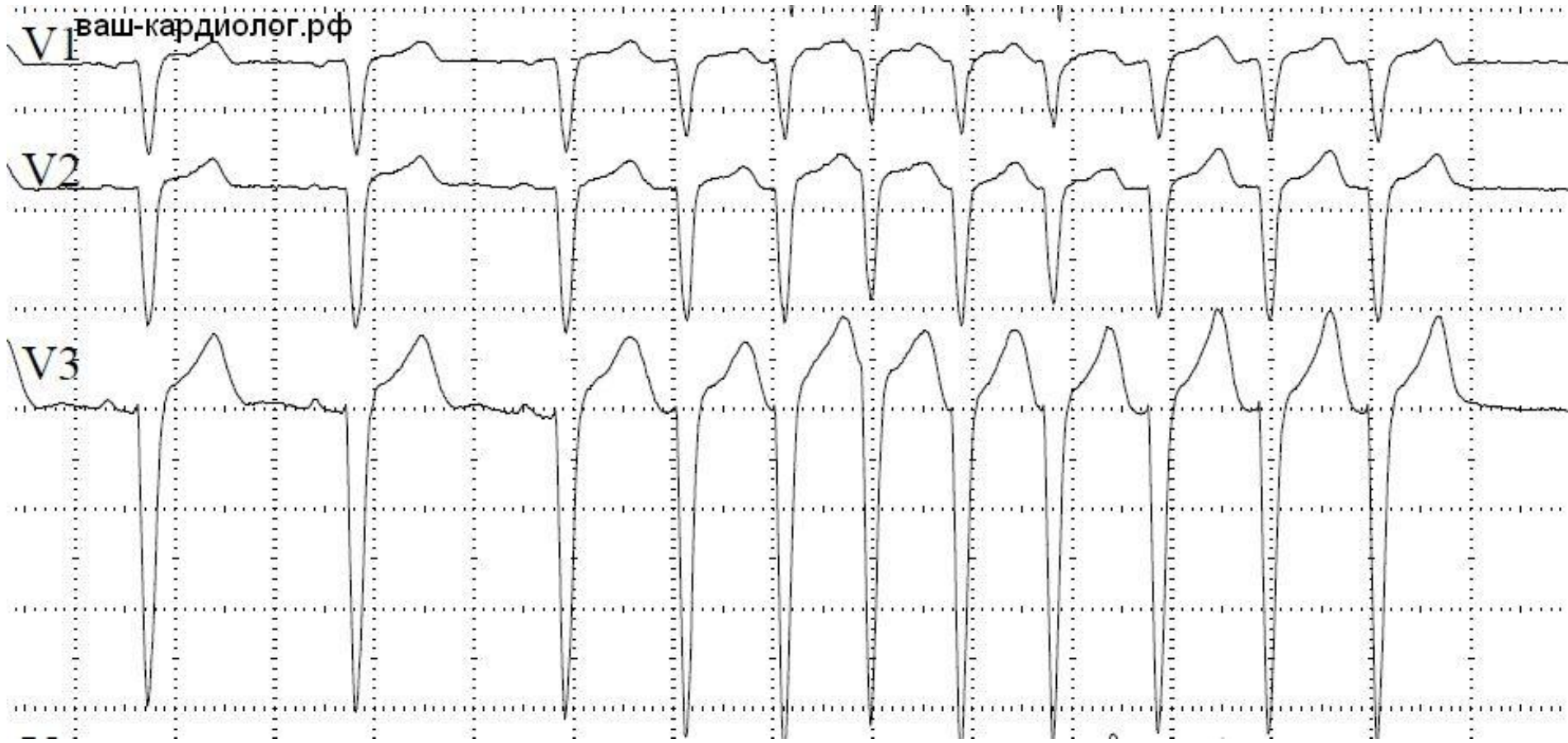


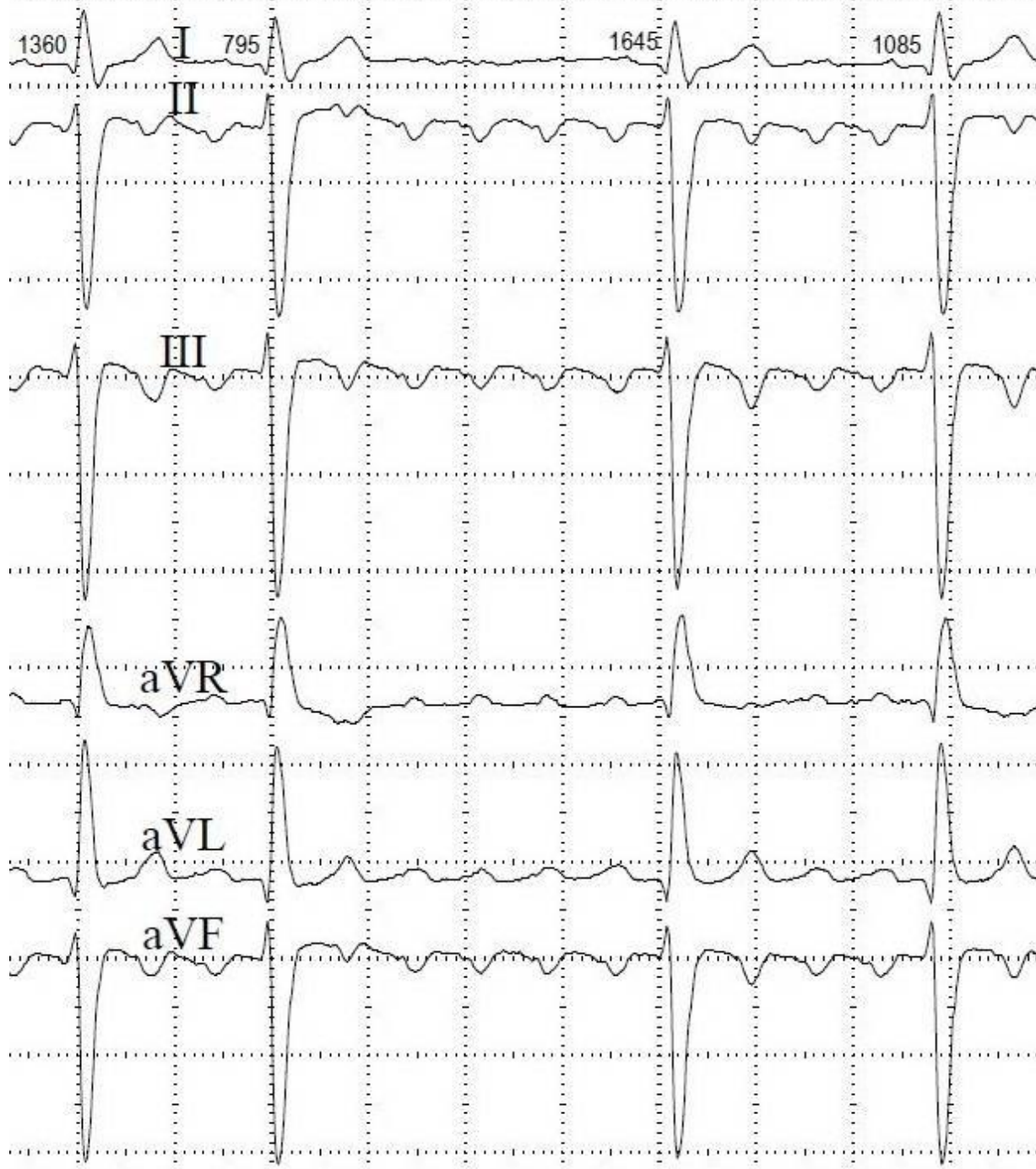


V1 ваш-кардиолог.рф

V2

V3





1110

I

2740

BI

1085

635

830

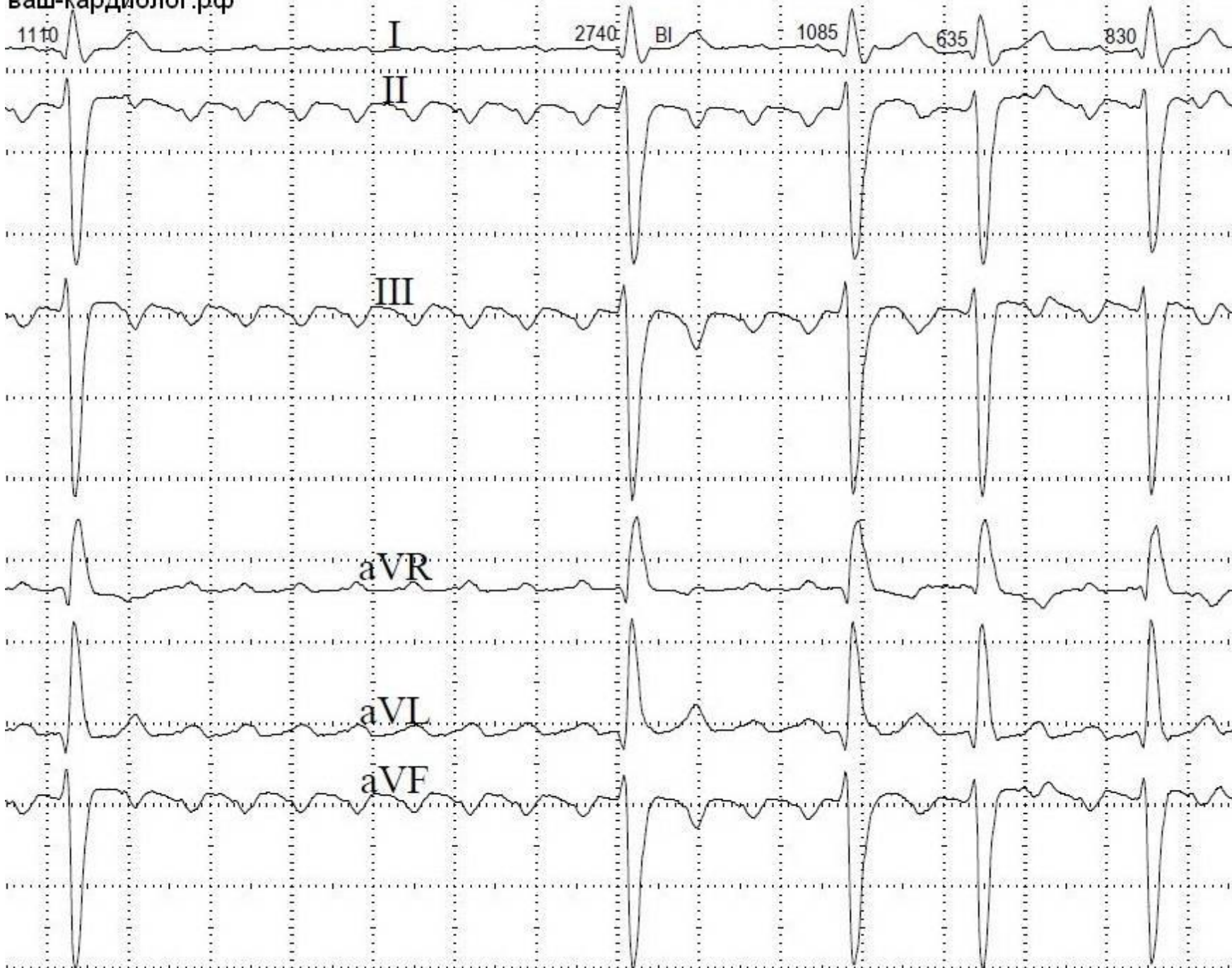
II

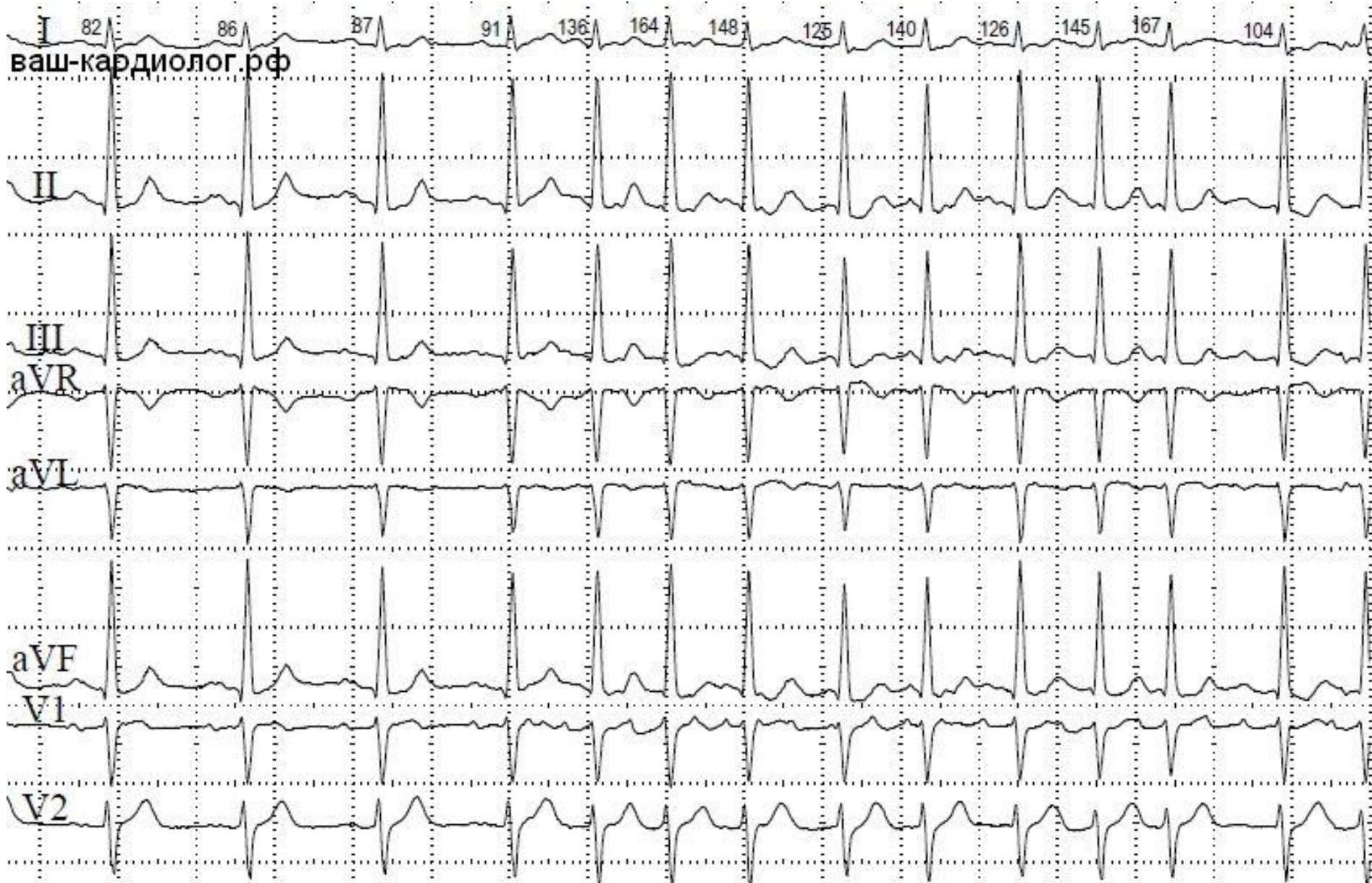
III

aVR

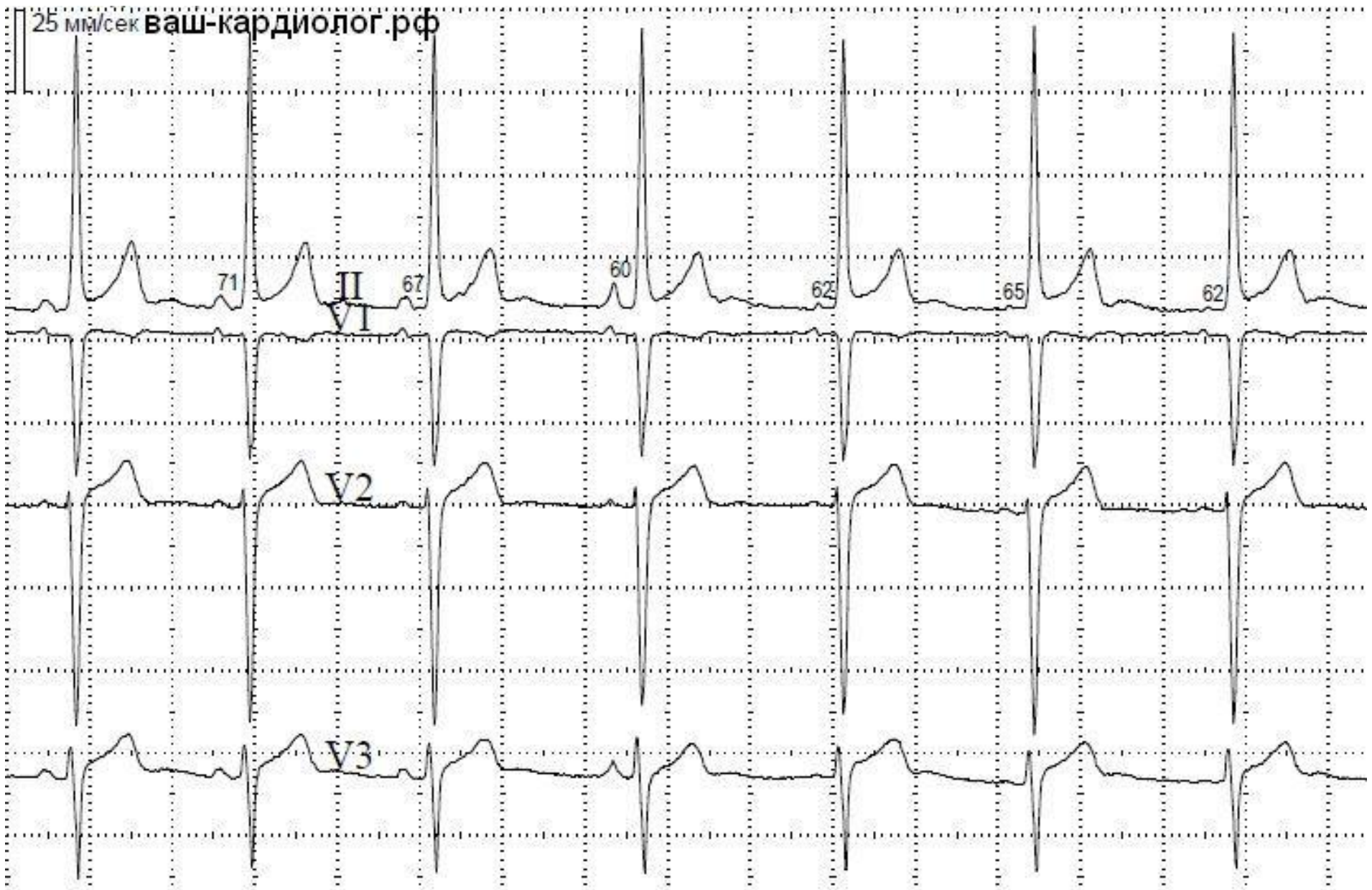
aVL

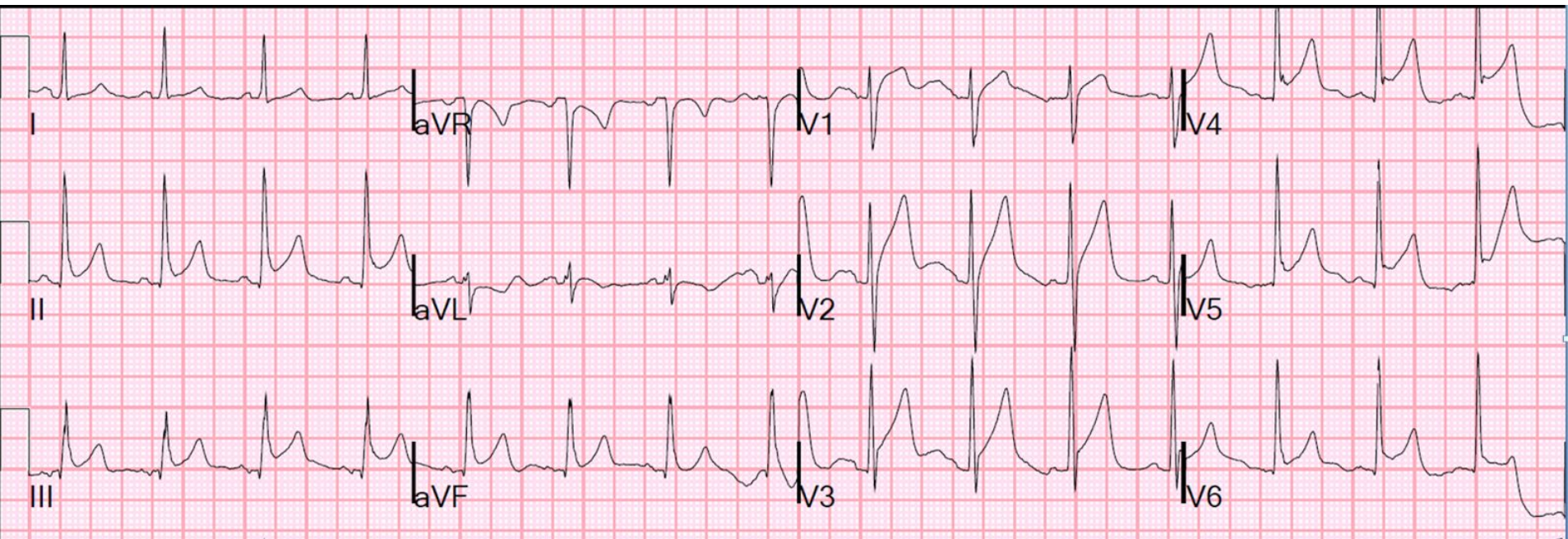aVF

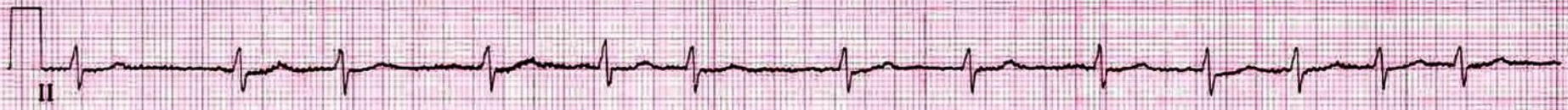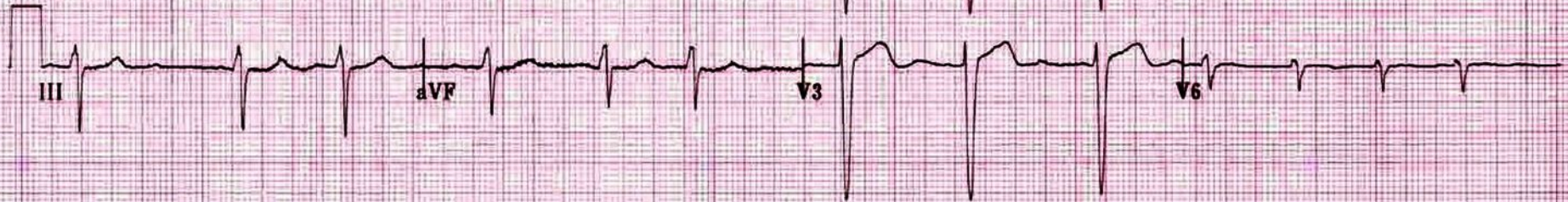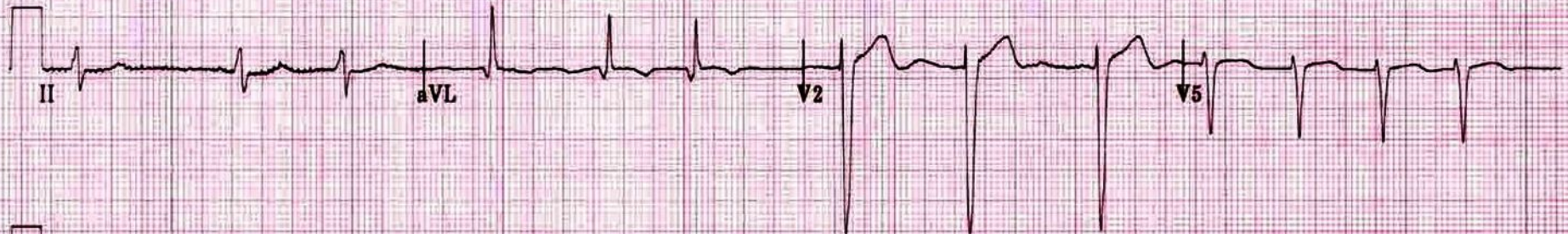


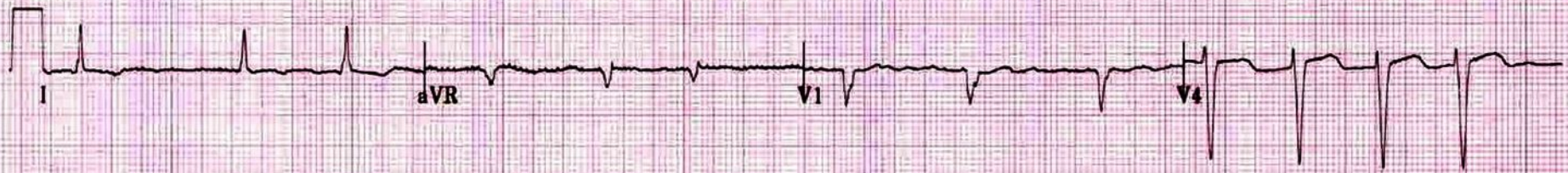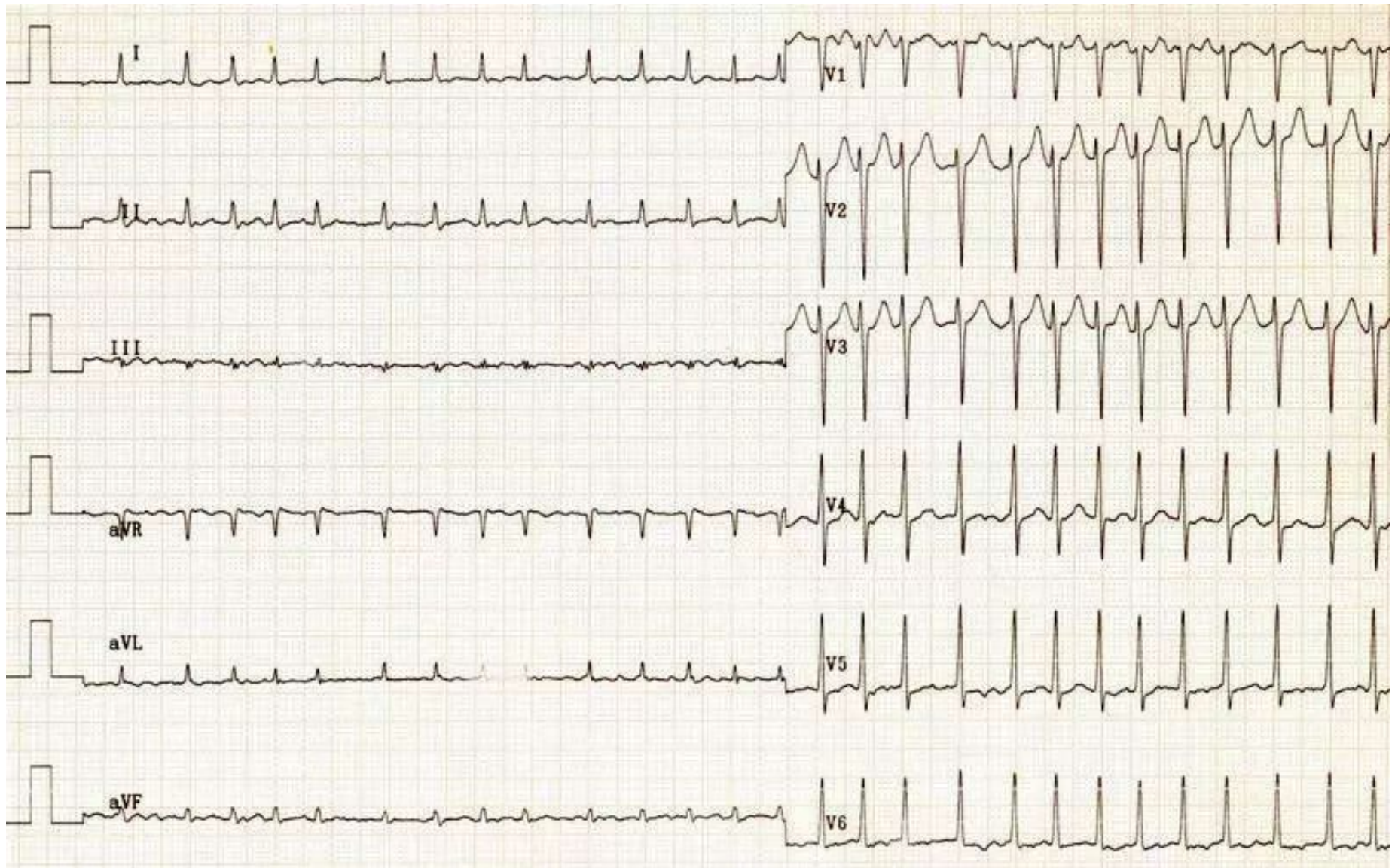


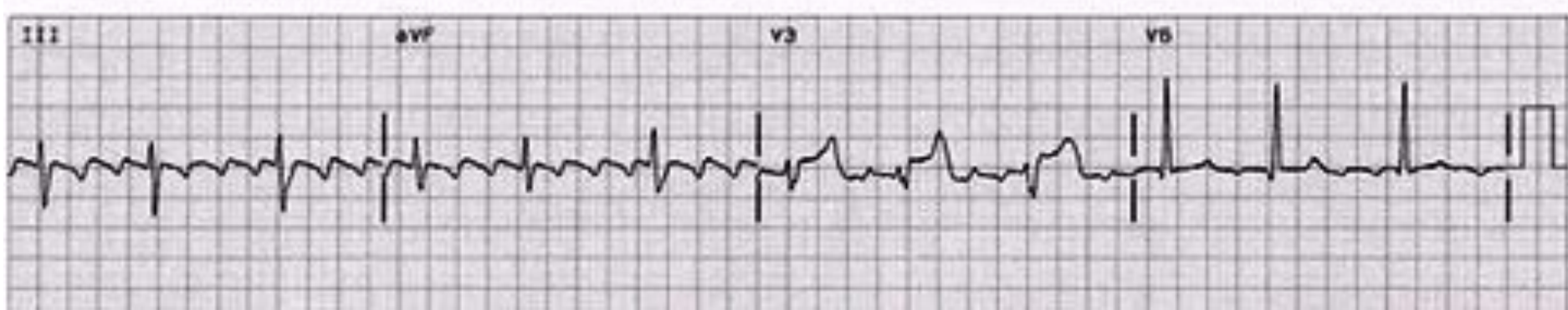
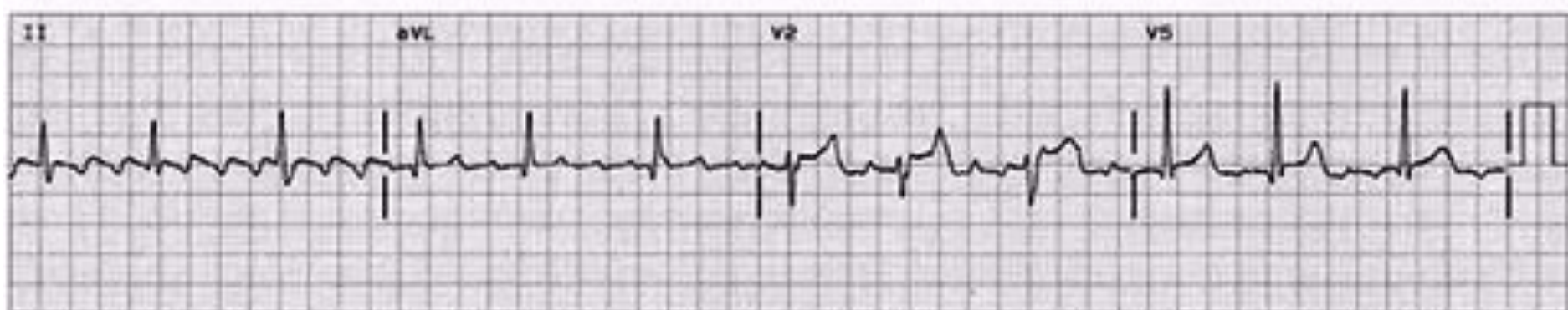
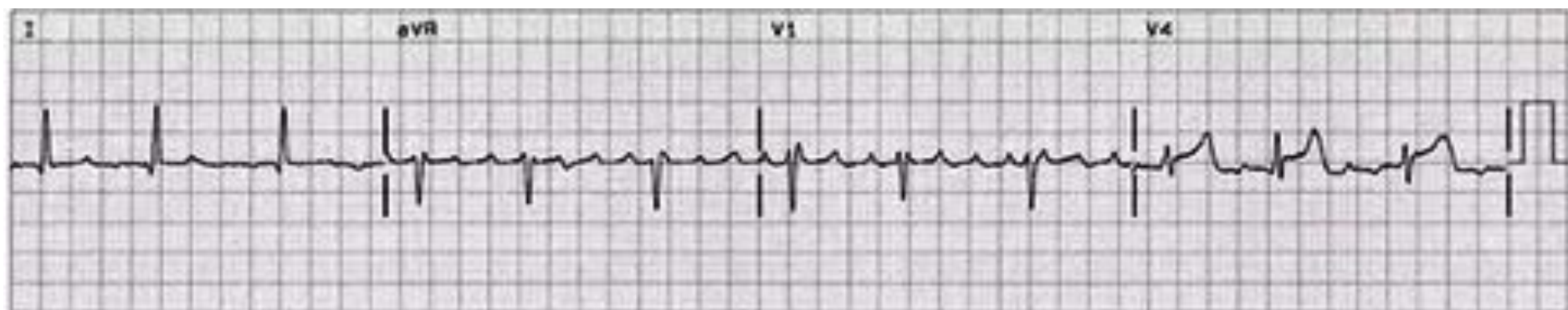
25 мм/сек ваш-кардиолог.рф



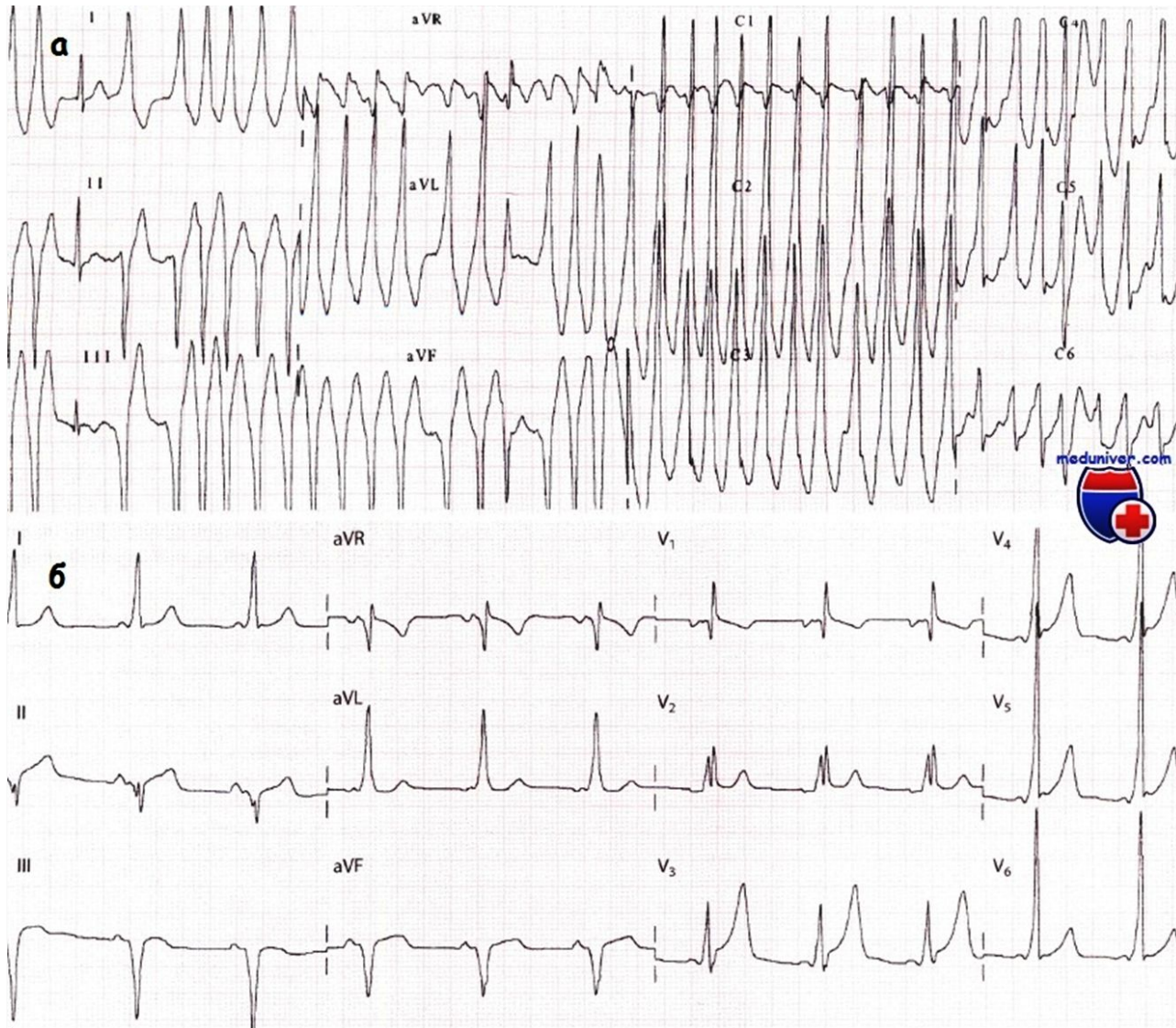


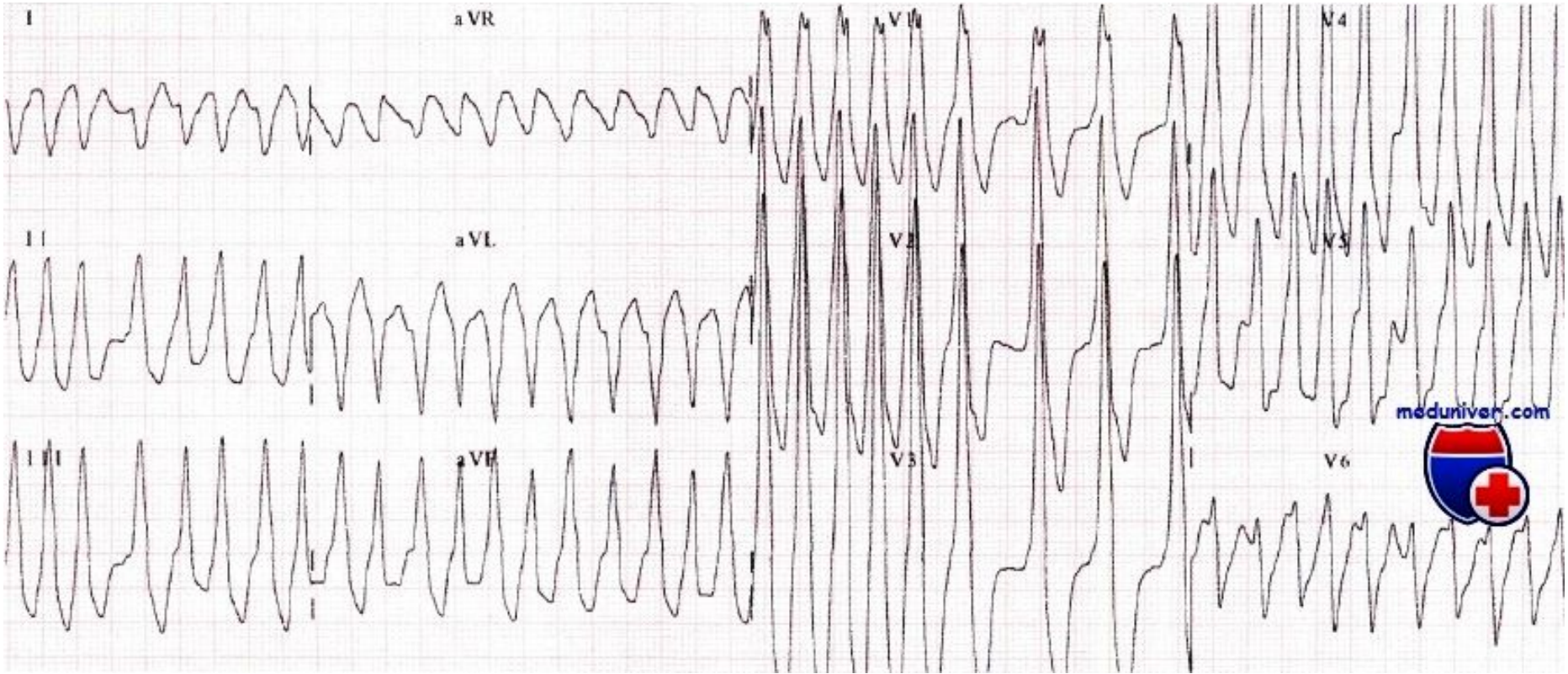






Фибрилляция предсердий при синдроме WPW





meduniver.com

