Магнитно-резонансная томография сердца

Быстрые методики получения изображений при МРТ

- Спин-эхо последовательности
- Градиентные импульсные последовательности

Быстрые спин-эхо последовательности

- Мульти – эхо последовательность
- RARE (FSE) последовательность

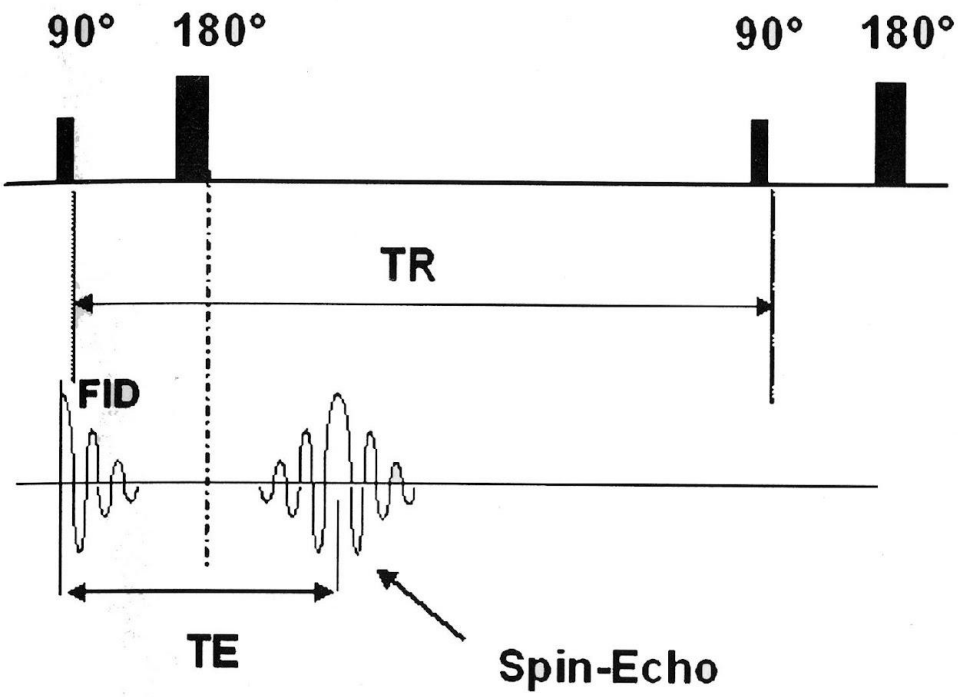

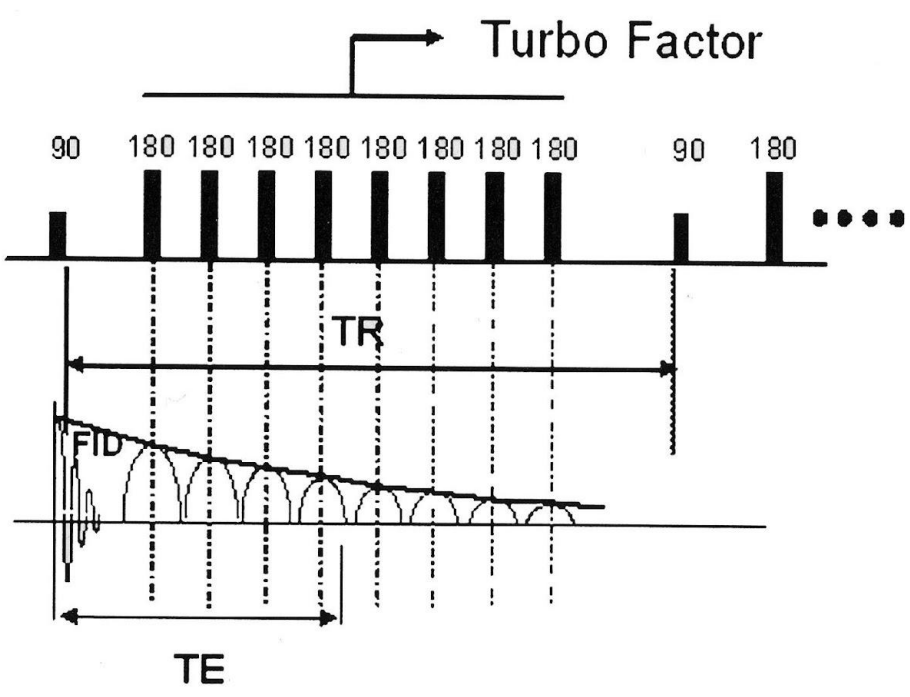

Градиентные импульсные последовательности

- Flash
- EPI

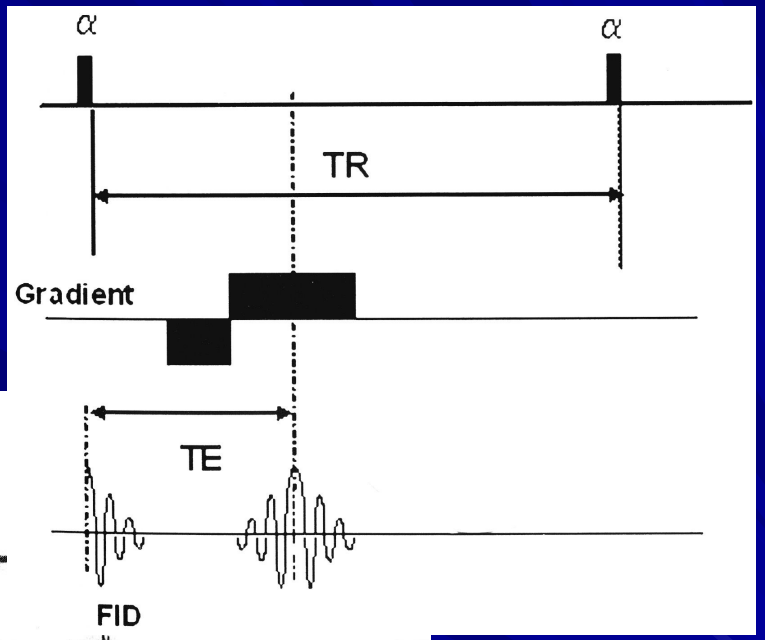

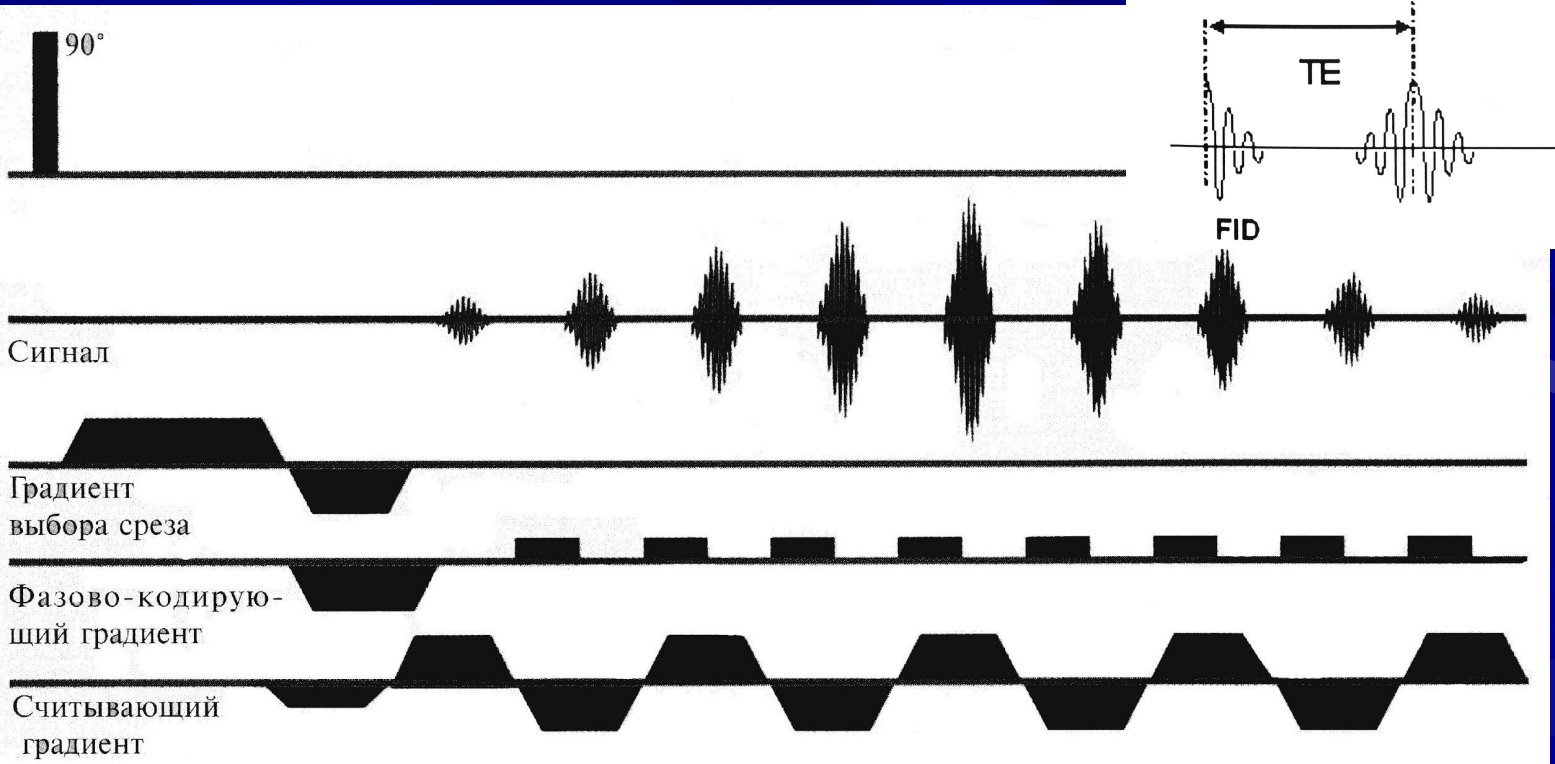

K - пространство




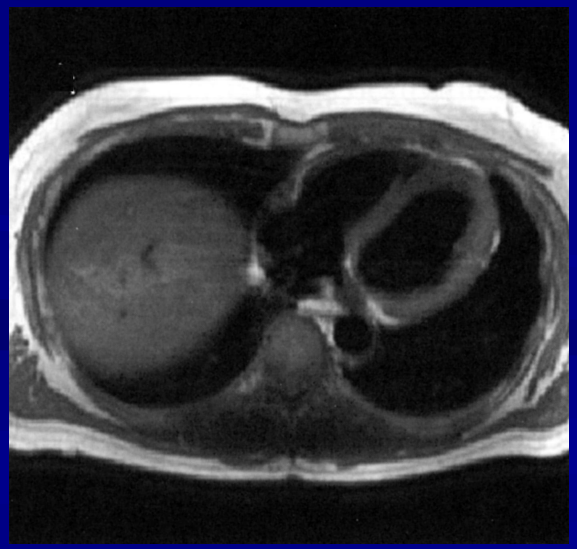
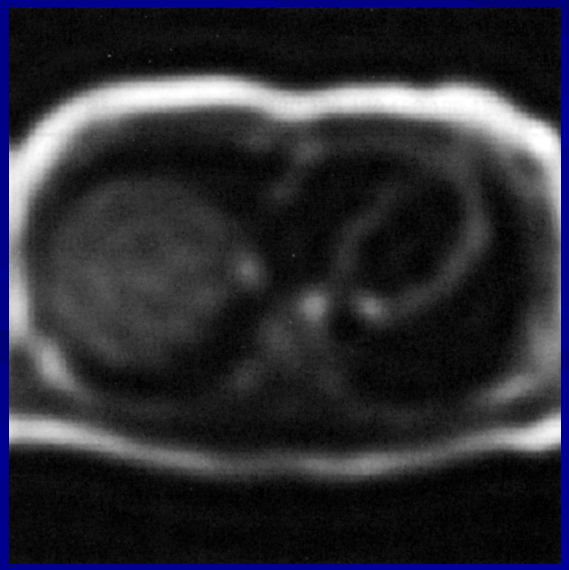
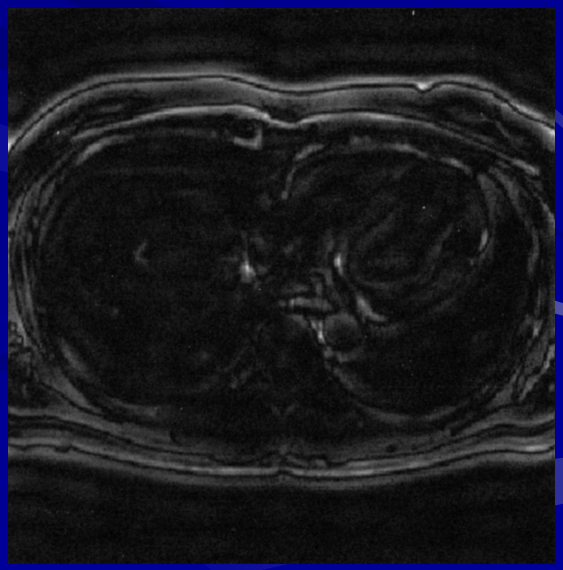

Синхронизация с ЭКГ

- Проспективный триггер

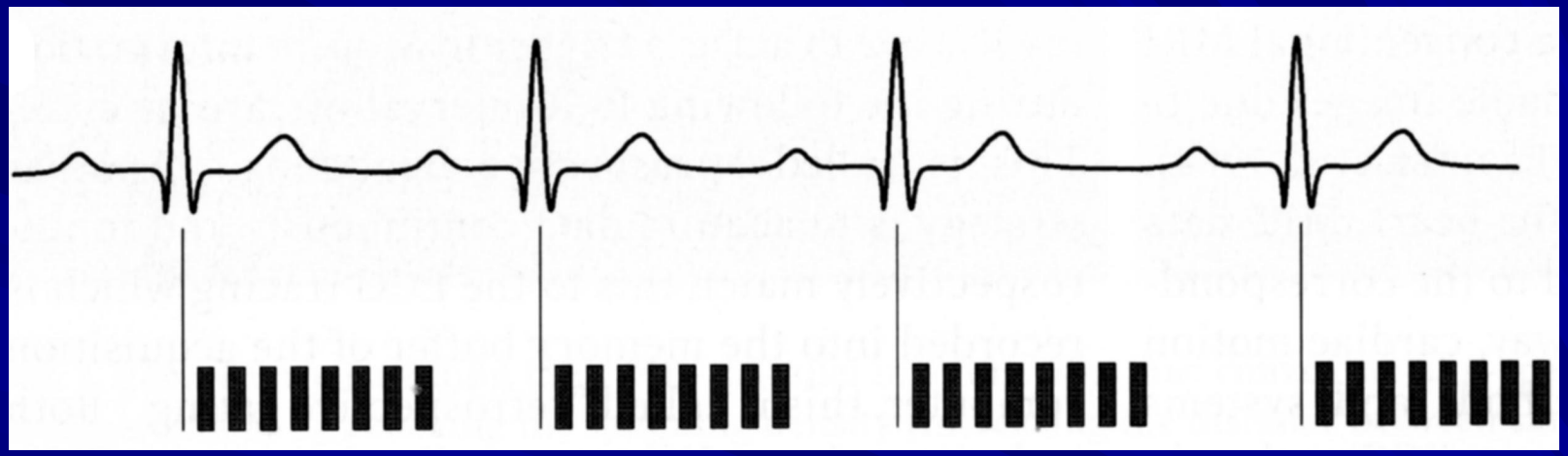

- Ретроспективный триггер

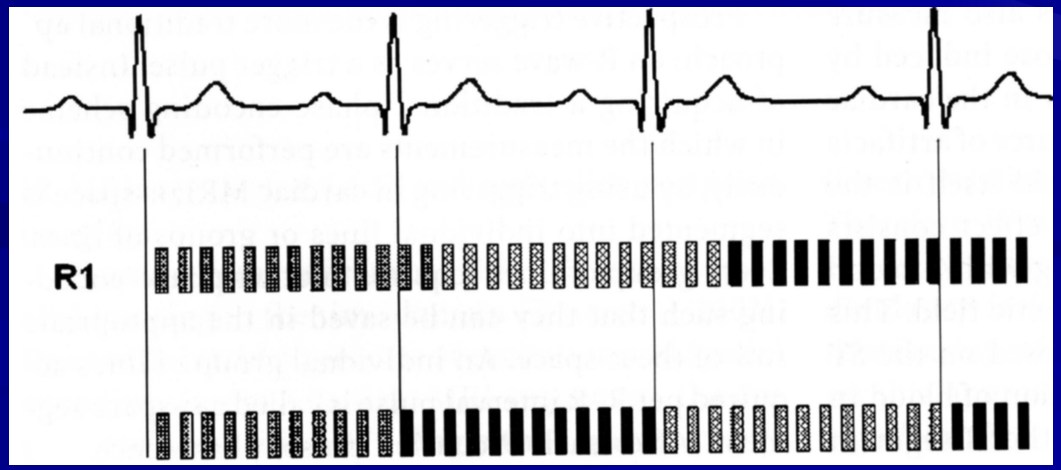

Синхронизация с ЭКГ

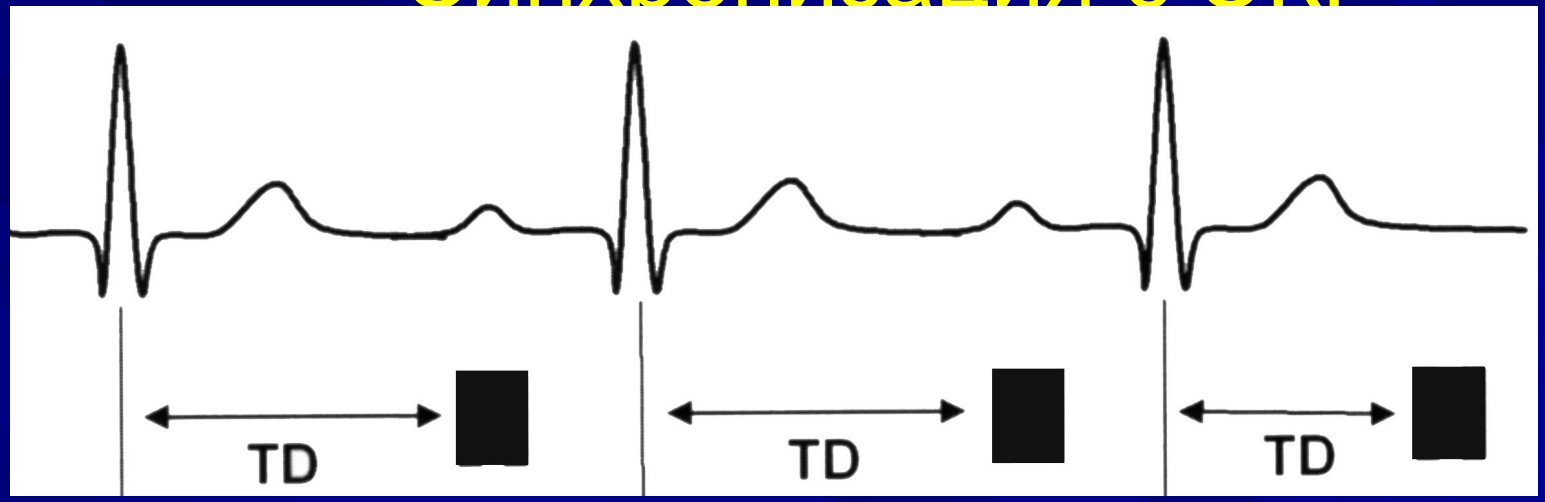

Сканирование в одну и туже фазу сердечного цикла



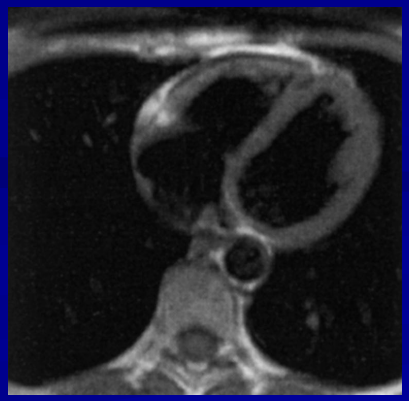

Синхронизация с ЭКГ

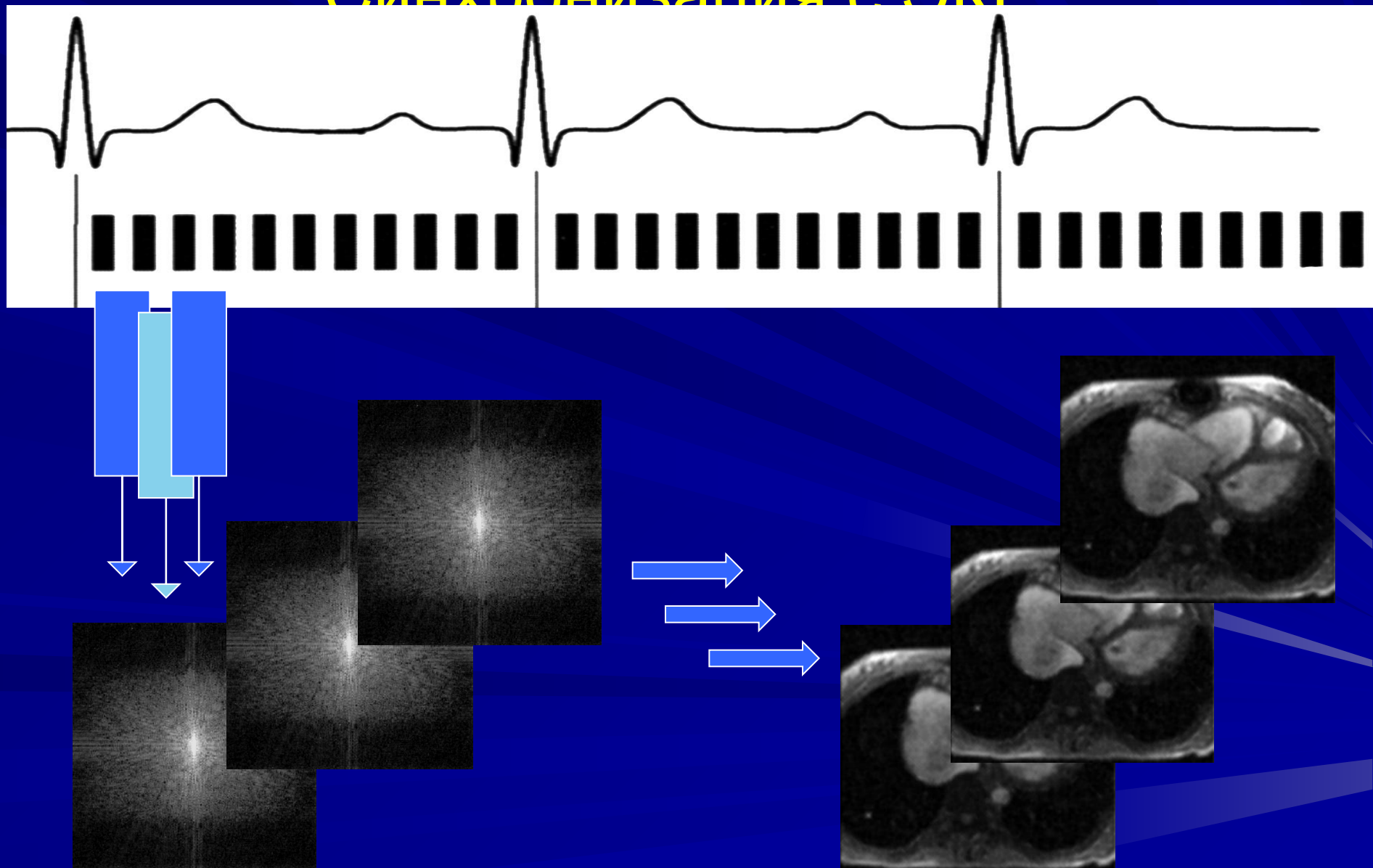

Синхронизация с дыханием

- Задержка дыхания самим пациентом по команде оператора
- Использование датчика дыхания
- Использование навигаторов

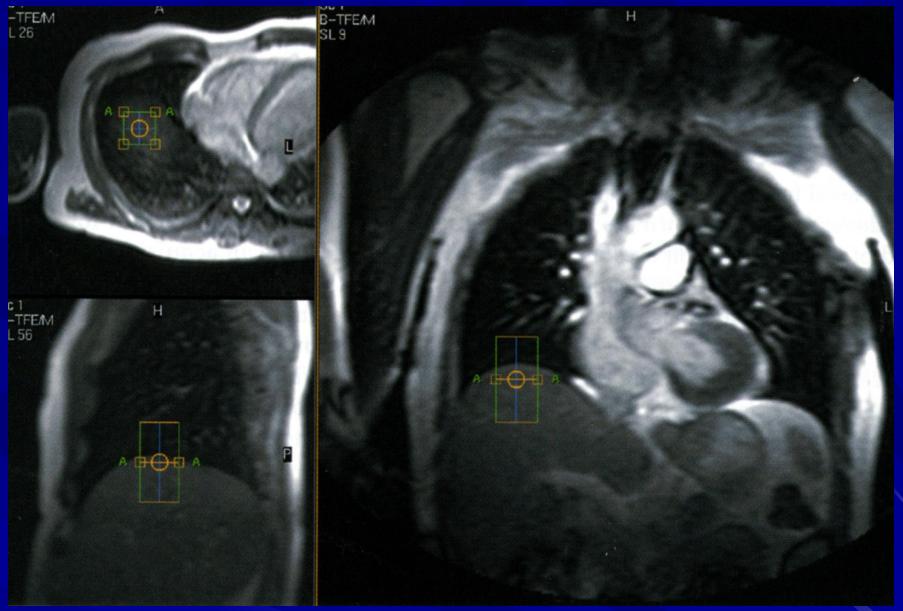



- Морфология

Жировая дегенерация
Жизнеспособность/фиброз
Отек/инфильтрация
Другие

- Ангиография

Аорта
Легочные вены
Коронарные артерии

- Функция

Глобальная функция
Регионарная функция
Функция створок клапанов

- Перфузия

Перфузия миокарда при нагрузке
Перфузия миокарда в покое

- Внутрисердечная гемодинамика

Недостаточность створок клапанов
Оценка объема шунтирующей крови
Оценка градиентов давлений

Общая оценка морфологии
Спектроскопия
Молекулярная визуализация

Основные оси сердца

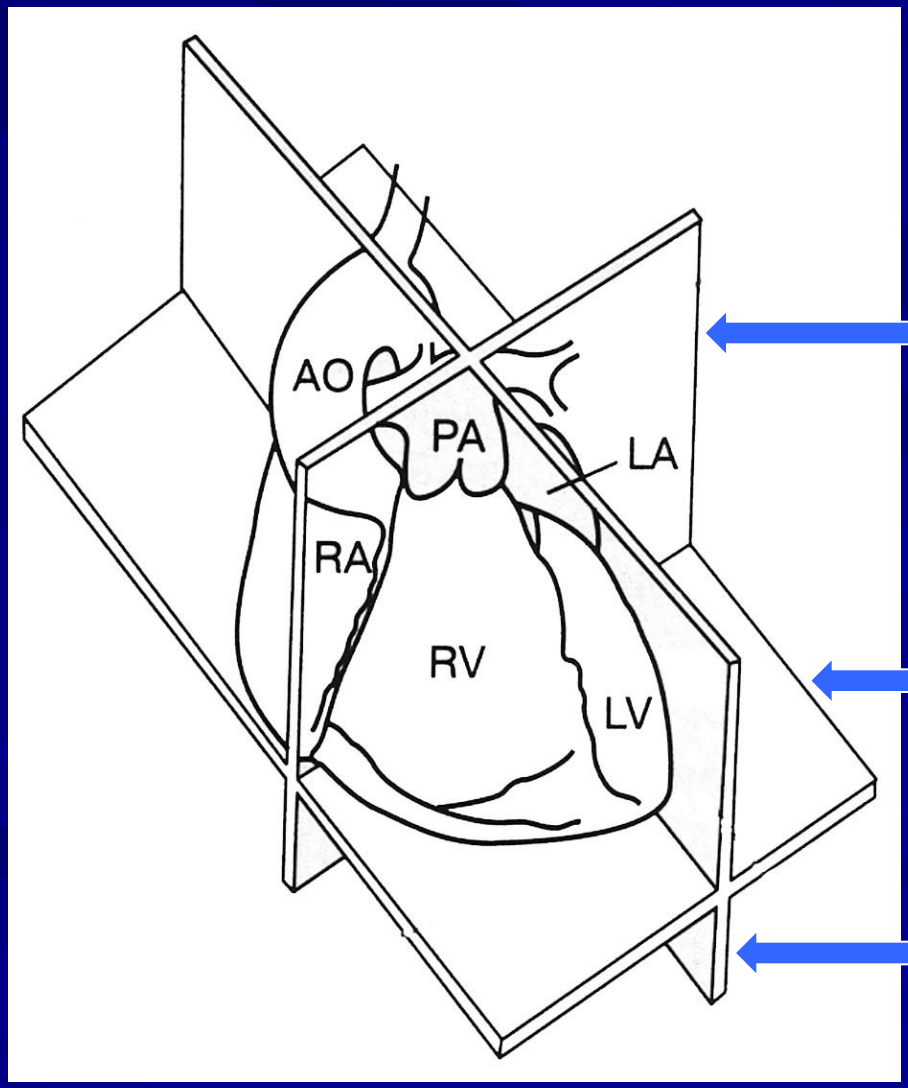

Позиция по короткой оси

Четырех камерная позиция

Двухкамерная позиция

Основные оси сердца

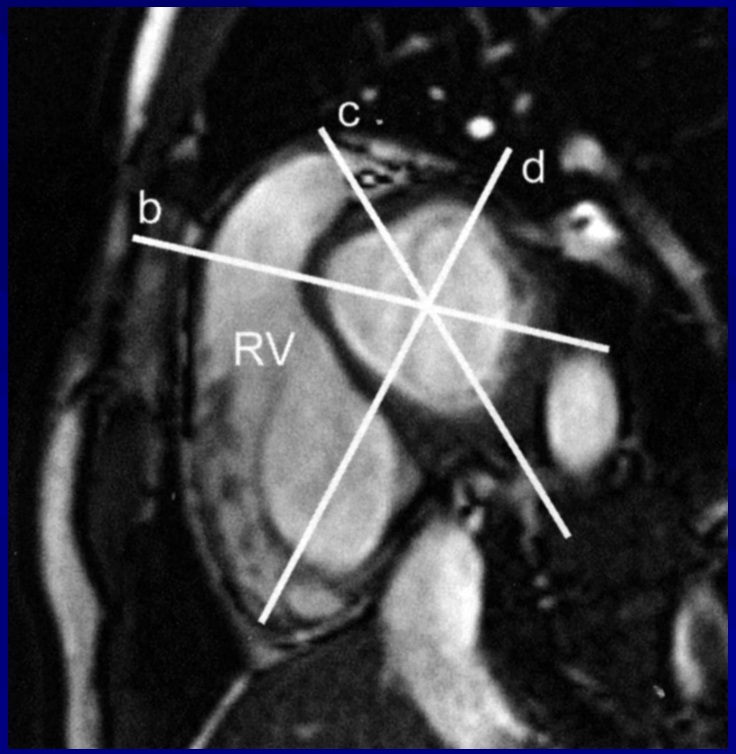

C

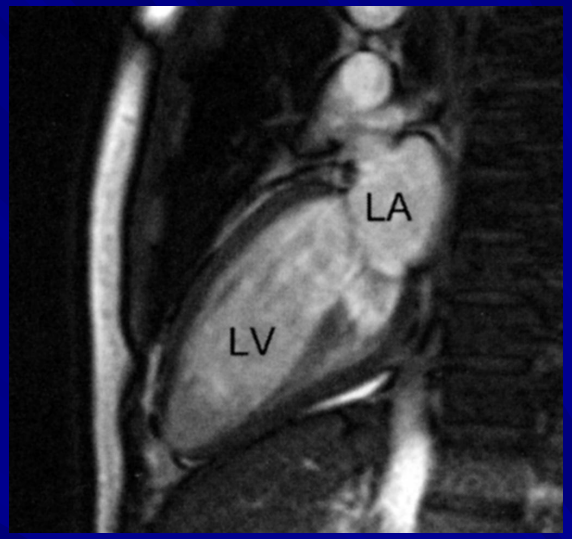

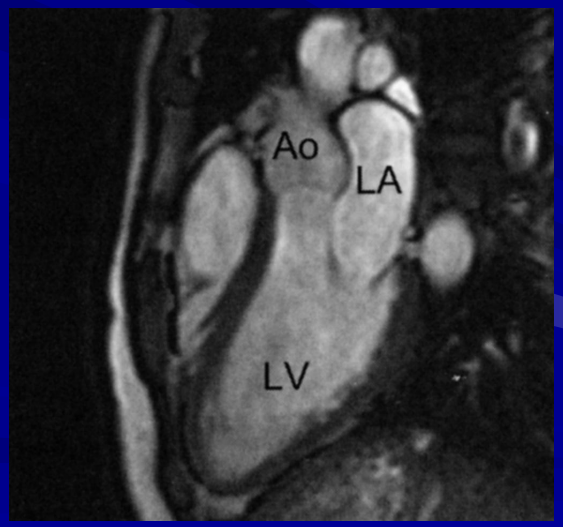

B

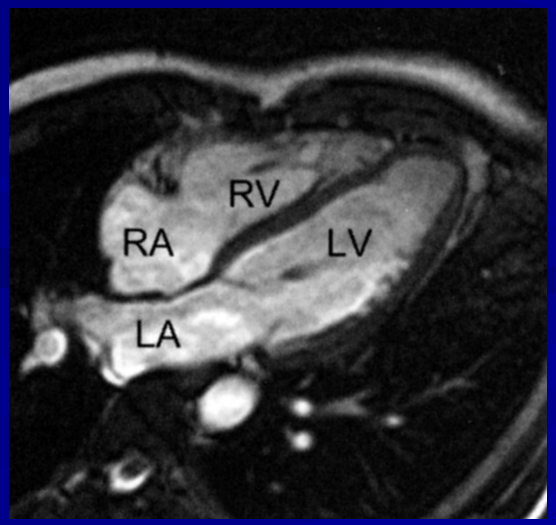

D

Двухкамерная позиция

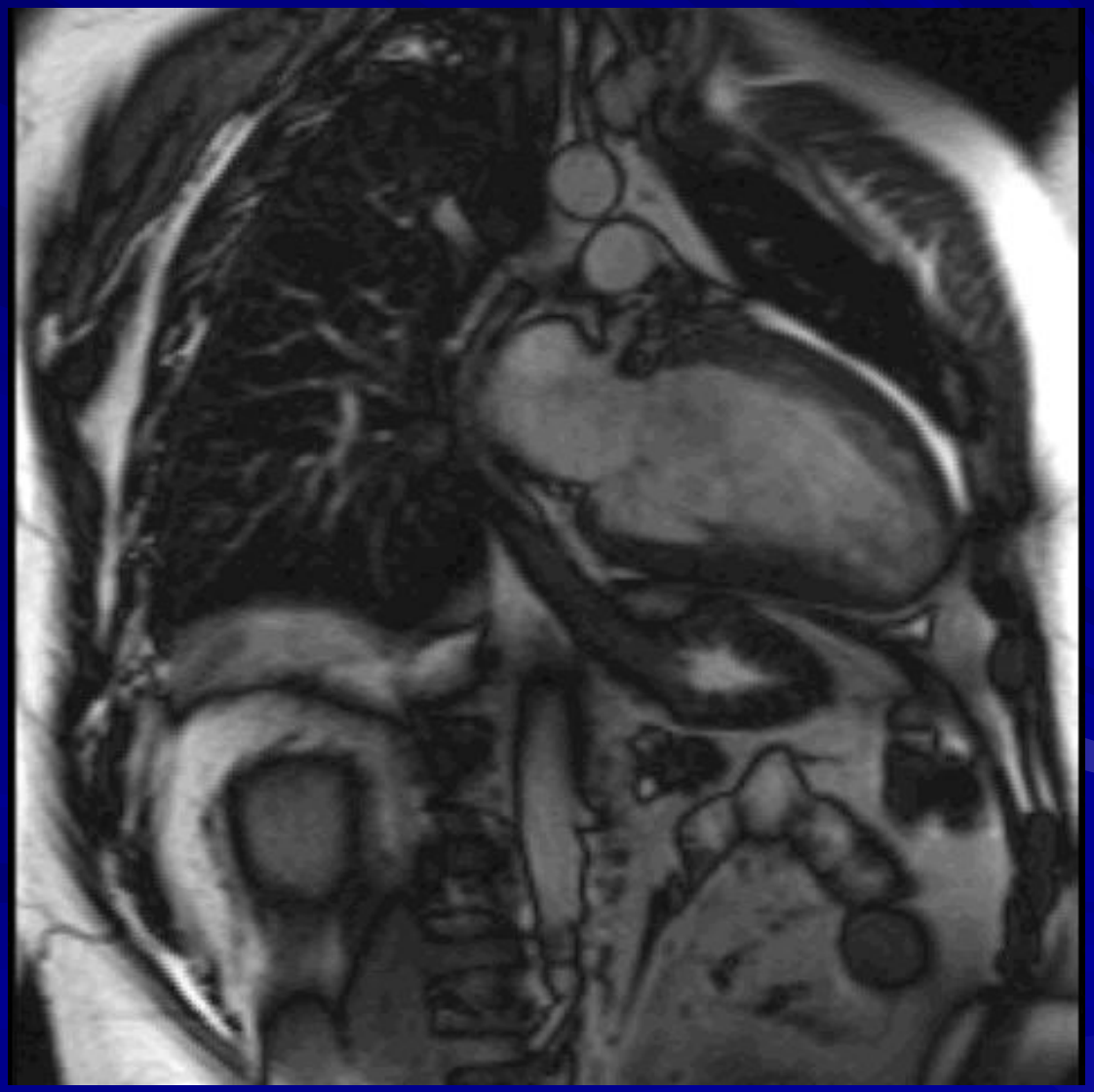

Четырехкамерная позиция

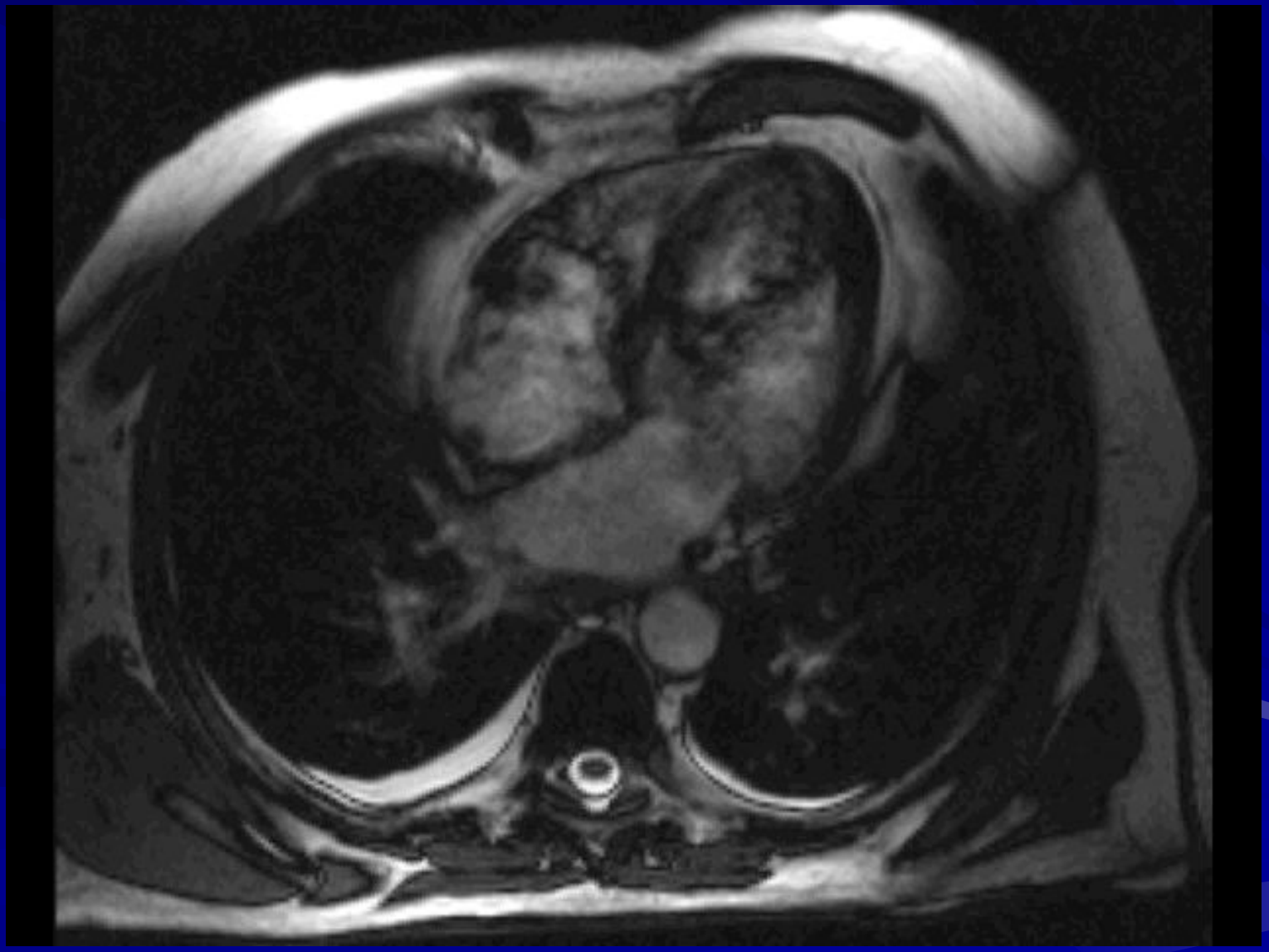

Изображения по короткой оси

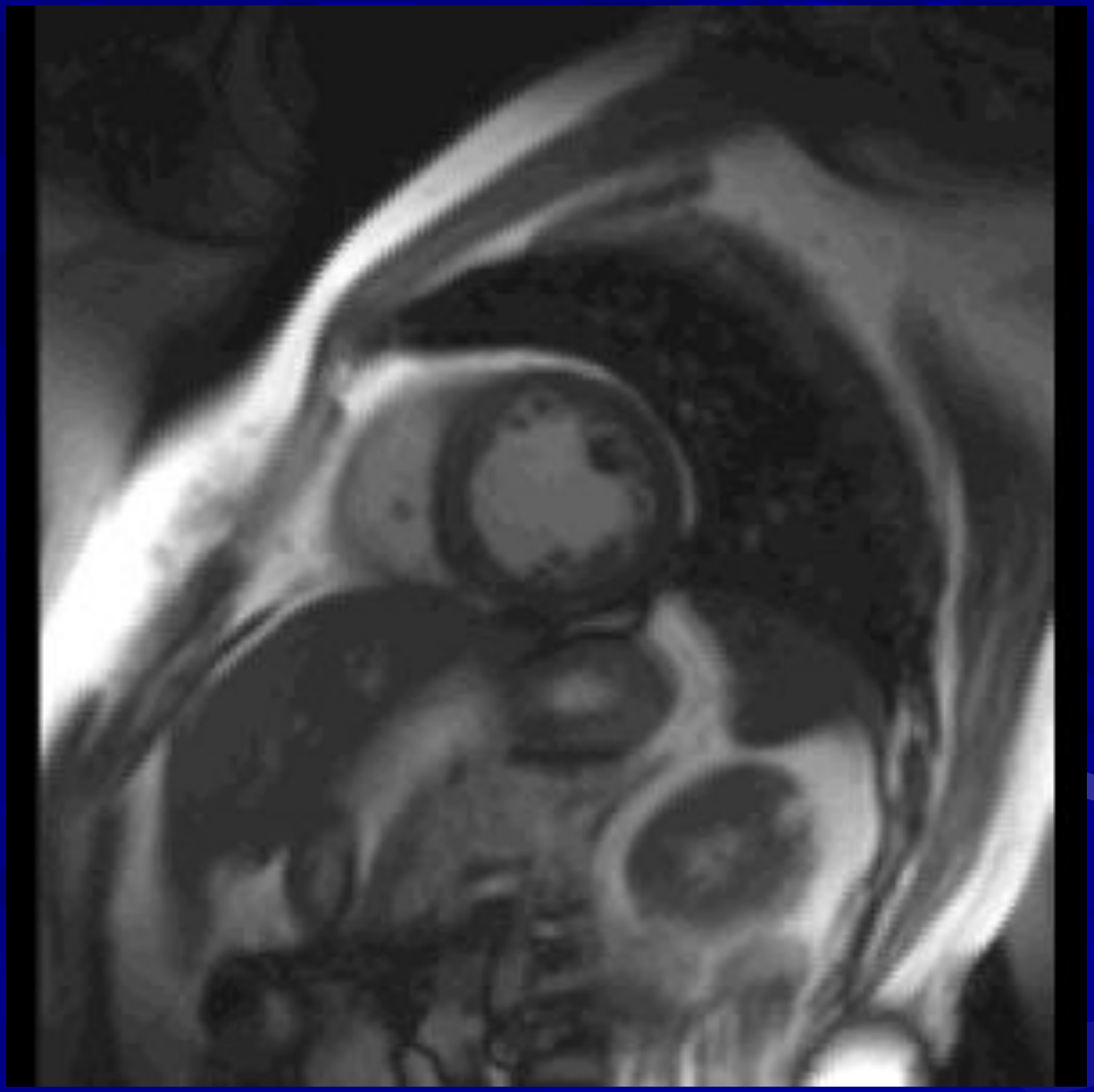

Входной и выходной тракты левого желудочка

Ишемическая болезнь сердца

Ишемический каскад

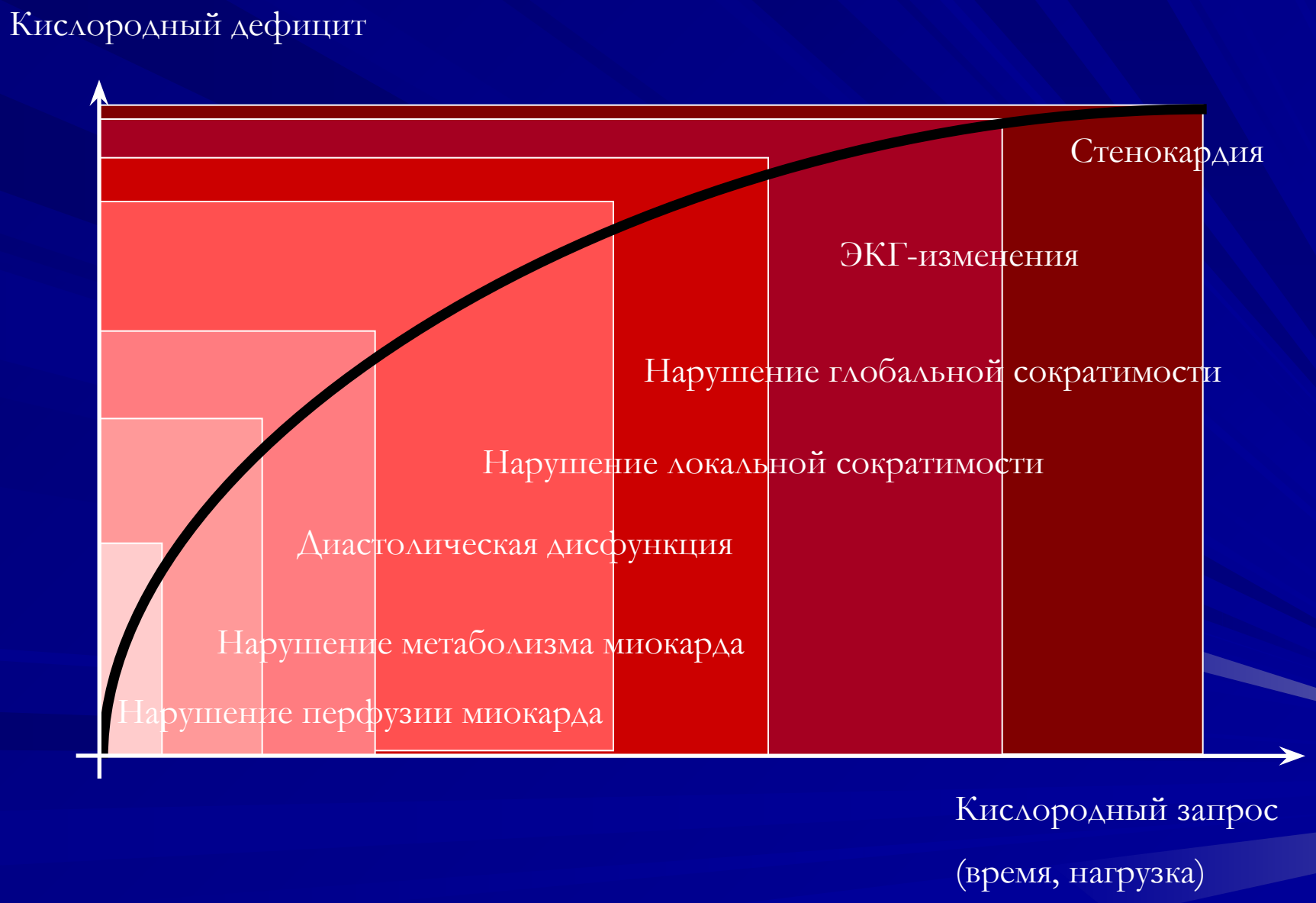

Распространение некроза в ишемизированном миокарде

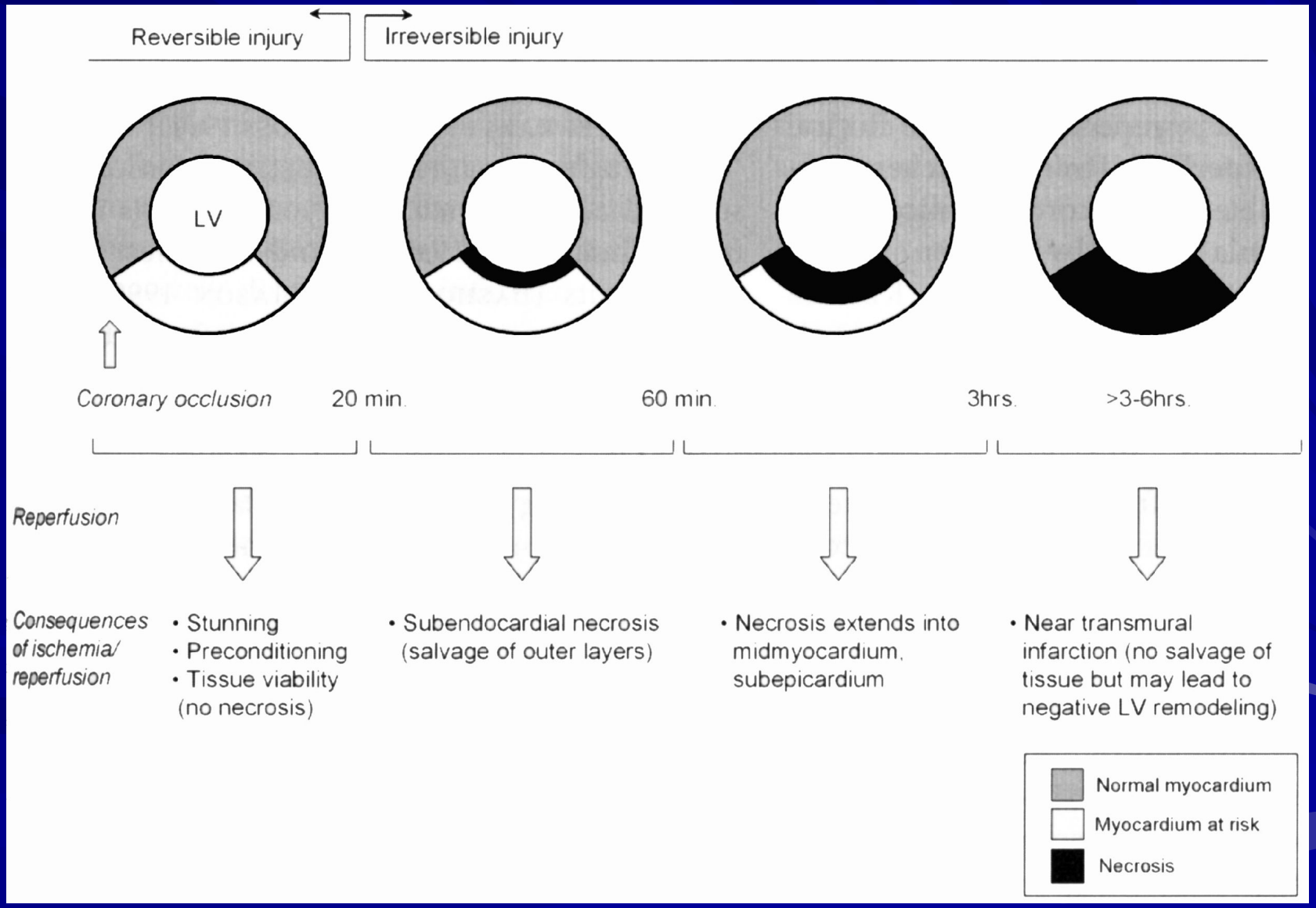

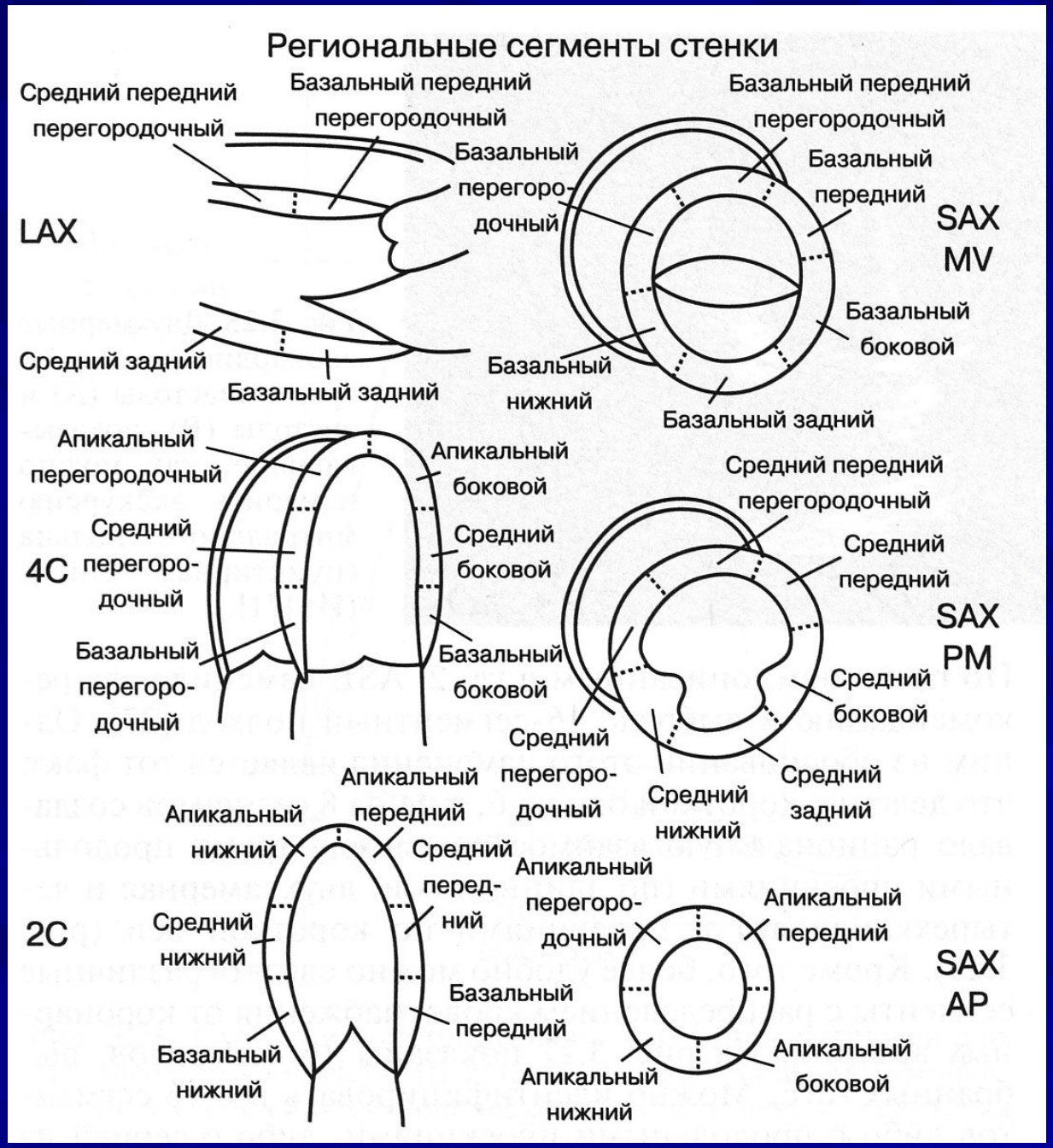
Региональные сегменты стенки
LAX
Средний передний перегородочный
Базальный передний перегородочный
Базальный перегородочный
Средний задний
Базальный задний
SAX MV
Базальный передний перегородочный
Базальный передний
Базальный боковой
Базальный нижний
Базальный задний
4C
Апикальный перегородочный
Апикальный боковой
Средний перегородочный
Средний боковой
Базальный перегородочный
Базальный боковой
SAX PM
Средний передний перегородочный
Средний передний
Средний боковой
Средний перегородочный
Средний нижний
Средний задний
2C
Апикальный нижний
Апикальный передний
Средний нижний
Средний передний
Базальный передний
Базальный нижний
SAX AP
Апикальный перегородочный
Апикальный передний
Апикальный боковой
Апикальный нижний

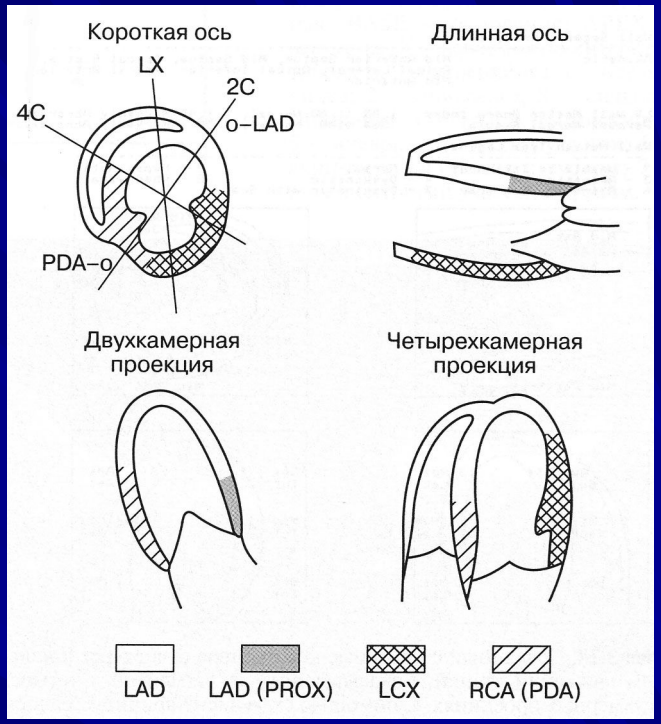
Короткая ось
Длинная ось
LX
2C
4C
o–LAD
PDA–o
Двухкамерная проекция
Четырехкамерная проекция
LAD
LAD (PROX)
LCX
RCA (PDA)

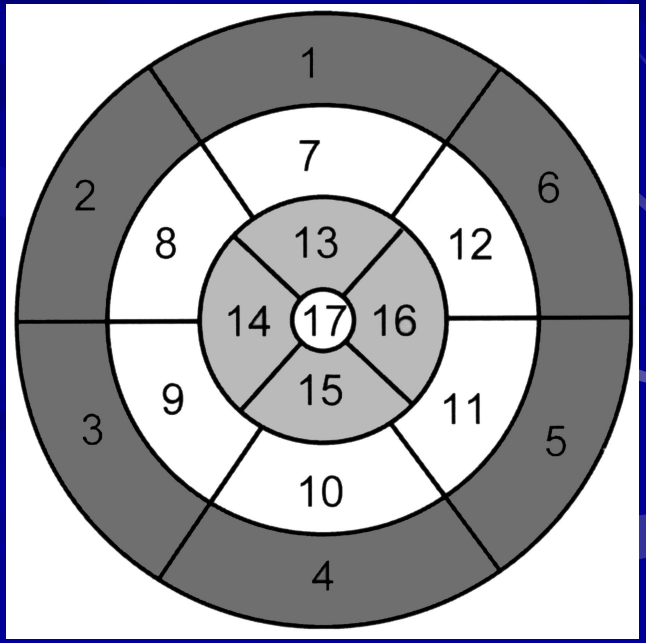
1
2
3
4
5
6
7
8
9
10
11
12
13
14
15
16
17

Визуальная оценка подвижности стенки миокарда

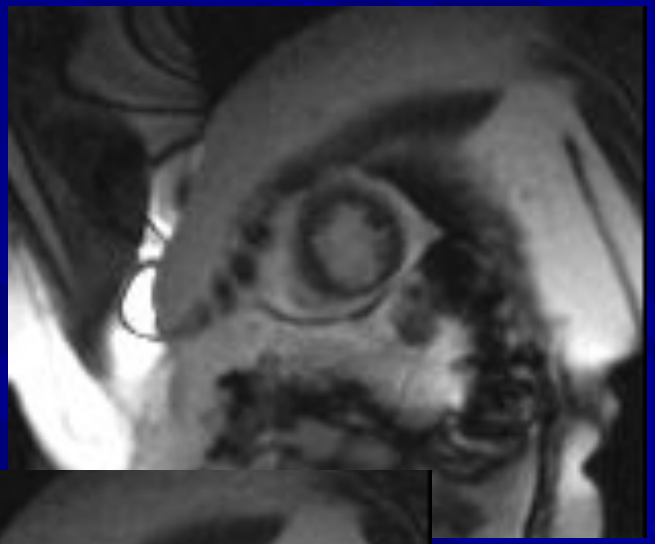

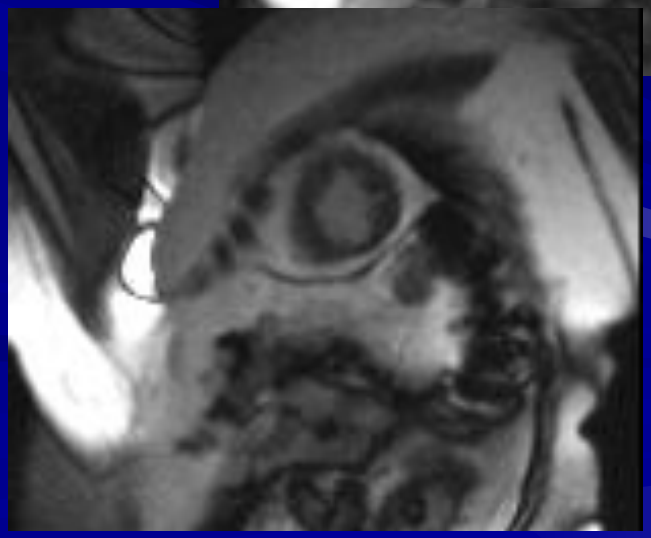

Оценка локальной подвижности и утолщения миокарда левого желудочка

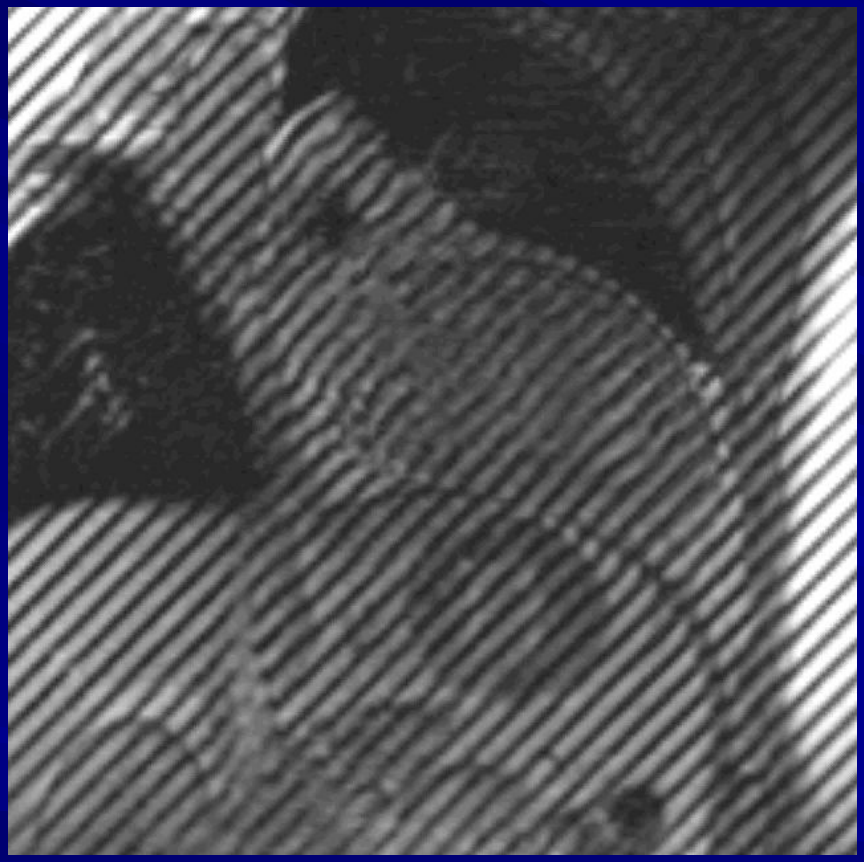

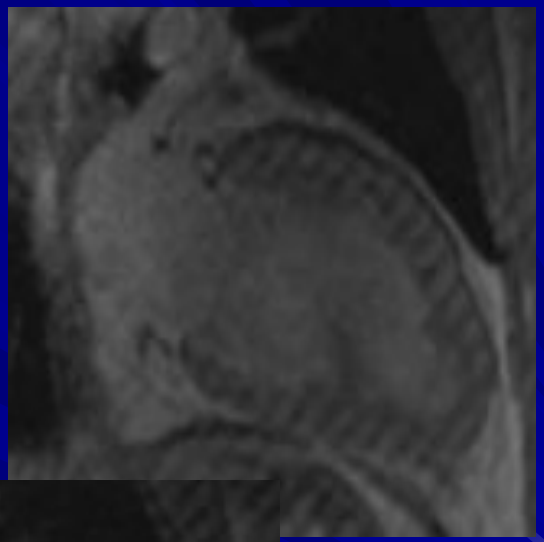

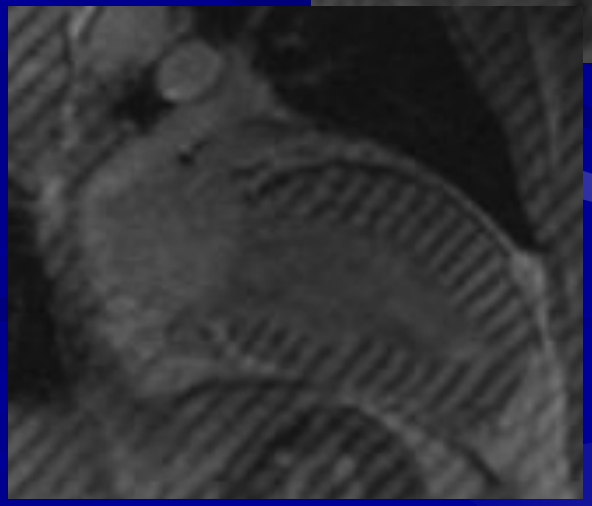

Flash_tagging

Оценка локальной подвижности и утолщения миокарда левого желудочка

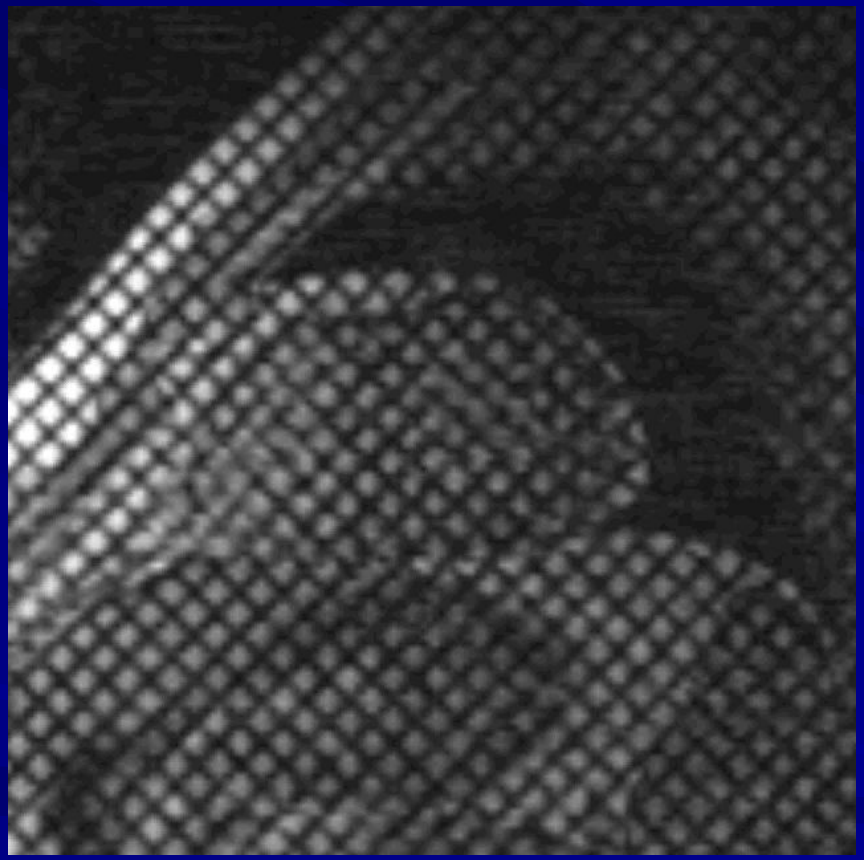

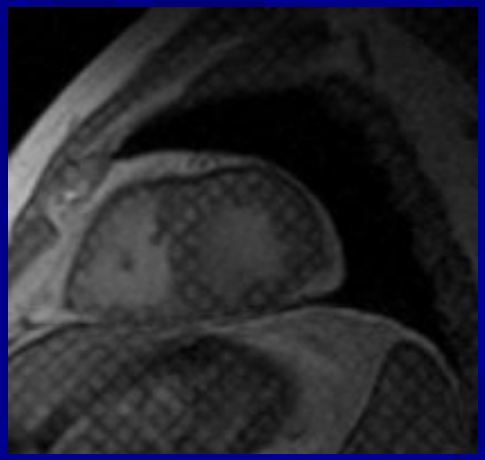

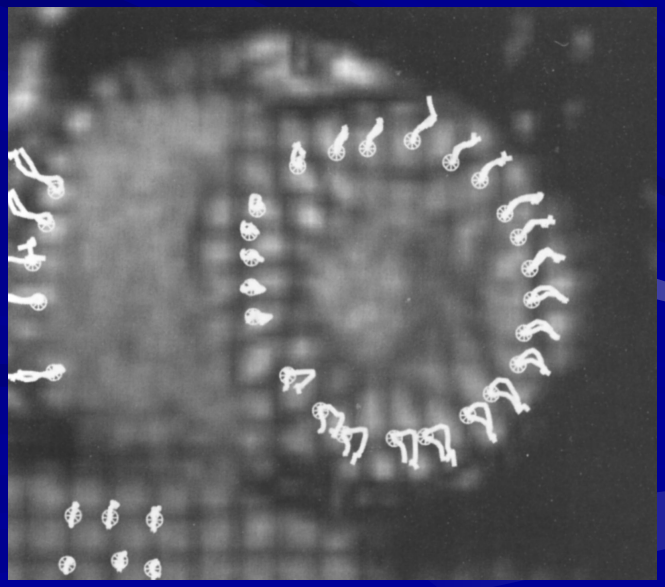

Flash_tagging

Оценка локальной подвижности и утолщения миокарда левого желудочка

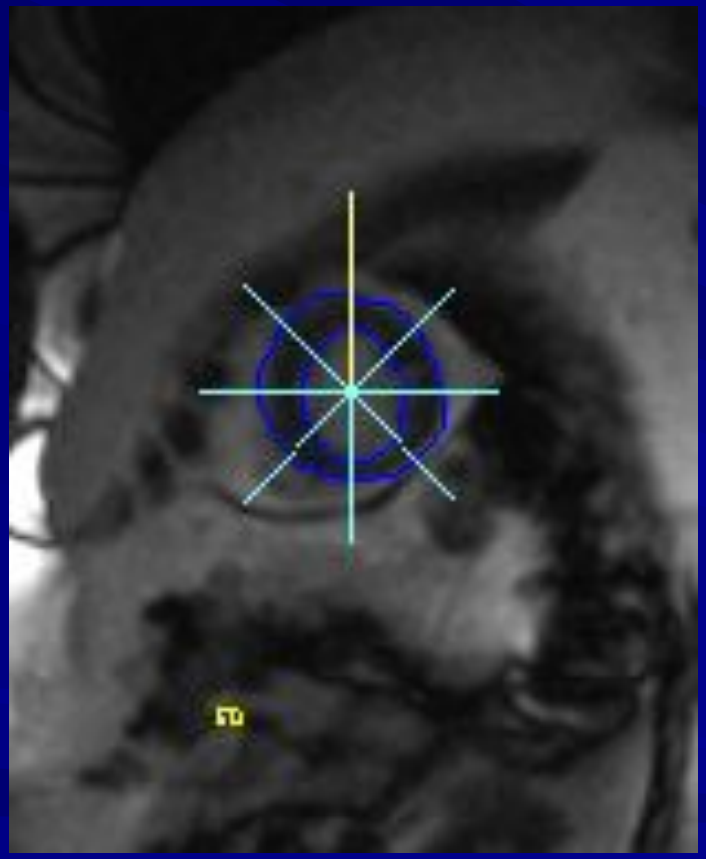

систола

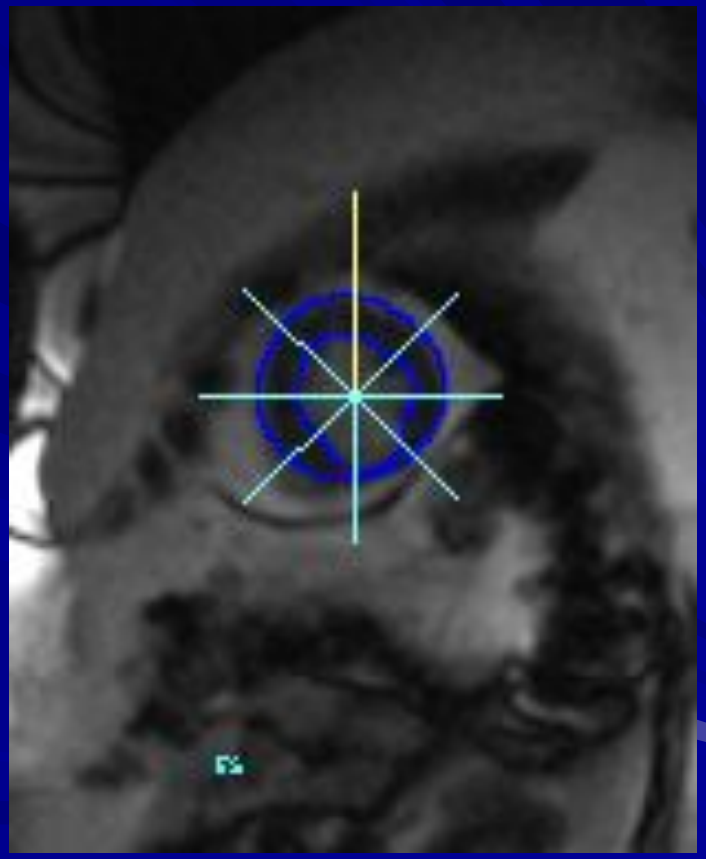

диастола

Оценка локальной подвижности и утолщения миокарда левого желудочка

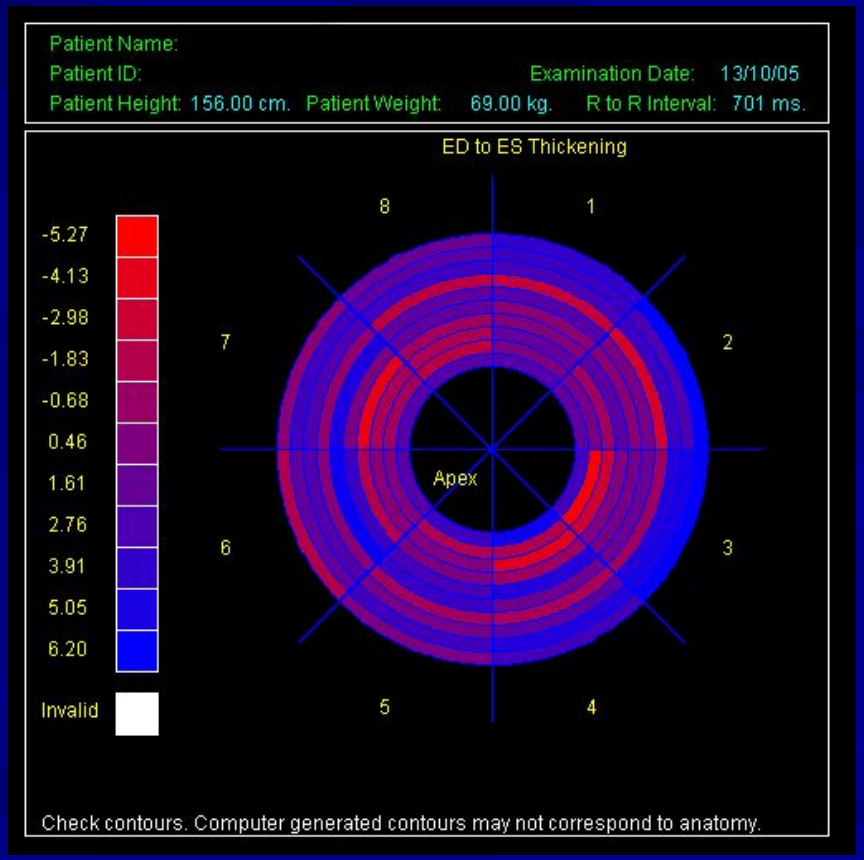

Систолическое утолщение

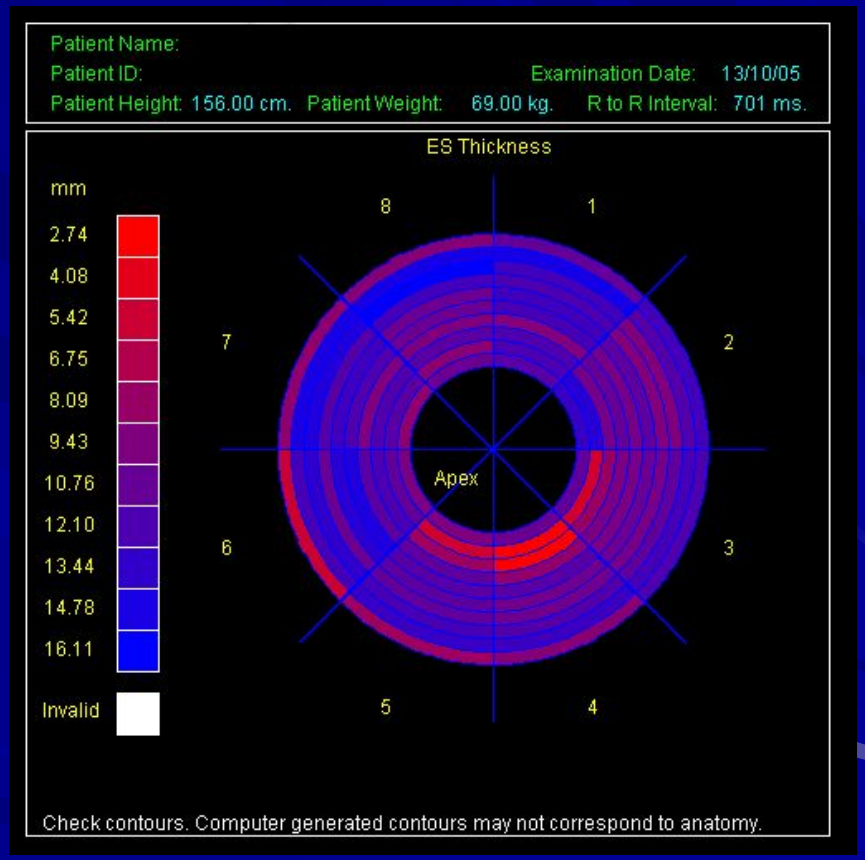

Толщина

Нагрузочные пробы

Добутамин (5, 10, 20, 30, 40 мкг/кг/мин)	Обладает высокой воспроизводимостью результатов. Может использоваться для оценки жизнеспособного миокарда. Высокий риск развития осложнений. Требует проведения оценки региональной подвижности после каждой ступени нагрузки.
Аденозин (140 мкг/кг/мин в течении 6 мин)	Обладает высокой управляемостью и меньшей частотой развития осложнений. Более низкая чувствительность по сравнению с добутамином.
Дипиридамол (0,56 мг/кг/мин в течении 4 мин)	Меньшая управляемость по сравнению с аденозином

Стресс – МРТ с формакологической положительной пробой (добутамин)

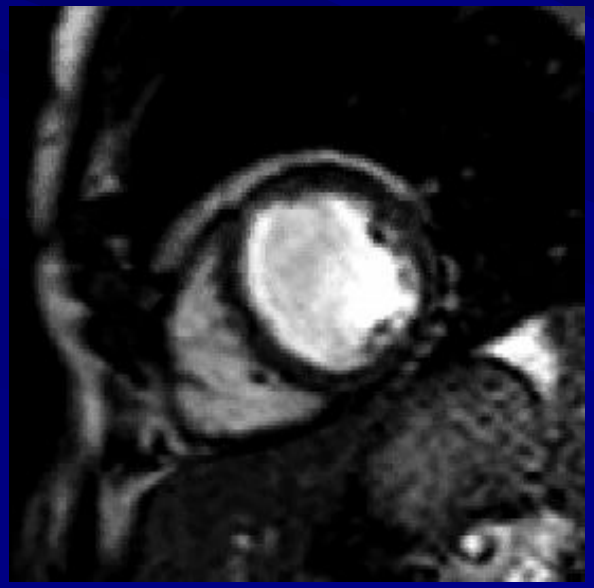

Покой

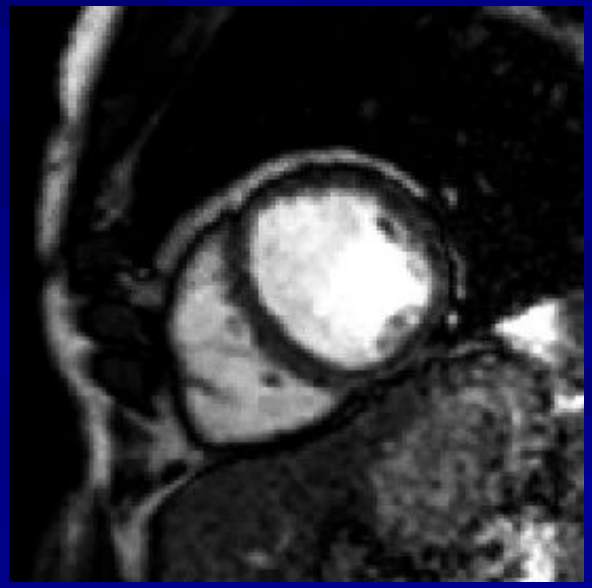

10 мкг/кг/мин

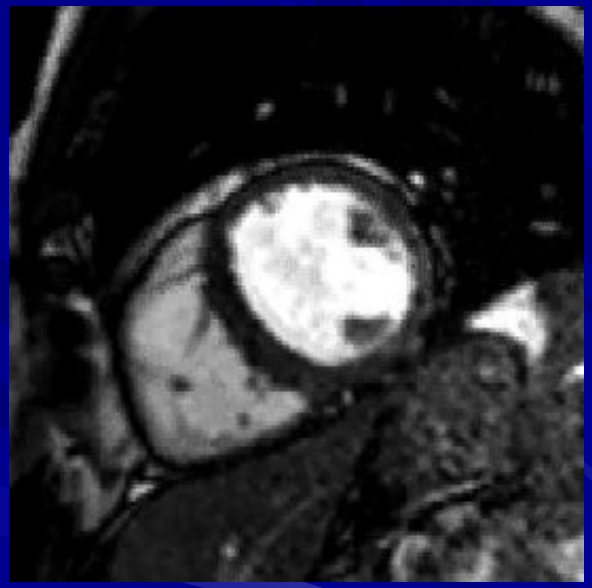

40 мкг/кг/мин

Стресс – МРТ с фармакологической положительной пробой (добутамин)

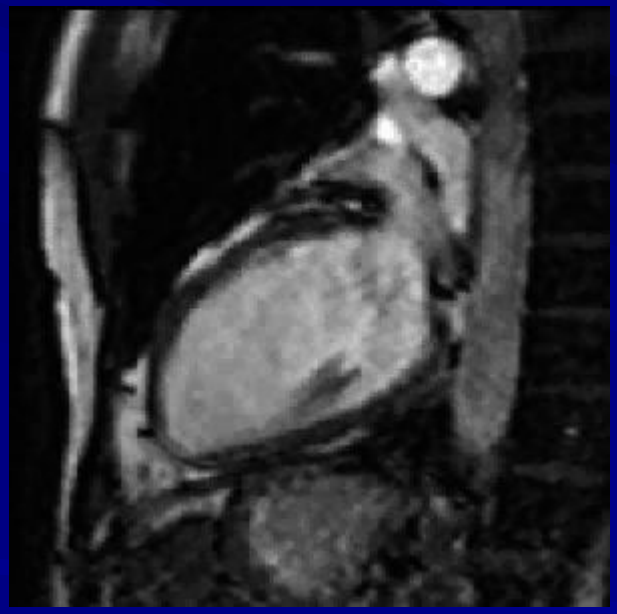

Покой

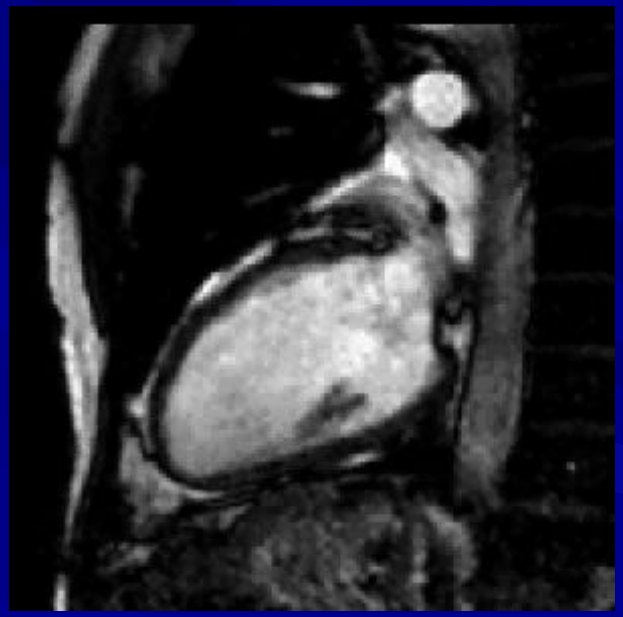

10 мкг/кг/мин

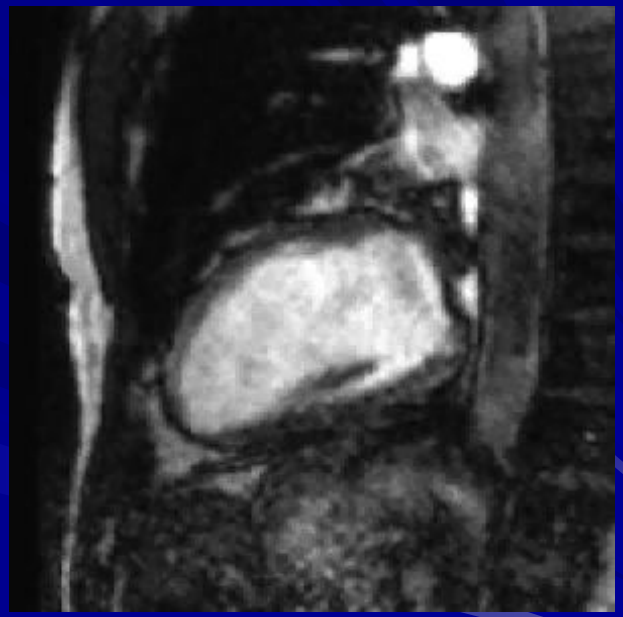

40 мкг/кг/мин

Перфузионная МРТ сердца

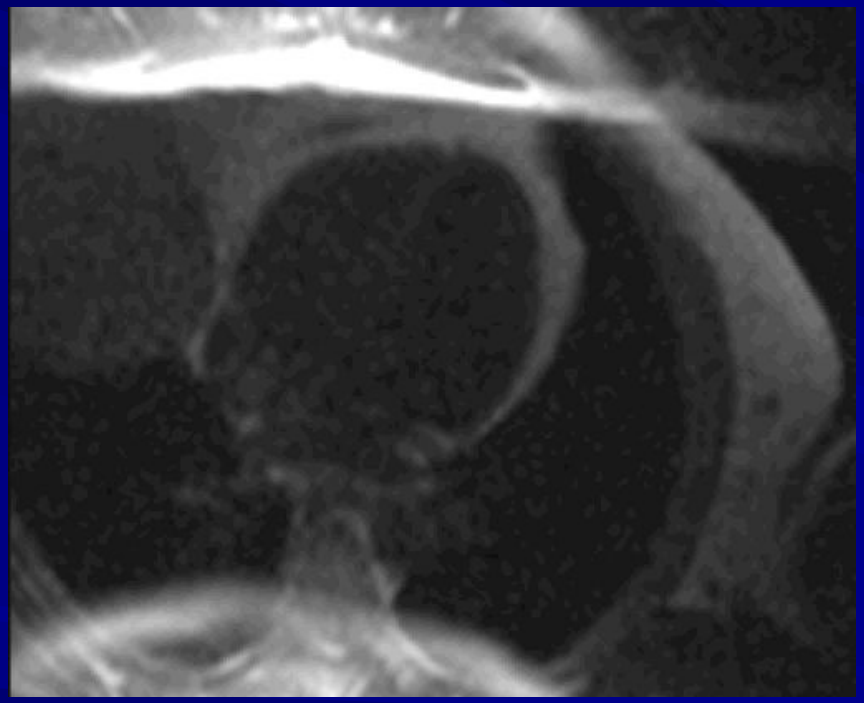

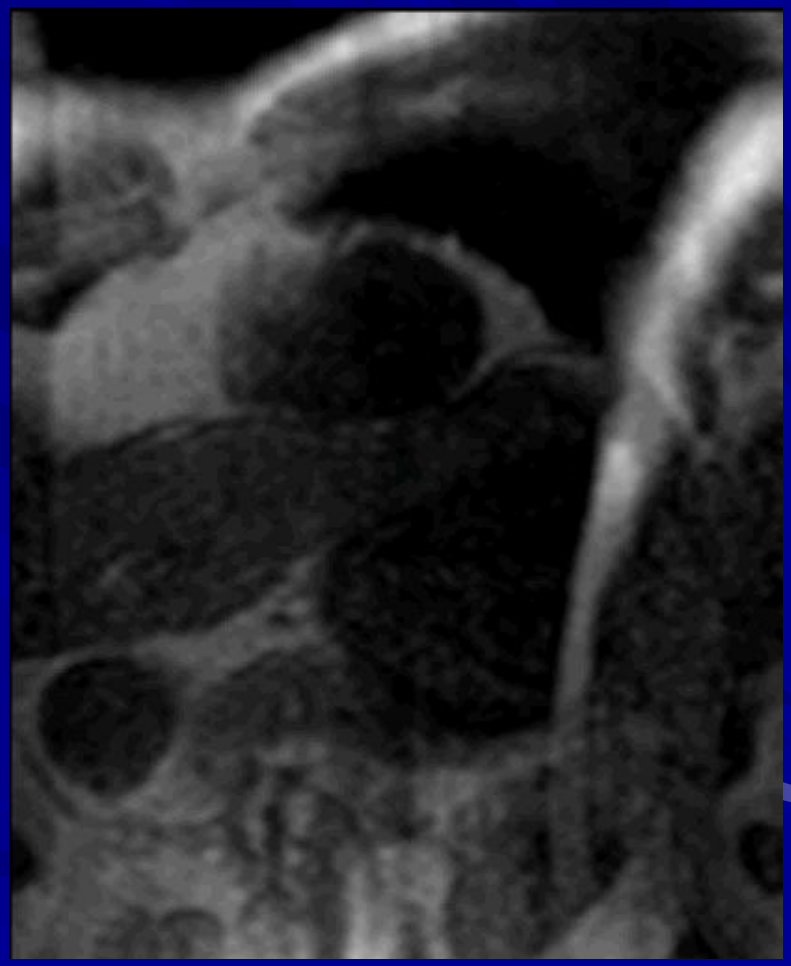

Повреждение миокарда без инфаркта

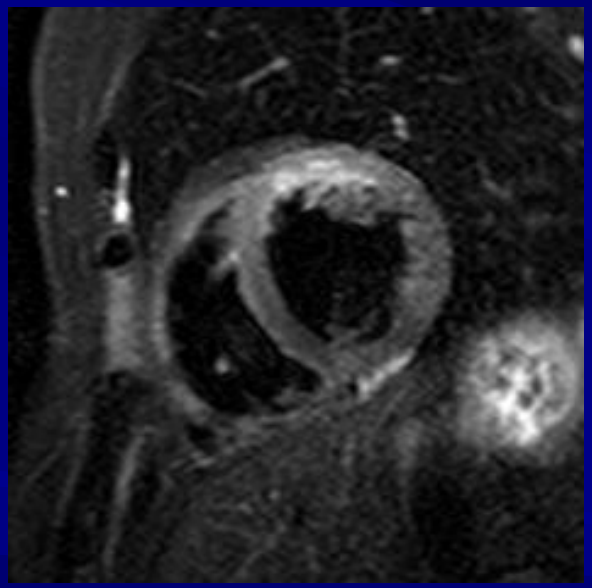

T2

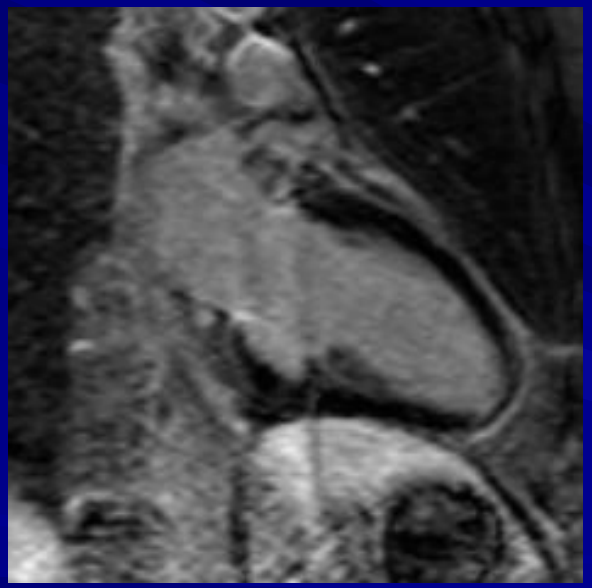

IR

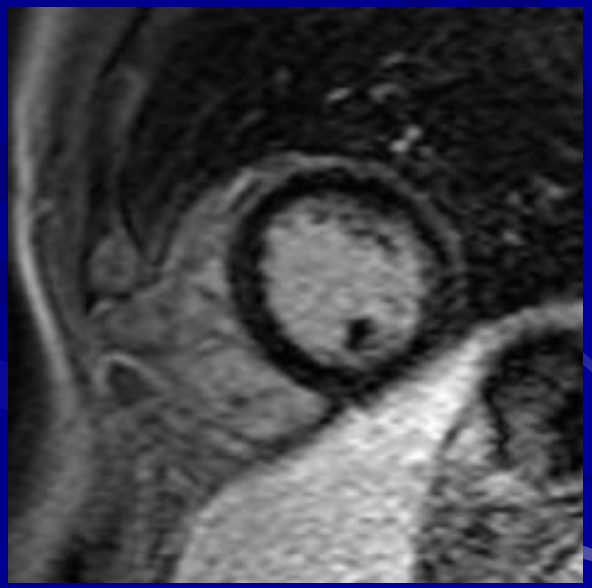

IR

Повреждение миокарда без инфаркта

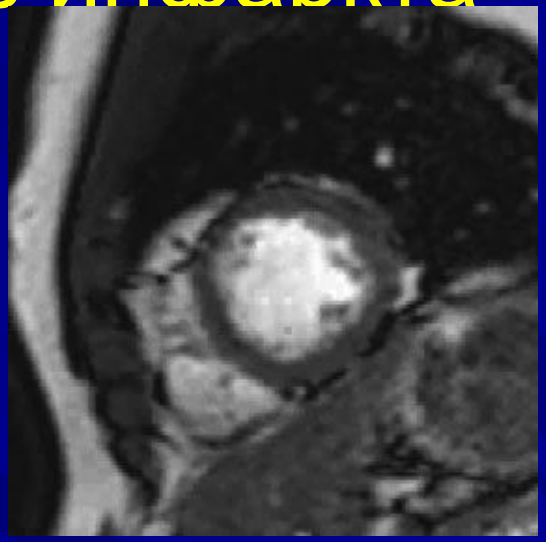

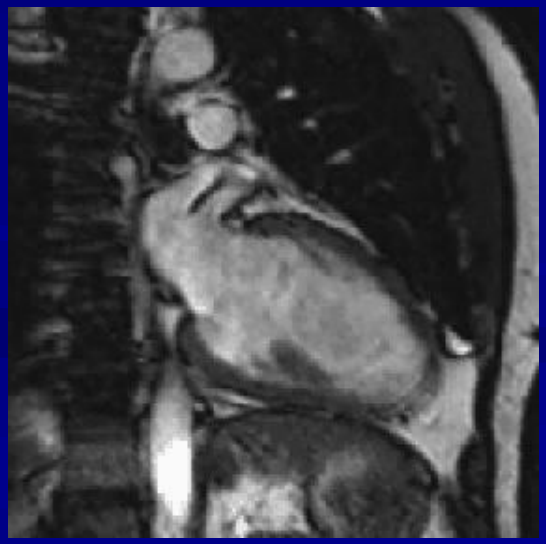

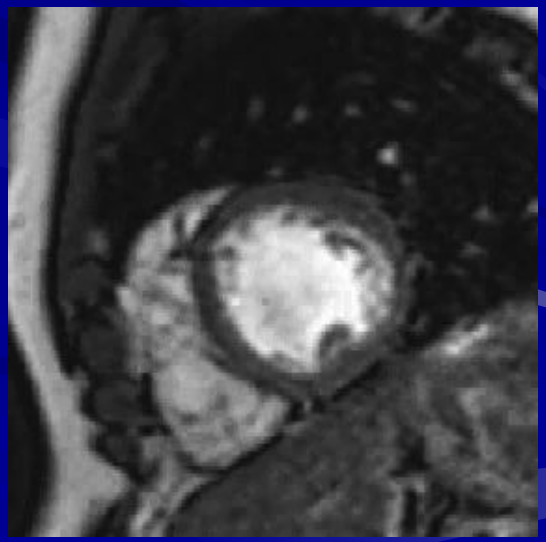

Субэндокардиальный инфаркт миокарда

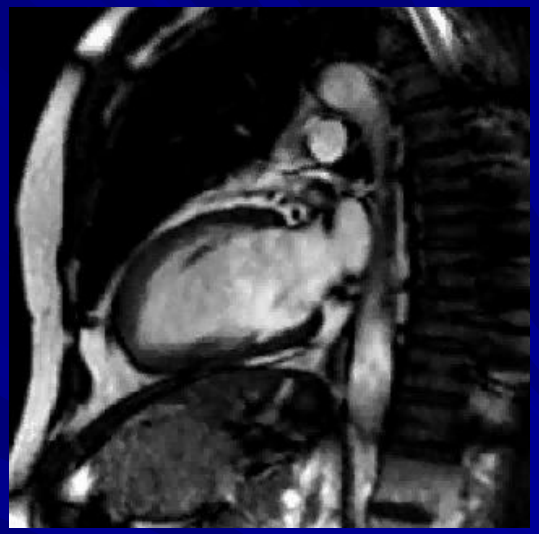

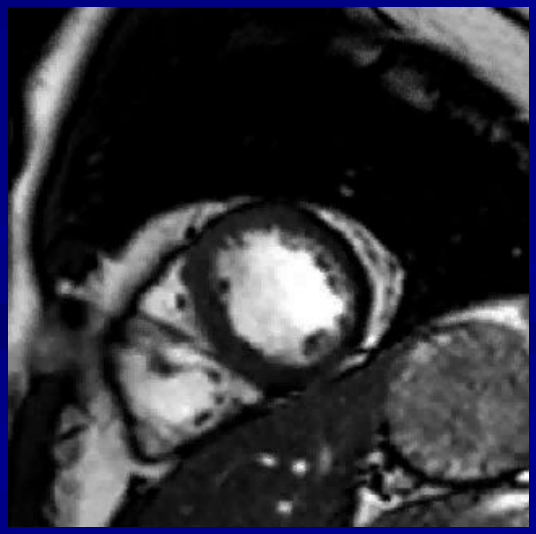

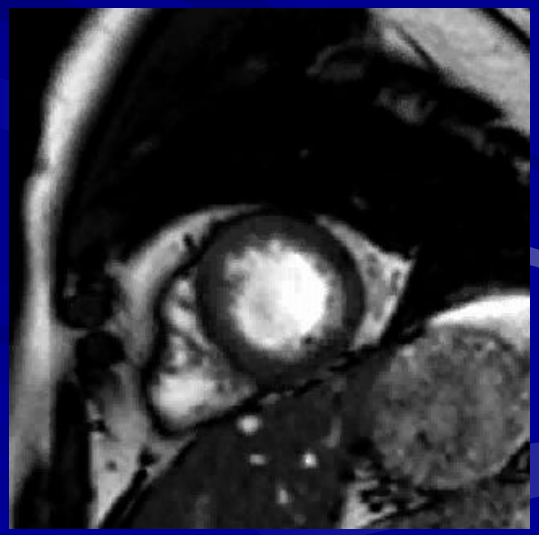

Субэндокардиальный острый инфаркт миокарда

T2

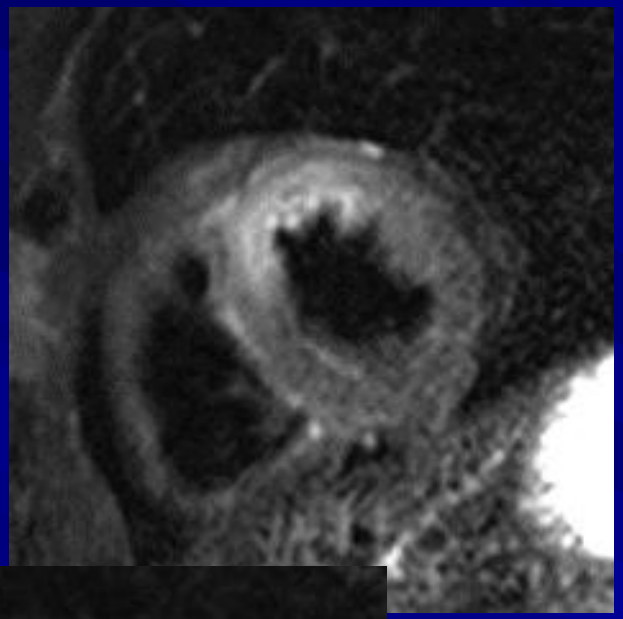

ОН

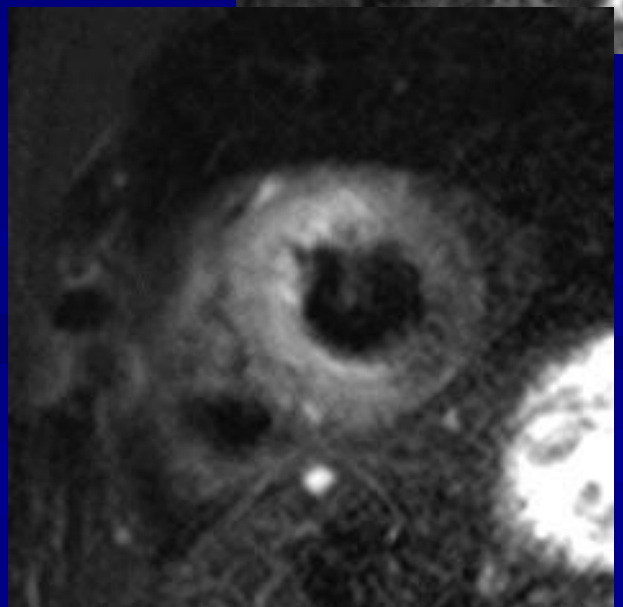

Трансмуральный инфаркт миокарда

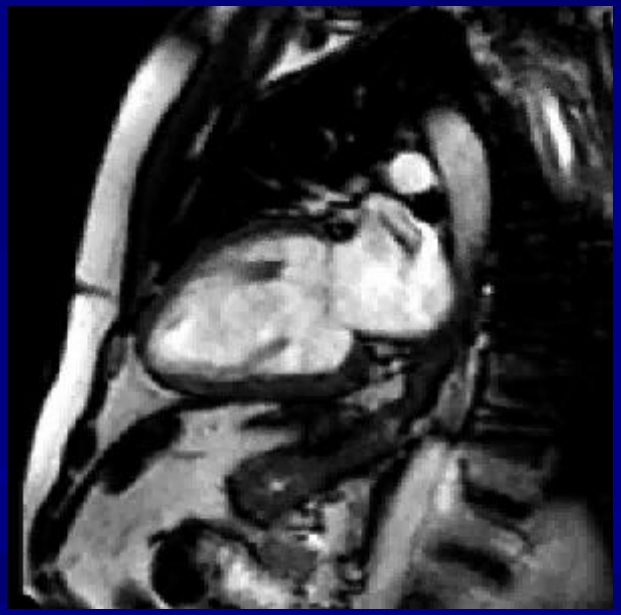

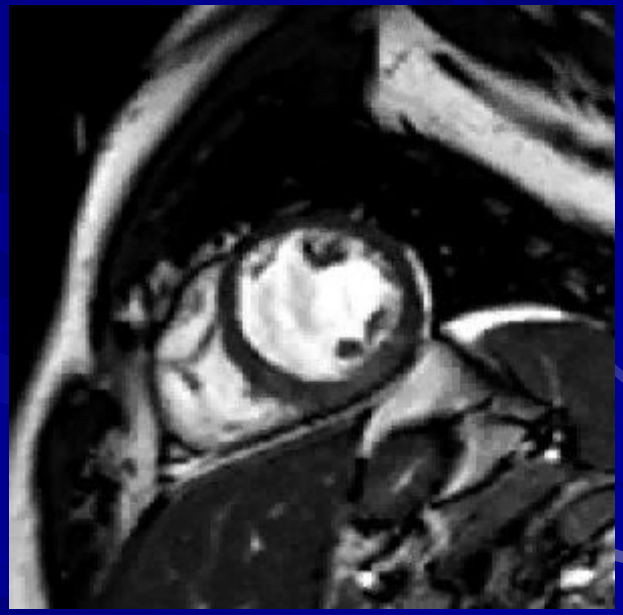

Трансмуральный инфаркт миокарда

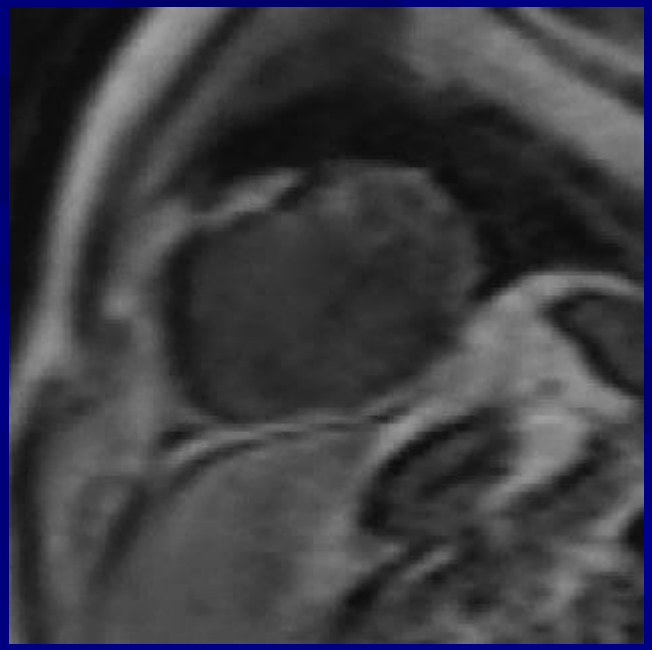

TF

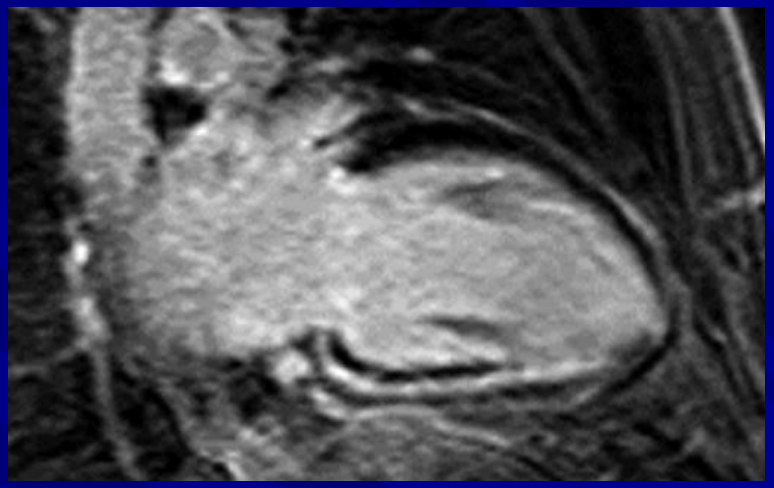

IR

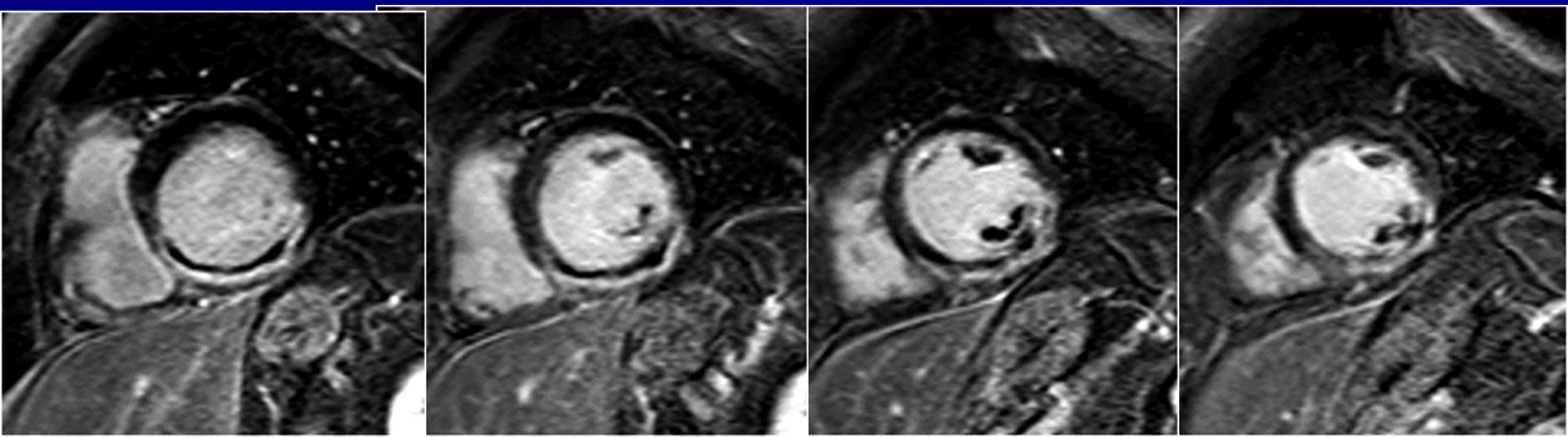

Ишемическая кардиомиопатия с аневризмой в области верхушки и пристеночным тромбом

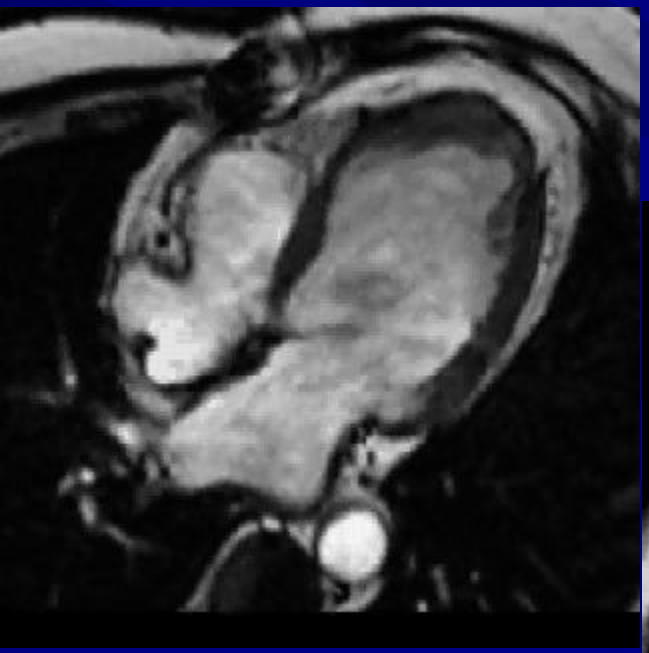

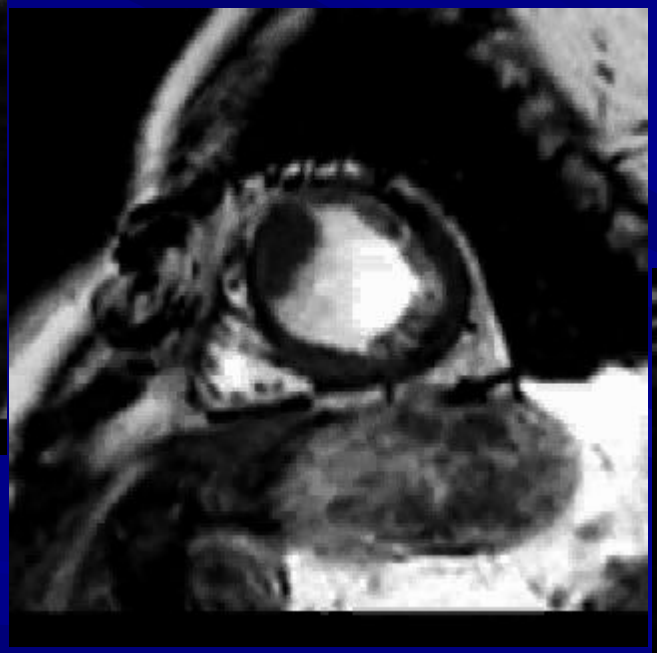

Ишемическая кардиомиопатия с аневризмой в области верхушки и пристеночным тромбом

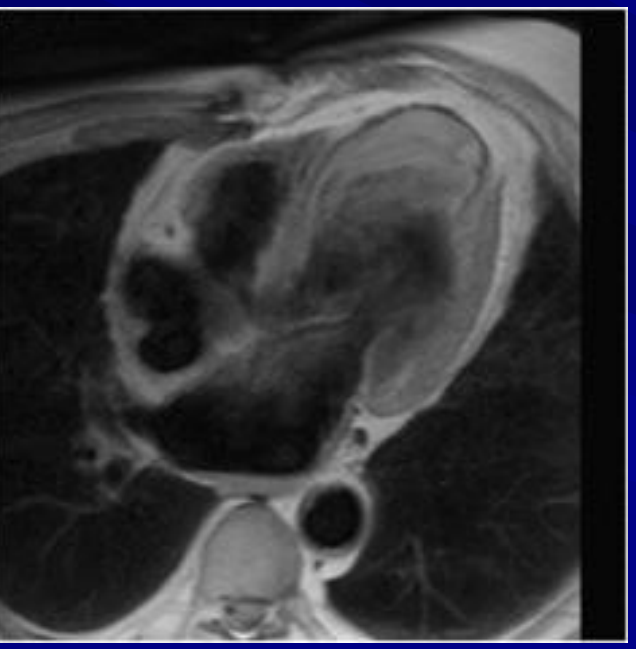

SE dark blood

IR

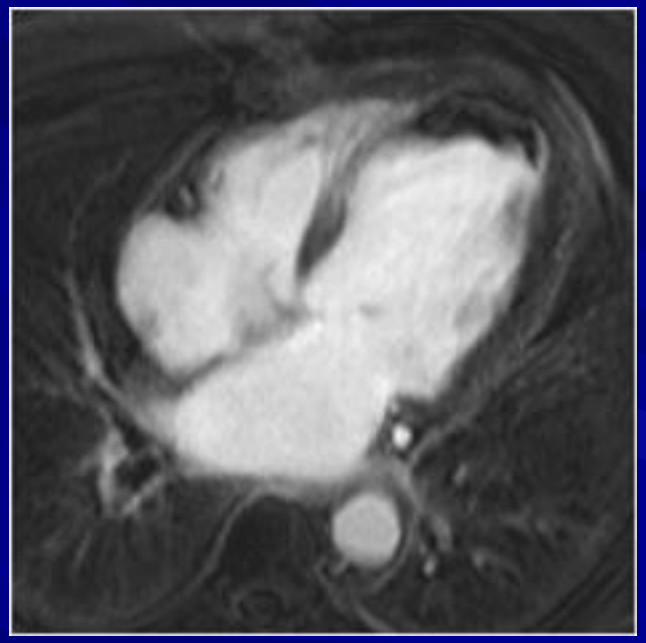

T2

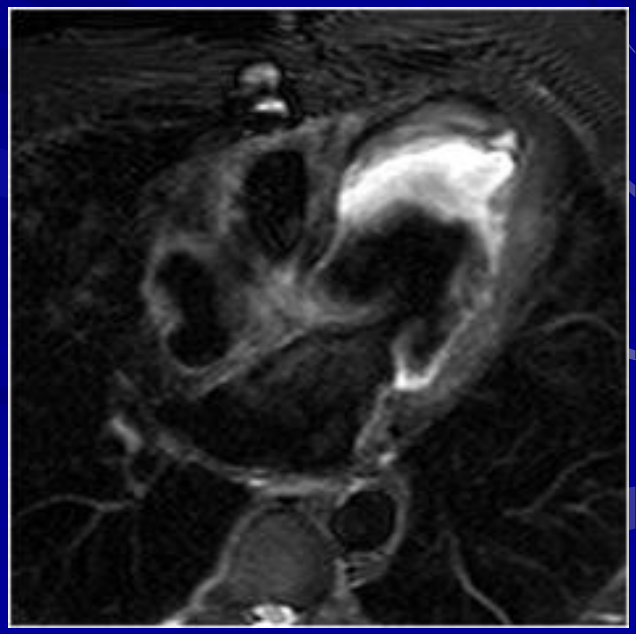

Геморрагический инфаркт миокарда

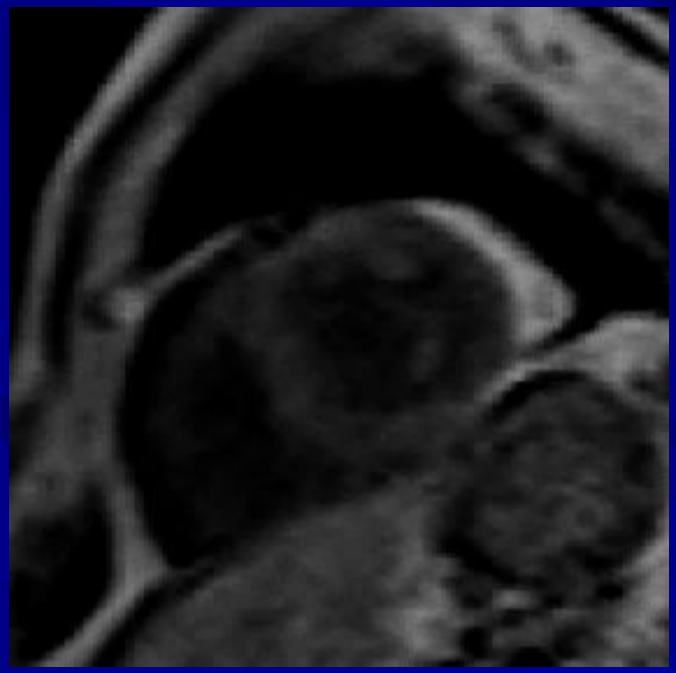

Геморрагический инфаркт миокарда

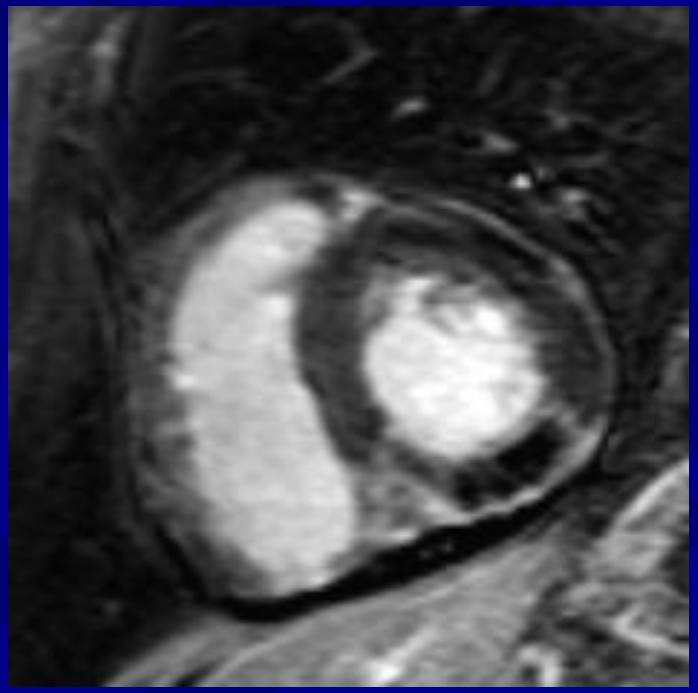

SE

TF
perf

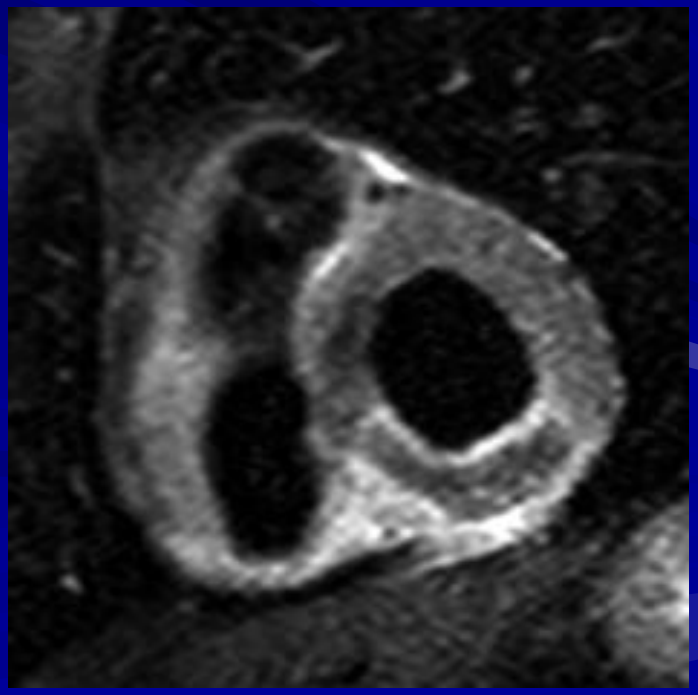

T2

Дисфункция левого желудочка с восстановлением после реваскуляризации (гибернированый миокард)

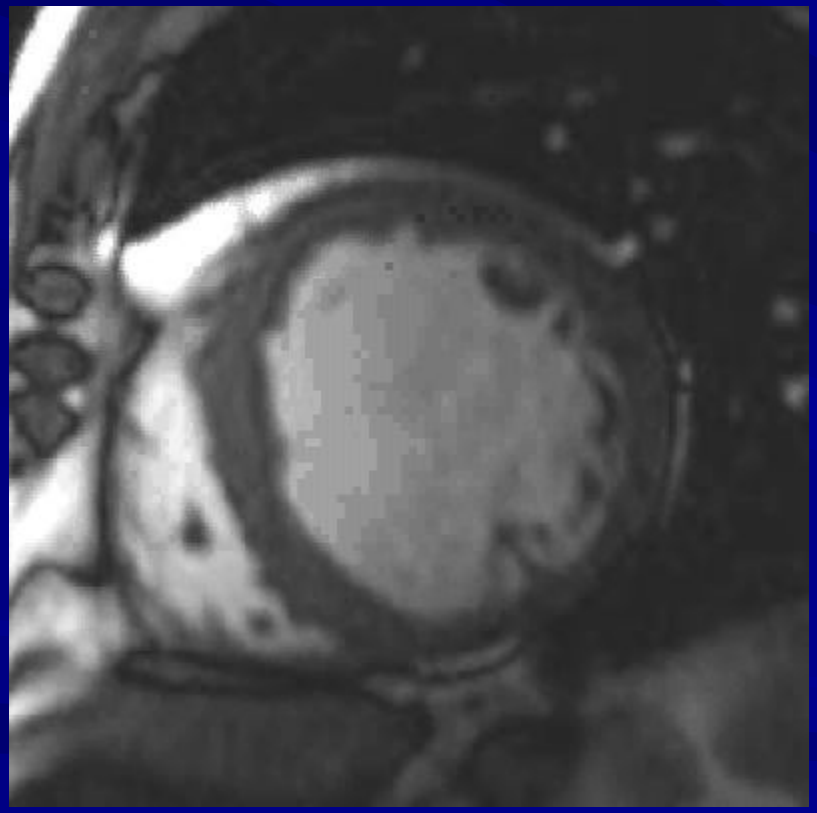

Дисфункция левого желудочка с восстановлением после реваскуляризации (гибернированый миокард)

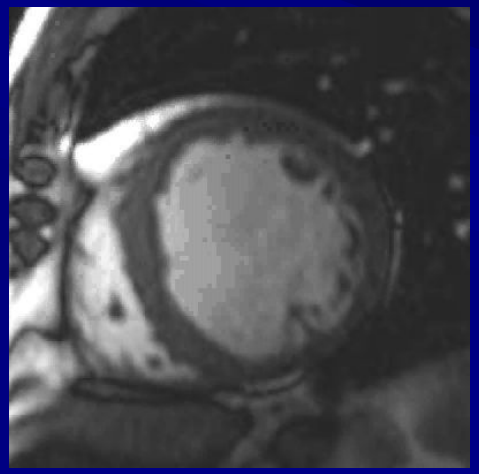

Перед реваскуляризацией

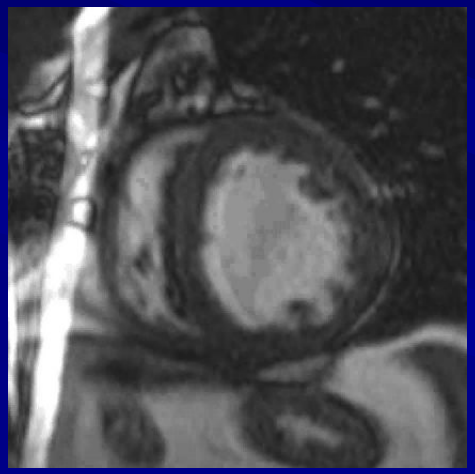

6 месяца после

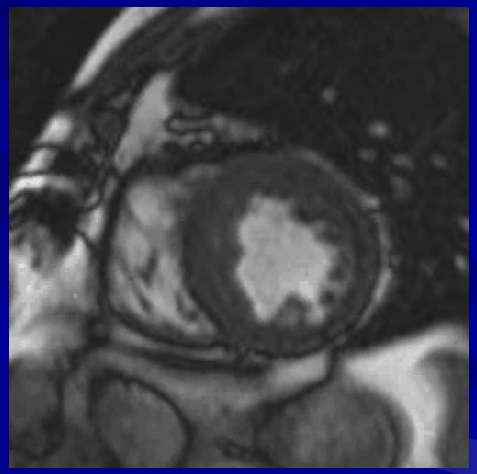

4 месяца

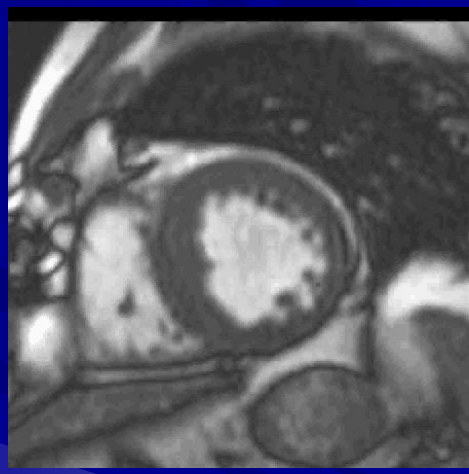

6 месяцев

Опухоли сердца

Миксома левого предсердия

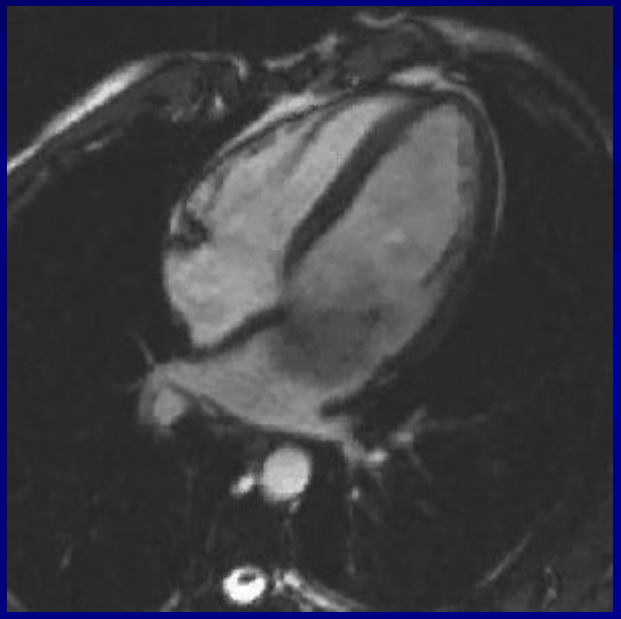

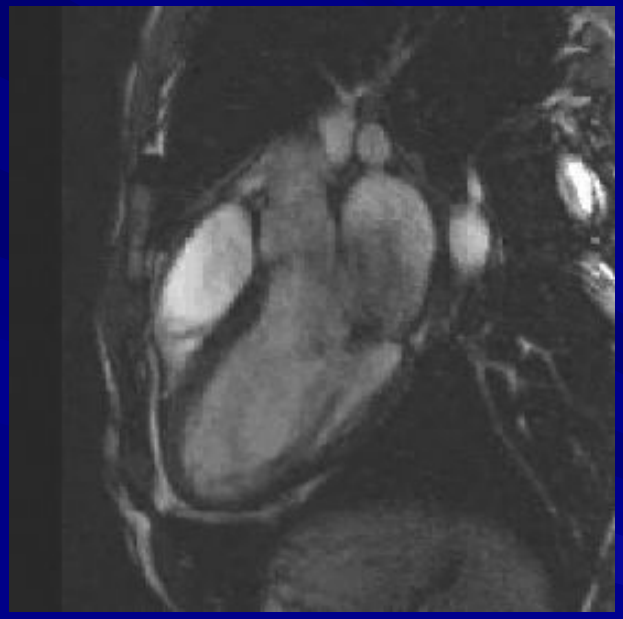

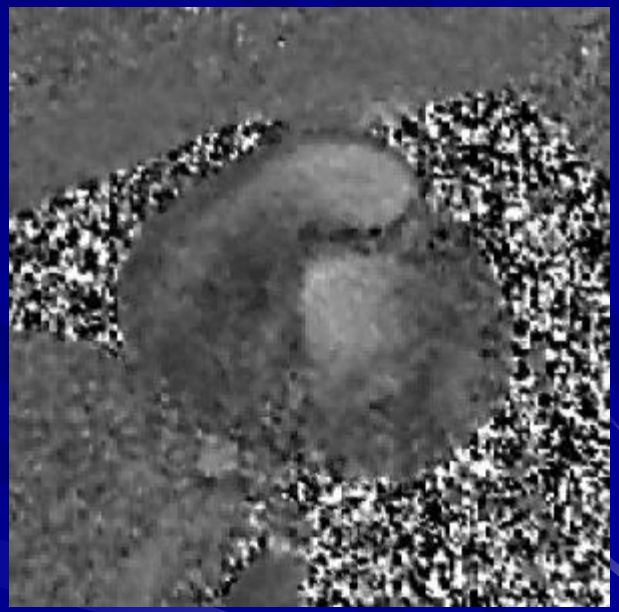

Множественные метастазы меланомы

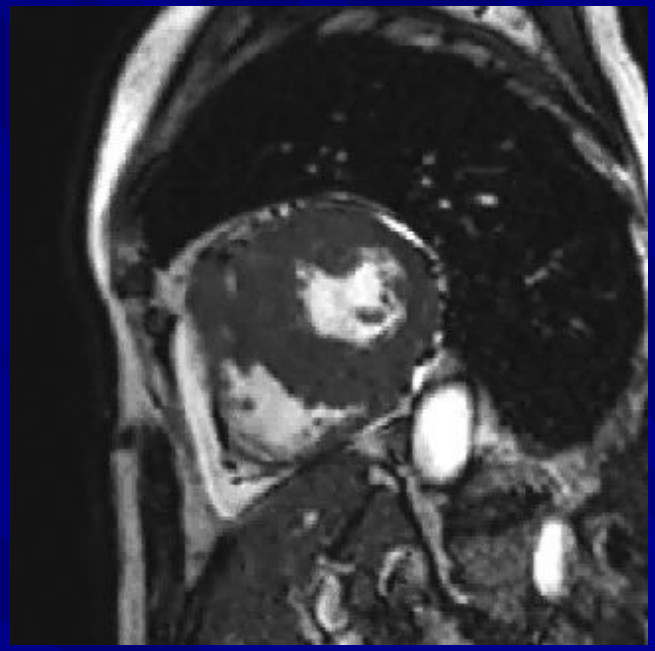

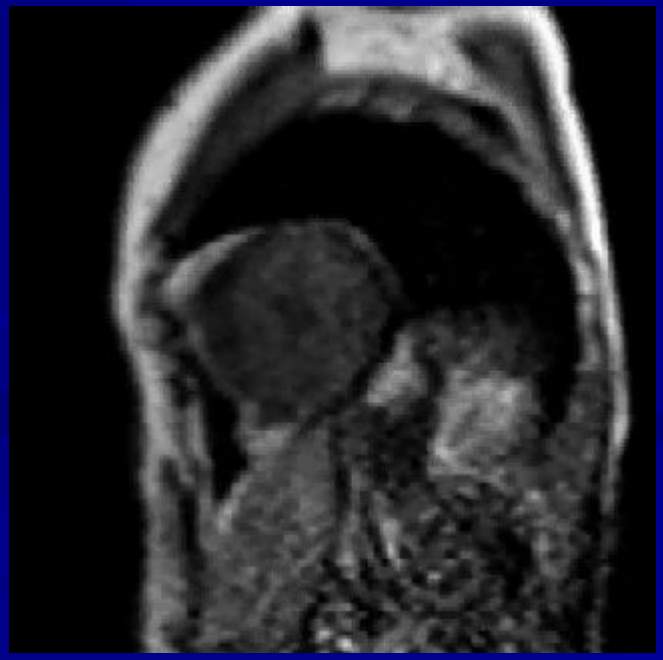



Множественные метастазы меланомы

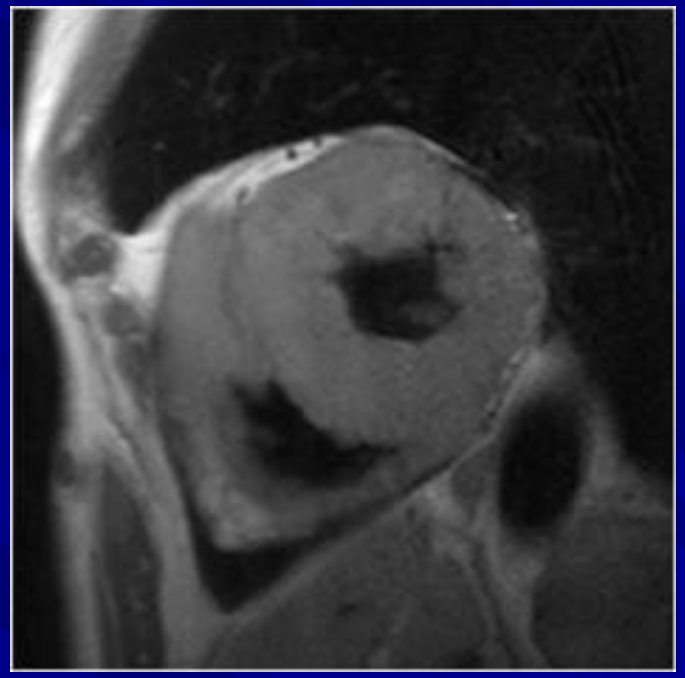

SE

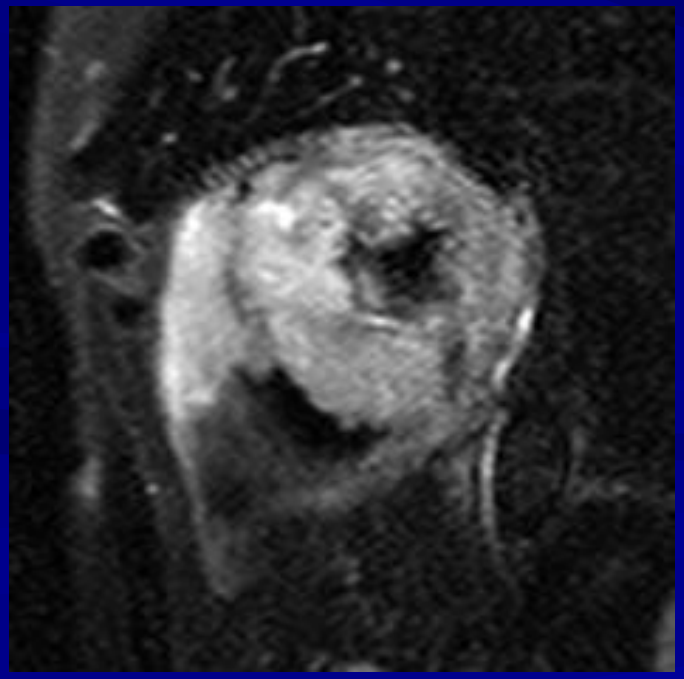

STIR

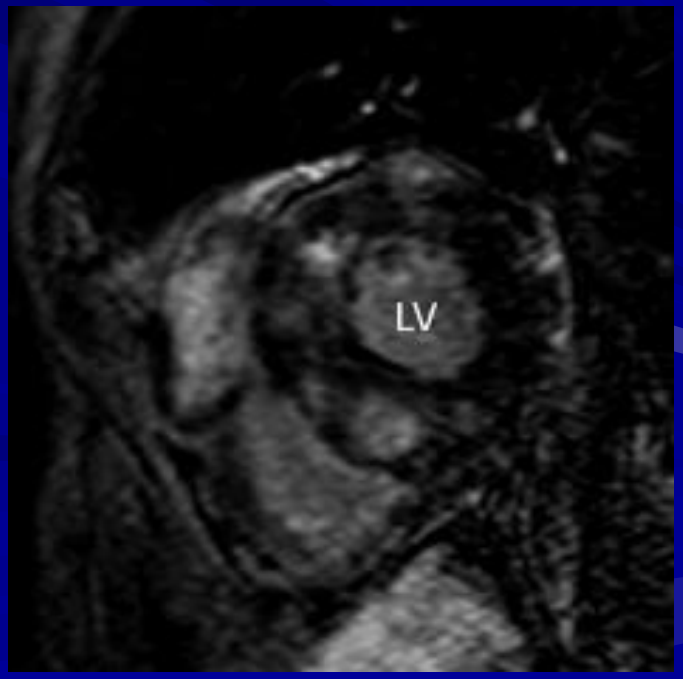

IR

Лимфома

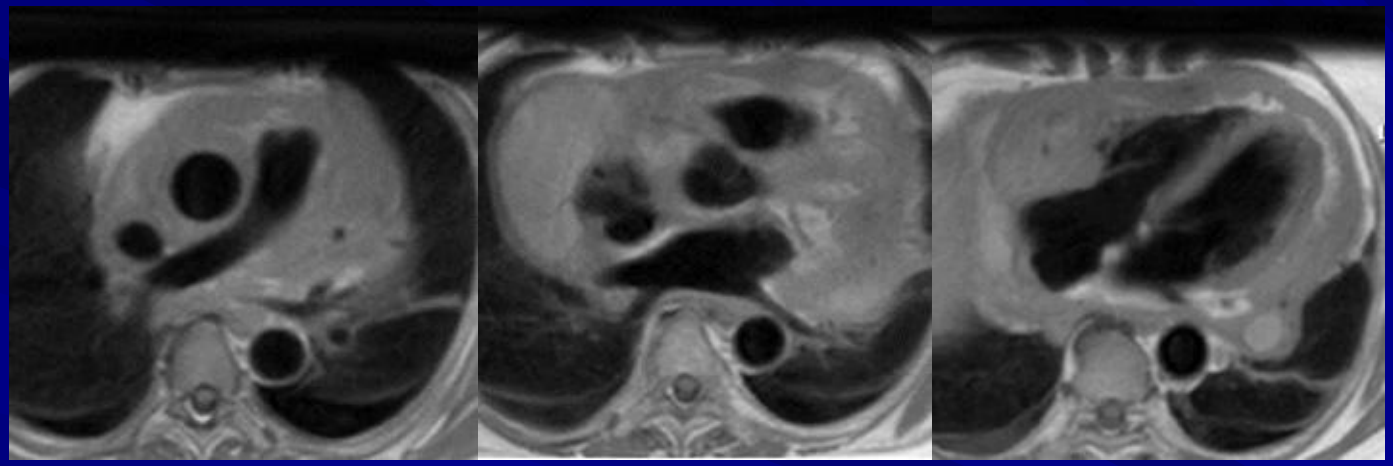

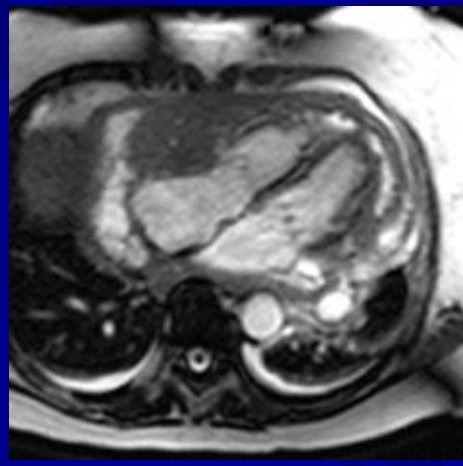

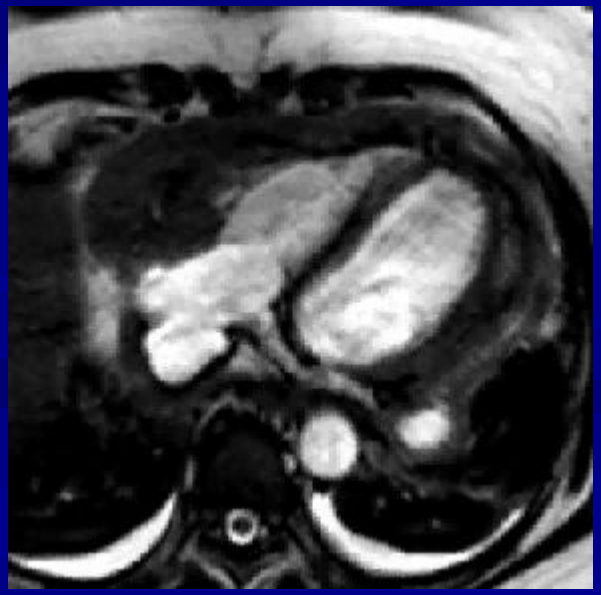

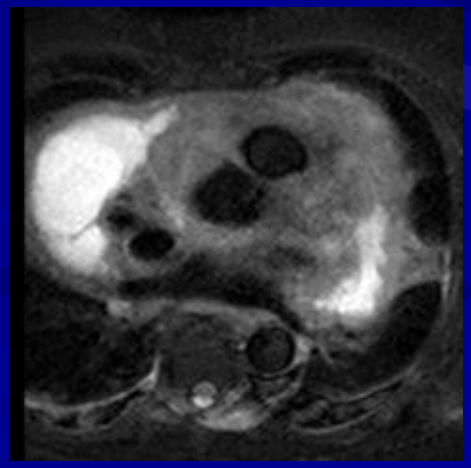

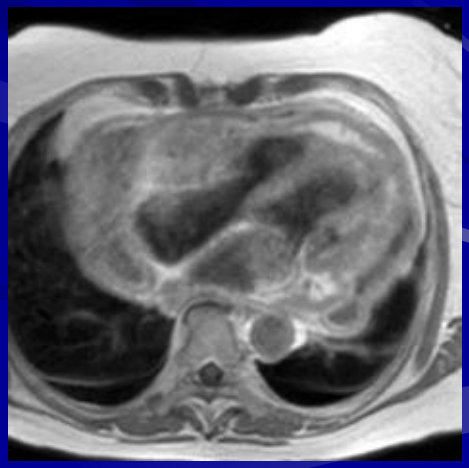

Неишемические заболевания сердца

Аритмогенная дисплазия миокарда правого желудочка

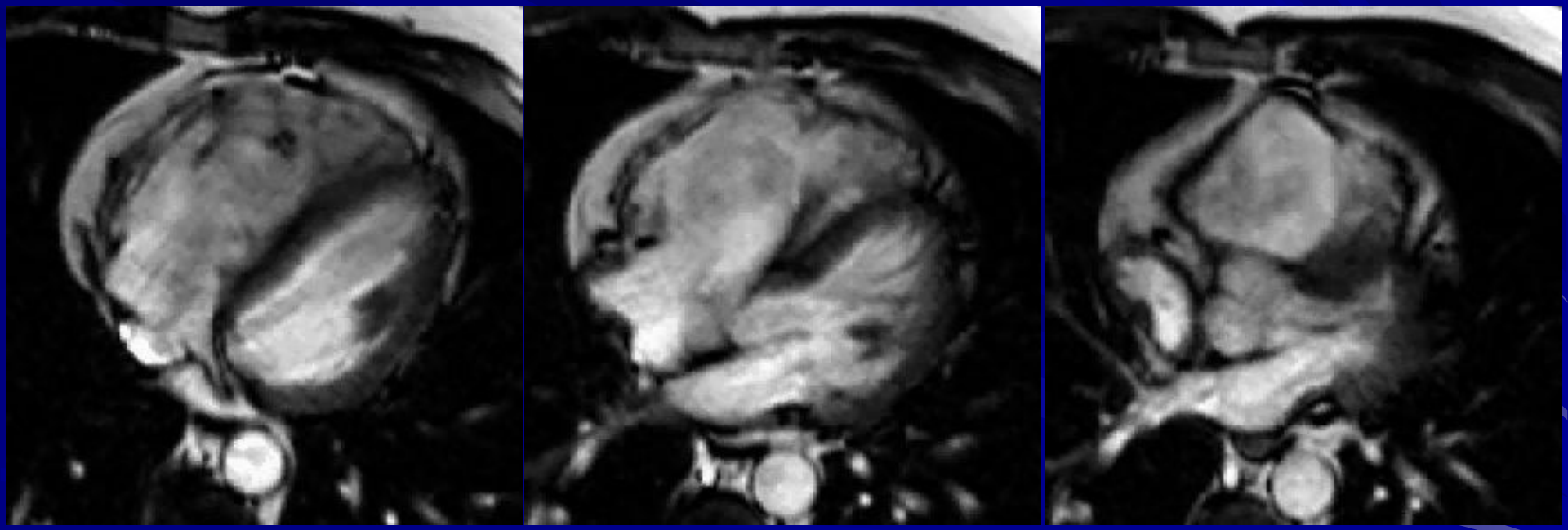

Аритмогенная дисплазия миокарда правого желудочка

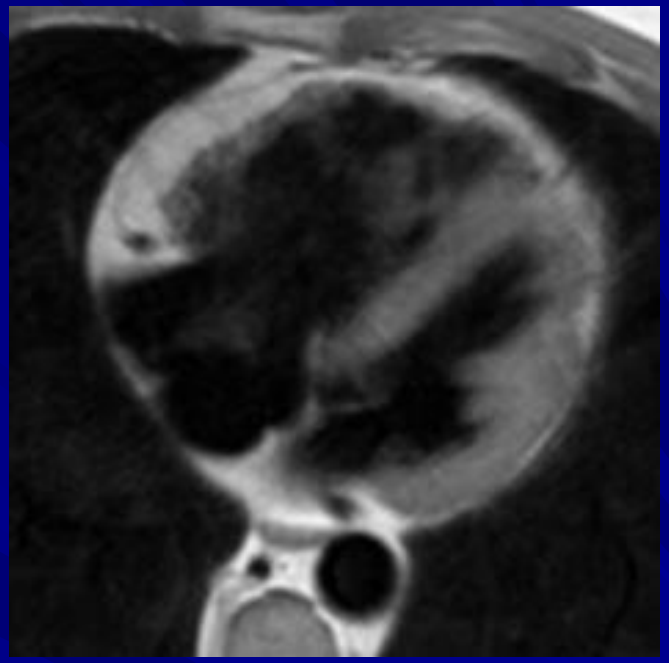

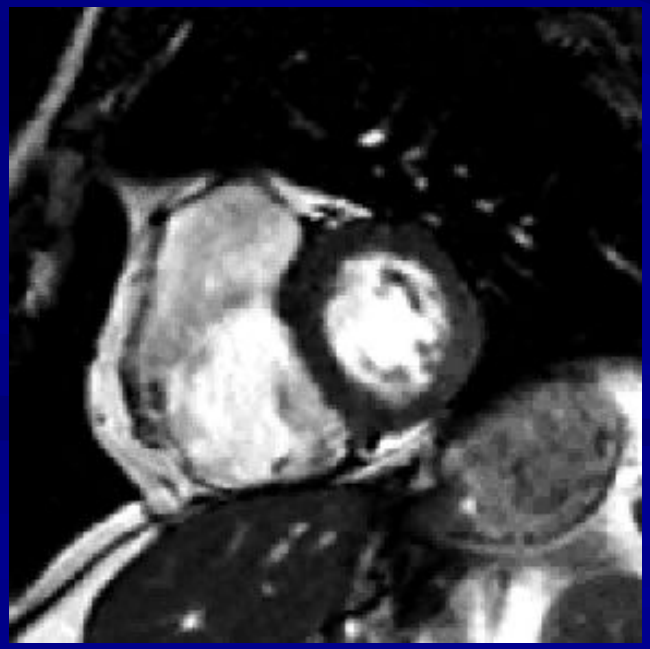

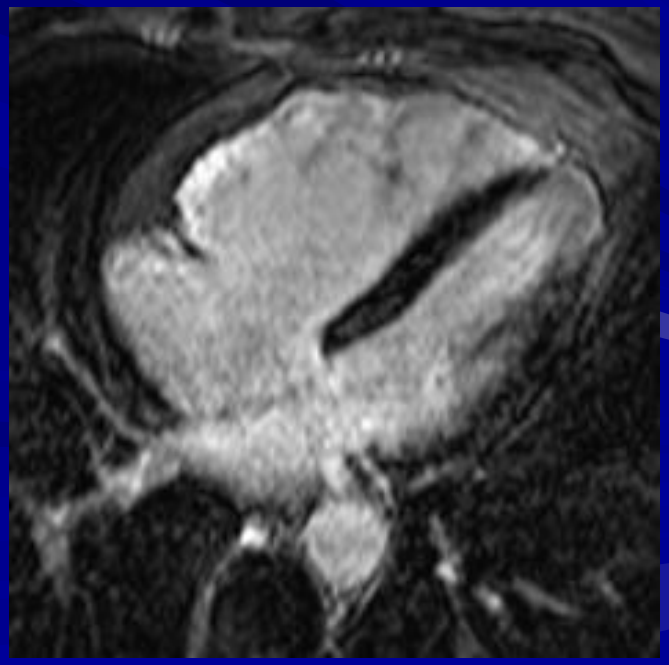

Некомпактный миокард

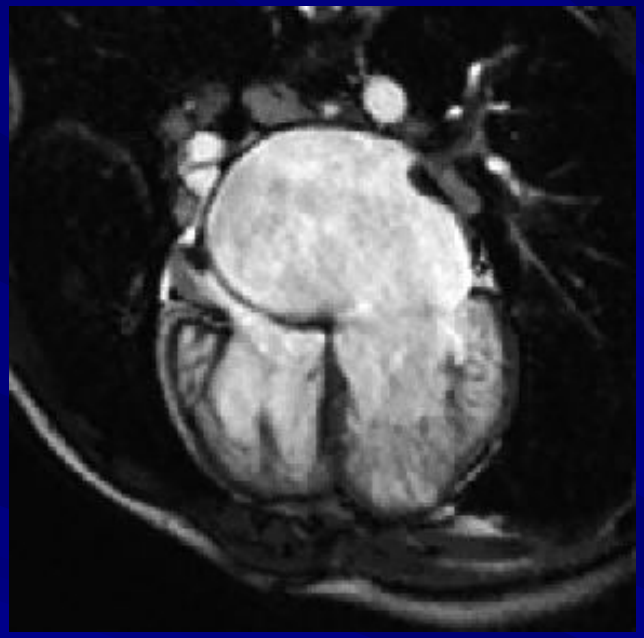

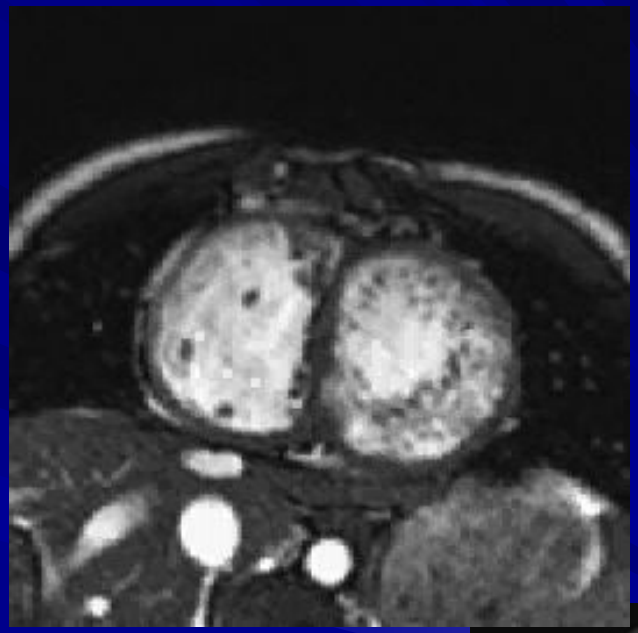

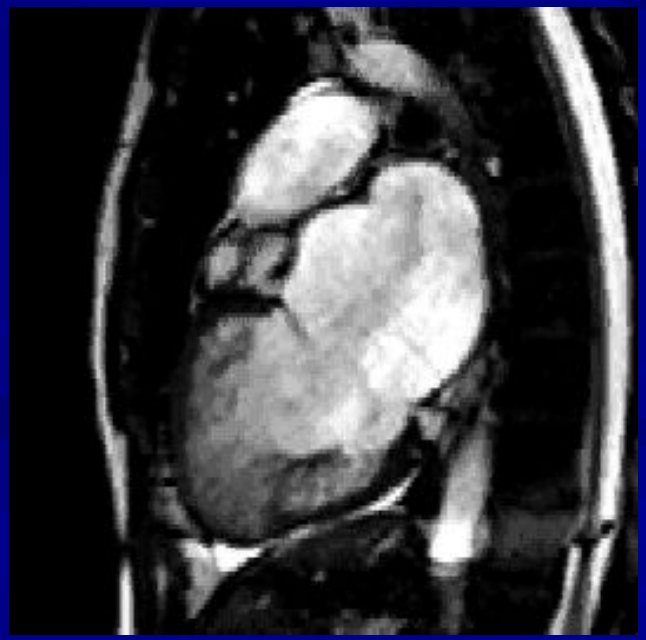

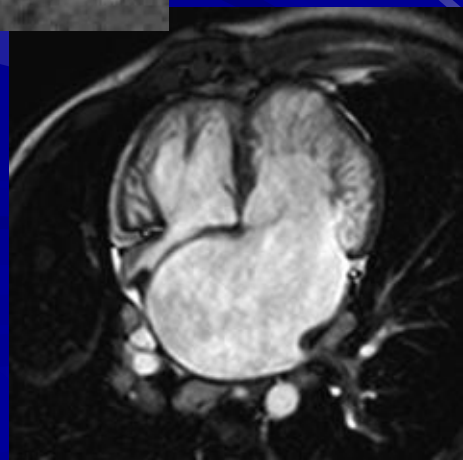

Миокардит

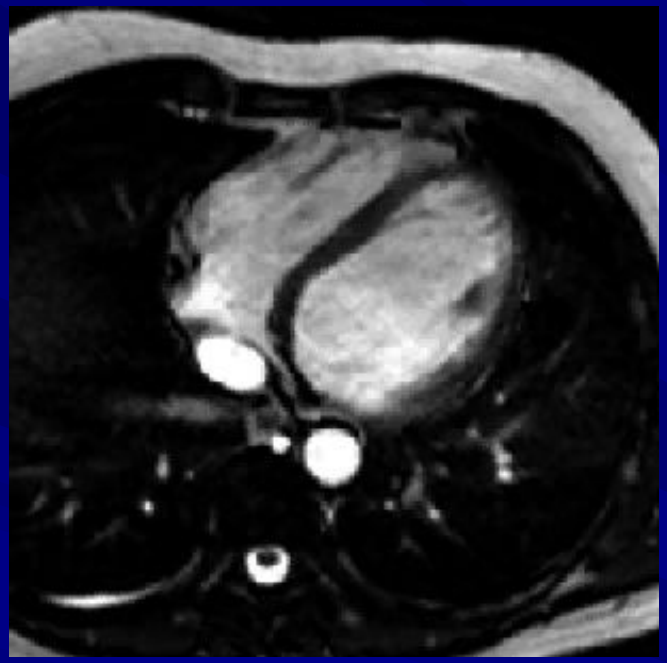

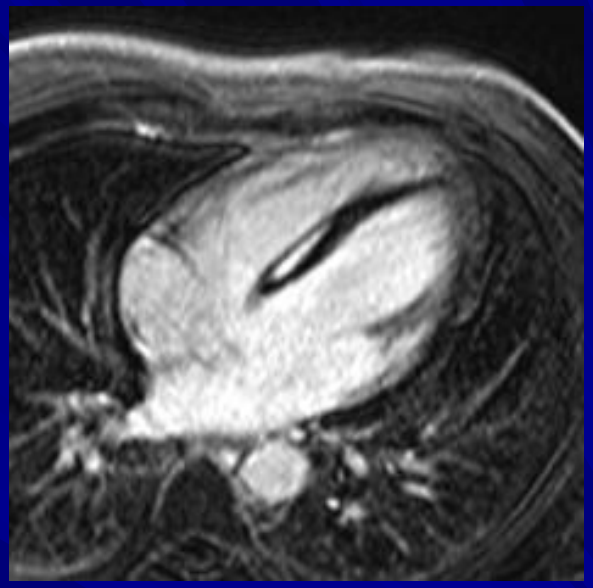

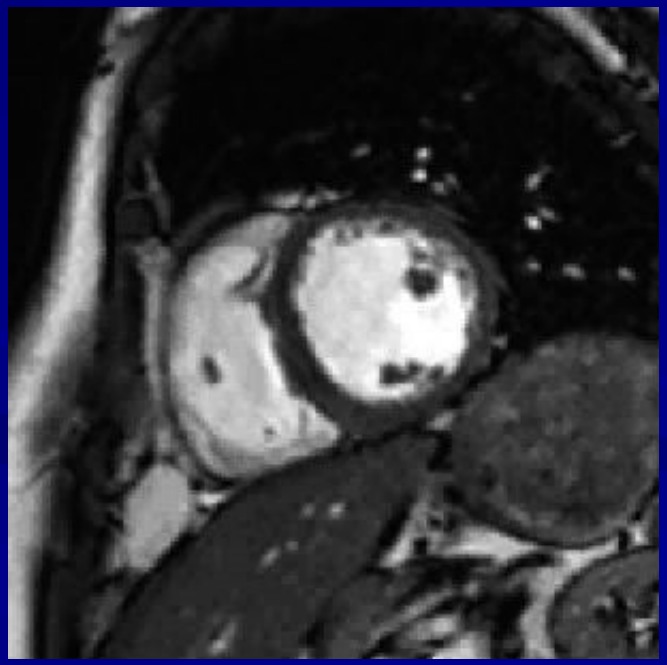

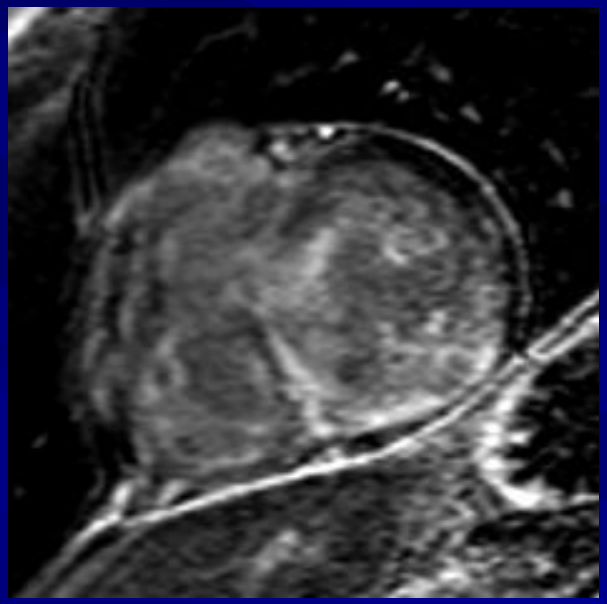

Амилоидоз

IR

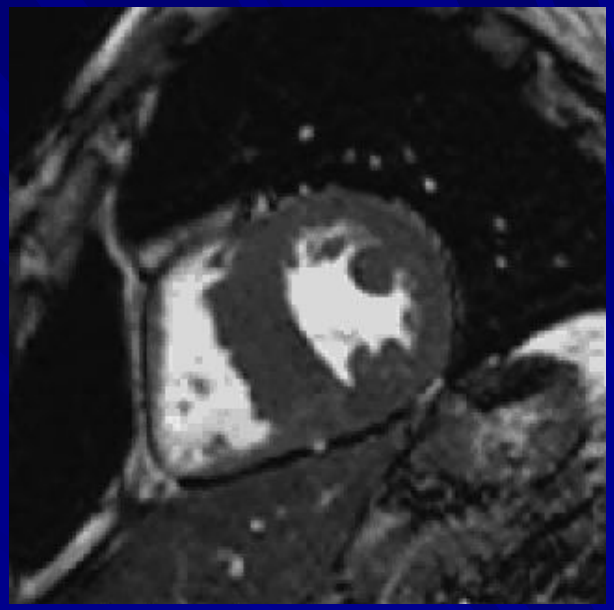

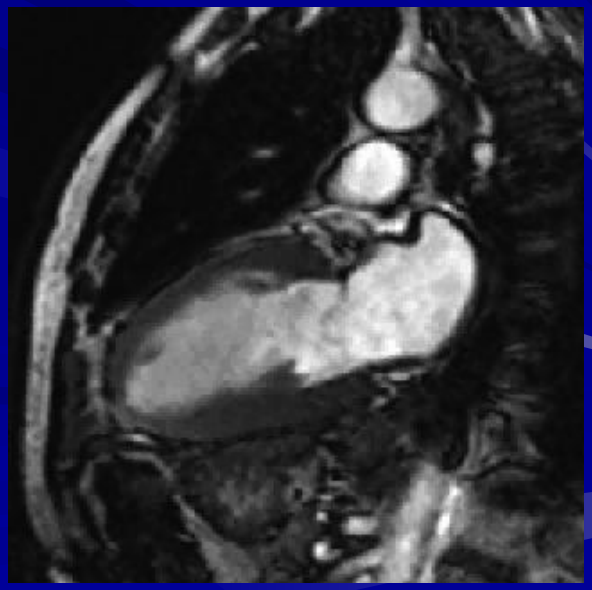

Патология клапанов сердца

Комбинированный аортальный порок

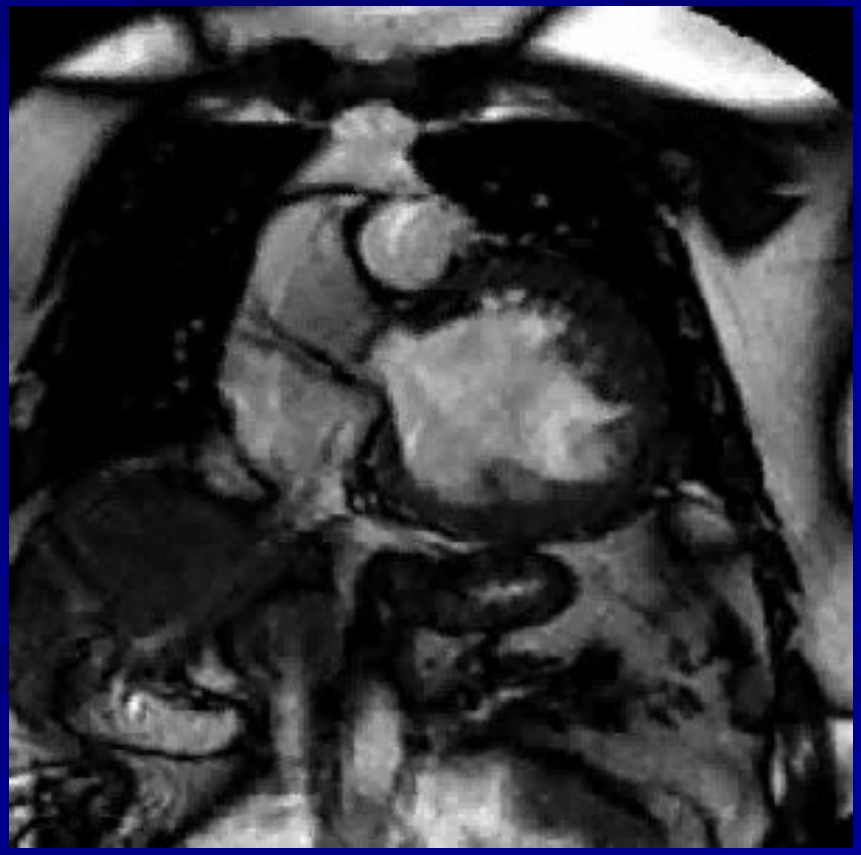

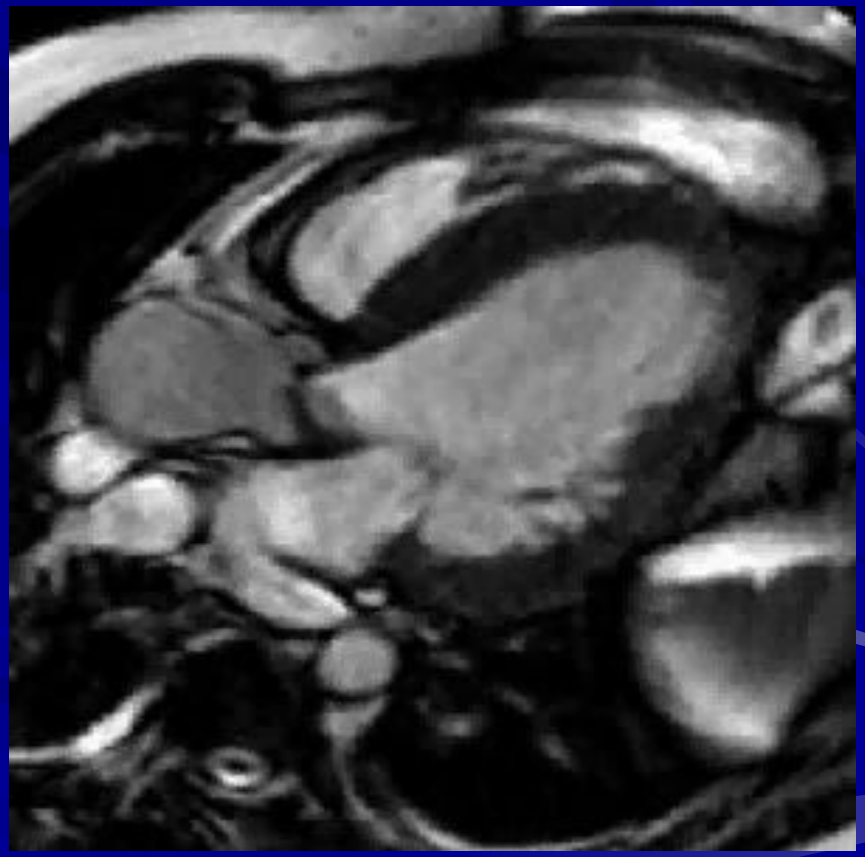
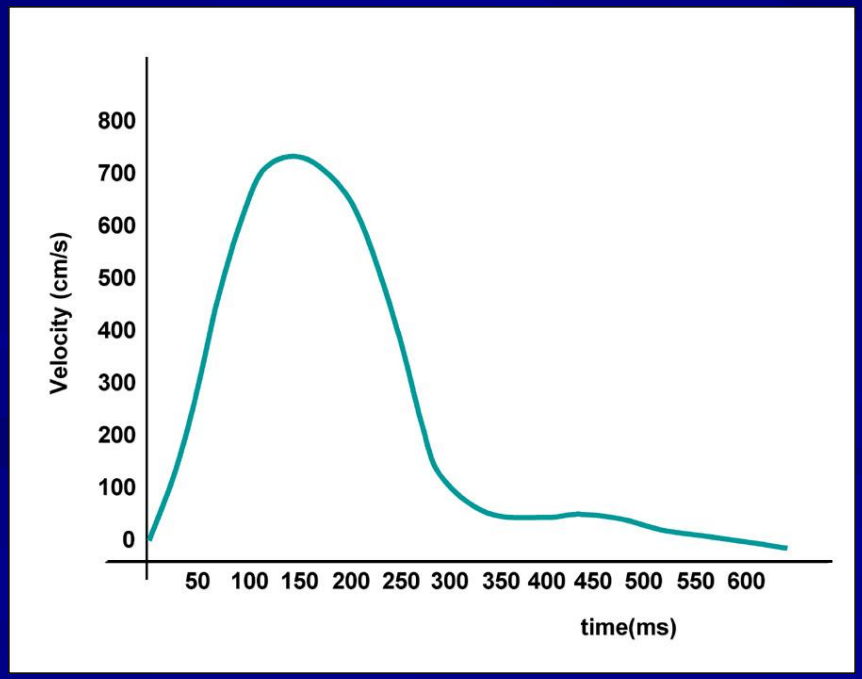
Фазово-контрастные изображения