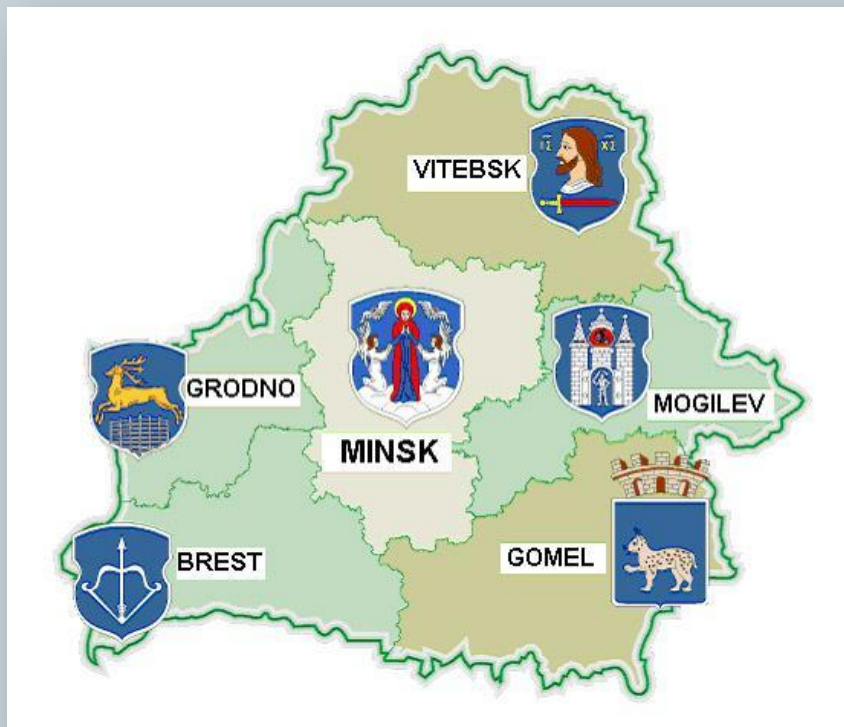

Clinical case of a patient with Hodgkin's lymphoma



PRESENT BY
MELESHKO SVETLANA

MINSK 2017

Clinical case



- Patient X
- Age: 18 years (June 1996)
- Sex: female
- Date of diagnosis: 09.2014



Clinical case



Diagnosis:

Hodgkin's lymphoma, stage III A. Variant of nodular sclerosis, with affection cervical, supraclavicular, axillary, mediastinal, retroperitoneal lymphatic nodes.

Clinical case



- Therapy

8 courses of chemotherapy according to the ABVD protocol (09.2014- 04.2015)

- Result

partial effect:

Lymphatic node biopsy - Hodgkin's lymphoma cells

Belorussian Hematology and BMT Centre



- ❖ 19 - 28.05.2015 - courses of reinduction therapy
DHAP
- ❖ 26.-29.06.2015 – DHAP
- ❖ 28.07-13.08.2015 – DHAP and 2 sessions of stem
cells apheresis

□ Result

- partial remission

Belorussian Hematology and BMT Centre



● 13.11-01.12.2015

high-dose chemotherapy (BEAM) + autologous HSCT

- CD34+ $4.12 \times 10^6/\text{kg}$
- nucleated cells $-6.63 \times 10^8/\text{kg}$
- Hematopoietic recovery: day +9

Well done!

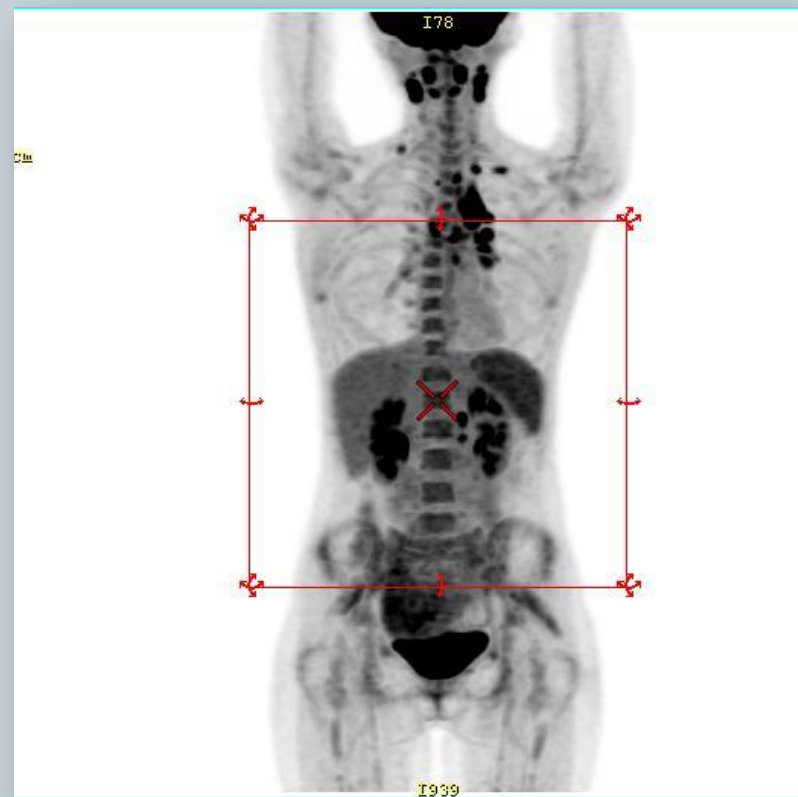
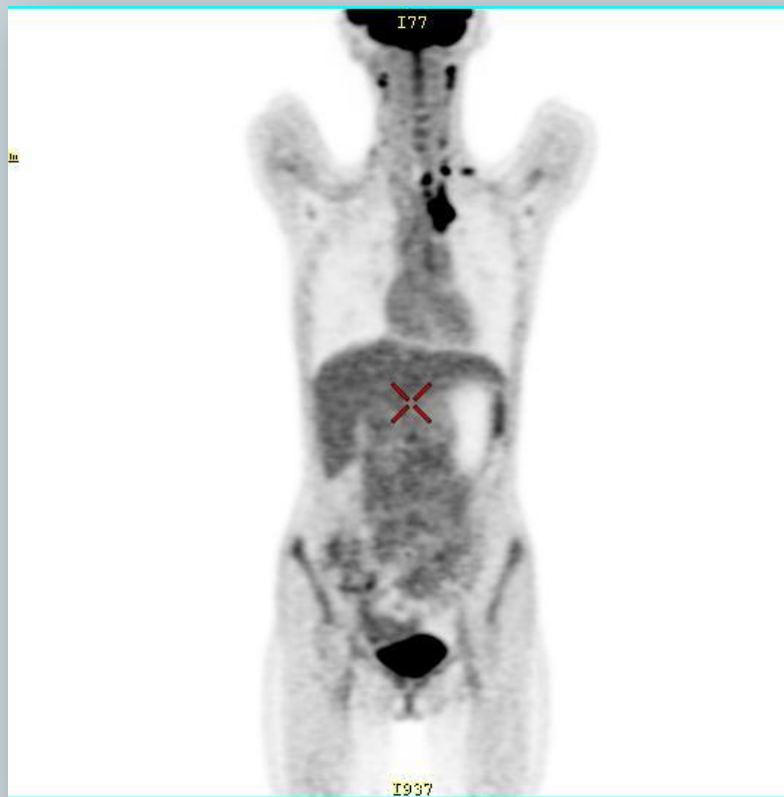

But...

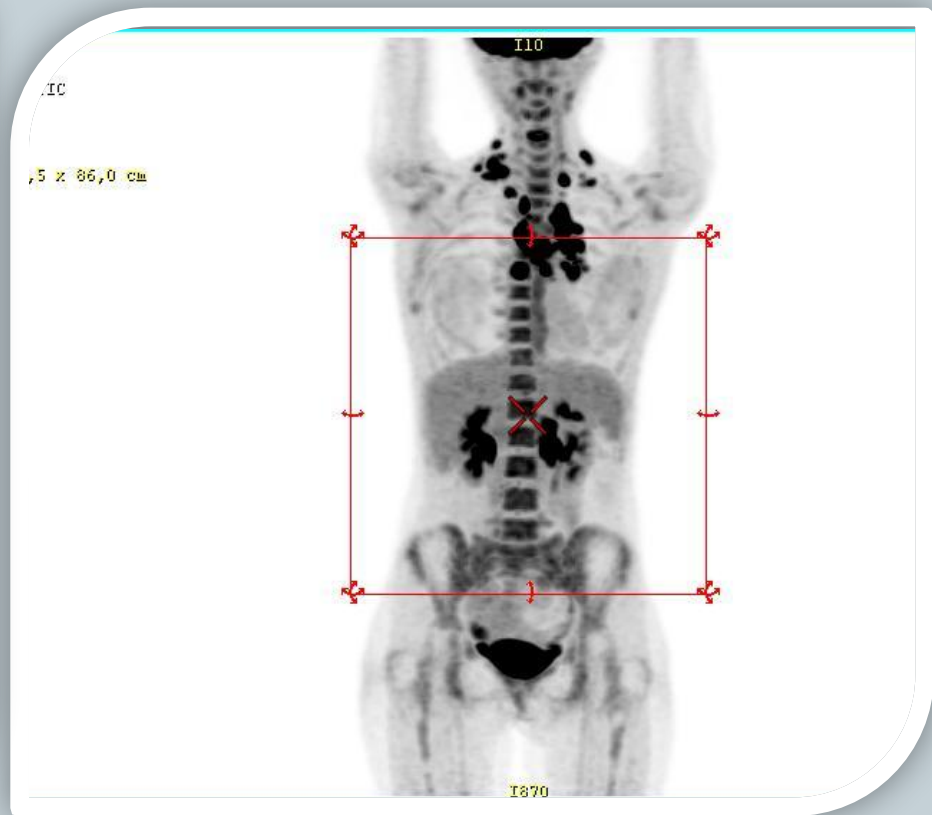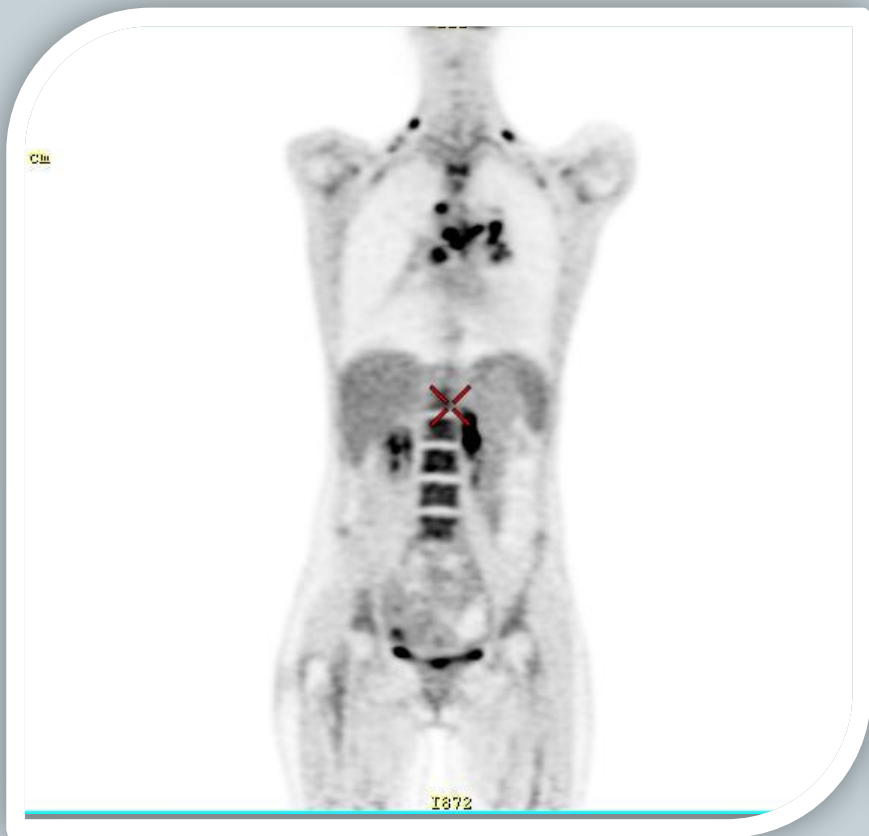


- November 2016 - Relapse (lesion of cervical, supraclavicular, mediastinal, retrocrural, paraaortal, retroperitoneal lymphatic nodes and soft tissues of the right lung, thyroid) confirmed by PET CT.

PET -CT 24.02.2017



PET -CT 16.05.2017



Further tactics is...



Further tactic?



- Way #1 – monotherapy with Brentuximab
- Way#2 – modified courses PCT with **Brentuximab**
(*DHAP+Brentuximab,*
Bendamustine+Brentuximab..?)
- Way #3 – HD PCT and the second transplantation
- Way #4 - your advises



**THANK
YOU
FOR
YOUR
ATTENTION**