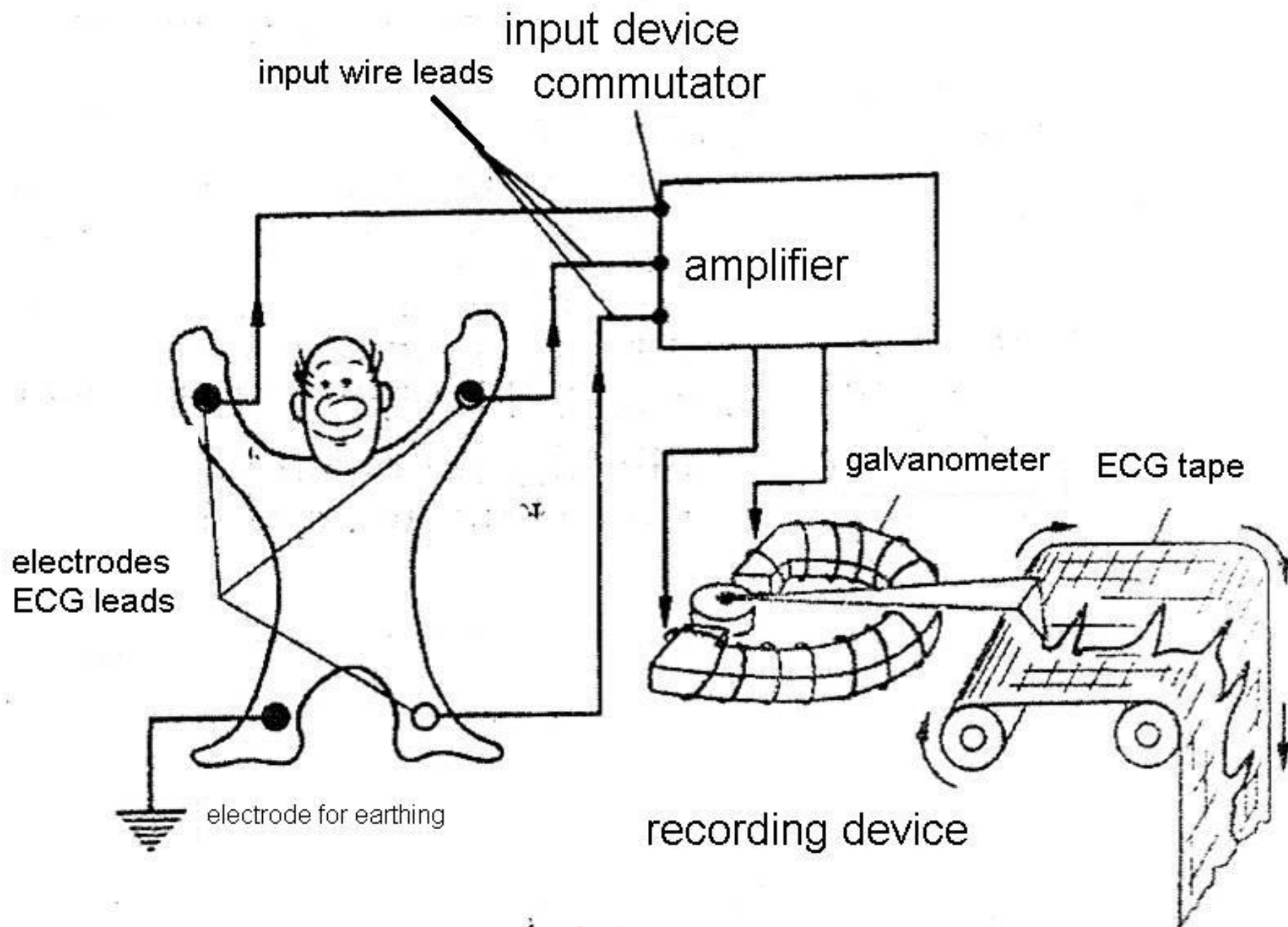
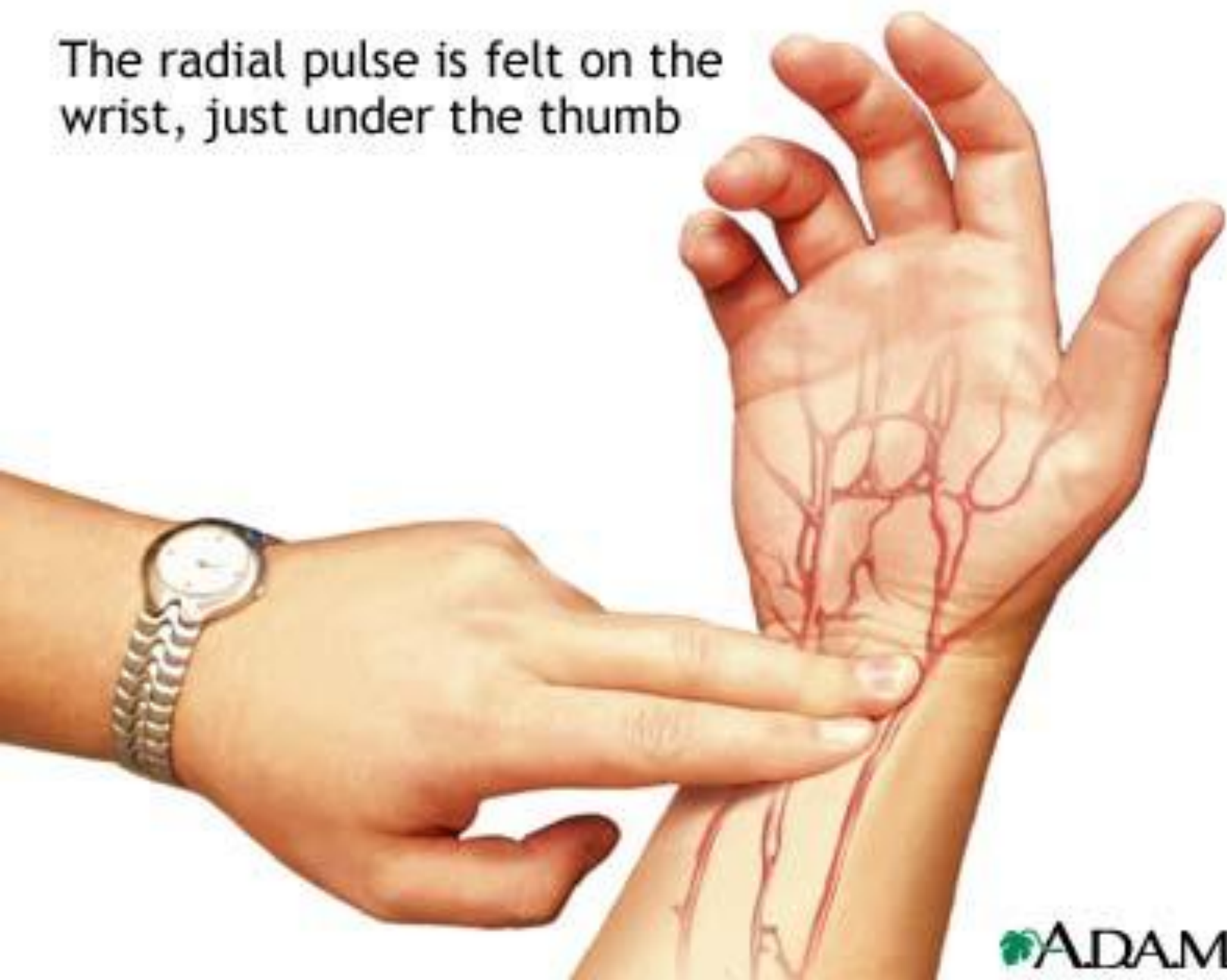

Functional diagnostics



The radial pulse is felt on the wrist, just under the thumb



RESPIRATORY ACIDOSIS

- Hypoventilation → Hypoxia

- Rapid, Shallow Respirations

- ↓ BP

- Skin/Mucosa Pale to Cyanotic

- Headache

- Hyperkalemia

- Dysrhythmias (↑K⁺)

I can't catch my breath.

- Drowsiness, Dizziness, Disorientation

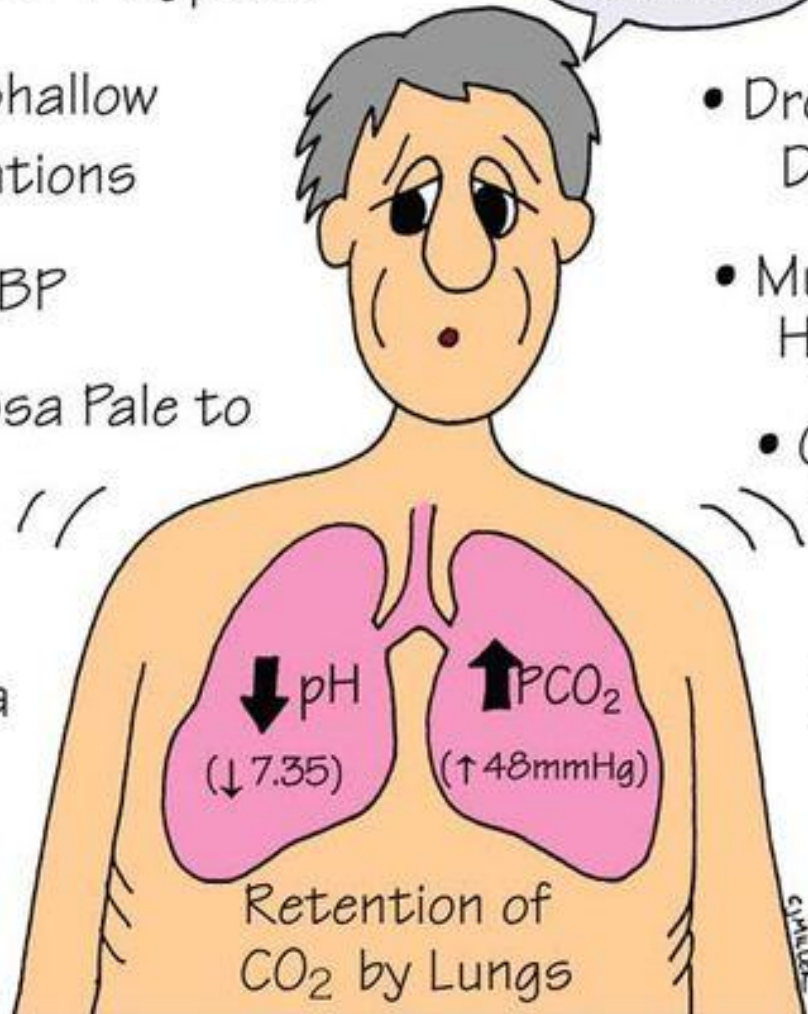
- Muscle Weakness, Hyperreflexia

- Causes:

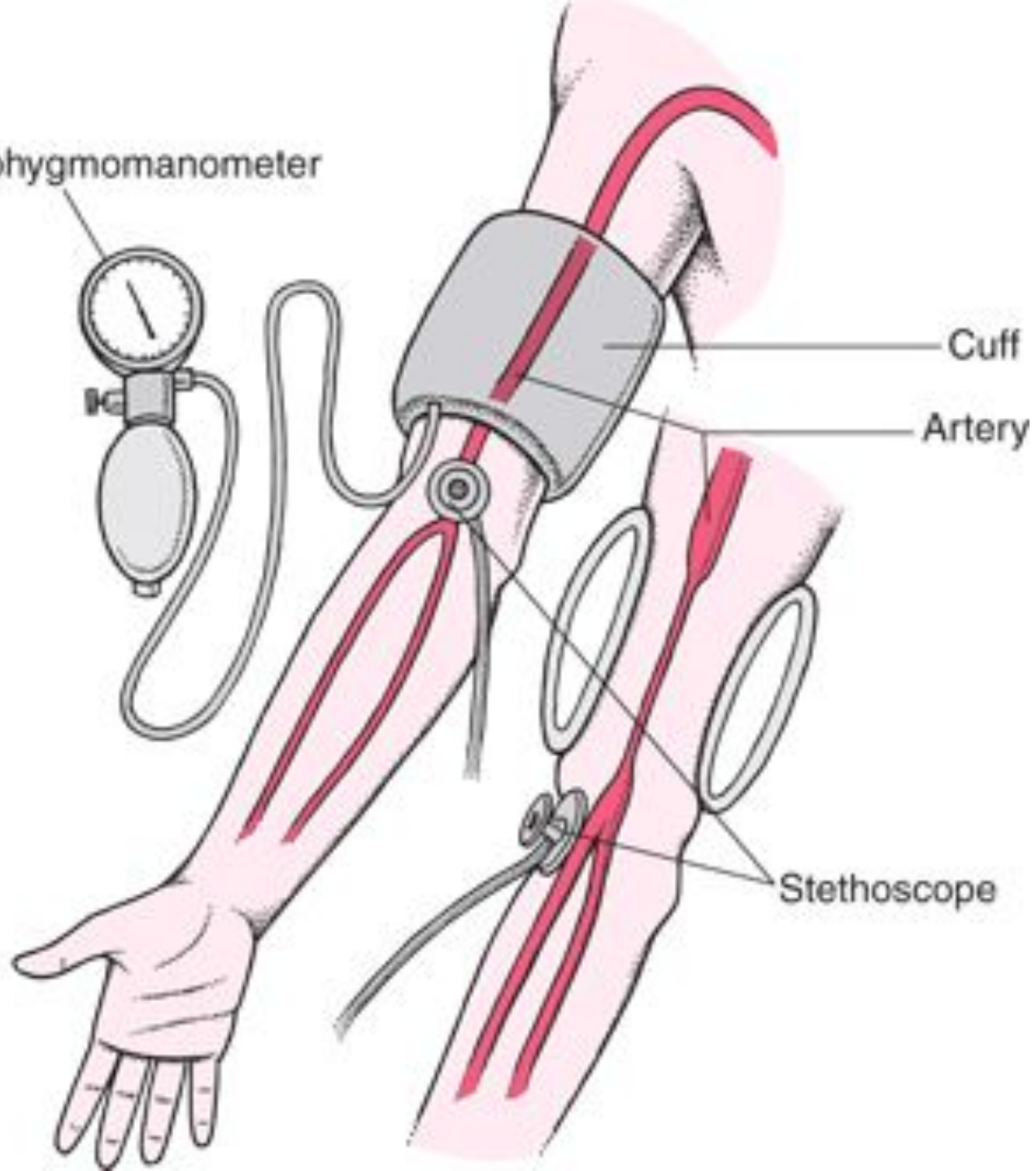
Respiratory Depression
(Anesthesia, Overdose, ↑ICP)

Airway Obstruction

↓ Alveolar Capillary Diffusion (Pneumonia, COPD, ARDS, PE)



Sphygmomanometer



Cuff

Artery

Stethoscope





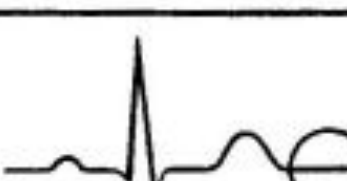
Electrical Activity	Graphic Depiction	Associated Pattern
Atrial Depolarization		P Wave
Delay at AV Node		PR Segment
Ventricular Depolarization		QRS Complex
Ventricular Repolarization		T Wave
No electrical activity		Isoelectric Line

Figure 2-5. Electrocardiogram wave patterns produced by electrical activity in the heart.