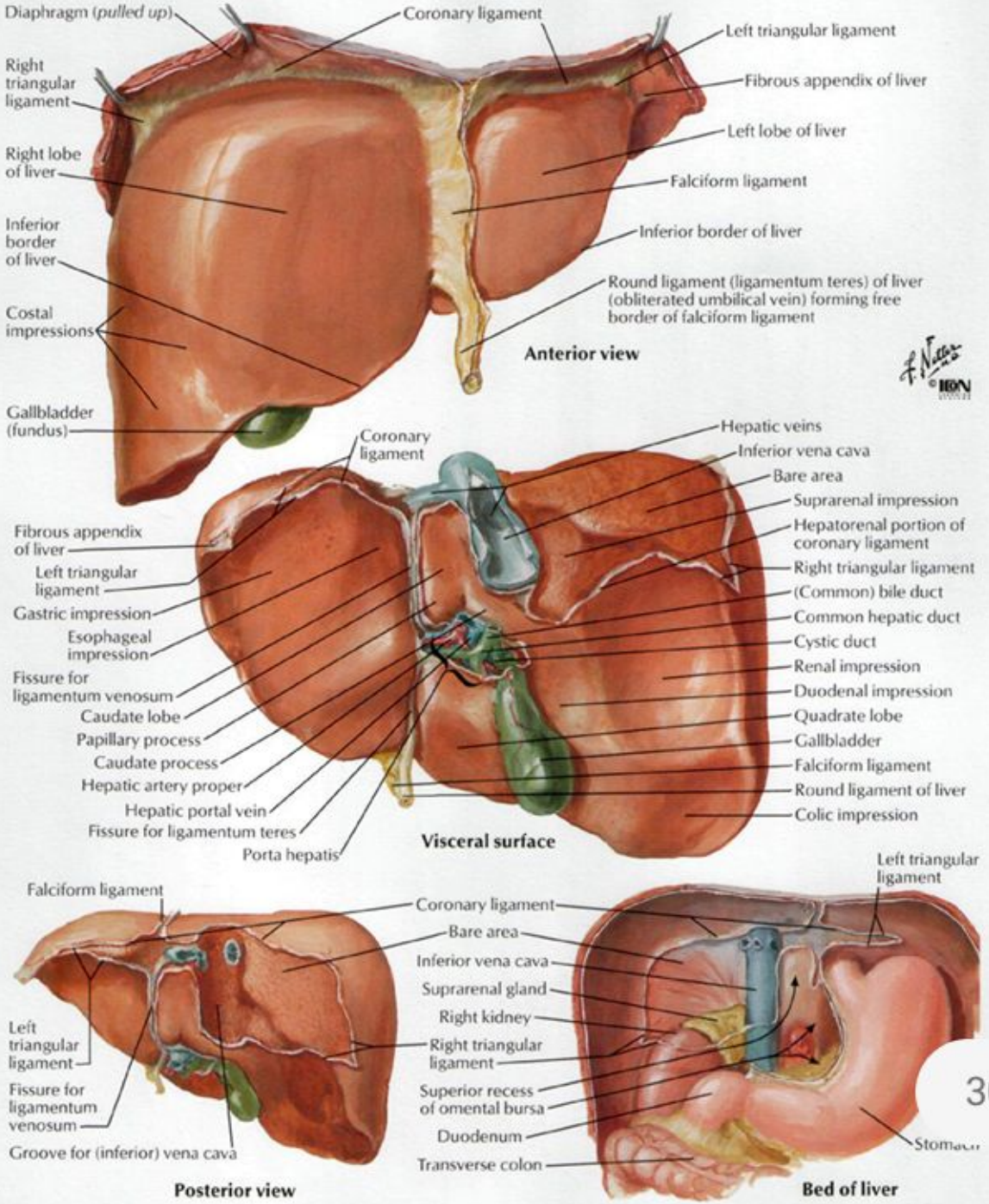
Diaphragm (pulled up)
Coronary ligament
Left triangular ligament
Right triangular ligament
Fibrous appendix of liver
Left lobe of liver
Right lobe of liver
Falciform ligament
Inferior border of liver
Inferior border of liver
Round ligament (ligamentum teres) of liver (obliterated umbilical vein) forming free border of falciform ligament
Costal impressions
Anterior view
Gallbladder (fundus)
Coronary ligament
Hepatic veins
Inferior vena cava
Bare area
Suprarenal impression
Hepatorenal portion of coronary ligament
Fibrous appendix of liver
Left triangular ligament
Right triangular ligament
(Common) bile duct
Gastric impression
Common hepatic duct
Esophageal impression
Cystic duct
Fissure for ligamentum venosum
Renal impression
Duodenal impression
Caudate lobe
Quadrate lobe
Papillary process
Gallbladder
Caudate process
Falciform ligament
Hepatic artery proper
Round ligament of liver
Hepatic portal vein
Colic impression
Fissure for ligamentum teres
Porta hepatis
Visceral surface
Falciform ligament
Coronary ligament
Left triangular ligament
Bare area
Inferior vena cava
Suprarenal gland
Right kidney
Left triangular ligament
Right triangular ligament
Fissure for ligamentum venosum
Superior recess of omental bursa
Duodenum
Groove for (inferior) vena cava
Transverse colon
Posterior view
Bed of liver

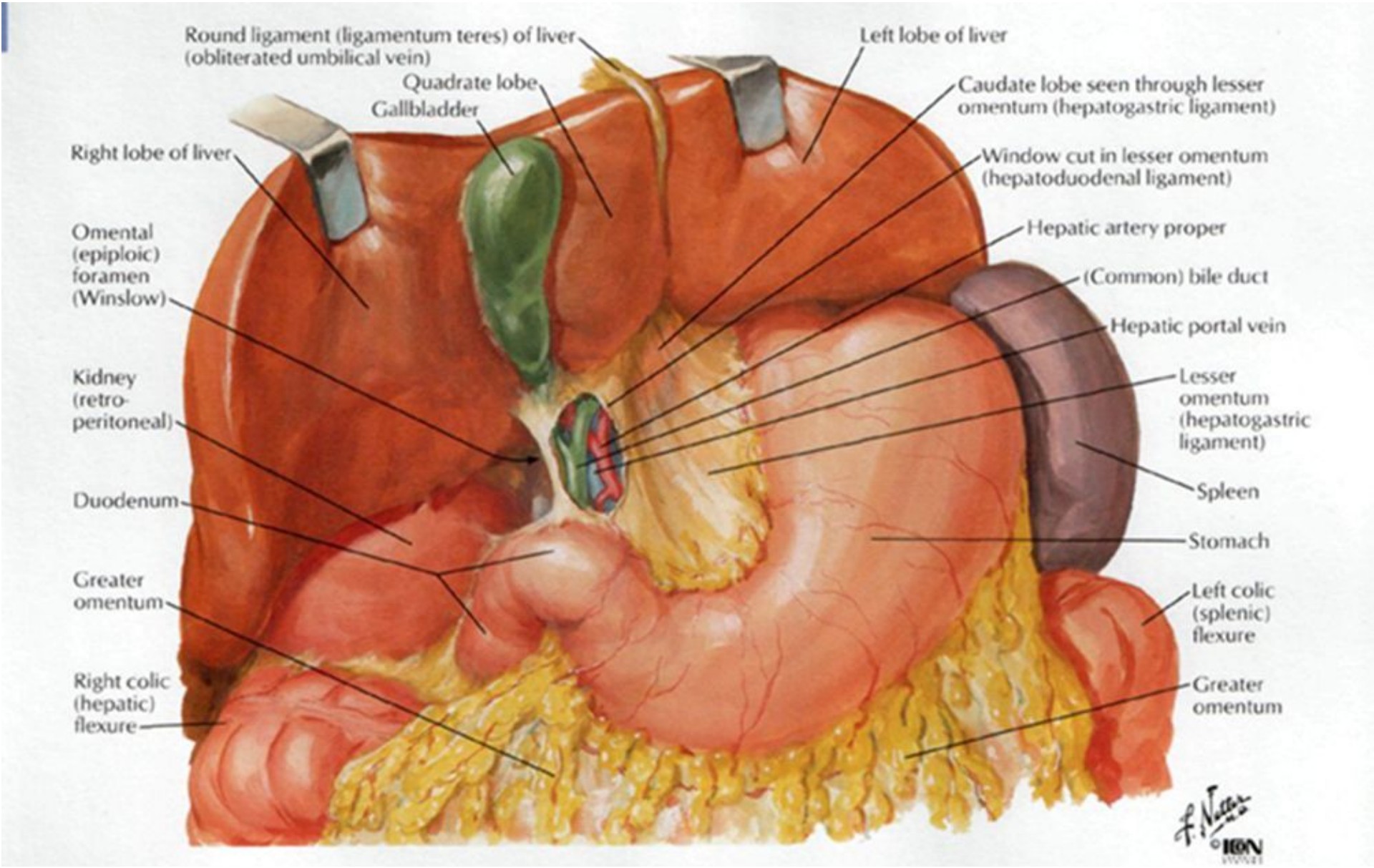
Round ligament (ligamentum teres) of liver (obliterated umbilical vein)
Quadrate lobe
Gallbladder
Left lobe of liver
Caudate lobe seen through lesser omentum (hepatogastric ligament)
Right lobe of liver
Window cut in lesser omentum (hepatoduodenal ligament)
Omental (epiploic) foramen (Winslow)
Hepatic artery proper
(Common) bile duct
Hepatic portal vein
Kidney (retro-peritoneal)
Lesser omentum (hepatogastric ligament)
Spleen
Duodenum
Stomach
Greater omentum
Left colic (splenic) flexure
Right colic (hepatic) flexure
Greater omentum
©ION

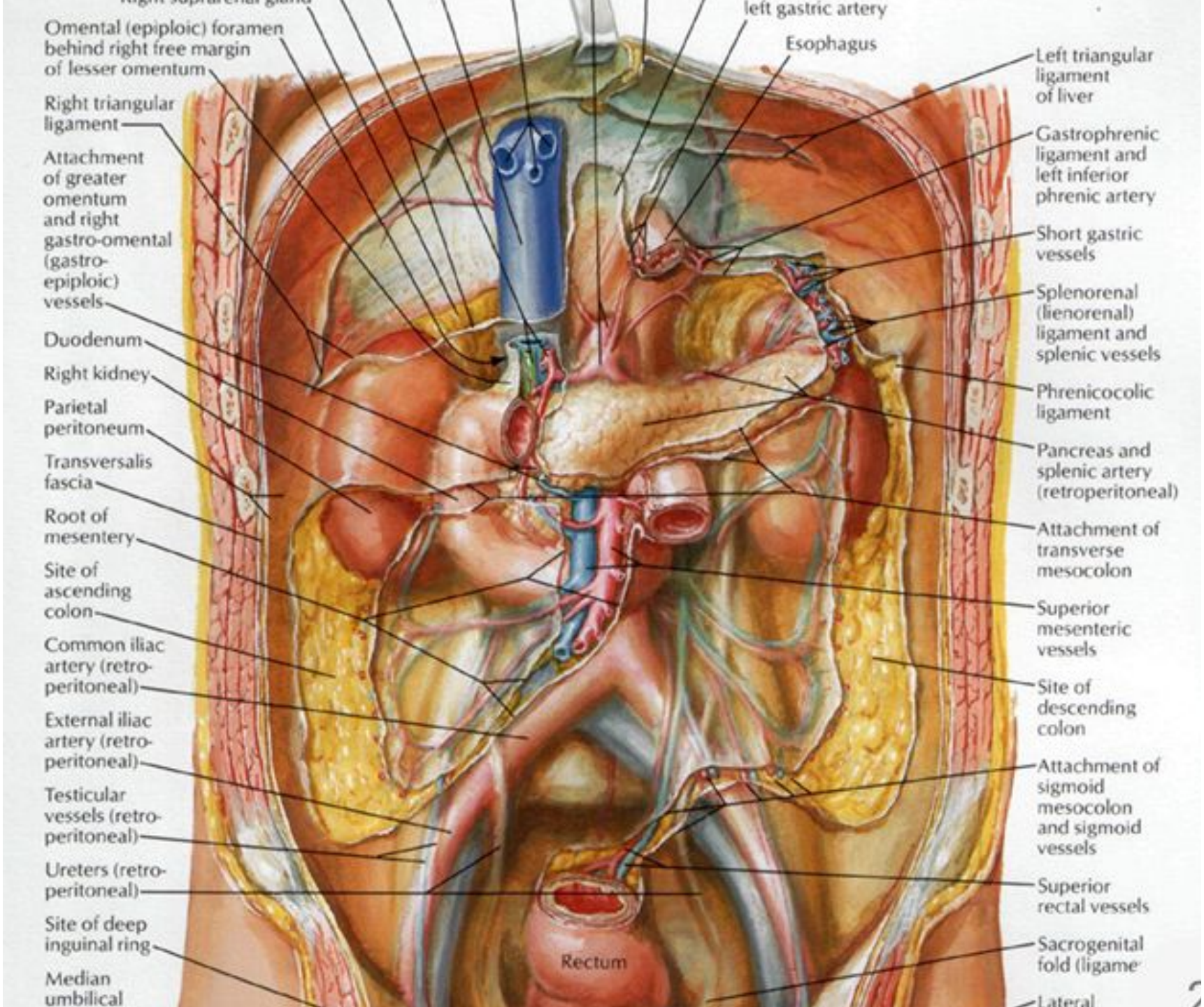
Omental (epiploic) foramen behind right free margin of lesser omentum
Right triangular ligament
Attachment of greater omentum and right gastro-omental (gastro-epiploic) vessels
Duodenum
Right kidney
Parietal peritoneum
Transversalis fascia
Root of mesentery
Site of ascending colon
Common iliac artery (retro-peritoneal)
External iliac artery (retro-peritoneal)
Testicular vessels (retro-peritoneal)
Ureters (retro-peritoneal)
Site of deep inguinal ring
Median umbilical
left gastric artery
Esophagus
Left triangular ligament of liver
Gastrophrenic ligament and left inferior phrenic artery
Short gastric vessels
Splenorenal (lienorenal) ligament and splenic vessels
Phrenicocolic ligament
Pancreas and splenic artery (retroperitoneal)
Attachment of transverse mesocolon
Superior mesenteric vessels
Site of descending colon
Attachment of sigmoid mesocolon and sigmoid vessels
Superior rectal vessels
Sacrogenital fold (ligame
Lateral
Rectum

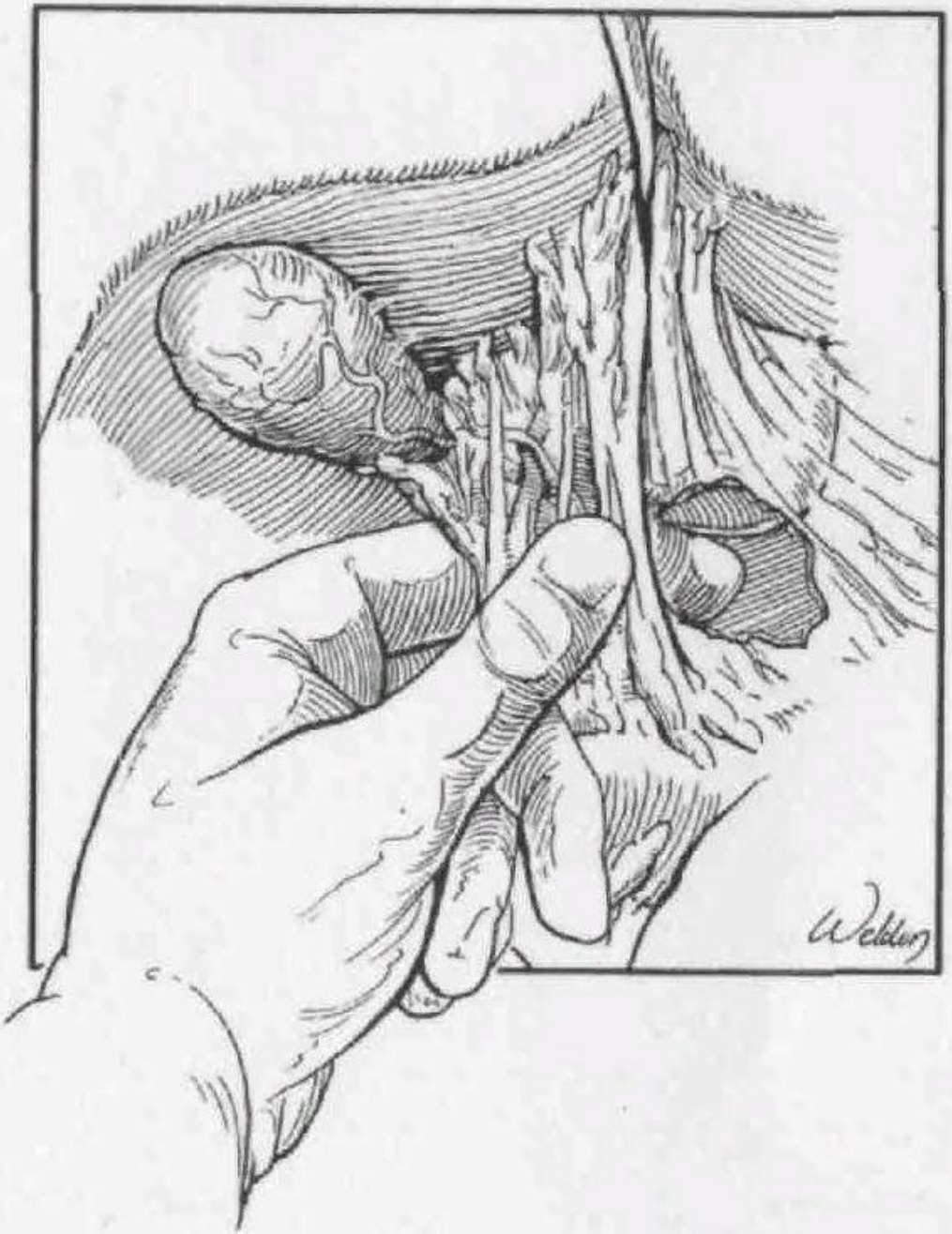
Welling

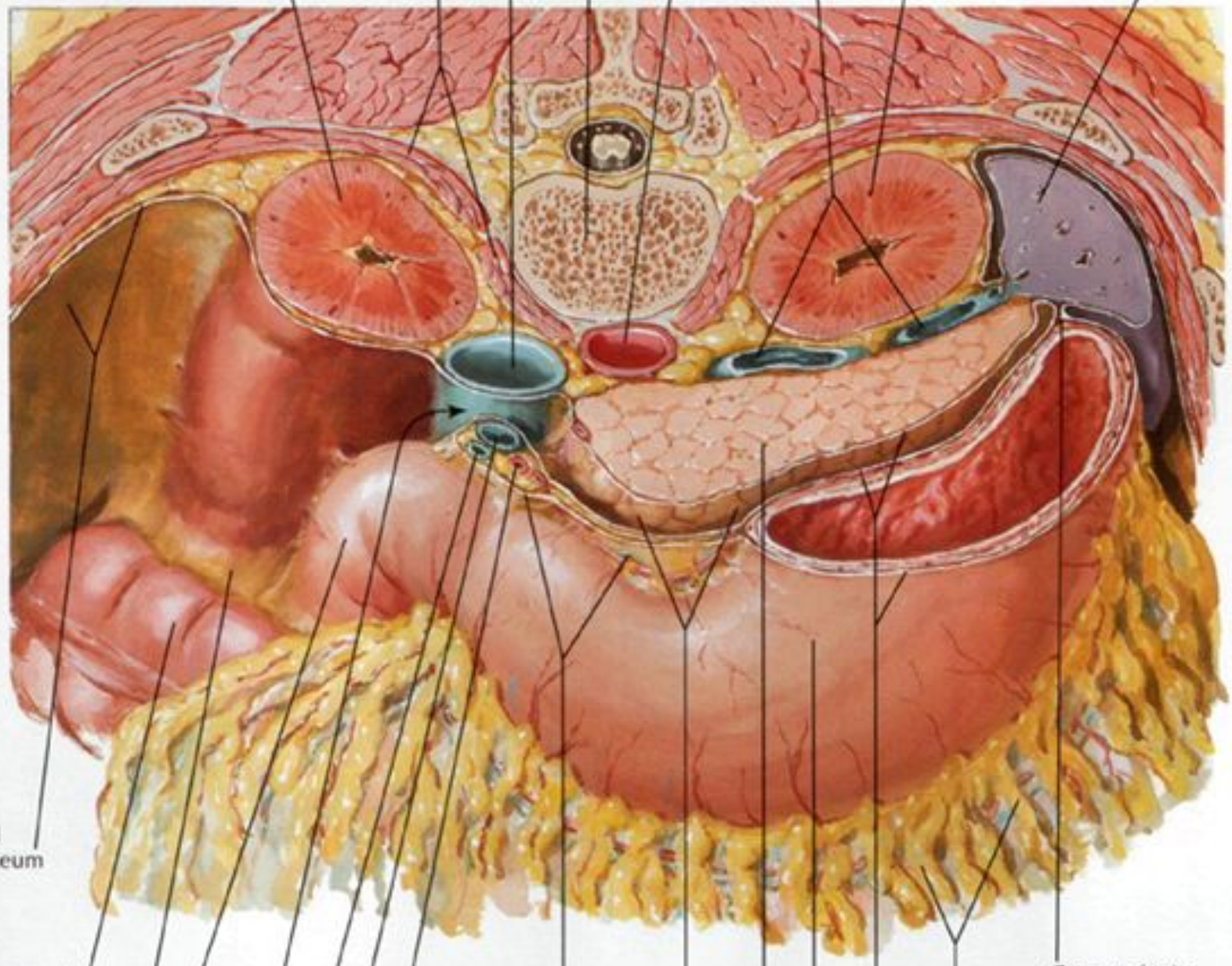
Parietal peritoneum
Transverse colon
Transverse mesocolon
Duodenum
Gastrosplenic (gastrolienal) ligament
Greater omentum

100%
12dB
15.0
Text

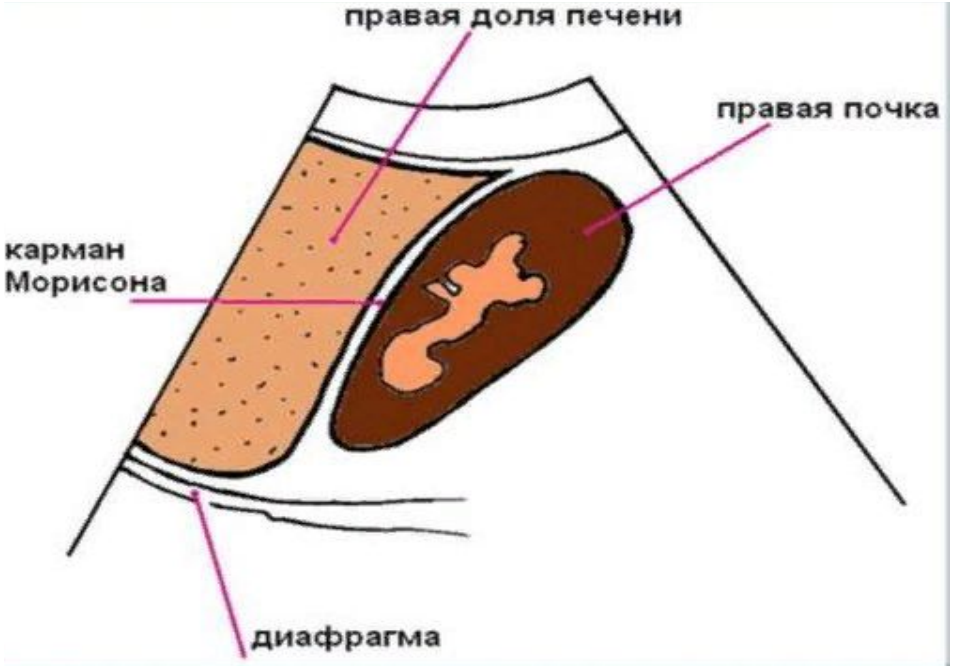
правая доля печени
правая почка
карман
Морисона
диафрагма

Асцит
Гепаторенальное
углубление
Печень
Правая
почка
Нижняя
полая
вена

Round ligament (ligamentum teres) of liver (obliterated umbilical vein)
Quadrate lobe
Gallbladder
Left lobe of liver
Caudate lobe seen through lesser omentum (hepatogastric ligament)
Right lobe of liver
Window cut in lesser omentum (hepatoduodenal ligament)
Omental (epiploic) foramen (Winslow)
Hepatic artery proper
(Common) bile duct
Hepatic portal vein
Kidney (retro-peritoneal)
Lesser omentum (hepatogastric ligament)
Spleen
Duodenum
Stomach
Greater omentum
Left colic (splenic) flexure
Right colic (hepatic) flexure
Greater omentum

Variations in form of liver

Very small left lobe, deep costal impressions

Complete atrophy of left lobe (left portal vein compression)

Transverse, "saddlelike" liver, relatively large left lobe

"Tonguelike" process of right lobe

Very deep renal impression and "corset constriction"

Diaphragmatic grooves

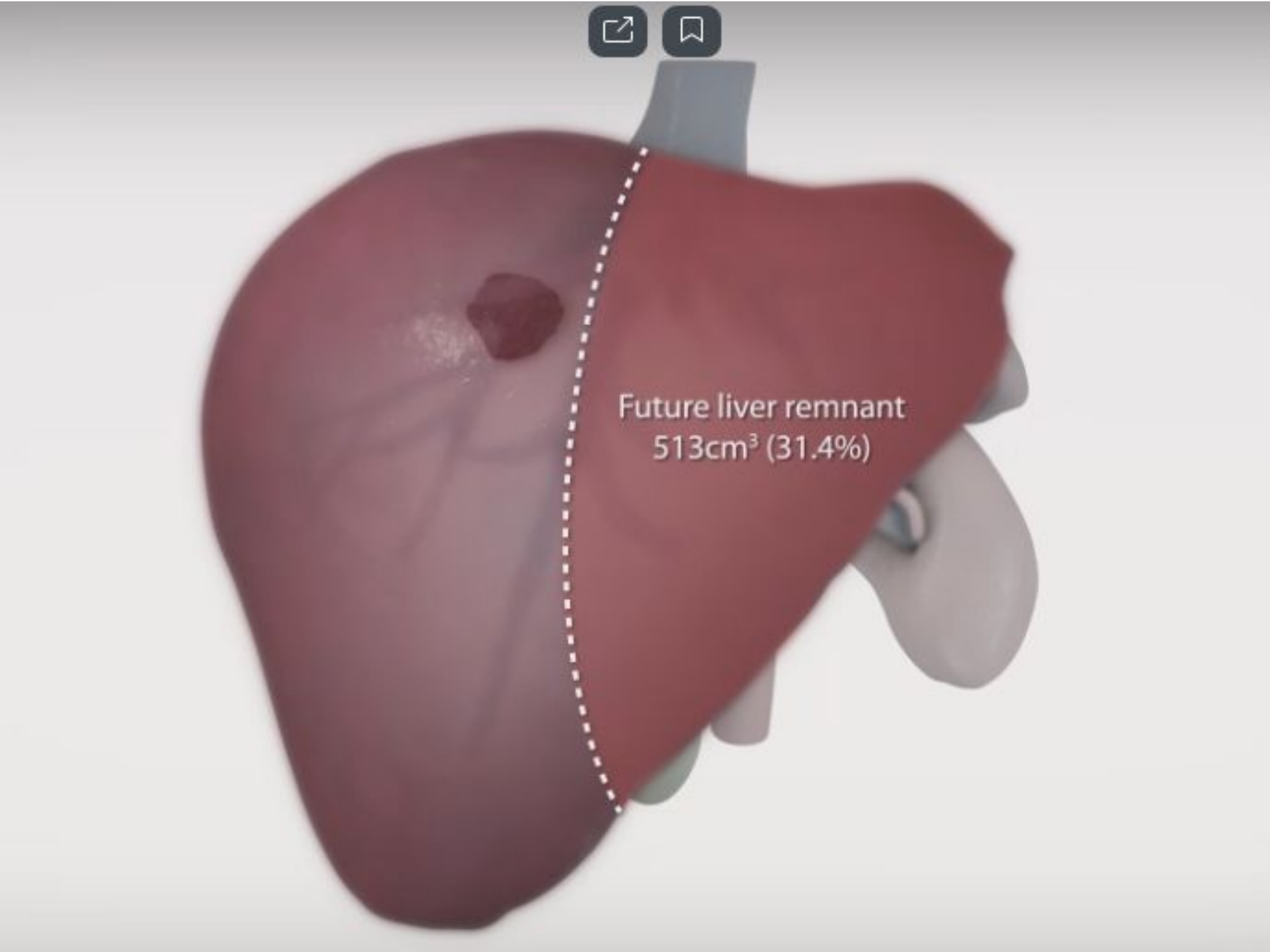
Future liver remnant
513cm³ (31.4%)

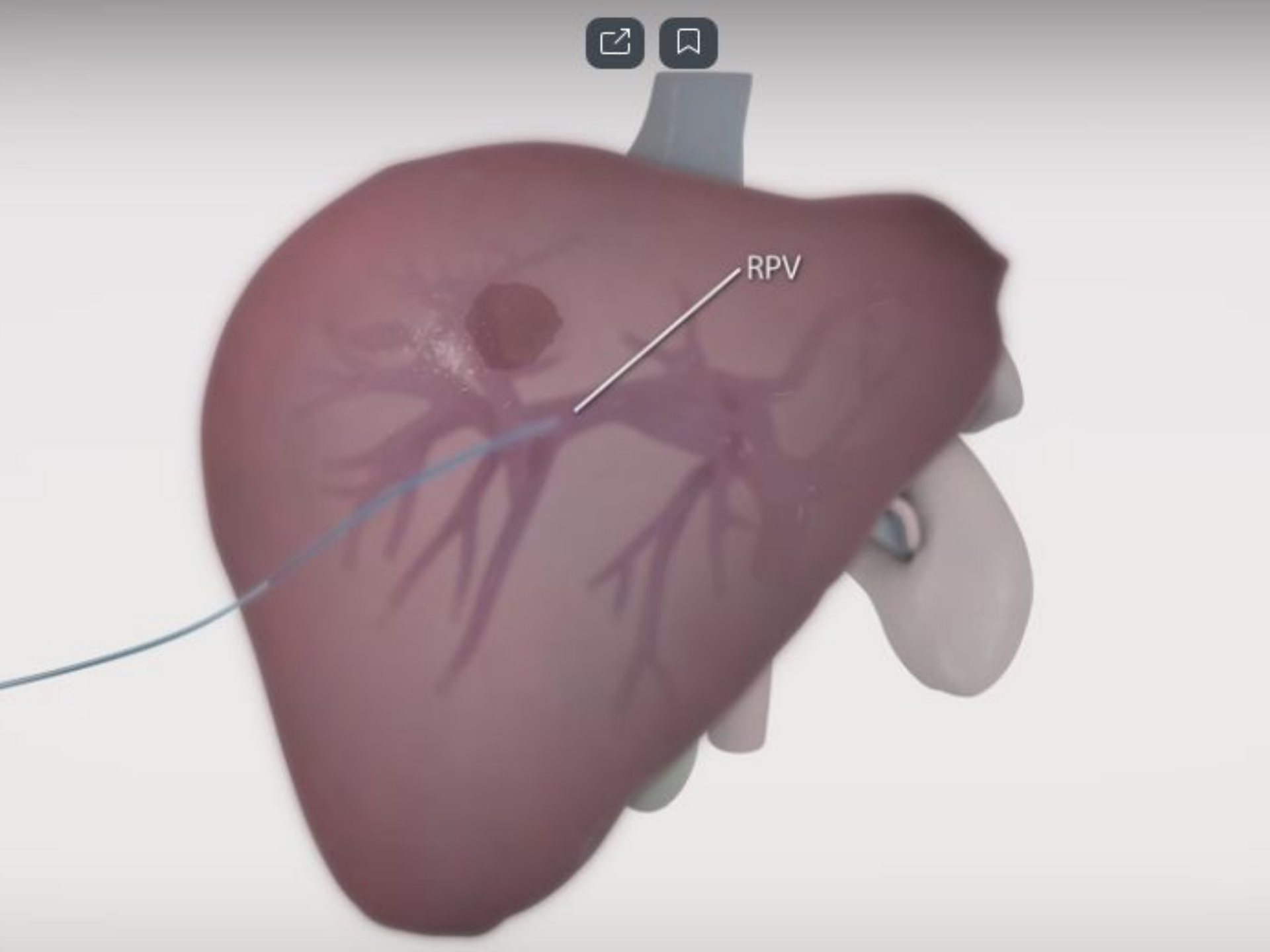
RPV

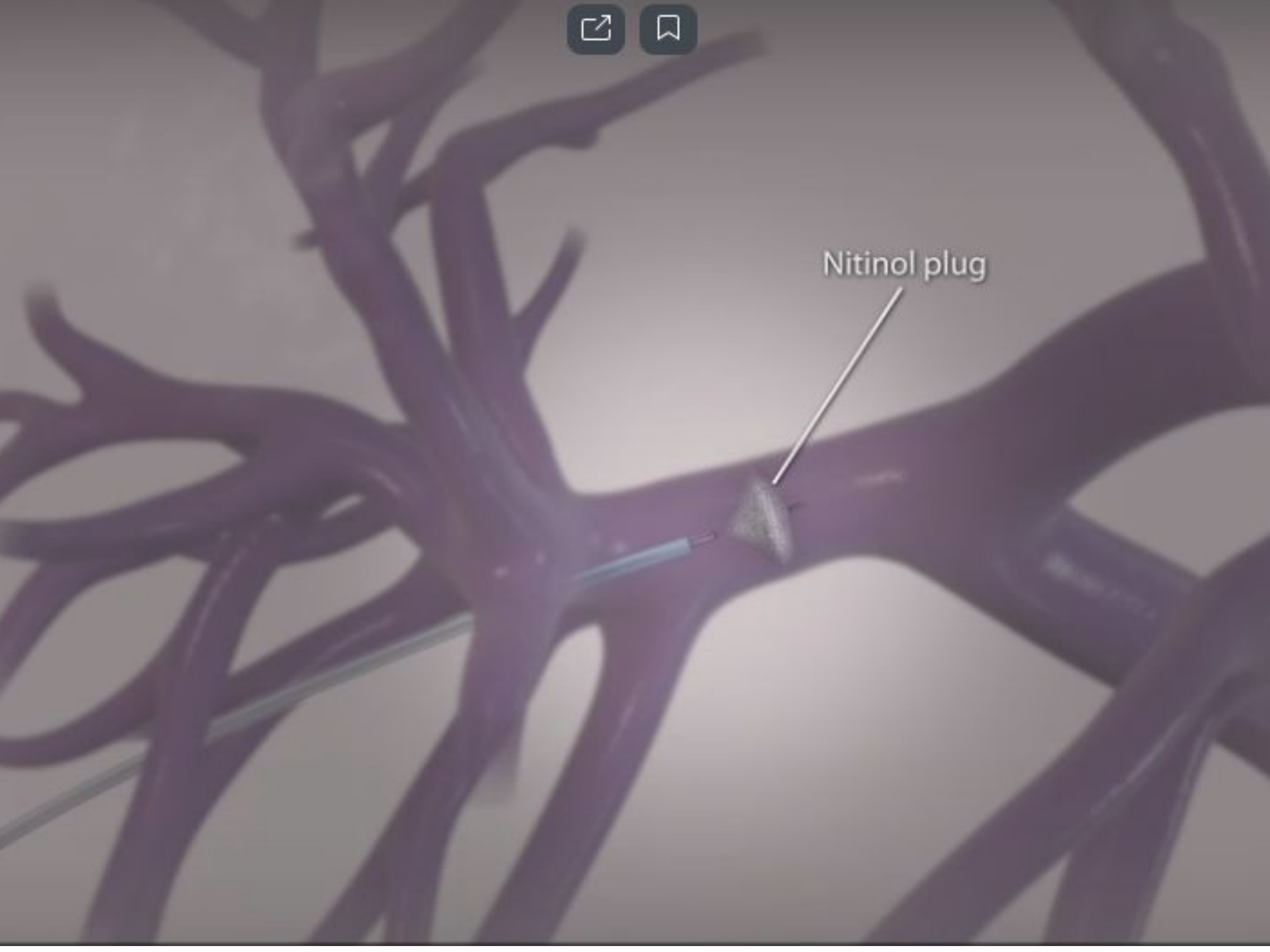
Nitinol plug

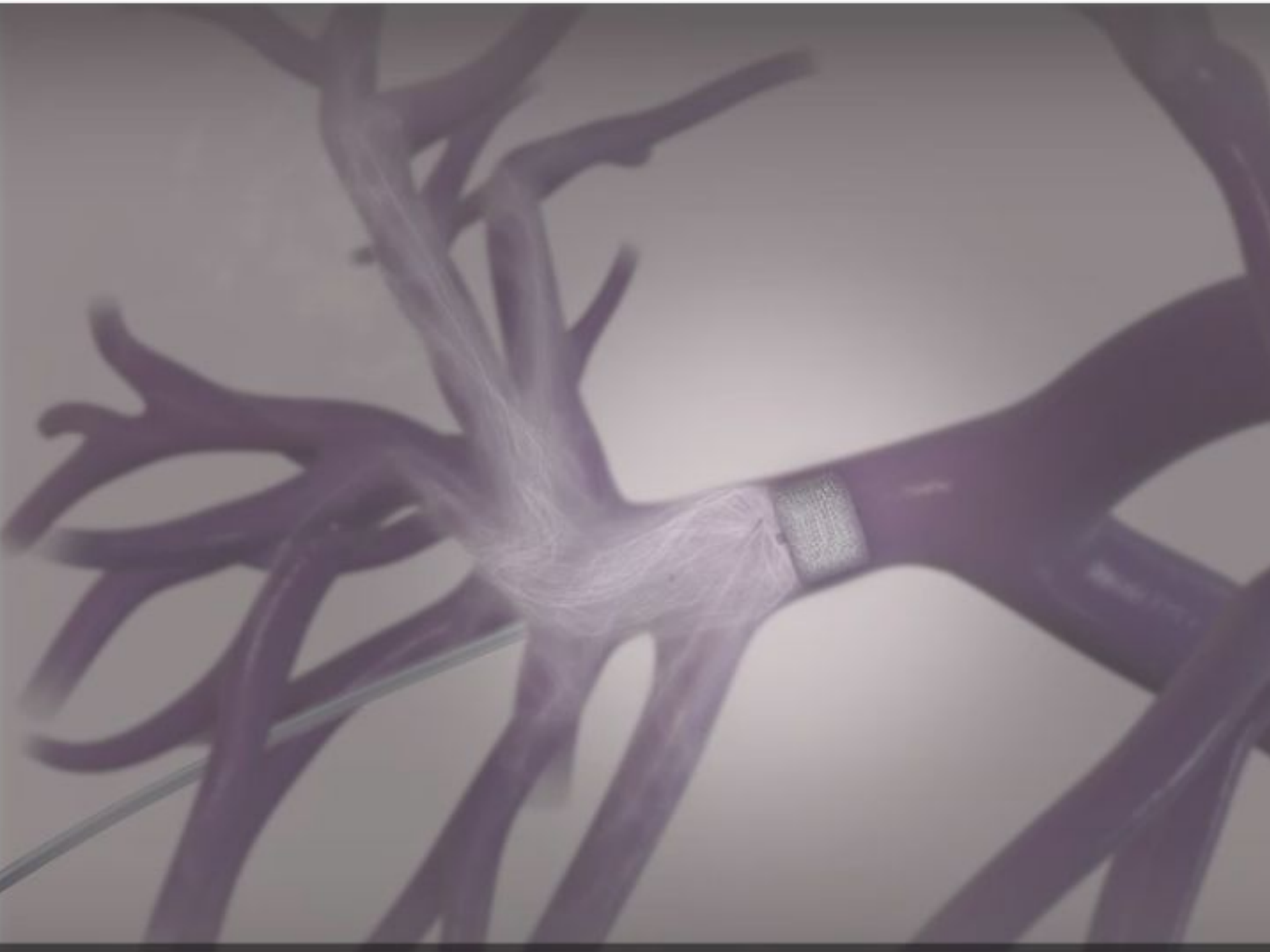

до ЭПВВ

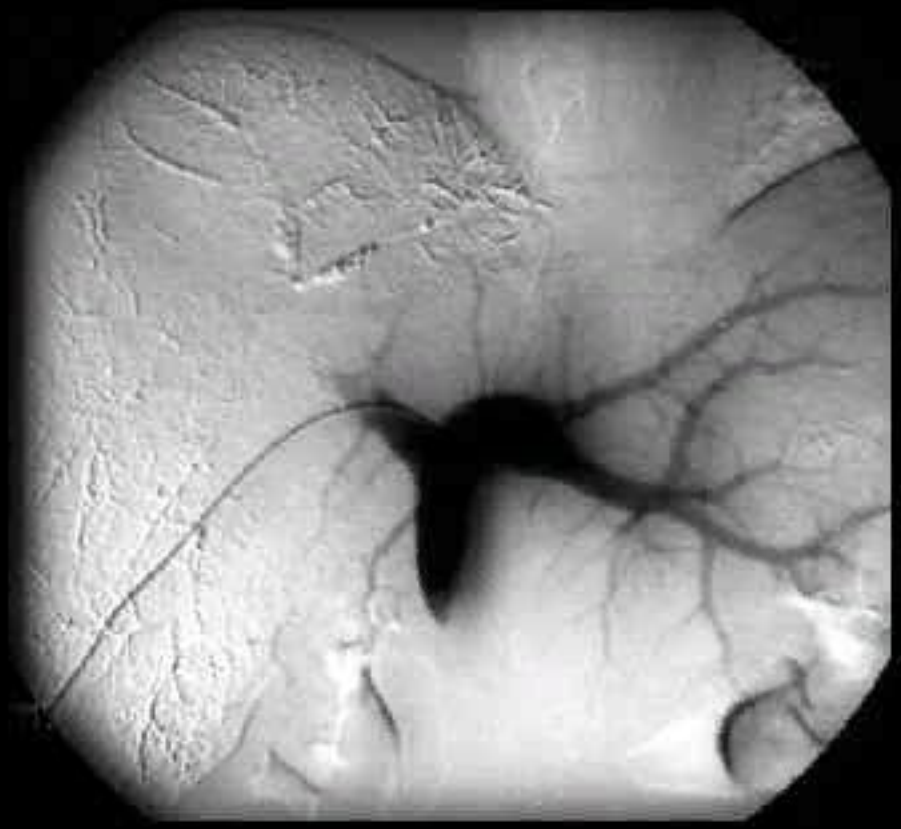

после ЭПВВ

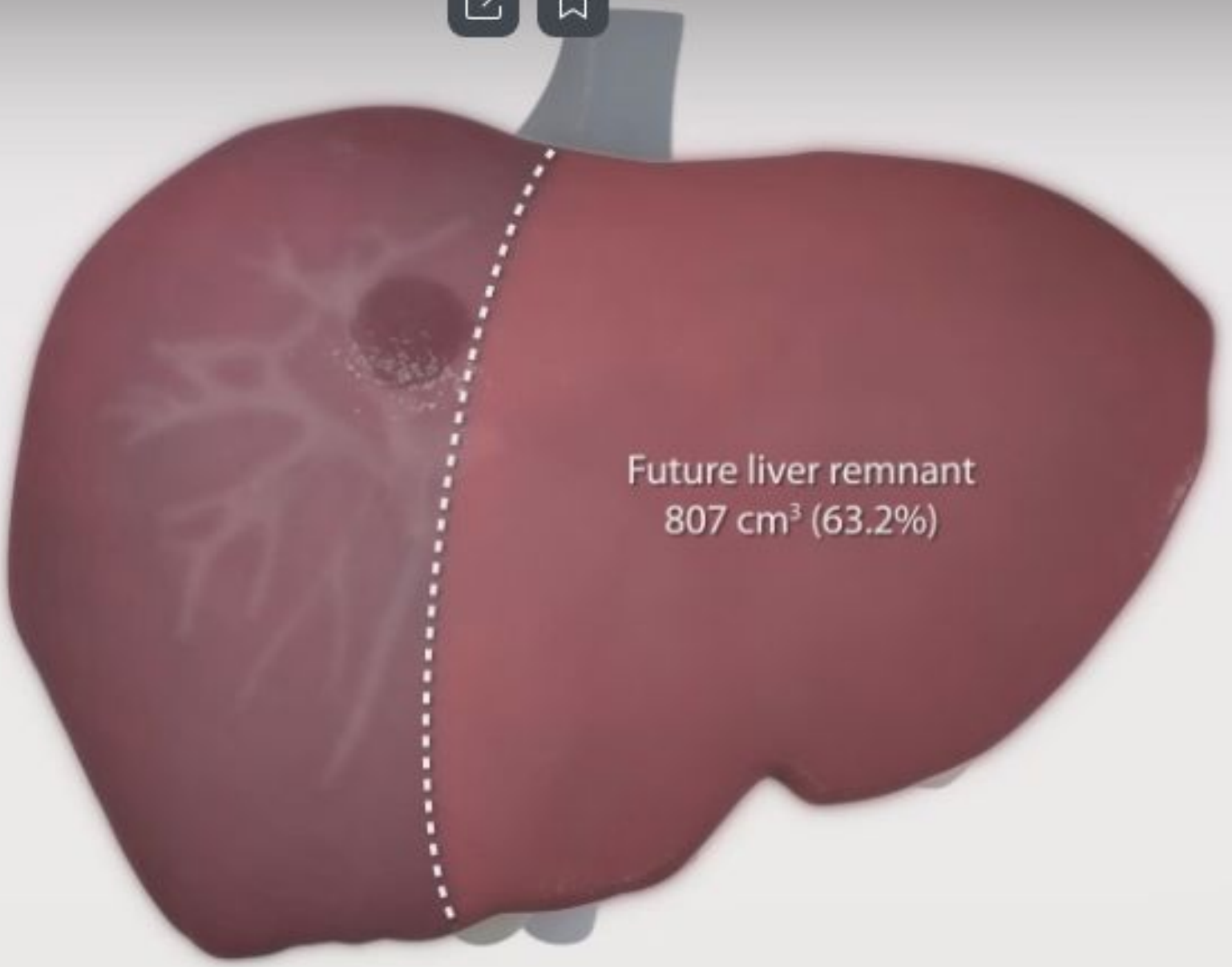
Future liver remnant
807 cm³ (63.2%)

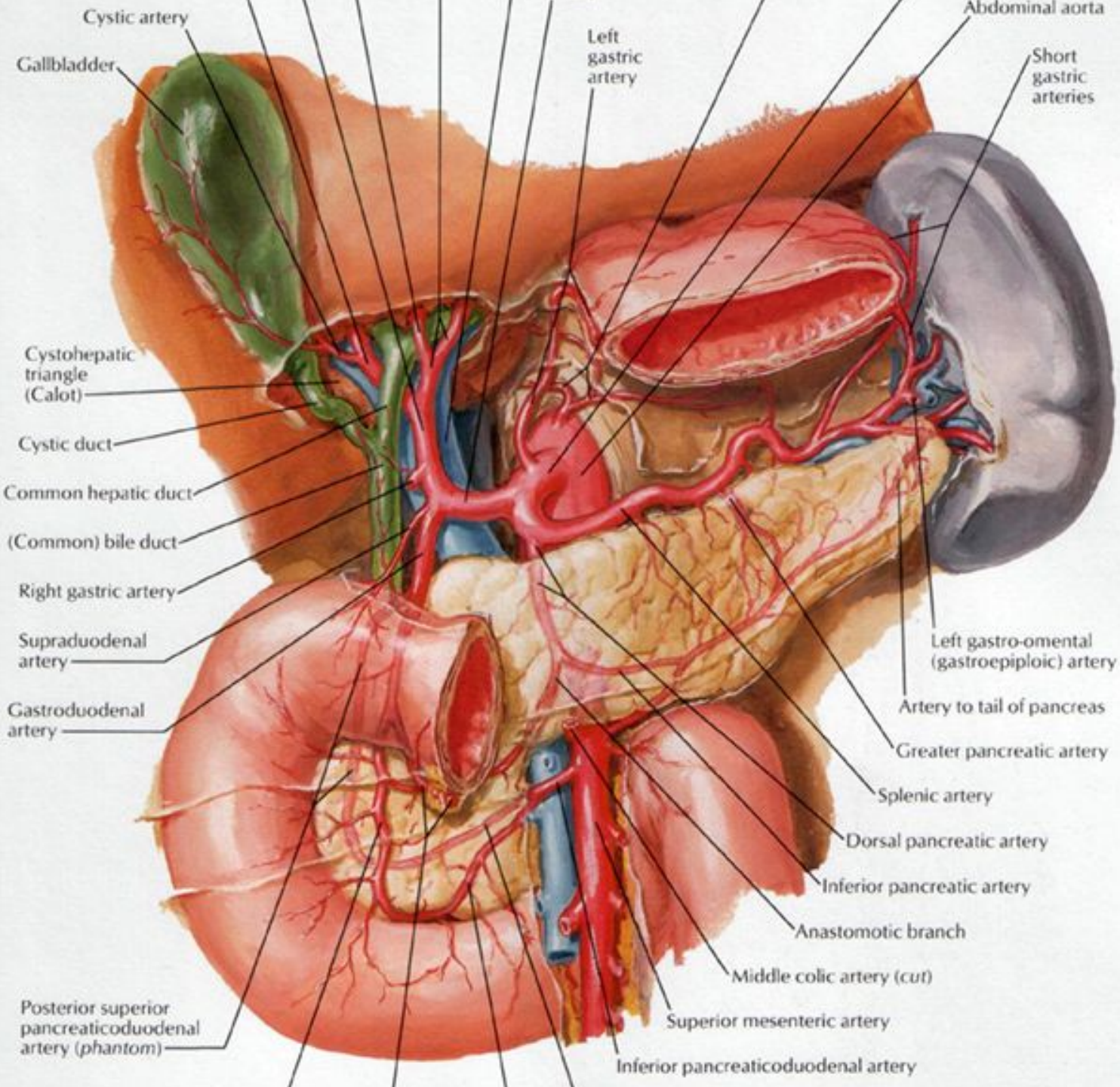
Cystic artery
Gallbladder
Left gastric artery
Abdominal aorta
Short gastric arteries
Cystohepatic triangle (Calot)
Cystic duct
Common hepatic duct
(Common) bile duct
Right gastric artery
Supraduodenal artery
Gastroduodenal artery
Left gastro-omental (gastroepiploic) artery
Artery to tail of pancreas
Greater pancreatic artery
Splenic artery
Dorsal pancreatic artery
Inferior pancreatic artery
Anastomotic branch
Middle colic artery (cut)
Superior mesenteric artery
Inferior pancreaticoduodenal artery
Posterior superior pancreaticoduodenal artery (phantom)

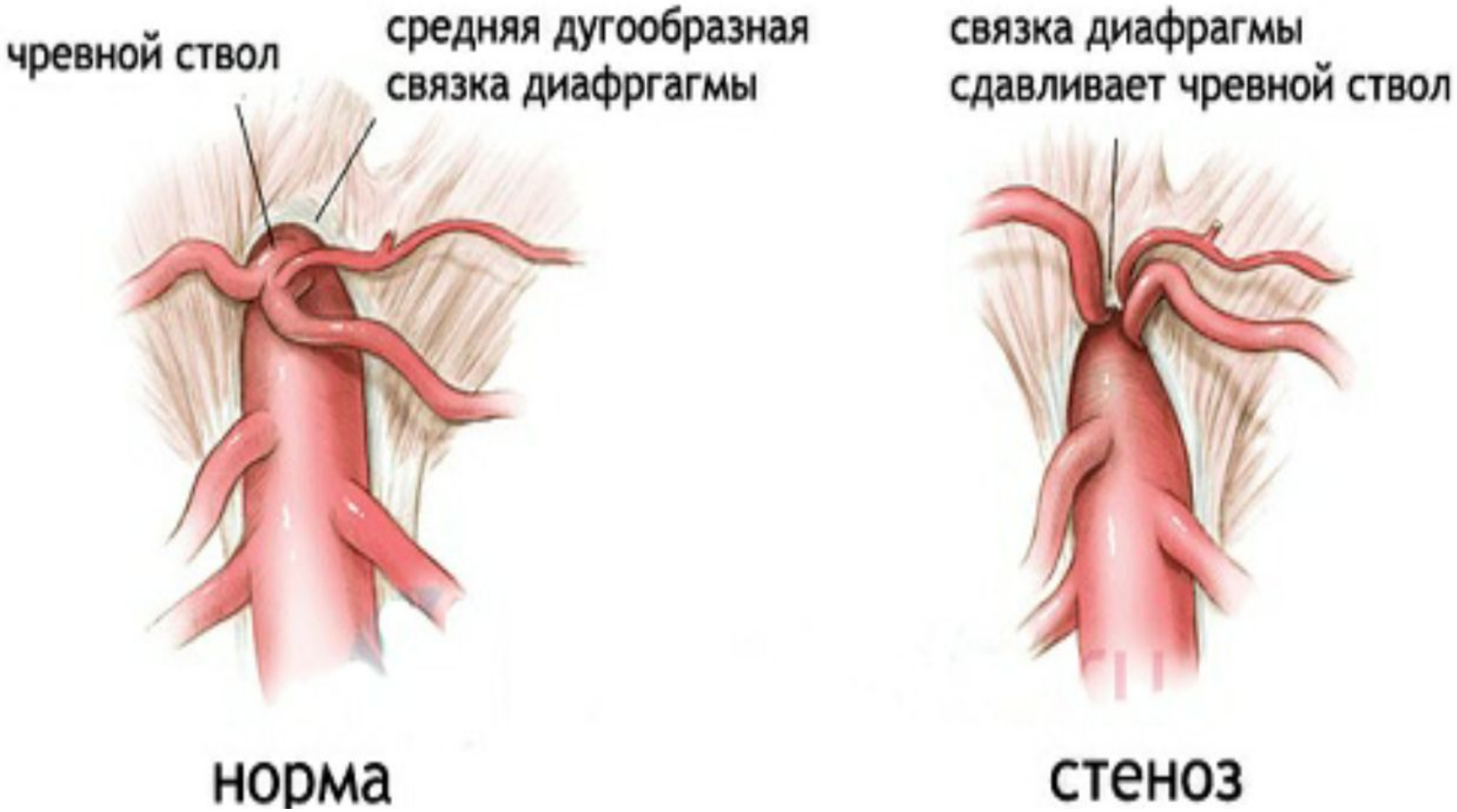

Схематическое изображение
синдрома Данбара (компрессионный стеноз чревного ствола).

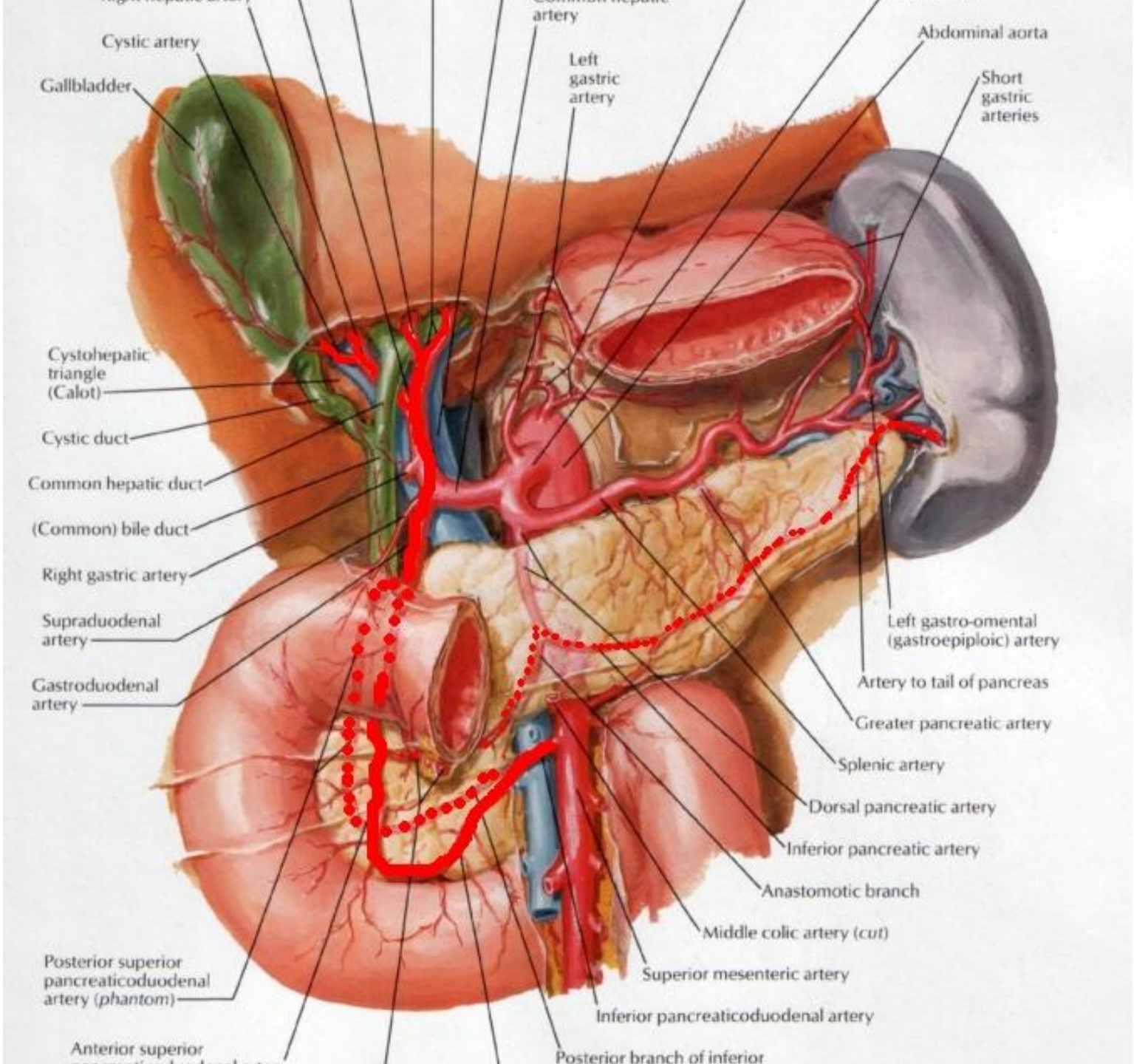
Cystic artery
Gallbladder
Left gastric artery
Abdominal aorta
Short gastric arteries
Cystohepatic triangle (Calot)
Cystic duct
Common hepatic duct
(Common) bile duct
Right gastric artery
Supraduodenal artery
Gastroduodenal artery
Left gastro-omental (gastroepiploic) artery
Artery to tail of pancreas
Greater pancreatic artery
Splenic artery
Dorsal pancreatic artery
Inferior pancreatic artery
Anastomotic branch
Middle colic artery (cut)
Superior mesenteric artery
Inferior pancreaticoduodenal artery
Posterior superior pancreaticoduodenal artery (phantom)
Anterior superior
Posterior branch of inferior

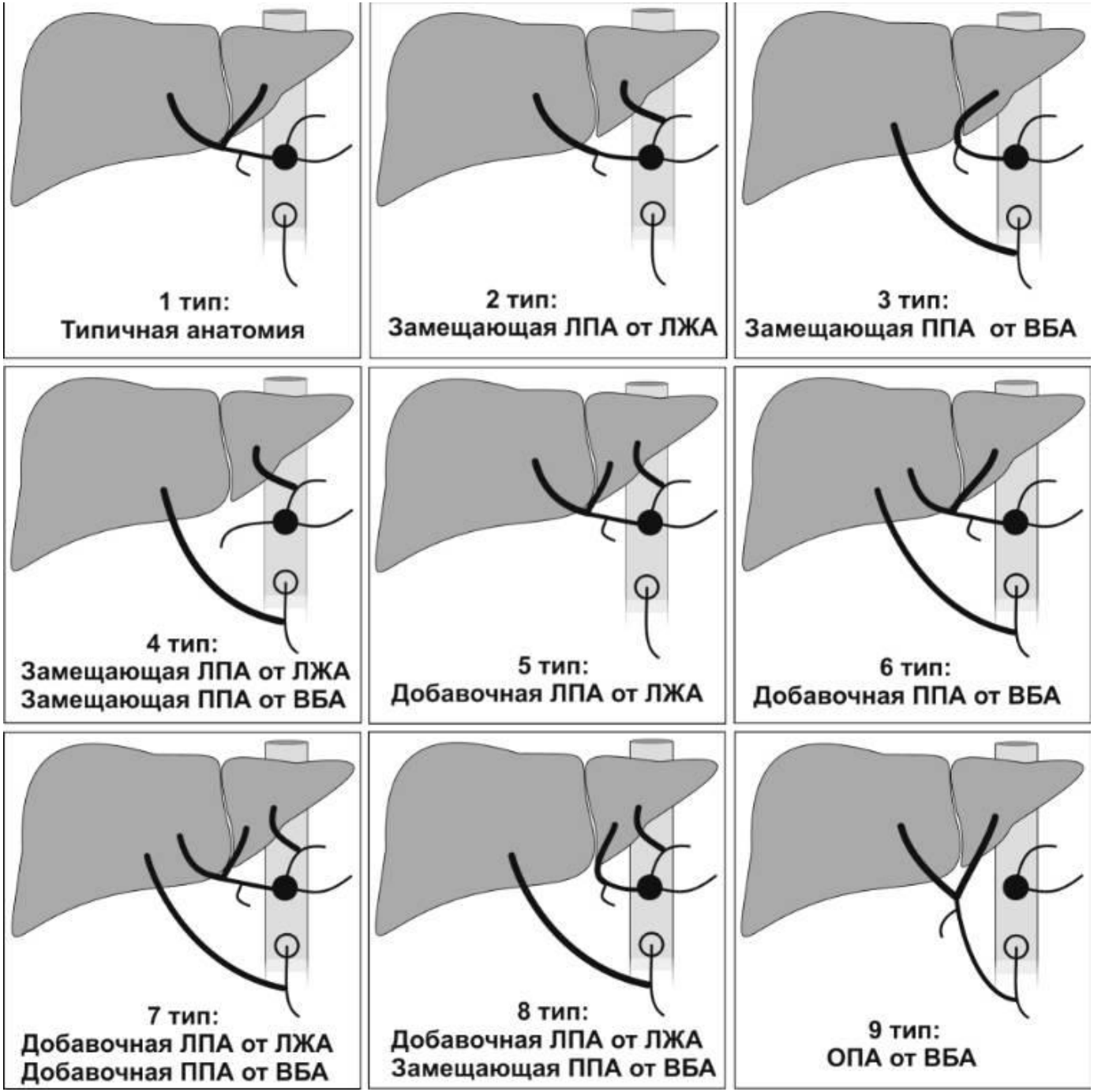
1 тип:
Типичная анатомия
2 тип:
Замещающая ЛПА от ЛЖА
3 тип:
Замещающая ППА от ВБА
4 тип:
Замещающая ЛПА от ЛЖА
Замещающая ППА от ВБА
5 тип:
Добавочная ЛПА от ЛЖА
6 тип:
Добавочная ППА от ВБА
7 тип:
Добавочная ЛПА от ЛЖА
Добавочная ППА от ВБА
8 тип:
Добавочная ЛПА от ЛЖА
Замещающая ППА от ВБА
9 тип:
ОПА от ВБА

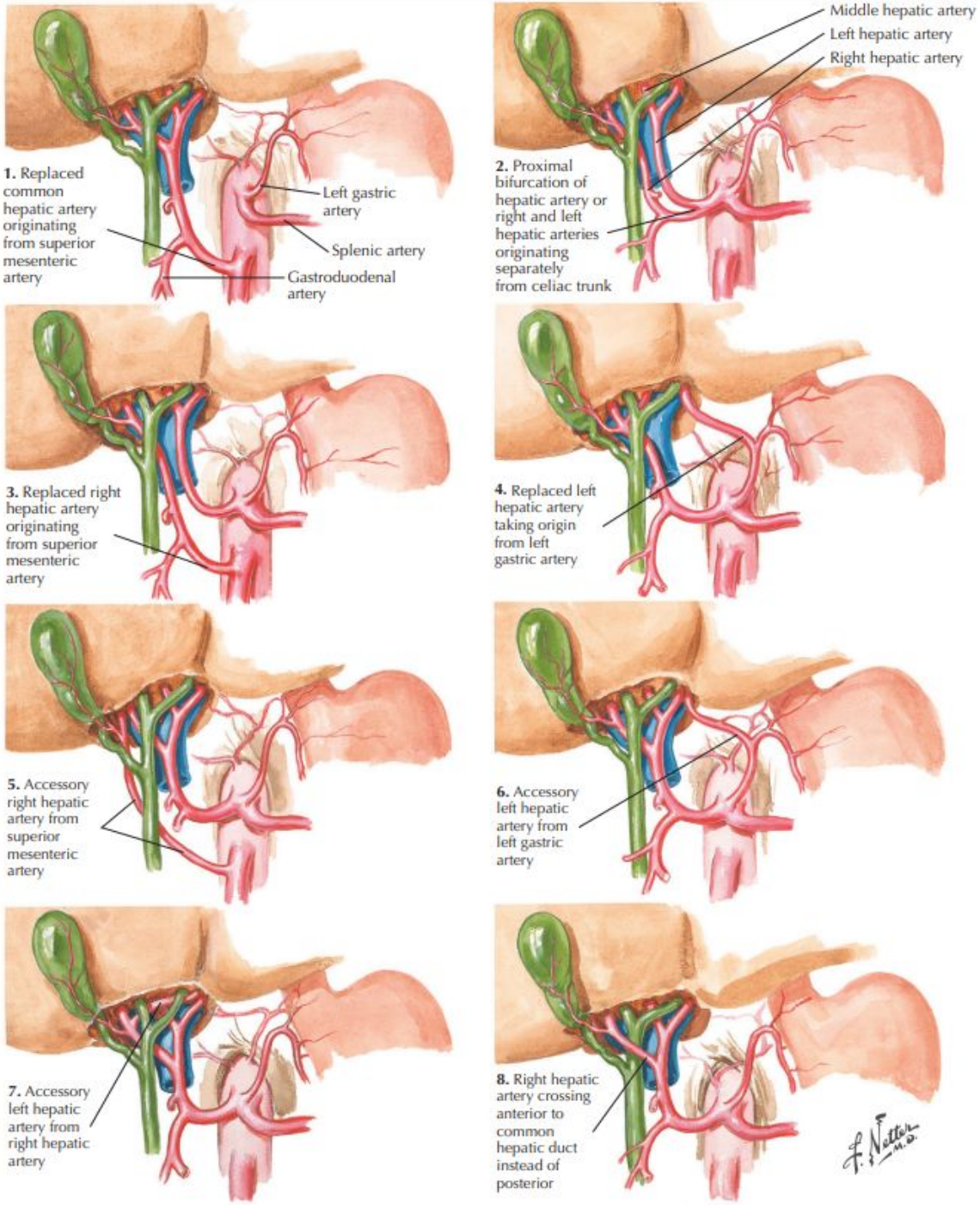
1. Replaced common hepatic artery originating from superior mesenteric artery
Left gastric artery
Splenic artery
Gastroduodenal artery
2. Proximal bifurcation of hepatic artery or right and left hepatic arteries originating separately from celiac trunk
Middle hepatic artery
Left hepatic artery
Right hepatic artery
3. Replaced right hepatic artery originating from superior mesenteric artery
4. Replaced left hepatic artery taking origin from left gastric artery
5. Accessory right hepatic artery from superior mesenteric artery
6. Accessory left hepatic artery from left gastric artery
7. Accessory left hepatic artery from right hepatic artery
8. Right hepatic artery crossing anterior to common hepatic duct instead of posterior
F. Netter M.D.

Операция из МКНЦ. Добавочная артерия к S2 из ЛЖА питающая гемангиому. + на операции видно дольку Ридля

02:30 – и далее

https://laparoscopyrf.ru/videos/292/jivaya-hirurgiya-i-rossiyskaya-shkola-po-laparoskopicheskoy-hirurgii-pecheni/

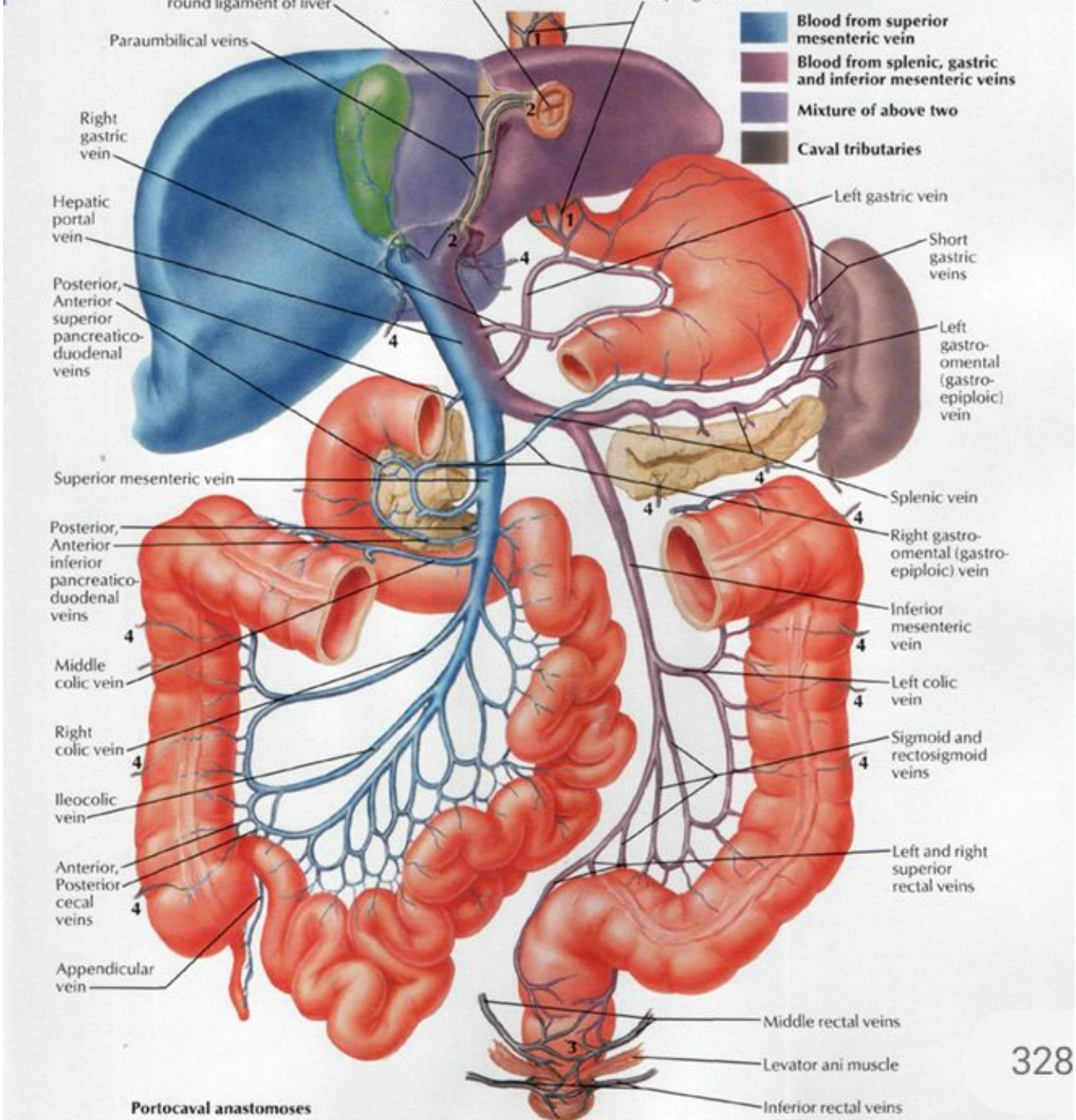

Portocaval anastomoses

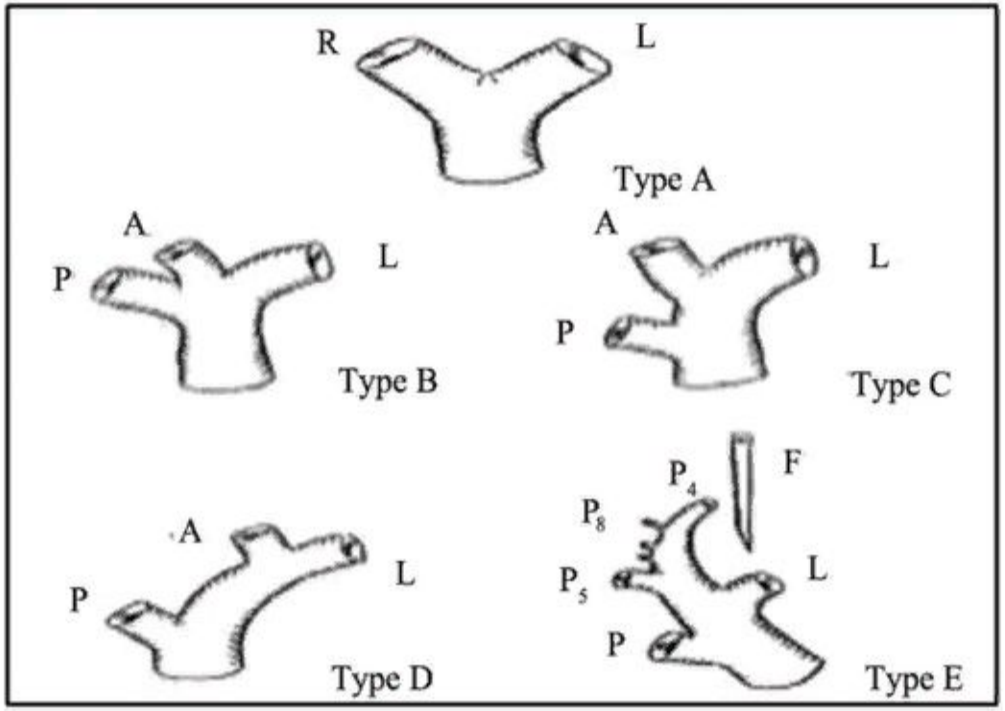

L — левая ВВ

R — правая ВВ

A — передняя правая ветвь

P — задняя правая ветвь

Type A — классический тип деления ВВ на правый и левый стволы

Type B — истинная трифуркация, без основного ствола правой воротной вены

Type C — внепеченочное отхождение передней ветви правой воротной вены

Type D — внутрипеченочное отхождение передней ветви правой воротной вены

Type E — отсутствие целостной ветви передней правой воротной вены

Отхождение отдельных сегментарных ветвей от ВВ

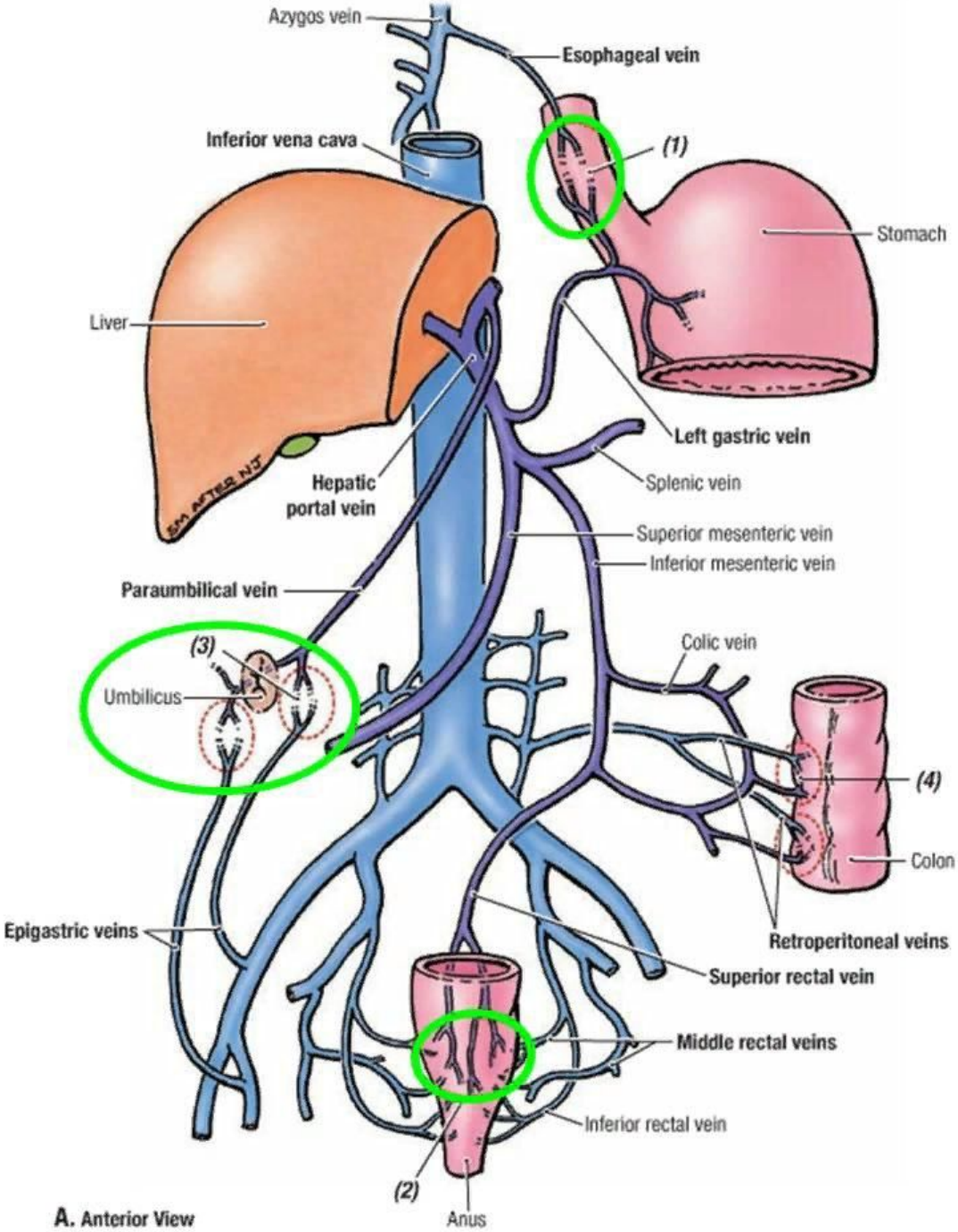

A. Anterior View

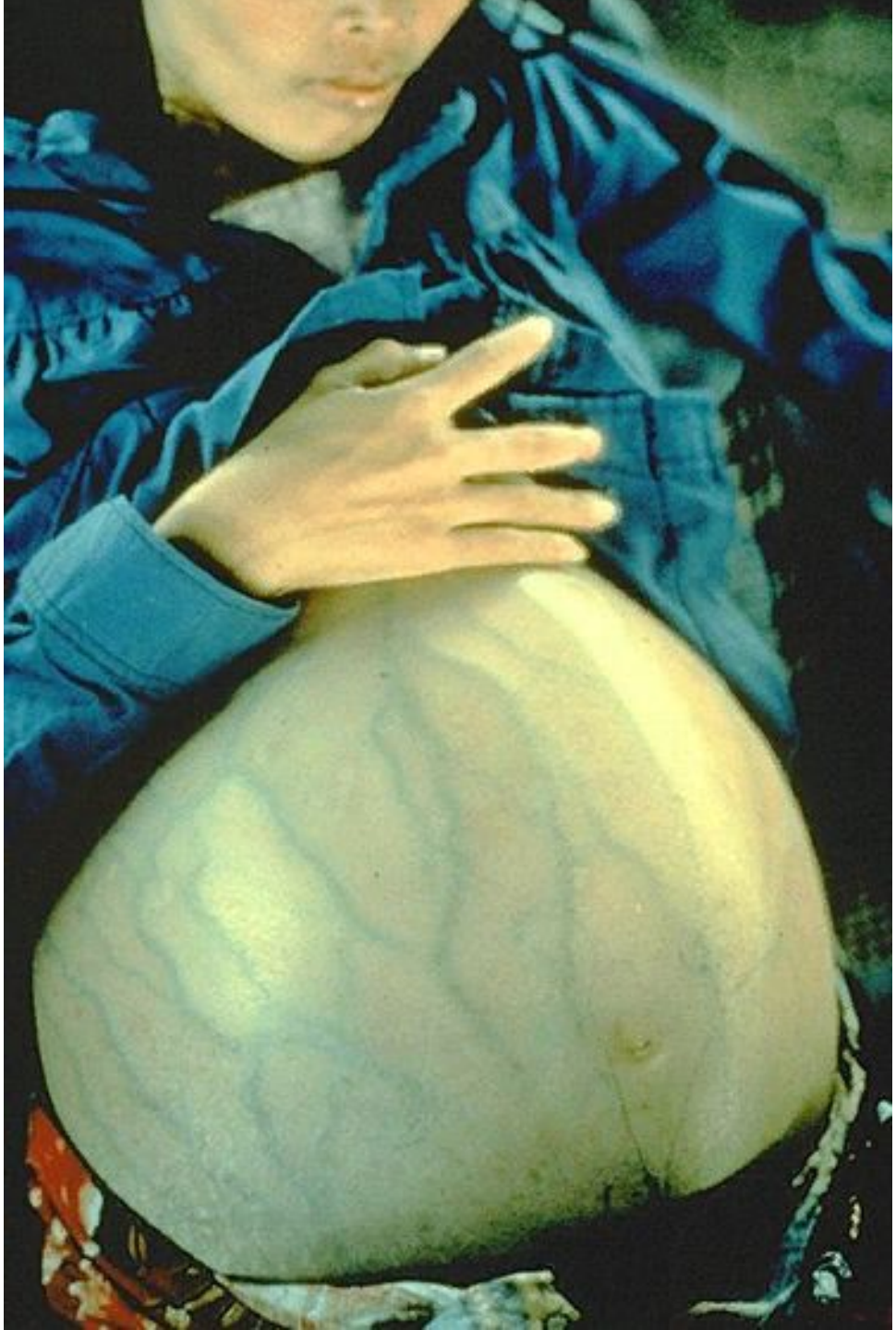

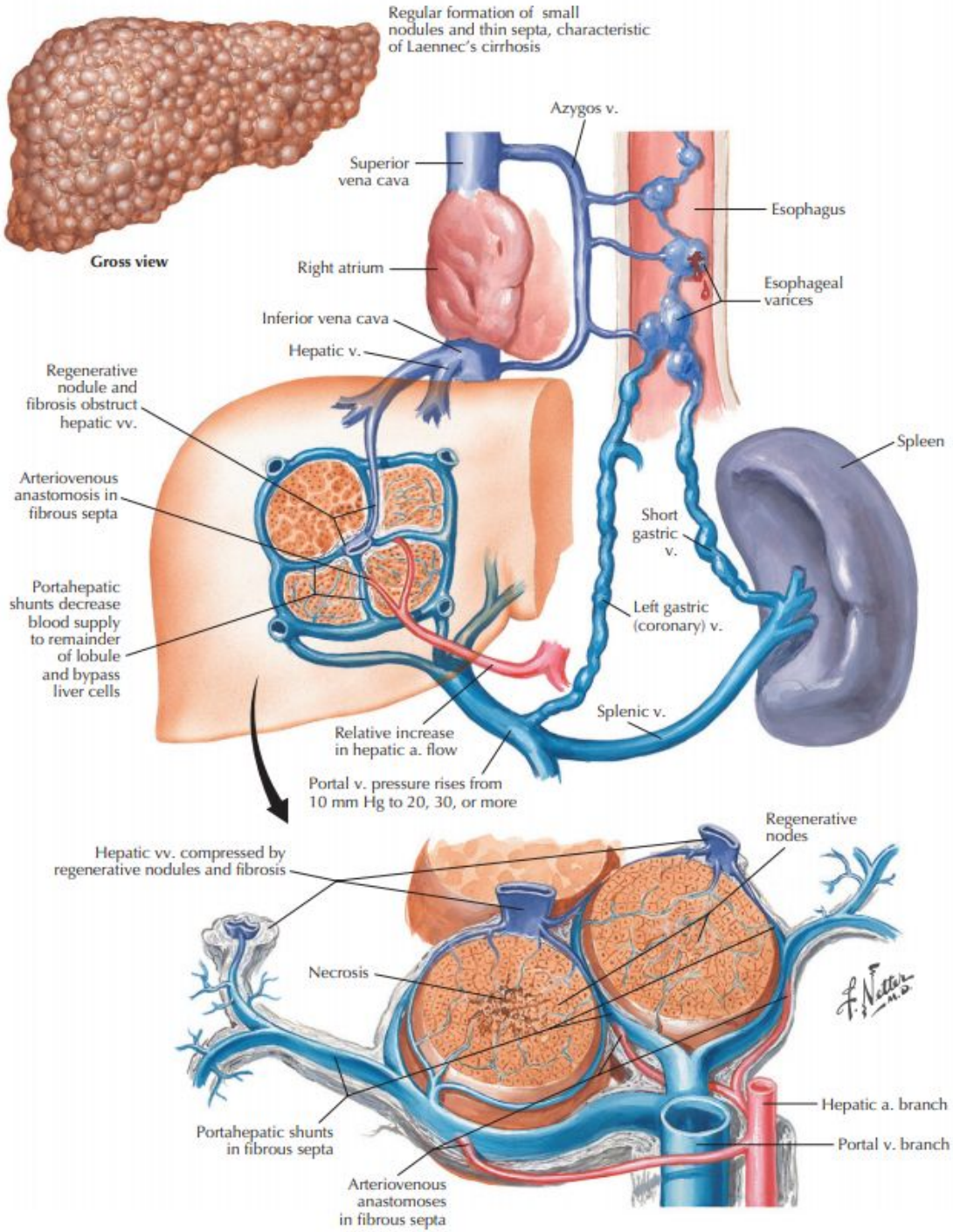
Regular formation of small nodules and thin septa, characteristic of Laennec's cirrhosis
Gross view
Azygos v.
Superior vena cava
Esophagus
Right atrium
Esophageal varices
Inferior vena cava
Hepatic v.
Regenerative nodule and fibrosis obstruct hepatic vv.
Spleen
Arteriovenous anastomosis in fibrous septa
Short gastric v.
Portahepatic shunts decrease blood supply to remainder of lobule and bypass liver cells
Left gastric (coronary) v.
Splenic v.
Relative increase in hepatic a. flow
Portal v. pressure rises from 10 mm Hg to 20, 30, or more
Regenerative nodes
Hepatic vv. compressed by regenerative nodules and fibrosis
Necrosis
Hepatic a. branch
Portal v. branch
Portahepatic shunts in fibrous septa
Arteriovenous anastomoses in fibrous septa

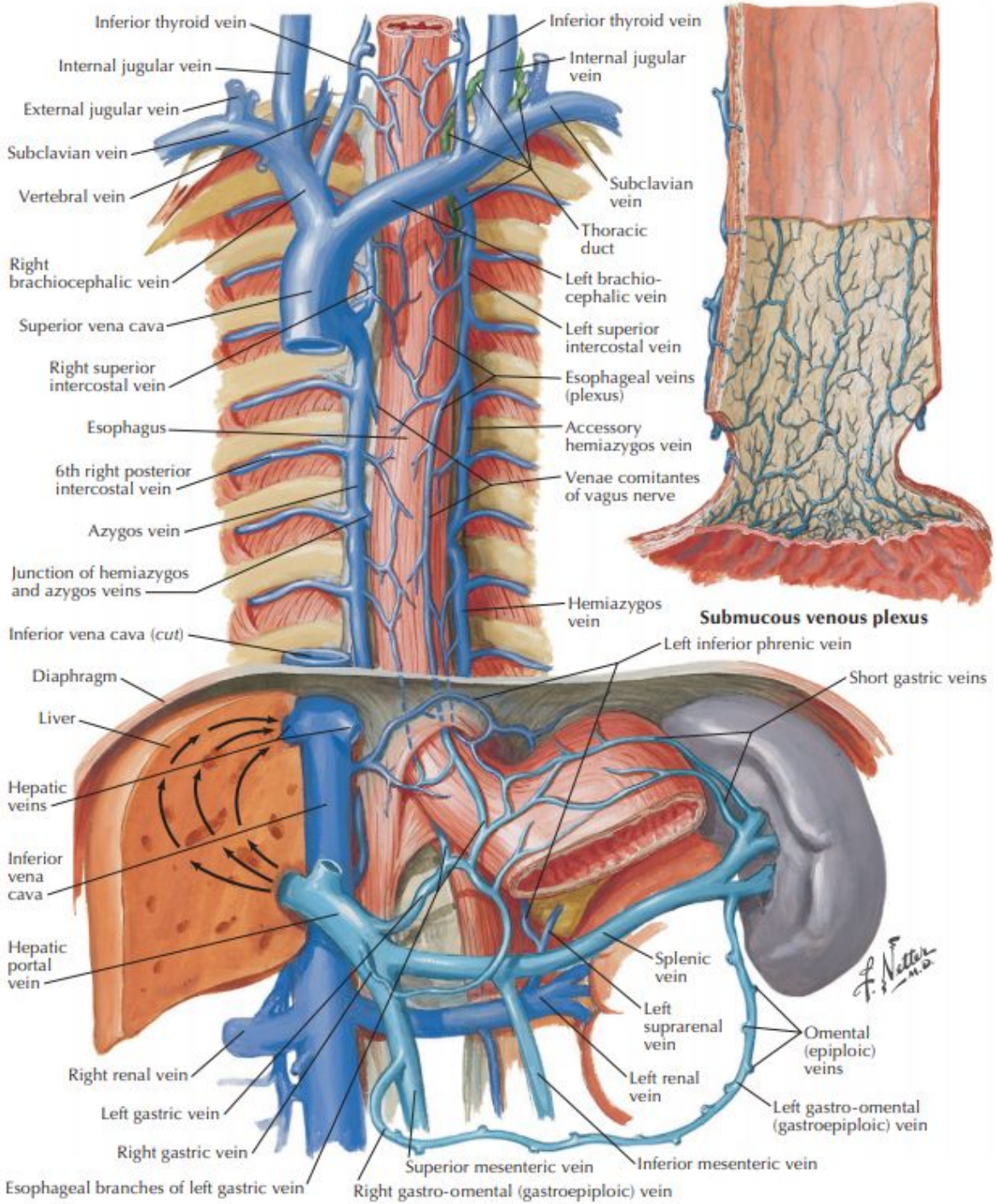
Inferior thyroid vein
Internal jugular vein
External jugular vein
Subclavian vein
Vertebral vein
Right brachiocephalic vein
Superior vena cava
Right superior intercostal vein
Esophagus
6th right posterior intercostal vein
Azygos vein
Junction of hemiazygos and azygos veins
Inferior vena cava (cut)
Inferior thyroid vein
Internal jugular vein
Subclavian vein
Thoracic duct
Left brachio-cephalic vein
Left superior intercostal vein
Esophageal veins (plexus)
Accessory hemiazygos vein
Venae comitantes of vagus nerve
Hemiazygos vein
Submucous venous plexus
Left inferior phrenic vein
Short gastric veins
Diaphragm
Liver
Hepatic veins
Inferior vena cava
Hepatic portal vein
Splenic vein
Left suprarenal vein
Left renal vein
Omental (epiploic) veins
Left gastro-omental (gastroepiploic) vein
Right renal vein
Left gastric vein
Right gastric vein
Esophageal branches of left gastric vein
Superior mesenteric vein
Right gastro-omental (gastroepiploic) vein
Inferior mesenteric vein
F. Netter M.D.

эзофагоскопия

расширенная вена пищевода

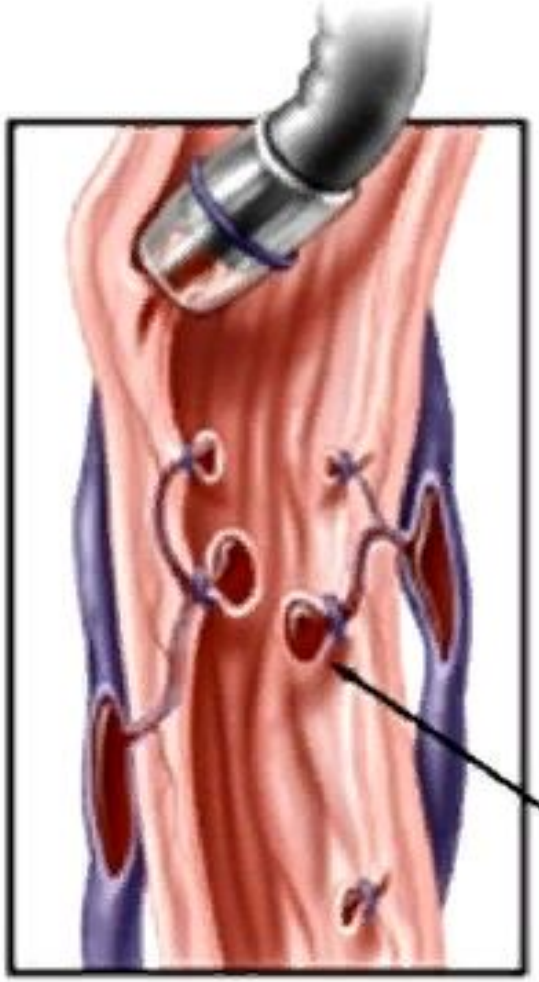

Лигированные ВРВ пищевода

Если захочется видео из МКНЦ по лигированию вен. Смотреть 07:32 – 09:15

- https://yandex.ru/video/preview/?filmId=3322308443689264692&from=tabbar&parent-reqid=1587826932223447-855981273579961176000291-production-app-host-sas-web-yp-75&text=кровотечение+из+врв+пищевода+мкб+10

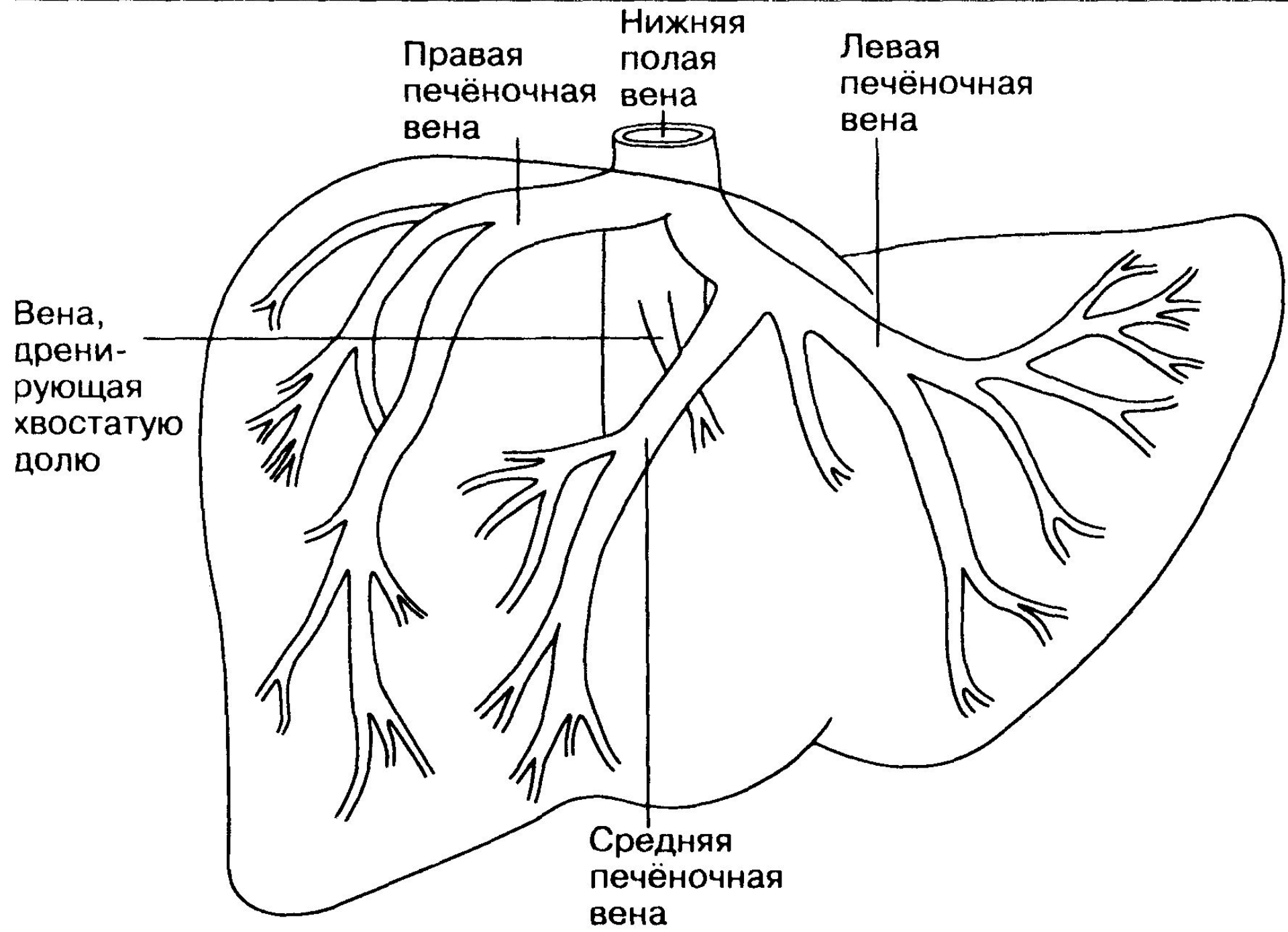
Нижняя полая вена
Правая печёночная вена
Левая печёночная вена
Вена, дрени-рующая хвостатую долю
Средняя печёночная вена

Left hepatic vein
Right hepatic vein
Middle hepatic vein
Hepatic portal vein

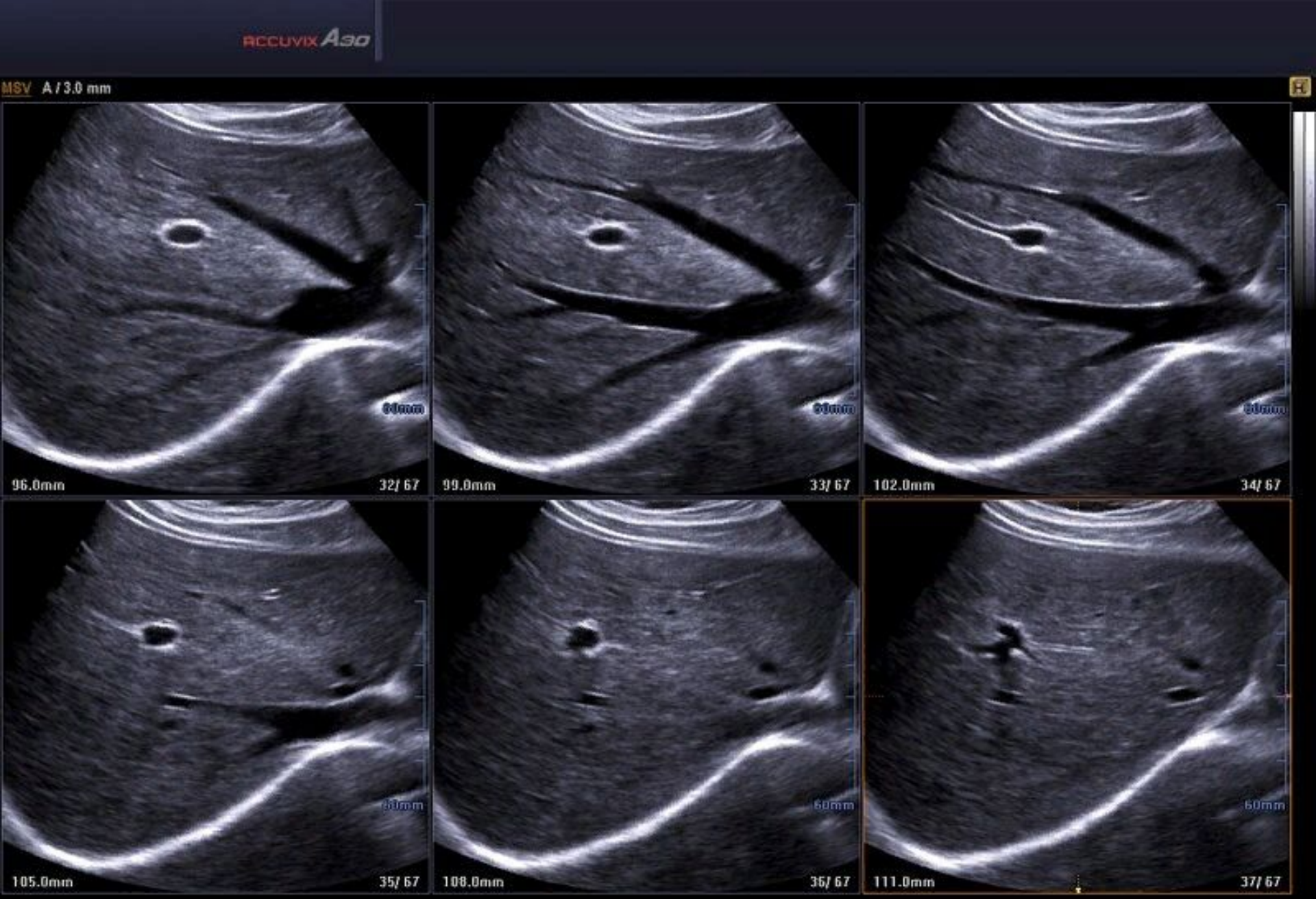
ACCUVIX A30
MSV A / 3.0 mm
96.0mm
32/ 67
99.0mm
33/ 67
102.0mm
34/ 67
105.0mm
35/ 67
108.0mm
36/ 67
111.0mm
37/ 67

Видео с операции. Чтобы понять где кавальные ворота печени и печеночные вены. 02:00 – 06:15

- https://www.youtube.com/watch?v=CajDSIIVZp8&feature=youtu.be

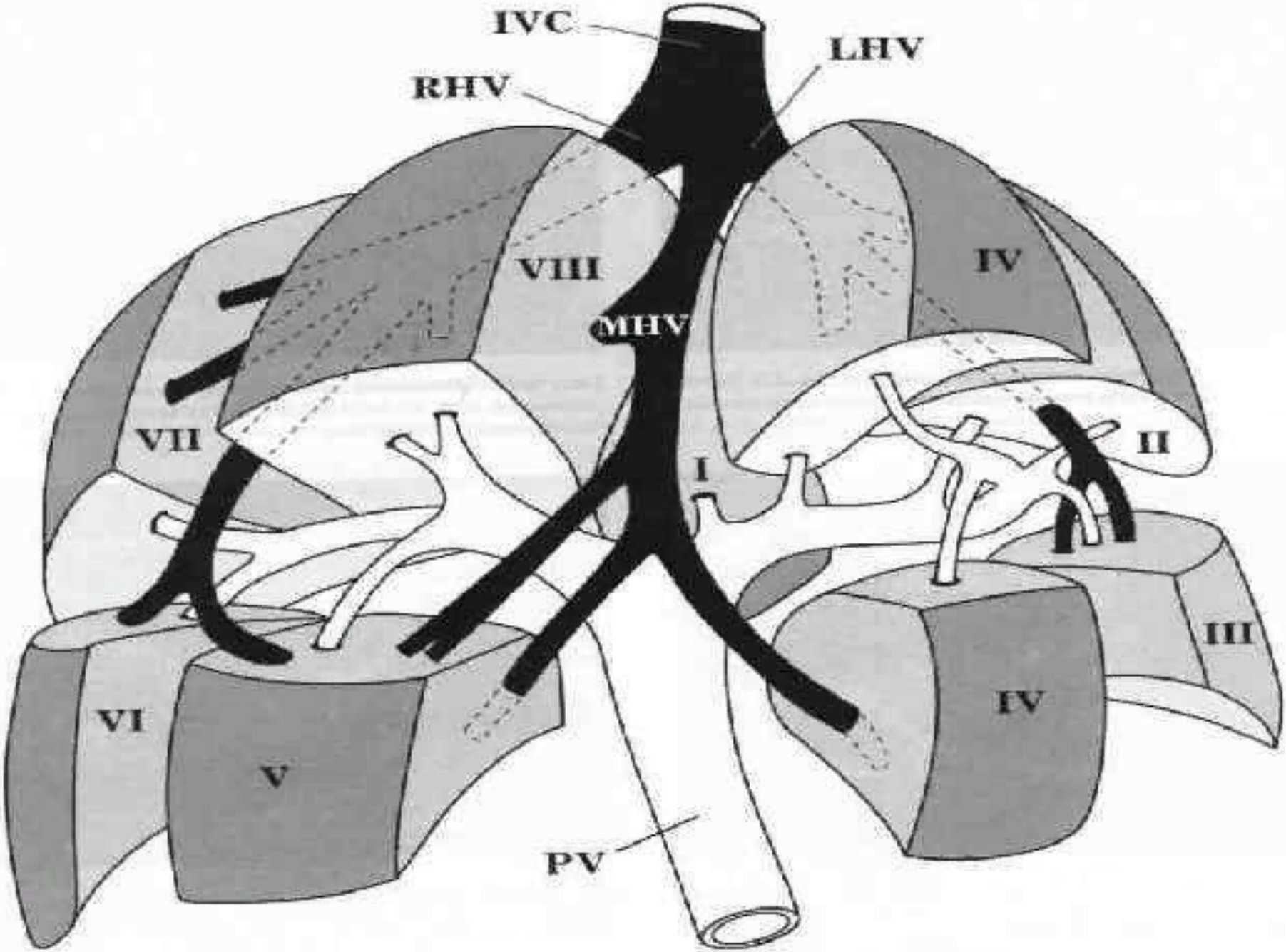
IVC
LHV
RHV
VIII
IV
MHV
VII
II
I
III
IV
VI
V
PV

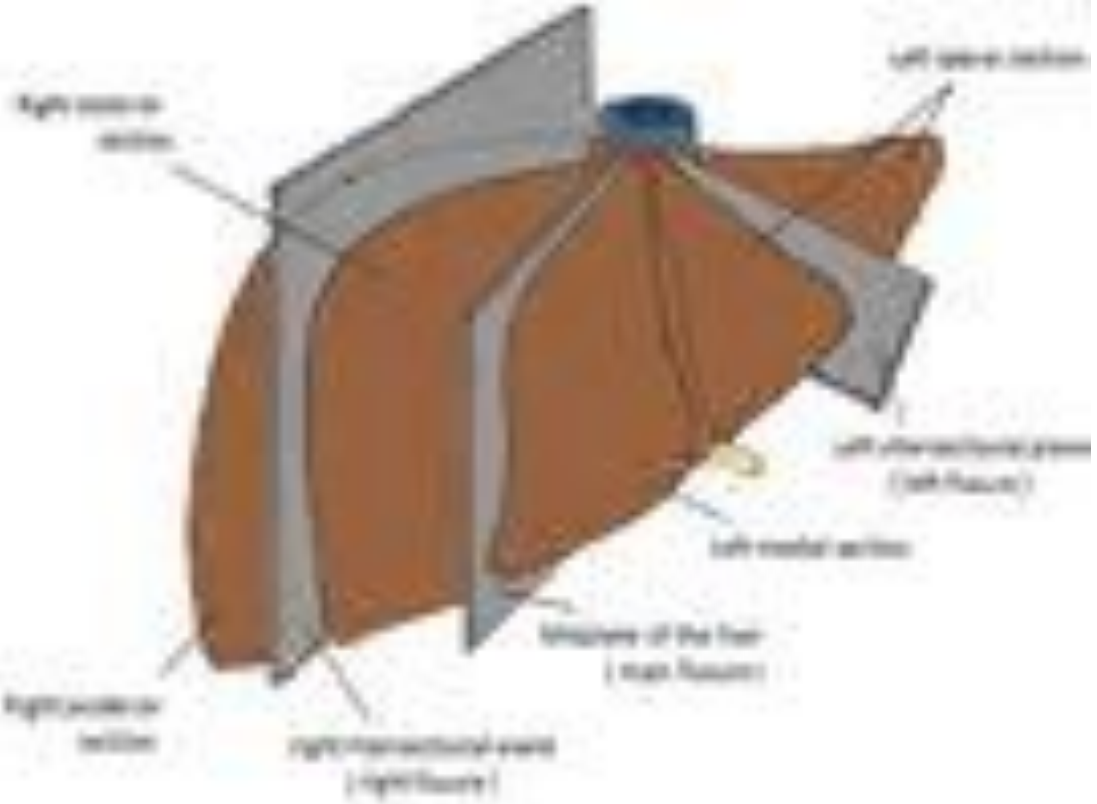
Left lateral section
Left sagittal plane
(left fissure)
Left medial section
Hilum of the liver
(main fissure)
Right anterior
section
right sagittal plane
(right fissure)
Right posterior
section

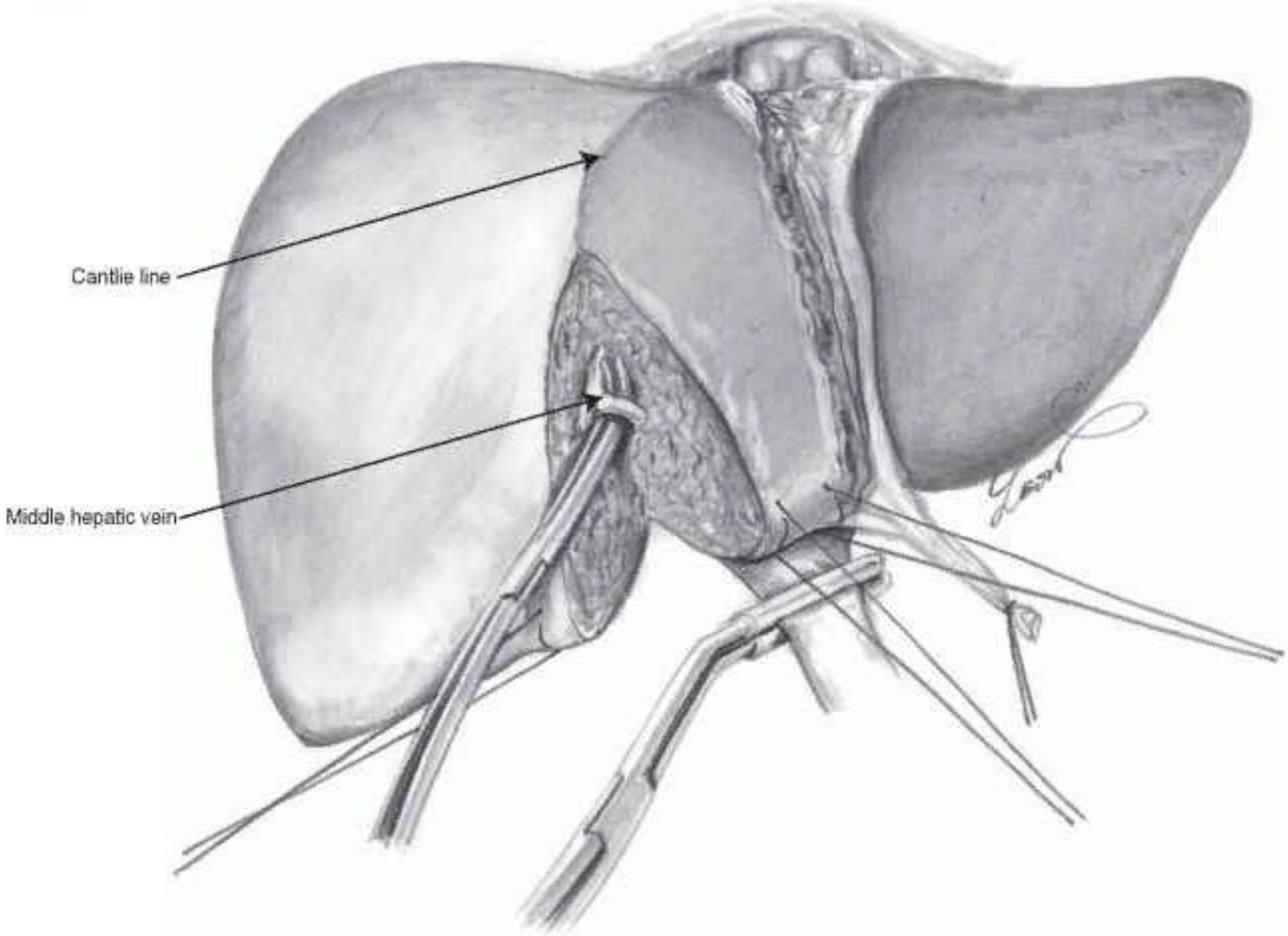
Cantlie line
Middle hepatic vein

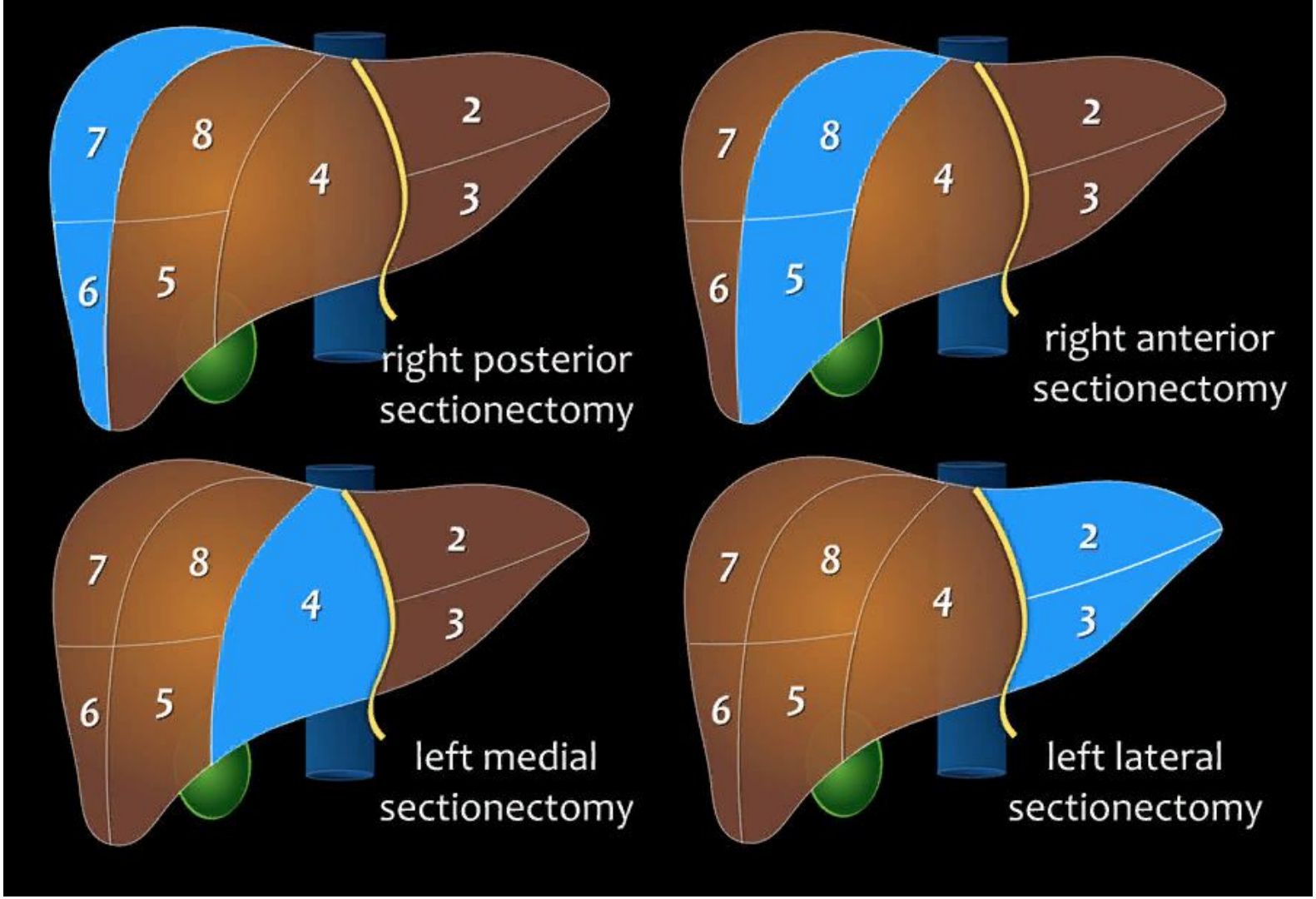

Классификация обширных резекций печени (по В.С. Шапкину, 1967).

- Гемигепатэктомия правосторонняя (удаление сегментов 5, 6, 7, 8).
- Гемигепатэктомия левосторонняя (удаление сегментов 2, 3, 4±1).
- Расширенная правосторонняя гемигепатэктомия (удаление сегментов 5, 6, 7, 8, 4±1).
- Расширенная левосторонняя гемигепатэктомия (удаление сегментов 2, 3, 4, 5, 8±1).

Видео по резекции печени. Хорошо видно линию Рекса-Кантли. 03:40 – и далее

- http://pie.med.utoronto.ca/TVASurg/project/righthep-pvembolization/

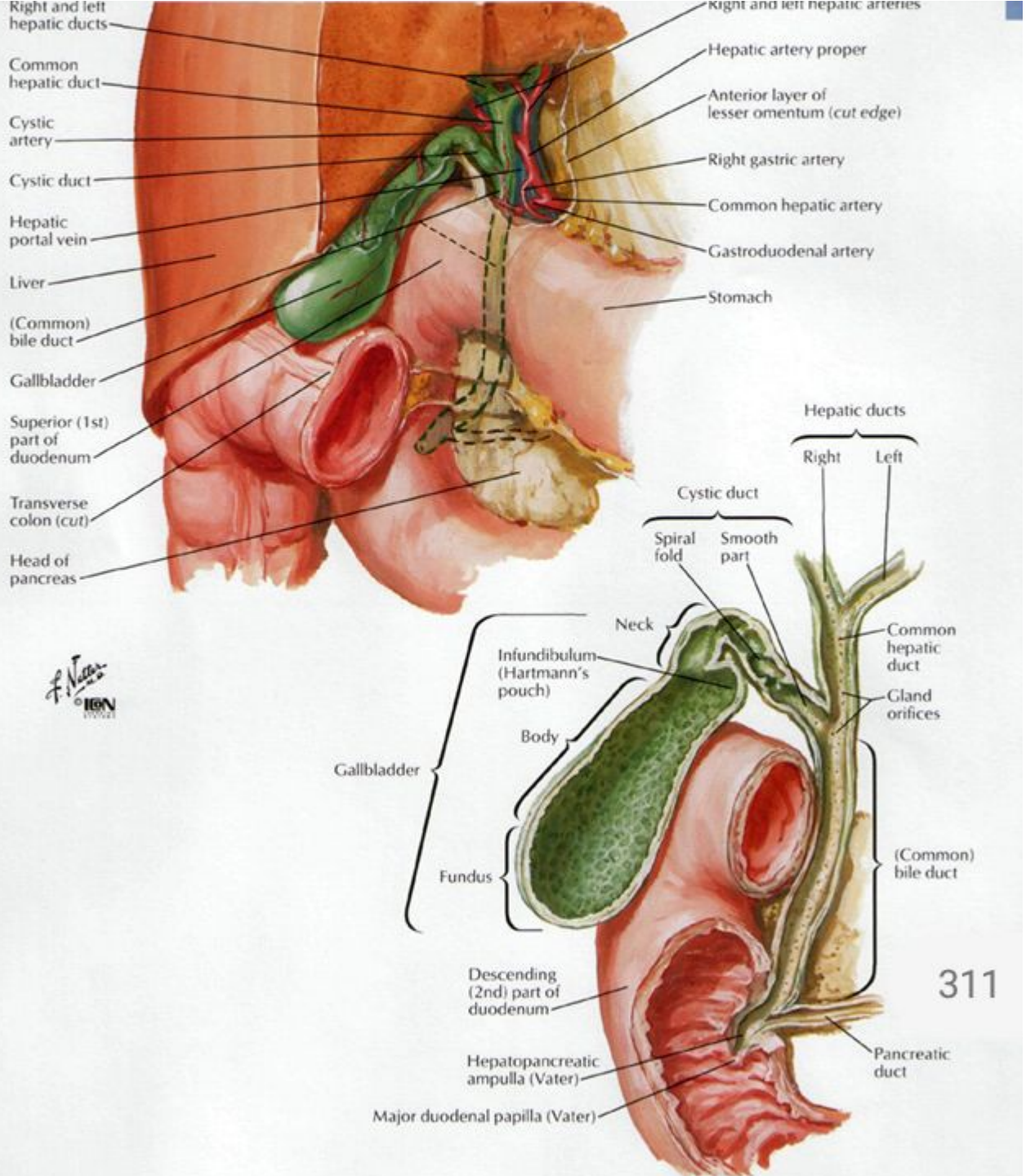
Right and left hepatic ducts
Common hepatic duct
Cystic artery
Cystic duct
Hepatic portal vein
Liver
(Common) bile duct
Gallbladder
Superior (1st) part of duodenum
Transverse colon (cut)
Head of pancreas
Right and left hepatic arteries
Hepatic artery proper
Anterior layer of lesser omentum (cut edge)
Right gastric artery
Common hepatic artery
Gastroduodenal artery
Stomach
Hepatic ducts
Right
Left
Cystic duct
Spiral fold
Smooth part
Neck
Infundibulum (Hartmann's pouch)
Body
Gallbladder
Fundus
Common hepatic duct
Gland orifices
(Common) bile duct
Descending (2nd) part of duodenum
Hepatopancreatic ampulla (Vater)
Major duodenal papilla (Vater)
Pancreatic duct

Variations in cystic duct

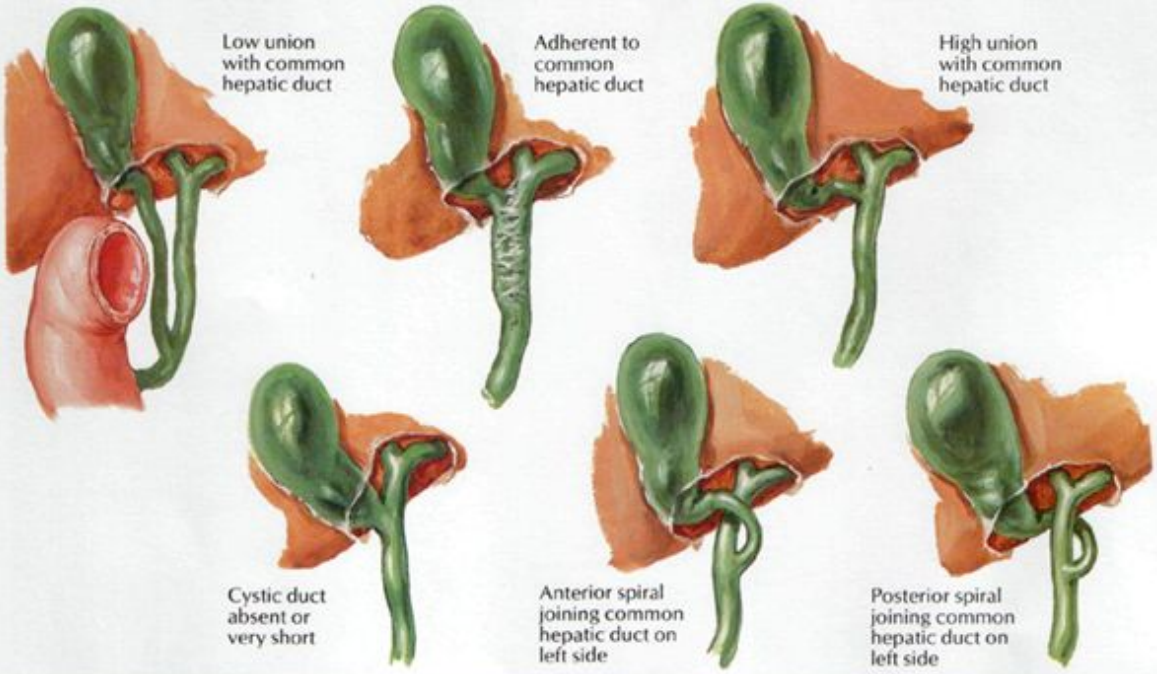

Accessory (aberrant) hepatic ducts

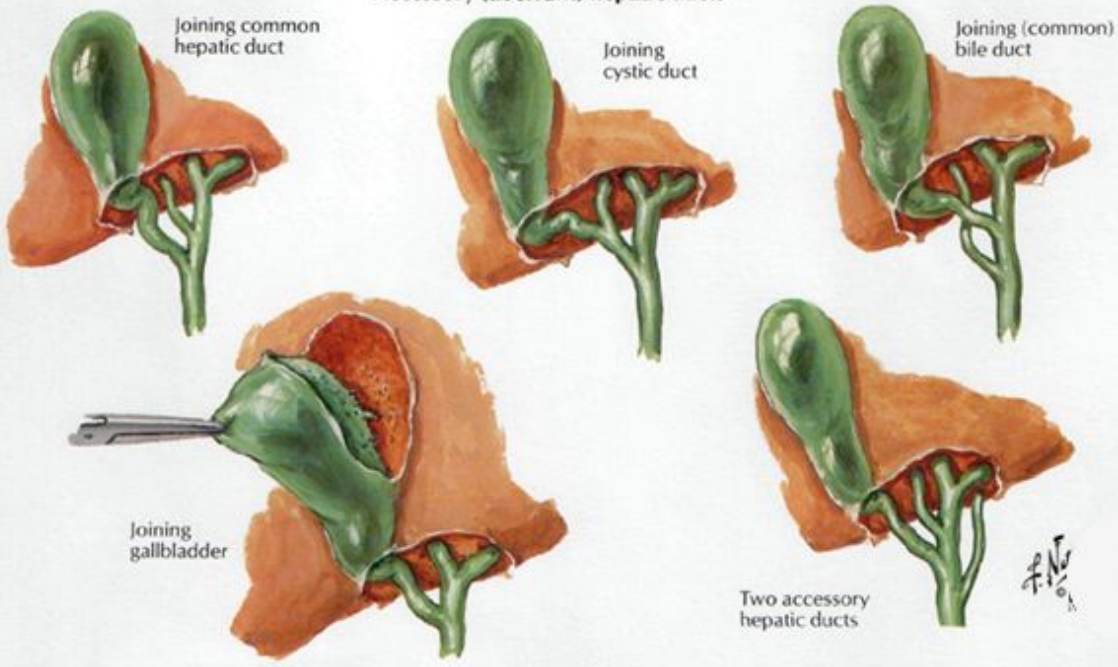

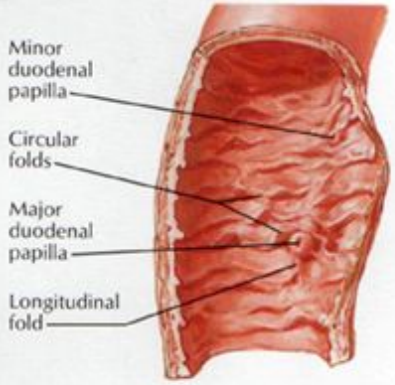

Interior of descending (2nd) part of duodenum

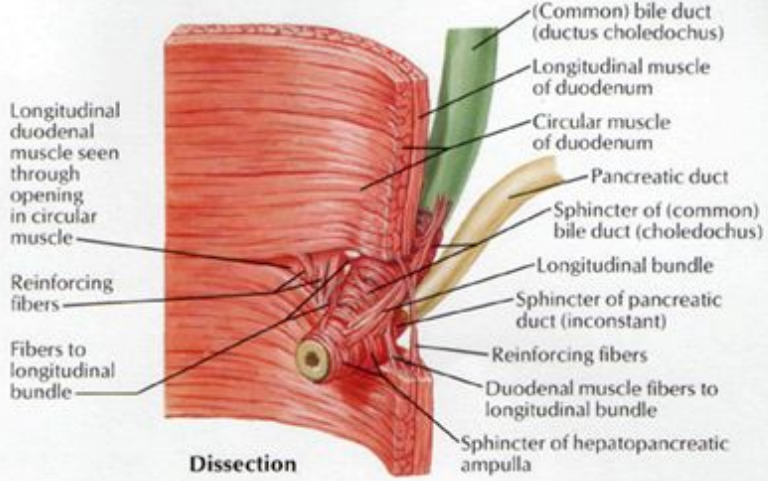

Dissection

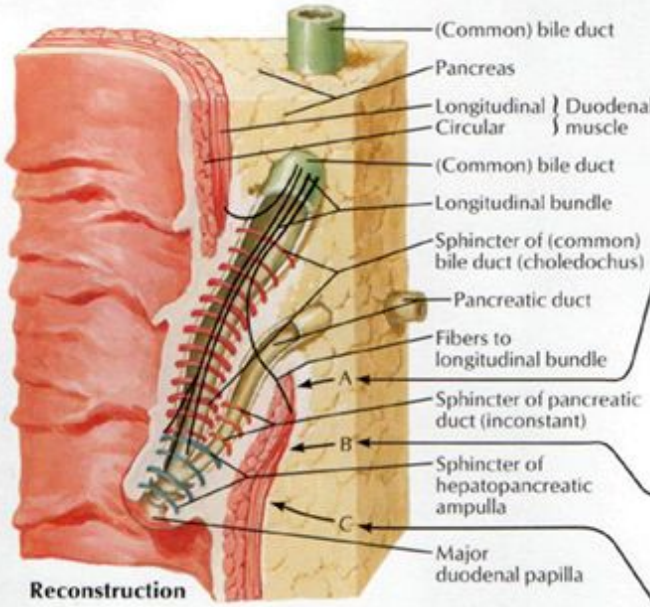

Reconstruction

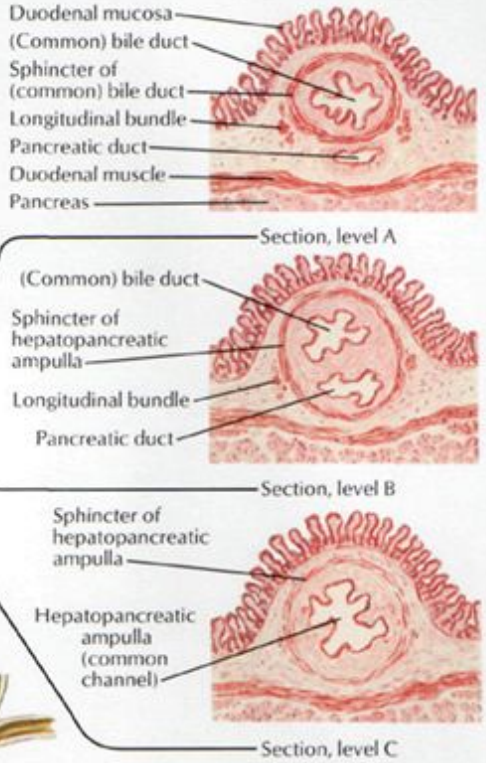

Variations in union of bile and pancreatic ducts

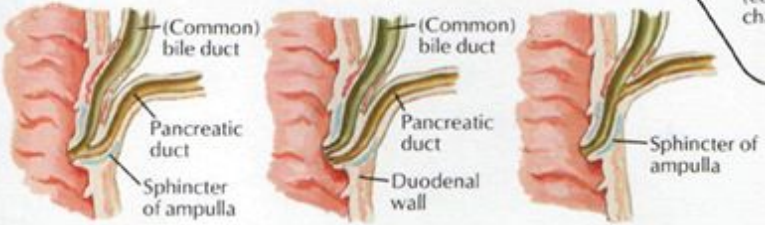

Short common channel | No common channel | Long common channel

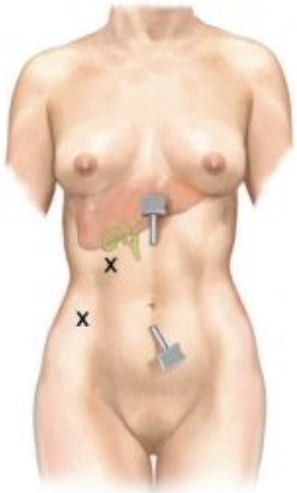

Laparoscopic port placement for bile duct exploration

T-tube cholangiogram shows retained stone in common duct

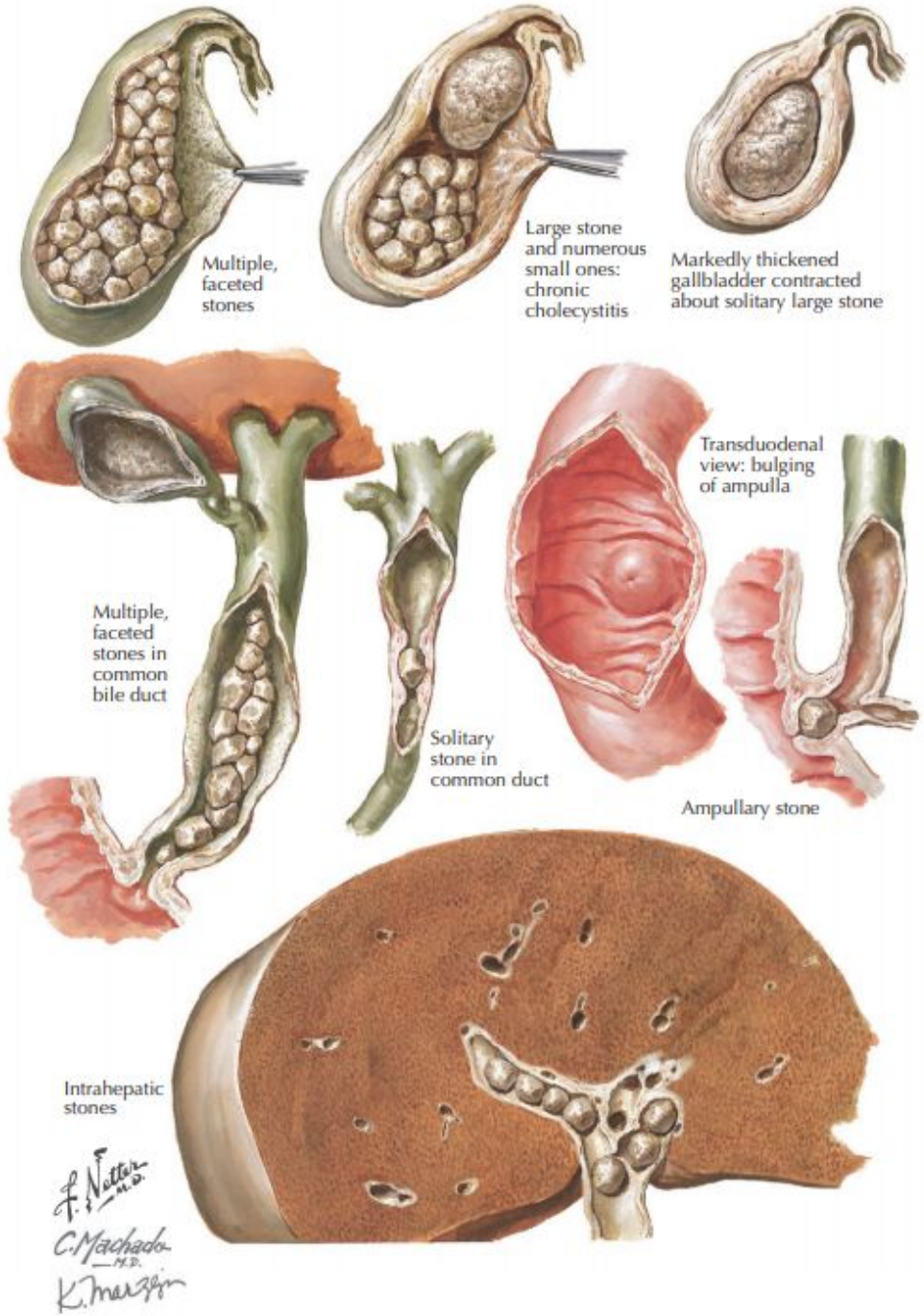

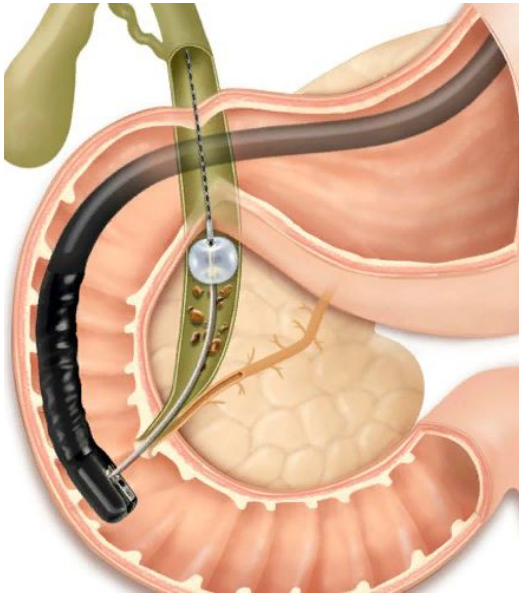

Видео ЭГХПГ, ЭГЮТ, Литоэкстракция. 02:10 и далее на быстрой промотке

- https://www.youtube.com/watch?v=x9OceQhcg-I

правая печёночная артерия
пузырная артерия
левая печёночная артерия
пузырный проток
общий печёночный проток
треугольник Кало
общий желчный проток

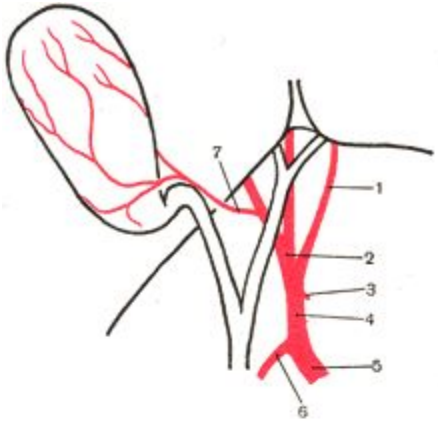
7
1
2
3
4
5
6

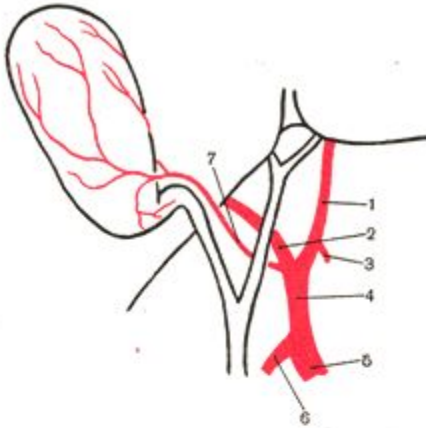
7
1
2
3
4
5
6

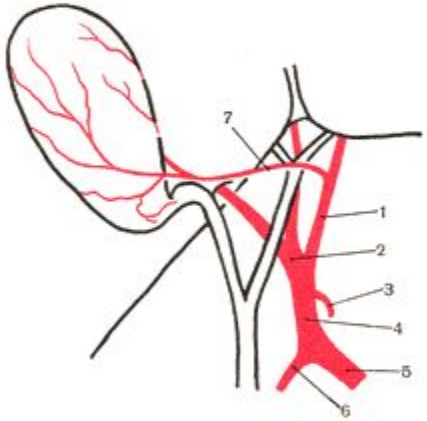
7
1
2
3
4
5
6

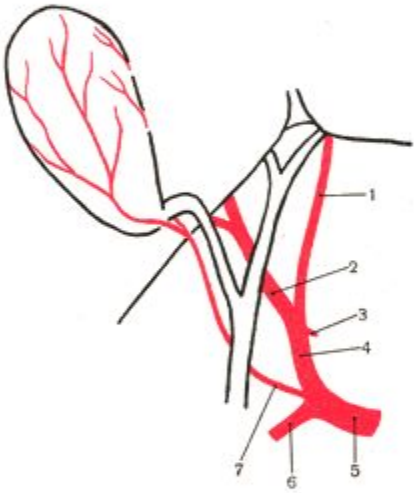
1
2
3
4
7
6
5

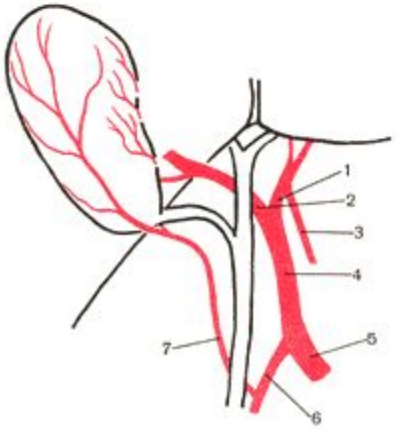
1
2
3
4
7
5
6

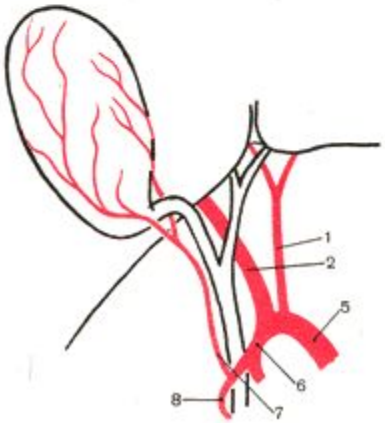
1
2
5
6
8
7

Cholecystectomy

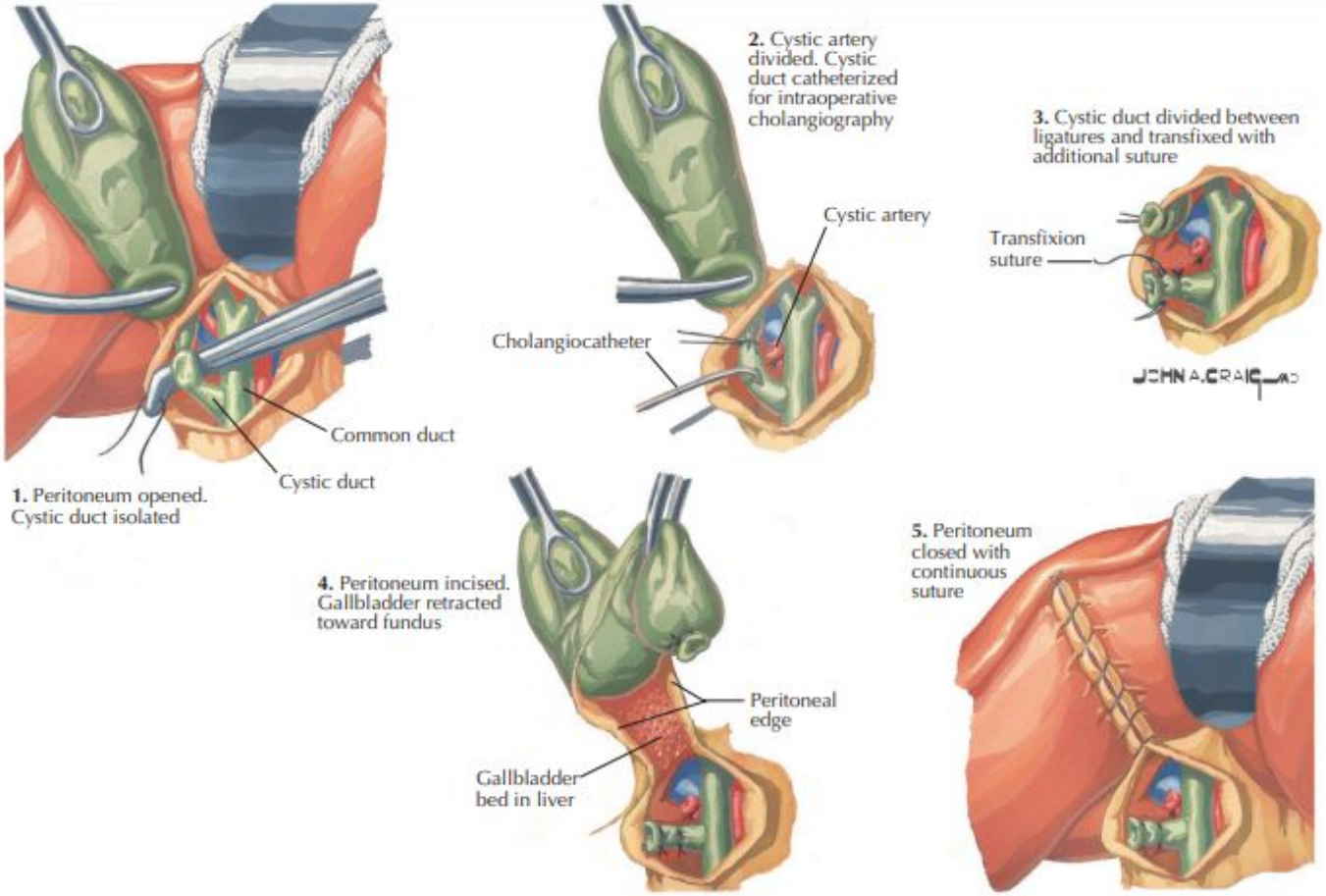

Critical view in open and laparoscopic cholecystectomy

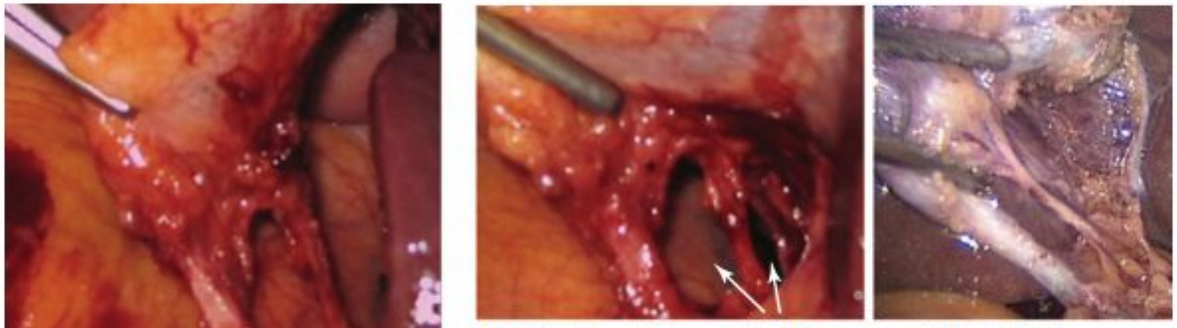

The critical view in laparoscopic cholecystectomy. Although similar retraction is exercised as in an open cholecystectomy (GB is retracted in a cephalad fashion by its fundus while the infundibulum is retracted in a lateral way, opening the critical view), not enough dissection is initially seen between

ЛХЭ

http://pie.med.utoronto.ca/TVASurg/project/standardlapchole/