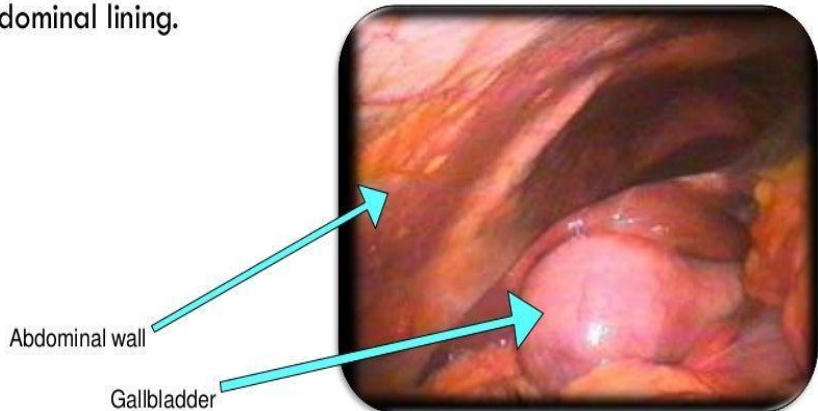


Cholecystitis And Gall bladder Cancer

**Nihar Panchal
Shreyash Tikar
Sem-5 Group-5**

CHOLECYSTITIS

- By definition, **cholecystitis** is an inflammation of the gallbladder wall and nearby abdominal lining.

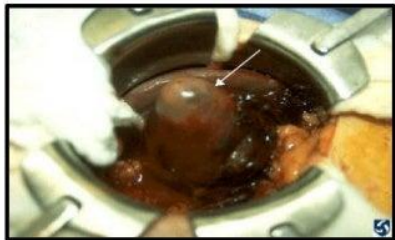

PATHOPHYSIOLOGY

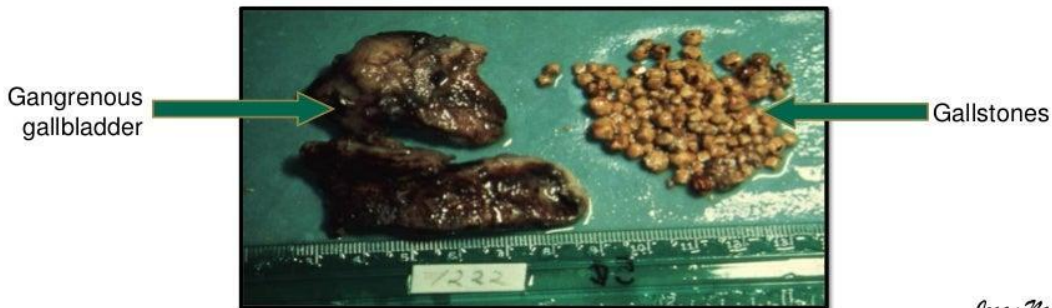
- ❖ Can be caused by an obstruction, gallstone or a tumor.
- ❖ 90% of all cases caused by gallstones.
- ❖ The exact cause of gallstone formation is unknown.
- ❖ When there is an obstruction, gallstone or tumor it prevents bile from leaving the gallbladder.
- ❖ Bile gets trapped and acts as an irritant which causes cellular infiltration within 3 – 4 days

- ❖ This infiltration causes an inflammatory process – the gallbladder becomes enlarged and edematous.
- ❖ Eventually this occlusion along with bile stasis causes the mucosal lining of the gallbladder to become necrotic.
- ❖ Bacterial growth occurs due to ischemia

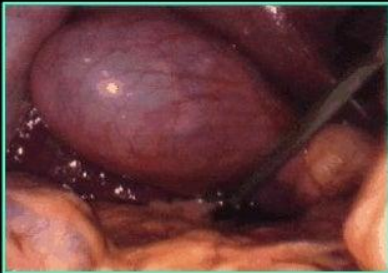NECROTIC GALLBLADDER



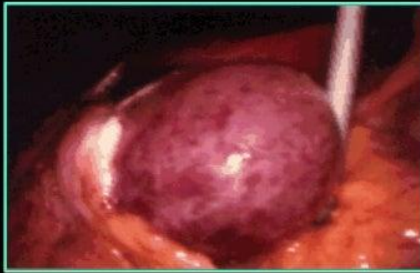
- ❖ Rupture of the gallbladder becomes a danger, along with spread of infection of the hepatic duct and liver.
- ❖ If the disease is severe and interferes with the blood supply it can cause the gallbladder to become gangrenous.



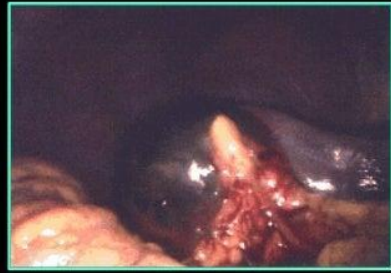STAGES OF ACUTE CHOLECYSTITIS



- ❖ Gallbladder has a grayish appearance & is edematous.
- ❖ There is an obstruction of the cystic duct and the gallbladder begins to swell.
- ❖ It no longer has the "robin egg blue" appearance of a normal gallbladder.



- ❖ As acute cholecystitis progresses, the gallbladder begins to become necrotic and gets a speckled appearance as the wall begins to die.



- ❖ Gallbladder undergoes gangrenous change and the wall becomes very dark green or black.
- ❖ This is the stage when perforation occurs.

Case Summary

- A 40 Year old female presented to OPD SHL on 11th Jan 14, with pain in upper abdomen for 15 days which was acute in onset, progressive, continuous, constricting, moderate to severe, radiating to back side, aggravated by fatty meals and relieved temporarily by medications.
- No h/o fever, vomiting, constipation/diarrhea ,weight loss
- Unremarkable medical and surgical history

- On examination: **RHC was tender with Murphy sign +ve.** Rest of examination unremarkable.
- USG showed **gall stones with no edema and thick GB wall.**
- Serum amylase levels were 26, lipase levels were 11 and total bilirubin was 0.4 . TLC was 11.0

- Patient was admitted and managed on lines of acute cholecystitis
- During her stay in the ward departmental USG showed **cholelithiasis and multiple enlarged lymph nodes in porta hepatis and peripancreatic area** . Patient was sent on leave and advised follow up after CT scan and CA 19-9 report.

Case Summary

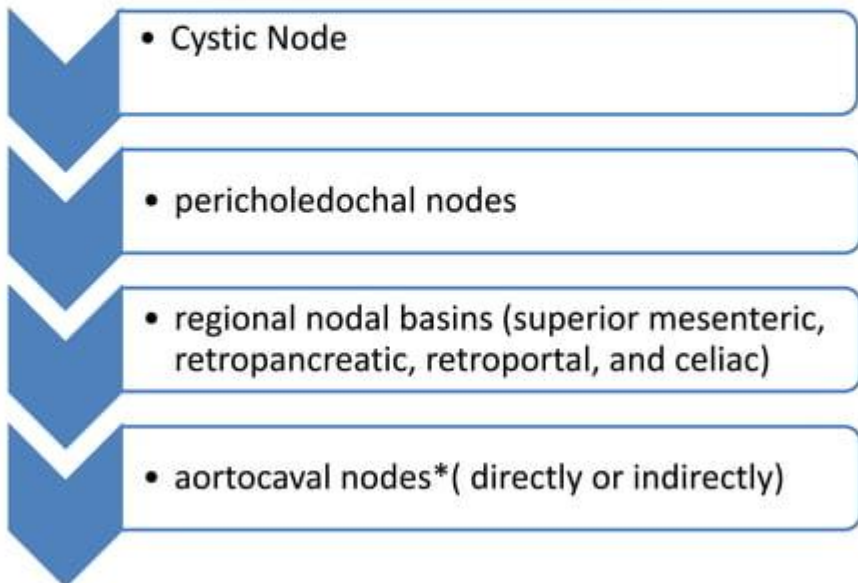
- CT scan(17th Jan 14) showed **multiple enlarged lymph nodes in porta hepatis and both para-aortic planes and pleuropericardial recess. CA19-9 level (24th Jan 2014)were 15.68** (normal range less than 37)
- Patient was re-evaluated and was discharged on conservative treatment
- Patient again presented in ER on 7th Feb 14, with pain RHC and was readmitted for workup
- Serum amylase was 60, total bilirubin was 0.7 ,TLC 10.0
- Repeat USG showed **Multiple Gallstones with soft tissue density mass.** However wall is not thick and no pericholecystic fluid. CHD dilated upto 6mm but distal CBD and intrahepatic duct was not dilated . **Multiple enlarged lymph nodes in para aortic, celiac, peri pancreatic and porta hepatic regions with liver slightly coarse in echo texture.**
- Laparotomy was done on 13th Feb 14 and intraoperatively gall bladder mass was seen infiltrating the liver and GB biopsy was taken, which showed **Poorly Differentiated adenocarcinoma.**

Relevant Anatomy

- Saccular structure located at the inferior surface of the liver, at the division of the right and left lobes, just below segments IV and V
- Composed of 4 areas: fundus, body, infundibulum, and neck
- Approx. 7-10 cm long and about 2.5-3.5 cm wide
- Normally contains approx. 30-50 mL of fluid(max up to 300 mL)

Relevant Anatomy

Lymphatic Drainage



*exposure of this region is a necessary step in the operative staging of gallbladder cancer

Relevant Anatomy

Spread of GB cancer

- spreads via the lymphatic channels and venous drainage
- Peritoneal metastasis common
- Due to adjacent location → liver, bile duct, portal vein, hepatic artery, duodenum, and transverse colon involvement is common

Relevant Anatomy

Cystic Plate*

- It is reflection of the visceral peritoneum between the liver and the gallbladder.
- Dissection between the gallbladder and the liver during cholecystectomy → divides the plane between the cystic plate and the muscle layer of the gallbladder

*anatomic basis for the improved survival in patients undergoing liver resection for T1b gallbladder cancer.

Introduction

- Gallbladder carcinoma was first described by Maximilian Stoll in 1777 and more than 200 years later it is still considered to be a highly malignant disease with a poor survival rate
- G.B cancer is relatively uncommon but it is the 5th most common GIT malignancy(worldwide)
- most frequent malignant tumor of the biliary tract
- 90 % → Adenocarcinomas.
- Mucosal squamous metapalsia → Squamous cell carcinoma

Introduction

Premalignant Lesions

- **Adenomatous polyps**

- Papillary adenomas grow as pedunculated, complex, branching tumors projecting into the gallbladder lumen.
- Tubular adenomas arise as a flat, sessile neoplasm.

- **Adenomyomatosis**

- extensions of Rokitansky-Aschoff sinuses through the muscular wall of the gallbladder
- USG reveals a thickened gallbladder wall with intramural diverticula
- serial evaluation with USG is indicated to rule out enlarging adenomatous polyps and gallbladder cancer

Epidemiology

- incidence of GC → 1 to 23 per 100,000 worldwide
- over the last three decades there is decrease in incidence in developed and increase in incidence in developing countries
- The highest incidence of gallbladder carcinoma is reported more recently from the Indian-Subcontinent including India and Pakistan (18-23/100,000) → mirror image of worldwide distribution of gall stones
- A relatively rare malignancy worldwide but is the second commonest gastrointestinal cancer in Pakistani women
- Most common cause of gastrointestinal cancer related mortality in females in subcontinent.[17,18]

Epidemiology

- Rise in incidence of GC from Northern India and Southern Pakistan over the past two decades
- Frequency of gallbladder cancer in Pakistan varies between 6-7%. [13-15]
- Highest incidence is found in Chelians, American Indian and in parts of Northern India where it accounts for 9% of all biliary tract diseases.
- Female to male ratio is 3:1
- Peak incidence is in 7th decade of life.[2]

Etiology/Pathophysiology

- Gallstones are present in 60-90 % of GB cancer cases (World wide) [3][12].
 - a small proportion of patients (1-3%) with gall stones developed G.B cancer [16,17]
 - inverse relationship between the incidence of GC and rate of cholecystectomy
 - In pakistan 98-100 % of cases of GC have gall stone^{[18][19]}
- Risk factors include
 - Chronic inflammation and infection.
 - Porcelain Gallbladder
 - Typhoid carrier
 - Adenomatous polyp (size of the polyp is strongest predictor of malignant transformation)[3]
 - Advanced age(>55 yr)
 - Multiparity(>5)
 - Presence of gallstone larger than 1^[17]-3^[18]cm.
 - Anomalous pancreatobiliary junction
 - Drugs :OCP, methyl dopa

- Occupational exposure to rubber, cigarette smoking
 - Bile acid composition.
 - Diet: low fibre, low calories. High fine CHO, low protein
-
- A 2008 study found evidence that excess body weight in women, specifically a 5 kg/m² increase in the body-mass index, is strongly associated with an increased risk of gallbladder cancer.[4]
 - Numerous studies have investigated genetic abnormalities in gallbladder cancer and have shown that approximately 39-59% of gallbladder cancers are associated with the *K-ras* mutation, while more than 90% of them are associated with a *p53* mutation.[5]

Presentation

- Usually asymptomatic at the time of diagnosis
- Symptoms if present are similar to benign diseases such as cholecystitis or biliary colic.
- Jaundice and anorexia are late features
- Palpable mass is a late sign[2]
- Given this presentation, less than 50% of gallbladder cancers are diagnosed preoperatively. Many are diagnosed incidentally in gallbladders removed for biliary colic or cholecystitis.

Work Up

- Laboratory studies are generally nonspecific for gallbladder cancer.
- In the later stages, liver function enzyme levels may be slightly elevated. These levels are generally not elevated in stages I and II.
- An elevated bilirubin or alkaline phosphatase level generally indicates advanced or obstructive disease.

Tumour Marker	Sensitivity	Specificity
CA 19-9 *	79.4 %	79.5%
CEA	50 %	93%

*Found in 80% of the cases

Imaging studies

- Ultrasonography is a very useful tool in the workup of gallbladder cancer. Polypoid lesions need to be at least 5 mm in size to be detected by ultrasonography. Cholesterol polyps (benign) generally appear as pedunculated lesions attached to the gallbladder wall.
- Ultrasonographic findings that indicate possible malignancy
 - a thick gallbladder wall,
 - vascular polyp,
 - a mass projecting into the lumen or invading the wall, multiple masses or a fixed mass in the gallbladder,
 - a porcelain gallbladder, and an extracholecystic mass. Invasion of the liver can also be seen on ultrasonograms.

- Computed tomography (CT) scanning and magnetic resonance imaging (MRI) are useful in evaluating the extent of invasion and resectability of gall bladder tumors. CT scan results suggestive of gallbladder cancer include asymmetrical wall thickening or gallbladder mass with or without invasion into the liver.
- CT scanning of the chest, abdomen, and pelvis is a common staging modality that can determine the presence of distant metastases and give reliable information about involvement of other organs and vascular structures.
- Positron emission tomography (PET) scanning has a sensitivity of 75% and a specificity of 88% in gallbladder cancer but is not used routinely.

Diagnostic procedures

- **Percutaneous CT scan – guided biopsy** is avoided in patients considered resectable based on preoperative imaging. Because of the substantial risk of peritoneal seeding, percutaneous biopsy and diagnostic cholecystectomy are not necessary in the patient suspected of having gallbladder cancer. In these patients, exploration with curative intent is planned based on preoperative imaging alone.
- **Percutaneous CT scan – guided biopsy** is a useful diagnostic tool in patients who appear to have a nonresectable tumor. Tissue diagnosis is necessary for palliative treatment.
- **Endoscopic ultrasonography with fine-needle aspiration Biopsy** can be used to evaluate for peripancreatic and periportal lymphadenopathy.

Staging

- The American Joint Committee on Cancer (AJCC) has designated staging by the TNM (primary tumor, regional lymph nodes, distant metastasis) classification as follows ^[6]

- **TNM Definitions**

- **Primary tumor (T)**

- TX - Primary tumor cannot be assessed
- T0 - No evidence of primary tumor
- Tis - Carcinoma *in situ*
- T1 - Tumor invades lamina propria or muscle layer . T1a - Tumor invades lamina propria
- T1b - Tumor invades the muscularis
- T2 - Tumor invades the perimuscular connective tissue; no extension beyond the serosa or into the liver
- T3 - Tumor perforates the serosa (visceral peritoneum) and/or directly invades the liver and/or 1 other adjacent organ or structure, such as the stomach, duodenum, colon, pancreas, omentum, or extrahepatic bile ducts
- T4 - Tumor invades the main portal vein or hepatic artery or invades multiple extrahepatic organs or structures

- **Regional lymph nodes (N)**

- NX - Regional lymph nodes cannot be assessed
- N0 - No regional lymph node metastasis
- N1 - Portal lymph node metastasis
- N2 - Distant lymph node metastasis such as periaortic, pericaval, superior mesenteric artery, or celiac artery

- **Distant metastasis (M)**

- MX - Distant metastasis cannot be assessed
- M0 - No distant metastasis
- M1 - Distant metastasis

Non surgical Management

- Small gallbladder tumors are common and many can be safely followed with serial ultrasonographic examination. It is generally thought that polyps of less than 1 cm are safe to follow, although a study^[7] has recommended that polyps that are greater than or equal to 6 mm should be considered for cholecystectomy.
- Chemotherapy is used in the adjuvant and palliative treatment of gallbladder cancer. Phase II studies have shown that the use of single-agent chemotherapy (with gemcitabine or 5-fluorouracil) in the palliative setting can be beneficial.
- Combination chemotherapy also has been shown to be beneficial and is usually based on gemcitabine, capecitabine, and 5-fluorouracil used in combination with cis-platinum or oxaliplatin. Fluoropyrimidine-based chemoradiotherapy is commonly employed in the palliative and adjuvant setting as well.

Surgical management

- **Cholecystectomy** recommended in
 - polyps larger than 1 cm or with polyps in the setting of primary sclerosing cholangitis
 - porcelain gallbladder.[2]
- **Diagnostic Laparoscopy**
 - In order to exclude the presence of undetected intra-abdominal metastases prior to curative laparotomy.
 - Surgery is contraindicated in the presence of distant metastases.
- **Exploratory Laparotomy**
 - The initial exploration focuses on the presence of metastatic disease that was not detected by preoperative imaging and staging laparoscopy.(15%)
 - In view of North American surgeons Biopsy-proven metastases in the celiac nodes preclude resection.
 - Aortocaval nodal metastases are considered distant metastatic disease.

STAGE	TREATMENT
T1a	Simple cholecystectomy
T1b or deeper	Hepatic resection + lymph node dissection (portal , peripancreatic , and retroduodenal)+ Resection of liver segments IVb and V +/- extended liver resection and/or bile duct resection

- Surgical exploration
 - will determine the need to resect other organs that may be involved, such as the stomach, duodenum, and colon.
 - It may be difficult to distinguish scar from malignancy. In these cases, suspicious tissue should be treated as malignancy in order to improve the chances of a margin-negative resection.
 - If tumor is suspected on the bile duct based on a previous pathology report or operative exploration, the presence of tumor on the right hepatic duct must be evaluated.
 - Suspicion of tumorous involvement of the right hepatic duct will require an extended right hepatectomy, excision of the extrahepatic biliary tree, and Roux-en-Y hepaticojejunostomy to the left hepatic duct.
- A recent study indicates that accurate staging requires examination of at least 6 lymph nodes.

Complications

- The overall complication and morbidity rate is approximately 25%.
- Complications are similar to those experienced with cholecystectomy and include infection, hematoma, and bile leaks.
- Complication rates are higher in patients undergoing more extensive resections.
- Liver failure can occur following extended hepatectomy, especially if jaundice is present preoperatively.

THANK
YOU

