

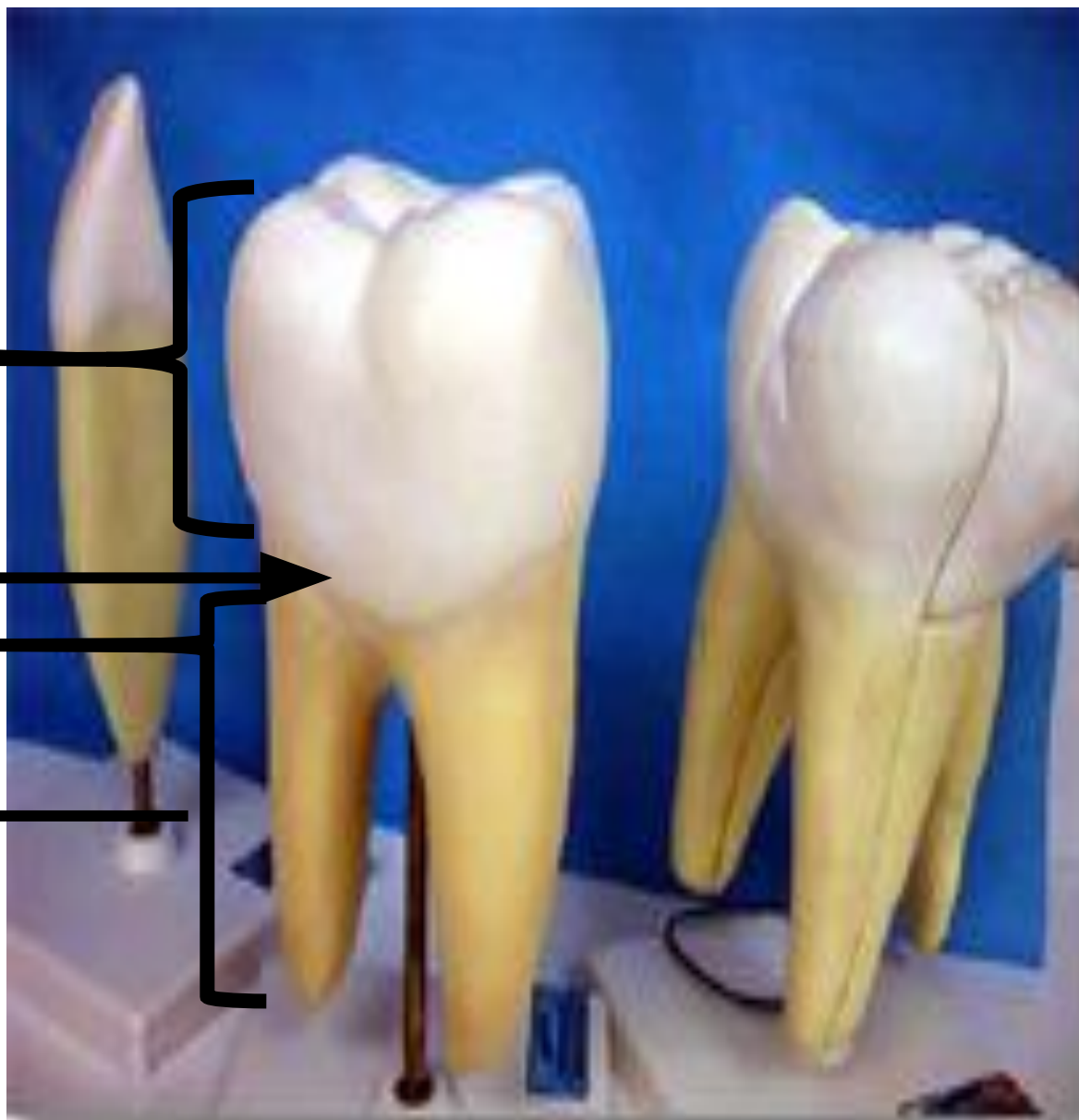DINȚII

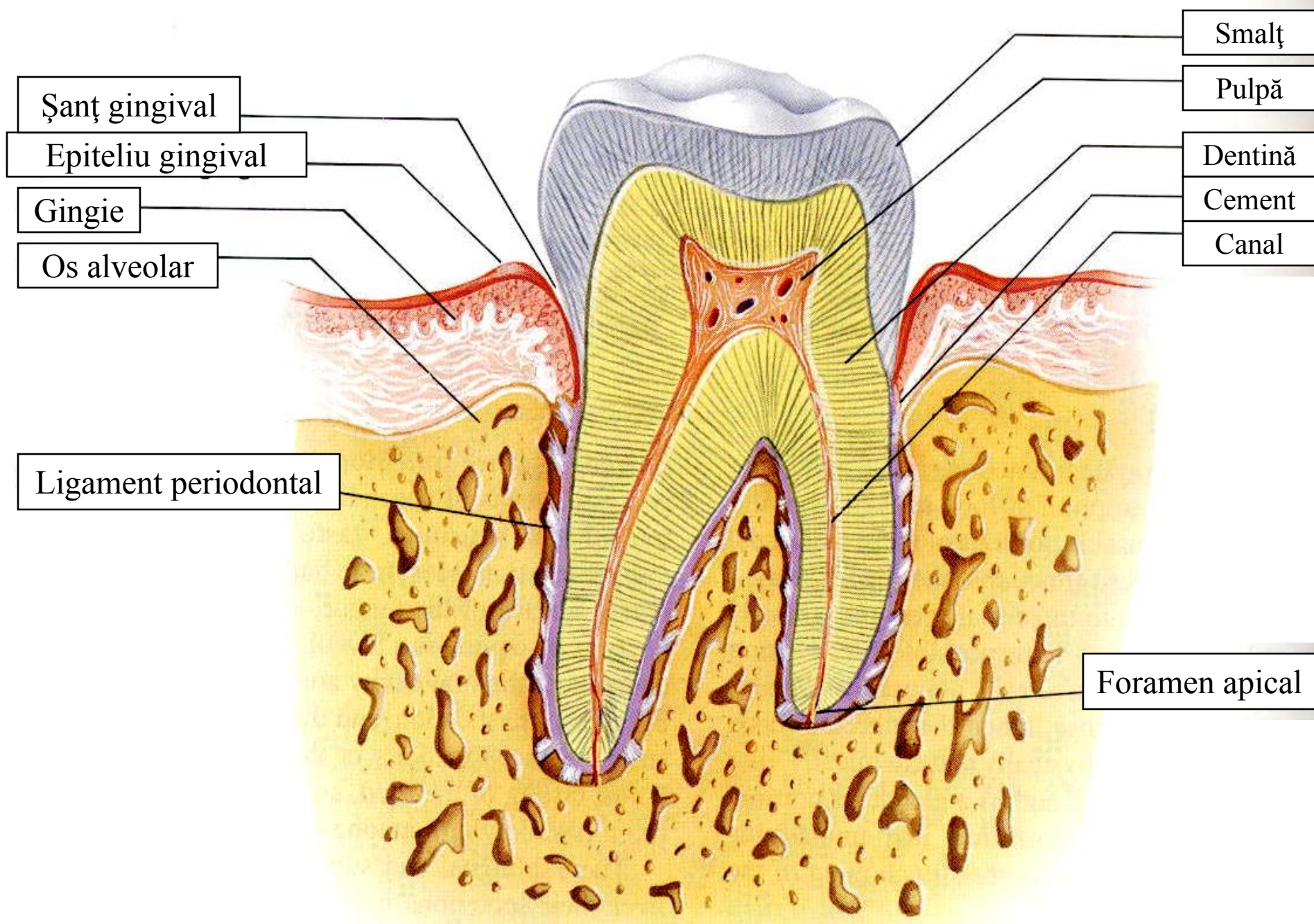
și structurile asociate

COROANA

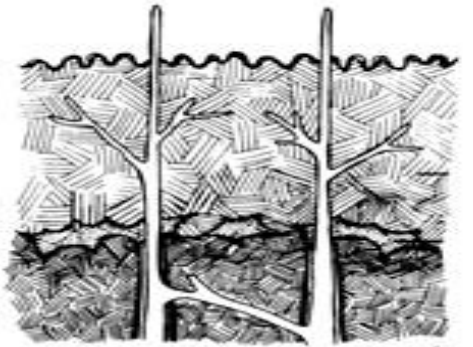
COLETUL

RĂDĂCINA





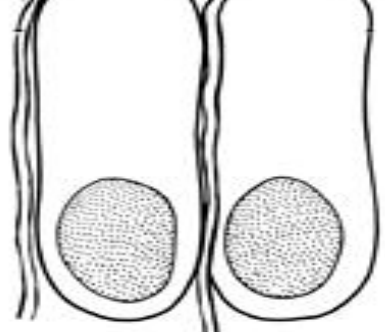
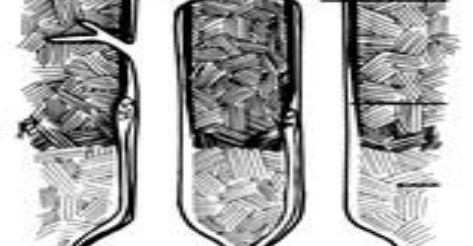Dentina
manta



Dentina
circumpul
pară



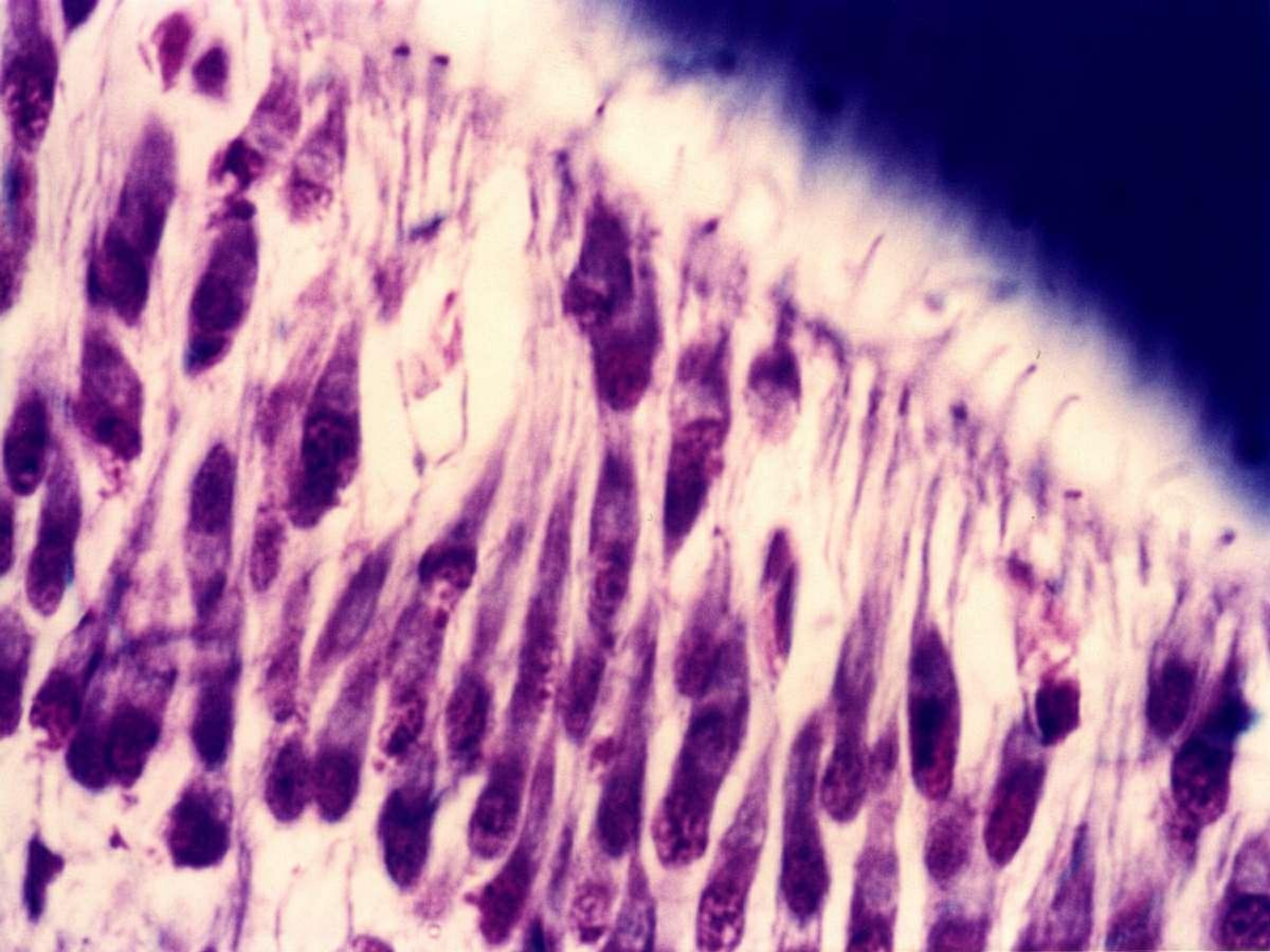
Pre-dentina

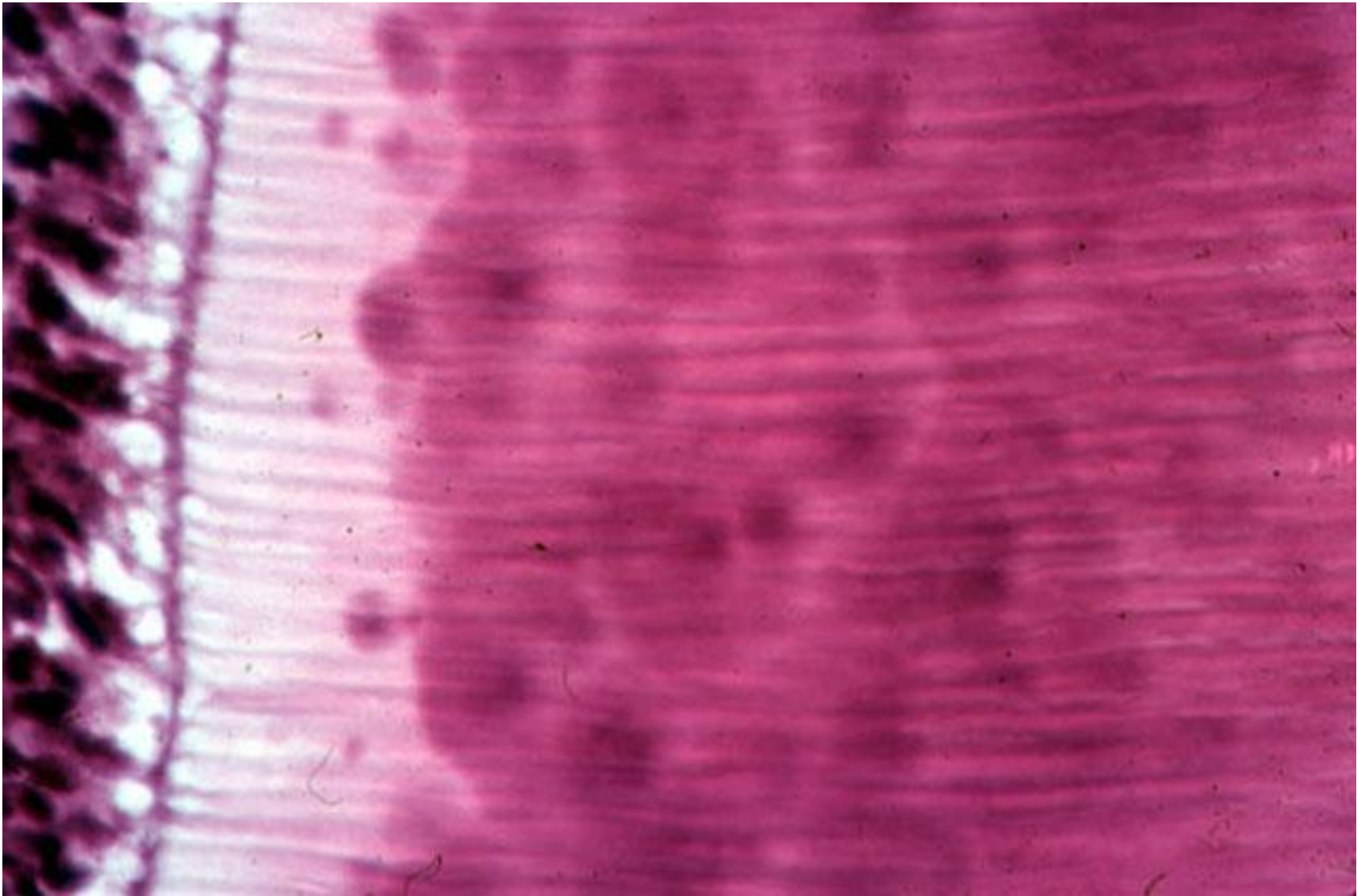


Prelungirea
TOMES

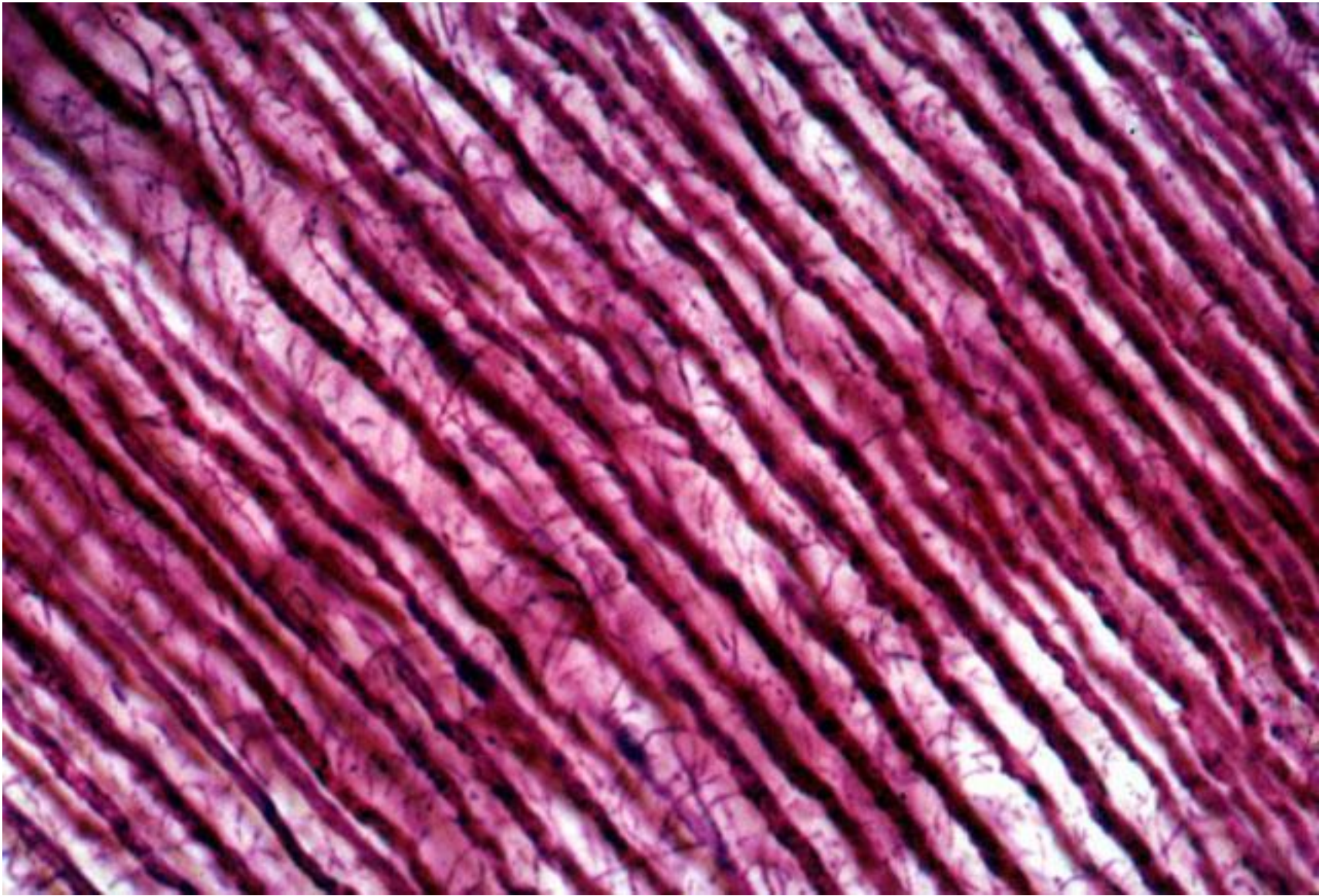
ODONTOBLASTUL

Corpul
celulei



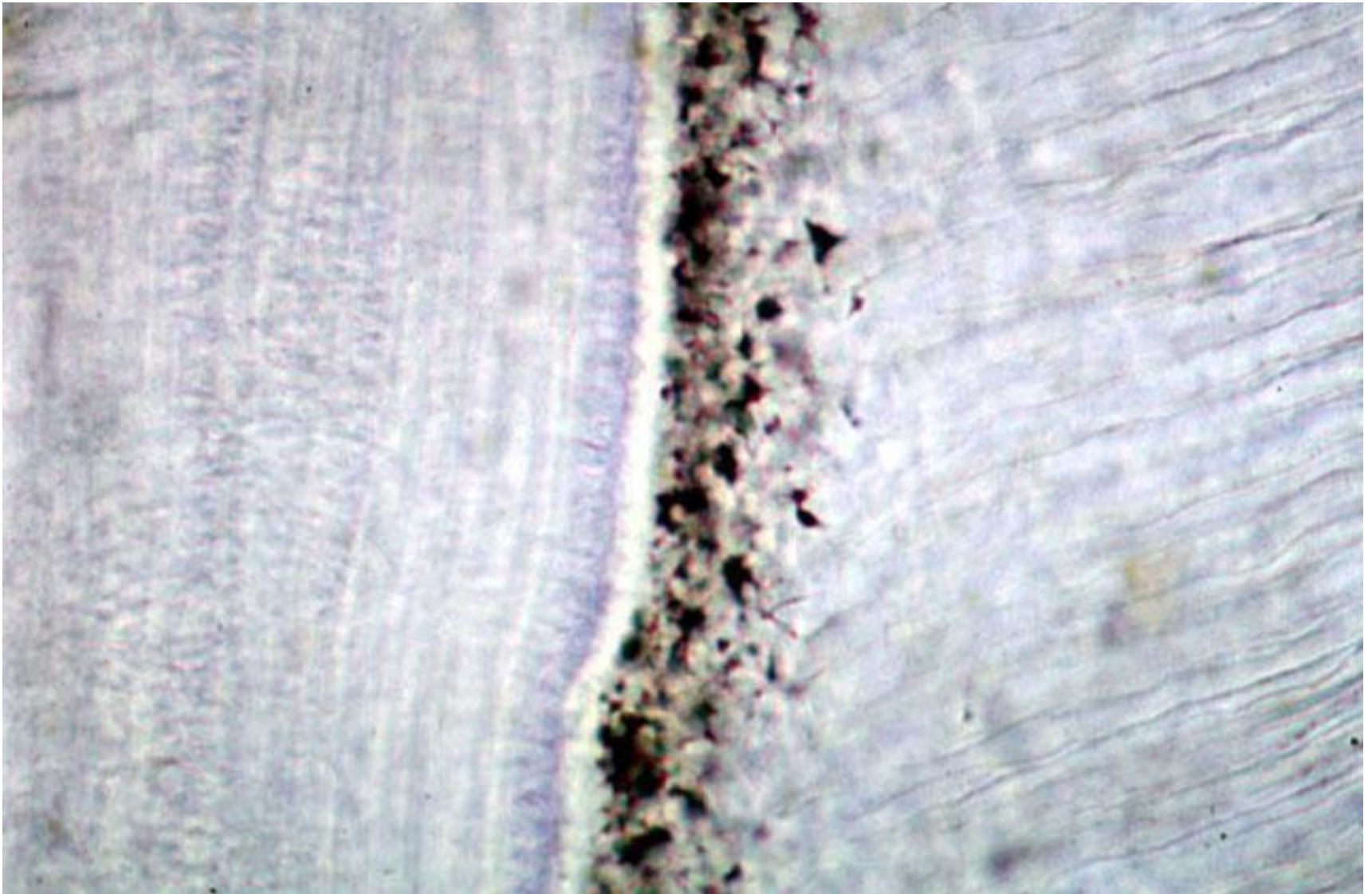


Odontoblaste, predentina, prelungirile odontoblastice Tomes, calcosferiți





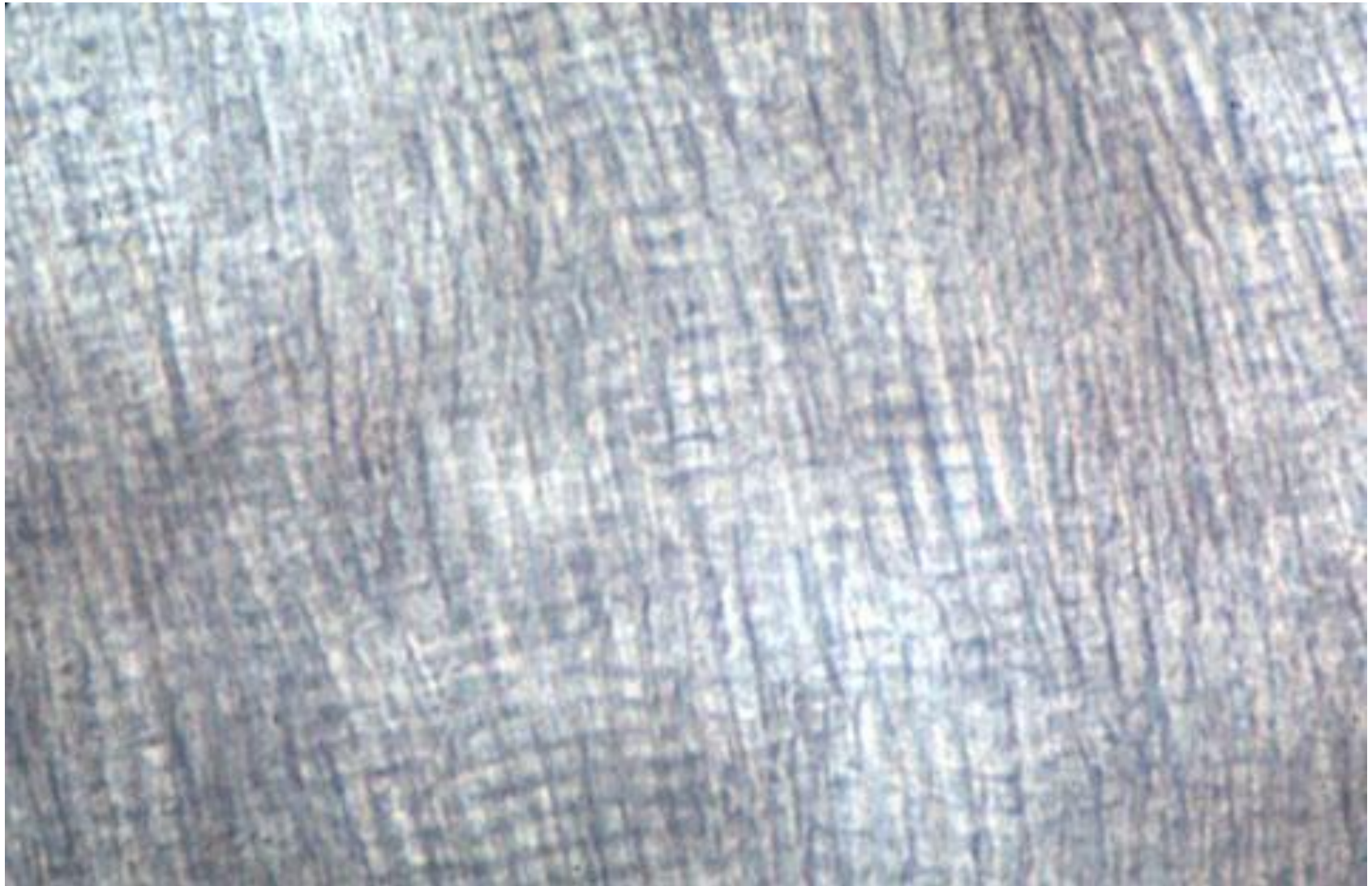
Secțiune transversală a tubulilor dentinali. Hematox.-Eoz.



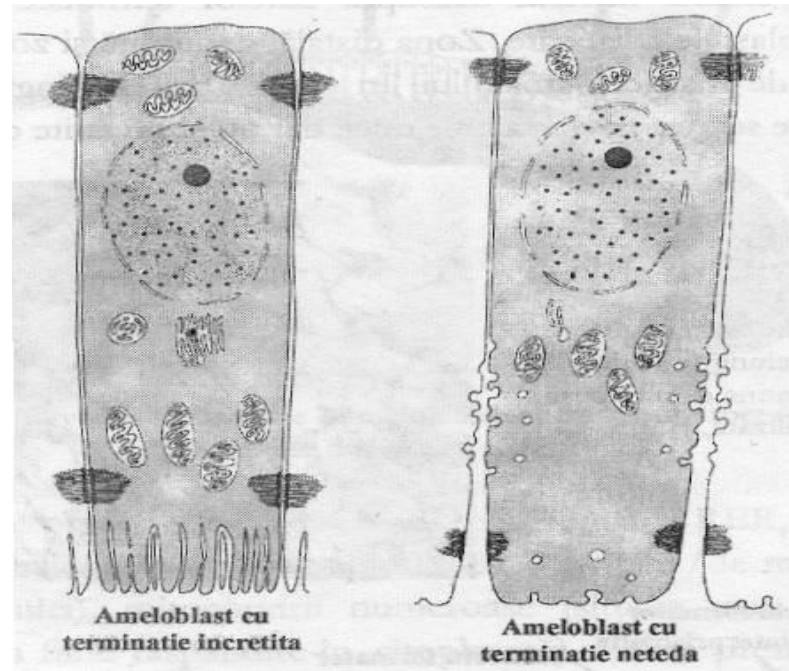
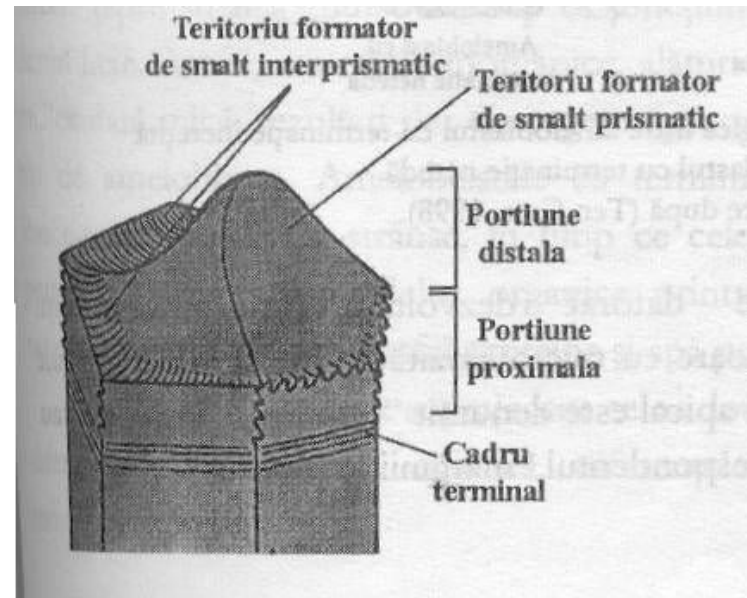
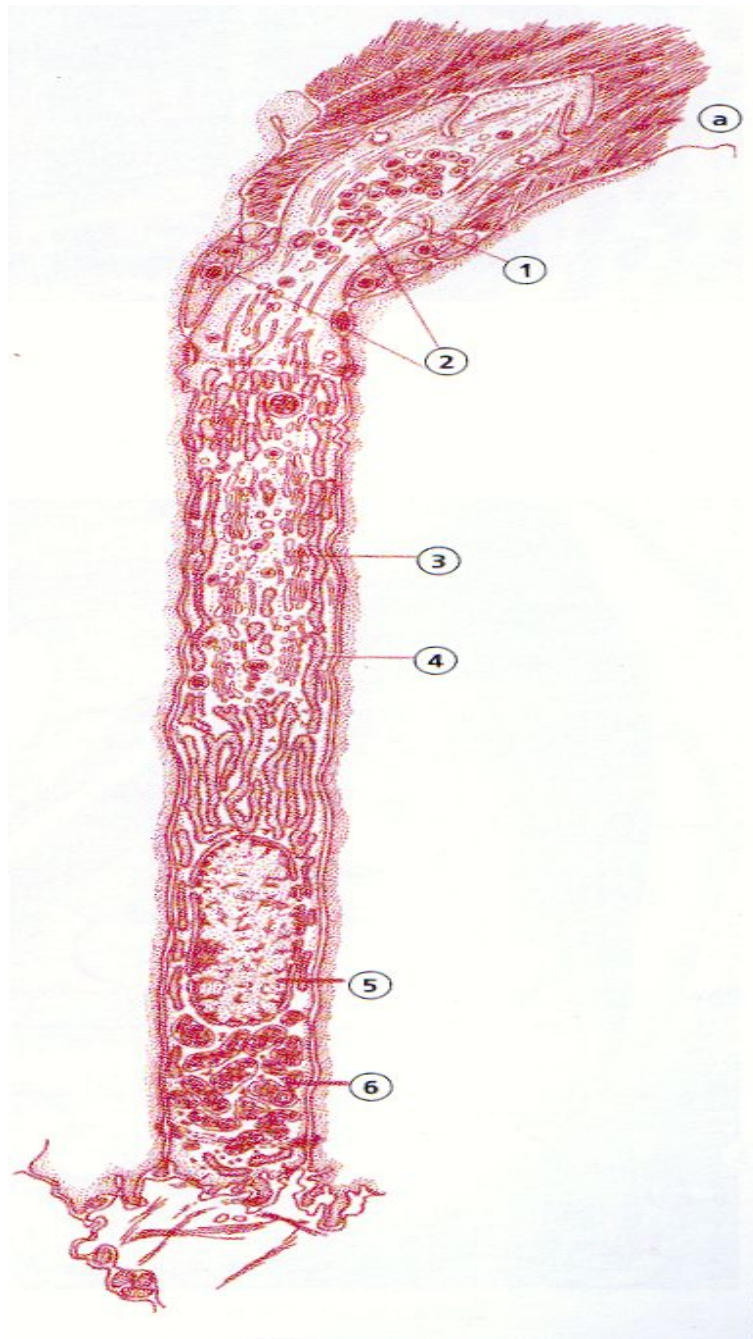
Dentina radiculară. Stratul granular Tomes.



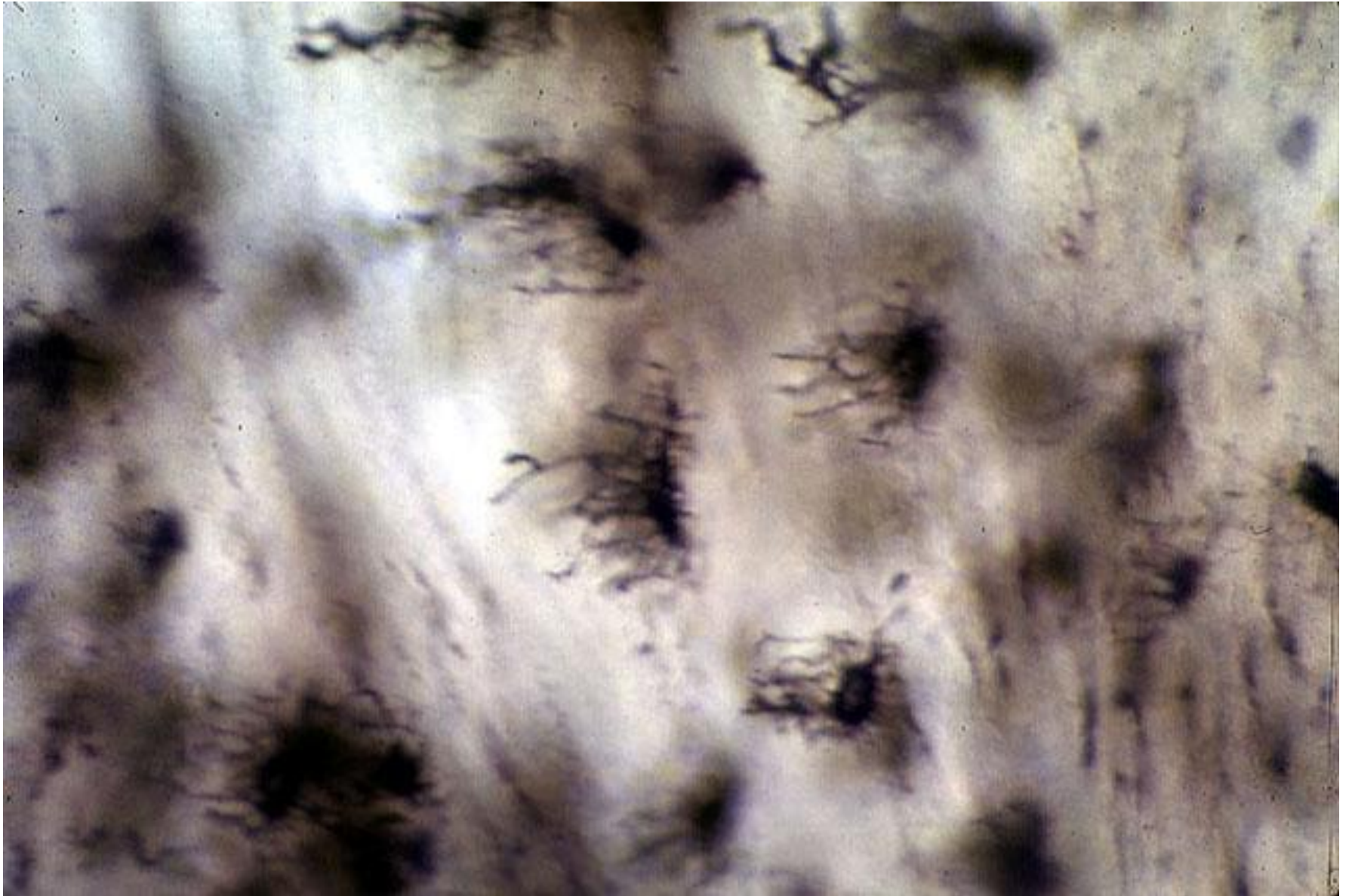
Smalt – imagine de ansamblu



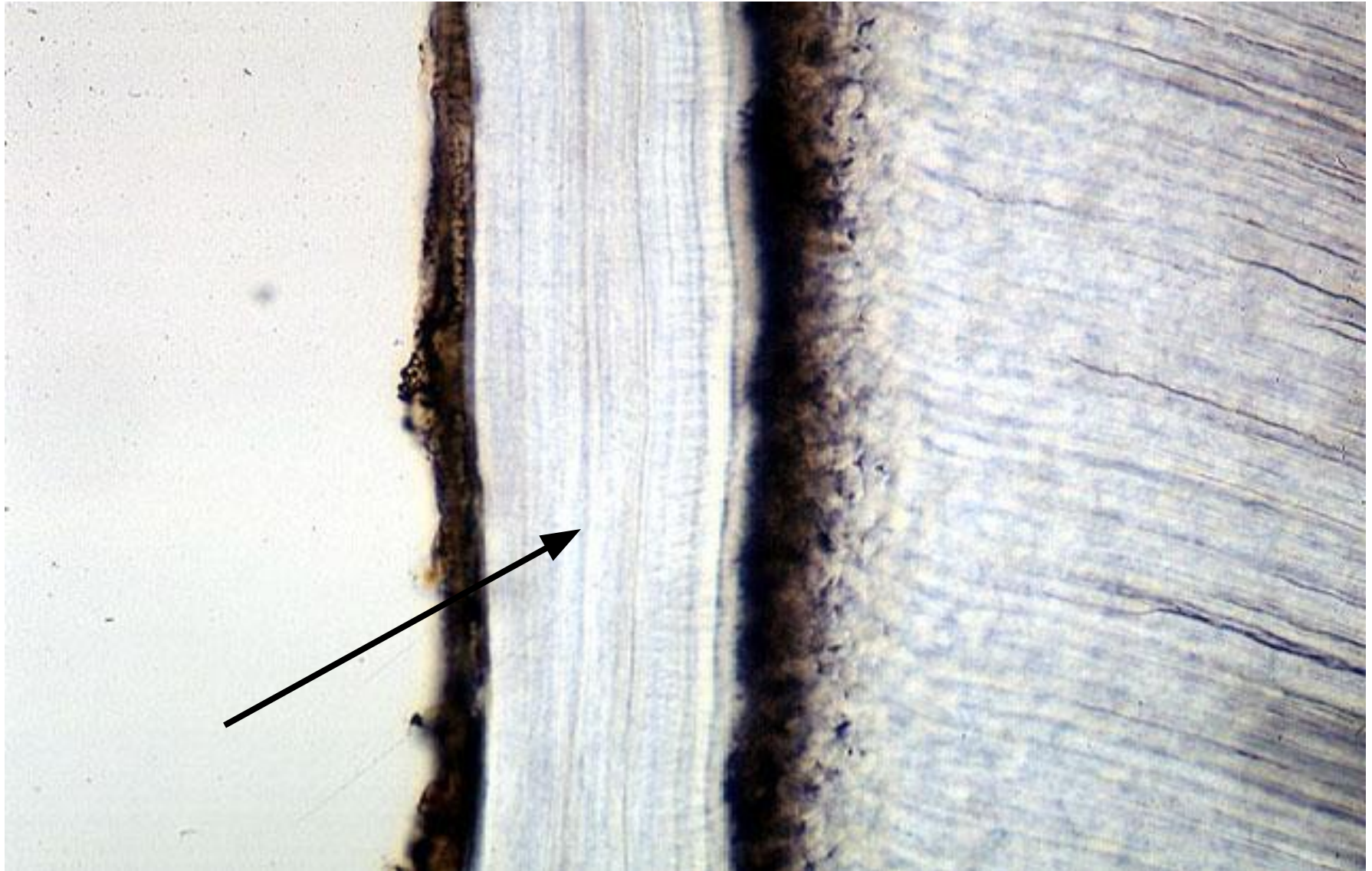
Striațiile prismelor smalțiene



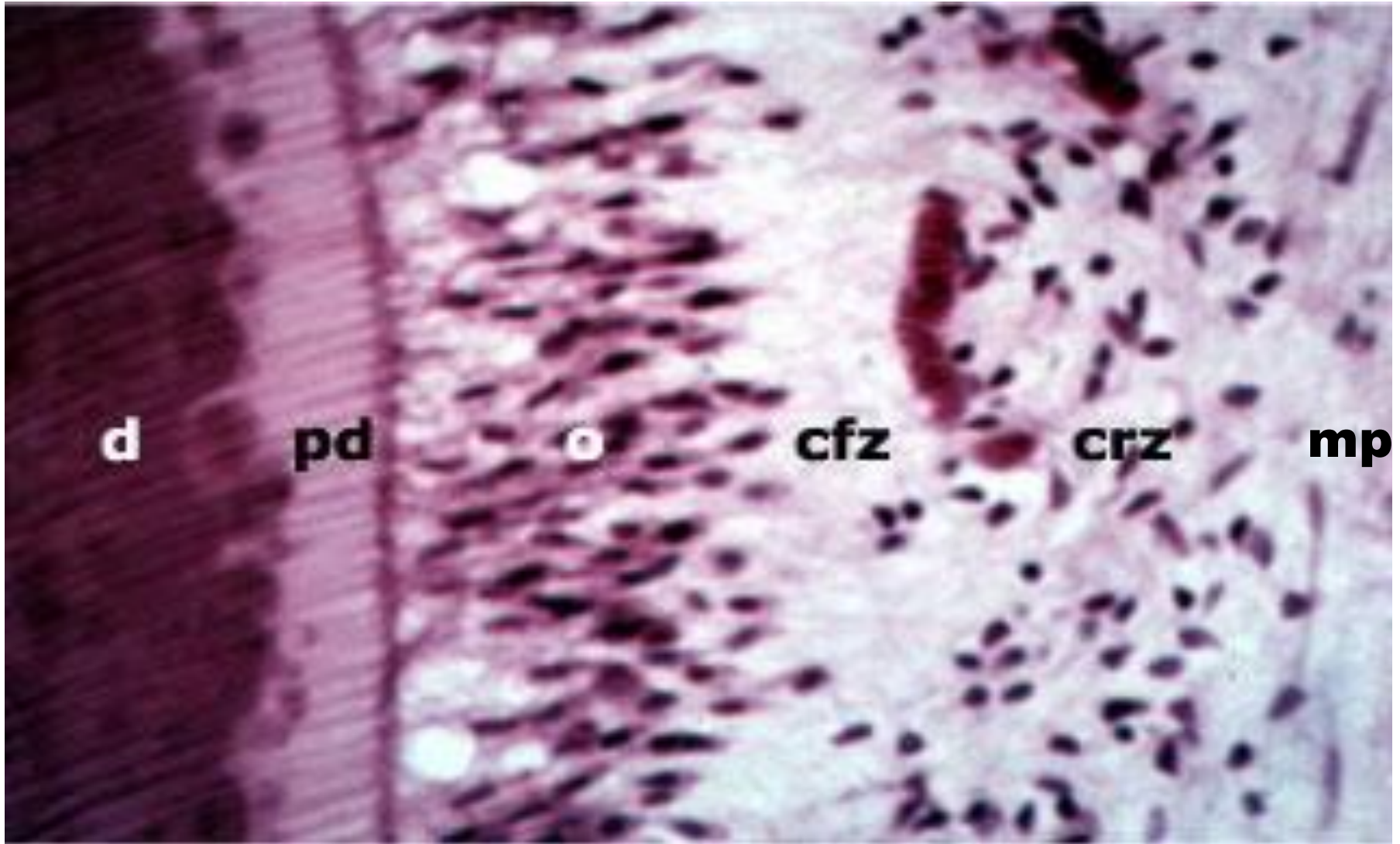
CEMENTUL CELULAR



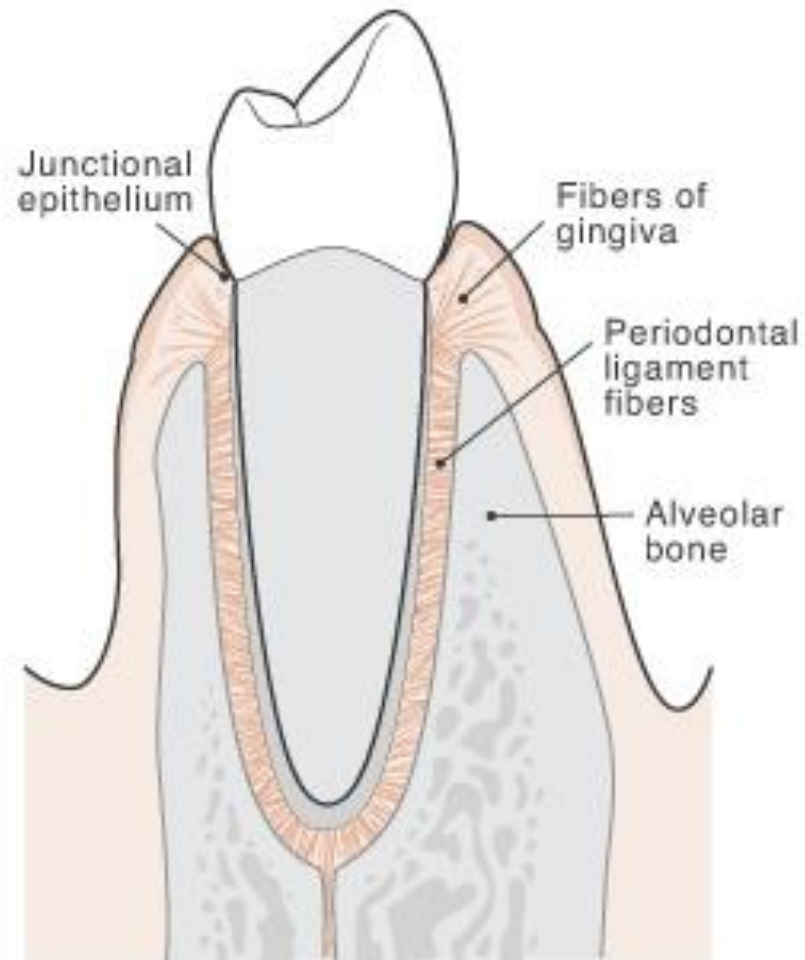
CEMENTUL ACELULAR



PULPA DENTARĂ



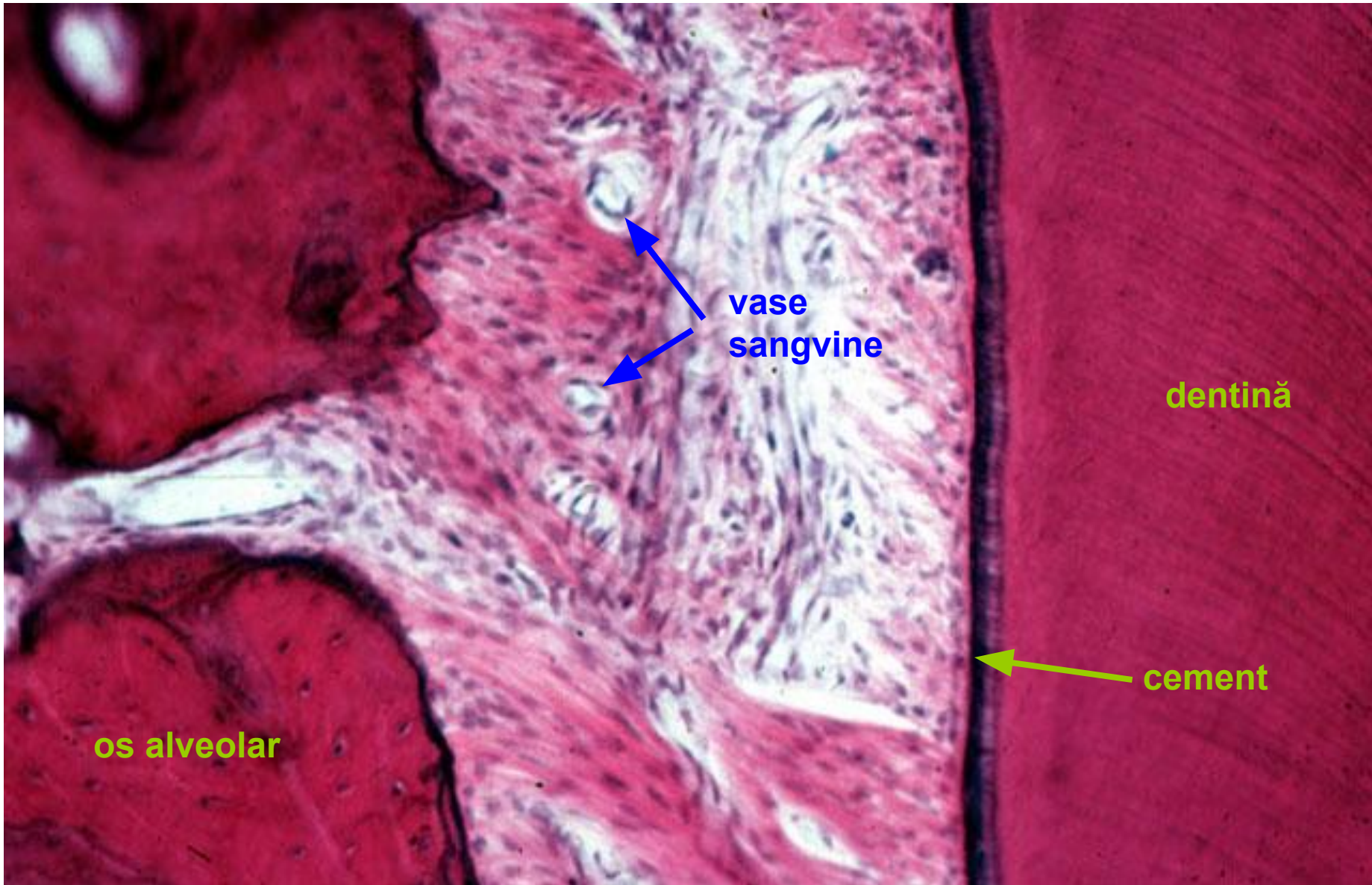d-dentina; **pd**-predentina; **o**-zona odontoblastică; **cfz**-zona acelulară Weil; **crz**-zona bogat celulară; **mp**-miezul pulpei



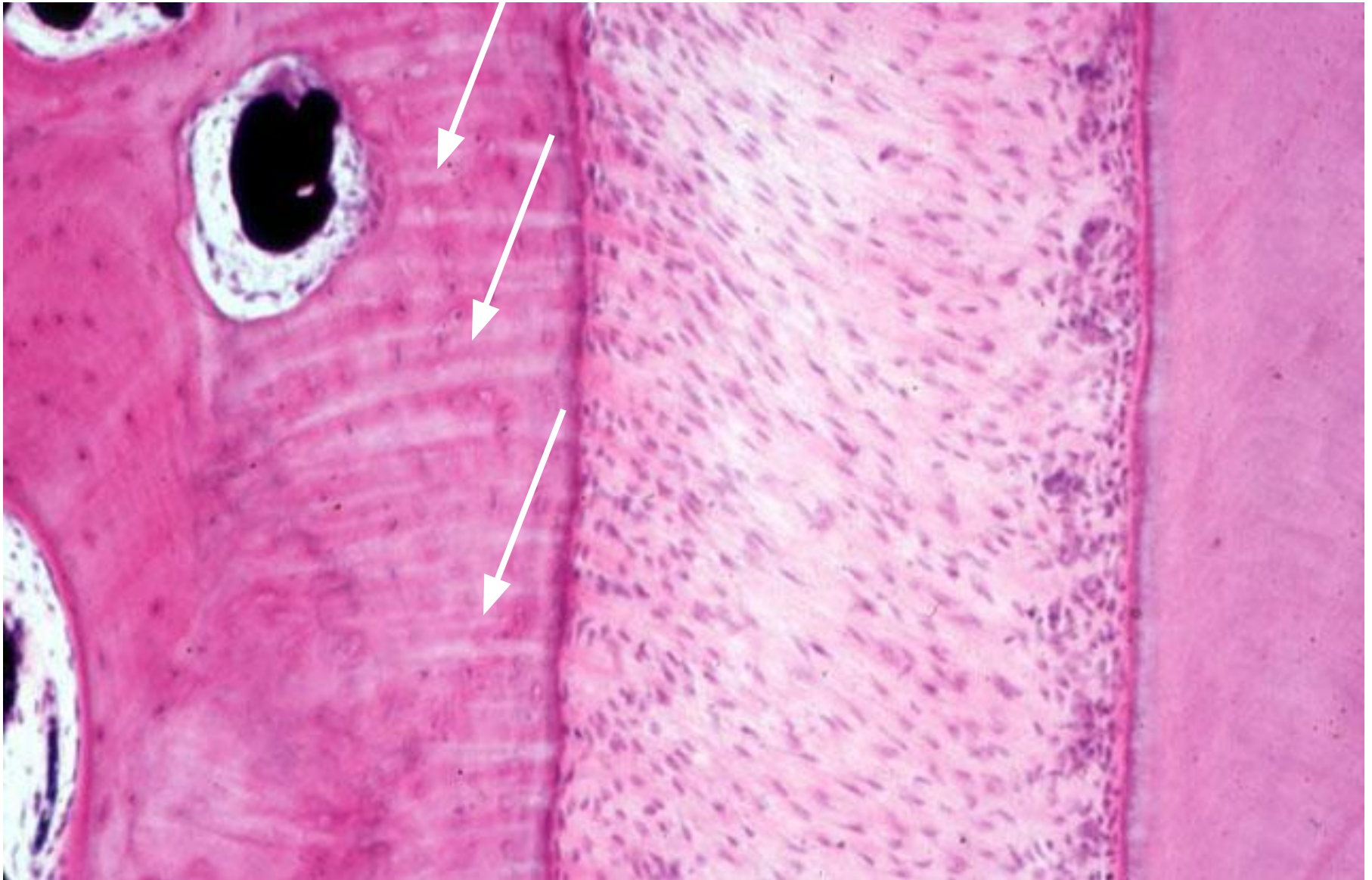
00000 0000000 00000 000 0000000 000 000 000 00000 00000

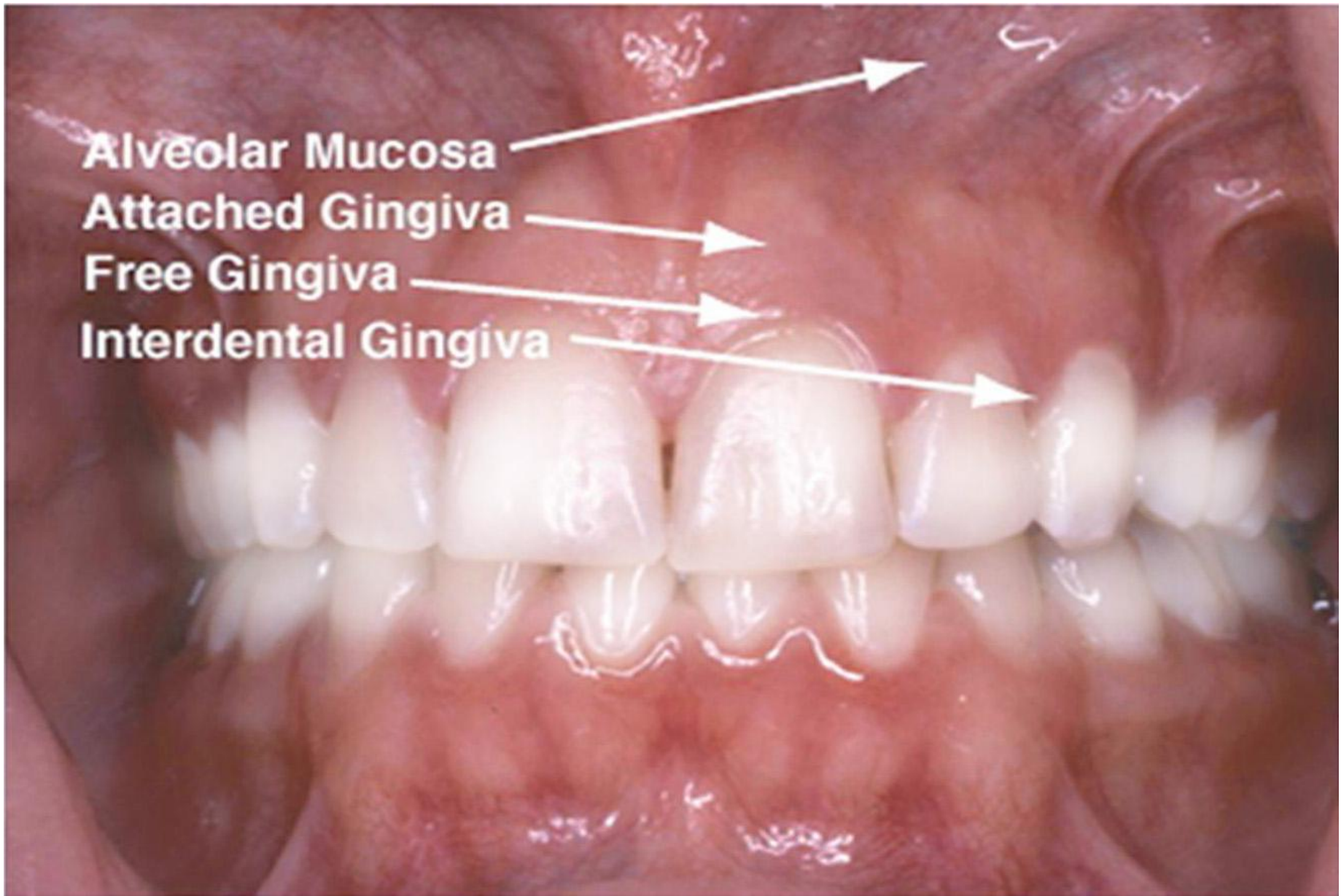PERIODONȚIUL

Periodonțiul



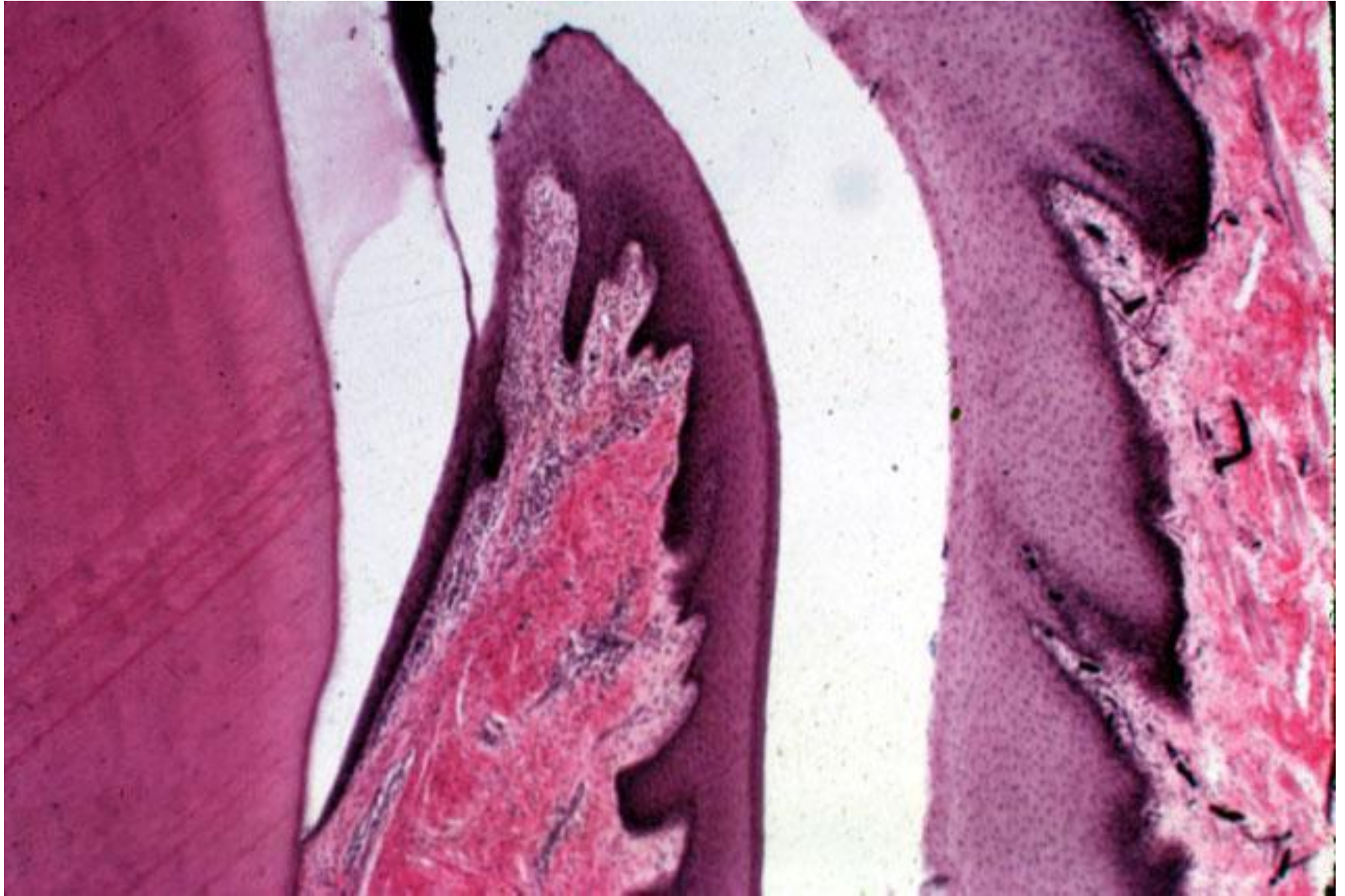
Fibrele Sharpey



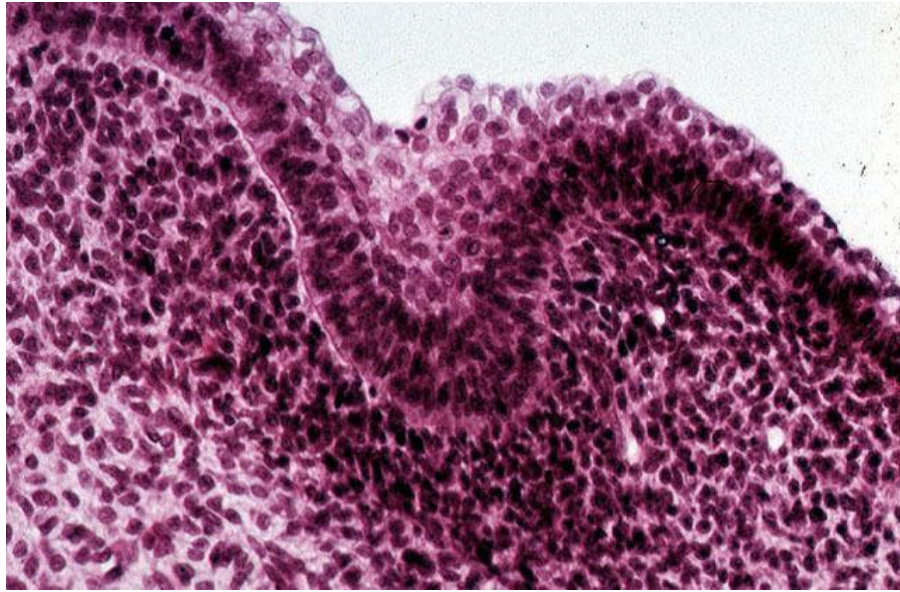


ZONELE GINGIEI

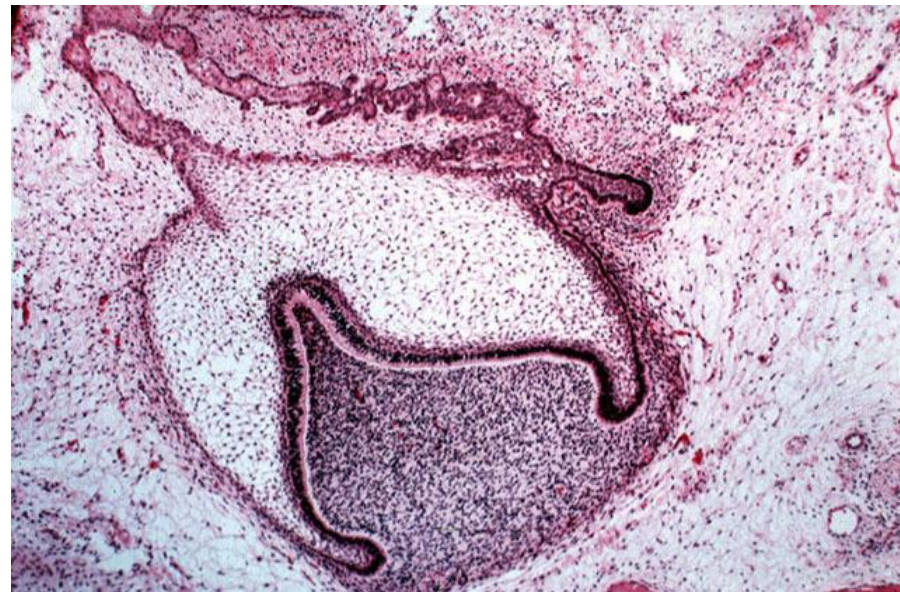Mucoasa Labială și Mucoasa Gingivală



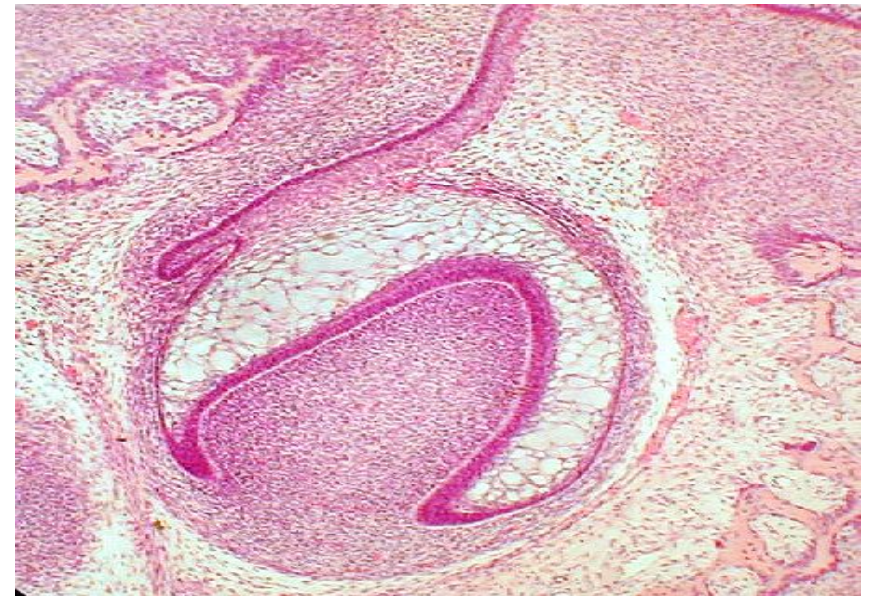MUGURE DENTAR



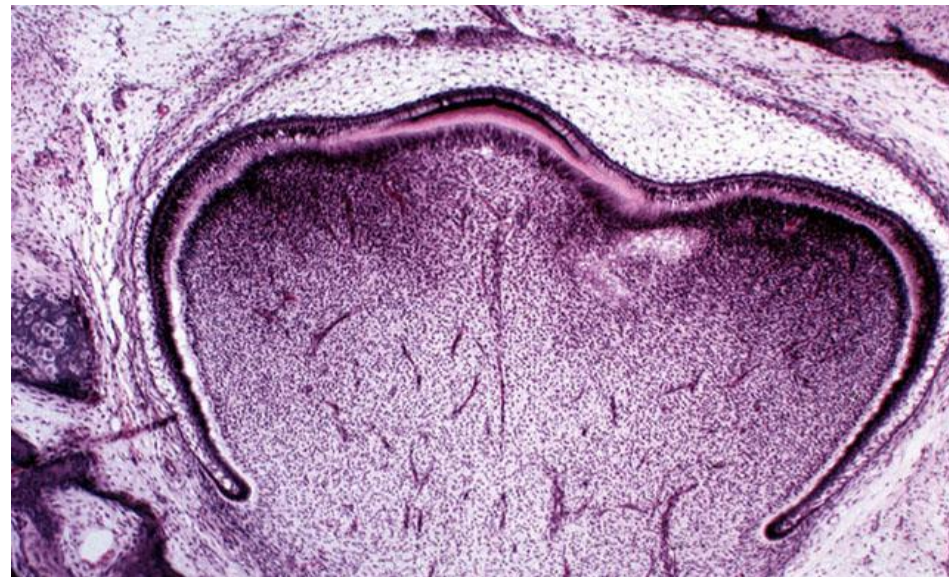
Stadiul de CLOPOT



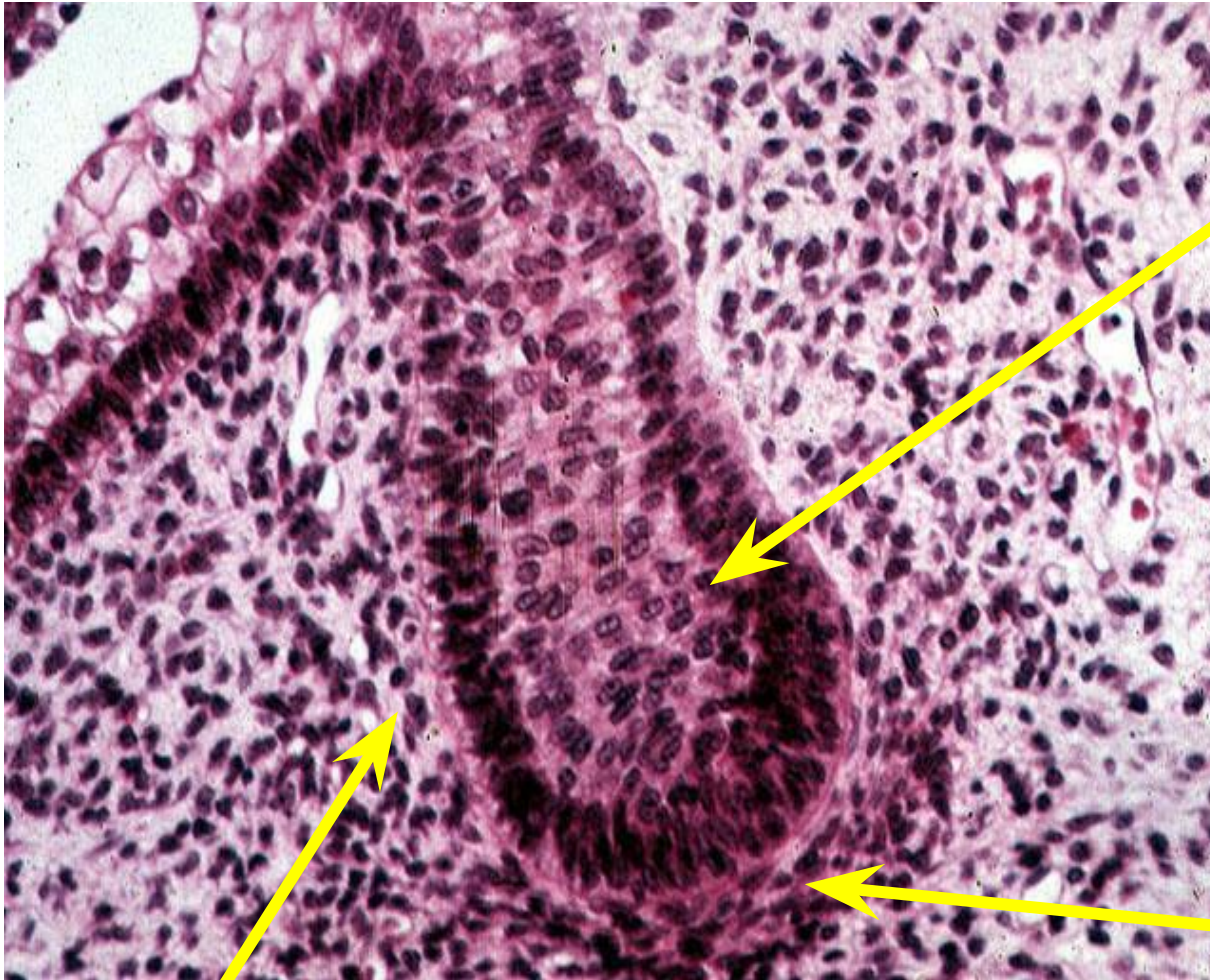
Stadiul de CAPISON



Finalizarea FORMĂRII COROANEI



MUGURE DENTAR



Mugurele dentar

- viitorul organ –
al smalțului

Celulele ectomezenchimale

- viitorul sac dentar -

**Celulele
ectomezenchimale**

– viitoarea papilă -
dentară







