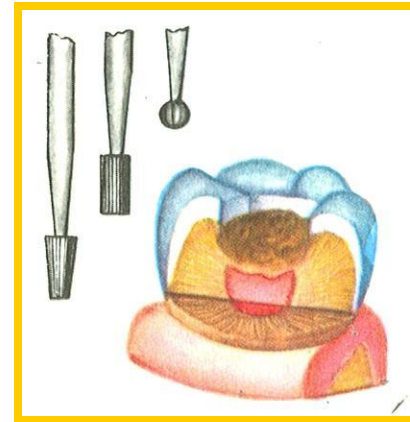
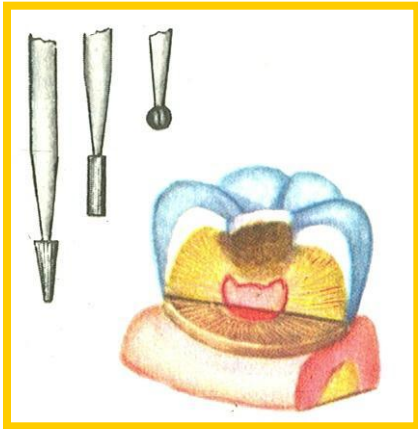


PREPARATION OF PRIMARY AND PERMANENT TEETH IN CHILDREN

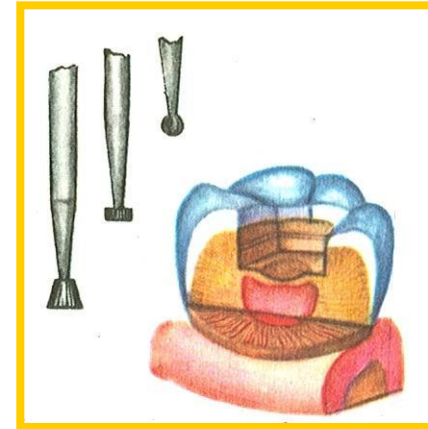
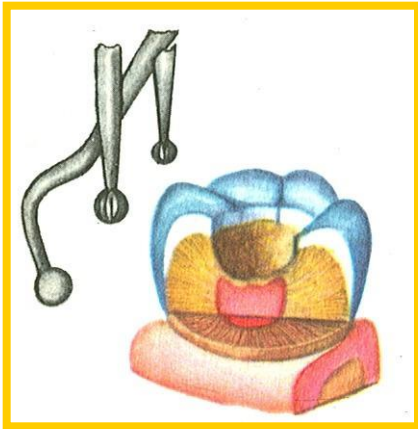
General

1. Opening (different size)

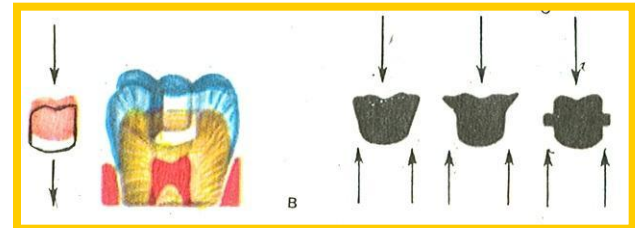
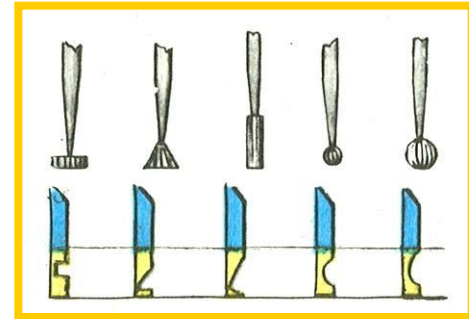
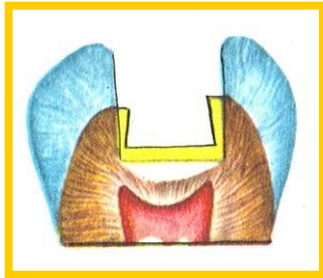


1.Necroectomy

2.Formation the cavity

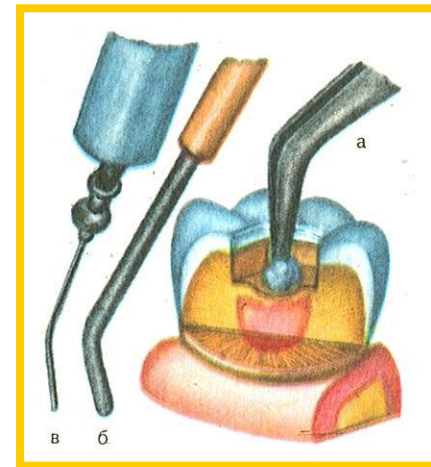
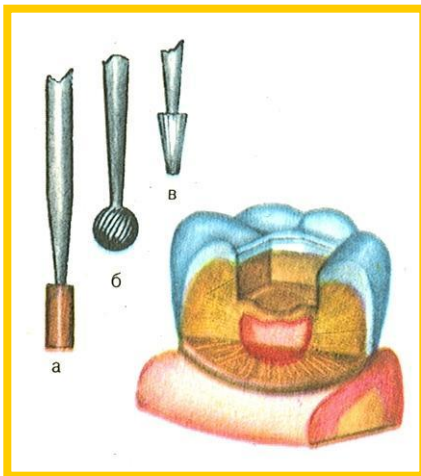


Forming the different shapes

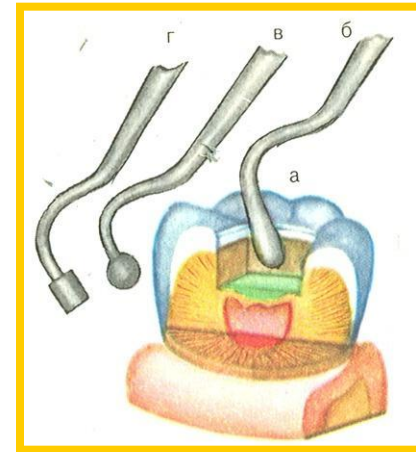
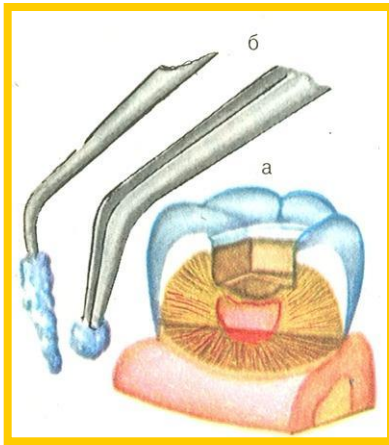


1. Cutting the enamel

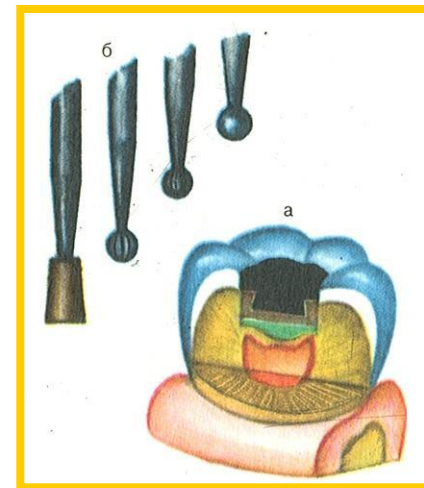
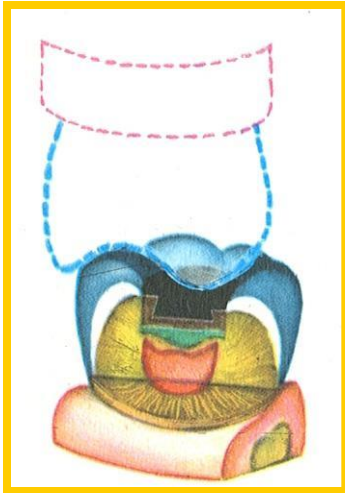
2. Medical cleaning



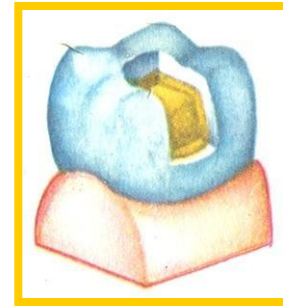
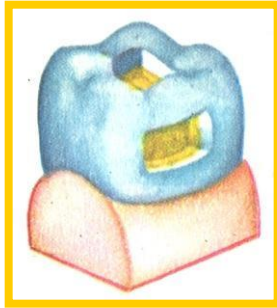
1. Chemical cleaning
2. Covering the pulp



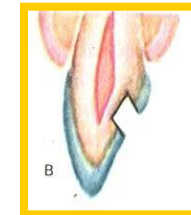

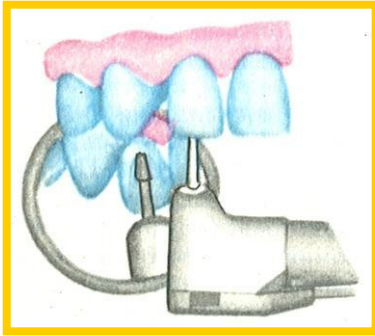
Forming the occlusion shape



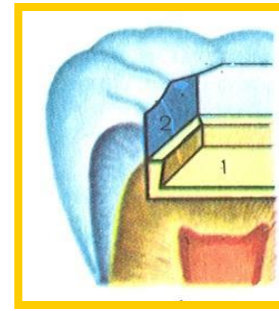
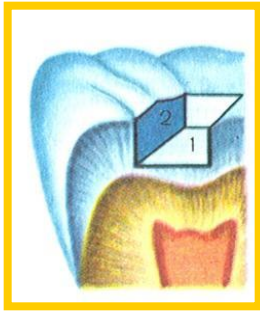
Different types of preparation



Access to the frontal tooth

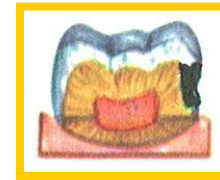
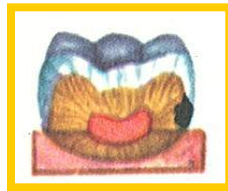


- 1.The form of Cavite 1-st class
- 2.Form of the flow (isolation layer)



Decay in the cervical area

Decay in the oprocsimal area



Stars te

