

Penetrating Neck Trauma

Rambam Medical Center

Dr Nordkin Dmitri

Introduction

- 5-10% of all trauma
- Overall mortality rate as high as 11%
- Major vessel injury fatal in 65%, including prehospital deaths
- Attending physician must have excellent knowledge of anatomy

Historical Perspective/ pre WW I

- Ligation of the major vessels described as early as 1522 by Ambrose Pare
- Ligation was the procedure of choice for vascular injury through WW 1
- Associated mortality rates up to 60%
- Significant neurologic impairment in 30 %

Historical / post WW II

- Mandatory exploration of all penetrating neck wounds, through the platysma
- Fogelman and Stewart reported Parkland Memorial Hospital experience of early, mandatory exploration with mortality of 65 vs.. 35% for delayed exploration
- 40% to 60% rate of negative explorations with mandatory exploration
- Present mortality for civilian wounds is 4% to 6%

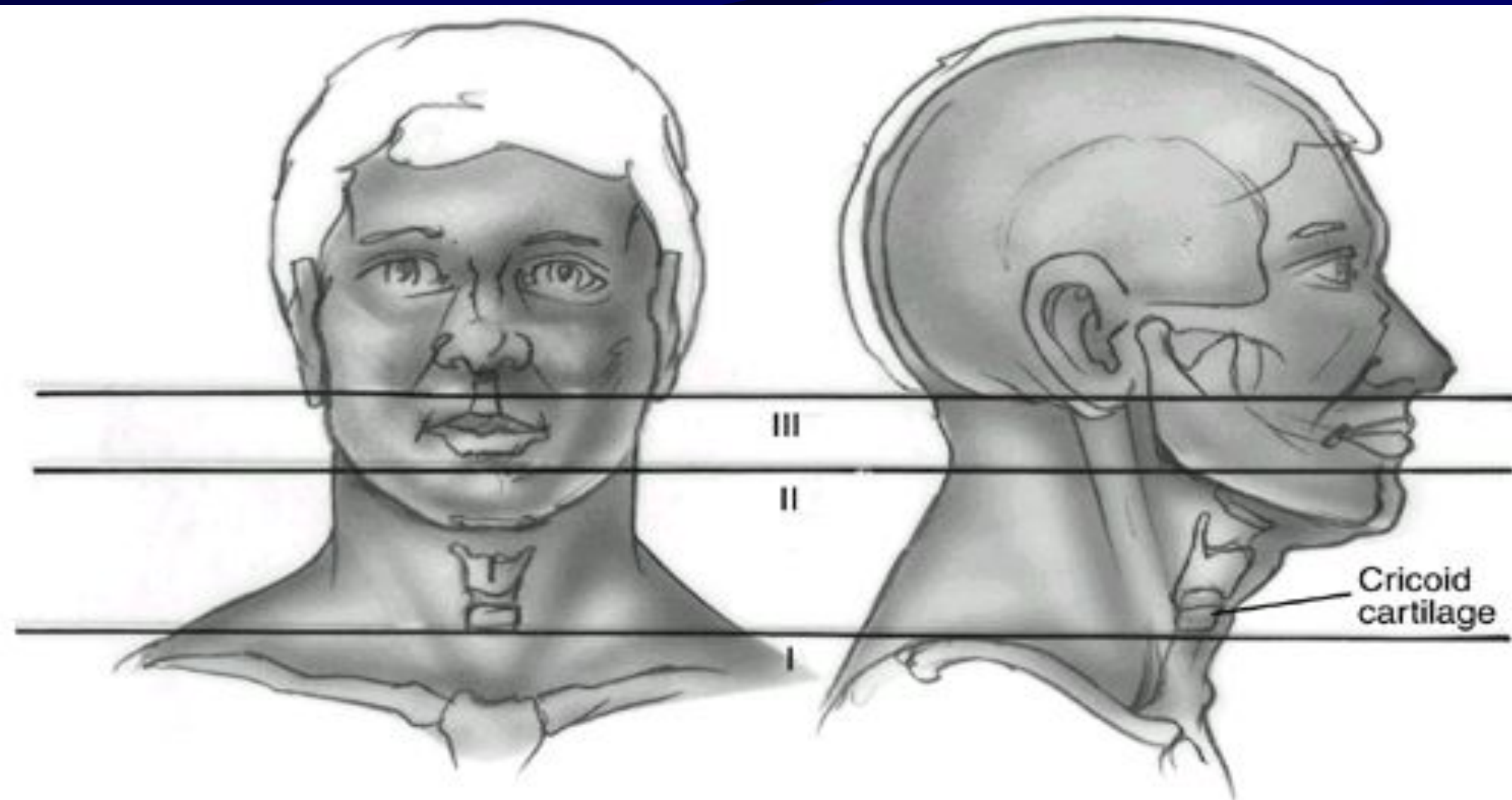


FIG. 73-8. Horizontal entry zones of the neck for penetrating injuries to the neck.
(Modified from Jurkovich GJ. The neck. In: Early care of the injured patient. Moore
EE, ed. Toronto: BC Becker, 1990:126.)

Anatomy/Zone I

- Bound superiorly by the cricoid and inferiorly by the sternum and clavicles
- Contains the subclavian arteries and veins, the dome of the pleura, esophagus, great vessels of the neck, recurrent nerve, trachea
- Signs of significant injury may be hidden from inspection in the mediastinum or chest

Anatomy/Zone II

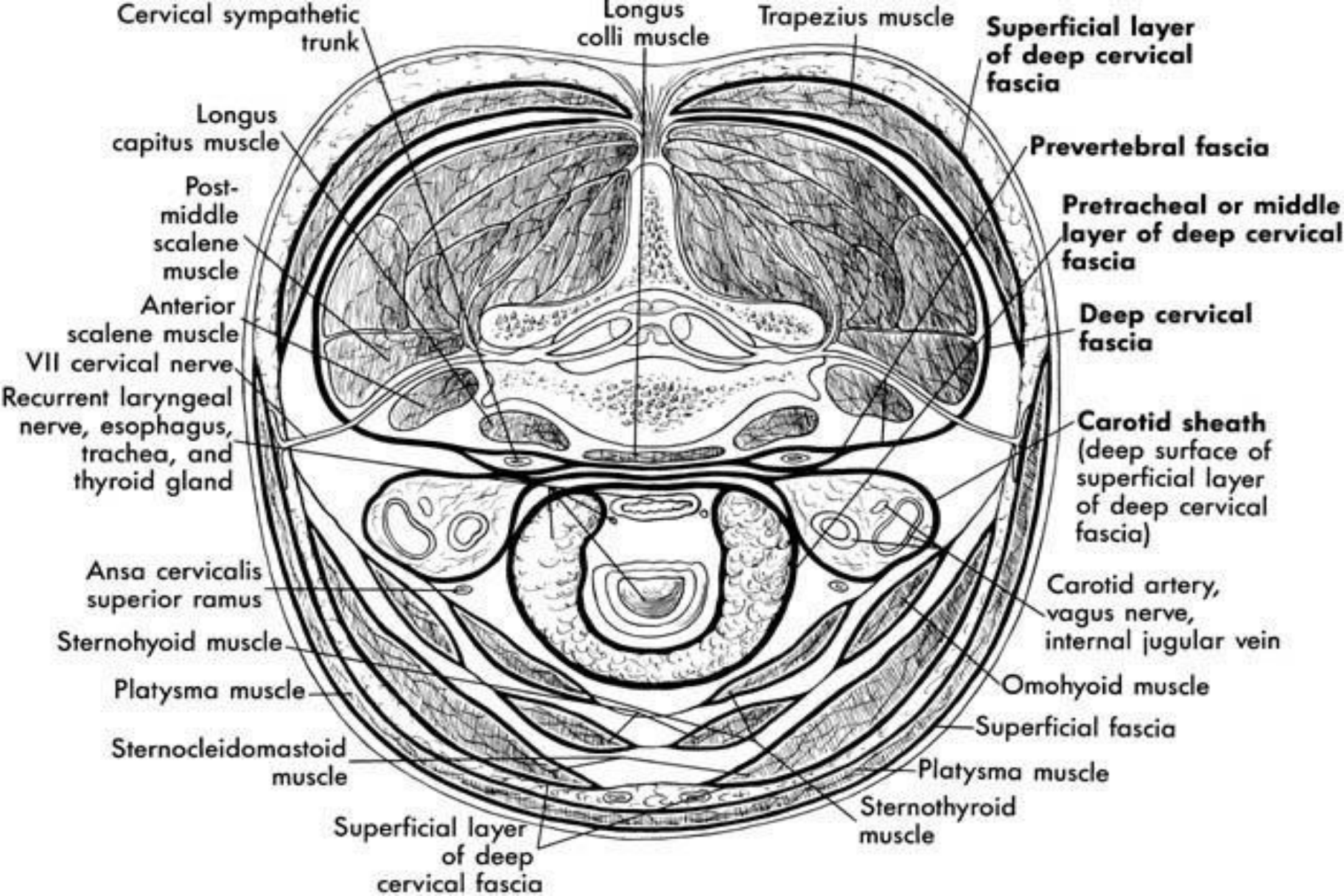
- Bound inferiorly by the cricoid and superiorly by the angle of the mandible
- Contains the larynx, pharynx, base of tongue, carotid artery and jugular vein, phrenic, vagus, and hypoglossal nerves
- Injuries here are seldom occult
- Common site of carotid injury

Anatomy/Zone III

- Lies above the angle of the mandible
- Contains the internal and external carotid arteries, the vertebral artery, and several cranial nerves
- Vascular and cranial nerve injuries common

Fascial Layers

- Superficial cervical fascia - platysma
- Deep cervical fascia
 - Investing: sternocleidomastoid muscle, trapezius muscle
 - Pretracheal: larynx, trachea, thyroid gland, pericardium
 - Prevertebral: prevertebral muscles, phrenic nerve, brachial plexus, axillary sheath
 - Carotid sheath: carotid artery, internal jugular vein, vagus nerve



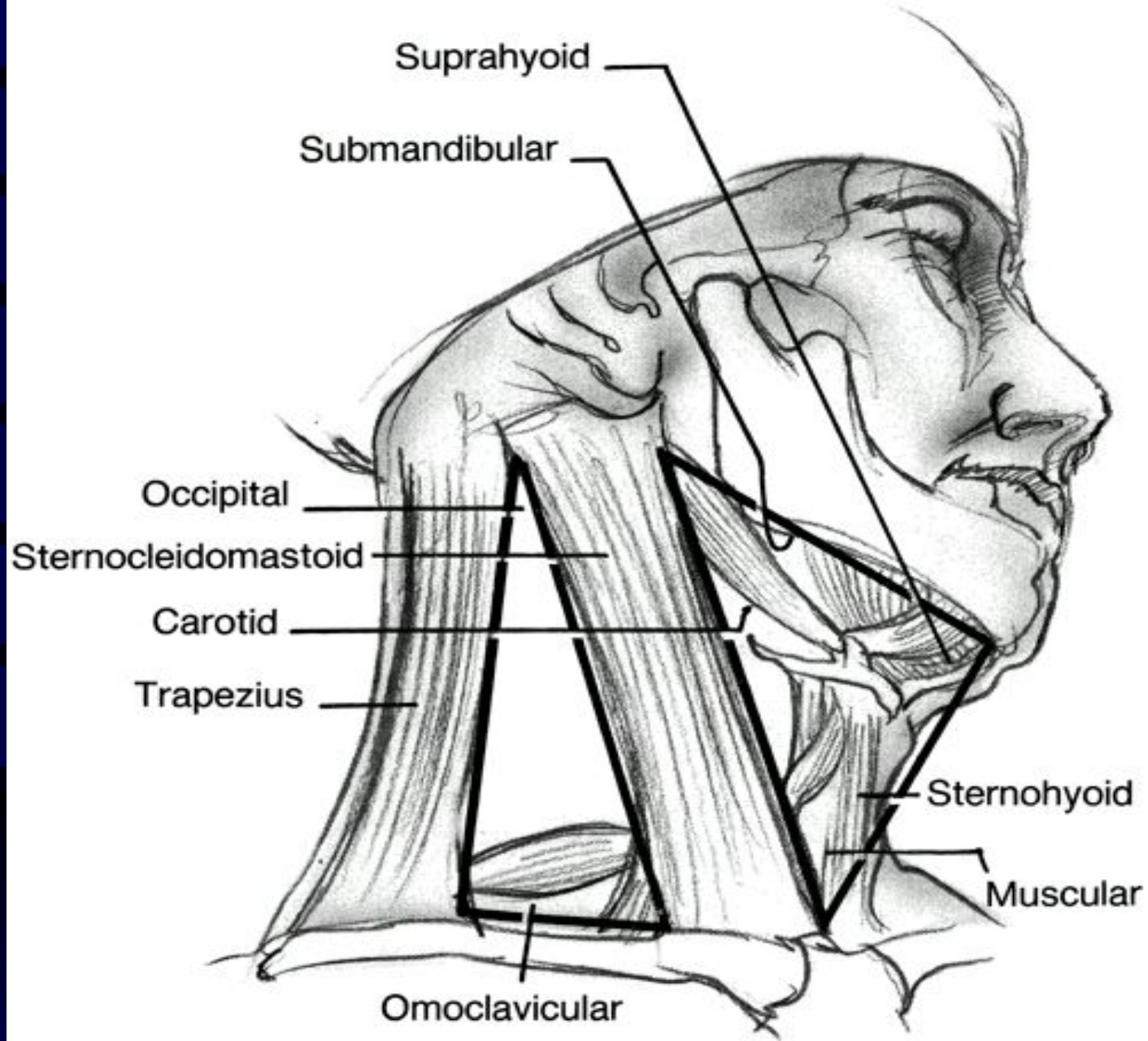
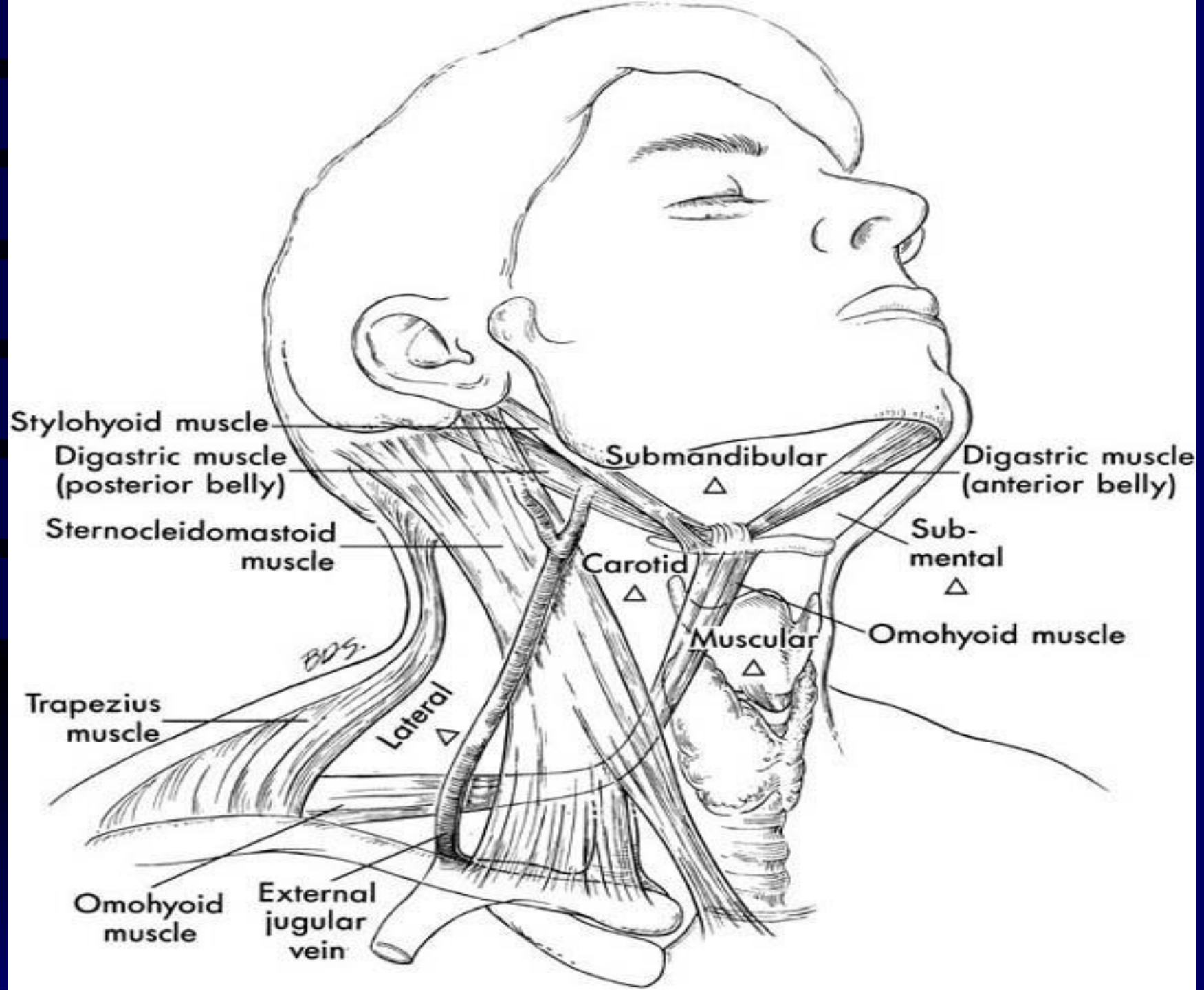


FIG. 73-7. Anatomic triangles of the neck: the neck is divided into anterior and posterior triangles by the sternocleidomastoid muscle.



Ballistics

- Over 95% of penetrating neck wounds are from guns and knives, remainder from motor vehicle, household, and industrial accidents
- The amount of energy transferred to tissue is difference between the kinetic energy of the projectile when it enters the tissue, and the kinetic energy of any exiting fragments or projectiles
- The velocity of the projectile is the most significant aspect of energy transfer ($K.E. = 1/2 mv^2$)

Ballistic cont...

- Muzzle velocity less than 1000 ft/s (610 m/s) is considered low velocity
- .22 and .38 caliber handguns have a velocity of 800 ft/sec
- .357 magnum and .45 as high as 1500 ft/sec
- High power rifles: 220-3000 ft/sec
- Shotguns at less than 20 feet -- 1200-1500 ft/sec

Ballistic cont.

- Injuries inflicted with high power rifles, shotguns at less than 20 feet, and .357 and .45 caliber handguns can cause extensive damage extending beyond the path of the projectile and should be explored
- Stab wounds do not have this effect
- Beware of the stab wound just over the clavicle -- the subclavian vein is at high risk

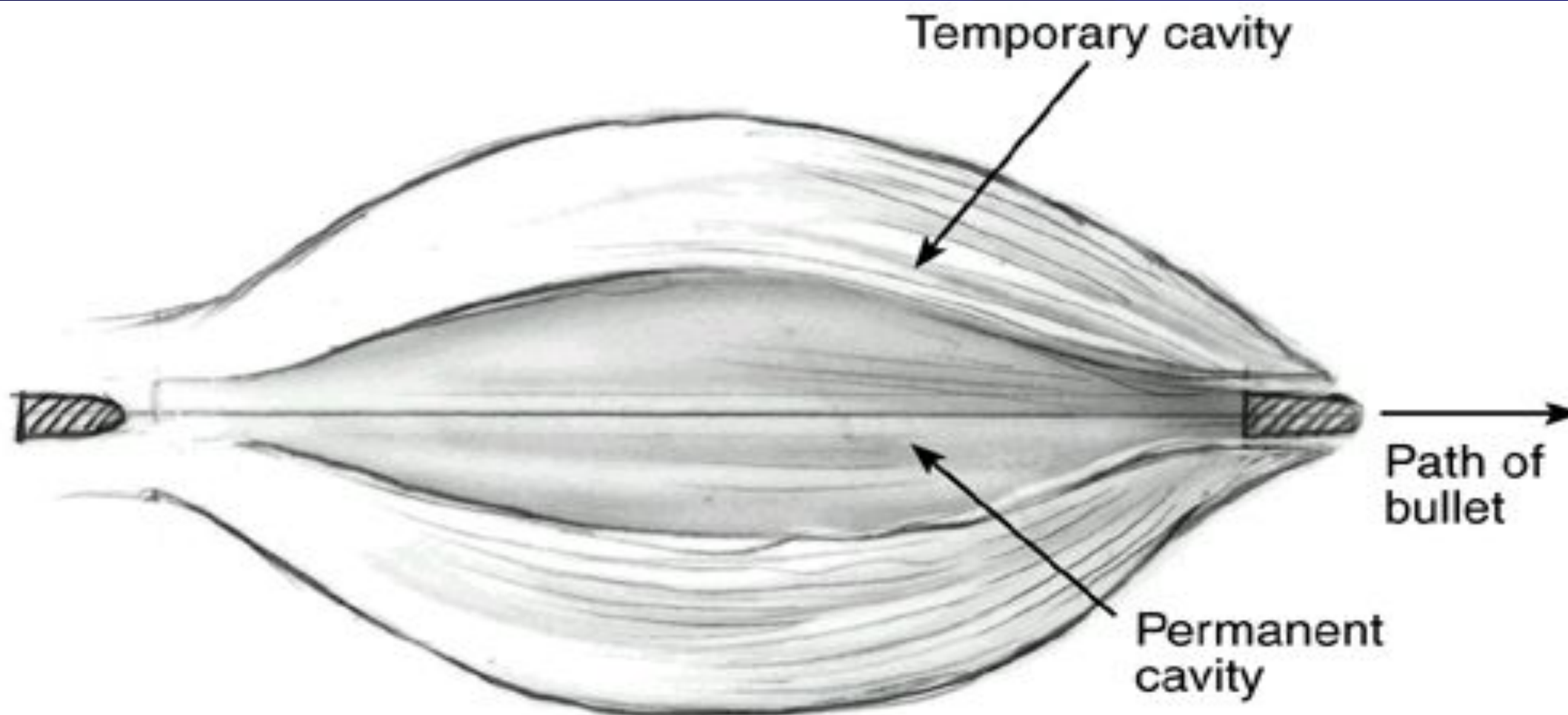
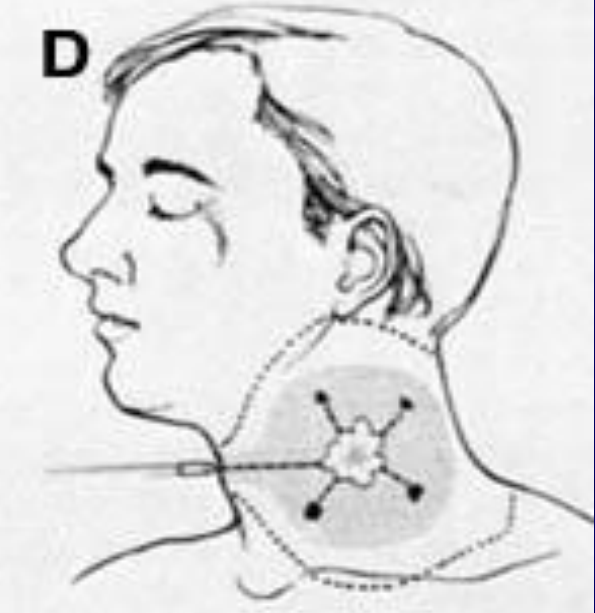
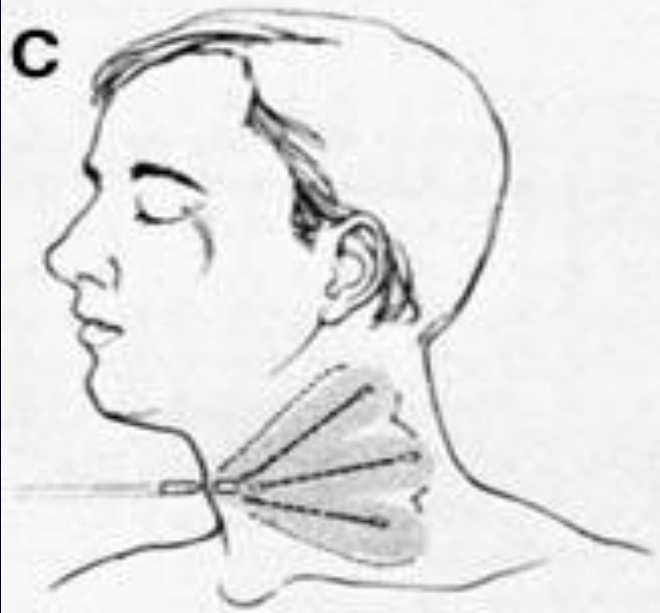
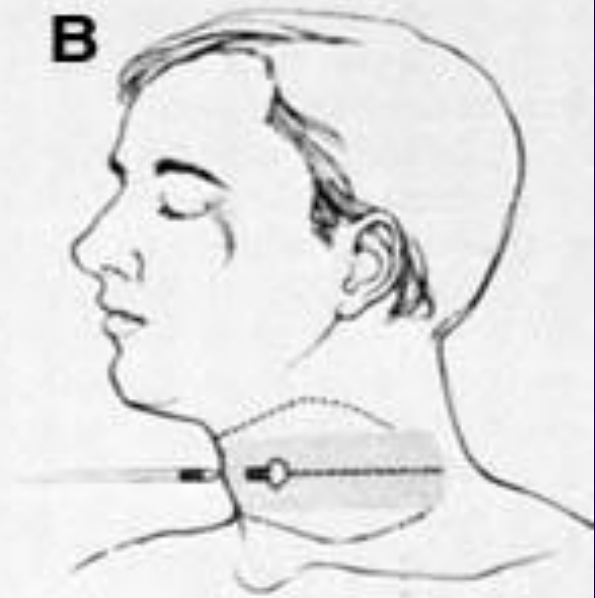
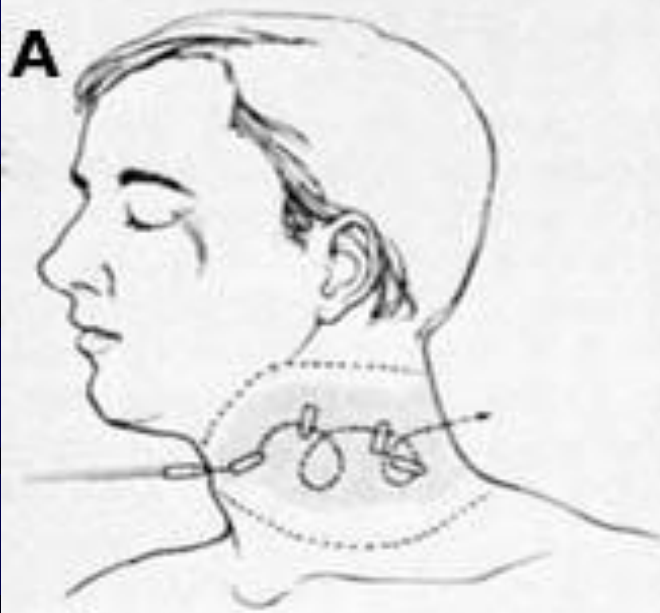


FIG. 73-1. Cavitation effects of a bullet wound to soft tissue.



Stabilization/Airway

- Established Airway
 - be prepared to obtain an airway emergently
 - intubation or cricothyrotomy
 - beware of cutting the neck in the region of the hematoma -- disruption there of may lead to massive bleeding
 - must assume cervical spine injury until proven otherwise

Breathing

- Zone I injuries with concomitant thoracic injuries
 - pneumothorax
 - hemopneumothorax
 - tension pneumothorax

Circulation

- Bleeding should be controlled by pressure
- Do not clamp blindly or probe the wound depths
- The absence of visible hemorrhage does not rule out
- Two large bore IVs
- Careful of IV in arm unilateral to subclavian injury

History

- Obtain from EMS witnesses, patient
- Mechanisms of injury - stab wounds, gunshot wound, high-energy, low-energy, trajectory of stab
- Estimate of blood loss at scene
- Any associated thoracic, abdominal, extremity injuries
- Neurologic history

Physical Examination

- Thorough head and neck exam using palpation and stethoscope to search for thrills and bruits
- Neuro exam: mental status, cranial nerves, and spinal column
- Examine the chest, abdomen, and extremities
- Be sure to examine the back of the patient as unsuspected stab or gunshot wounds have been missed here
- Don't blindly explore wound or clamp vessel

Radiographs

- CXR - inspiratory/expiratory films to assess for phrenic nerve injury, look for pneumothorax
- Cervical spine film to rule out fractures
- Soft tissue neck films AP and Lateral
- Arteriograms, contrast studies as indicated

Preoperative Preparation

- Surgeon and staff ready for emergent/urgent tracheotomy
- Gentle cleansing of wound, betadine paint only
- Prep vein donor site, and chest for possible thoracotomy
- Avoid NG tube until airway secure and patient anesthetized

Penetrating neck trauma

Diagnosis

Signs and symptoms

Vascular injury

Shock

Hematoma

Hemorrhage

Pulse deficit

Neurologic deficit

Bruit or thrill in neck

Laryngotracheal injury

Subcutaneous emphysema

Airway obstruction

Sucking wound

Hemoptysis

Dyspnea

Stridor

Hoarseness or dysphonia

Pharynx/esophagus injury

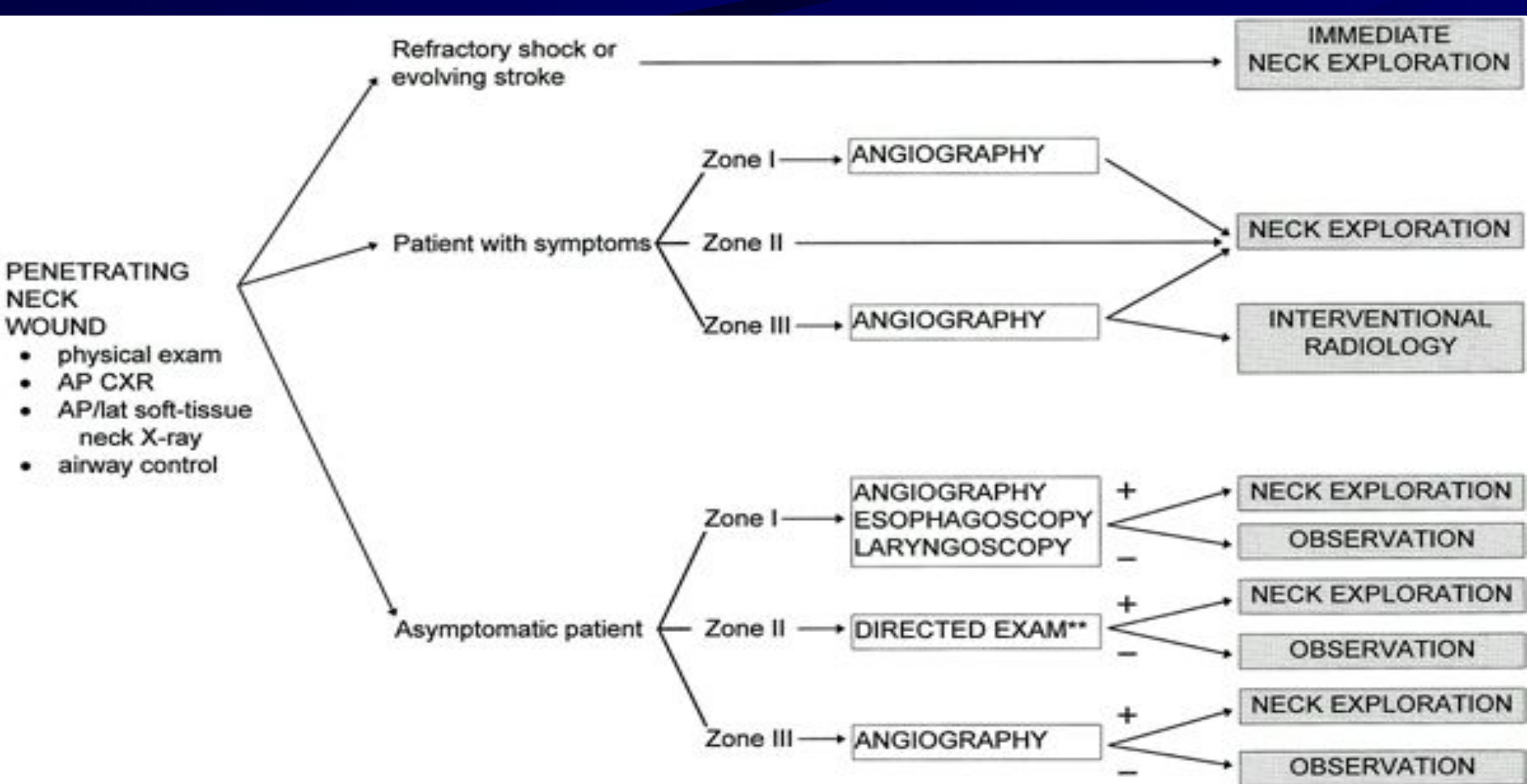
Subcutaneous emphysema

Hematemesis

Dysphagia or odynophagia

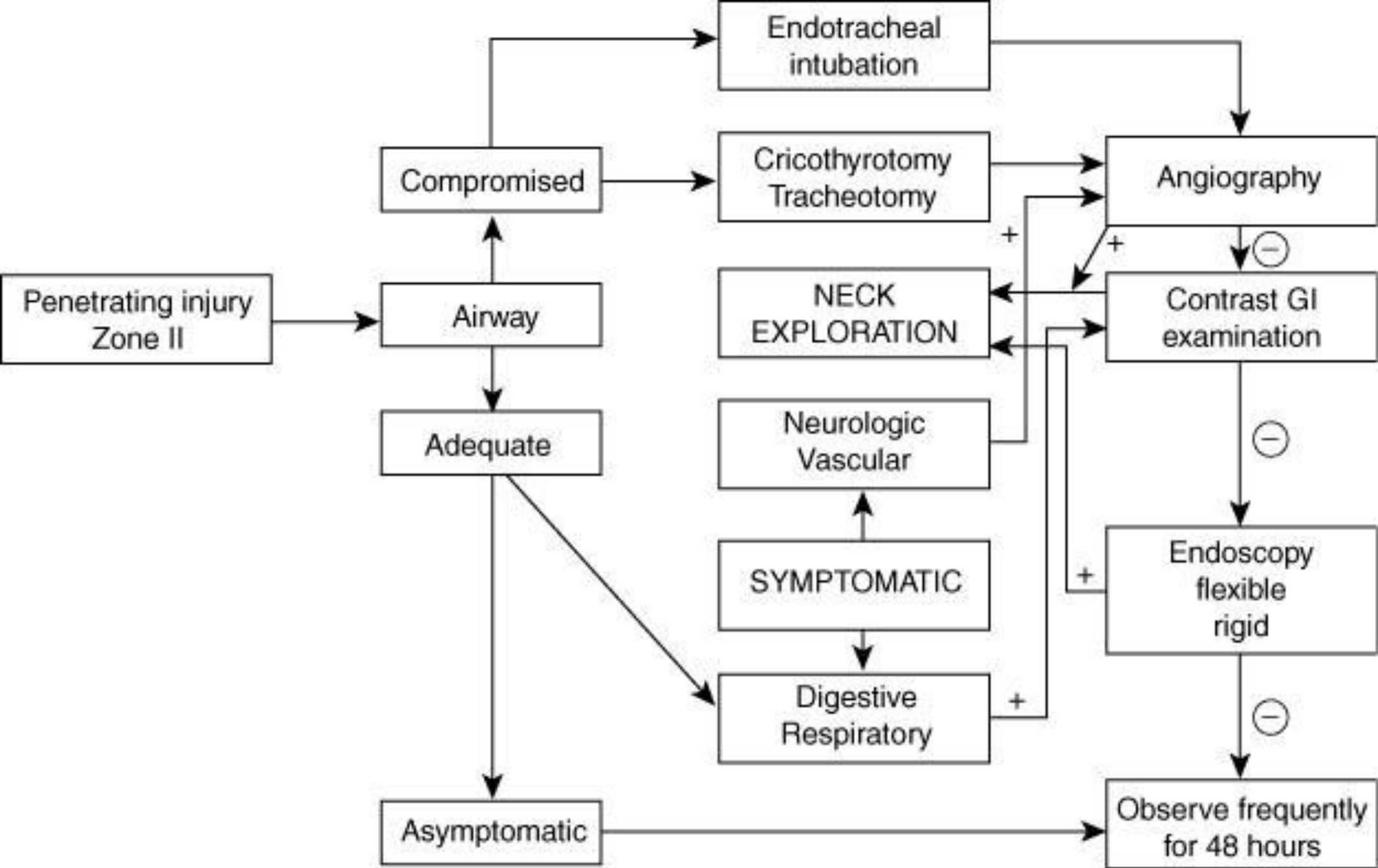
Exploration vs. Observation

- Many experts have adopted a policy of selective exploration
- Decreased number of negative explorations, increased number of positive explorations
- Decreased cost of medical care, maybe
- No increase in mortality when adjunctive diagnostic studies and serial exams performed
- Patients taken to OR if clinical exam changes, around 2% in most studies



**DIRECTED EXAM: Angiography, esophagoscopy, and/or laryngoscopy based on path of projectile and clinical exam

FIG. 73-9. Algorithm for the initial management of patients with penetrating injuries to the neck. (Modified from ref. 14, with permission.)



Site/Zone I

- Adequate exposure for exploration and repair may require sternotomy, clavicle resection, or thoracotomy
- High morbidity of exploration, thus suspicion must be great before taking the patient to OR
- Cardiothoracic surgery consultation a must
- Angiography is essential

Site/Zone II

- Few injuries will escape clinical examination
- Most carotid injuries occur here
- Adjunctive studies, except barium swallow and esophagoscopy where indicated, are not necessary
- Symptomatic zone II injuries can generally be safely managed by observation

Site/Zone III

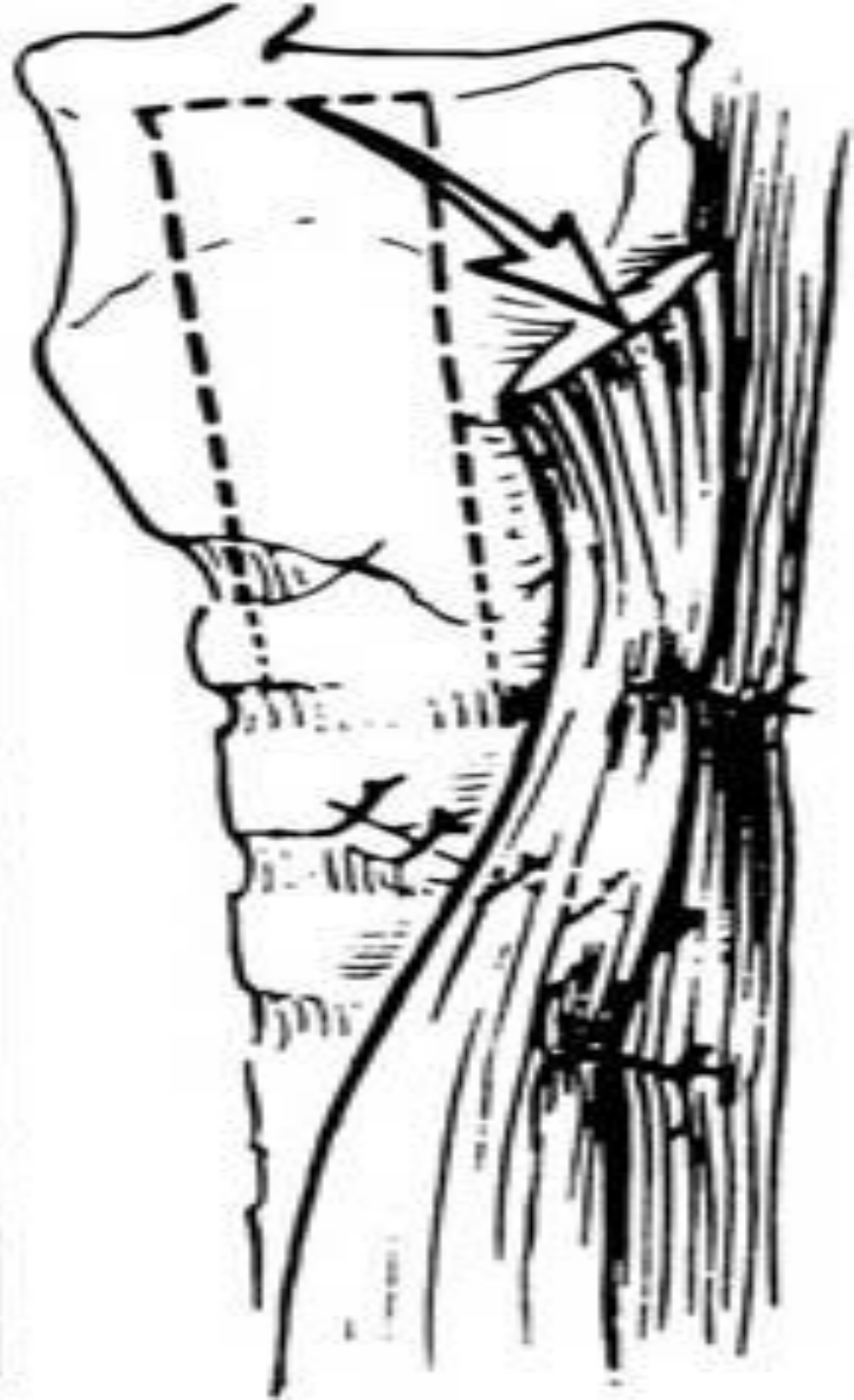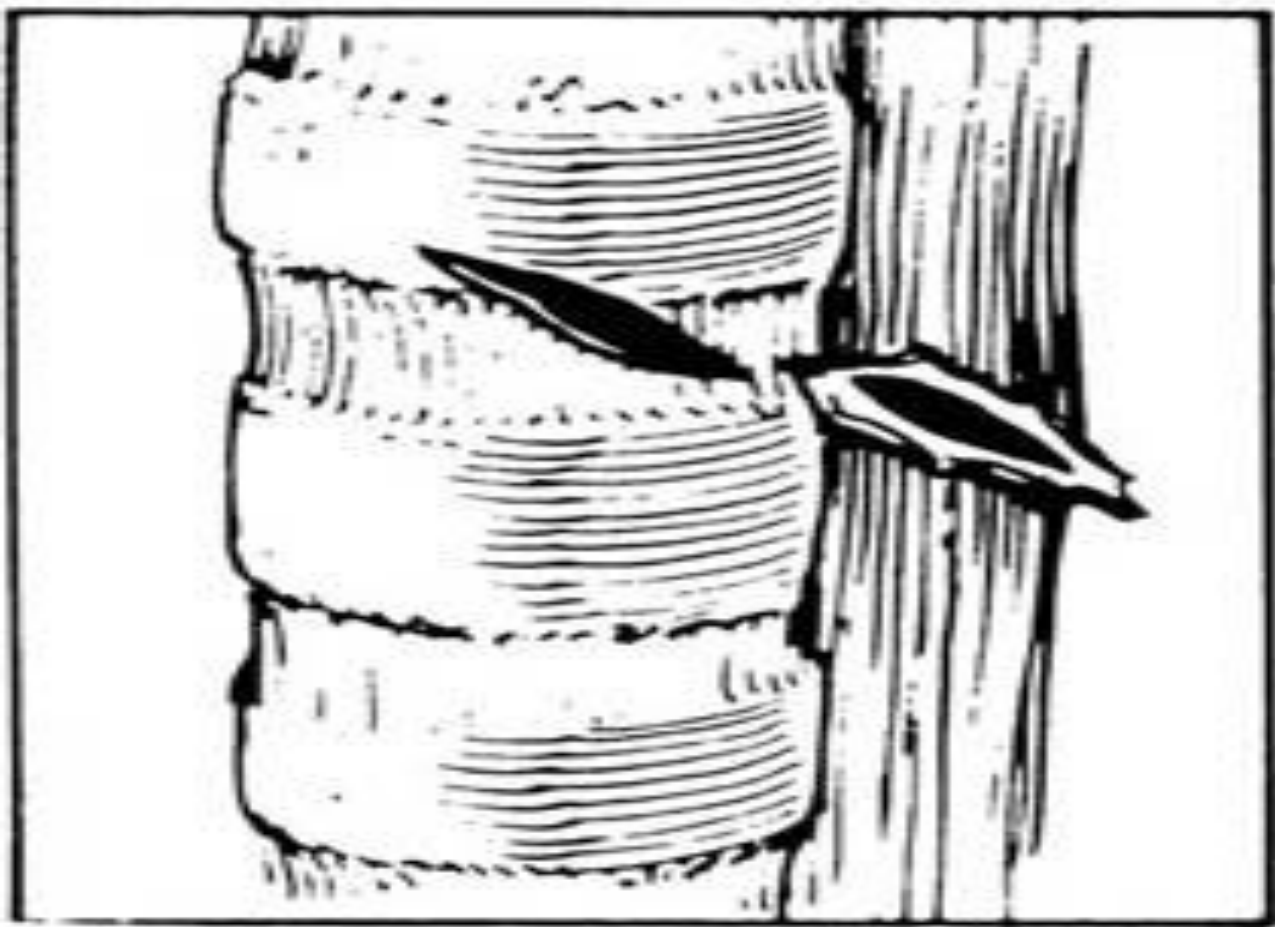- High rate of vascular injury, often multiple
- Often difficult to obtain proximal and distal vessel control
- Exploration has high rate of injury to cranial nerves
- Adequate exposure may require mandibular subluxation or mandibulotomy
- Angiography needed to delineate site of injury
- Embolization techniques of greatest value here

Clinical Setting

- Observation requires admission to an intensive care unit where serial examination can be performed by a surgeon
- Adjunctive studies must be available at all times and at a moments notice
- Absence of these dictates exploration of all patients - such as in a rural setting

Pharyngo Esophageal

- Gastrografin swallow followed by Barium if negative
- Flexible \pm rigid esophagoscopy
- Invert the mucosal edges and close with two layers of absorbable sutures
- JP drain and muscle flap



Airway

- DL where laryngeal injury is suspected
- Mucosal tears are closed with absorbable sutures
- Cover raw surfaces with nasal, buccal, or local mucosal flap
- A keel or soft stent is placed when denuded areas are opposed
- Tracheotomy one ring below injury when high tracheal injury
- Suprahyoid muscle release for primary closure of segmental defect

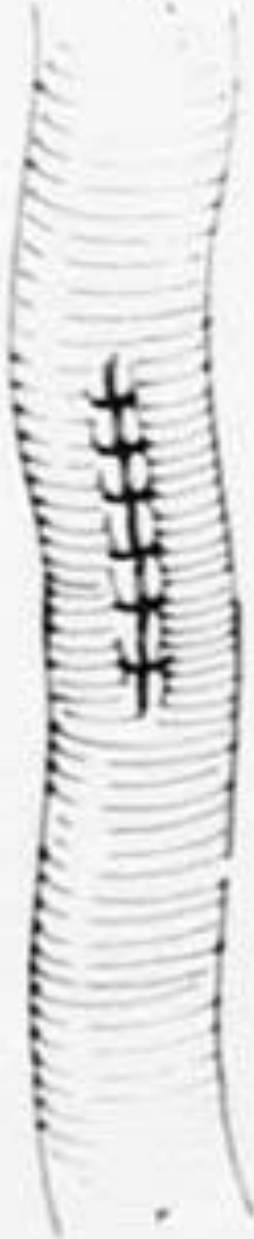
Vascular

- The subclavian and internal jugular veins can be ligated without adverse effect
- Major arteries should be repaired where possible except the vertebral which can be ligated
- Partial lacerations can be closed primarily -- vein patches will help prevent subsequent stenosis
- High velocity wounds produce a surrounding area of contusion which may be thrombogenic and which must be resected; then primary reanastomosis if possible

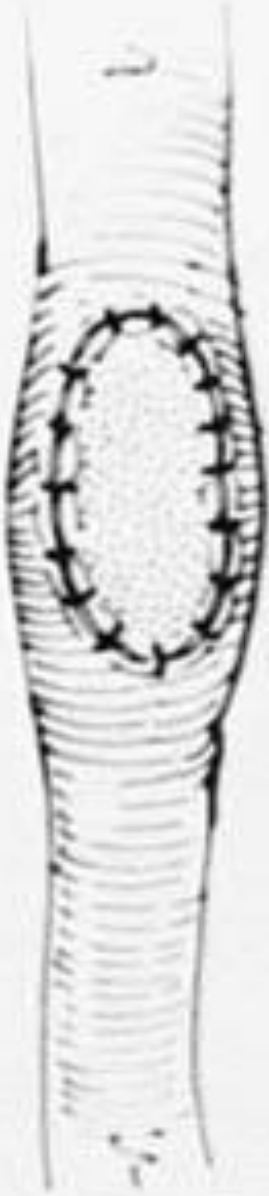
1



2



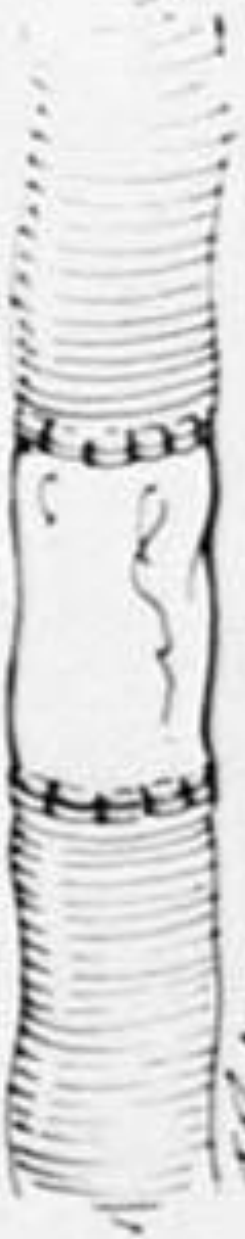3



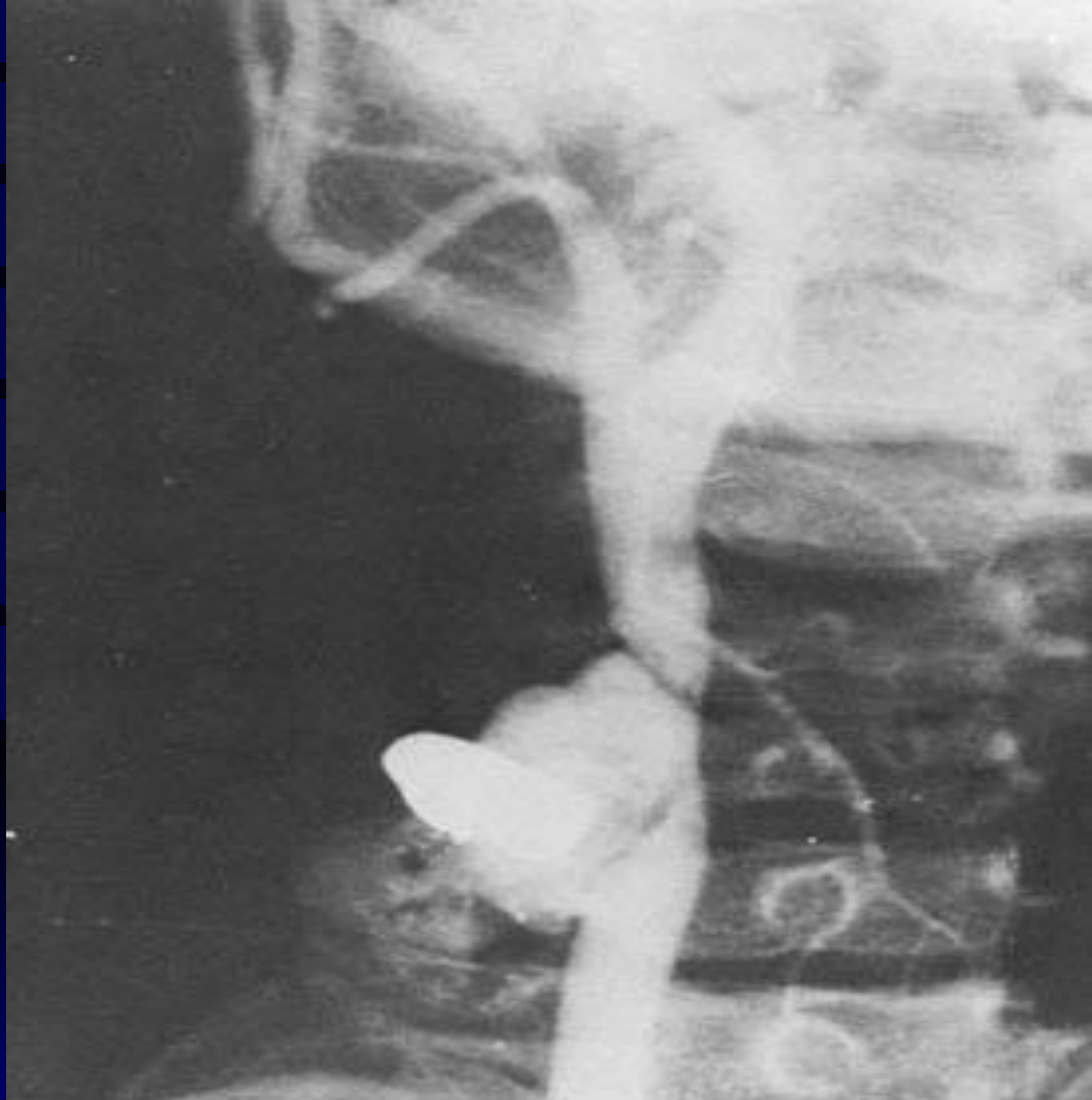4a



4b

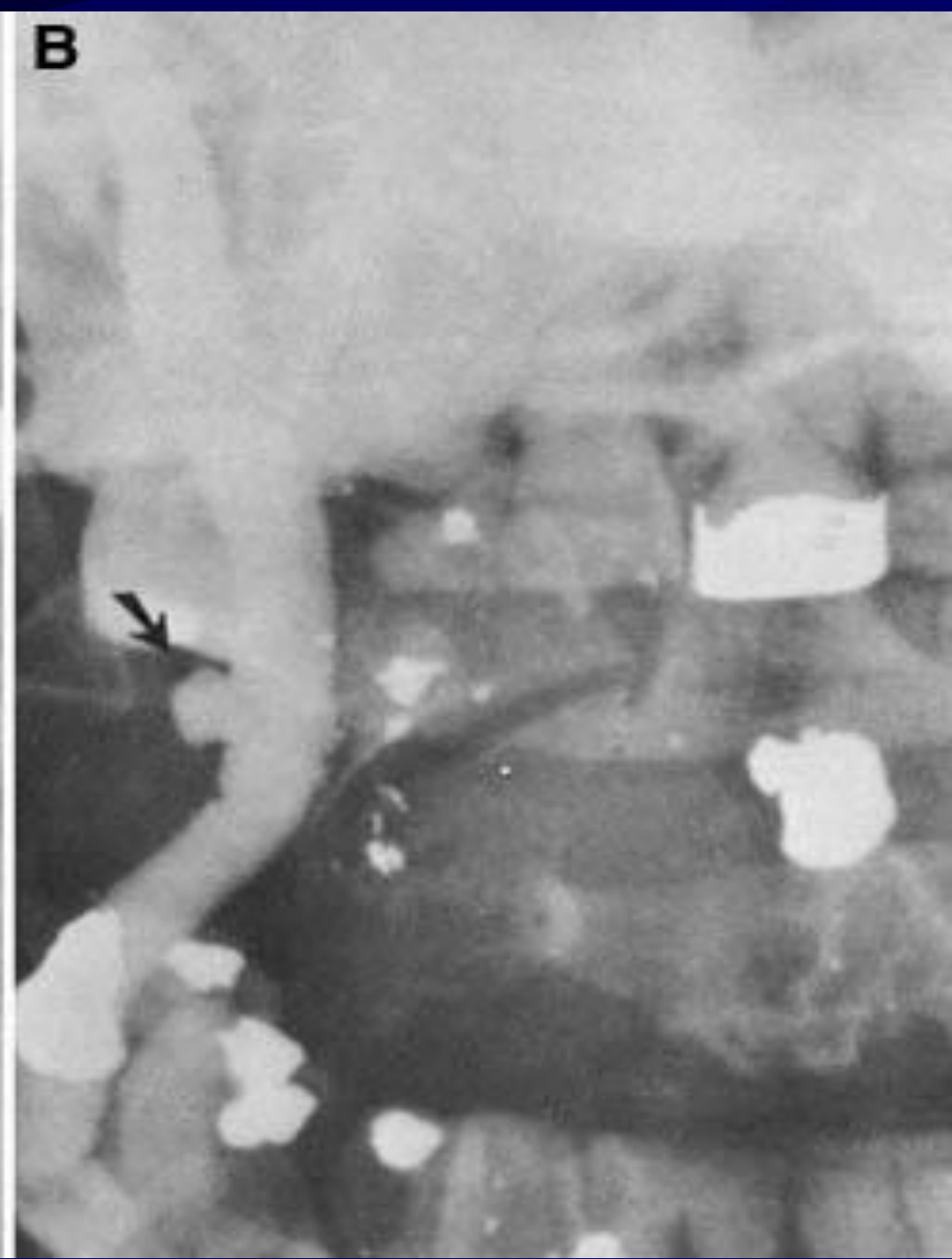
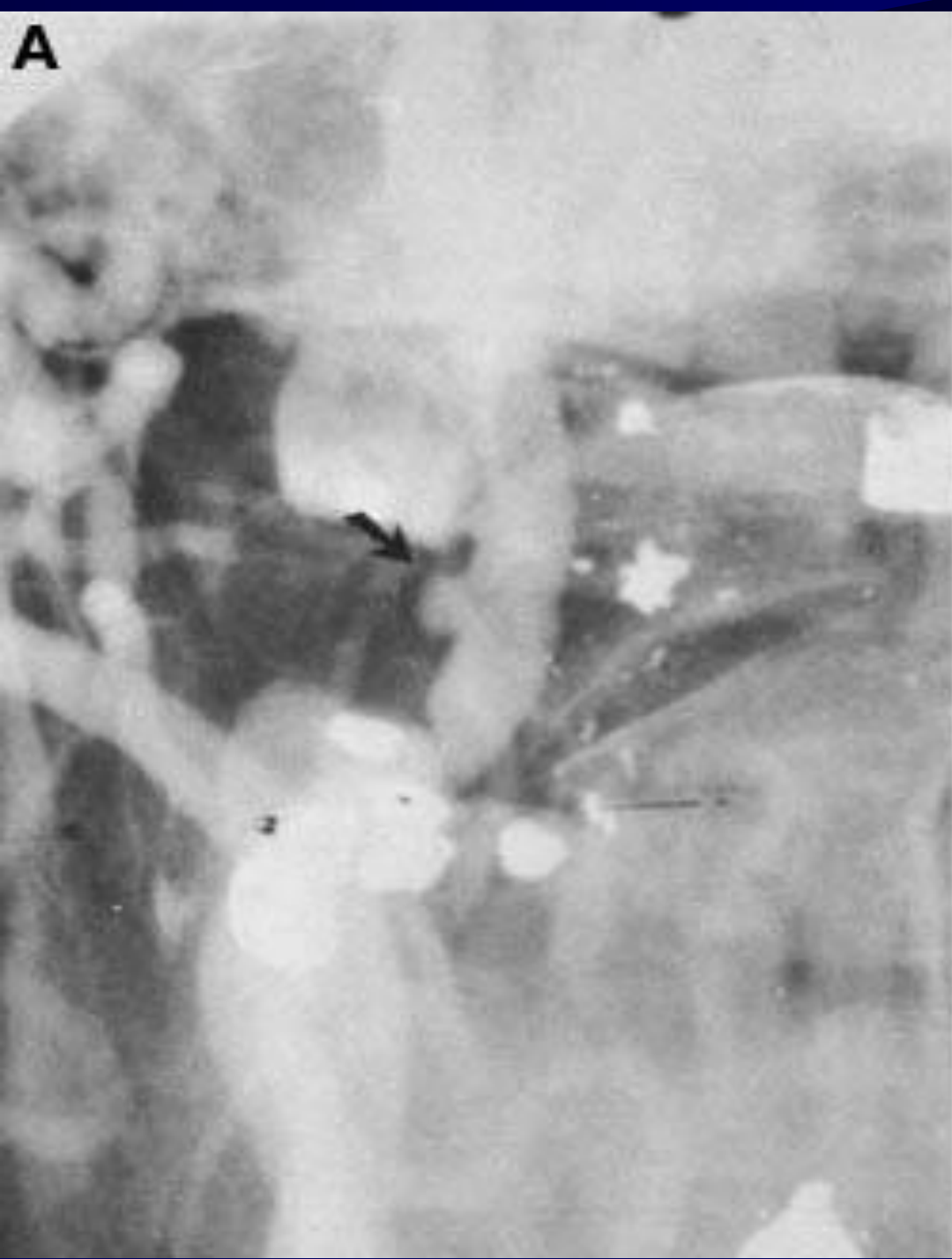
T. H. H. H.



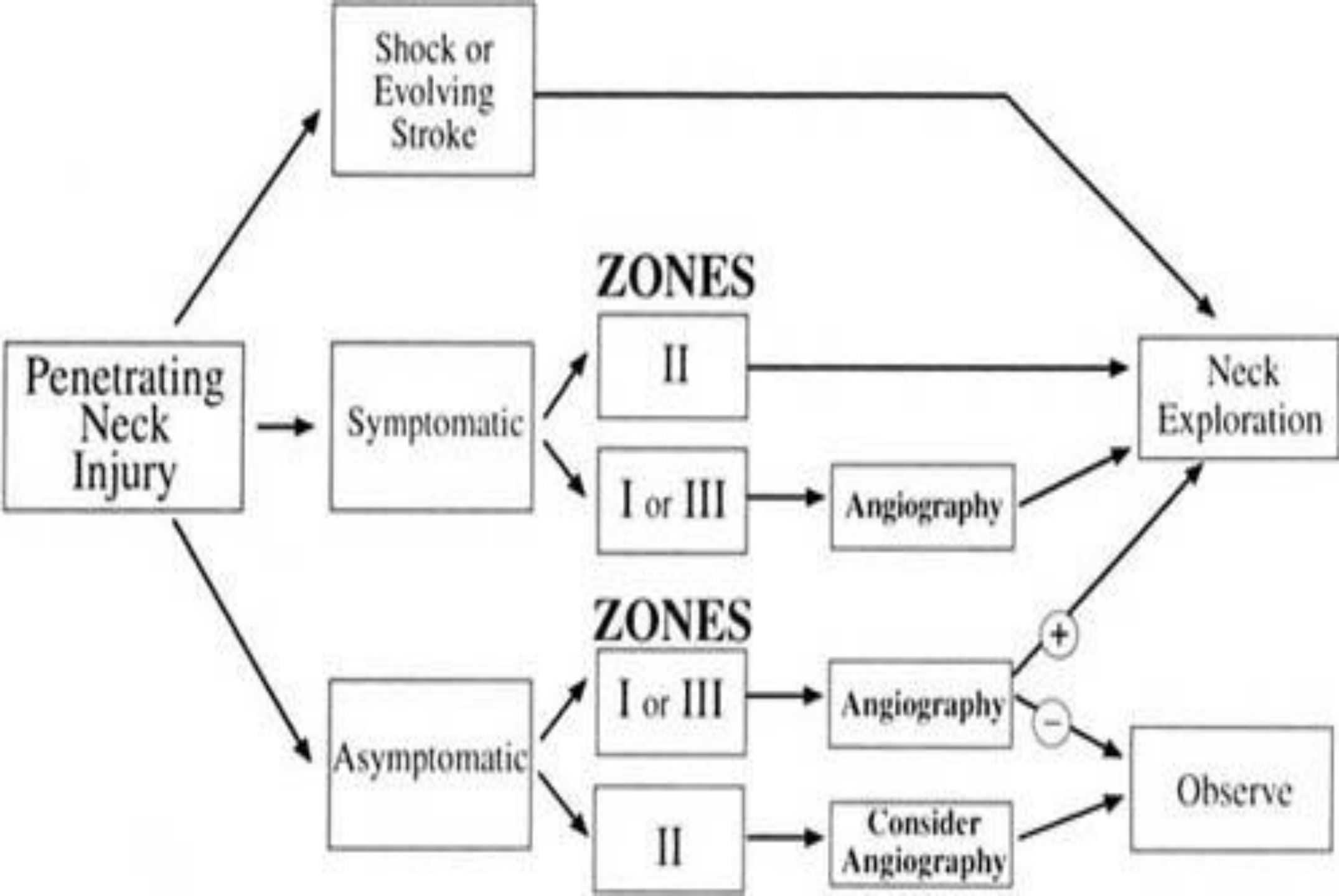
Vascular cont.

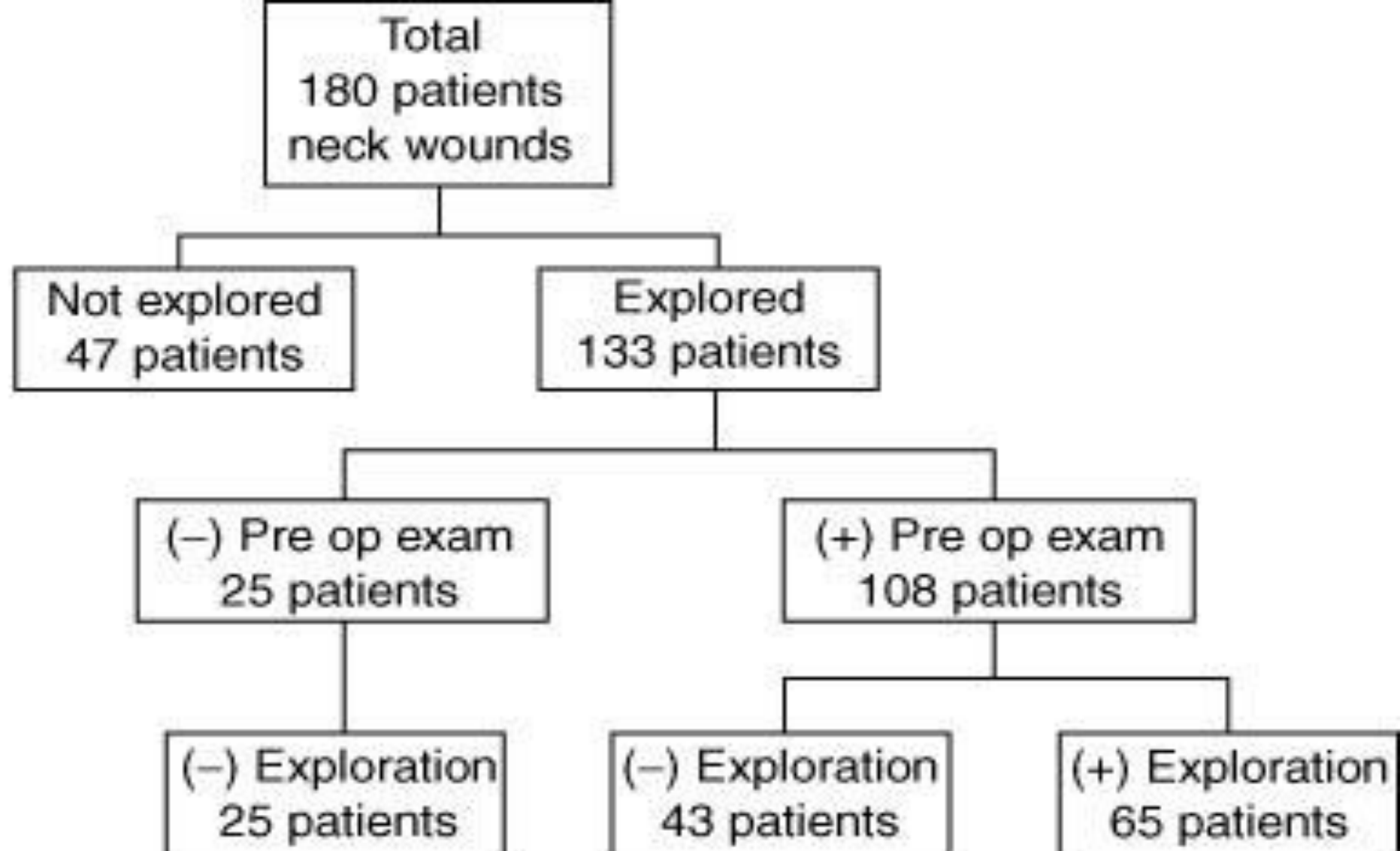
- When tension is required, vein grafts from the sphenous or internal jugular are interposed
- In central neurologic deficits:
 - repair the artery when there are minimal deficits, with gross deficits restoration of flow can convert ischemic infarcts into hemorrhagic ones -- the artery should be ligated
 - a deterioration in neurologic status dictates arteriography and reexploration
 - EC-IC bypass when irreparable injury to ICA



Conclusions

- Maintain a healthy respect for apparently minor neck wounds because of potential fatal outcome for initially benign appearing injuries
- Do not try to infer trajectories of gunshot wounds from clinical or radiographic studies
- Careful history and complete physical exam with appropriate ancillary studies will avoid missed injuries
- Arteriography for zone I and zone III injuries
- Vascular injuries most immediately life-threatening, missed esophageal injury causes late mortality





Gunshot wounds:	7 Patients	21 Patients	30 Patients
Stab wounds:	18 Patients	22 Patients	35 Patients

