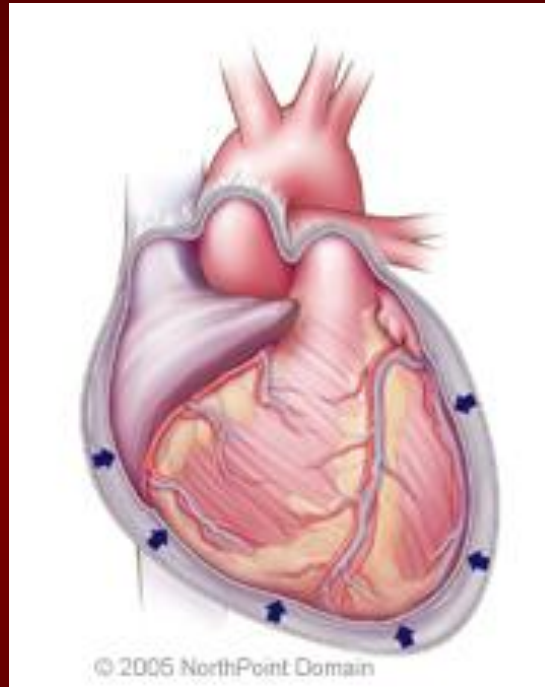


# VALVULAR HEART DISEASE



Internal Medicine Didactics

August 12, 2009

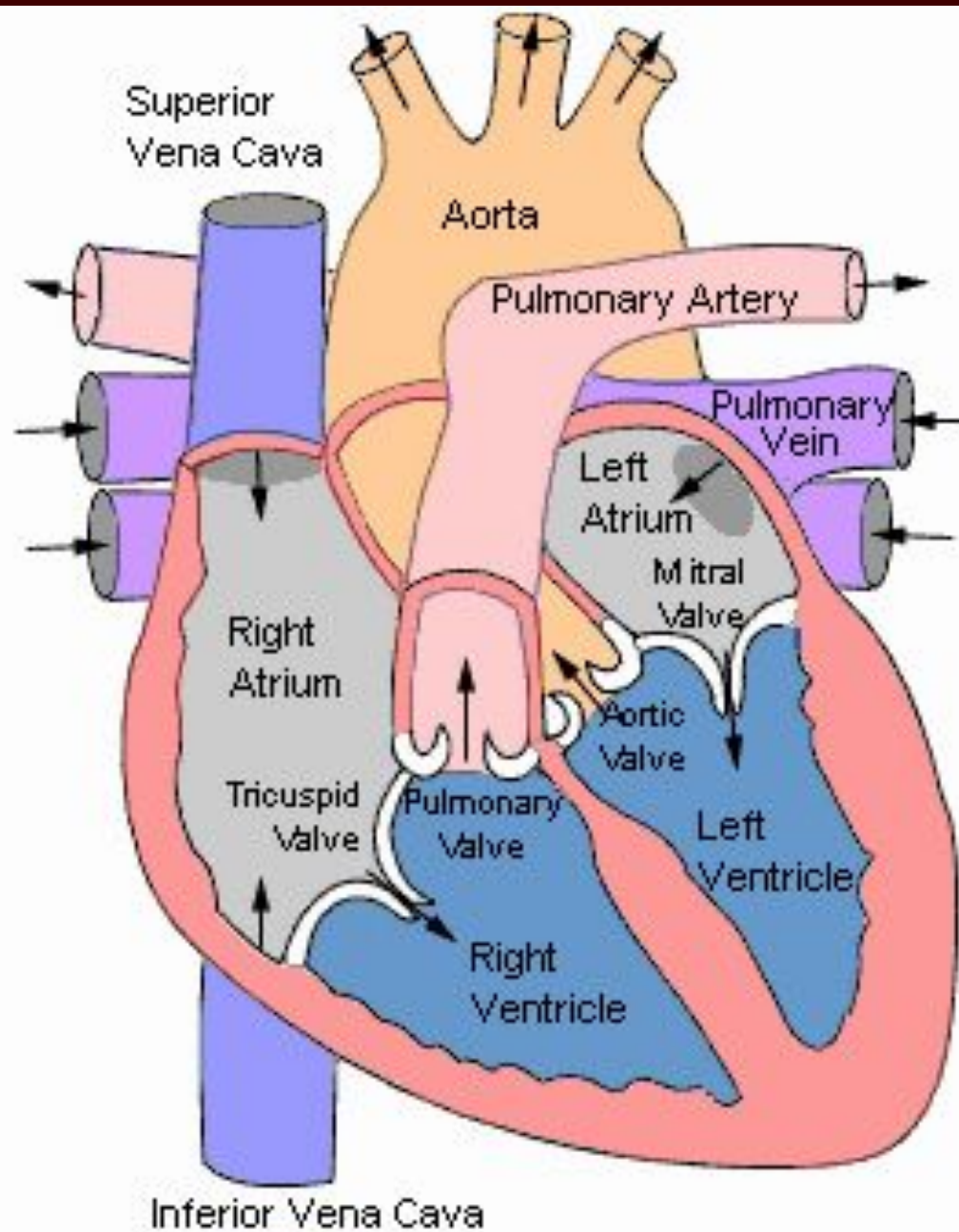
Steven R. Bruhl MD, MS

# Overview

- Aortic Stenosis
- Mitral Stenosis
- Aortic Regurgitation
  - Acute and Chronic
- Mitral Regurgitation
  - Acute and Chronic

- Etiology
- Pathophysiology
- Physical Exam
- Natural History
- Testing
- Treatment

# Aortic Stenosis



# Aortic Stenosis Overview:

- **Normal Aortic Valve Area:** 3-4 cm<sup>2</sup>
- **Symptoms:** Occur when valve area is 1/4<sup>th</sup> of normal area.
- **Types:**
  - Supravalvular
  - Subvalvular
  - **Valvular**

# Etiology of Aortic Stenosis

- **Congenital**
- **Rheumatic**
- **Degenerative/Calcific**

**Patients under 70: >50% have a congenital cause**

**Patients over 70: 50% due to degenerative**

**TABLE 12-2****Etiology of AS**

Etiology	Notes
<b>Congenital</b> 1. <b>Congenital aortic stenosis</b> 2. <b>Congenital bicuspid valve</b>	Can occur with unicuspid, bicuspid, tricuspid valve Commonly associated with aortic coarctation, dissection, or aneurysm. Onset of symptoms in third to fifth decade
<b>Acquired</b> 1. <b>Degenerative calcification</b> 2. <b>Rheumatic heart disease</b> 3. <b>Rare causes</b>	Onset of symptoms in seventh to eighth decade. Higher incidence of risk factors for coronary artery disease (CAD) Adhesions and fusion of commissures and cusps Infectious vegetations, Paget disease, SLE, RA, Postradiation (typically occurs 11.5–16.5 years after radiation <sup>5</sup> )



Short axis views from  
above aortic valves

Left parasternal  
long axis view

Aortic arch

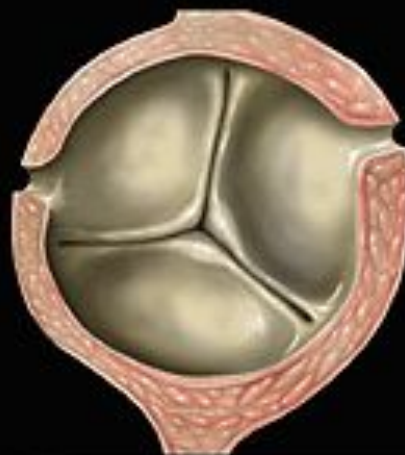Bicuspid aortic valve

Left  
atrium

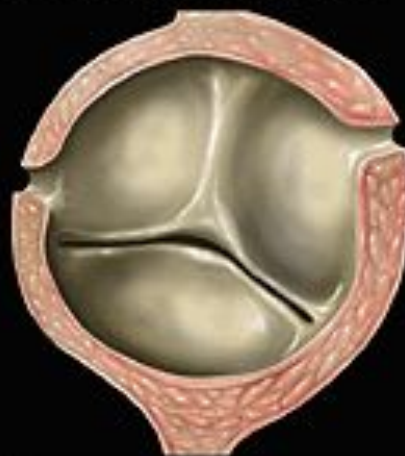Mitral valve

Left ventricle

Normal aortic valve



Bicuspid aortic valve



Short axis views from  
above aortic valves

Left parasternal  
long axis view

Aortic arch

Stenotic aortic valve

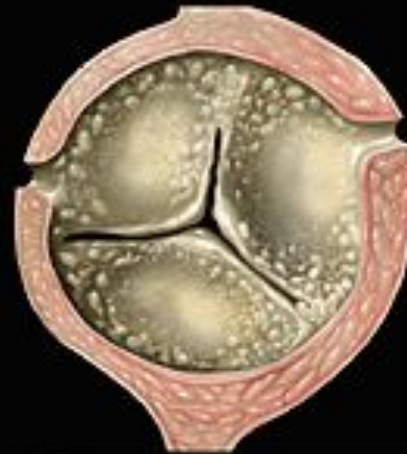Left  
atrium

Mitral valve

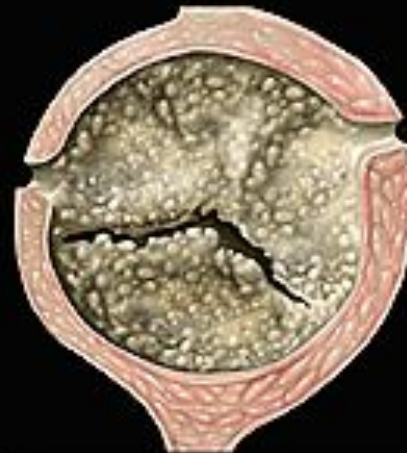Left ventricle

P. Lynch

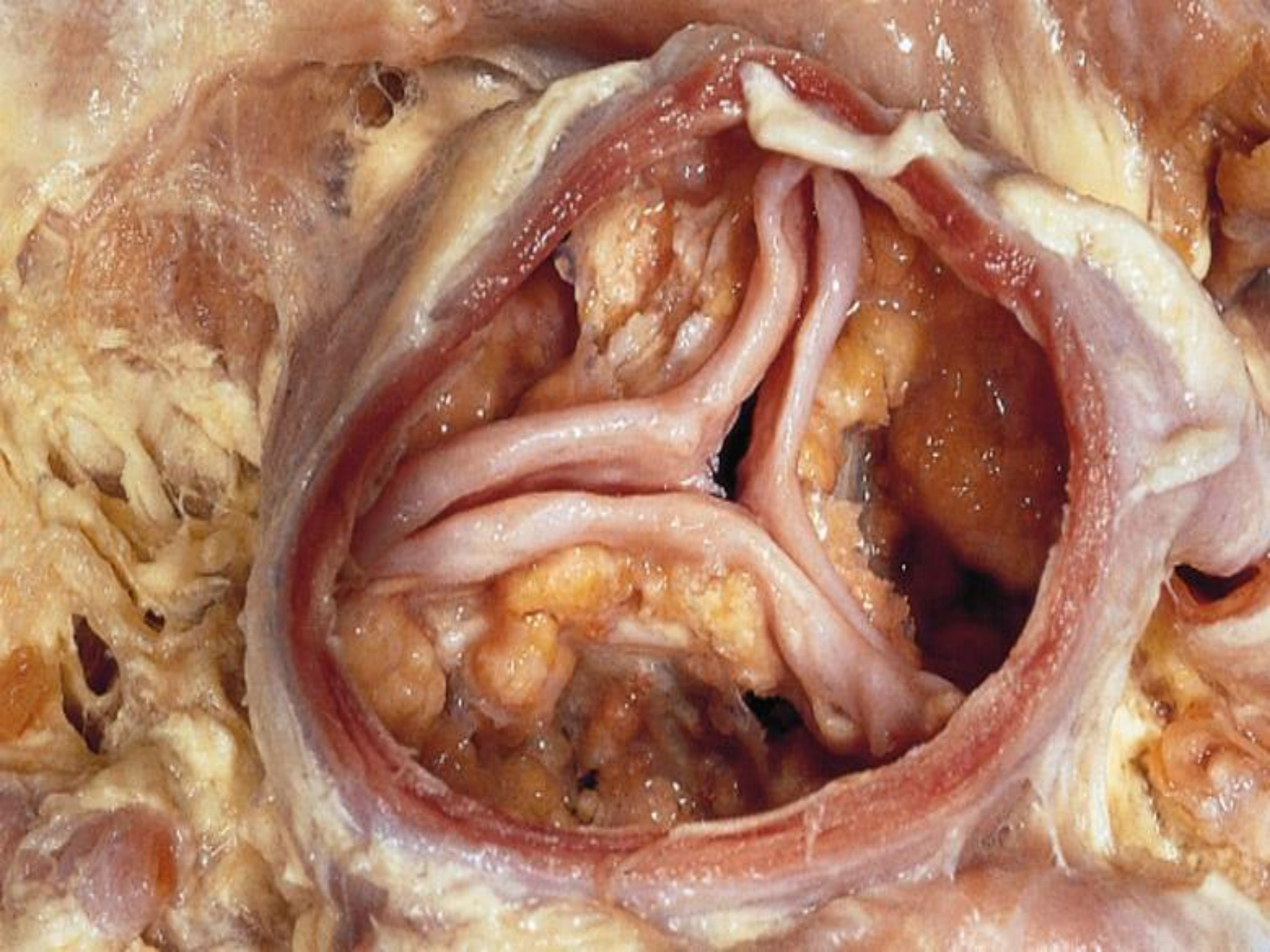
Senile aortic stenosis



Bicuspid aortic stenosis







# Pathophysiology of Aortic Stenosis

- A pressure gradient develops between the left ventricle and the aorta. (increased afterload)
- LV function initially maintained by compensatory pressure hypertrophy
- When compensatory mechanisms exhausted, LV function declines.

# Presentation of Aortic Stenosis

- **Syncope:** (exertional)
- **Angina:** (increased myocardial oxygen demand; demand/supply mismatch)
- **Dyspnea:** on exertion due to heart failure (systolic and diastolic)
- Sudden death

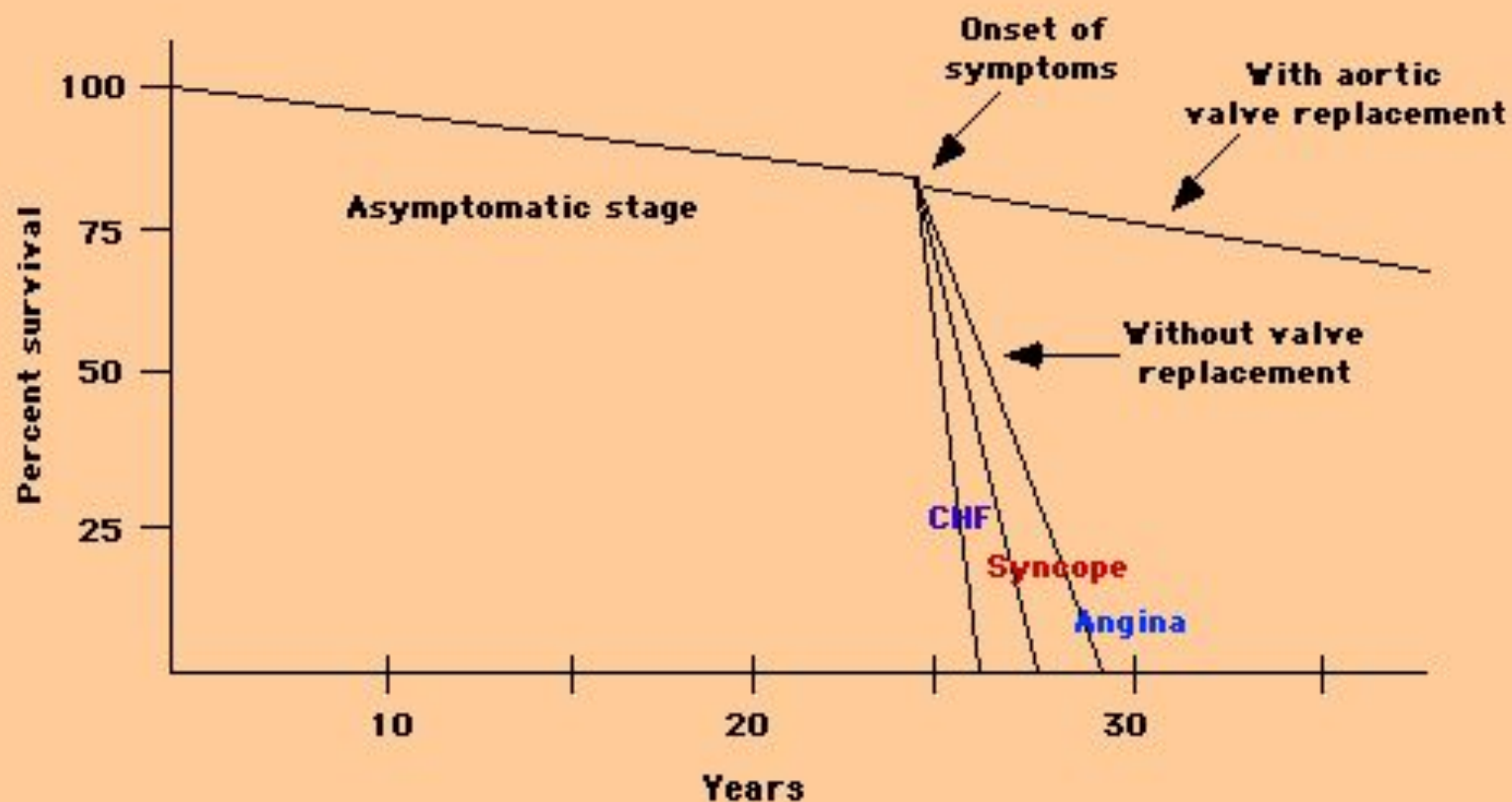
# Physical Findings in Aortic Stenosis

- Slow rising carotid pulse (*pulsus tardus*) & decreased pulse amplitude (*pulsus parvus*)
- Heart sounds- soft and split second heart sound, S4 gallop due to LVH.
- Systolic ejection murmur- crescendo-decrescendo character. This peaks later as the severity of the stenosis increases.
  - Loudness does **NOT** tell you anything about severity

# Natural History

- Mild AS to Severe AS:
  - 8% in 10 years
  - 22% in 22 years
  - 38% in 25 years
- **The onset of symptoms is a poor prognostic indicator.**





**Natural history of aortic stenosis** Schematic representation of the natural history of aortic stenosis and of the major impact of aortic valve replacement. Survival is excellent during the prolonged asymptomatic phase. After the development of symptoms, however, mortality exceeds 90 percent within a few years. Aortic valve replacement prevents this rapid downhill course.



# Evaluation of AS

- Echocardiography is the most valuable test for diagnosis, quantification and follow-up of patients with AS.
- Two measurements obtained are:
  - a) Left ventricular size and function: LVH, Dilation, and EF
  - b) Doppler derived gradient and valve area (AVA)

# Evaluation of AS

TABLE 12-1		Grading of severity of AS	
Severity of AS	AVA	Velocity	
Mild	$>1.5 \text{ cm}^2$	2.6–3.0 m/s	
Moderate	$1.0\text{--}1.5 \text{ cm}^2$	3.0–4.0 m/s	
Severe	$<1.0 \text{ cm}^2$	$>4.0 \text{ m/s}$	

**Cardiac catheterization:** Should only be done for a direct measurement if symptom severity and echo severity don't match OR prior to replacement when replacement is planned.

# Management of AS

- **General-** IE prophylaxis in dental procedures with a prosthetic AV or history of endocarditis.
- **Medical** - limited role since AS is a mechanical problem. Vasodilators are *relatively contraindicated* in severe AS
- **Aortic Balloon Valvotomy-** shows little benefit.
- **Surgical Replacement:** Definitive treatment

# Echo Surveillance

- **Mild:** Every 5 years
- **Moderate:** Every 2 years
- **Severe:** Every 6 months to 1 year

**TABLE 12-3****Indications for AVR in AS****Class I**

1. Symptomatic patients with severe AS
2. Patients with severe AS undergoing CABG, or surgery on aorta/other valves
3. Patients with severe AS and depressed LVEF ( $<50\%$ )

**Class II**

1. Patients with moderate AS undergoing CABG, surgery of the aorta, or other heart valves (IIa)
2. Asymptomatic patients with severe AS and
  - Abnormal response to exercise (symptoms or hypotension) (IIb)
  - Critical AS (valve area  $<0.6\text{ cm}^2$ , mean gradient  $>60\text{ mm Hg}$ , aortic jet velocity  $>5\text{ m/s}$ )
  - High likelihood of rapid progression (age, calcification, CAD)

# **Simplified Indications for Surgery in Aortic Stenosis**

- Any SYMPTOMATIC patient with severe AS (includes symptoms with exercise)
- Any patient with decreasing EF
- Any patient undergoing CABG with moderate or severe AS

# Summary

- Disease of aging
- Look for the signs on physical exam
- Echocardiogram to assess severity
- Asymptomatic: Medical management and surveillance
- Symptomatic: AoV replacement (even in elderly and CHF)

# Mitral Stenosis

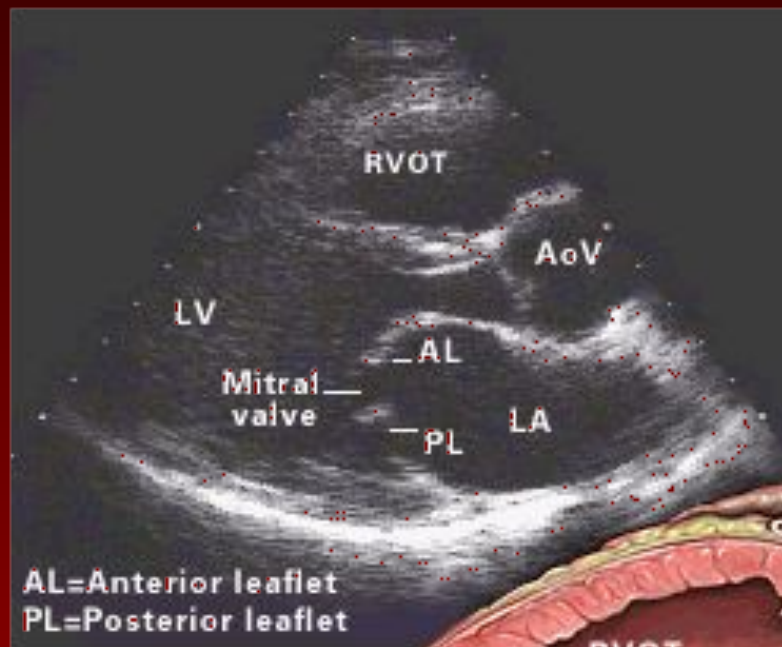


# Mitral Stenosis Overview

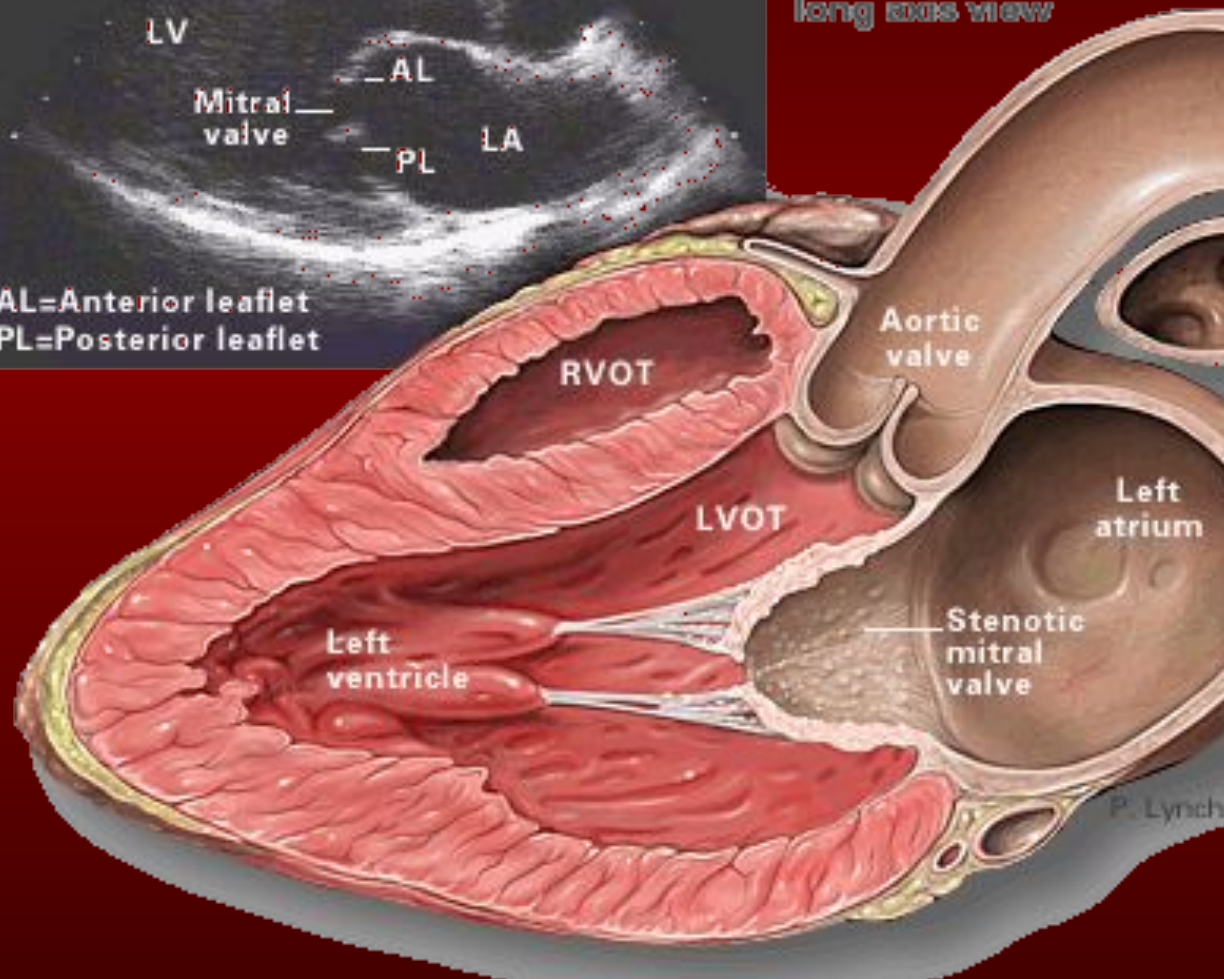
- **Definition:** Obstruction of LV inflow that prevents proper filling during diastole
- **Normal MV Area:** 4-6 cm<sup>2</sup>
- Transmitral gradients and symptoms begin at areas less than 2 cm<sup>2</sup>
- Rheumatic carditis is the predominant cause
- **Prevalence and incidence:** decreasing due to a reduction of rheumatic heart disease.

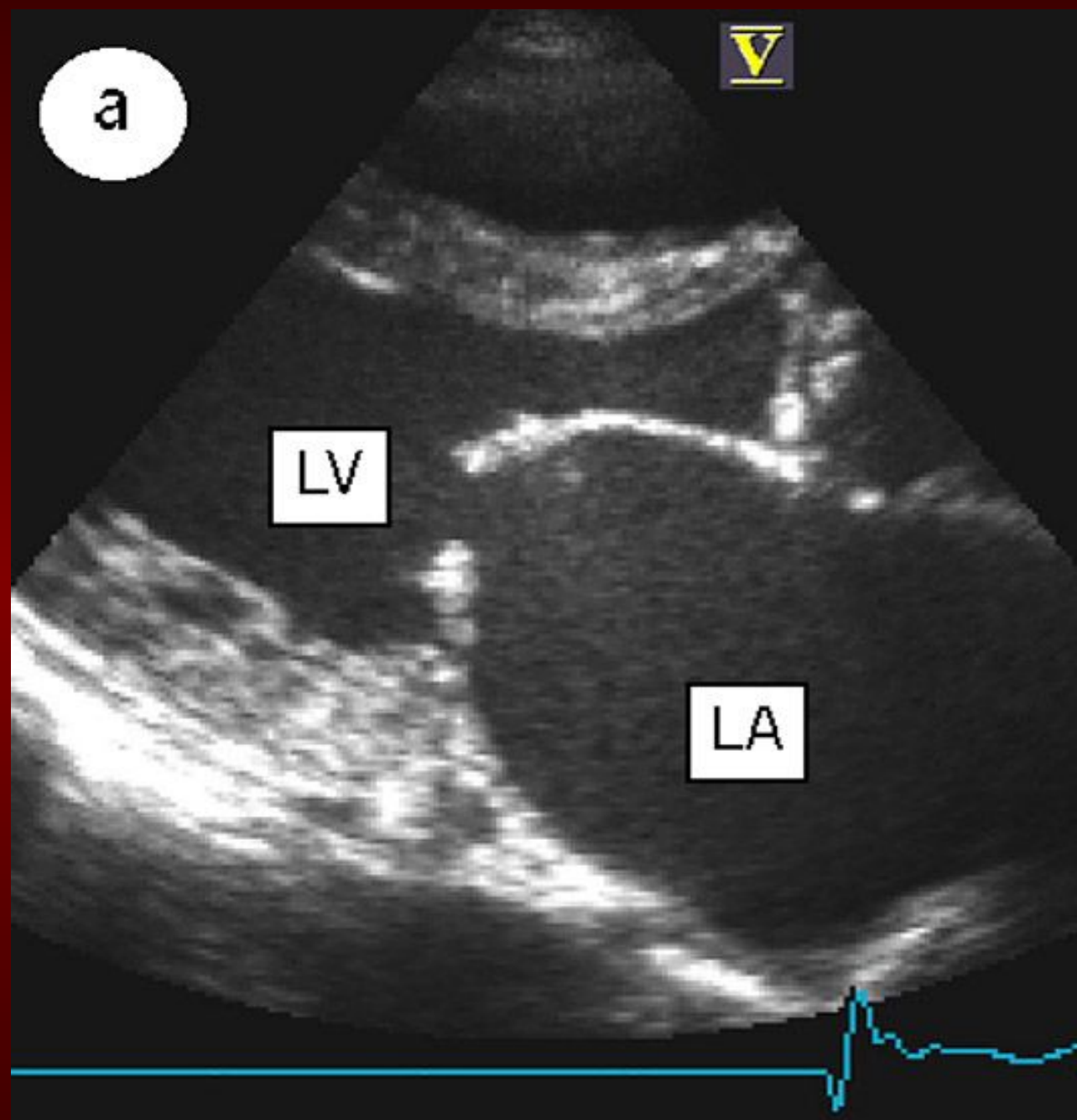
# Etiology of Mitral Stenosis

- Rheumatic heart disease: 77-99% of all cases
- Infective endocarditis: 3.3%
- Mitral annular calcification: 2.7%

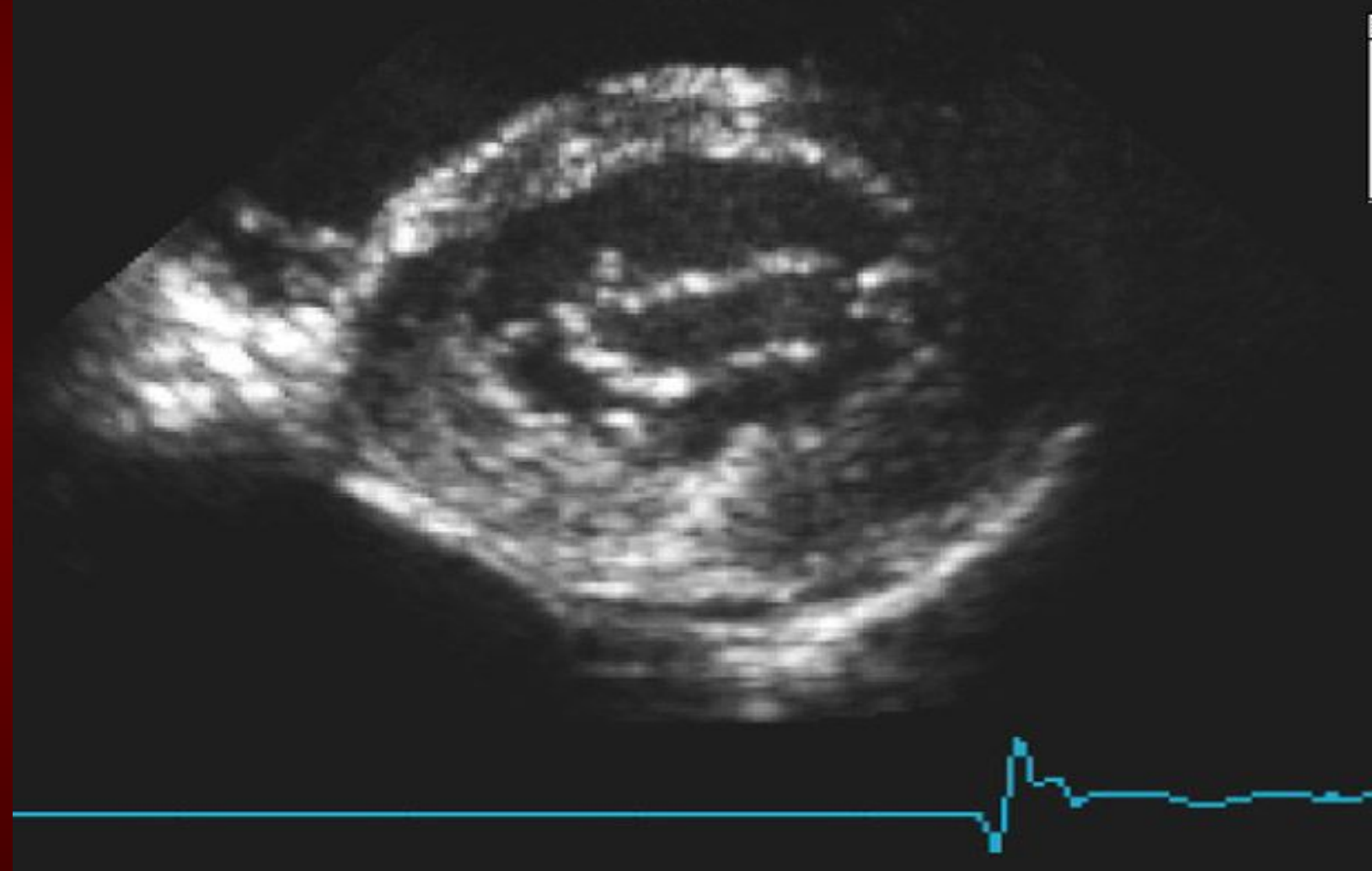


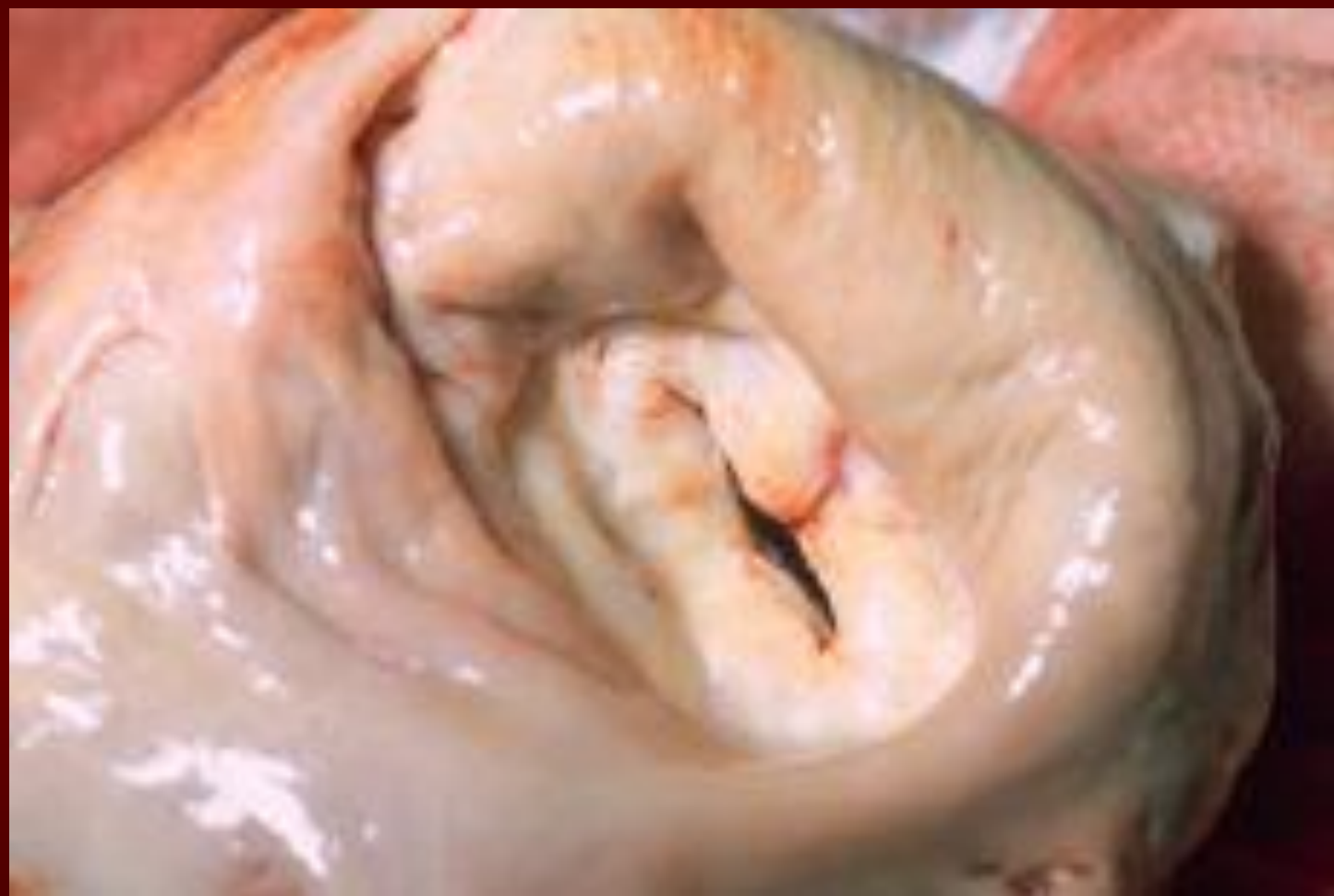Left parasternal  
long axis view





b





# MS Pathophysiology

- **Progressive Dyspnea (70 %):** LA dilation □ pulmonary congestion (reduced emptying)
  - worse with exercise, fever, tachycardia, and pregnancy
- **Increased Transmitral Pressures:** Leads to left atrial enlargement and atrial fibrillation.
- **Right heart failure symptoms:** due to Pulmonary venous HTN
- **Hemoptysis:** due to rupture of bronchial vessels due to elevated pulmonary pressure

# Natural History of MS

- **Disease of plateaus:**
  - Mild MS: 10 years after initial RHD insult
  - **Moderate:** 10 years later
  - **Severe:** 10 years later
- **Mortality:** Due to progressive pulmonary congestion, infection, and thromboembolism.



# Physical Exam Findings of MS

- **prominent "a" wave in jugular venous pulsations:** Due to pulmonary hypertension and right ventricular hypertrophy
- **Signs of right-sided heart failure:** in advanced disease
- **Mitral facies:** When MS is severe and the cardiac output is diminished, there is vasoconstriction, resulting in pinkish-purple patches on the cheeks

# Heart Sounds in MS

- **Diastolic murmur:**
  - Low-pitched diastolic rumble most prominent at the apex.
  - Heard best with the patient lying on the left side in held expiration
  - Intensity of the diastolic murmur does not correlate with the severity of the stenosis

# Heart Sounds in MS

- **Loud Opening S<sub>1</sub> snap:** heard at the apex when leaflets are still mobile
  - Due to the abrupt halt in leaflet motion in early diastole, after rapid initial rapid opening, due to fusion at the leaflet tips.
  - **A shorter S2 to opening snap interval indicates more severe disease.**

# Evaluation of MS

- **ECG:** may show atrial fibrillation and LA enlargement
- **CXR:** LA enlargement and pulmonary congestion. Occasionally calcified MV
- **ECHO:** The *GOLD STANDARD* for diagnosis. Asses mitral valve mobility, gradient and mitral valve area

**TABLE 12-11****Severity of MS**

Severity of MR	Mild	Moderate	Severe
<b>Parameter</b>			
Mean gradient (mm Hg)	<5	5–10	>10
PA systolic pressure (mm Hg)	<30	30–50	>50
Valve area (cm <sup>2</sup> )	>1.5	1.0–1.5	<1.0

# Management of MS

## Serial echocardiography:

- Mild: 3-5 years
- Moderate: 1-2 years
- Severe: yearly

- **Medications:** MS like AS is a mechanical problem and medical therapy does not prevent progression
  - $\beta$ -blockers, CCBs, Digoxin which control heart rate and hence prolong diastole for improved diastolic filling
  - Diuretics for fluid overload

# Management of MS

- Identify patient early who might benefit from percutaneous mitral balloon valvotomy.
- **IE prophylaxis:** Patients with prosthetic valves or a Hx of IE for dental procedures.

## **TABLE 12-13** Indications for intervention in MS

### Indications for percutaneous mitral balloon valvulotomy

#### **Class I**

1. Moderate/severe MS with NYHA II-IV symptoms with favorable morphology if no atria thrombus or moderate/severe MR
2. Asymptomatic moderate/severe MS with pulmonary HTN ( $>50$  mm Hg at rest,  $>60$  mm Hg with exercise) if morphology is favorable and no concomitant left atrial thrombus/significant MR

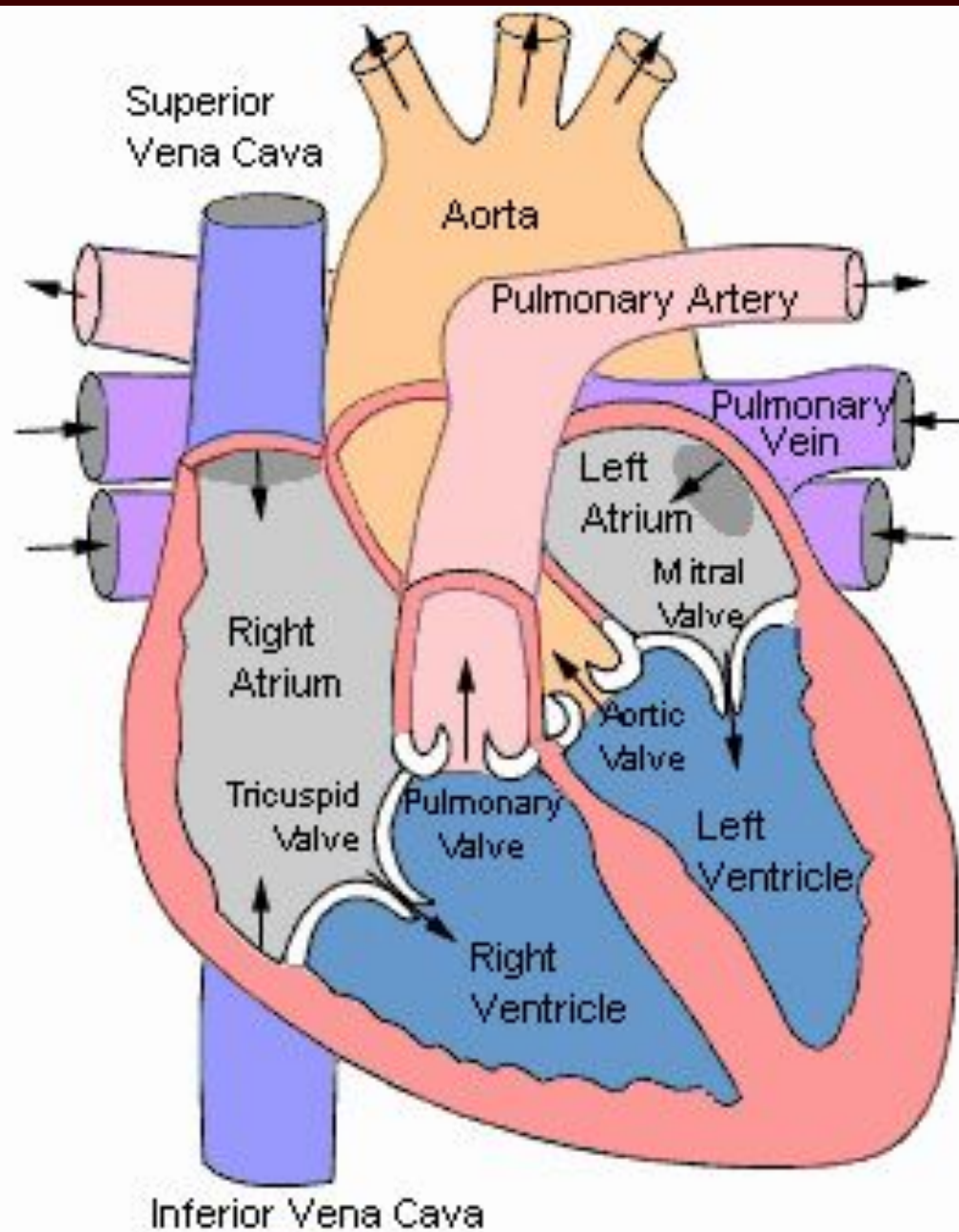
#### **Class II**

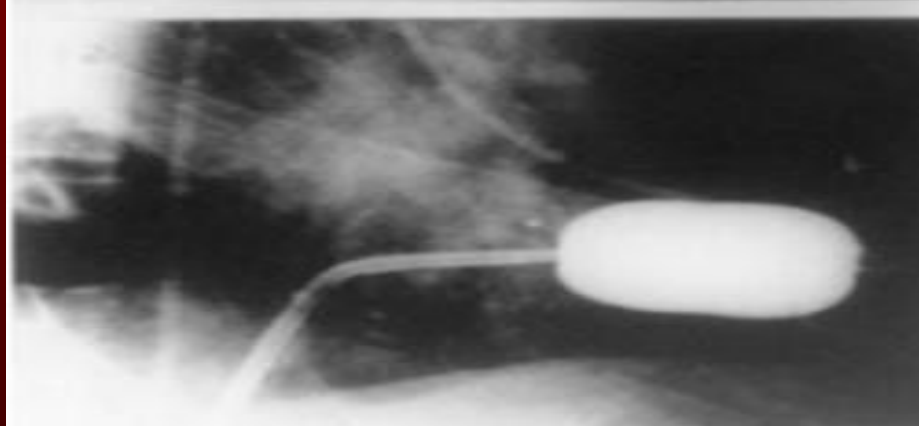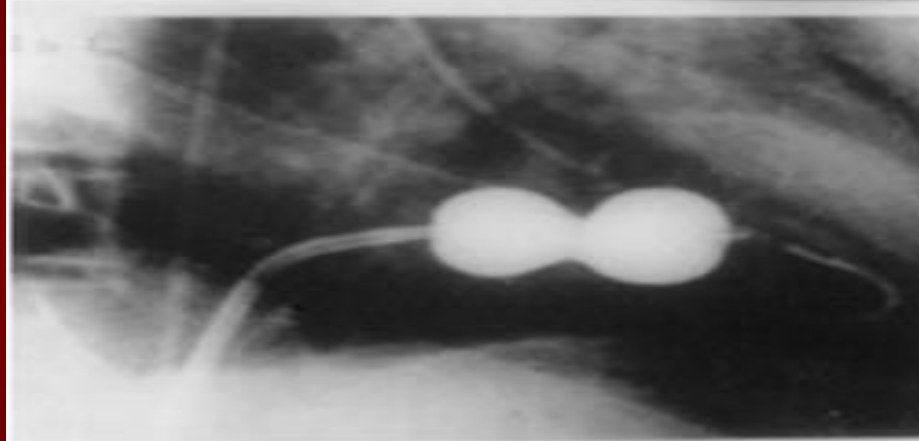
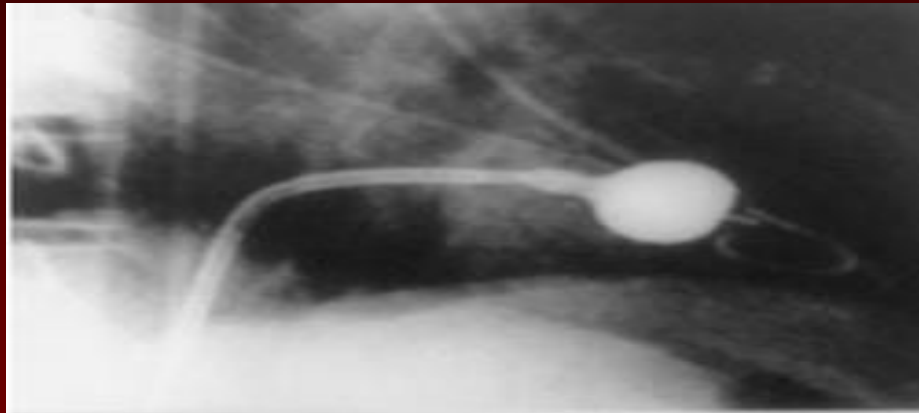
1. Symptomatic (NYHA II-IV) moderate/severe MS with nonpliable calcified valve if NOT a candidate for surgical intervention or high risk for surgery
2. Symptomatic patients (NYHA II-IV) with valve area  $>1.5$  cm<sup>2</sup> if there is evidence of pulmonary HTN ( $>50$  mm Hg at rest and  $>60$  mm Hg with exercise)
3. Asymptomatic patients with moderate/severe MS with favorable morphology with new onset AF (if no left atrial thrombus/significant MR)

#### **Class III**

1. Mild MS
2. Mild MS with left atrial thrombus, significant MR







## **TABLE 12-13**    Indications for intervention in MS

### Indications for surgery

#### **Class I**

1. Symptomatic moderate/severe MS with acceptable operative risk when (a) percutaneous mitral valvulotomy is not available or contraindicated or (b) unfavorable anatomy is present
2. Symptomatic patients with moderate/severe MS with concomitant severe MR

#### **Class II**

1. MV replacement for symptomatic patients with severe MS and severe pulmonary HTN who are not candidates for percutaneous intervention or surgical commissurotomy
2. MV repair for asymptomatic patients with moderate or severe MS who have had recurrent embolic events while receiving adequate anticoagulation with favorable anatomy for repair

#### **Class III**

1. MV repair is not indicated in mild MS

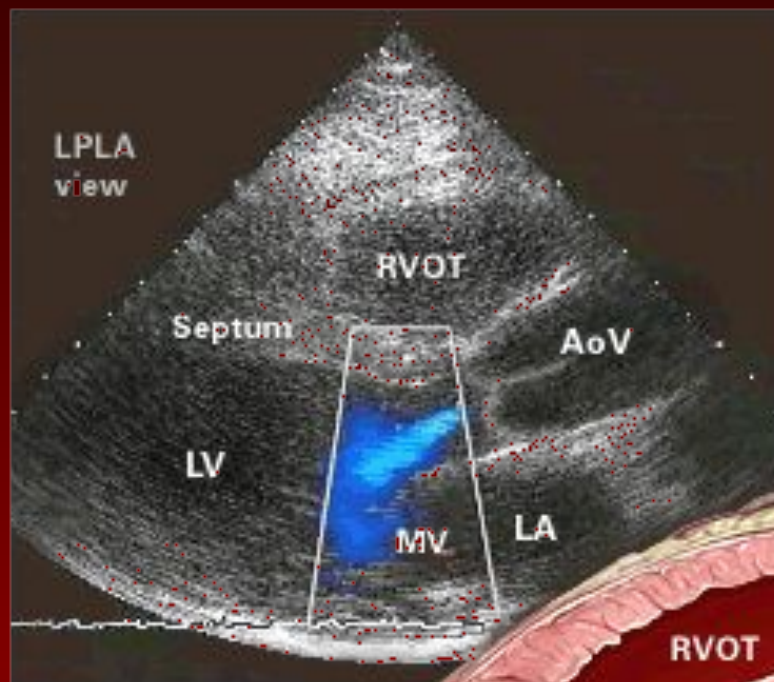
---

Adapted from AHA/ACC 2006 Guidelines on Management of Patients with Valvular Heart Disease.<sup>1</sup>

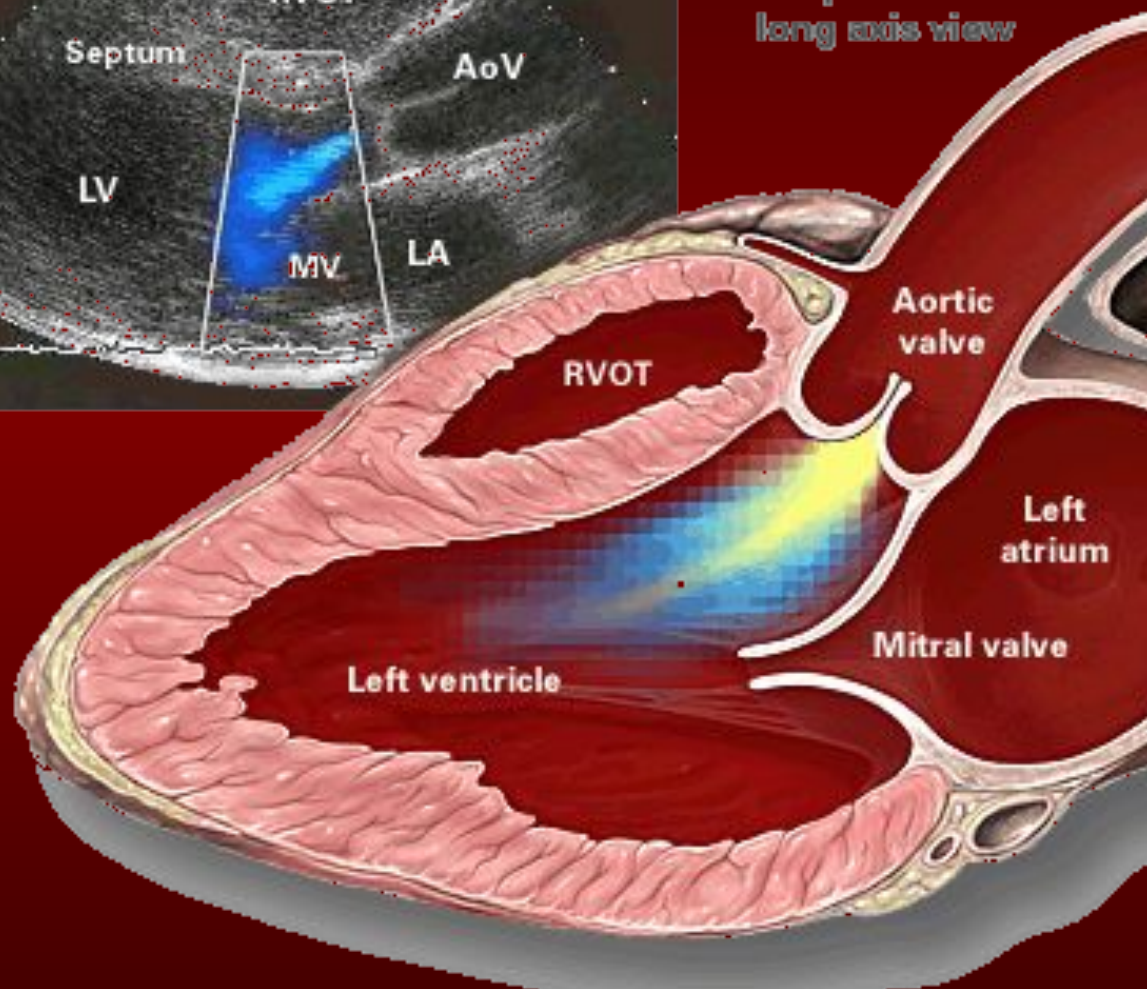
# **Simplified Indications for Mitral valve replacement**

- **ANY SYMPTOMATIC Patient with NYHA Class III or IV Symptoms**
- **Asymptomatic moderate or Severe MS with a pliable valve suitable for PMBV**

# Aortic Regurgitation



Left parasternal  
long axis view





# Aortic Regurgitation Overview

- **Definition:** Leakage of blood into LV during diastole due to ineffective coaptation of the aortic cusps

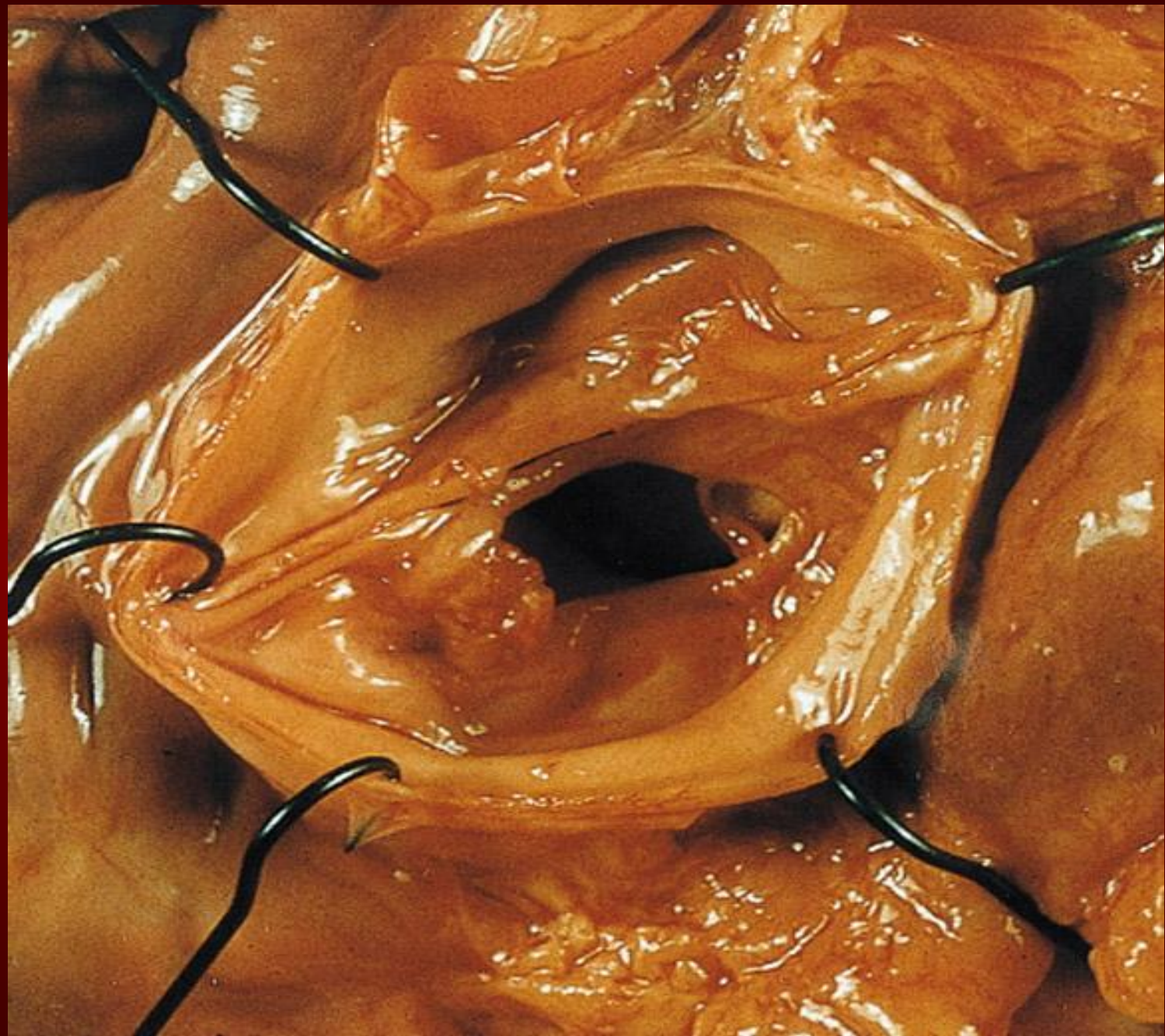# **Etiology of Acute AR**

- Endocarditis
- Aortic Dissection
- **Physical Findings:**
  - Wide pulse pressure
  - Diastolic murmur
  - Florid pulmonary edema



# Treatment of Acute AR

- True Surgical Emergency:
- Positive inotrope: (eg, dopamine, dobutamine)
- Vasodilators: (eg, nitroprusside)
- Avoid beta-blockers
- Do not even consider a balloon pump



# Etiology of Chronic AR

- Bicuspid aortic valve
- Rheumatic
- Infective endocarditis

# Pathophysiology of AR

- Combined pressure AND volume overload
- **Compensatory Mechanisms:** LV dilation, LVH. Progressive dilation leads to heart failure

# Natural History of AR

- **Asymptomatic until 4<sup>th</sup> or 5<sup>th</sup> decade**
- **Rate of Progression: 4-6% per year**
- **Progressive Symptoms include:**
  - **Dyspnea:** exertional, orthopnea, and paroxysmal nocturnal dyspnea
  - **Nocturnal angina:** due to slowing of heart rate and reduction of diastolic blood pressure
  - **Palpitations:** due to increased force of contraction

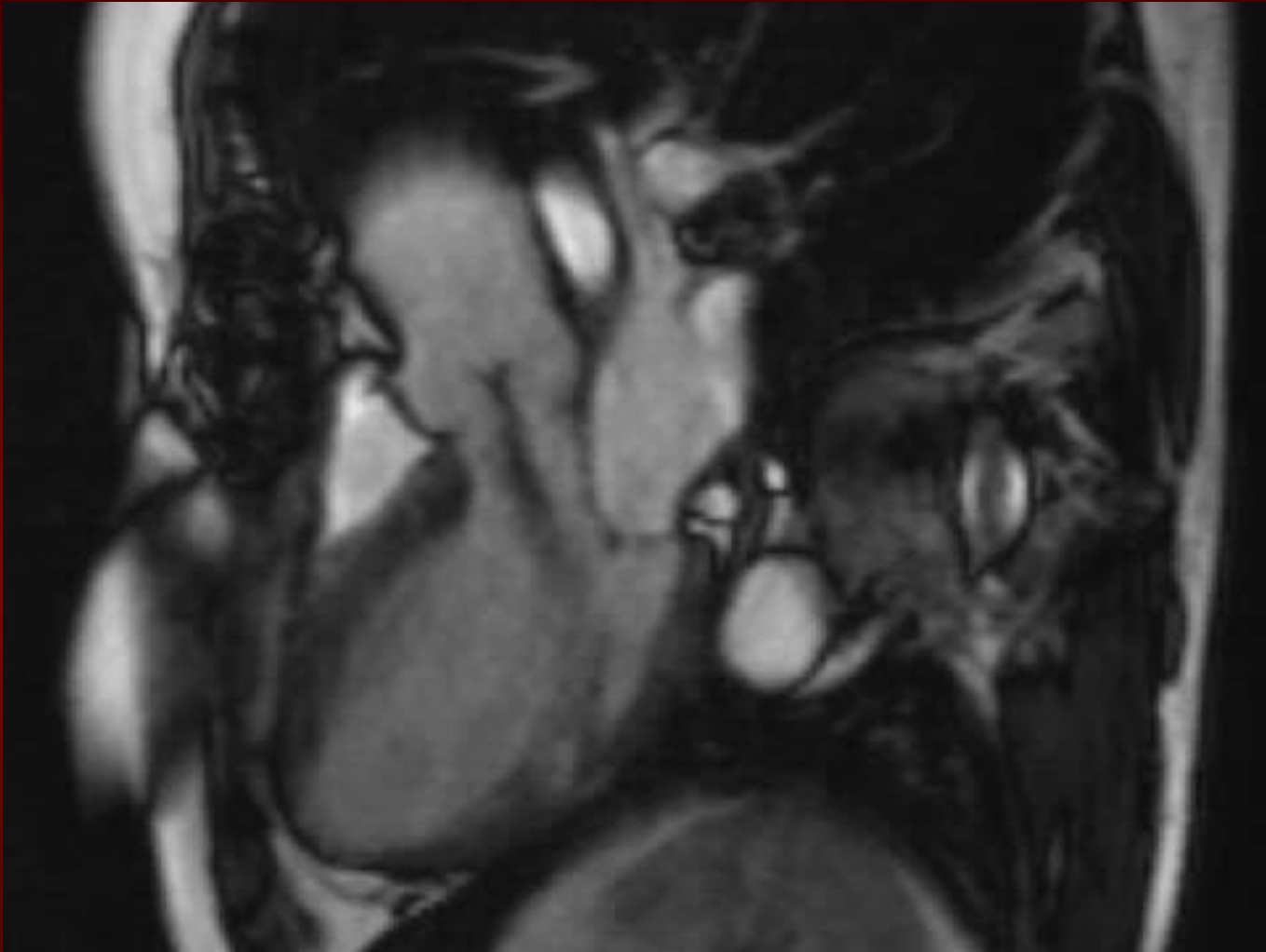
# Physical Exam findings of AR

- **Wide pulse pressure:** most sensitive
- Hyperdynamic and displaced apical impulse
- **Auscultation-**
  - **Diastolic blowing murmur** at the left sternal border
  - *Austin flint murmur* (apex): Regurgitant jet impinges on anterior MVL causing it to vibrate
  - *Systolic ejection murmur*: due to increased flow across the aortic valve



**TABLE 12-6****Auscultatory and peripheral findings in severe AR: A glossary of eponyms**

Sign	Description
Austin Flint murmur <sup>a</sup>	Low-pitched apical mid-diastolic rumble
Corrigan pulse <sup>a</sup>	High-amplitude, abruptly collapsing pulse
Duroziez sign <sup>a</sup>	To-and-fro bruit over femoral artery
Hill sign <sup>a</sup>	>40 mm Hg $\Delta$ between popliteal and brachial pressures
Mayne sign	>15 mm Hg drop in SBP with arm elevation pressure
Traube sign	Loud systolic "pistol shots" over the femoral artery
Quincke pulse	Exaggerated reddening and blanching of nail beds
Mueller sign	Visible pulsations of the uvula
de Musset sign	Visible bobbing of the head



MRI of the Heart Revealing a Central, High-Velocity Jet Projecting into the Left Ventricular Cavity.

The jet clearly strikes the anterior mitral-valve leaflet, causing distortion and premature closure during diastole.



# The Evaluation of AR

- **CXR:** enlarged cardiac silhouette and aortic root enlargement
- **ECHO:** Evaluation of the AV and aortic root with measurements of LV dimensions and function (cornerstone for decision making and follow up evaluation)
- **Aortography:** Used to confirm the severity of disease

**TABLE 12-4****Grading of severity of AR**

Severity of AR	Mild	Moderate	Severe
<b>Qualitative</b>			
Angiographic grade	1+	2+	3+
Doppler central jet width	<25% LVOT	25%–65% LVOT	>65%
Vena contracta width (cm)	<0.3	0.3–0.6	LVOT >0.6
<b>Quantitative</b>			
Regurgitant volume (mL/beat)	<30	30–59	>60
Regurgitant fraction	<30%	30–49	>50
Regurgitant orifice area (cm <sup>2</sup> )	<0.1	0.1–0.29	>0.3

# Management of AR

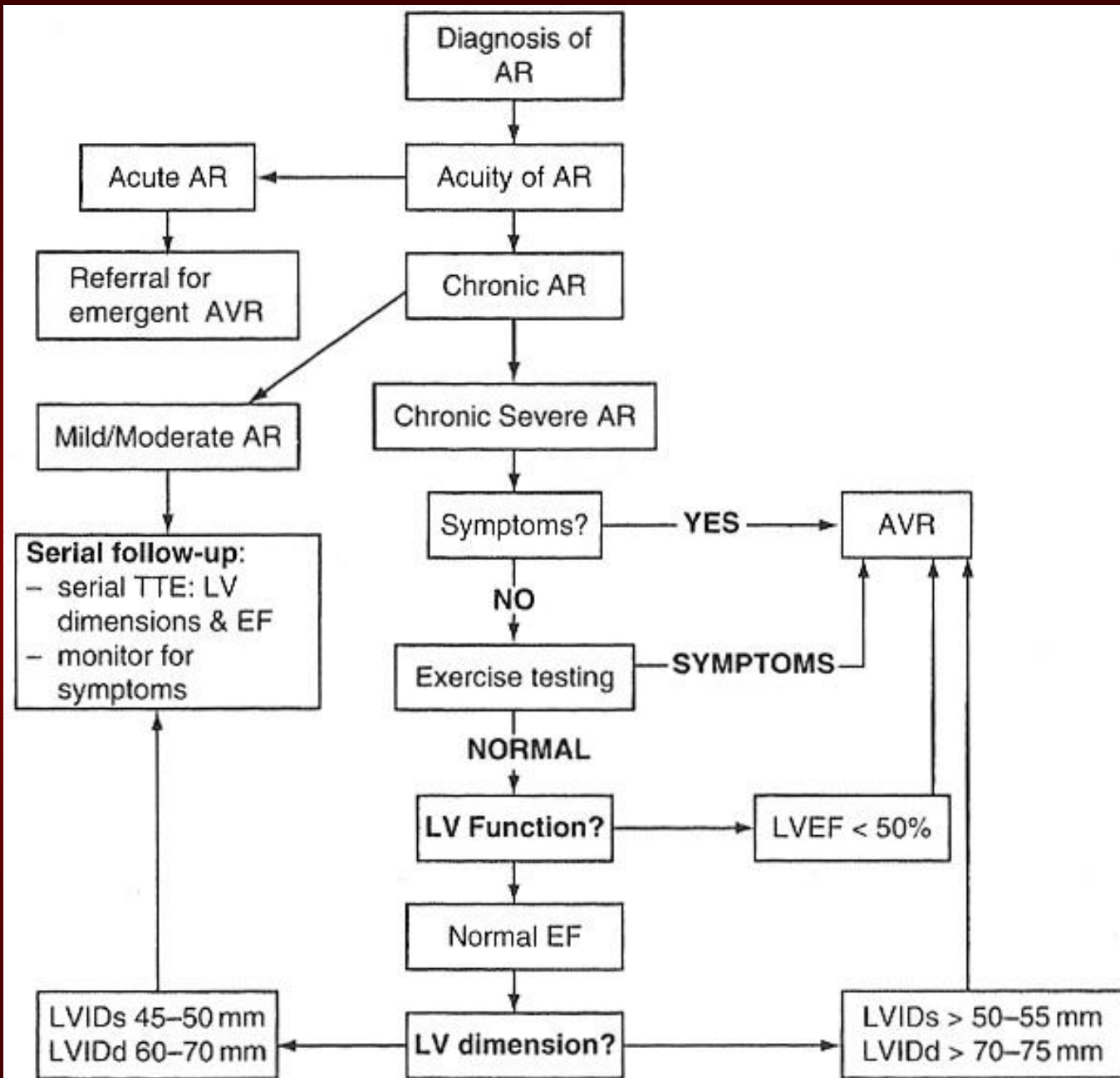
- **General:** IE prophylaxis in dental procedures with a prosthetic AV or history of endocarditis.
- **Medical:** Vasodilators (ACEI's), Nifedipine improve stroke volume and reduce regurgitation *only if pt symptomatic or HTN.*
- **Serial Echocardiograms:** to monitor progression.
- **Surgical Treatment:** Definitive Tx

**TABLE 12-7****Indications for AVR in AR****Class I**

1. Symptomatic patients with severe AR
2. Patients with severe AR undergoing CABG, or surgery on aorta/other valves
3. Asymptomatic patients with severe AR and LV dysfunction (LVEF <50%)

**Class II**

1. Asymptomatic patients with severe AR with normal LVEF but severe LV dilation (LVIDd 70–75 mm and LVIDs 50–55 mm)
2. Patients with moderate AR undergoing CABG or surgery of the aorta or other heart valves



# Simplified Indications for Surgical Treatment of AR

- ANY Symptoms at rest or exercise
- Asymptomatic treatment if:
  - EF drops below 50% or LV becomes dilated

# Mitral Regurgitation

# Chronic Mitral Regurgitation

## Overview

- **Definition:** Backflow of blood from the LV to the LA during systole
- Mild (physiological) MR is seen in 80% of normal individuals.



# Acute MR

- Endocarditis
- Acute MI:
- Malfunction or disruption of prosthetic valve

# Management of Acute MR

- **Myocardial infarction: Cardiac cath or thrombolytics**
- **Most other cases of mitral regurgitation is afterload reduction:**
  - **Diuretics and nitrates**
  - **nitroprusside, even in the setting of a normal blood pressure.**

# Management of Acute MR

- **Do not attempt to alleviate tachycardia with beta-blockers. Mild-to-moderate tachycardia is beneficial in these patients because it allows less time for the heart to have backfill, which lowers regurgitant volume.**

# Treatment of Acute MR

- Balloon Pump
- Nitroprusside even if hypotensive
- Emergent Surgery

# Etiologies of Chronic Mitral Regurgitation

- Myxomatous degeneration (MVP)
- Ischemic MR
- Rheumatic heart disease
- Infective Endocarditis

# Pathophysiology of MR

- **Pure Volume Overload**
- **Compensatory Mechanisms:** Left atrial enlargement, LVH and increased contractility
  - Progressive left atrial dilation and right ventricular dysfunction due to pulmonary hypertension.
  - Progressive left ventricular *volume overload leads to dilation* and progressive heart failure.

# Physical Exam findings in MR

- **Auscultation:** soft S1 and a **holosystolic** murmur at the apex radiating to the axilla
  - S3 (CHF/LA overload)
  - In chronic MR, the intensity of the murmur does correlate with the severity.
- **Exertion Dyspnea:** ( exercise intolerance)
- **Heart Failure:** May coincide with increased hemodynamic burden e.g., pregnancy, infection or atrial fibrillation

# The Natural History of MR

- **Compensatory phase:** 10-15 years
- Patients with asymptomatic severe MR have a 5%/year mortality rate
- Once the patient's EF becomes  $<60\%$  and/or becomes symptomatic, mortality rises sharply
- **Mortality:** From progressive dyspnea and heart failure



# Imaging studies in MR

- **ECG:** May show, LA enlargement, atrial fibrillation and LV hypertrophy with severe MR
- **CXR:** LA enlargement, central pulmonary artery enlargement.
- **ECHO:** Estimation of LA, LV size and function. Valve structure assessment
  - TEE if transthoracic echo is inconclusive

**TABLE 12-8****Grading of severity of MR**

Severity of MR	Mild	Moderate	Severe
<b>Qualitative</b>			
Angiographic grade	1+	2+	3+-4+
Doppler central jet width	<20% LA area	20%–40% LA area	>40% LA area
Vena contracta width (cm)	<0.3	0.3–0.69	>0.7
LA/LV size			Enlarged
<b>Quantitative</b>			
Regurgitant volume (mL/beat)	<30	30–59	>60
Regurgitant fraction	<30%	30–49	>50
Regurgitant orifice area (cm <sup>2</sup> )	<0.2	0.2–0.39	>0.4

# Management of MR

- **Medications**
  - a) Vasodilator such as hydralazine
  - b) Rate control for atrial fibrillation with  $\beta$ -blockers, CCB, digoxin
  - c) Anticoagulation in atrial fibrillation and flutter
  - d) Diuretics for fluid overload

# Management of MR

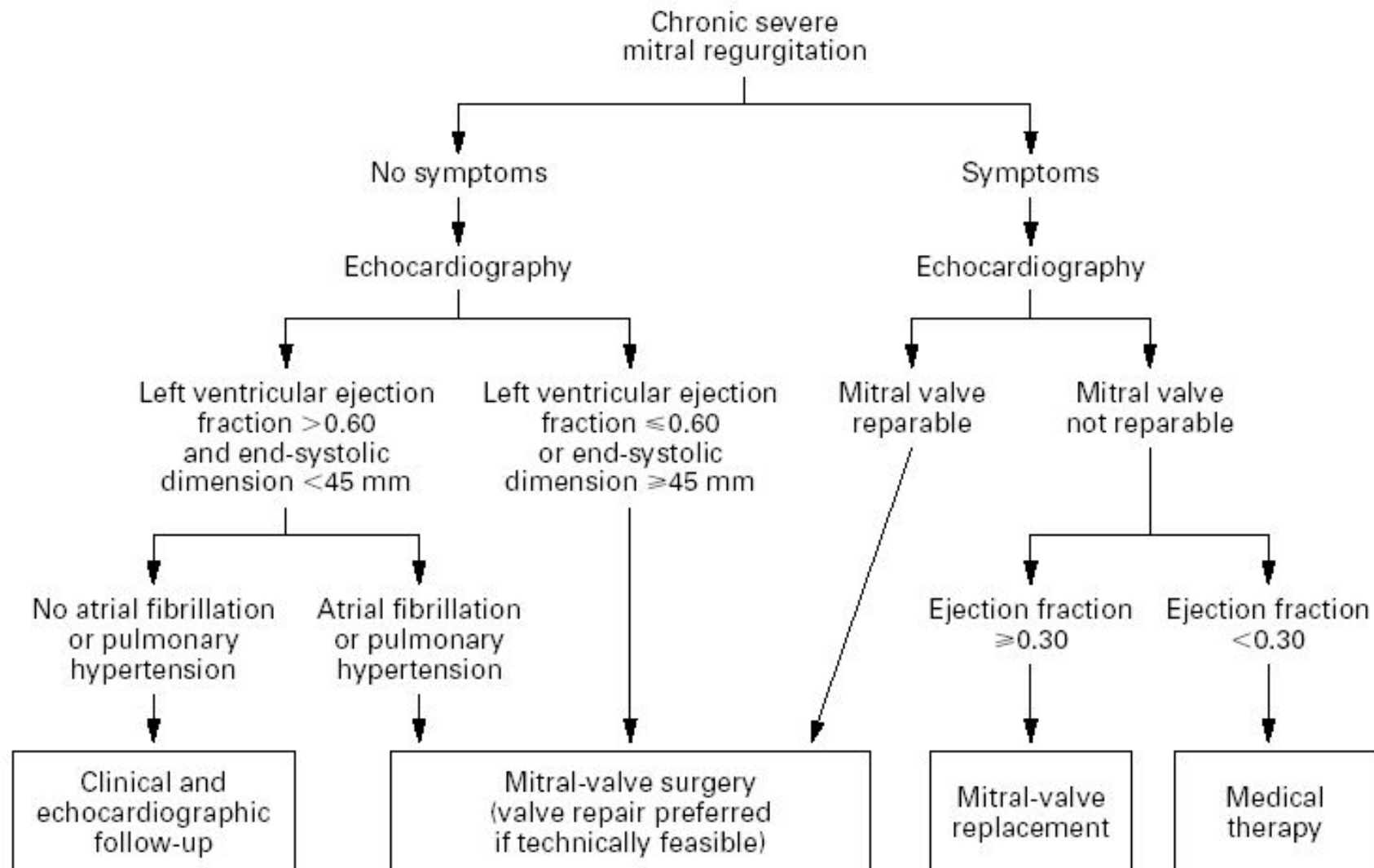
- **Serial Echocardiography:**
  - **Mild:** 2-3 years
  - **Moderate:** 1-2 years
  - **Severe:** 6-12 months
- **IE prophylaxis:** Patients with prosthetic valves or a Hx of IE for dental procedures.

**TABLE 12-10****Indications for surgical intervention in MR****Class I**

1. Acute symptomatic severe MR
2. Chronic severe MR
  - Symptomatic patients (NYHA Class II-IV) in *absence* of severe LV dysfunction (LVEF <30% and/or LVIDs >55 mm)
  - Asymptomatic patients with mild-moderate LV dysfunction (LVEF 30%-60%, LVIDs >40 mm)
3. MV repair preferable to MVR if repair is feasible

**Class II**

1. Asymptomatic chronic severe MR
  - New onset AF
  - Pulmonary HTN ( >50 mm Hg at rest, >60 mm Hg with exercise)
  - MV repair in patients with preserved LV function (LVEF >60% and LVIDs <40 mm) if likelihood of successful repair >90%
  - MV repair in patients with severe LV dysfunction (LVEF <30% and/or LVIDs >40 mm) if likelihood of successful repair >90%



**Figure 3.** Management of Chronic Severe Mitral Regurgitation.

Modified from the American College of Cardiology–American Heart Association guidelines.<sup>18</sup>

# Simplified Indications for MV Replacement in Severe MR

- ANY Symptoms at rest or exercise with (repair if feasible)
- Asymptomatic:
  - If EF <60%
  - If new onset atrial fibrillation



**THANK YOU**