



Cardiac Murmurs

Lubna Piracha, D.O.
Assistant Professor of Medicine
Department of Cardiology

What is a Murmur?

- It maybe a normal or abnormal sound that is heard secondary to turbulent blood flow.
- **Characteristics of Murmurs:**
 - Timing
 - Intensity
 - frequency
 - location

Timing and Location

- **Timing:**

- Systolic
- Diastolic
- Continuous

- **Location:**

- RUSB
- LUSB
- LLSB
- apex

Intensity and Frequency

- **High Frequency**

- MR
- TR
- AR

- **Low Frequency**

- MS
- TS

- **Intensity**

- Grade 1
- Grade 2
- Grade 3
- Grade 4
- Grade 5
- Grade 6

Maneuvers

TABLE 38-4 Systolic murmurs and maneuvers*

FINDING (REF)†	SENSITIVITY (%)	SPECIFICITY (%)	POSITIVE LR	NEGATIVE LR
Respiration				
Louder During Inspiration				
Detecting right-sided murmurs (tricuspid regurgitation or pulmonic stenosis) ^{32,46}	78-95	87-97	7.8	0.2
Changing Venous Return				
Louder with Valsalva Strain				
Detecting hypertrophic cardiomyopathy ³²	70	95	14.0	0.3
Louder with Squatting-to-Standing				
Detecting hypertrophic cardiomyopathy ³²	95	84	6.0	0.1
Softer with Standing-to-Squatting				
Detecting hypertrophic cardiomyopathy ^{32,47}	88-95	84-97	7.6	0.1
Softer with Passive Leg Elevation				
Detecting hypertrophic cardiomyopathy ³²	90	90	9.0	0.1

*Diagnostic standards: Doppler echocardiography or angiography.

†Definition of finding: See text.

Continued

Maneuvers

TABLE 38-4 Systolic murmurs and maneuvers*—cont'd

FINDING (REF)†	SENSITIVITY (%)	SPECIFICITY (%)	POSITIVE LR	NEGATIVE LR
Changing Systemic Vascular Resistance (Afterload)				
<i>Softer with Isometric Hand Grip</i>				
Detecting hypertrophic cardiomyopathy ³²	90	75	3.6	0.1
<i>Louder with Isometric Hand Grip</i>				
Detecting mitral regurgitation or ventricular septal defect ^{32,33}	70-76	78-93	5.8	0.3
<i>Louder with Transient Arterial Occlusion</i>				
Detecting mitral regurgitation or ventricular septal defect ³²	79	98	48.7	0.2
<i>Softer with Amyl Nitrite Inhalation</i>				
Detecting mitral regurgitation or ventricular septal defect ^{32,33,48,49}	41-95	89-95	10.5	0.2

*Diagnostic standards: Doppler echocardiography or angiography.

†Definition of finding: See text; for amyl nitrite inhalation, the test was interpretable only if it induced tachycardia.

Case Studies

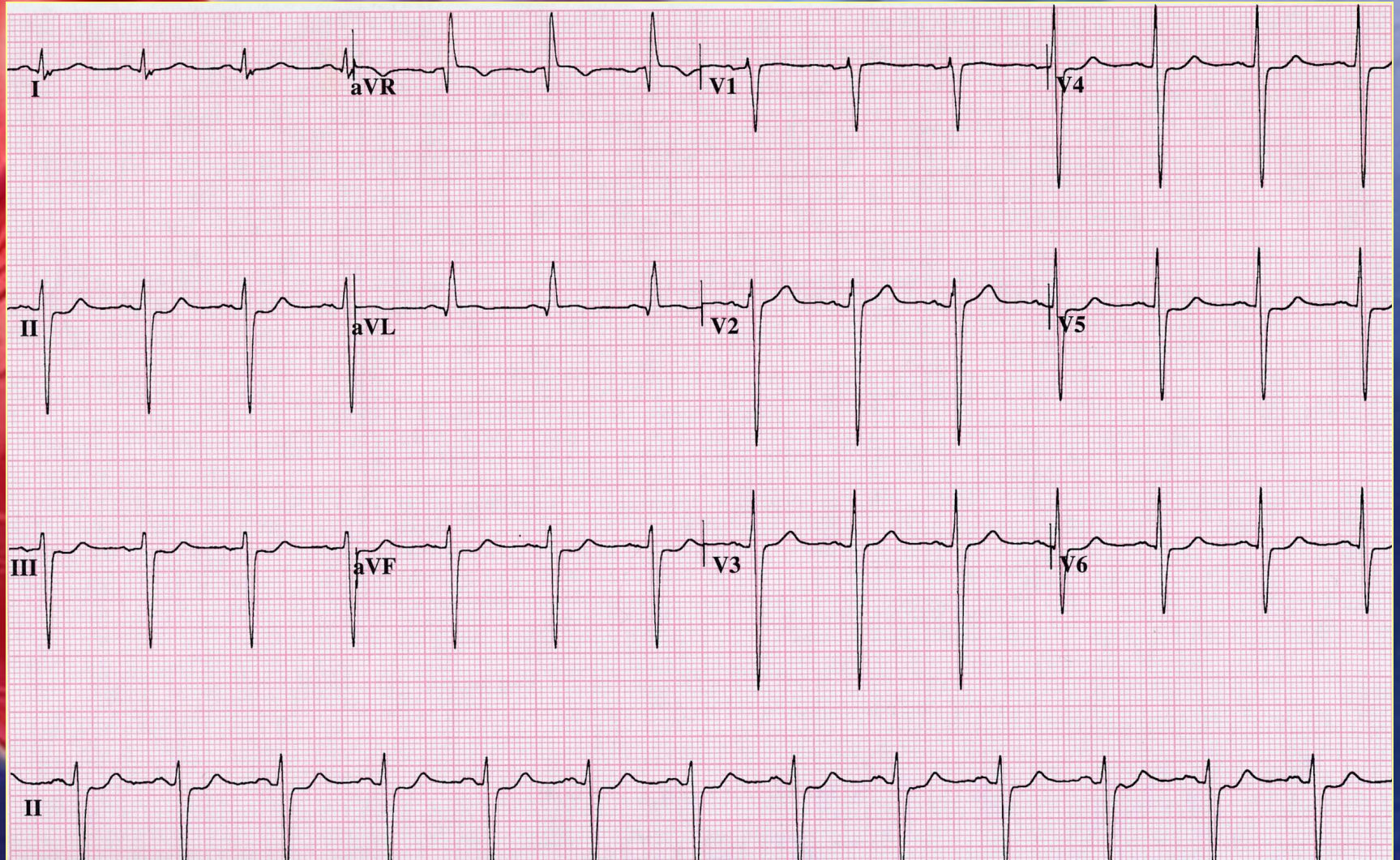
- A 50 year old male with a known heart murmur presents with complaints of substernal chest pain, which increases with exertion, and shortness of breath which is starting to limit his lifestyle. No risk factors for coronary artery disease.
 - On Physical Exam you find the following:
 - Delayed carotid upstroke
 - A sustained apical pulse
 - Prominent A wave in the neck
 - PMI is sustained but not displaced laterally
 - and you hear

Physical Exam in AS

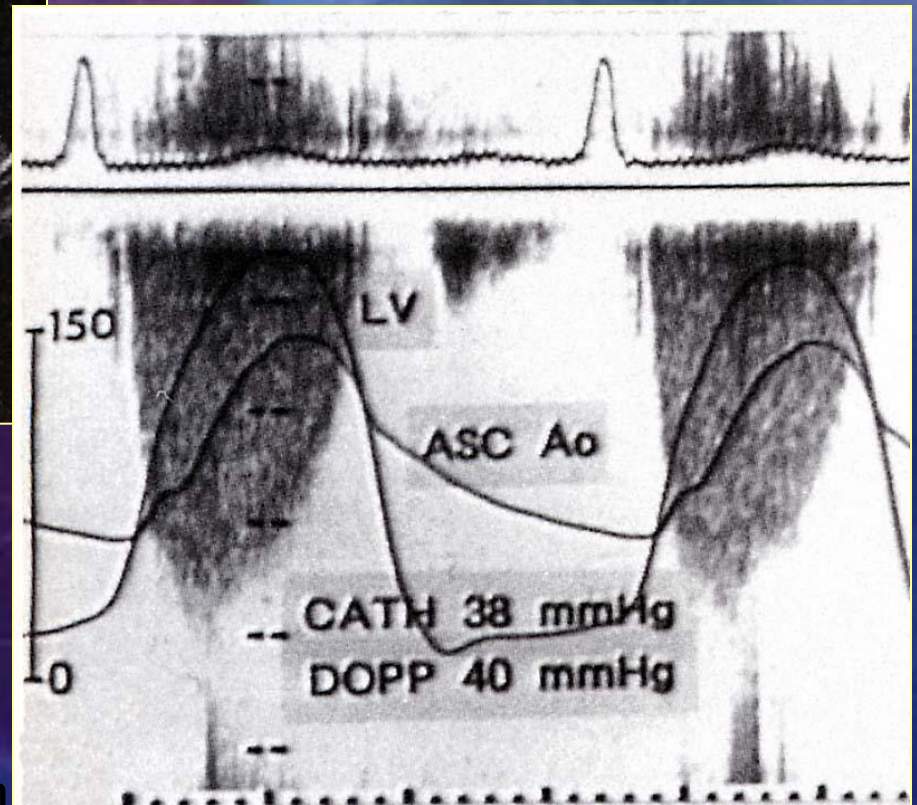
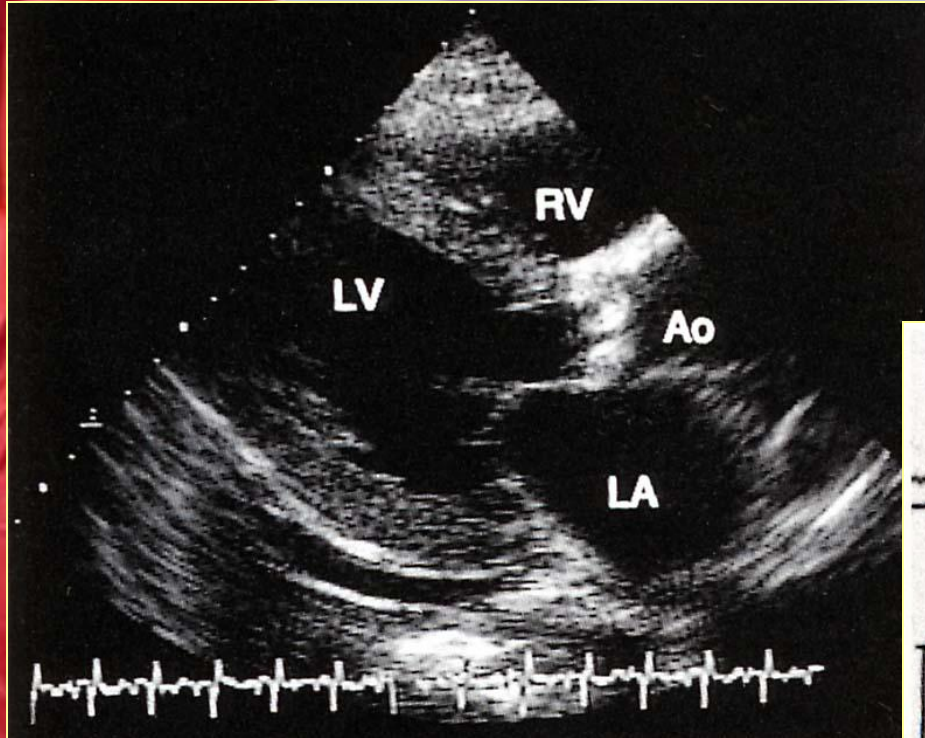
PHYSICAL EXAMINATION IN AS

	SEVERITY OF AS		
	<u>MILD</u>	<u>MODERATE</u>	<u>SEVERE</u>
Arterial pulse	Normal	Slowly rising	Parvus et tardus
Jugular venous pulse	Normal	Normal	Usually normal
Carotid thrill	±	±	±
Cardiac impulse	Normal	Heaving	Heaving, sustained
Precordial thrill	±	±	Palpable a wave Usually ++
Auscultation			
S ₄	-	±	++
ESC	+	±	-
Peak of ESM	Early systole	Mid systole	Late systole
S ₂	Normal	Normal or single	Single or paradoxical

EKG shows



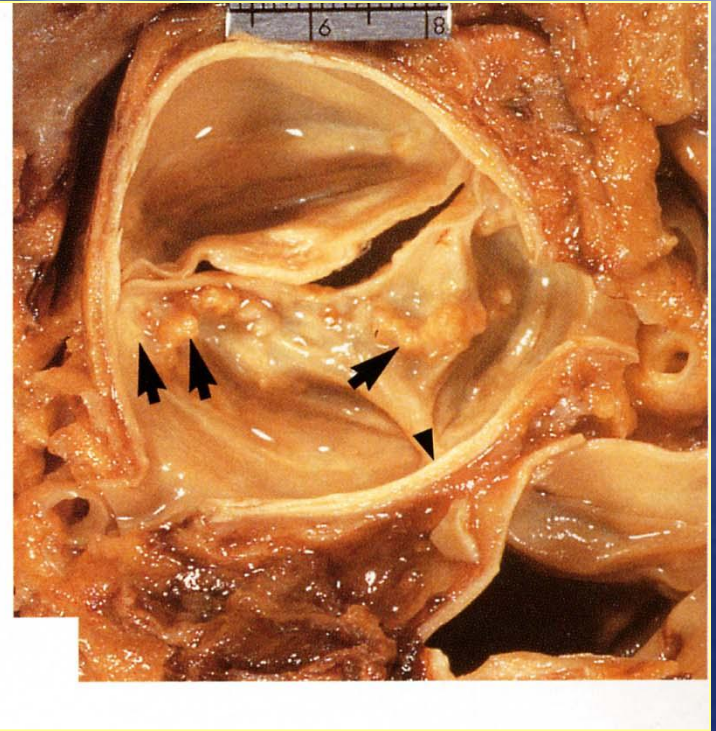
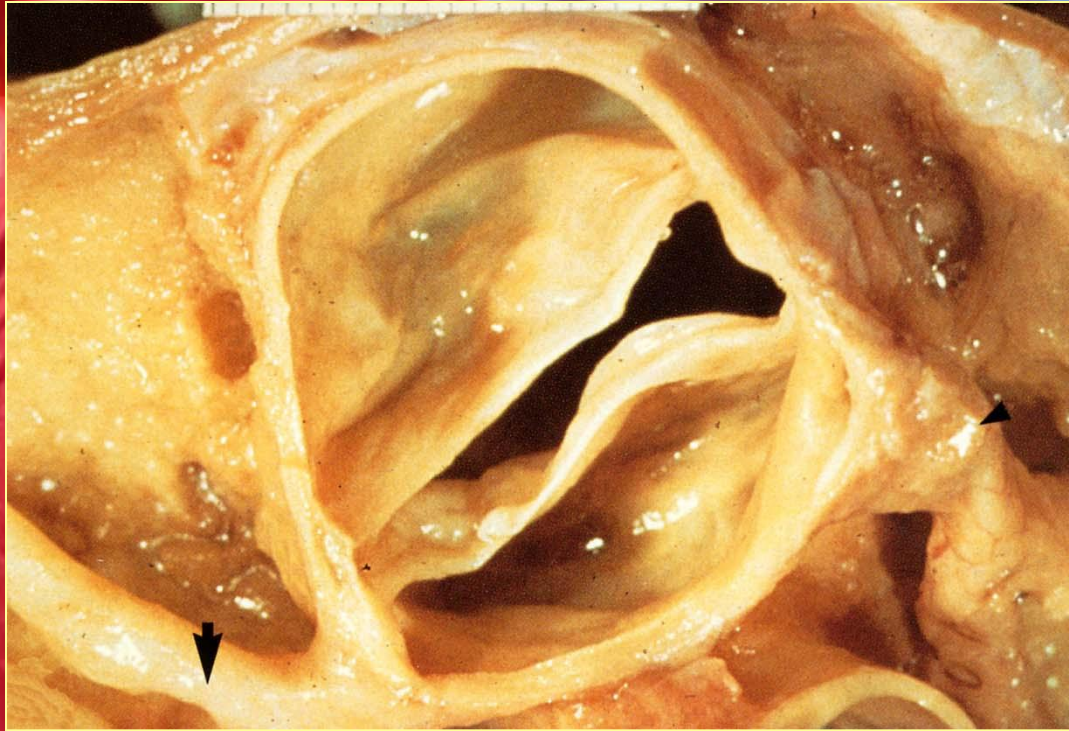
Echocardiography



11/12/02

Lubna Pira

Aortic Stenosis



A human heart is shown in the foreground on the left side, rendered in a realistic red color. The background is a soft-focus image of a person's hands raised in a gesture of praise or prayer, with a blue and purple color palette. The overall scene is dimly lit, with a bright light source from the top left creating a glow.

Aortic Stenosis

There is little hemodynamic disturbance that occurs as the valve area is reduced from 3 to 4 cm² to 1.5 to 2 cm². However, an additional reduction in the valve area from half its normal size to a quarter of its normal size produces severe obstruction to flow and progressive pressure overload on the left ventricle.

Aortic Stenosis continued:

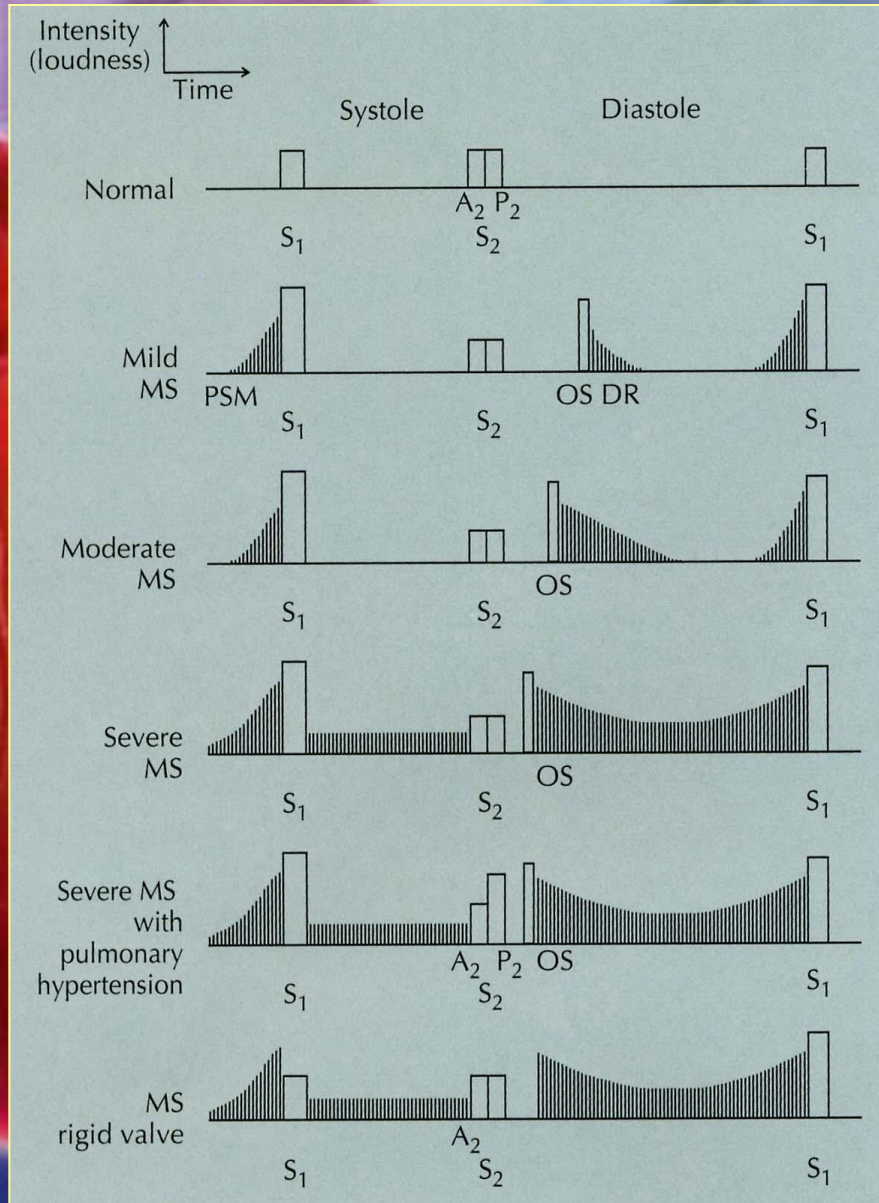
- Concentric hypertrophy develops in response to this overload. The increased muscle mass allows the ventricle to generate the increased force necessary to propel blood past the obstruction. The hypertrophied myocardium has decreased coronary blood flow reserve and can cause systolic and diastolic failure.
- Patients may present with symptoms:
 - Angina: 35% of patients with severe AS present with chest pain and half will die in 5 years.
 - Syncope: 15% of patients with severe AS present with syncope and half will die in 3 years.
 - CHF: 50% of patients with severe AS present with CHF and half will die in 2 years.



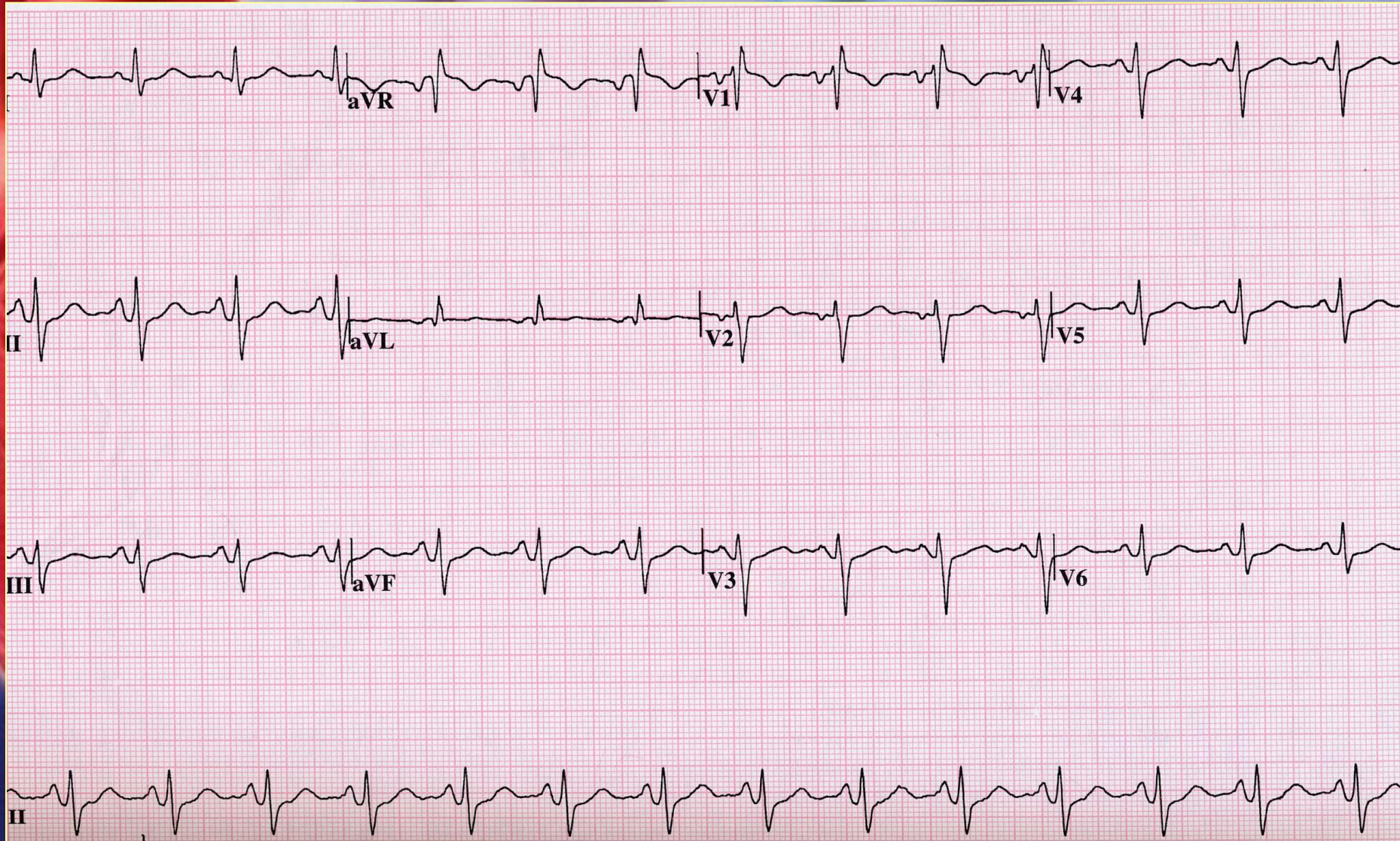
Case Study:

- A 45 year old male with a history of rheumatic fever presents with progressive shortness of breath and dyspnea on exertion and is progressively getting worse. He has also developed intermittent complaints of palpitations.
- On exam:
 - Increased respiratory rate
 - Normal PMI
 - RV lift
 - Increased JVP
 - Crackles on lung exam
 - You hear this upon auscultation


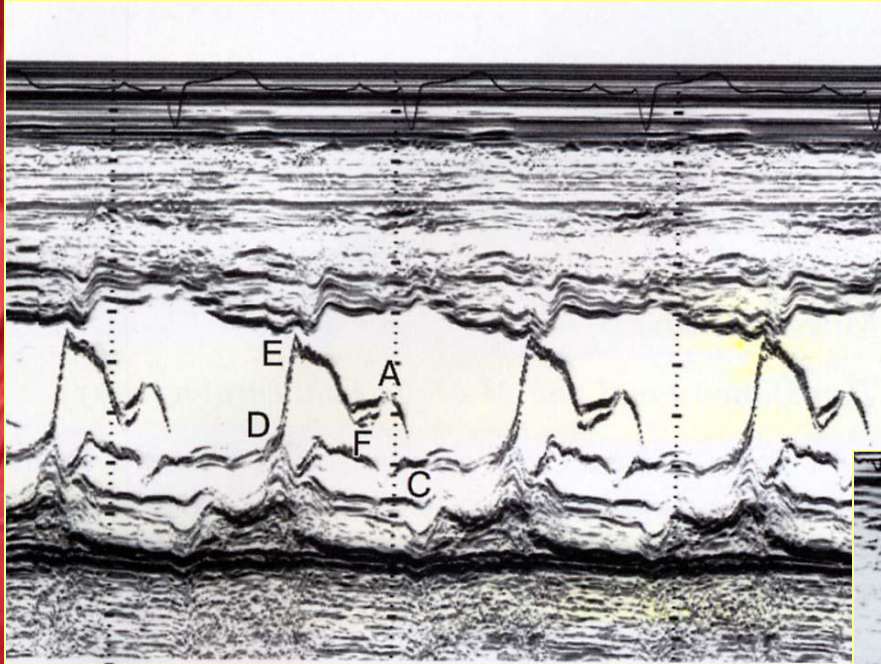
Physical Exam Review:



EKG Findings:



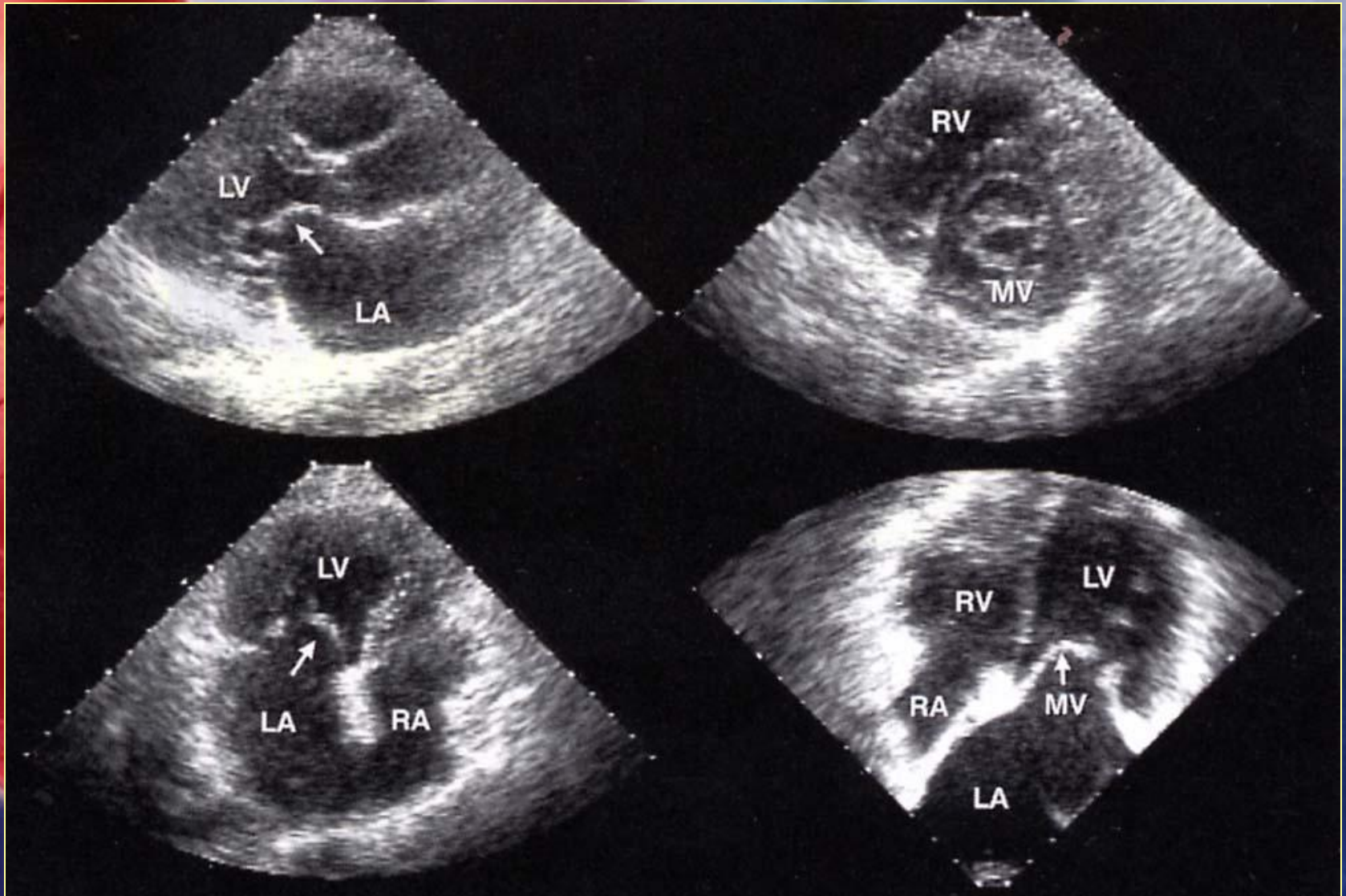
Echocardiography



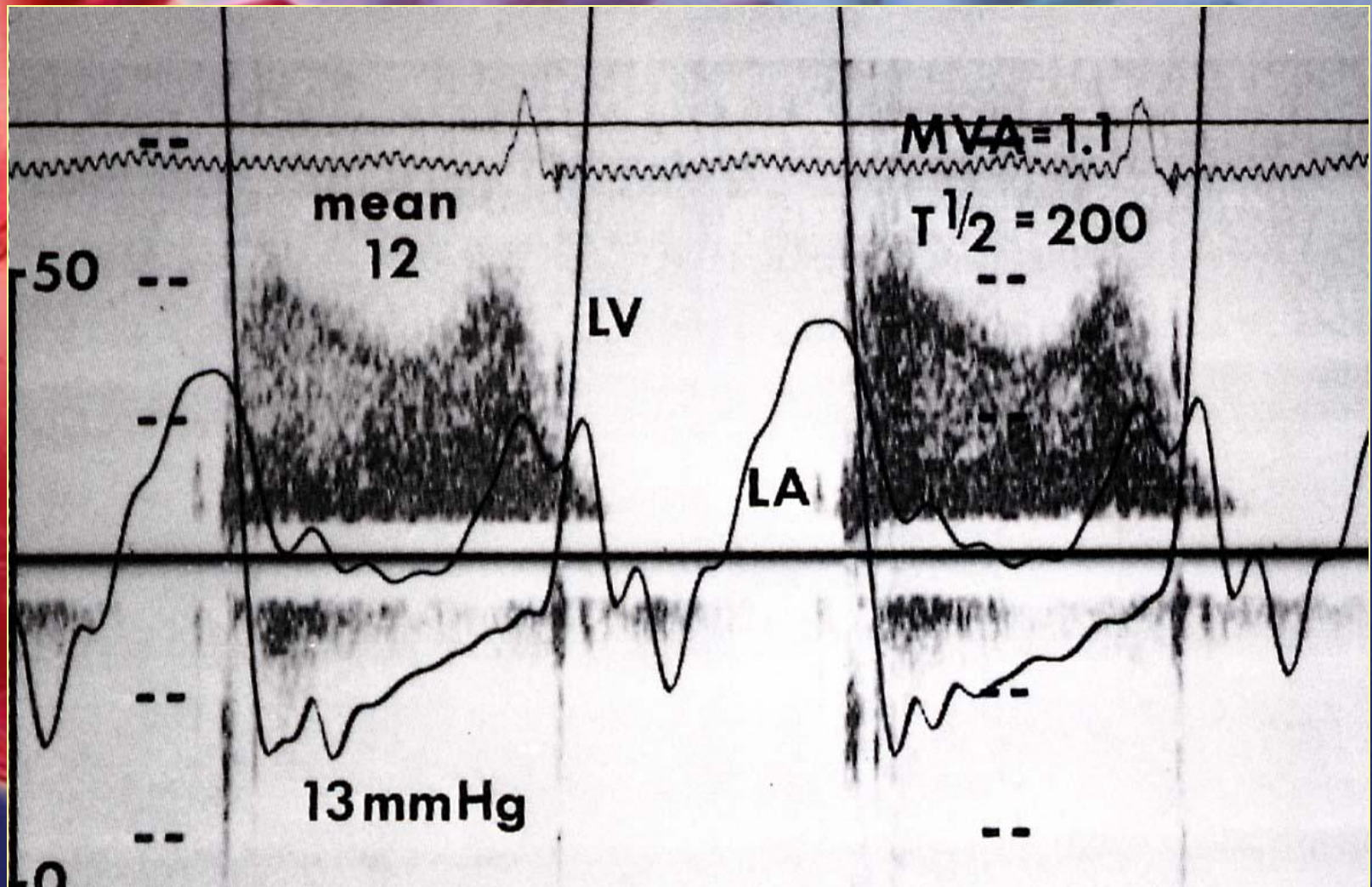
11/12/02

Lubna Pi

Echocardiography



Echocardiography



Mitral Stenosis

In severe mitral stenosis the left ventricle is spared and tends to be small and under filled. There is significant elevation in the left atrial pressures leading to left atrial enlargement which then gets transmitted to the pulmonary circulation leading to pulmonary edema and pulmonary hypertension. The left atrial enlargement can lead to atrial fibrillation and loss of atrial kick and decreased filling of the left ventricle. Systemic embolic events are seen in approximately one-third of patients with atrial fibrillation and mitral stenosis and maybe the presenting event before the diagnosis of mitral stenosis is made.

Case Studies:

A 52 year old female presents with complaints of slowly progressive dyspnea on exertion and an uncomfortable awareness of pulsations in the neck and chest.

On Exam you find the following:

- Abnormal brisk pulses
- Wide pulse pressures
- Quincke's pulse
- Head bobbing
- Pistol shot sounds

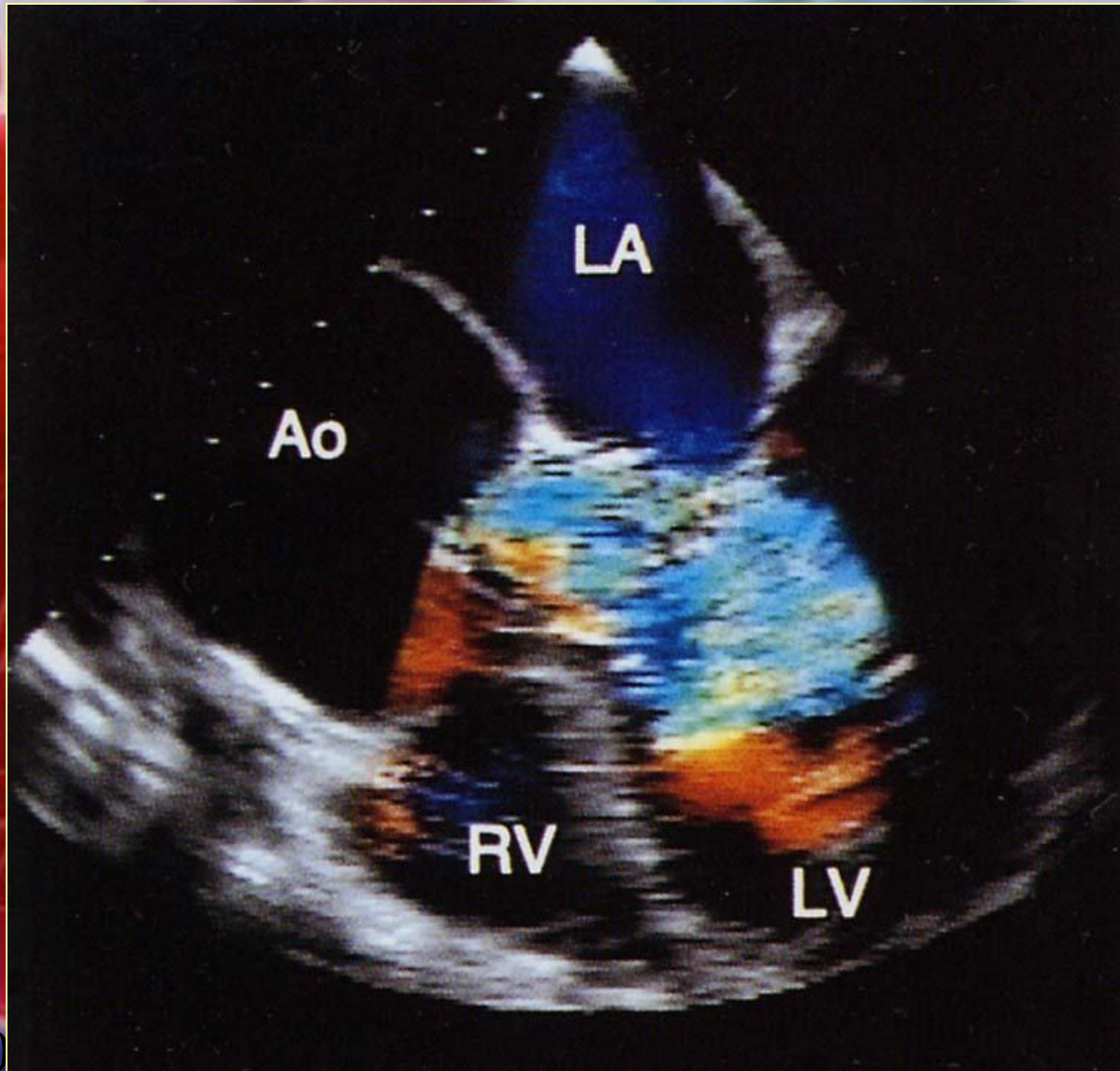
On auscultation you hear this:

Physical Exam Review



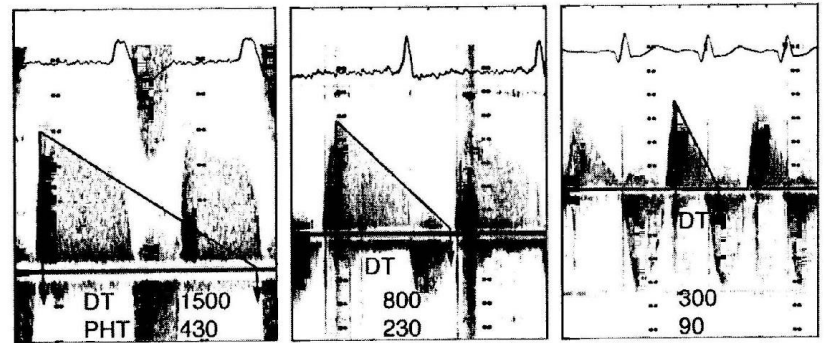
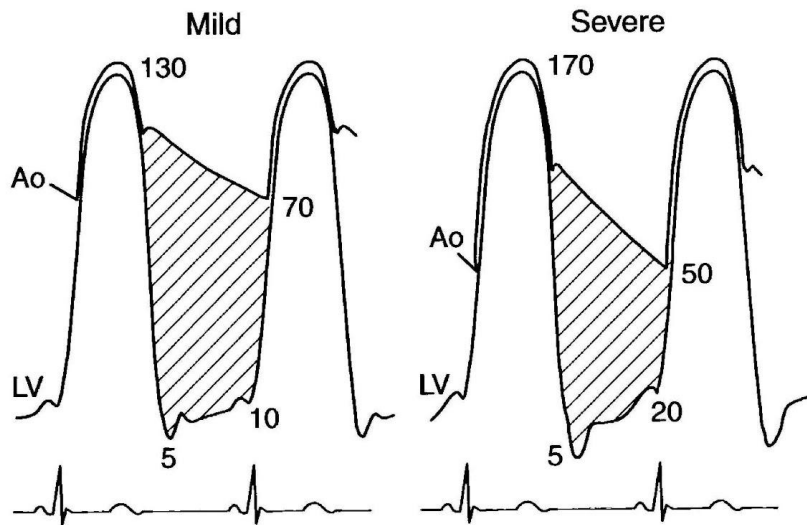
- Early diastolic murmur of regurgitation
 - blowing, and high frequency, and decrescendo in shape.
- Systolic aortic flow murmur
- Austin flint murmur

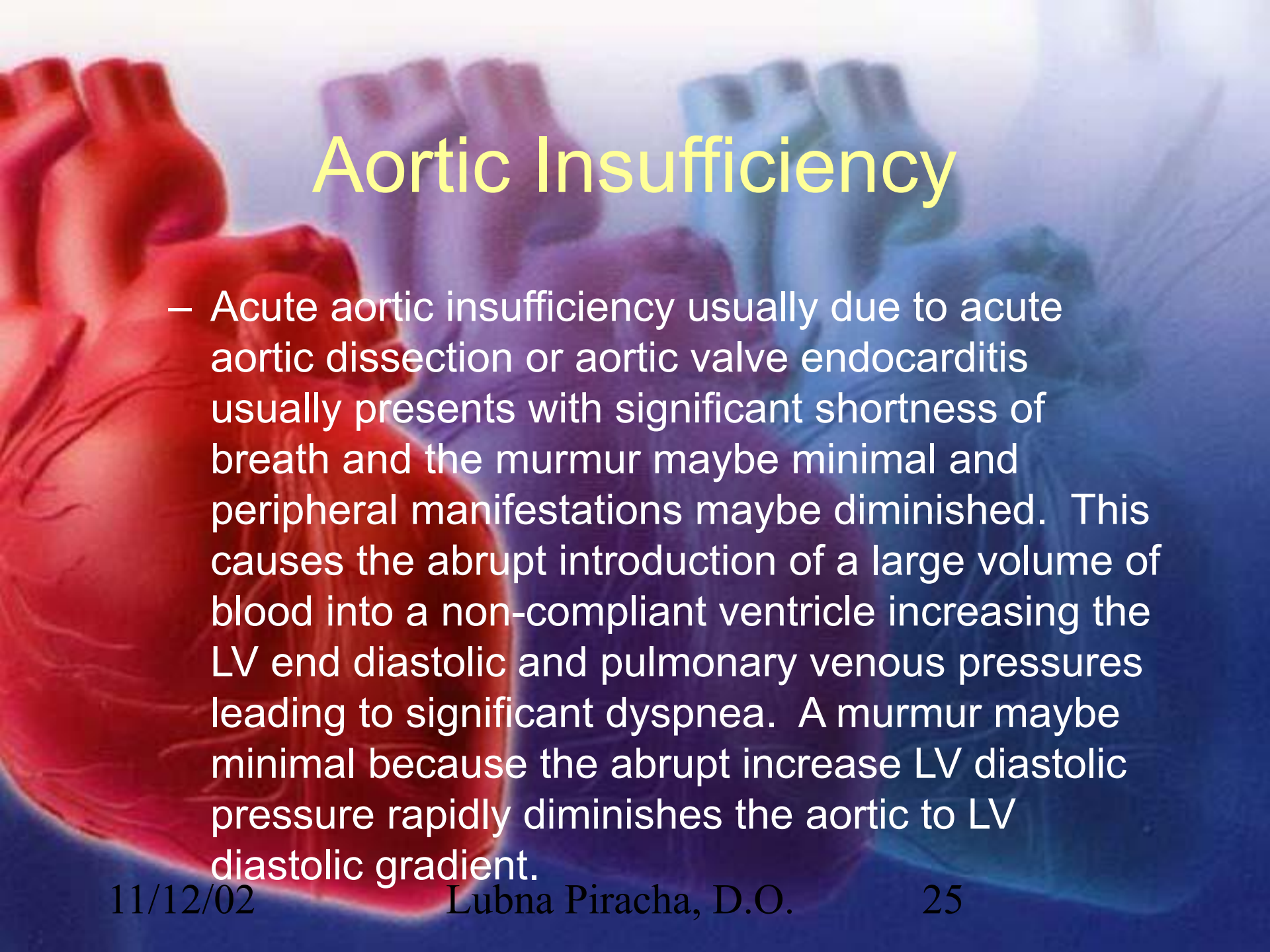
Echocardiography



11/12/0

Echocardiography





Aortic Insufficiency

- Acute aortic insufficiency usually due to acute aortic dissection or aortic valve endocarditis usually presents with significant shortness of breath and the murmur maybe minimal and peripheral manifestations maybe diminished. This causes the abrupt introduction of a large volume of blood into a non-compliant ventricle increasing the LV end diastolic and pulmonary venous pressures leading to significant dyspnea. A murmur maybe minimal because the abrupt increase LV diastolic pressure rapidly diminishes the aortic to LV diastolic gradient.

Aortic Insufficiency

- In chronic aortic insufficiency, compensatory left ventricular changes occur over time. The chronic volume overload causes stretching and elongation of myocardial fibers (eccentric hypertrophy). Eventually, the LV cannot compensate and you have LV dilatation and congestive heart failure.

Case Study



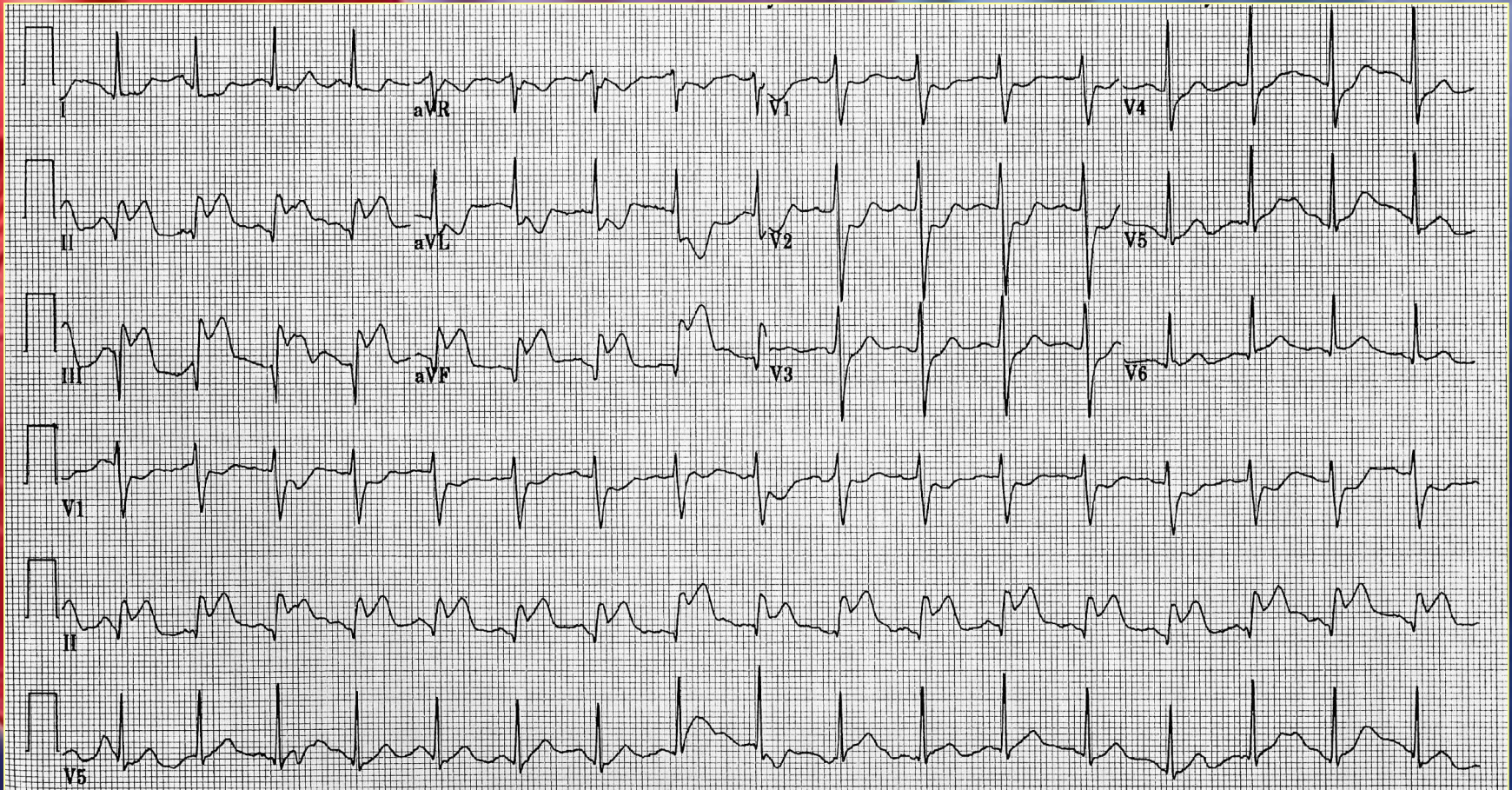
- A 75 year old male present to the emergency room with complaints of severe chest tightness (10/10) and acutely short of breath. He has PND and orthopnea. He is hypotensive, tachycardic and in respiratory distress. His EKG reveals an inferior and posterior wall myocardial infarction.
 - On Exam:
 - Vital signs are unstable
 - Crackles are noted bilaterally
 - PMI is still relatively normal
 - Auscultatory findings reveal this:



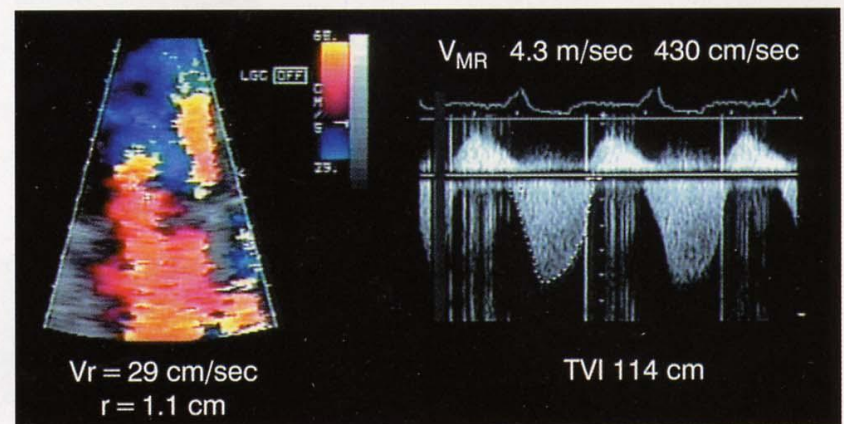
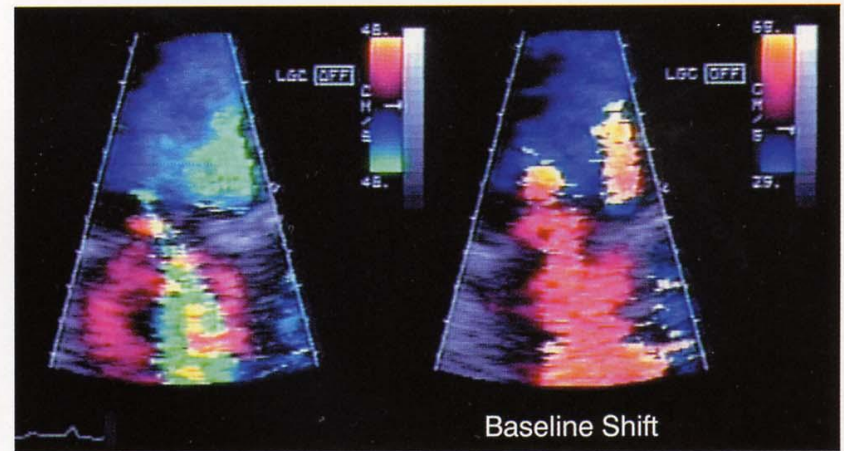
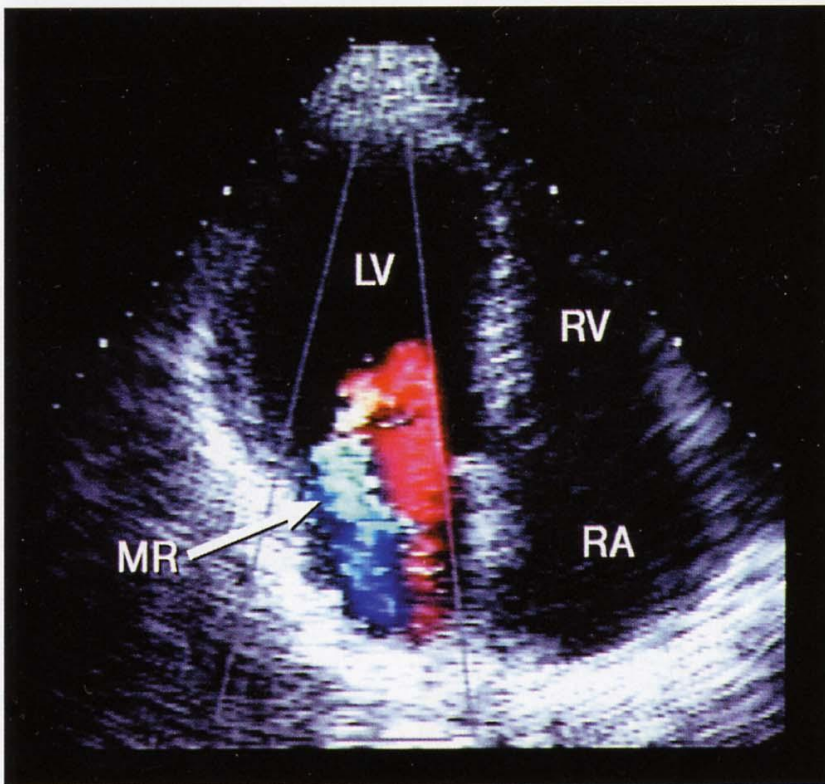
Physical Exam Review

- In acute MR, there is tachycardia, the murmur maybe short and confined to early systole, because the LA pressures are elevated.
- In chronic MR, the murmur is typically holosystolic starting after S1.

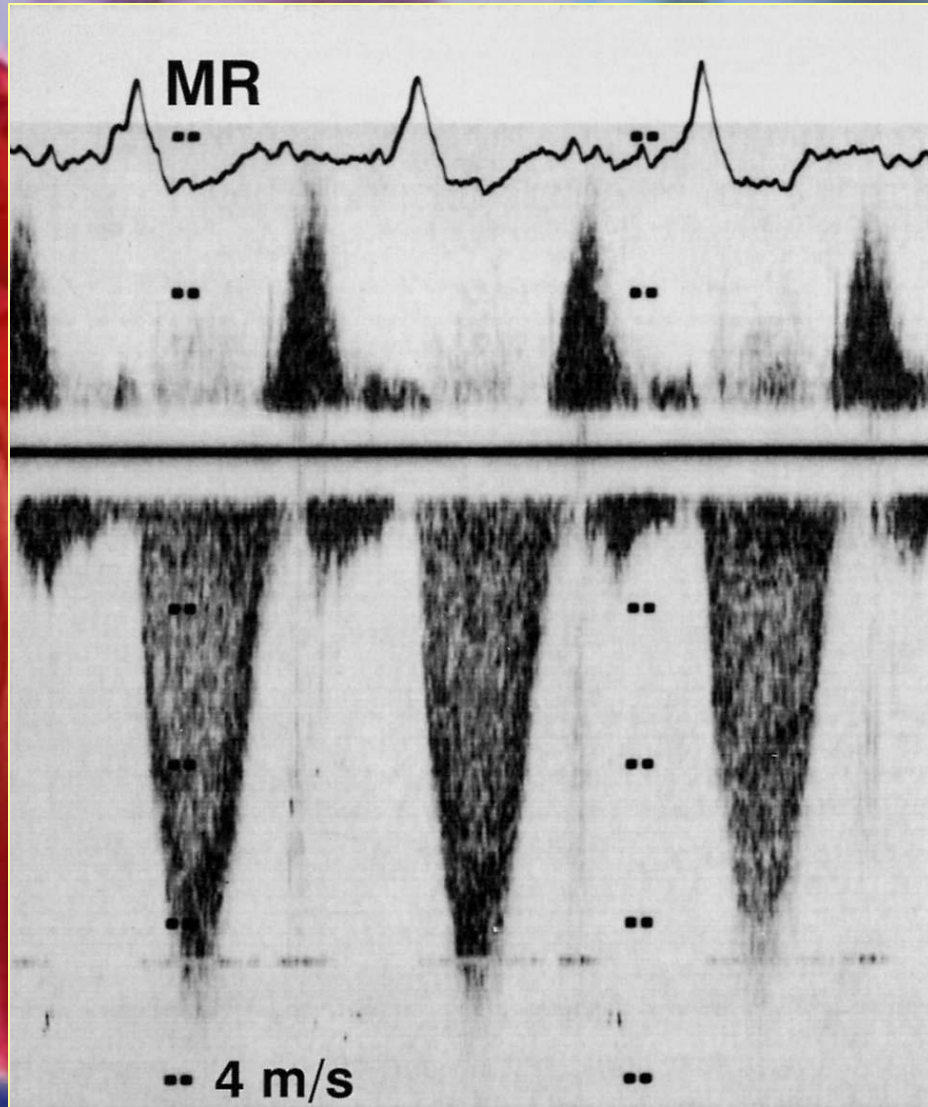
EKG Findings:



Echocardiography



Echocardiography



11/12/02

31

Mitral Regurgitation

- There is acute volume overload on left ventricle with an increase in end diastolic volume. At the same time, there is new pathway for LV ejection into a low pressure system into the LA. The left ventricle initially is hypercontractile because it can eject blood back into the LA and out the aortic valve. Forward stroke volume is actually decreased.
- In acute MR, the LA cannot accommodate the increased volume and builds up in the lungs leading to respiratory distress.

Mitral Regurgitation



- In chronic MR, the LA will slowly dilate, the LV will constantly be volume overloaded and eventually weaken. Both of these will eventually lead to congestive heart failure.

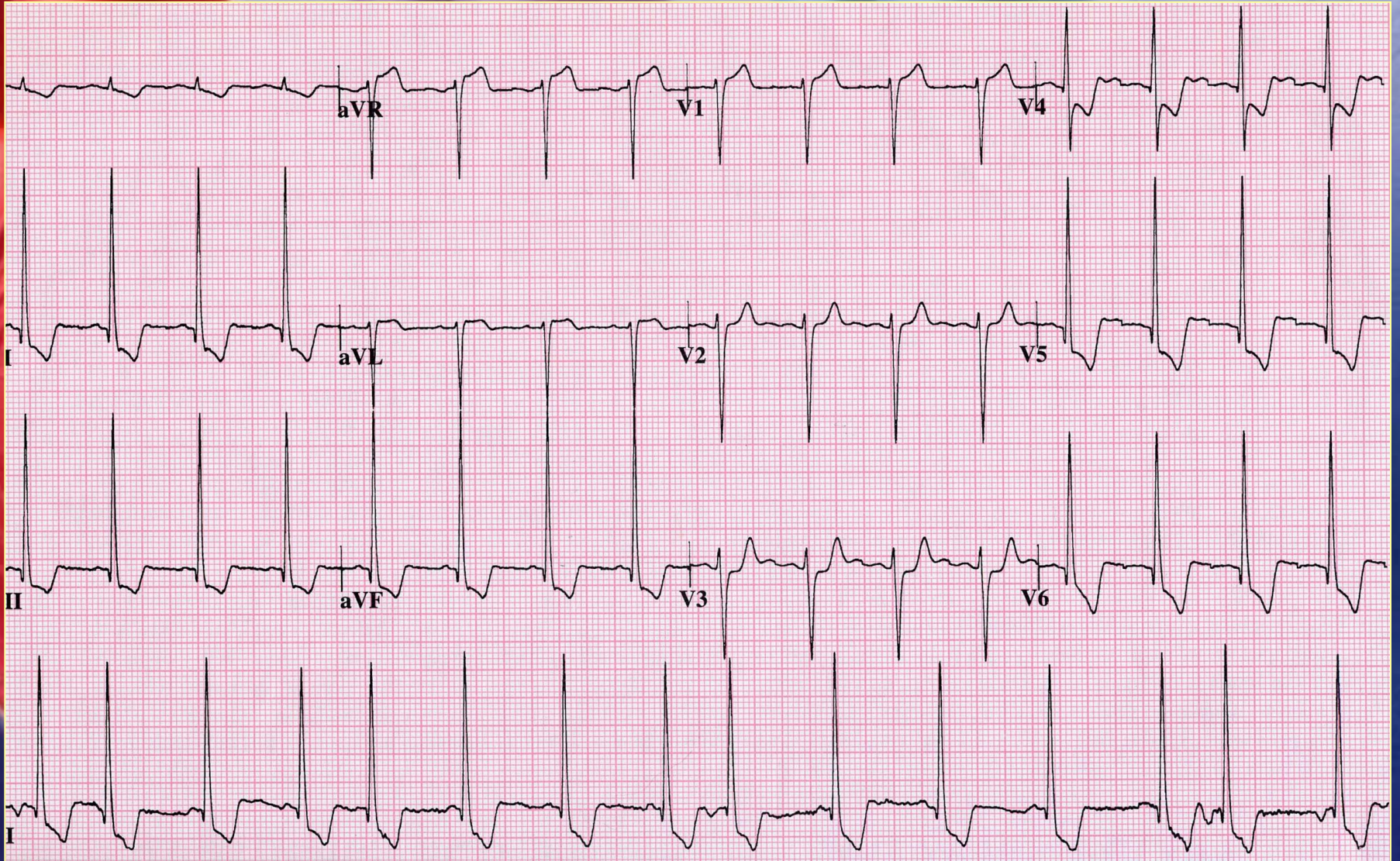
Case Study

- A 22 year old male presents for a routine physical exam. He was referred to cardiology because of a murmur and wanted clearance to play sports. He has a family history of sudden cardiac death.
 - On cardiac exam:
 - PMI is markedly sustained with a palpable a wave.

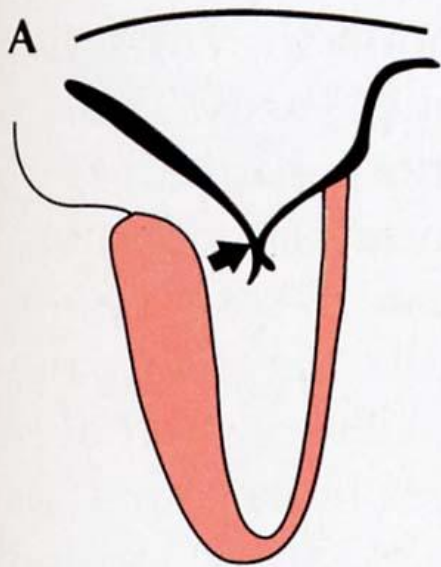
Physical Exam Review

- A spike and dome arterial pulse
- PMI will be sustained with a triple apical beat secondary a palpable a wave
- There is a harsh mid systolic murmur radiating throughout the precordium.
- There is usually also a holosystolic murmur c/w MR
- Maneuvers have specific affects on this murmur

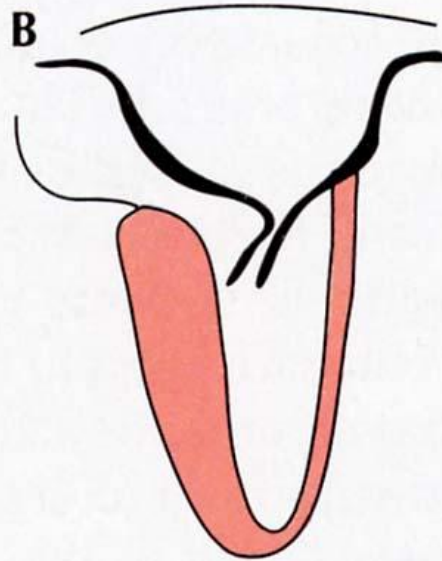
EKG Findings:



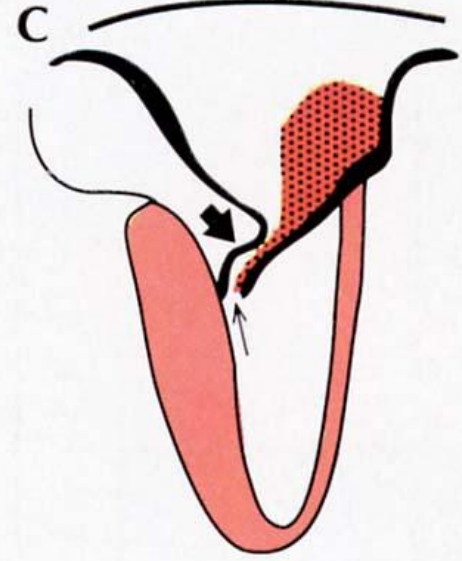
Echocardiography



Onset of systole

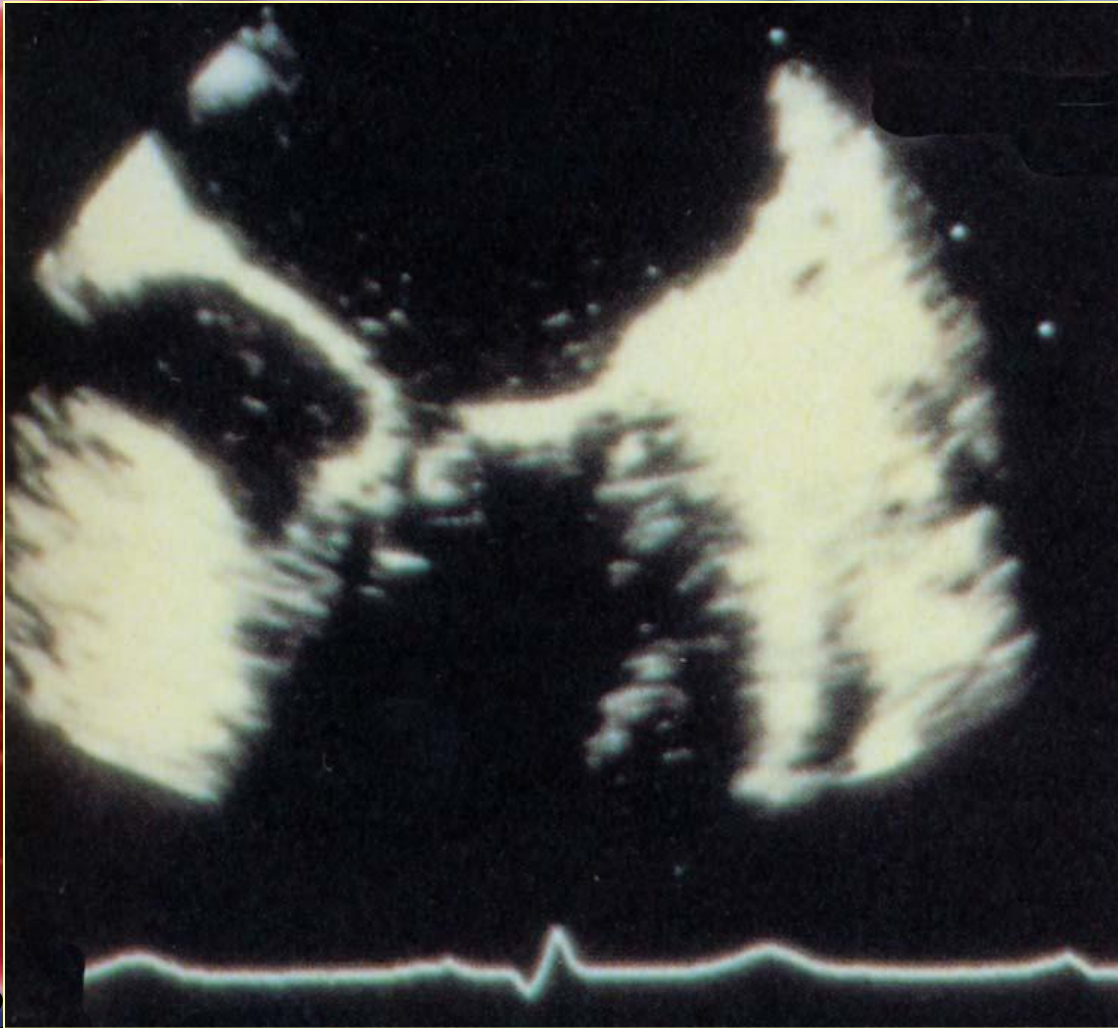
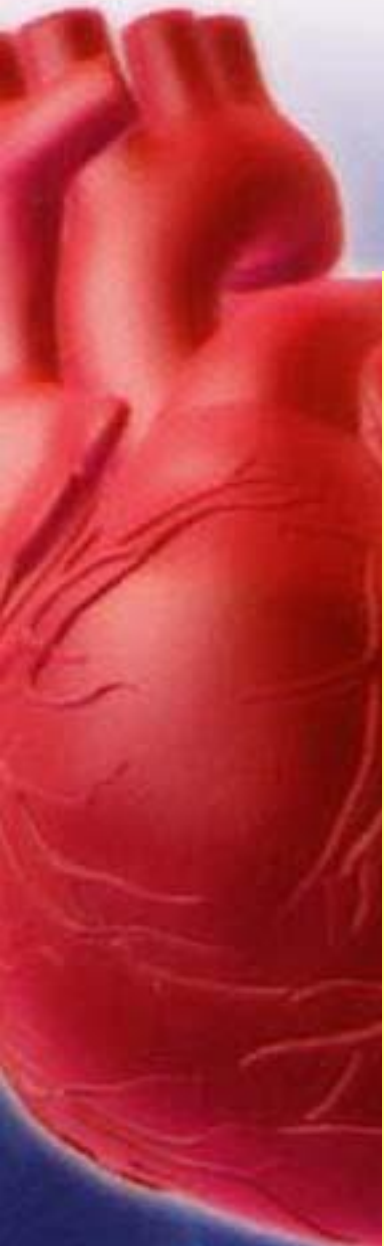

Early systole



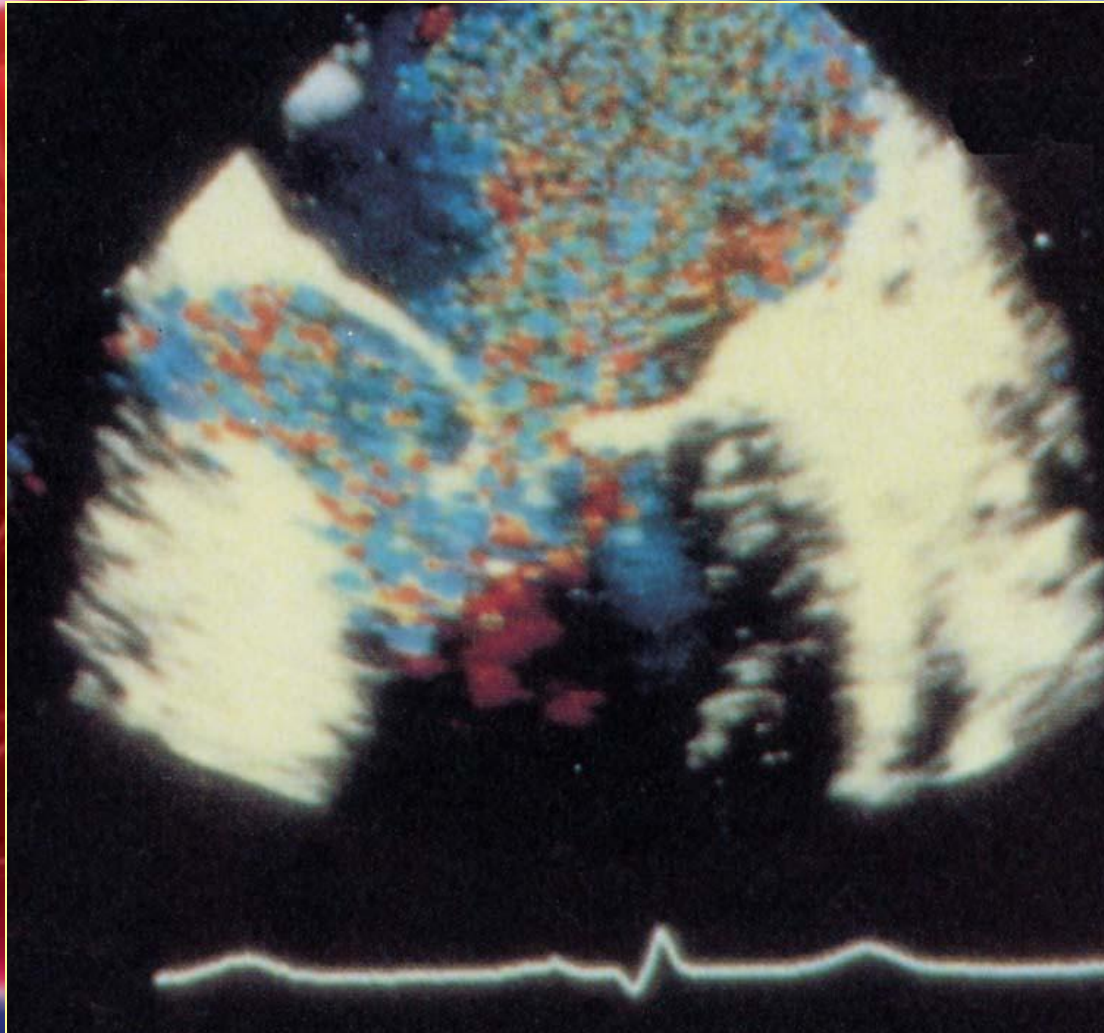
Midsystole

Echocardiography



11/12/02

Echocardiography



11/12/02

Hypertrophic Cardiomyopathy

- HCM is frequently a hereditary disorder, with transmission to first-degree relatives in 50% of cases. The most common location of ventricular hypertrophy is subaortic, septal, and anterior wall hypertrophy.
- Traditionally, dynamic left ventricular outflow tract obstruction has been considered as the cause of symptoms in patients, but it should be remembered that diastolic dysfunction, ischemia, MR, and arrhythmia's are also important in producing symptoms.

Hypertrophic Cardiomyopathy



- Atrial arrhythmias are common. Ventricular ectopy is a common finding on Holter monitoring. Sustained ventricular tachycardia and fibrillation are the most likely mechanisms of syncope and sudden death in these patients.
- Cardiac output may decrease as much as 40% if atrial fibrillation occurs, and these patients tend to rely on their atrial kick.