Анатомия человека

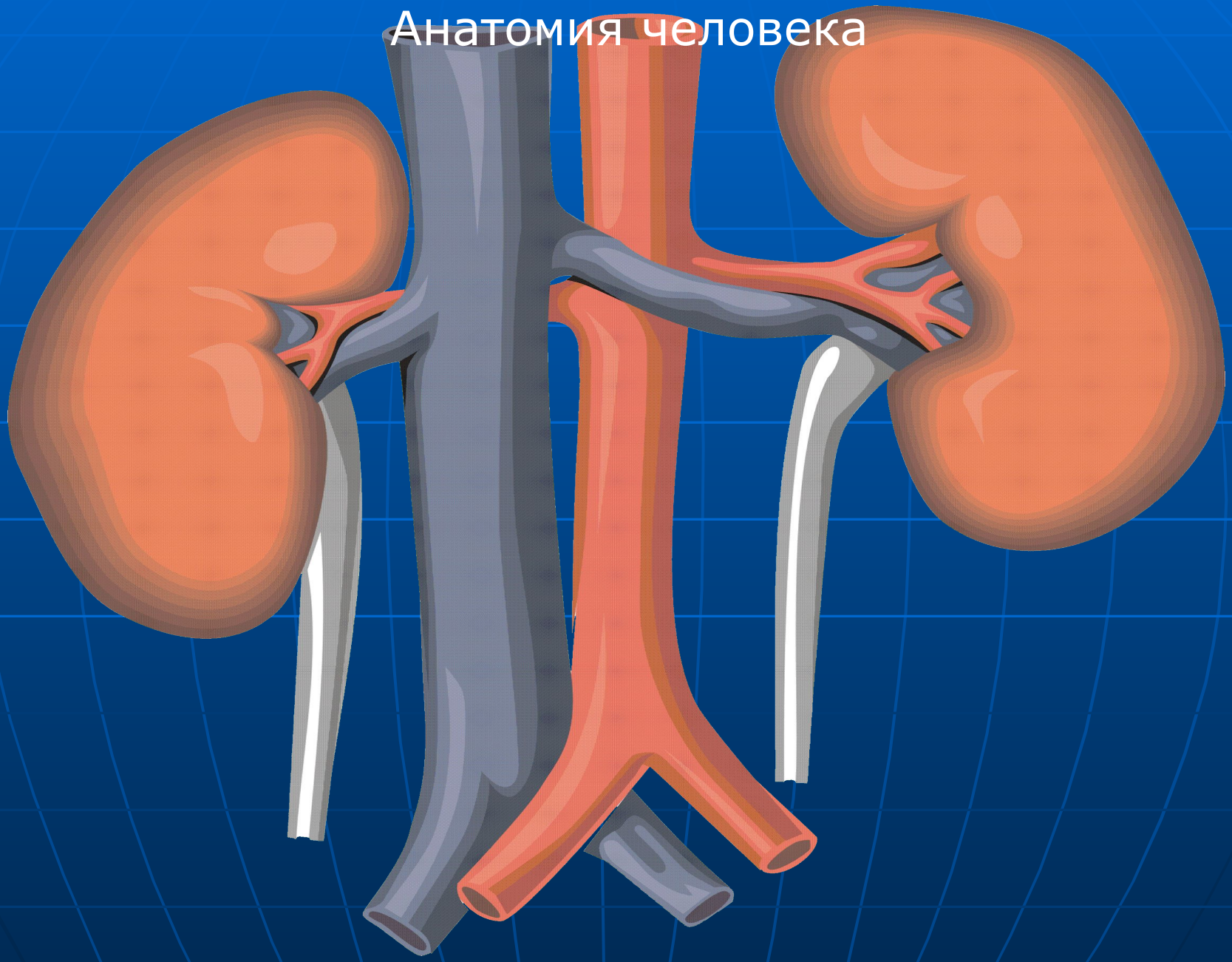

Анатомические плоскости

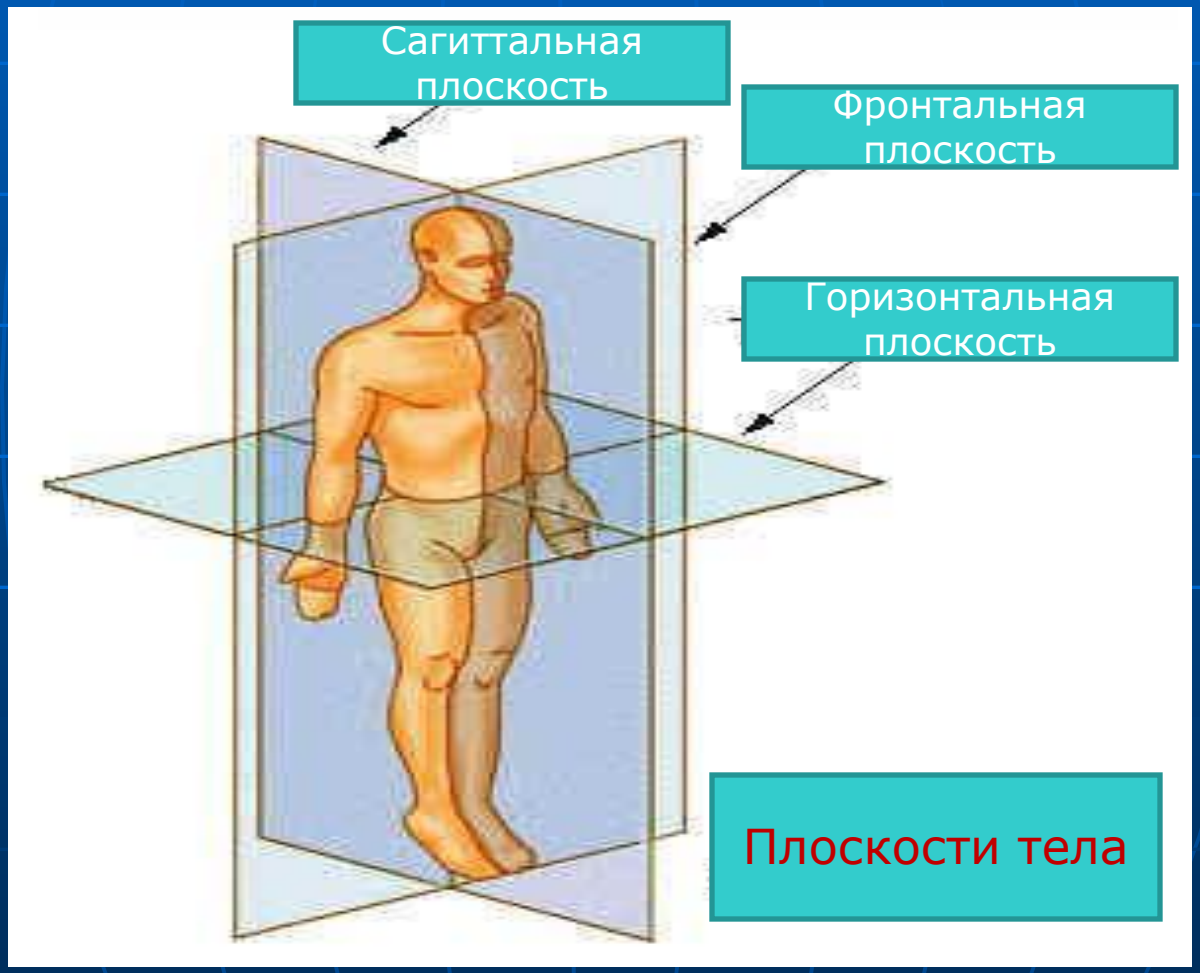

Эпителиальная ткань

Виды эпителиальных клеток

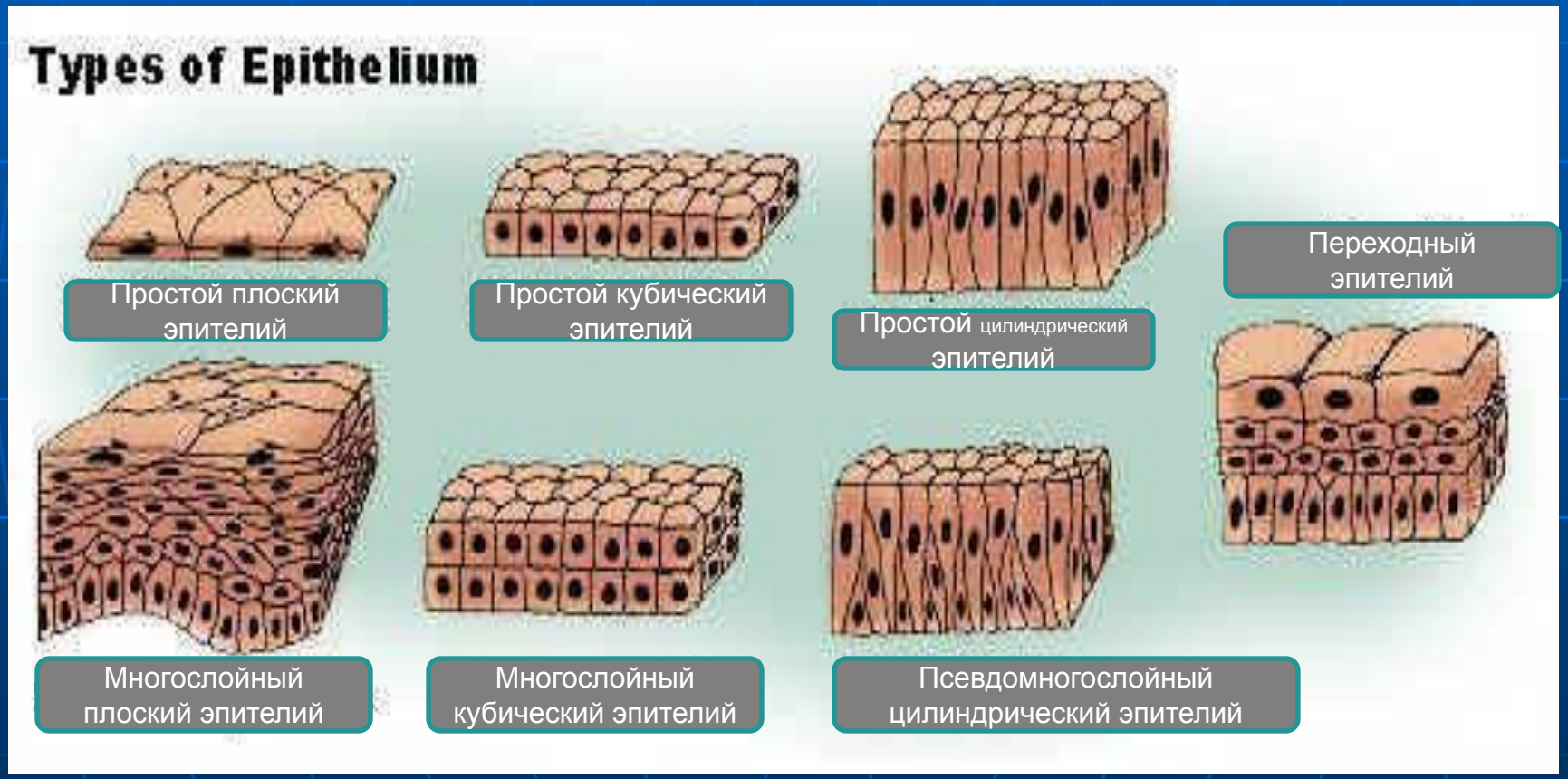

Нервная ткань
Строение нейрона

- 1 — дендриты; 2 — тело ; 3 — ядро;
- 4 — аксон; 5 — миелиновая оболочка;
- б — ветви аксона; 7 — перехват;
- 8 — неврилемма.



Neuron (Nervous tissue)

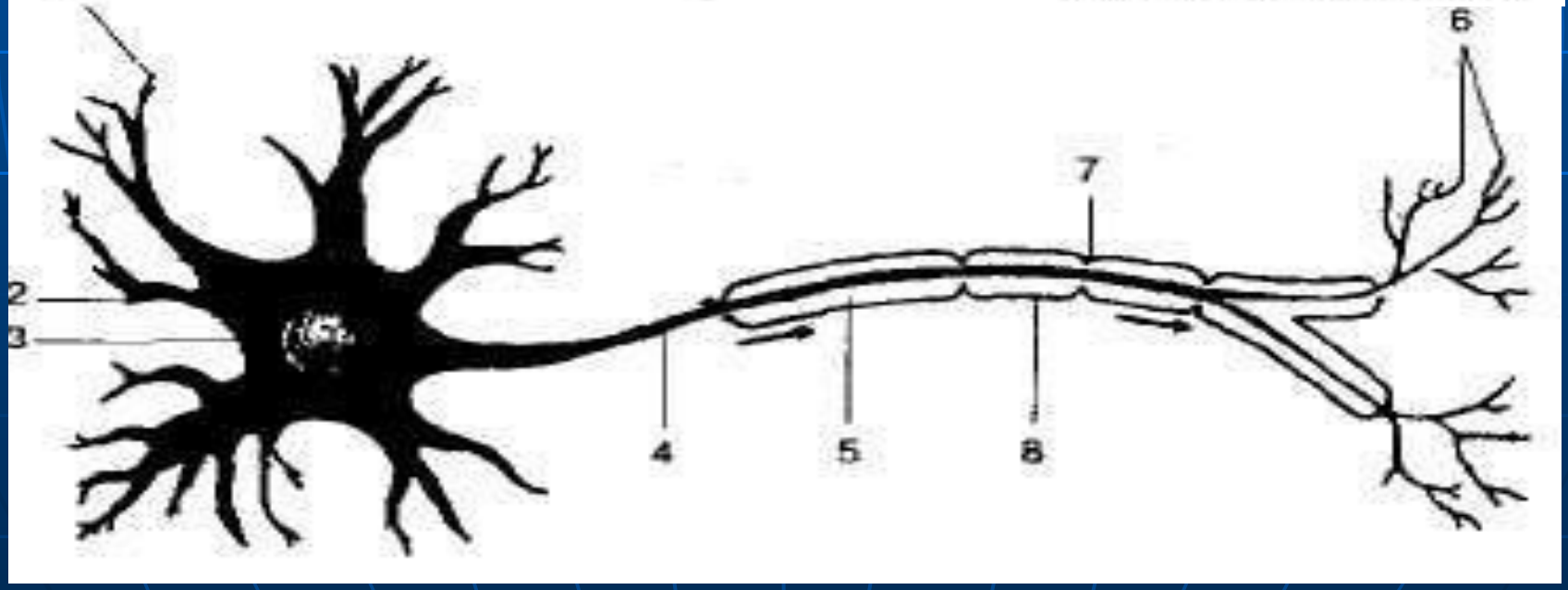

Мышечная ткань

Скелетная мышца

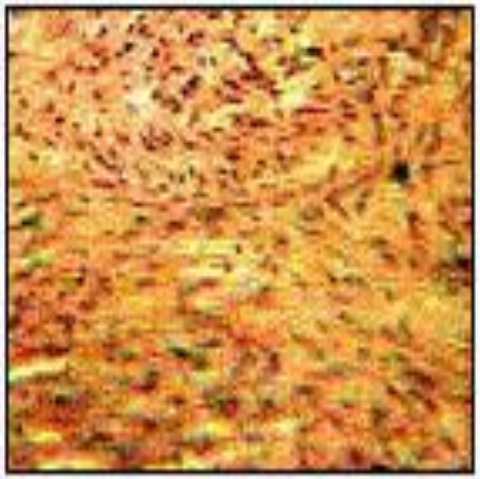

Гладкая мышца

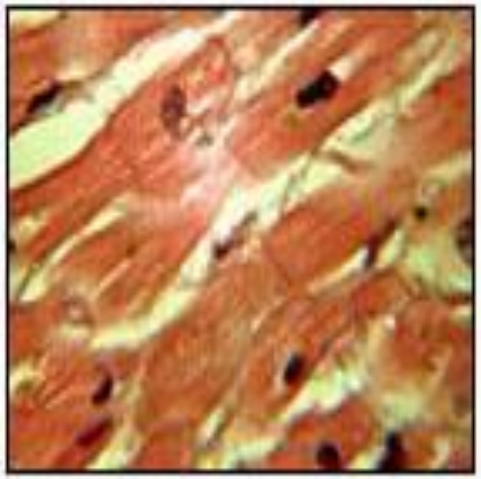

Сердечная мышца

Соединительная ткань

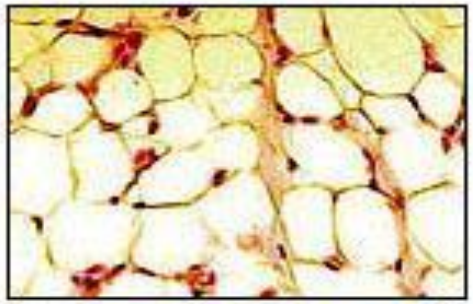

Жировая ткань

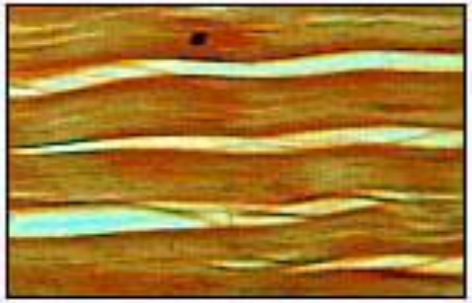

Волокнистая соединительная ткань

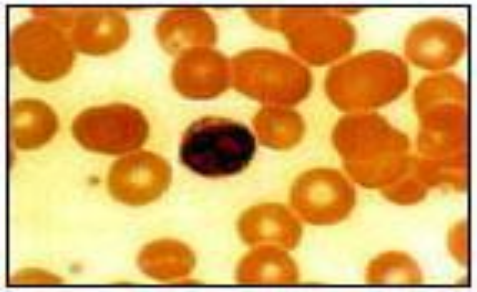

Кровь

Костная ткань

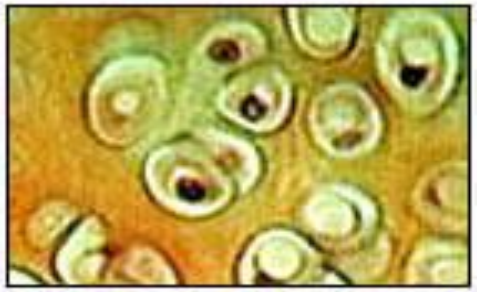

Гиалиновый хрящ

Кости черепа

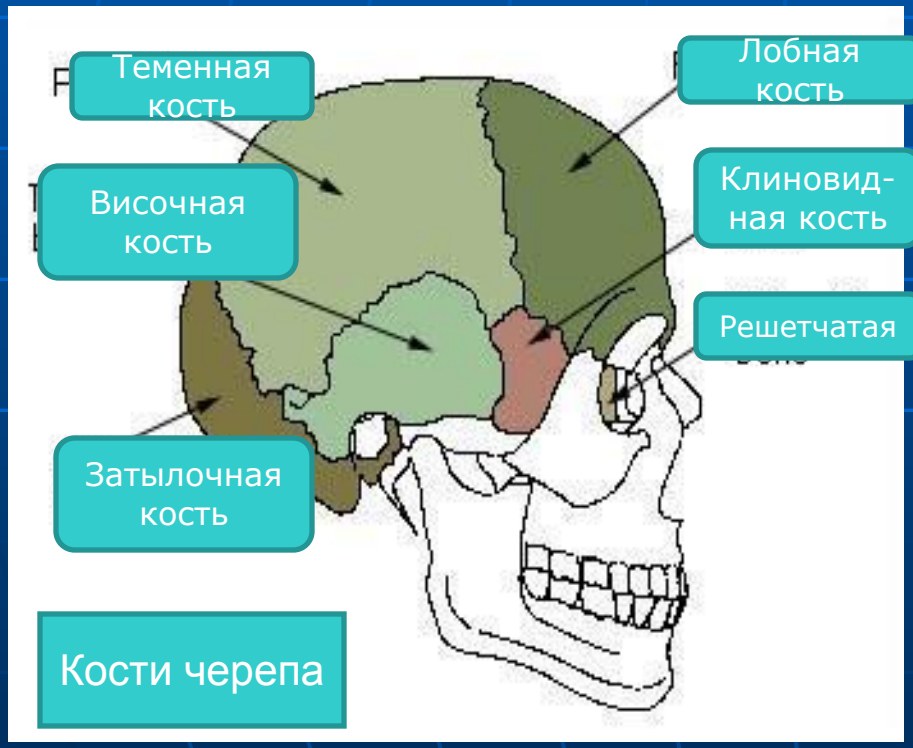

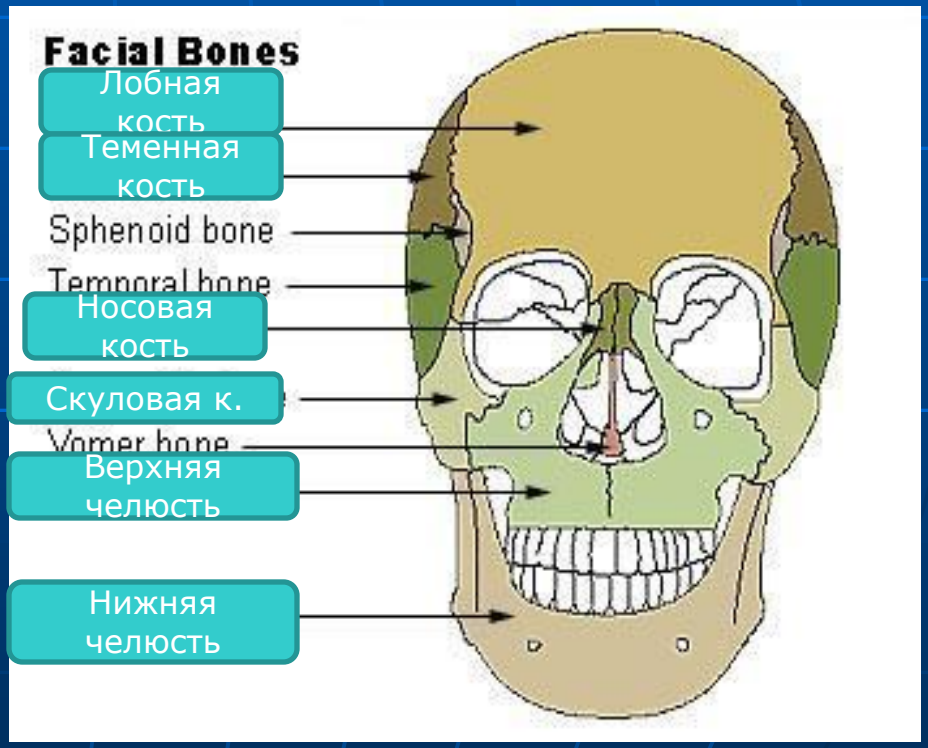

Слуховые косточки

Позвоночный столб

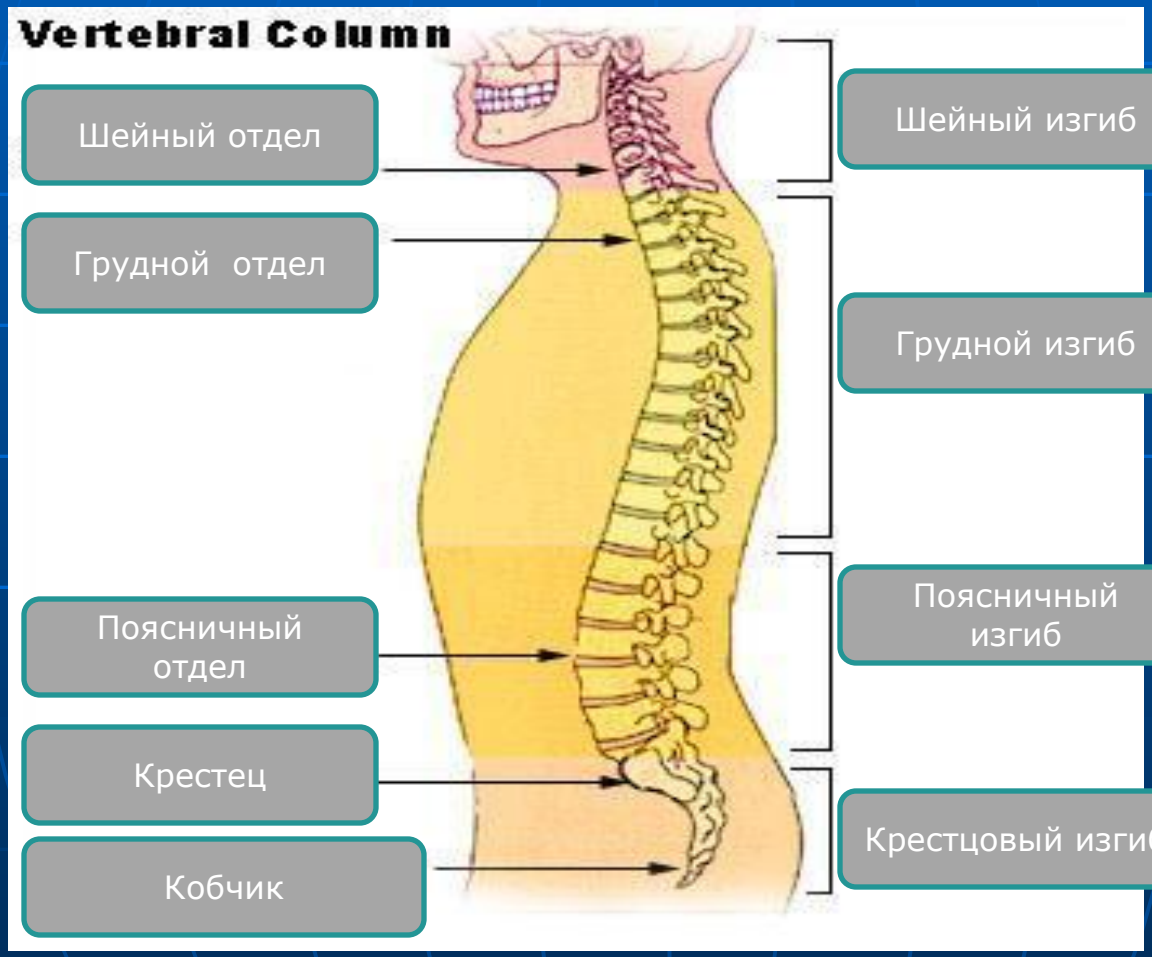

Грудная клетка (полость)

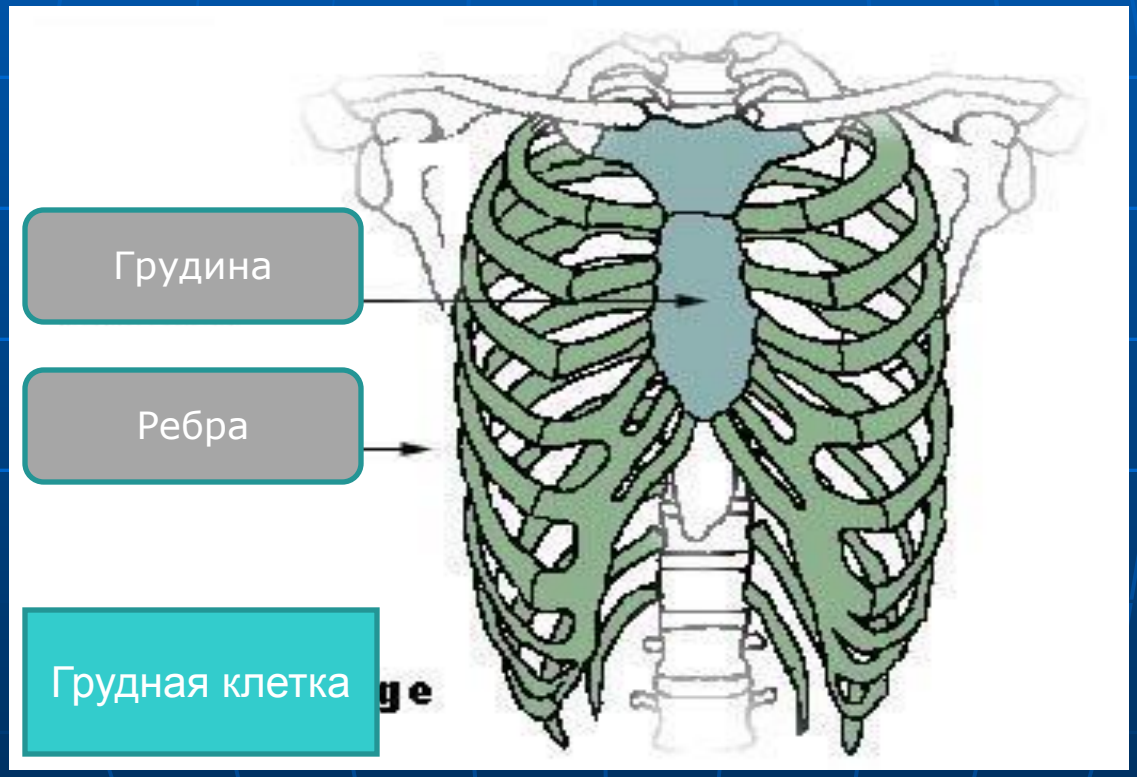

Плечевой пояс

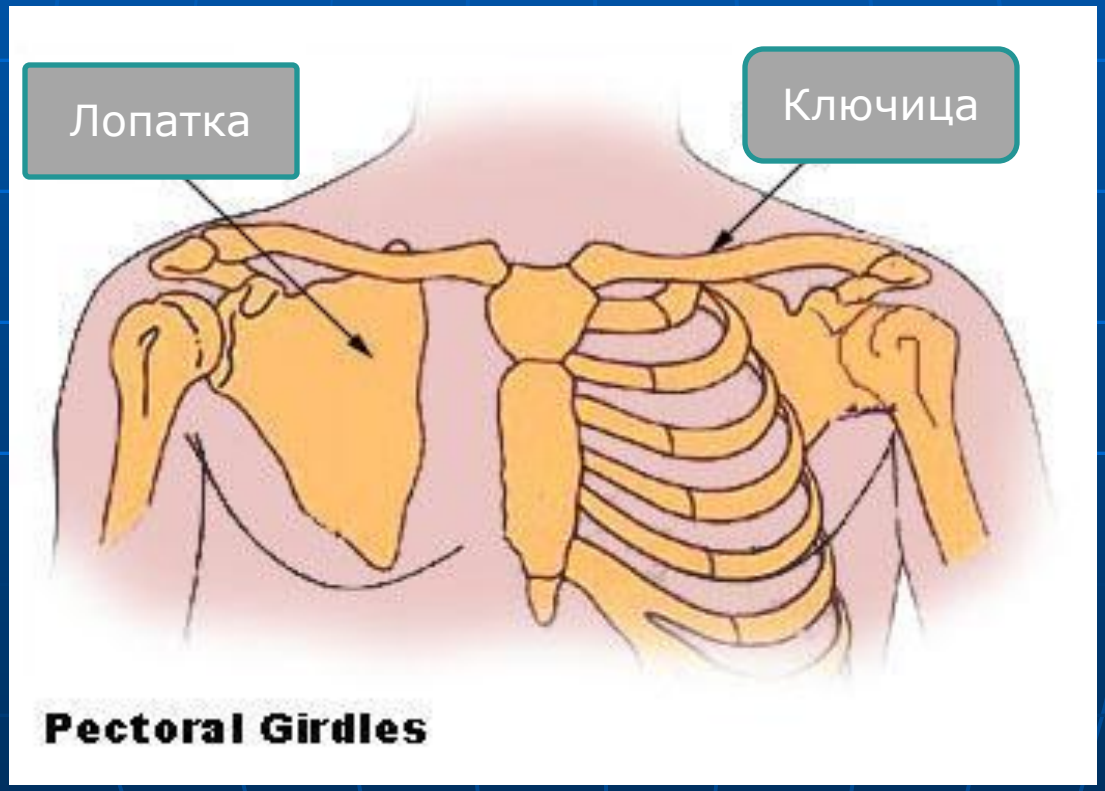

Верхняя конечность

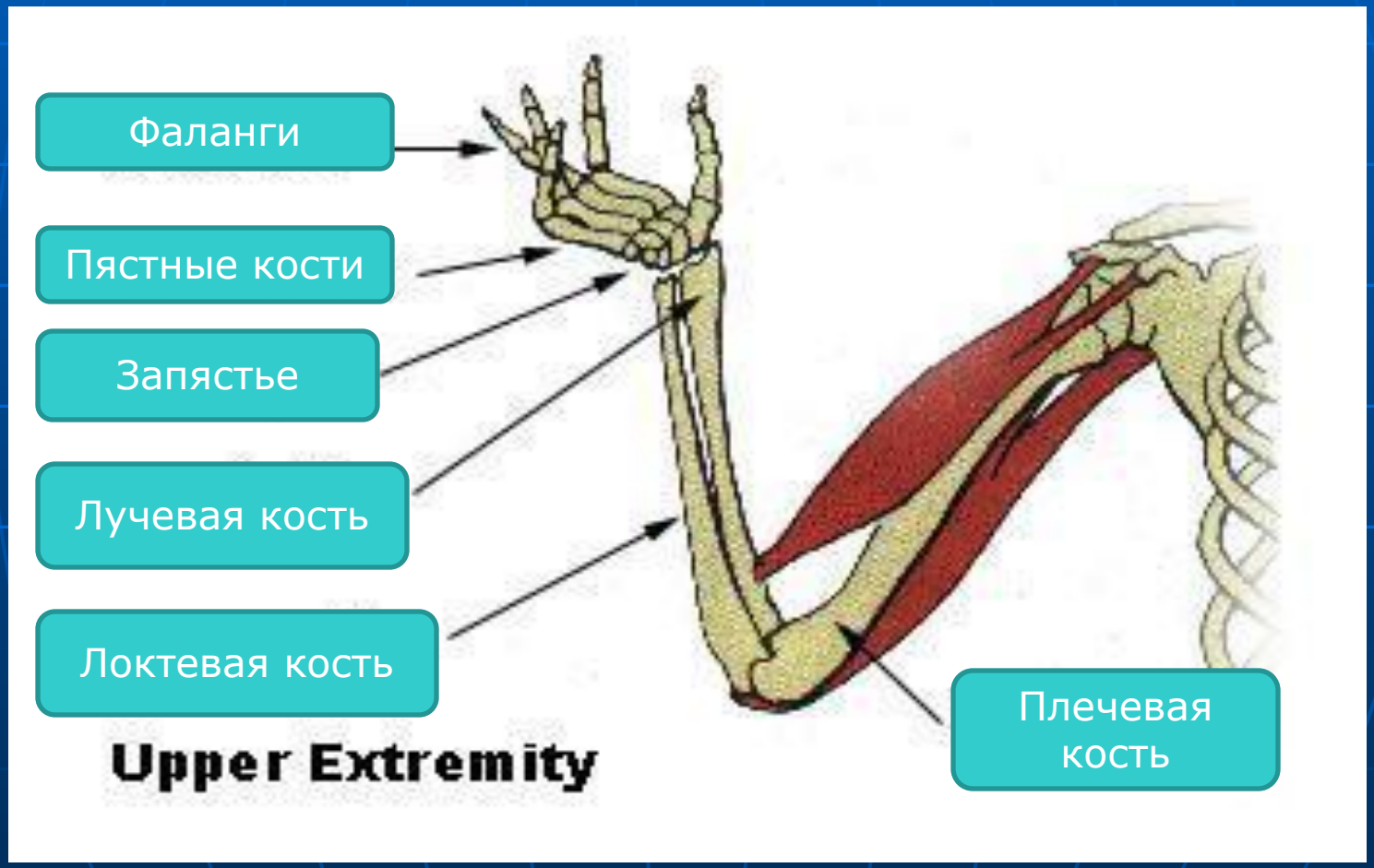

Тазовый пояс

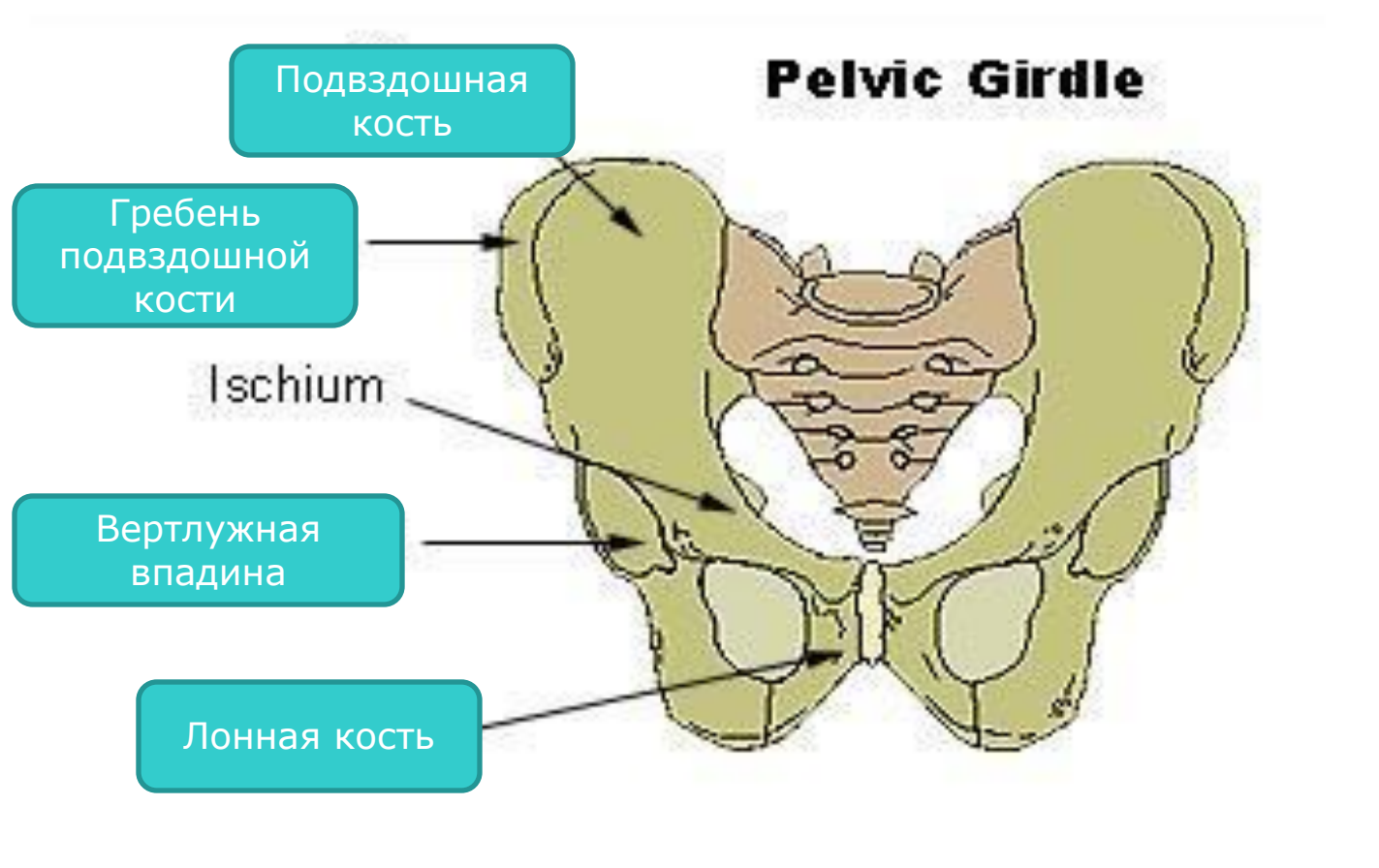

Нижняя конечность

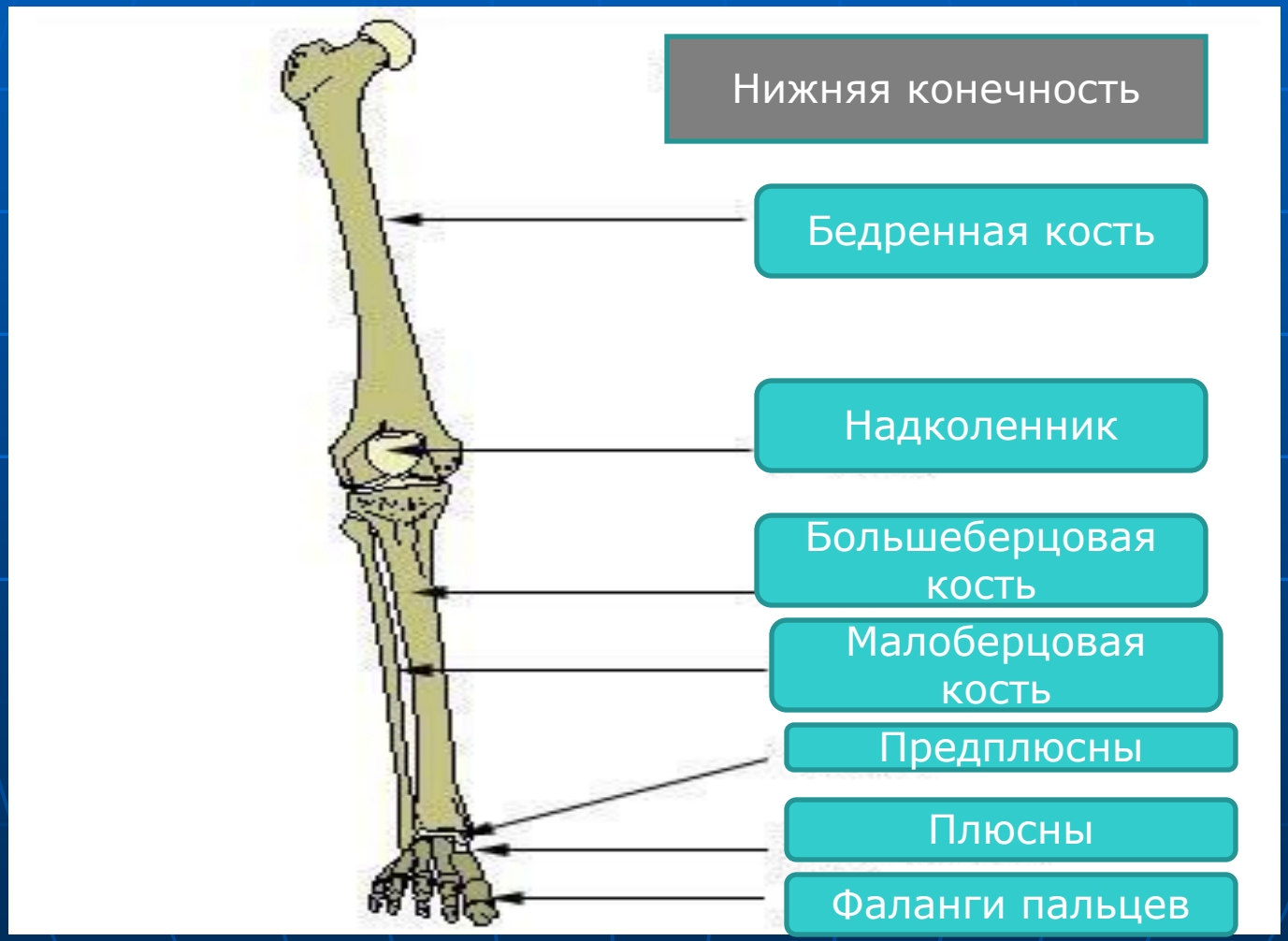

Соединения костей

- Синдесмозы
- Синостозы
- Синхондрози

Строение скелетной мышцы

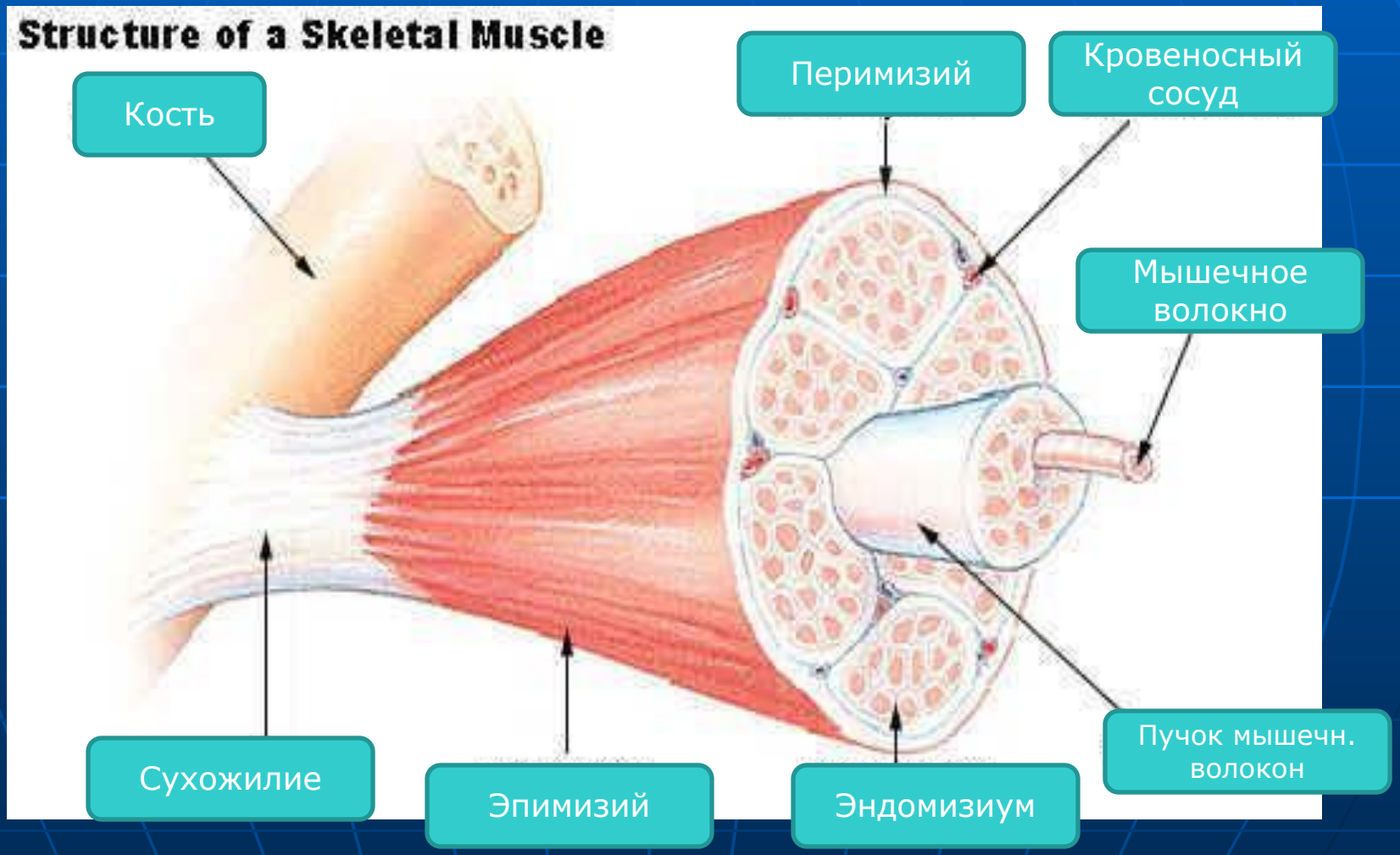

Мышцы головы и шеи

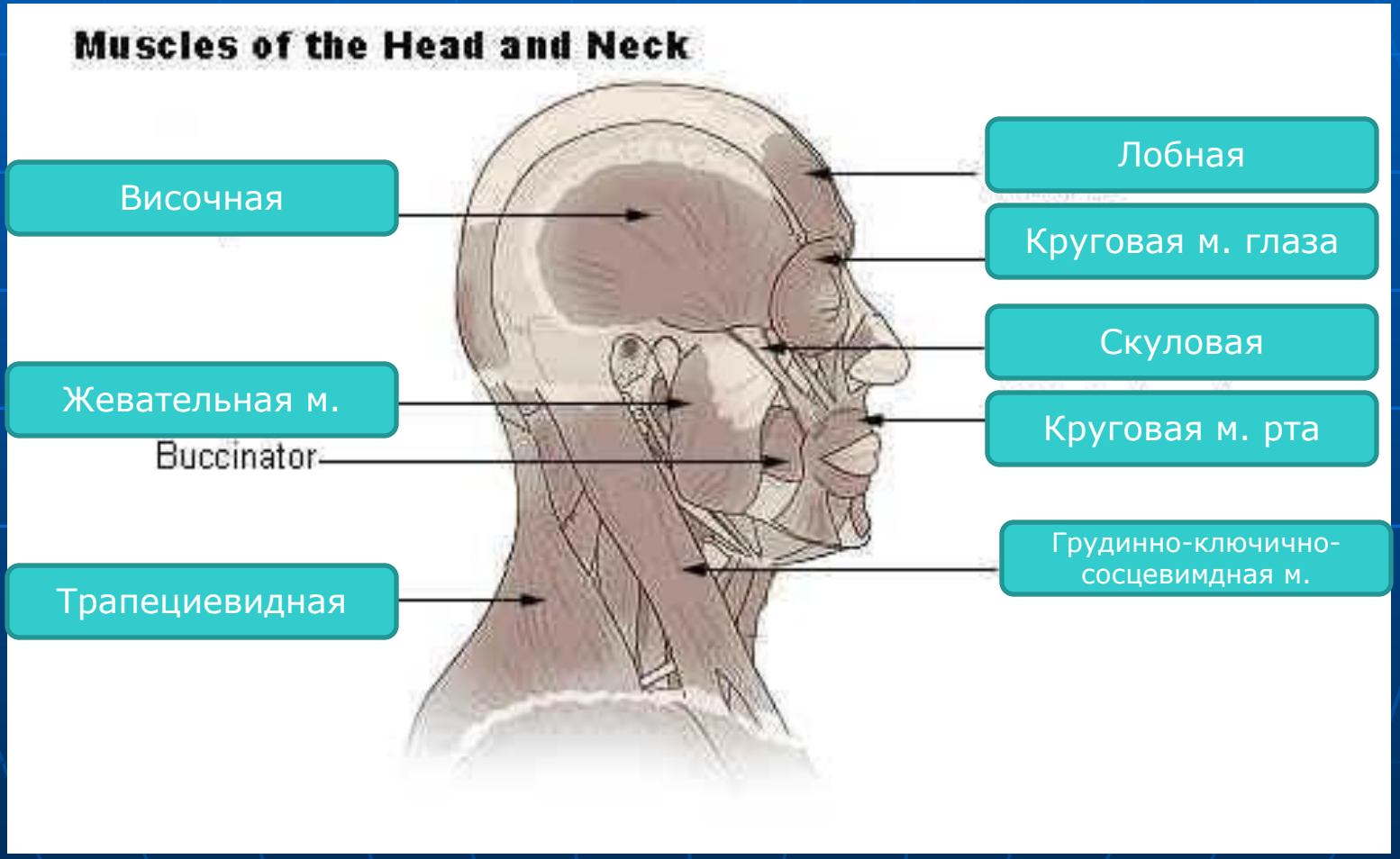

Мышцы туловища

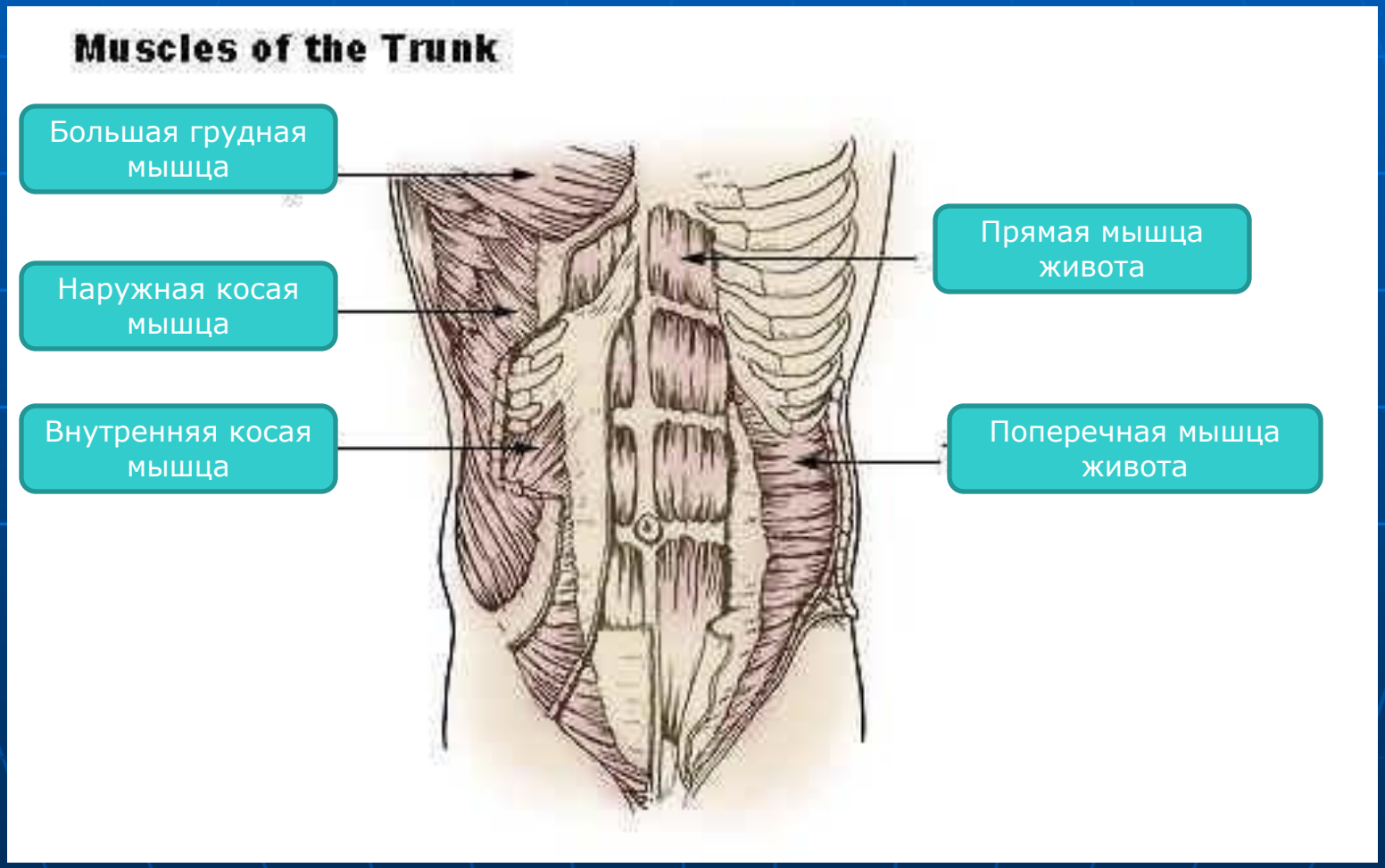

Мышцы верхней клонечности

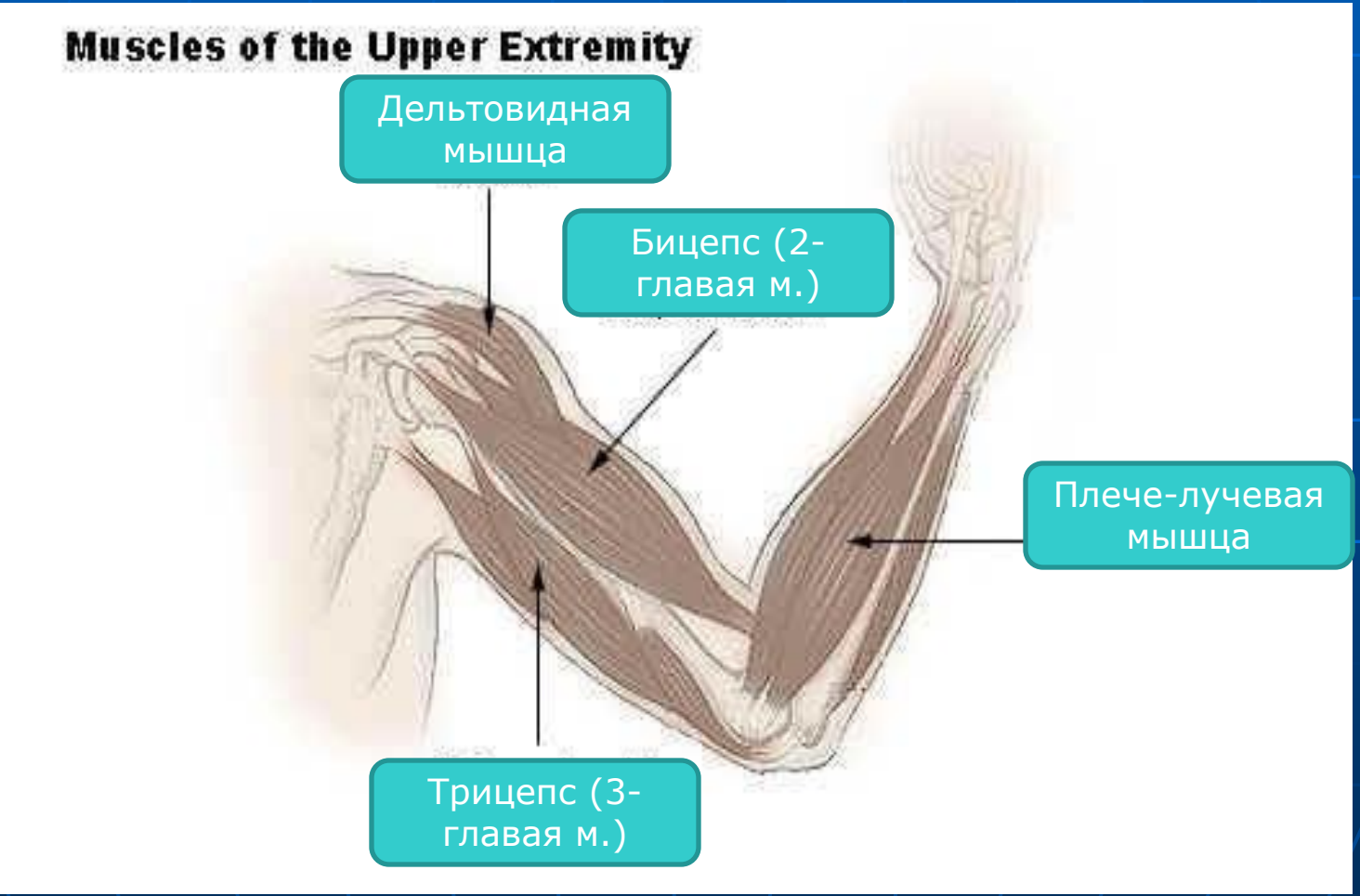

Мышцы нижней конечности

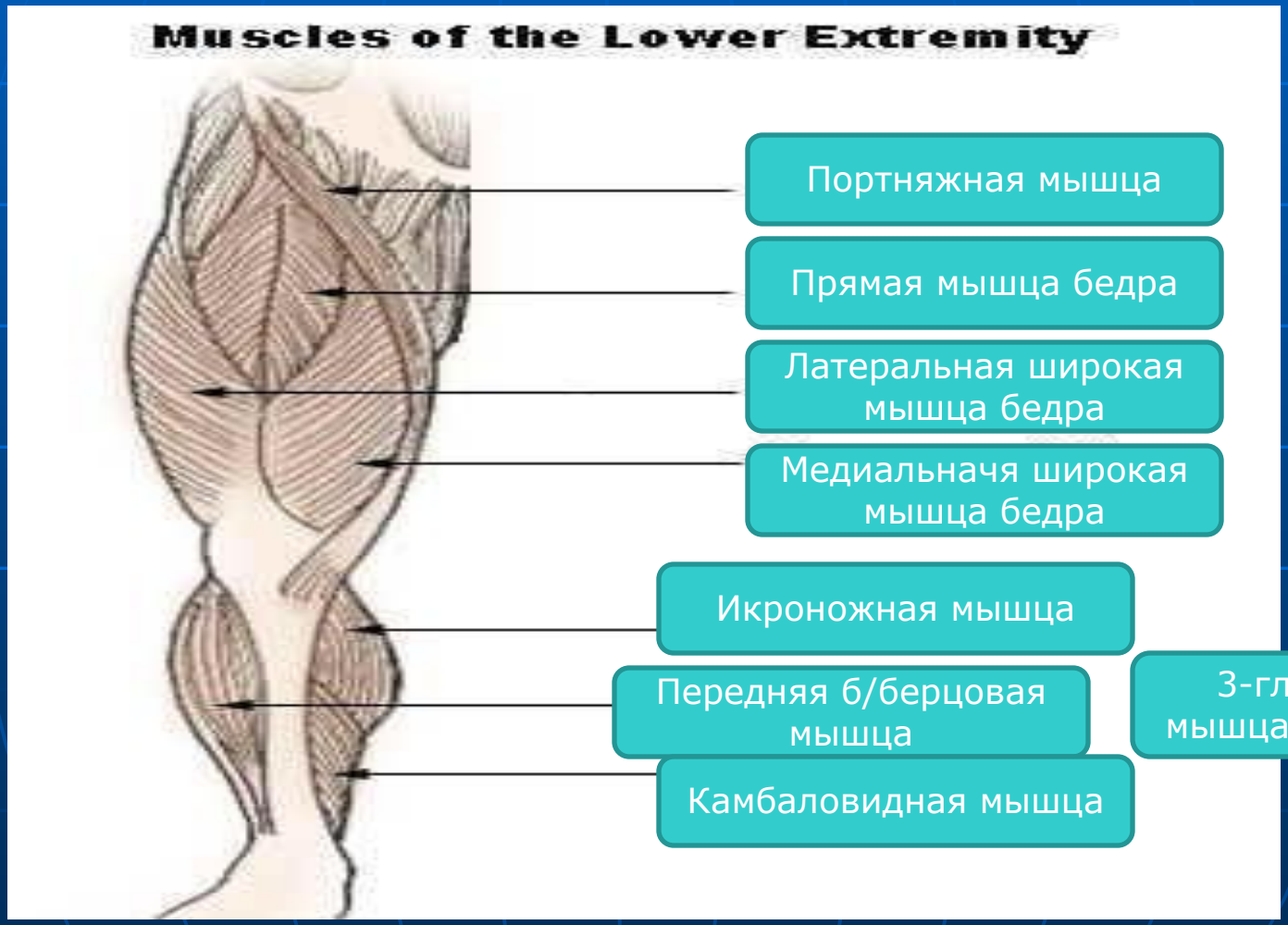

Строение сердца

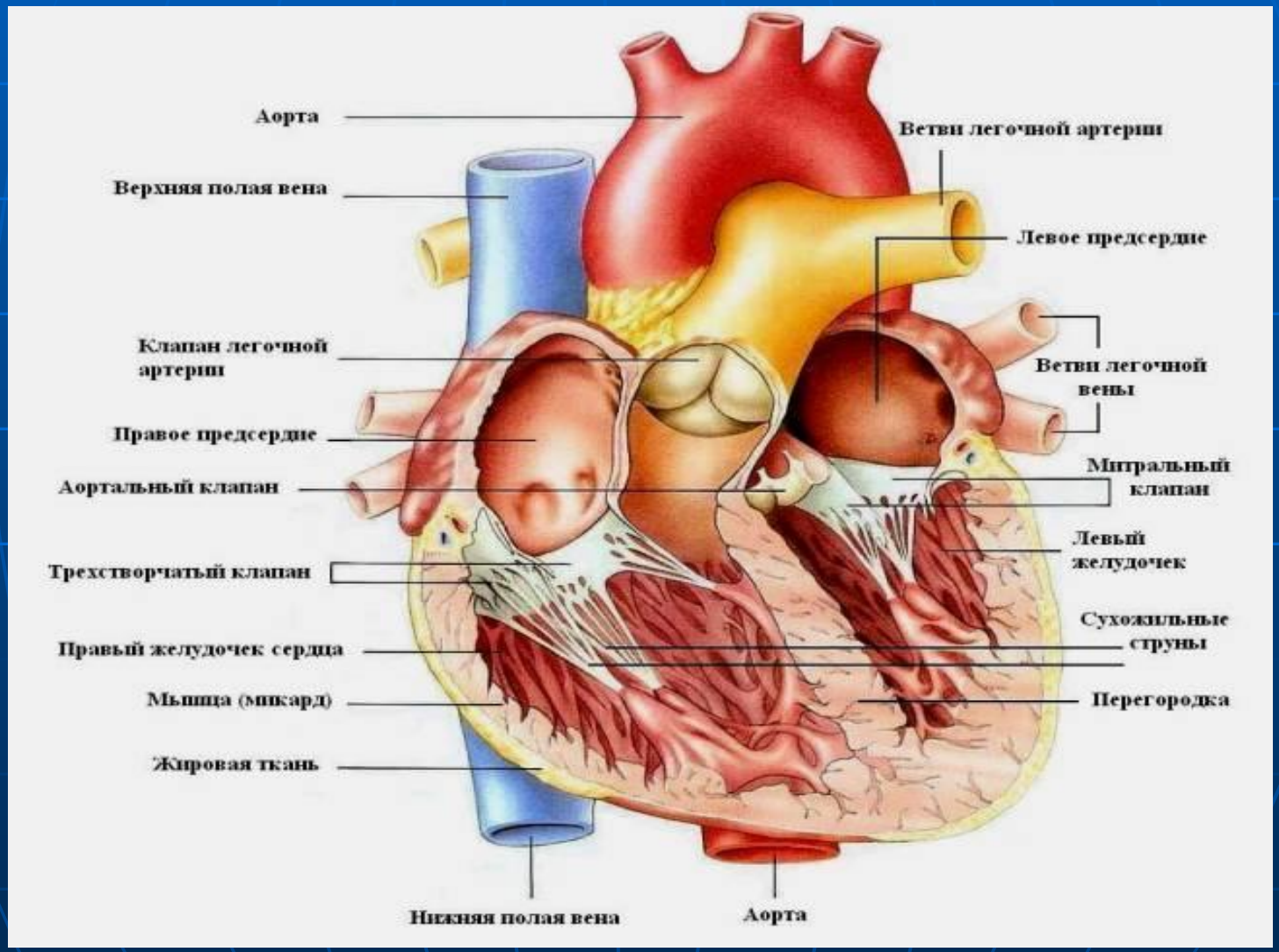

Система автоматизма сердца и венечное кровообращение

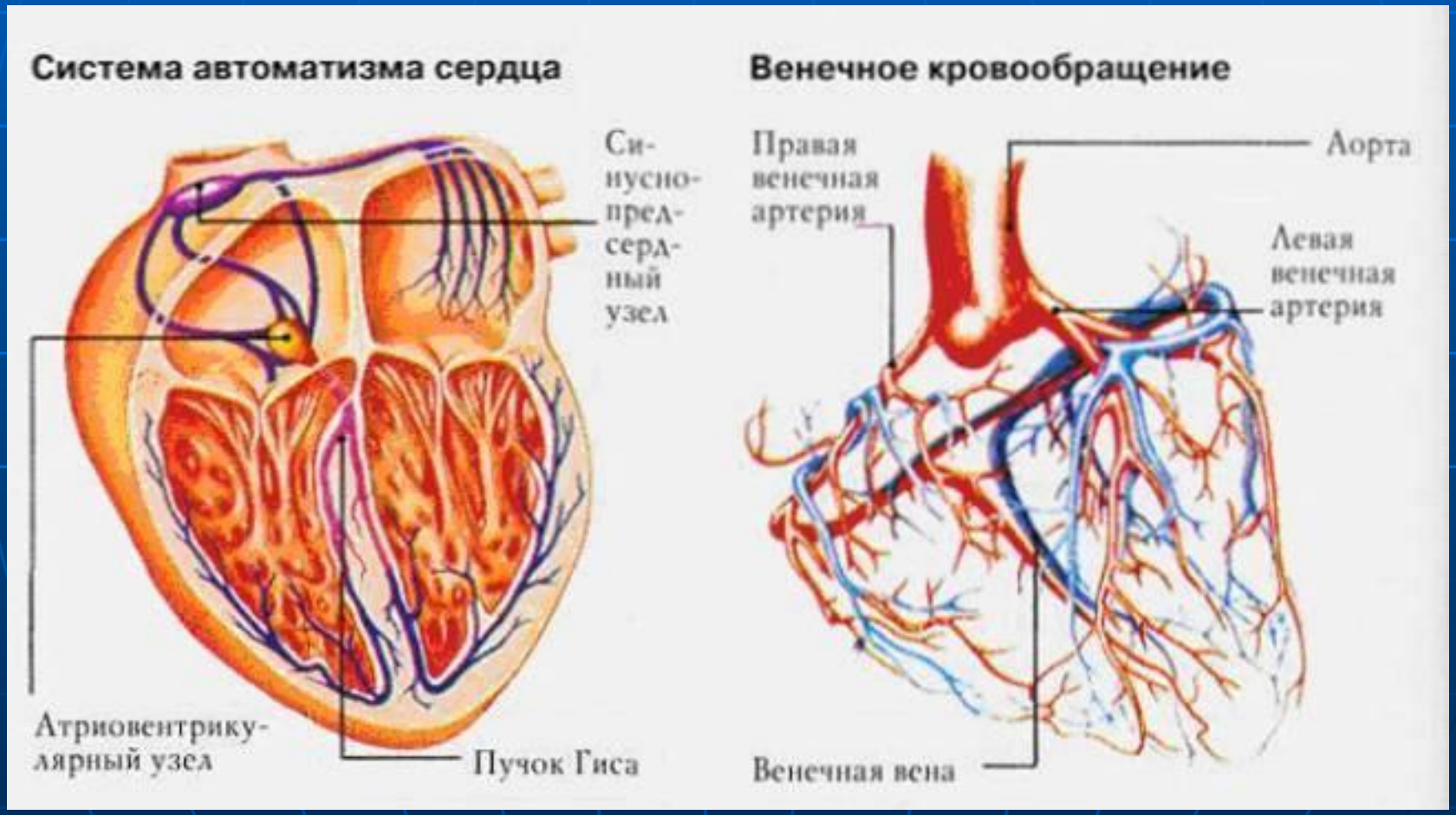

Артериальная и венозная системы

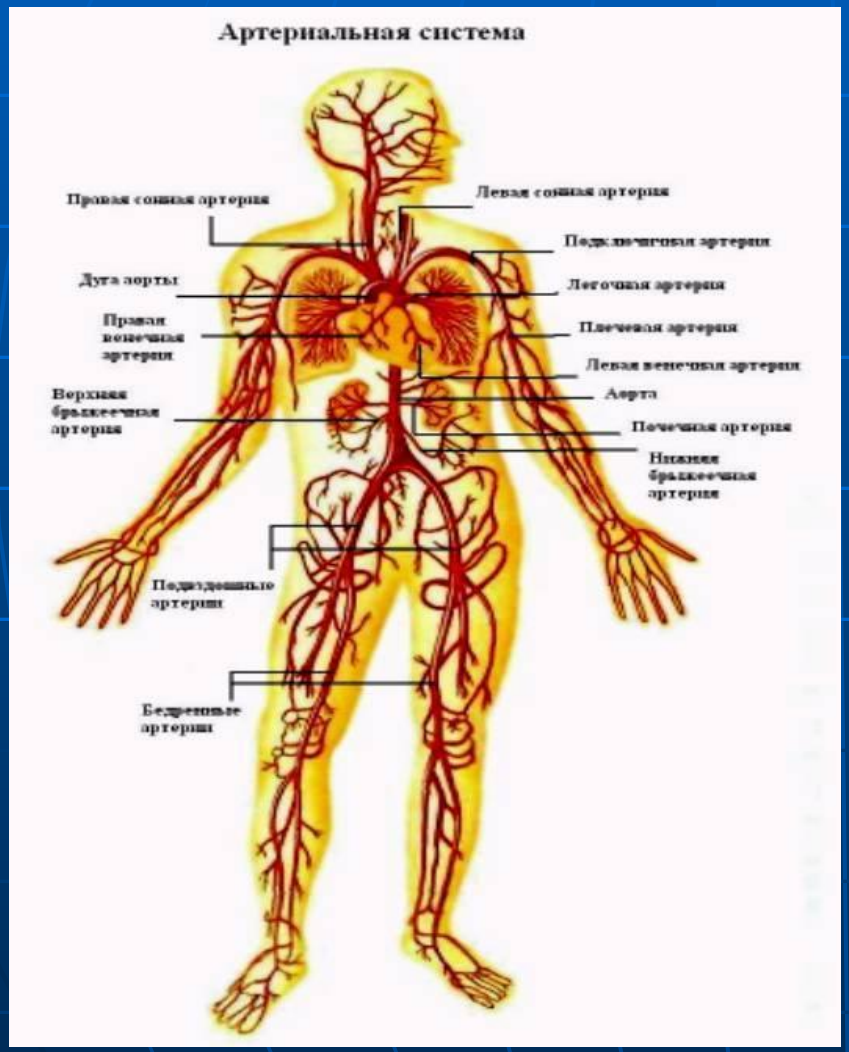

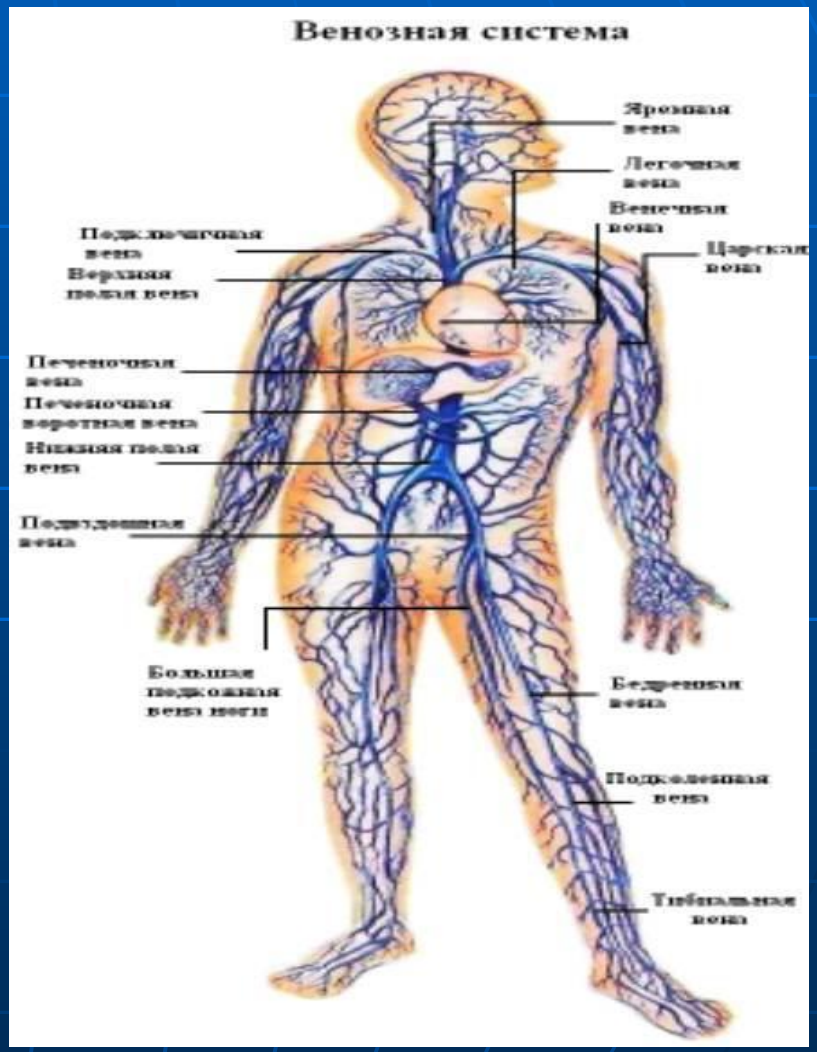

Строение стенок сосудов

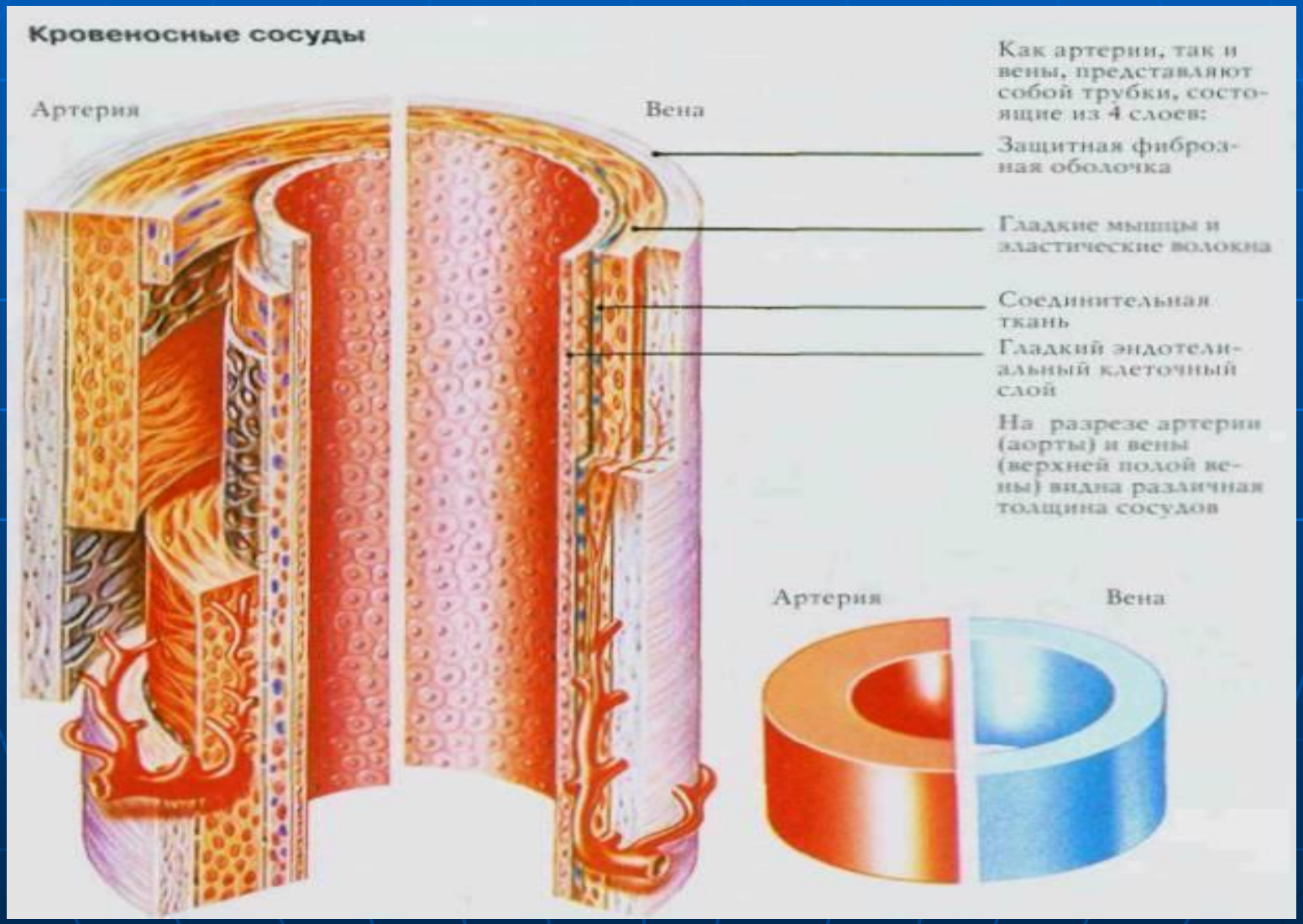

Лимфатическая система

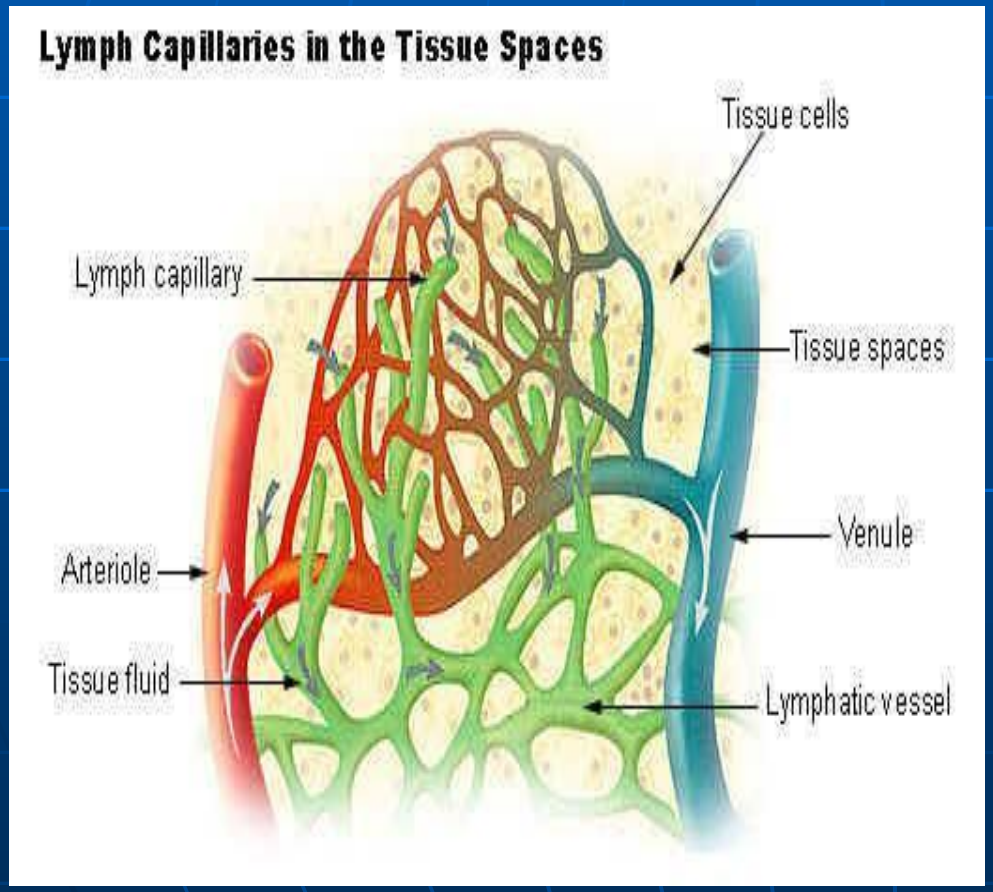

Дыхательная система

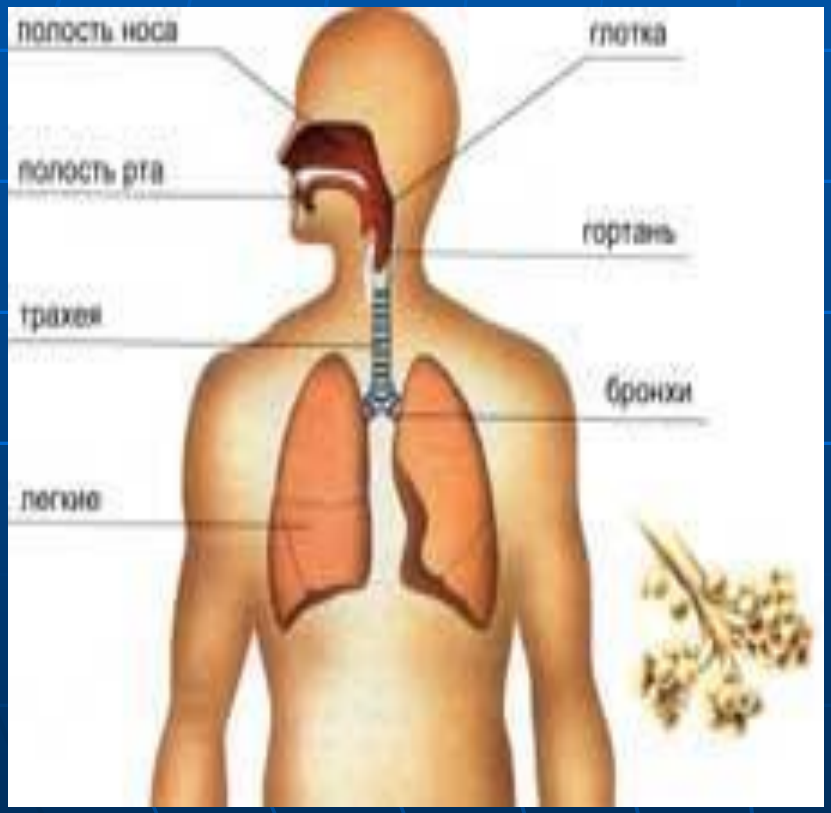

(1) дно желудка, (2) большая кривизна, (3) тело, (4) нижний полюс желудка, (5) привратниковая (пилорическая) часть, (6) отверстие привратника, (7) угловая вырезка, (8) малая кривизна, (9) складки слизистой оболочки

Анатомия пищеварительной системы

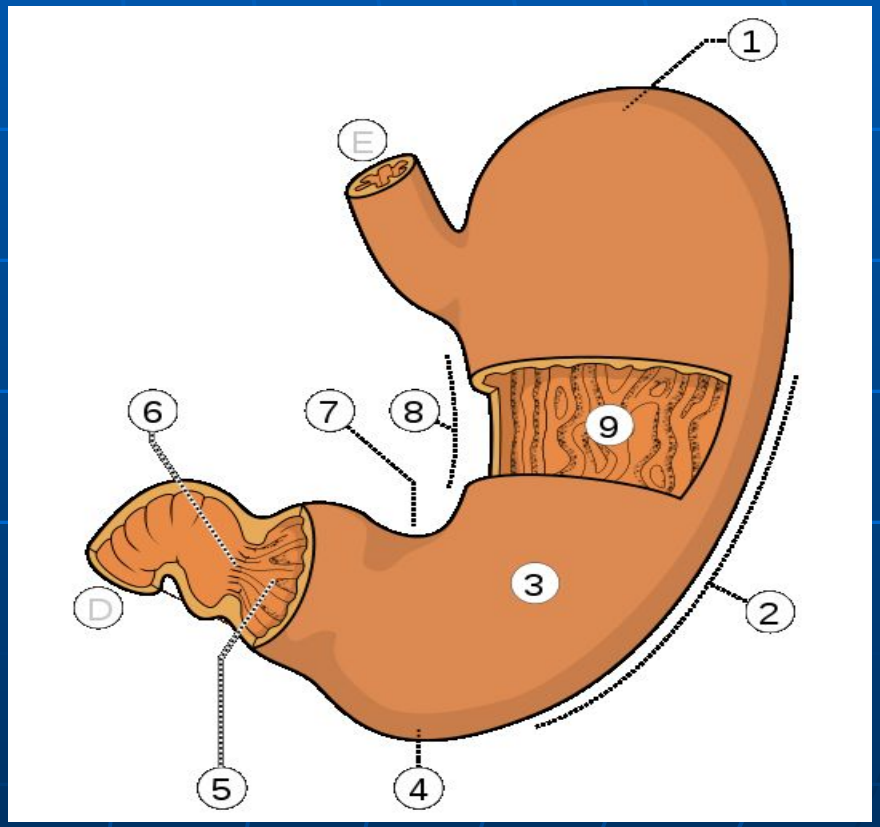

1-дно желудка; 2-большая кривизна; 3-тело; 4-нижний полюс; 5-привратниковая часть; 6-отверстие привратника; 7-угловая вырезка; 8-малая кривизна; складки слизистой оболочки

Строение печеночной дольки

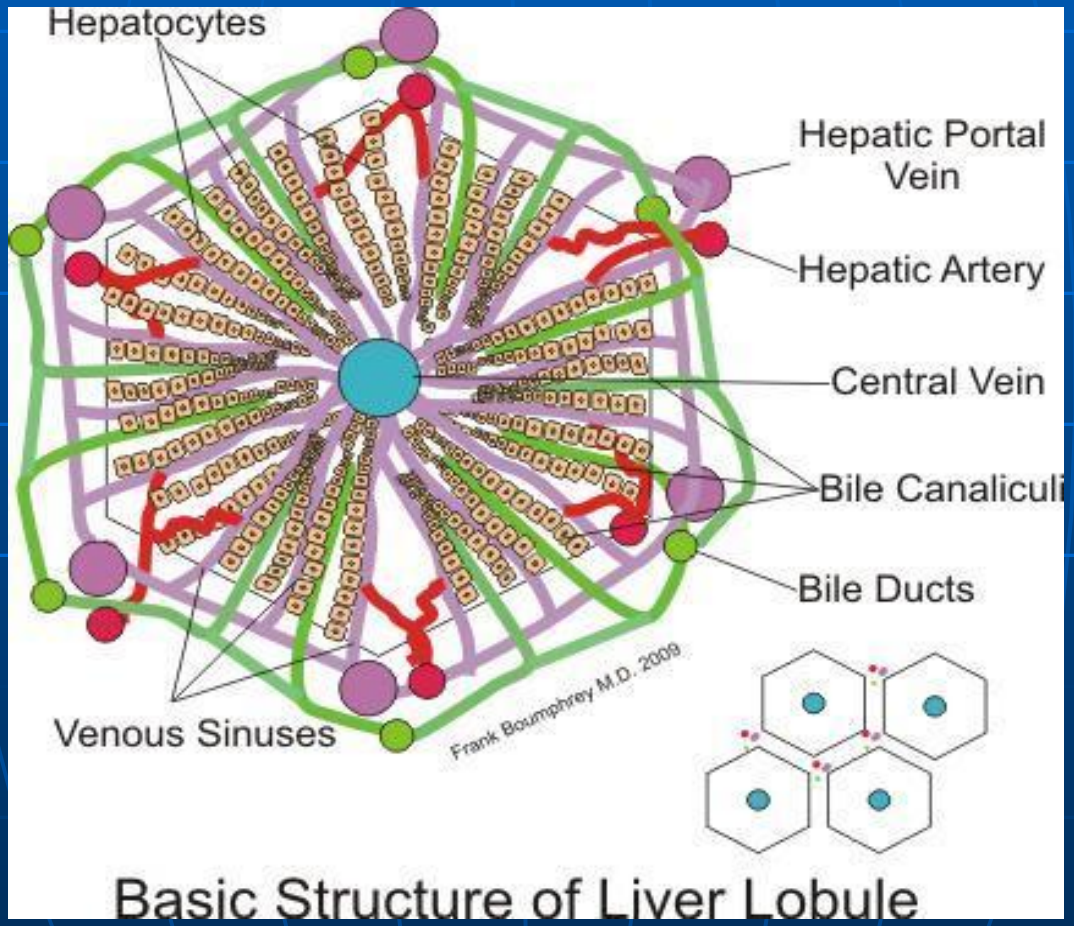

Поджелудочная железа

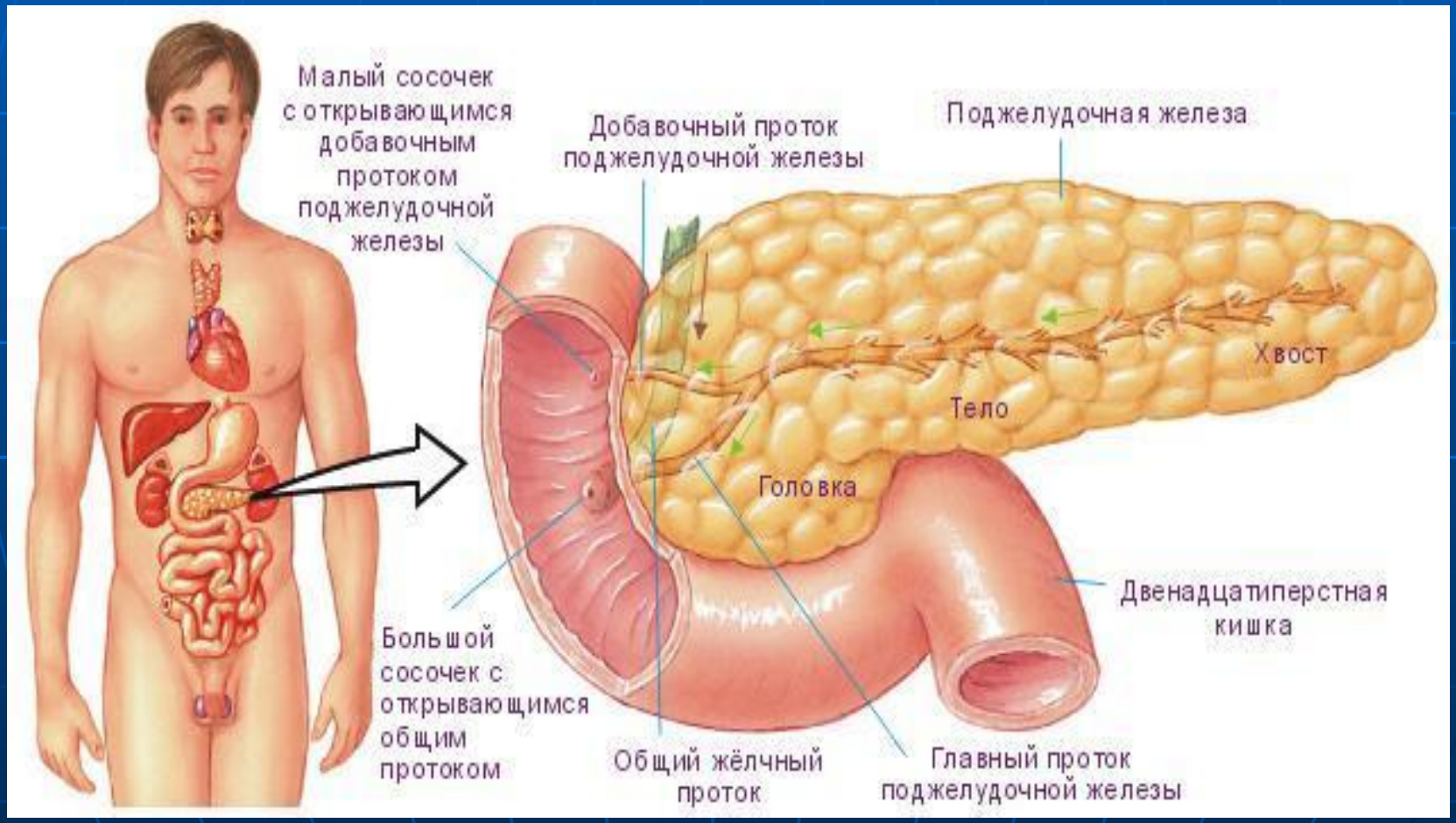

Мочевыделительная система

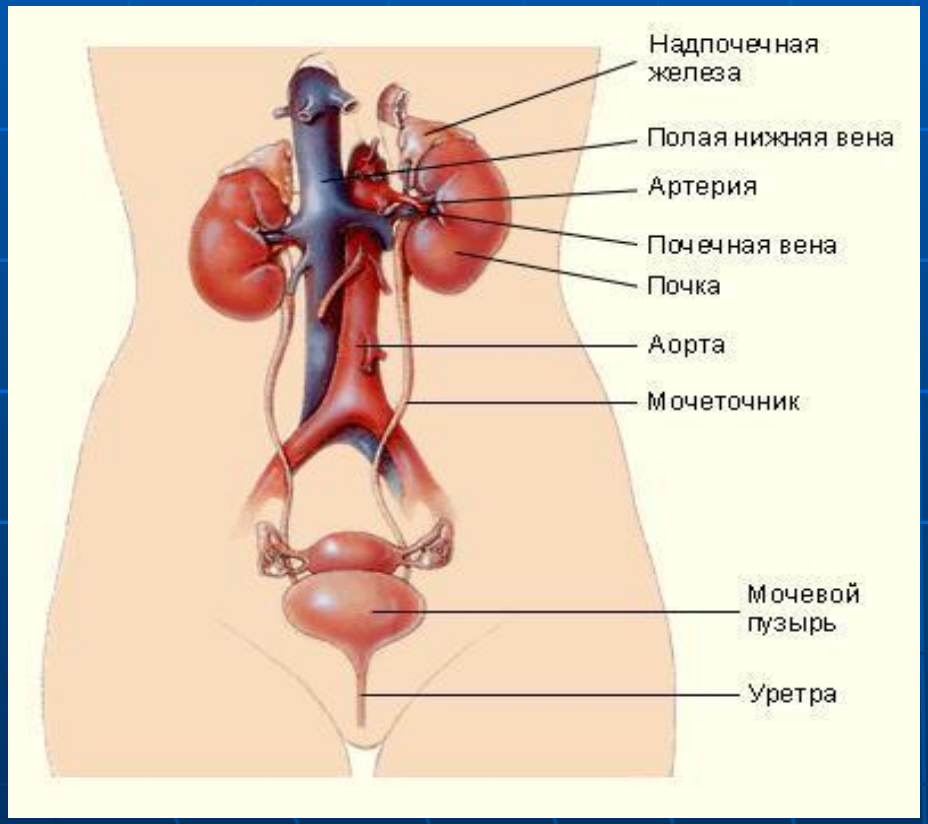

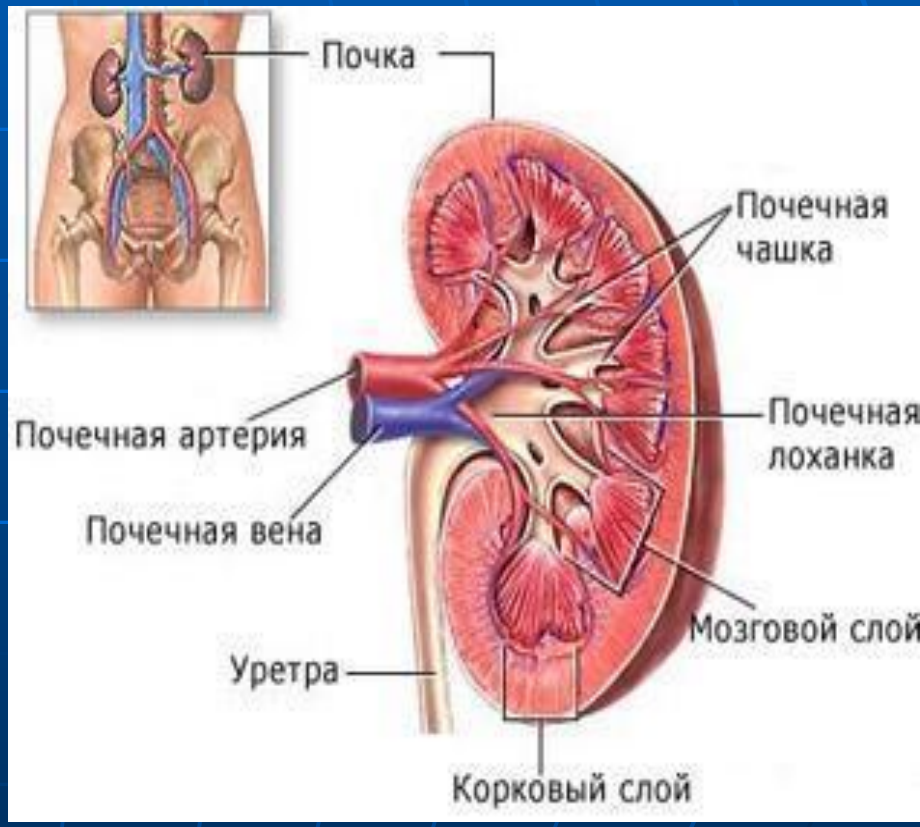

Центральная нервная система

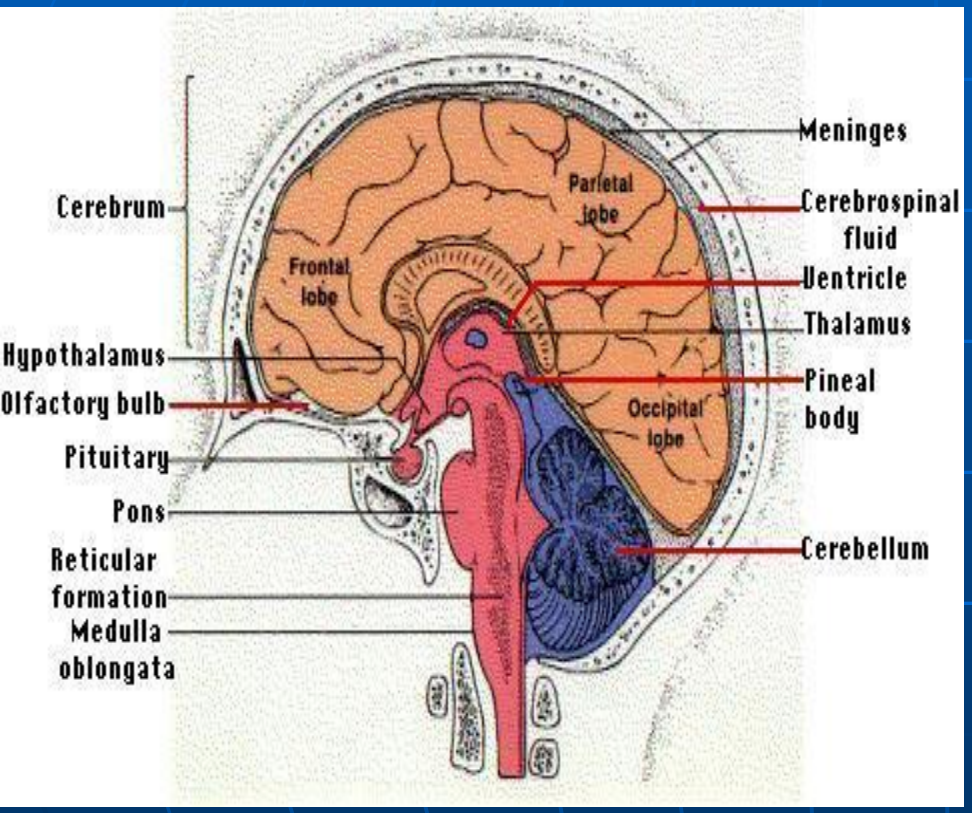

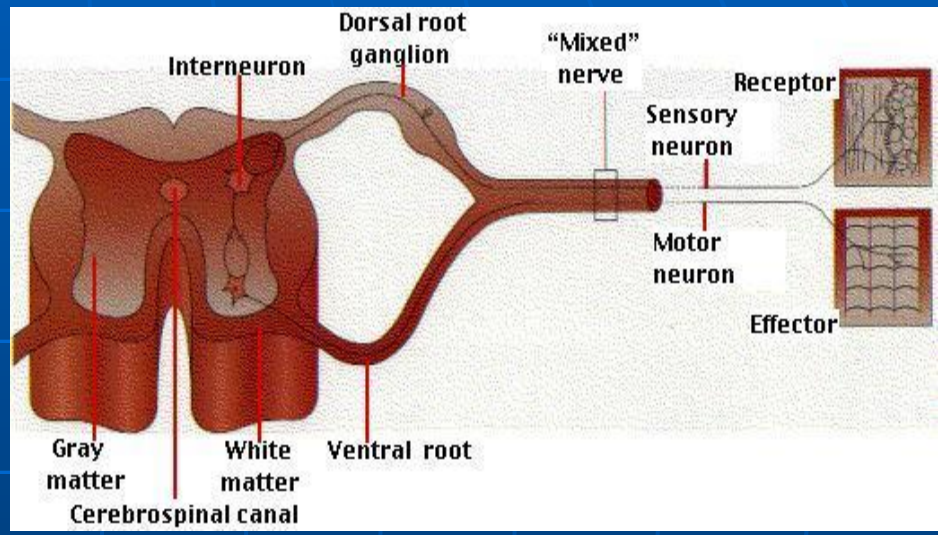

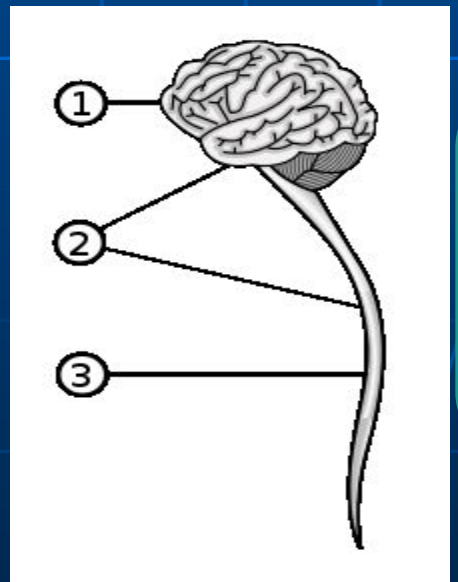

1 – головной мозг
2 – ЦНС
3 – спинной мозг

Эндокринная система

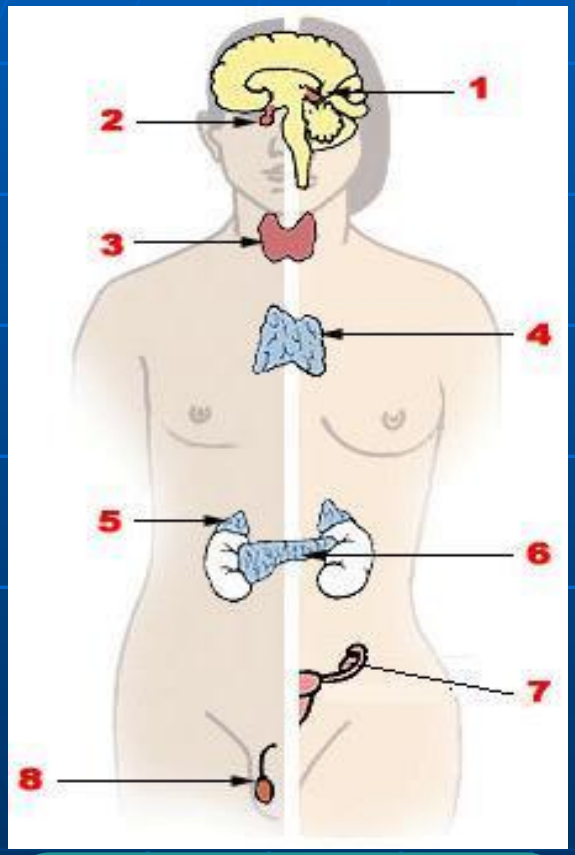
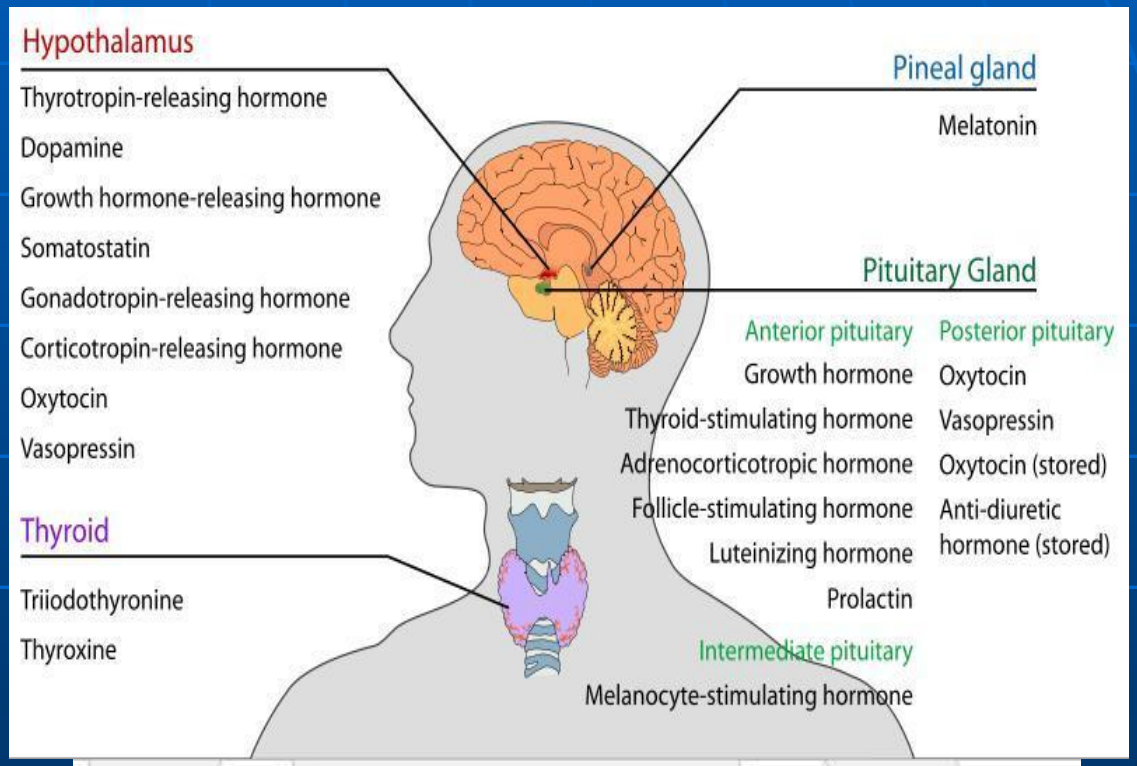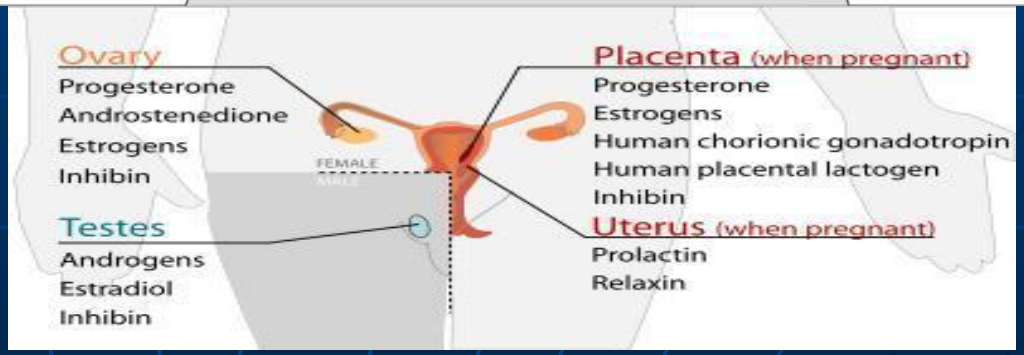
Основные эндокринные железы. (Мужчины слева, женщины справа.) 1. Шишковидныежелезы 2. Гипофиз 3. Щитовидноая железа 4. Thymus 5. Надпочечники6. Поджелудочная железа 7. Яичники 8. Яички