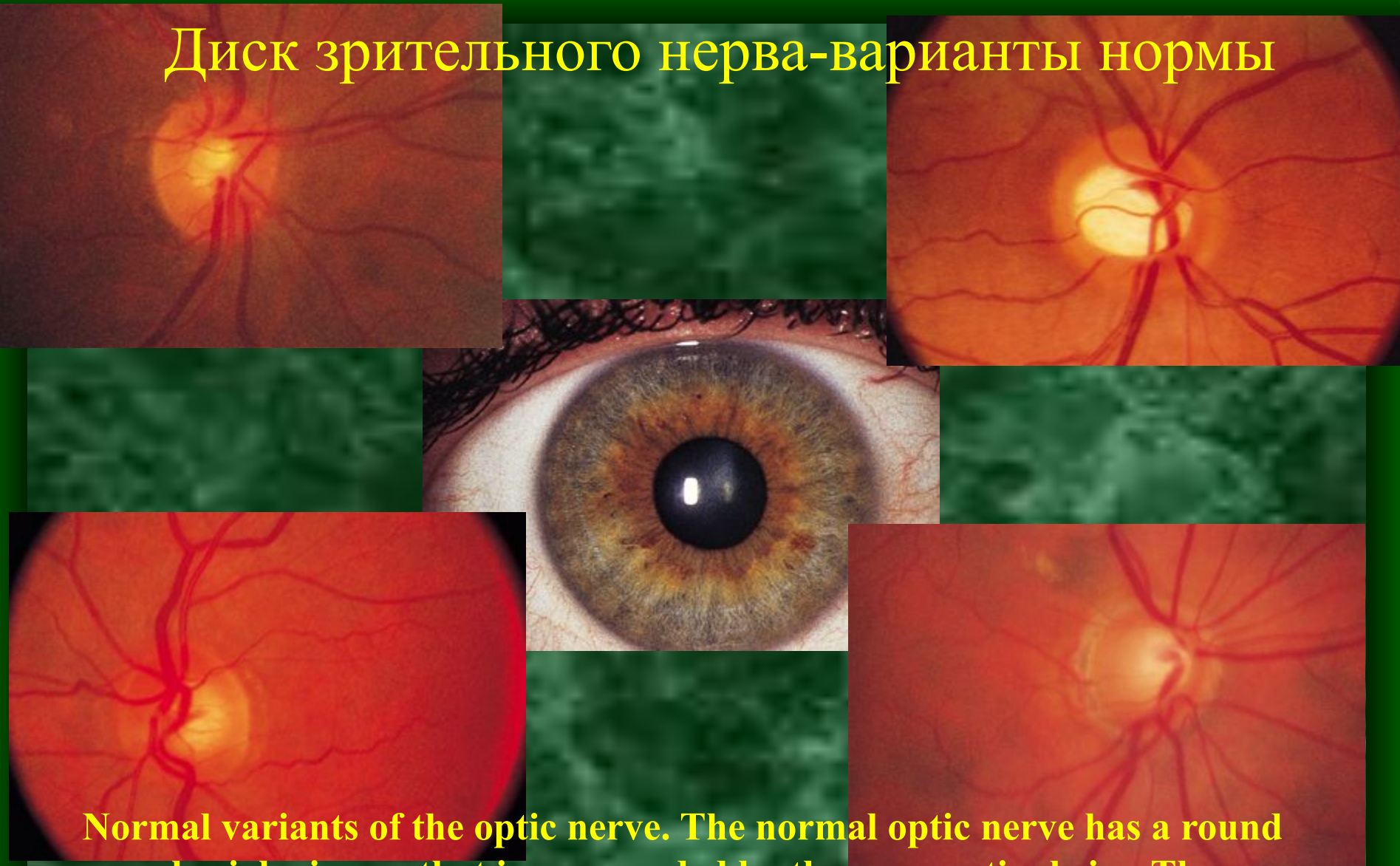

Доцент В.И.Барашков

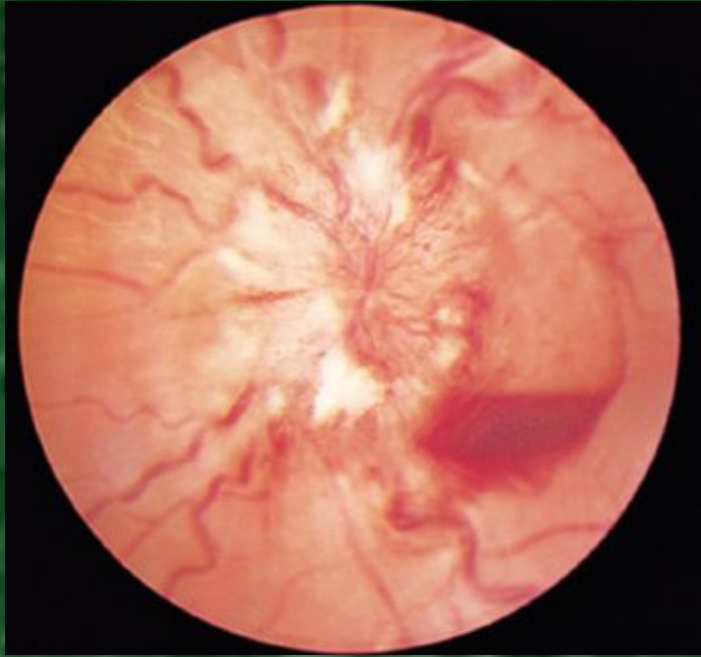Изменения зрительного нерва при общих заболеваниях:

- Воспалительном процессе.
- Внутричерепной гипертензии
- Сосудистой патологии.
- Врожденной патологии

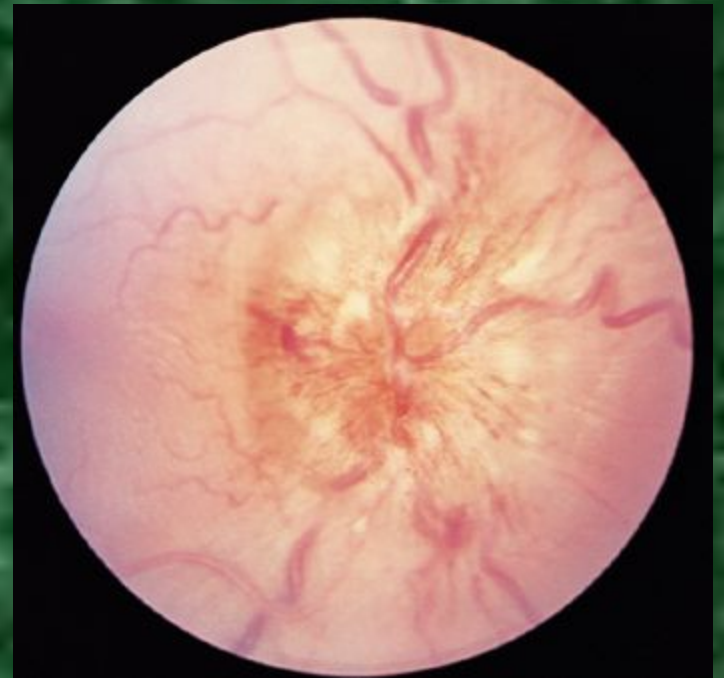Диск зрительного нерва-варианты нормы

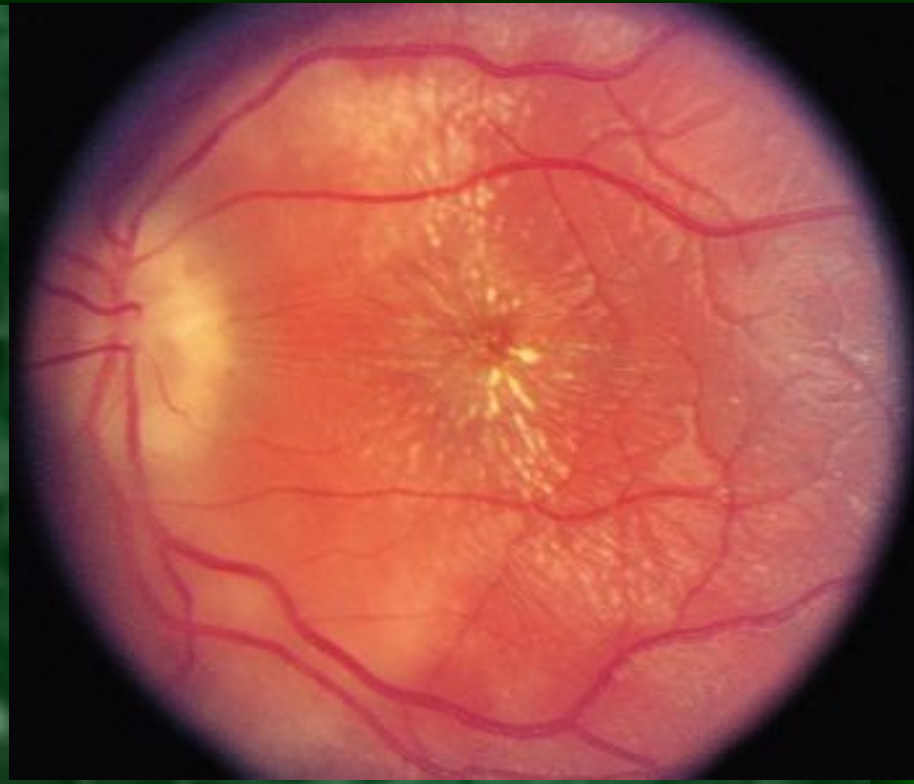
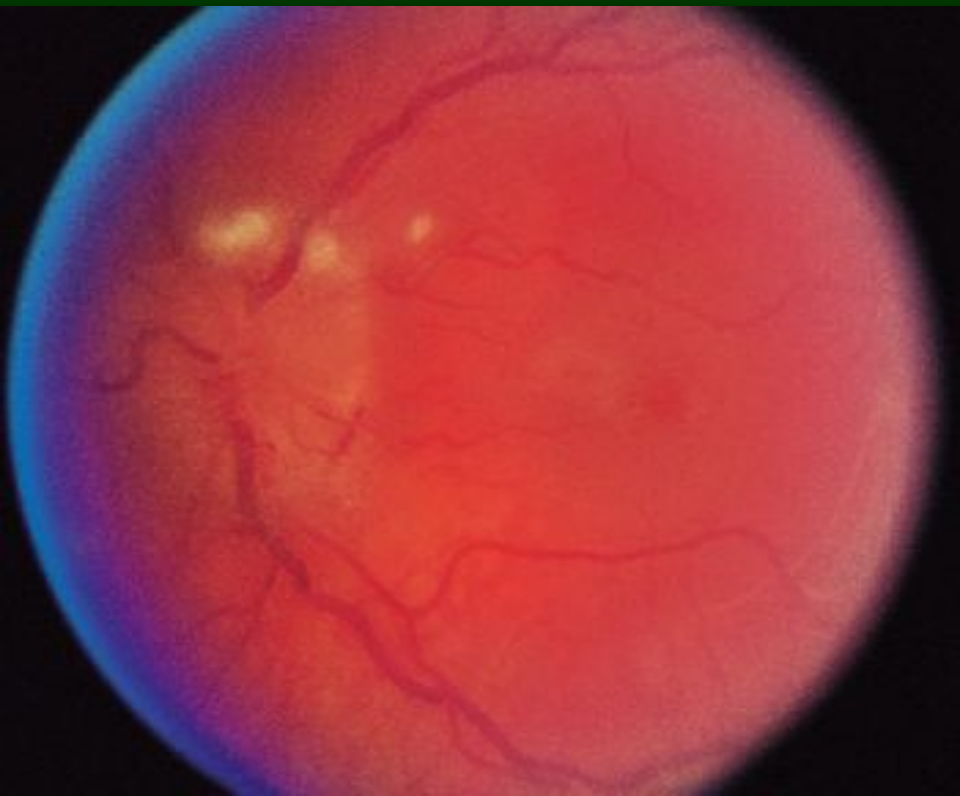

Normal variants of the optic nerve. The normal optic nerve has a round physiologic cup that is surrounded by the neuroretinal rim. The neuroretinal rim is formed by the edges of the neural retina, retinal pigment epithelium, choroid, and sclera at the disc margin. The inferior neuroretinal rim is usually the thicker quadrant.



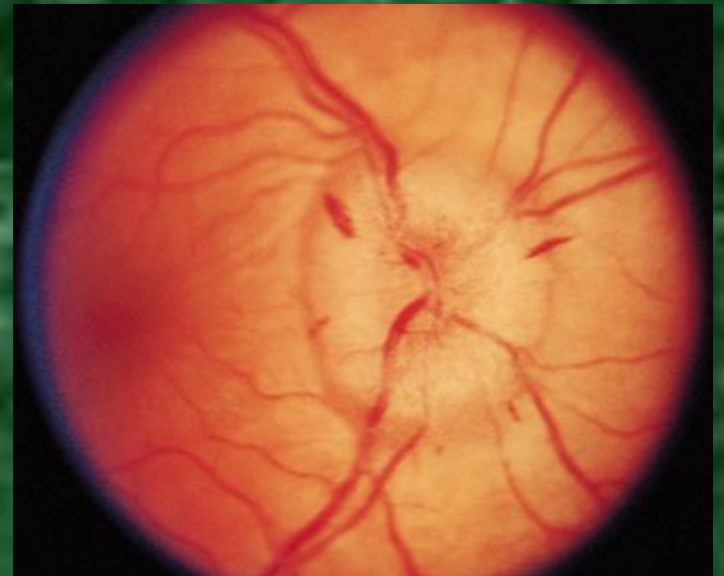
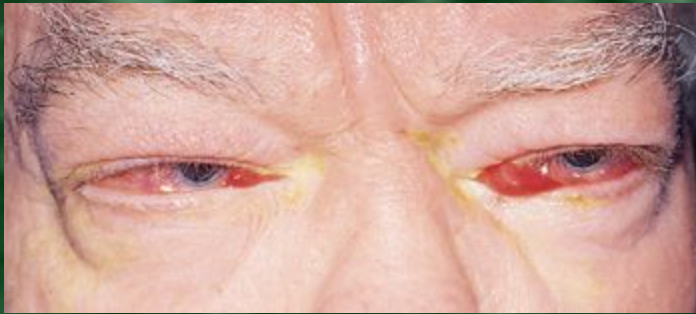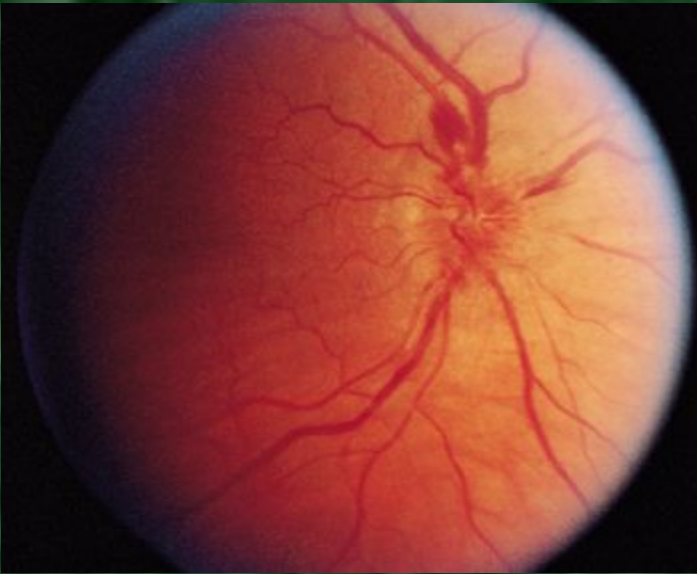Thyroid eye disease. The patient is a 63-year-old man with advanced thyroid-related optic neuropathy. The presenting visual acuity was 20/80 and 20/100, respectively. A, External photograph with marked bilateral chemosis. B and C, Bilateral disc swelling with choroidal folds emanating from optic disc. D,



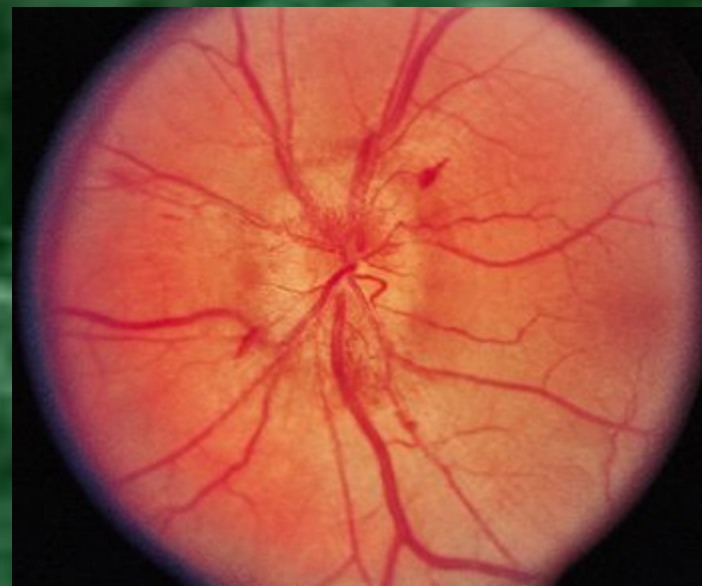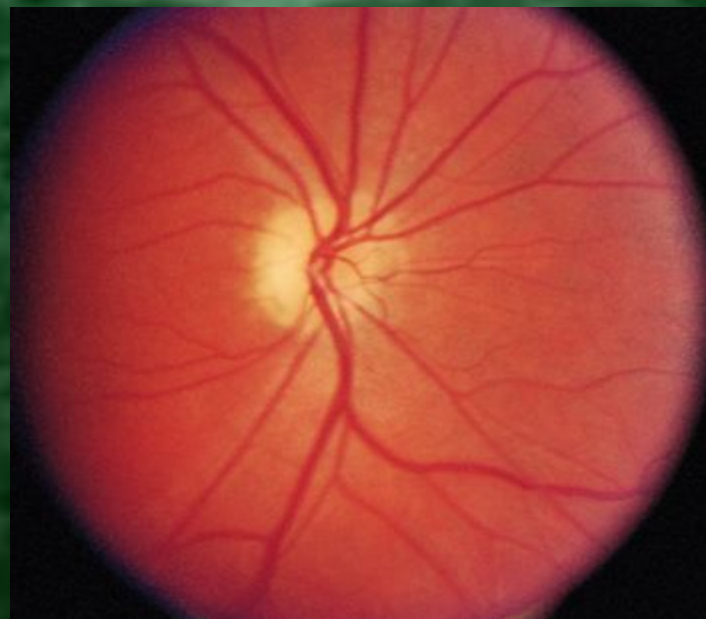

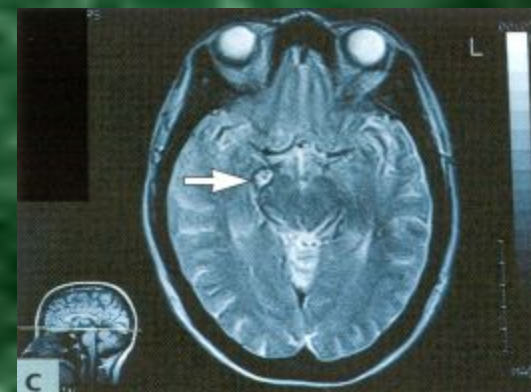
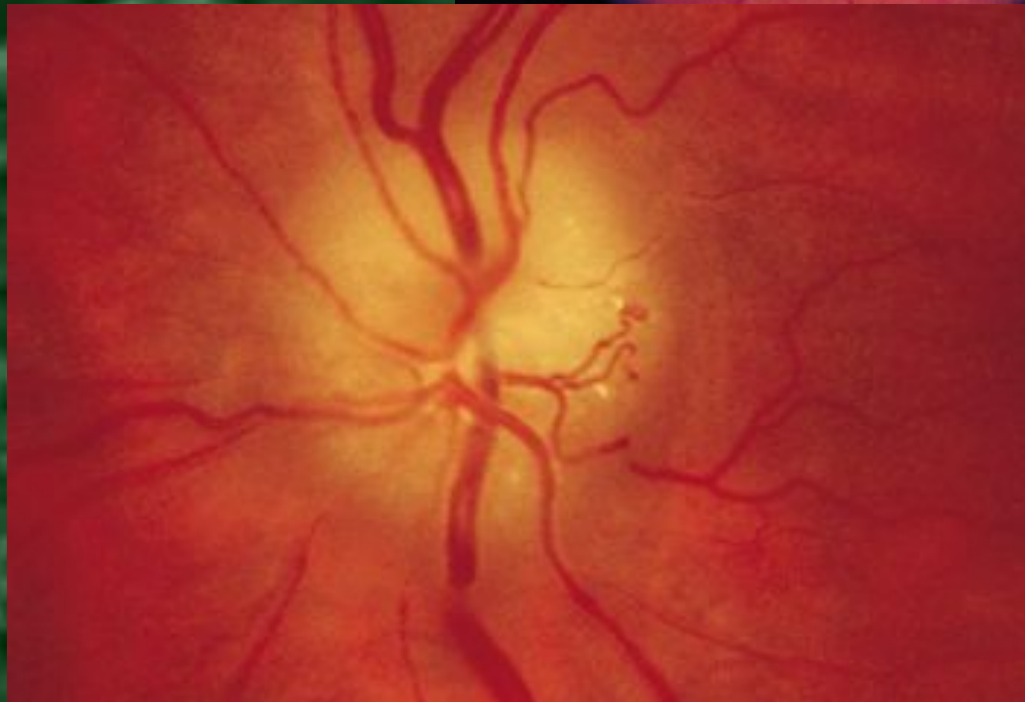
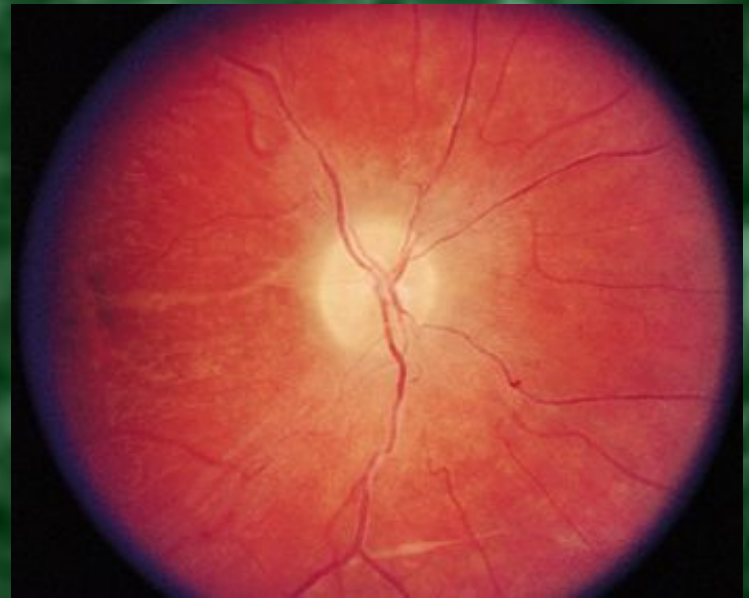
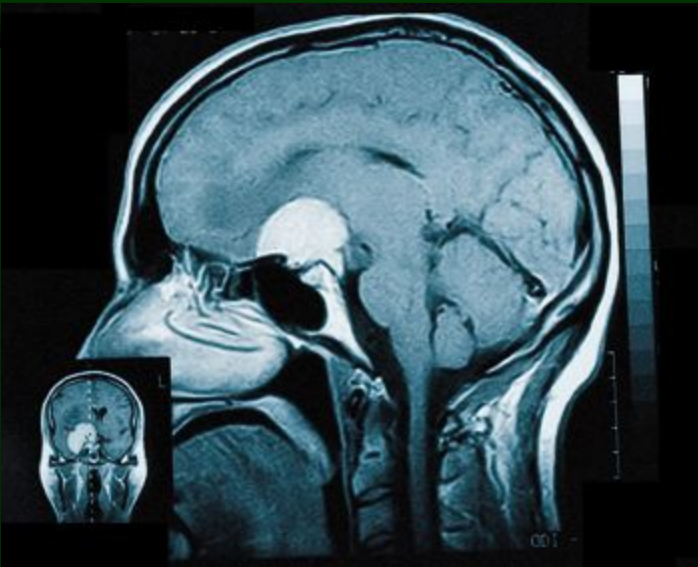
Axial computed tomography scan showing orbital apex congestion bilaterally secondary to marked muscle enlargement (arrows). The patient underwent bilateral orbital radiation and orbital decompression. Final visual acuity was 20/40 in each eye.

Нейропатия при гипертериозе.

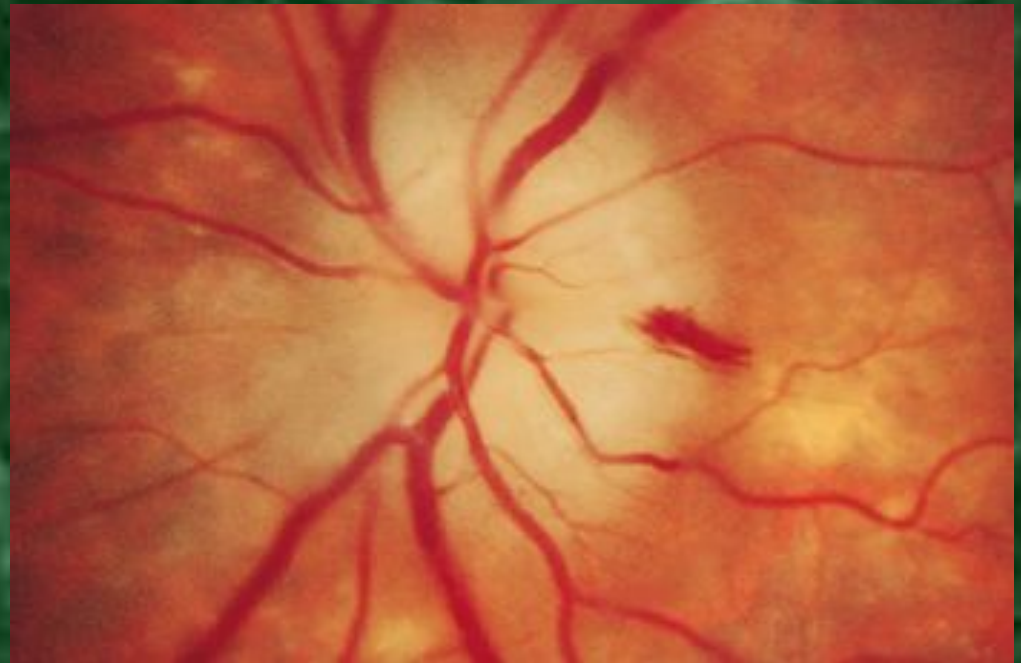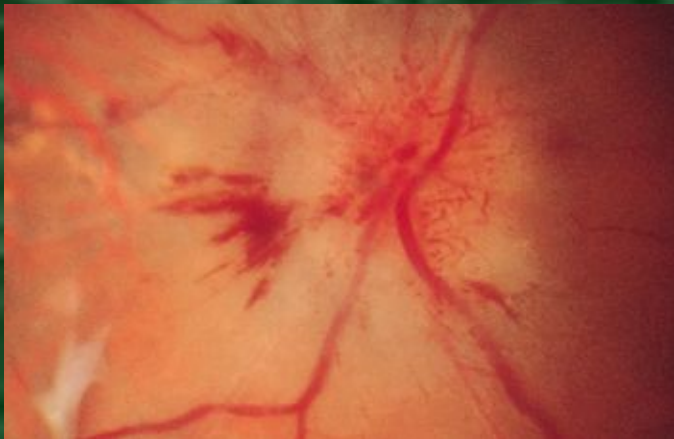


Синдром Форстнера- Кеннеди. Картина атрофии з.н. На правом глазу и застойного соска на левом. На рентгенограмме локализация опухоли справа.

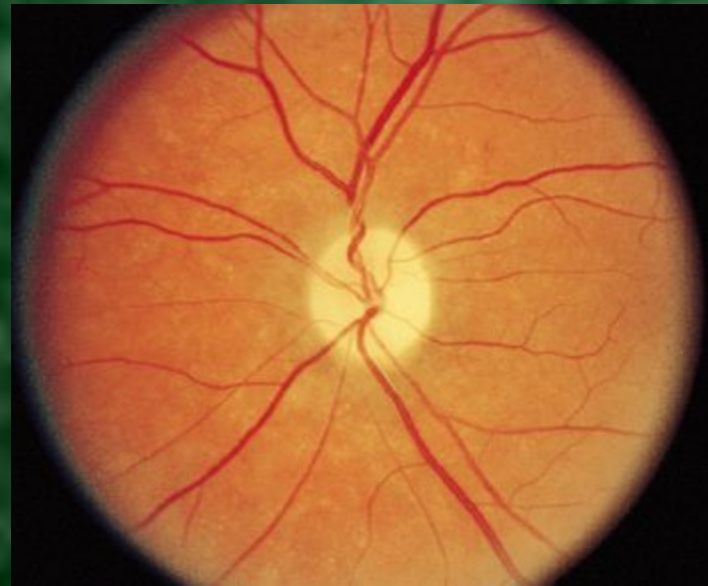
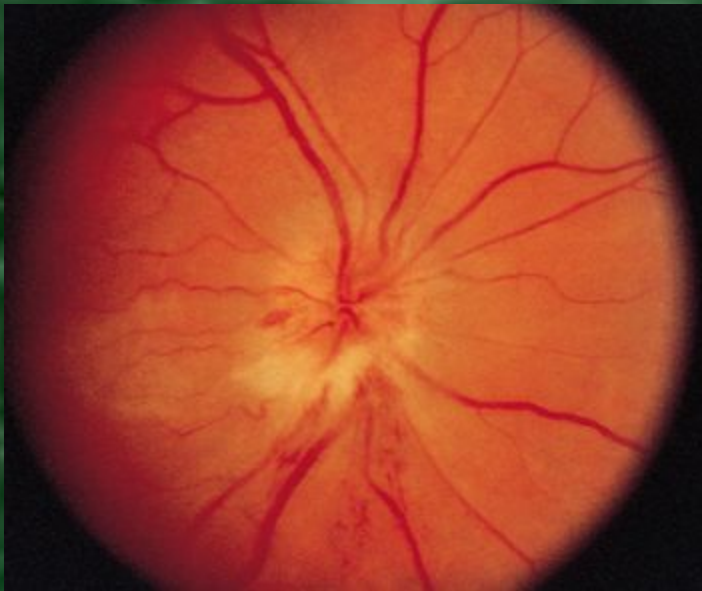


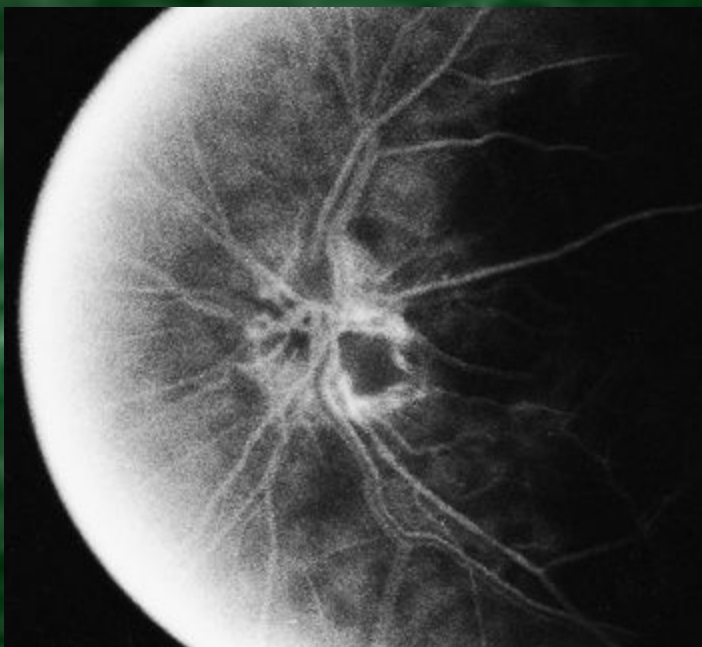

Fully developed papilledema. Advanced papilledema in a patient with pseudotumor cerebri. There is marked disc elevation and vessel engorgement bilaterally with complete loss of the disc margins and central cup.

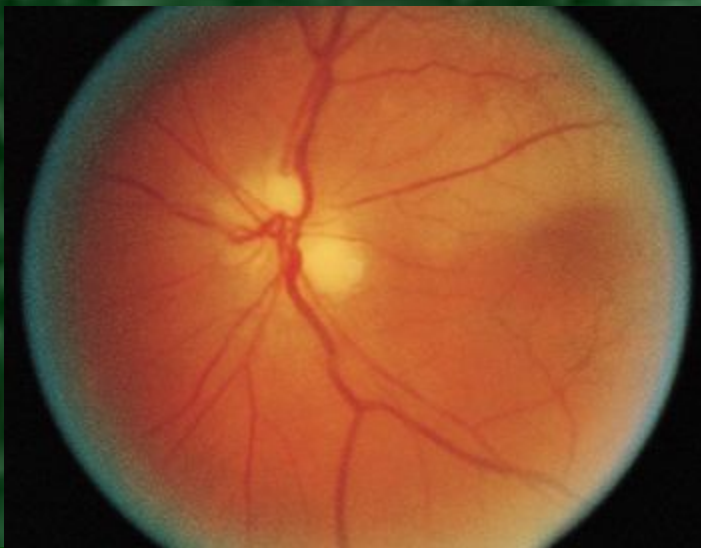

Передняя ишемическая
оптикопатия. Динамика развития.

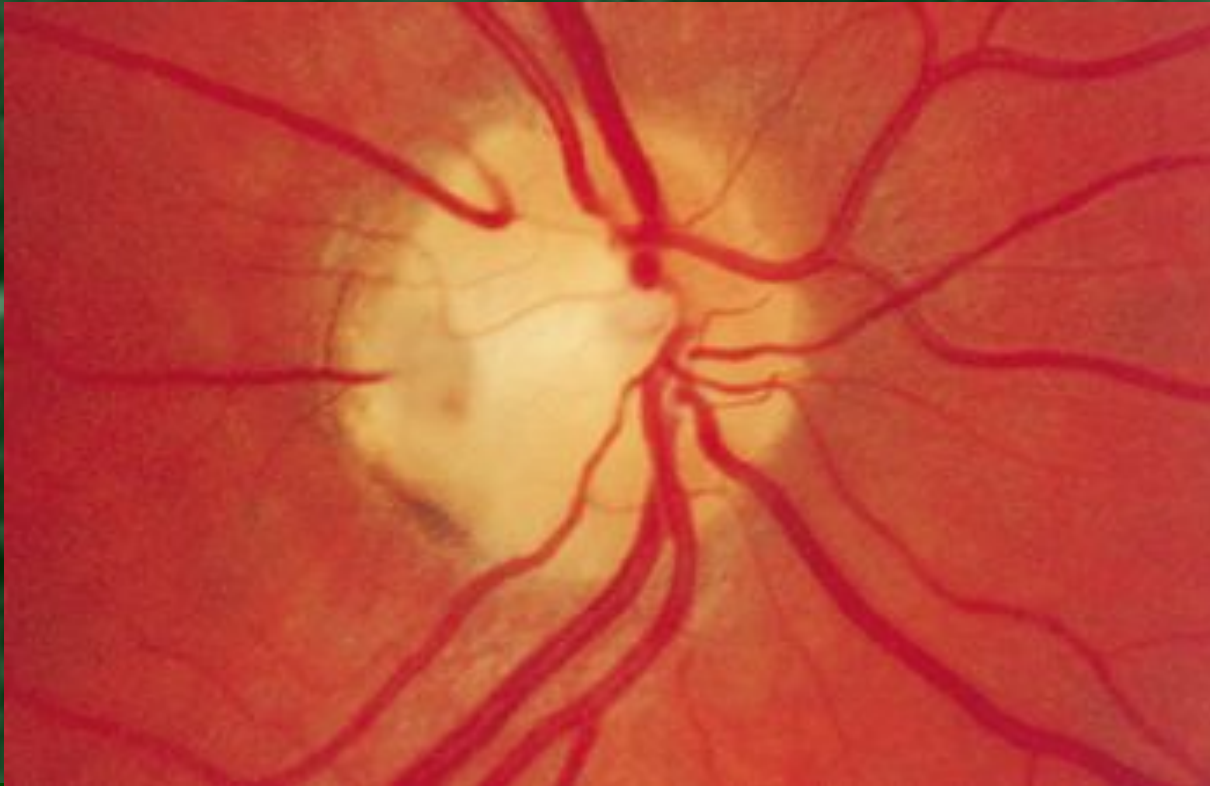



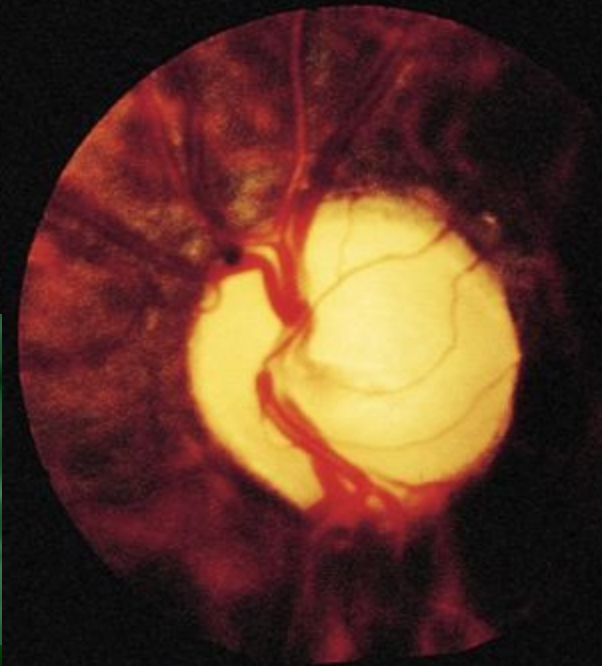
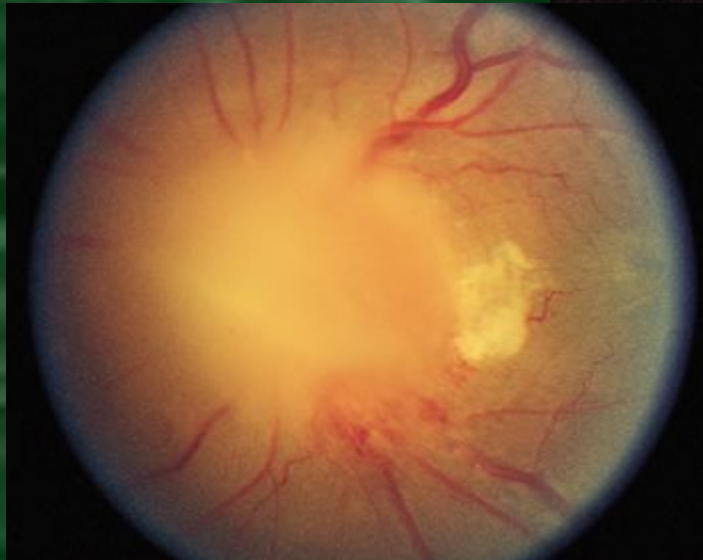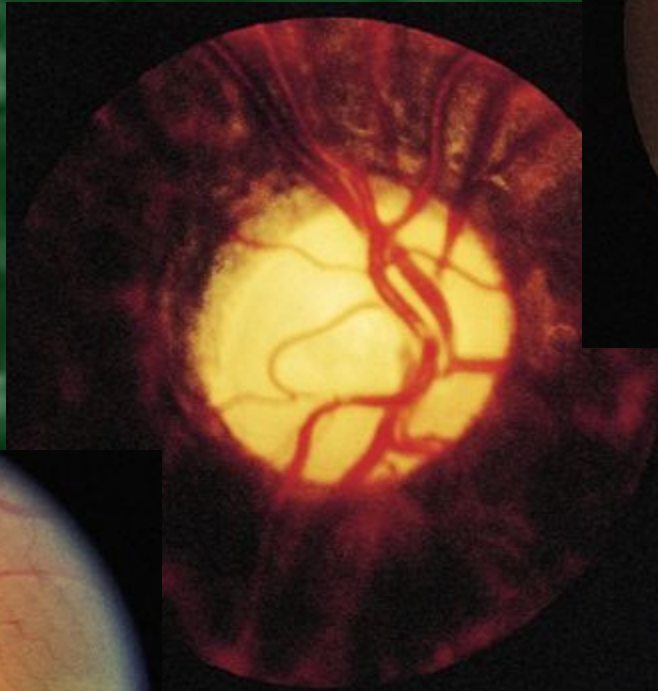
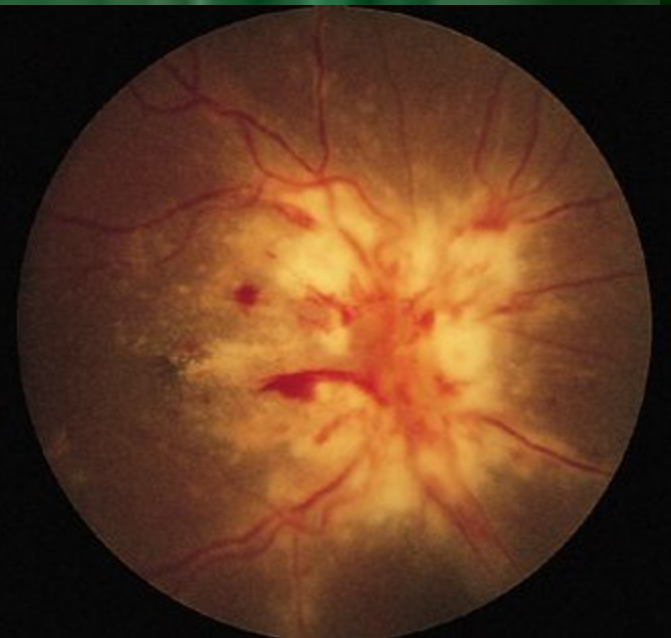
Передняя ишемическая
оптикопатия.
Ангиографическая
картина.



Друзы зрительного нерва.



Колобома зрительного нерва



Благодарим
за внимание.

Надеемся, что дальнейшие выступления будут оформлены по образцу настоящей презентац или лутше. С ув. Докладчик

