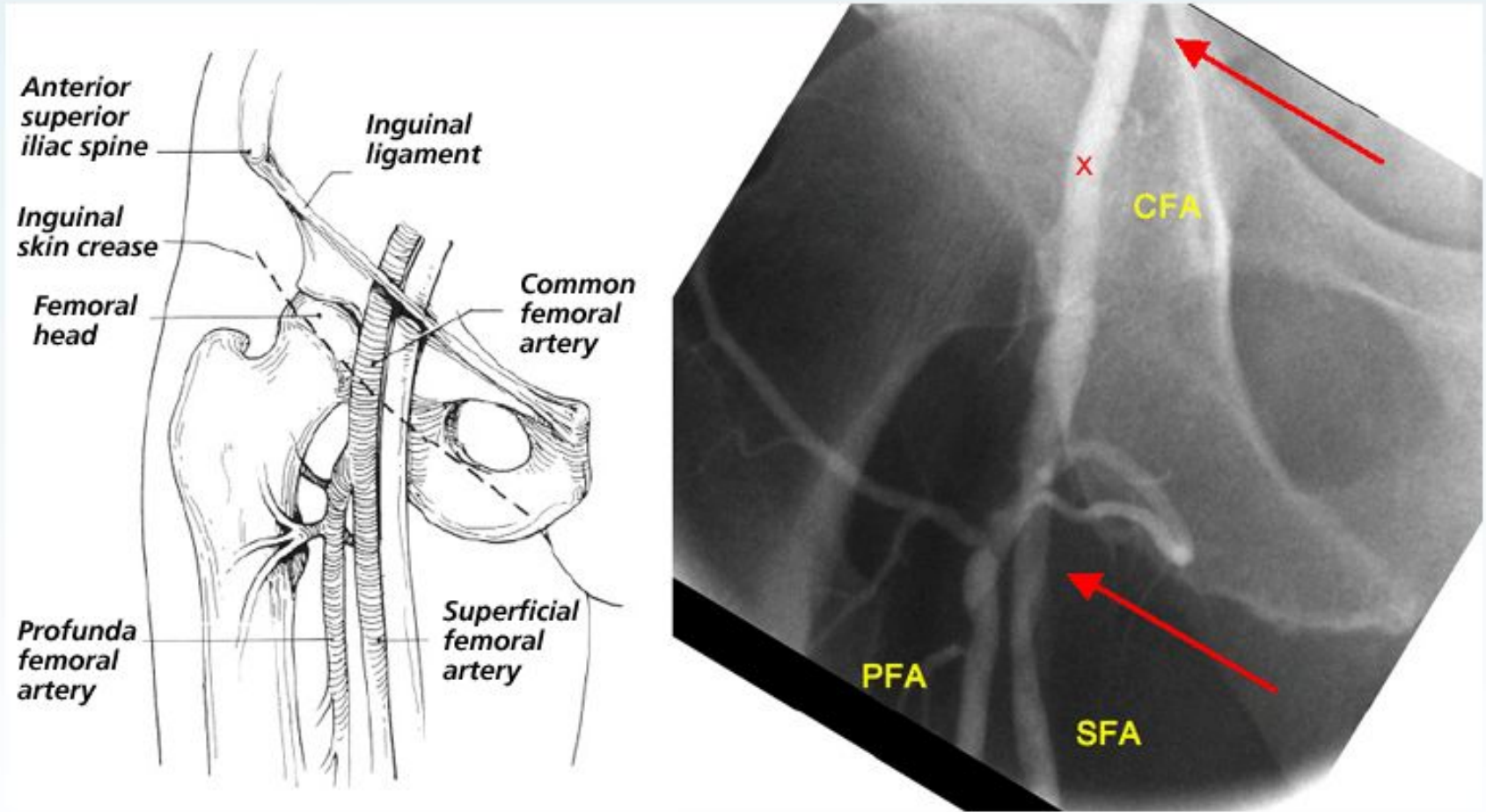
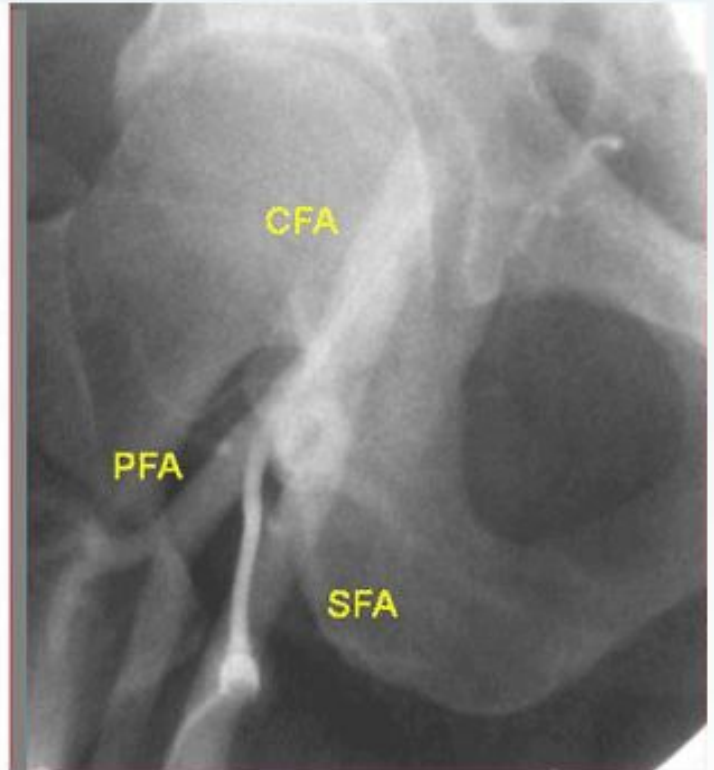
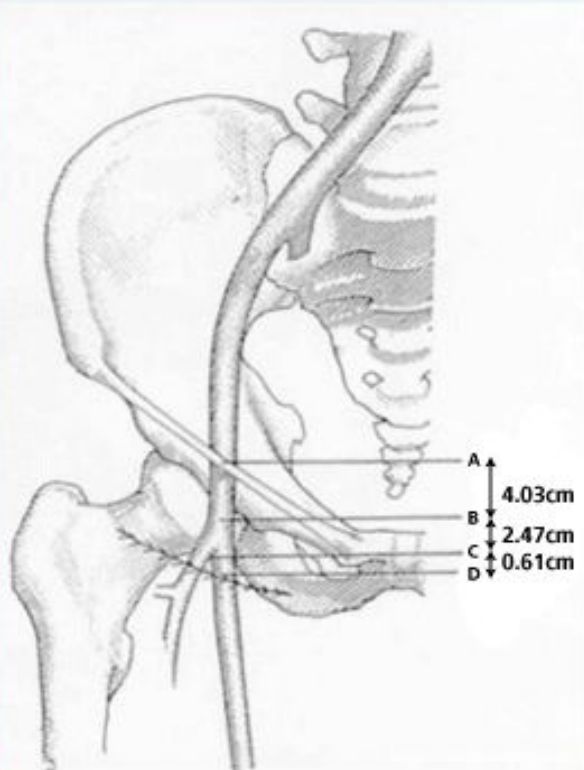
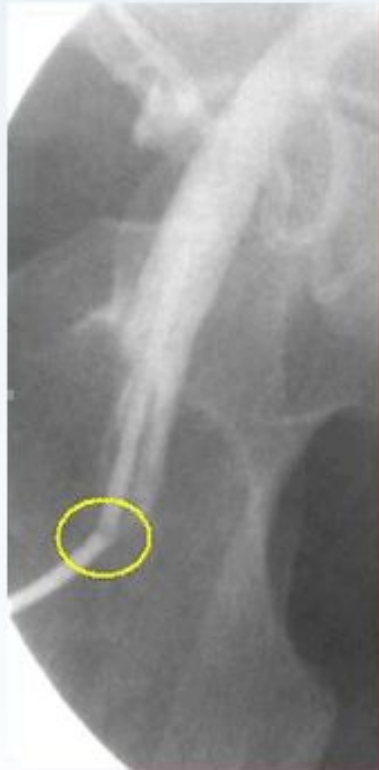

Anatomy and Puncture Site

"Normal" Anatomy

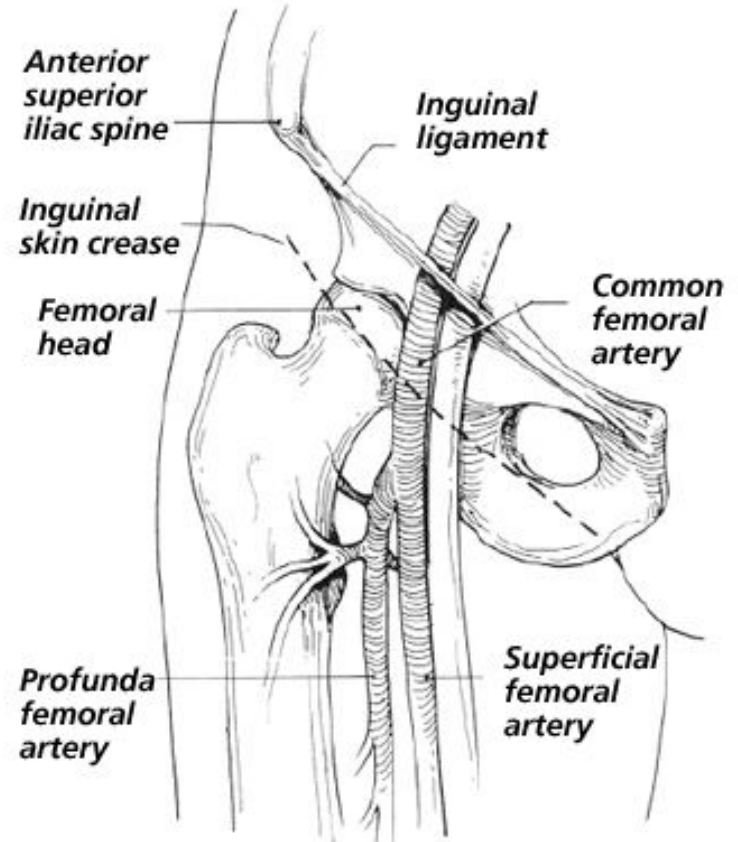
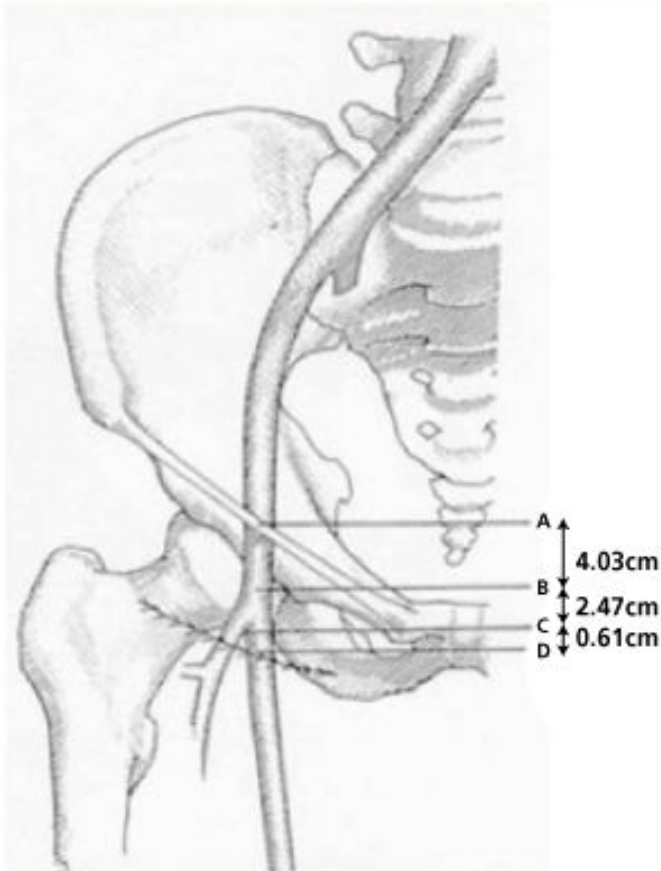


Misconceptions despite 50 years experience

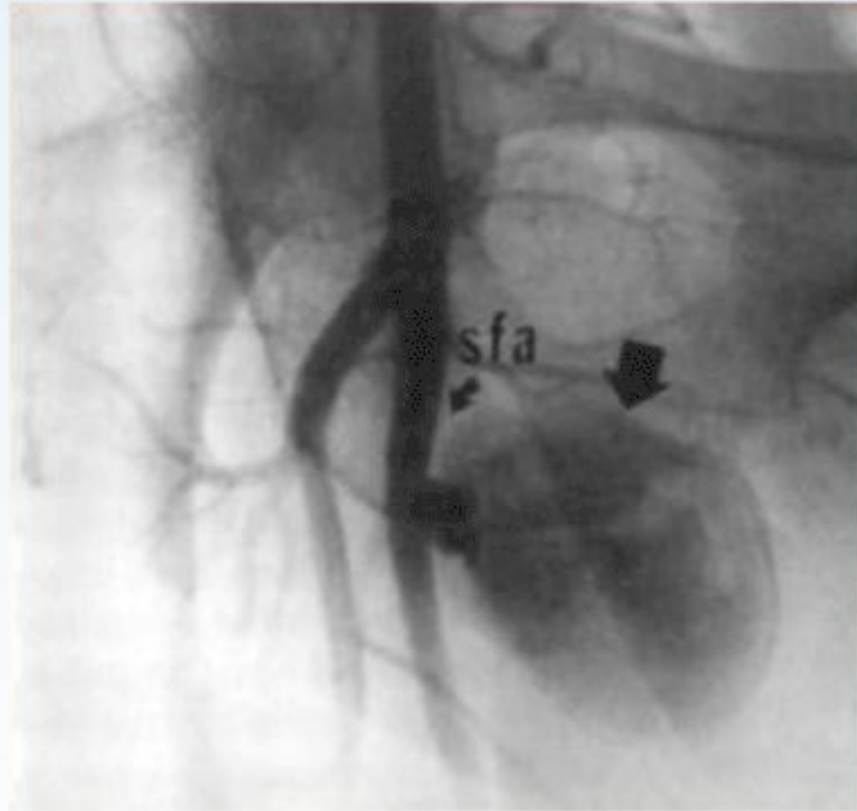


CFA and Landmarks

- Skin Crease
 - Bifurcation above crease in 71.9%
 - Mean distance above skin crease 6.1 mm

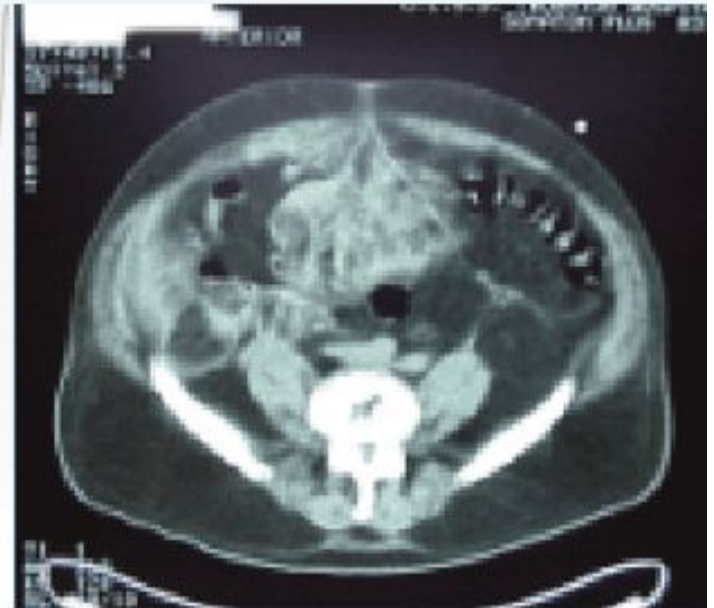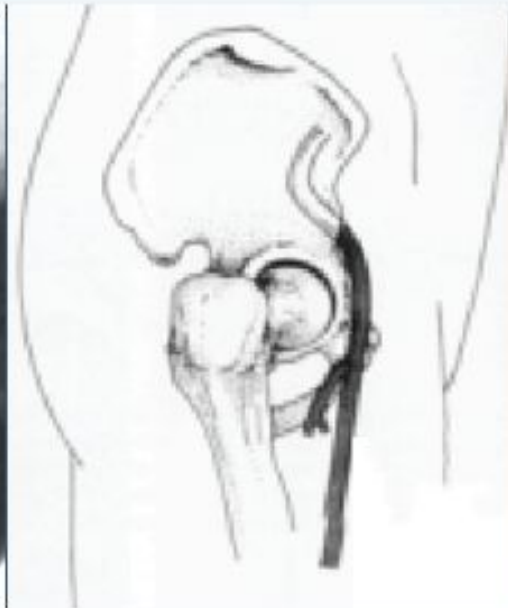

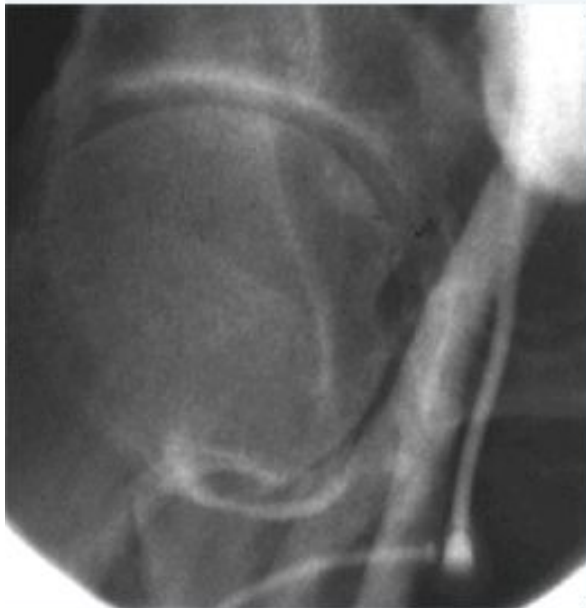
Low Puncture

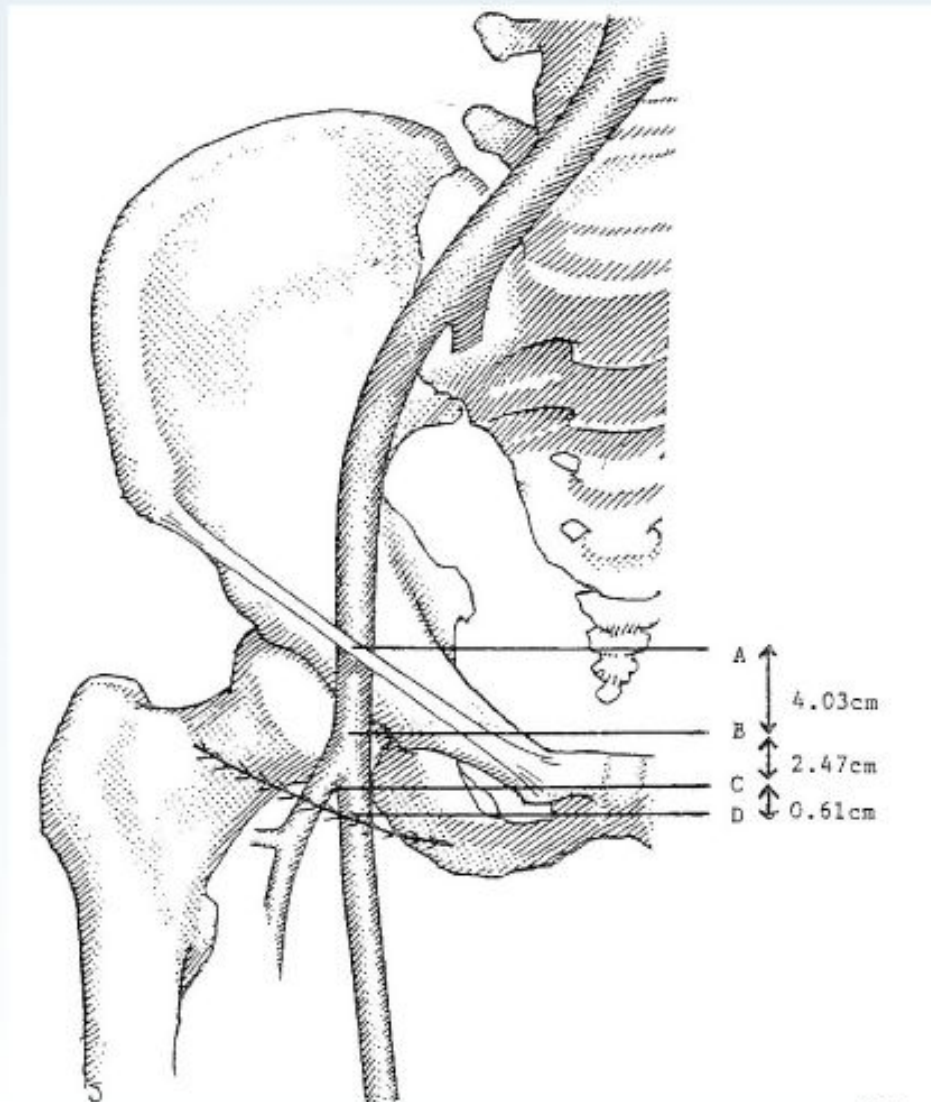


High Puncture

“High” puncture of the femoral artery: Increases risk of retroperitoneal bleeding



Femoral Artery Puncture



Grier et al. *Br J Radiol* 1990;63:602

Arterial Puncture Angle

