Эндоваскулярная хирургия

Вопросы нейроинтервенции

Орлов Е.А.
Москва
2021

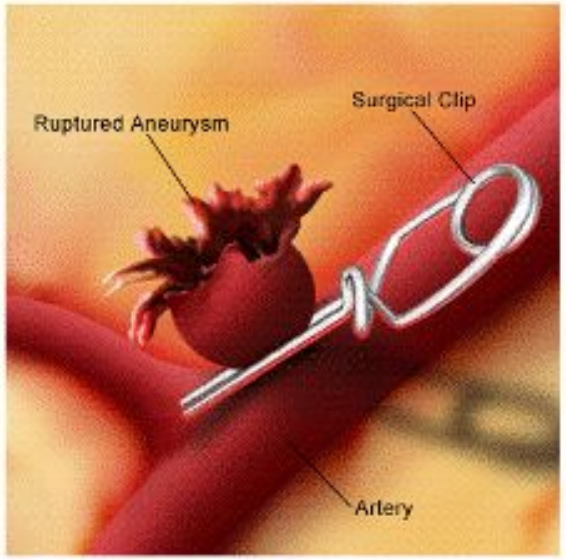

Dandy
1938



Yasargil
1967

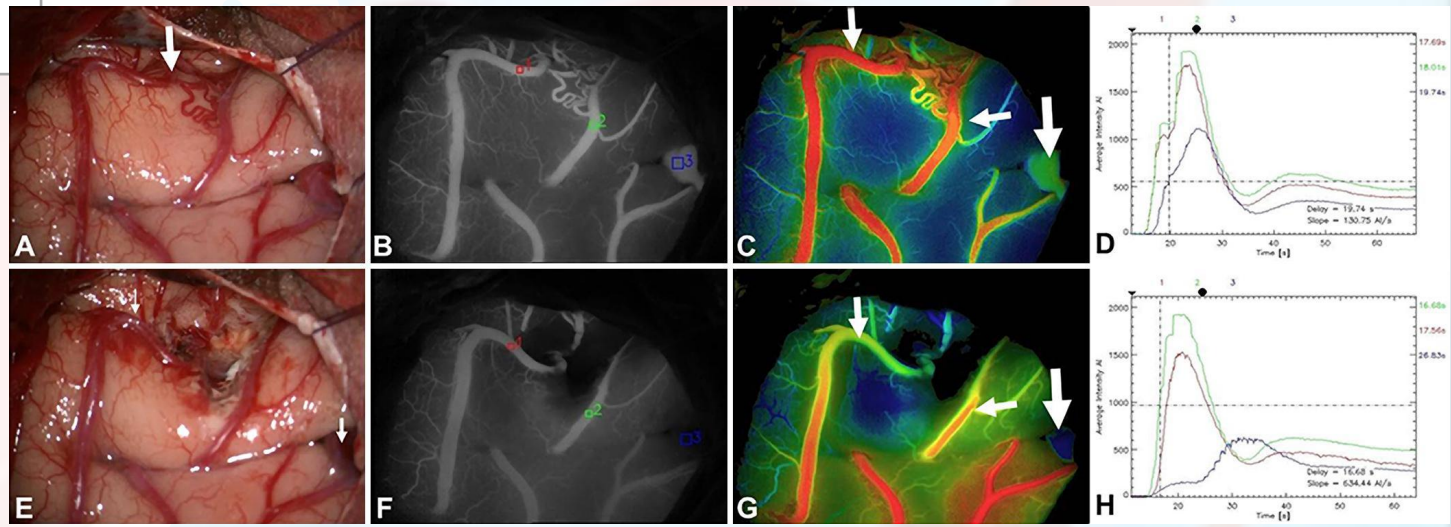

Raabe
2003

Langer
2018

Egas Moniz
1927

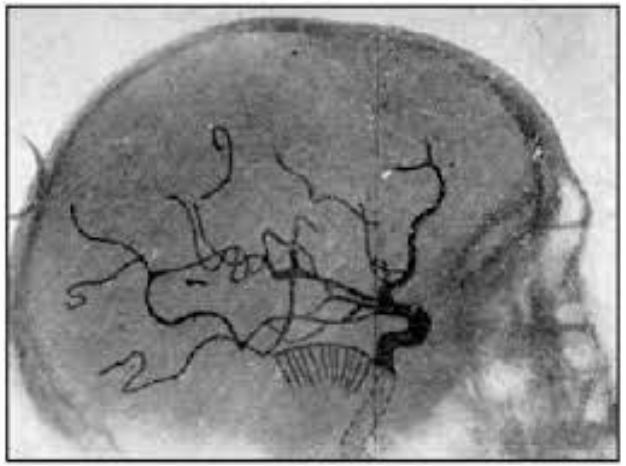

Guglielmi
1990

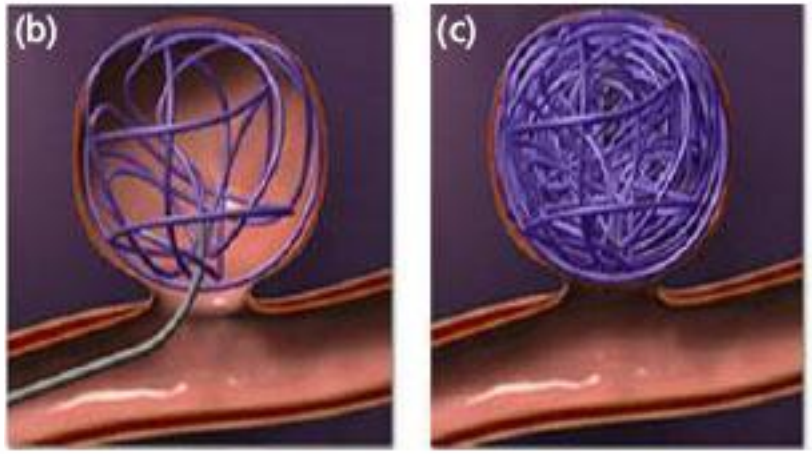

Nelson
2011

Pierot
2019

Применение сегодня

- Церебральная ангиография
- Лечение ОНМК (ИИ)
- Стентирование каротидных артерий
- Выключение аневризм
- Эмболизация АВМ и АВ-фистул
- Лечение вазоспазма
- Предоперационная эмболизация опухолей
- Лечение венозных мальформаций

(вены Галена) и синус-тромбозов

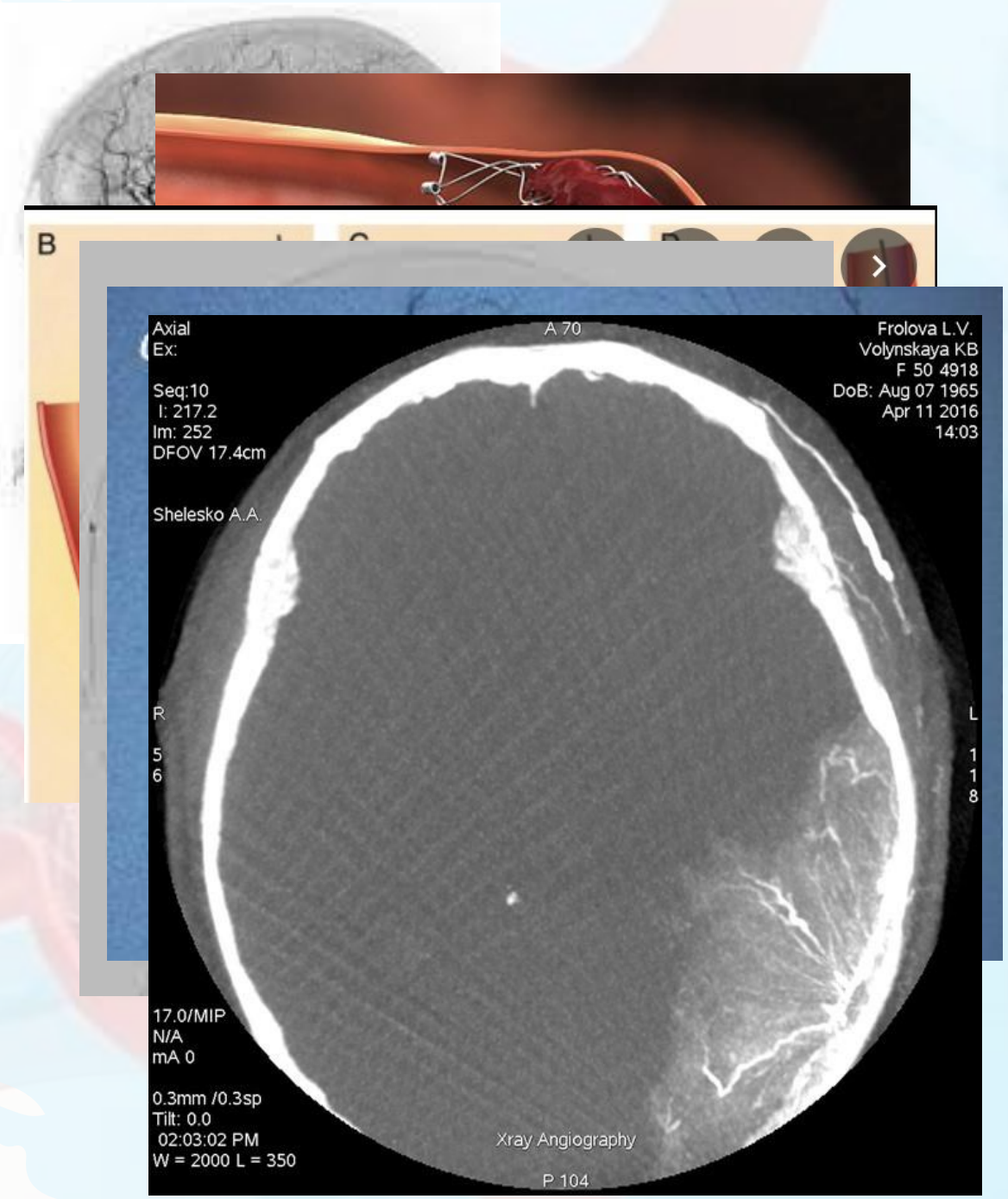

Церебральная ангиография – ACA

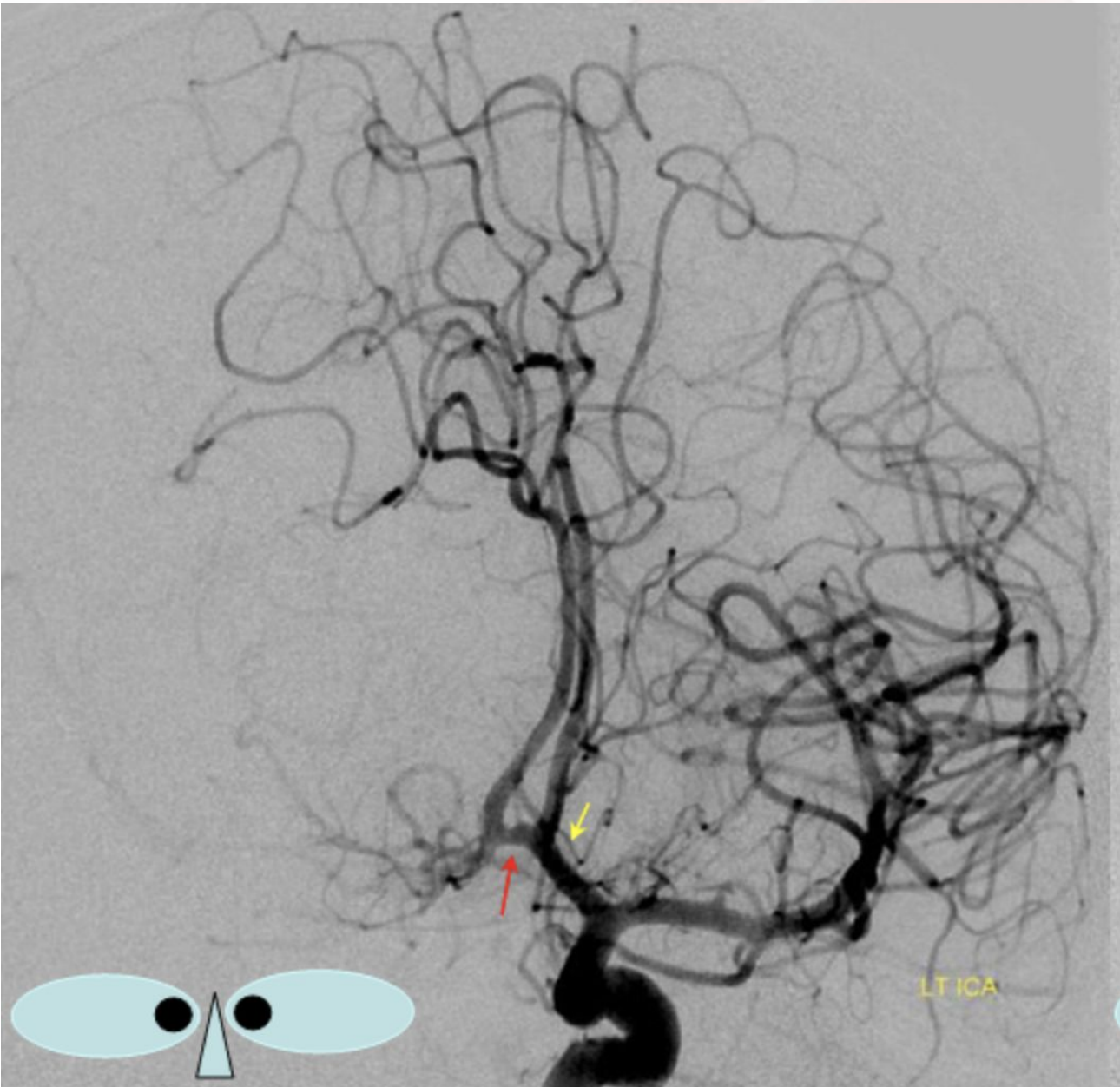

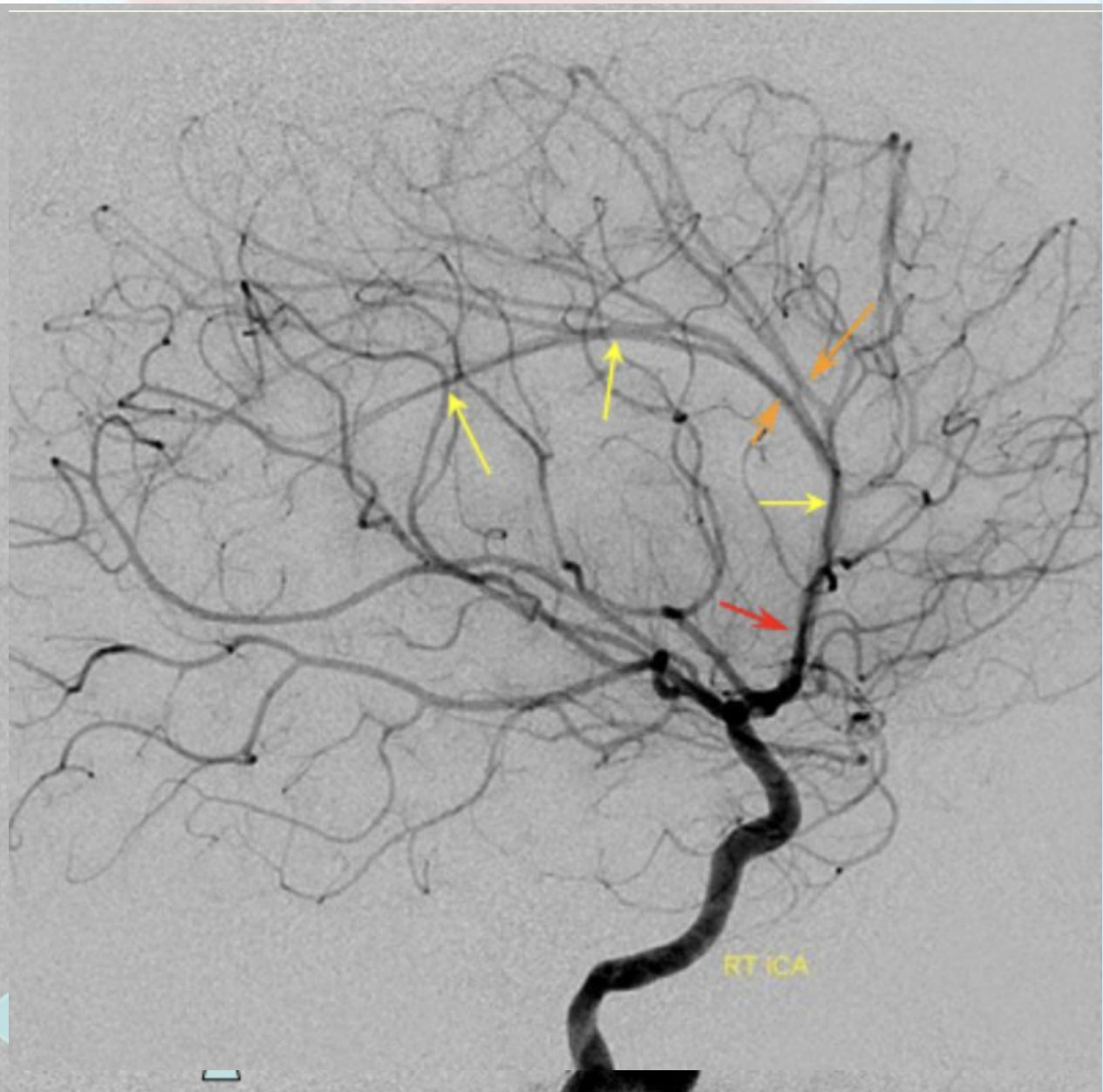

Церебральная ангиография – МСА

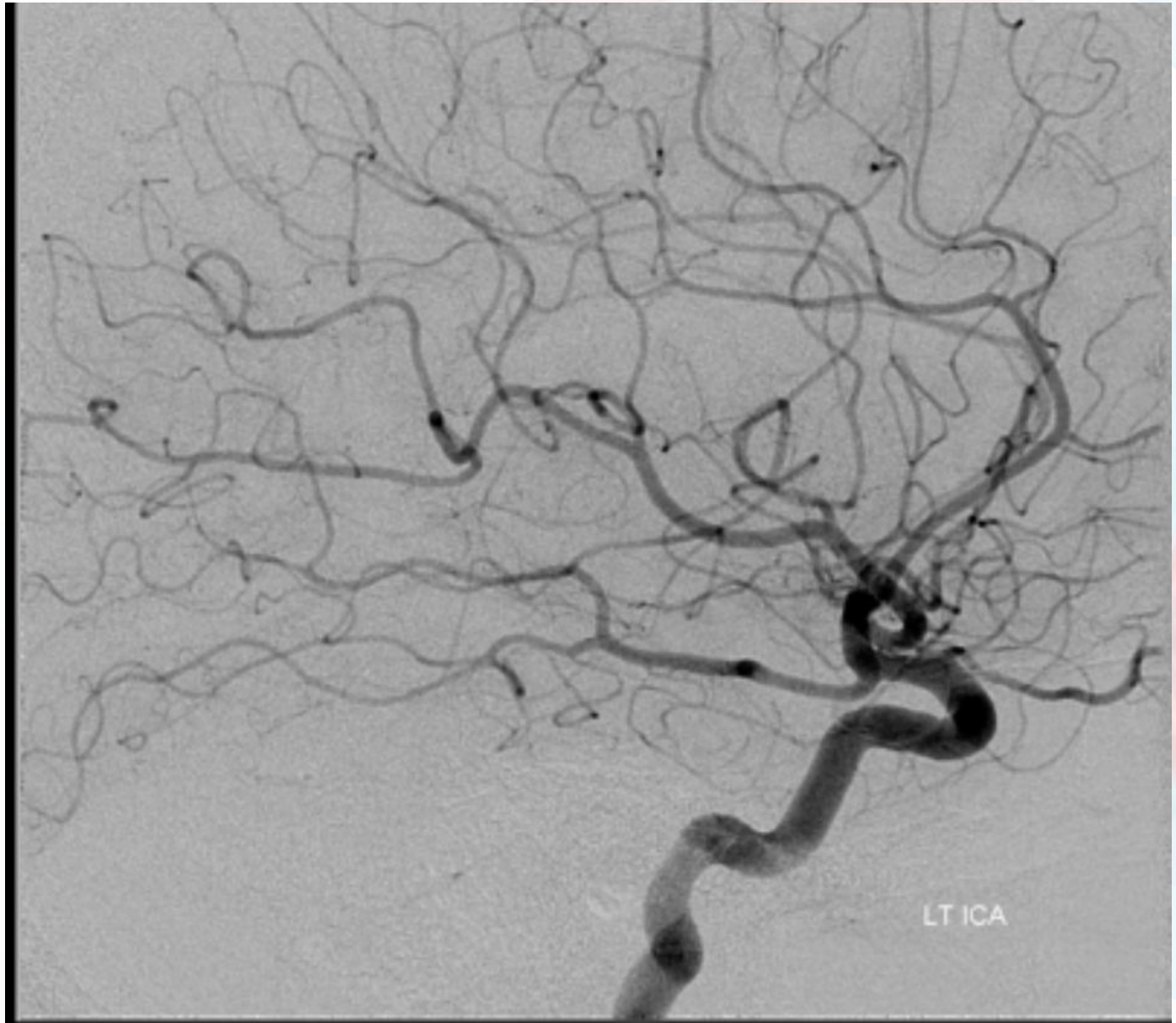

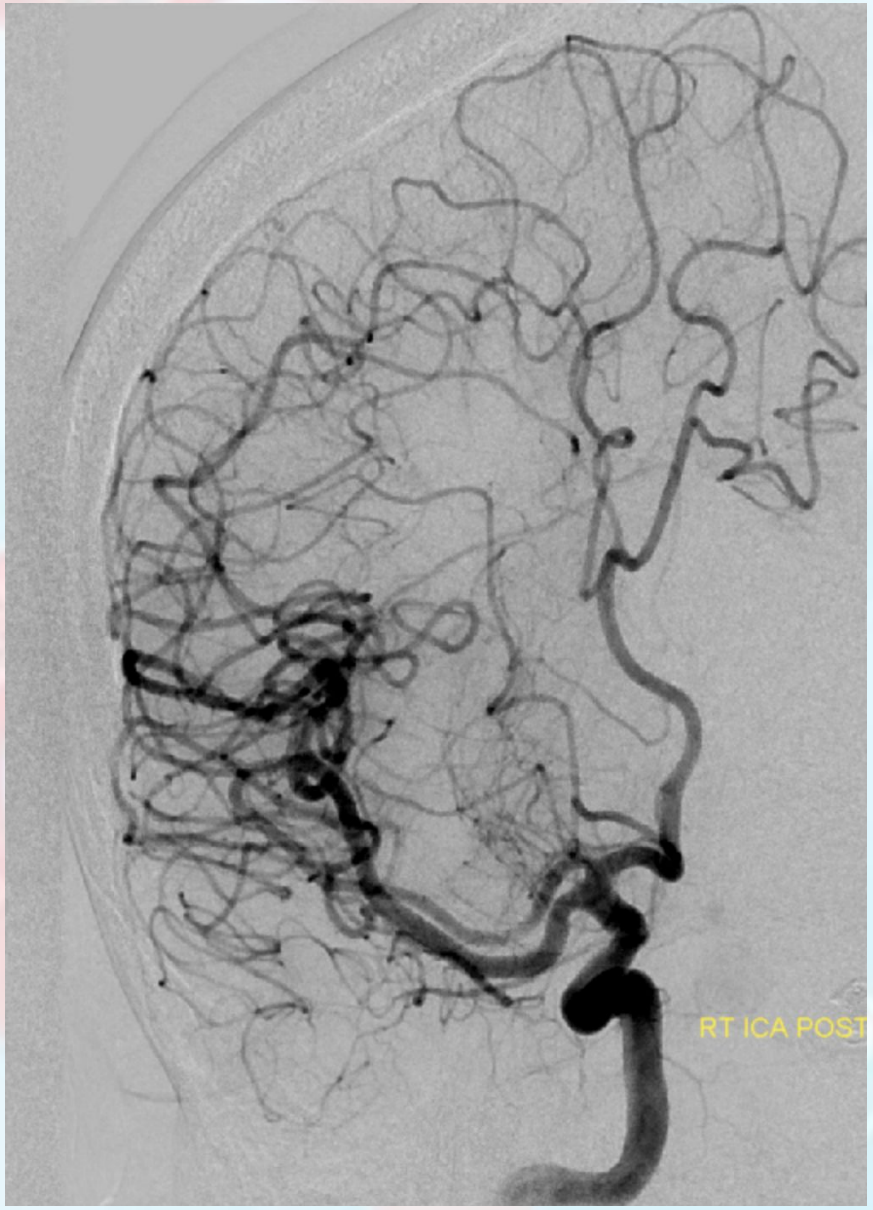

Церебральная ангиография – BA, PCA, SCA

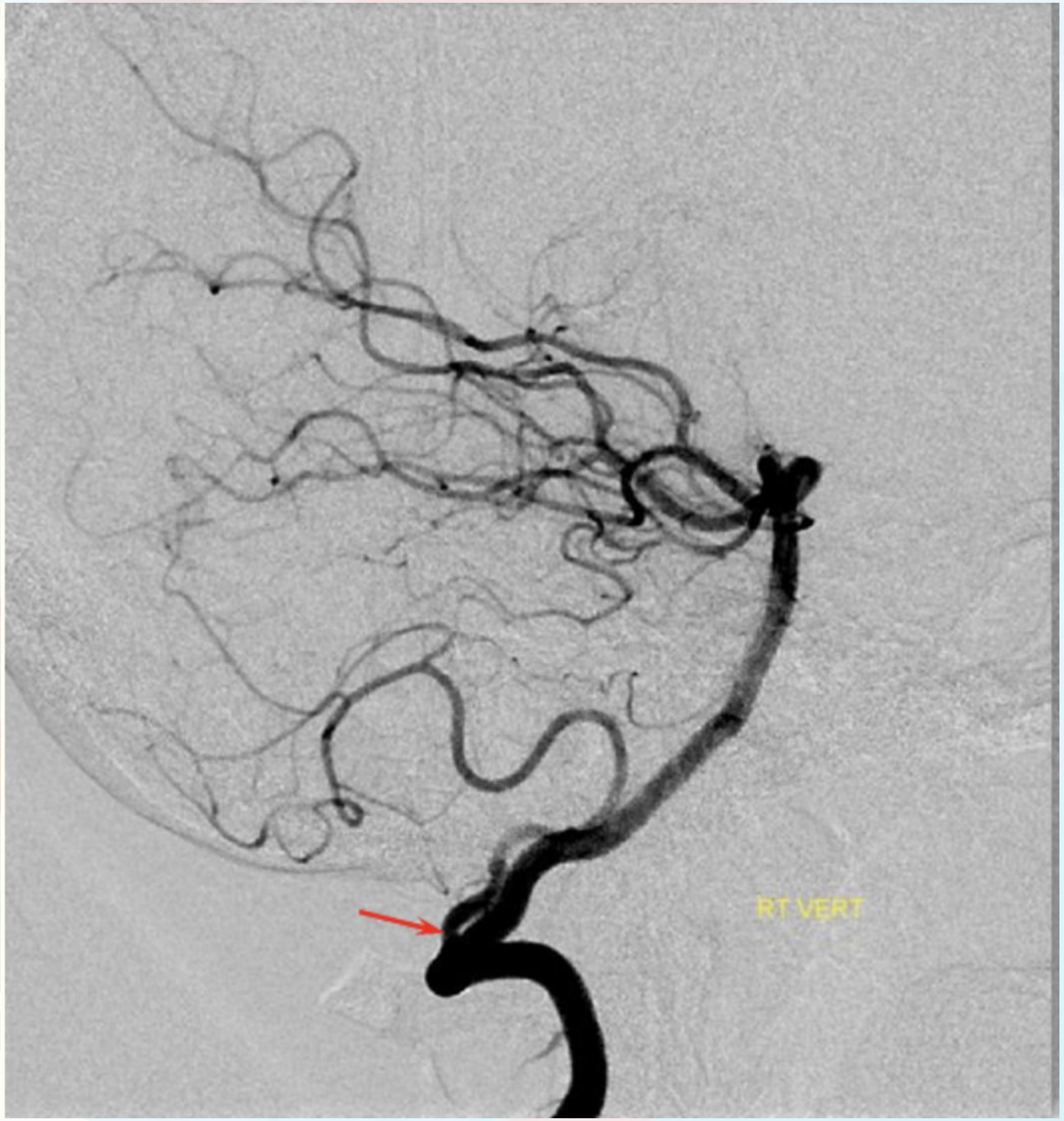

Лечение ОНМК

- Локальный тромболизис
- Тромбоэкстракция

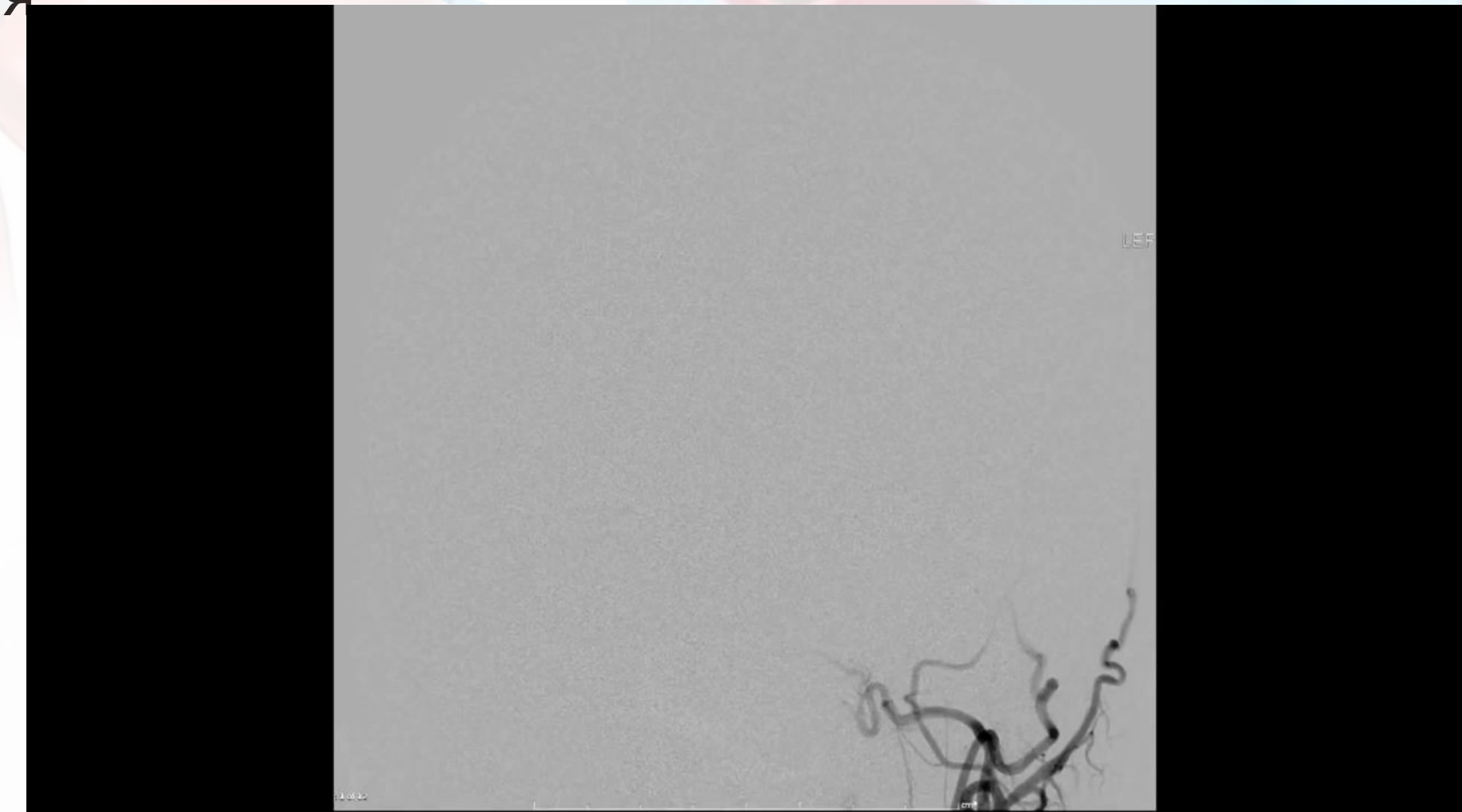

Стентирование сонных артерий

The NEW ENGLAND JOURNAL of MEDICINE
ESTABLISHED IN 1812 JULY 1, 2010 VOL. 363 NO. 1

Stenting versus Endarterectomy for Treatment of Carotid-Artery Stenosis

Б)

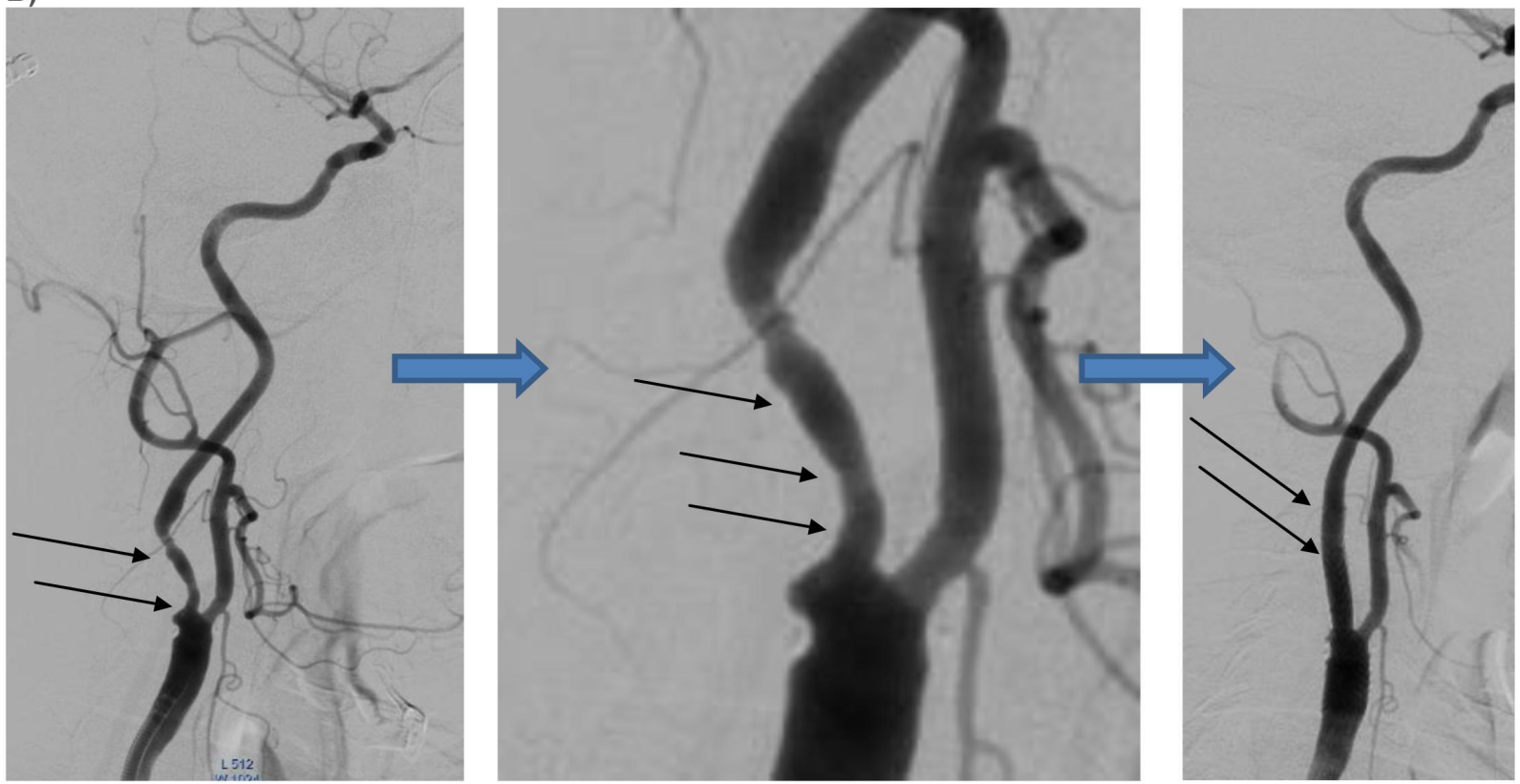

До вмешательства Фрагмент стеноза После стентирования

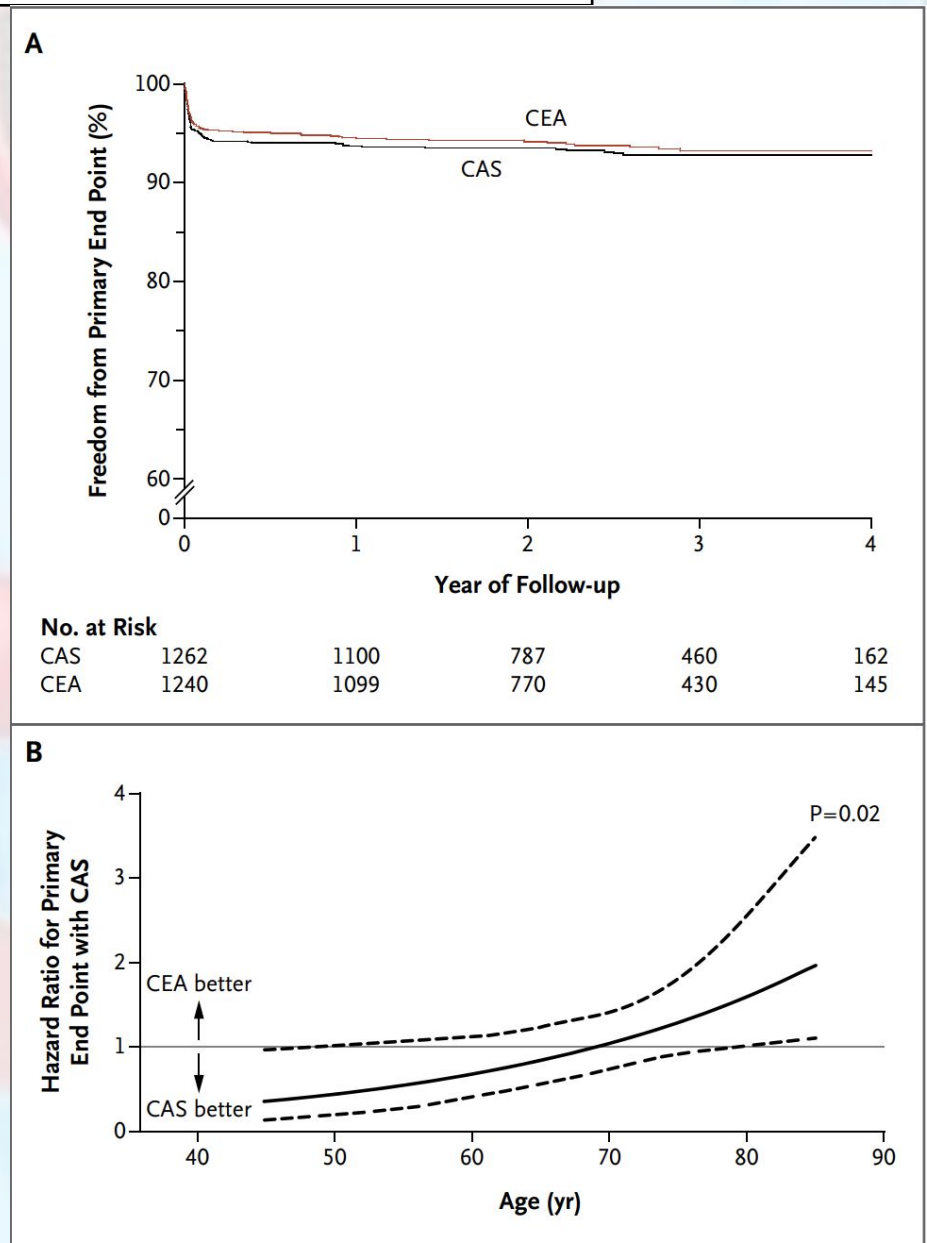

Trends in aneurysm surgery

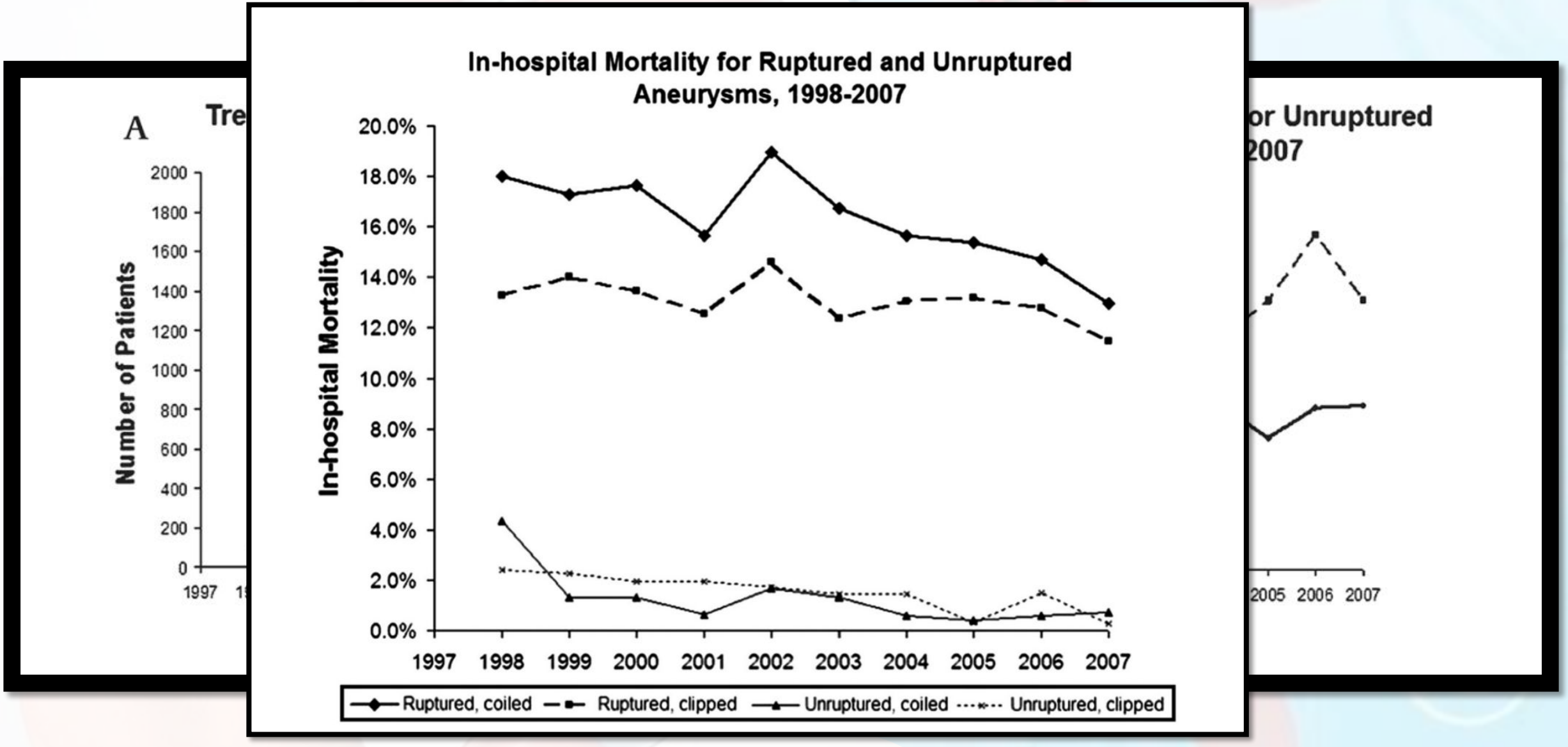

Clip vs Coil

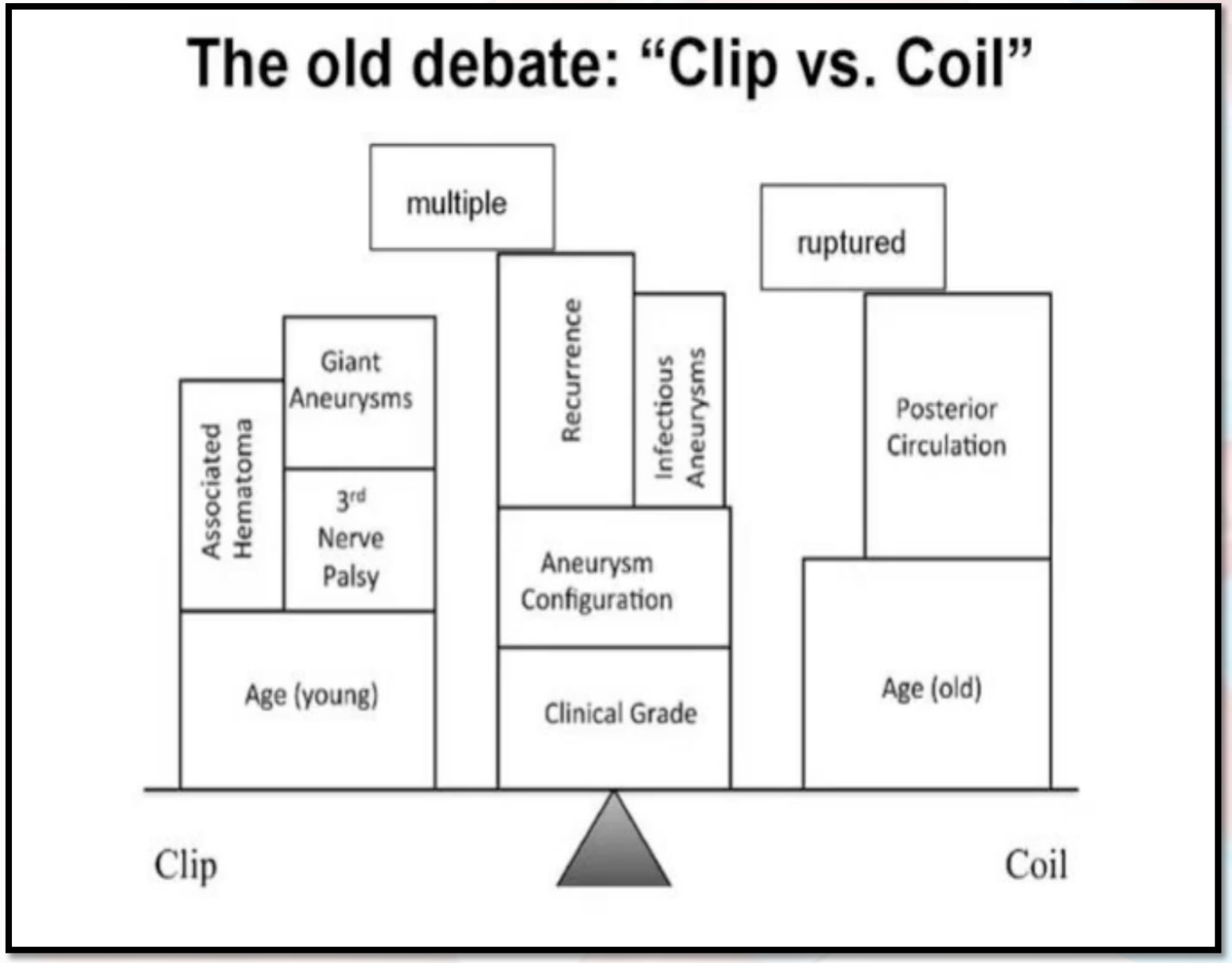
The old debate: "Clip vs. Coil"
multiple
ruptured
Giant Aneurysms
Associated Hematoma
3rd Nerve Palsy
Recurrence
Infectious Aneurysms
Aneurysm Configuration
Clinical Grade
Posterior Circulation
Age (young)
Age (old)
Clip
Coil

n=1787 aSAH (2009-2015)

Coiling

Эмболизация спиралями

Стент/Баллон-асистрированная эмболизация

Установка поток-перенаправляющих стентов (pepline)

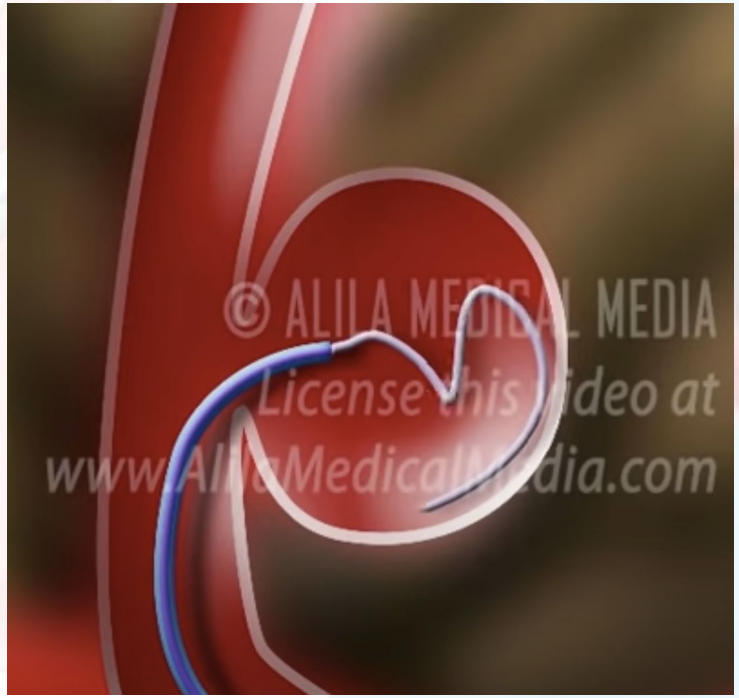

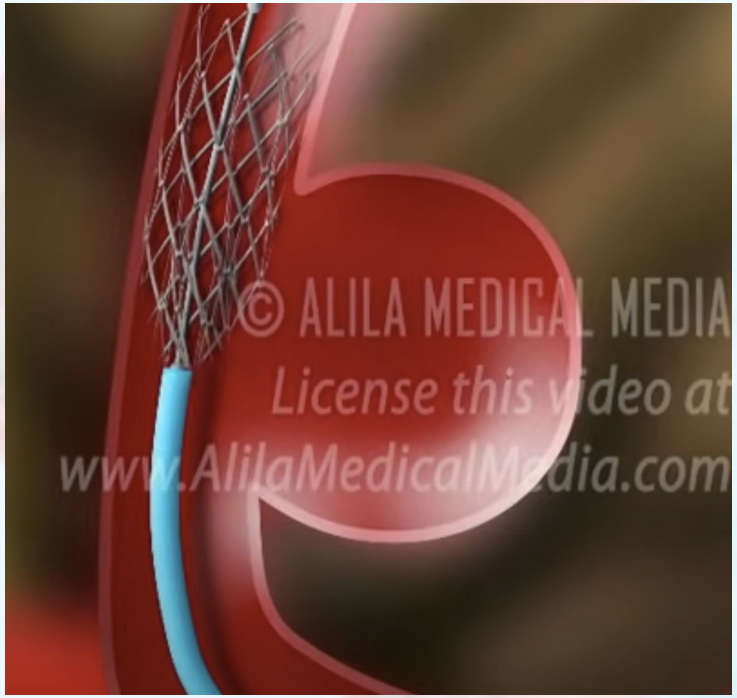

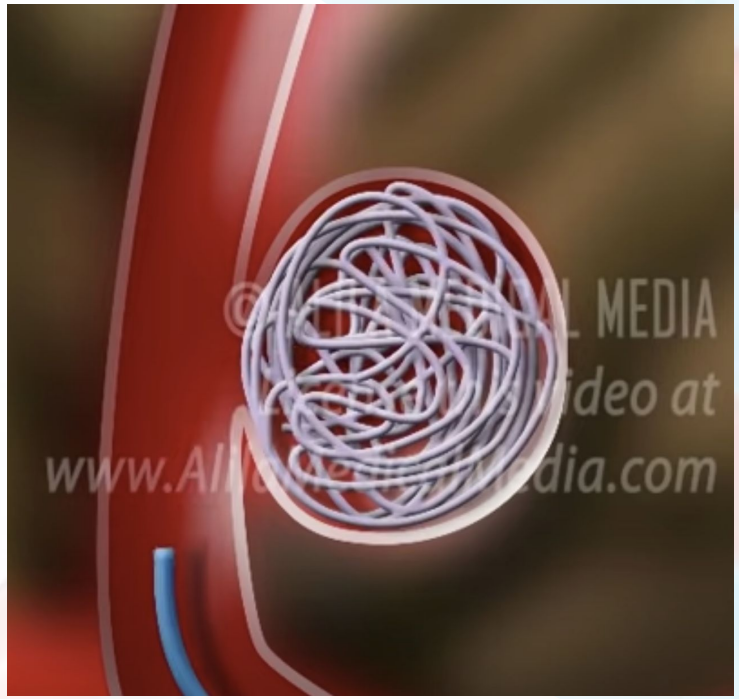



Терапия вазоспазма

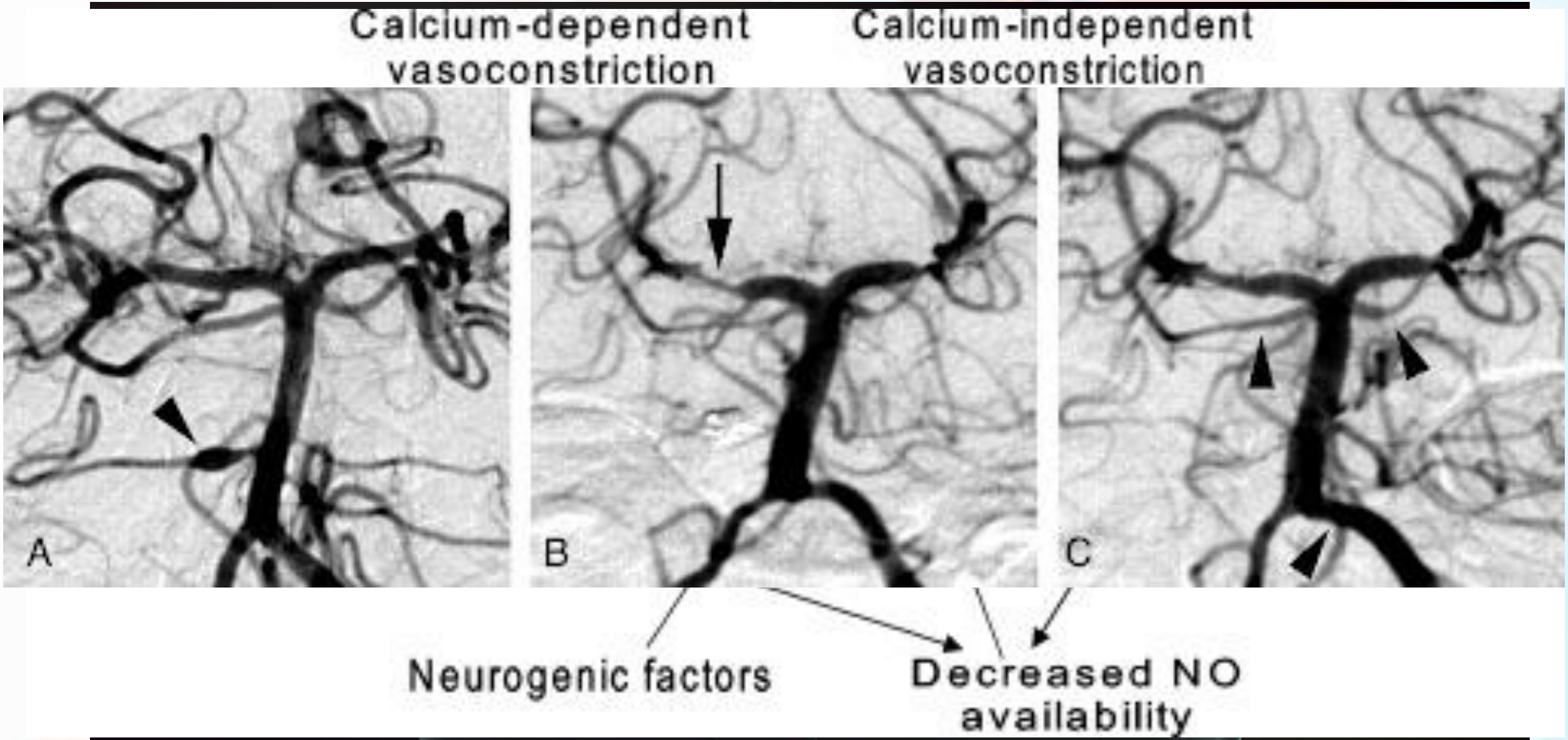

АВ-мальформации

Surgery vs Embolization vs Radiotherapy

TABLE 19-1 Spetzler–Martin Scale for Prediction of Surgical Risk for AVM

GRADED FEATURE	POINTS
Maximum Diameter of AVM	
Measured from the angiogram and correcting for magnification.	
Small <3 cm	1
Medium 3–6 cm	2
Large >6 cm	3
Eloquence of Adjacent Brain	
Eloquent brain includes primary sensorimotor, language, and visual cortex, hypothalamus, thalamus, internal capsule, brainstem, cerebellar peduncles, and the deep cerebellar nuclei.	
Eloquent	1
Noneloquent	0
Pattern of Venous Drainage	
Deep veins are considered those that drain to the internal cerebral vein, the basal vein of Rosenthal, or the precentral cerebellar vein.	
Superficial	0
Deep	1

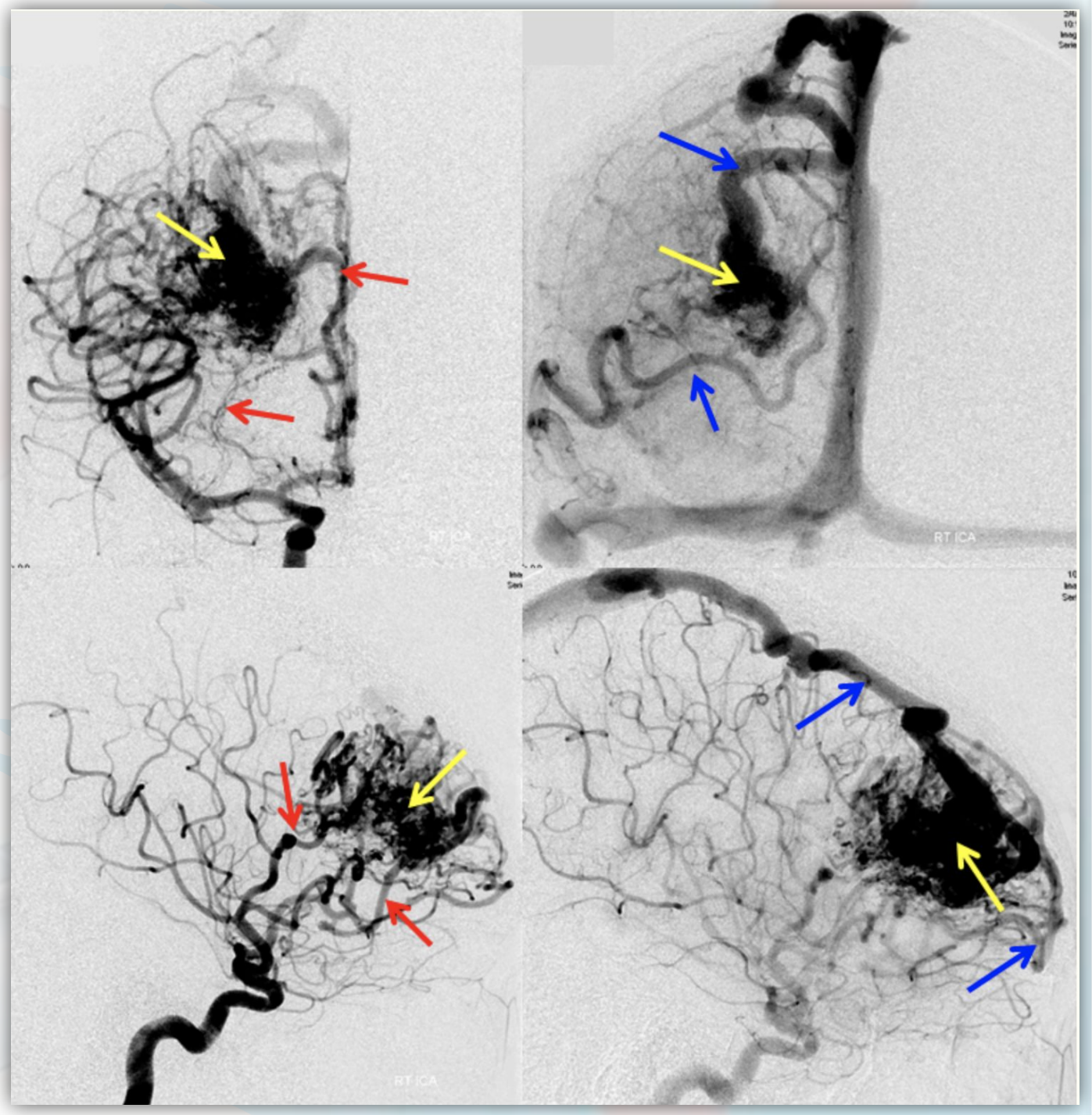

Эмболизация опухолей

Box 4
Hypervascular tumors amenable to preoperative embolization

Intracranial
- Meningioma
- Hemangiopericytoma
- Hemangioblastoma
- Glomus jugulare tumor
- Metastases (renal cell)

Head and neck
- Juvenile nasal angiofibroma
- Carotid body tumor
- Glomus vagale tumor

Spinal
- Hemangioblastoma
- Hemangioma
- Aneurysmal bone cyst
- Giant cell tumor
- Osteoblastoma
- Metastases (renal cell, thyroid)

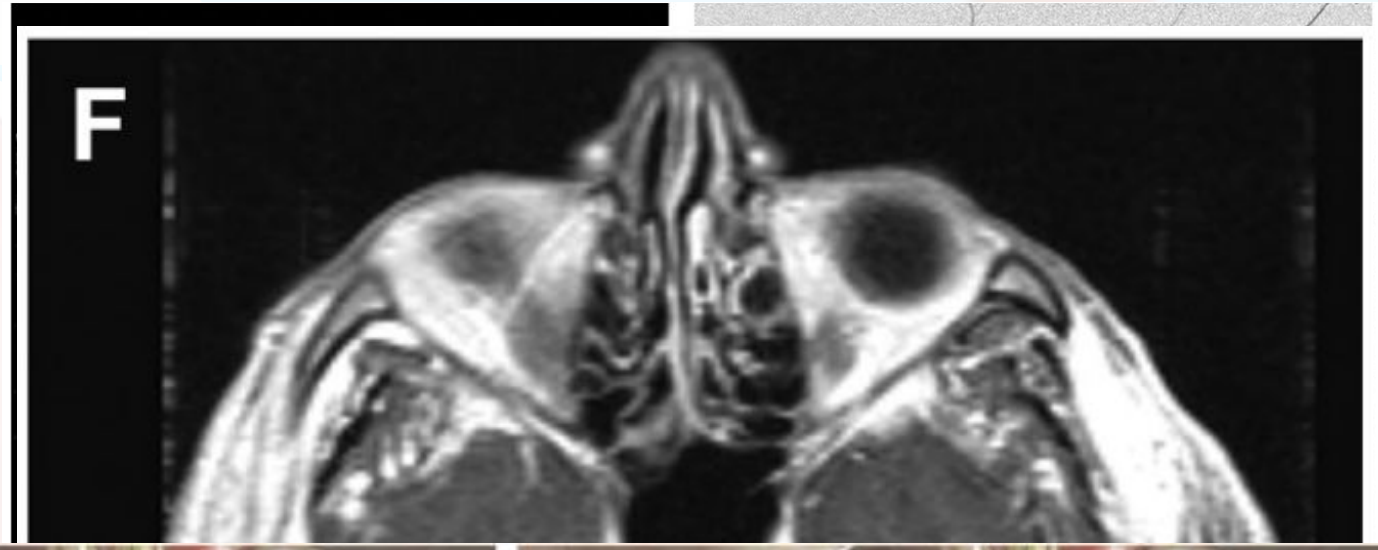

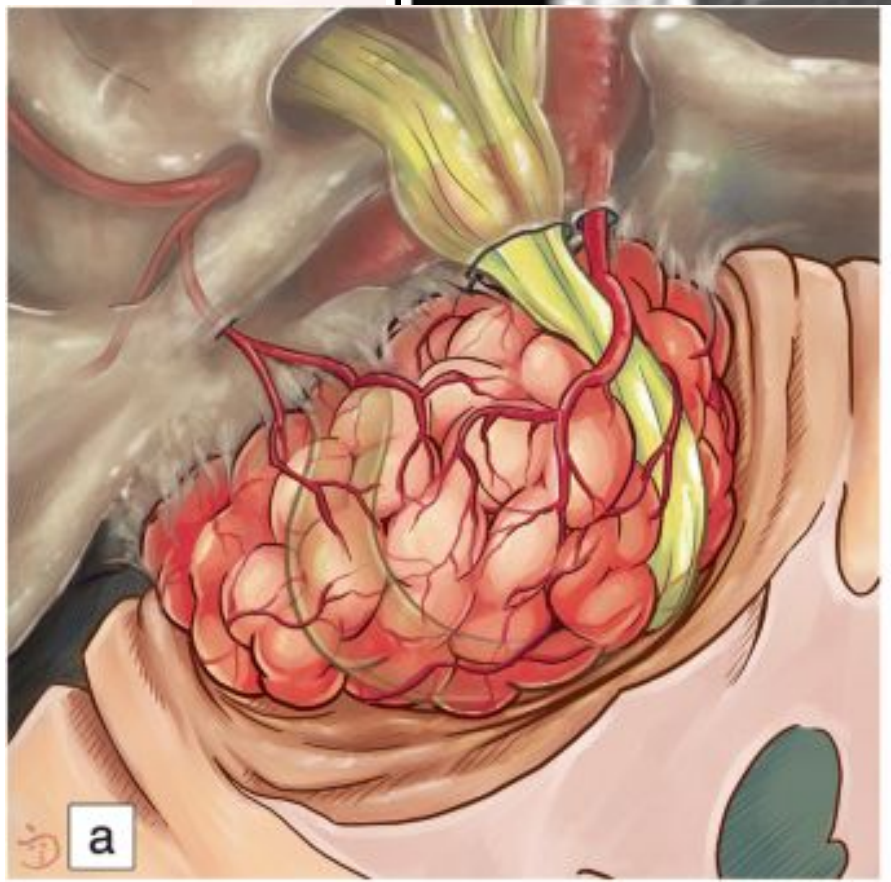

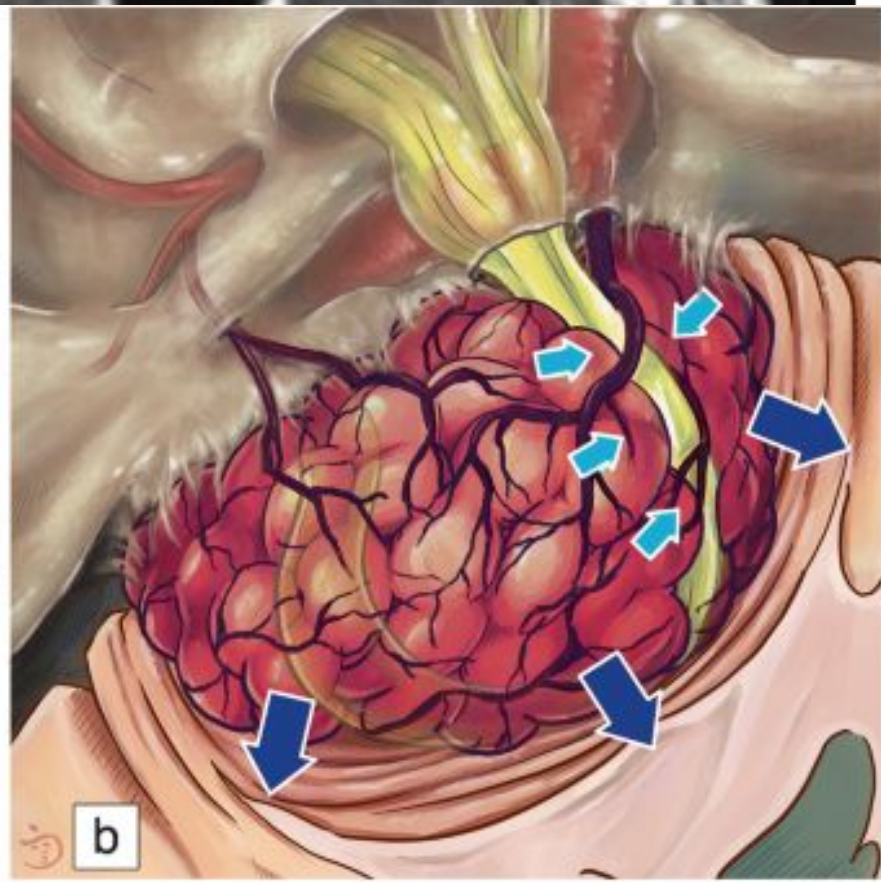

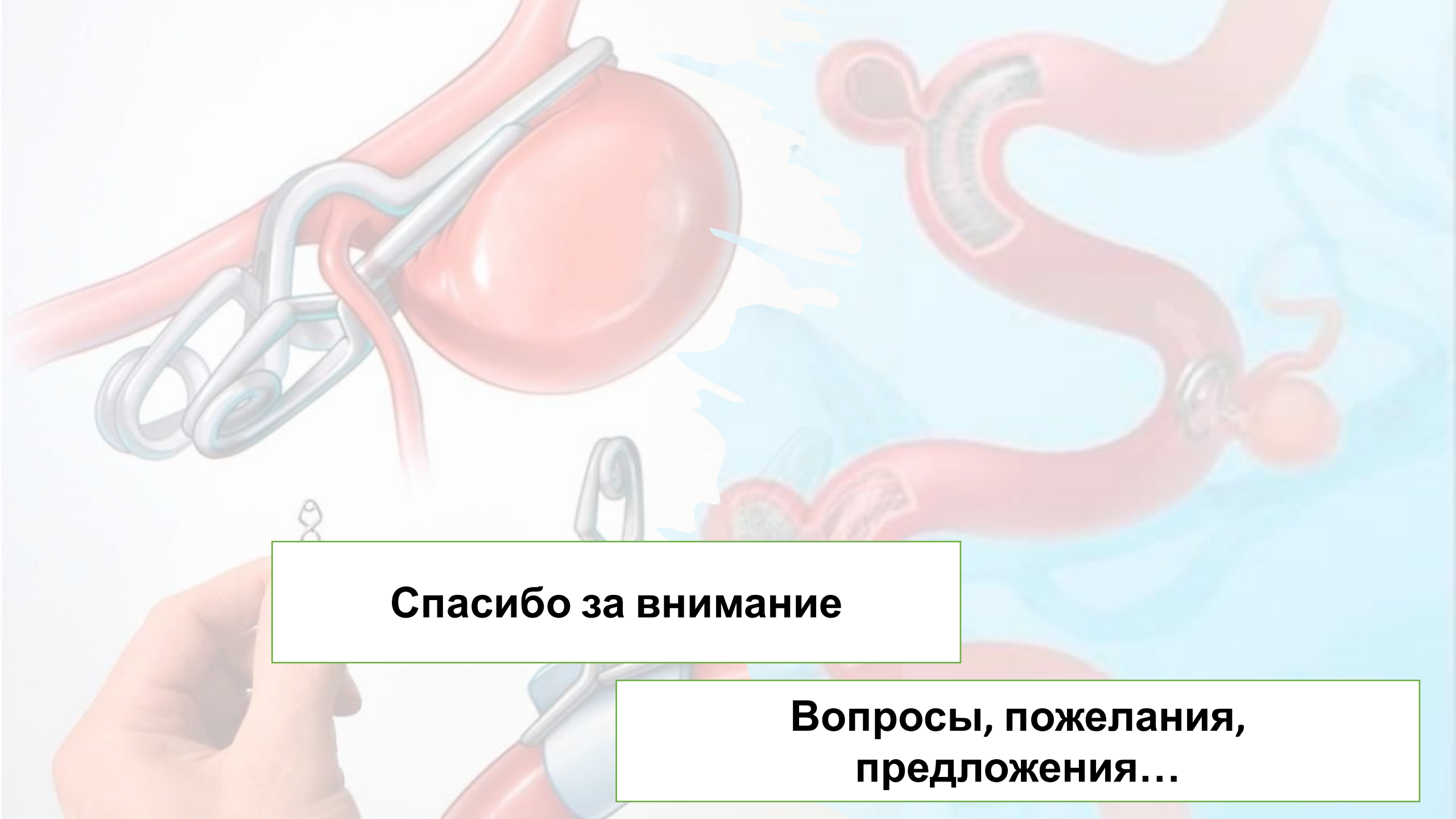

Спасибо за внимание

Вопросы, пожелания, предложения…