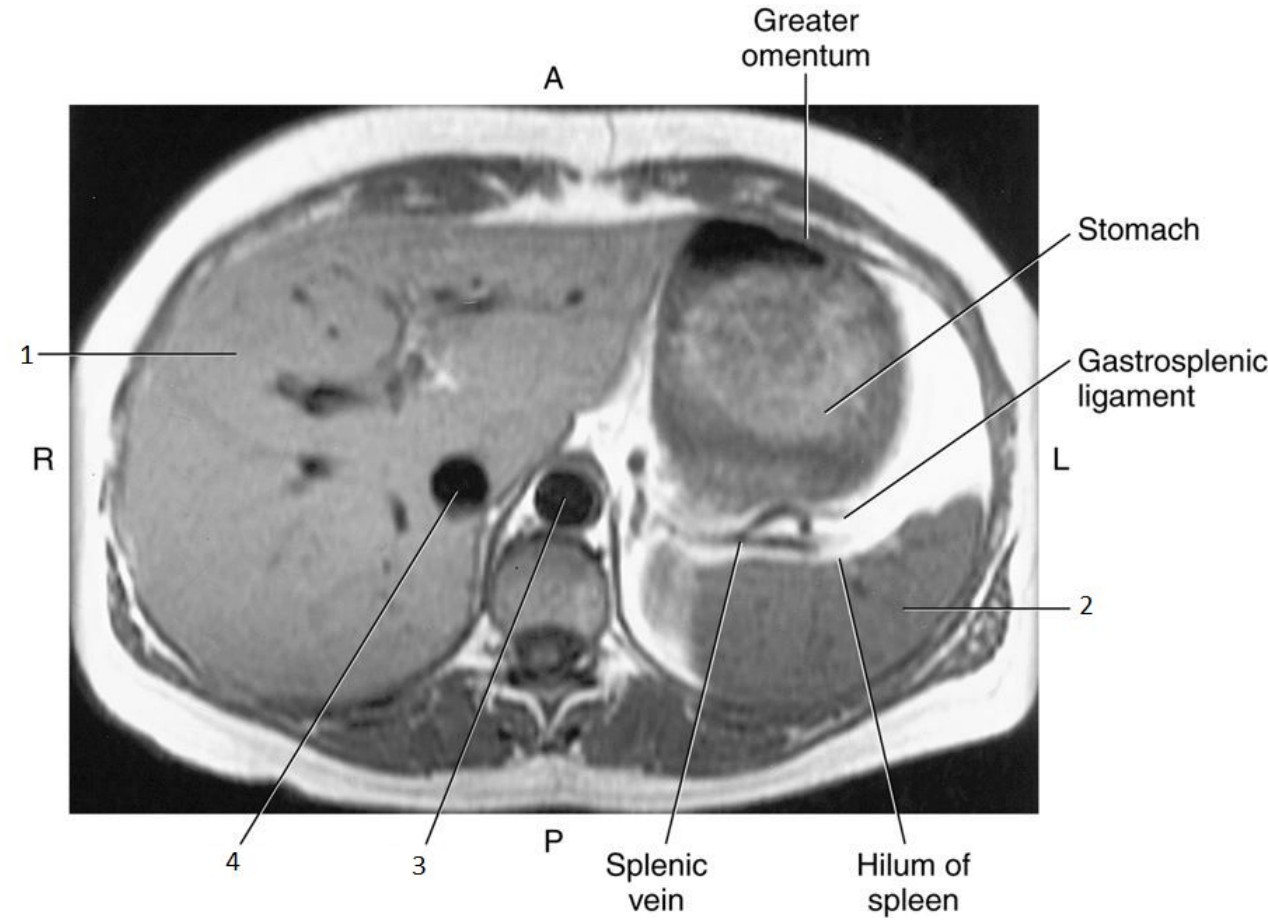


Sectional Anatomy II

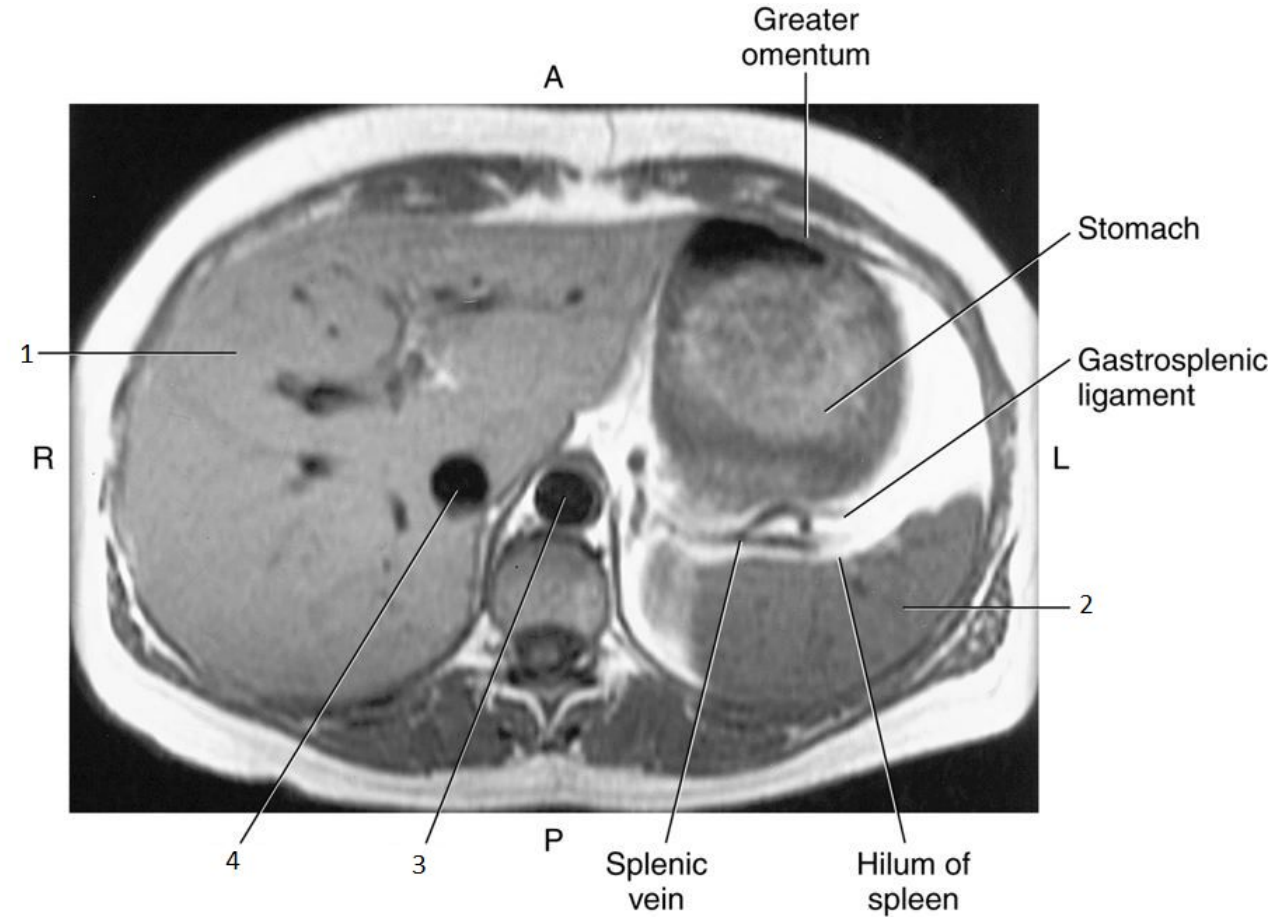
Chapter 7: Abdomen (Image Review)

1

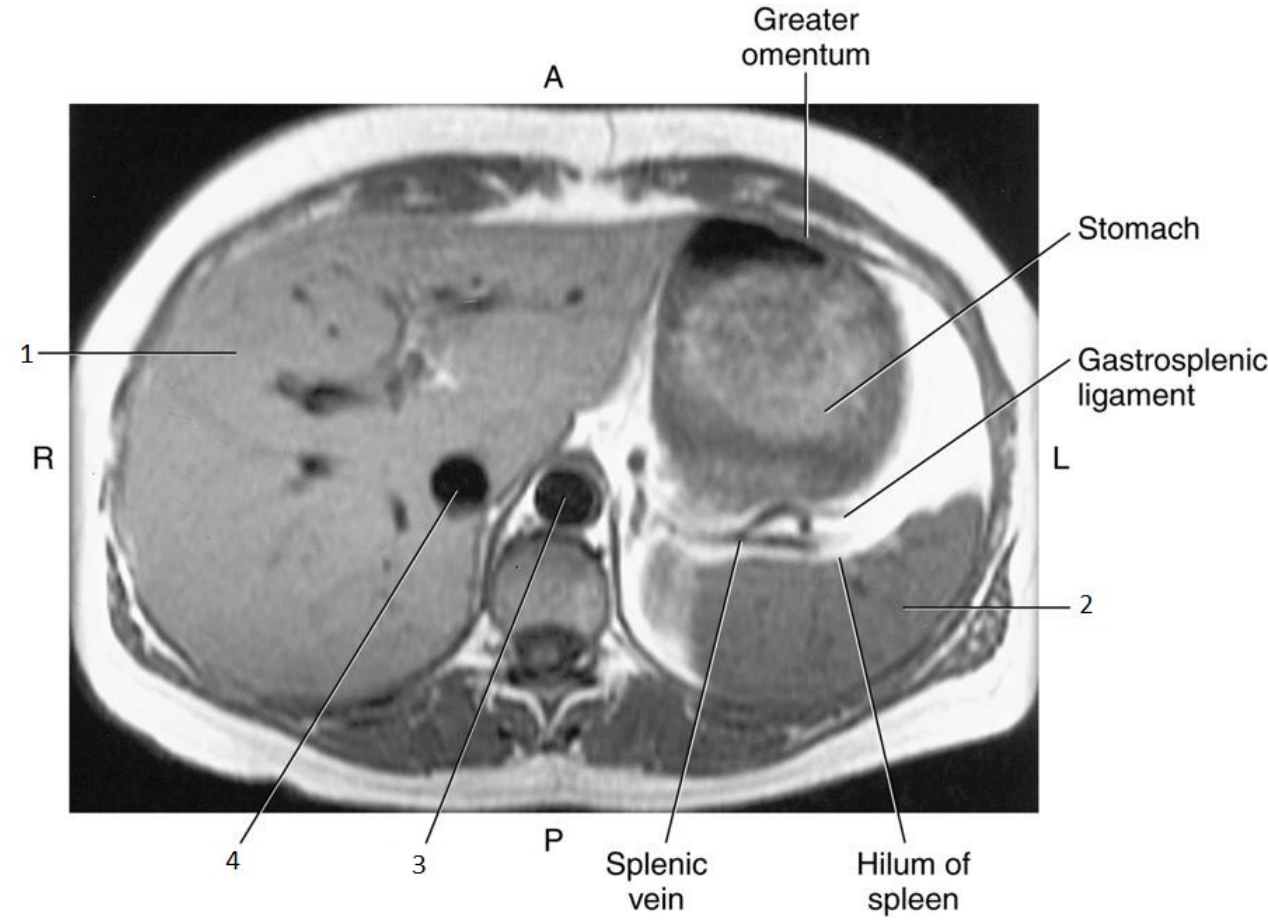


1

- Liver

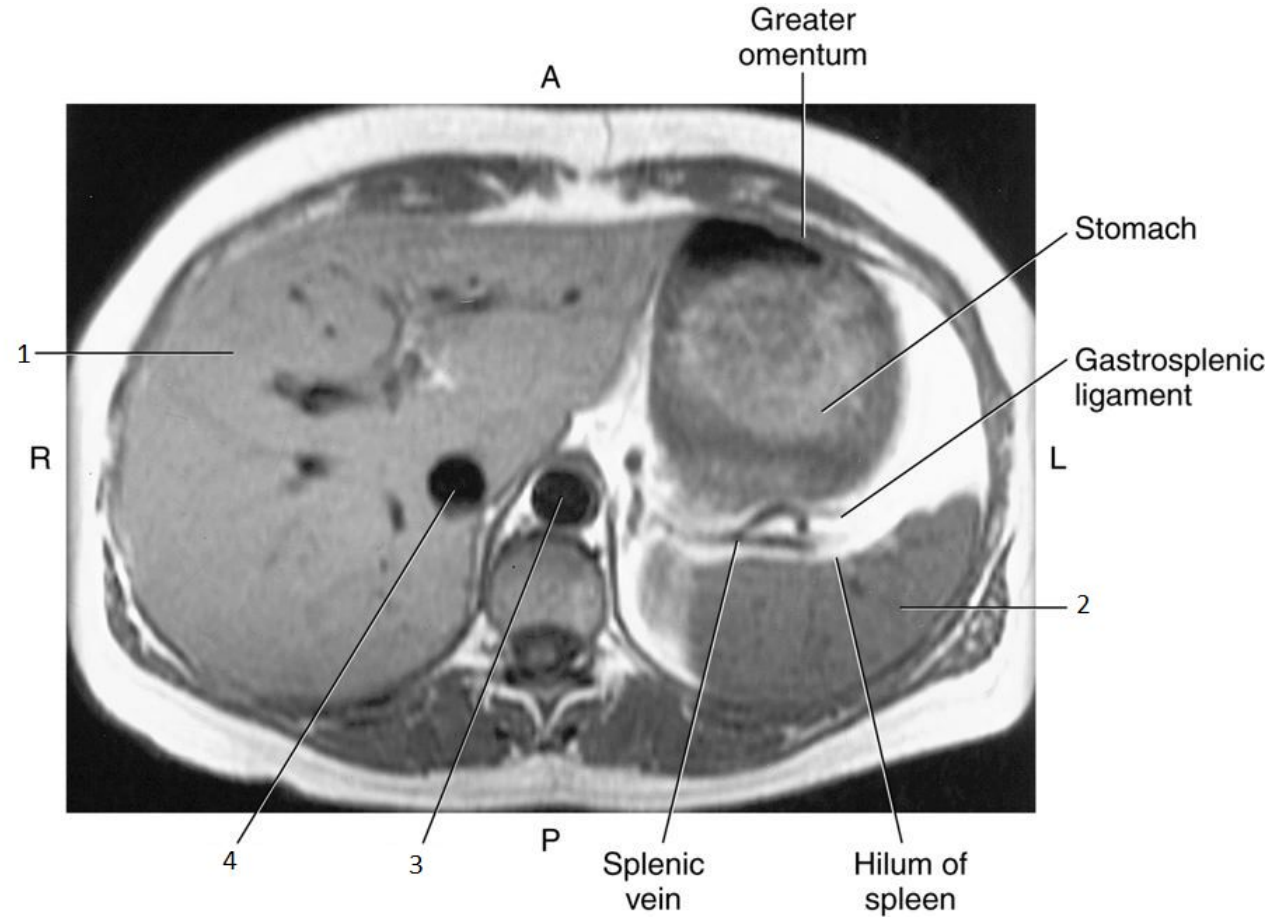


2

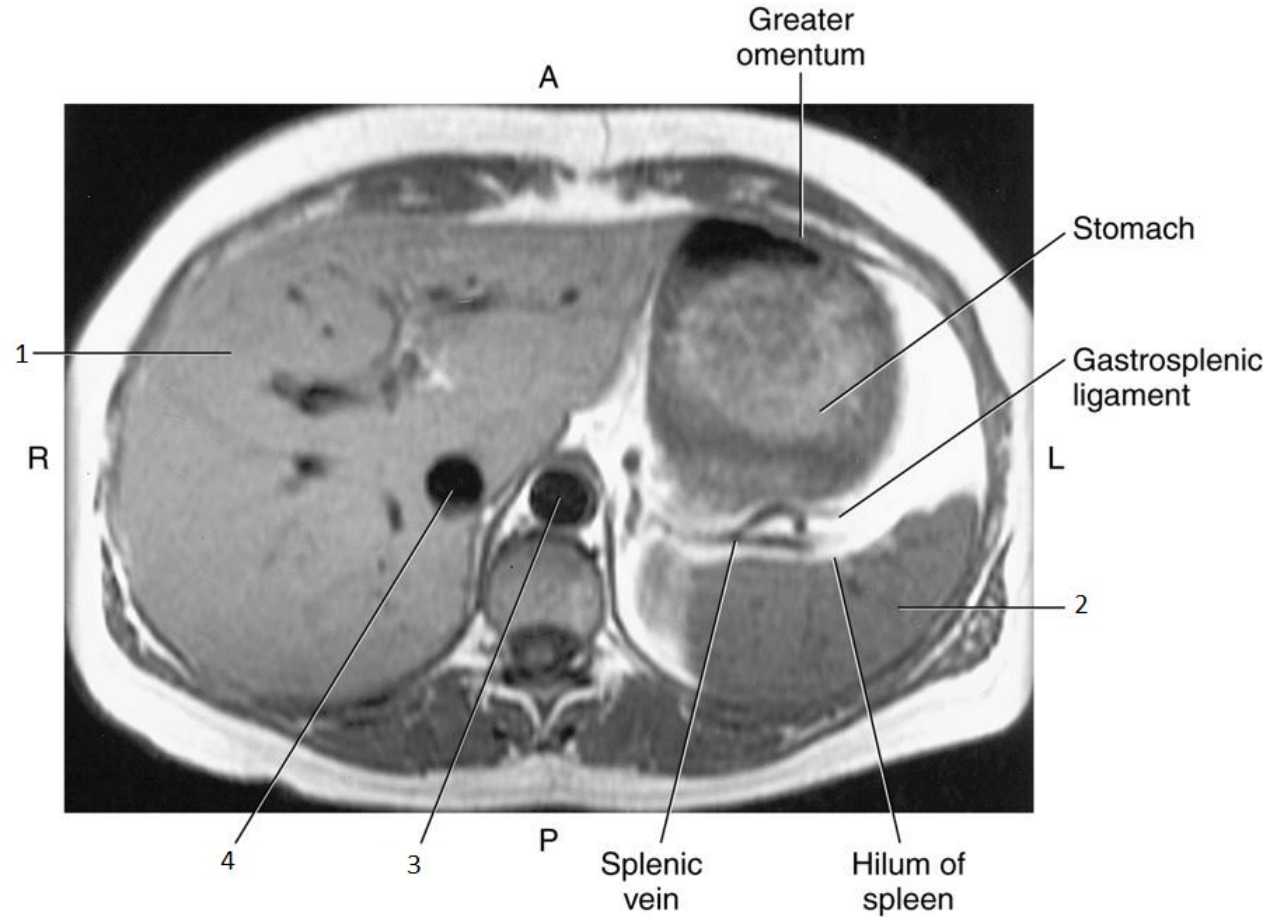


2

- Spleen

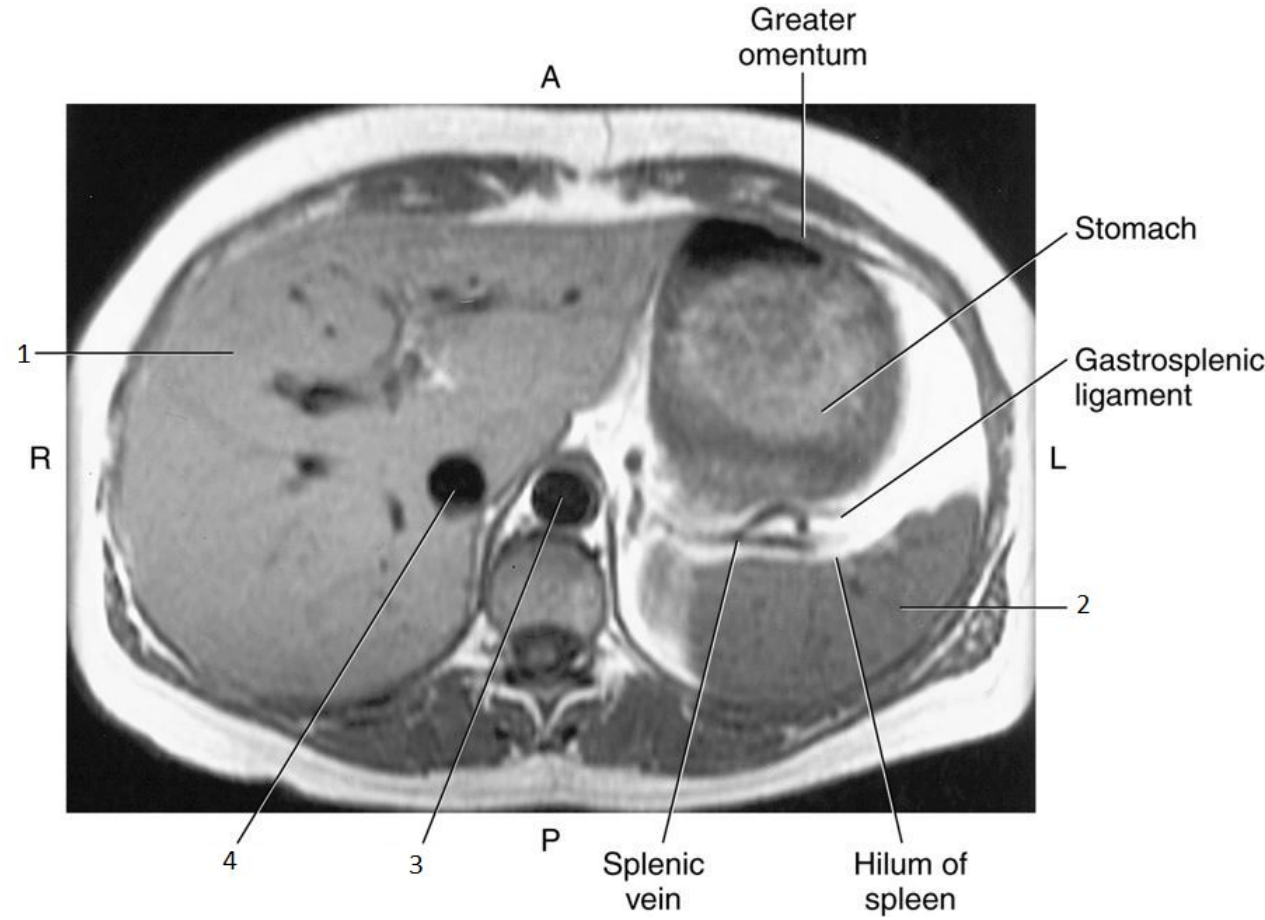


3

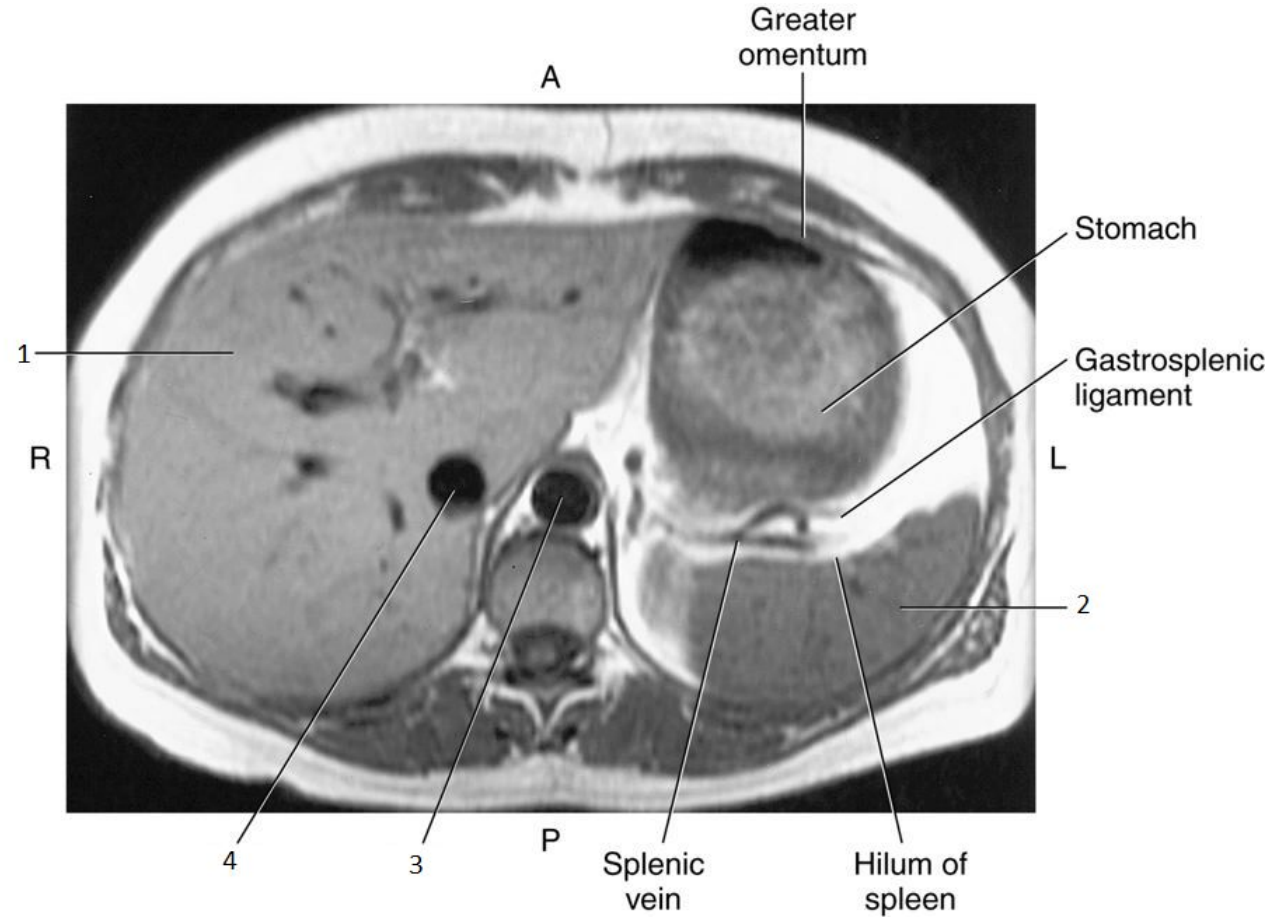


3

- Aorta

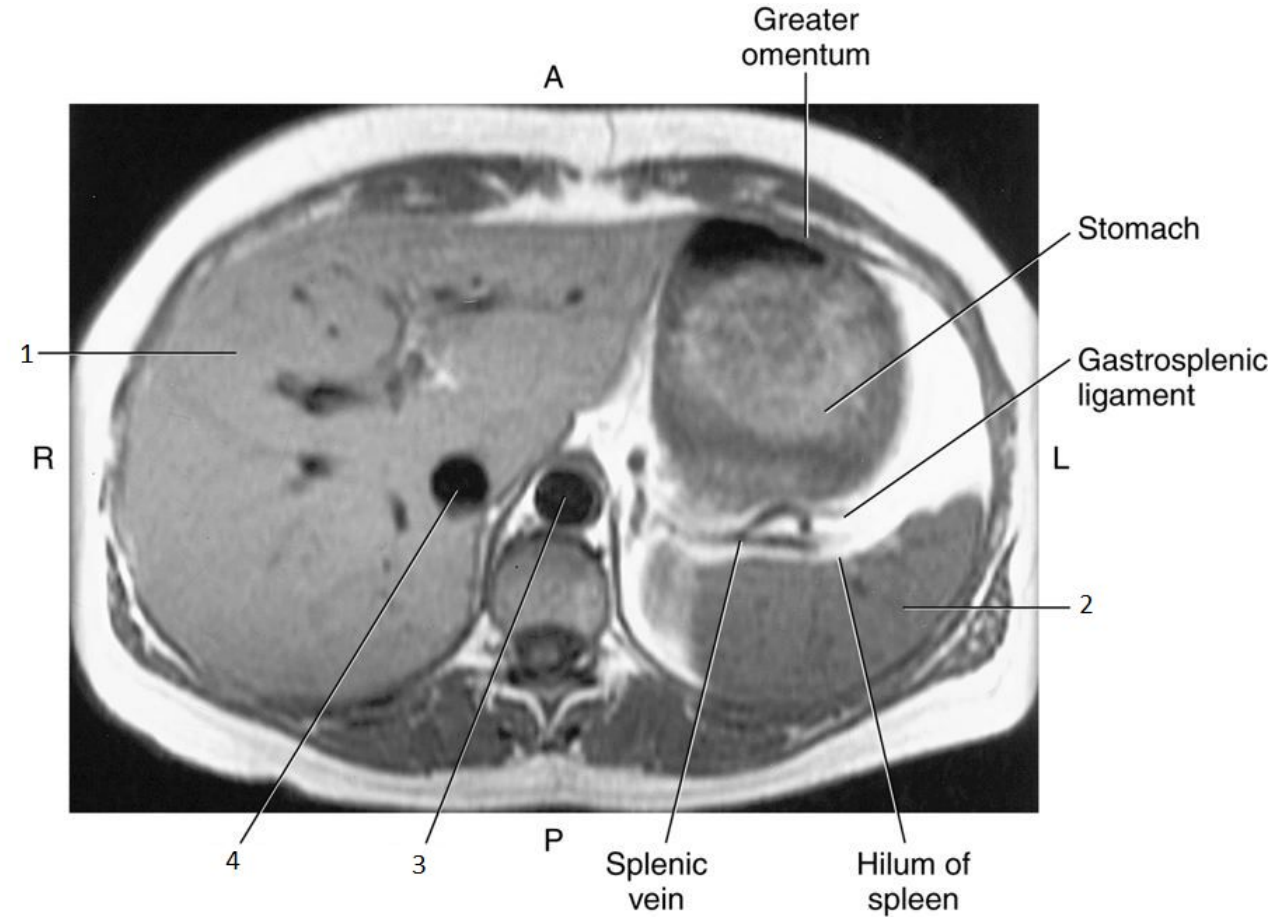


4

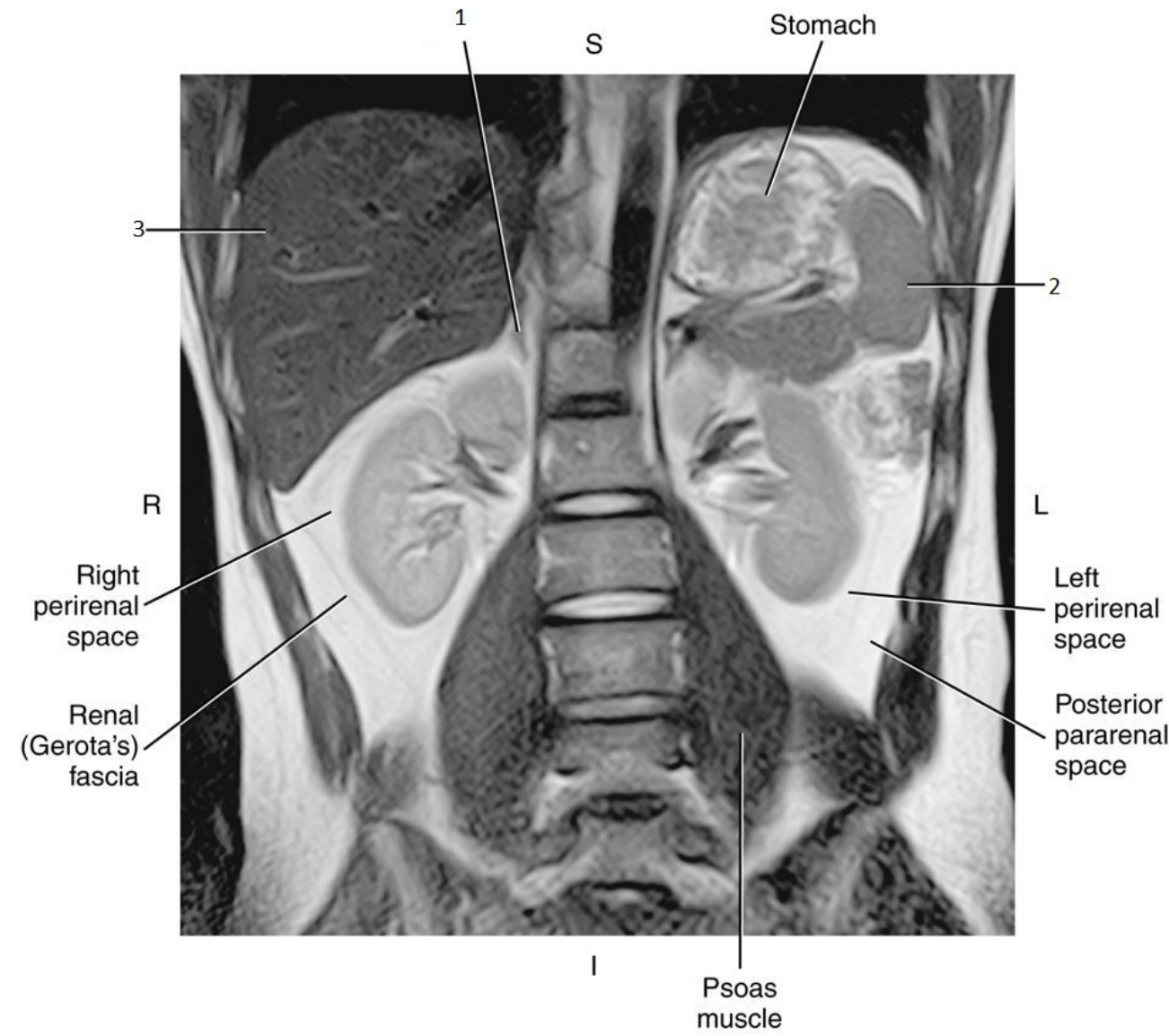


4

- Inferior Vena Cava (IVC)

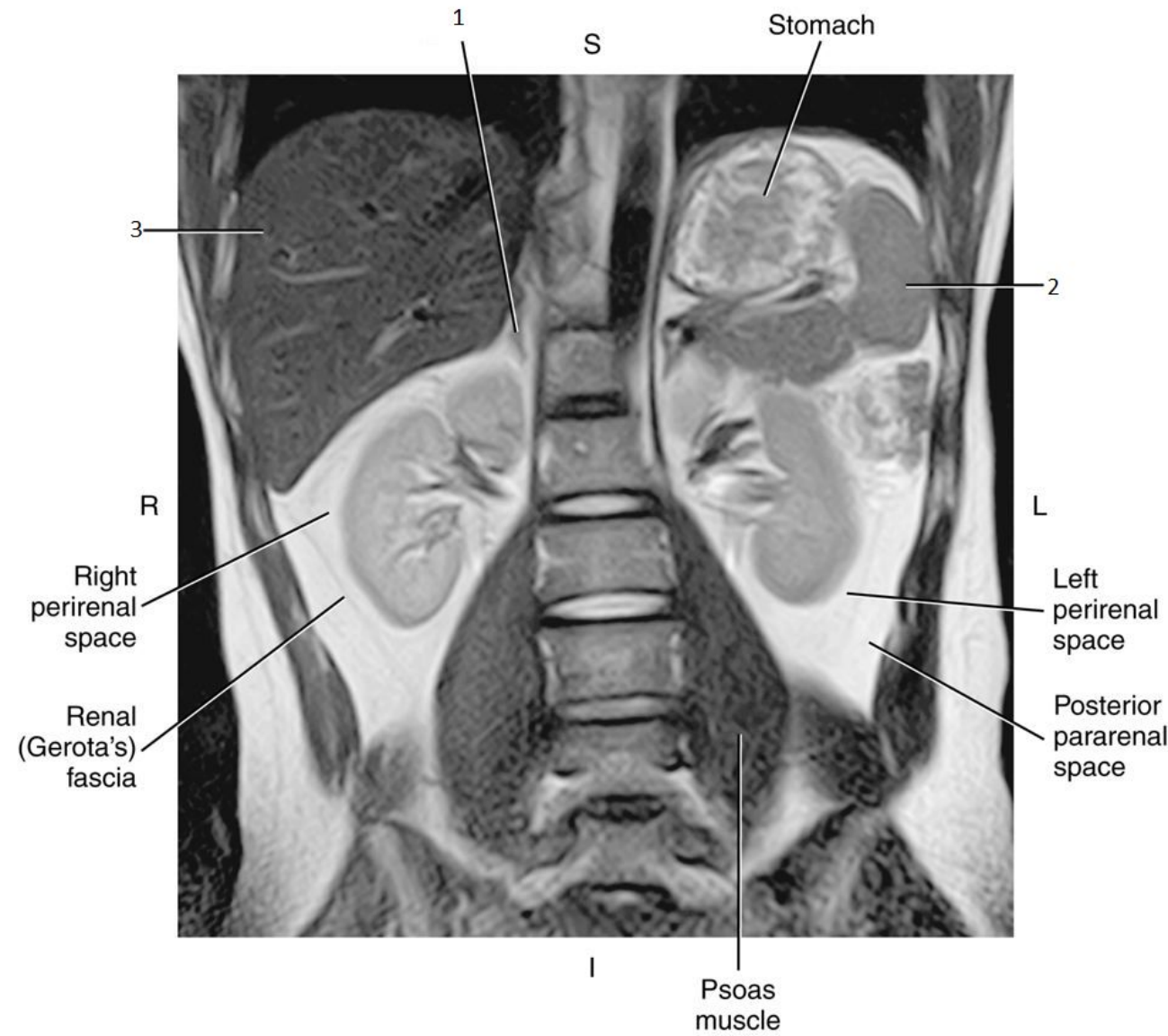


1

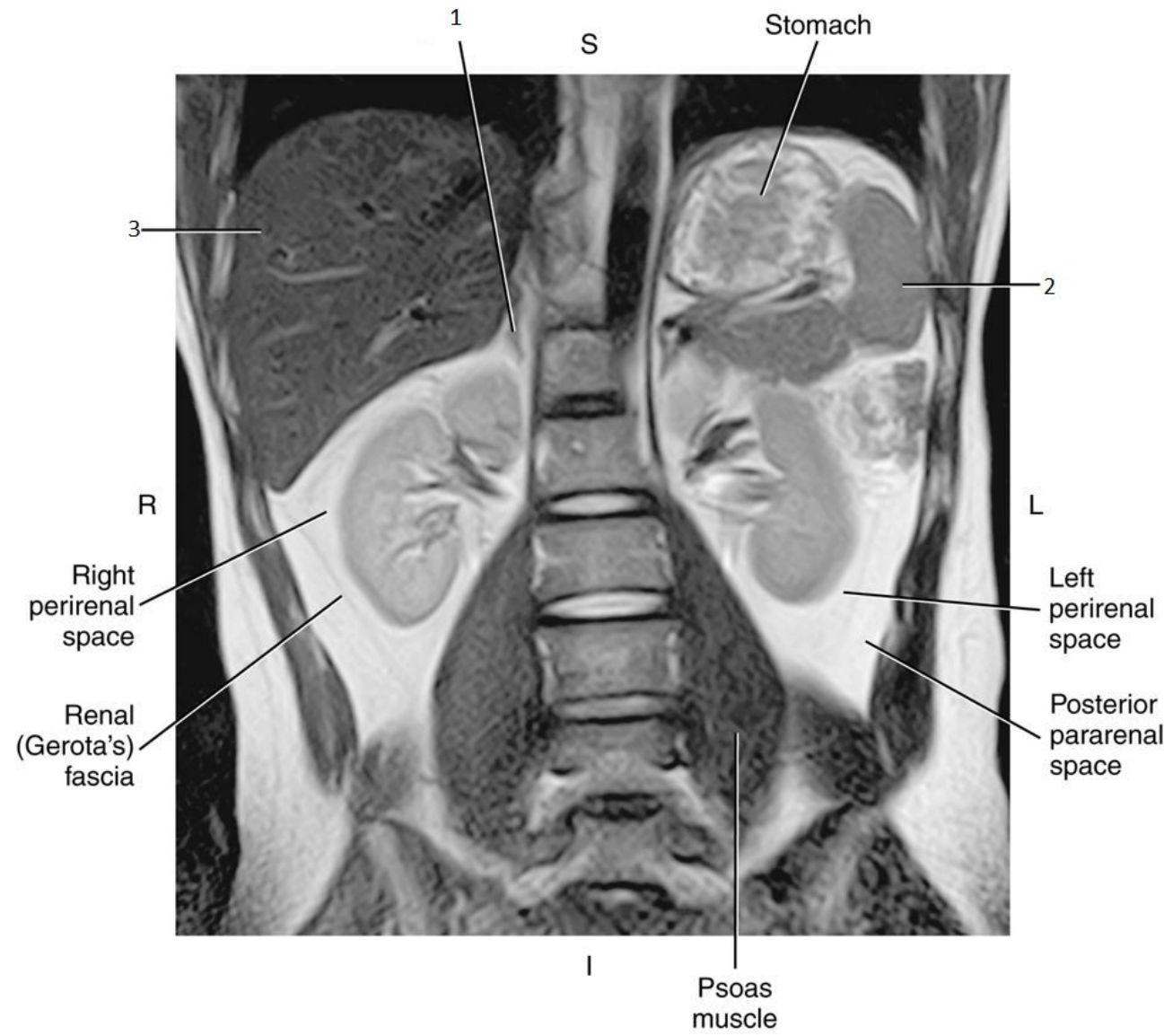


1

- Right Adrenal Gland

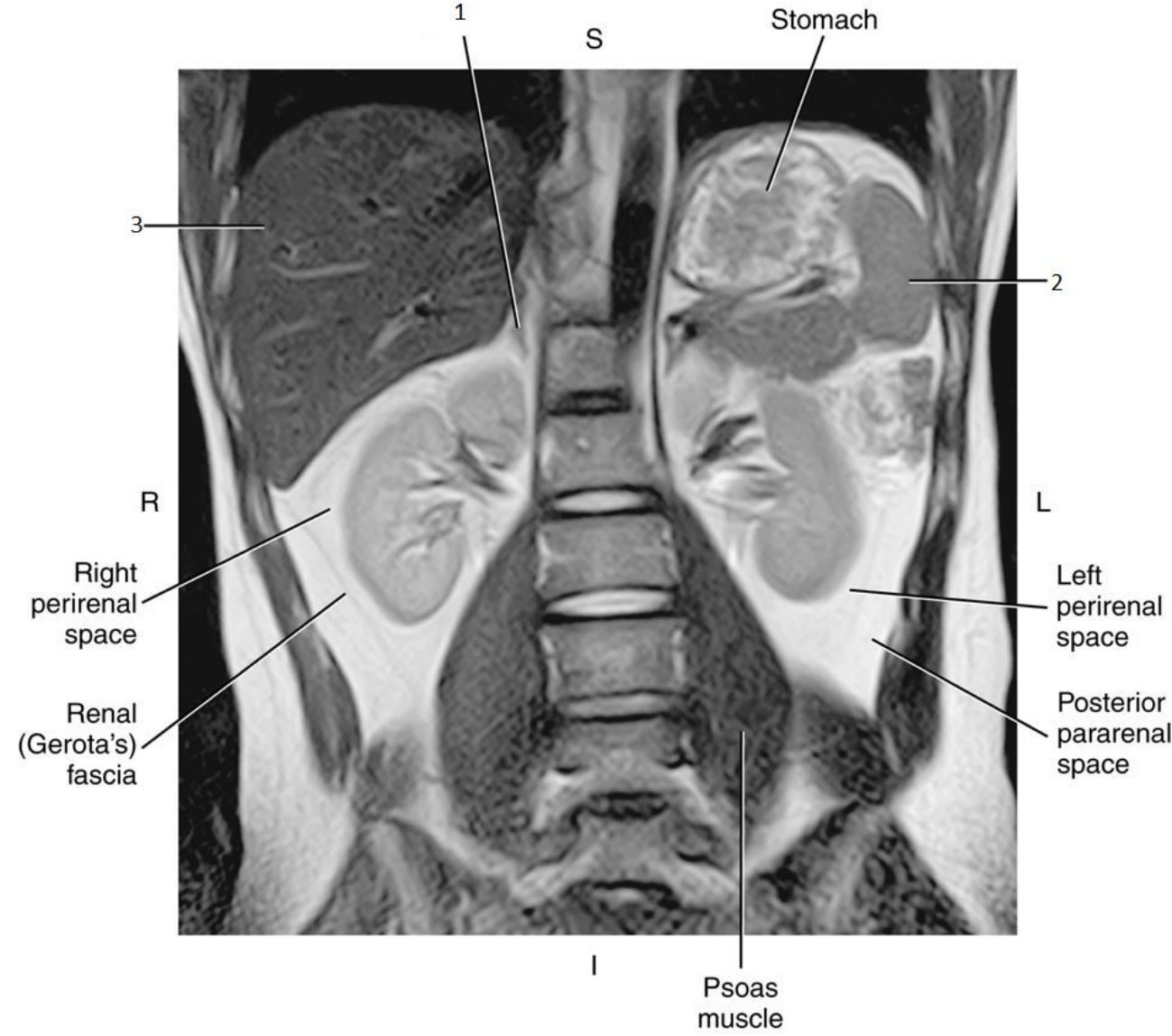


2

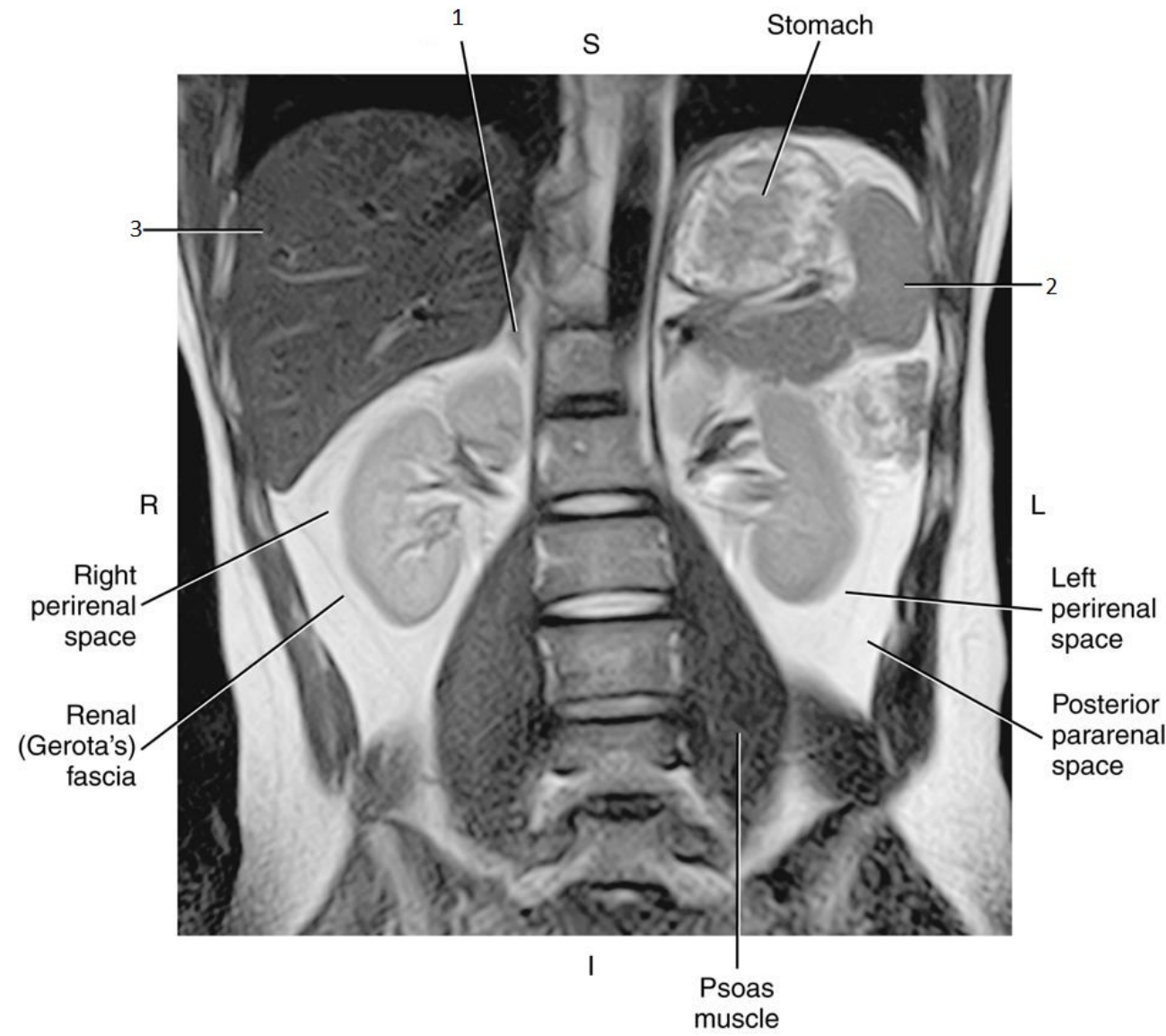


2

- Spleen

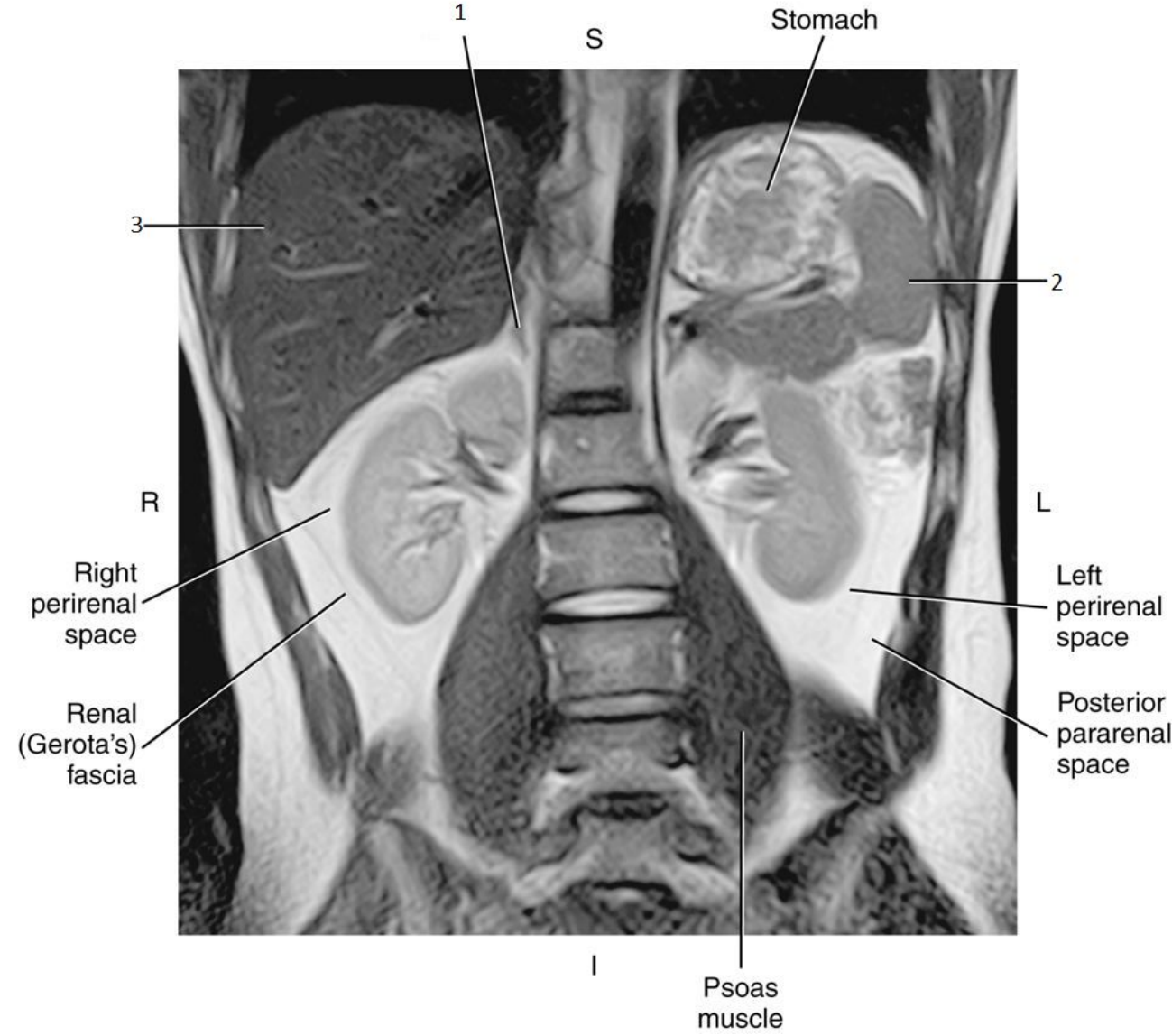


3

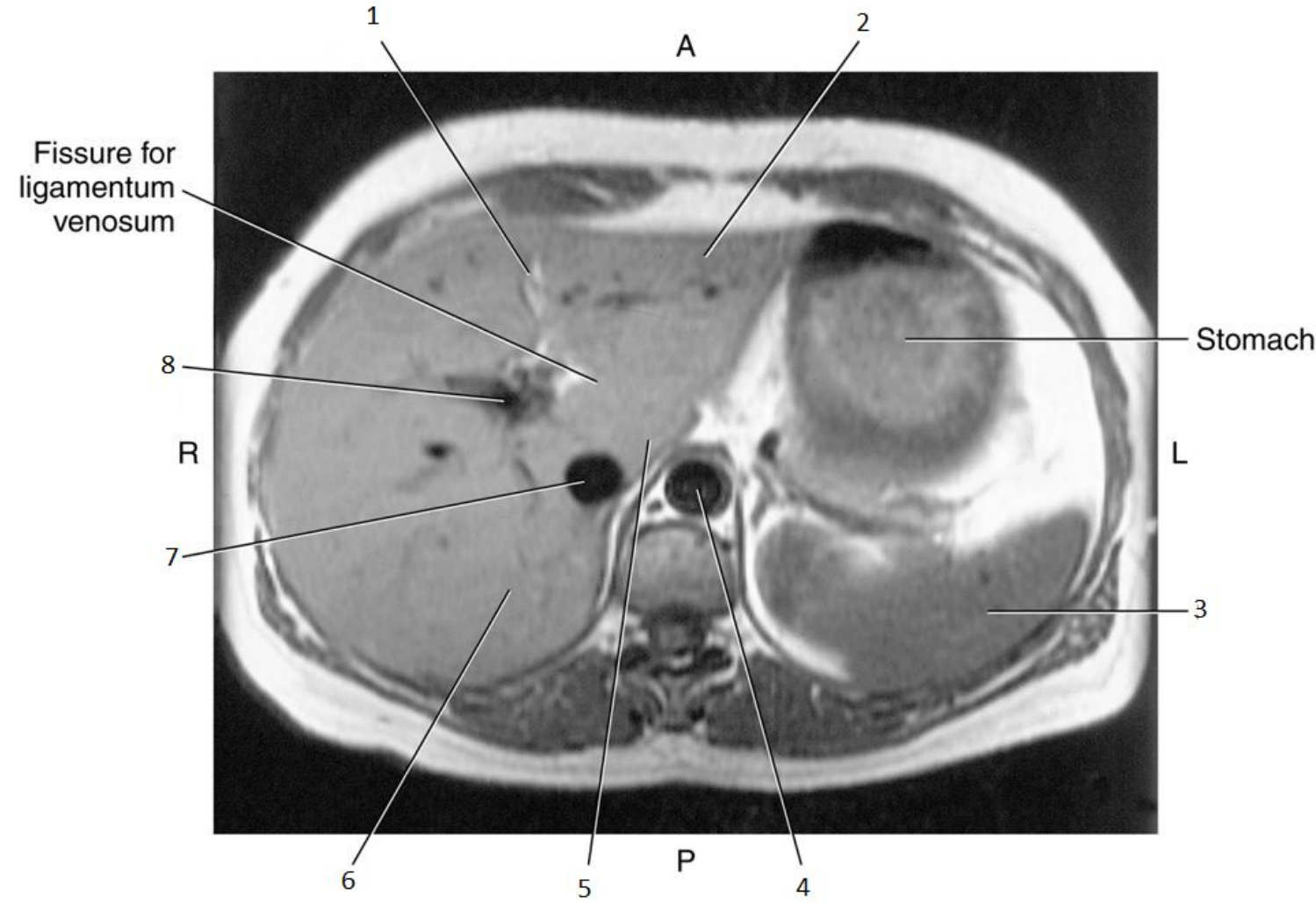


3

- Liver

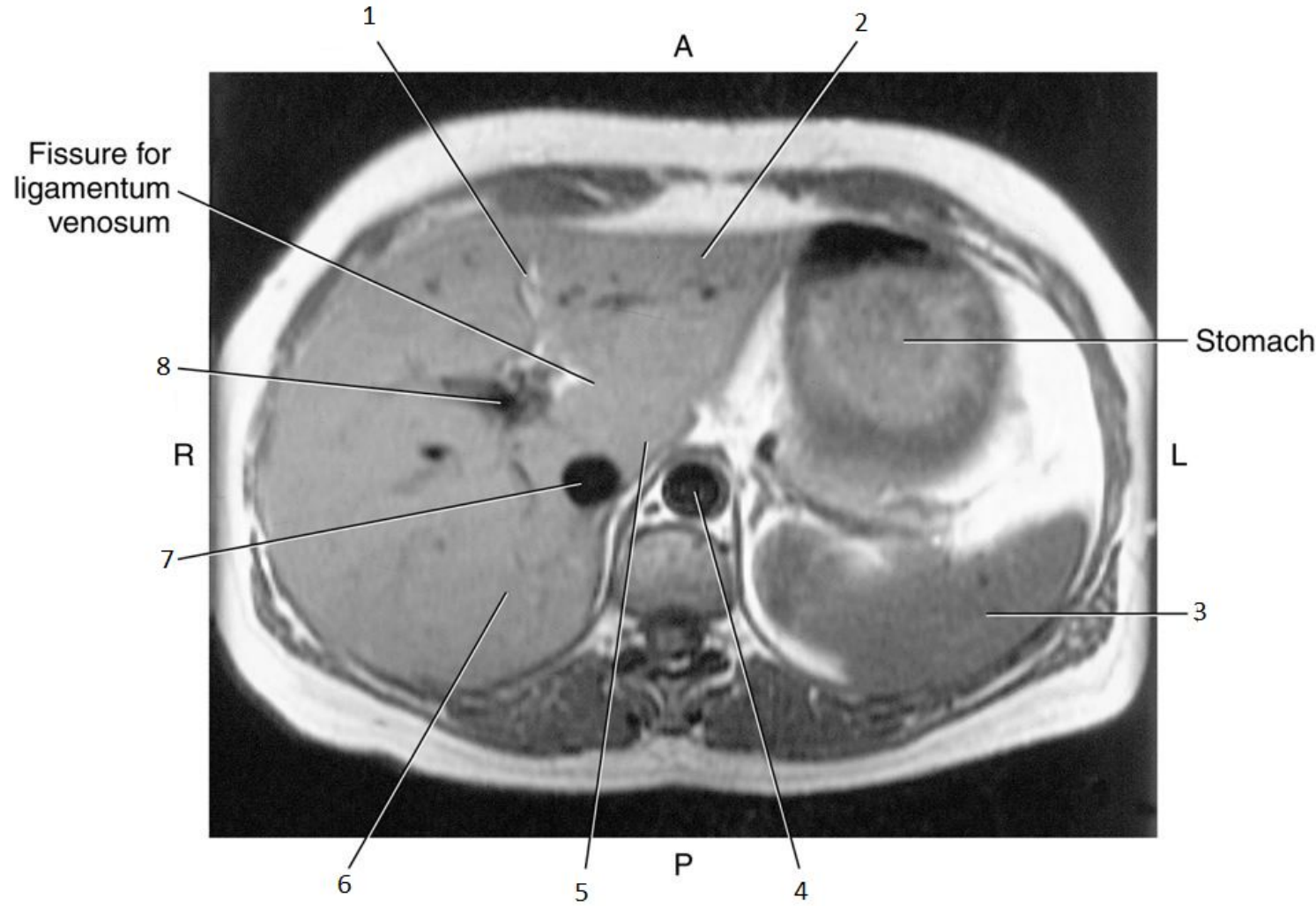


1

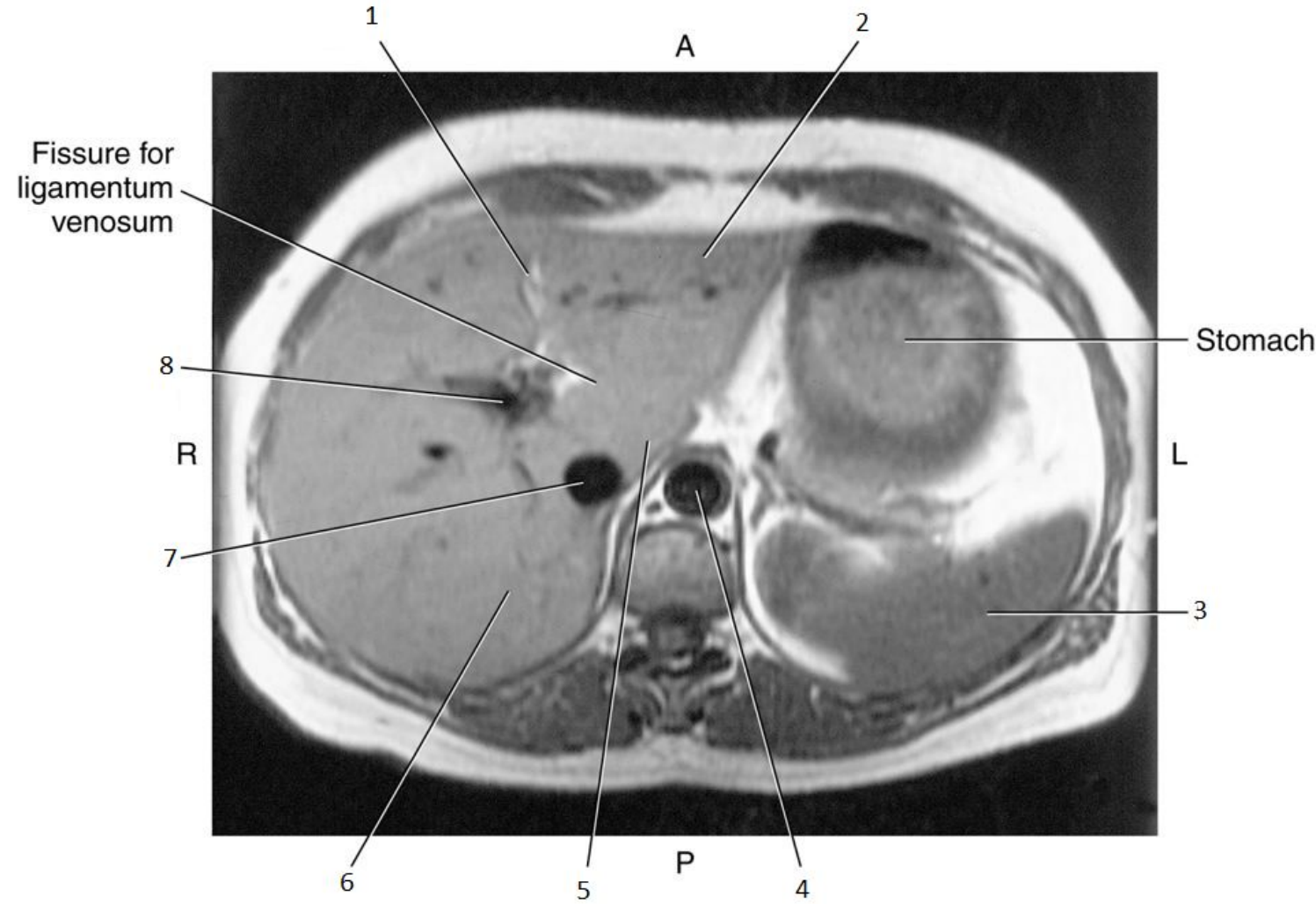


1

- Falciform Ligament

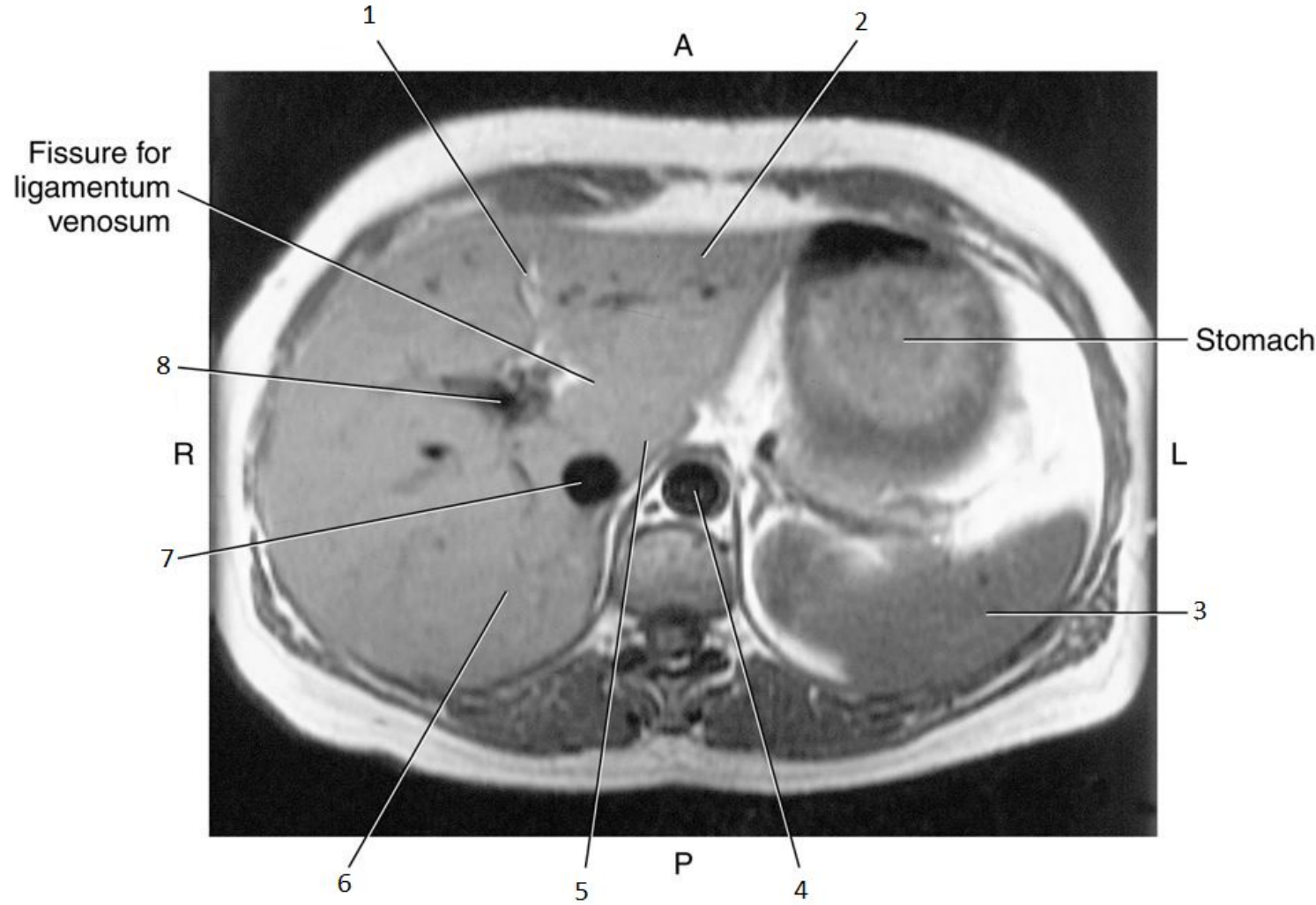


2

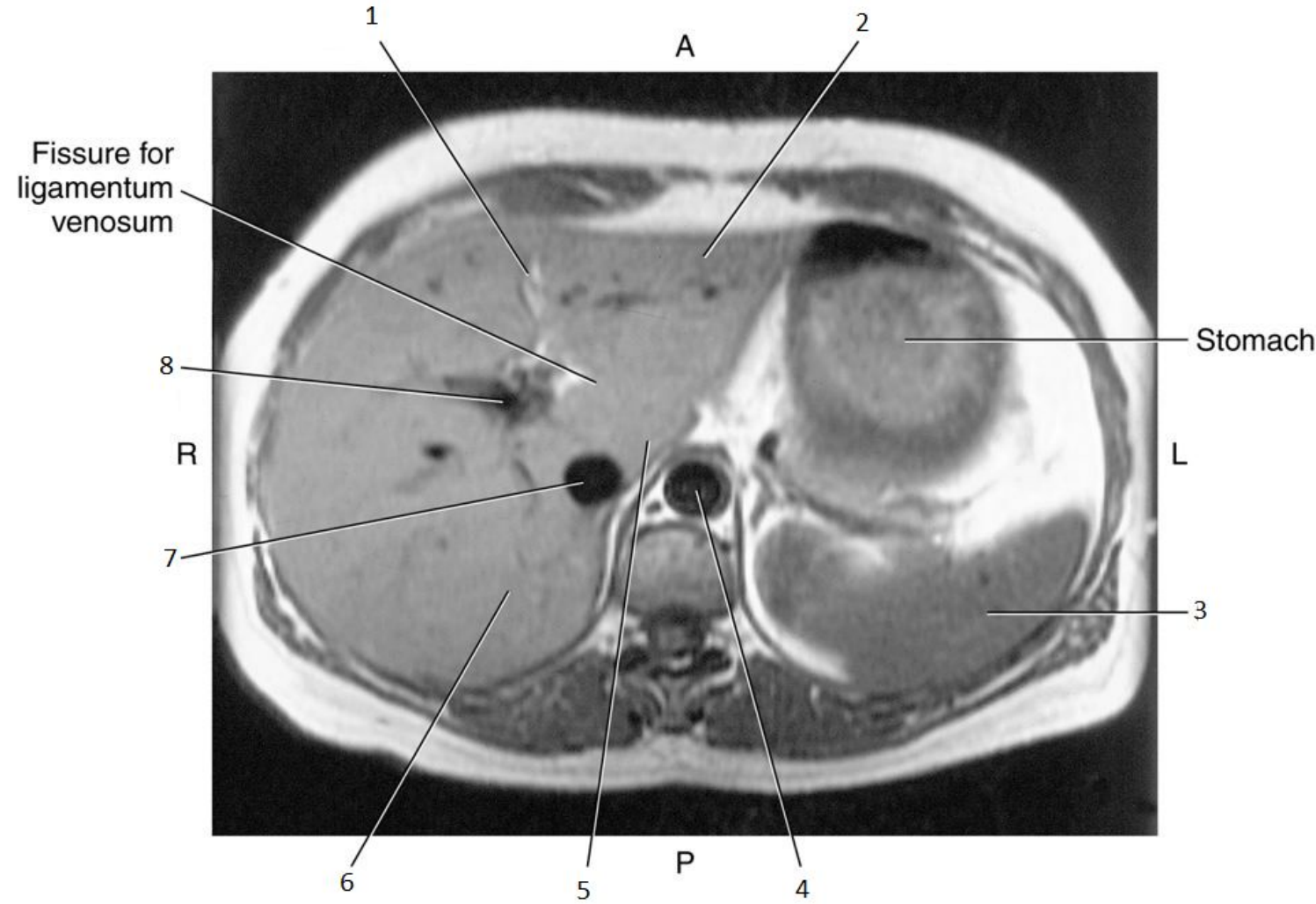


2

- Left lobe of Liver

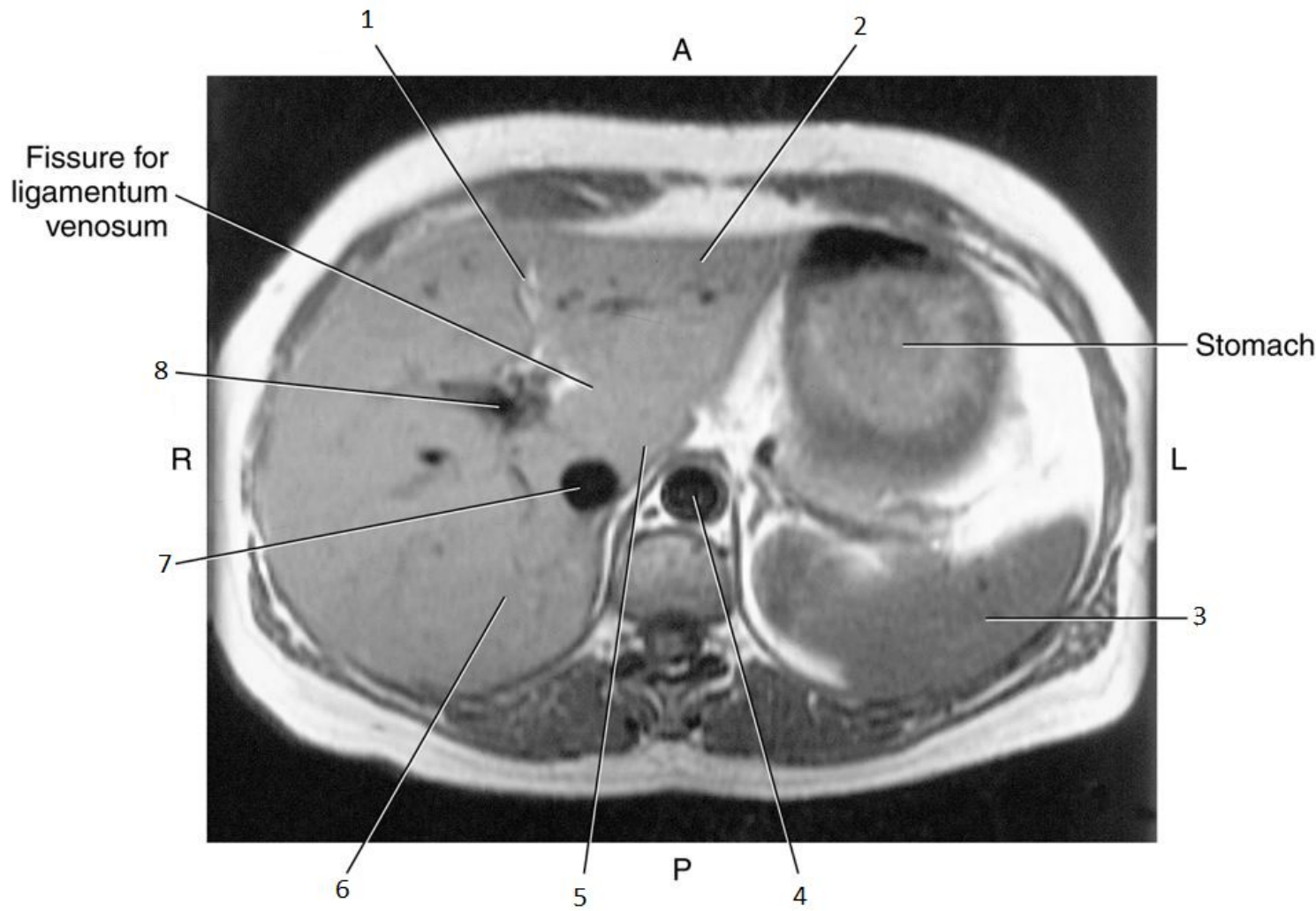


3

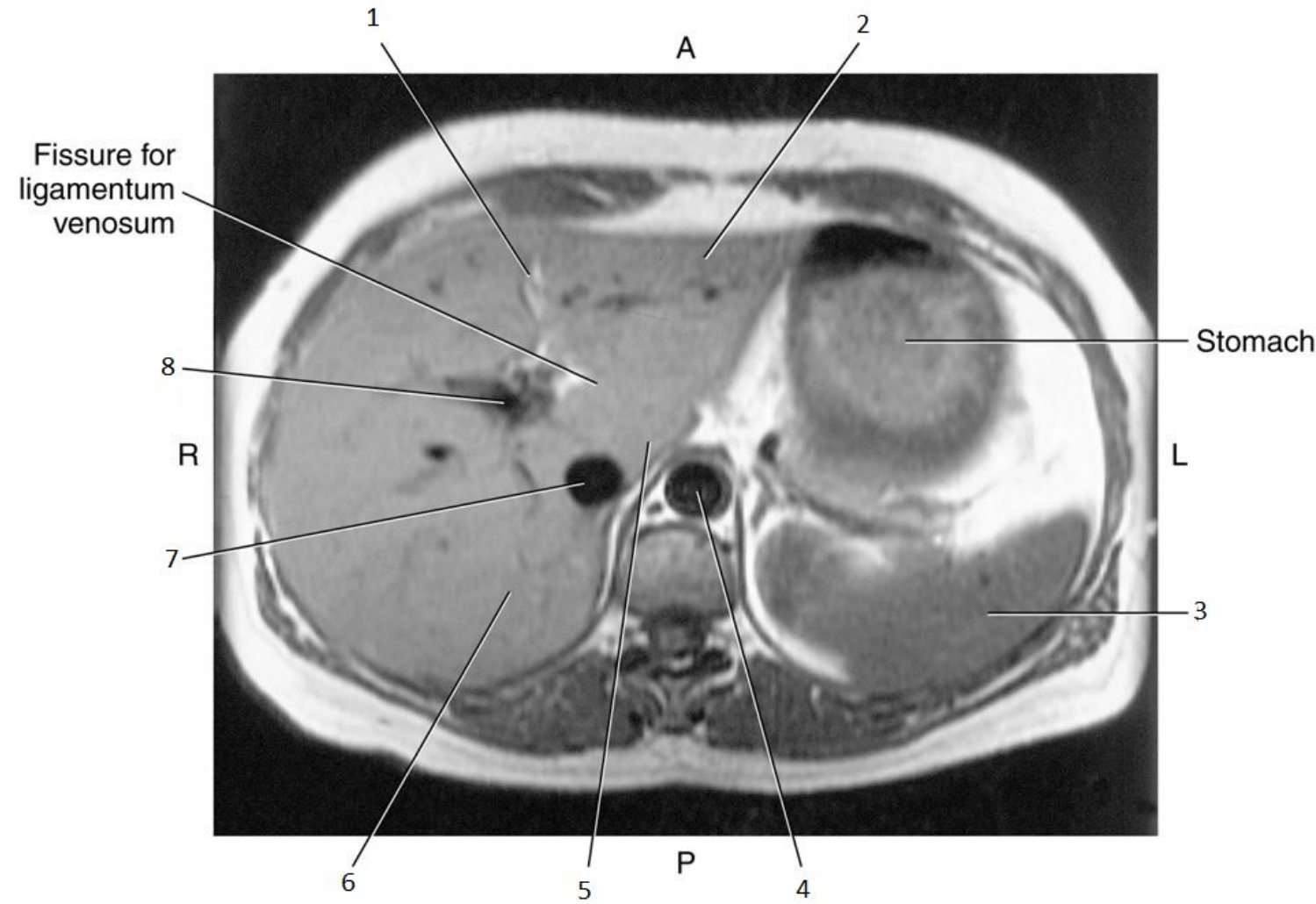


3

• Spleen

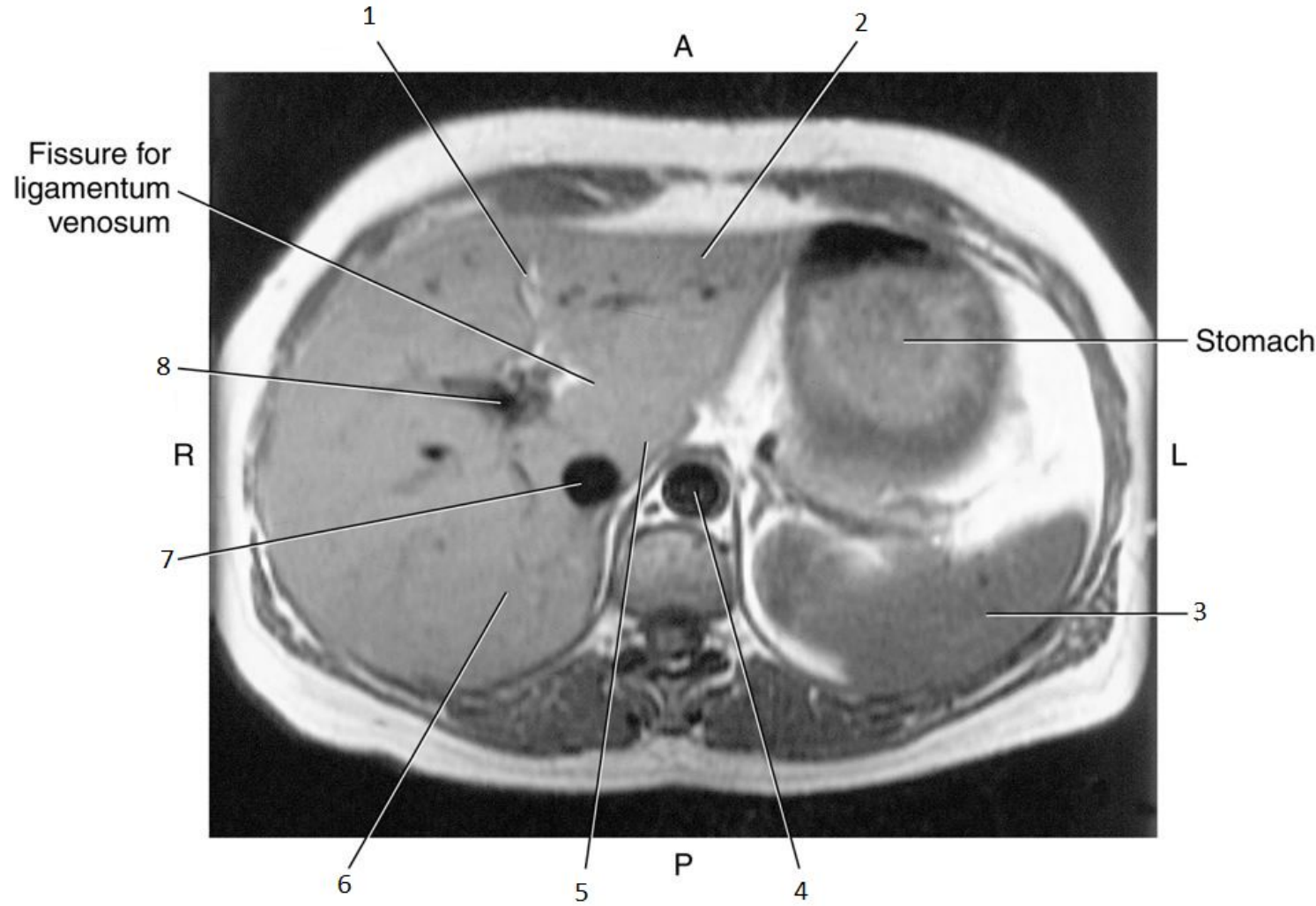


4

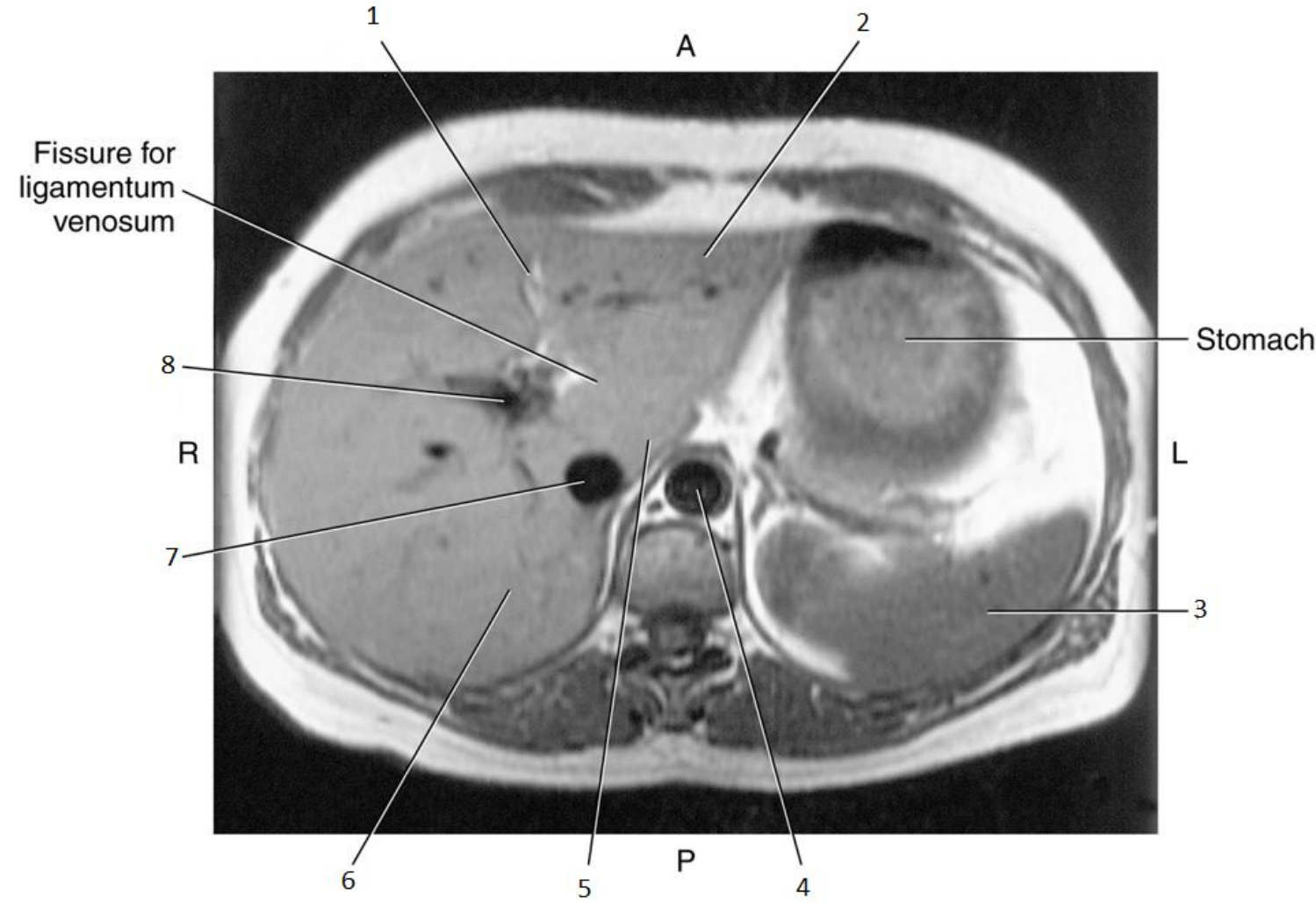


4

• Aorta

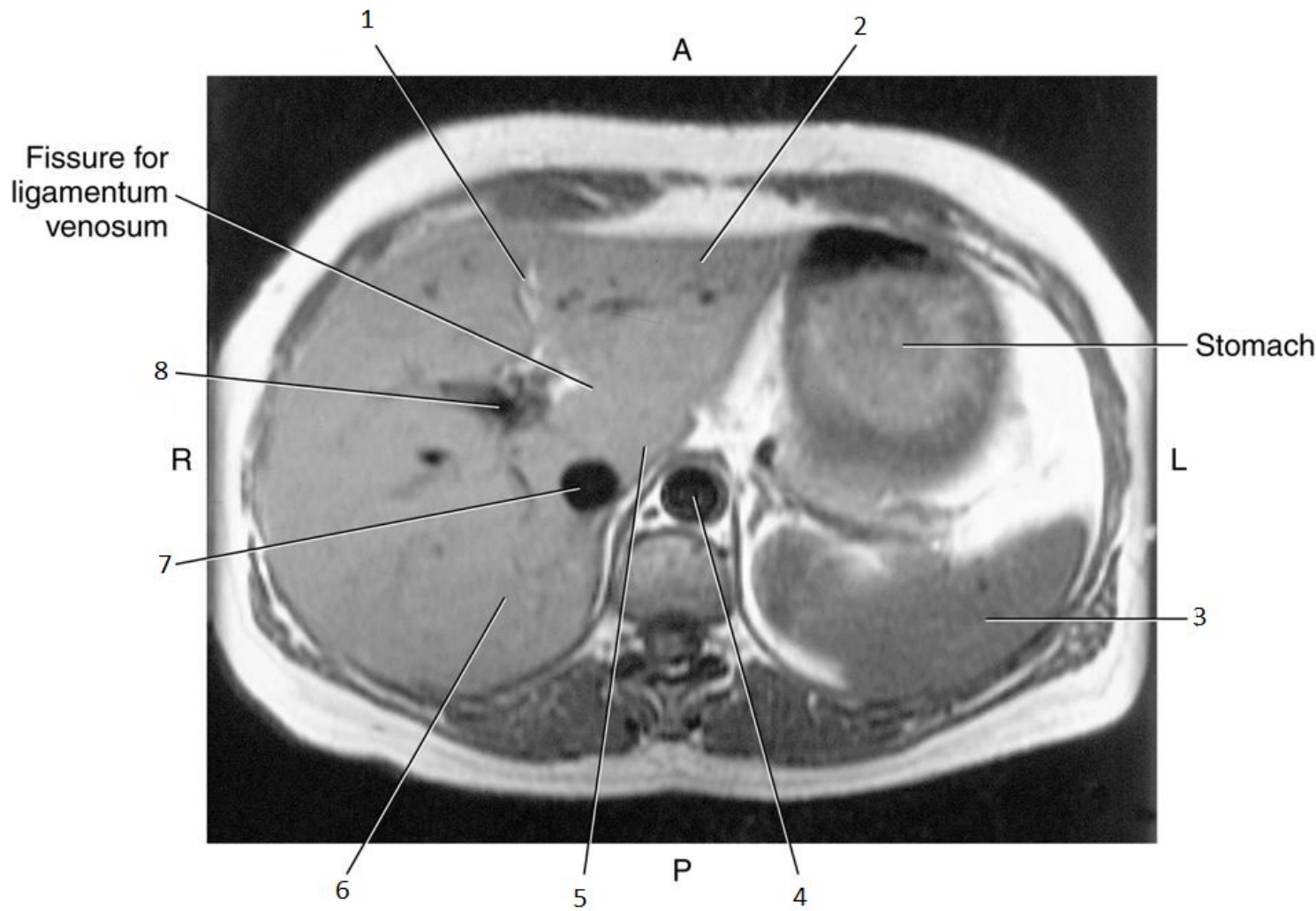


5

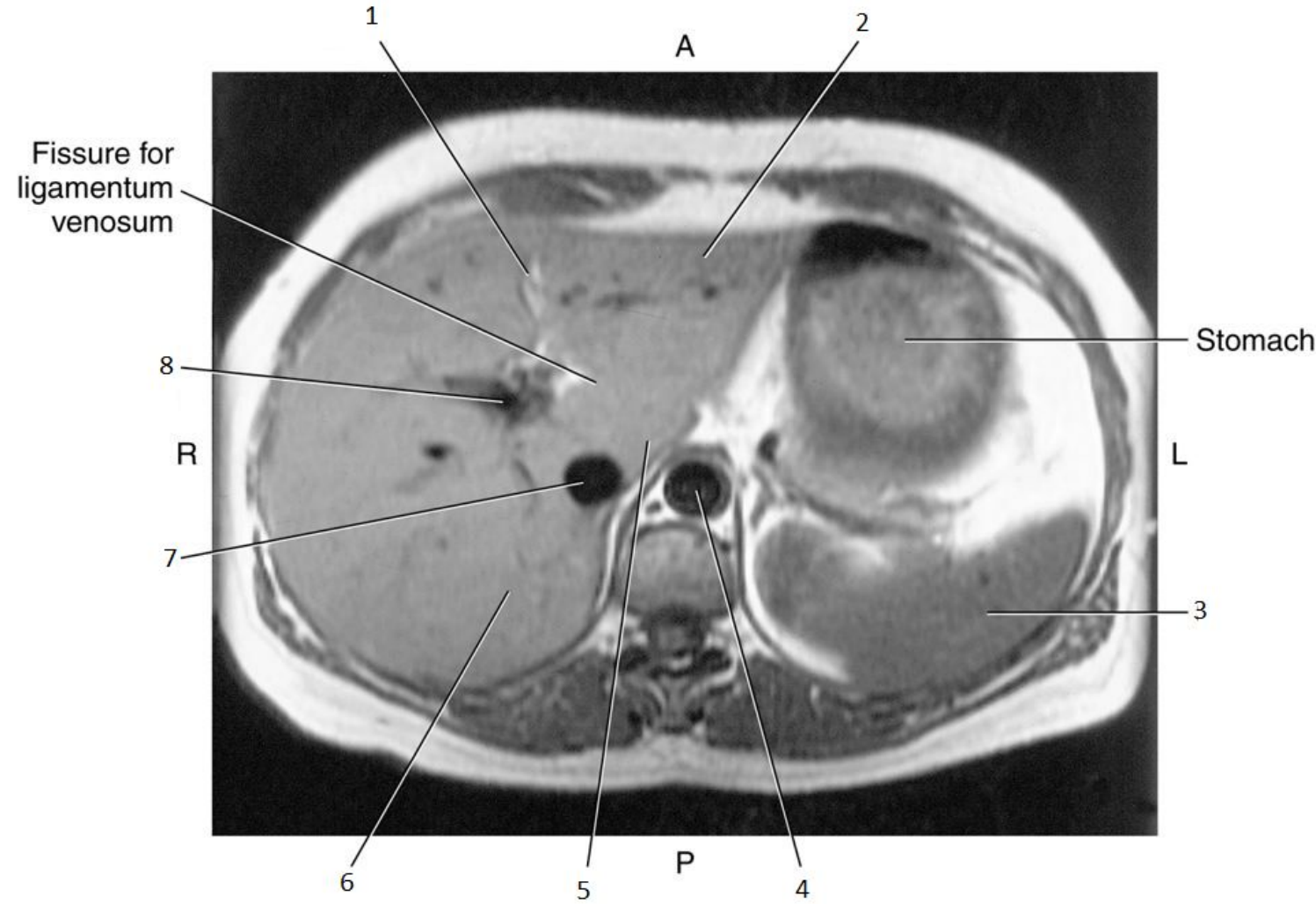


5

- Caudate Lobe of Liver

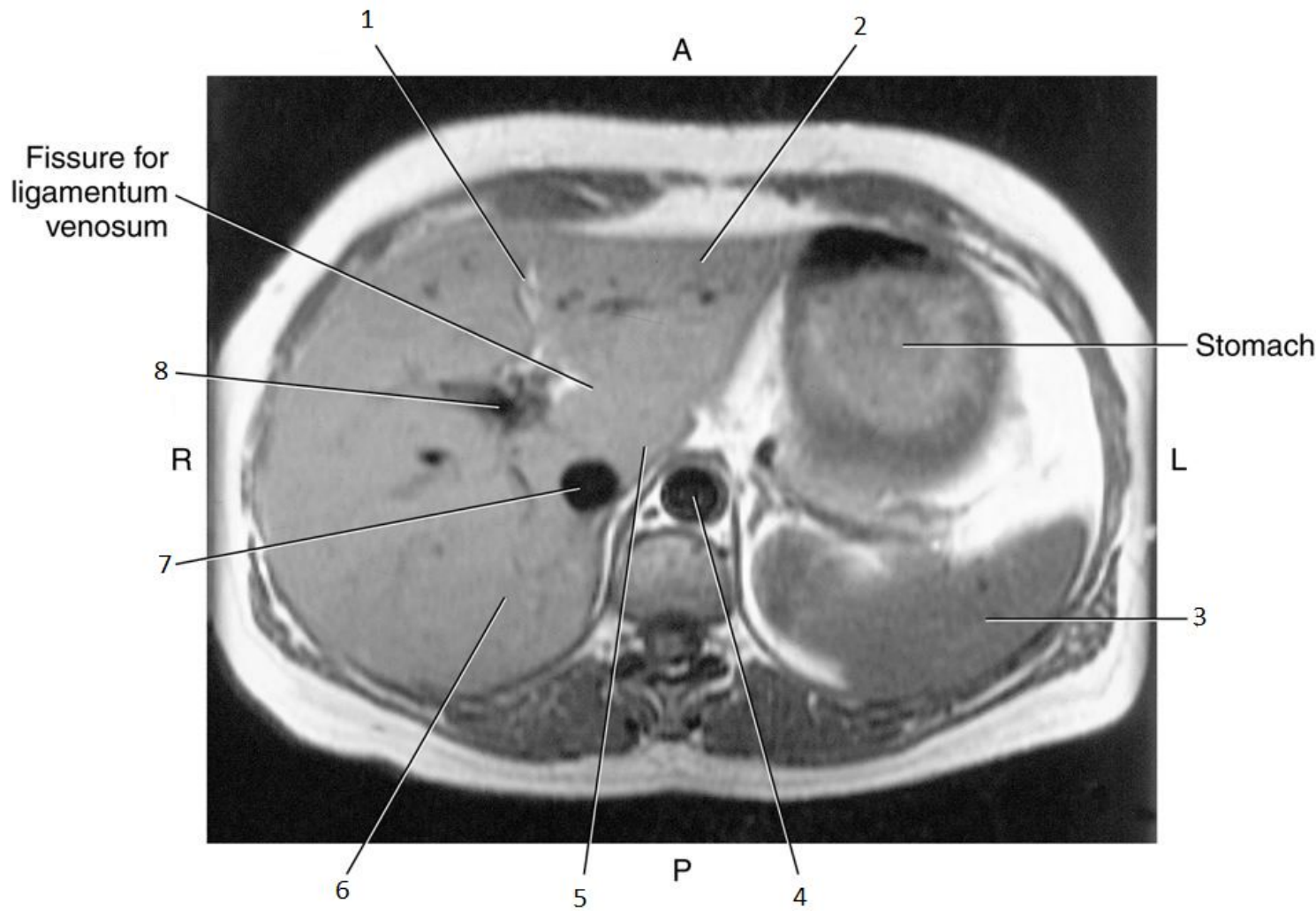


6

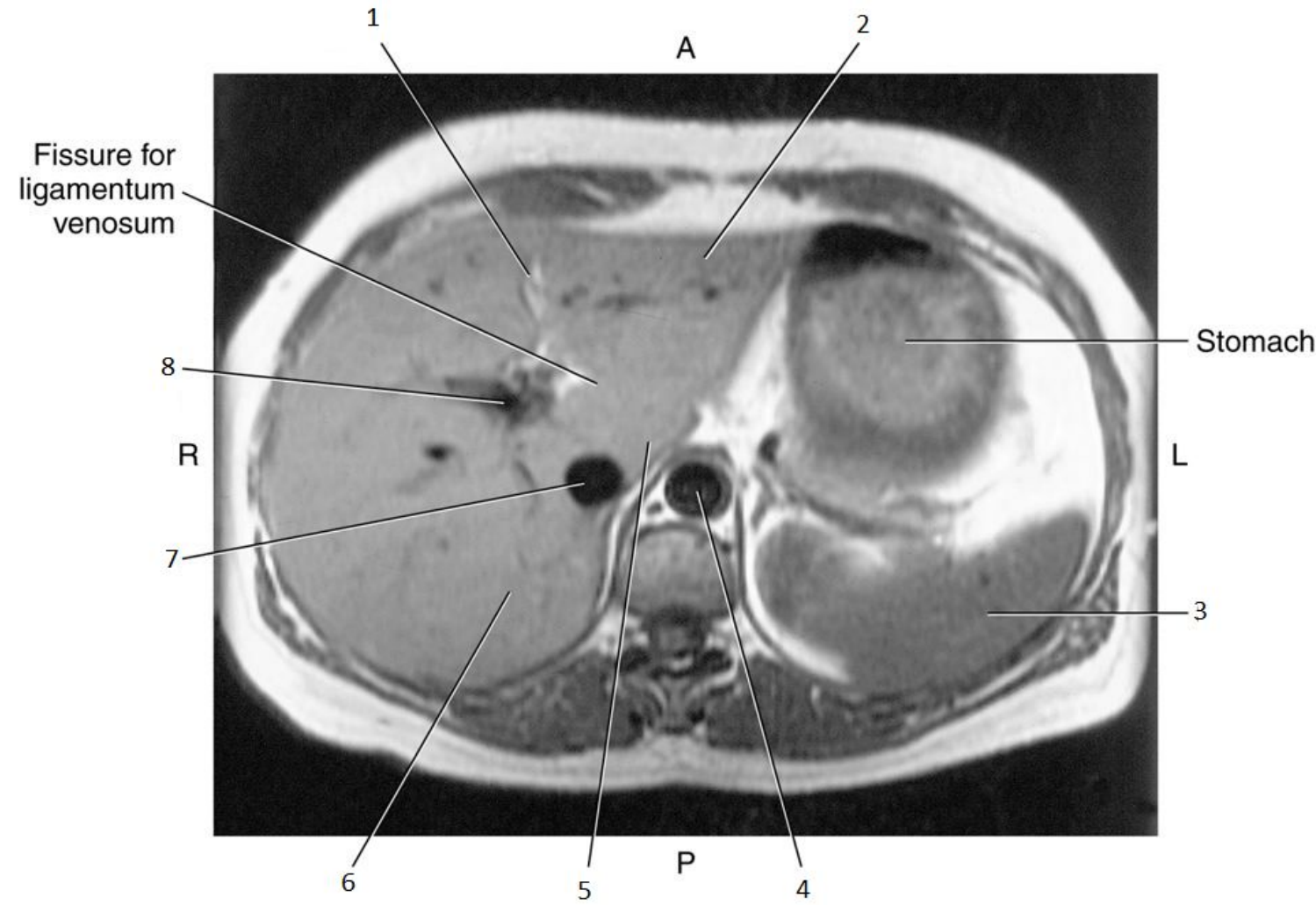


6

- Right Lobe of Liver

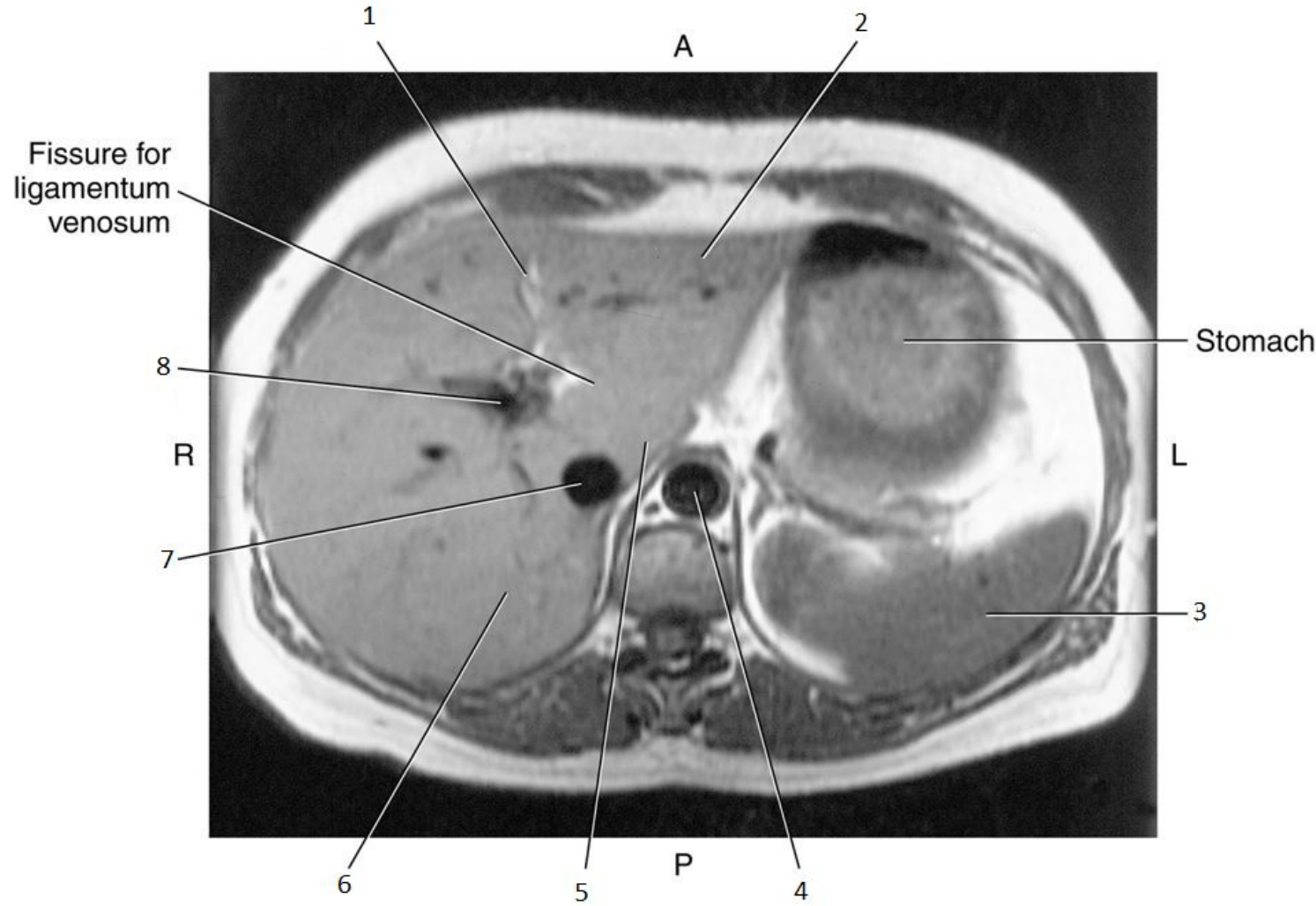


7

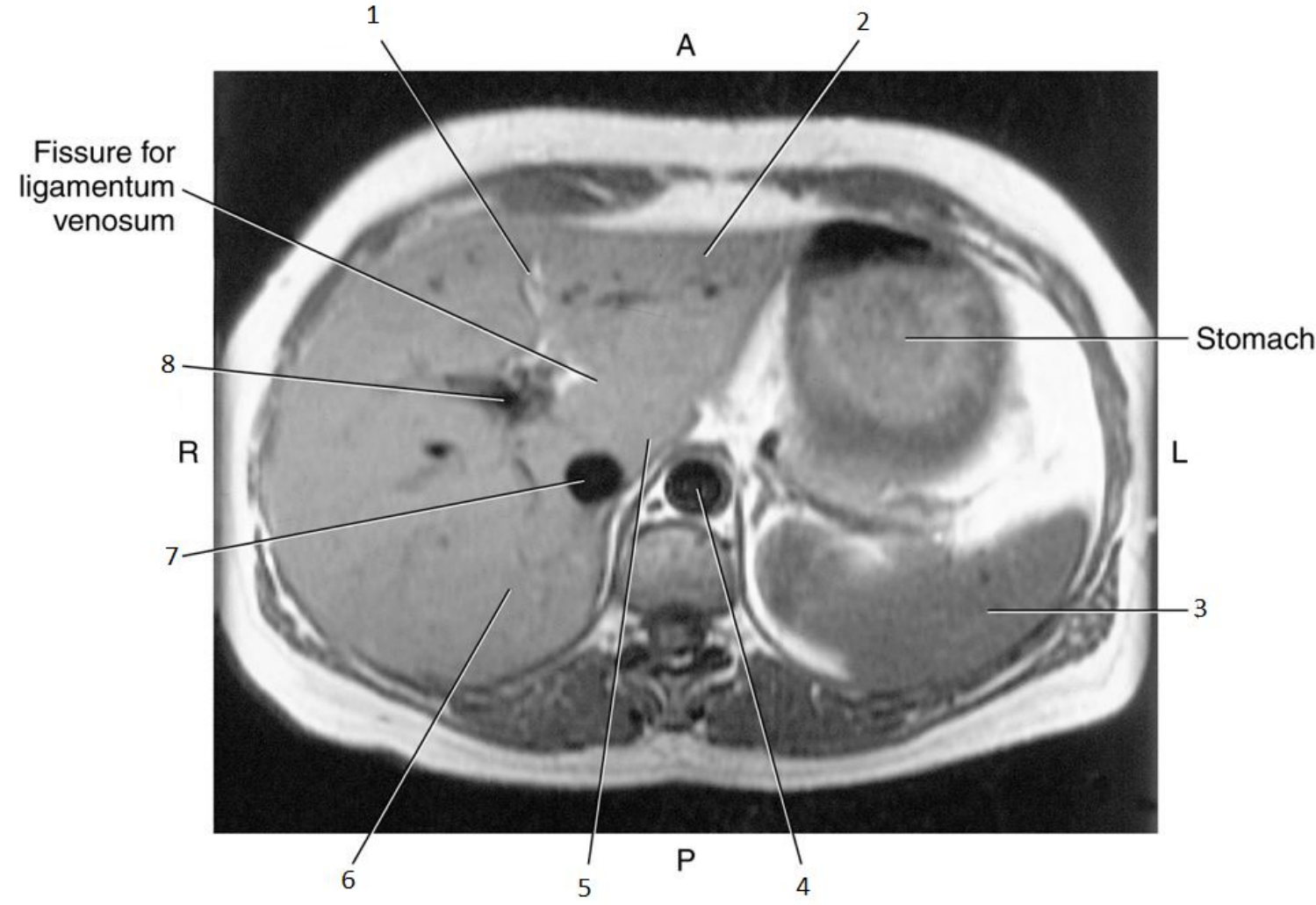


7

- Inferior Vena Cava (IVC)

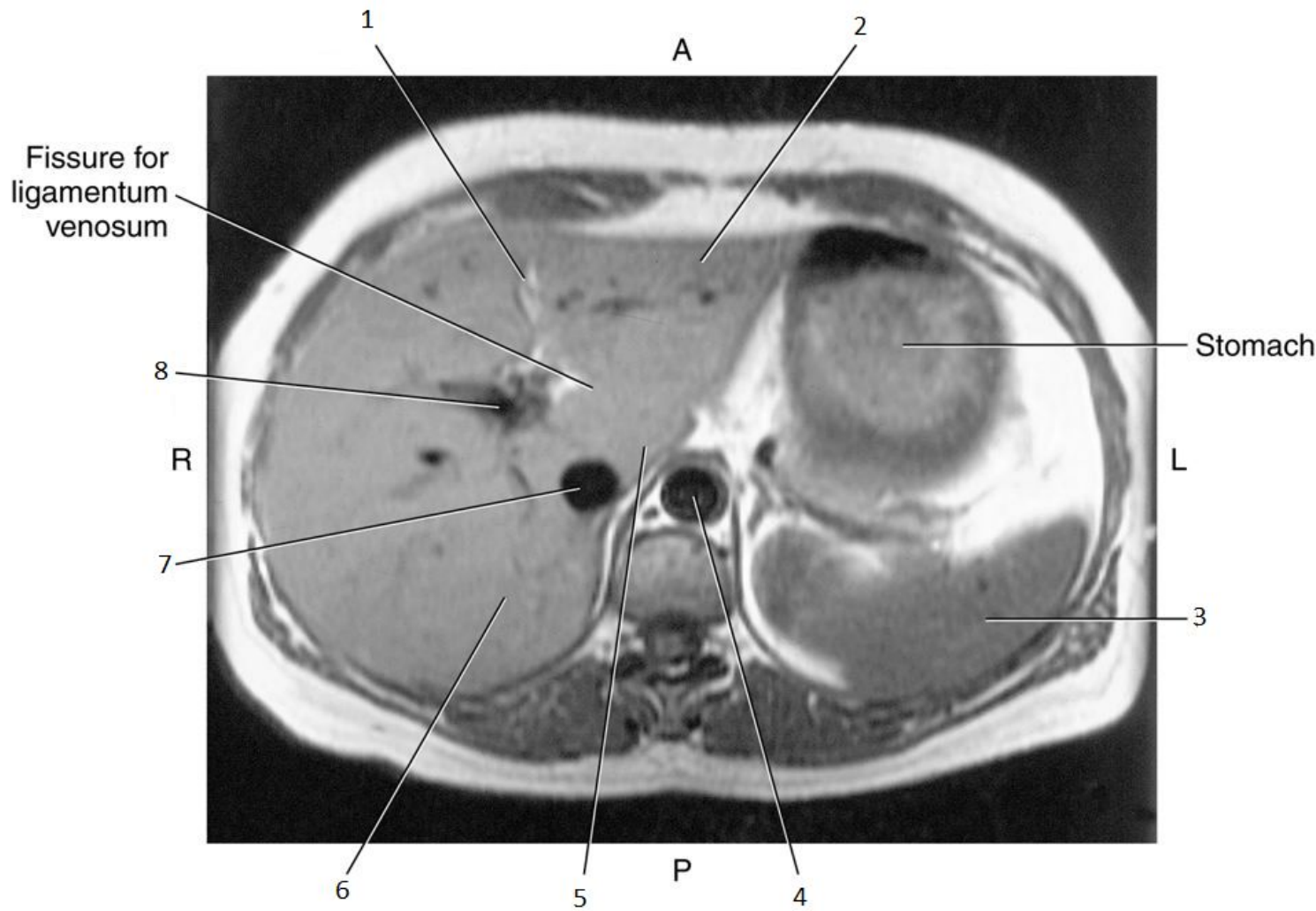


8

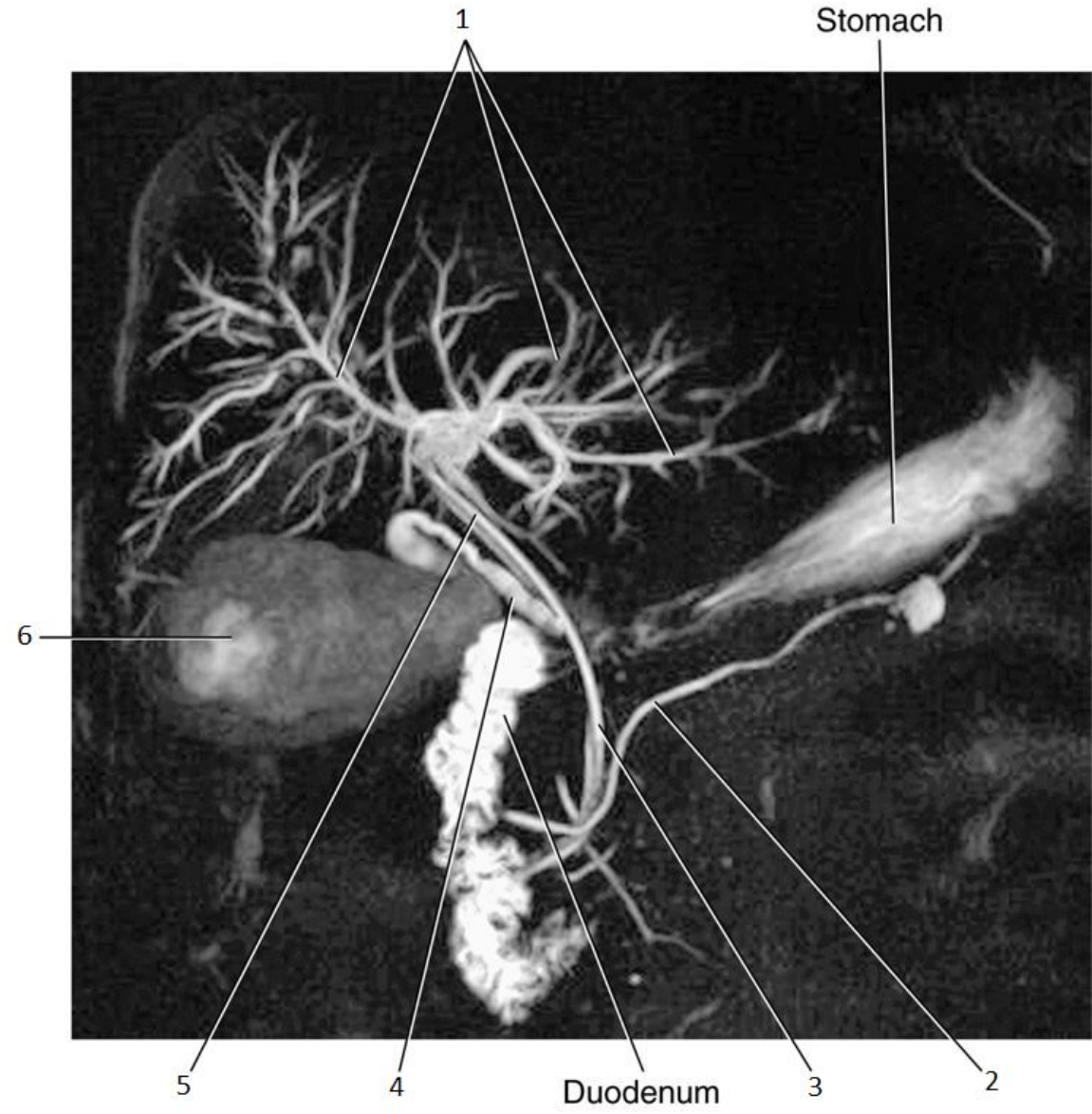


8

- Portal Vein

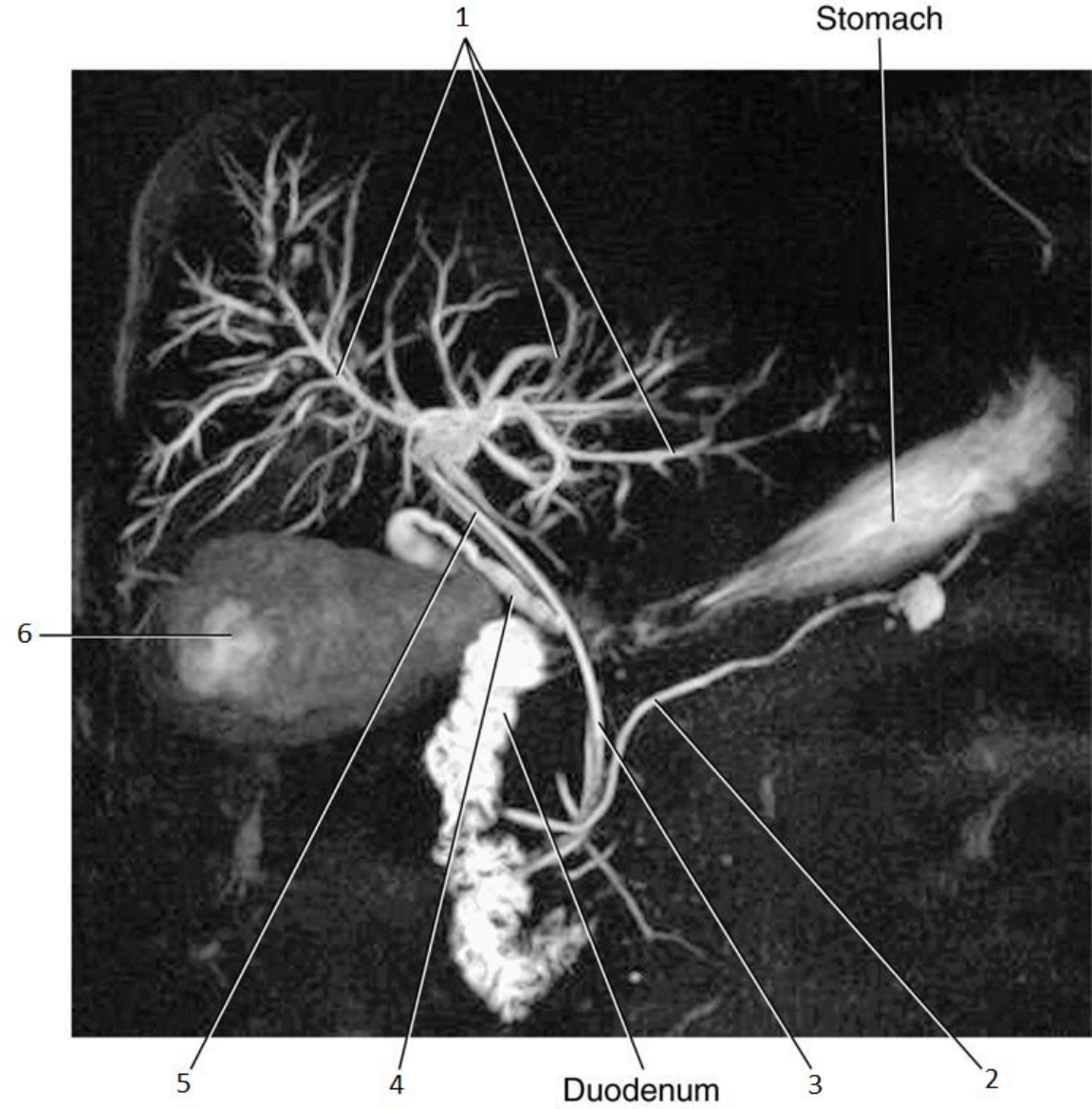


1

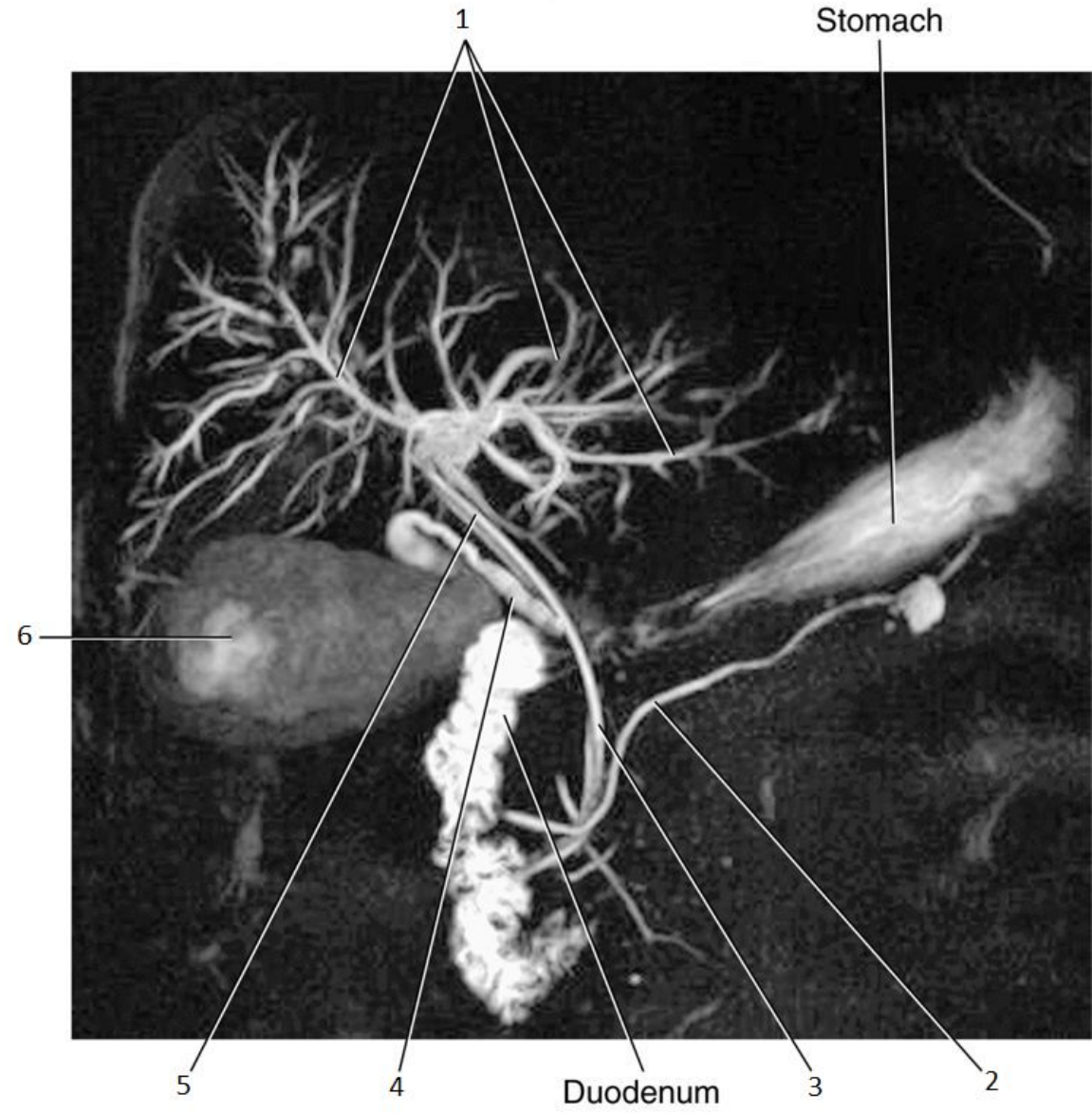


1

- Intrahepatic Ducts

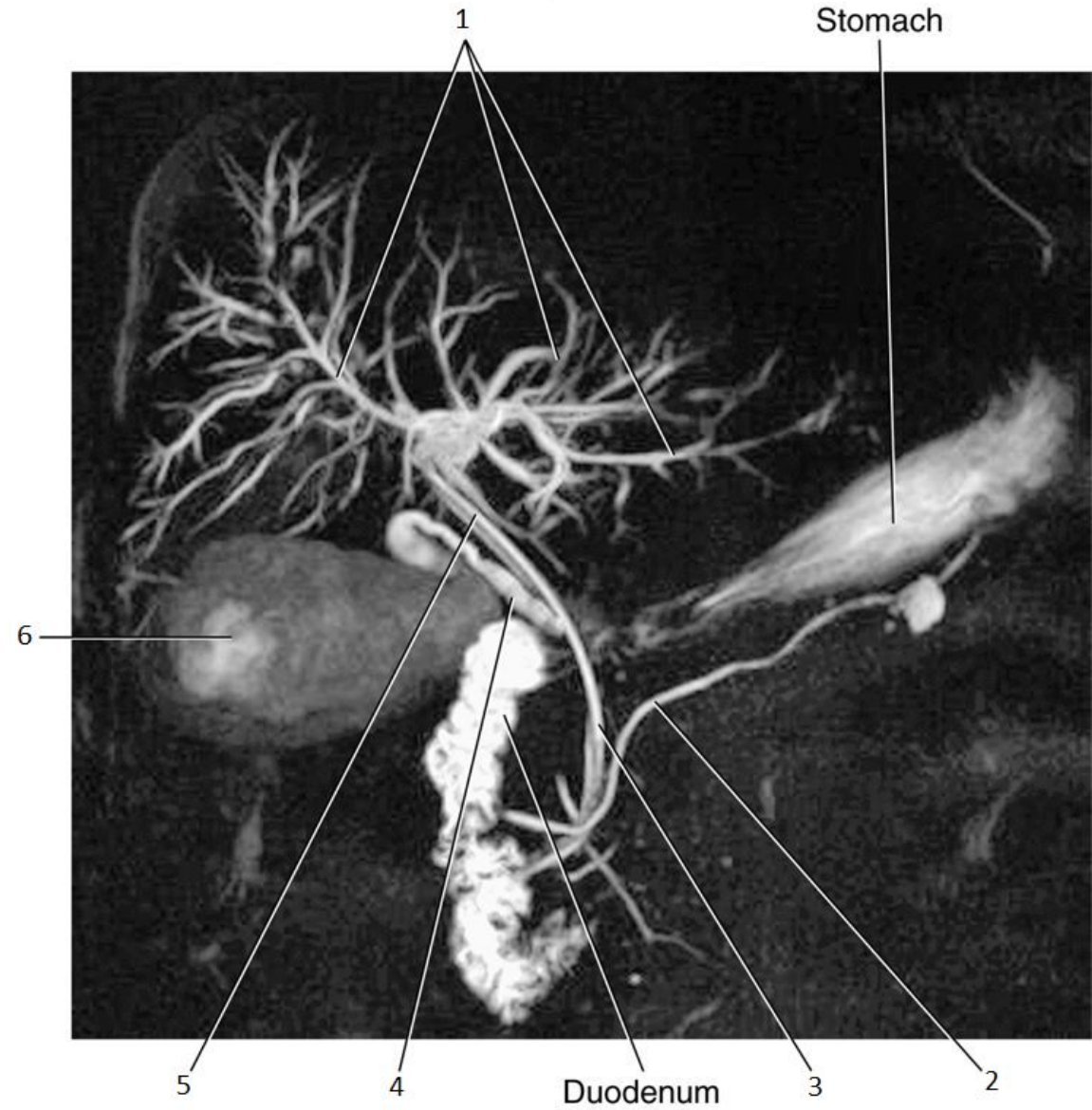


2

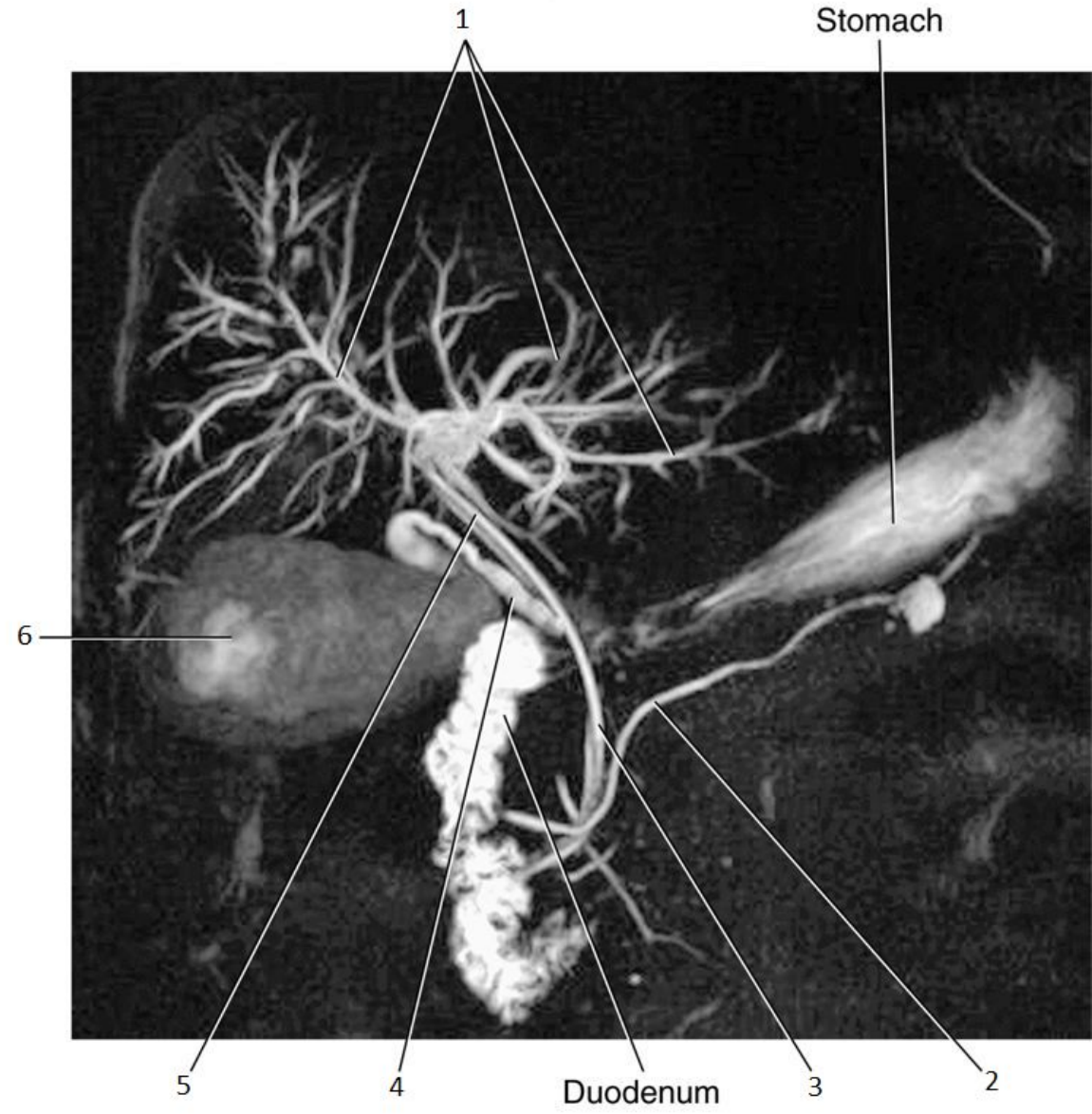


2

- Pancreatic Duct

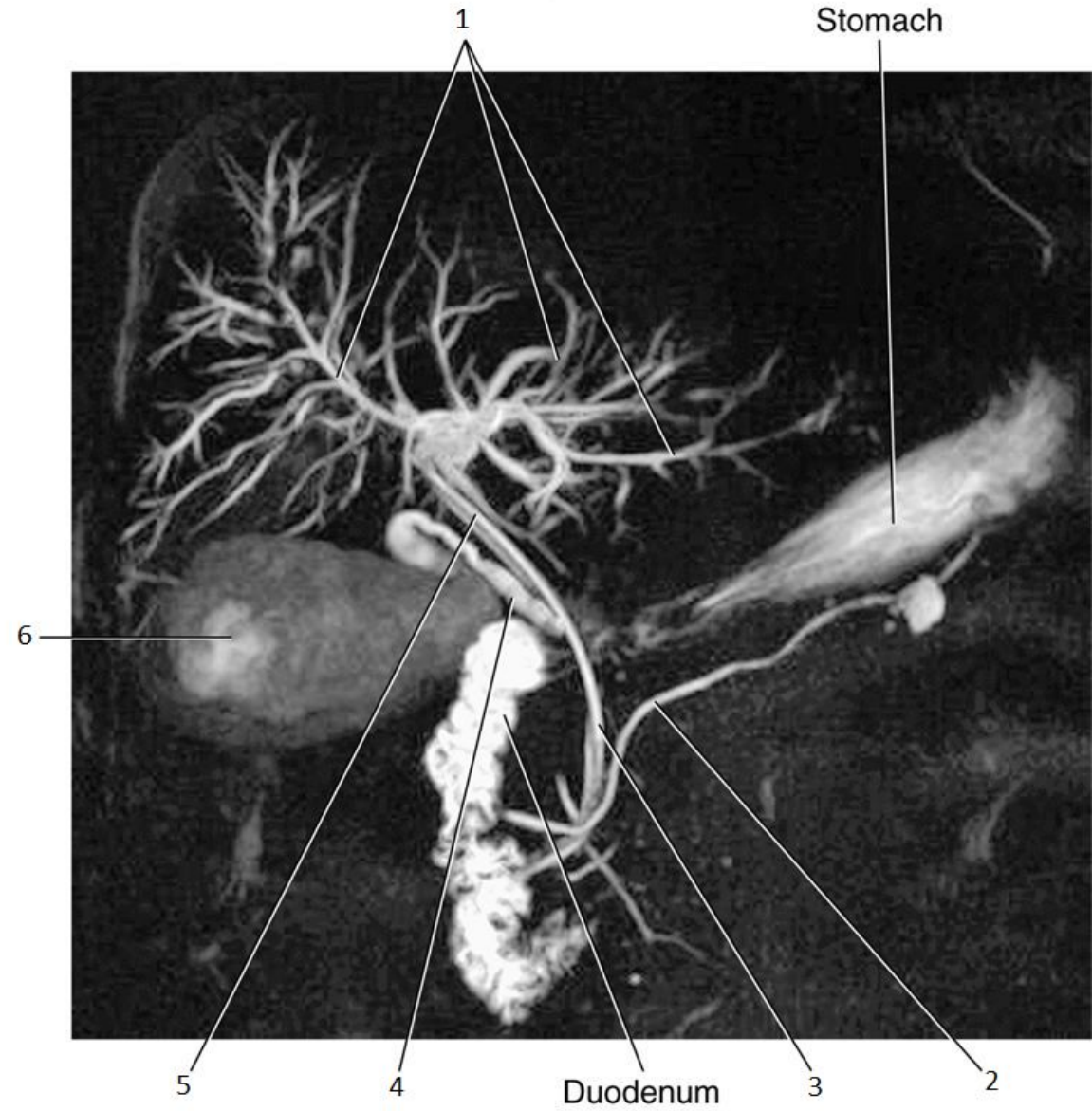


3

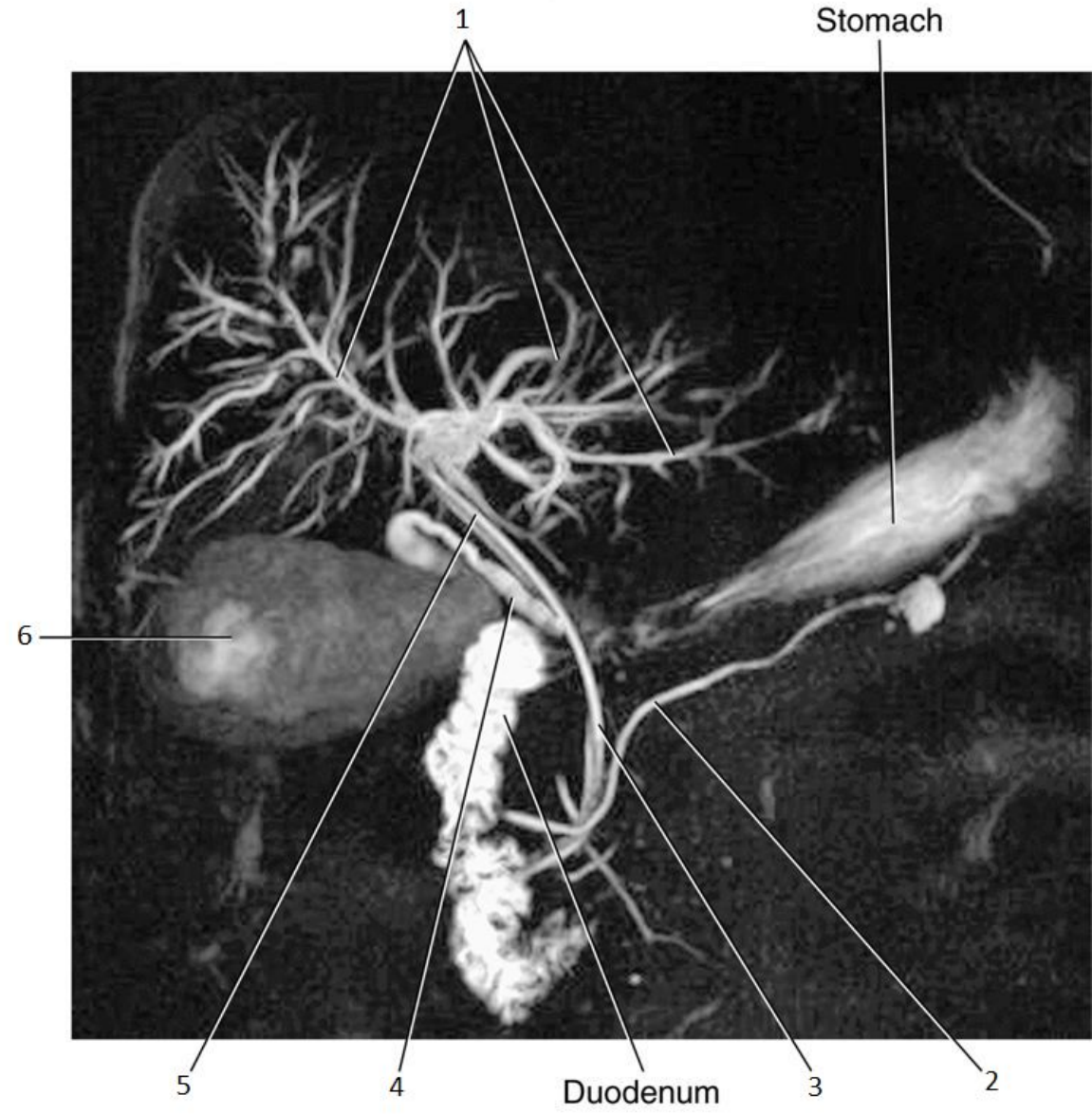


3

- Common Bile Duct

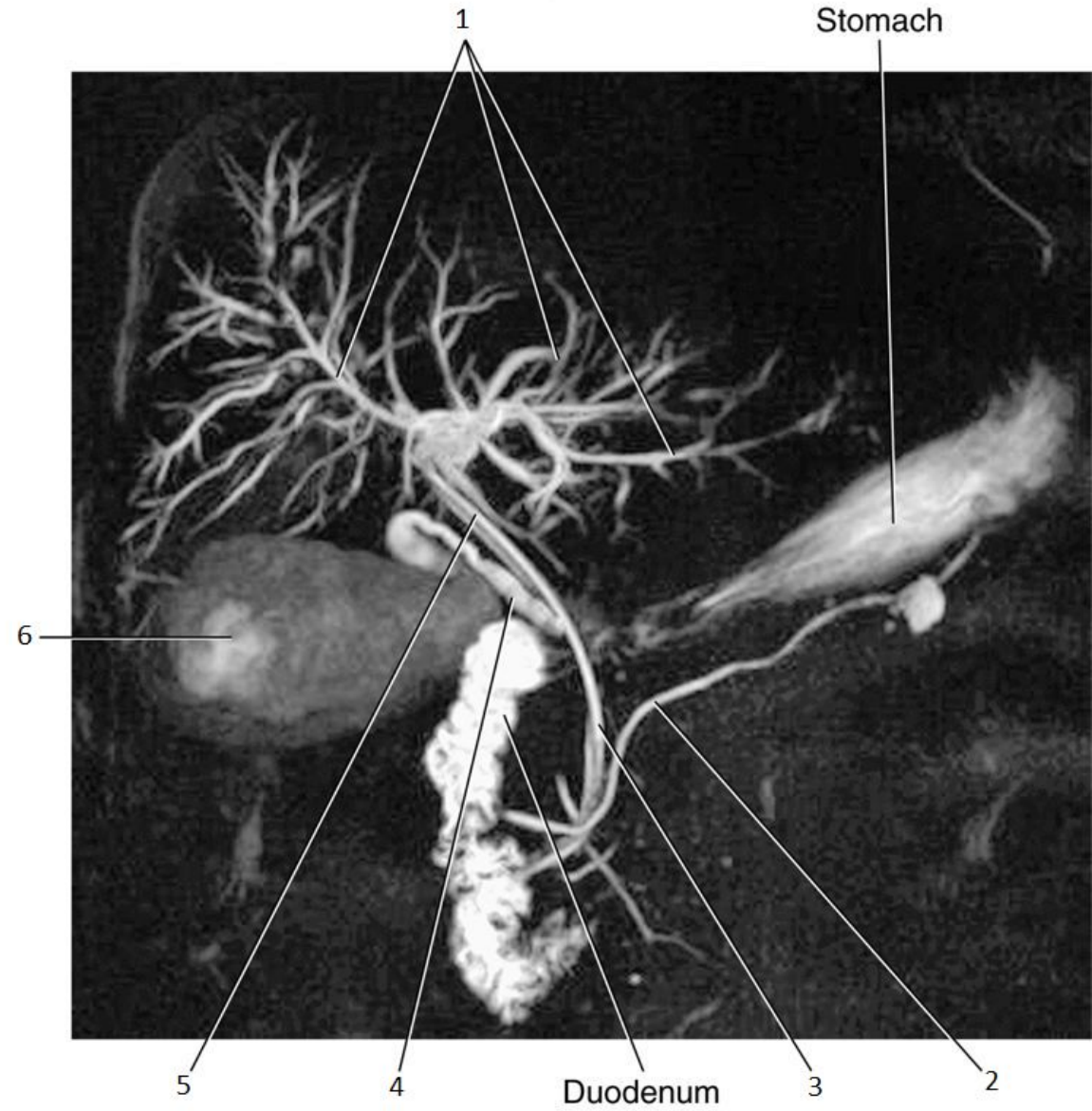


4

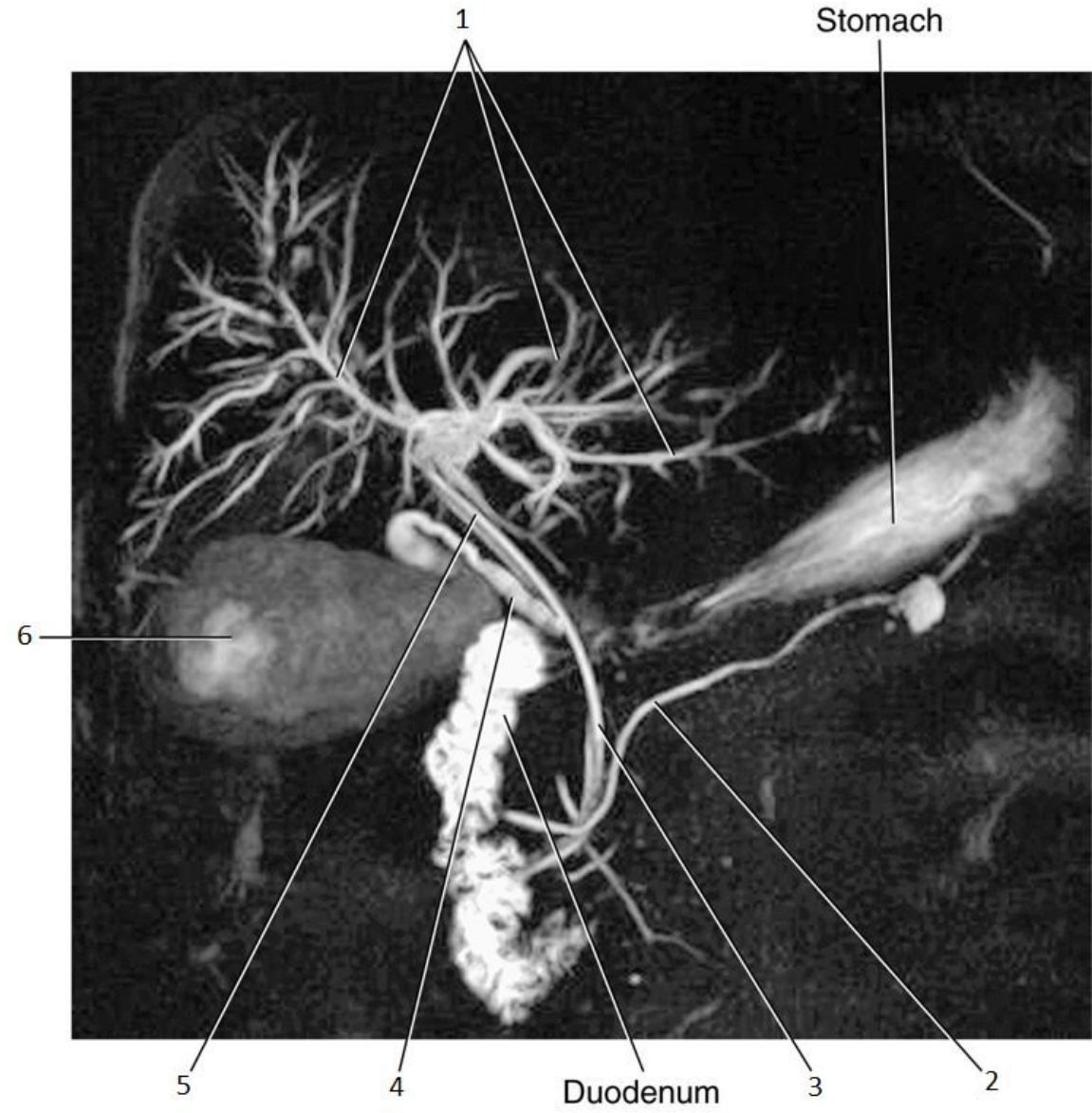


4

- Cystic Duct

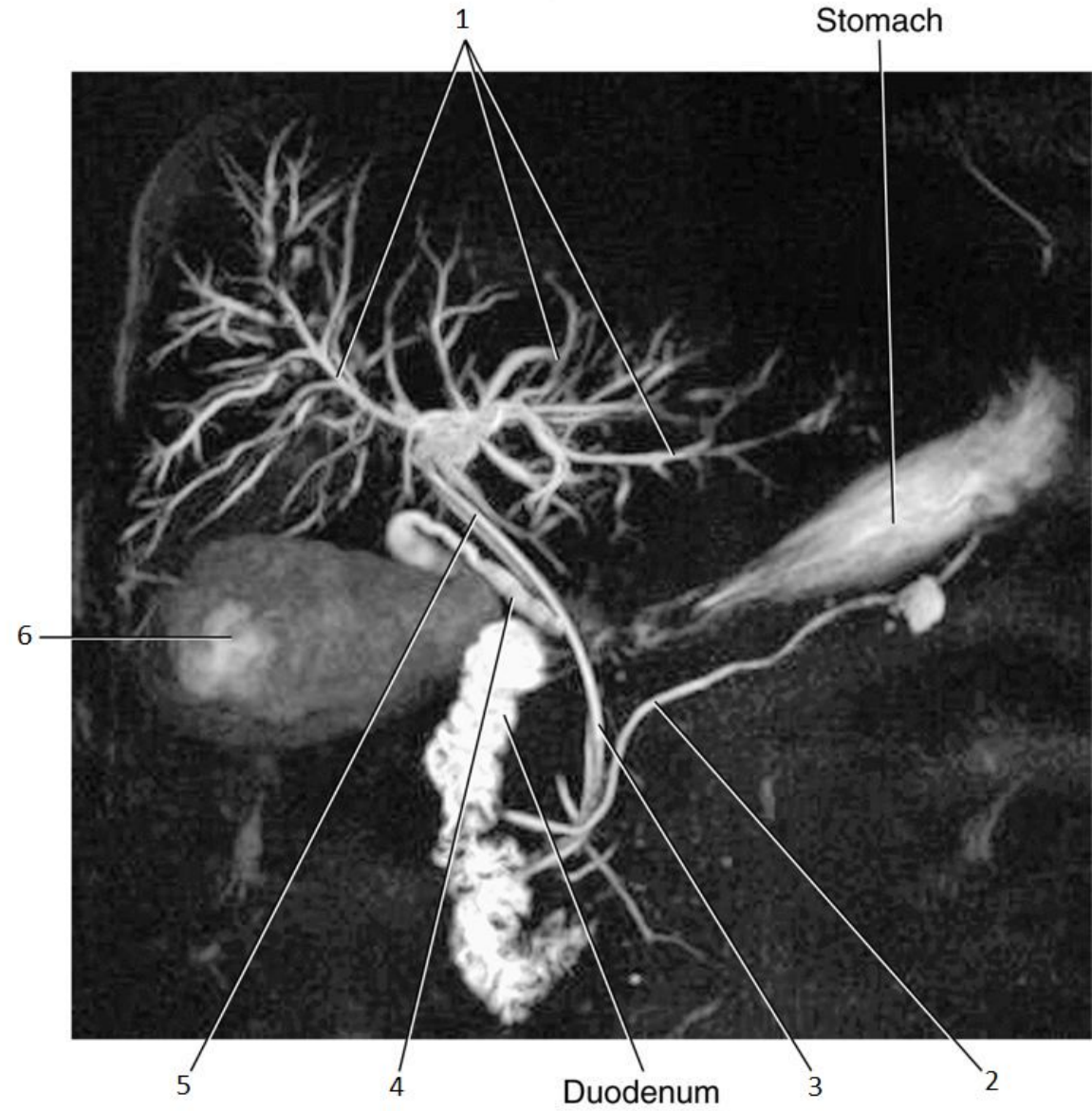


5

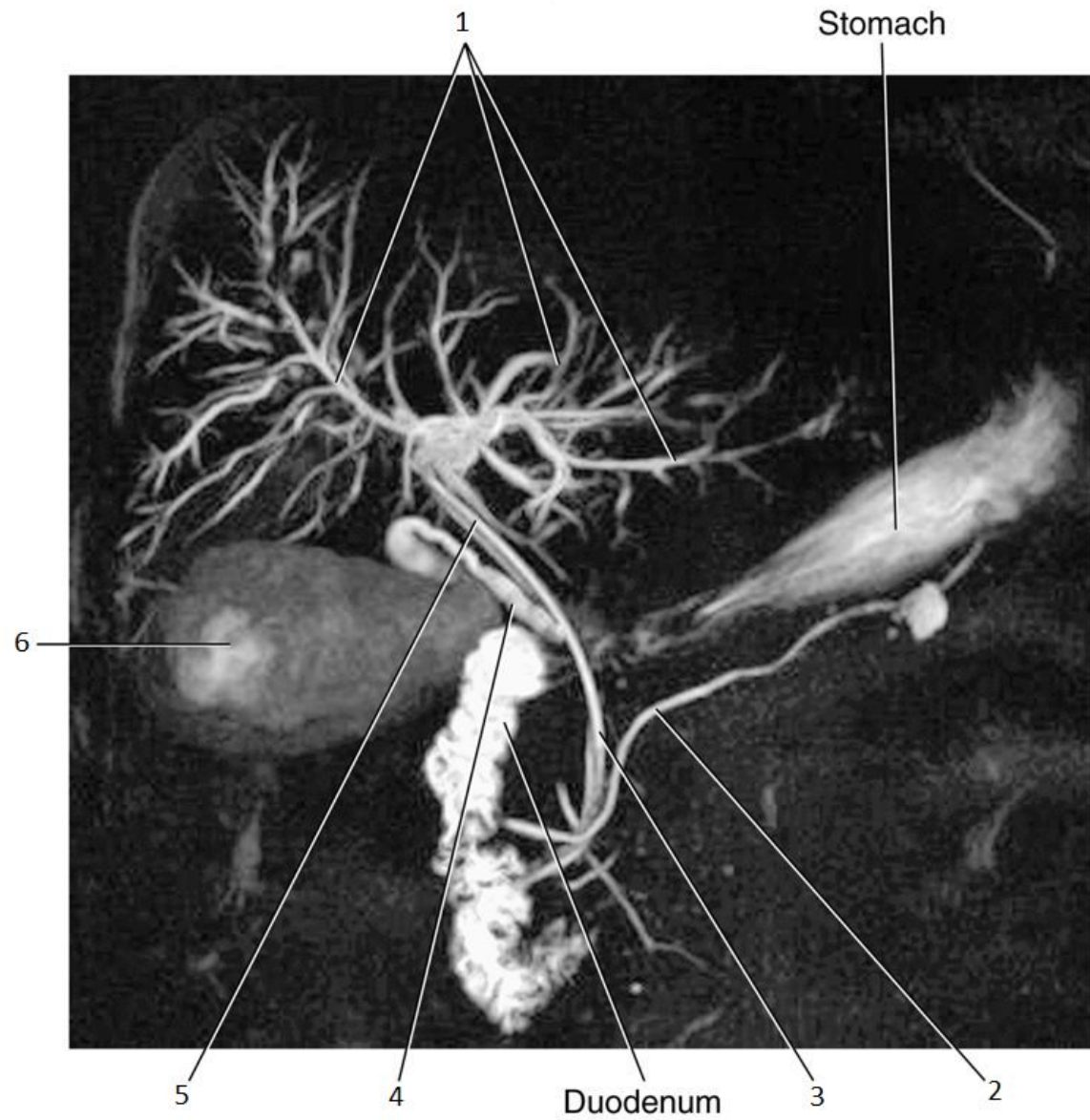


5

- Common Hepatic Duct

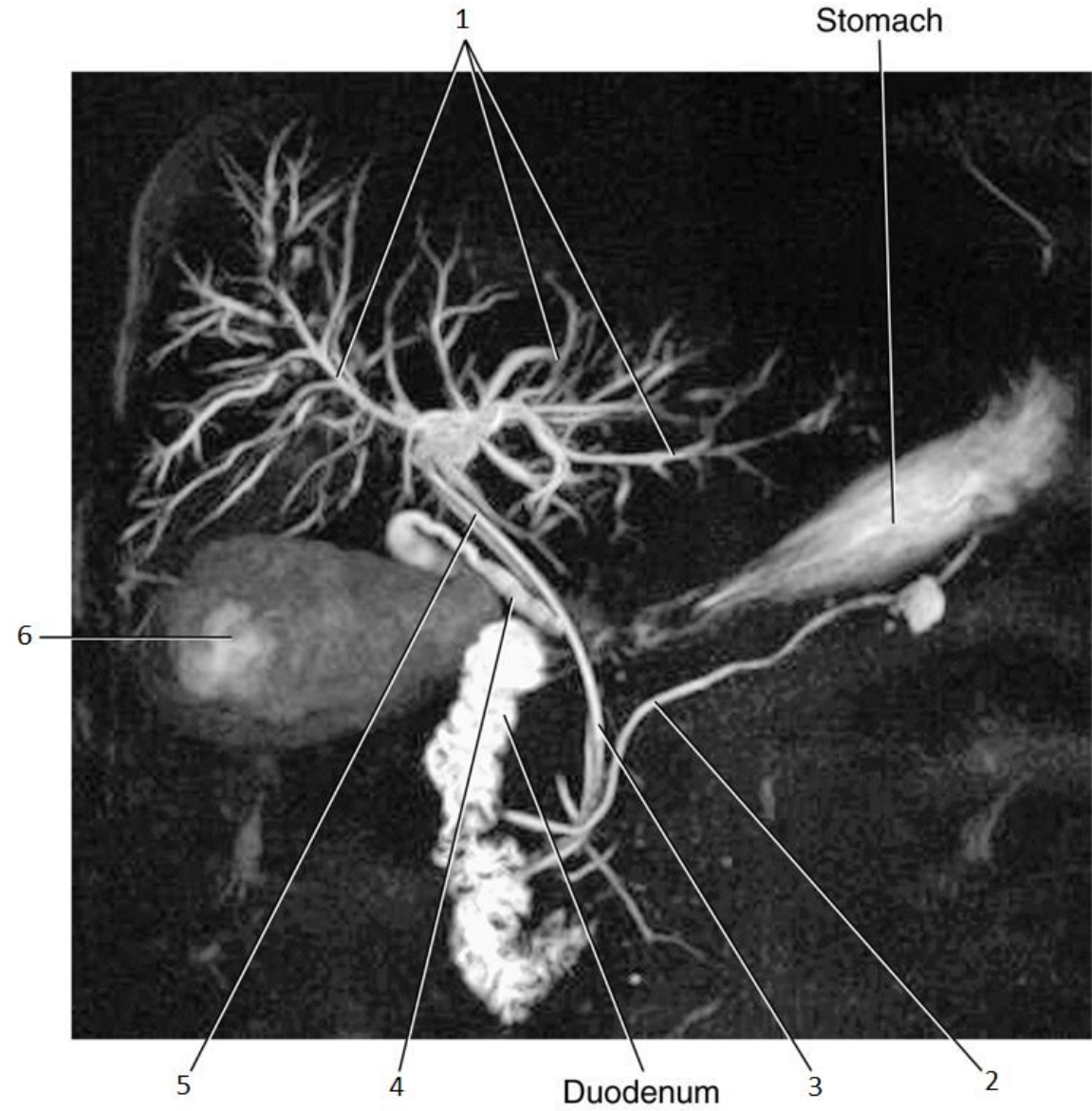


6

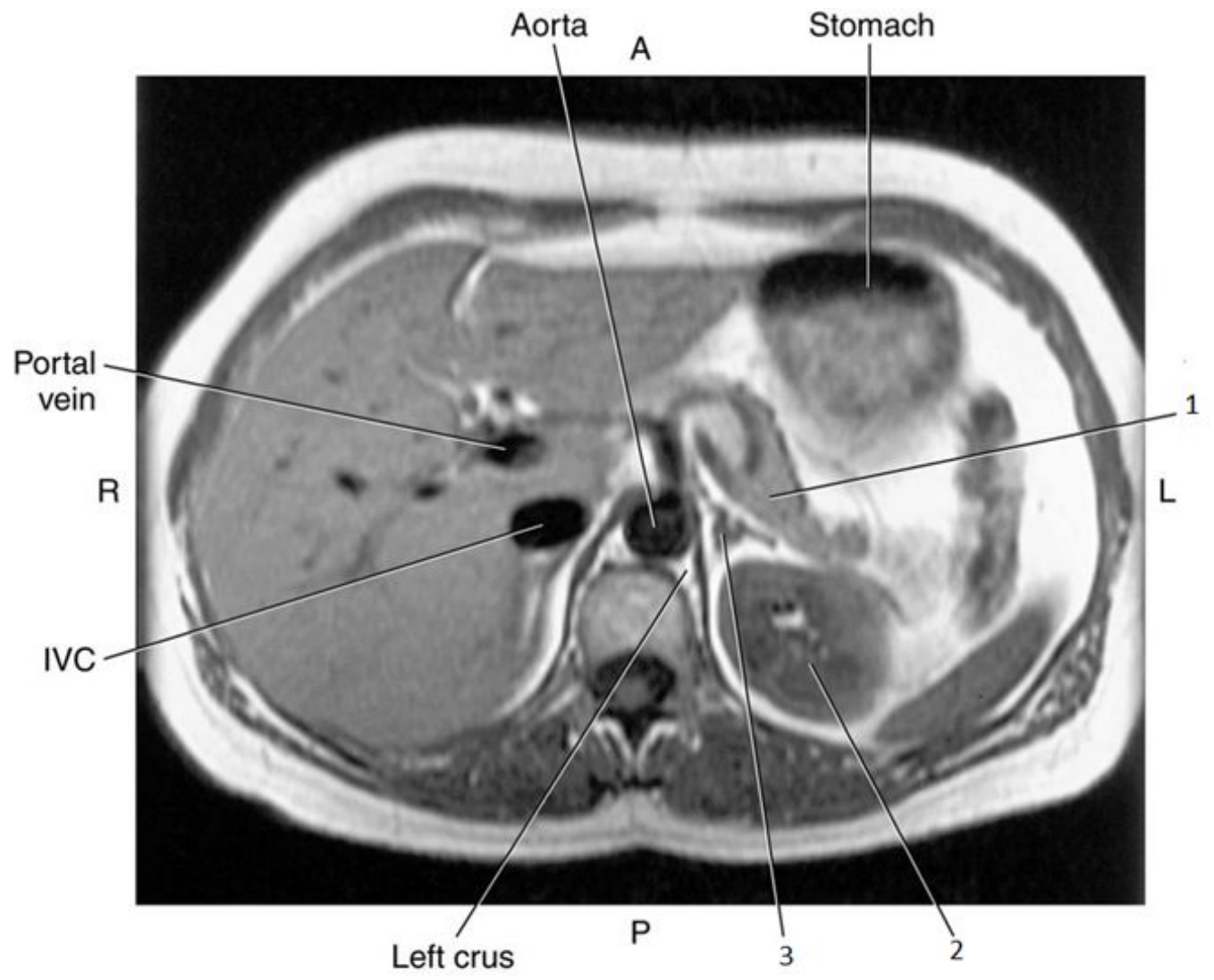


6

- Gallbladder

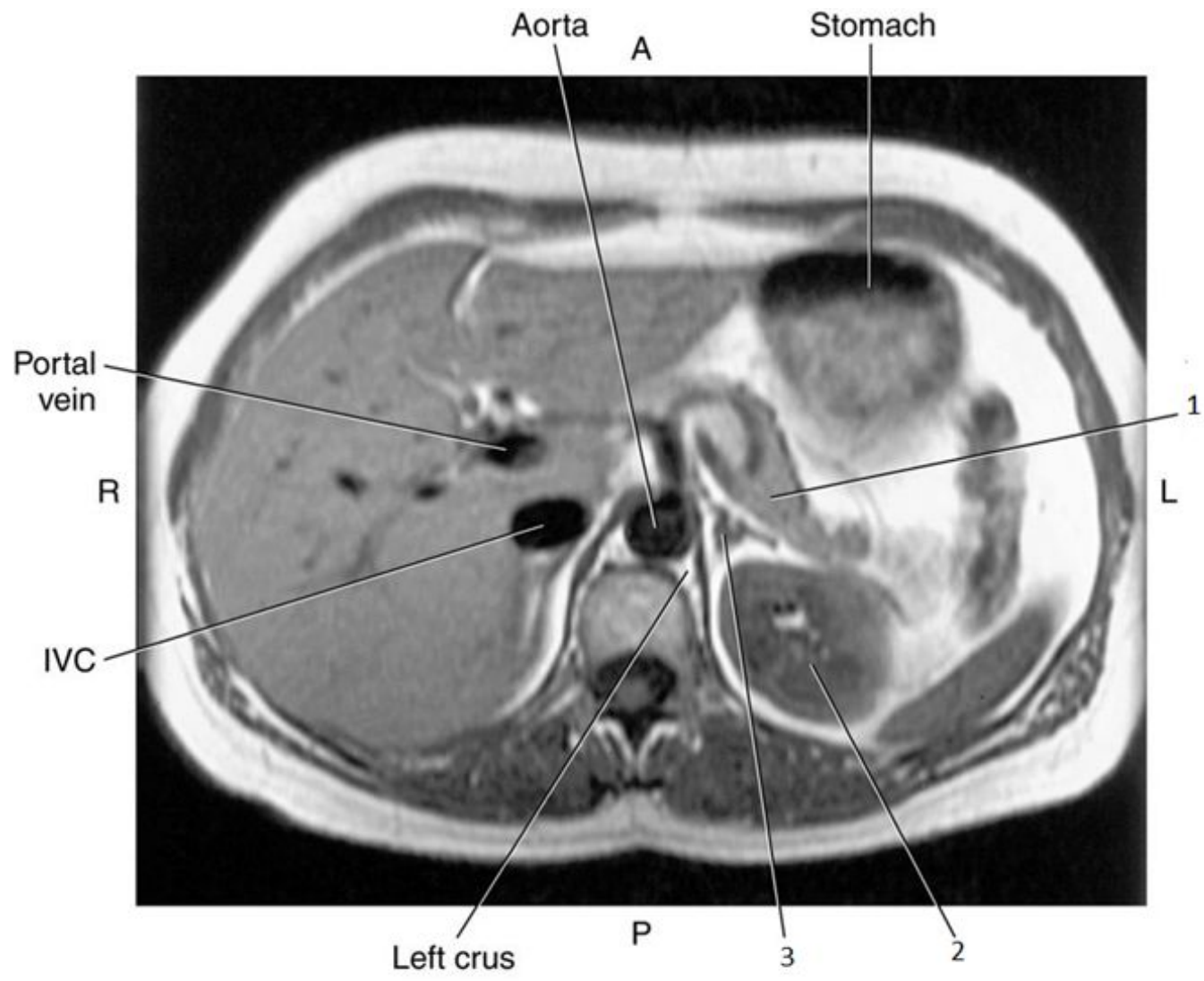


1

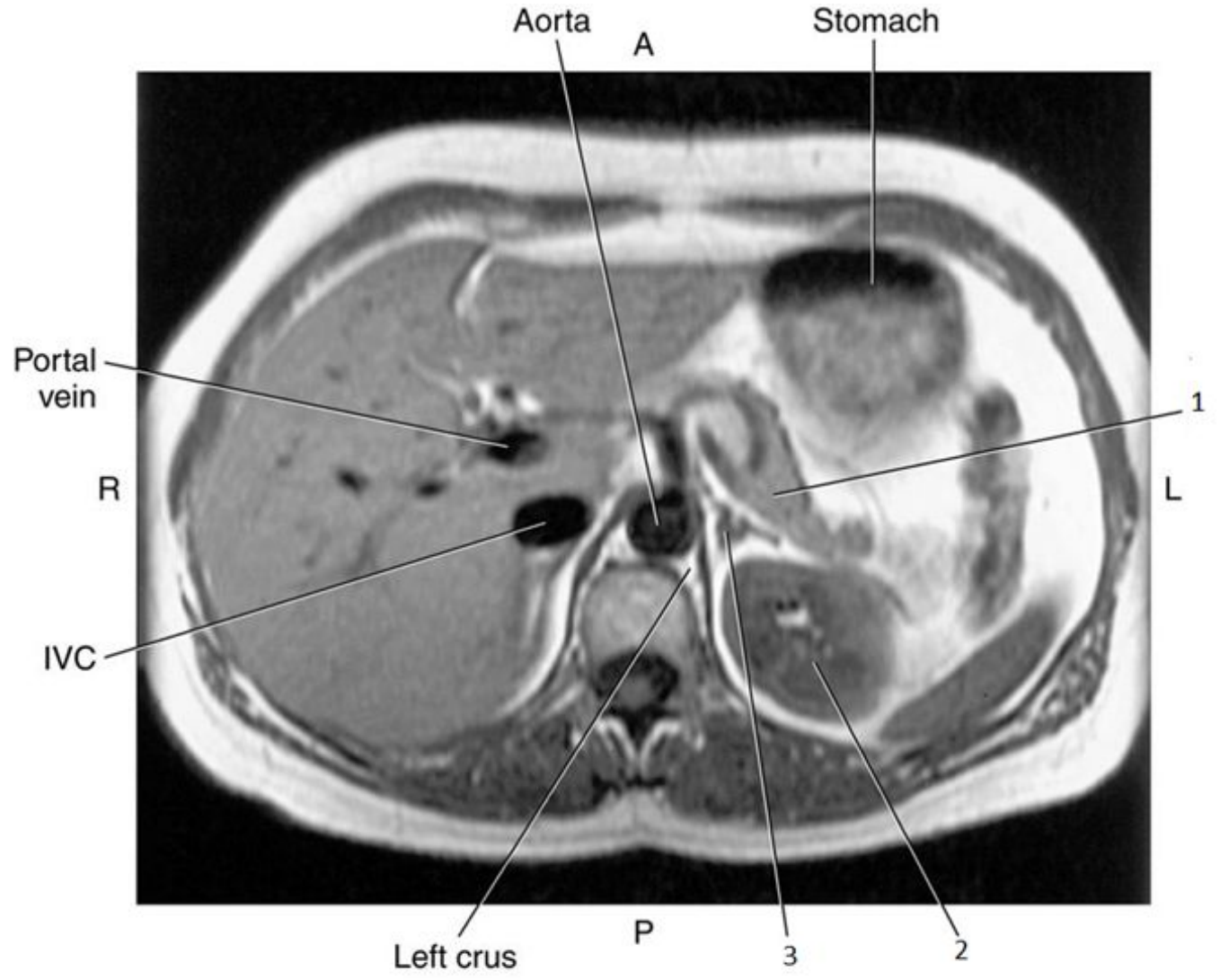


1

- Pancreas

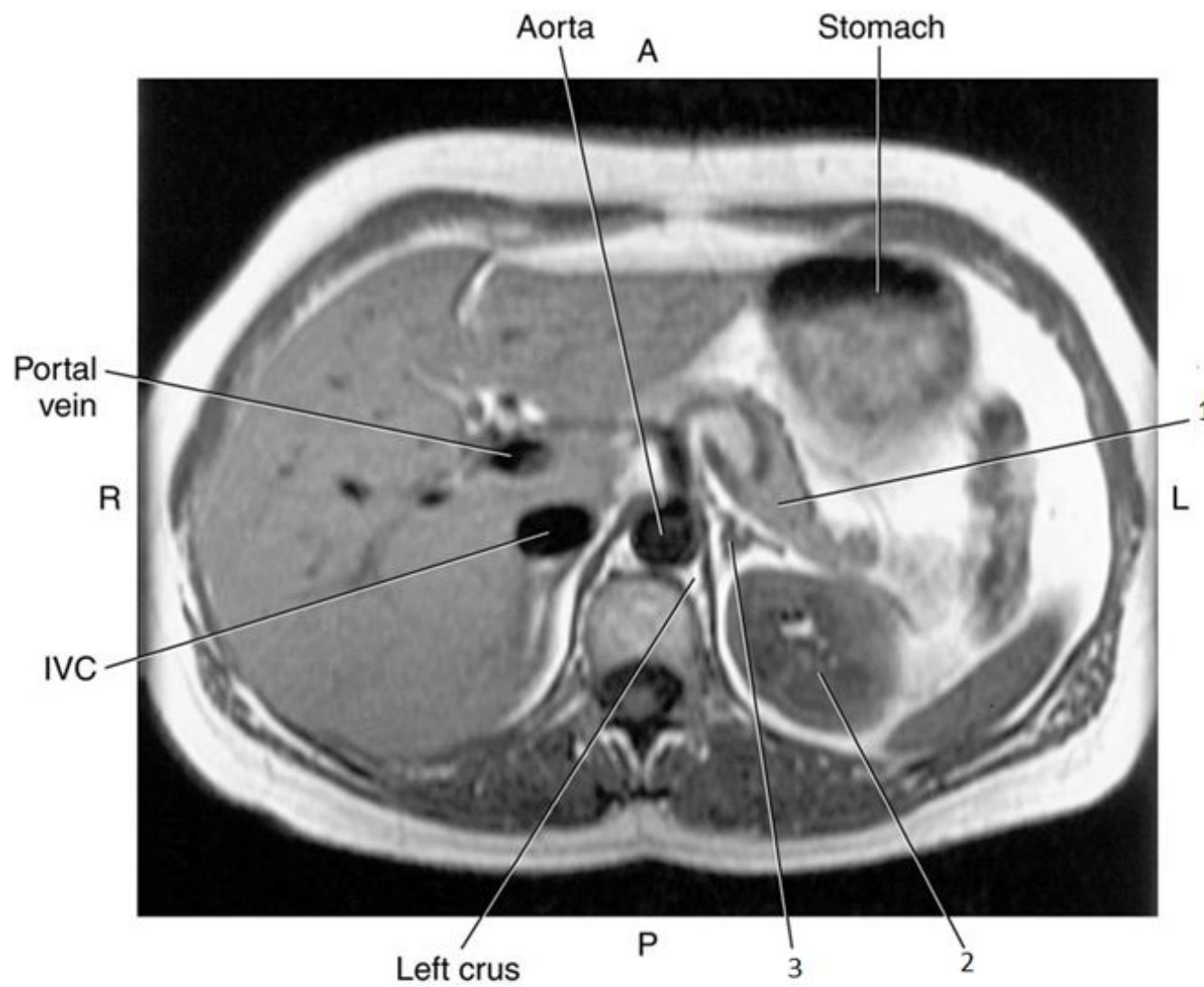

2

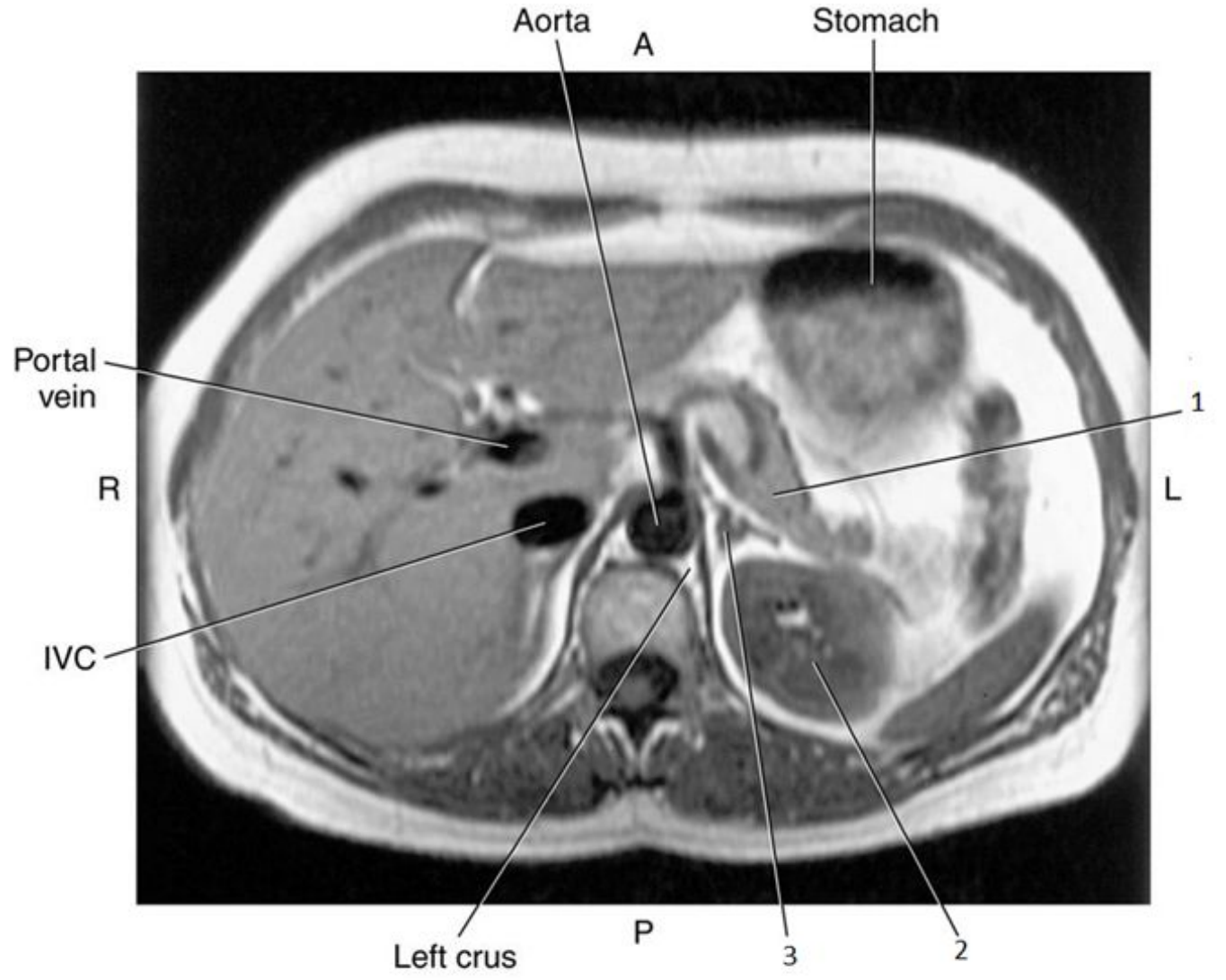


2

- Left Kidney

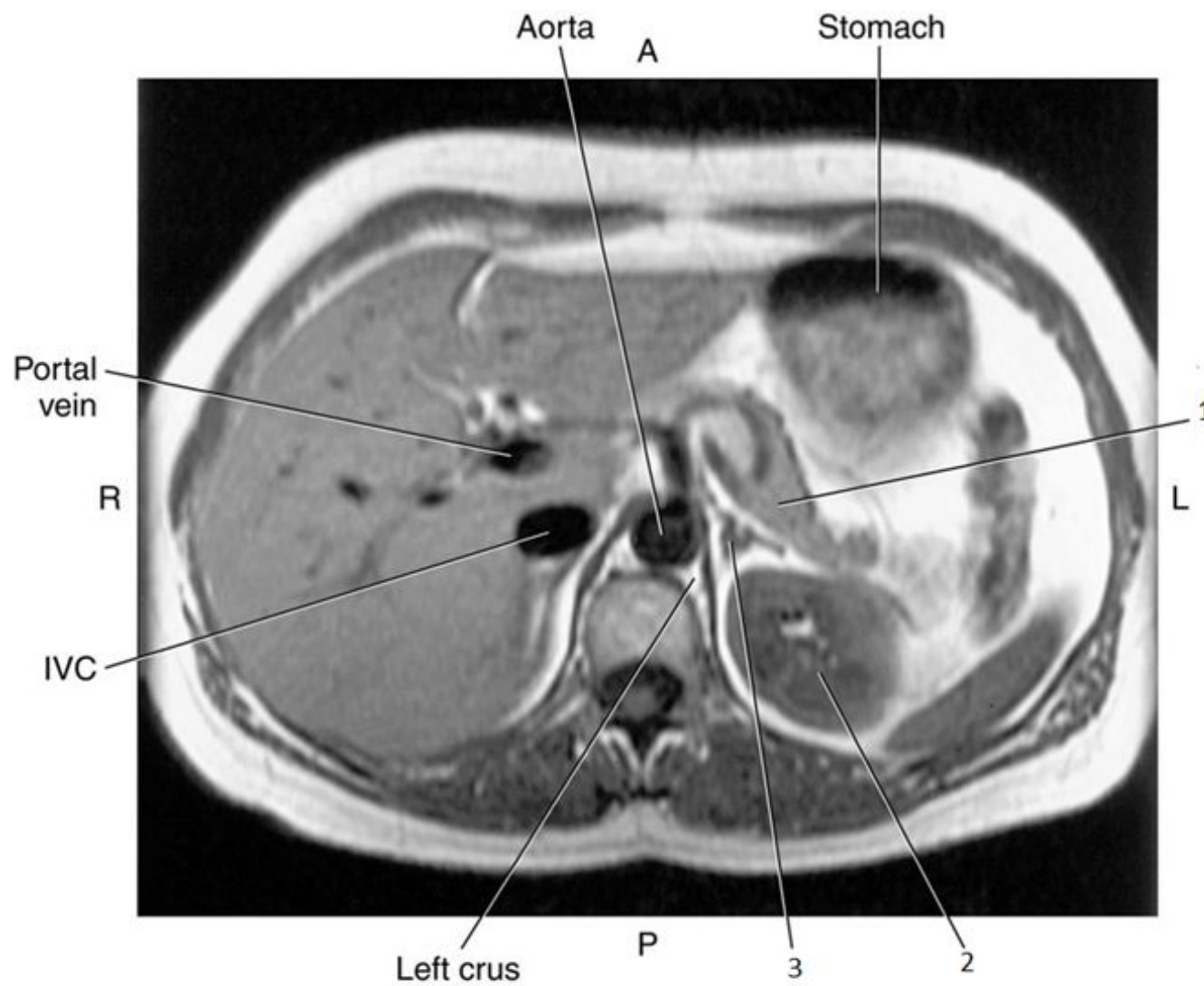

3

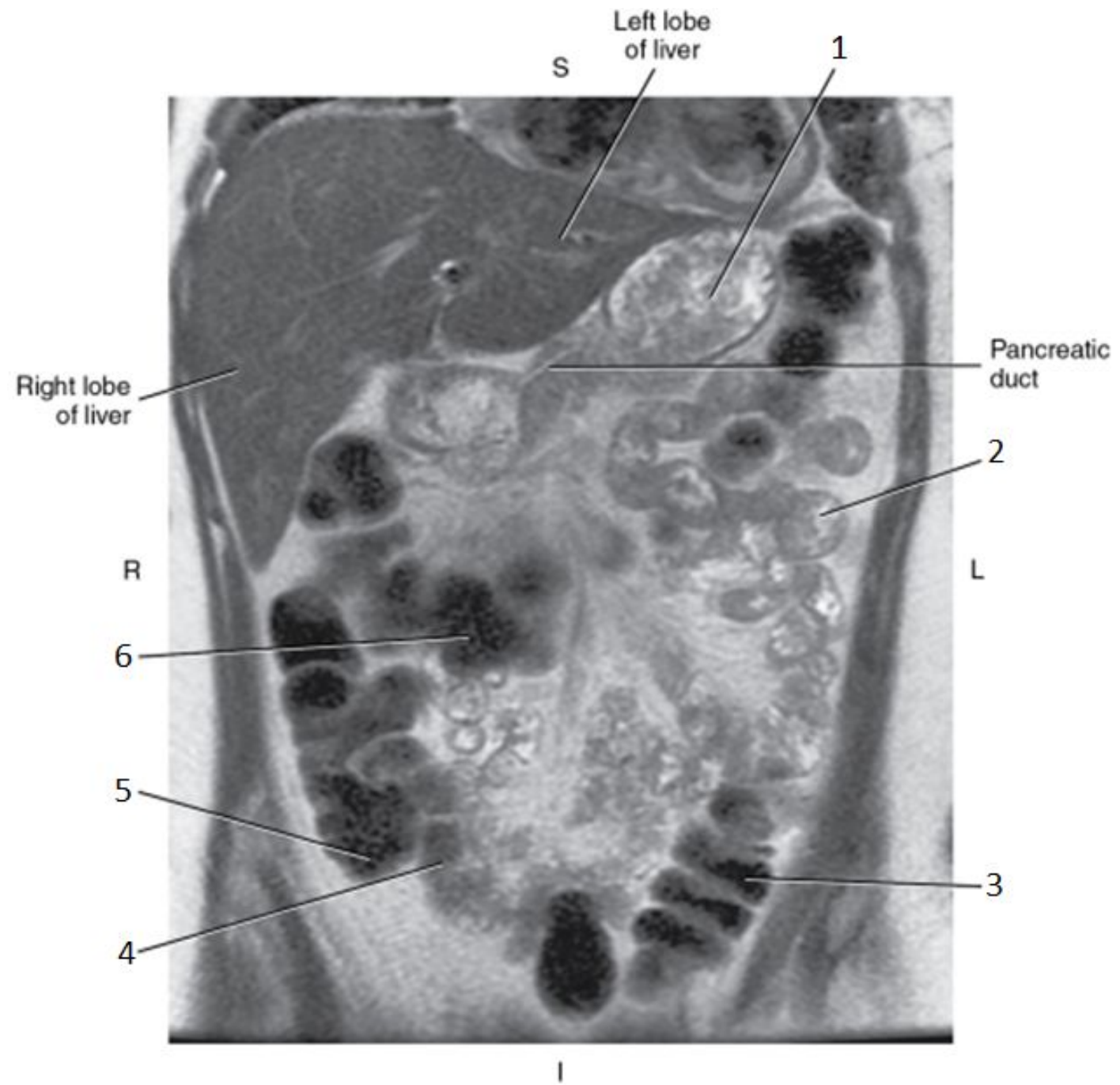


3

- Left Adrenal Gland

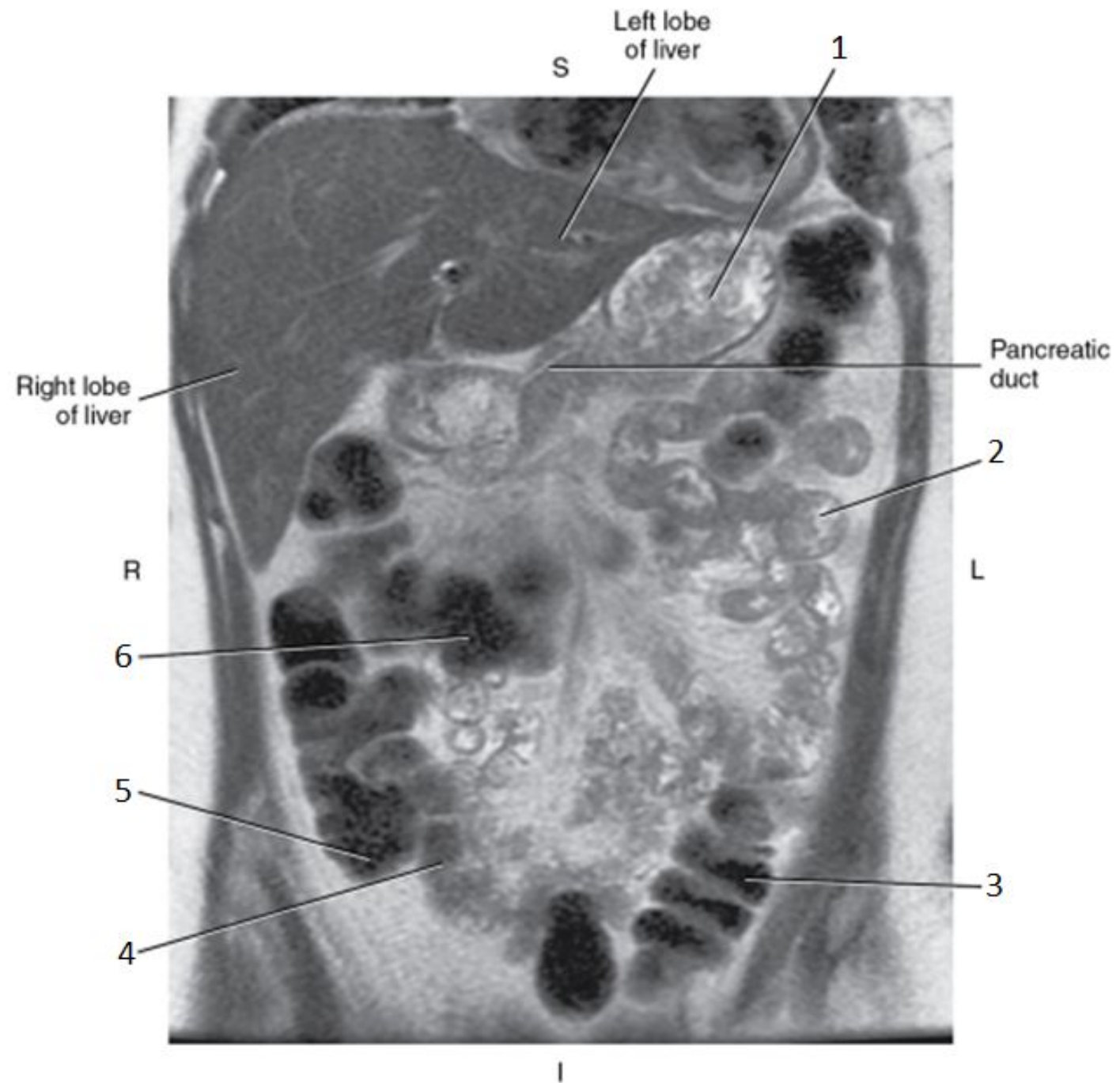


1

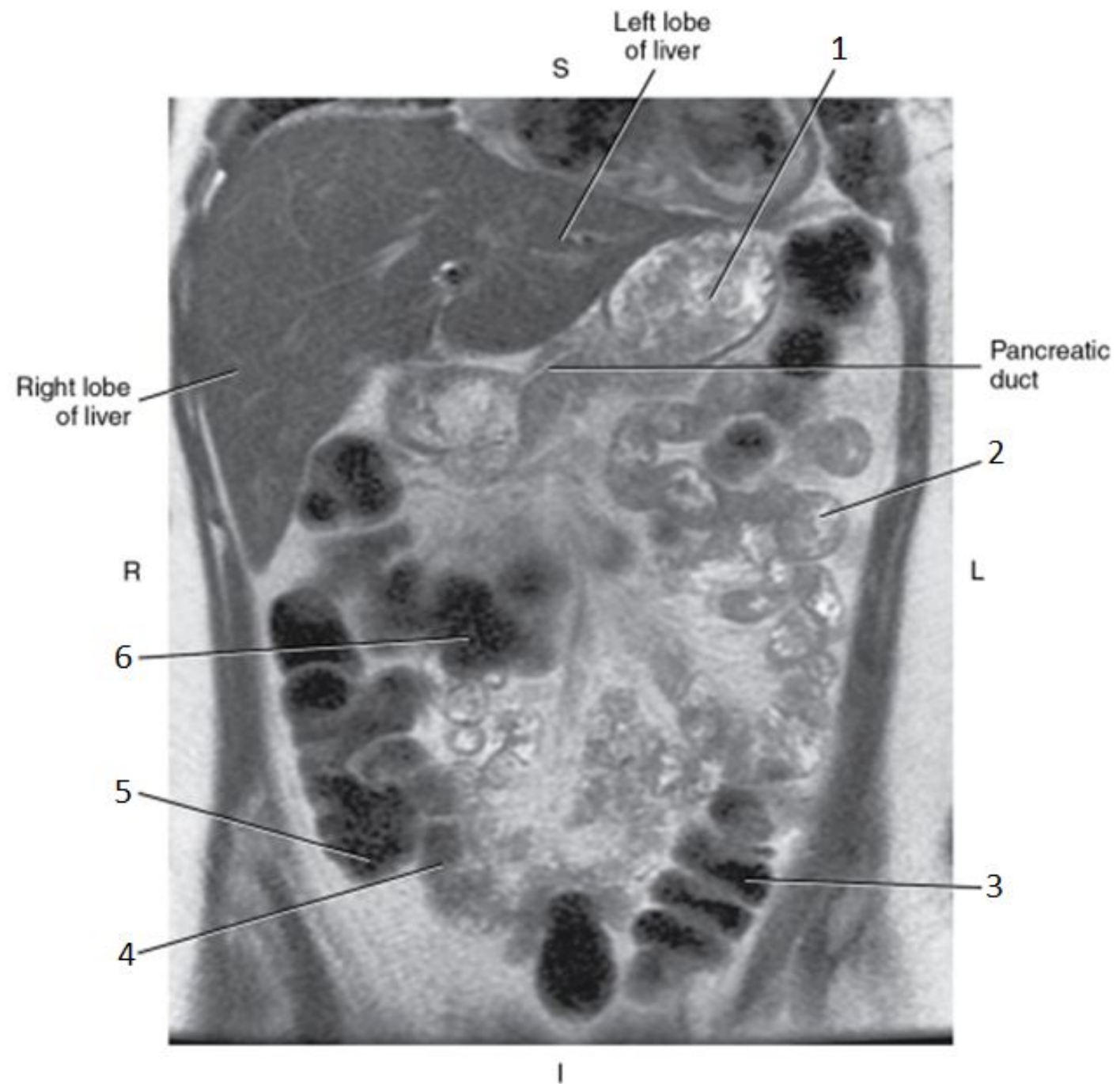


1

- Stomach

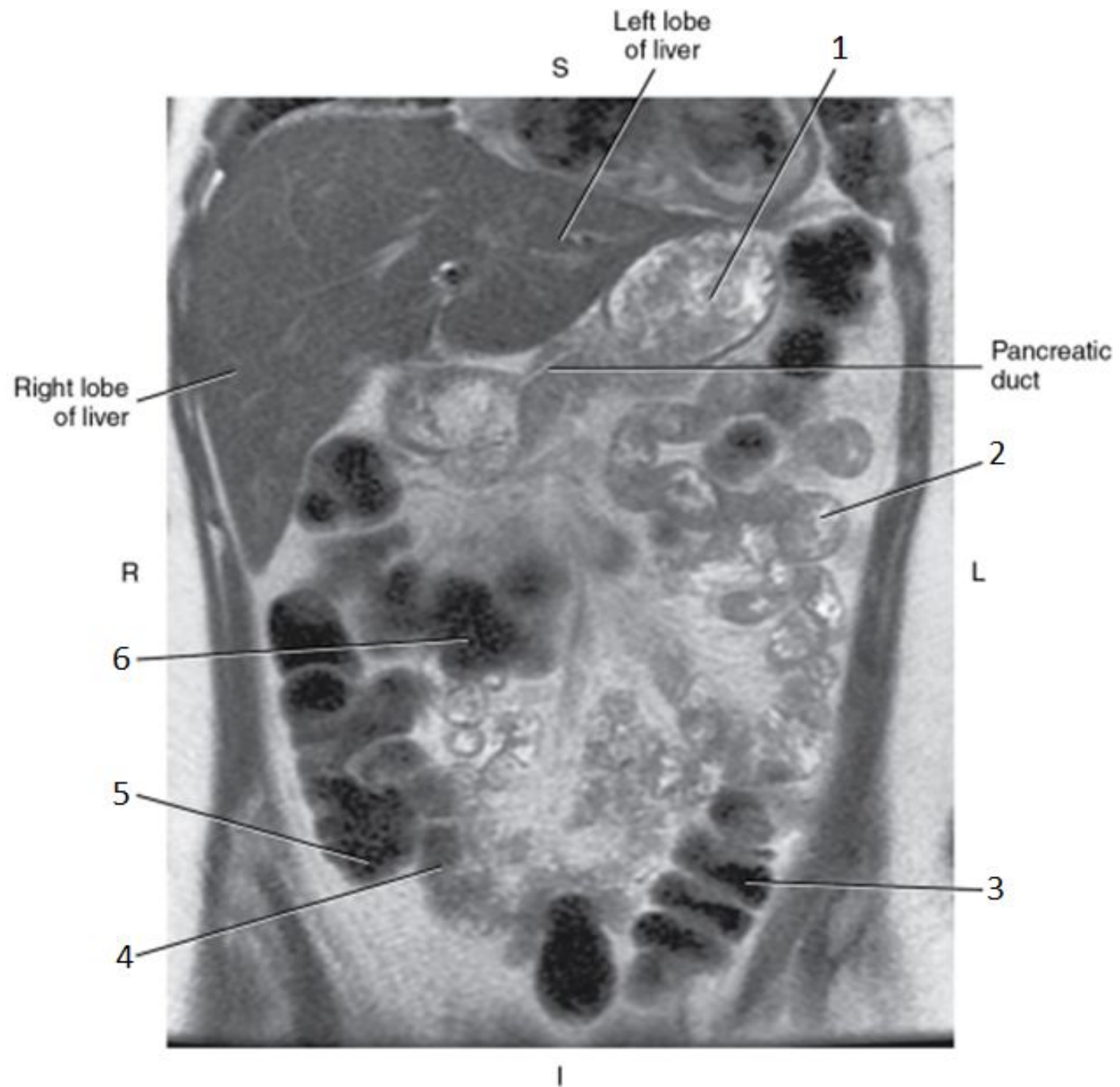


2

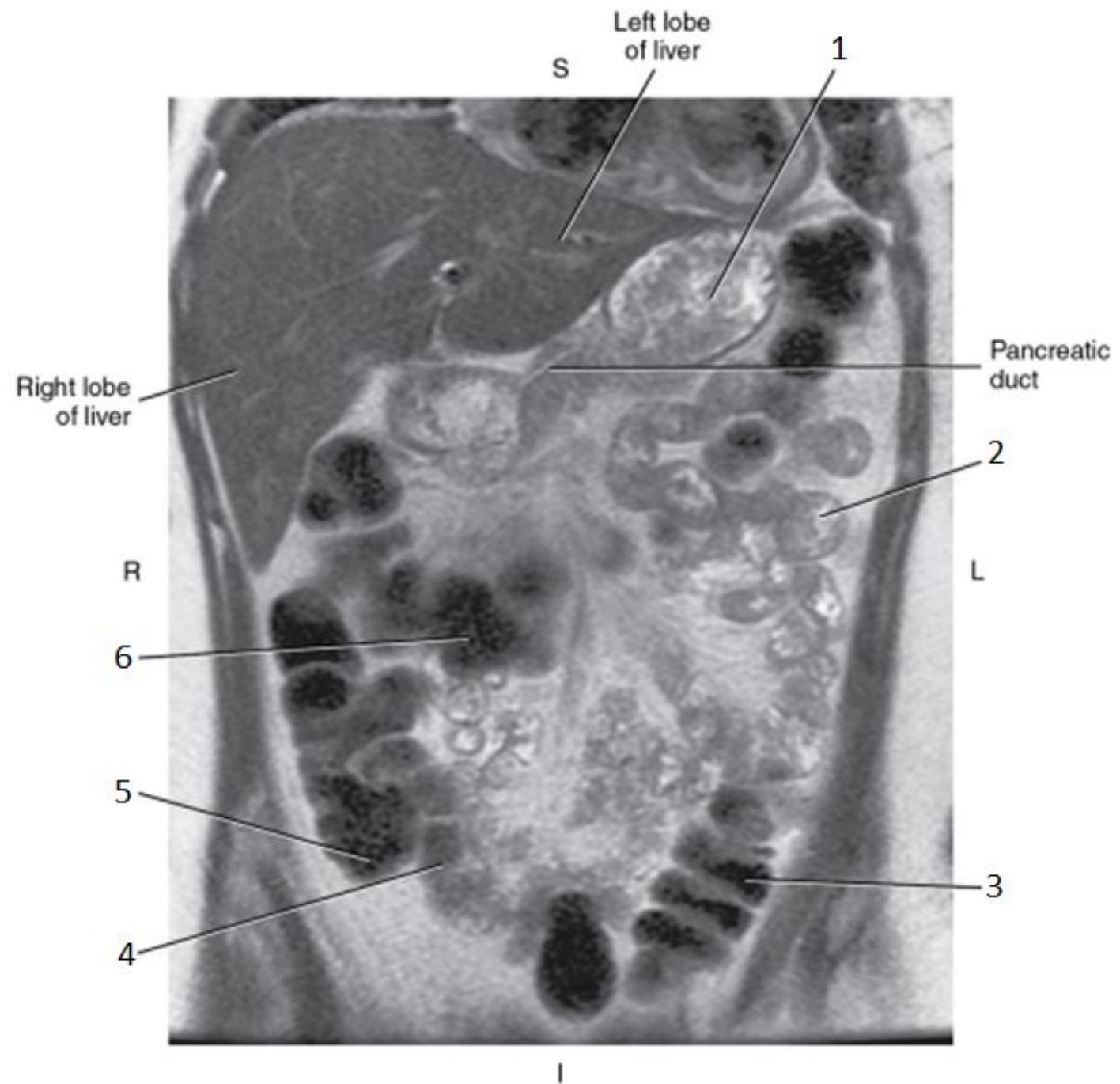


2

- Jejunum

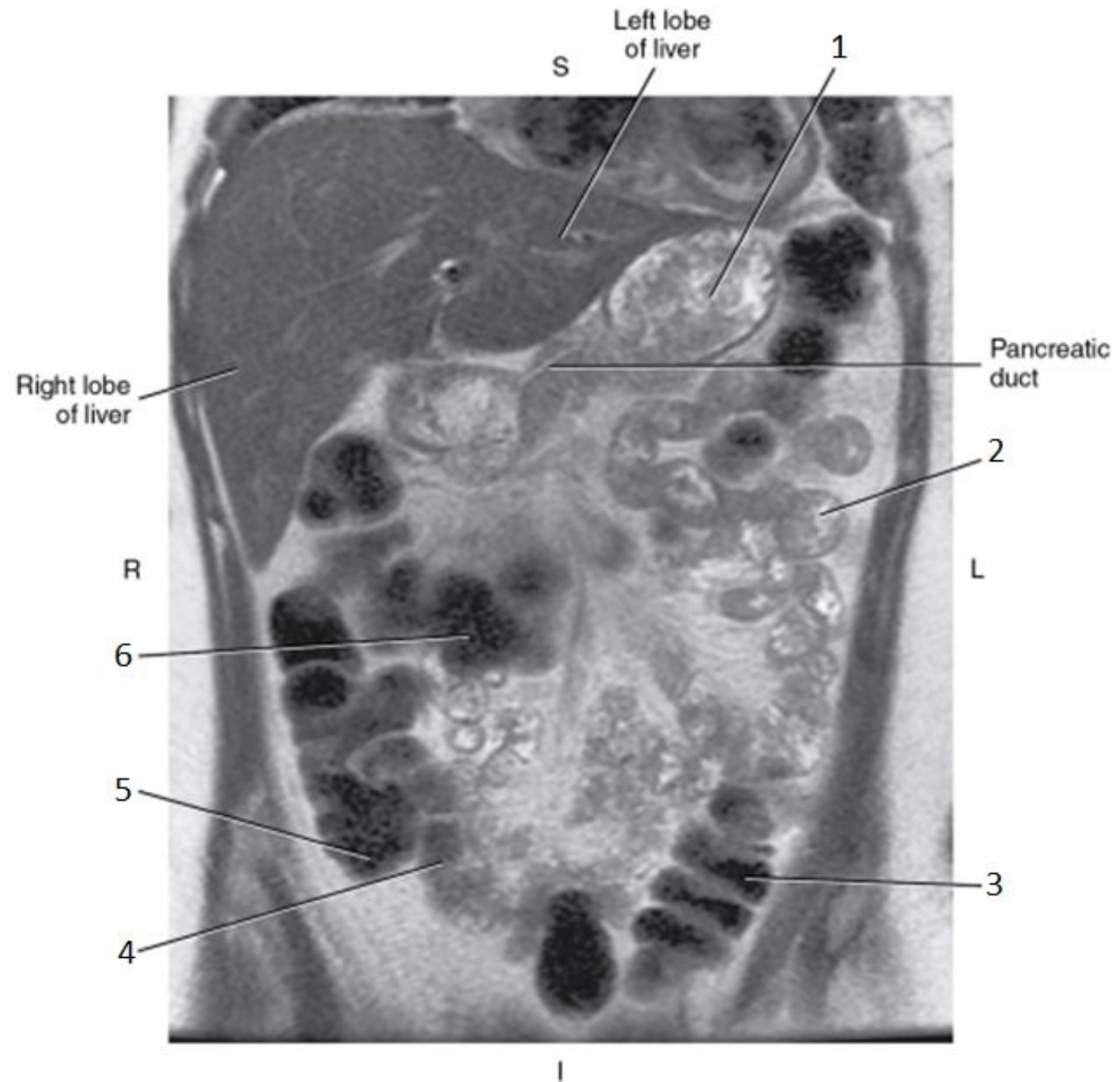


3

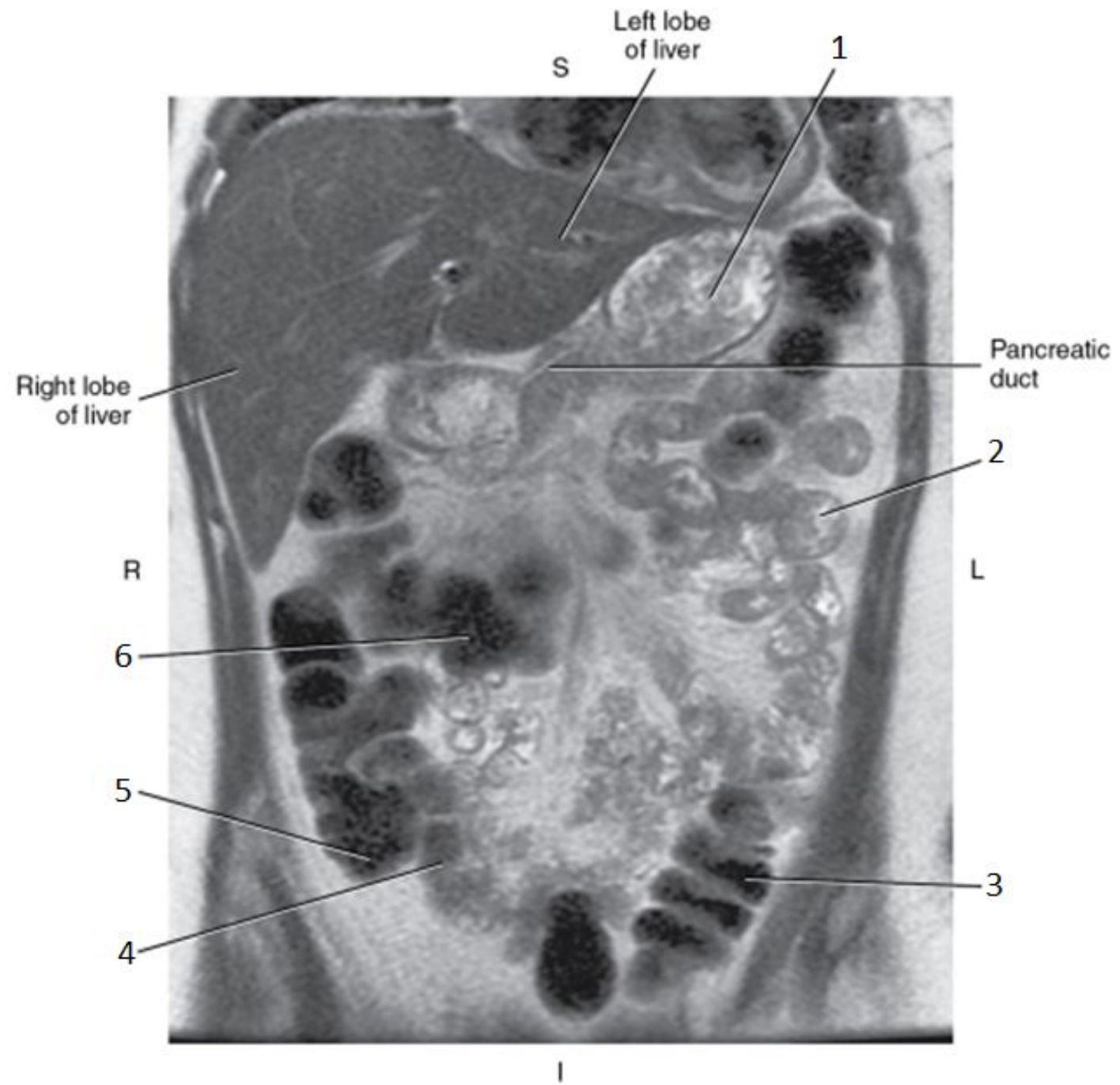


3

- Descending Colon

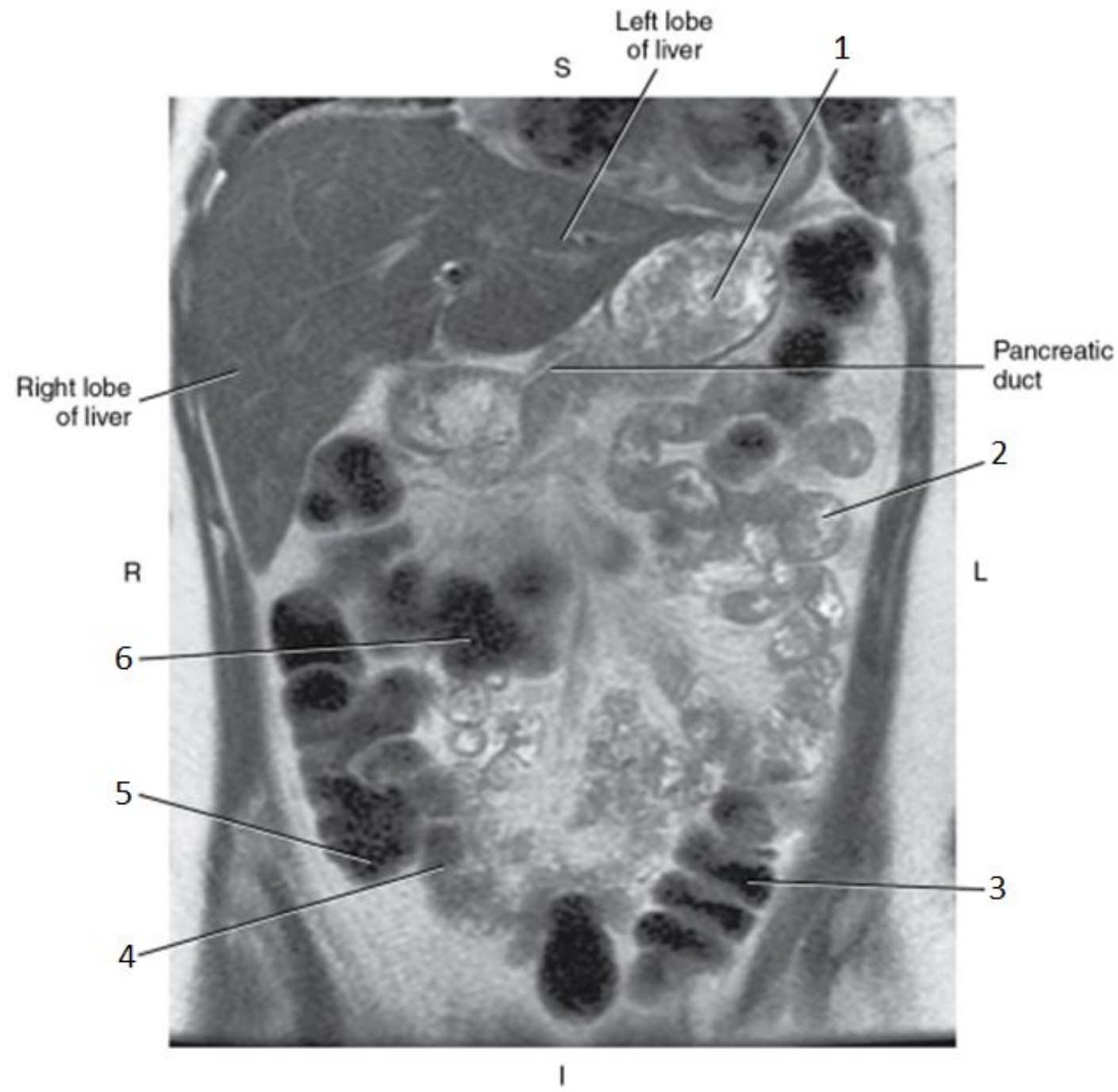


4

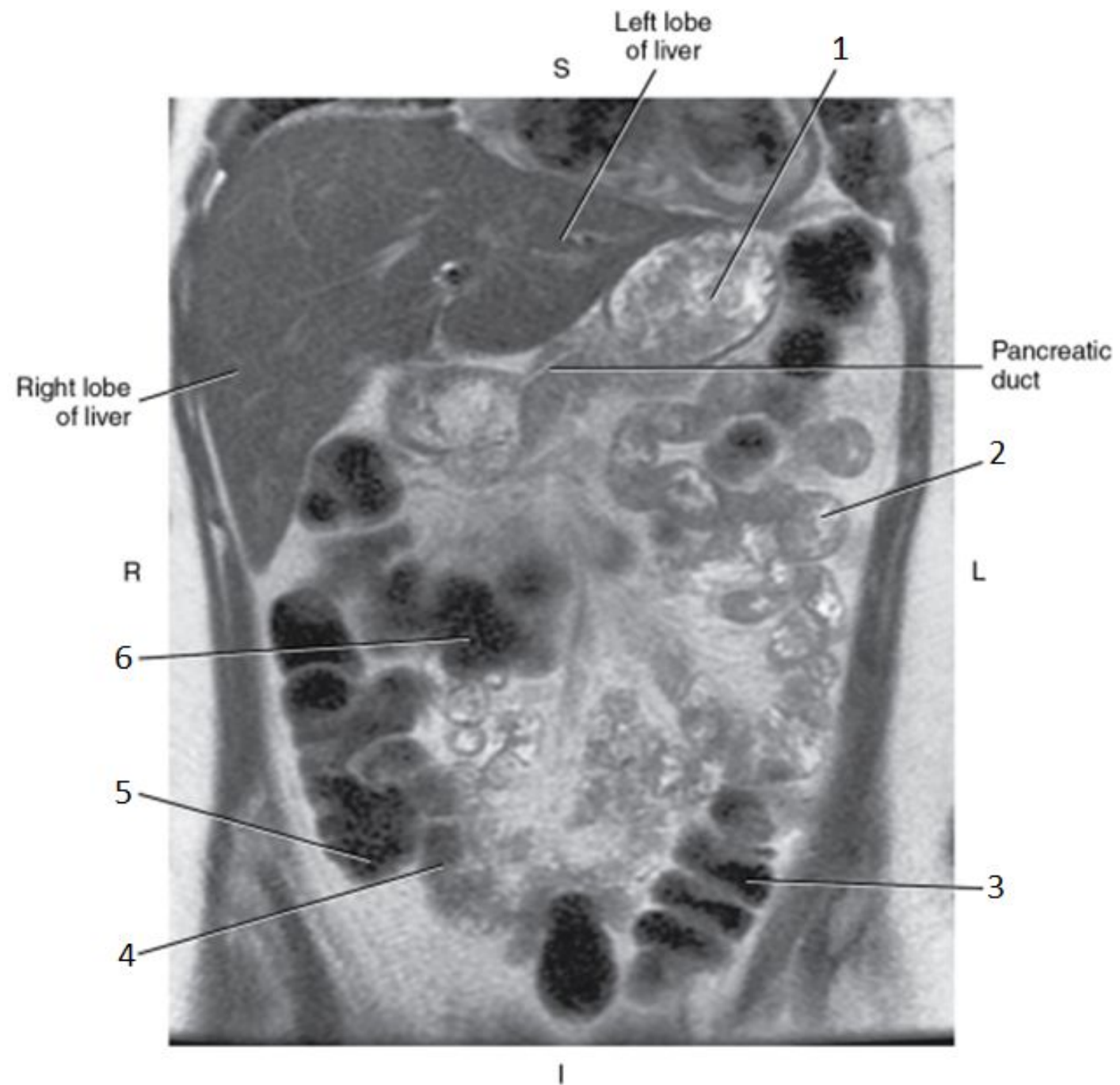


4

- Ileum

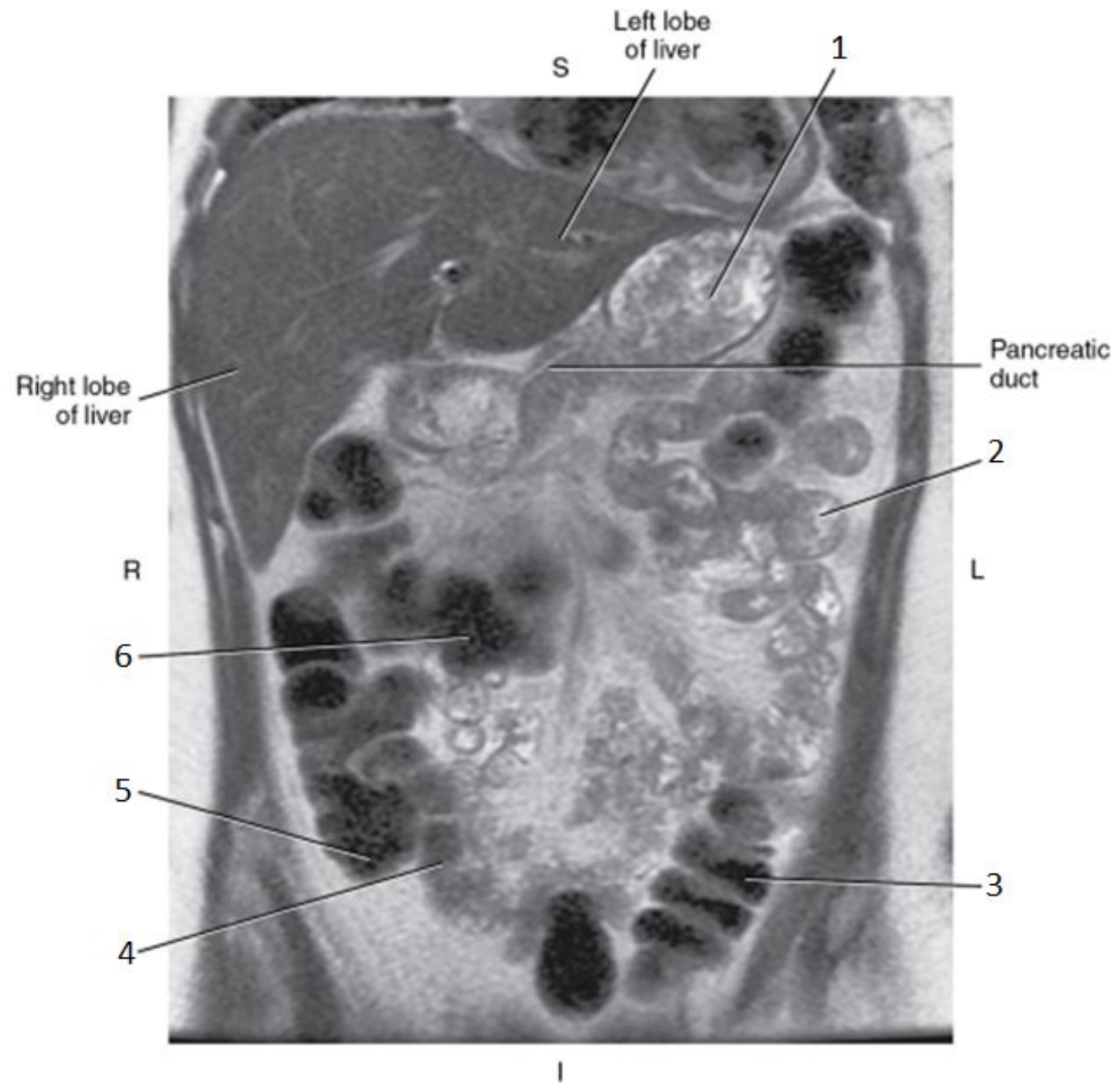


5

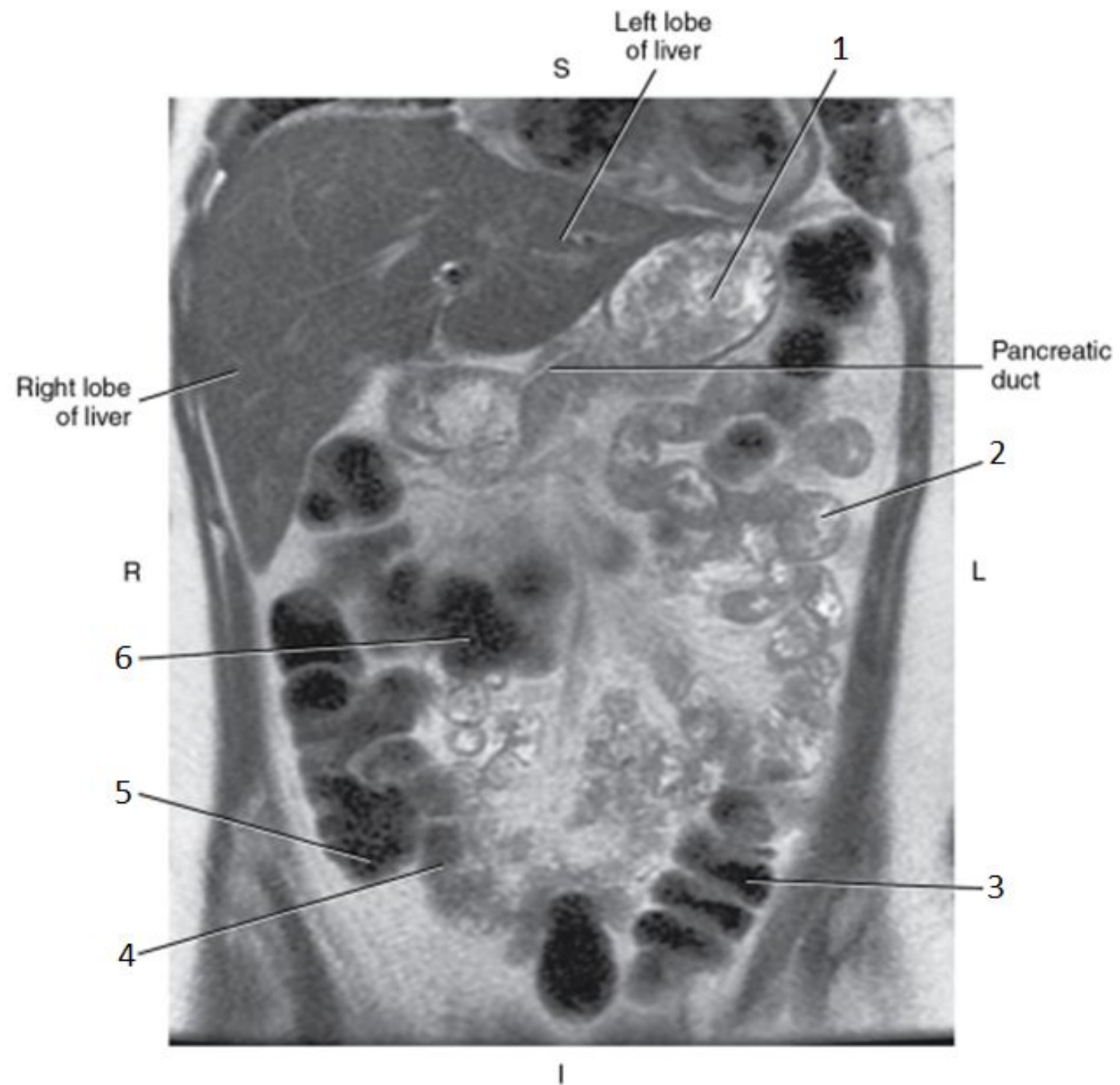


5

- Cecum

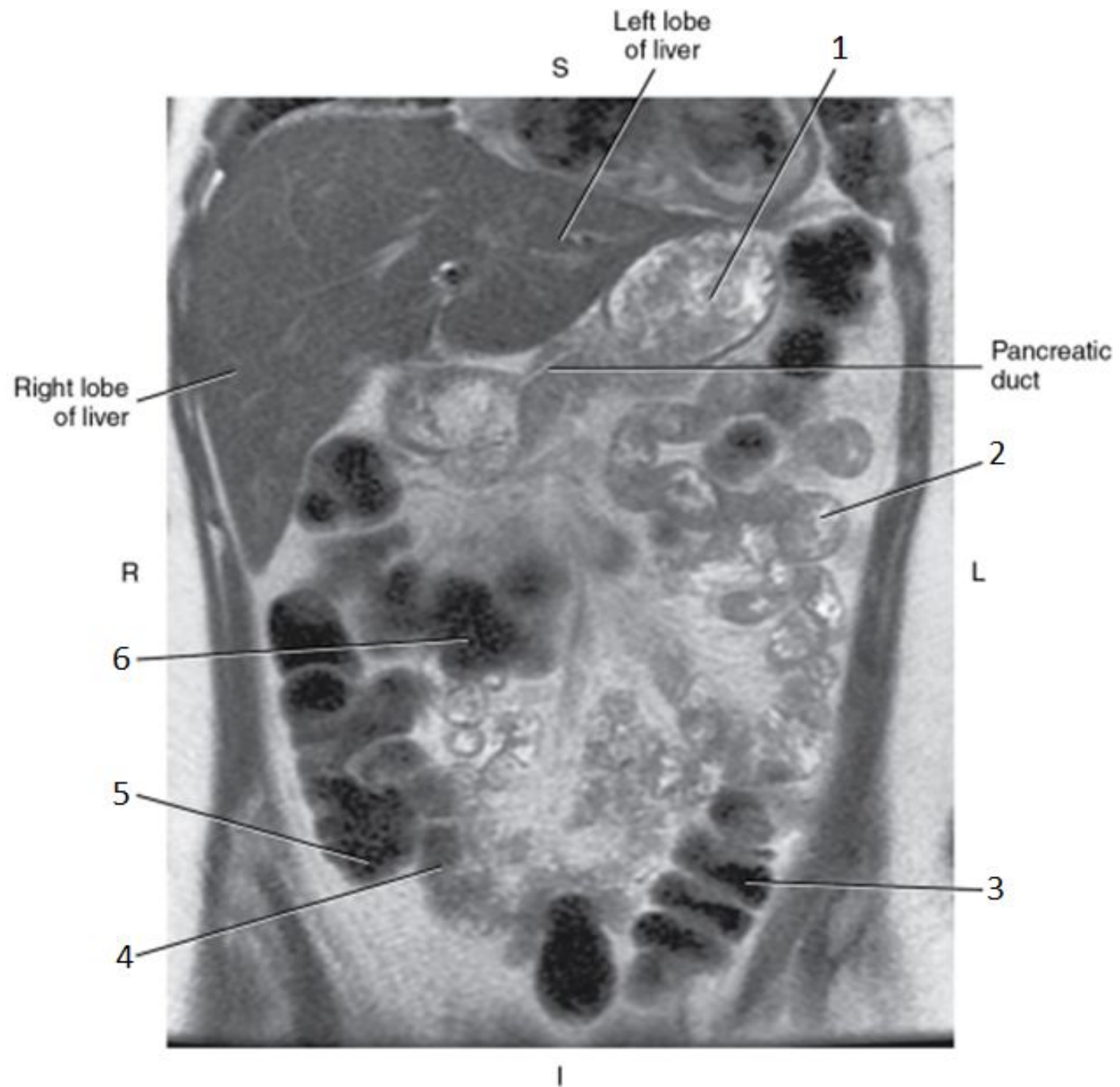


6

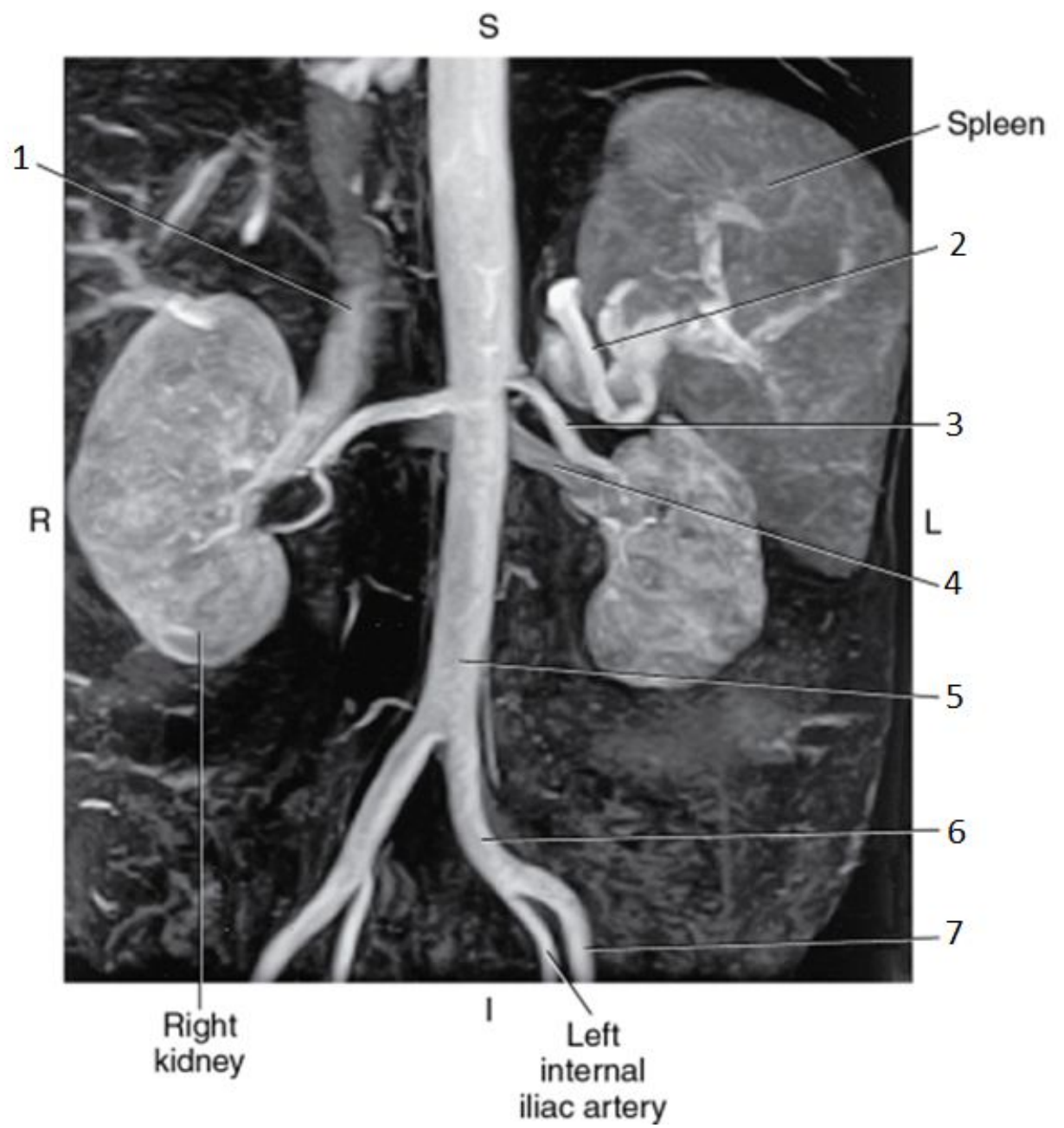


6

- Transverse Colon

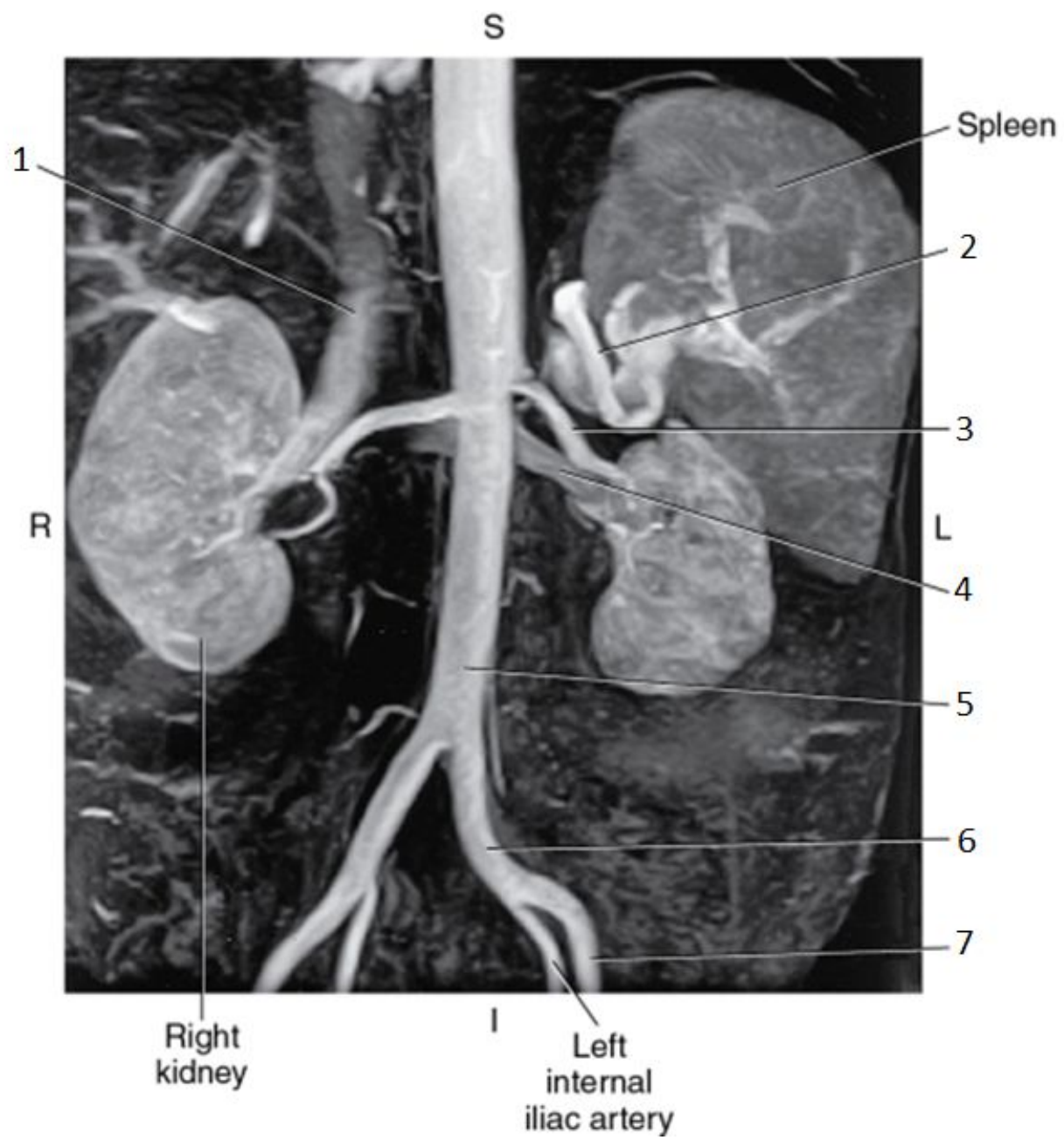


1

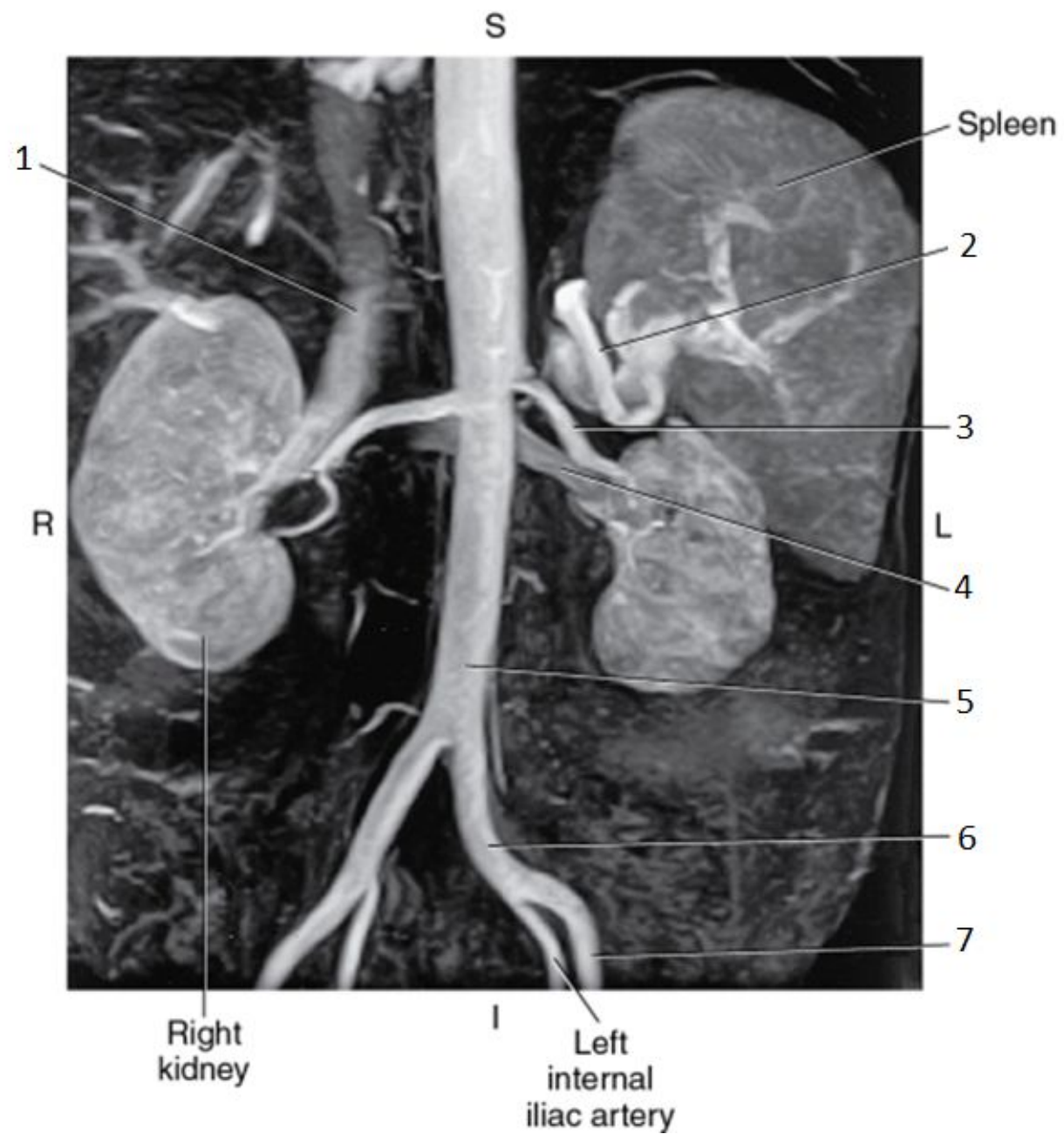


1

- Inferior Vena Cava (IVC)

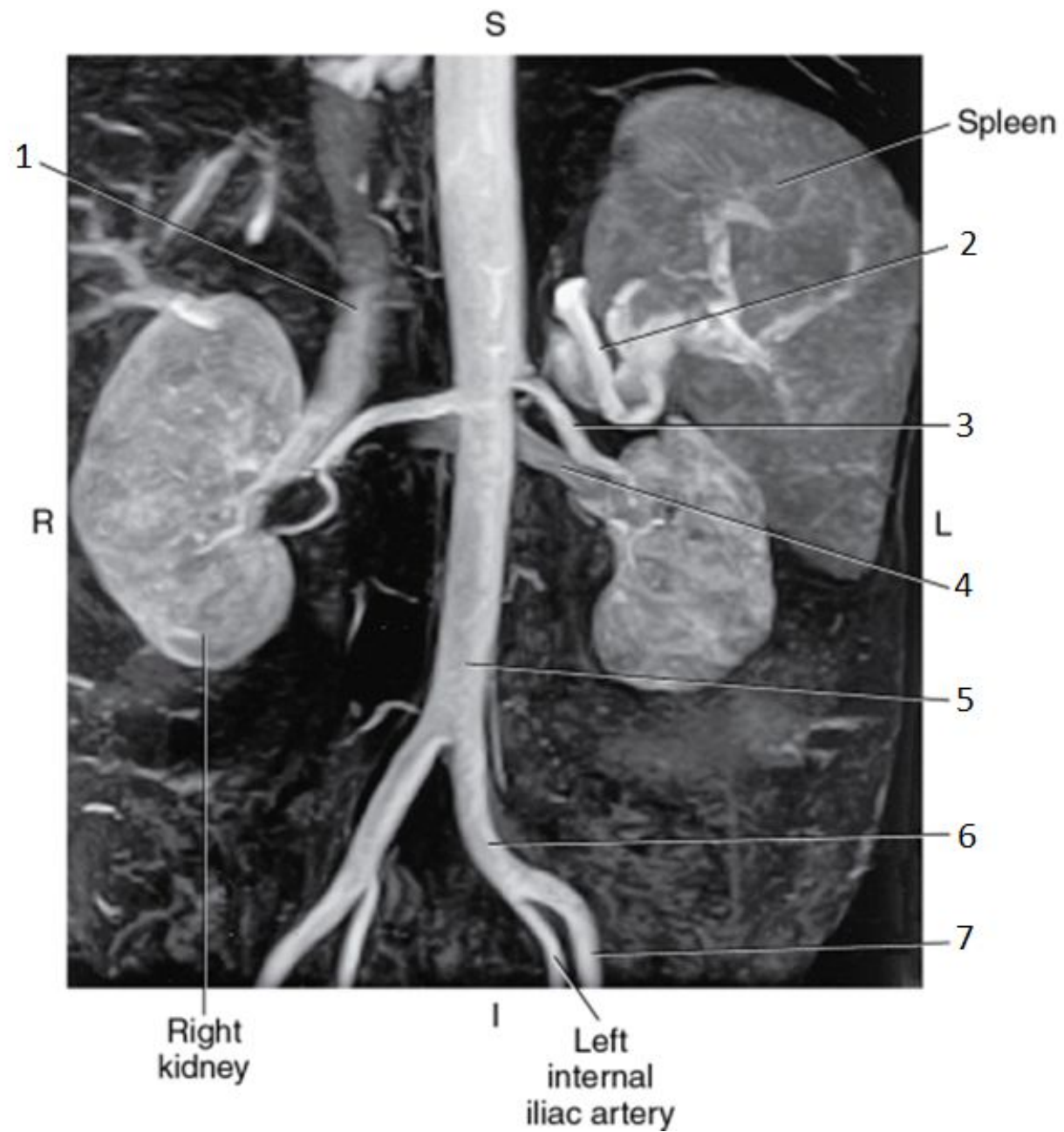


2

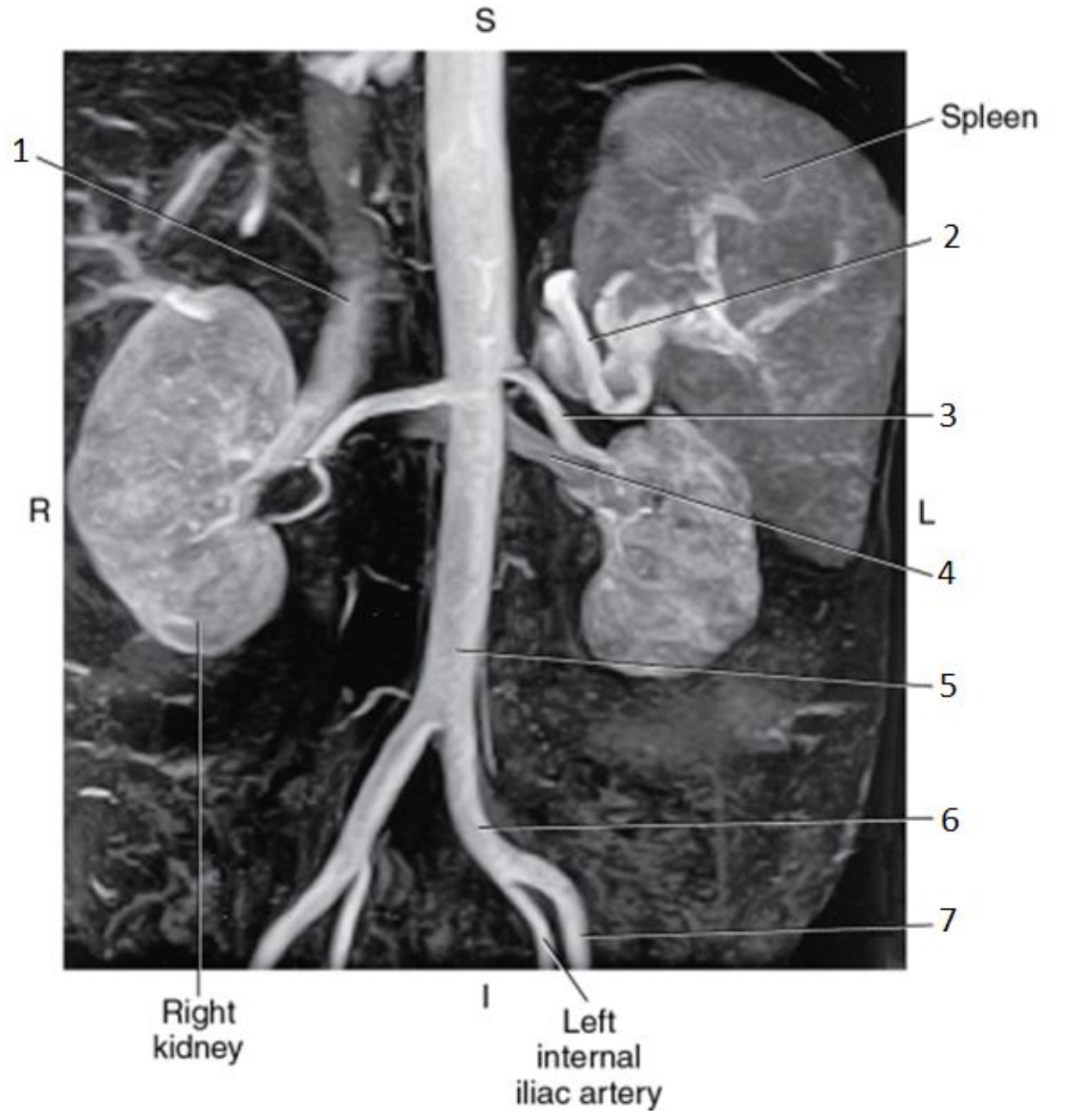


2

- Splenic Artery

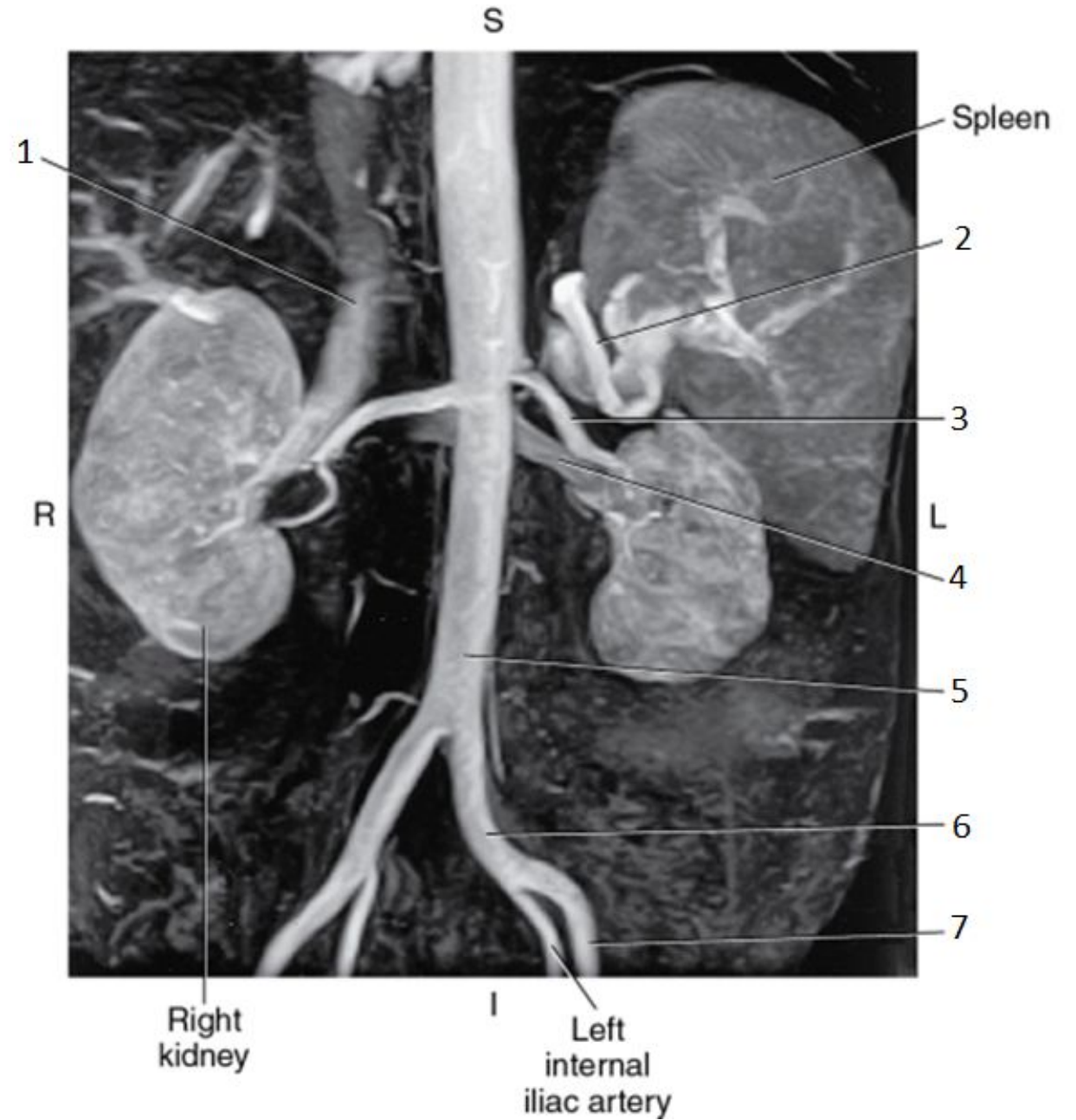


3

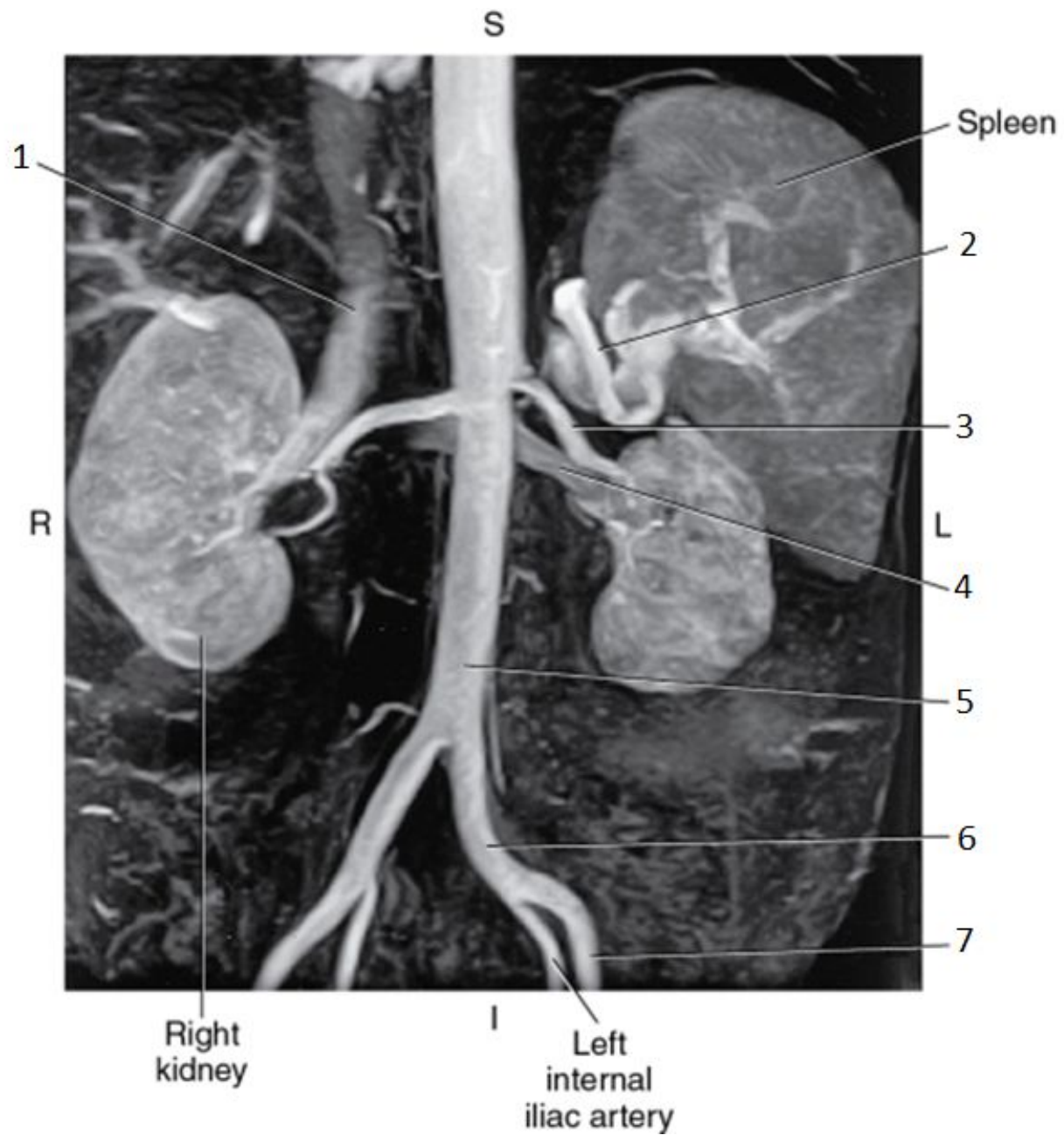


3

- Left Renal Artery

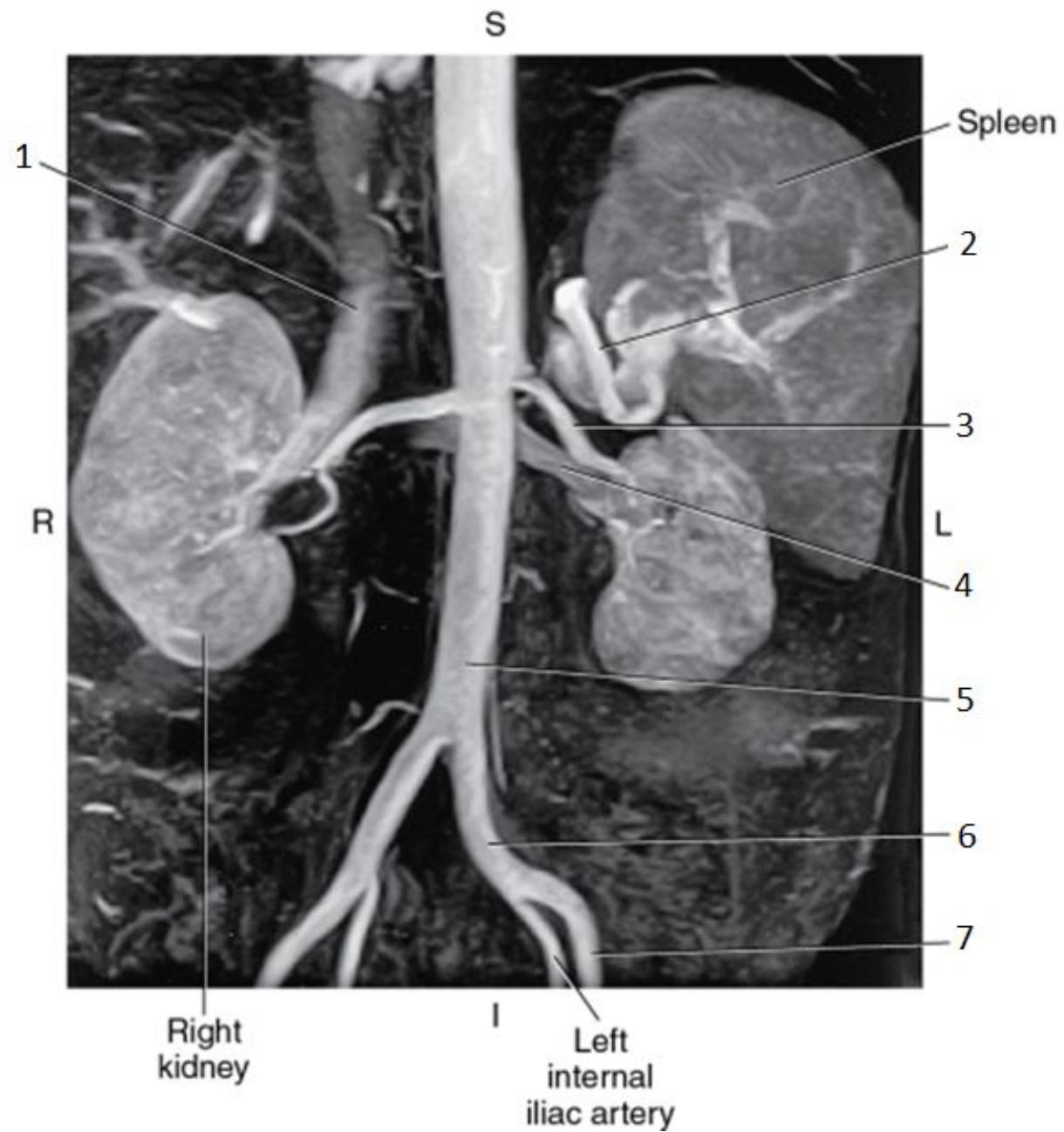


4

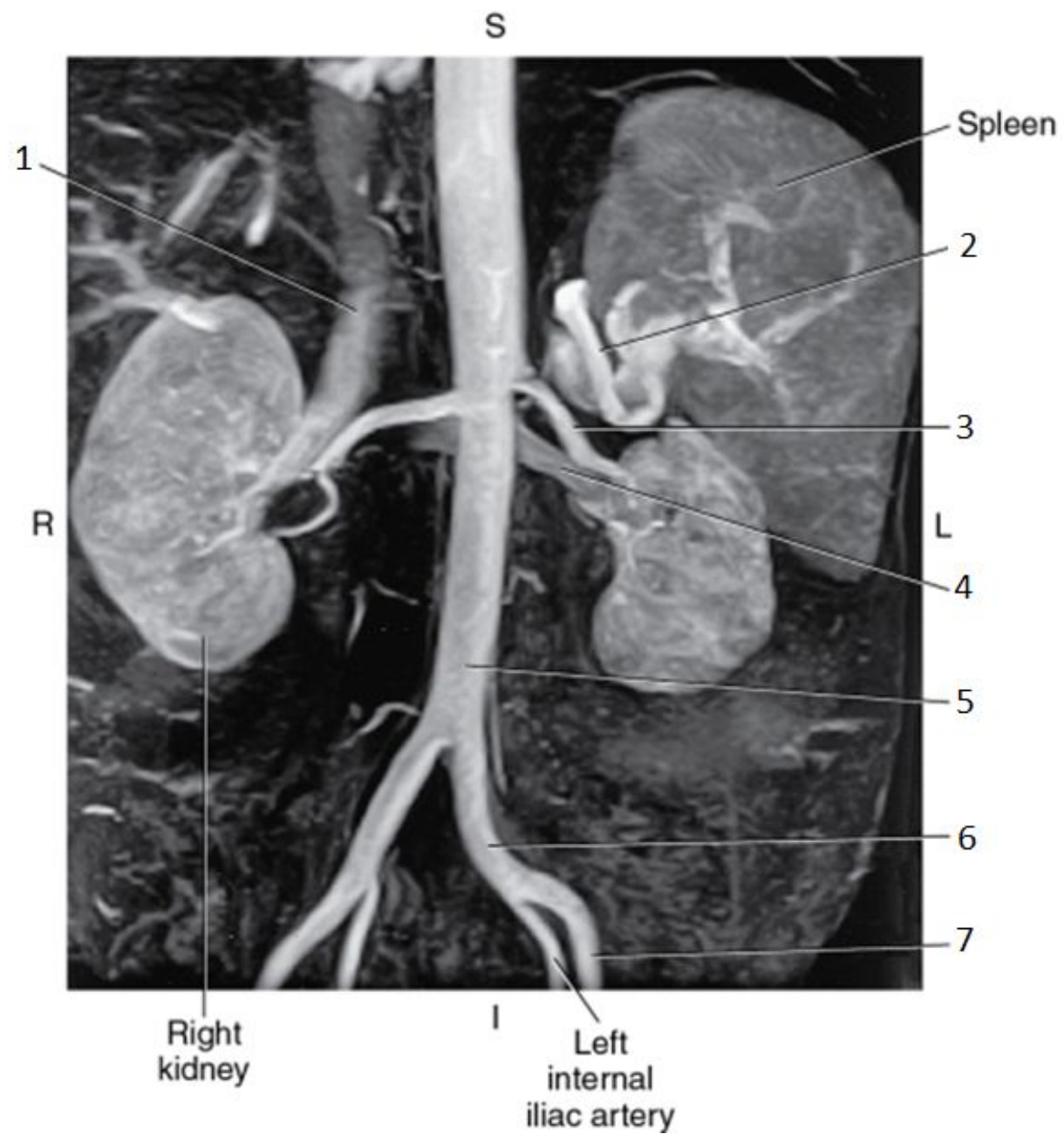


4

- Left Renal Vein

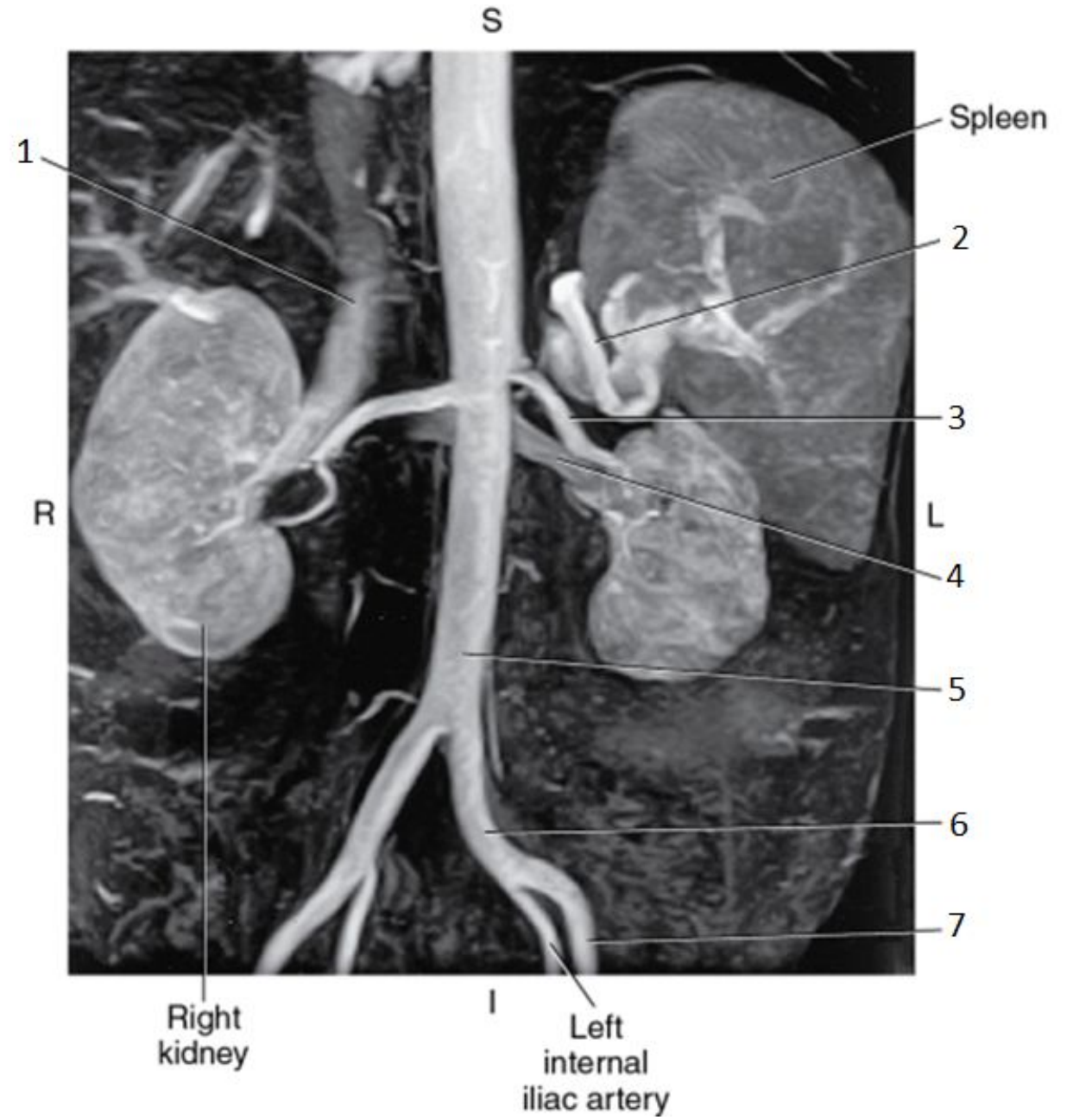


5

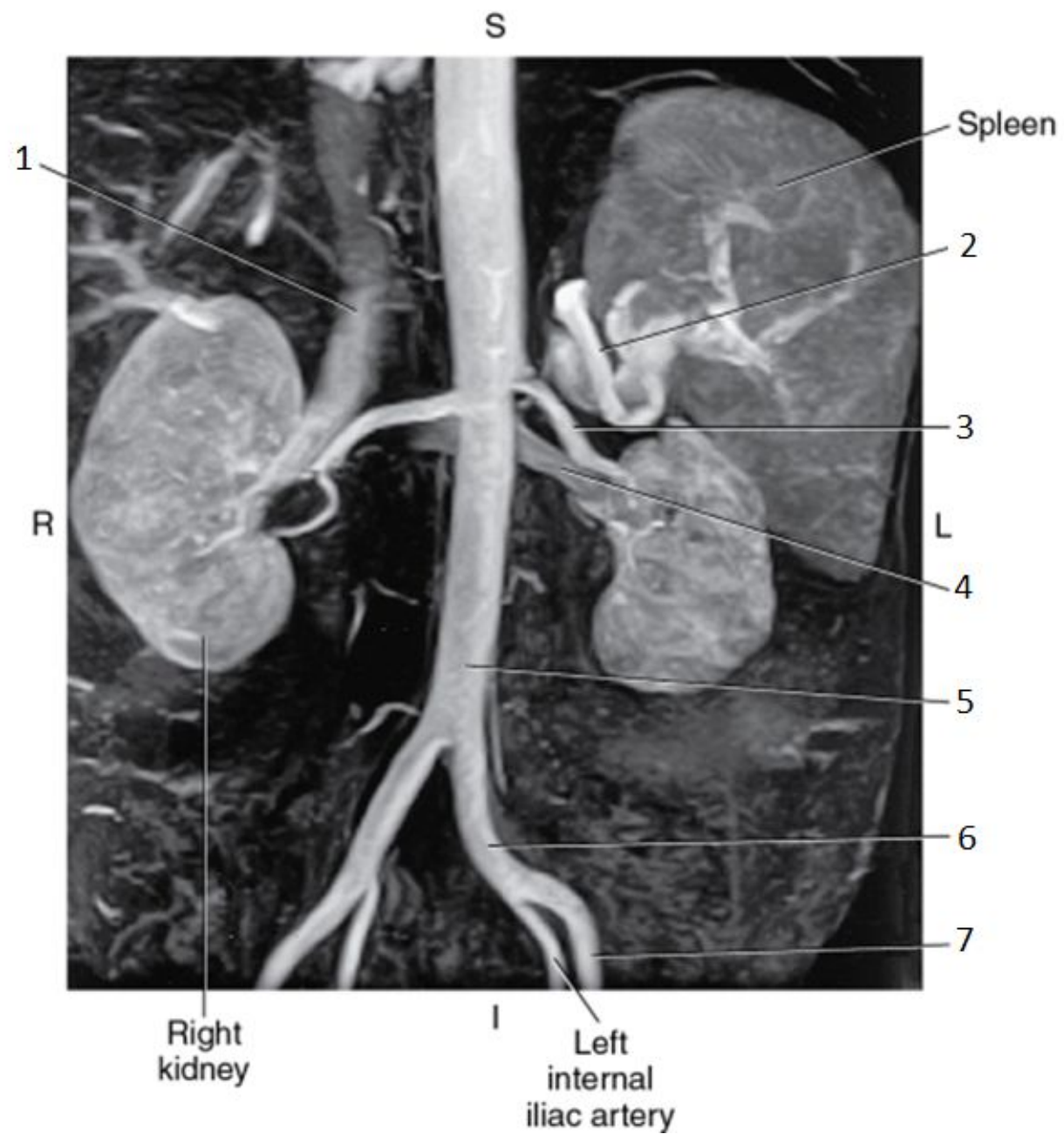


5

- Aorta

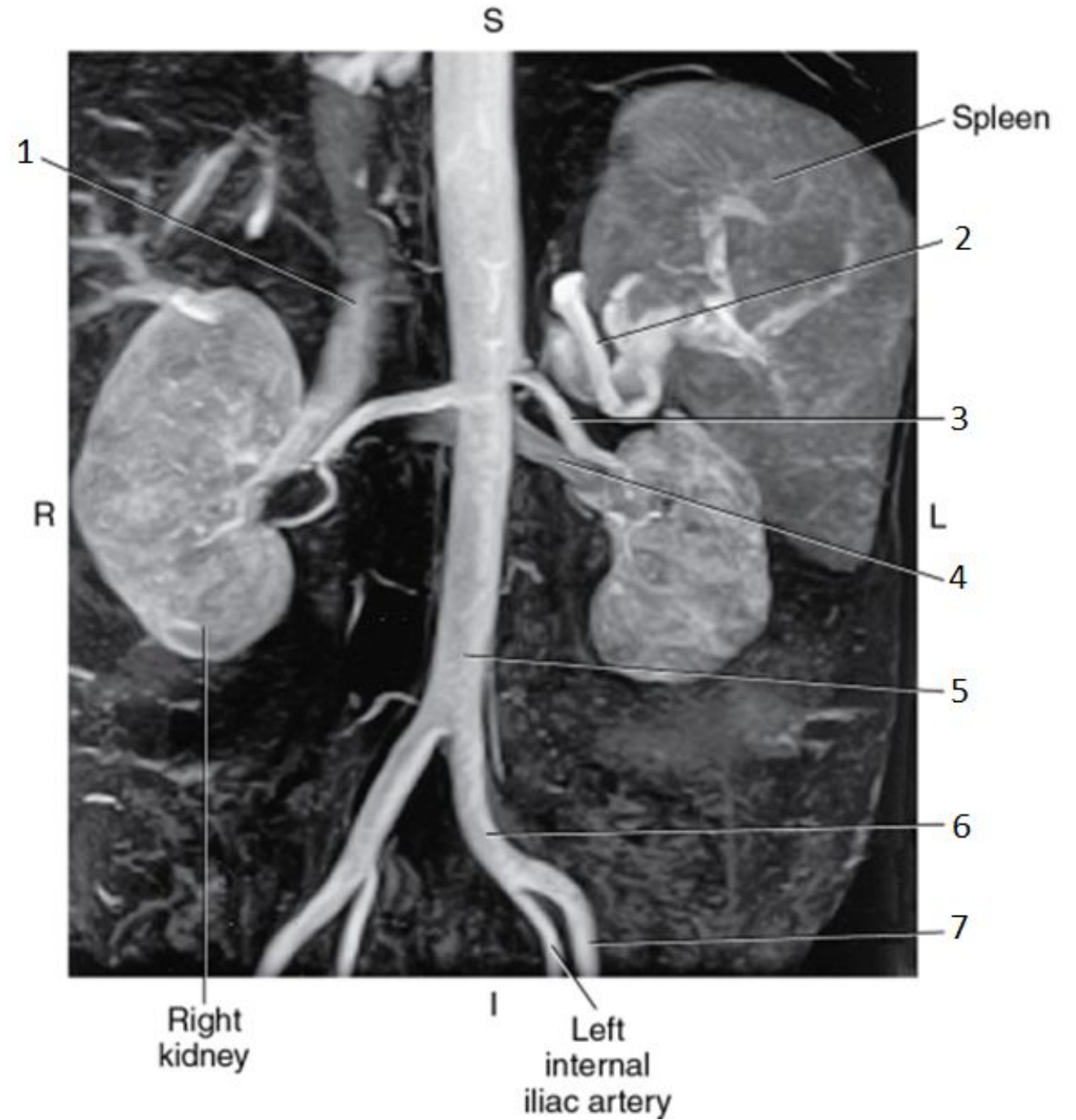


6

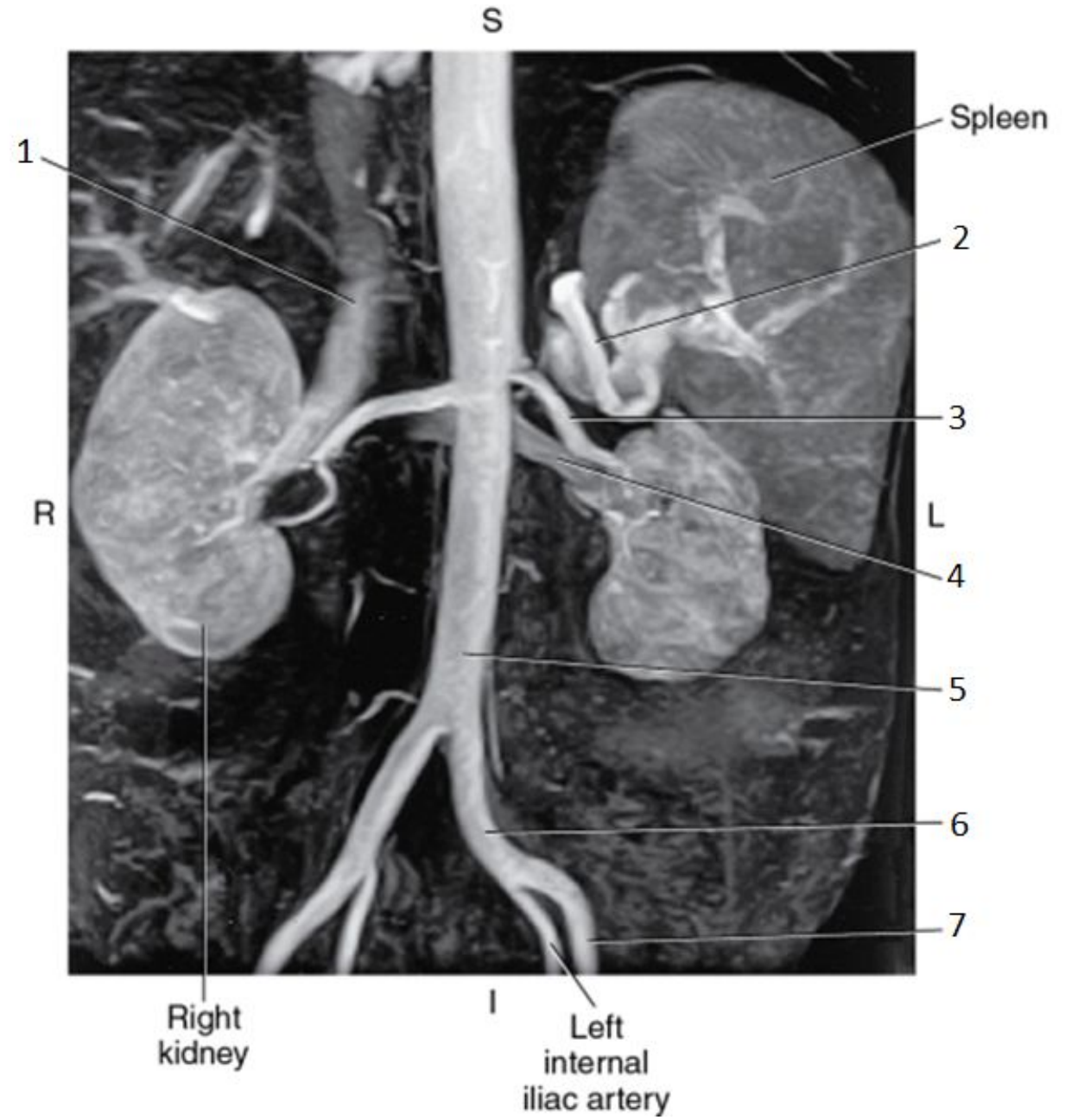


6

- Left Common Iliac Artery



7



7

- Left External Iliac Artery

