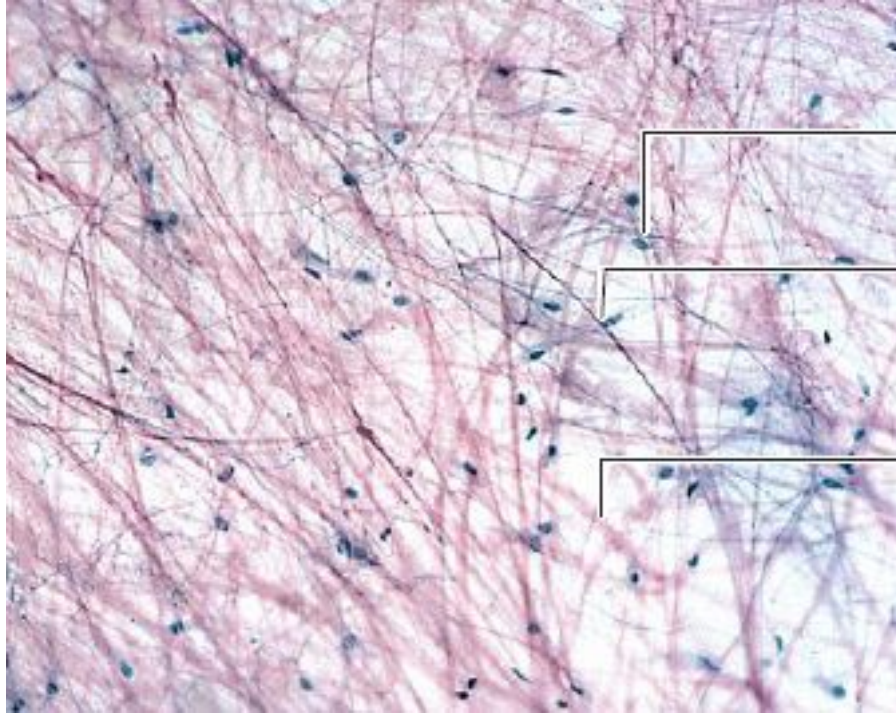
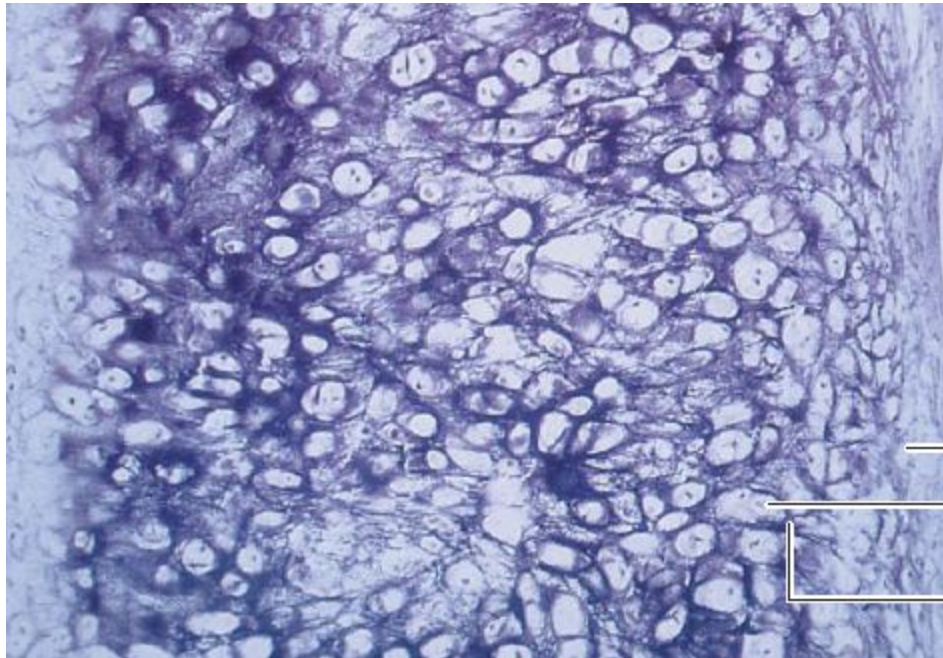


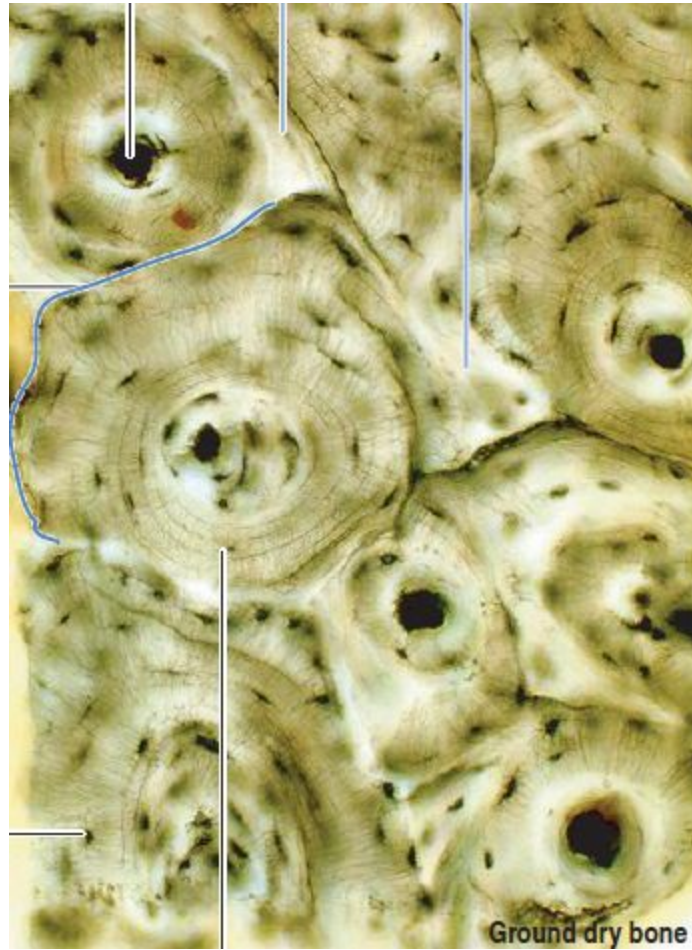18



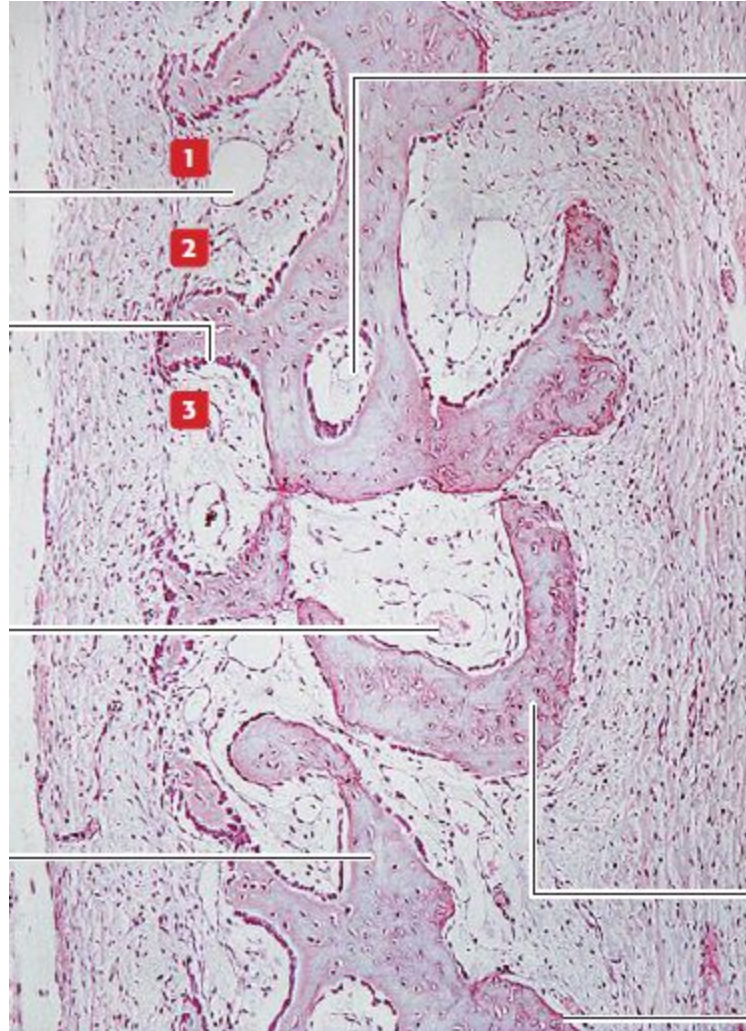24



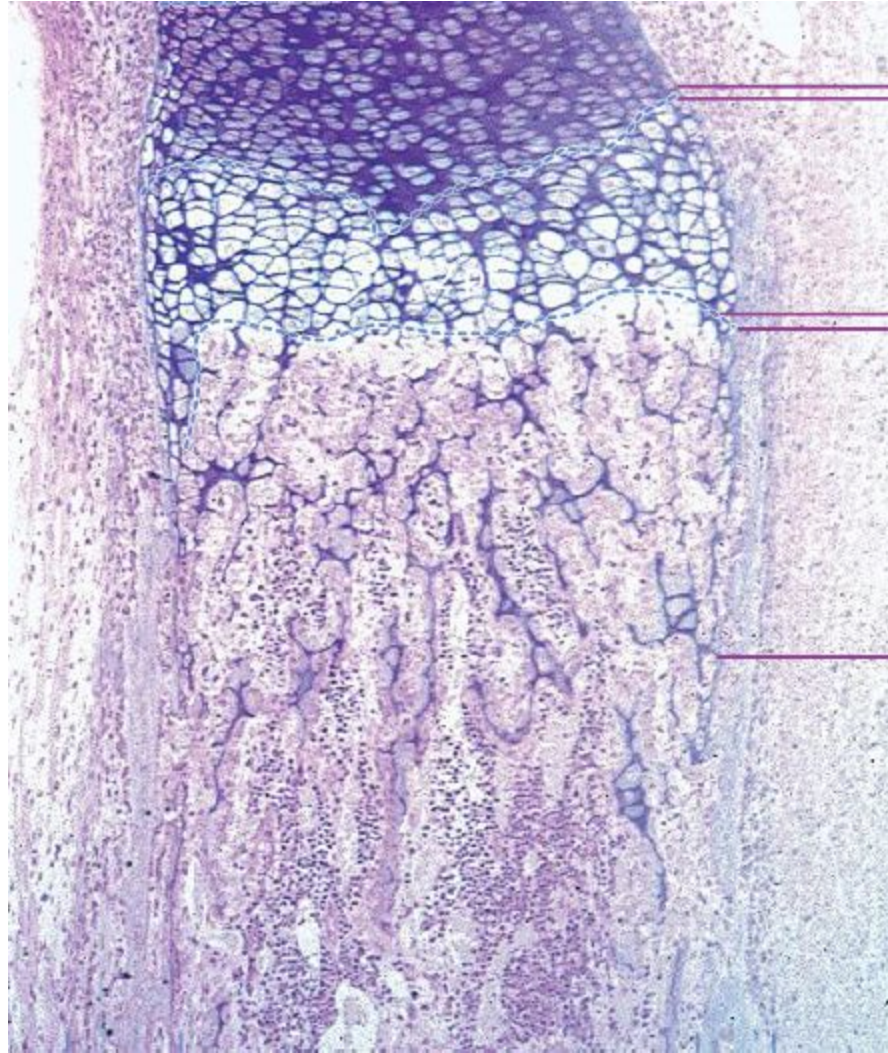
26



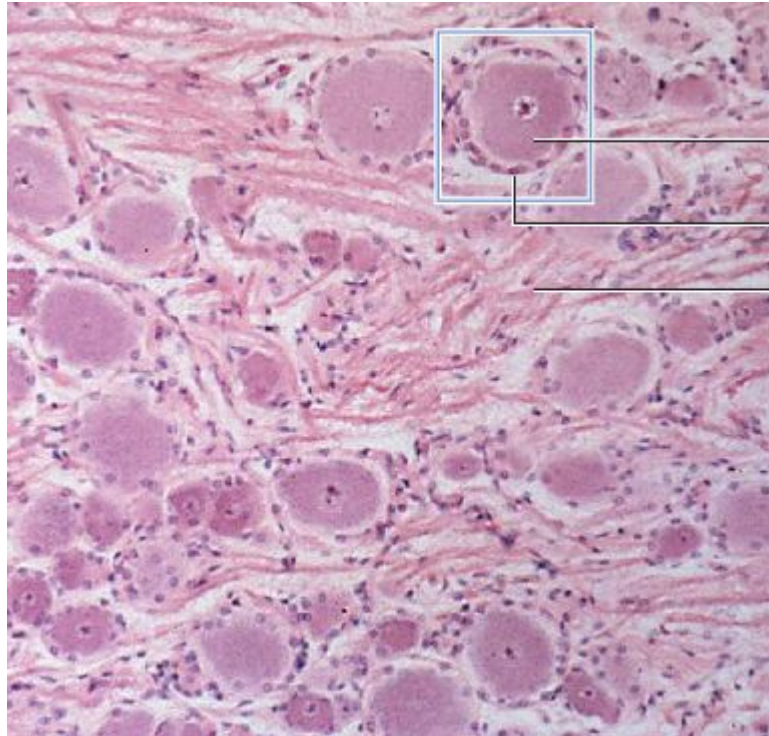
29



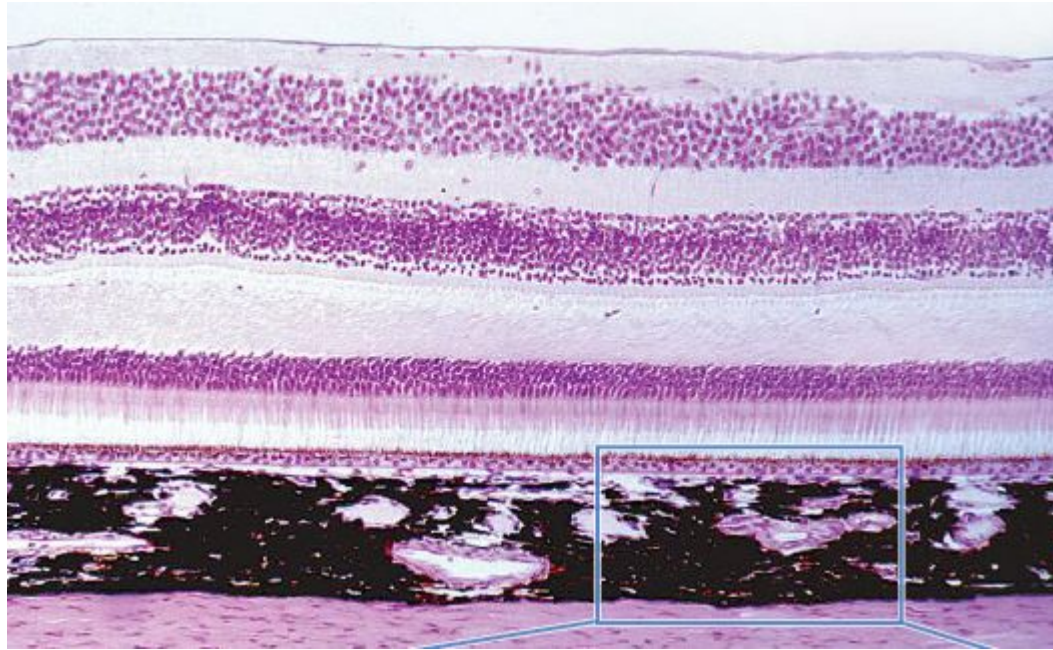
29



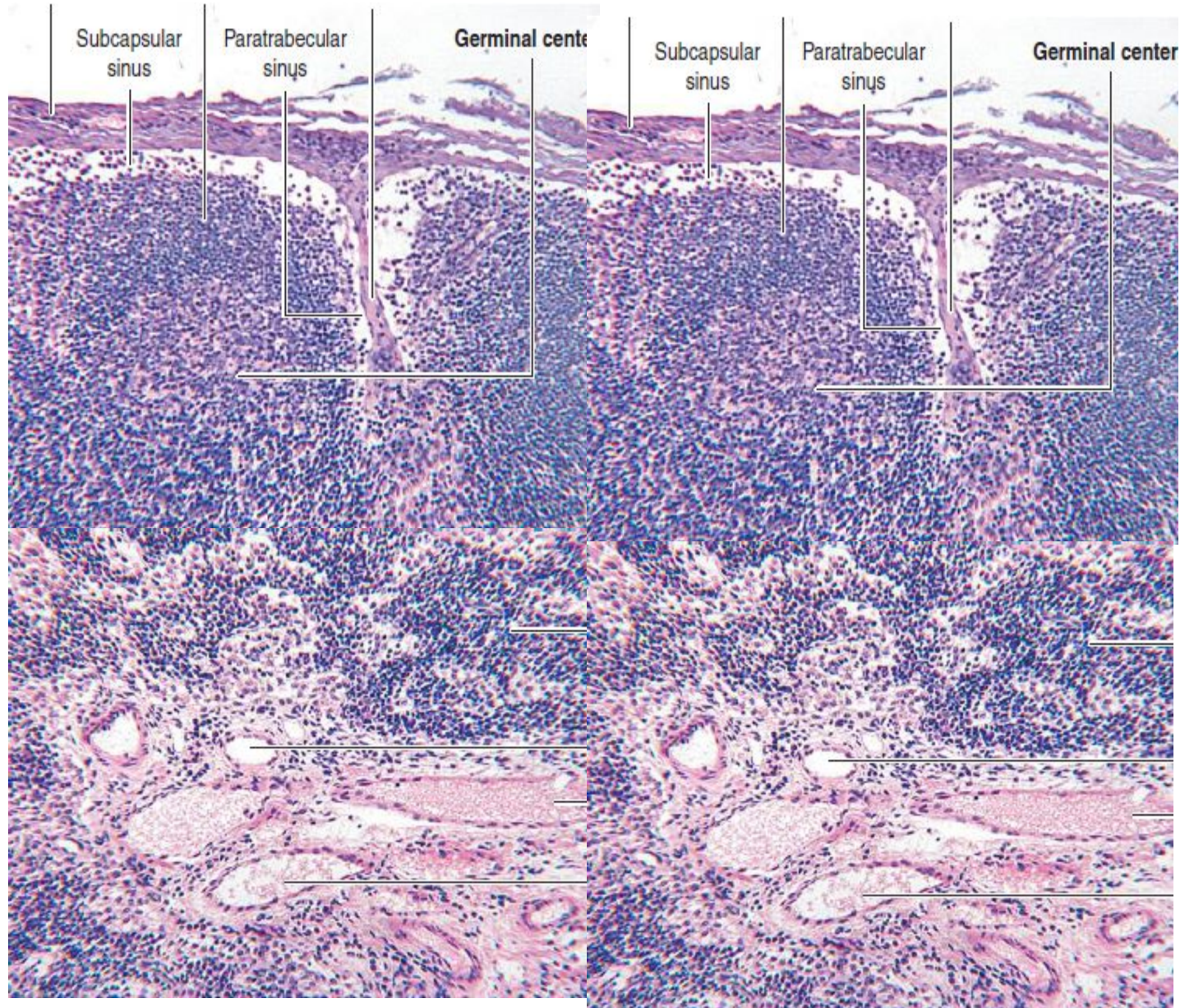
43



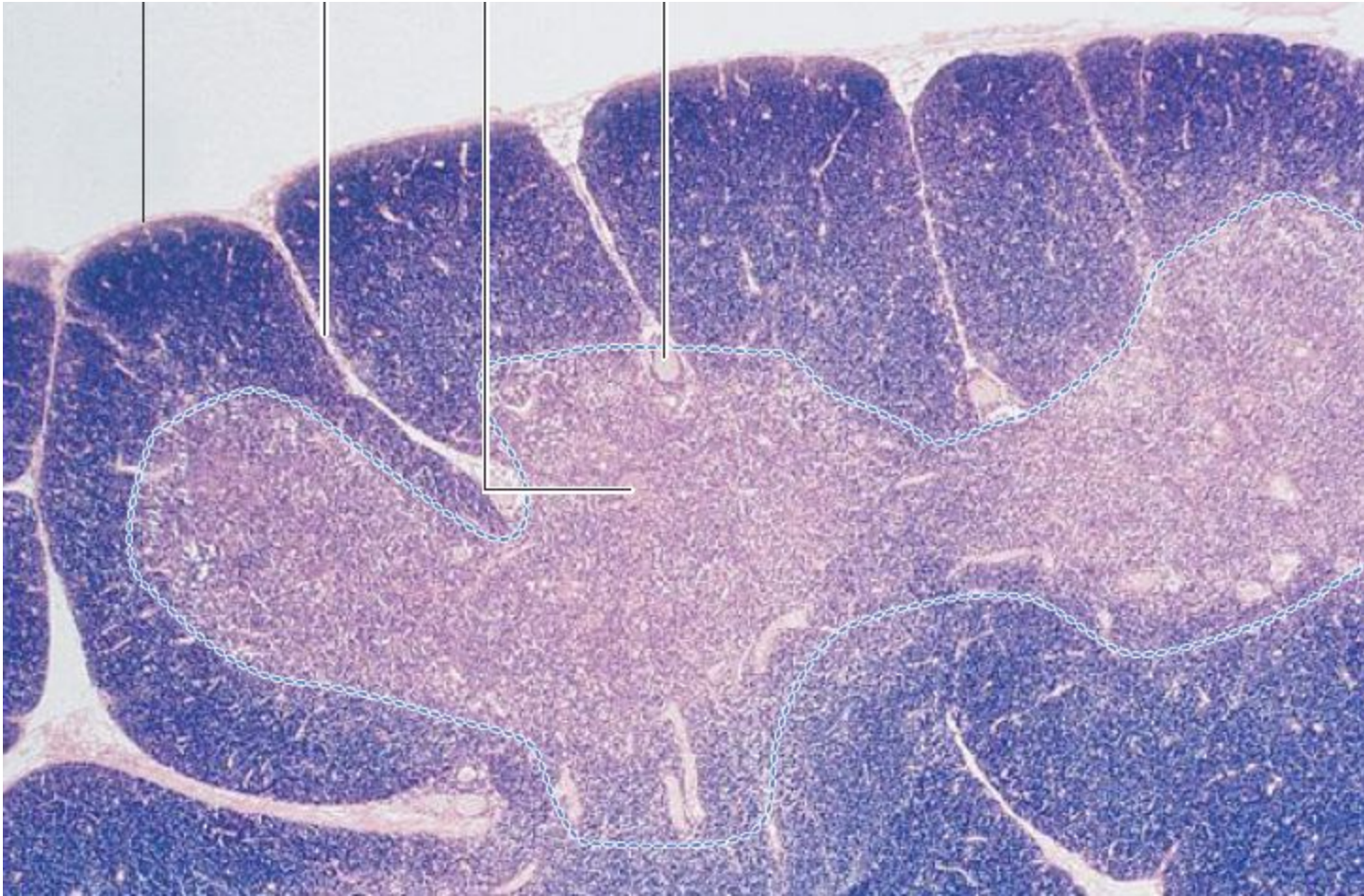
64



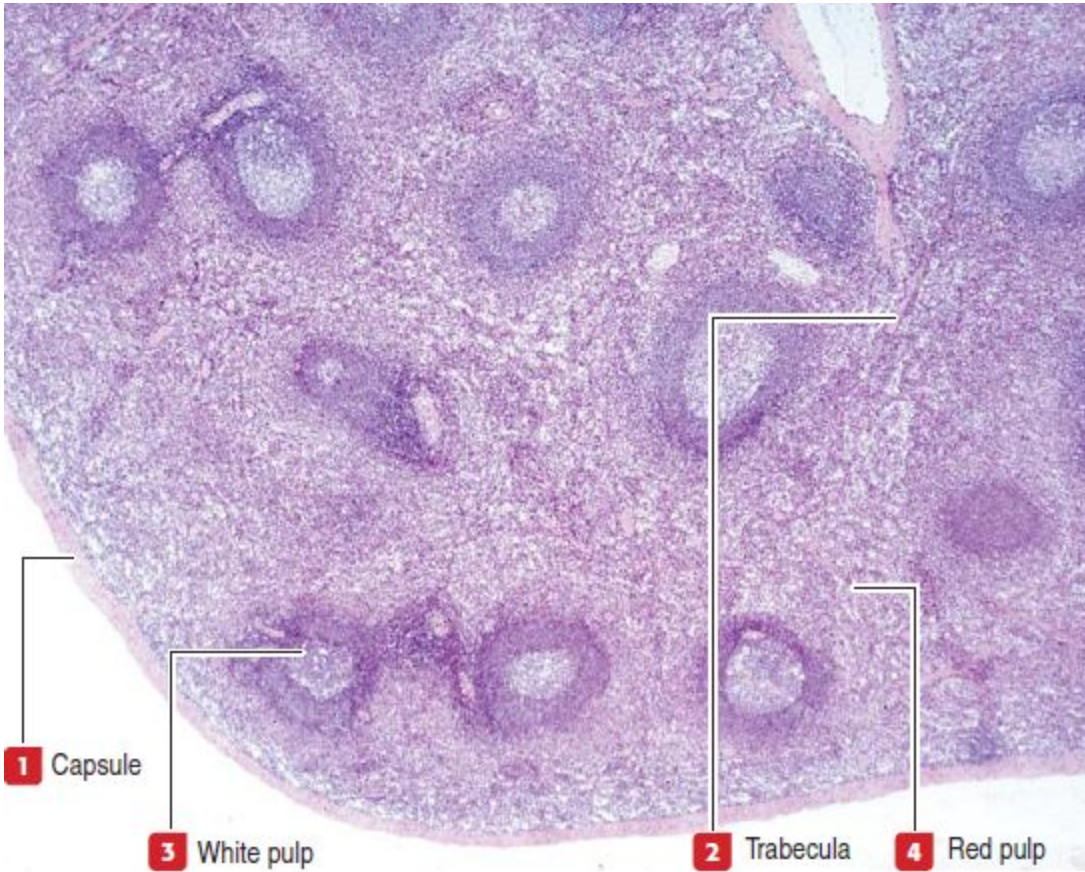
• 66



72



68



1 Capsule

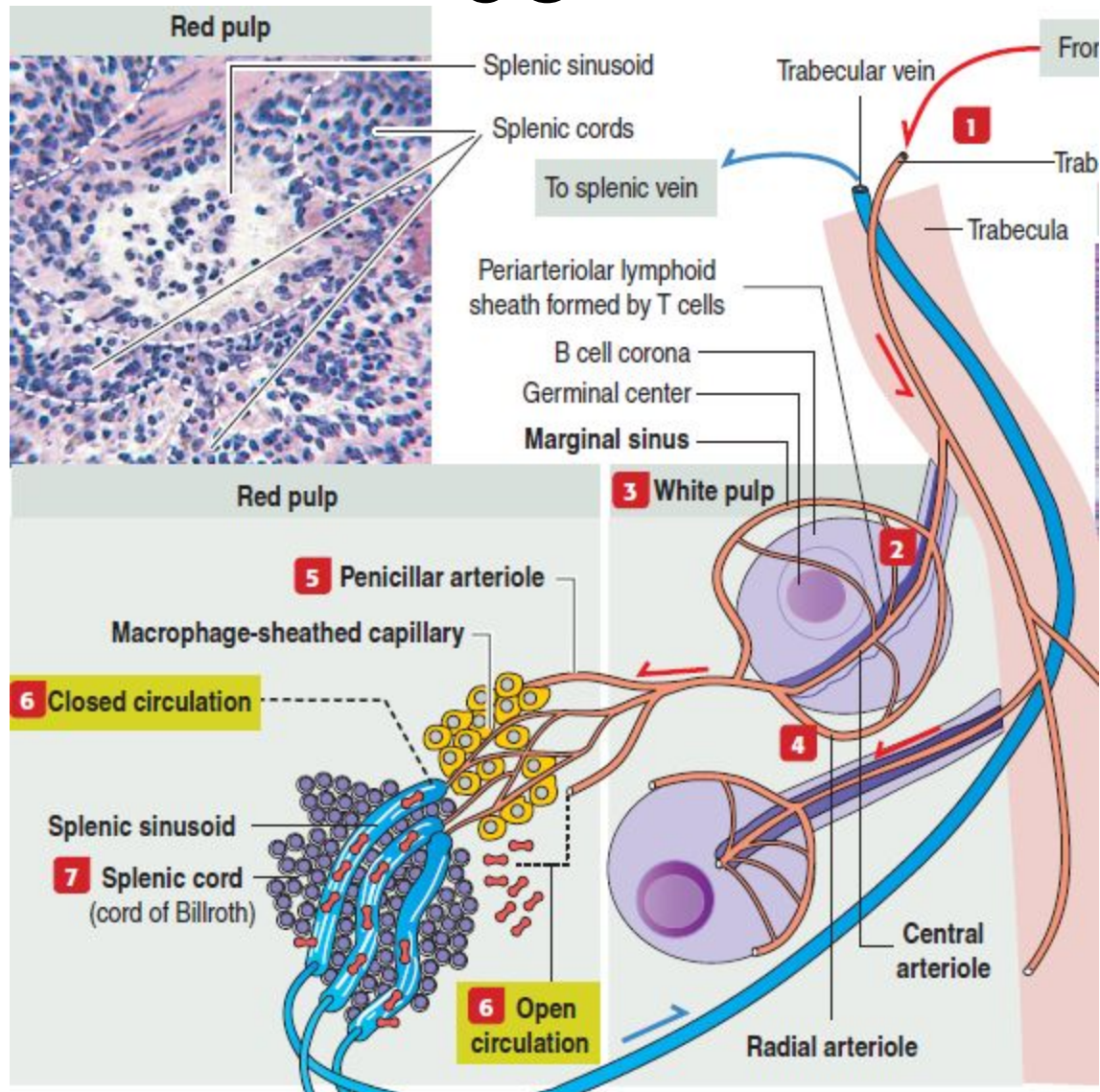
3 White pulp

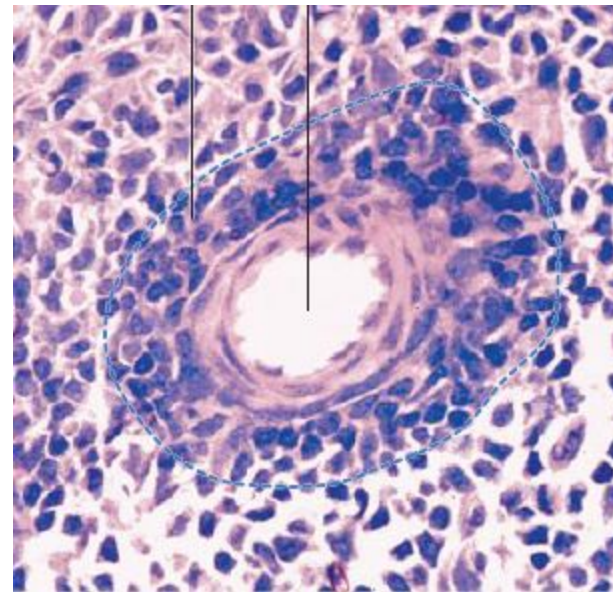
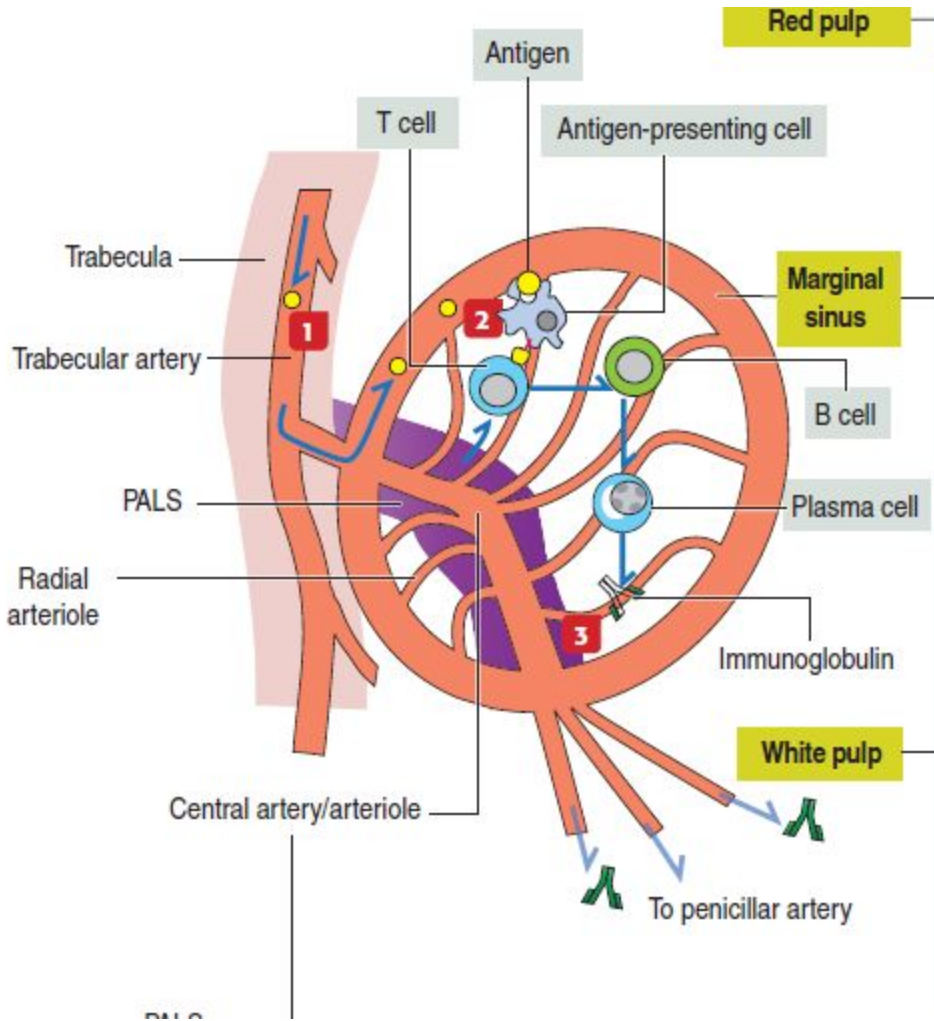
2 Trabecula

4 Red pulp

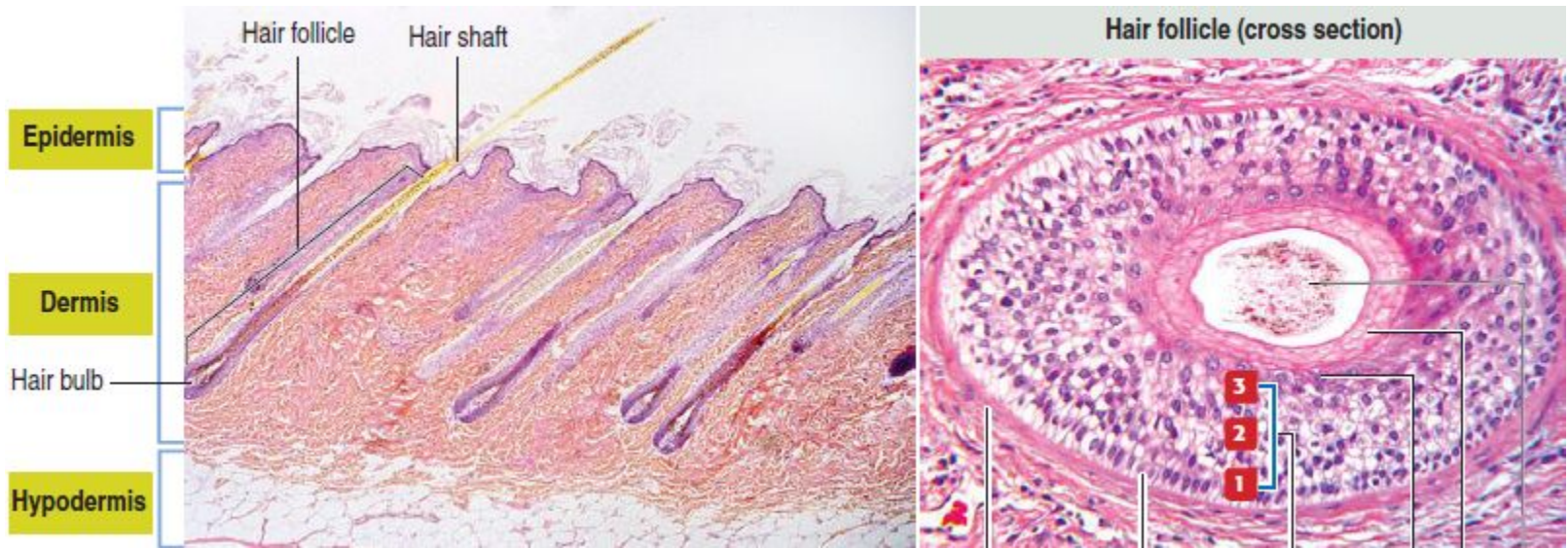
Trabecula

68

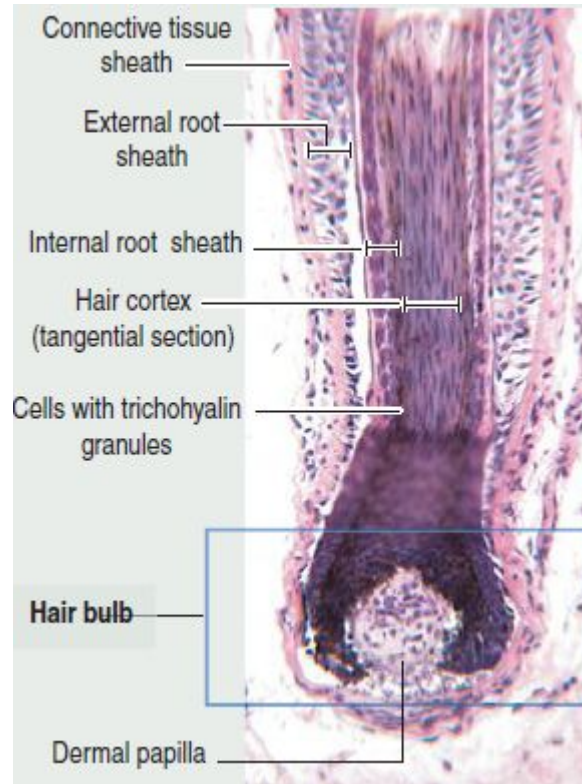




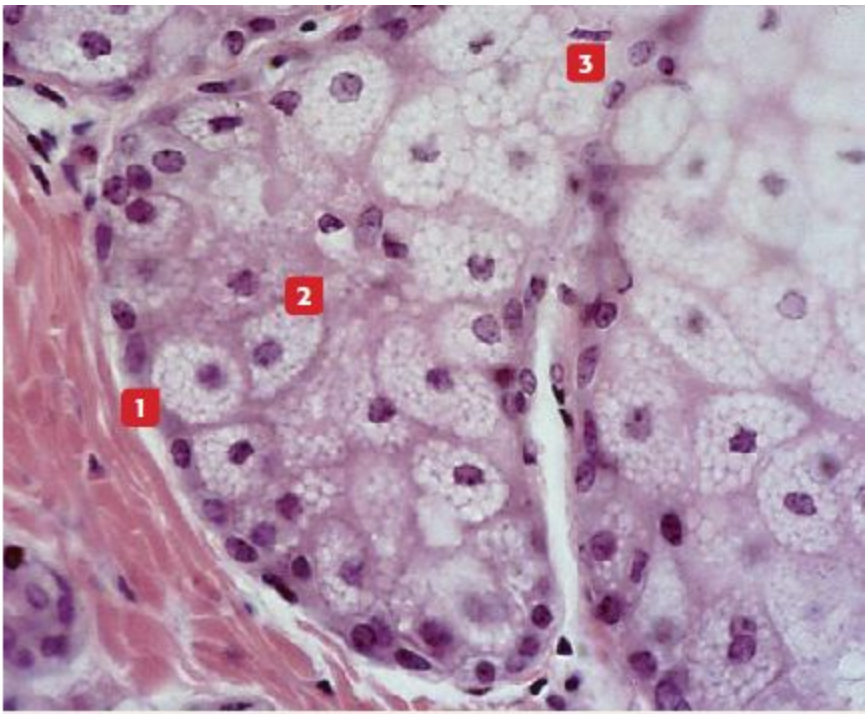
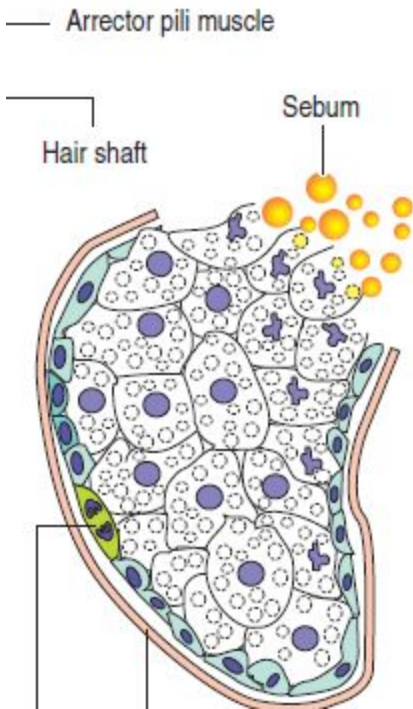
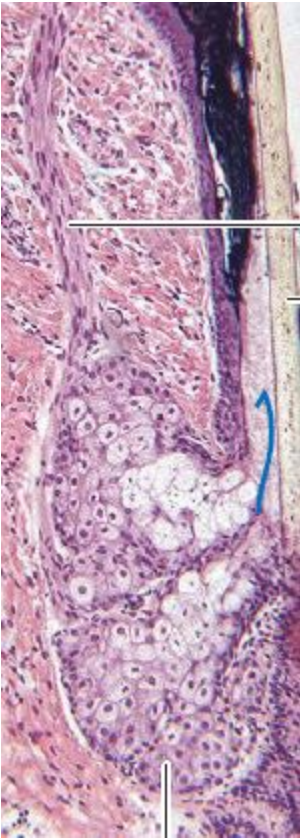
58



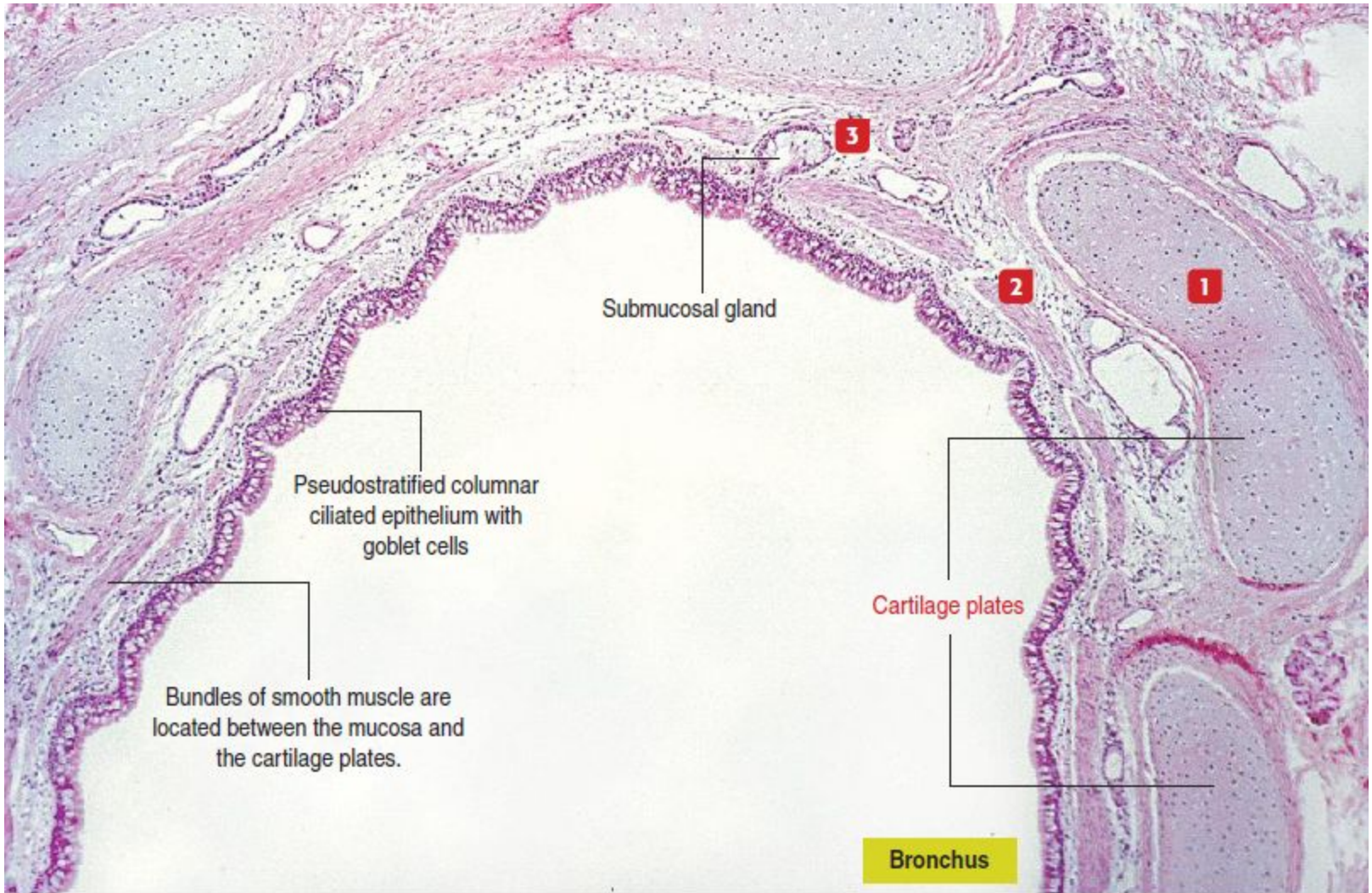
58

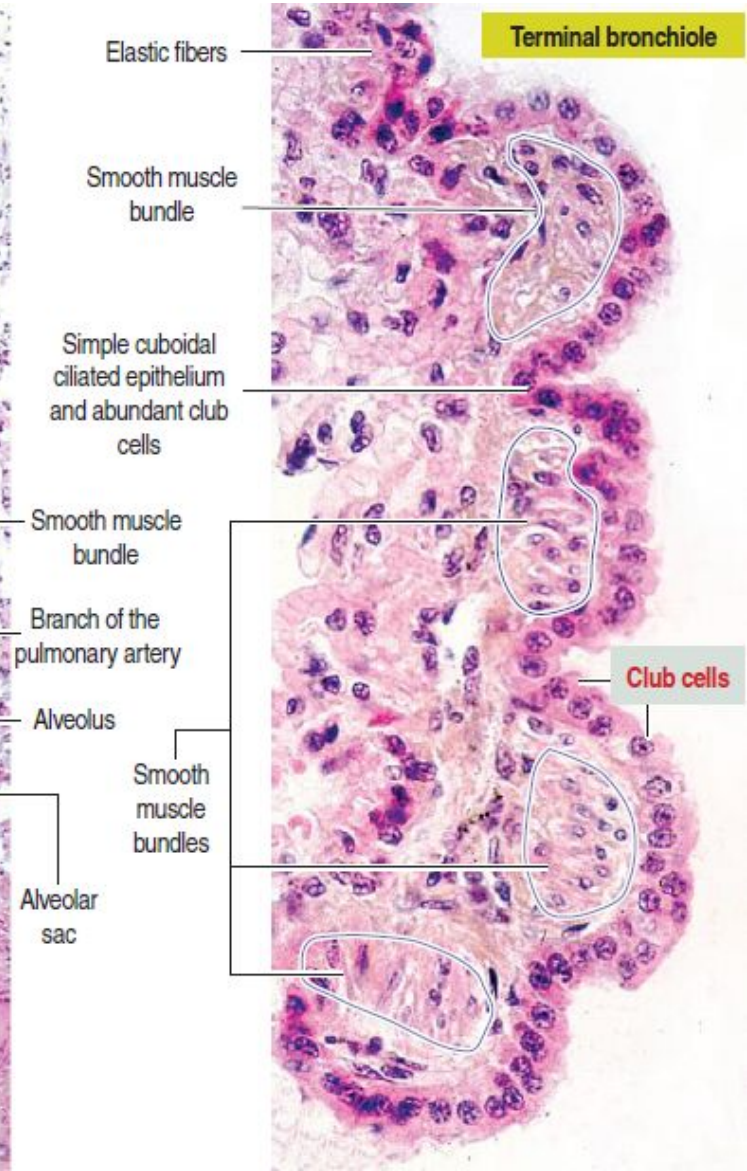
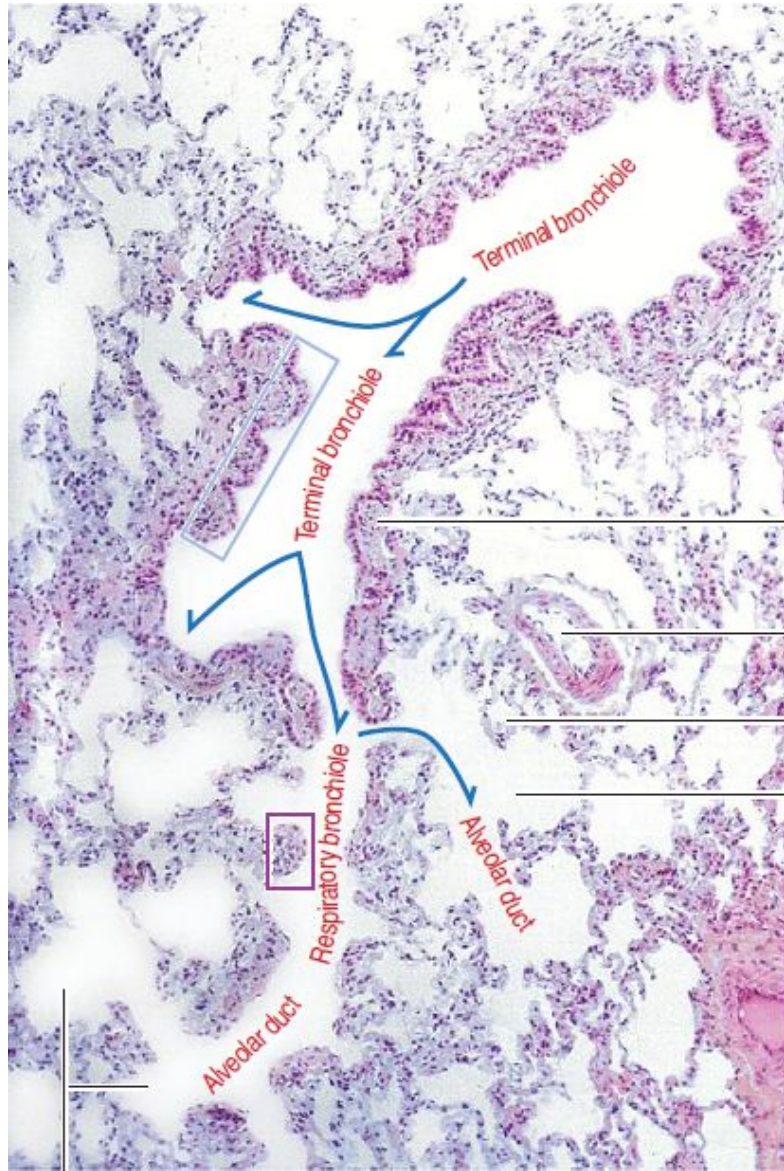


58



95





Elastic fibers

Terminal bronchiole

Smooth muscle bundle

Simple cuboidal ciliated epithelium and abundant club cells

Smooth muscle bundle

Branch of the pulmonary artery

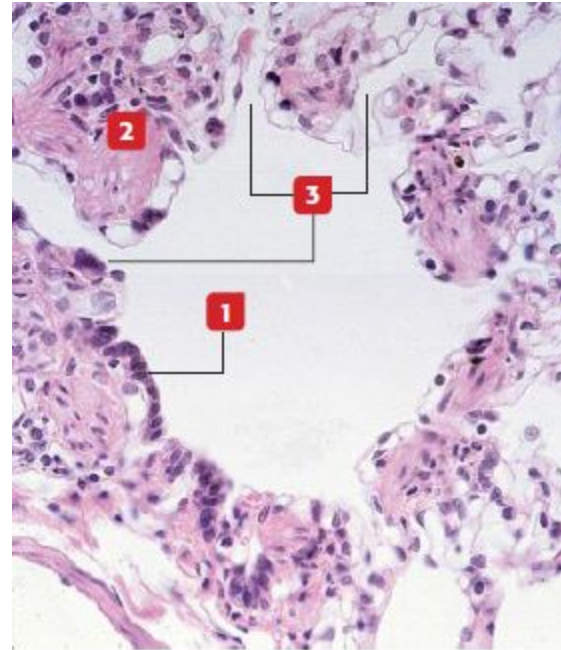
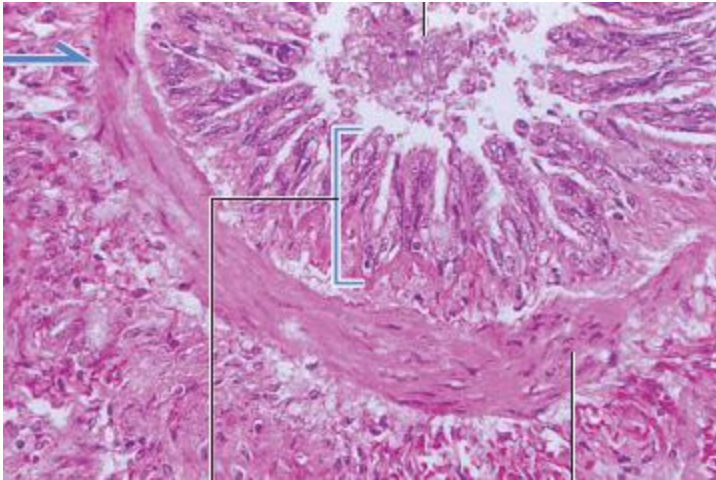
Alveolus

Club cells

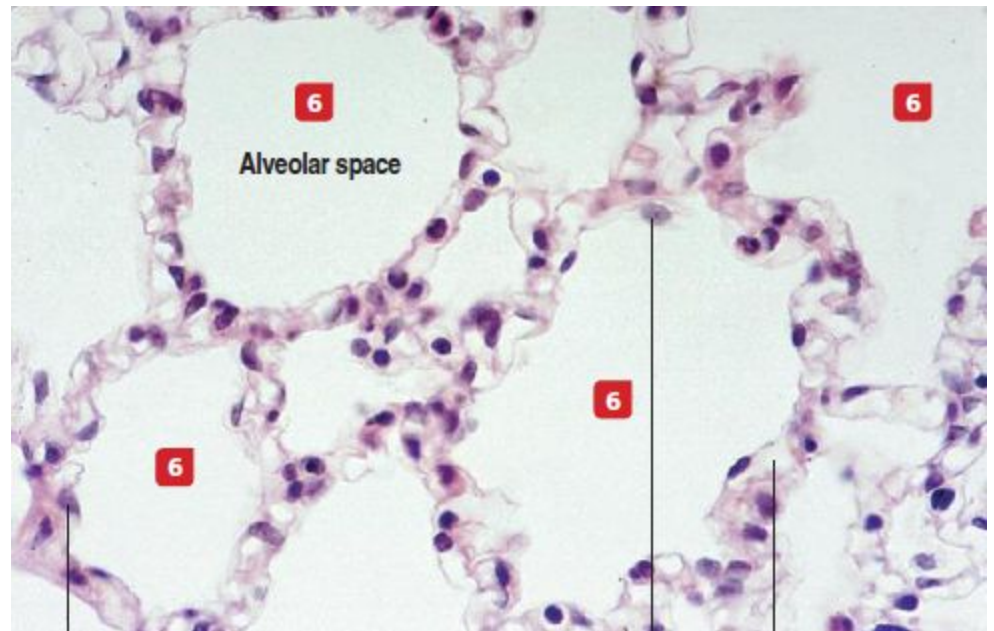
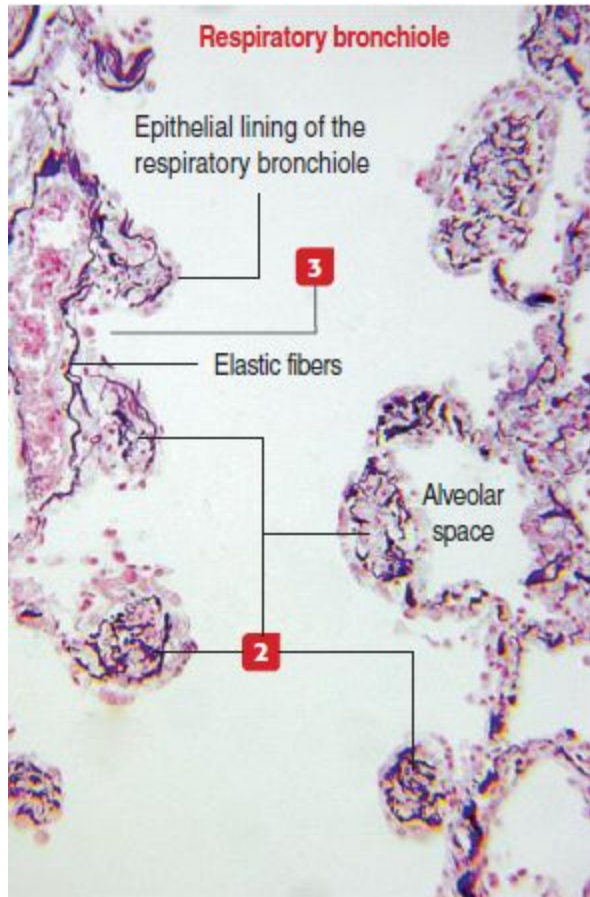
Smooth muscle bundles

Alveolar sac

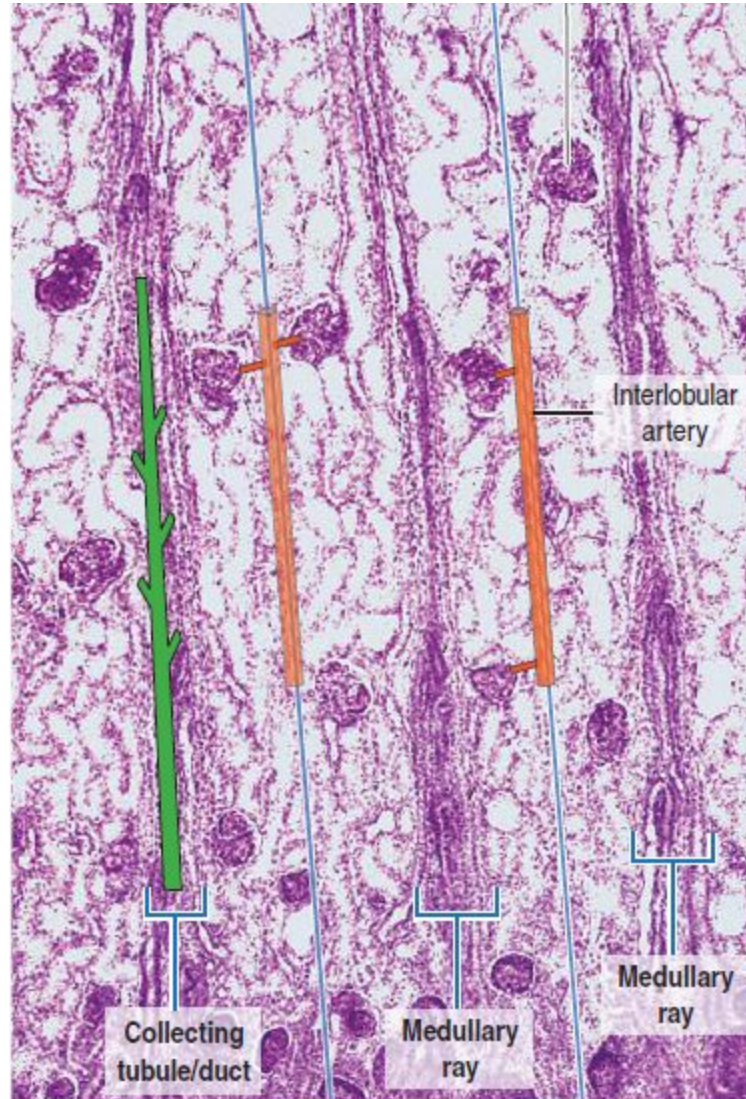
95



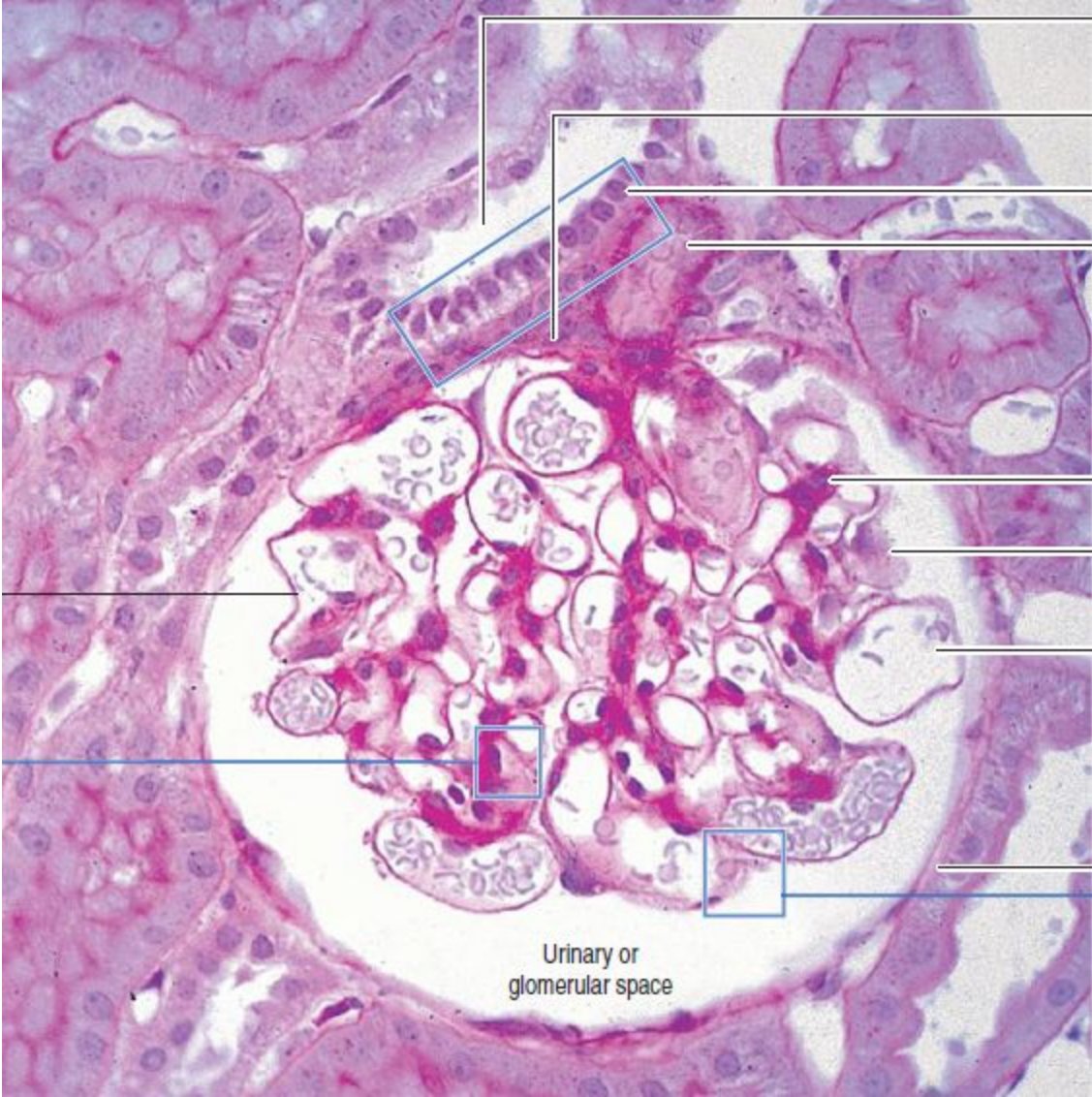
95



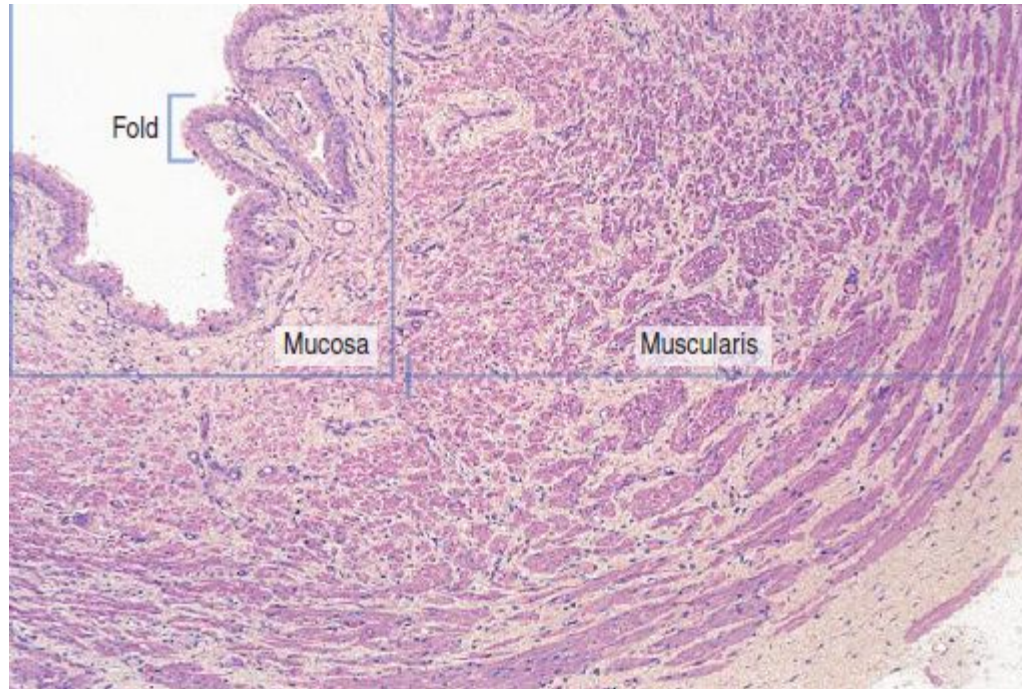
96



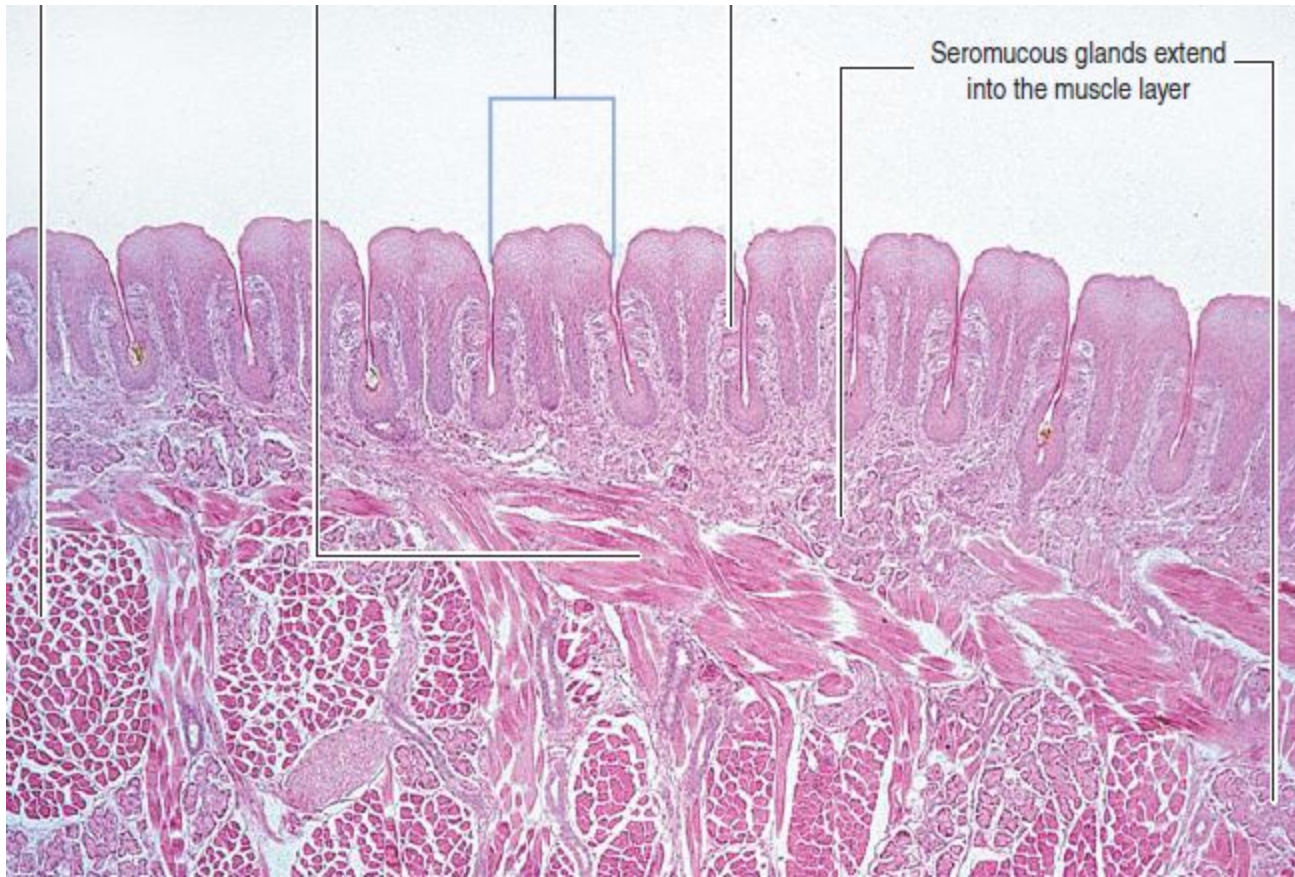
96



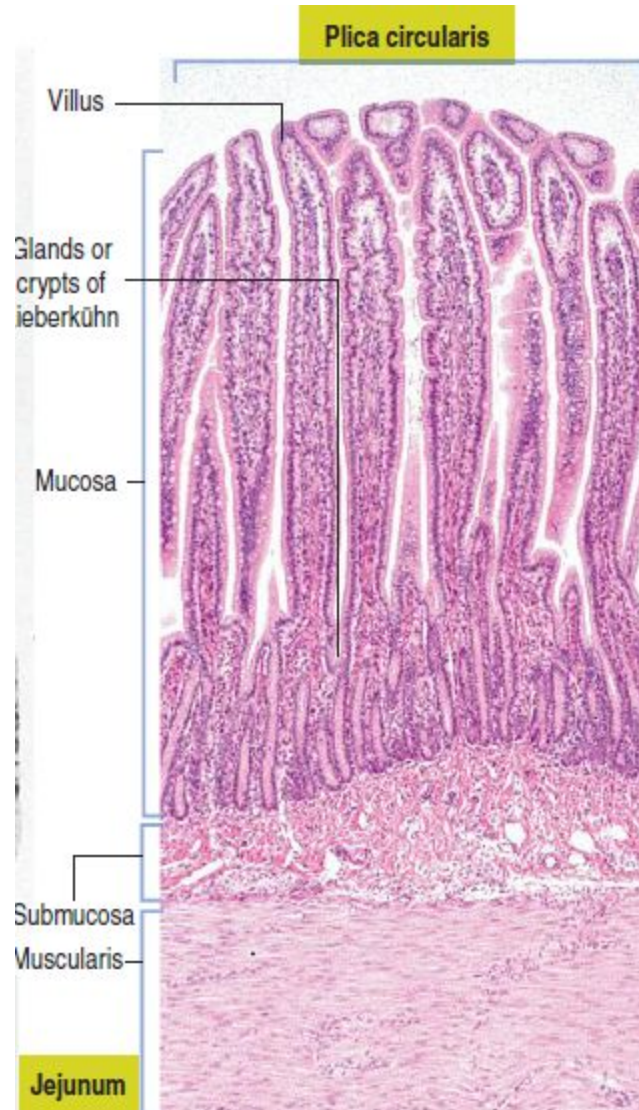
97



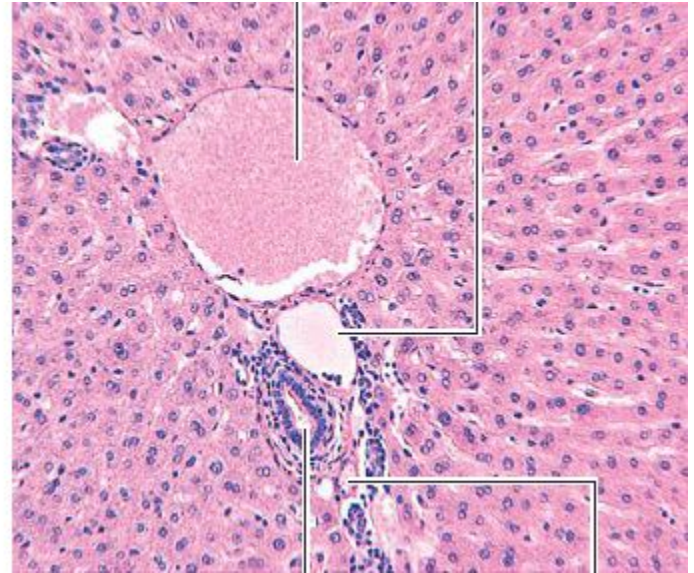
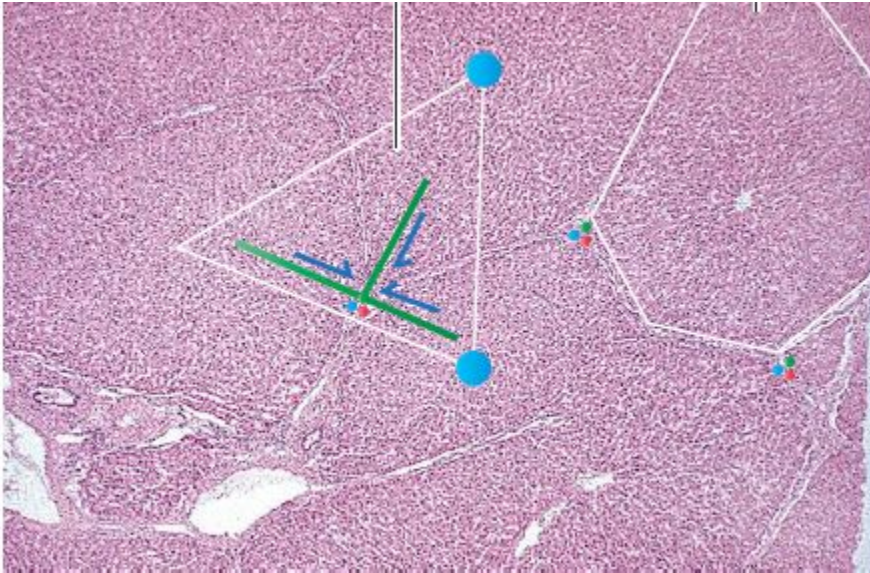
33



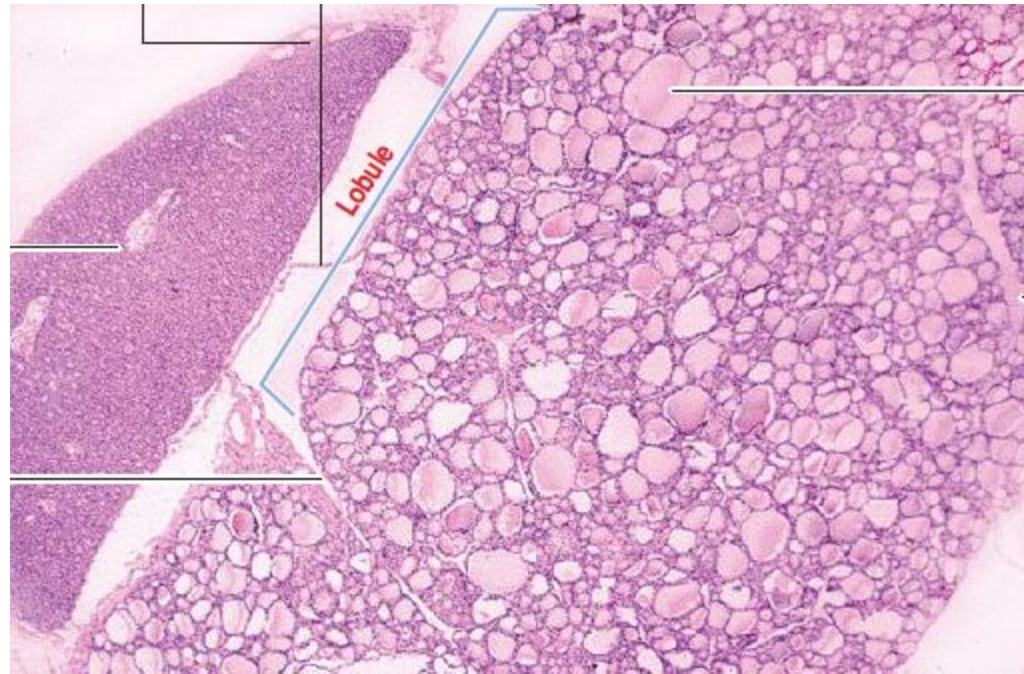
87



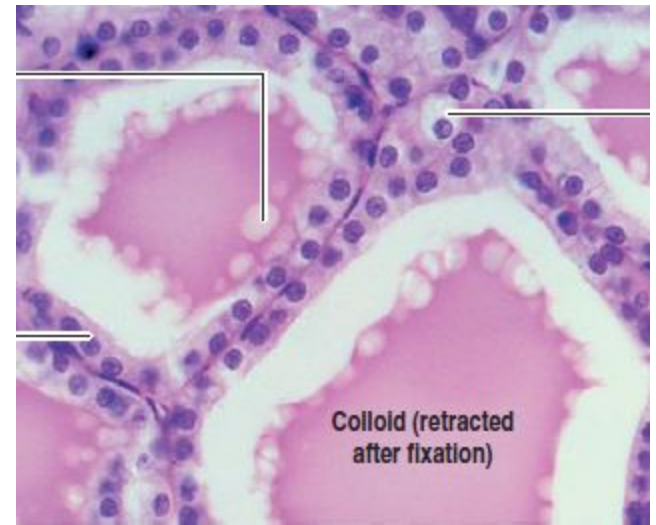
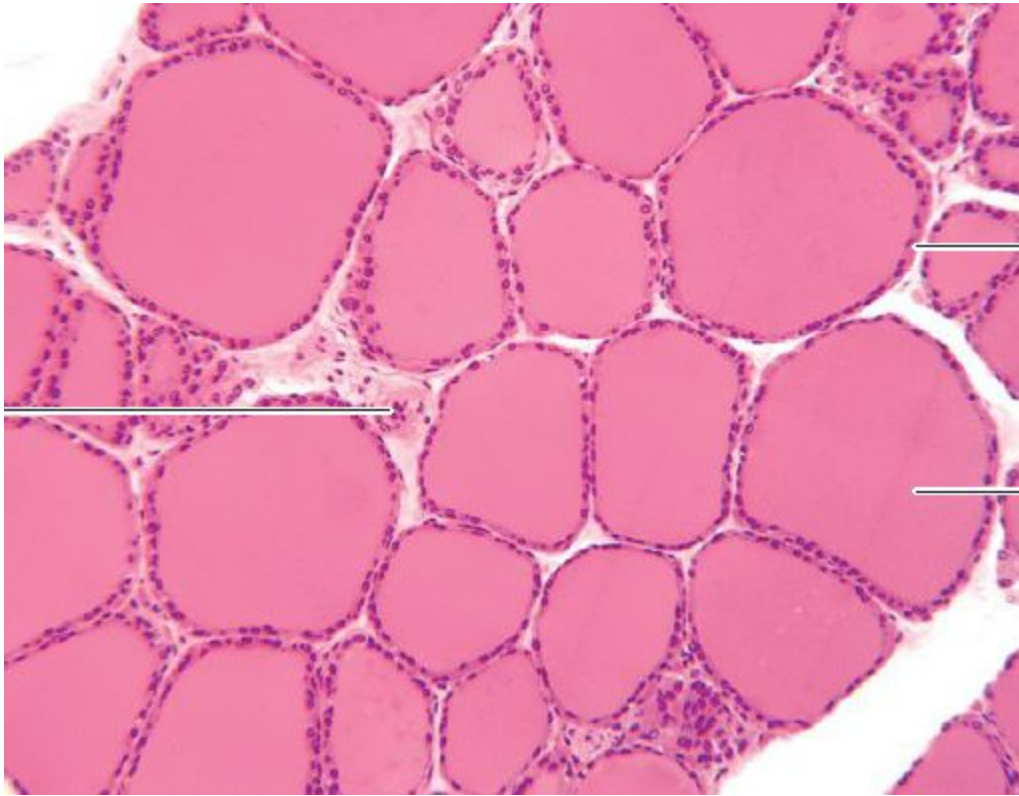
92



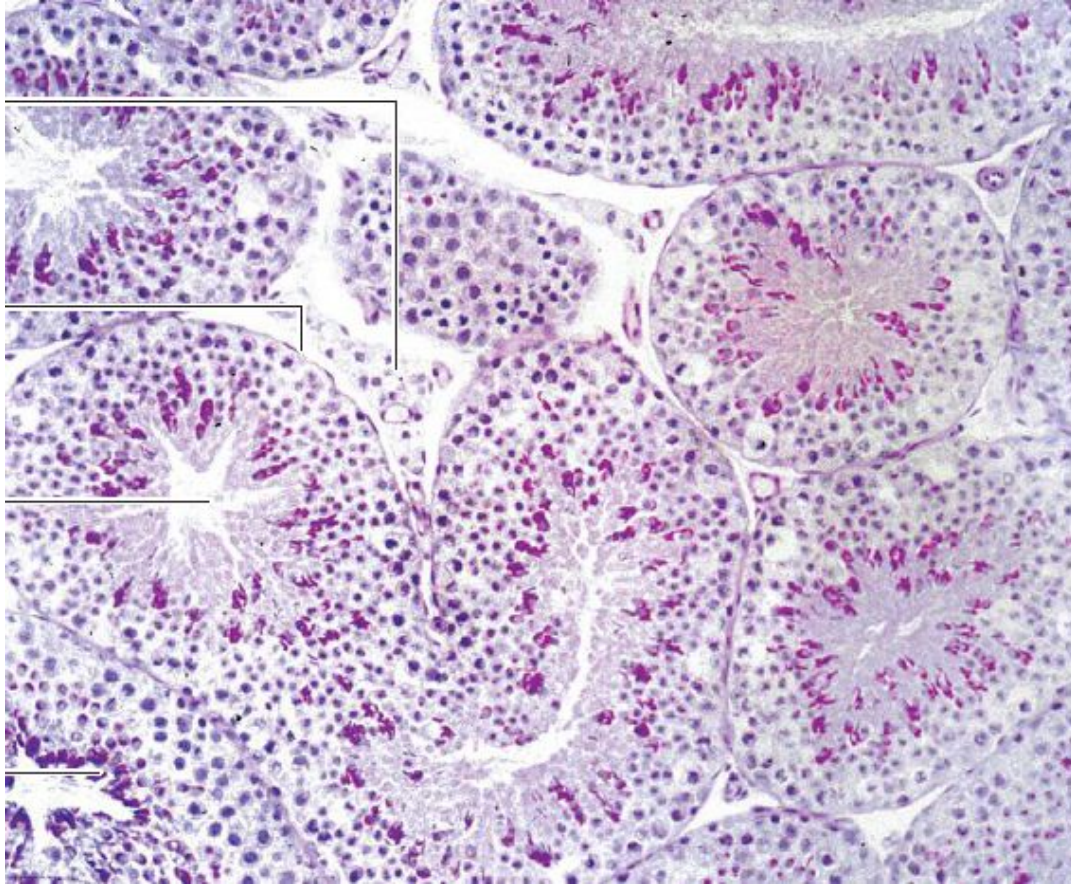
74

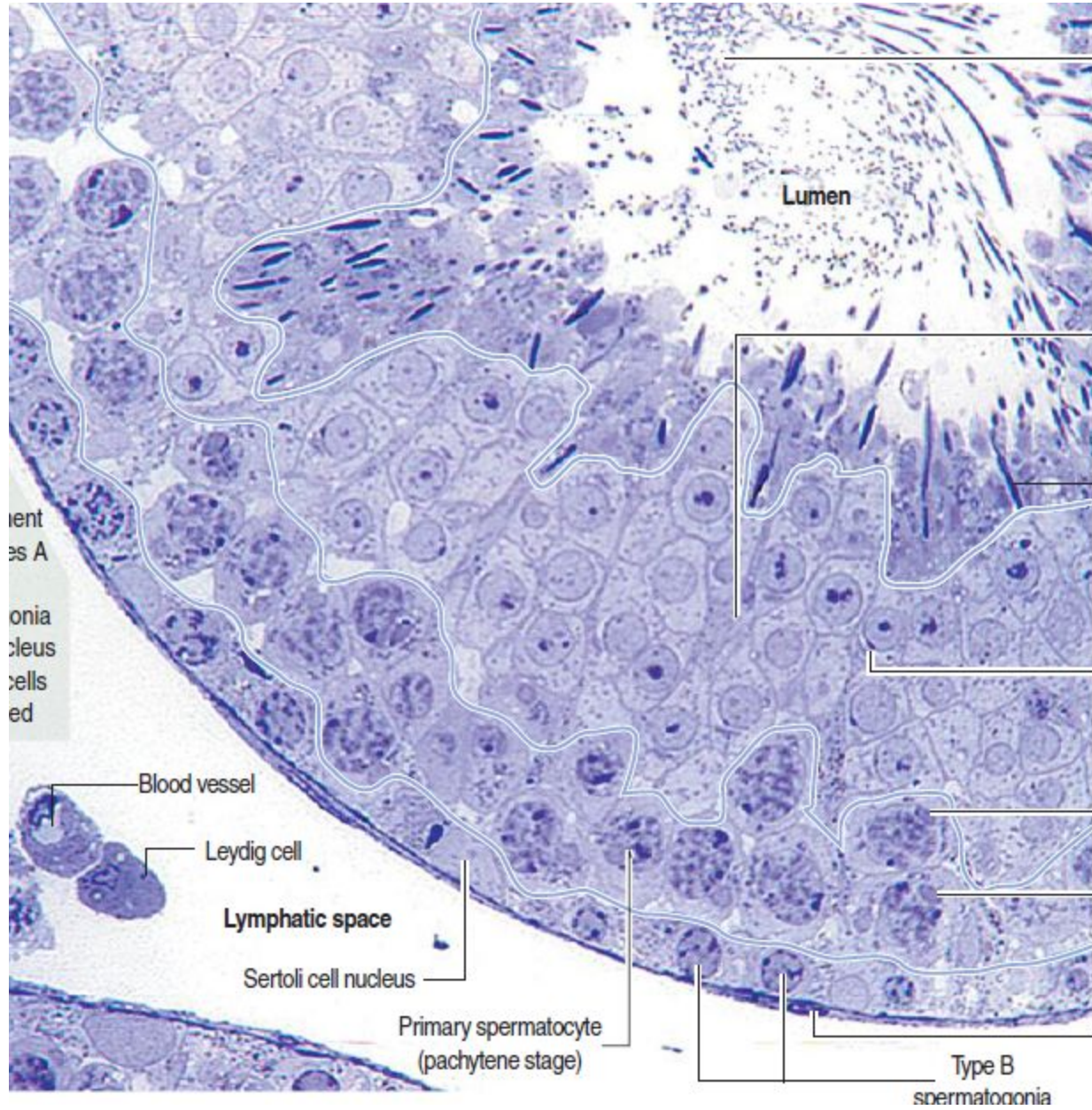


74

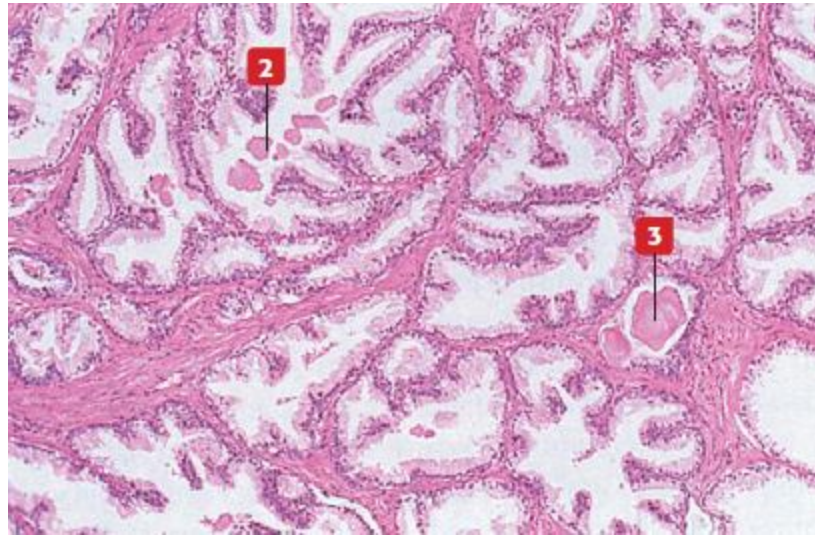


99

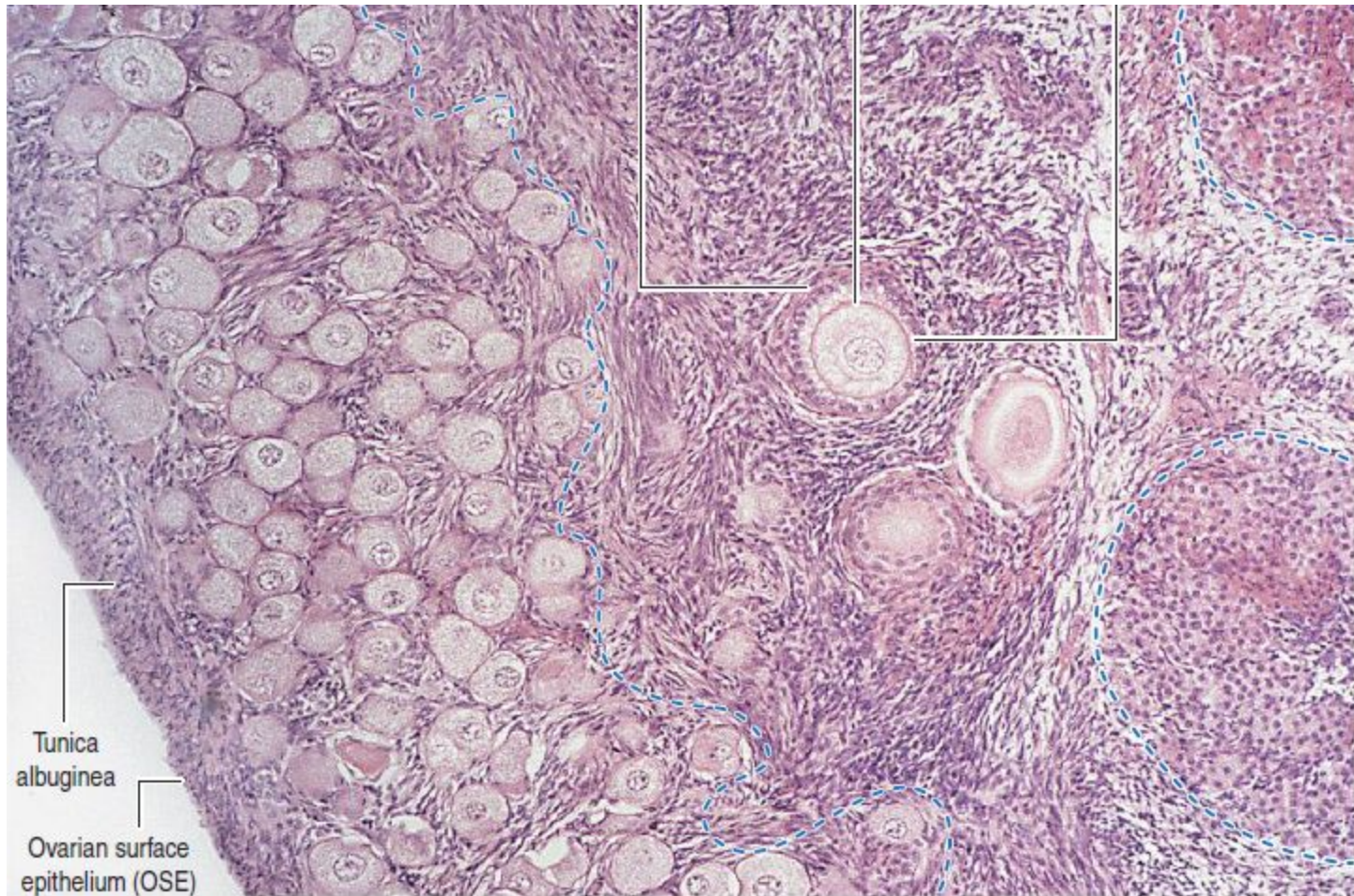




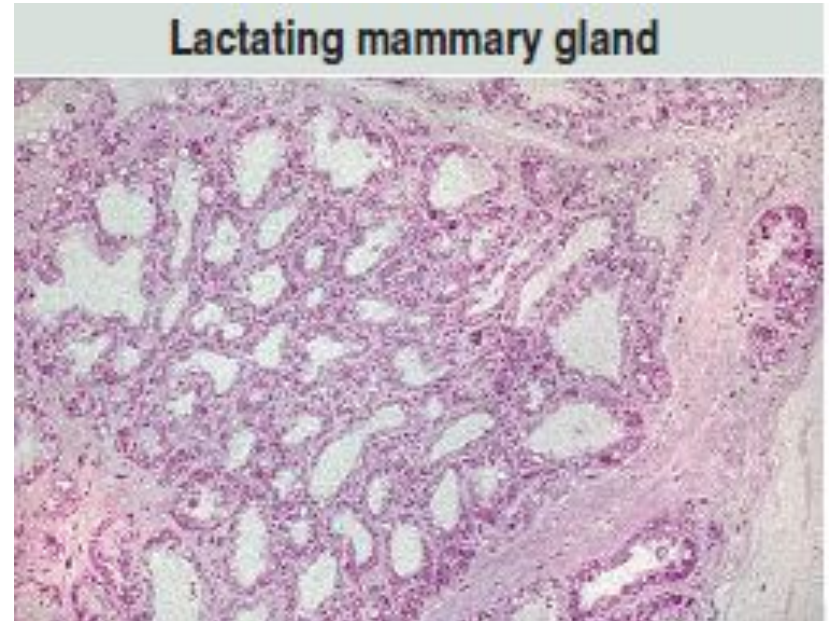
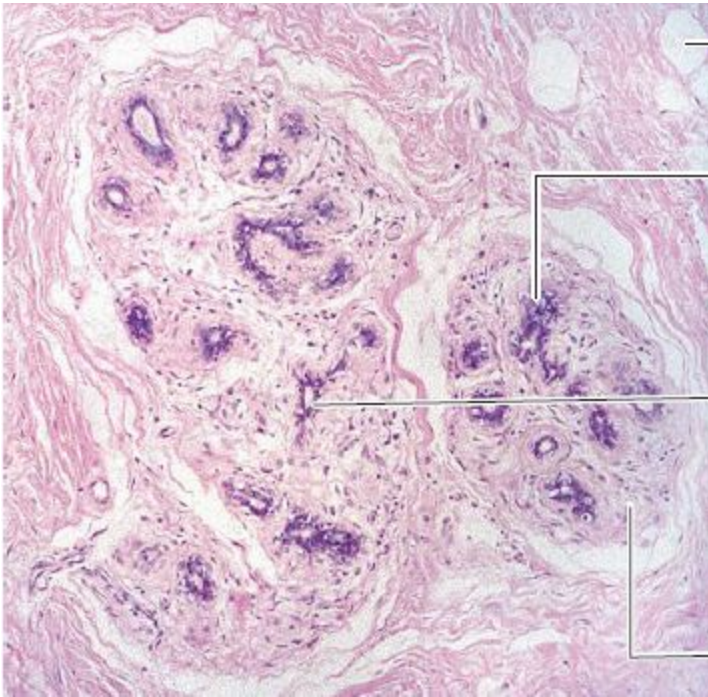
100



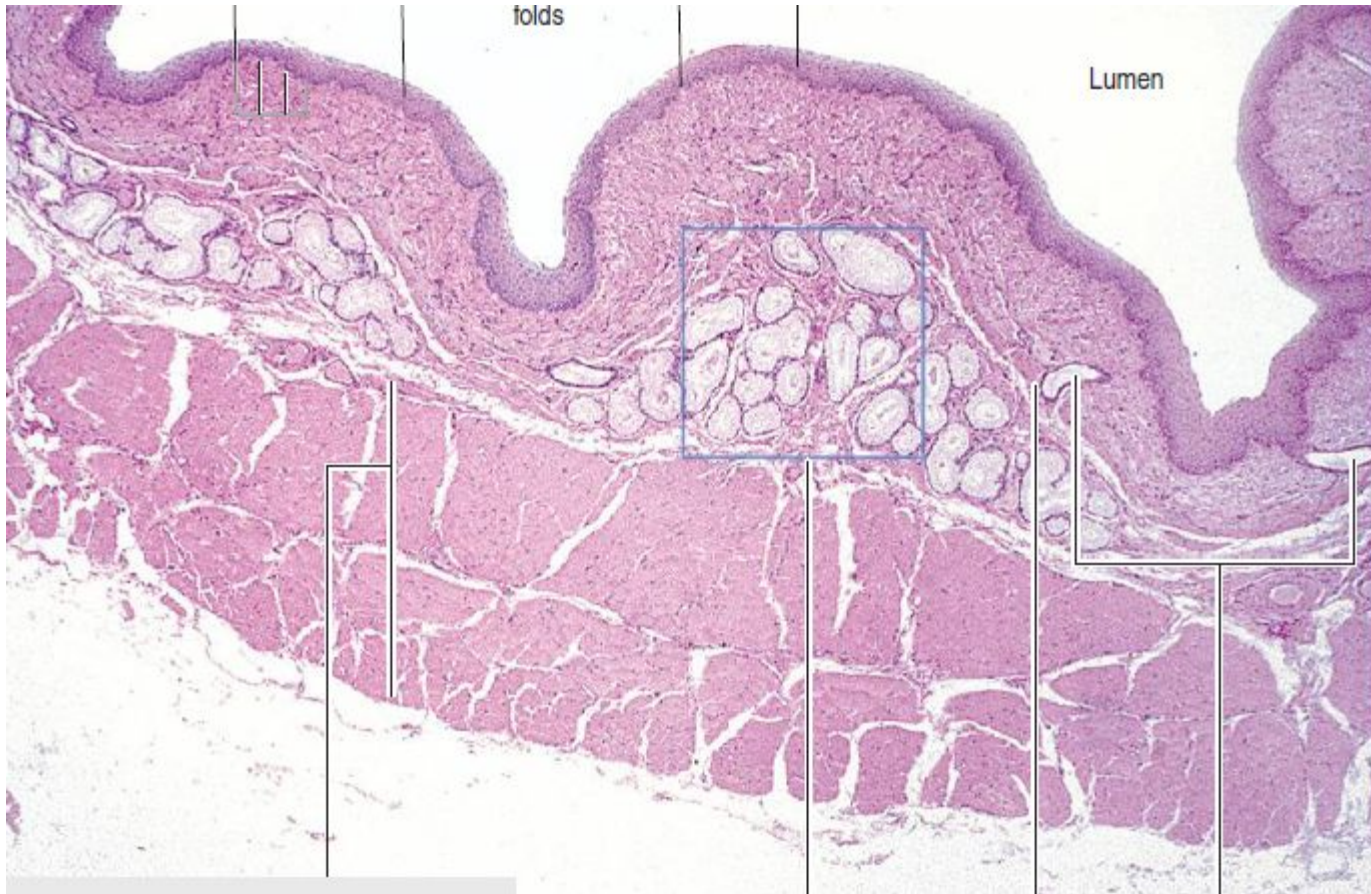
101



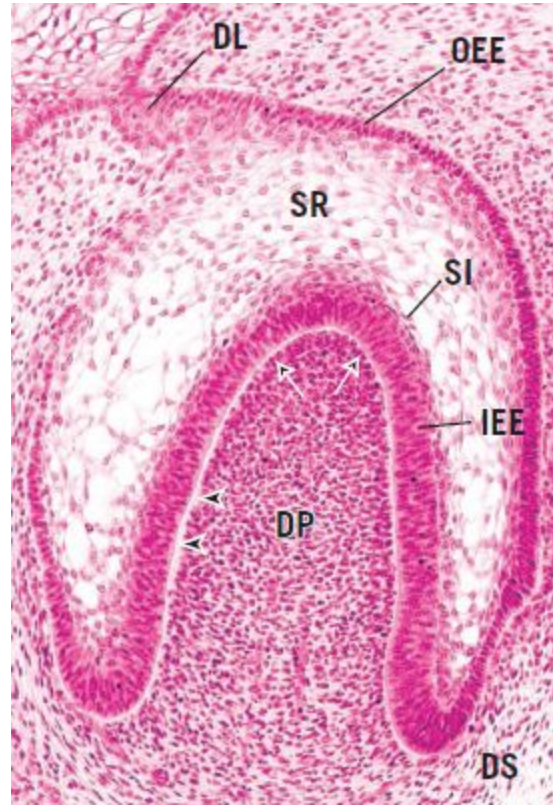
59



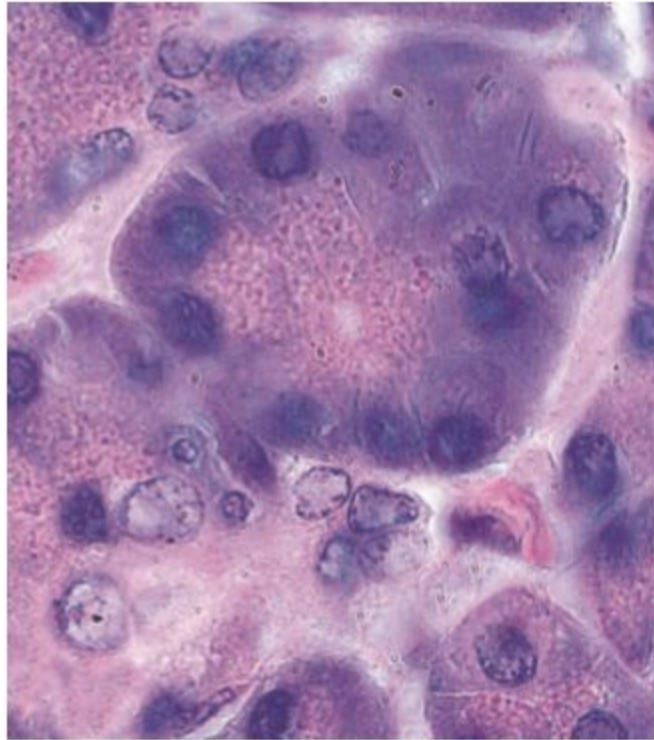
83



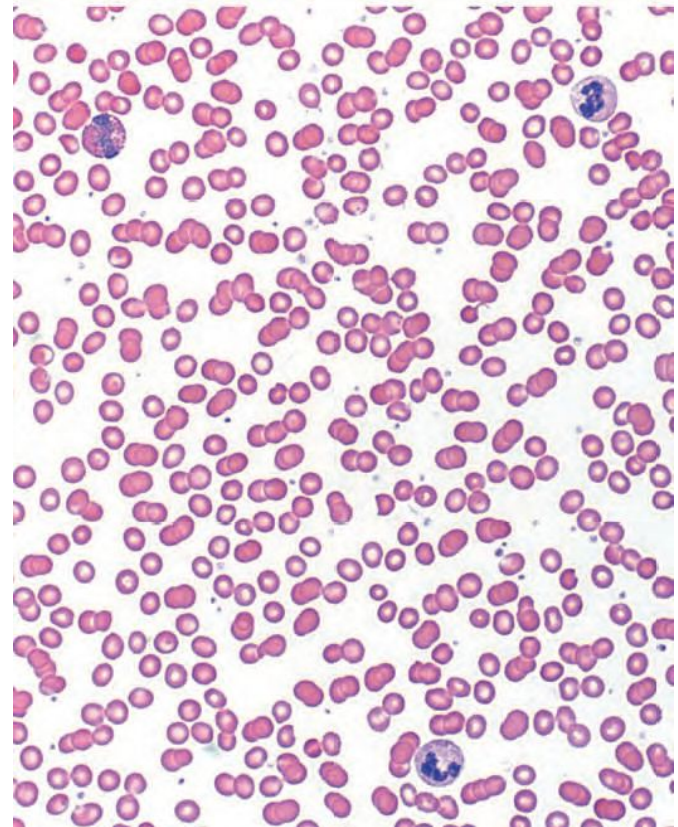
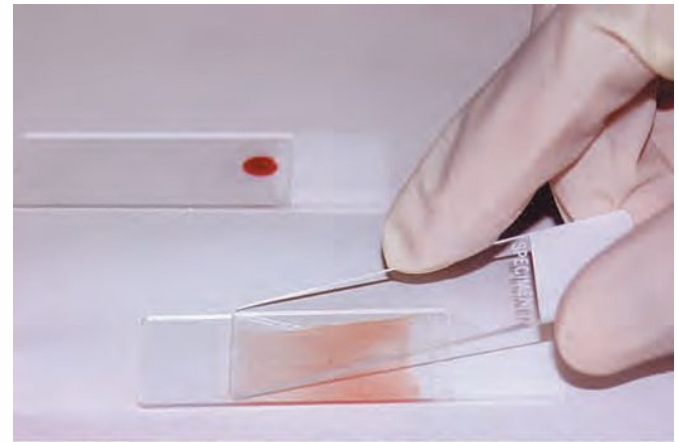
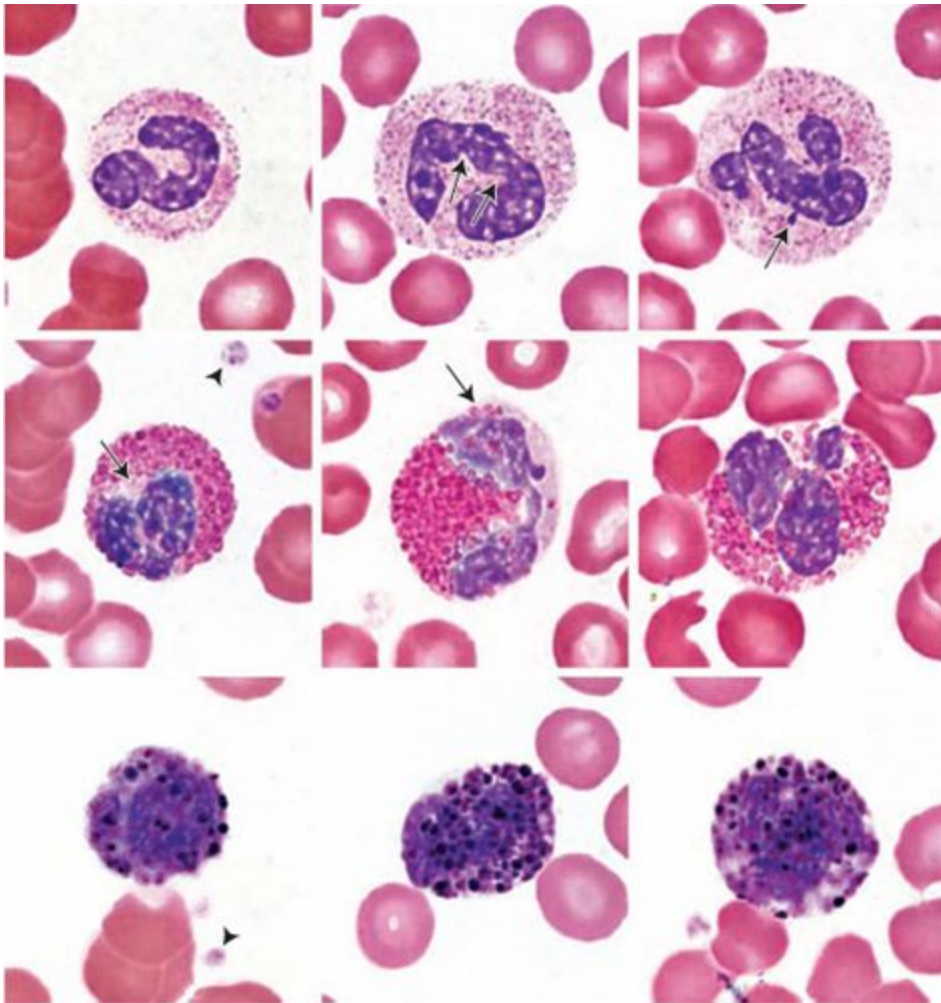
80



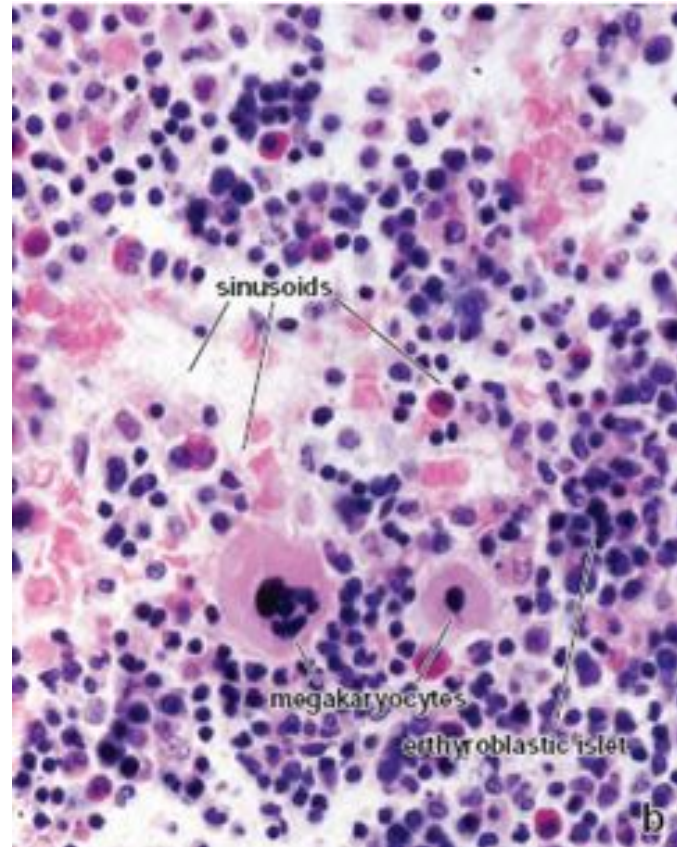
90



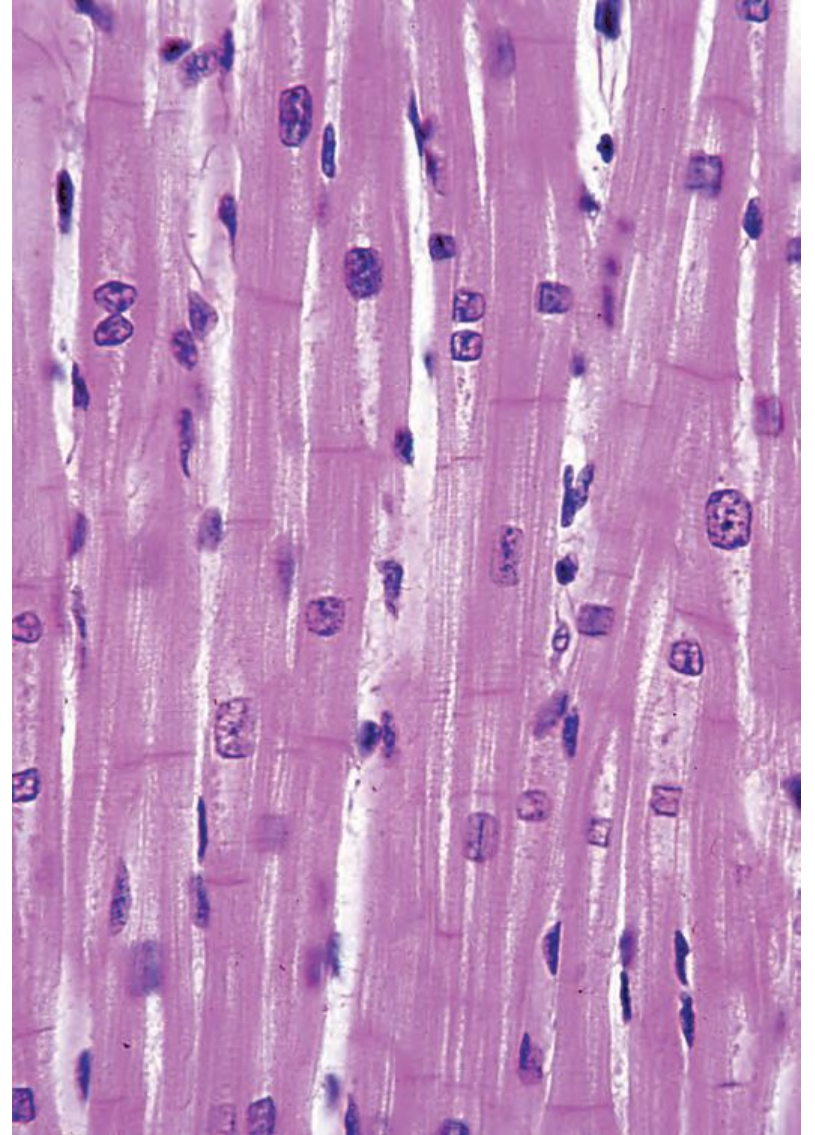
16



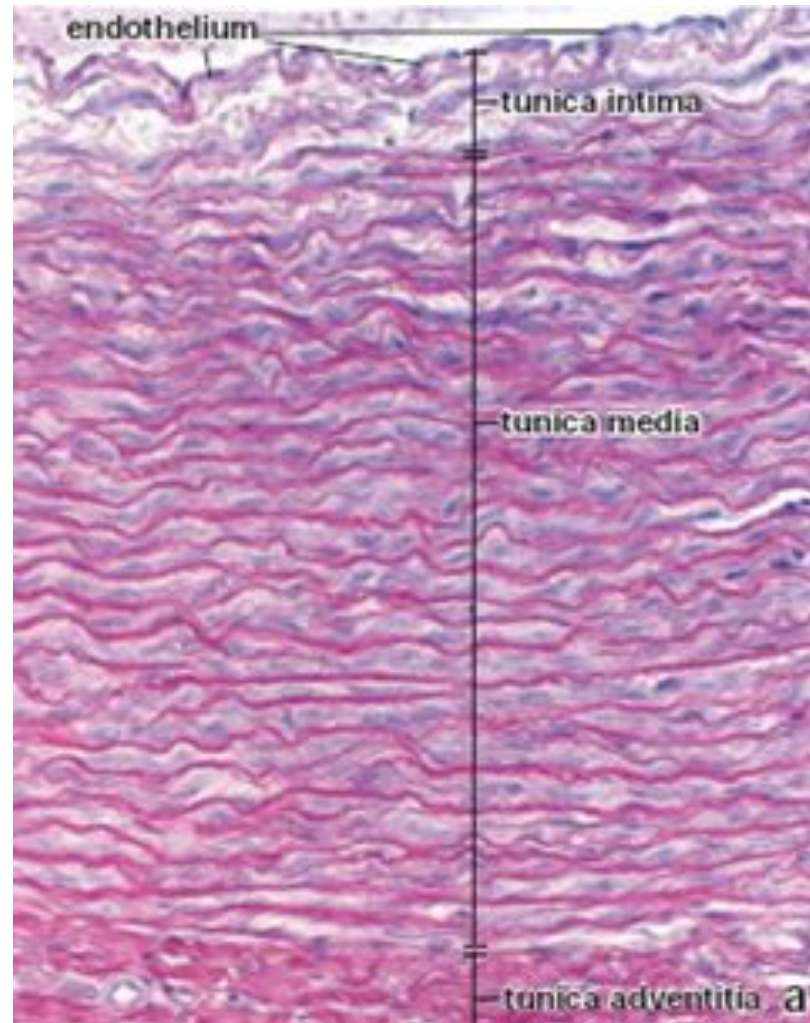
70



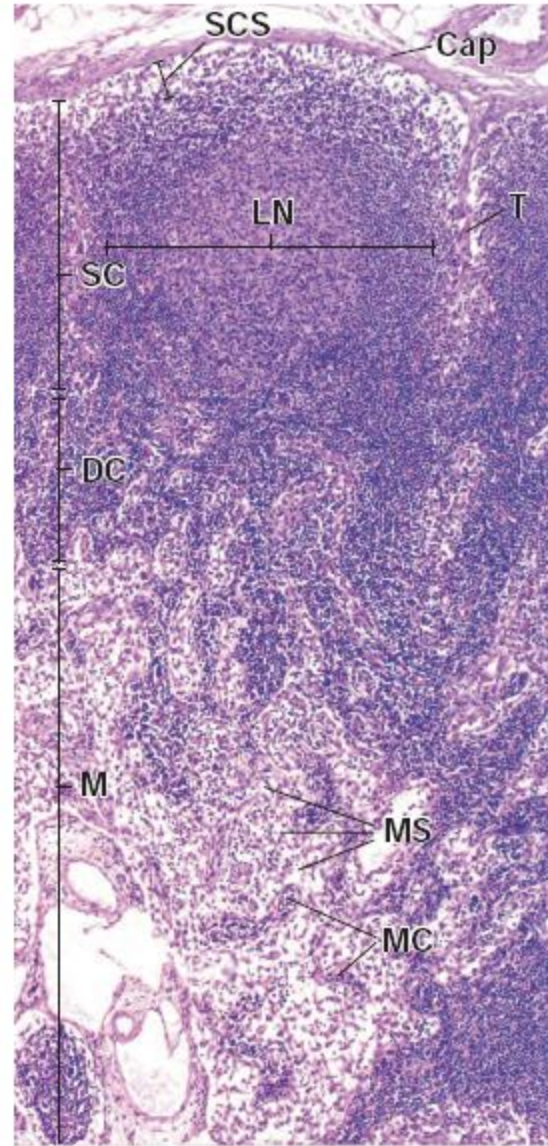
55



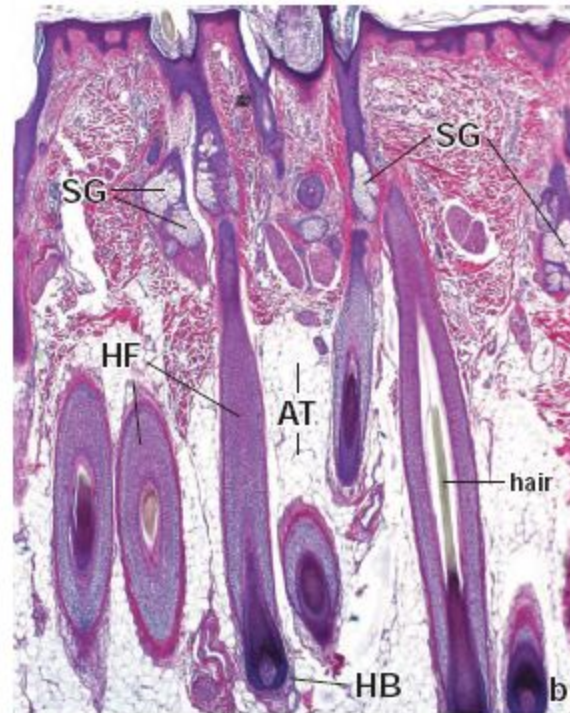
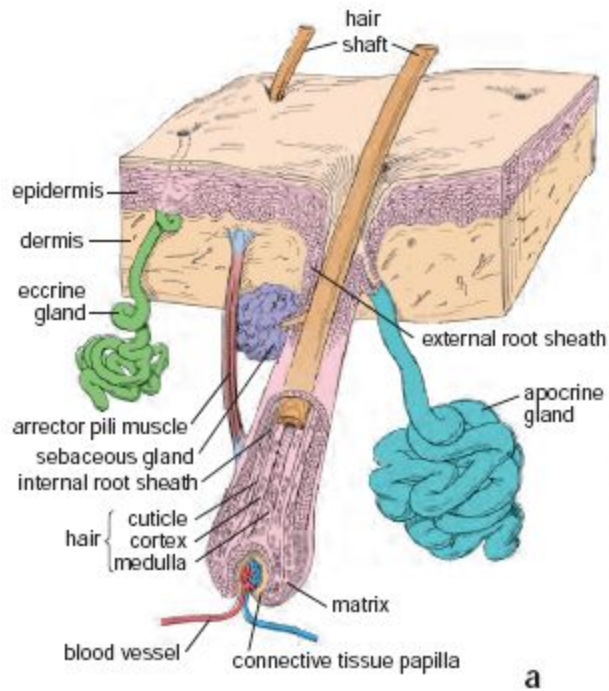
53

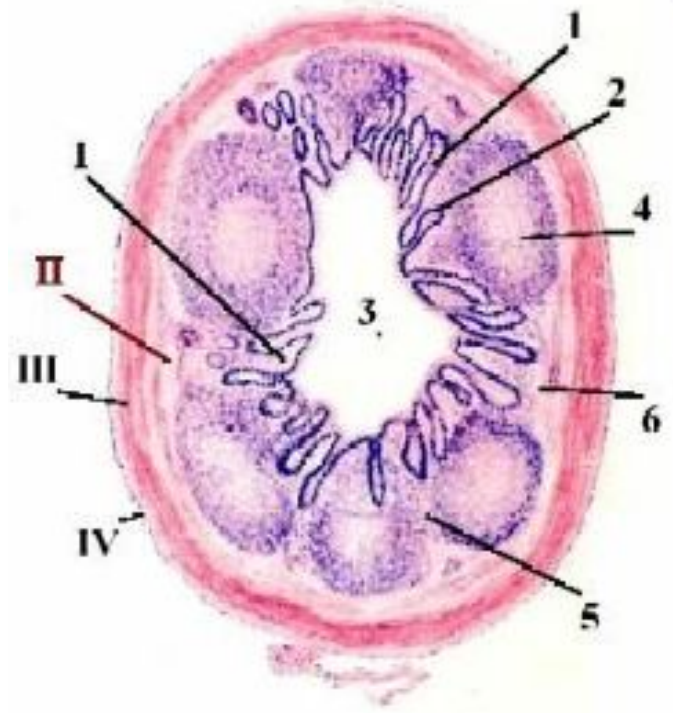
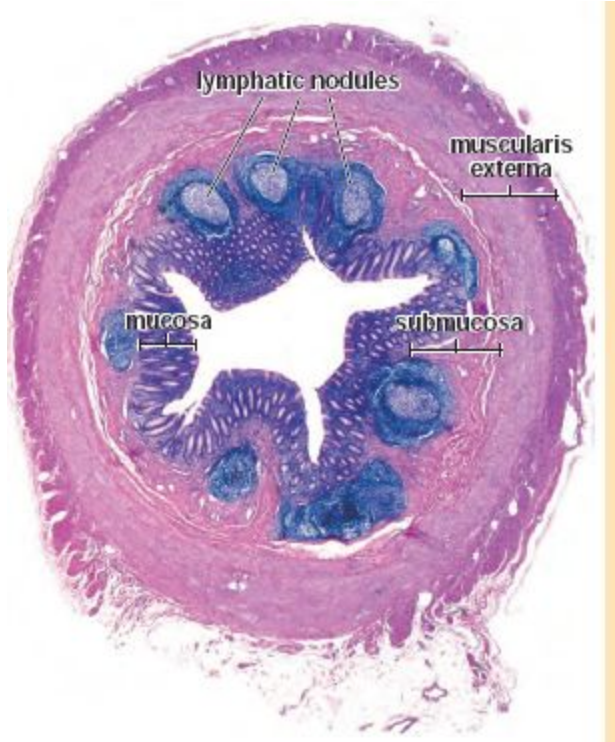


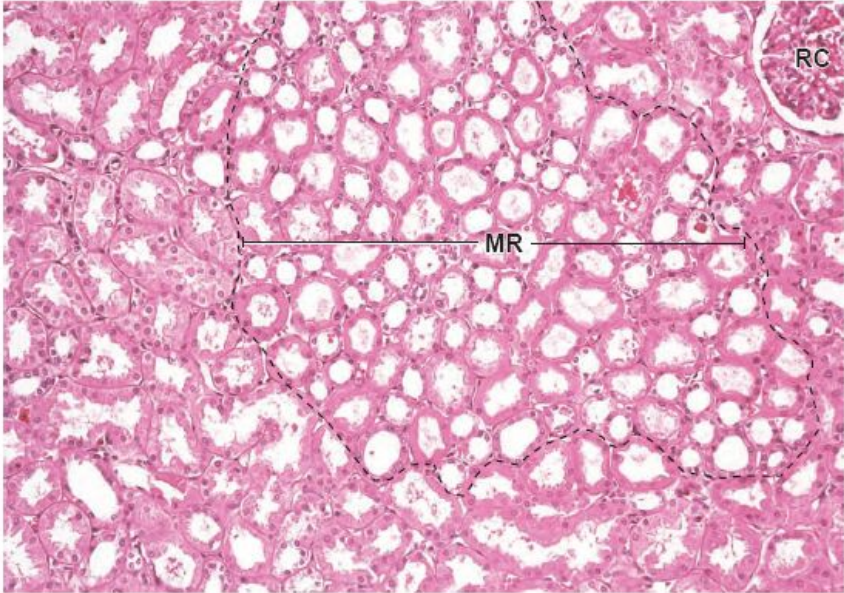
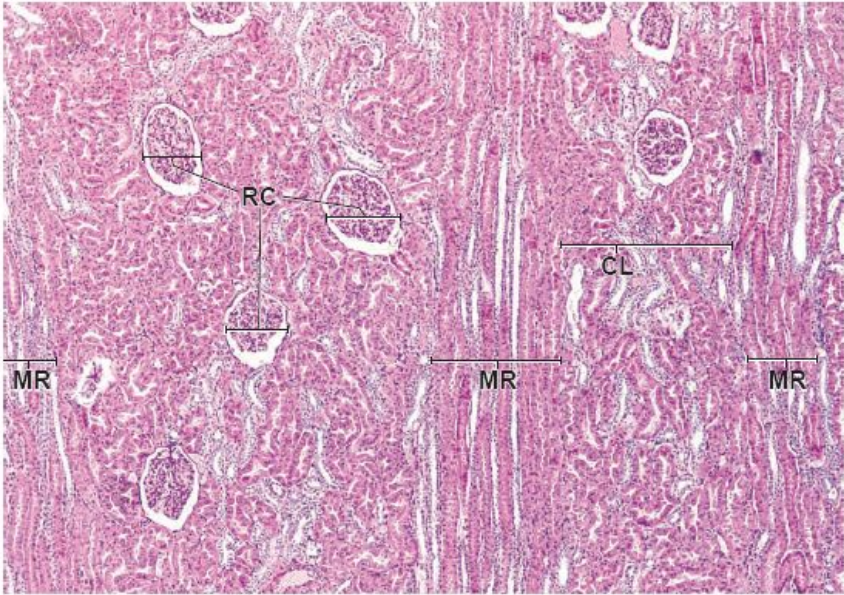
66



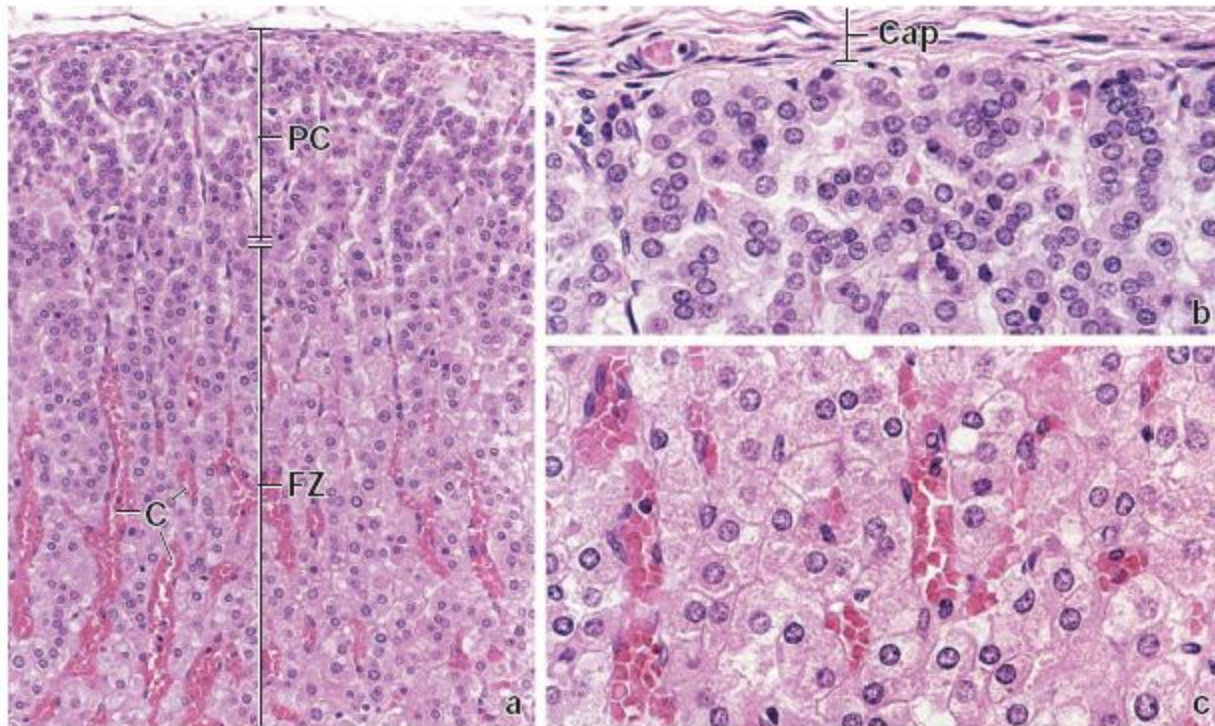
58



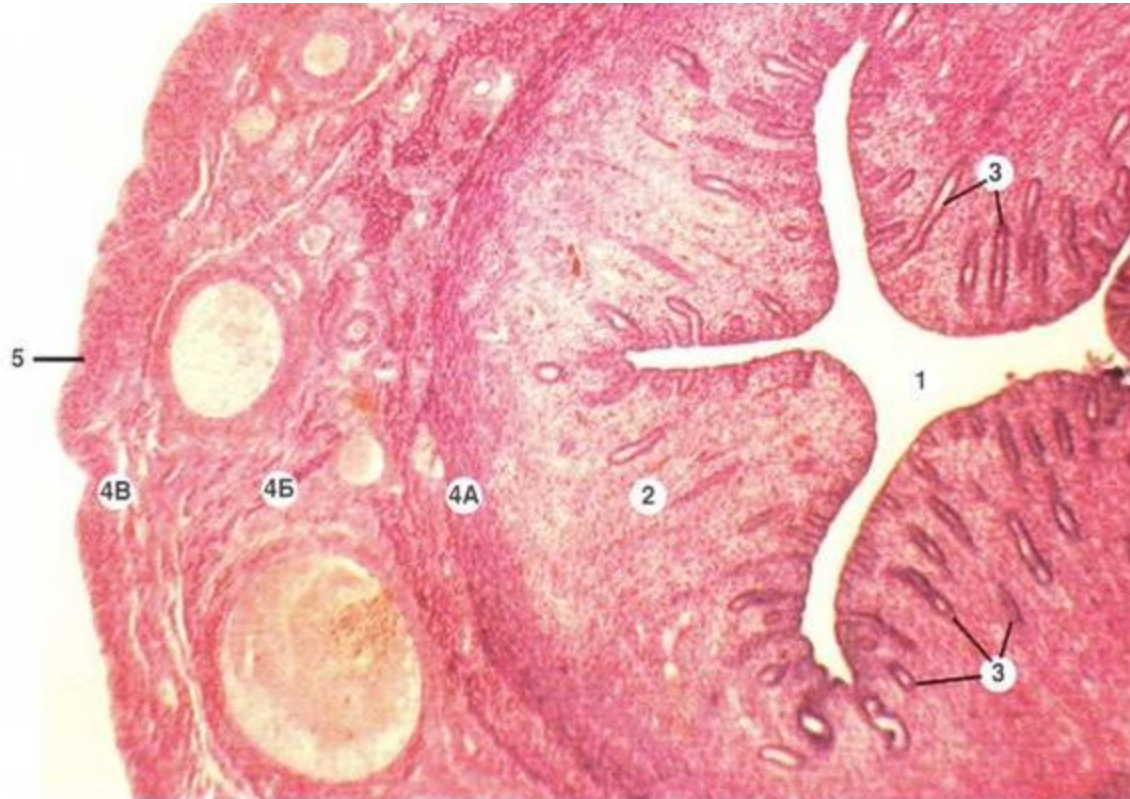




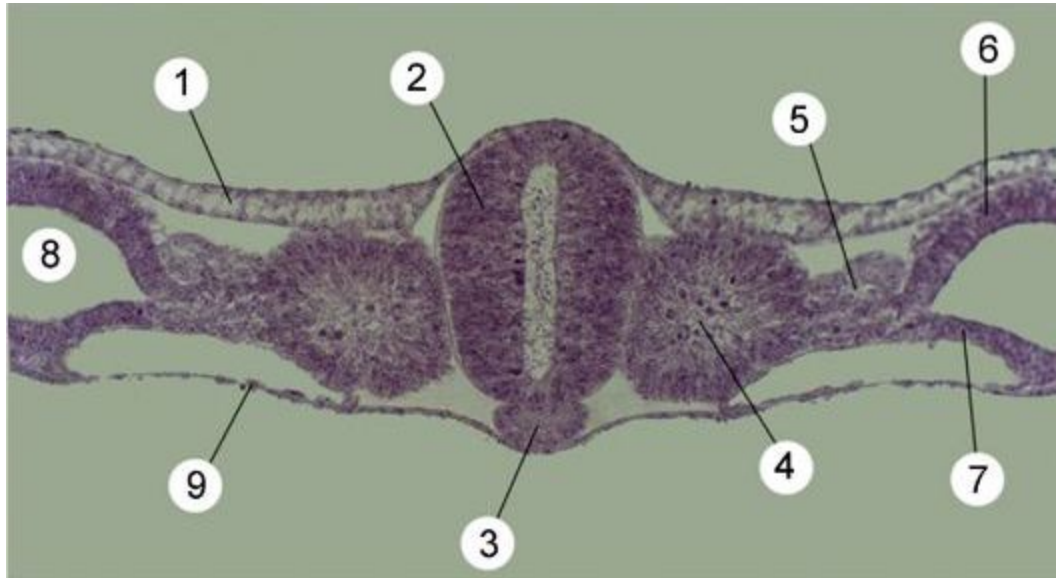
76



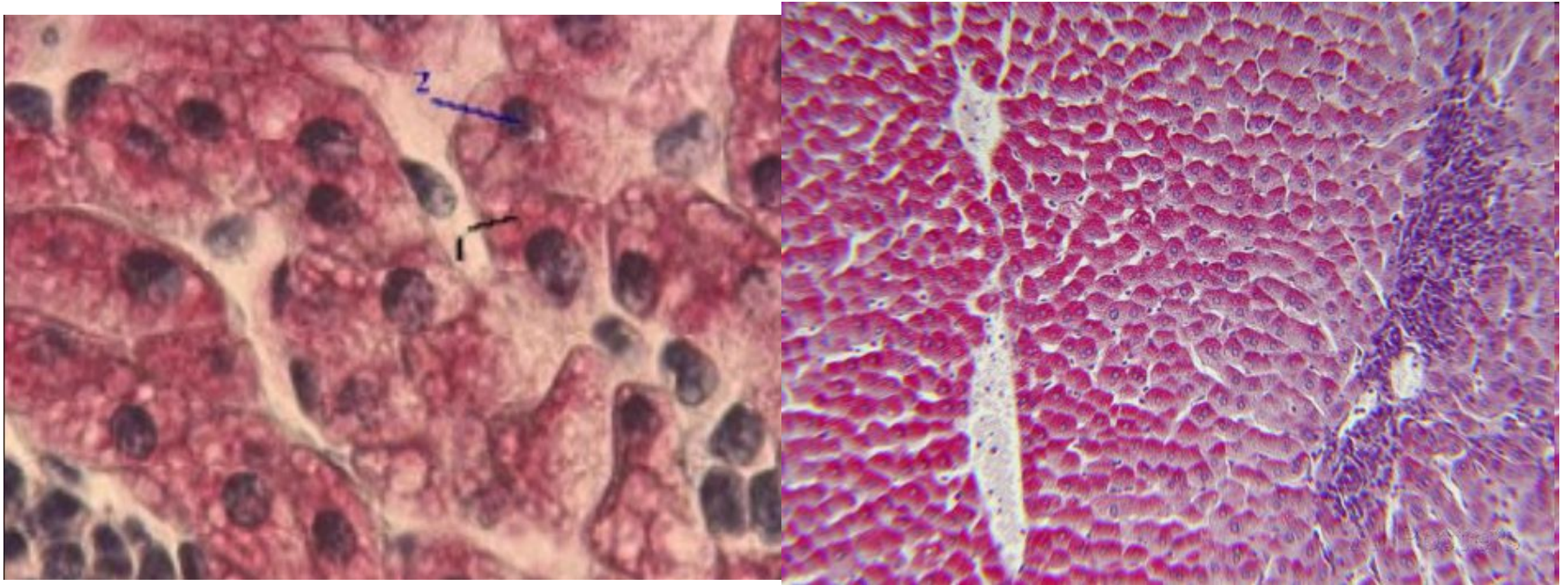
103



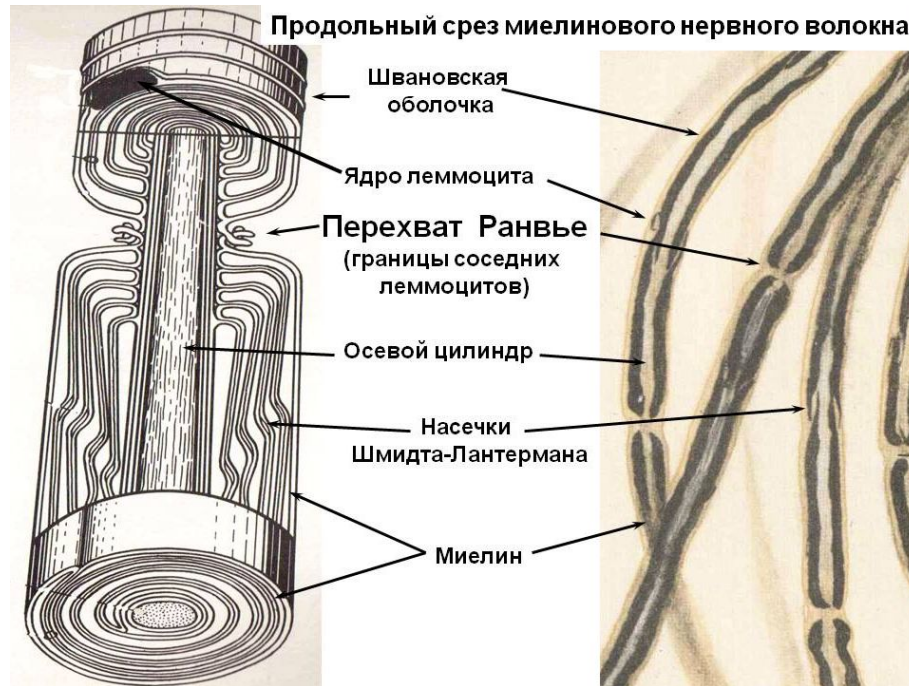
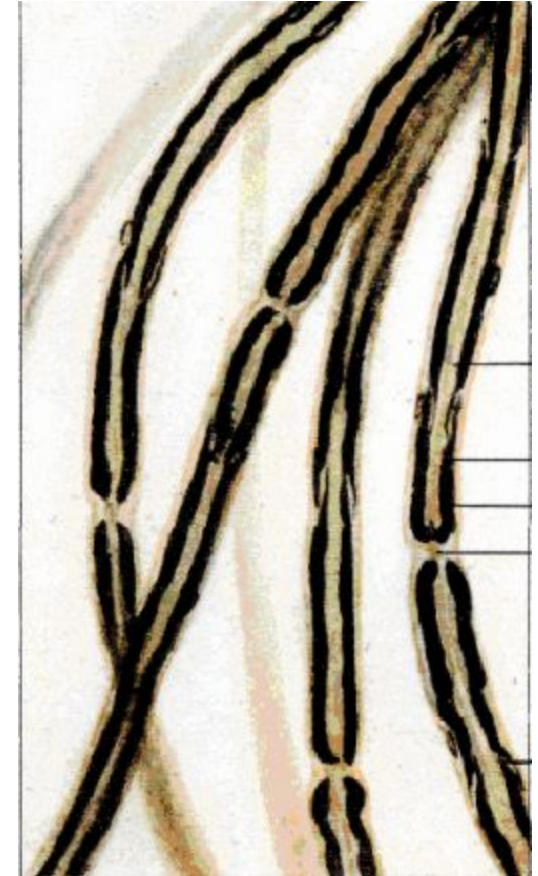
8



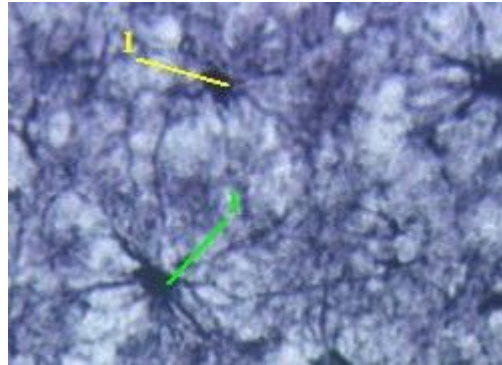
4



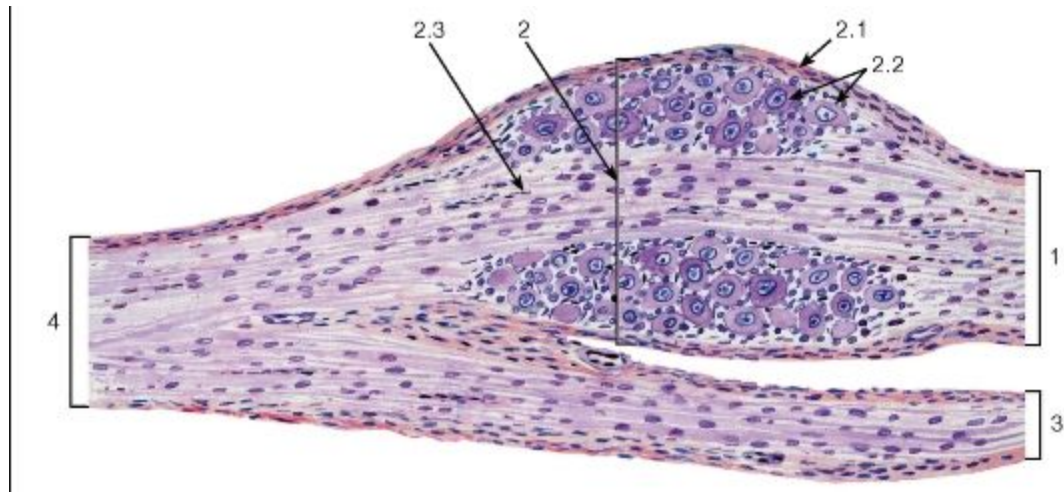
37



38

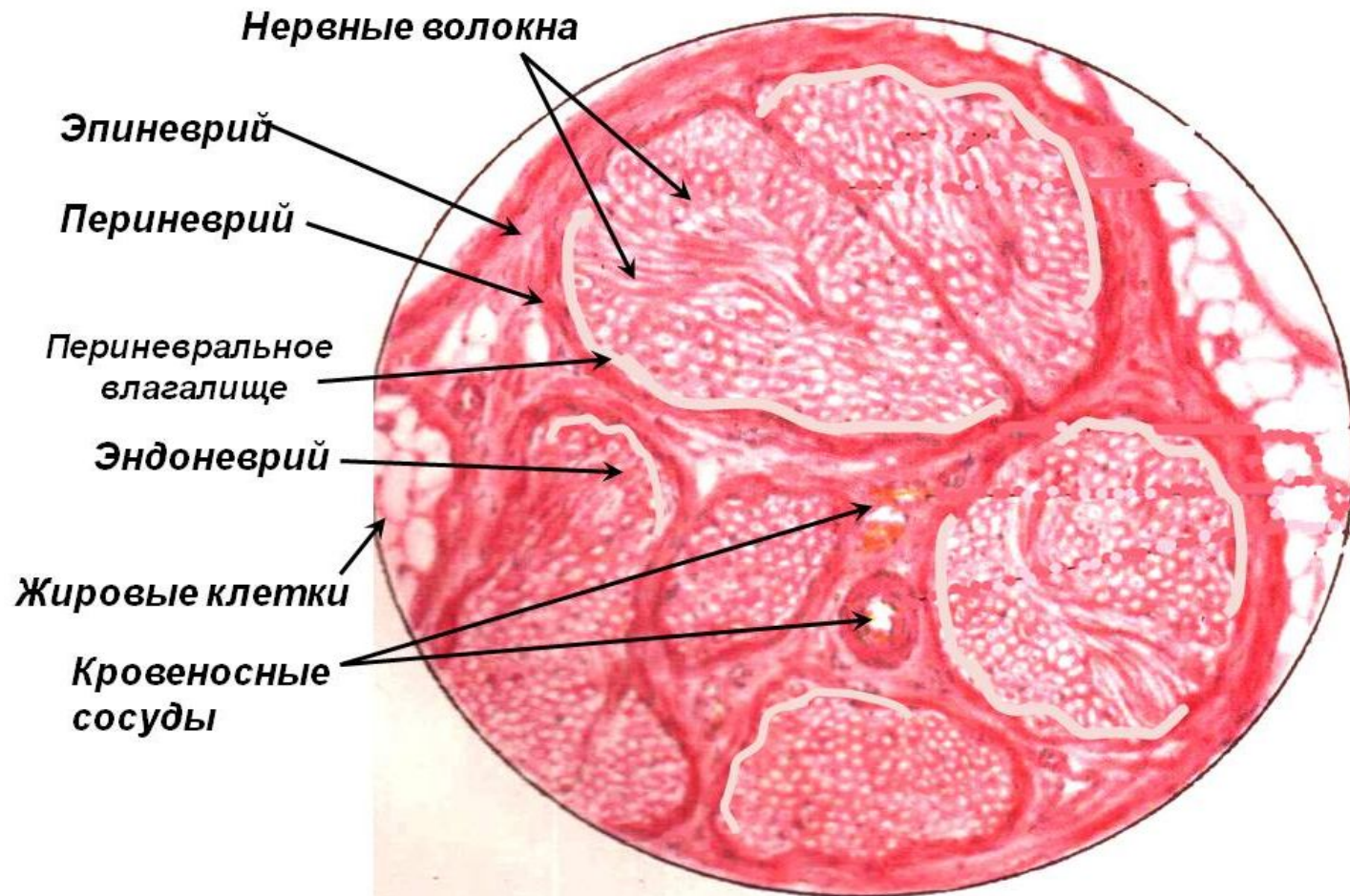


43

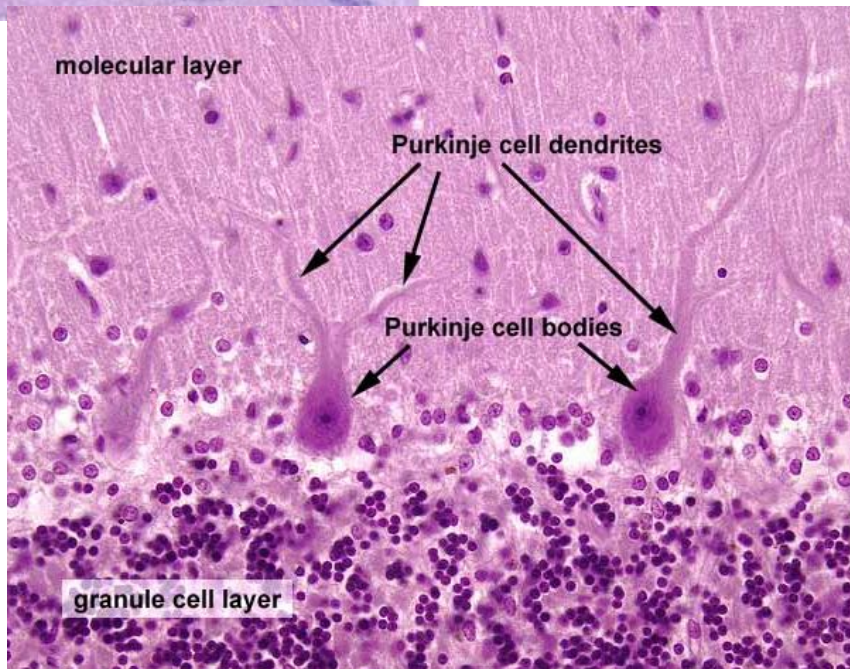
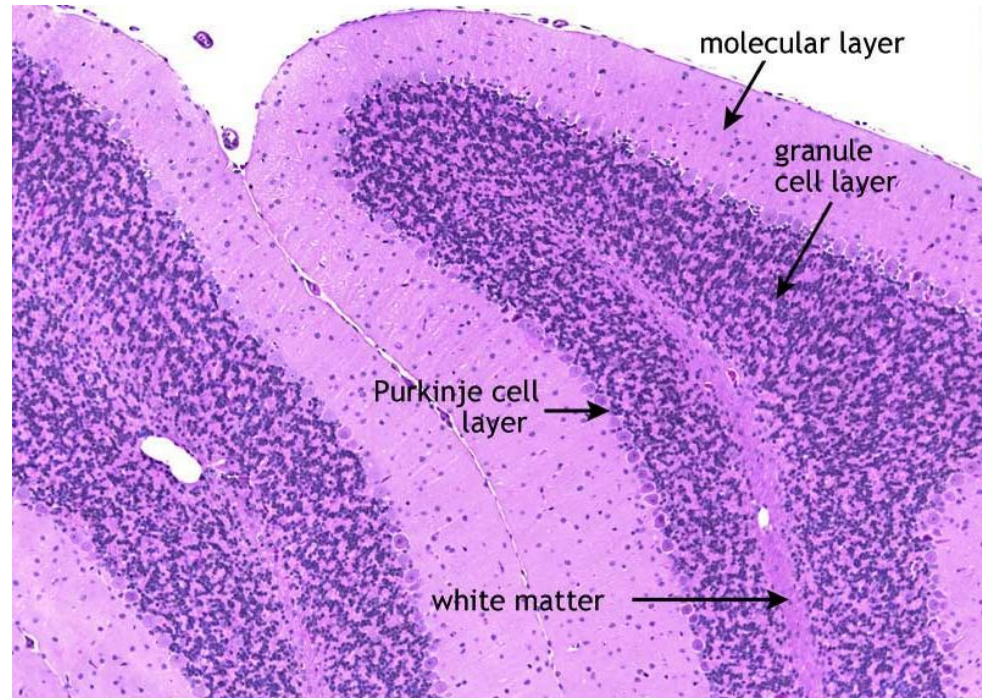
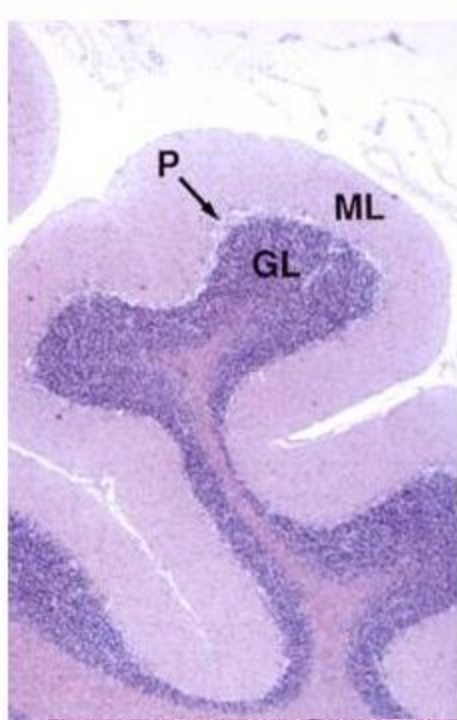


45

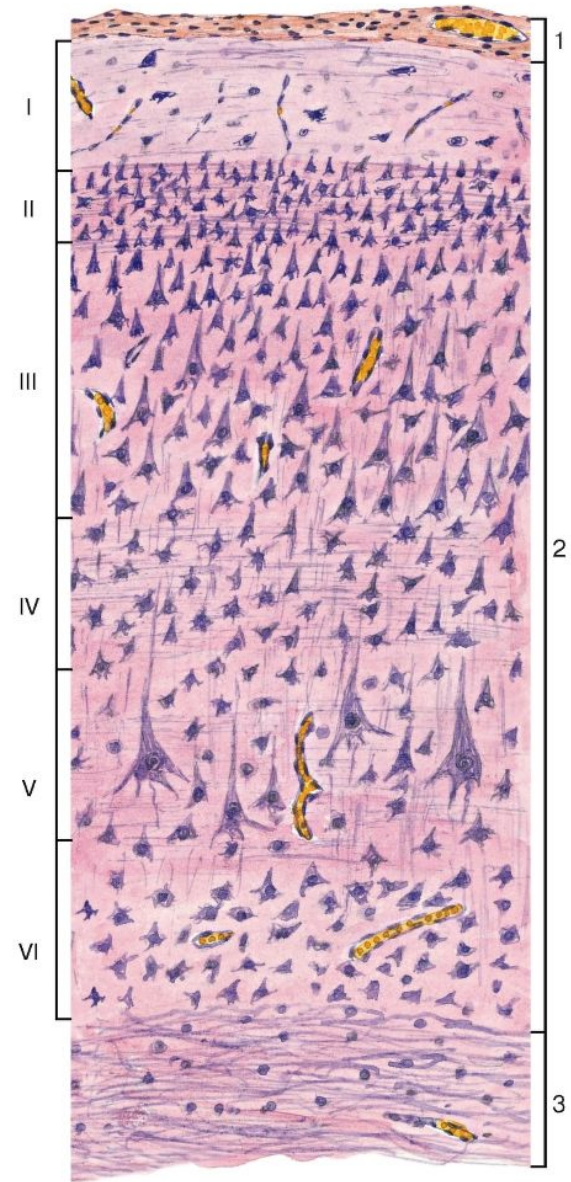
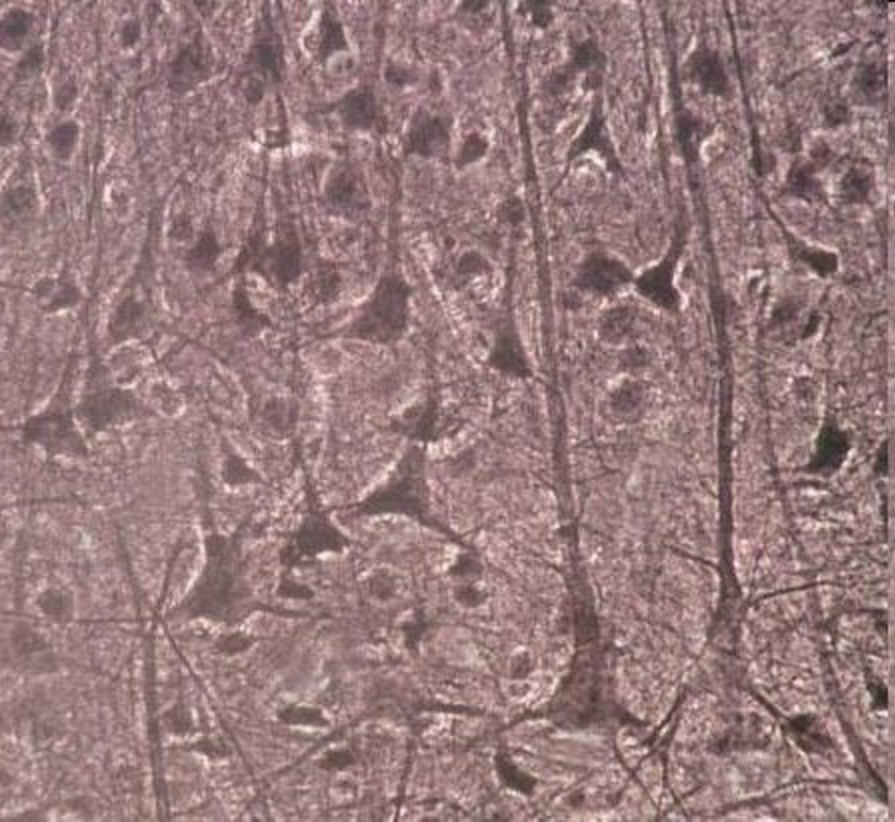
Поперечный срез нерва



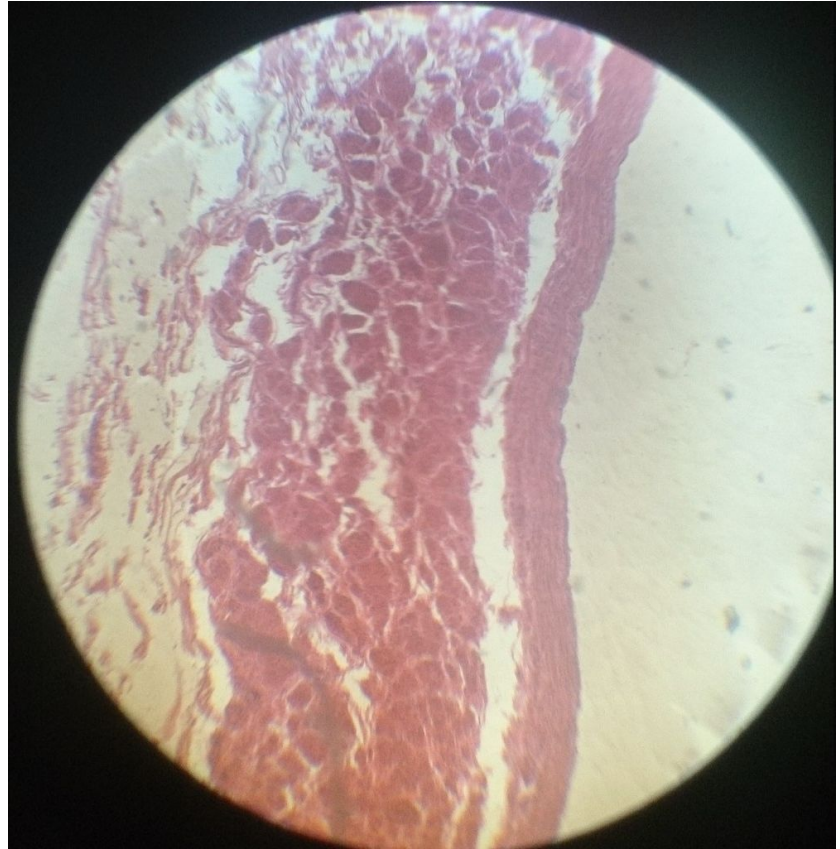
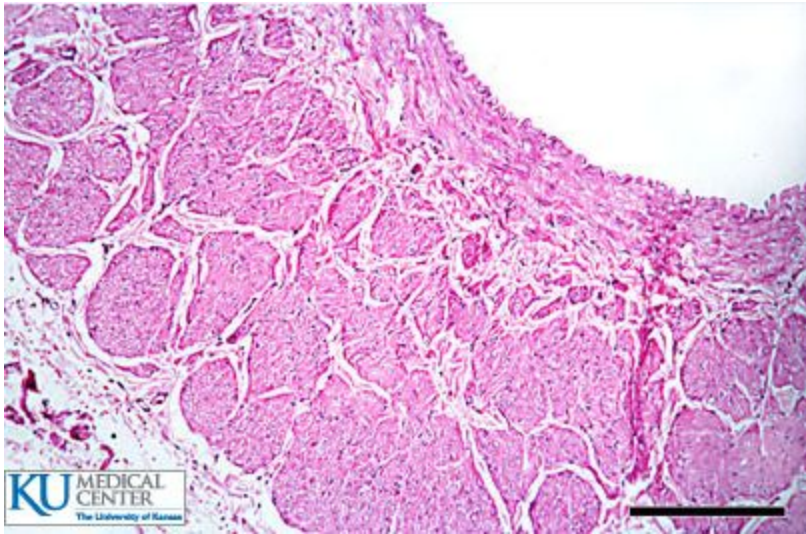
- Молекулярный
- Ганглионарный
- Зернистый



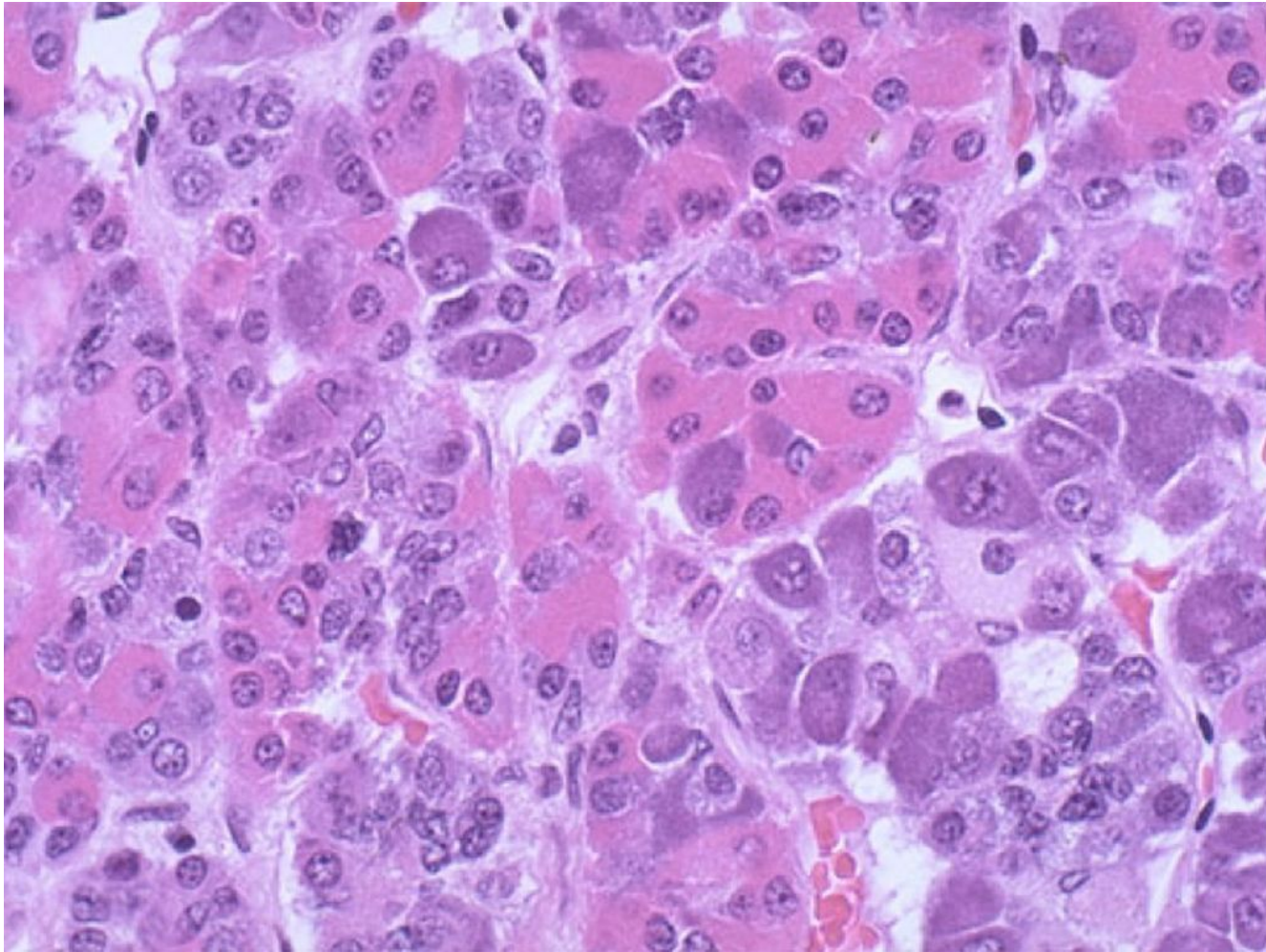
48



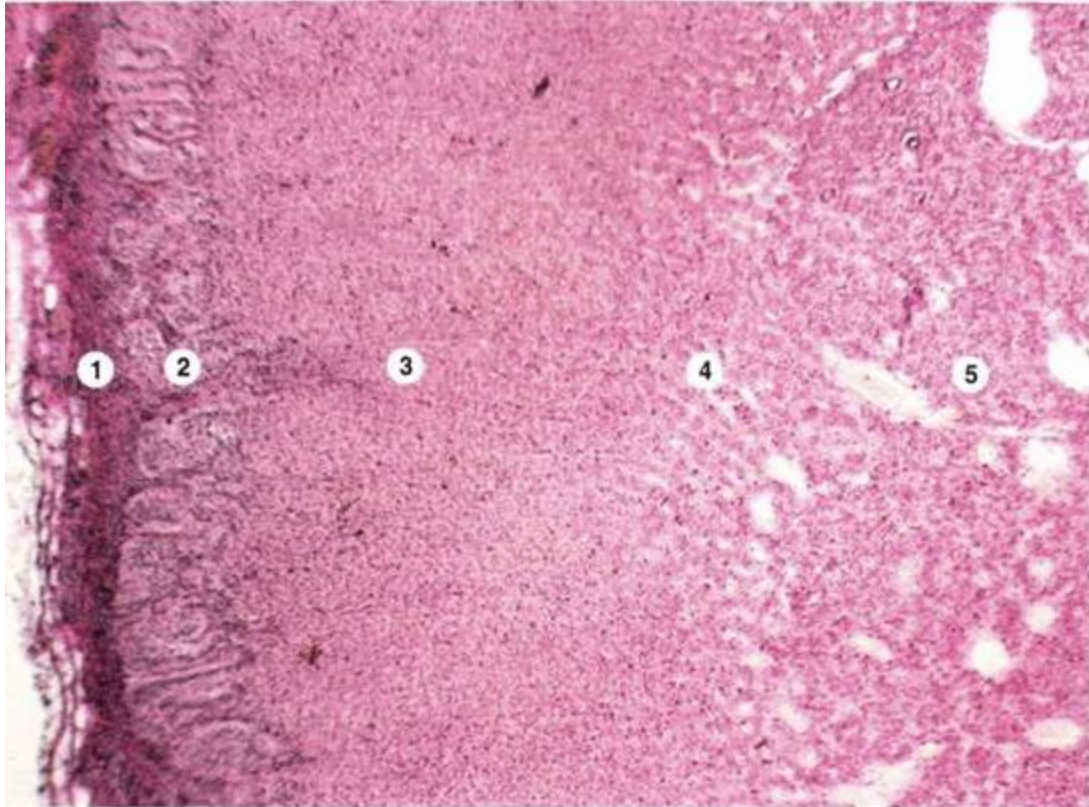
54



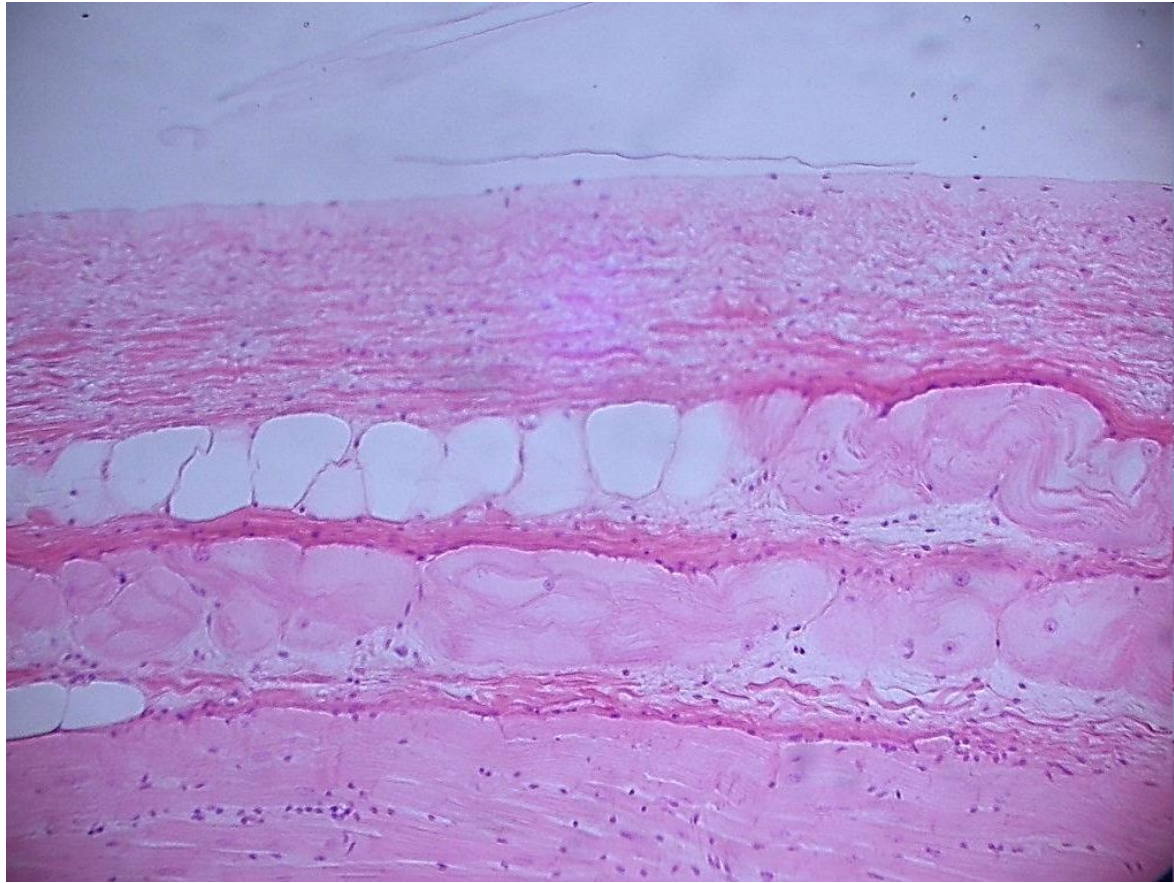
75/1



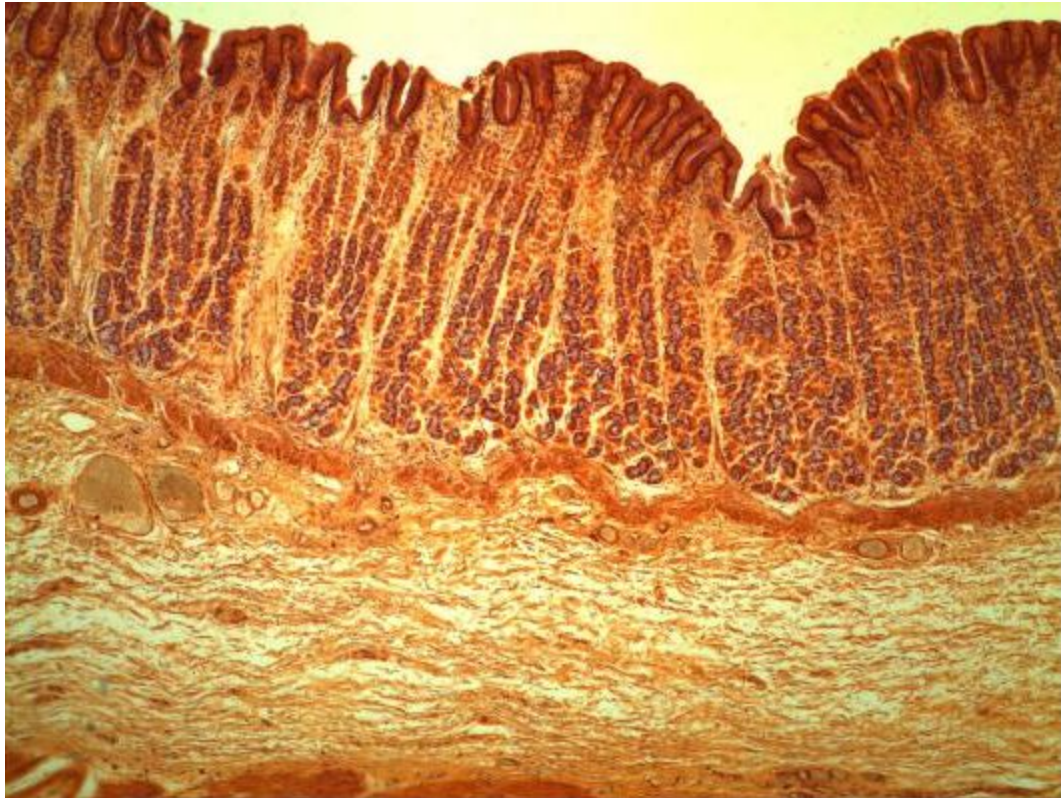
76



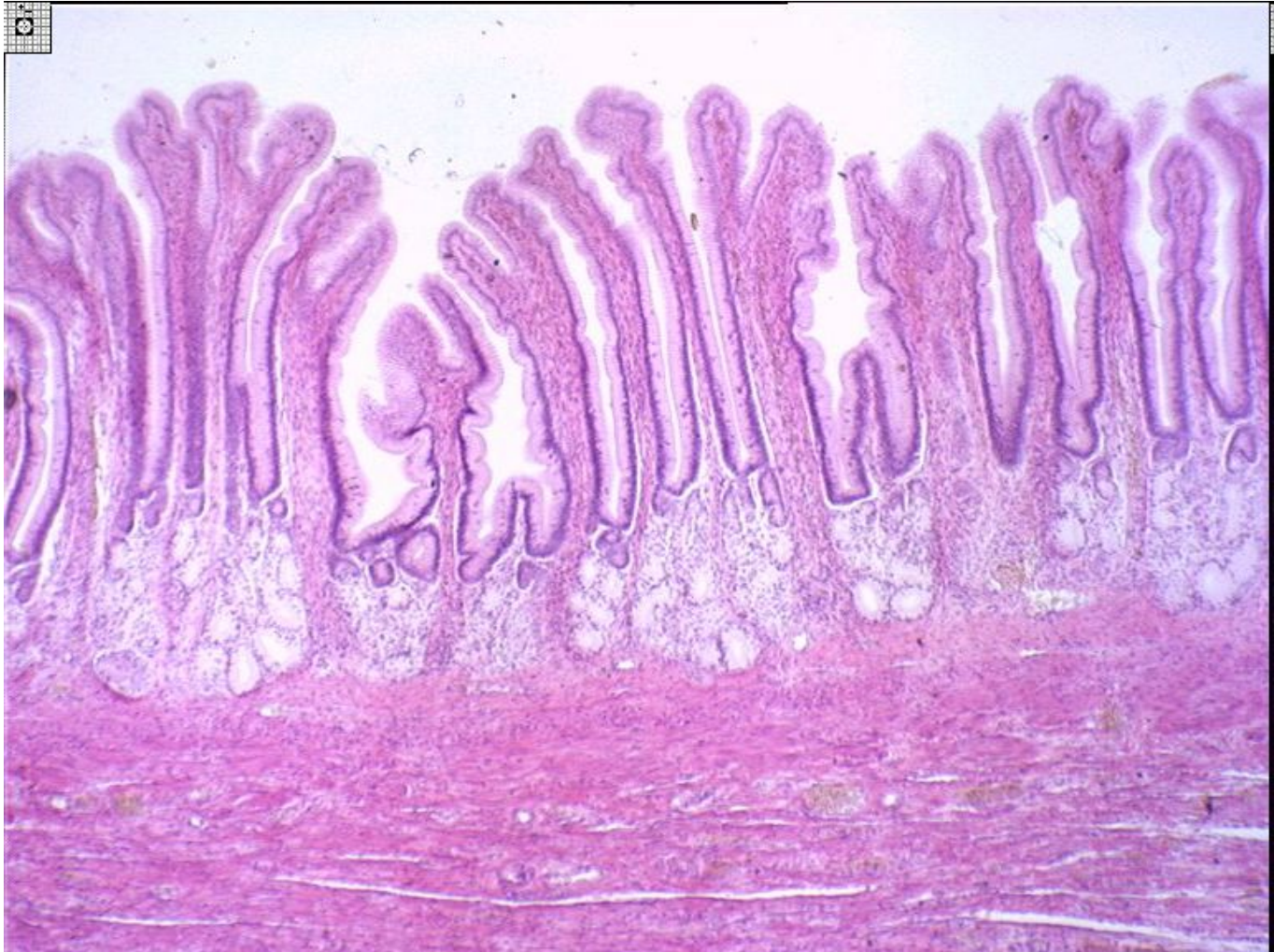55



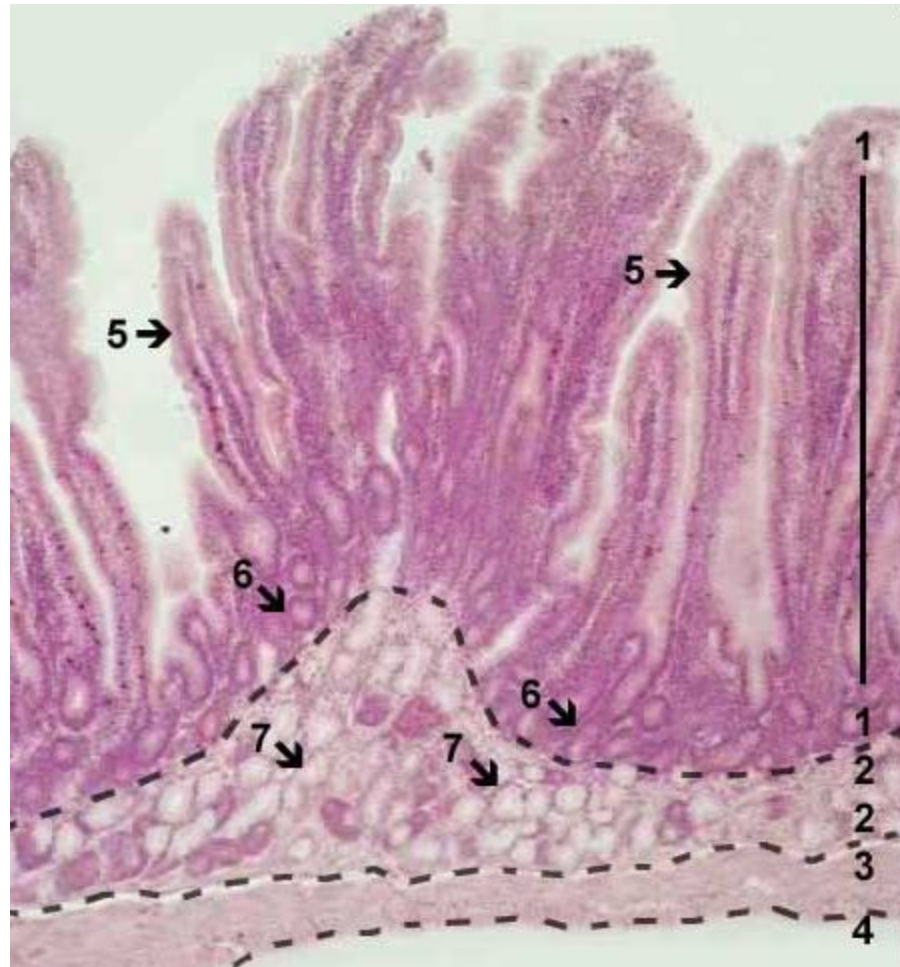84



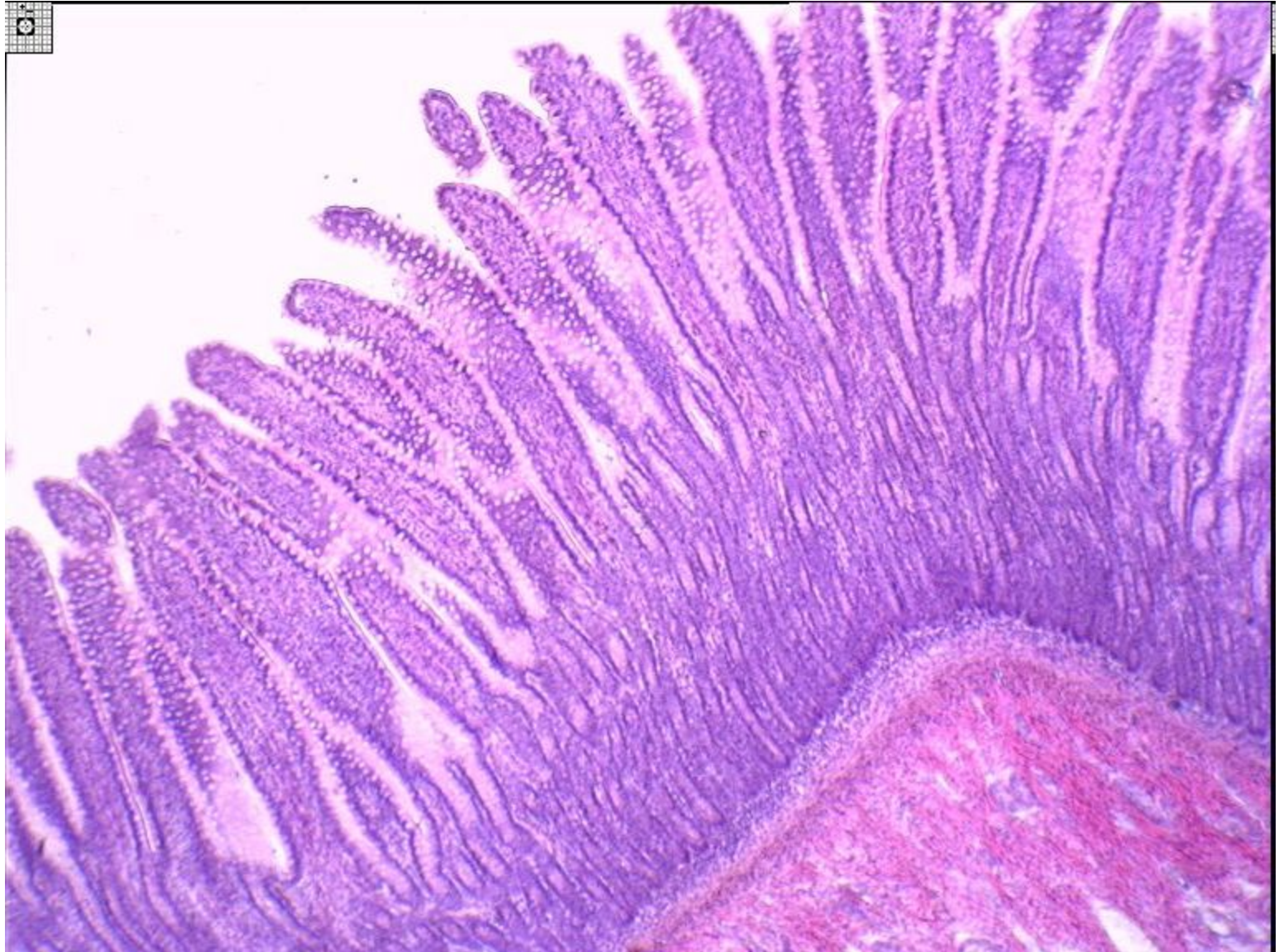
85



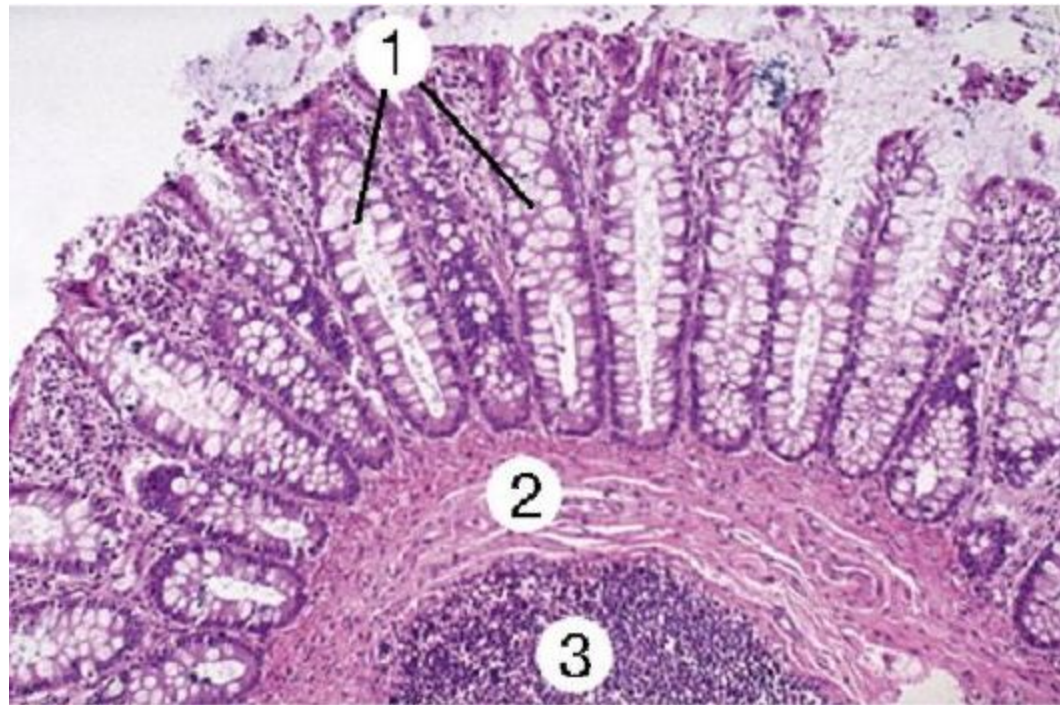
86



87



88



51

