Нарушения проводимости

Структура и функции проводящей системы сердца

Структура	Функция
Синоатриальный узел	Доминантный пейсмейкер сердца. Собственная частота 60-100/мин.
Межузловые пучки	Проведение импульса между СА и АВ узлами.
Атриовентрикулярный узел	Замедление проведения импульса на желудочки. Собственная частота 40-60/мин.
Пучок Гиса	Проведение импульса от АВ узла к ножкам.
Левая ножка	Проведение импульса к левому желудочку.
Правая ножка	Проведение импульса к правому желудочку.
Система Пуркинье	Сеть волокон, проводящая импульс в стенках желудочков. Собственная частота 20-40/мин.

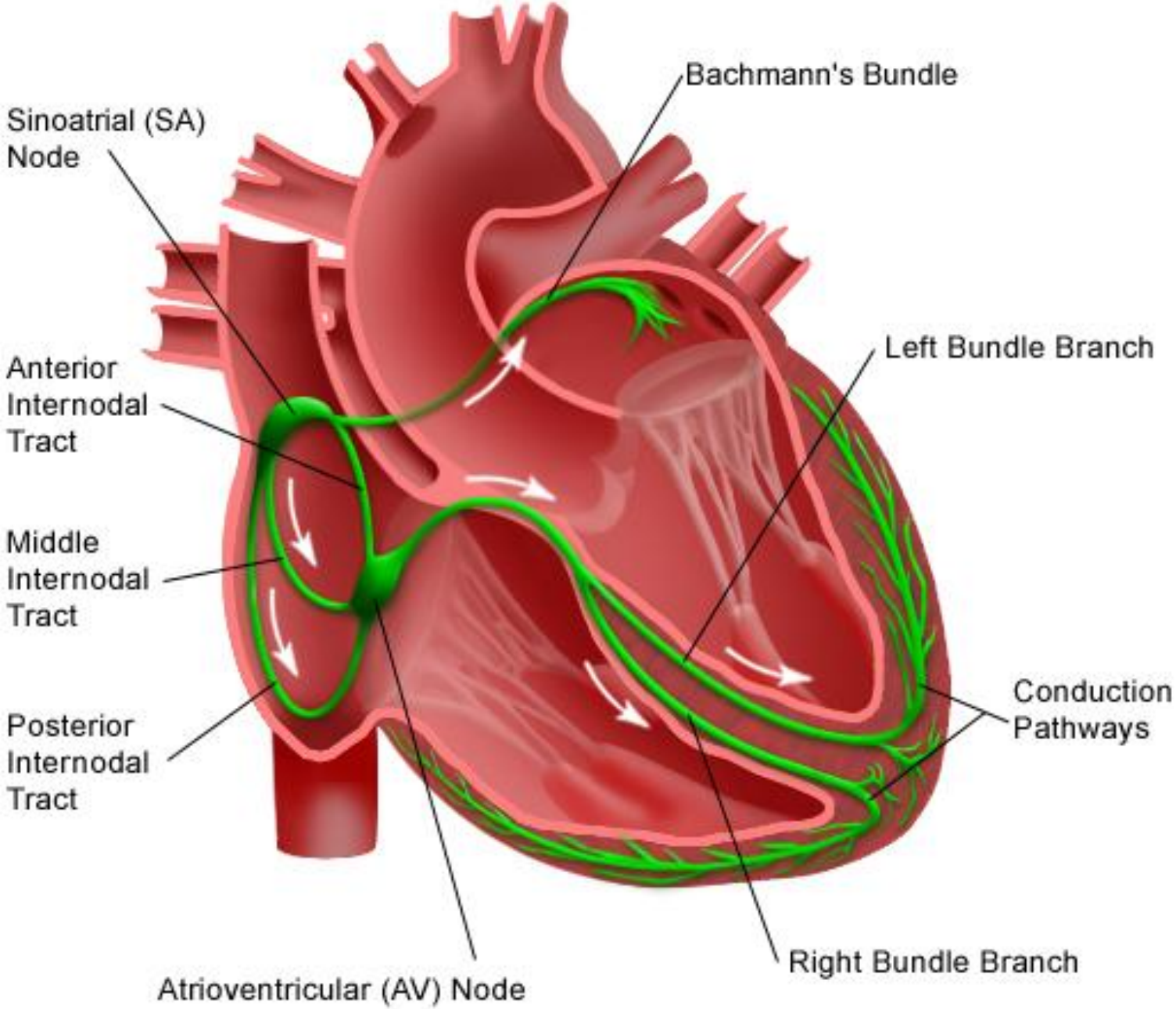
Bachmann's Bundle
Sinoatrial (SA) Node
Left Bundle Branch
Anterior Internodal Tract
Middle Internodal Tract
Conduction Pathways
Posterior Internodal Tract
Right Bundle Branch
Atrioventricular (AV) Node

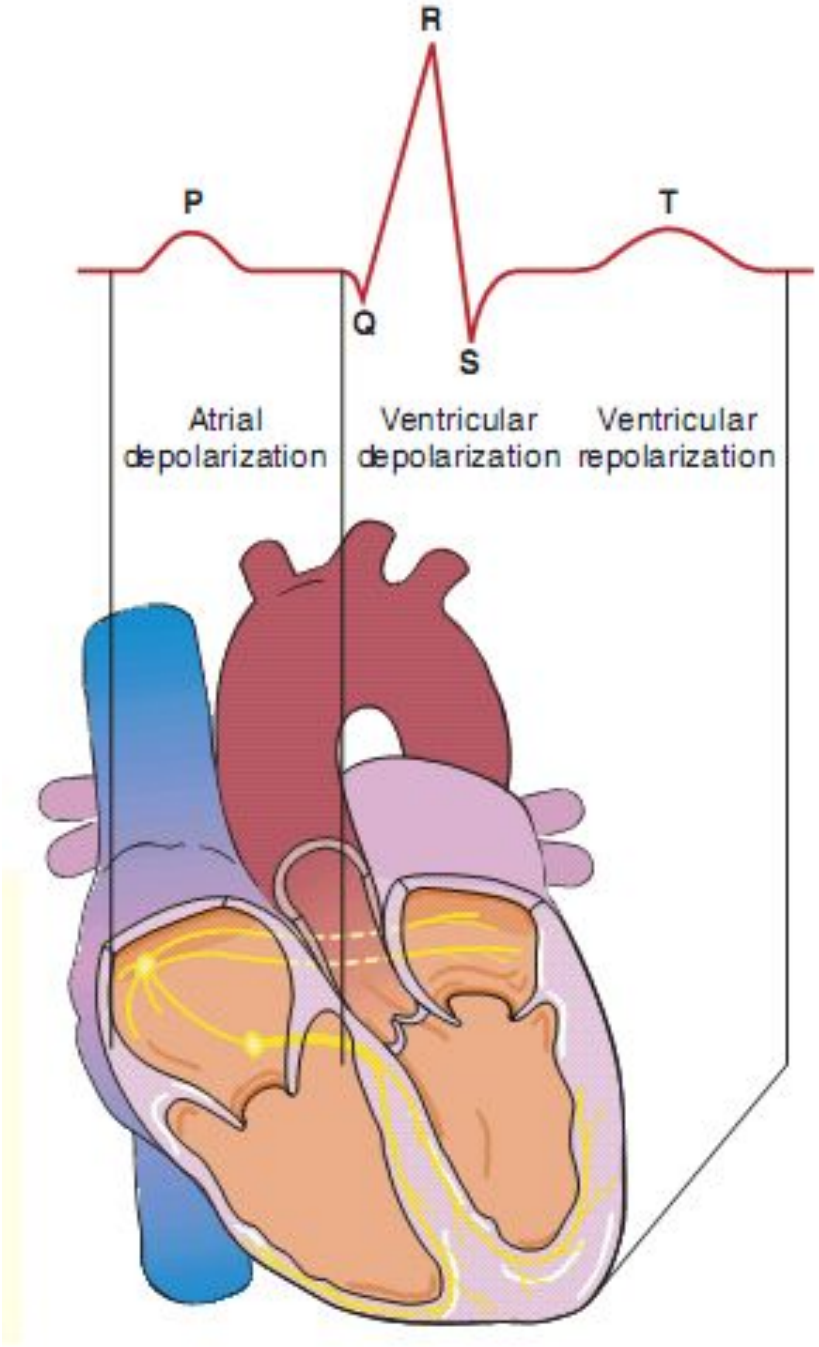

- Формирование ЭКГ-комплексов

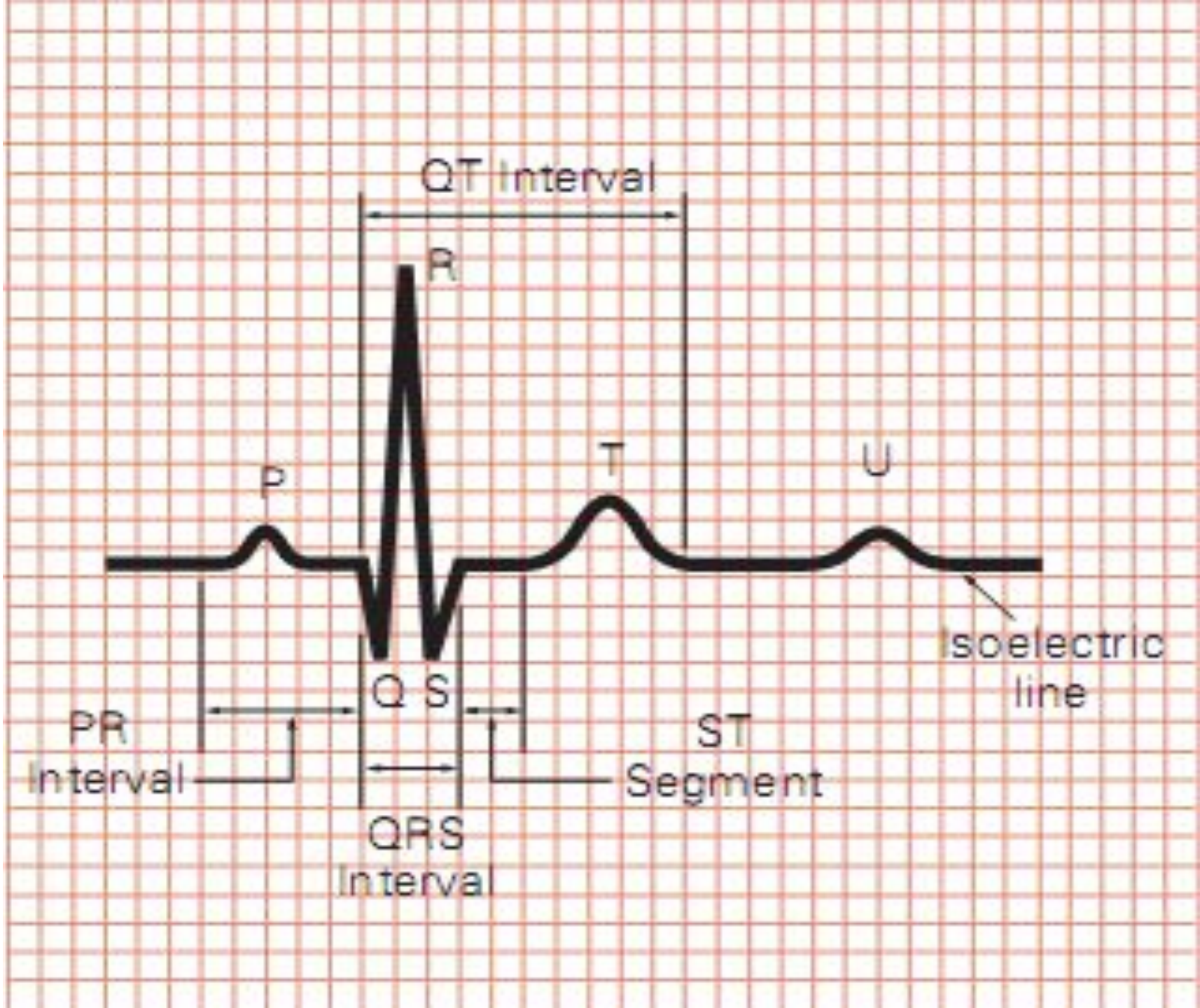
QT Interval
R
P
T
U
Isoelectric line
Q S
PR Interval
ST Segment
QRS Interval

Определение ЧСС

Нормальный синусовый ритм

- Нормальная частота (60-100/мин)
- Ритм регулярный
- P-зубец нормальный (положительный и униформный)
- PR-интервал нормальный (0,12-0,20 сек)
- QRS нормальный (0,06-0,10 сек)

Синусовая пауза

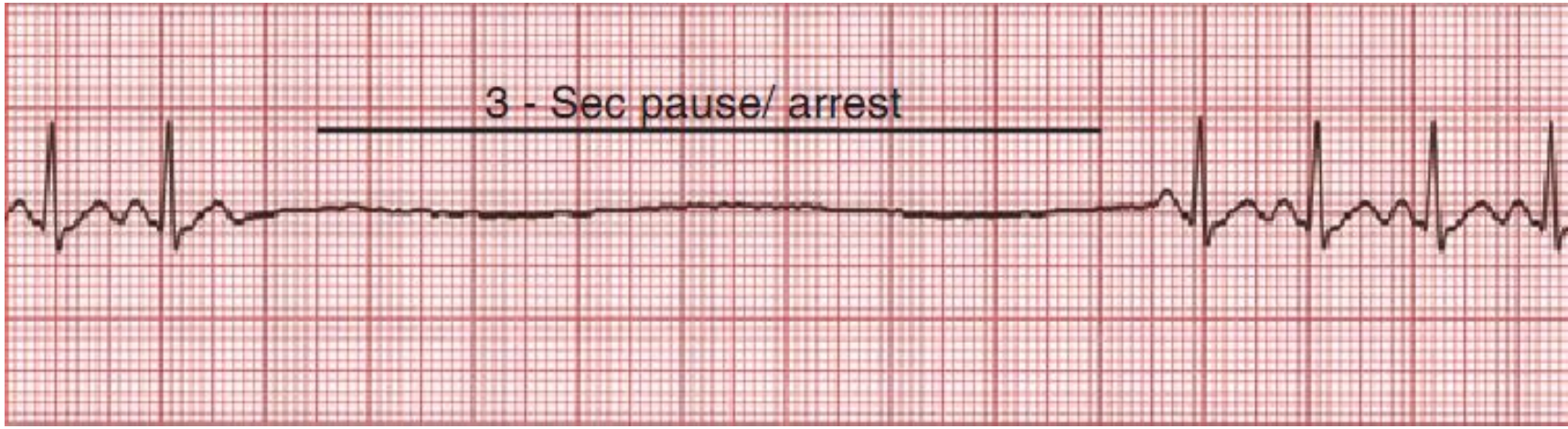

- Частота нормальная или сниженная (определяется частотой и продолжительностью пауз)
- Ритм нерегулярный при паузах
- Р-зубцы нормальные, кроме участков выпадения импульса
- **PR**-интервал нормальный
- **QRS** нормальный

Сердечный импульс снижается, что может быть причиной синкопе или головокружения

Синоатриальная блокада

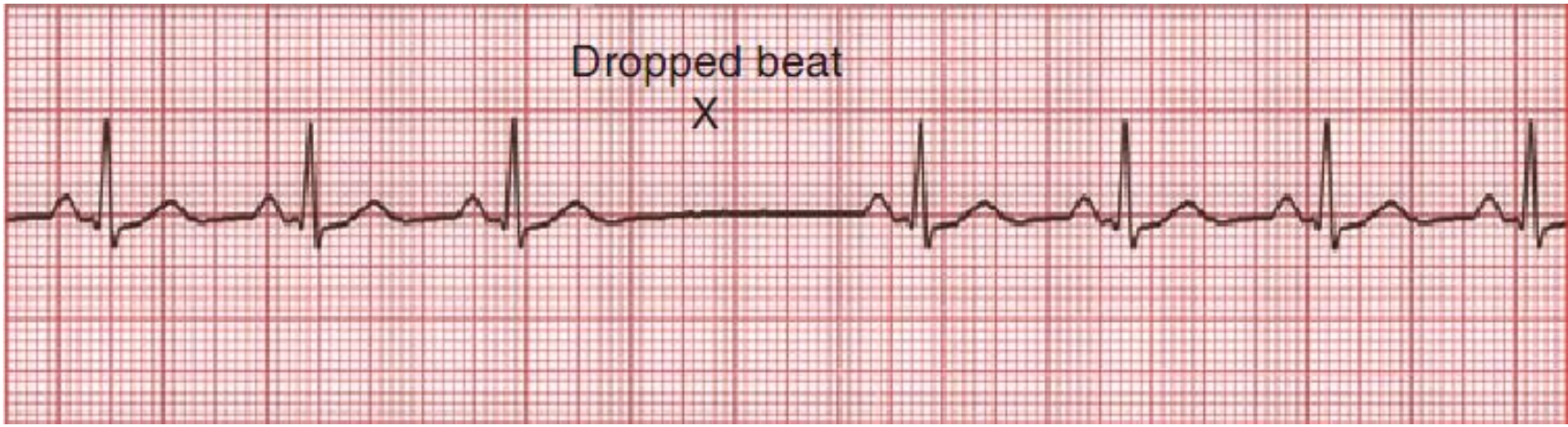

- Частота нормальная или сниженная (определяется частотой и продолжительностью пауз)
- Ритм нерегулярный при паузах
- P-зубцы нормальные, кроме участков пауз
- **PR**-интервал нормальный
- **QRS** нормальный

Сердечный импульс снижается, что может быть причиной синкопе или головокружения

WPW синдром

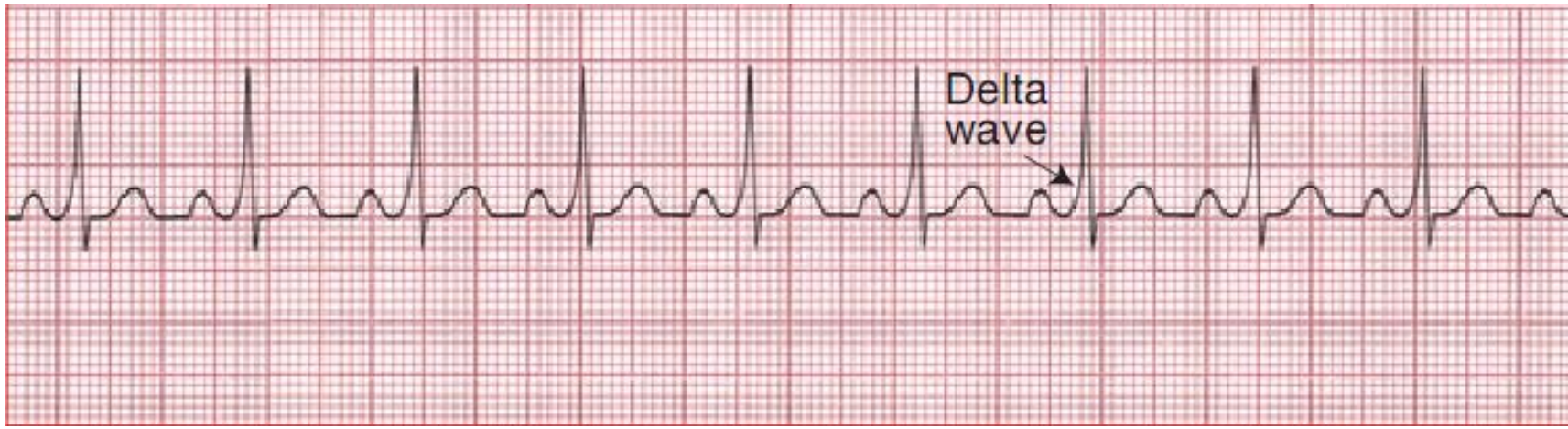

- Частота зависит от основного ритма
- Ритм регулярный
- P-зубец нормальный
- **PR**-интервал короткий (<0,12 сек), если P-зубец присутствует
- **QRS** широкий (>0,10 сек); дельта-волна

Дополнительные пучки между A и V, быстро проводящие импульс. Связан с тахикардиями с узким комплексом, включая трепетание и фибрилляцию предсердий.

АВ блокада 1 степени

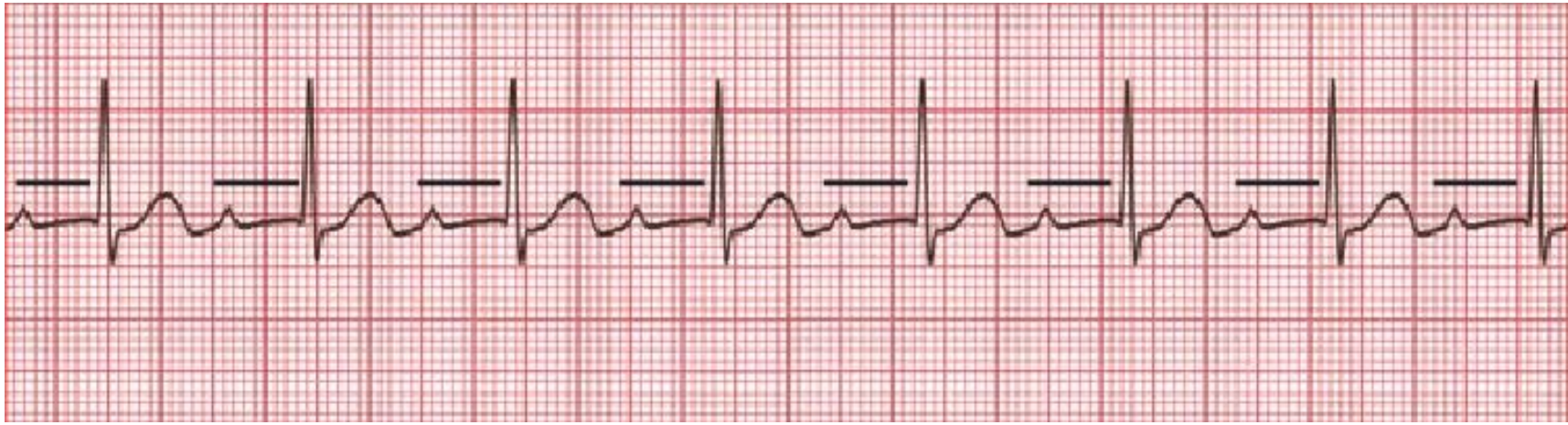

- Частота зависит от основного ритма
- Ритм регулярный
- Р-зубец нормальный
- **PR**-интервал длинный (>0,20 сек), если Р-зубец присутствует
- **QRS** нормальный

Клинически обычно благоприятна, но если связана с ОИМ, может привести к нарушению АВ проведения.

АВ блокада 2 степени (тип 1)

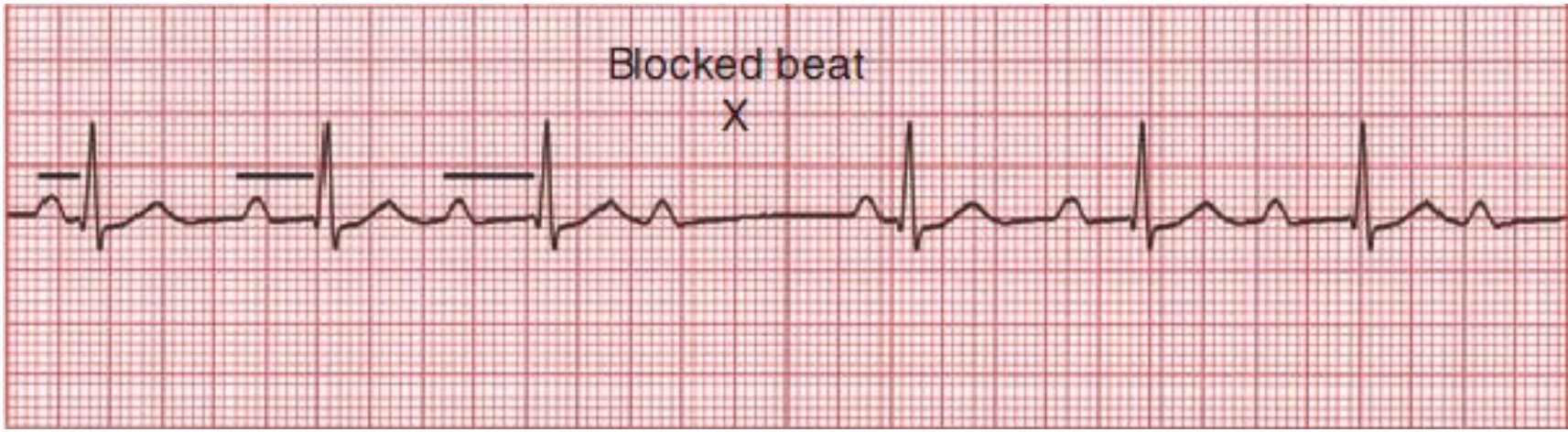

- Частота зависит от основного ритма
- Ритм нерегулярный
- Р-зубец нормальный
- **PR**-интервал: постепенное удлинение, пока один зР не будет блокирован и **QRS** выпадет
- **QRS** нормальный

М.б. обусловлен БАБ, дигоксином, АКК и ишемией (правая коронарная артерия). Mobitz I или Wenckebach.

АВ блокада 2 степени (тип 2)

- Частота предсердий (обычно 60-100/мин) больше частоты желудочков
- Ритм предсердий регулярный, желудочков нерегулярный
- Р-зубец нормальный
- **PR**-интервал: нормальный или удлиненный, но постоянный
- **QRS** обычно уширен (>0,10 сек)

Брадикардия может снижать сердечный выброс и приводить к полной АВ блокаде. Часто появляется при ишемии или ИМ

АВ блокада 3 степени

- Частота предсердий 60-100/мин, желудочков 40-60/мин (<40/мин, если из желудочков)
- Ритм обычно регулярный, но предсердия и желудочки сокращаются независимо
- Р-зубец нормальный; может наслаиваться на **QRS** и з**Т**
- **PR**-интервал: очень вариабельный
- **QRS** нормальный , если из АВ узла; широкий, если из желудочков

Полная поперечная блокада

Блокада ножки Гиса

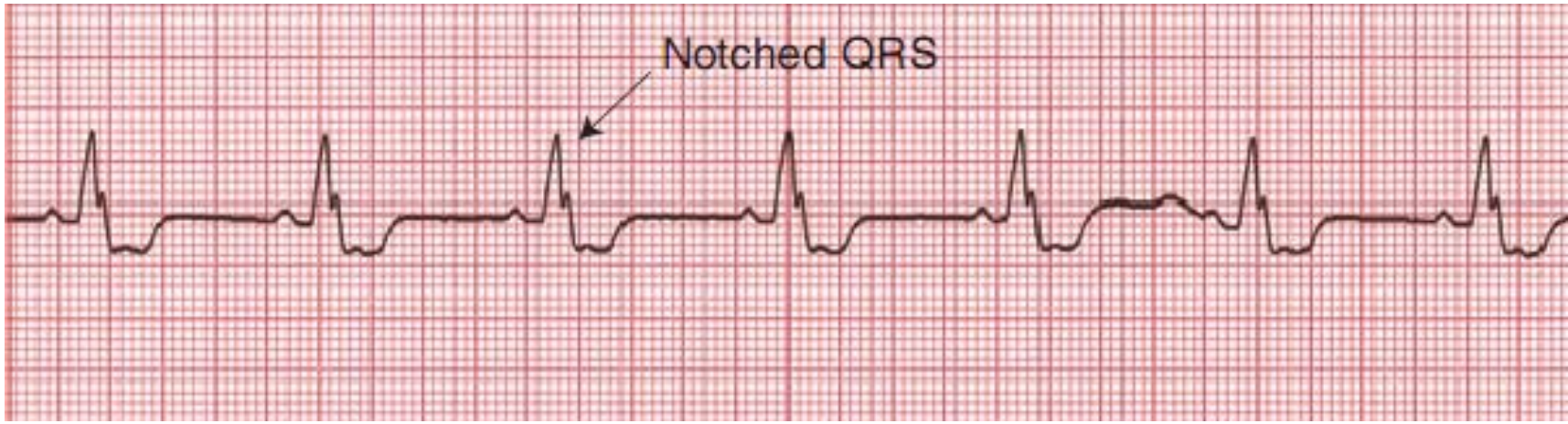

- Частота зависит от основного ритма
- Ритм регулярный
- P-зубец нормальный
- **PR**-интервал: нормальный
- **QRS** обычно уширен (>0,10 сек) с зазубринами

Обычно появляется при ИБС. Правый или левый желудочек деполяризуется позже, что приводит к зазубрине на QRS.

Нормальная ЭОС

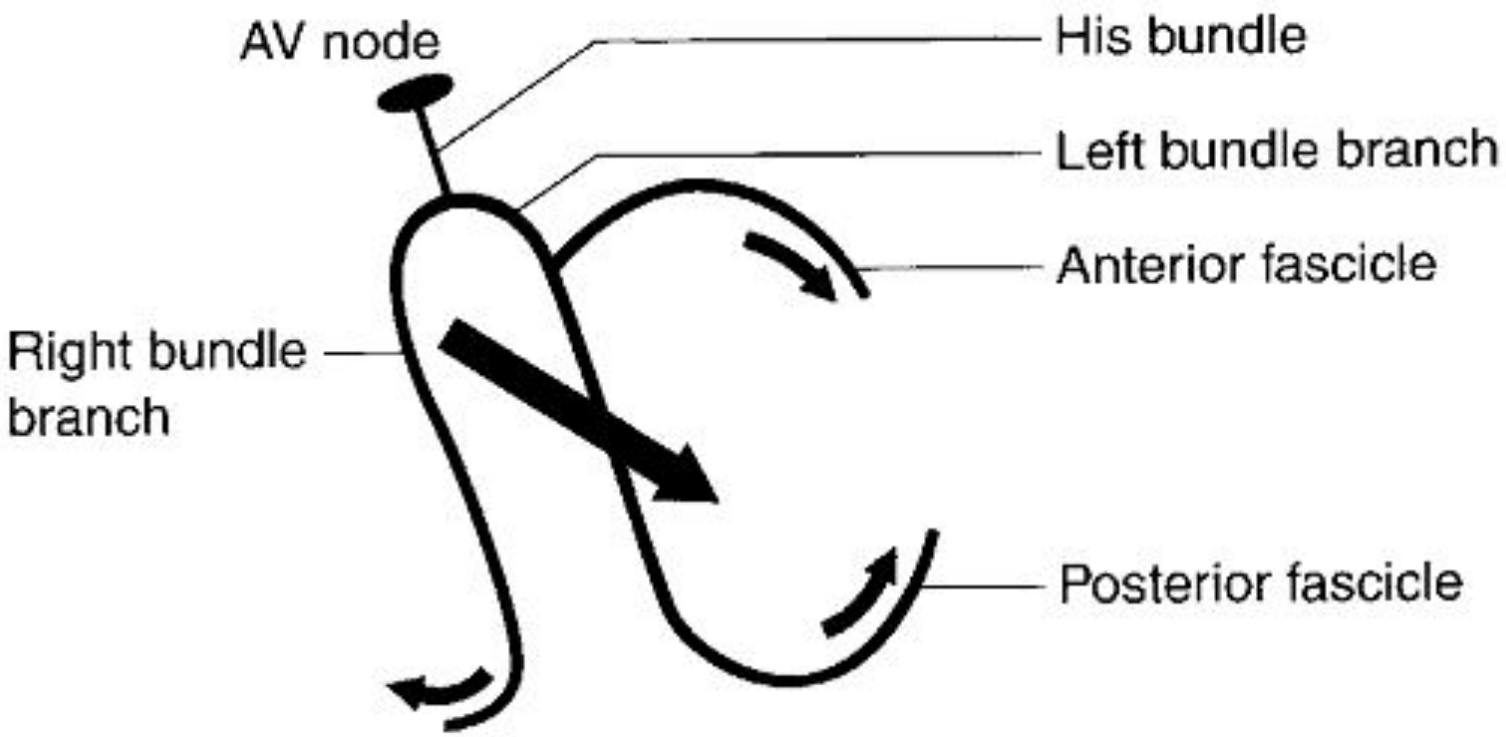

- **Ритм синусовый; широкий QRS с зазубриной R в I, aVL,V5,V6; инверсия T (изменение реполяризации)**

Блокада ПНПГ

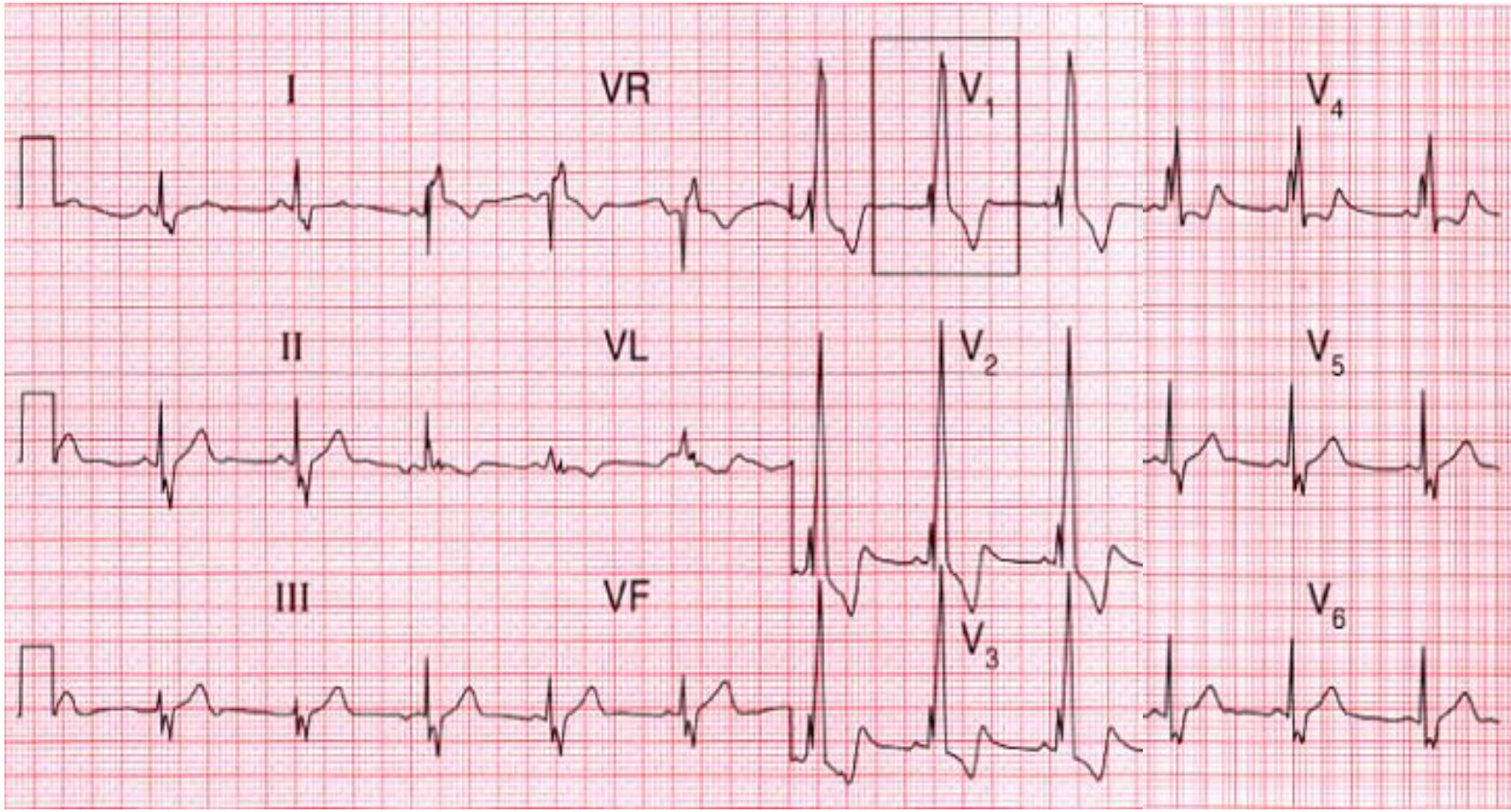

- **Синусовый ритм; RSR1 в V1; доминирующий R из-за БПНПГ; широкий и расщепленный S в V6**

Блокада ПНПГ

- **RSR'тип в V_1**

Блокада ЛНПГ

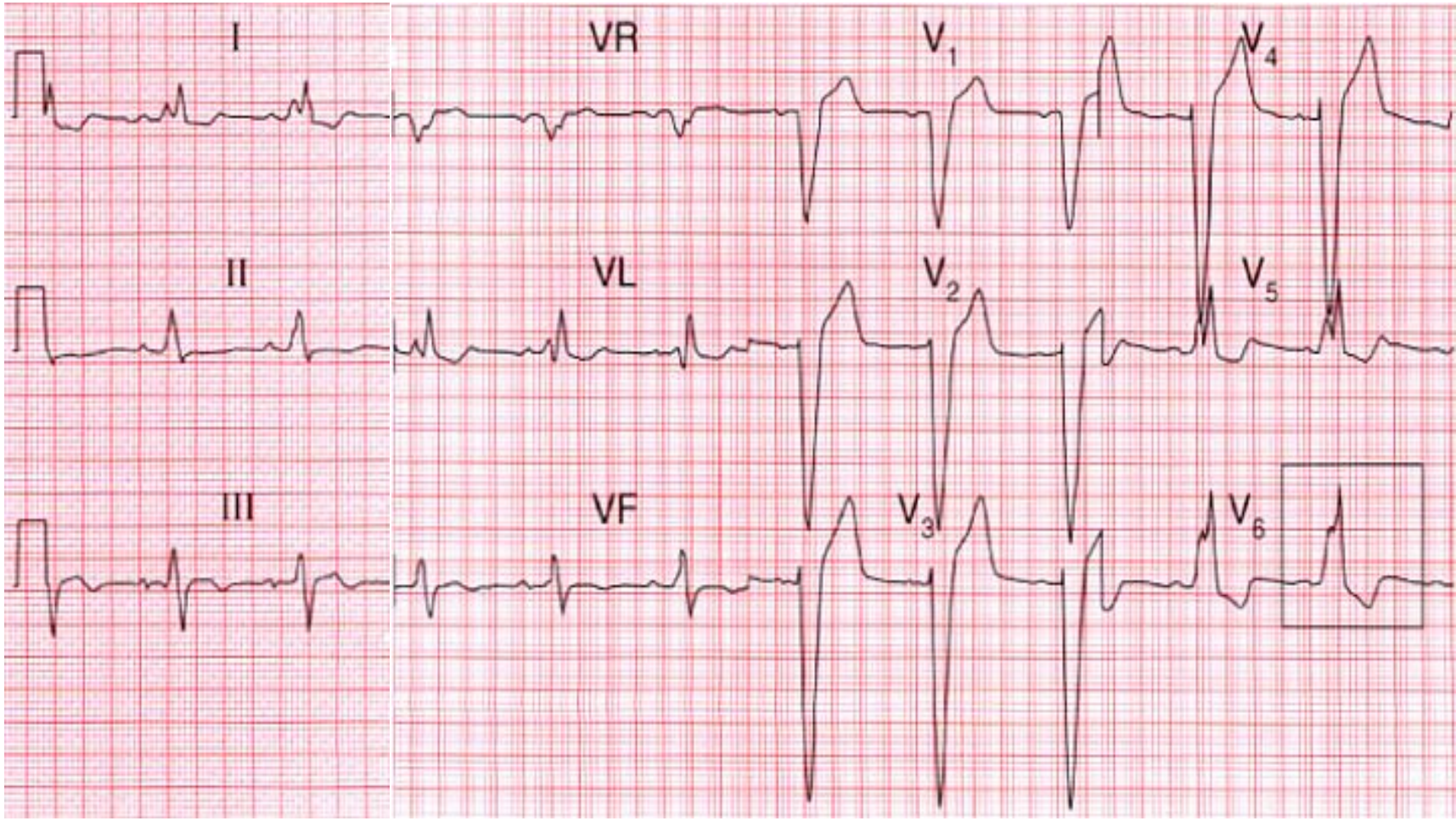

- **Ритм синусовый; широкий QRS с зазубриной R в I, aVL,V5,V6; инверсия T (изменение реполяризации)**

Блокада ЛНПГ

- **Потеря септального зQ и зазубрина QRS в латеральных отведениях**

АВ блокада 1ст + БПНПГ

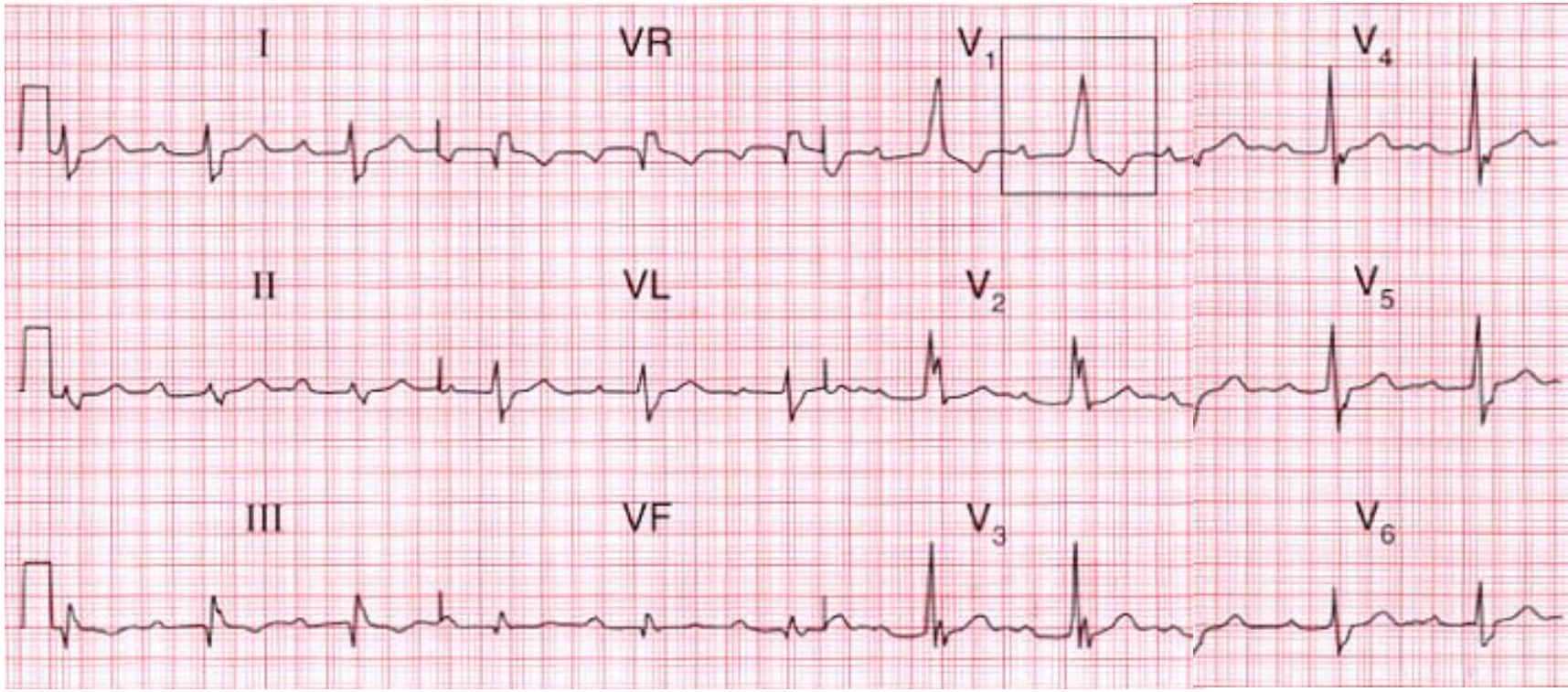

- **Ритм синусовый**
- **PR 320 мсек**
- **Широкий QRS**
- **RSR1 в V2**
- **Широкий расщепленный S в V6**

АВ блокада 1ст + БПНПГ

- **Ритм синусовый**
- **PR 320 мсек**
- **Широкий QRS**
- **RSR1 в V2**
- **Широкий расщепленный S в V6**

Блокада ЛПНПГ

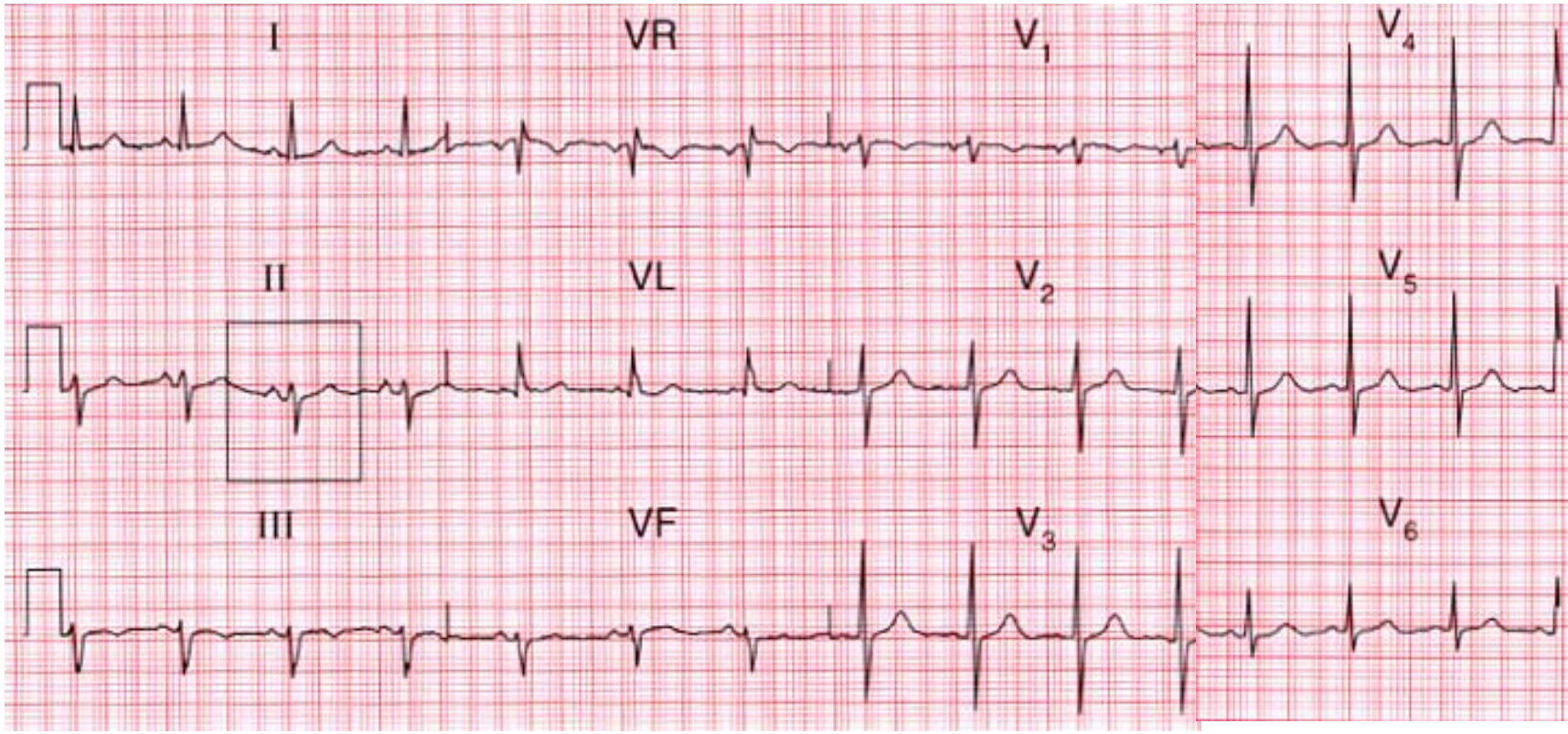

- **Ритм синусовый; нормальный PR**
- **Отклонение ЭОС влево**
- **Доминирующий S в II, III**

Блокада ЛПНПГ

- **Ритм синусовый; нормальный PR**
- **Отклонение ЭОС влево**
- **Доминирующий S в II, III**

Бифасцикулярная блокада

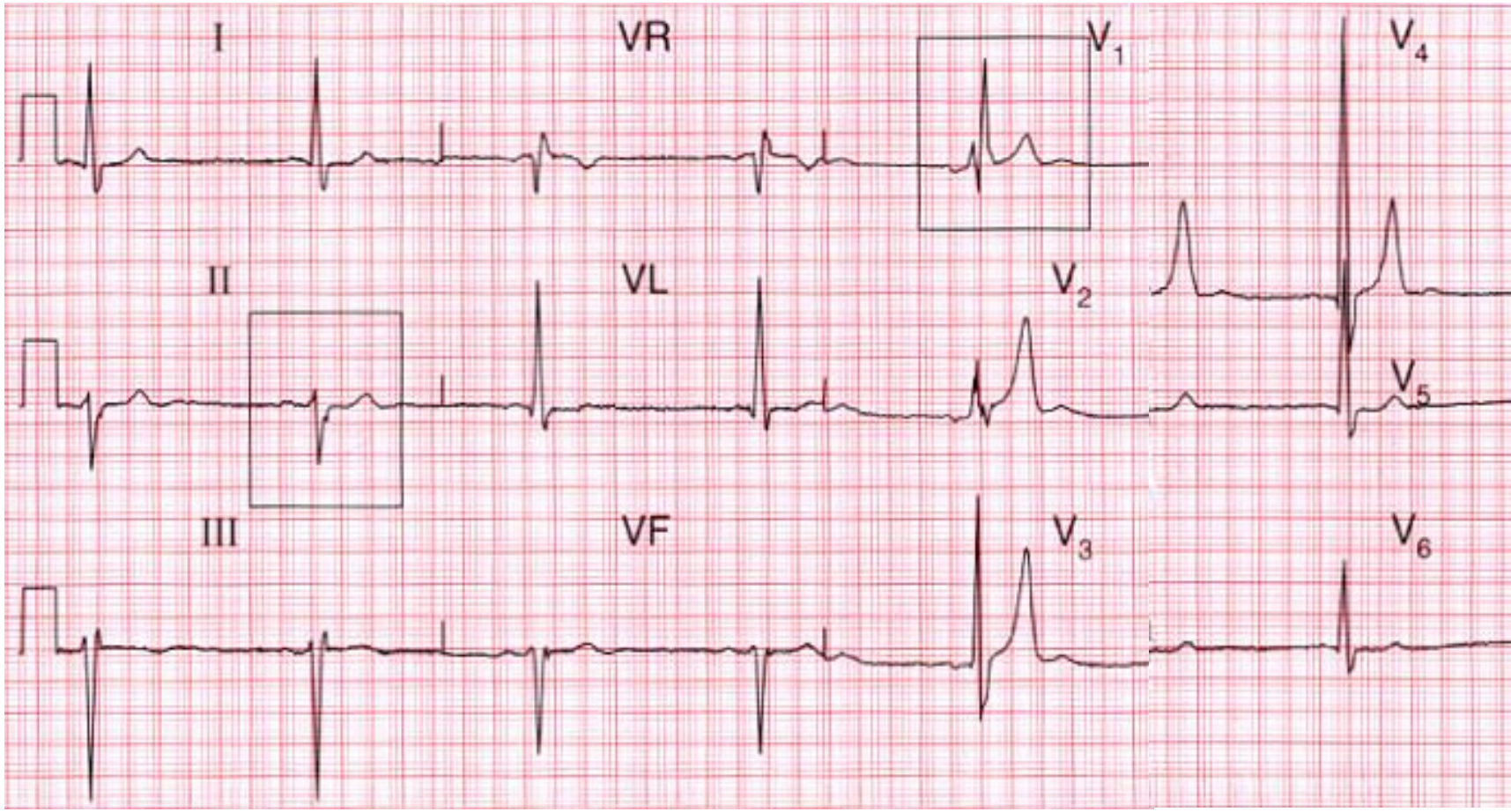

- **Ритм синусовый; нормальный PR**
- **Отклонение ЭОС влево**
- **RSR1 в V1 и широкий S в V6**

Бифасцикулярная блокада

- **Ритм синусовый; нормальный PR**
- **Отклонение ЭОС влево**
- **RSR1 в V1 и широкий S в V6**

Трифасцикулярная блокада

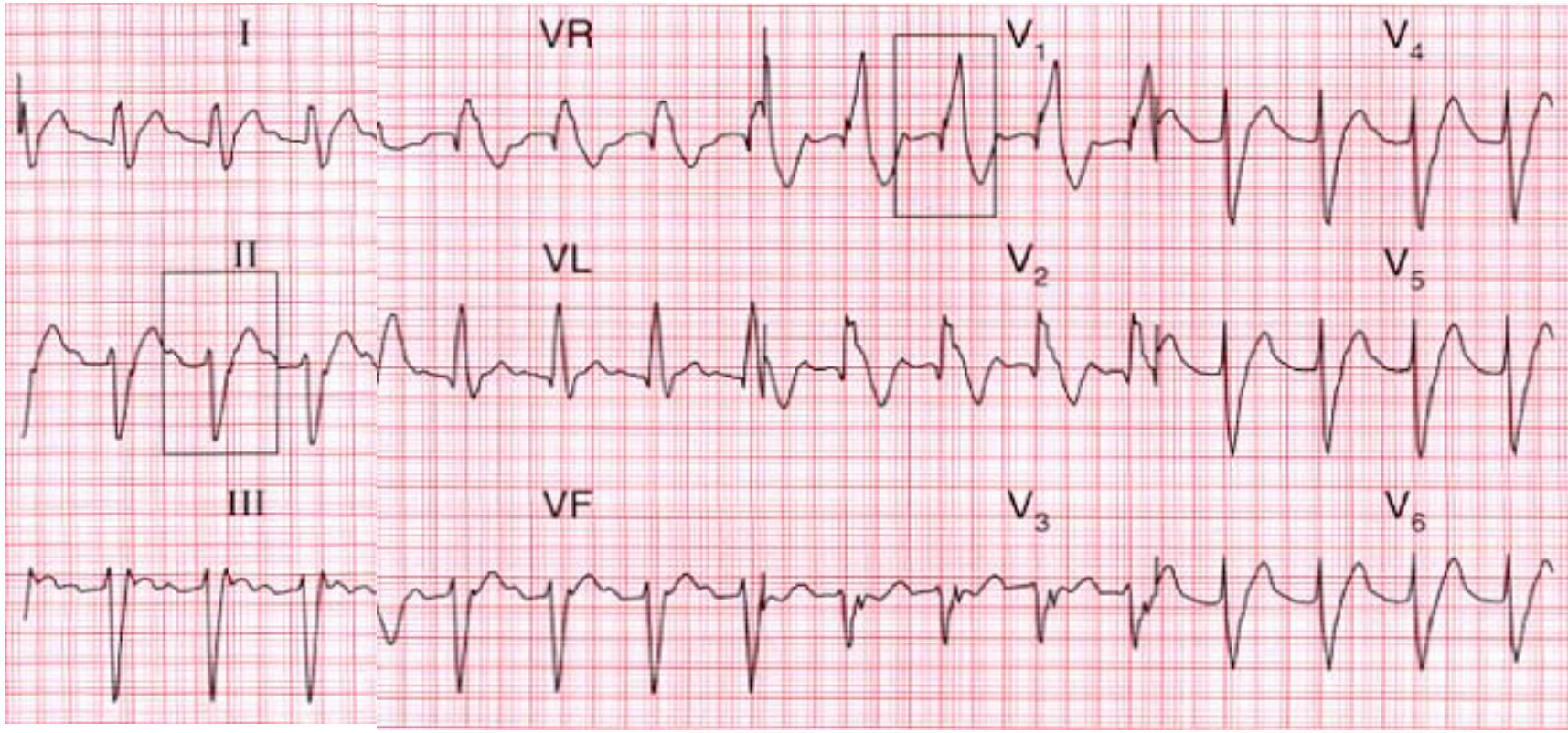

- **PR интервал 280 мсек**
- **Отклонение ЭОС влево**
- **Широкий QRS**
- **RSR1 в V1**

Трифасцикулярная блокада

- **PR интервал 280 мсек**
- **Отклонение ЭОС влево**
- **Широкий QRS**
- **RSR1 в V1**

Искусственный водитель ритма

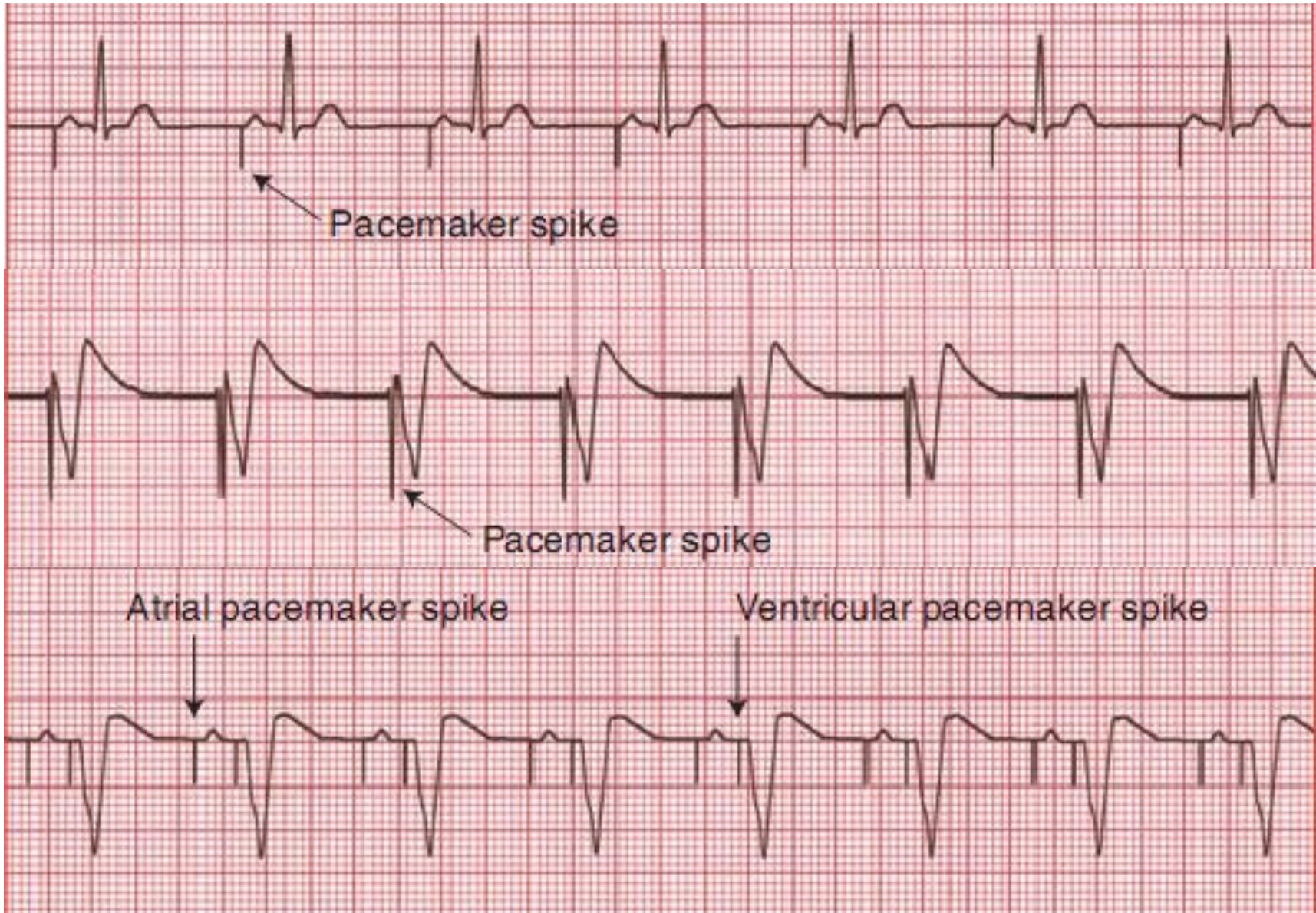

Состояния, ассоциированные с дисфункцией СА узла

- **Возраст**
- **Идиопатический фиброз**
- **Ишемия,в т.ч.ИМ**
- **Высокий парасимпатический тонус**
- **Миокардит**
- **Токсичность дигоксина**

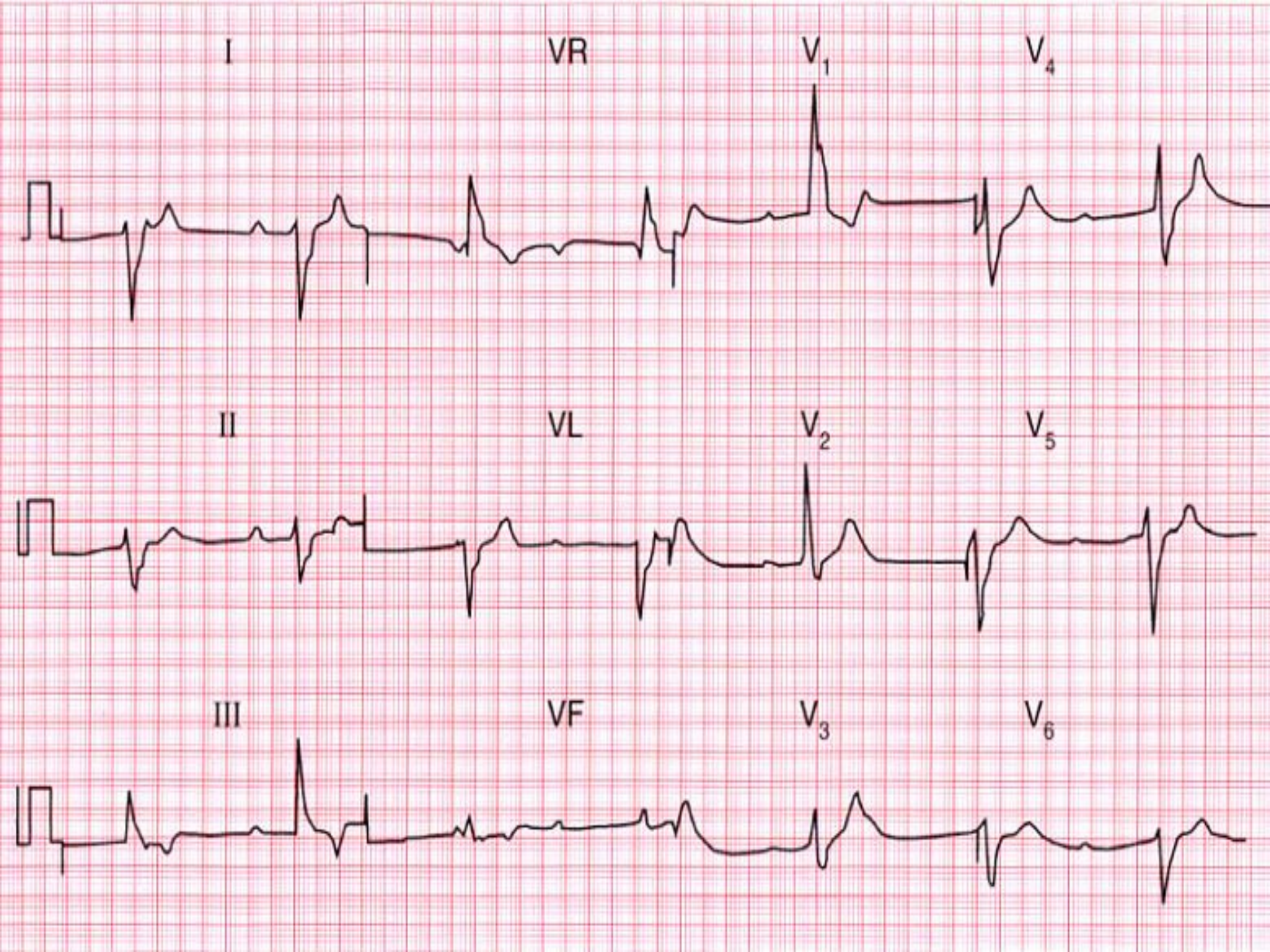
I
VR
V1
V4
II
VL
V2
V5
III
VF
V3
V6

The ECG shows:

- Complete heart block
- Ventricular rate 45/min

Clinical interpretation

In complete heart block there is no relationship between the P waves (here with a rate of 70/min) and the QRS complexes. The ventricular 'escape' rhythm has wide QRS complexes and abnormal T waves. No further interpretation of the ECG is possible.

What to do

In the absence of a history suggesting a myocardial infarction, this woman almost certainly has chronic heart block: the fall may or may not have been due to a Stokes–Adams attack. She needs a permanent pacemaker, ideally immediately to save the morbidity of first temporary, and then permanent, pacemaker insertion. If permanent pacing is not possible immediately, a temporary pacemaker will be needed preoperatively.

Summary ★

Complete (third degree) heart block.

ME See p. 33

IP See p. 213

(a)
(b)
(c)

ANSWER 8

The ECGs show:

(a) No P waves can be seen but the baseline is irregular; the QRS complexes are broad, regular, and slow. This is atrial fibrillation with complete block.
(b) In the conducted beats the PR interval is constant, so this is sinus rhythm with second degree (2:1) block. The second small deflection after the R wave is not a P wave, but is part of the QRS complex.
(c) There is no fixed relationship between the P waves and the QRS complexes, so this is complete (third degree) heart block.

Clinical interpretation

Single ECG leads can only be used to identify the rhythm, and further interpretation is unreliable.

What to do

All the patients are probably suffering the effects of their bradycardia; additional symptoms might be angina, dizziness, and collapse (Stokes–Adams attacks). In each case the likely diagnosis is idiopathic fibrosis of the conducting system, but almost all cardiac conditions can be associated with heart block – rheumatic disease, ischaemia, cardiomyopathy, trauma, metastases and so on. In the elderly, heart block is often associated with a calcified aortic valve. Whatever their age, such patients benefit from a permanent pacemaker.

Summary ★★

(a) Atrial fibrillation and complete block.
(b) Second degree (2:1) block.
(c) Complete (third degree) block.

ME See p. 30

IP See p. 199

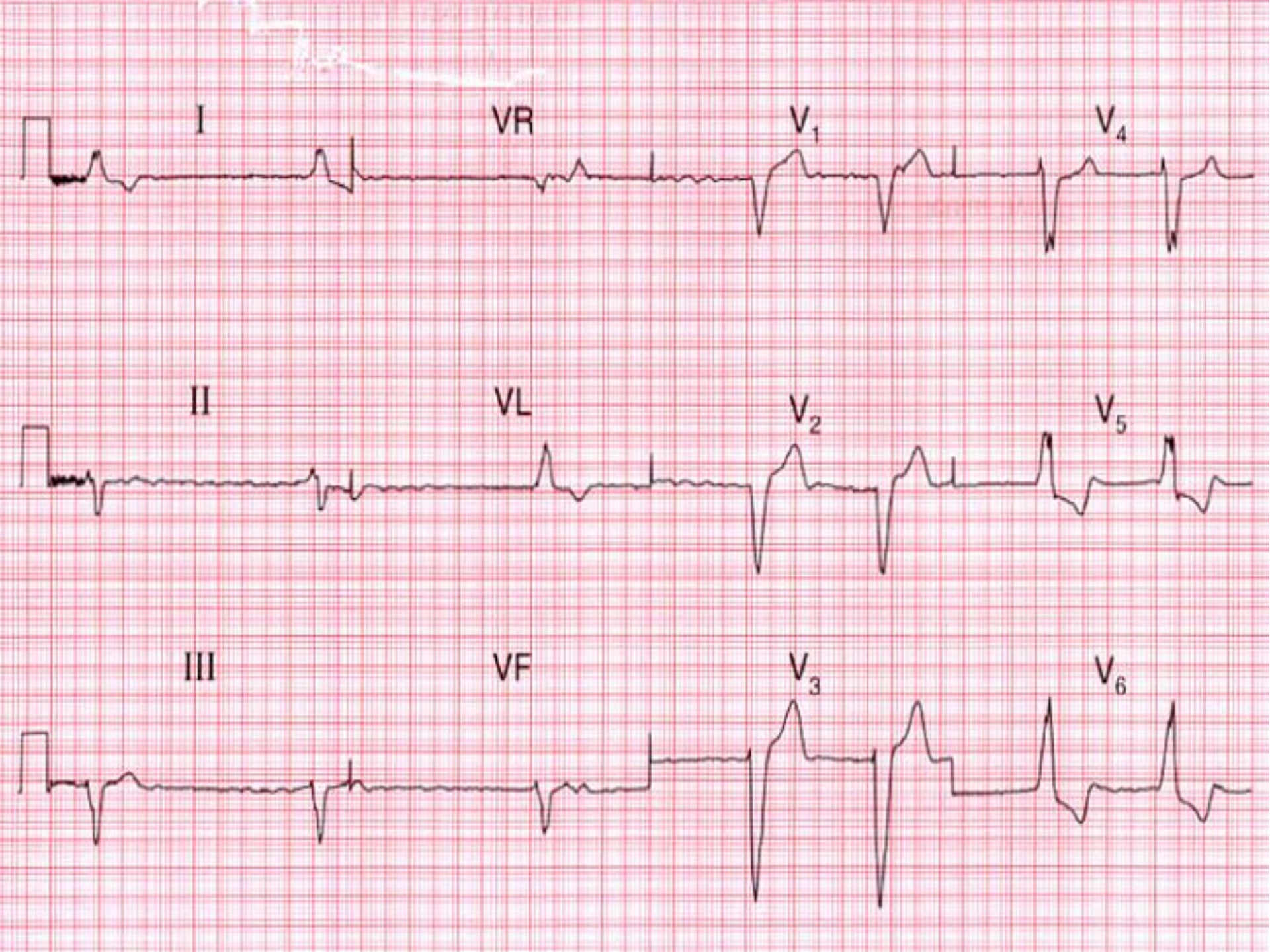
I
VR
V1
V4
II
VL
V2
V5
III
VF
V3
V6

ANSWER 10

The ECG shows:

- Atrial fibrillation with a ventricular rate of about 40/min
- Left axis
- Left bundle branch block

Clinical interpretation

When an ECG shows left bundle branch block, no further interpretation is usually possible. Here there is atrial fibrillation, and the ventricular response is very slow, suggesting that there is conduction delay in the His bundle as well as the left bundle branch.

What to do

It is always important to establish the cause of heart failure. In this patient the slow ventricular rate may be at least part of the problem. The most important causes of left bundle branch block are ischaemia, aortic stenosis and cardiomyopathy. In this patient an echocardiogram will show whether he has significant valve disease and how impaired left ventricular function is. In the absence of pain, coronary angiography is probably not indicated. The heart failure needs to be treated with diuretics and an angiotensin-converting enzyme inhibitor, but digoxin must be avoided as it may slow the ventricular response still further. He almost certainly needs a permanent pacemaker.

Summary ★

Atrial fibrillation and left bundle branch block.

ME See pp. 36 and 78

IP See p. 209

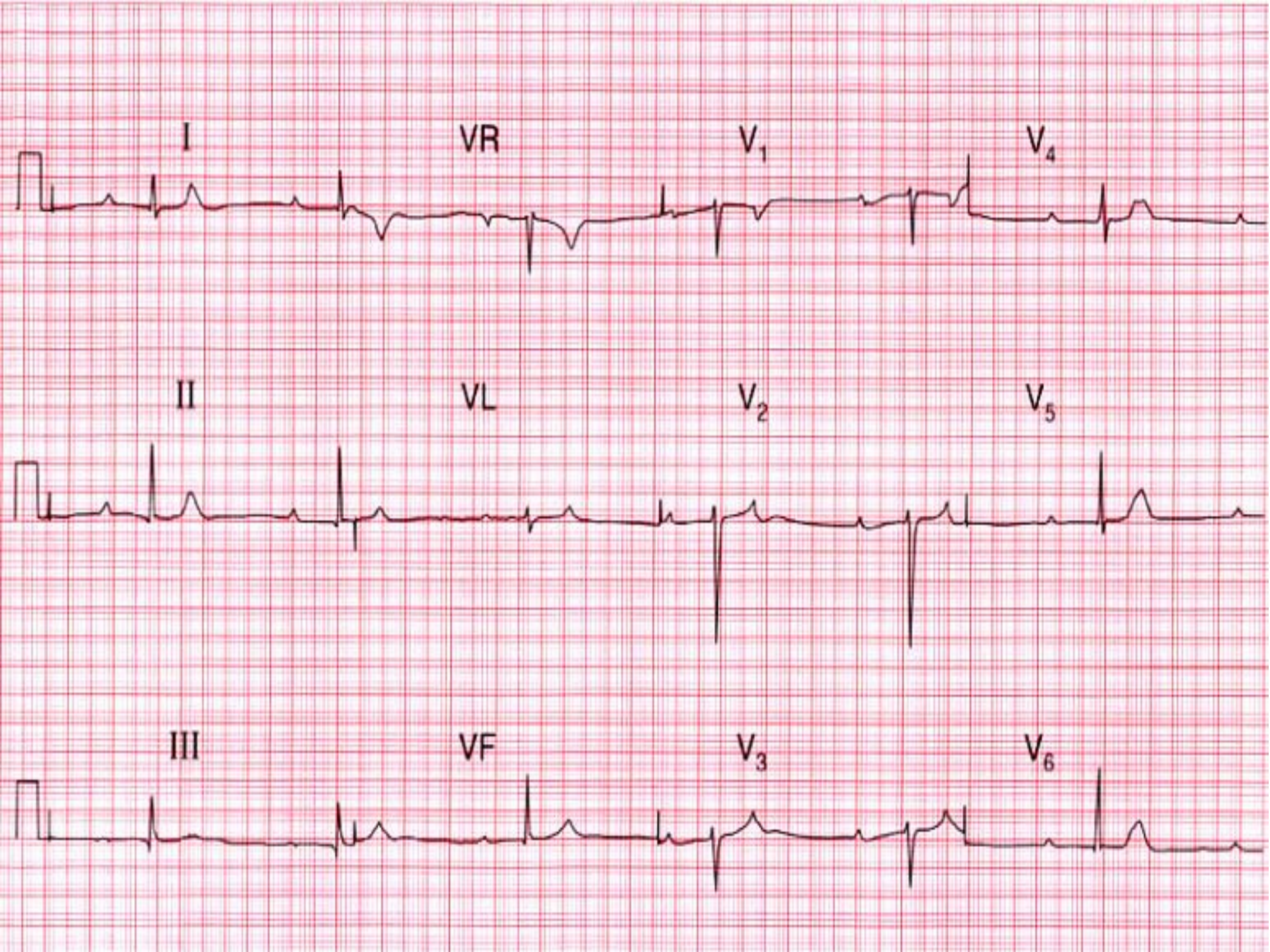
I
VR
V1
V4
II
VL
V2
V5
III
VF
V3
V6

ANSWER 12

The ECG shows:

- Second degree (2:1) heart block
- Prolonged PR interval (440 ms) in the conducted beats
- Ventricular rate about 40/min
- Normal QRS complexes and T waves

Clinical interpretation

Although the slow ventricular response raises the possibility of complete heart block, the fact that the PR interval is constant (albeit prolonged) shows that this is actually second degree block. The non-conducted P waves are not easy to see, but the clue lies in the abnormally shaped T waves in the anterior leads. Second degree block explains why the QRS complexes are narrow and the T waves are normal.

What to do

Since this woman has been breathless and dizzy for some time, and since there is nothing in the history or on the ECG to suggest an acute infarction, it is unlikely that this conduction disturbance is new. She therefore needs a permanent pacemaker: the only problem is to decide whether the urgent hip surgery should be covered with a temporary pacemaker – ideally she would be saved that procedure and a permanent system implanted immediately.

Summary ★

Second degree (2:1) heart block.

ME See p. 31

IP See p. 212

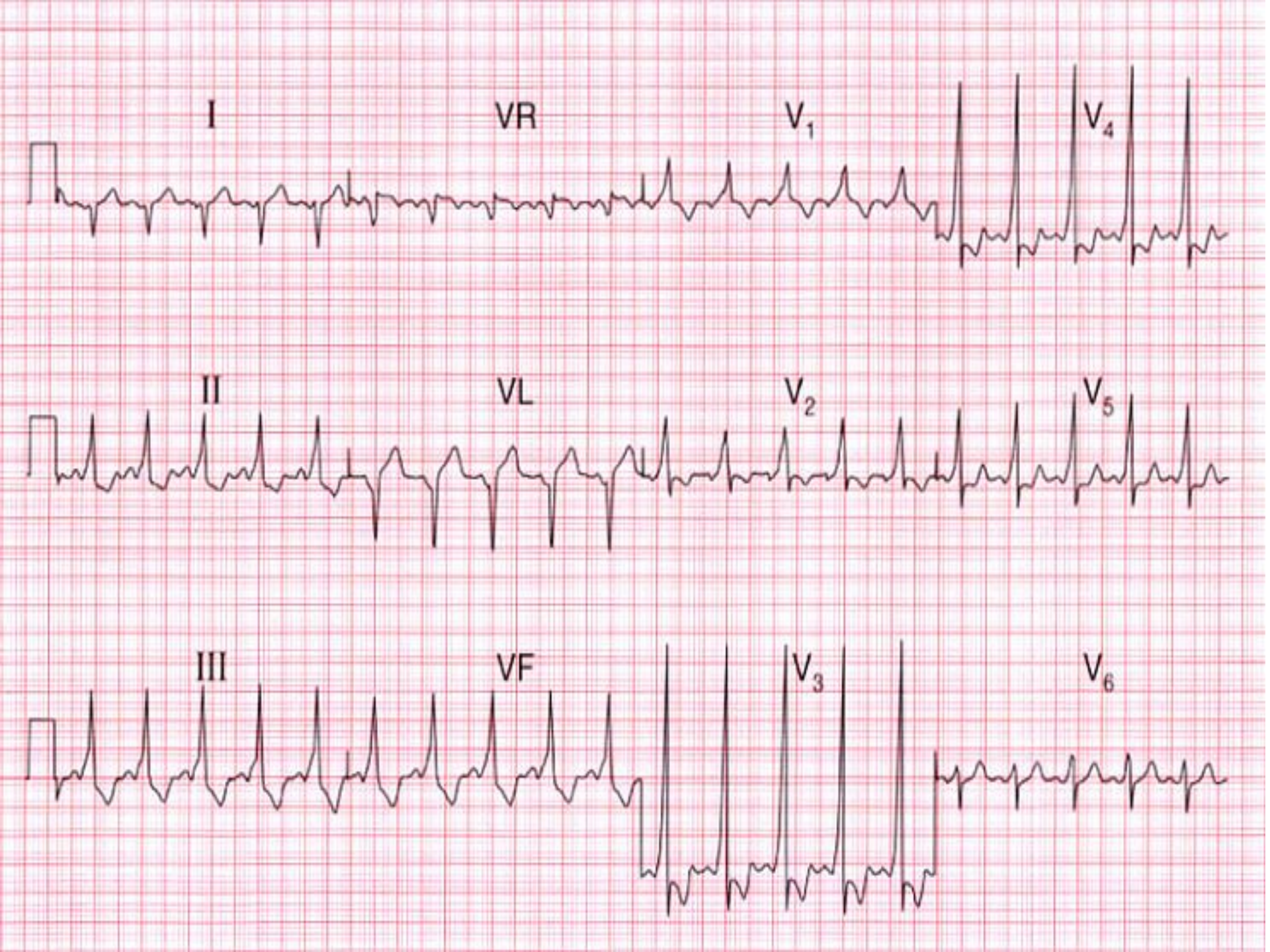
I
VR
V1
V4
II
VL
V2
V5
III
VF
V3
V6

ANSWER 15

The ECG shows:

- Sinus rhythm
- Right axis
- Short PR interval (112 ms)
- QRS complexes a little wide (124 ms)
- Slurred upstroke of QRS (delta wave)
- Dominant R wave in lead V_1
- Widespread T wave inversion

Clinical interpretation

This is a classical Wolff–Parkinson–White syndrome. The resemblance to the ECG of right ventricular hypertrophy is because this is type A, with a left-sided accessory pathway. The ECG changes of right axis, the dominant R wave in lead V_1, and the T wave changes have no further significance.

What to do

The patient gives a clear story of a paroxysmal tachycardia, and during attacks the circulation is clearly compromised because he feels dizzy. The attacks are infrequent so there is little point in ambulatory ECG recording. He needs immediate referral to an electrophysiologist for ablation of the aberrant conducting pathway.

Summary ★

Wolff–Parkinson–White syndrome type A.

ME See p. 81

IP See pp. 126 and 198

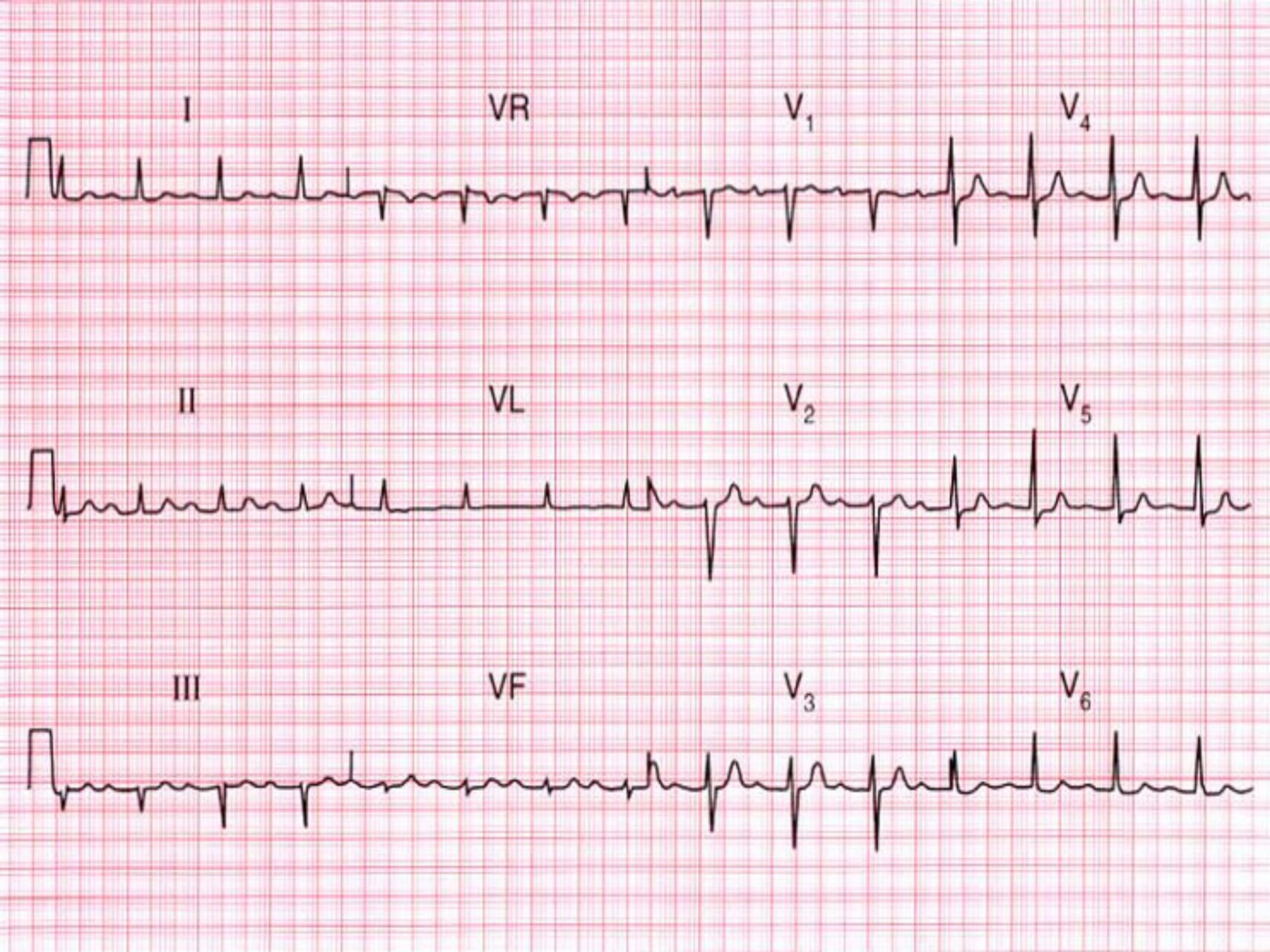
I
VR
V1
V4
II
VL
V2
V5
III
VF
V3
V6

ANSWER 16

The ECG shows:

- Sinus rhythm
- Prolonged PR interval of 280 ms (best seen in leads V_1, V_2)
- Normal axis
- Normal QRS complexes
- Normal ST segments and T waves

Clinical interpretation

Sinus rhythm with first degree block.

What to do

First degree block does not cause any haemodynamic impairment, and by itself is of little significance. However, when a patient has symptoms which might be due to a bradycardia (in this case dizziness), there may be episodes of second or third degree block, or possibly Stokes–Adams attacks, associated with a slow ventricular rate. The appropriate action is therefore to request a 24 h ECG tape-recording invthe hope that the patient will have one of her dizzy turns while wearing it. It would then be possible to see whether or not the dizziness was associated with a change in heart rhythm. First degree block itself is not an indication for permanent pacing or for any other intervention.

Summary ★★

Sinus rhythm with first degree block.

ME See p. 30

IP See p. 137

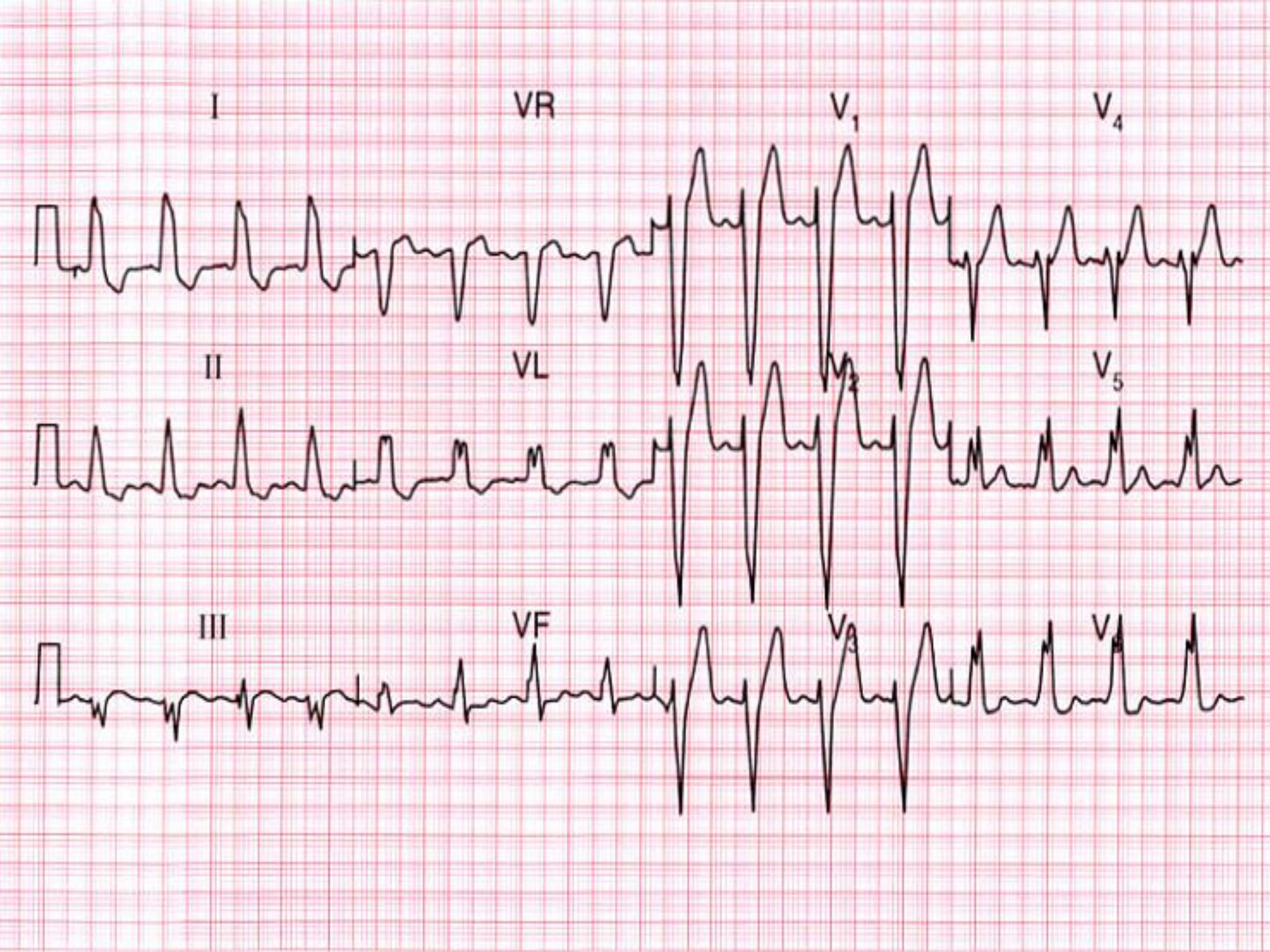
I
VR
V1
V4
II
VL
V2
V5
III
VF
V3
V6

ANSWER 19

The ECG shows:

- Sinus rhythm
- Broad QRS complexes (140 ms)
- 'M' pattern in lead V_6
- Inverted T waves in leads I, VL, V_6

Clinical interpretation

This is a characteristic pattern of left bundle branch block. The ECG cannot be interpreted further.

What to do

A patient who has chest pain that could be angina, and who has dizziness and syncope on exertion, probably has severe aortic stenosis and this was the case with this woman. Clinically she had a slow rising pulse, a blood pressure of 100/80, and a slightly enlarged heart. There was a loud ejection systolic murmur, best heard at the upper right sternal edge and radiating to both carotids. The diagnosis was confirmed by an echocardiogram, which showed a gradient across the aortic valve of about 100 mmHg. A cardiac catheter was necessary to exclude coronary disease and she then had an aortic valve replacement and made a complete recovery.

Summary ★

Sinus rhythm with left bundle branch block.

ME See p. 39

IP See p. 117

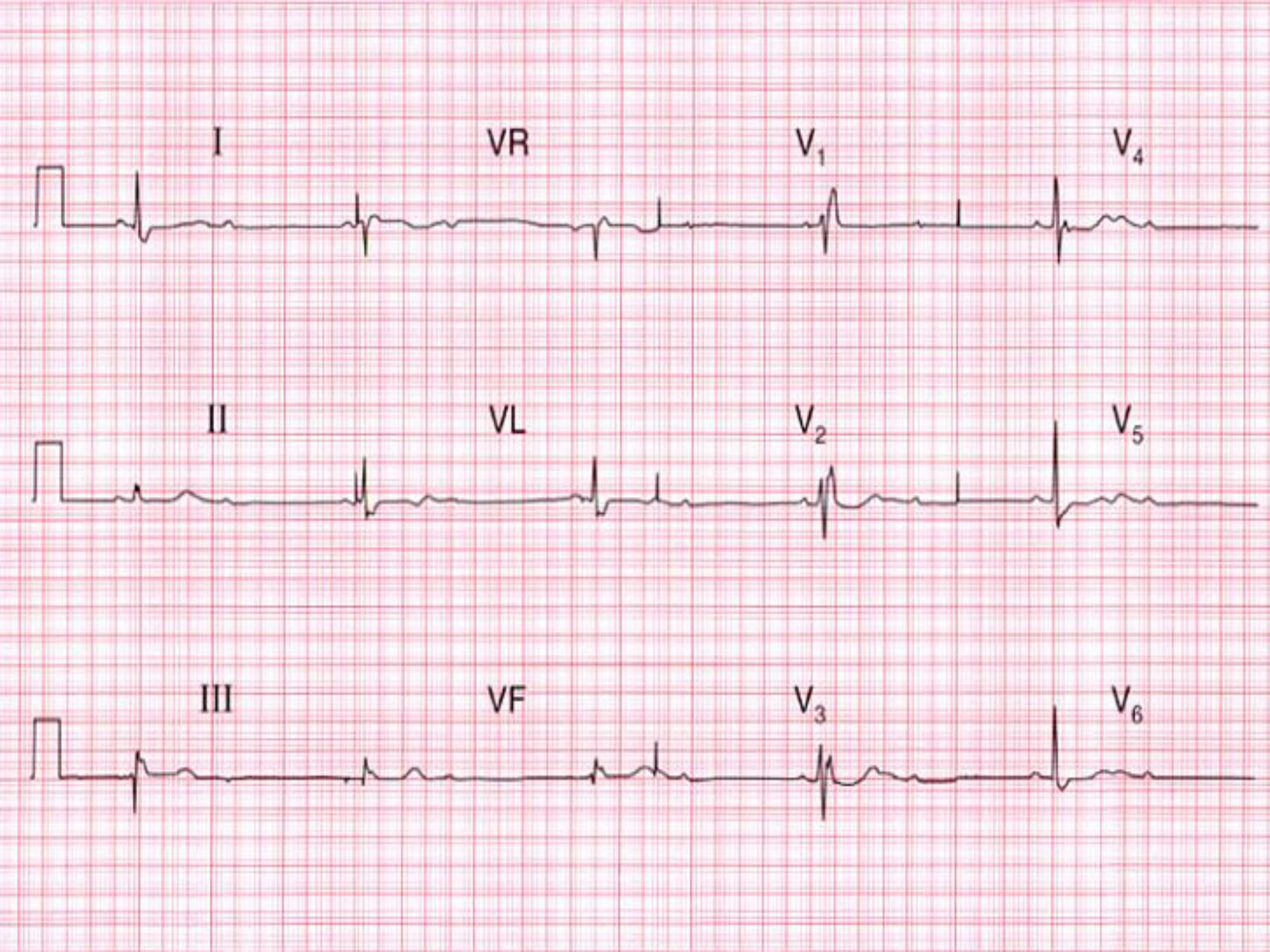
I
VR
V1
V4
II
VL
V2
V5
III
VF
V3
V6

ANSWER 20

The ECG shows:

- Sinus rhythm
- Second degree (2:1) heart block (most obvious in lead V_3)
- Ventricular rate 30/min
- Normal PR interval in the conducted beats
- Normal axis
- QRS duration prolonged (160 ms)
- RSR pattern in leads V_1–V_3 and a wide S wave in lead V_6
- Prominent U wave in leads V_3–V_6

Clinical interpretation

This patient has second degree block and right bundle branch block, so he clearly has extensive conduction tissue disease.

What to do

The slow heart rate is probably the cause of his heart failure, and he needs a permanent pacemaker. The story suggests that the onset of heart failure was not associated with chest pain, so the underlying disease is probably fibrosis of the conducting system rather than ischaemia. He needs an echocardiogram and treatment with an angiotensin-converting enzyme inhibitor if there is evidence of left ventricular dysfunction.

Summary ★★

Second degree atrioventricular block and right bundle branch block.

ME See pp. 31 and 37

IP See p. 140

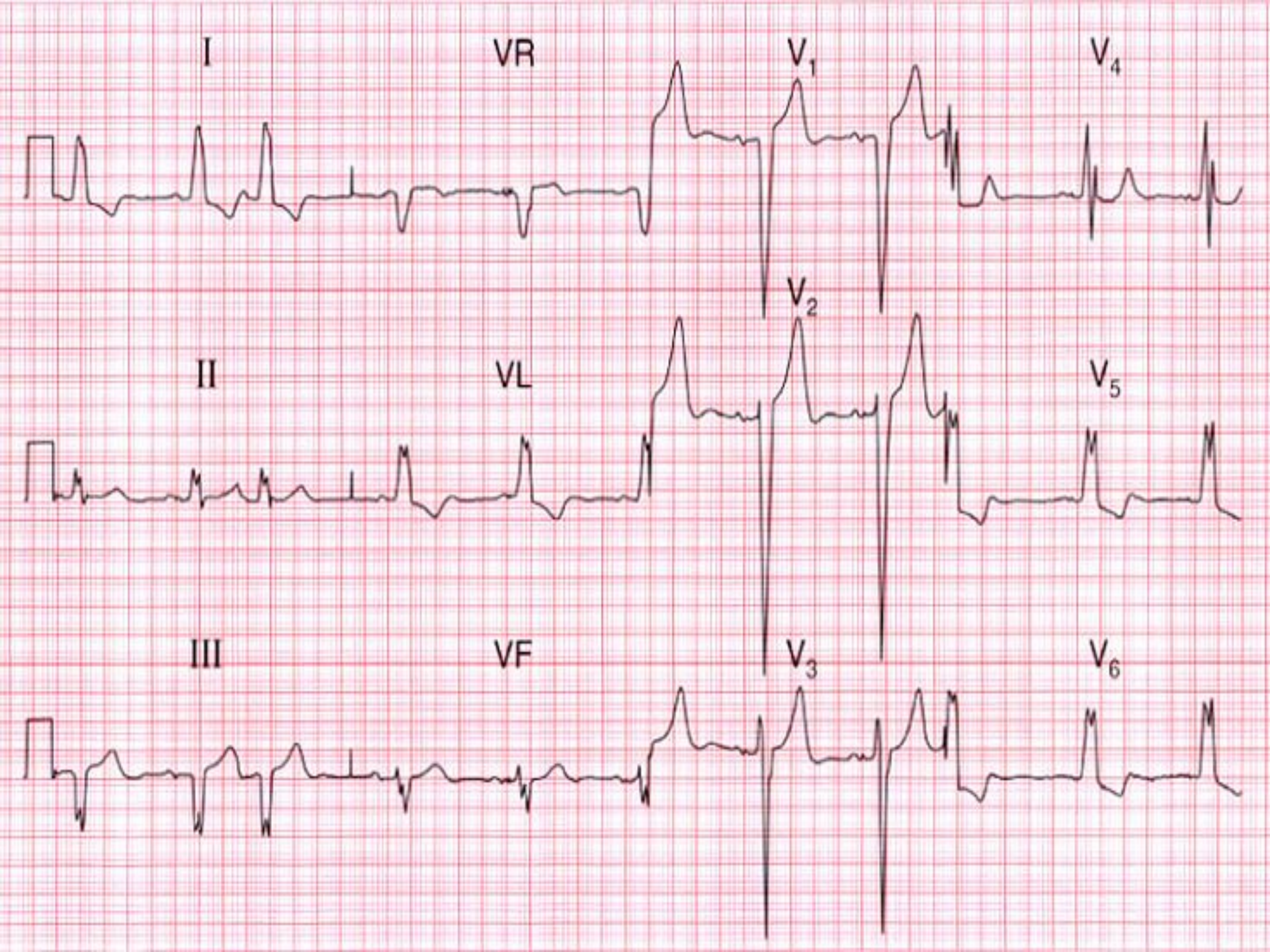
I
VR
V1
V4
II
VL
V2
V5
III
VF
V3
V6

ANSWER 23

The ECG shows (*note*: leads at half sensitivity):

- Sinus rhythm
- Supraventricular (junctional) extrasystoles
- Normal axis
- Broad QRS complexes (140 ms)
- 'M' pattern of QRS complex in leads V_4–V_6
- Inverted T waves in leads I, VL, V_4–V_6

Clinical interpretation

This ECG shows sinus rhythm with supraventricular extrasystoles and left bundle branch block (LBBB). No further interpretation is possible.

What to do

If a patient has symptoms suggestive of a myocardial infarction of less than 6 h duration but has LBBB on the ECG, thrombolysis should be given only if the bundle branch block is known to be new. Here the patient had a history of angina so the first thing to do is to relieve his pain and the second is to find his old notes and see if the LBBB had been noted previously. If no old ECGs are available, thrombolysis should not be given, and the patient should be treated as an acute coronary syndrome. The supraventricular extrasystoles are not important.

Summary ★

Left bundle branch block; supraventricular extrasystoles.

IP See pp. 36 and 62

ME See p. 259

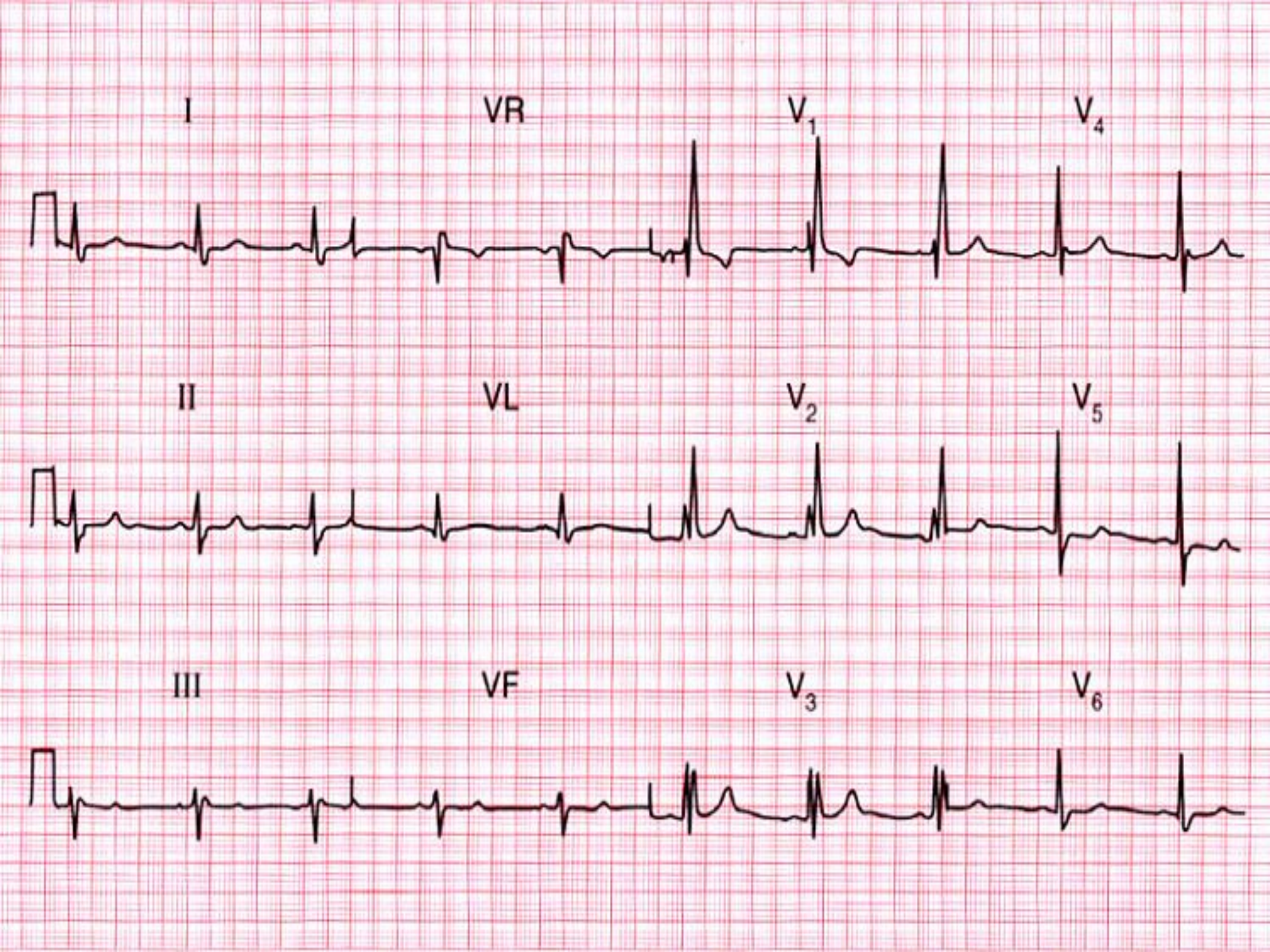
I
VR
V1
V4
II
VL
V2
V5
III
VF
V3
V6

ANSWER 26

The ECG shows:

- Sinus rhythm
- Normal axis
- Broad QRS complexes (140 ms)
- RSR pattern in lead I
- Wide and slurred S waves in lead V_5
- Normal ST segments and T waves

Clinical interpretation

Right bundle branch block.

What to do

Right bundle branch block is seen in a small proportion of people with perfectly normal hearts. In the presence of a heart murmur, however, the possibility of an atrial septal defect should be considered. This is what this patient had. The physical signs were a widely-split pulmonary second sound which did not vary with inspiration (this is typical of right bundle branch block) and an ejection systolic murmur best heard at the left sternal edge. On deep inspiration a soft diastolic murmur could be heard at the lower left sternal edge. The systolic murmur is a pulmonary flow murmur due to the extra flow through the right side of the heart, and the diastolic murmur that occurs on inspiration is a tricuspid flow murmur. The diagnosis was confirmed by echocardiography, and the defect was closed with a percutaneous 'umbrella' device. Following operation, the right bundle branch block persisted.

Summary ★

Sinus rhythm with right bundle branch block.

ME See p. 37

IP See pp. 103 and 352

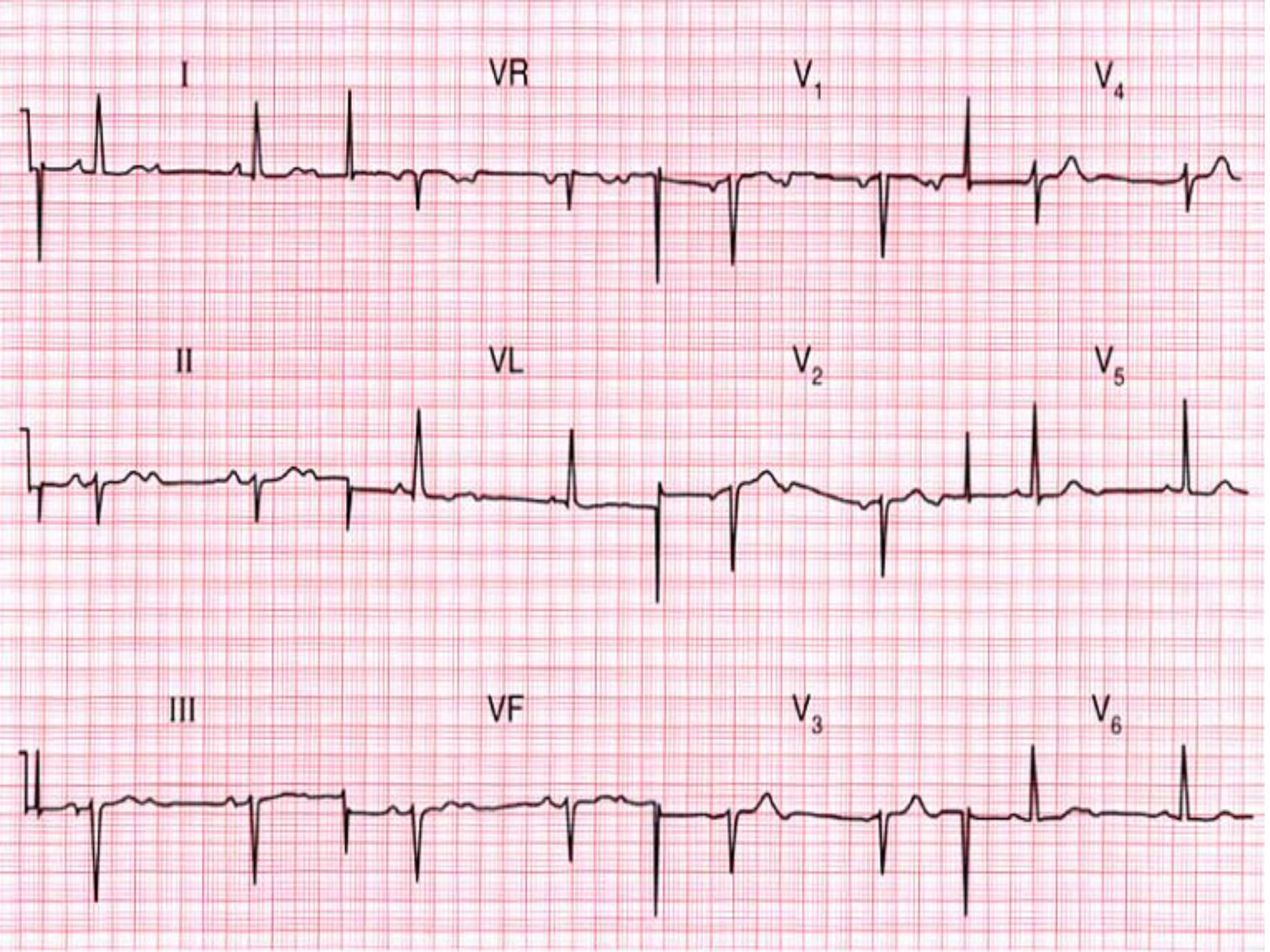
I
VR
V1
V4
II
VL
V2
V5
III
VF
V3
V6

ANSWER 35

The ECG shows:

- Sinus rhythm
- Second degree (2:1) block
- Left axis deviation
- Poor R wave progression in the anterior leads
- Normal T waves

Clinical interpretation

The second degree block is associated with a ventricular rate of 45/min, which may well be the cause of his breathlessness. The left axis deviation indicates left anterior hemiblock. The poor R wave progression (virtually no R wave in lead V_3, a small R wave in lead V_4, and a normal R wave in lead V_5) suggests an old anterior infarction.

What to do

This patient needs a permanent pacemaker.

Summary ★★★

Second degree (2:1) block, left anterior hemiblock, and probable old anterior infarction.

ME See pp. 31 and 46

IP See p. 140

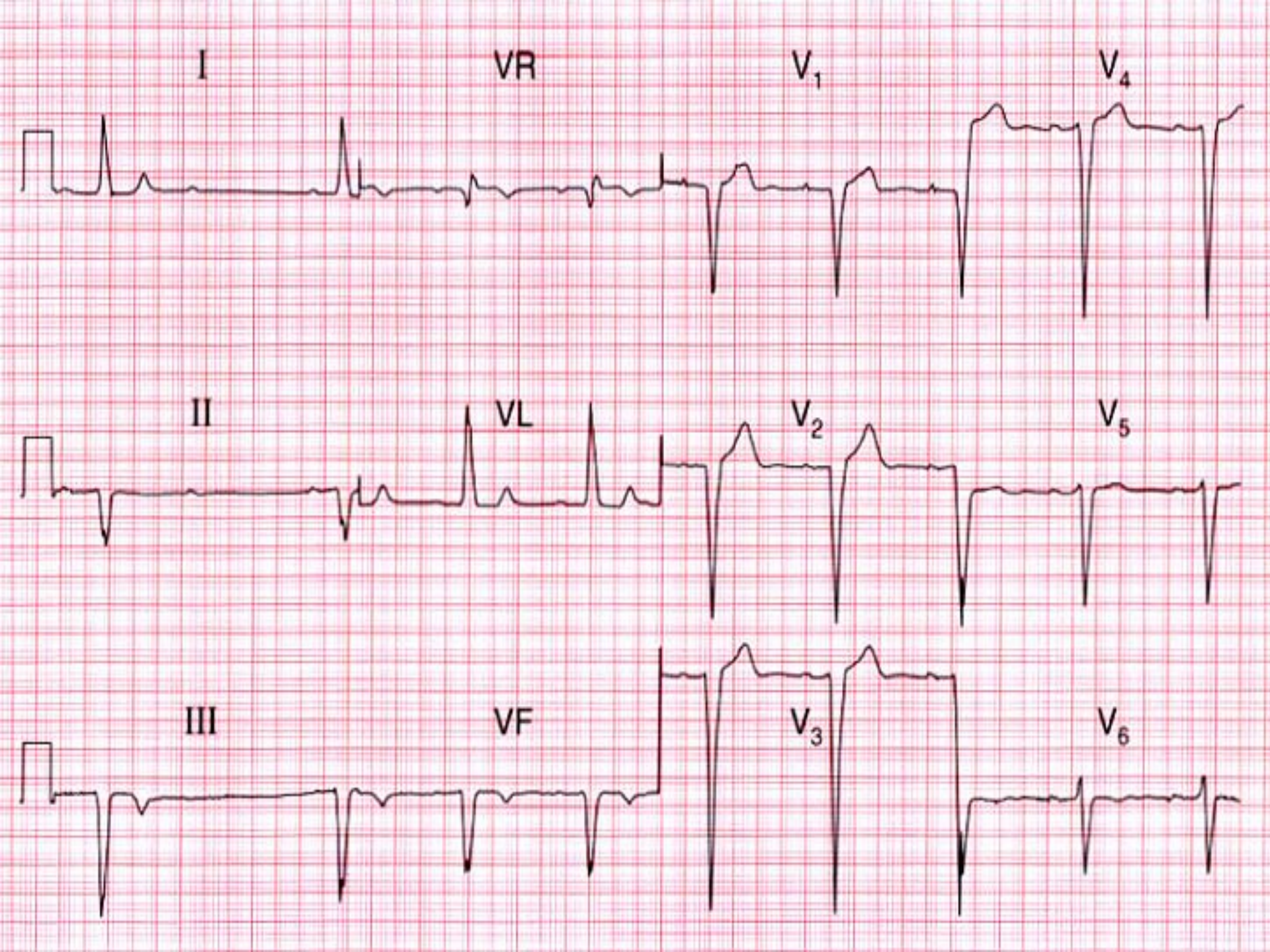
I
VR
V1
V4
II
VL
V2
V5
III
VF
V3
V6

ANSWER 39

The ECG shows:

- Sinus rhythm
- Second degree block (Mobitz type 2 – best seen in leads I and II)
- Ventricular rate 50/min
- Normal PR interval in the conducted beats
- Left axis deviation
- Broad QRS complexes (160 ms)
- No R waves in anterior chest leads
- Deep S wave in lead V_6

Clinical interpretation

The combination of Mobitz type 2 block and left interior hemiblock (shown by the left axis) indicates severe conduction tissue disease. The loss of R waves in the chest leads may be due to an old anterior infarction, but the deep S wave in lead V_6 may indicate an intraventricular conduction delay.

What to do

The recent episode of chest pain may have been due to a further myocardial infarction, or may have been associated with bradycardia due to complete heart block. If repeat ECGs and blood markers suggest there has no infarction, then a permanent pacemaker is needed; if there is evidence of a new infarction it would be reasonable to monitor the patient closely and see if the heart block improves.

Summary ★★

Mobitz type 2 (second degree) block and left anterior hemiblock; probable old anterior infarction.

ME See pp. 31 and 46

IP See p. 140