Кафедра анатомии человека имени профессора М.Г.Привеса
СПб ГБОУ СПО «Медицинский техникум 9»

Функциональная анатомия аппарата дыхания

Доцент М.В.Никитин

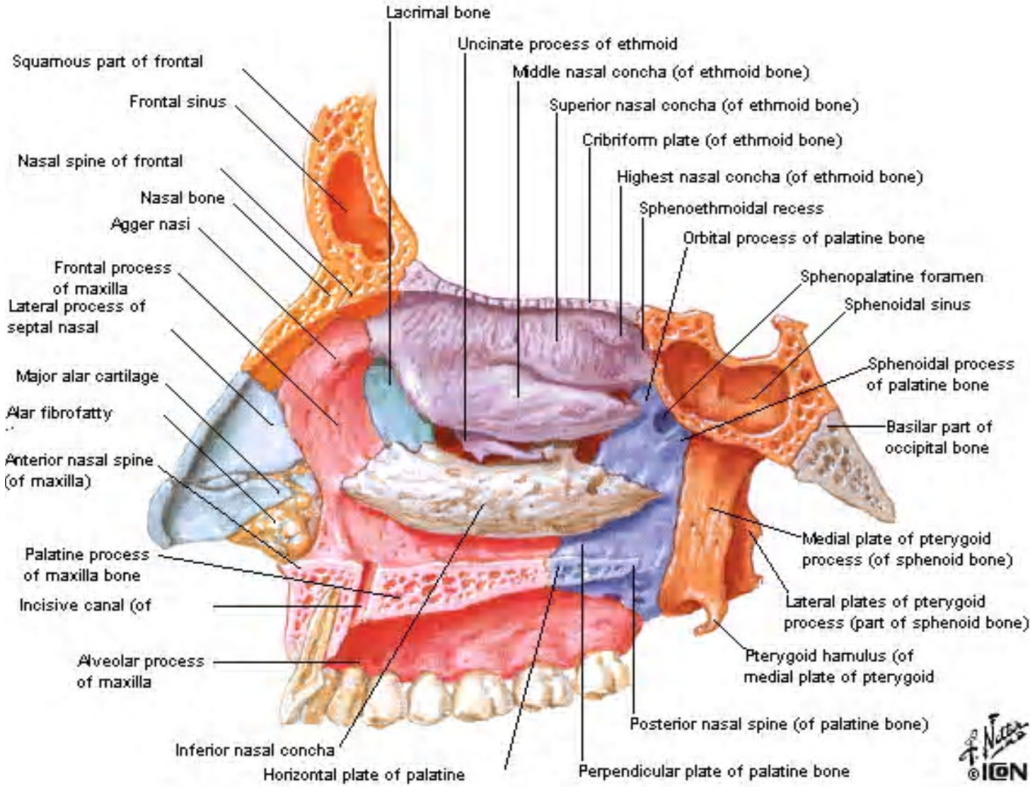
Lacrimal bone
Uncinate process of ethmoid
Middle nasal concha (of ethmoid bone)
Superior nasal concha (of ethmoid bone)
Cribriform plate (of ethmoid bone)
Highest nasal concha (of ethmoid bone)
Sphenoethmoidal recess
Orbital process of palatine bone
Sphenopalatine foramen
Sphenoidal sinus
Sphenoidal process of palatine bone
Basilar part of occipital bone
Medial plate of pterygoid process (of sphenoid bone)
Lateral plates of pterygoid process (part of sphenoid bone)
Pterygoid hamulus (of medial plate of pterygoid
Posterior nasal spine (of palatine bone)
Perpendicular plate of palatine bone
Squamous part of frontal
Frontal sinus
Nasal spine of frontal
Nasal bone
Agger nasi
Frontal process of maxilla
Lateral process of septal nasal
Major alar cartilage
Alar fibrofatty
Anterior nasal spine (of maxilla)
Palatine process of maxilla bone
Incisive canal (of
Alveolar process of maxilla
Inferior nasal concha
Horizontal plate of palatine
©ICON

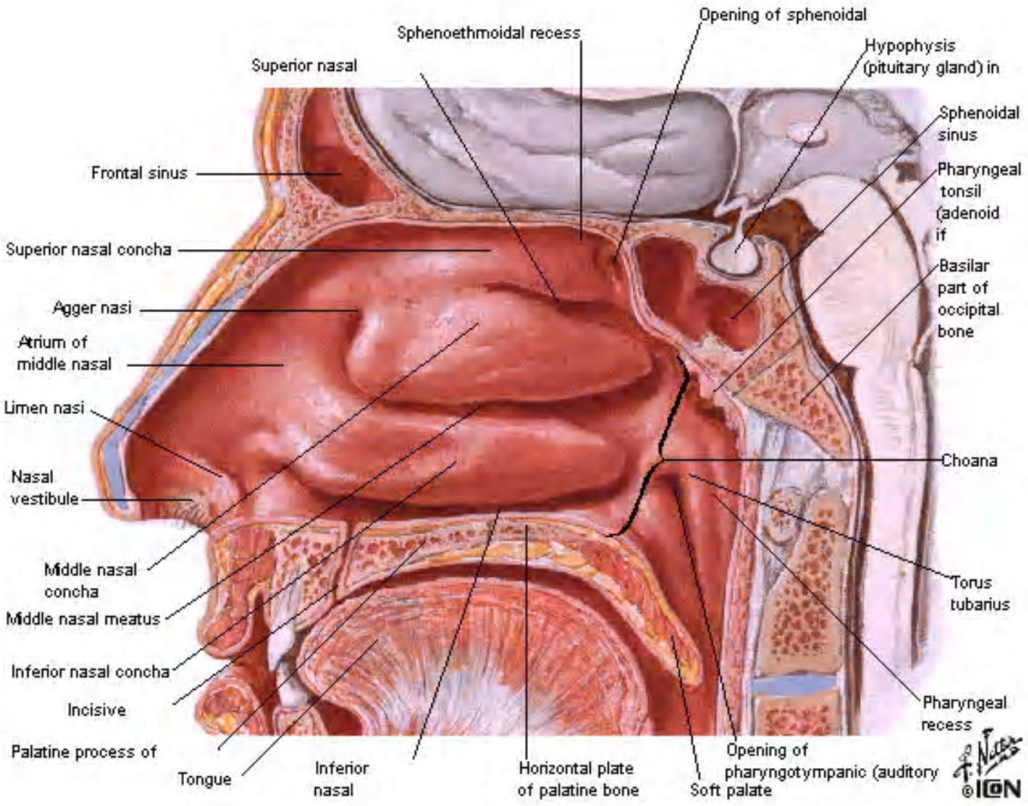
Sphenoethmoidal recess
Opening of sphenoidal
Hypophysis (pituitary gland) in
Superior nasal
Sphenoidal sinus
Frontal sinus
Pharyngeal tonsil (adenoid if
Superior nasal concha
Basilar part of occipital bone
Agger nasi
Atrium of middle nasal
Limen nasi
Choana
Nasal vestibule
Middle nasal concha
Torus tubarius
Middle nasal meatus
Inferior nasal concha
Incisive
Pharyngeal recess
Palatine process of
Tongue
Inferior nasal
Horizontal plate of palatine bone
Soft palate
Opening of pharyngotympanic (auditory
©IGN

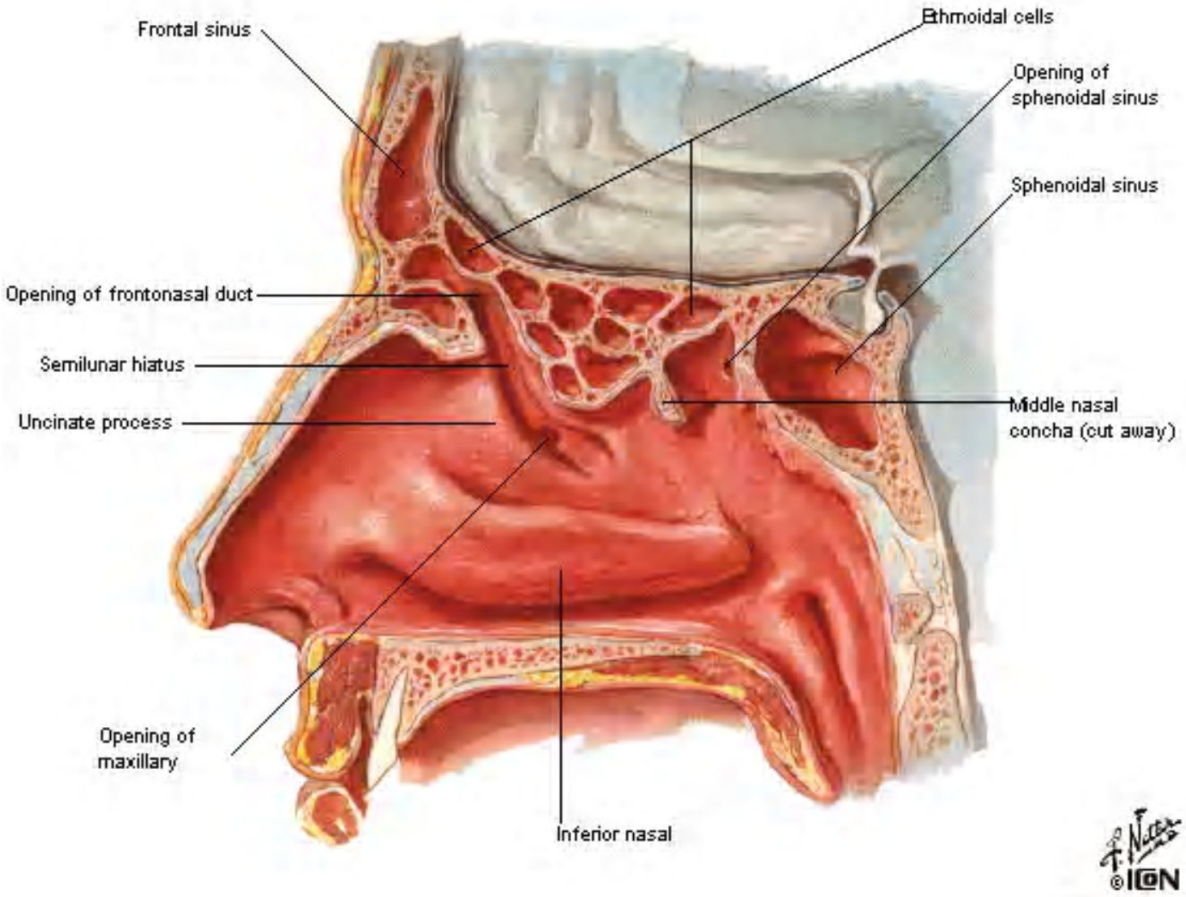
Frontal sinus
Ethmoidal cells
Opening of sphenoidal sinus
Sphenoidal sinus
Opening of frontonasal duct
Semilunar hiatus
Uncinate process
Middle nasal concha (cut away)
Opening of maxillary
Inferior nasal
©ICON

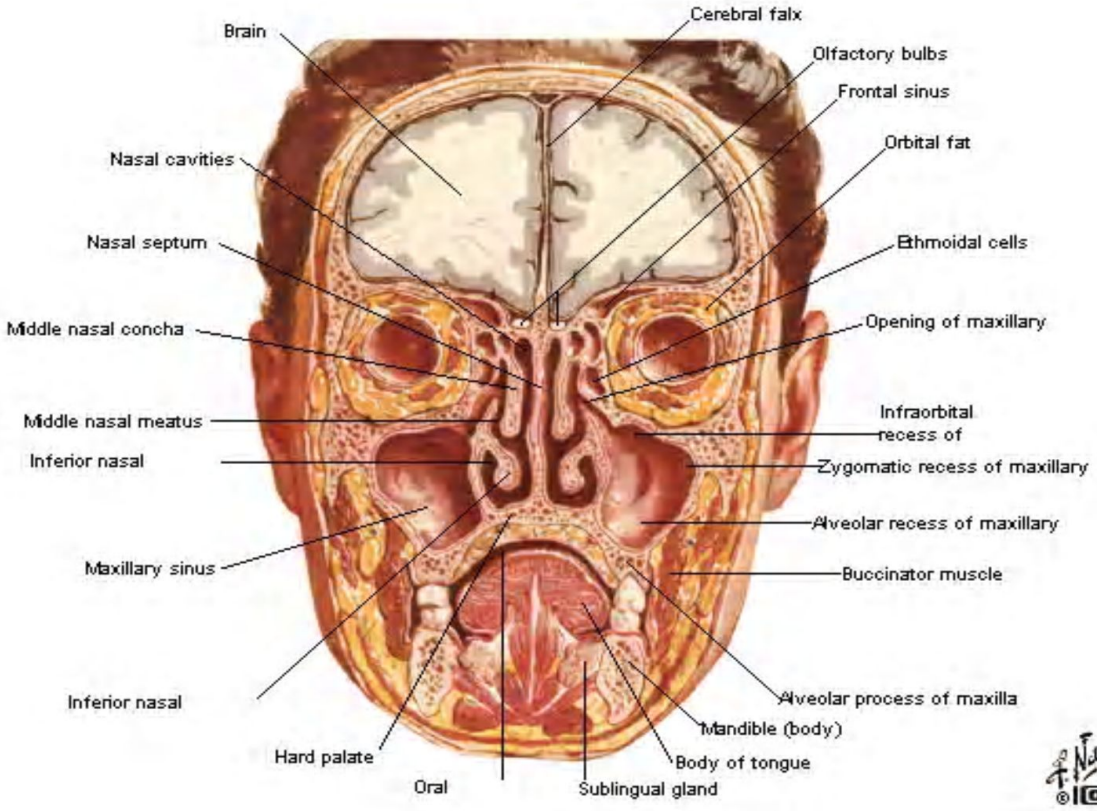
Brain
Cerebral falx
Olfactory bulbs
Frontal sinus
Orbital fat
Nasal cavities
Nasal septum
Ethmoidal cells
Middle nasal concha
Opening of maxillary
Middle nasal meatus
Infraorbital recess of
Inferior nasal
Zygomatic recess of maxillary
Alveolar recess of maxillary
Maxillary sinus
Buccinator muscle
Inferior nasal
Alveolar process of maxilla
Mandible (body)
Hard palate
Body of tongue
Oral
Sublingual gland

Paranasal Sinuses

At Birth

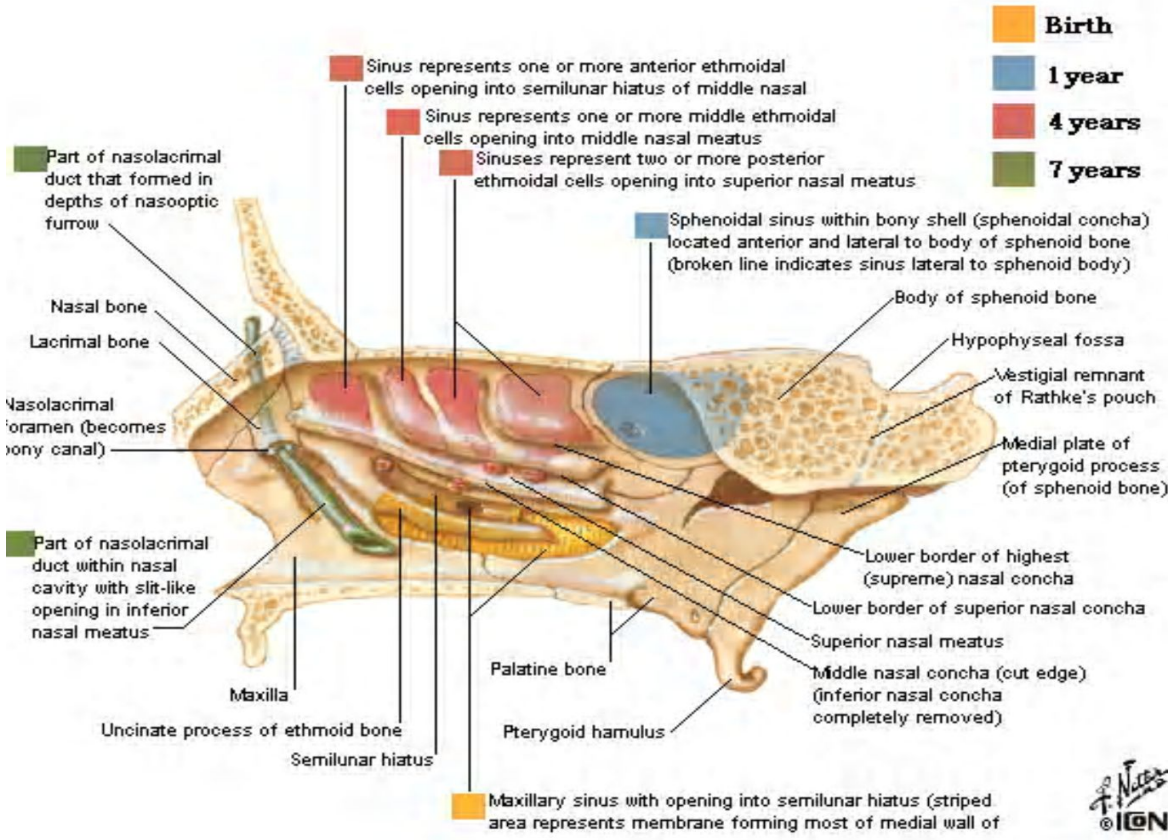

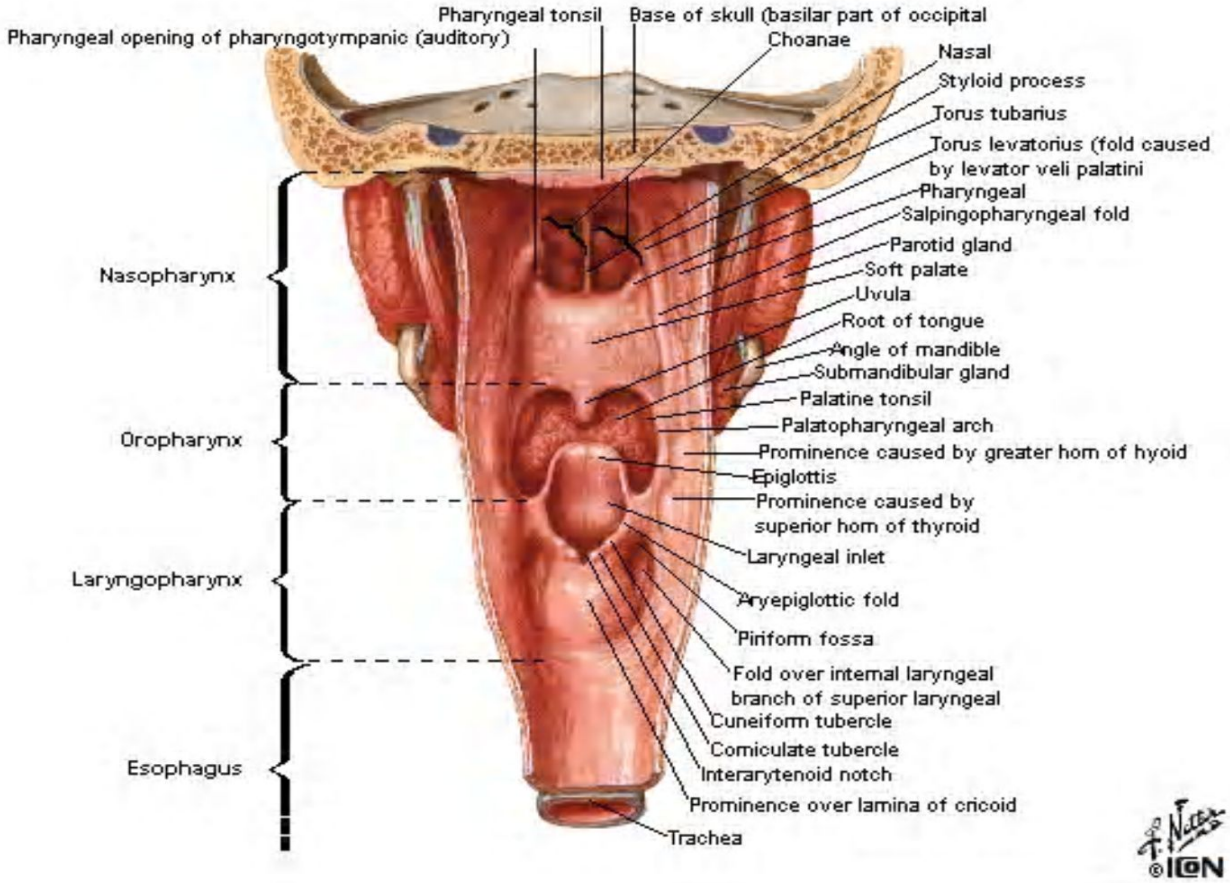
Pharyngeal tonsil
Base of skull (basilar part of occipital
Pharyngeal opening of pharyngotympanic (auditory)
Choanae
Nasal
Styloid process
Torus tubarius
Torus levatorius (fold caused by levator veli palatini
Pharyngeal
Salpingopharyngeal fold
Parotid gland
Soft palate
Uvula
Root of tongue
Angle of mandible
Submandibular gland
Palatine tonsil
Palatopharyngeal arch
Prominence caused by greater horn of hyoid
Epiglottis
Prominence caused by superior horn of thyroid
Laryngeal inlet
Aryepiglottic fold
Piriform fossa
Fold over internal laryngeal branch of superior laryngeal
Cuneiform tubercle
Corniculate tubercle
Interarytenoid notch
Prominence over lamina of cricoid
Trachea
Nasopharynx
Oropharynx
Laryngopharynx
Esophagus
©ICON

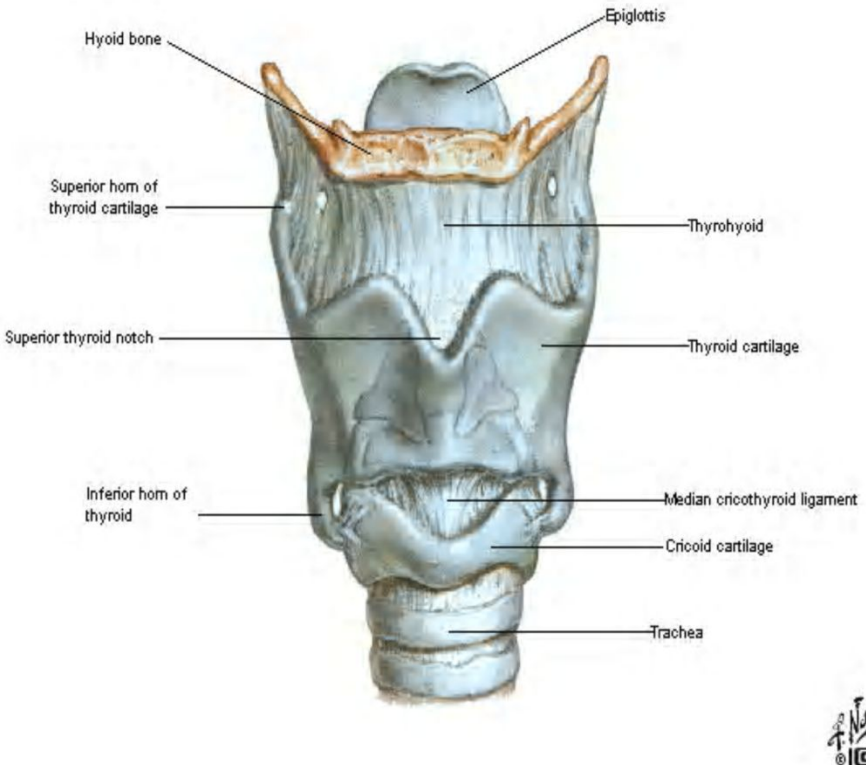
Hyoid bone
Epiglottis
Superior horn of thyroid cartilage
Thyrohyoid
Superior thyroid notch
Thyroid cartilage
Inferior horn of thyroid
Median cricothyroid ligament
Cricoid cartilage
Trachea

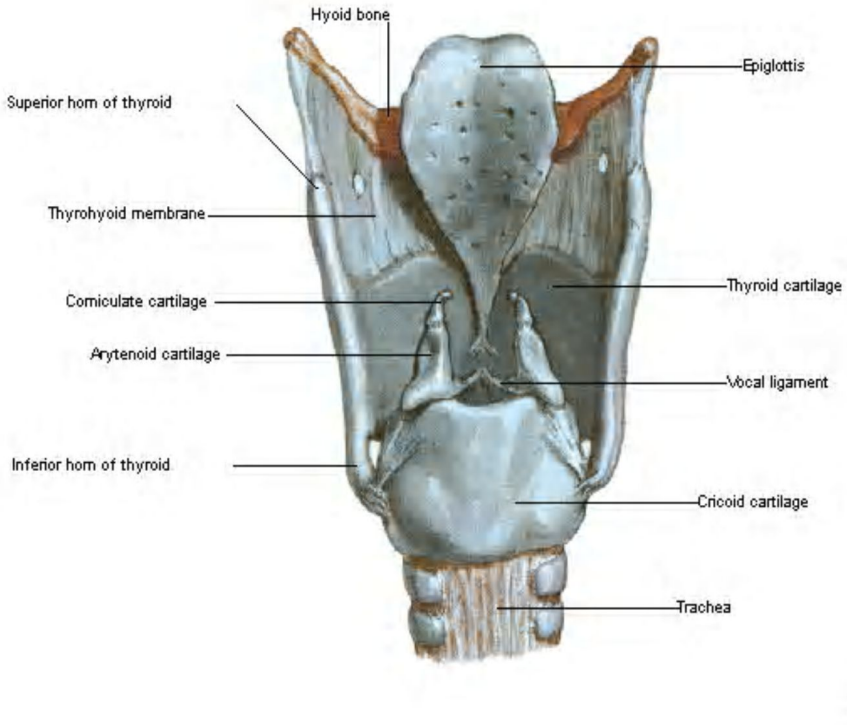
Hyoid bone
Epiglottis
Superior horn of thyroid
Thyrohyoid membrane
Thyroid cartilage
Corniculate cartilage
Arytenoid cartilage
Vocal ligament
Inferior horn of thyroid
Cricoid cartilage
Trachea

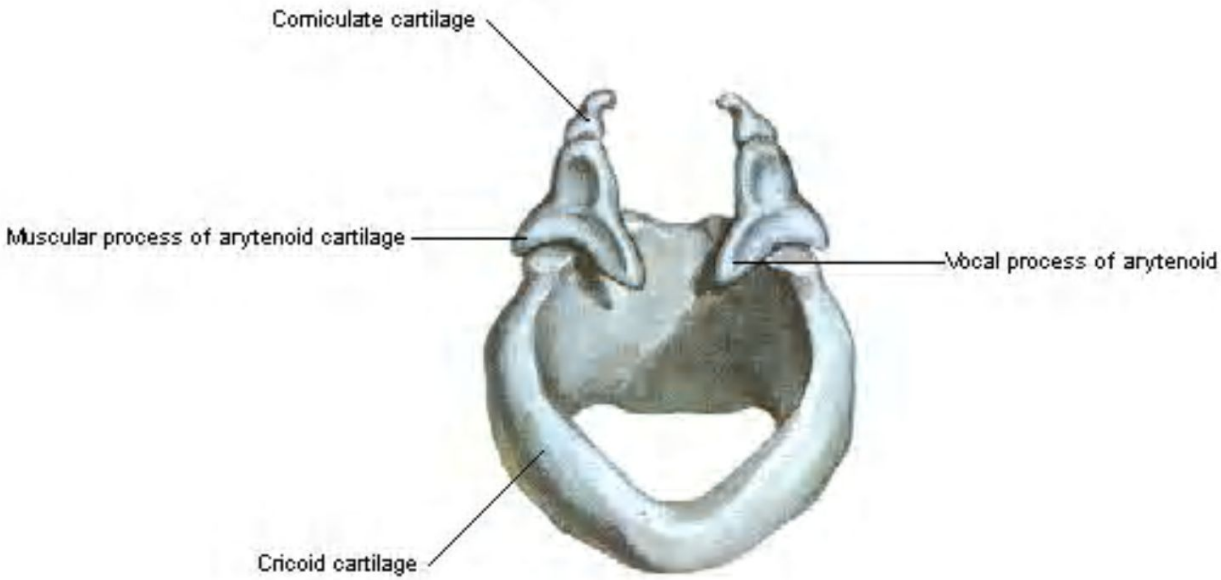
Corniculate cartilage
Muscular process of arytenoid cartilage
Vocal process of arytenoid
Cricoid cartilage

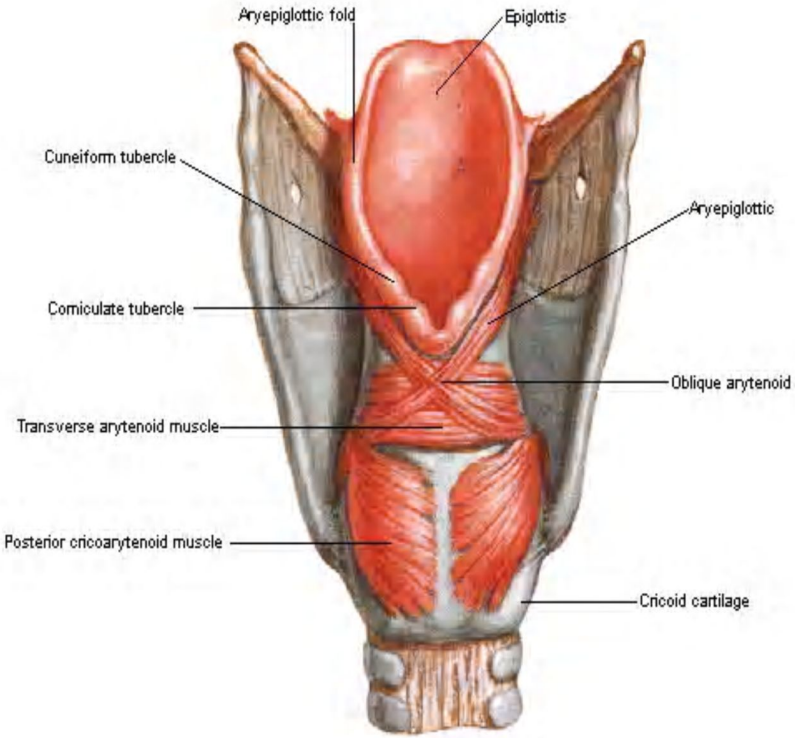
Aryepiglottic fold
Epiglottis
Cuneiform tubercle
Aryepiglottic
Corniculate tubercle
Oblique arytenoid
Transverse arytenoid muscle
Posterior cricoarytenoid muscle
Cricoid cartilage

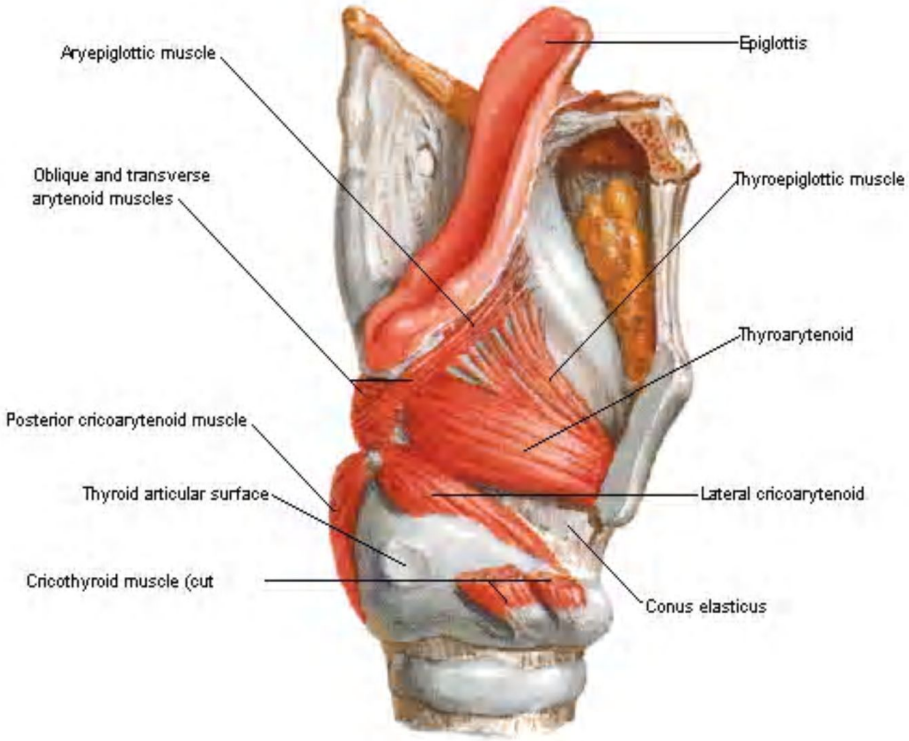
Aryepiglottic muscle
Epiglottis
Oblique and transverse
arytenoid muscles
Thyroepiglottic muscle
Thyroarytenoid
Posterior cricoarytenoid muscle
Thyroid articular surface
Lateral cricoarytenoid
Cricothyroid muscle (cut
Conus elasticus

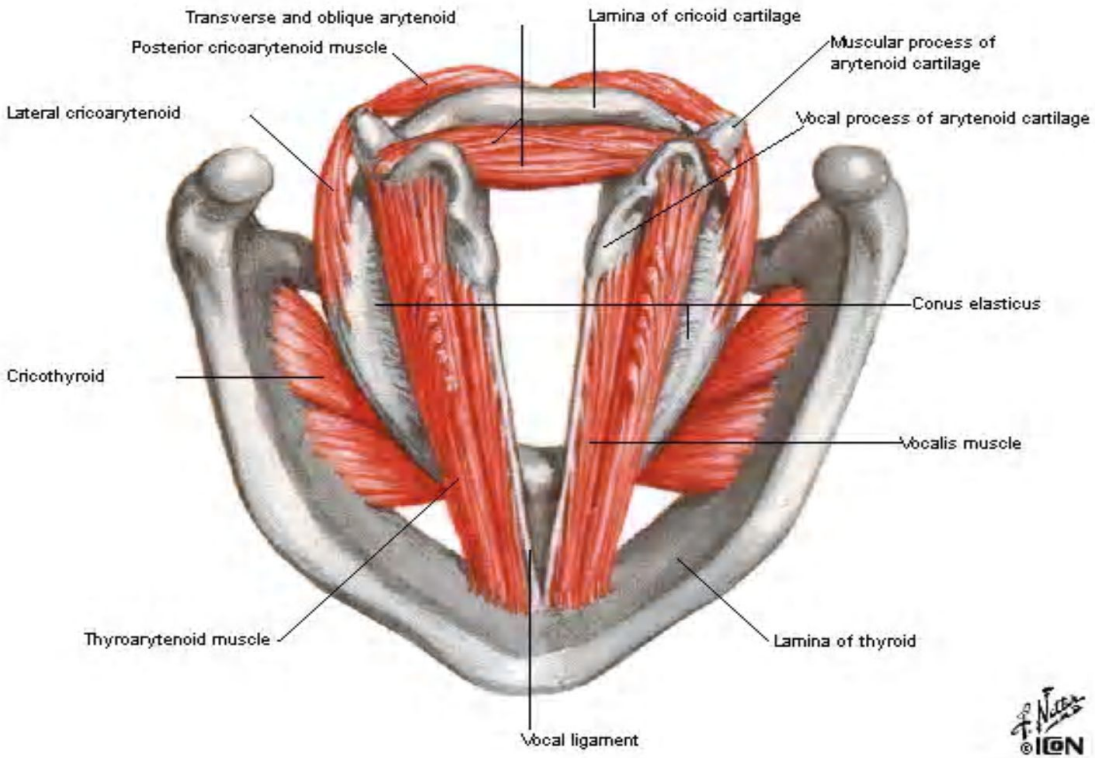
Transverse and oblique arytenoid
Posterior cricoarytenoid muscle
Lamina of cricoid cartilage
Muscular process of arytenoid cartilage
Lateral cricoarytenoid
Vocal process of arytenoid cartilage
Conus elasticus
Cricothyroid
Vocalis muscle
Thyroarytenoid muscle
Lamina of thyroid
Vocal ligament
©ICON

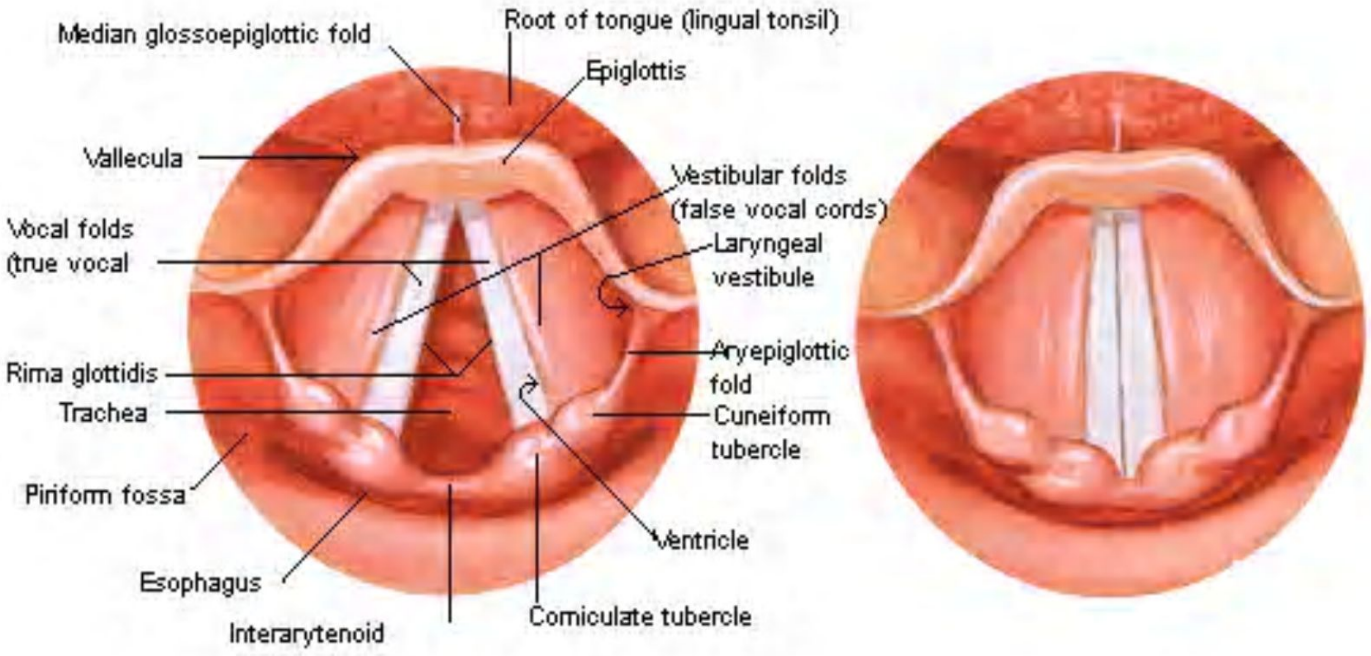

Normal larynx: inspiration

Normal larynx: phonation

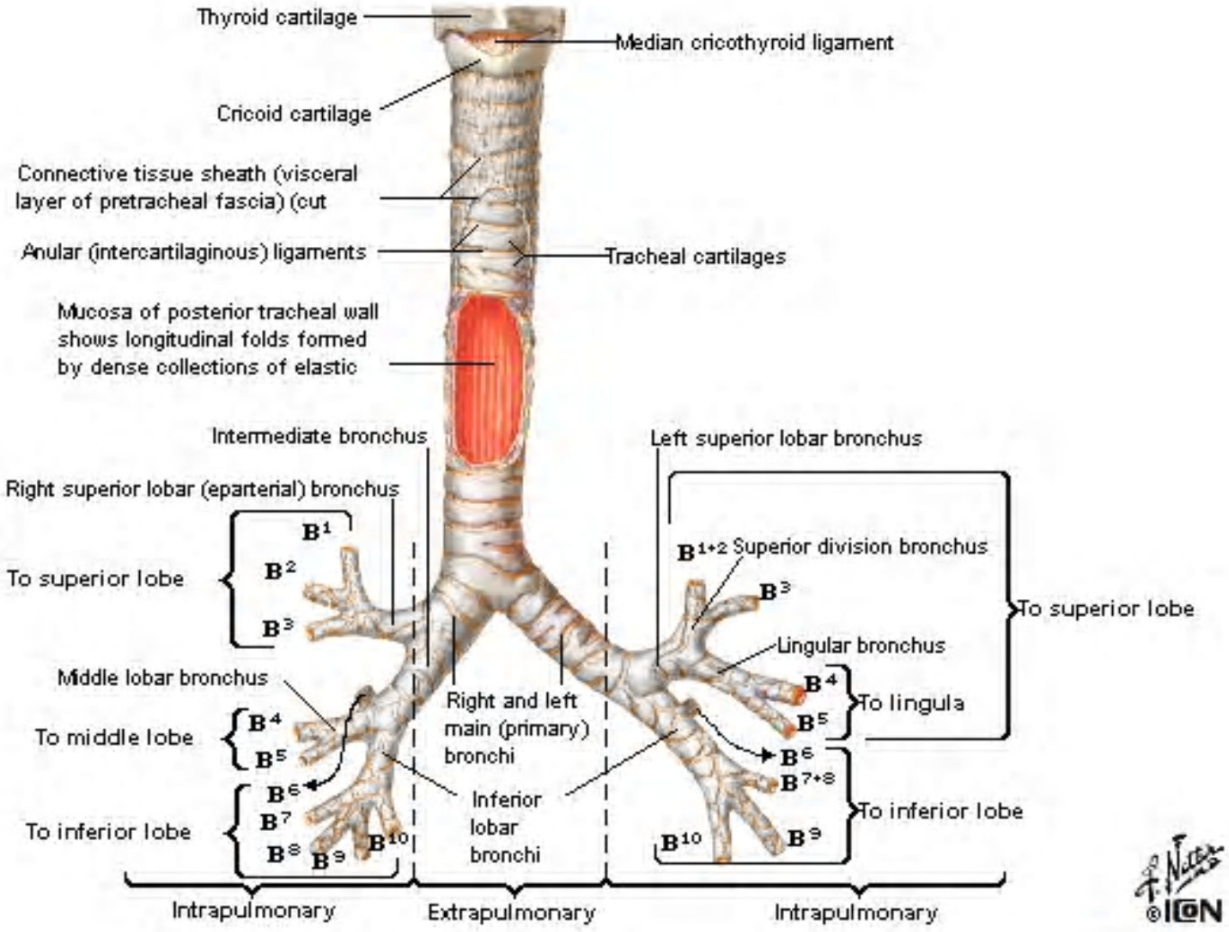
Thyroid cartilage
Median cricothyroid ligament
Cricoid cartilage
Connective tissue sheath (visceral layer of pretracheal fascia) (cut
Anular (intercartilaginous) ligaments
Tracheal cartilages
Mucosa of posterior tracheal wall shows longitudinal folds formed by dense collections of elastic
Intermediate bronchus
Left superior lobar bronchus
Right superior lobar (eparterial) bronchus
B1
B2
B3
To superior lobe
B1+2 Superior division bronchus
B3
To superior lobe
Lingular bronchus
B4
B5
To lingula
Middle lobar bronchus
To middle lobe
B4
B5
Right and left main (primary) bronchi
B6
B7+8
To inferior lobe
B6
B7
B8
B9
B10
To inferior lobe
Inferior lobar bronchi
B10
B9
Intrapulmonary
Extrapulmonary
Intrapulmonary
©ICON

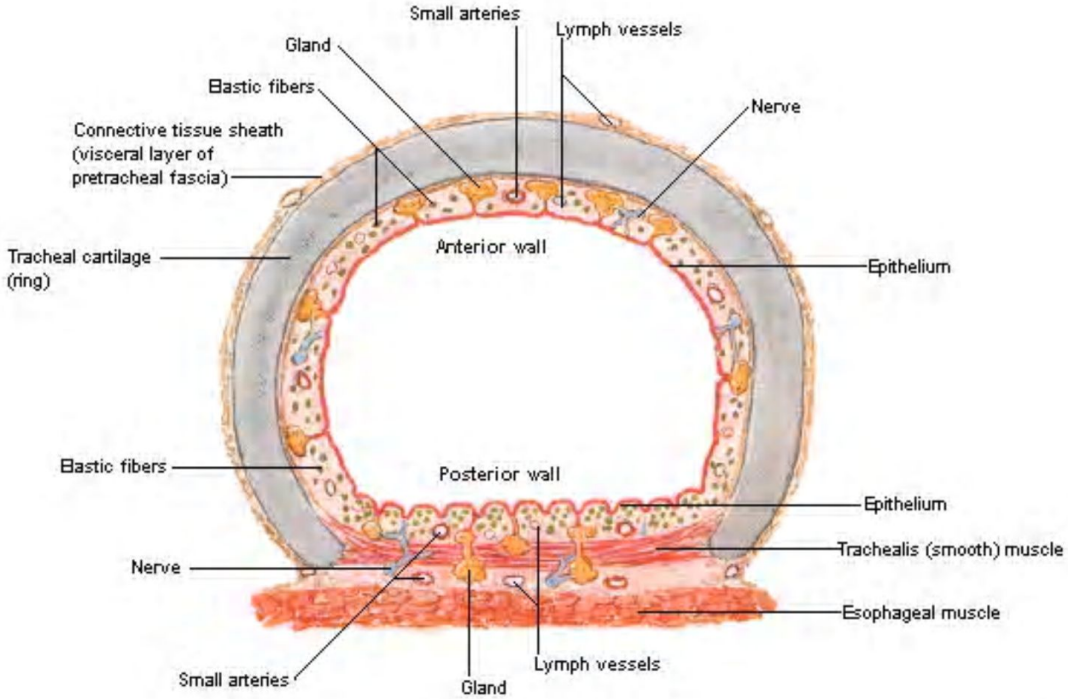
Small arteries
Lymph vessels
Gland
Elastic fibers
Nerve
Connective tissue sheath
(visceral layer of
pretracheal fascia)
Anterior wall
Tracheal cartilage
(ring)
Epithelium
Elastic fibers
Posterior wall
Epithelium
Trachealis (smooth) muscle
Nerve
Esophageal muscle
Lymph vessels
Small arteries
Gland

© ICON

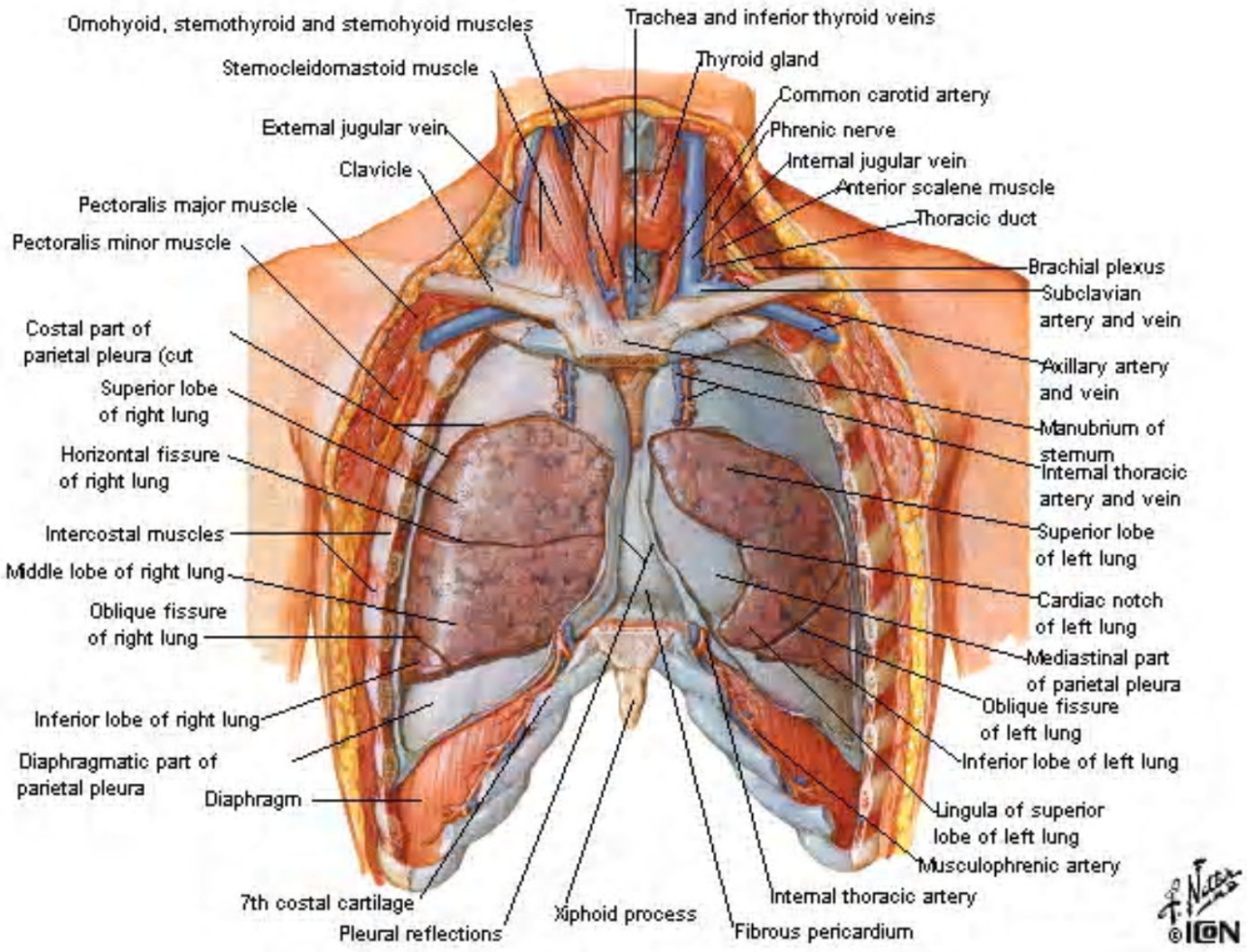
Omohyoid, sternothyroid and sternohyoid muscles
Sternocleidomastoid muscle
External jugular vein
Clavicle
Pectoralis major muscle
Pectoralis minor muscle
Costal part of parietal pleura (cut
Superior lobe of right lung
Horizontal fissure of right lung
Intercostal muscles
Middle lobe of right lung
Oblique fissure of right lung
Inferior lobe of right lung
Diaphragmatic part of parietal pleura
Diaphragm
7th costal cartilage
Pleural reflections
Xiphoid process
Fibrous pericardium
Internal thoracic artery
Musculophrenic artery
Lingula of superior lobe of left lung
Inferior lobe of left lung
Oblique fissure of left lung
Mediastinal part of parietal pleura
Cardiac notch of left lung
Superior lobe of left lung
Internal thoracic artery and vein
Manubrium of sternum
Axillary artery and vein
Subclavian artery and vein
Brachial plexus
Thoracic duct
Anterior scalene muscle
Internal jugular vein
Phrenic nerve
Common carotid artery
Thyroid gland
Trachea and inferior thyroid veins
©ICON

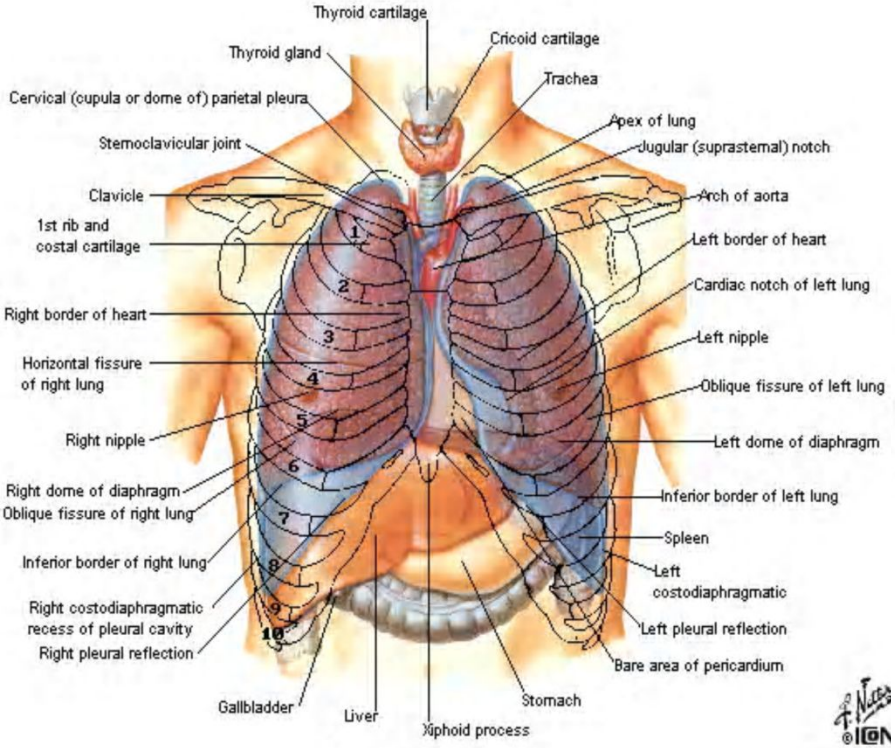
Thyroid cartilage
Thyroid gland
Cricoid cartilage
Trachea
Cervical (cupula or dome of) parietal pleura
Apex of lung
Sternoclavicular joint
Jugular (suprasternal) notch
Clavicle
Arch of aorta
1st rib and
costal cartilage
Left border of heart
Cardiac notch of left lung
Right border of heart
Left nipple
Horizontal fissure
of right lung
Oblique fissure of left lung
Right nipple
Left dome of diaphragm
Right dome of diaphragm
Oblique fissure of right lung
Inferior border of left lung
Spleen
Inferior border of right lung
Left
costodiaphragmatic
Right costodiaphragmatic
recess of pleural cavity
Left pleural reflection
Right pleural reflection
Bare area of pericardium
Stomach
Gallbladder
Liver
Xiphoid process

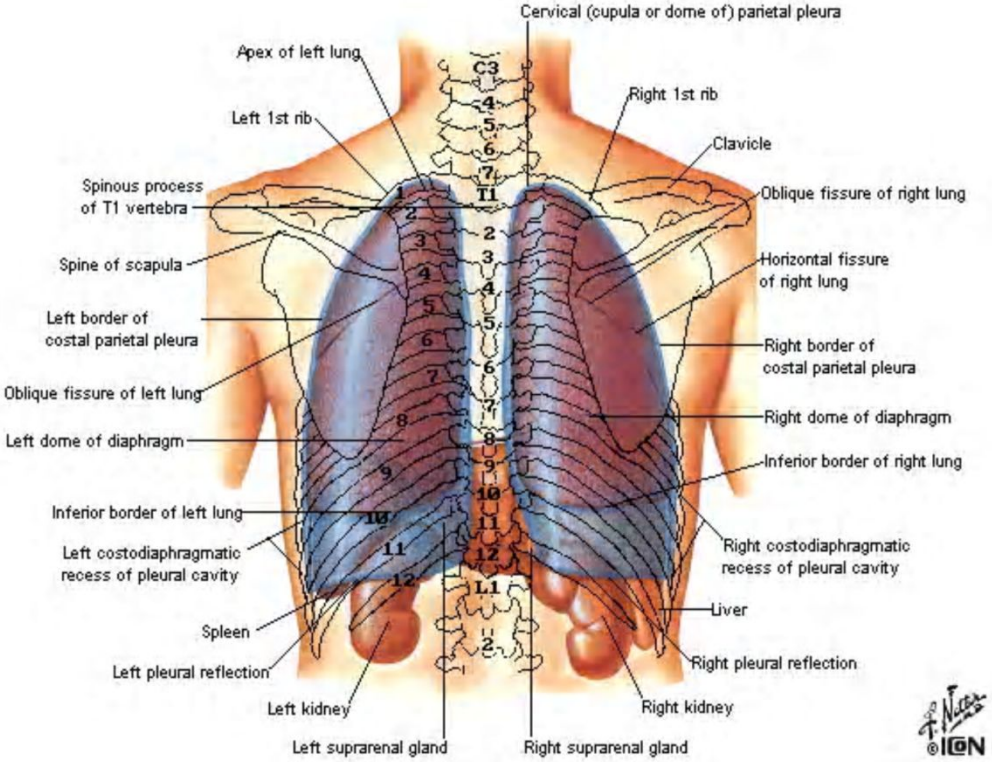
Cervical (cupula or dome of) parietal pleura
Apex of left lung
Right 1st rib
Left 1st rib
Clavicle
Spinous process
of T1 vertebra
Oblique fissure of right lung
Spine of scapula
Horizontal fissure
of right lung
Left border of
costal parietal pleura
Right border of
costal parietal pleura
Oblique fissure of left lung
Right dome of diaphragm
Left dome of diaphragm
Inferior border of right lung
Inferior border of left lung
Right costodiaphragmatic
recess of pleural cavity
Left costodiaphragmatic
recess of pleural cavity
Liver
Spleen
Right pleural reflection
Left pleural reflection
Left kidney
Right kidney
Left suprarenal gland
Right suprarenal gland

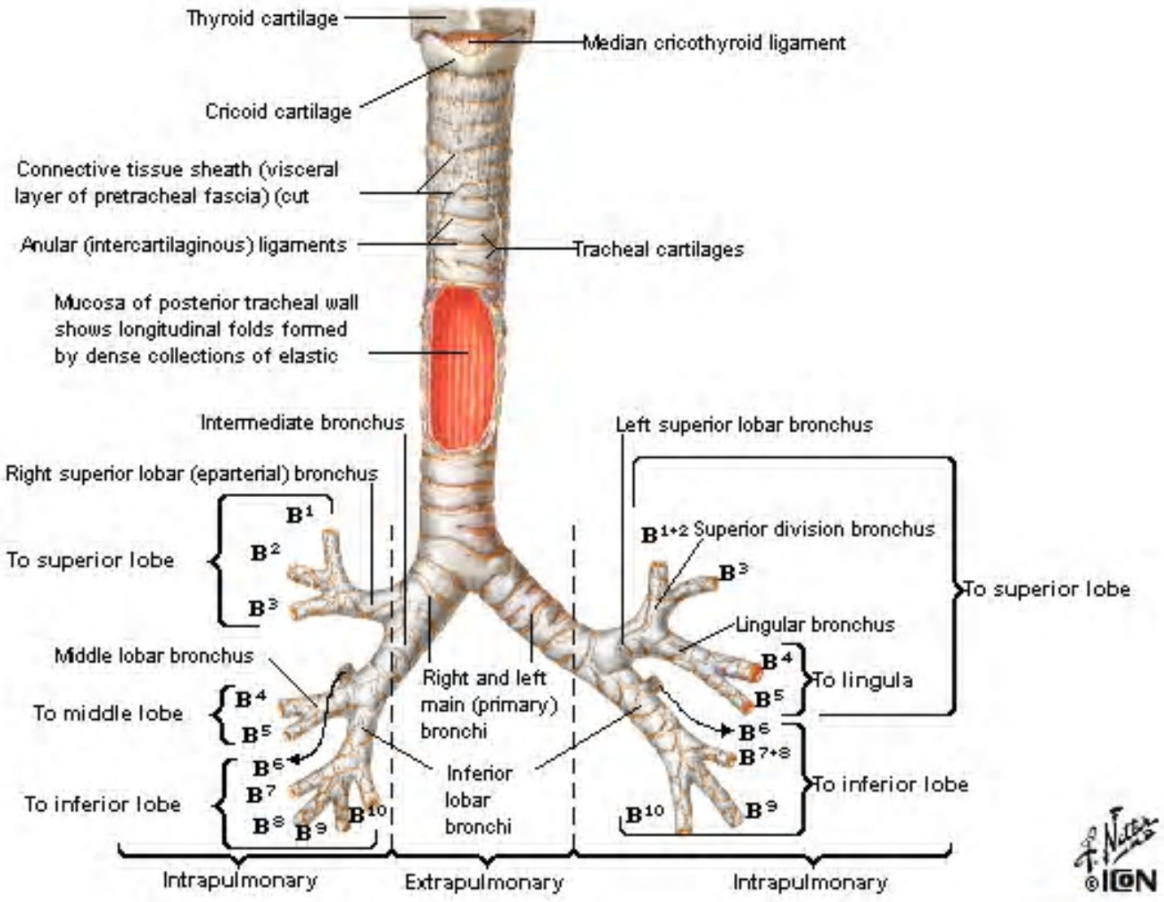
Thyroid cartilage
Median cricothyroid ligament
Cricoid cartilage
Connective tissue sheath (visceral layer of pretracheal fascia) (cut
Anular (intercartilaginous) ligaments
Tracheal cartilages
Mucosa of posterior tracheal wall shows longitudinal folds formed by dense collections of elastic
Intermediate bronchus
Left superior lobar bronchus
Right superior lobar (eparterial) bronchus
B1
B2
B3
To superior lobe
B1+2 Superior division bronchus
B3
To superior lobe
Lingular bronchus
B4
B5
To lingula
Middle lobar bronchus
To middle lobe
B4
B5
Right and left main (primary) bronchi
B6
B7+8
To inferior lobe
B6
B7
B8
B9
B10
To inferior lobe
Inferior lobar bronchi
B10
B9
Intrapulmonary
Extrapulmonary
Intrapulmonary
©ICON

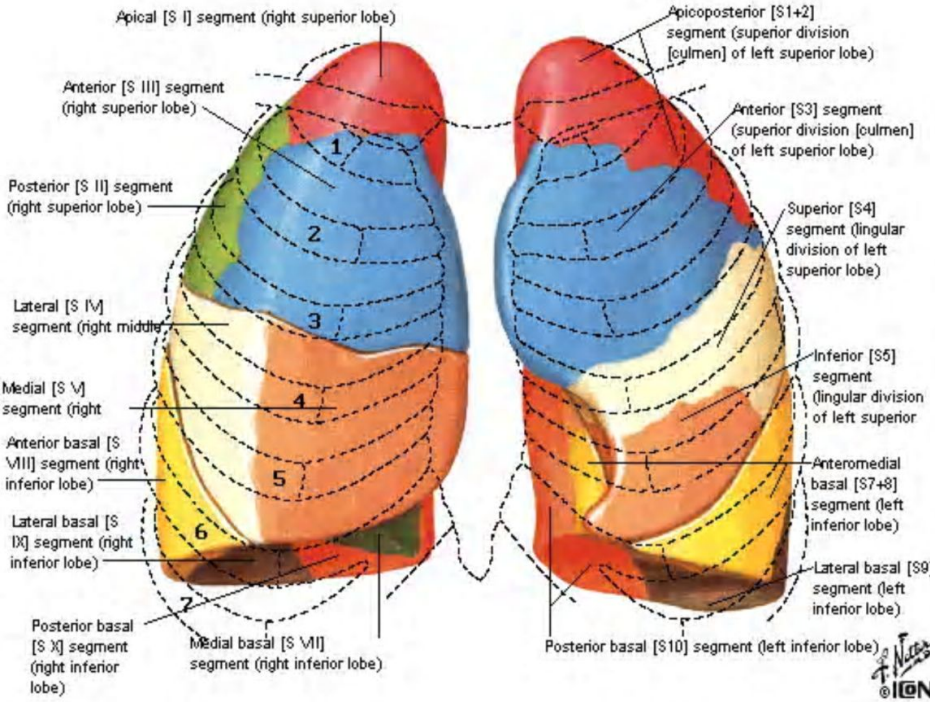

Right lung Left lung

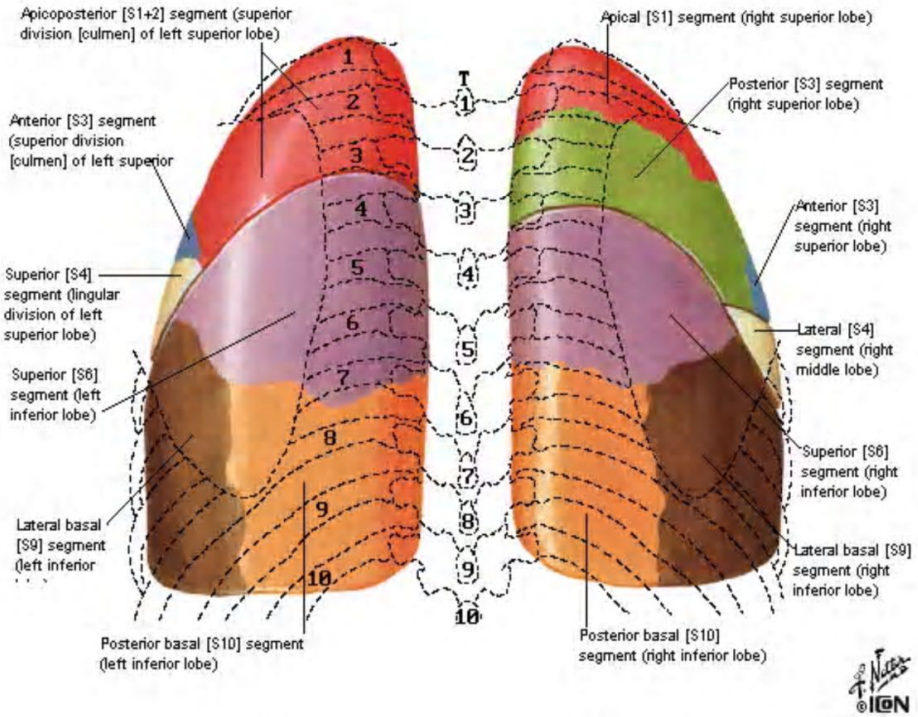

Left lung Right lung

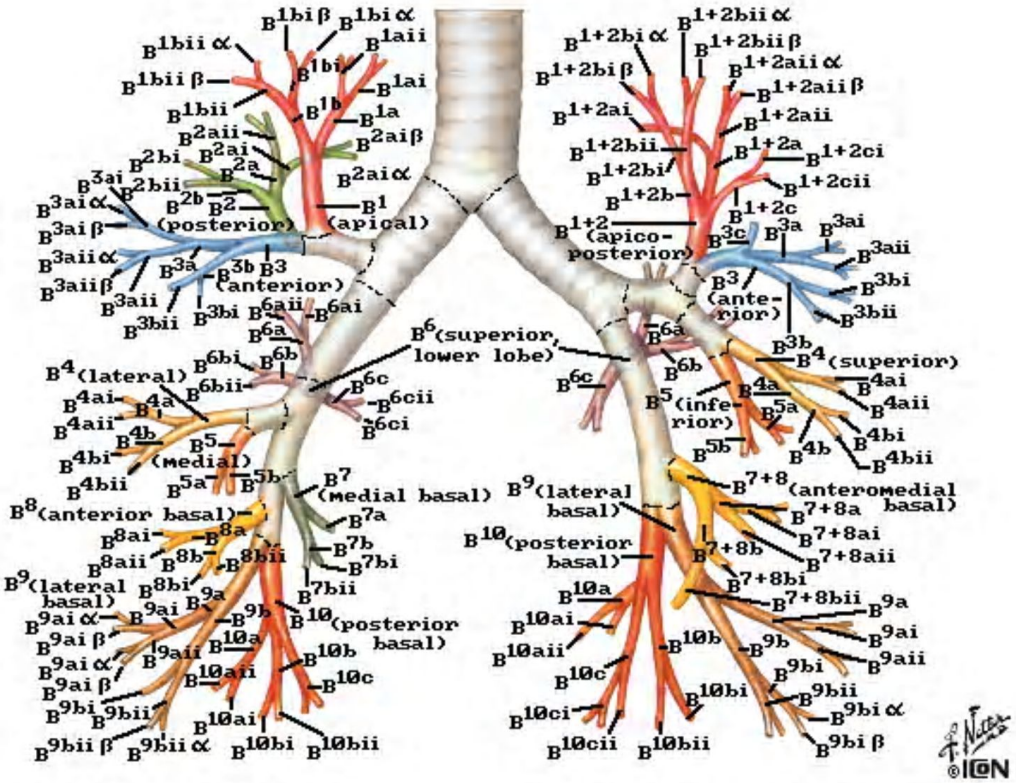
B1bi β
B1bi α
B1aii
B1bii α
B1bi
B1bii β
B1ai
B1bii
B1b
B1a
B2aii
B2ai β
B2bi
B2ai
B2a
B2ai α
B3ai
B2bii
B3ai α
B2b
B2
B1
(posterior)
(apical)
B3ai β
B3aii α
B3a
B3b
B3
B3aii β
(anterior)
B3aii
B3bii
B3bi
B6aii
B6ai
B6a
B6(superior,
lower lobe)
B4(lateral)
B6bi
B6b
B6bii
B6c
B4ai
B4a
B6cii
B4aii
B6ci
B4b
B5
B4bi
(medial)
B4bii
B5a
B5b
B7
(medial basal)
B8(anterior basal)
B7a
B8ai
B8a
B7b
B8aii
B8b
B8bii
B7bi
B9(lateral
basal)
B8bi
B7bii
B9a
B9ai
B9b
B10
(posterior
basal)
B9ai α
B9ai β
B9aii
B10a
B10b
B9ai α
B10aii
B10c
B9ai β
B9bi
B9bii
B10ai
B9bii β
B9bii α
B10bi
B10bii
B1+2bii α
B1+2bi α
B1+2bii β
B1+2aii α
B1+2bi β
B1+2aii β
B1+2ai
B1+2aii
B1+2bii
B1+2a
B1+2ci
B1+2bi
B1+2cii
B1+2b
B1+2c
B1+2
(apico-
posterior)
B3c
B3a
B3ai
B3aii
B3
(ante-
rior)
B3bi
B3bii
B6a
B3b
B6b
B4(superior)
B6c
B4ai
B5
(infe-
rior)
B4a
B4aii
B5a
B4bi
B5b
B4b
B4bii
B9(lateral
basal)
B7+8
(anteromedial
basal)
B7+8a
B10(posterior
basal)
B7+8ai
B7+8b
B7+8aii
B7+8bi
B10a
B7+8bii
B9a
B10ai
B10b
B9b
B9ai
B10aii
B9bi
B9aii
B10c
B9bii
B10bi
B9bi α
B10ci
B9bi β
B10cii
B10bii
©ICON

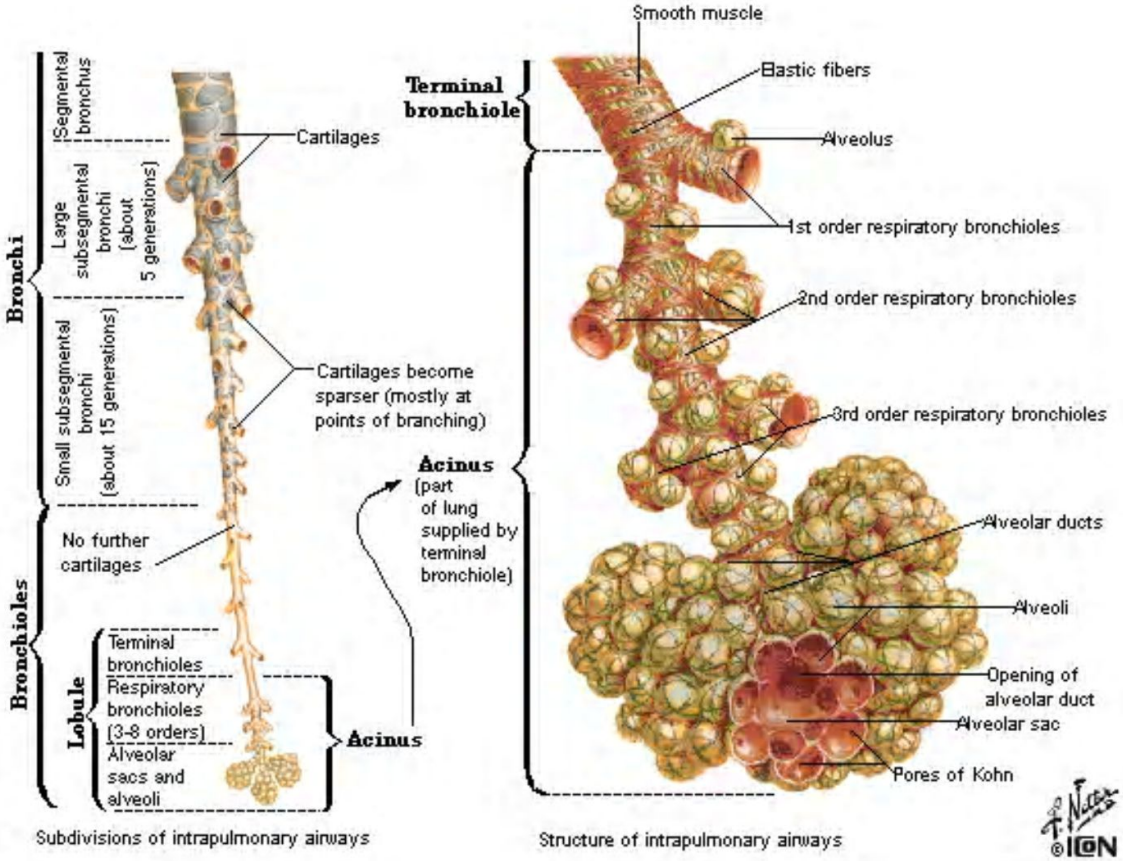

Subdivisions of intrapulmonary airways

Structure of intrapulmonary airways

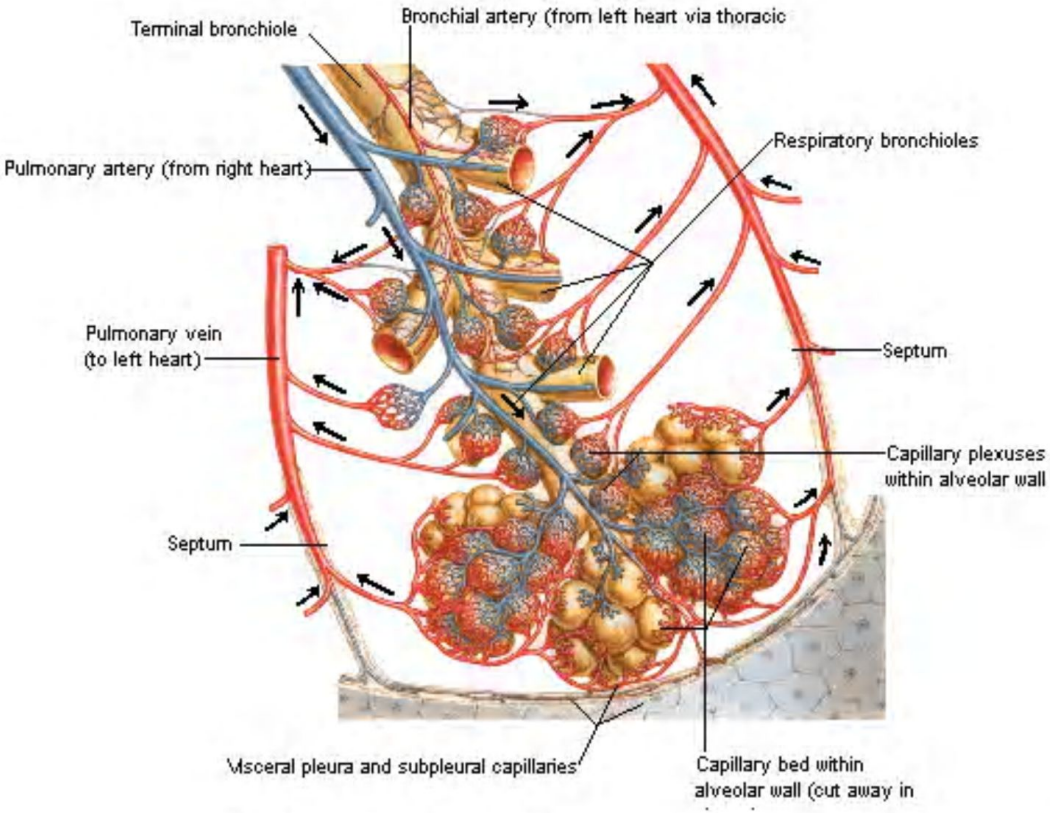
Terminal bronchiole
Bronchial artery (from left heart via thoracic
Respiratory bronchioles
Pulmonary artery (from right heart)
Pulmonary vein
(to left heart)
Septum
Capillary plexuses
within alveolar wall
Septum
Visceral pleura and subpleural capillaries
Capillary bed within
alveolar wall (cut away in

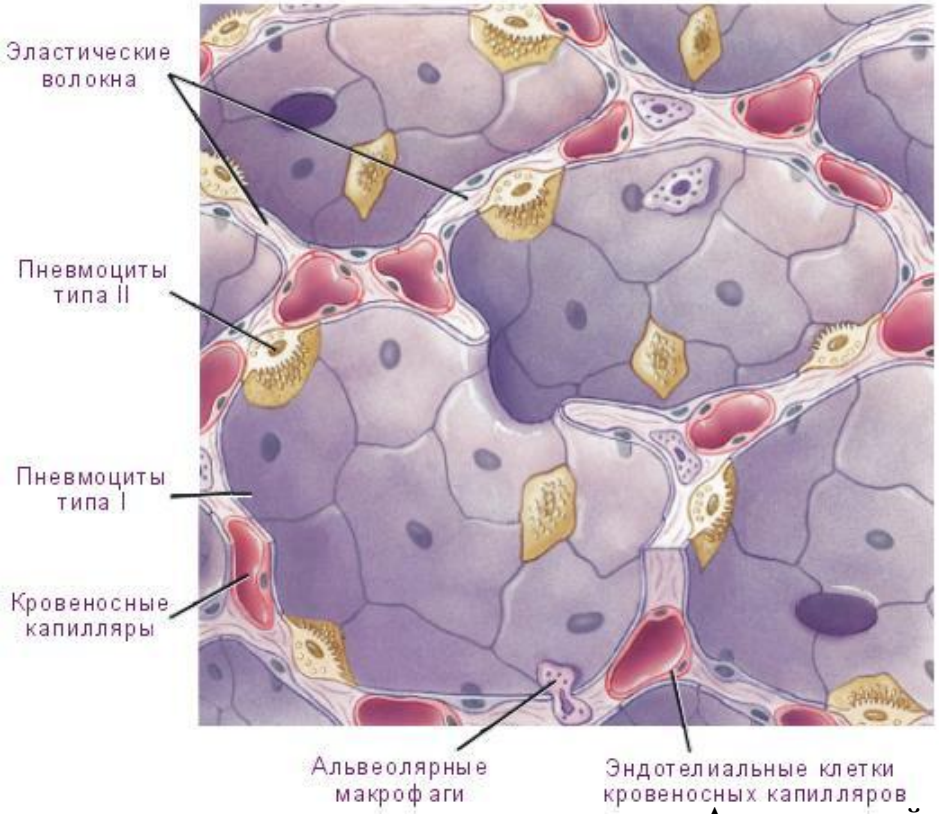

Альвеолярный эпителий представлен двумя главными типами клеток.

Пневмоциты (альвеолоциты) типа I - это чешуйчатые тонкие клетки однослойного плоского эпителия. У них одно ядро, располагающееся на периферии. Противоположные поверхности таких клеток могут быть обращены в полости соседних альвеол.

Пневмоциты (альвеолоциты) типа II - это гранулярные клетки кубовидной формы. Они покрывают остальную поверхность альвеол, выступая над их поверхностью. Эти клетки синтезируют и выделяют сурфактант, вещество, вещество, участвующее в поддержании однородной конфигурации и объёма альвеол. Пневмоциты типа II участвуют в транспорте жидкостей через альвеолярно-капиллярную мембрану.

Толщина альвеолярно- капиллярной мембраны приблизительно ~0,2мкм, в области клеточных ядер - 10мкм.

Сурфактант - поверхностноактивное вещество. Легочный сурфактант (pulmonary surfactant), секретируемый пневмоцитами II типа, представляет собой сложную смесь различных соединений (включая фосфолипиды, белки и полисахариды);

сурфактант препятствует спадению альвеол благодаря поддержанию поверхностного натяжения альвеолы.

При отсутствии сурфактанта, как, например, в случае недоразвитых легких у недоношенных детей, у них может развиться ателектаз (спадение легочной ткани).

«Dum spiro spero»

Благодарю за внимание