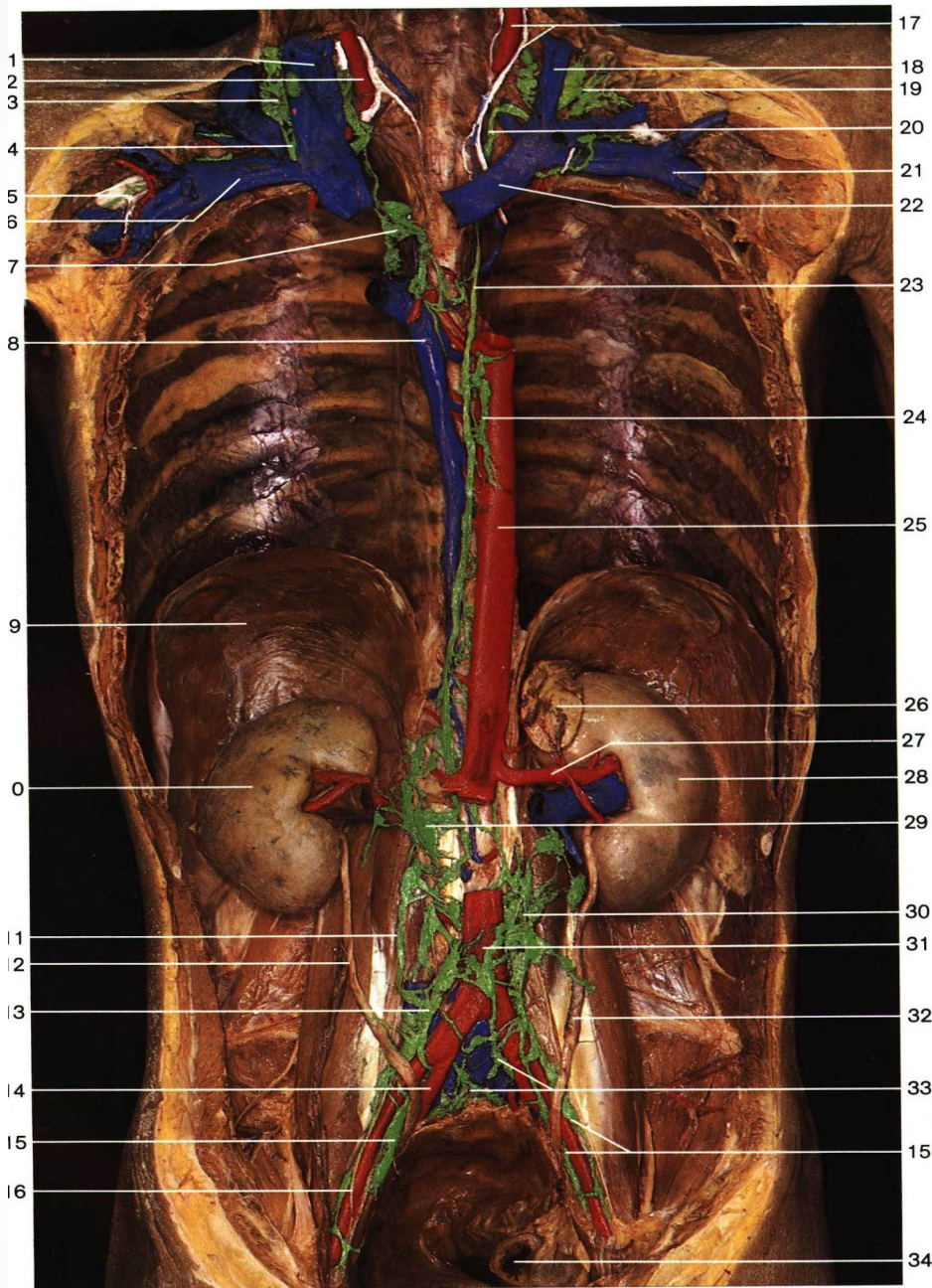


К

глазодвигательным

нервам:

Пути лимфатичес кого оттока



1
2
3
4
5
6
7
8
9
0
1
2
3
4
5
6

17
18
19
20
21
22
23
24
25
26
27
28
29
30
31
32
33
34

- 1 Internal jugular vein
- 2 Right common carotid artery and right vagus nerve
- 3 Jugulo-omohyoid lymph node
- 4 Right lymphatic duct
- 5 Subclavian trunk
- 6 Right subclavian vein
- 7 Bronchomediastinal trunk
- 8 Azygos vein
- 9 Diaphragm
- 10 Right kidney
- 11 Right lumbar trunk
- 12 Right ureter
- 13 Common iliac lymph nodes
- 14 Right internal iliac artery
- 15 External iliac lymph nodes
- 16 Right external iliac artery
- 17 Left common carotid artery and left vagus nerve
- 18 Internal jugular vein
- 19 Deep cervical lymph nodes
- 20 Thoracic duct entering left jugular angle
- 21 Left subclavian vein
- 22 Left brachiocephalic vein
- 23 **Thoracic duct**
- 24 Mediastinal lymph nodes
- 25 Thoracic aorta
- 26 Left suprarenal gland
- 27 Left renal artery
- 28 Left kidney
- 29 Cisterna chyli
- 30 Lumbar lymph nodes
- 31 Abdominal aorta
- 32 Left ureter
- 33 Sacral lymph nodes
- 34 Rectum (cut edge)

Lymph vessels and lymph nodes of the posterior wall of thoracic and abdominal cavities (anterior aspect). Green = lymph vessels and nodes; blue = veins; red = arteries; white = nerves.

Отводящий нерв

CN VI

n. abducens

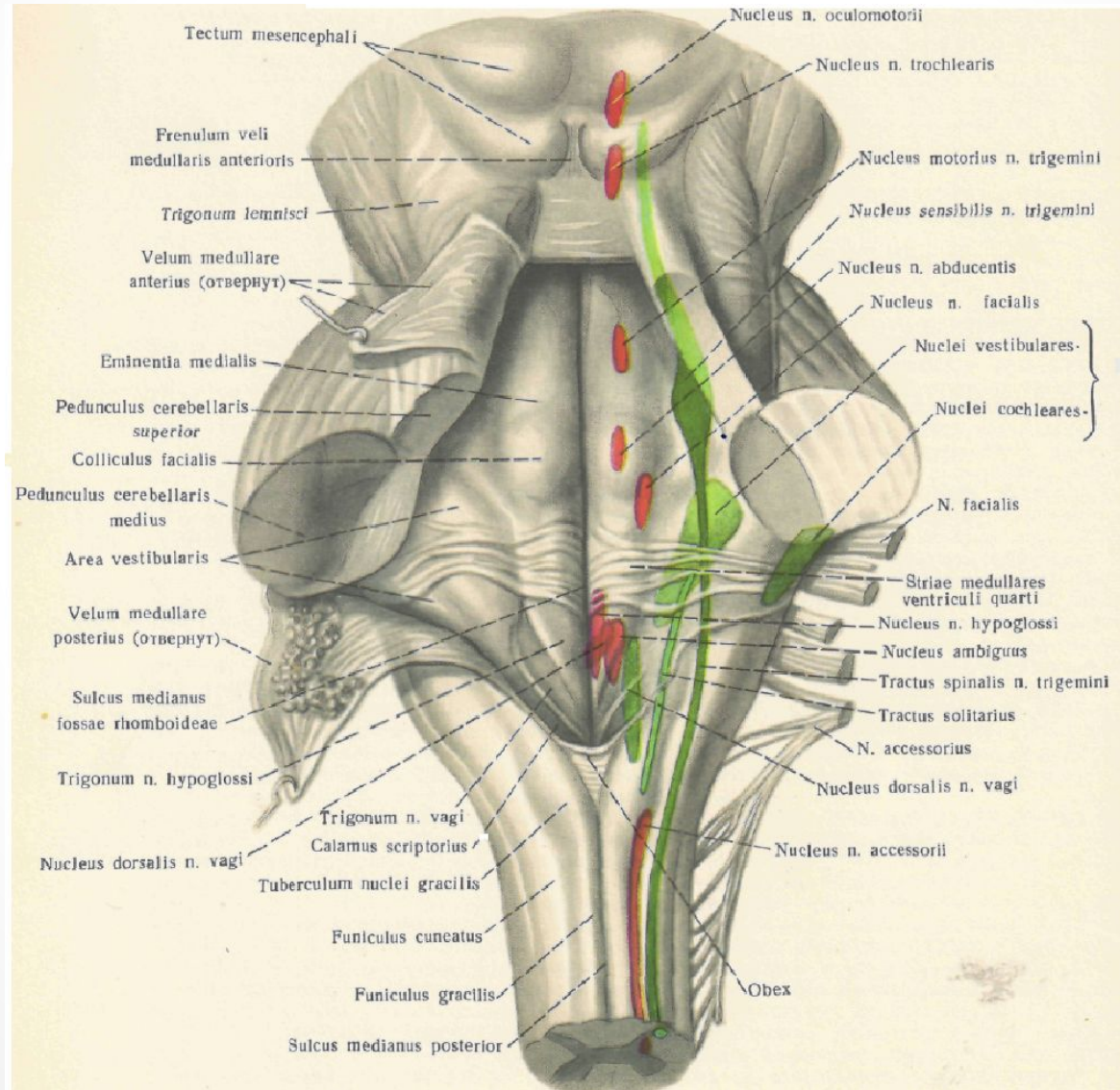
- Иллюстрации по отводящему нерву в презентации

взяты из книги

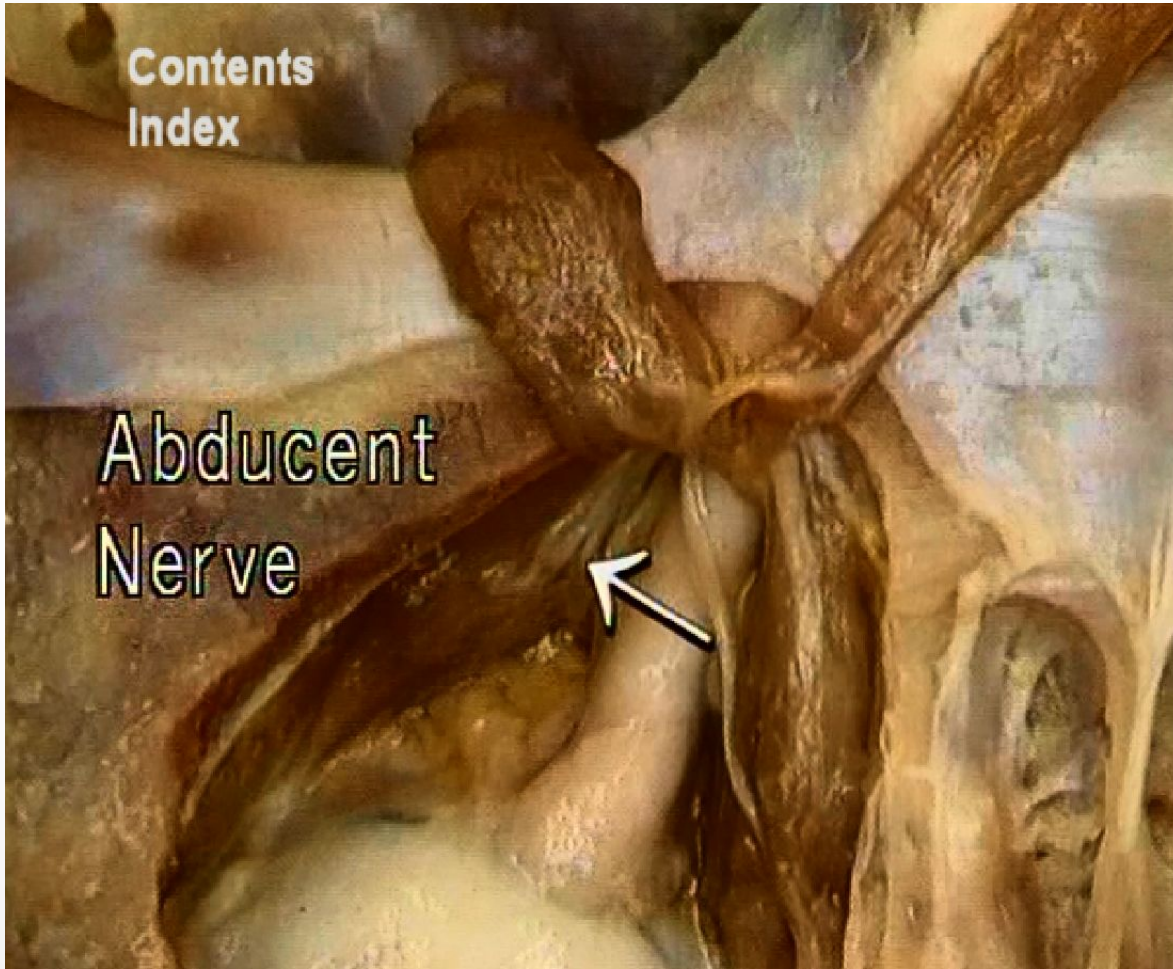
«Нейрокраниопатии»

Урлапова Е. В.

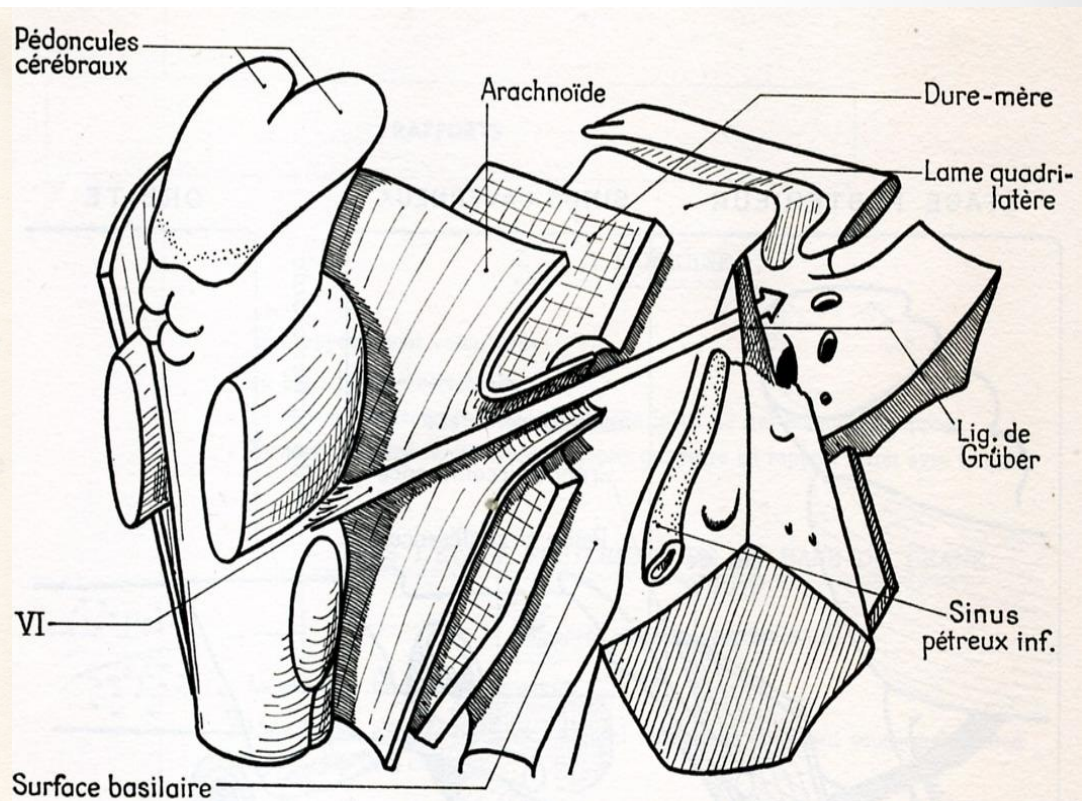
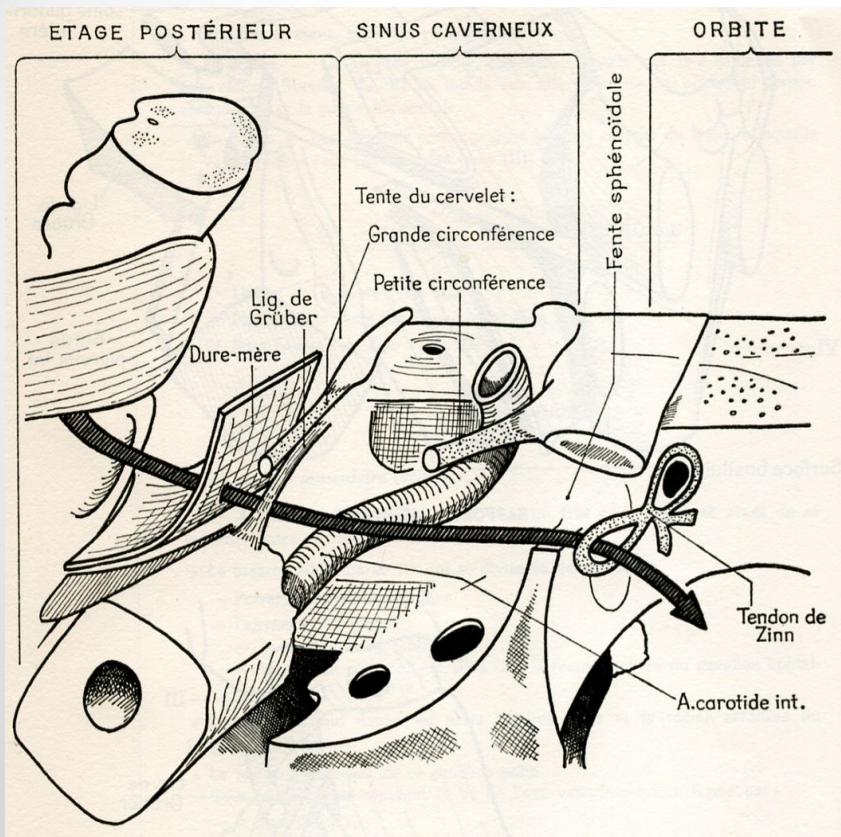
Отводящий нерв



Ход отводящего нерва



Зоны остеопатических конфликтов



Срез через кавернозный синус

