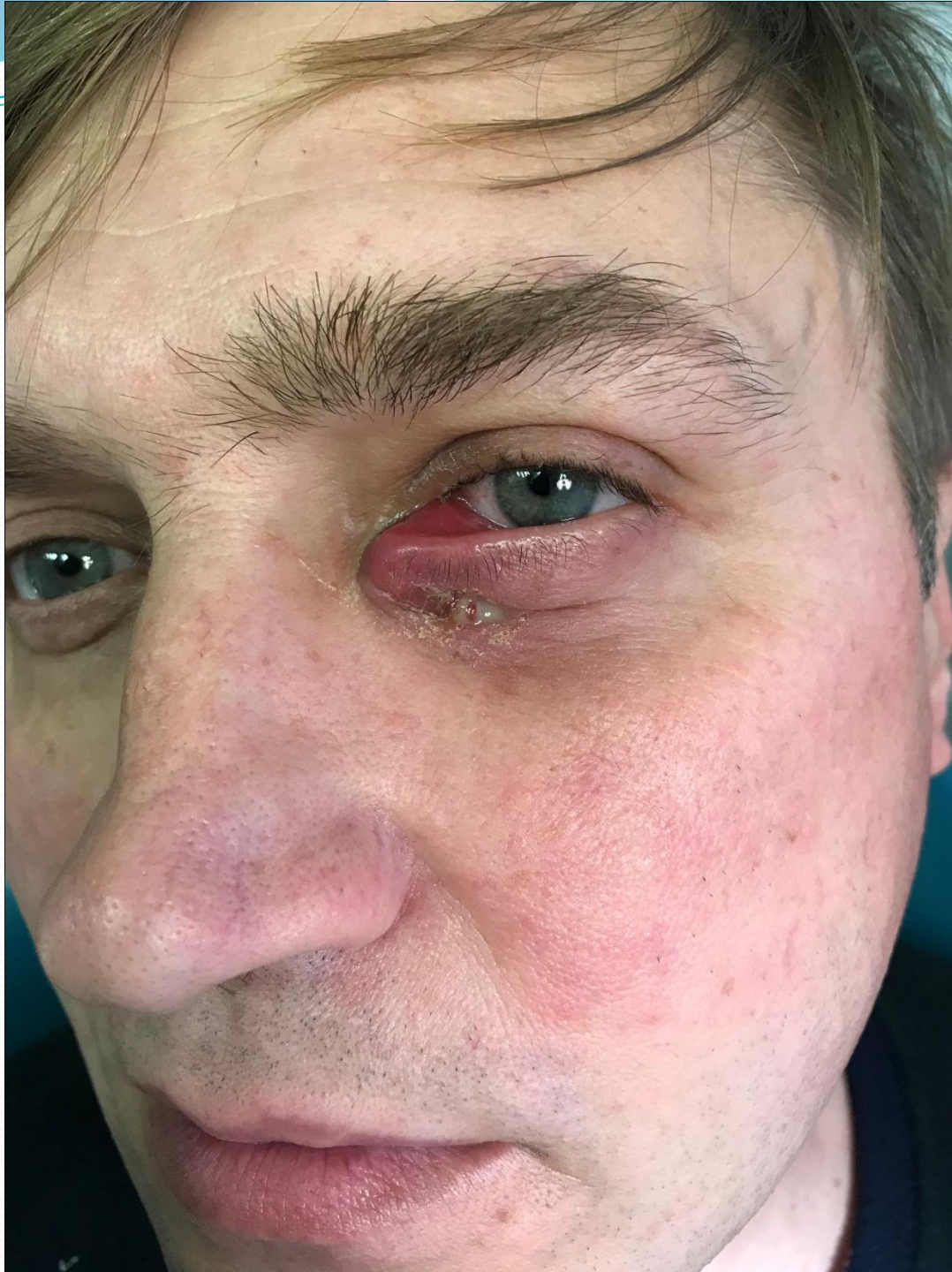
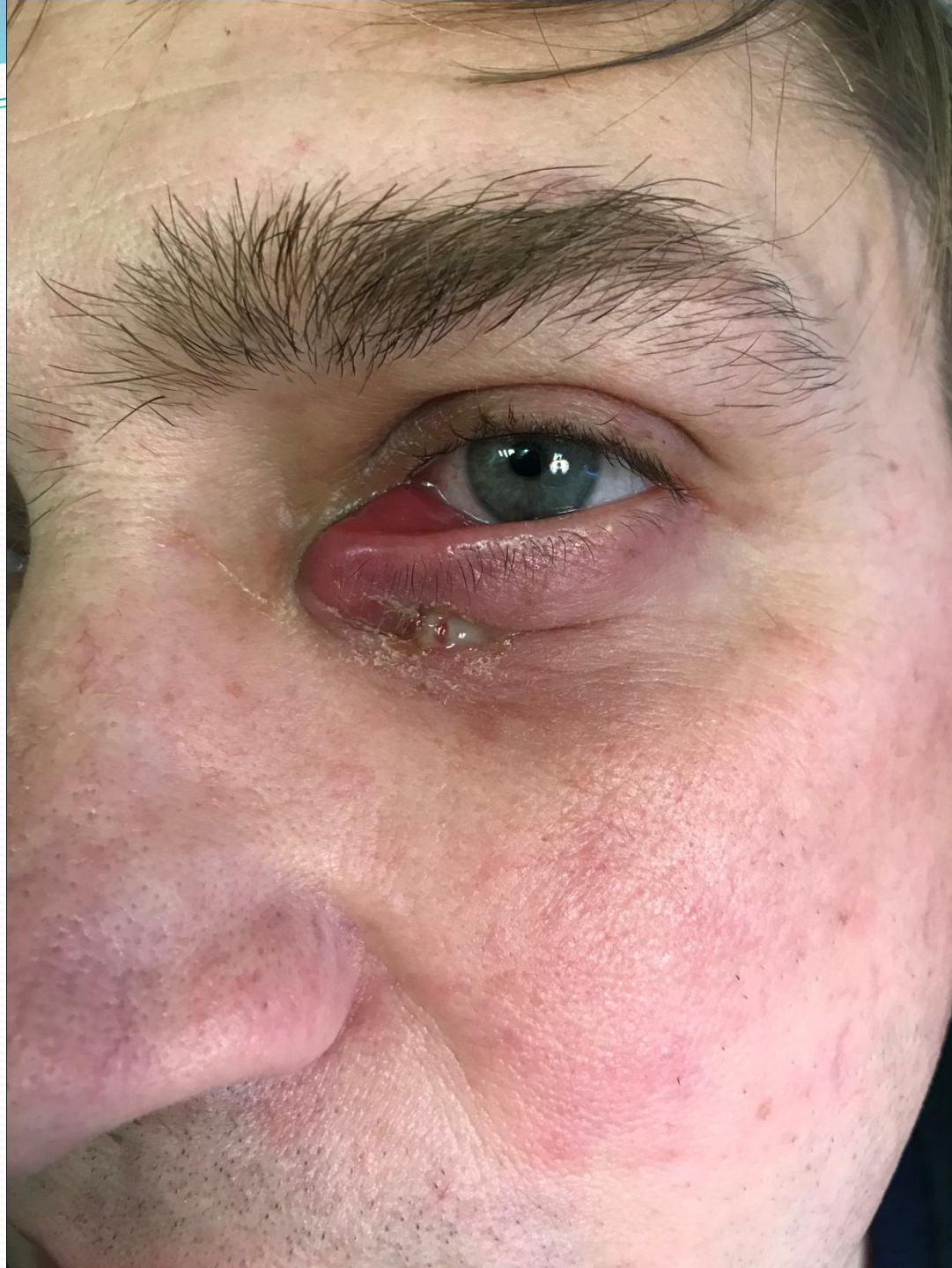
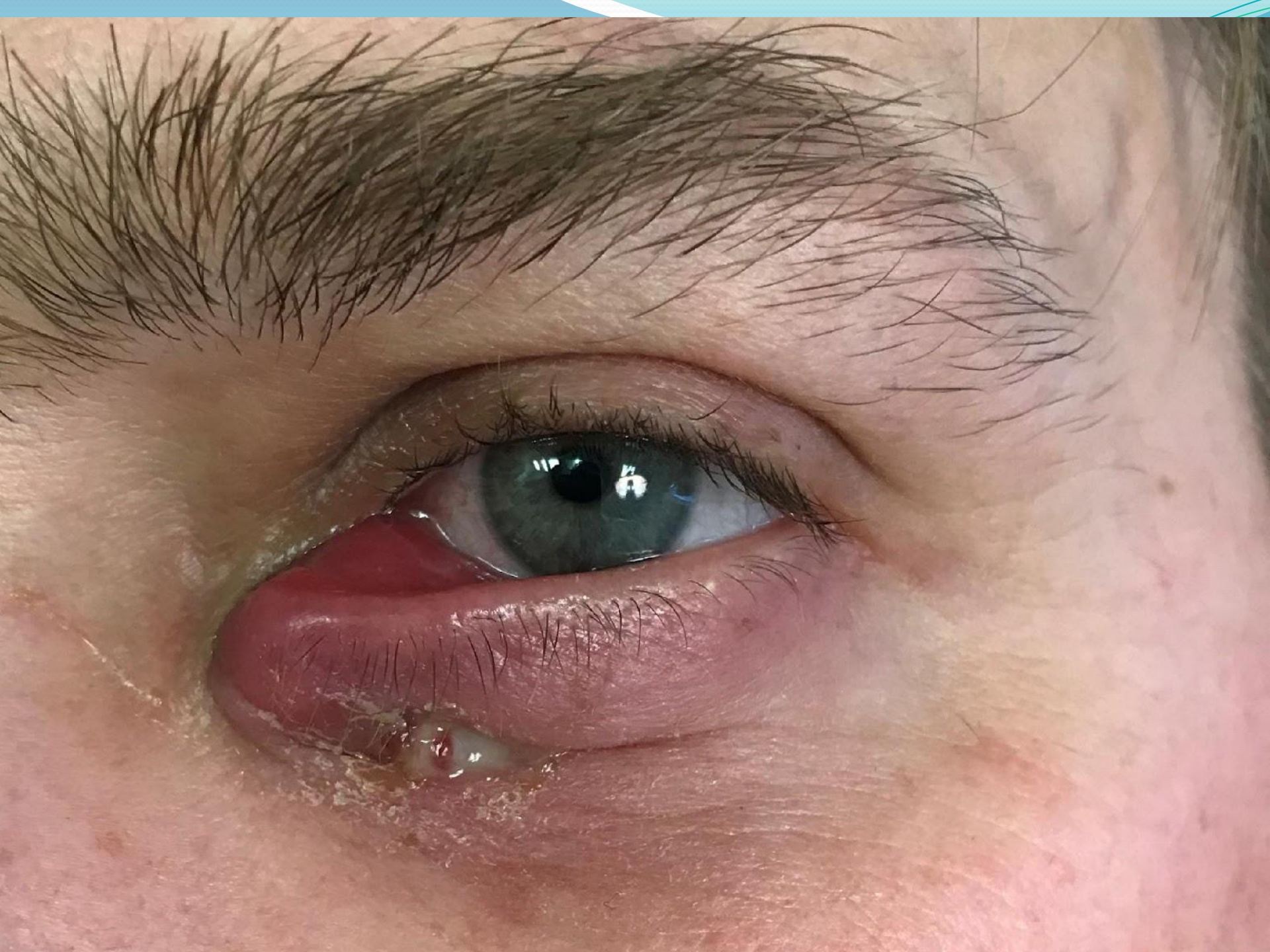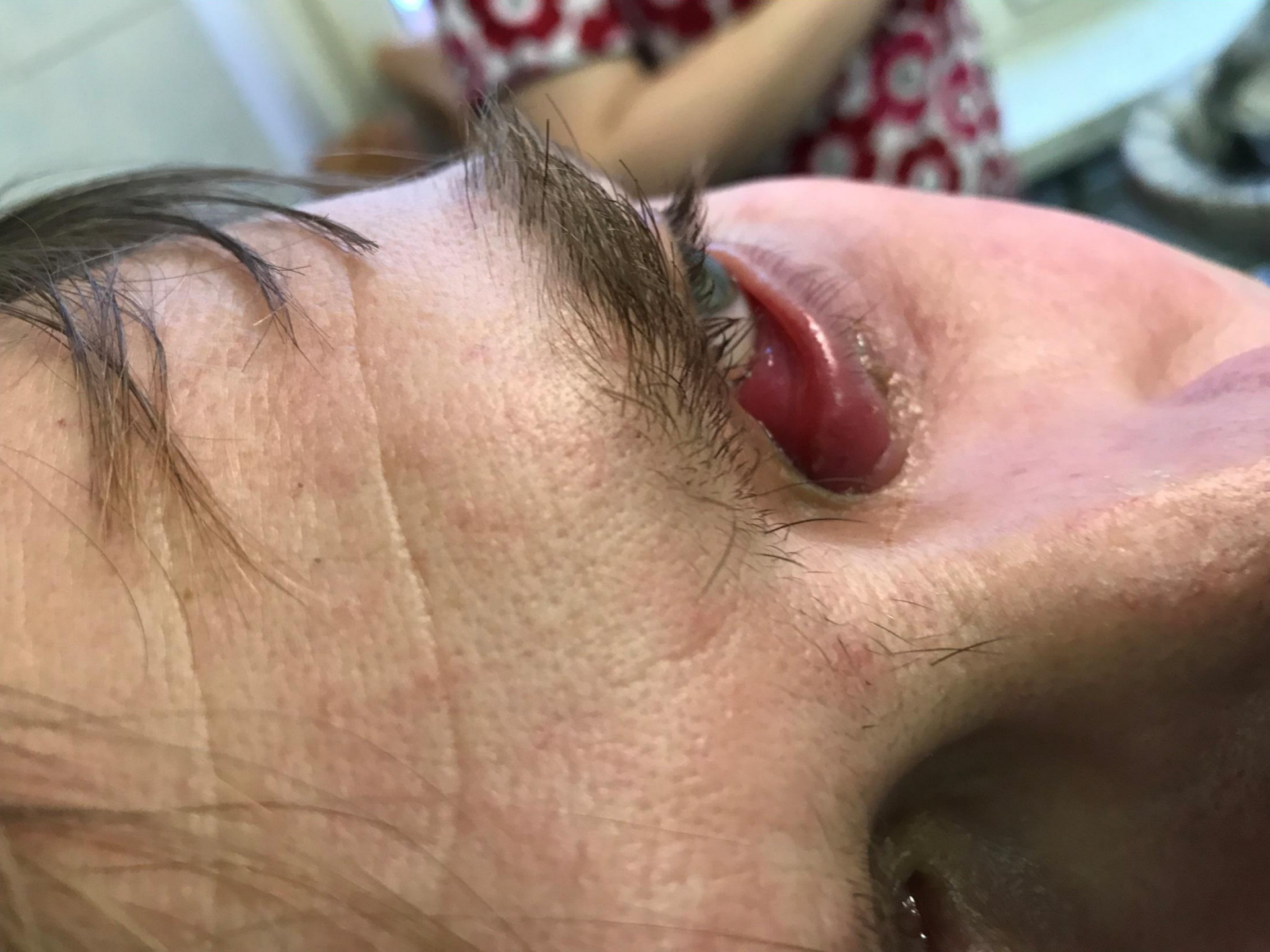**Клинический
случай № 1!
в чужом глазу
соринку видим в
своем бревна не
замечаем**

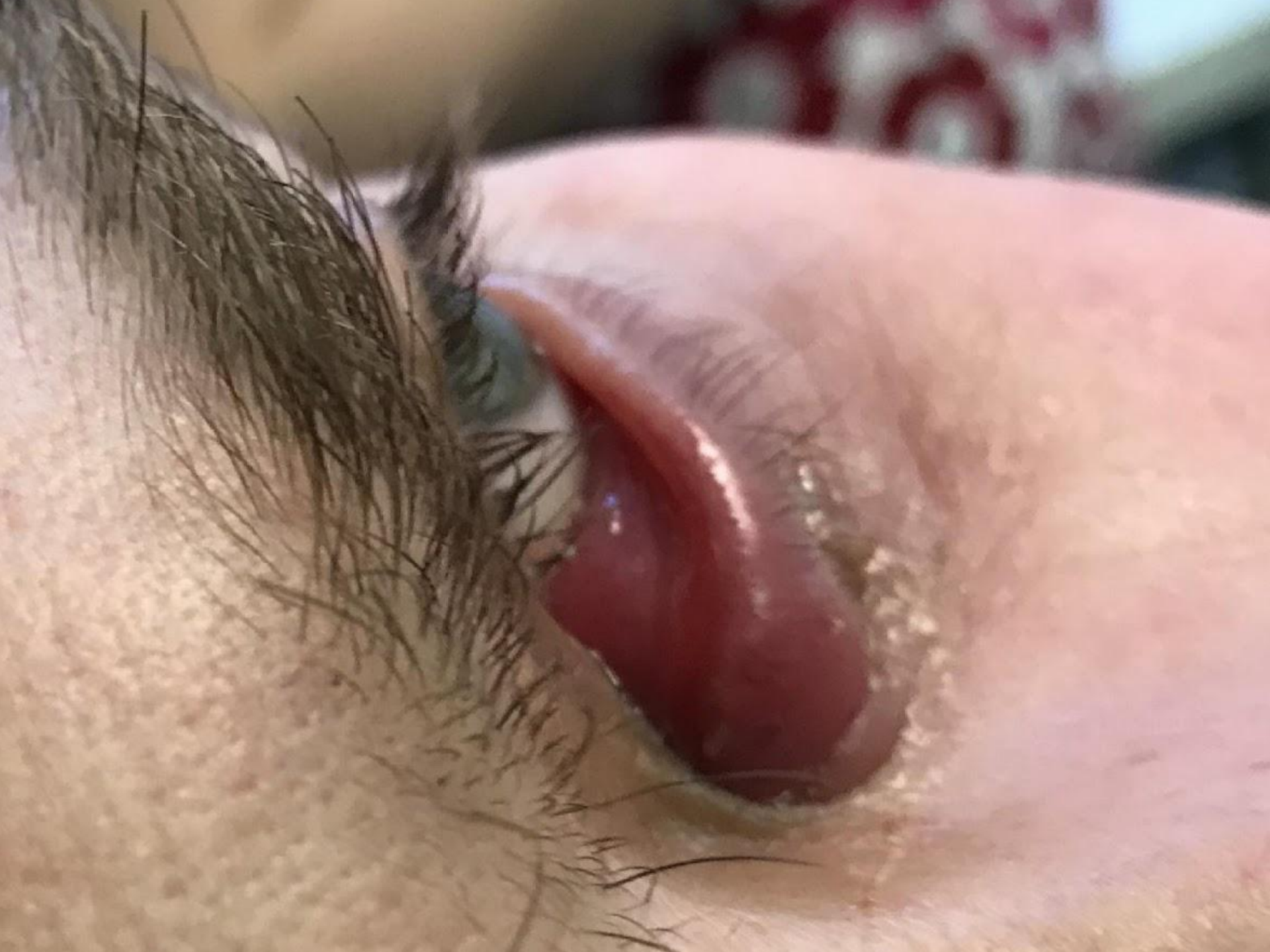Пациент К. 48 лет.

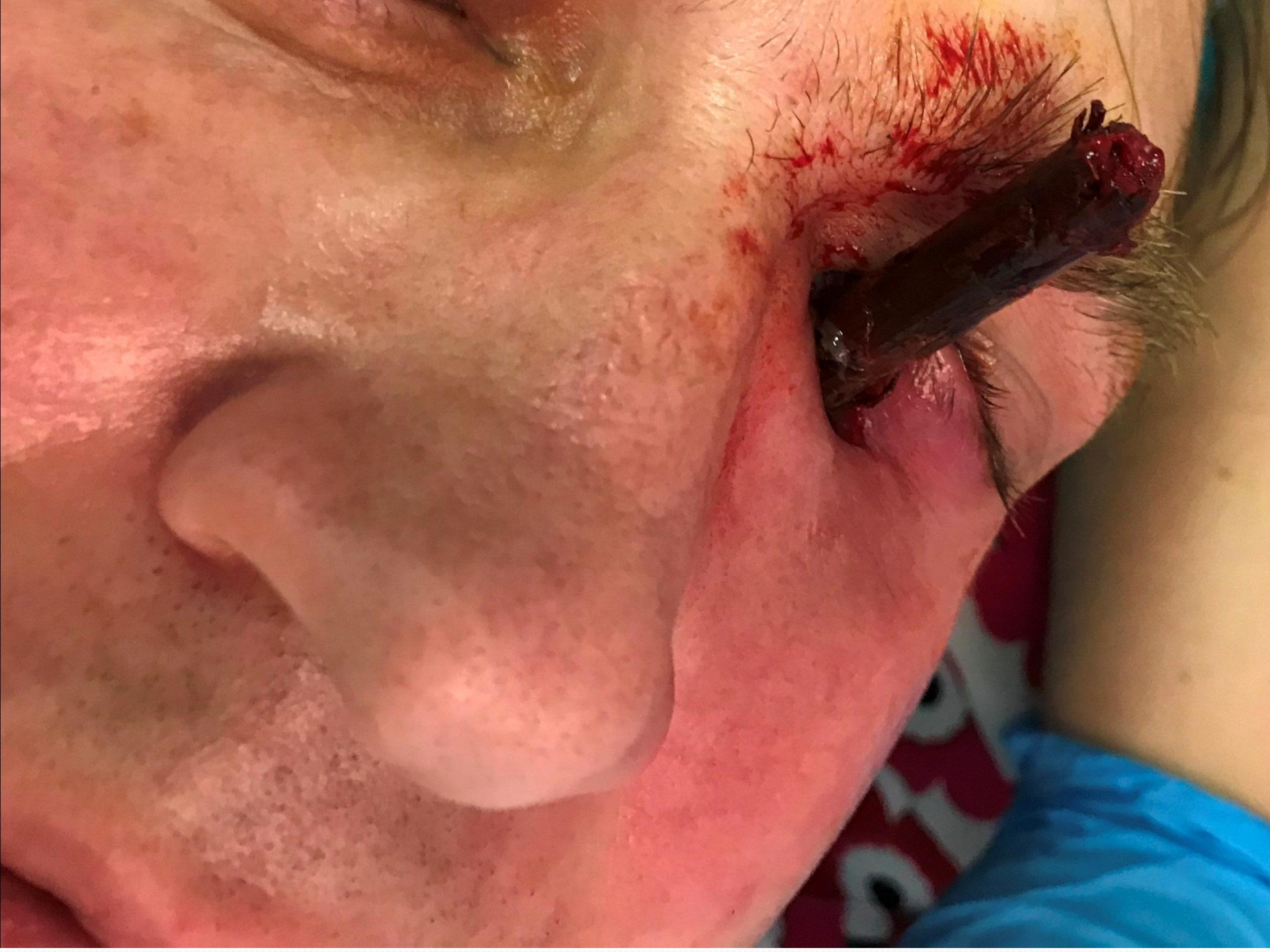


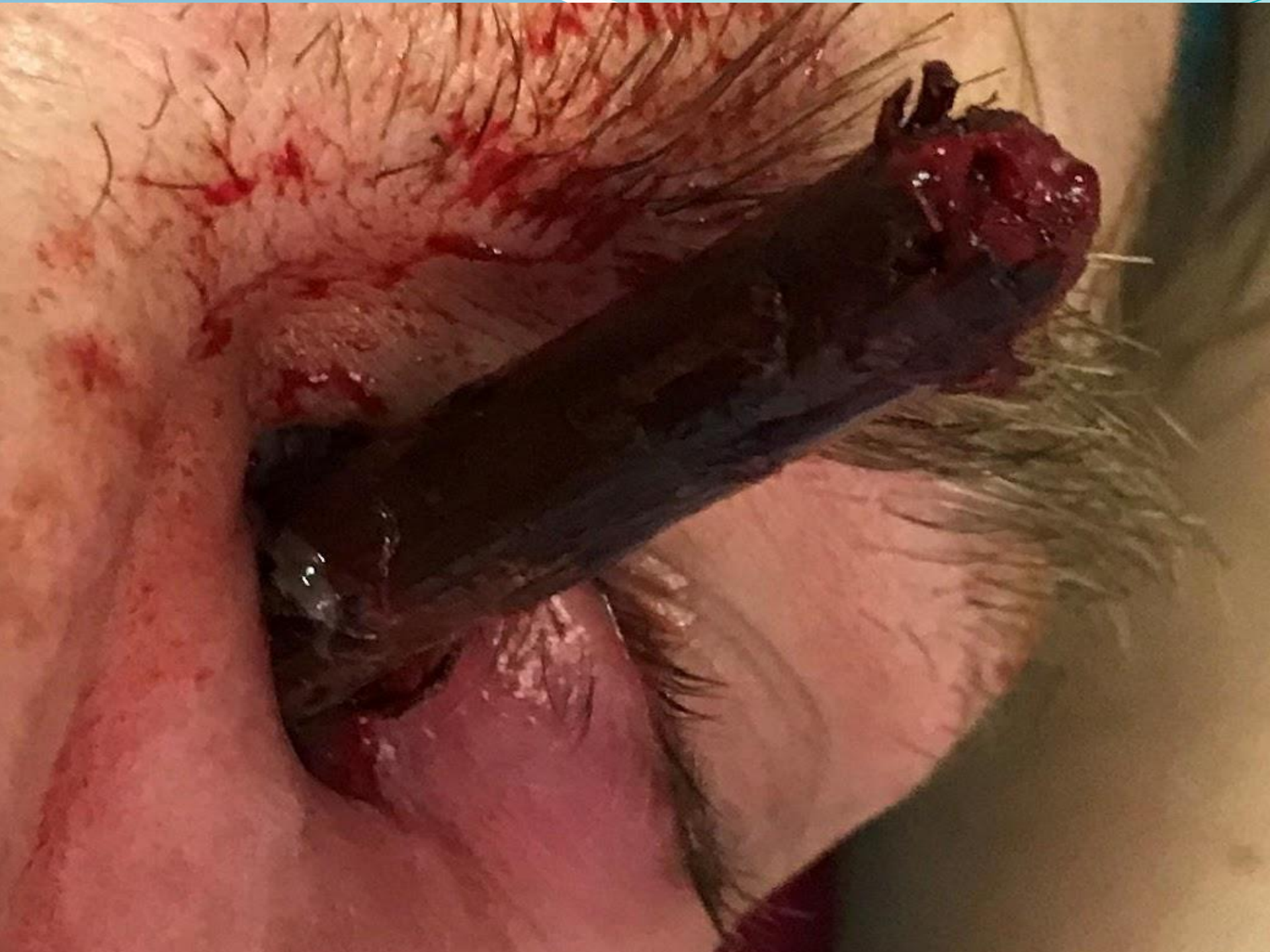


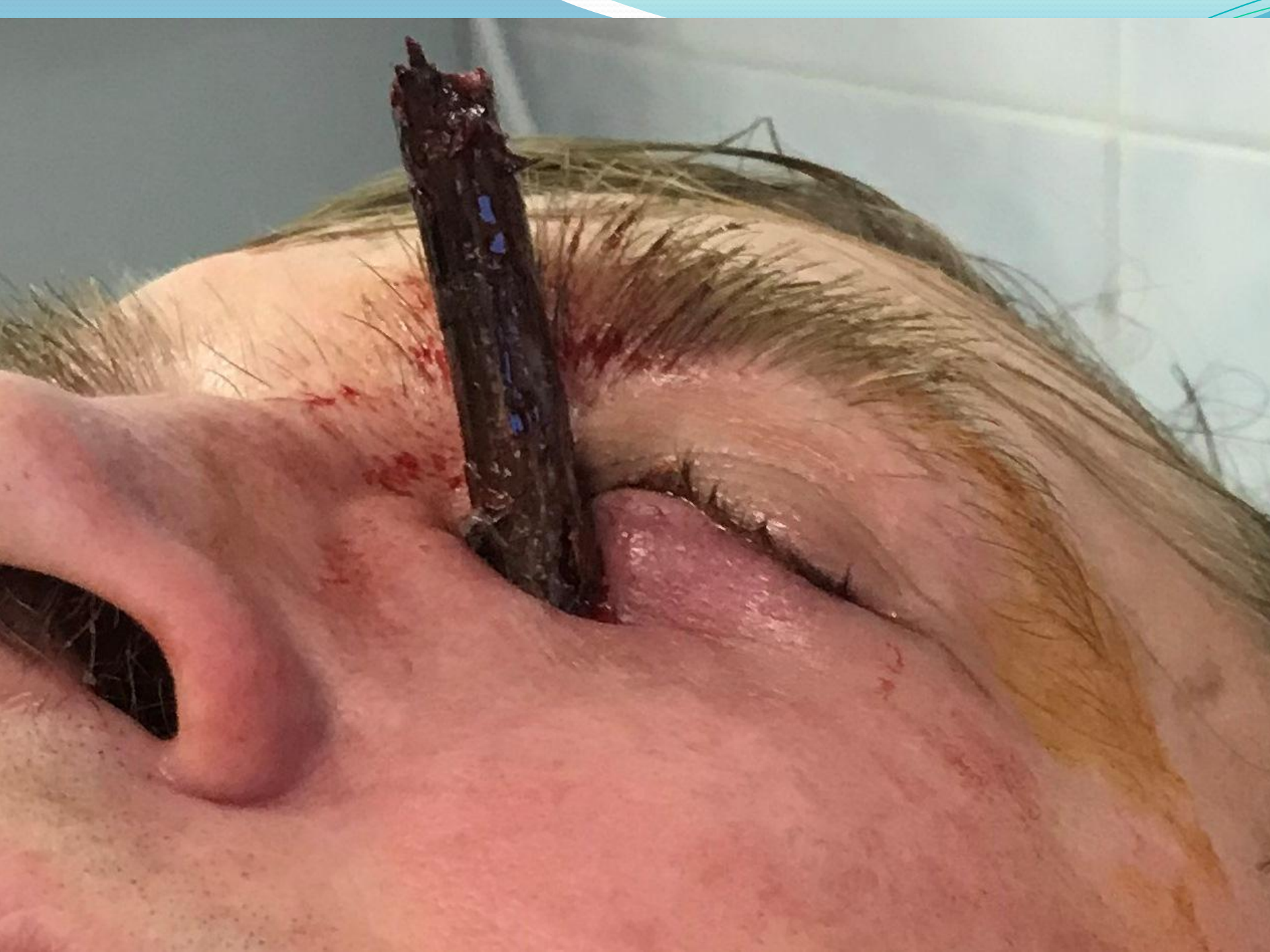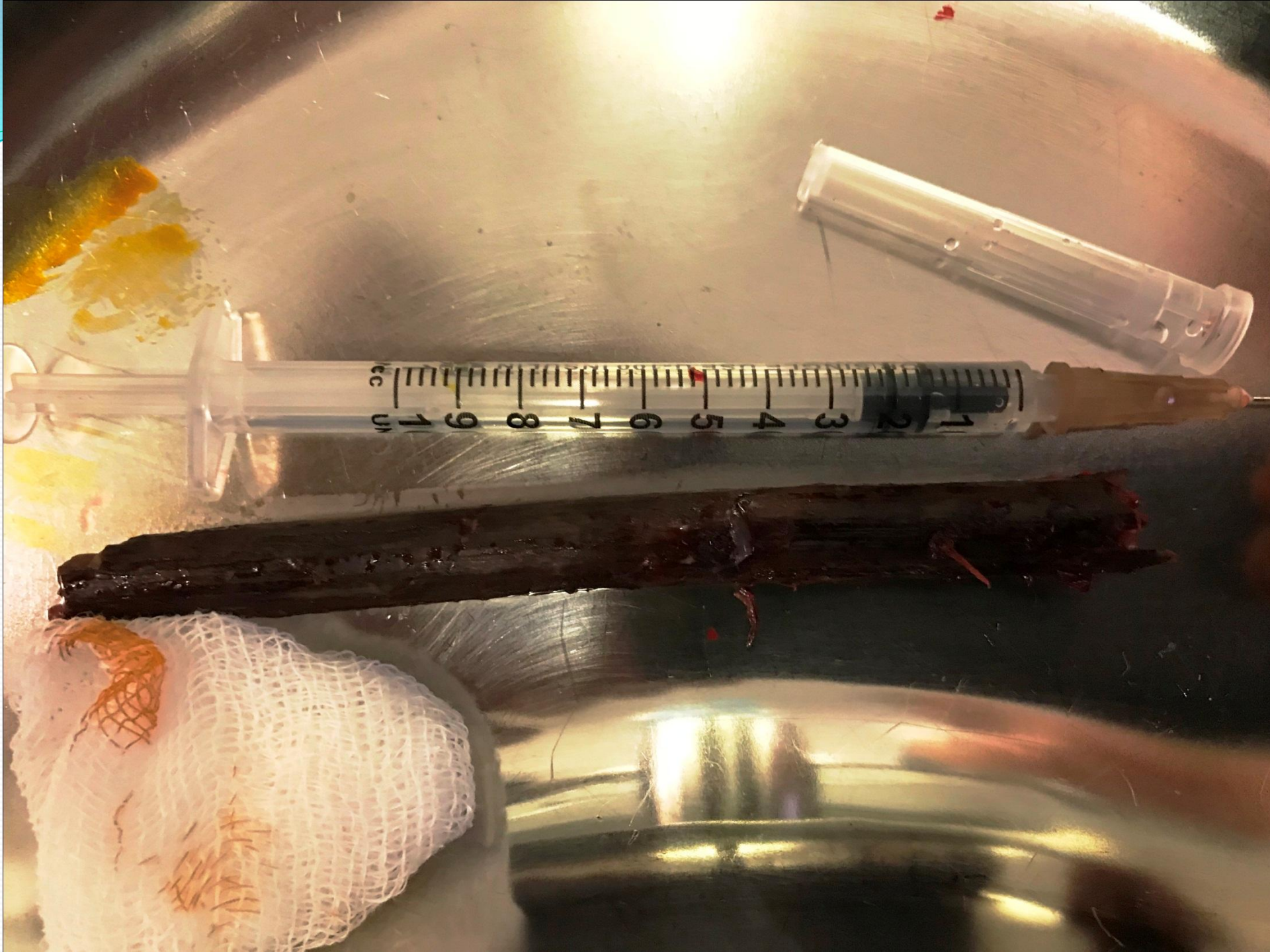





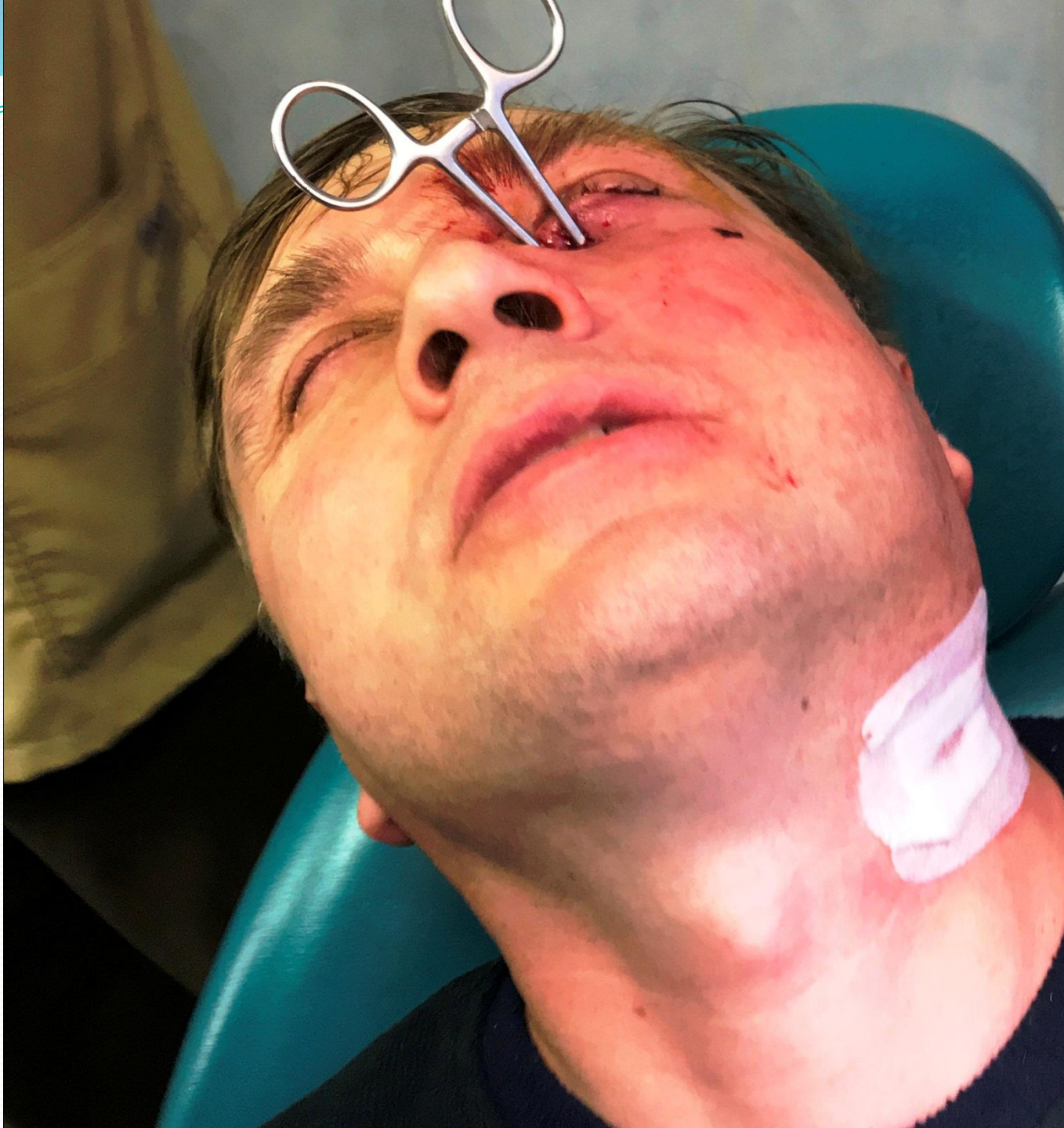








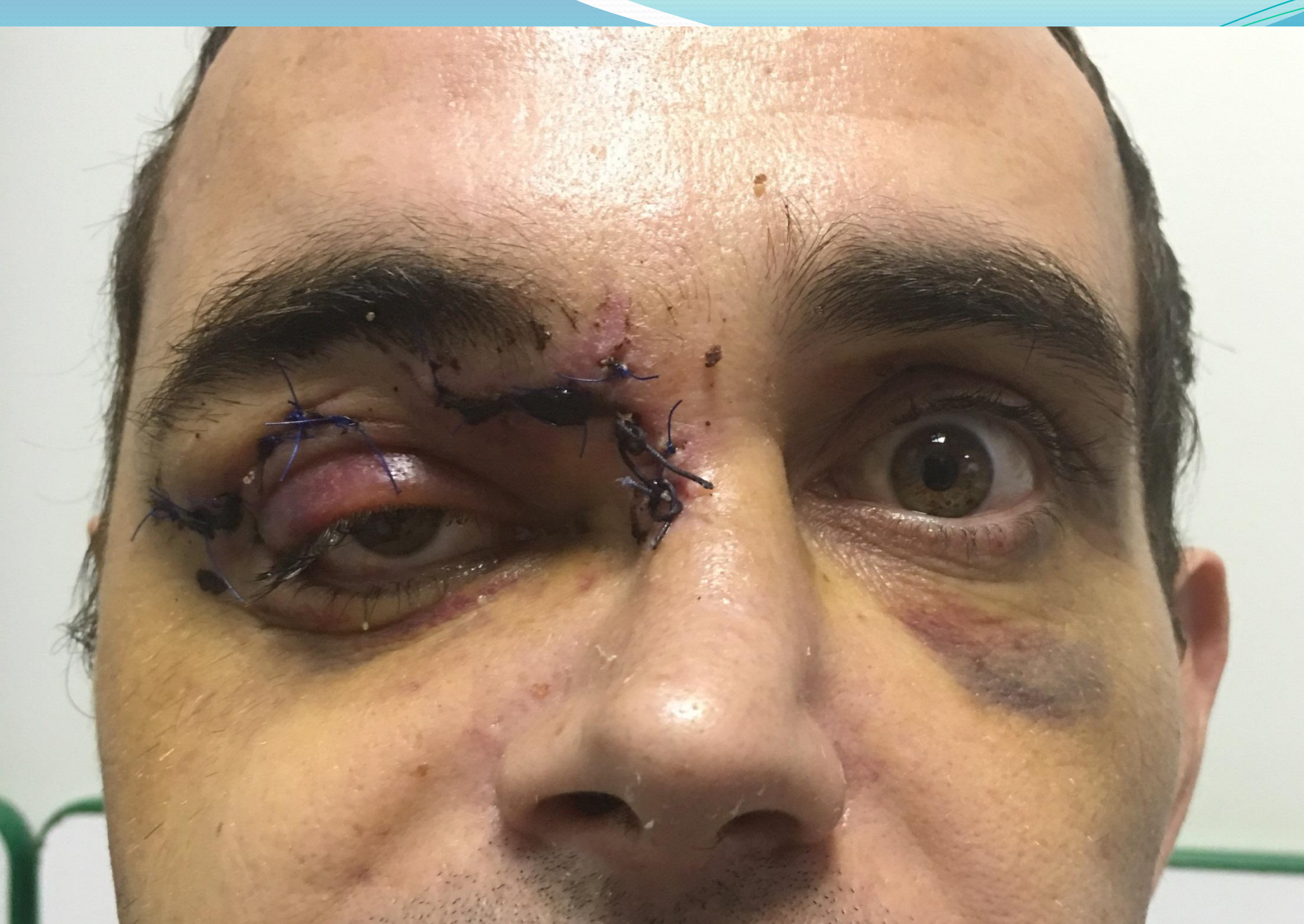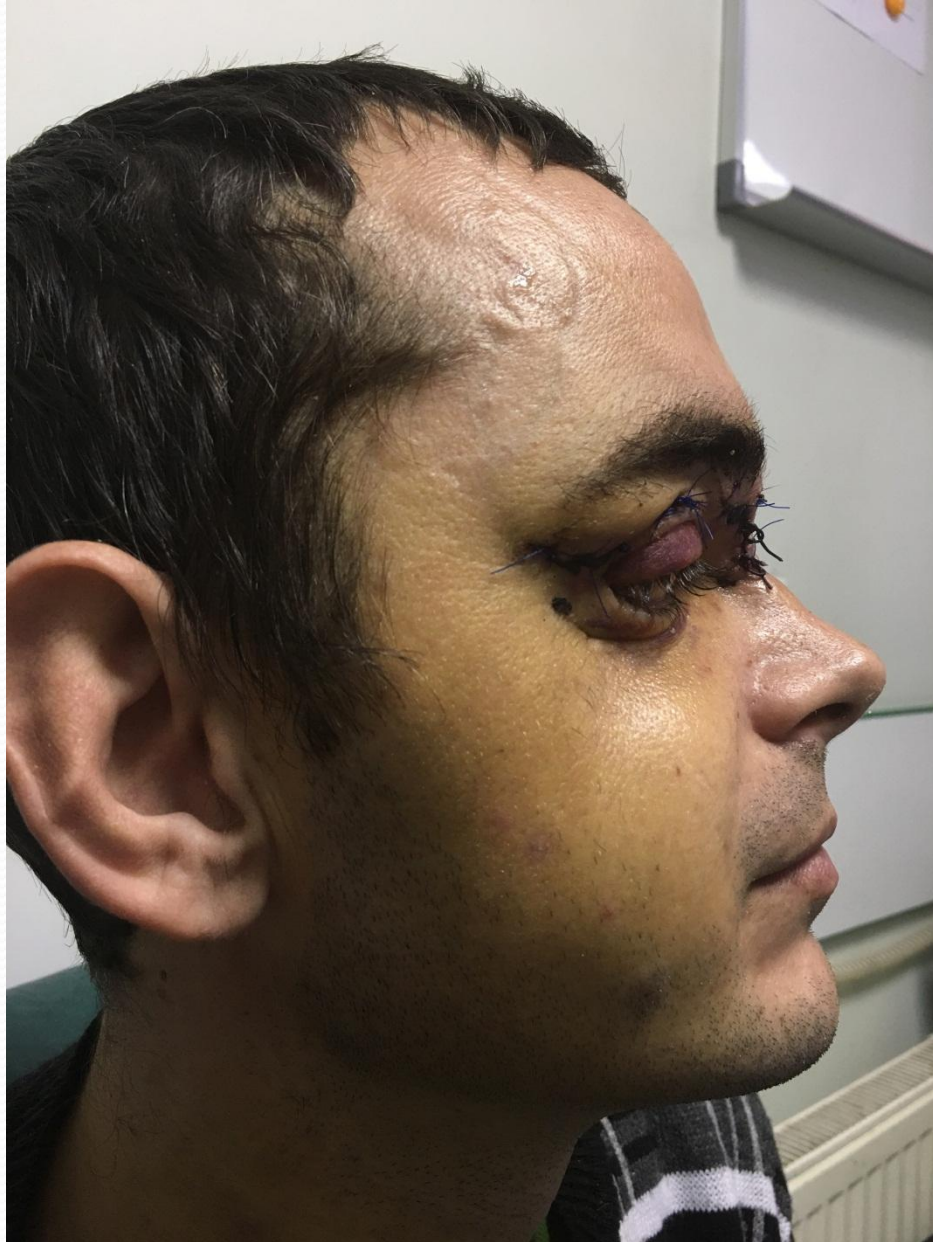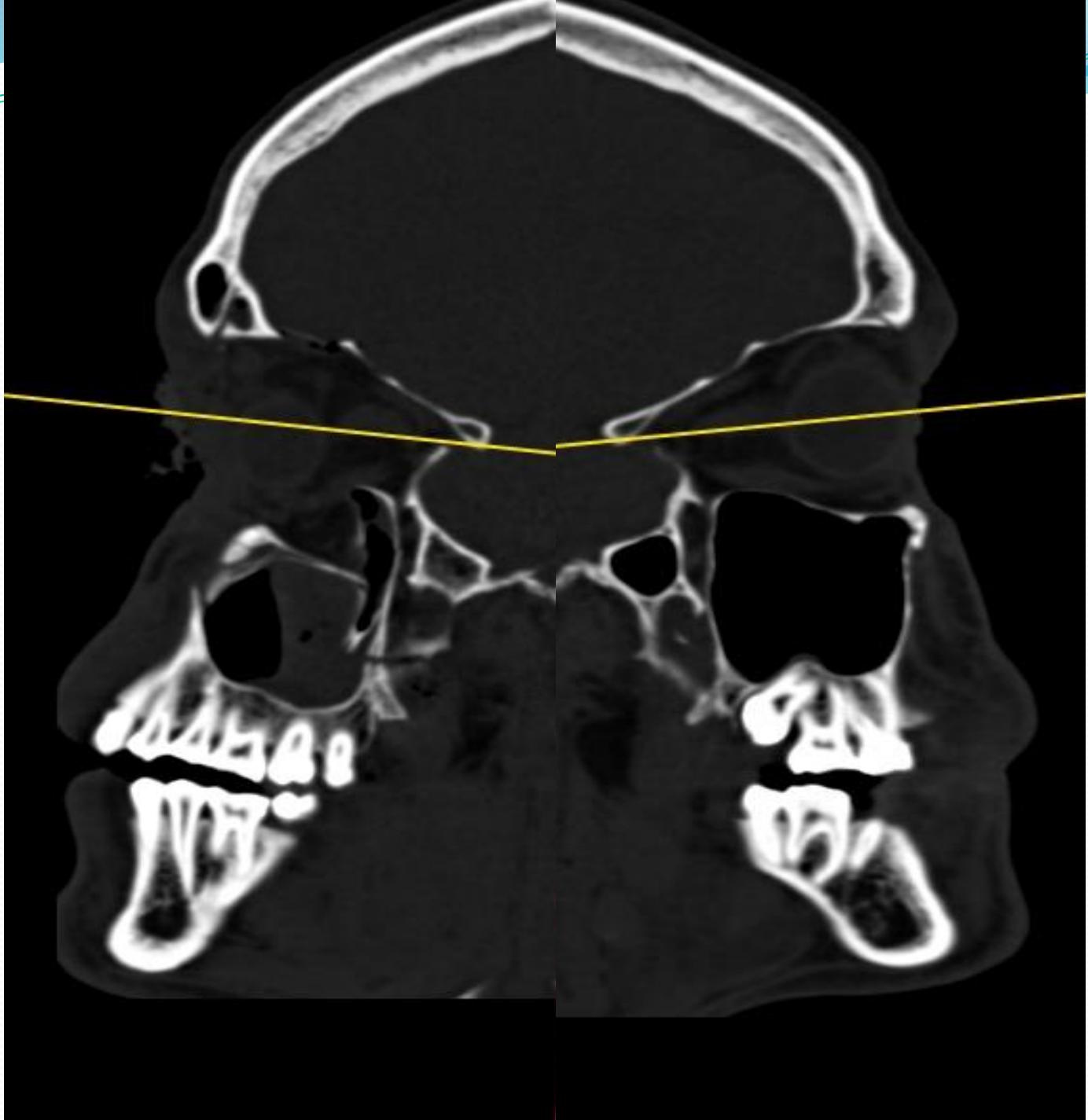
**Клинический
случай № 2!
Поскользнулся,
упал, потерял
сознание, очнулся**

...

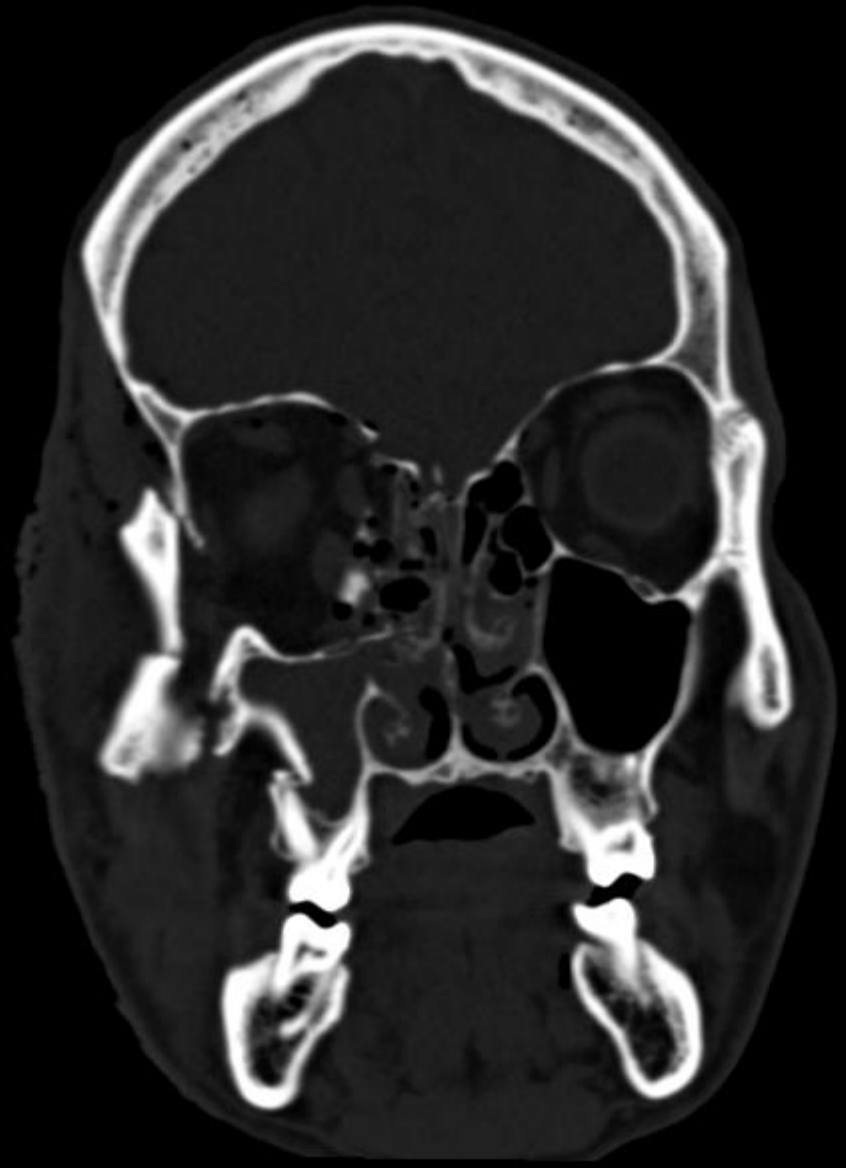Пациент С. 40 лет.







S



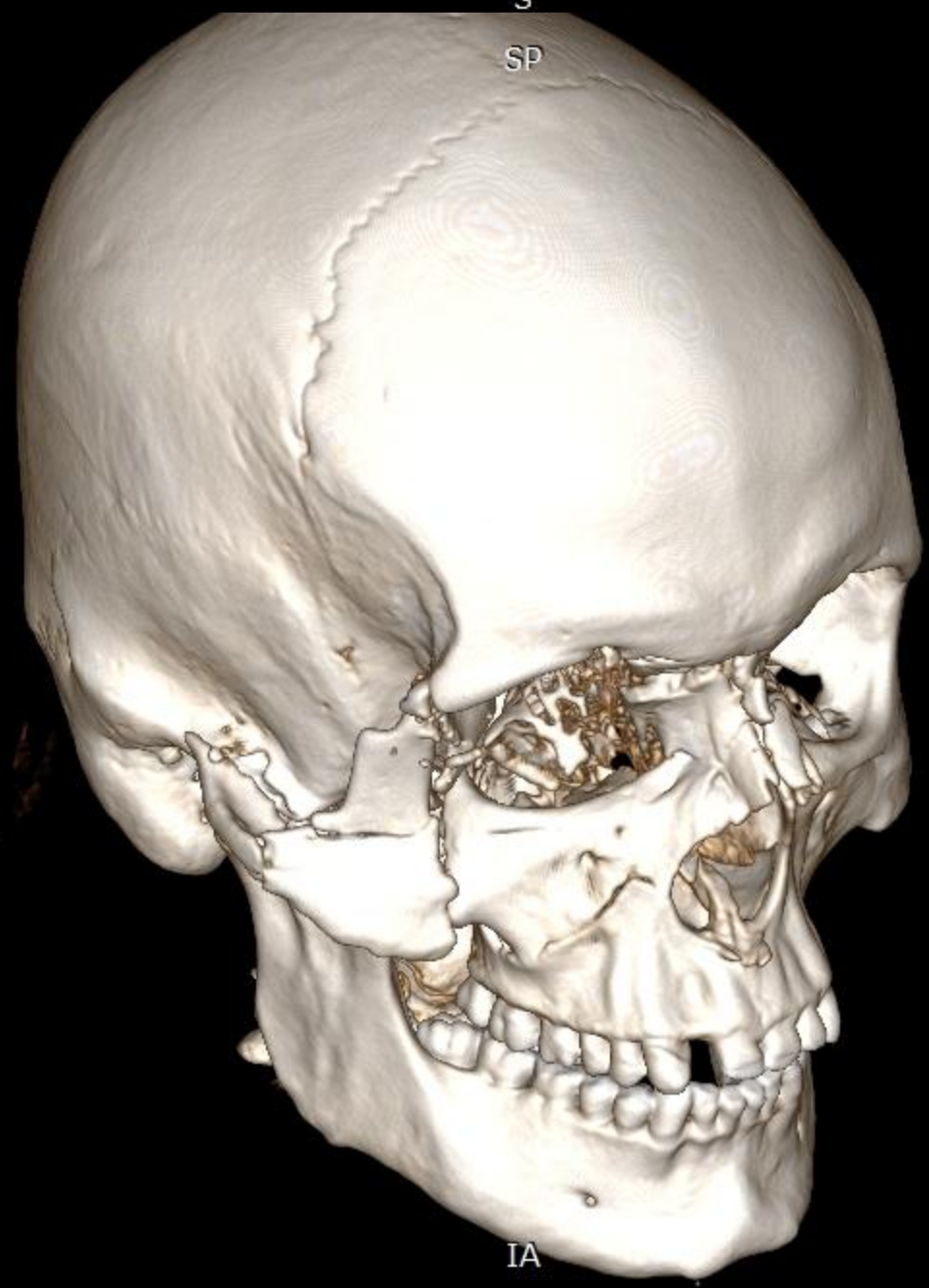I

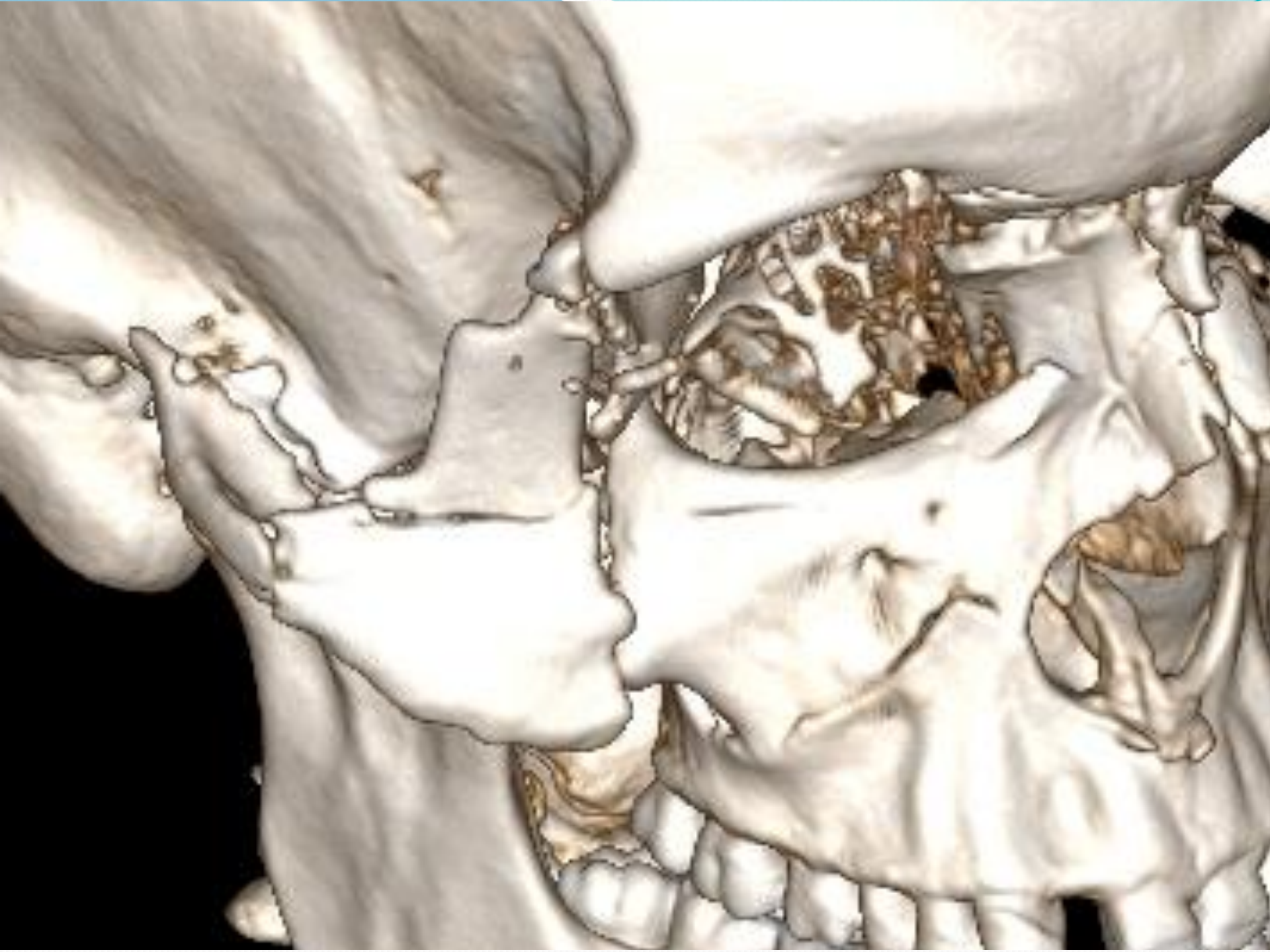S

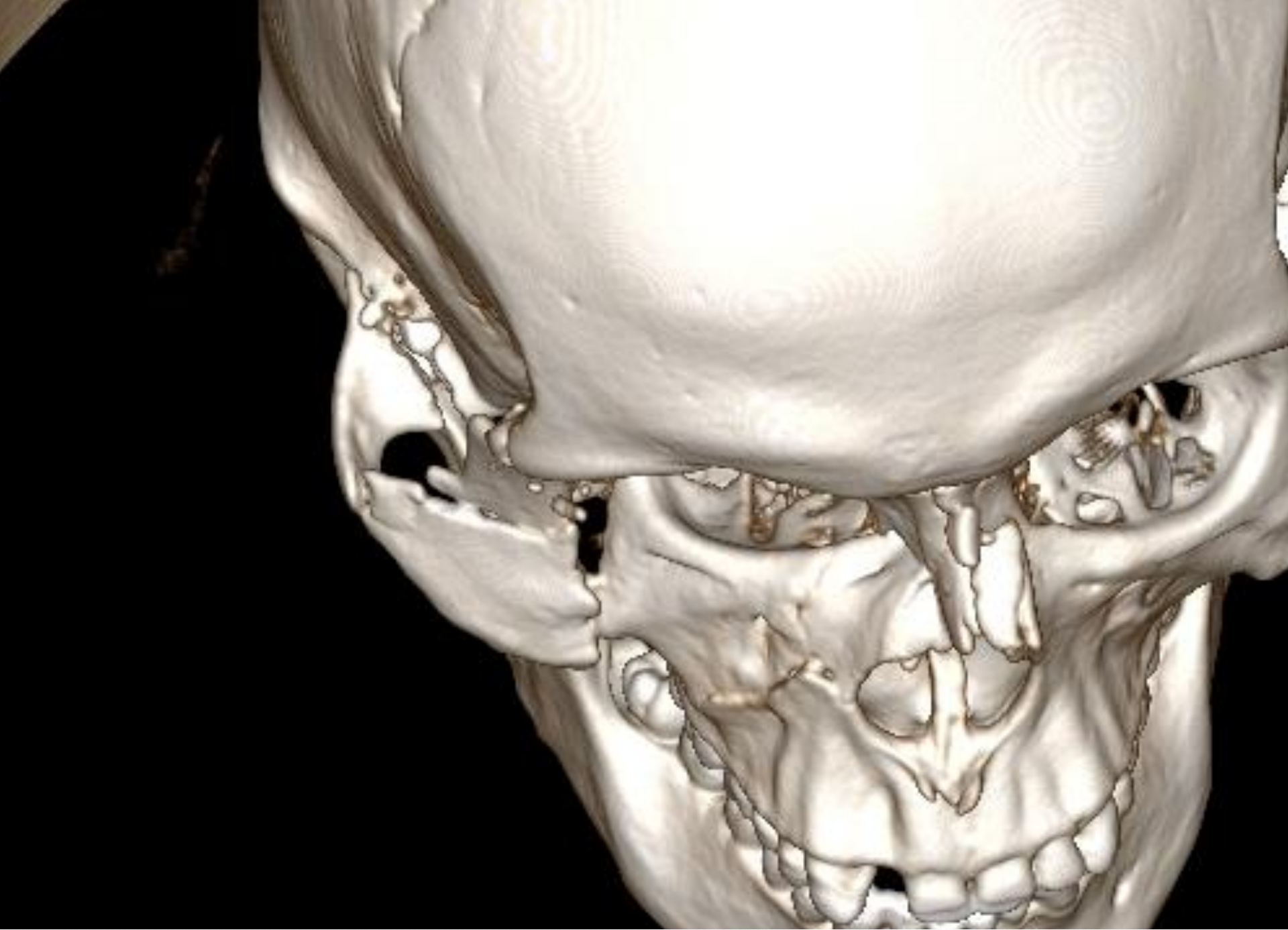
SP

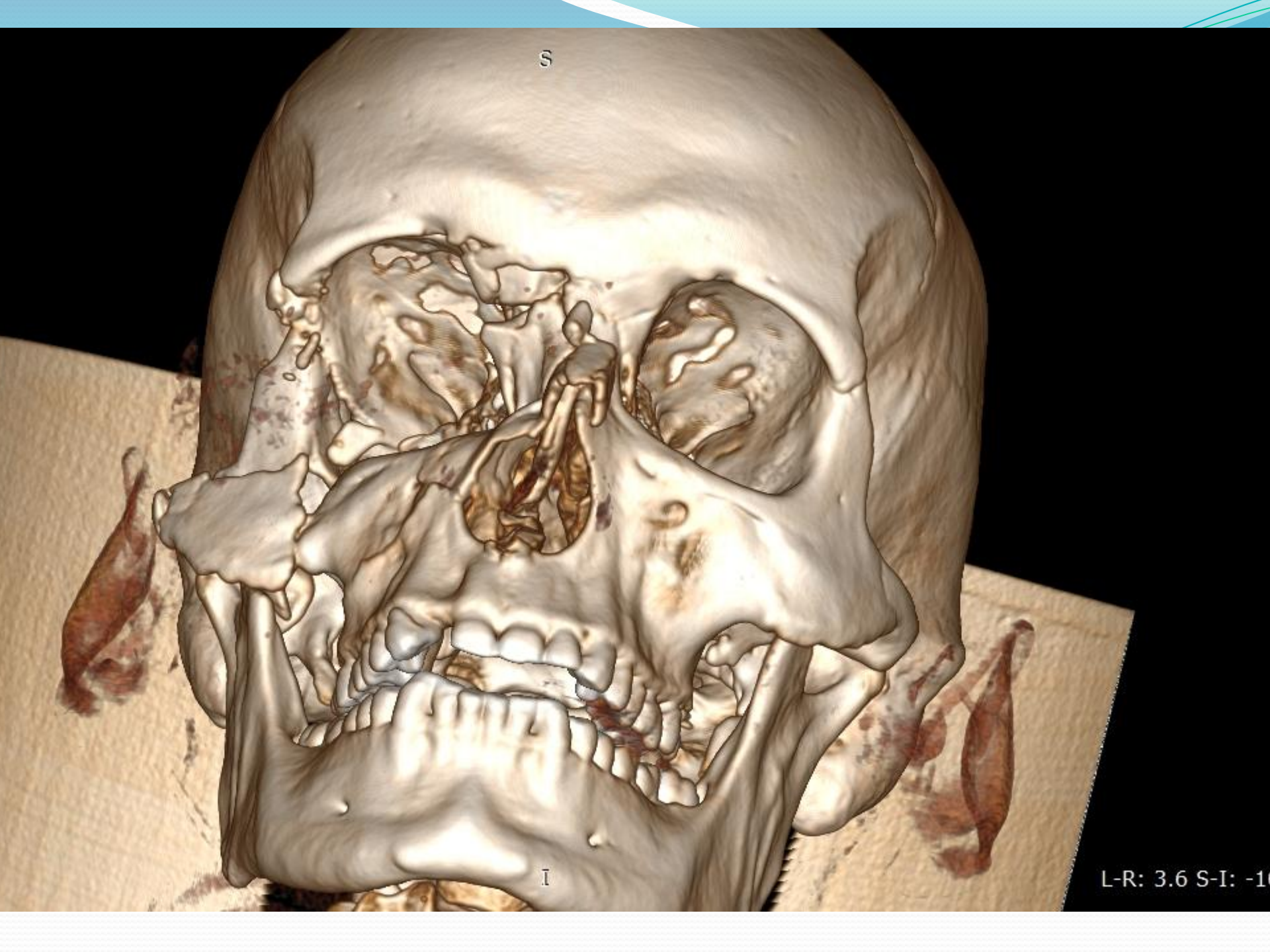
IA

I







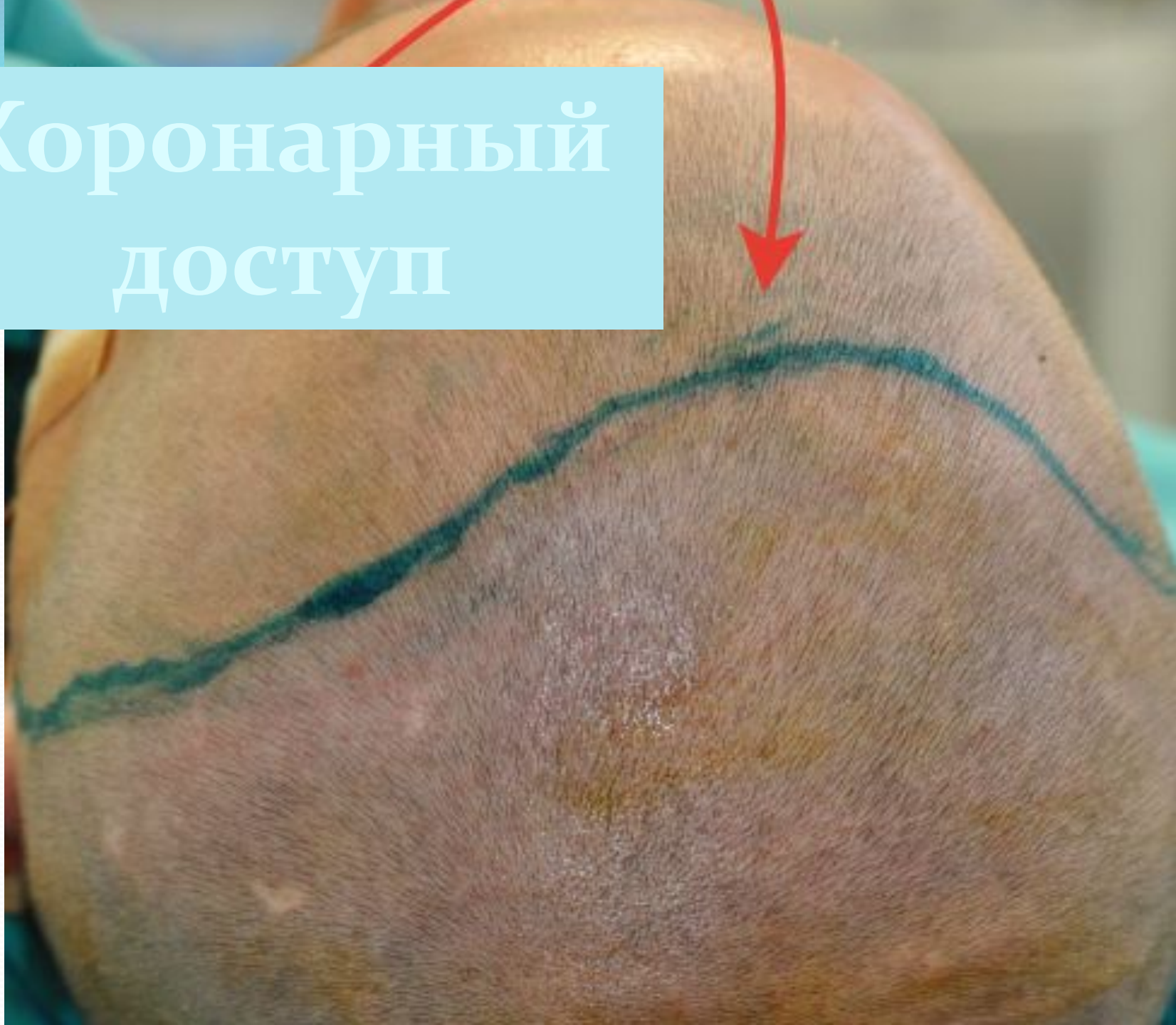

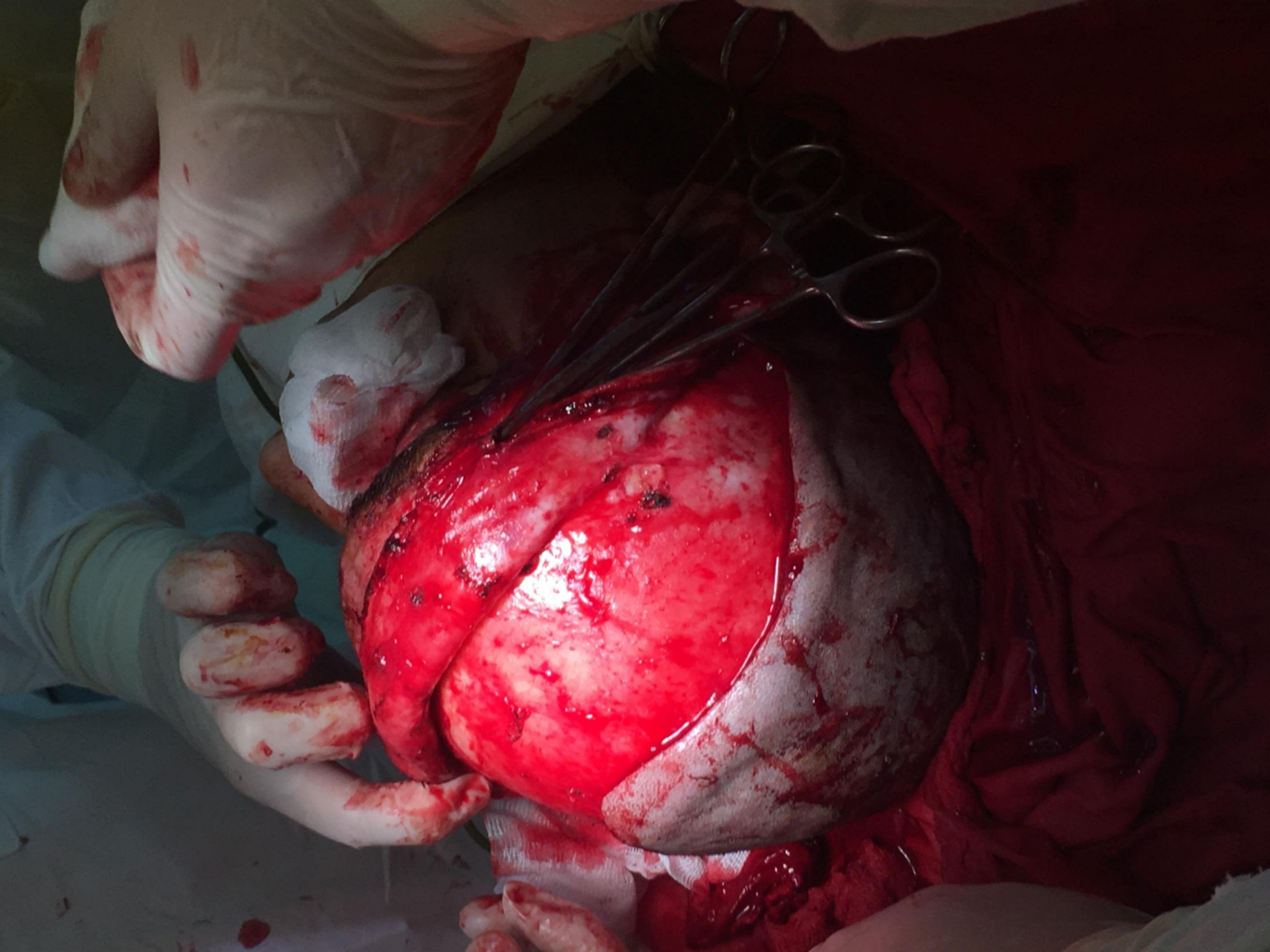
S

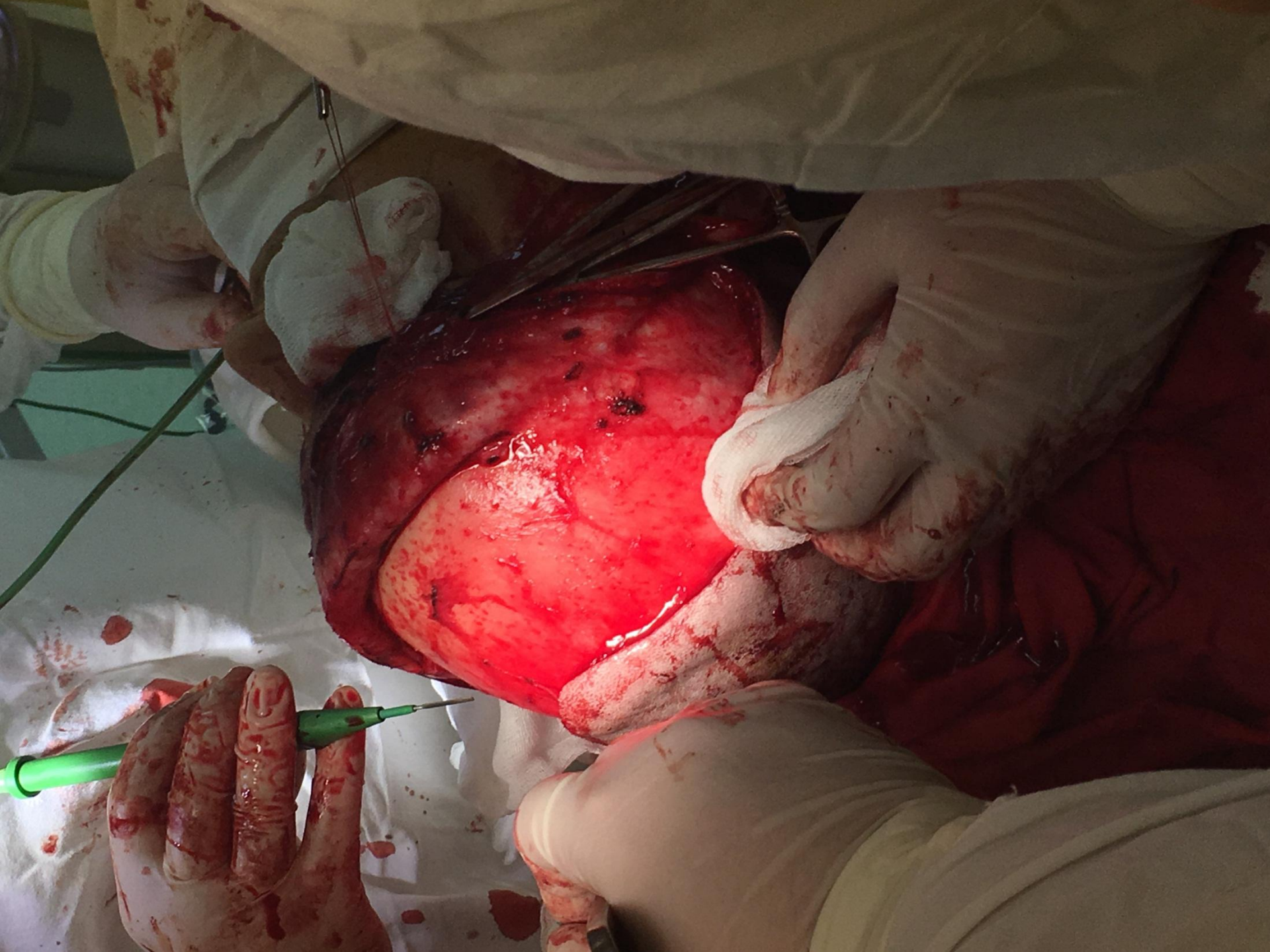I

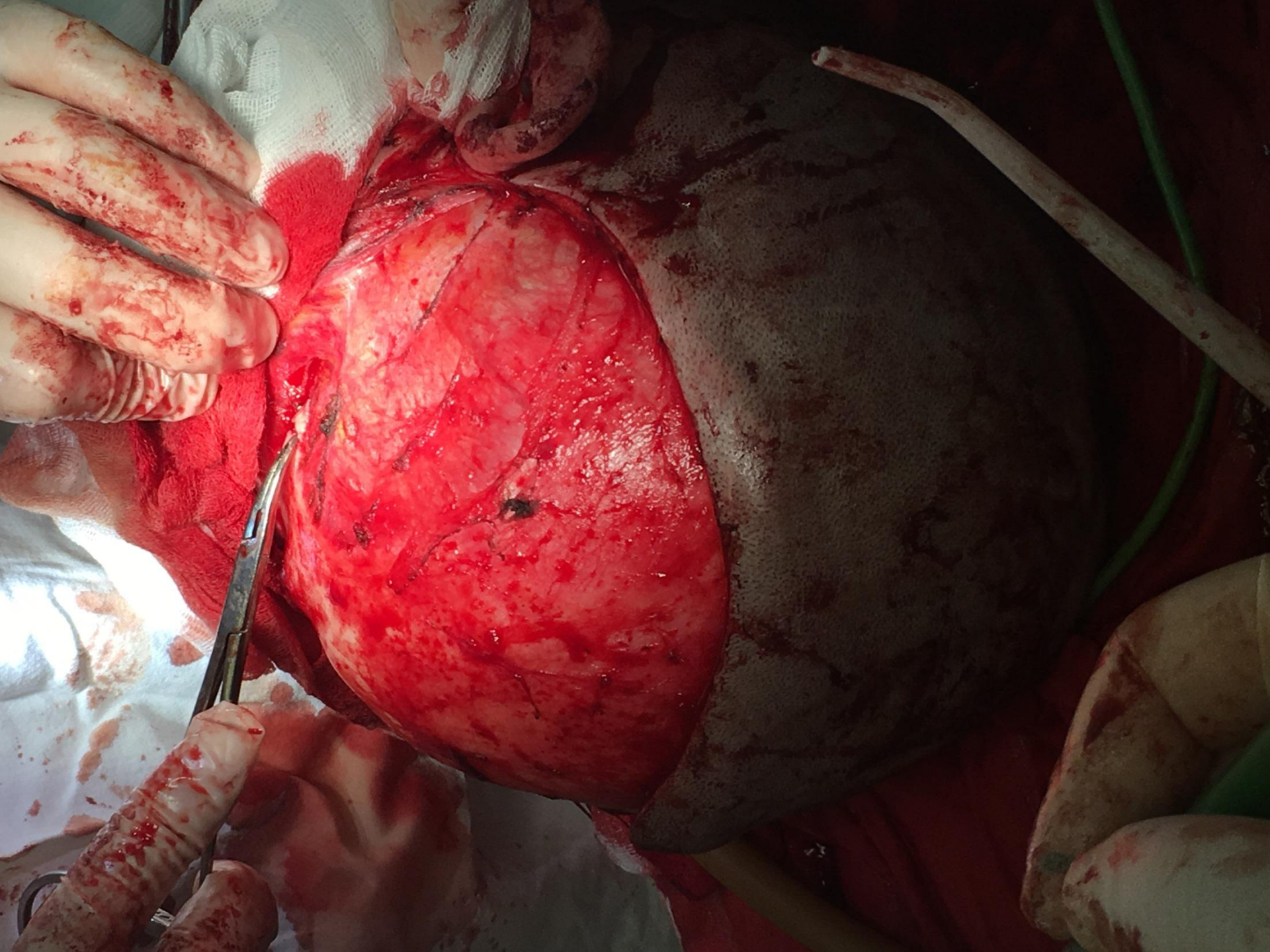
L-R: 3.6 S-I: -1

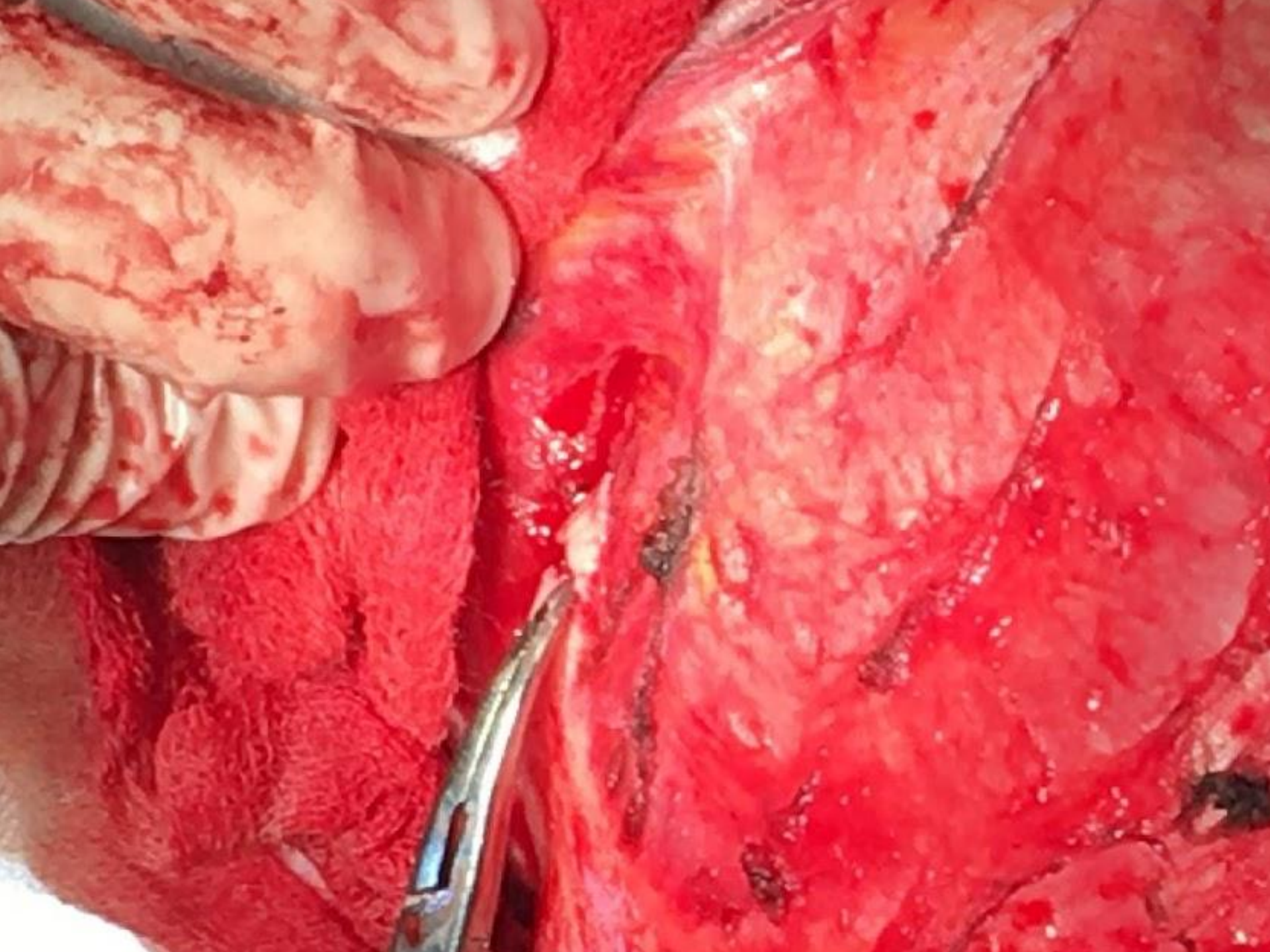
Коронарный доступ

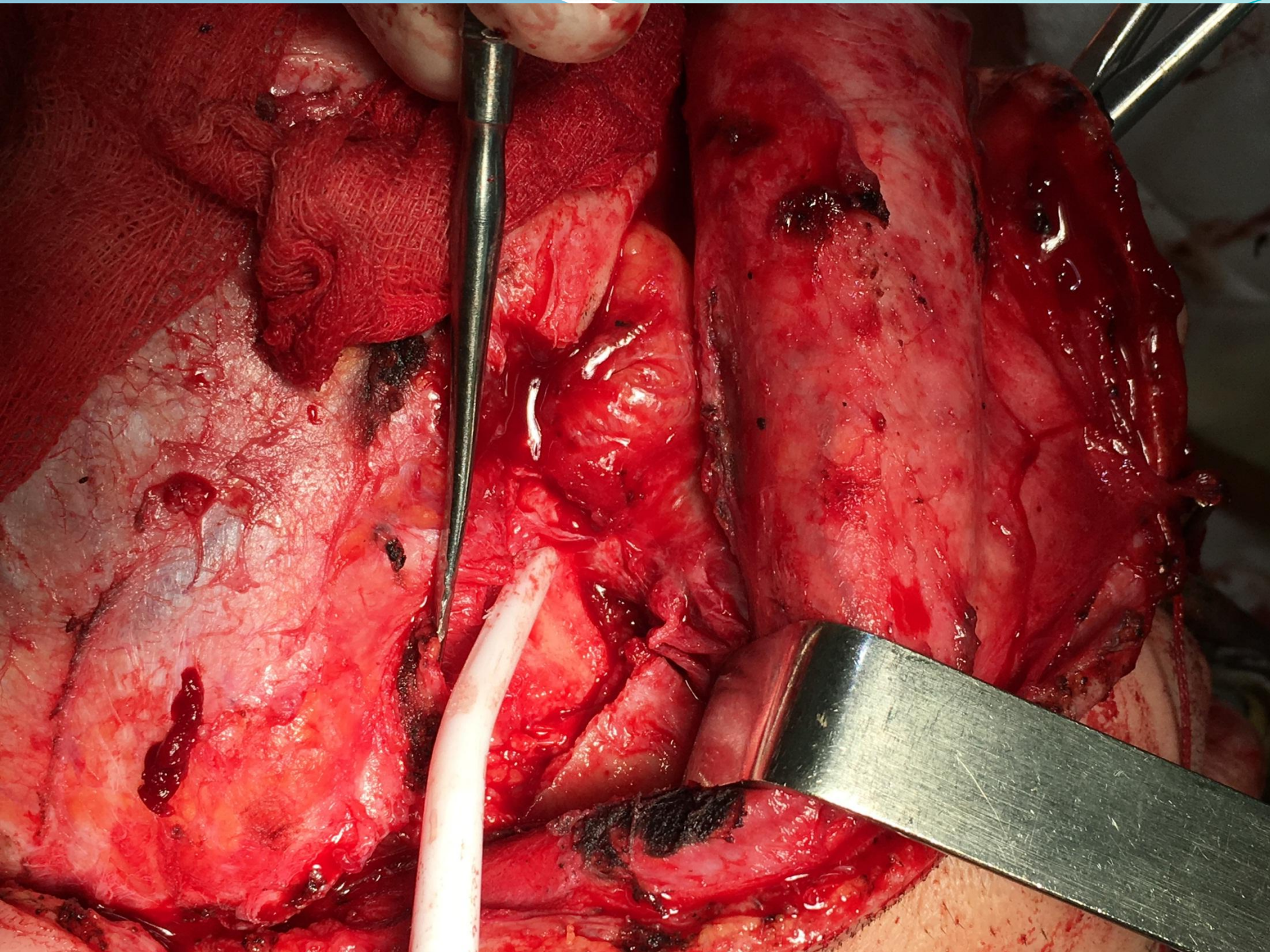




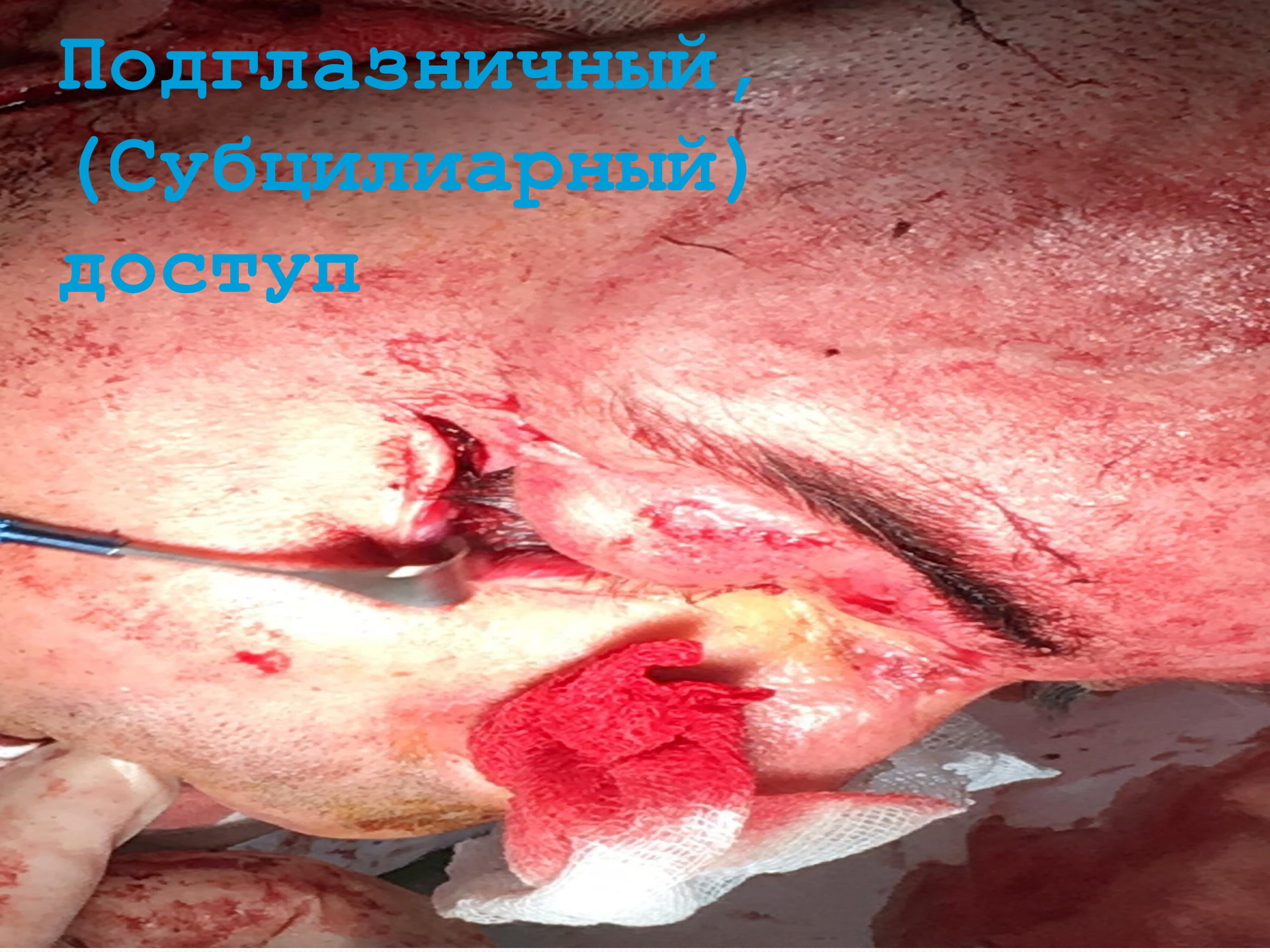

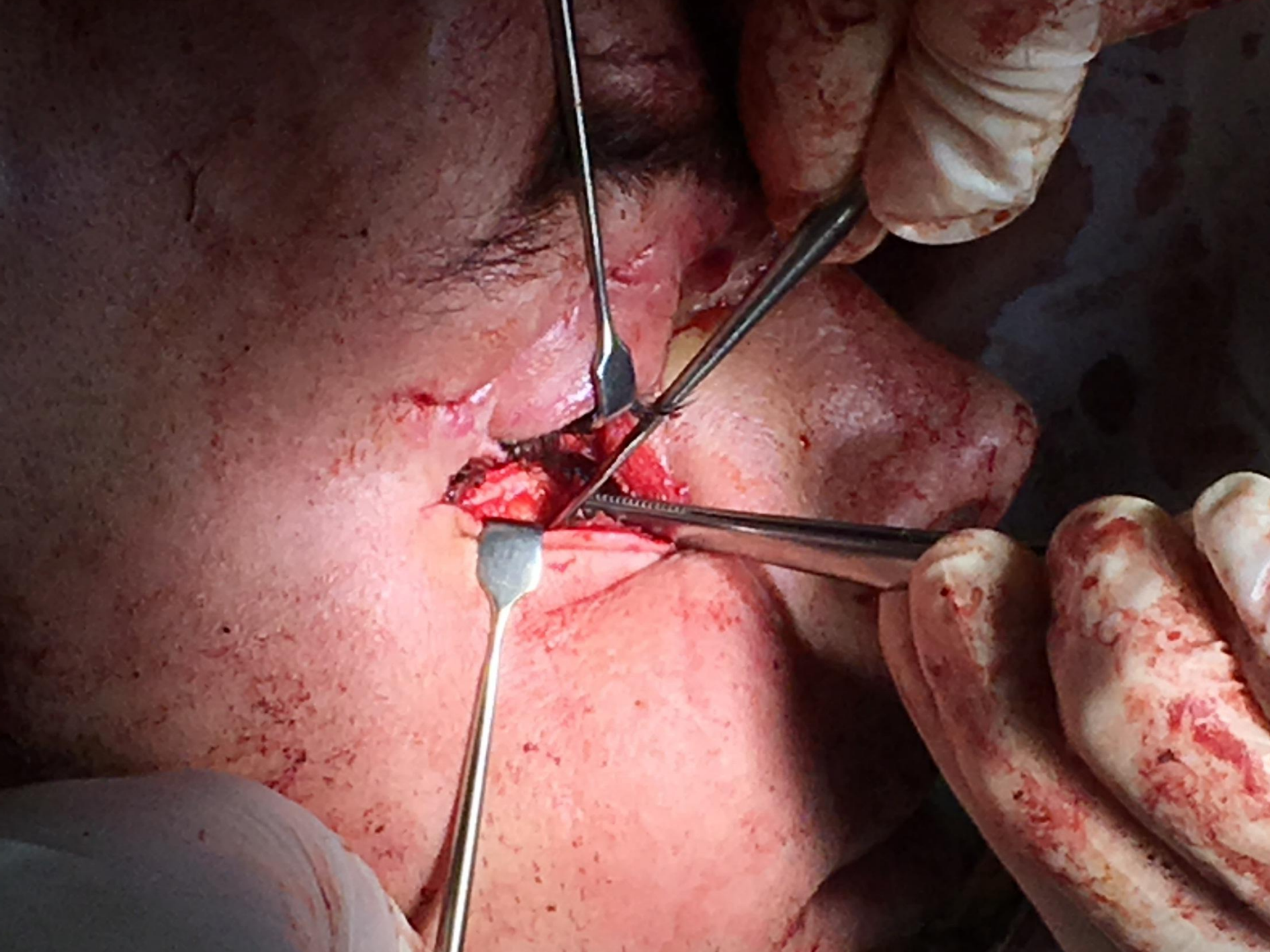


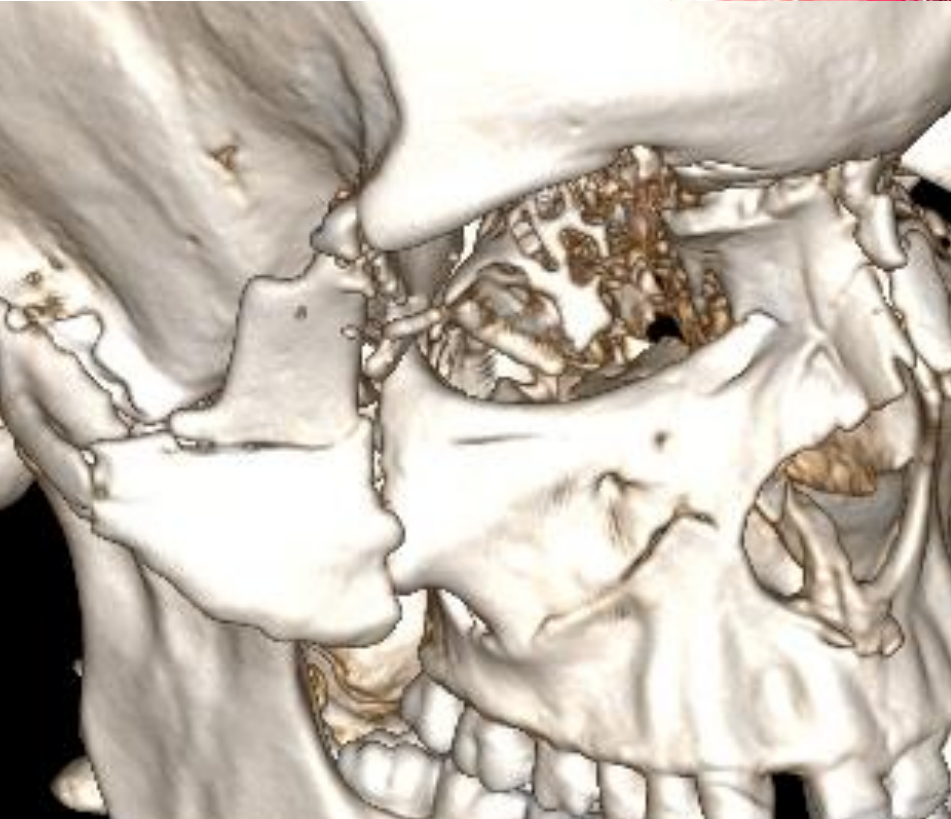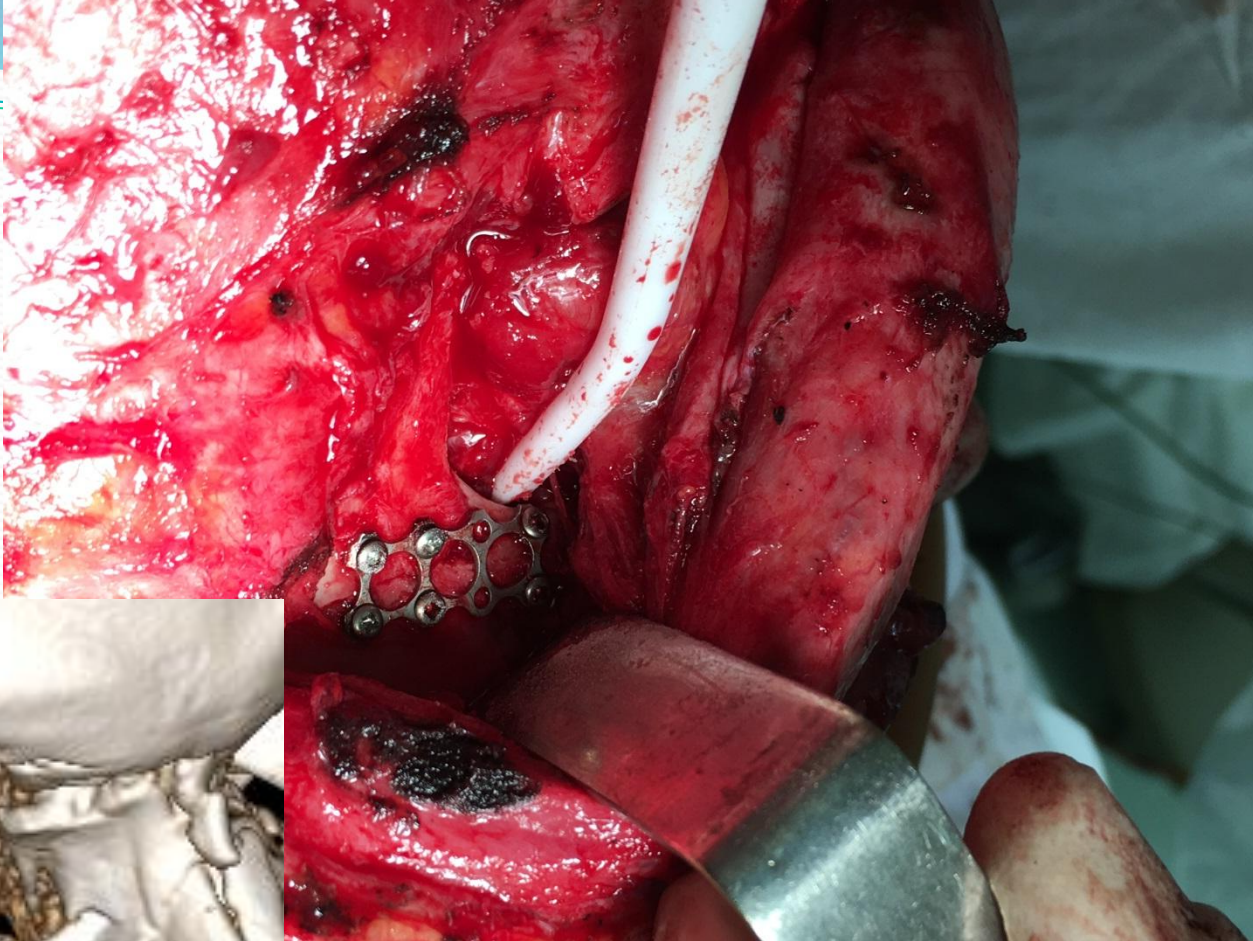



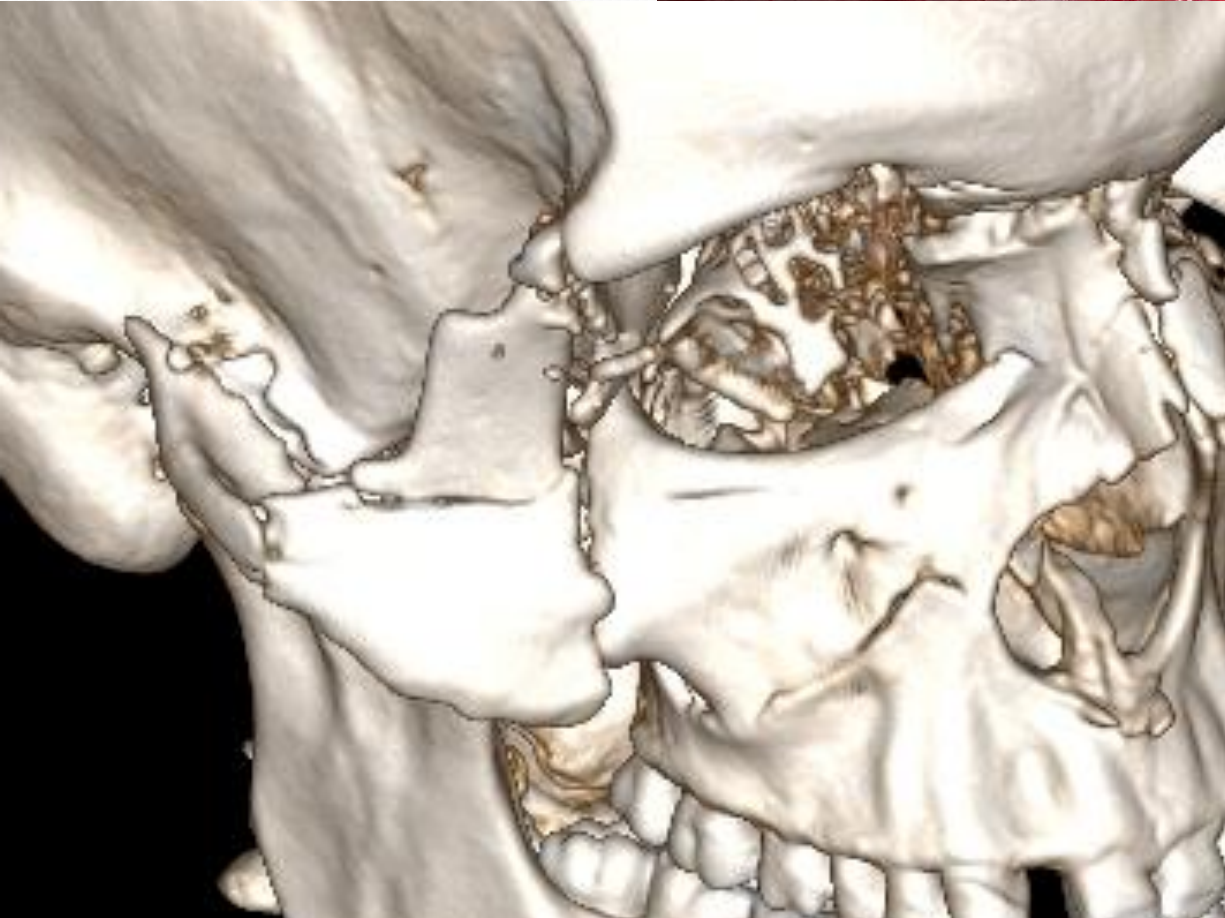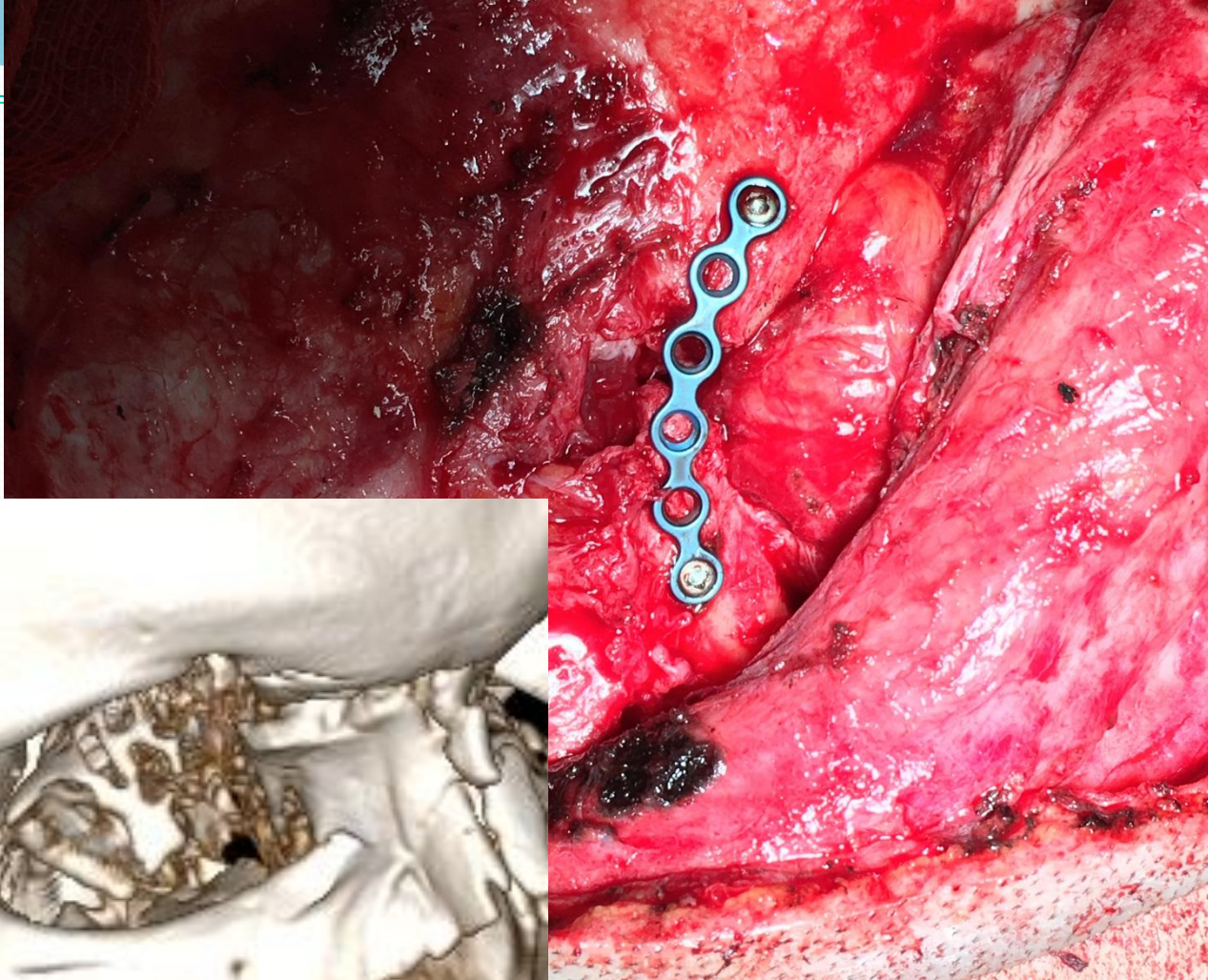



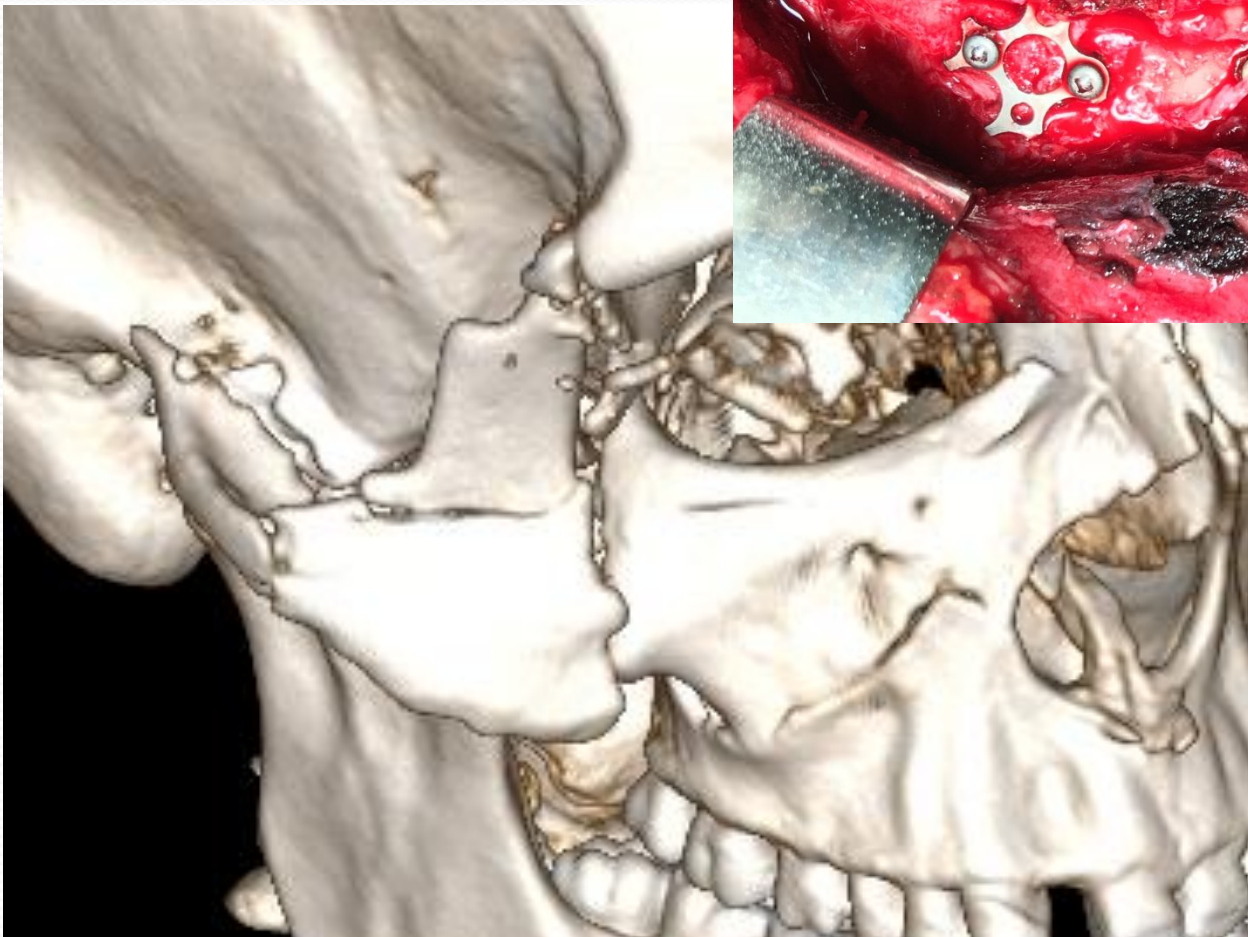
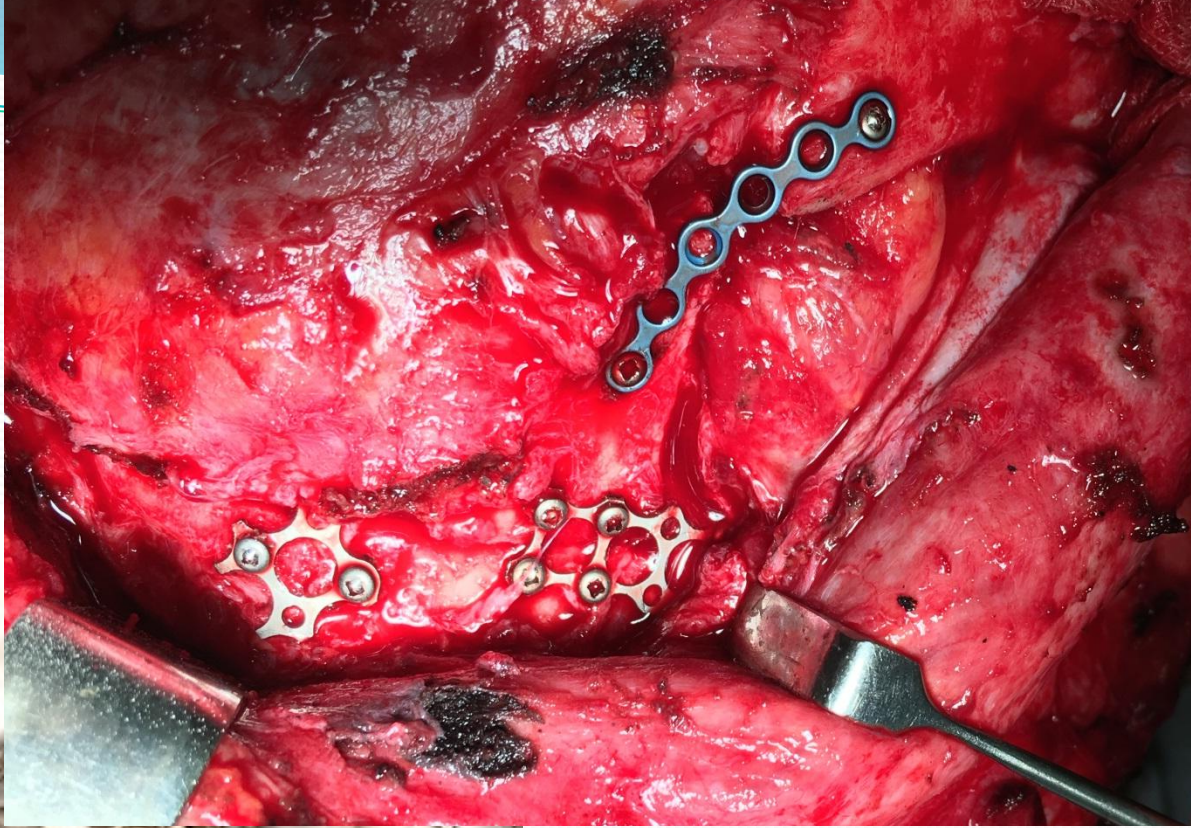
**Подглазничный,
(Субцилиарный)
доступ**

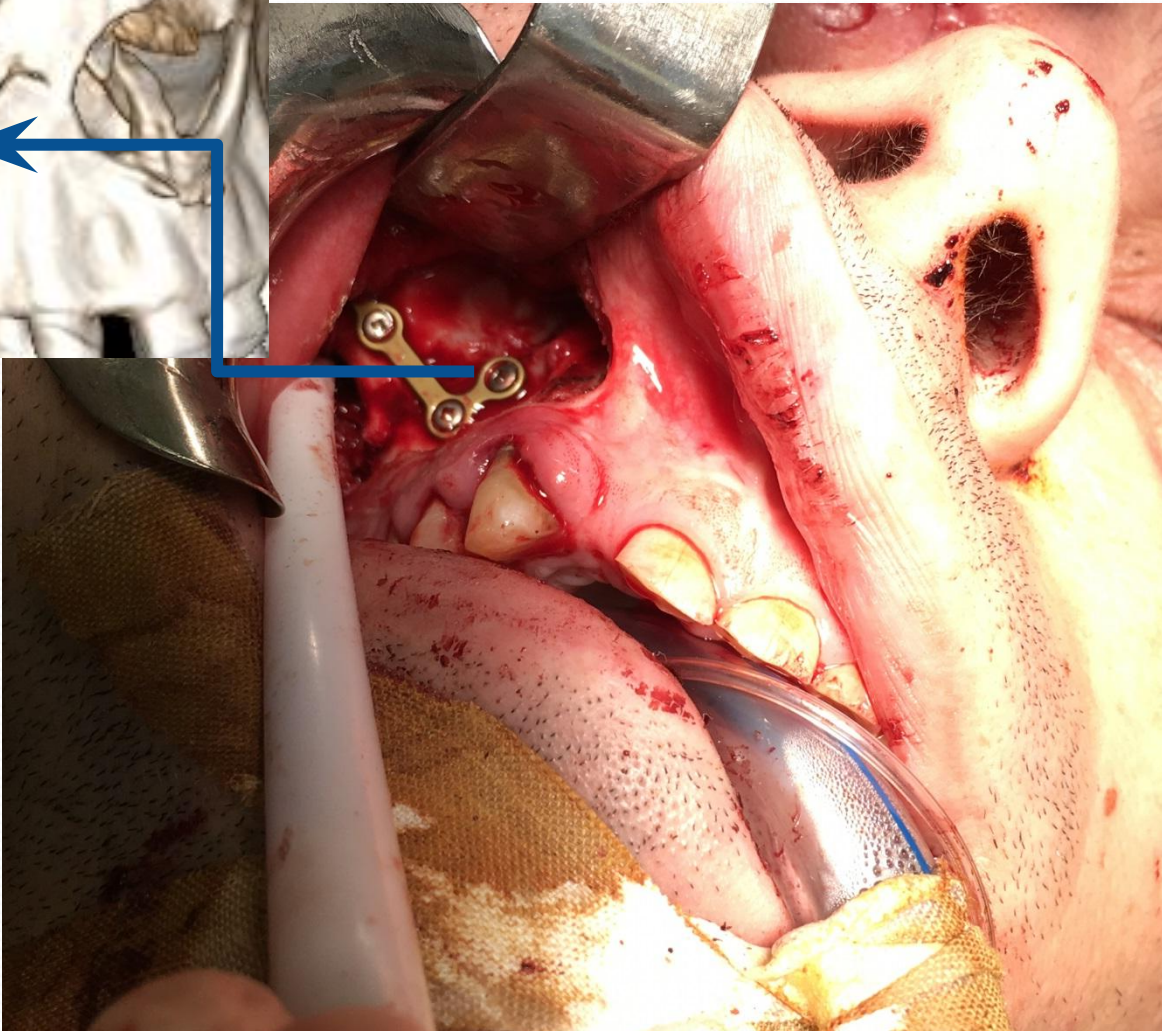

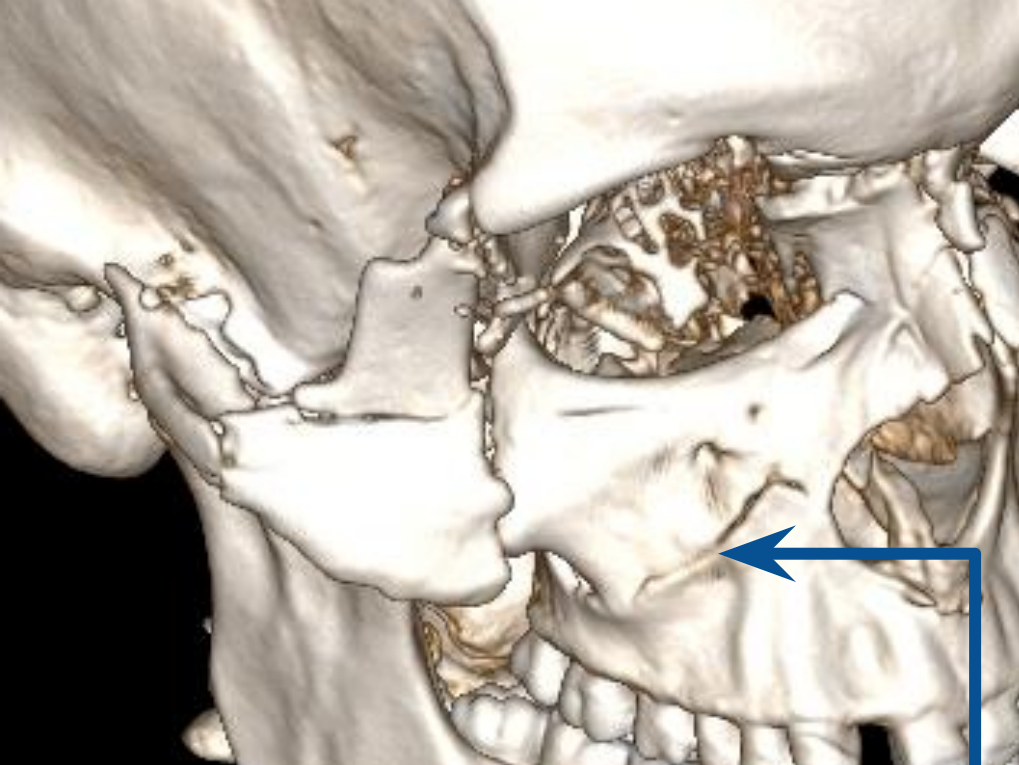

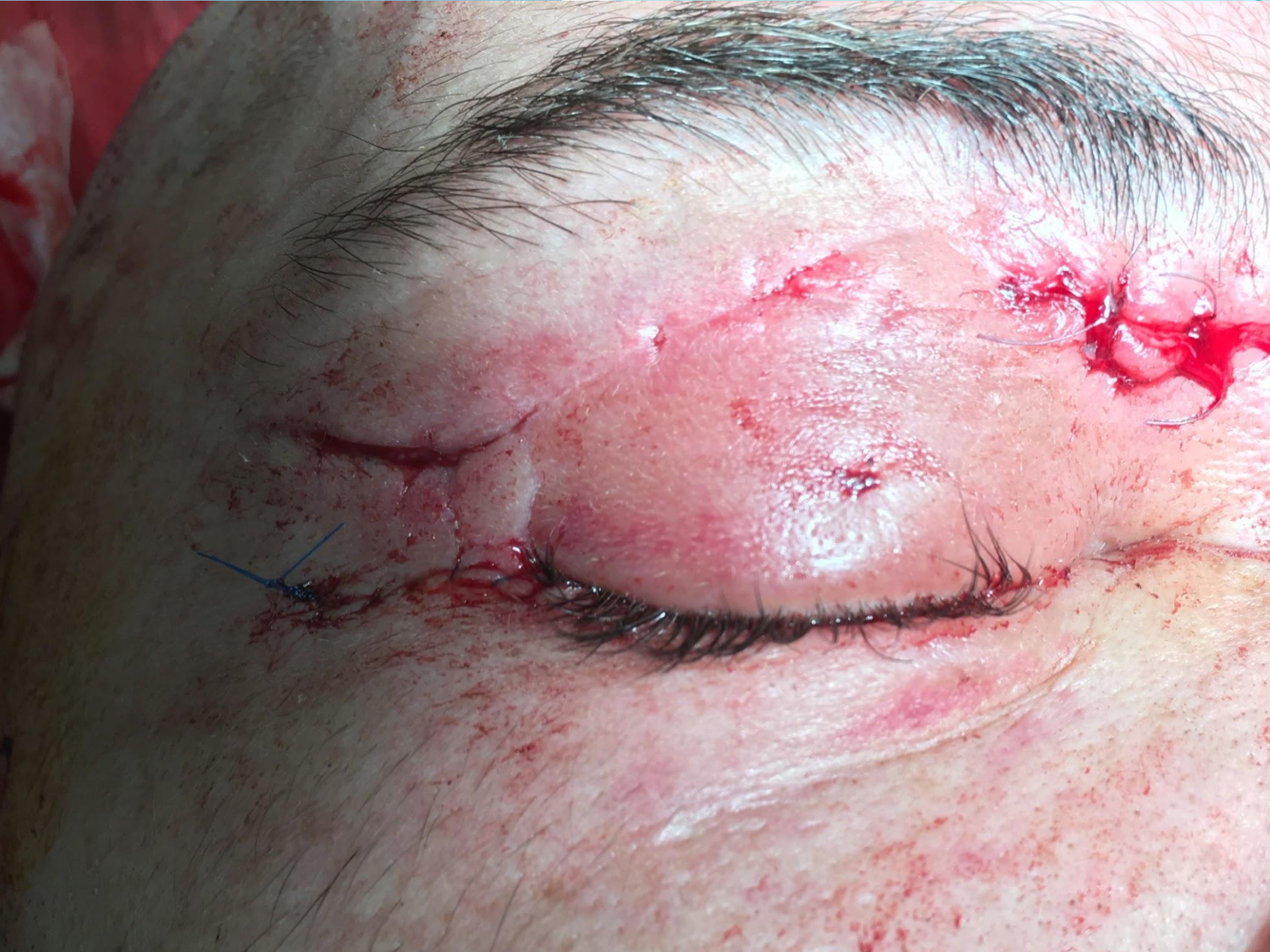


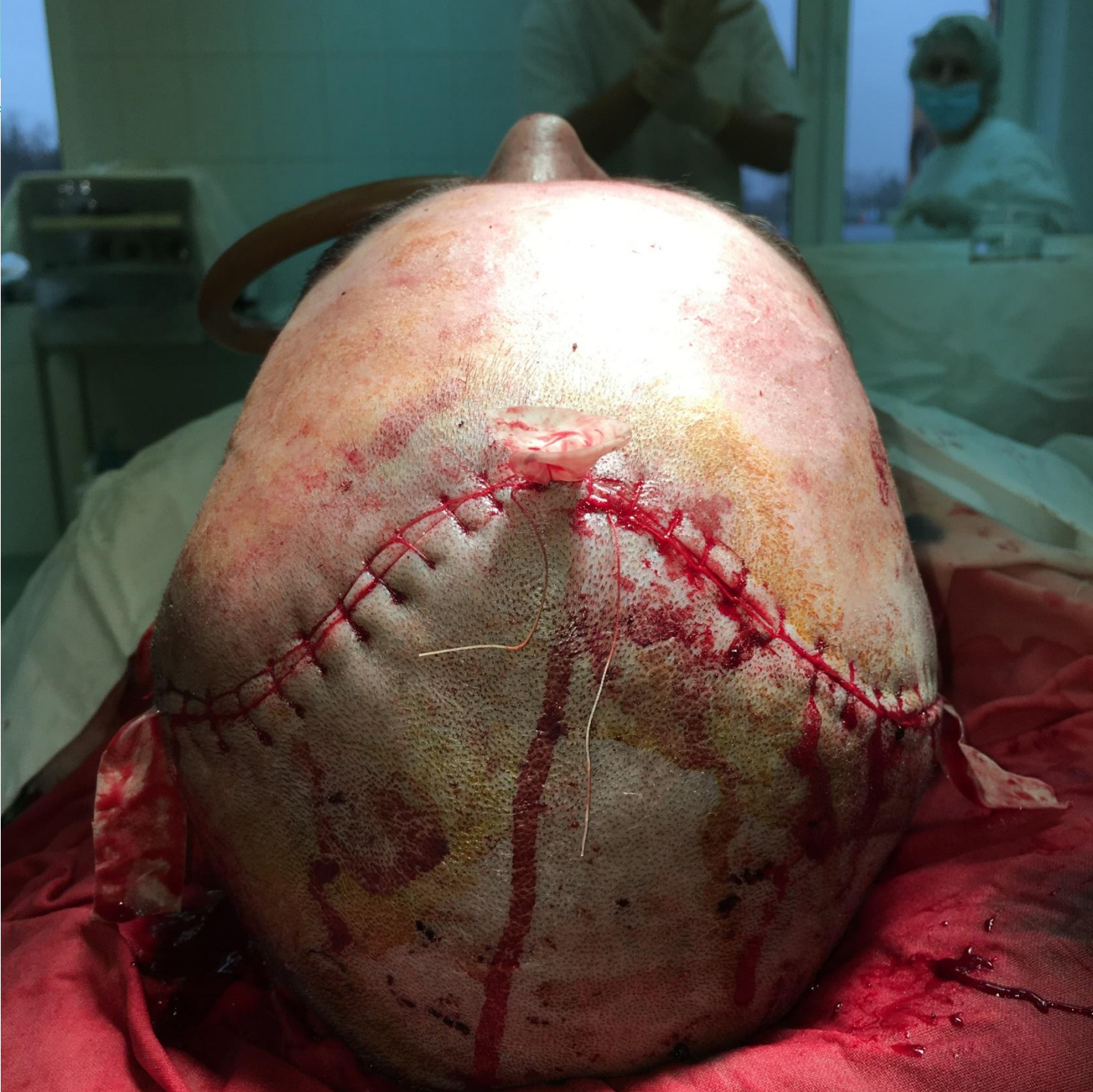













TO BE
CONTINUED



Продолжение следует