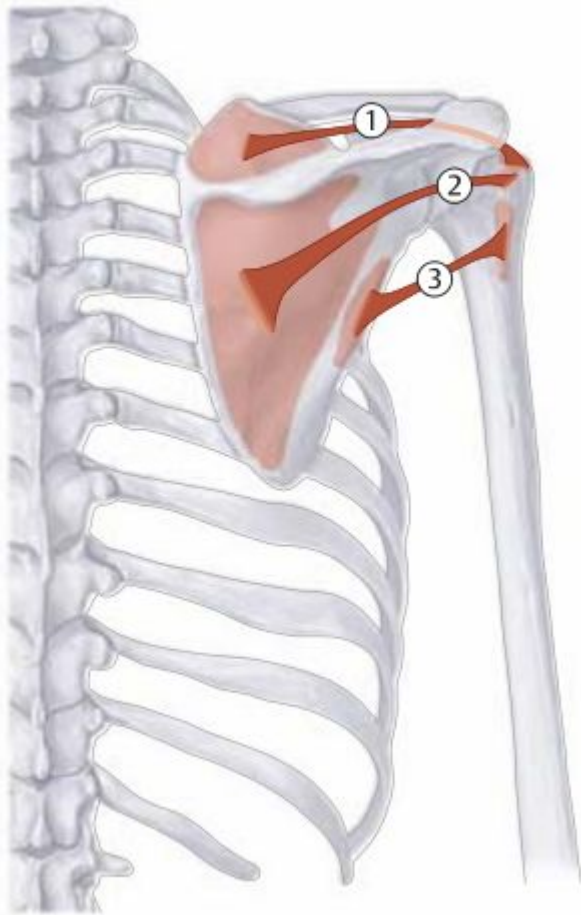


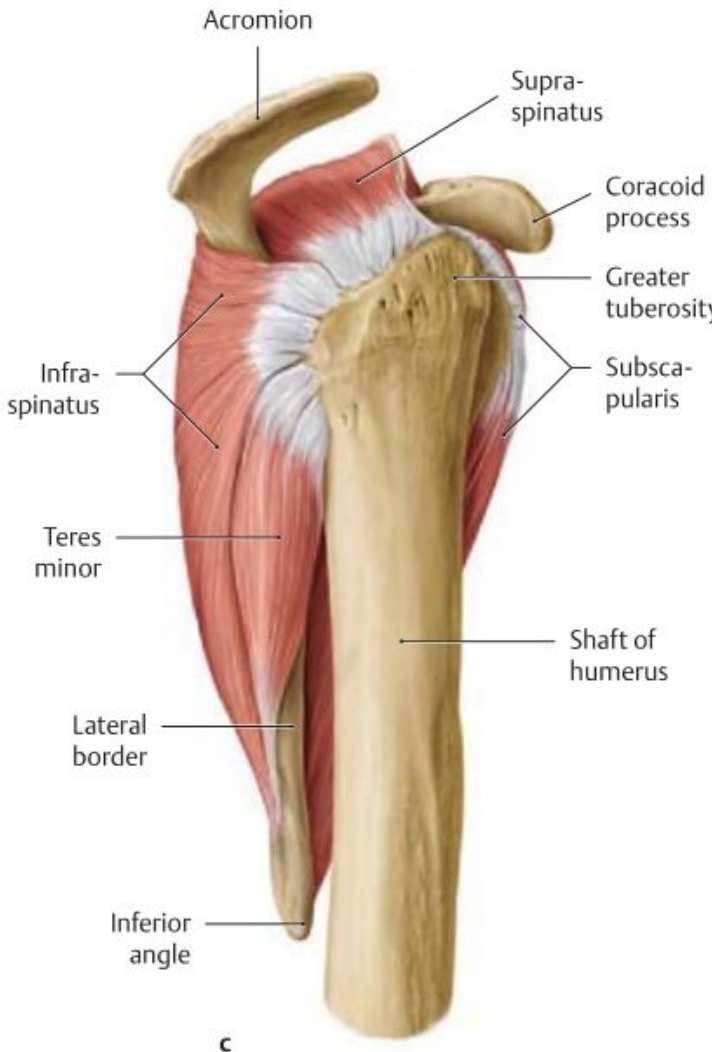
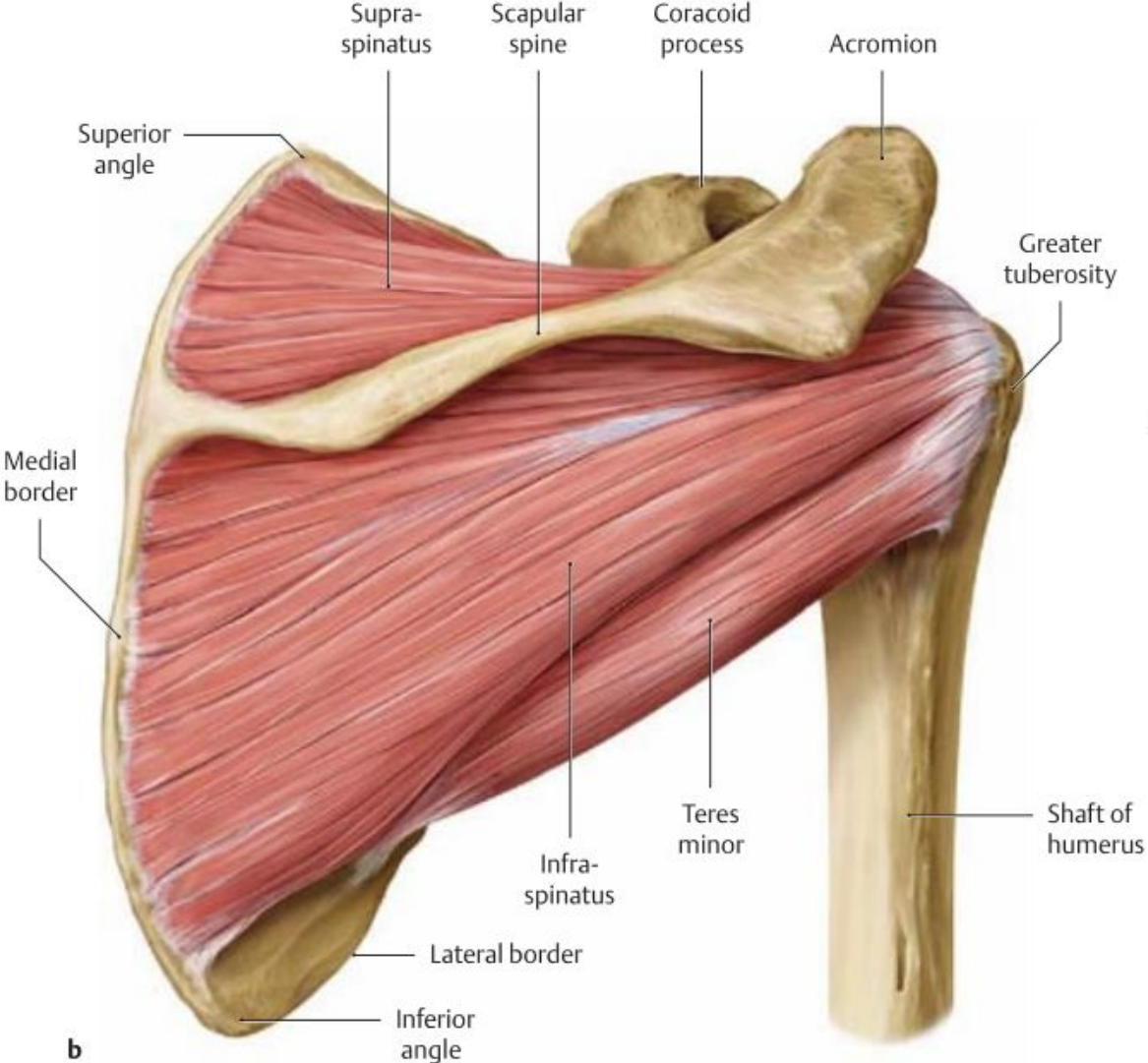
Мышцы плечевого пояса и верхней конечности



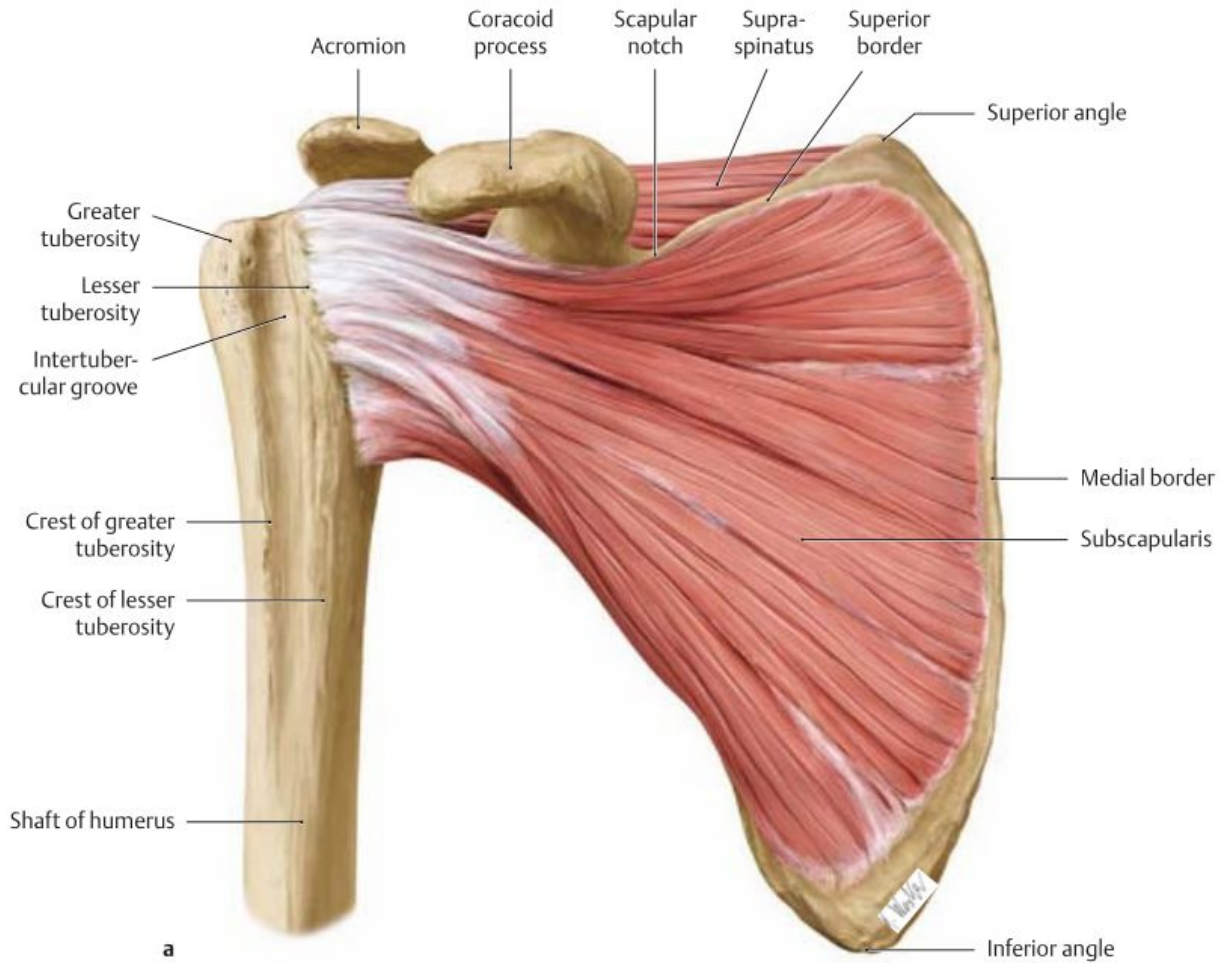
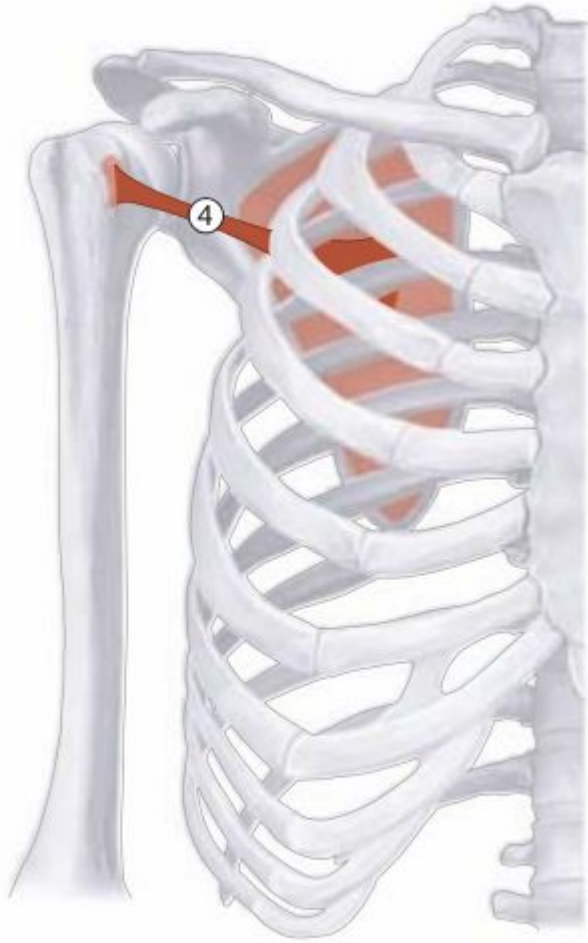1. m. supraspinatus
2. m. infraspinatus
3. m. teres minor

A Schematic of the supraspinatus, infraspinatus, and teres minor

1. m. supraspinatus
2. m. infraspinatus
3. m. teres minor

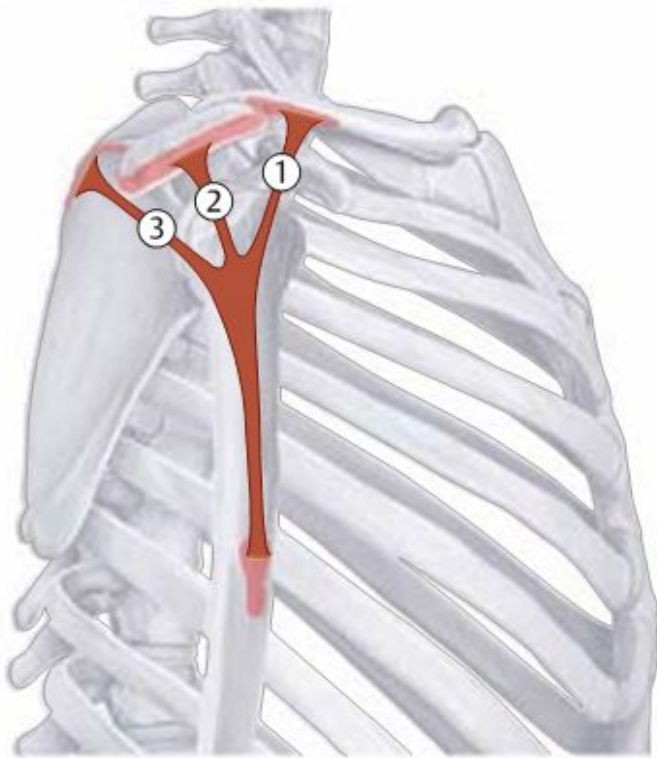


m. subcapularis

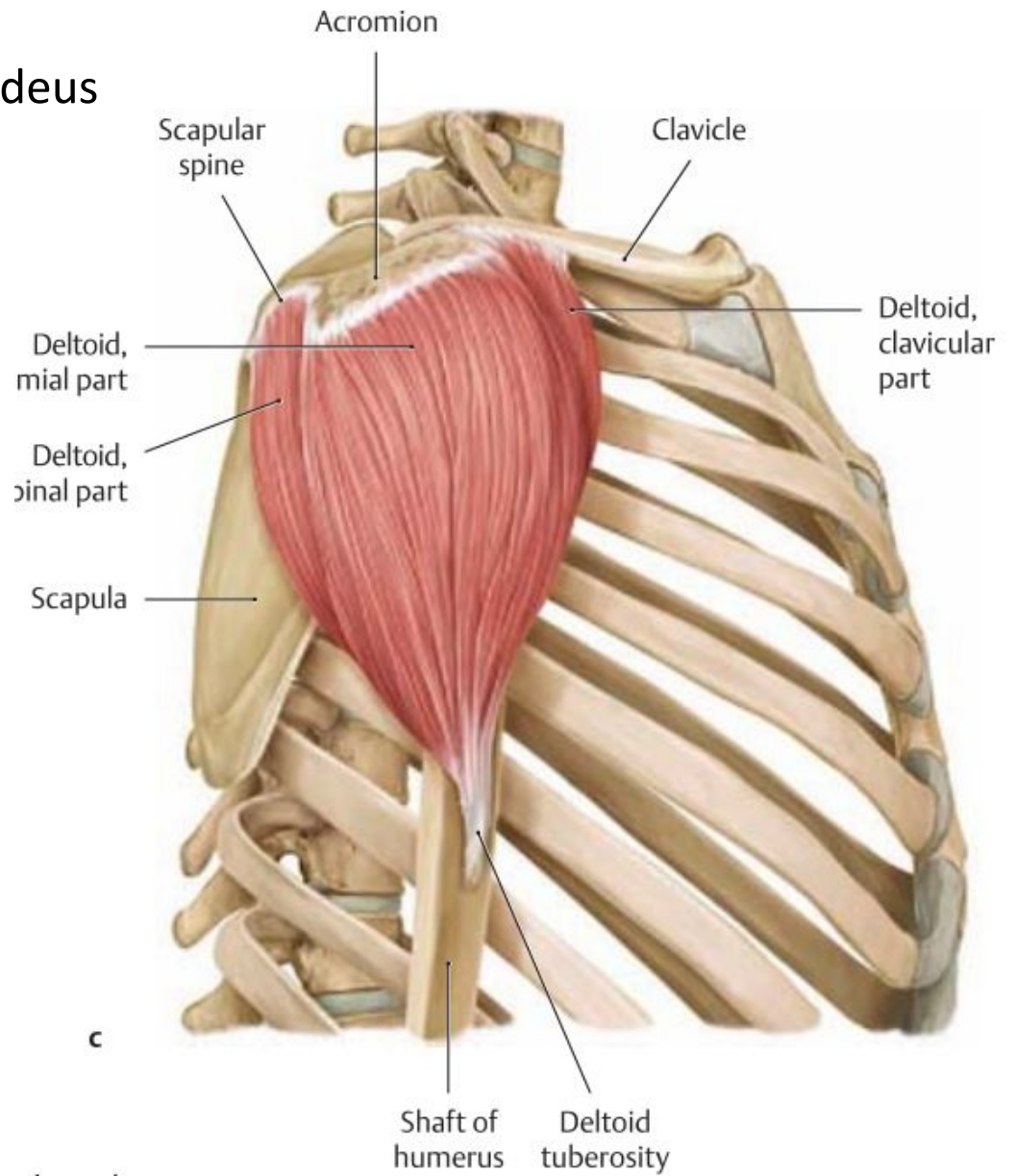


B Schematic of the subscapularis

m. deltoideus

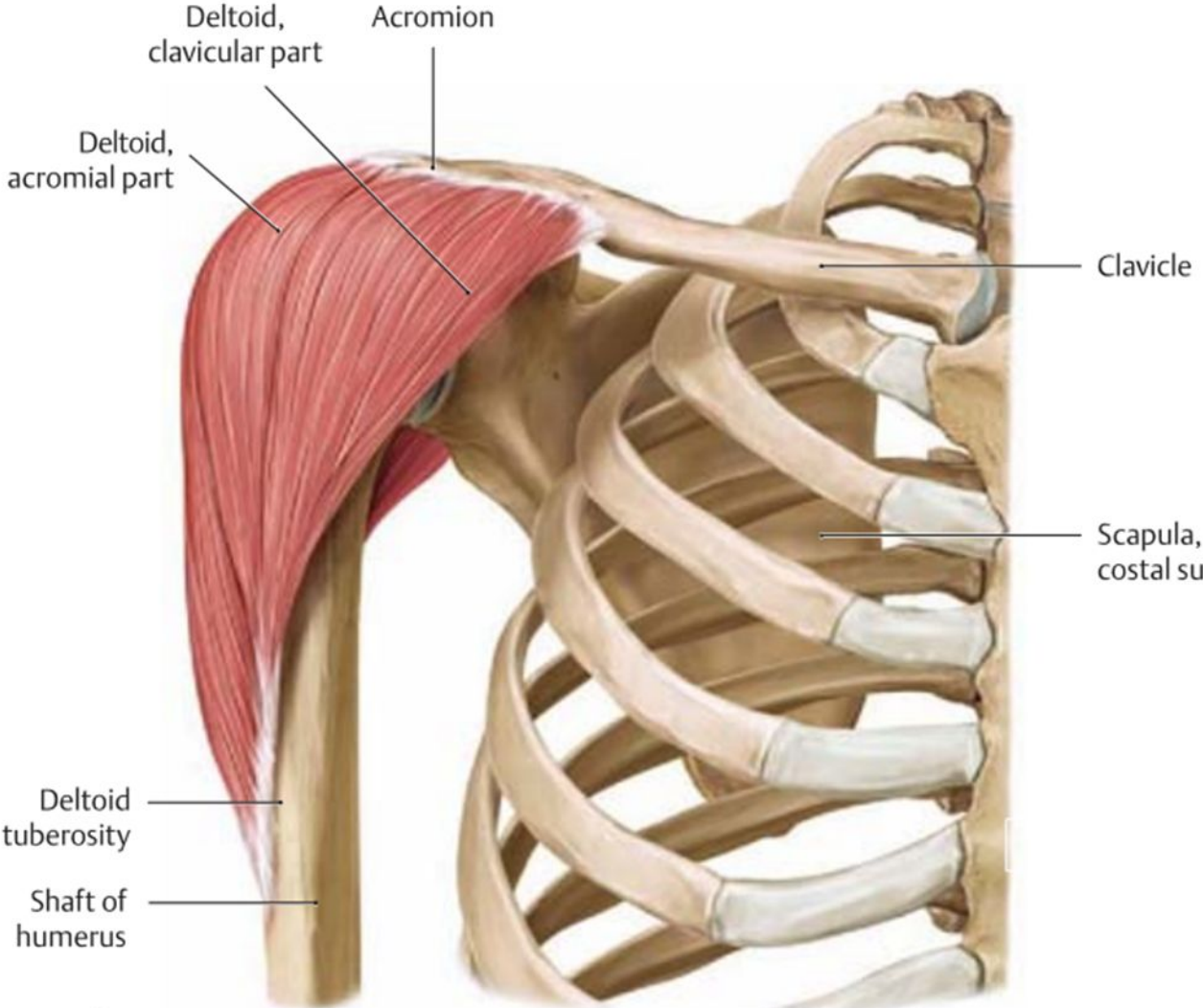


A Schematic of the deltoid



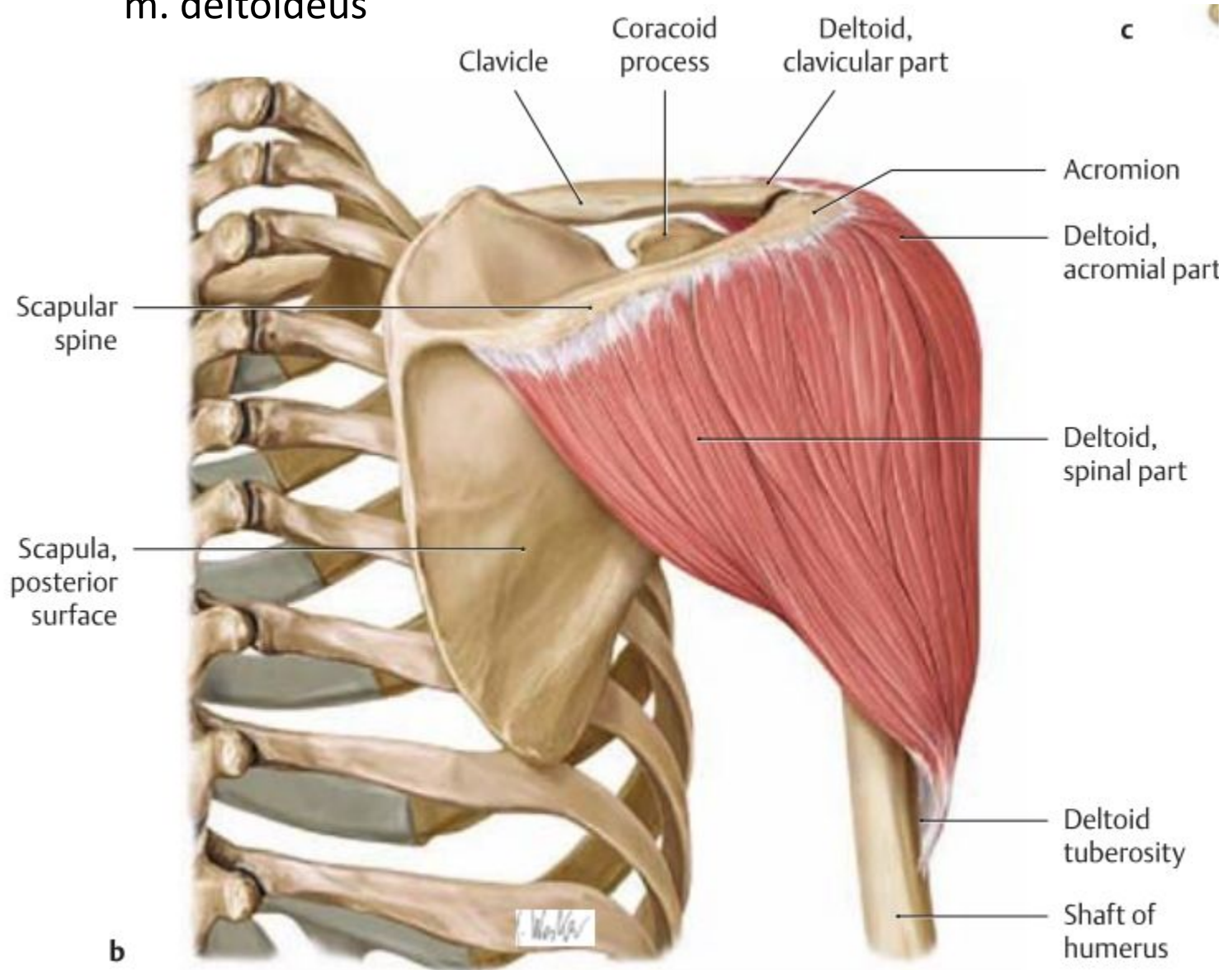
c

m. deltoideus

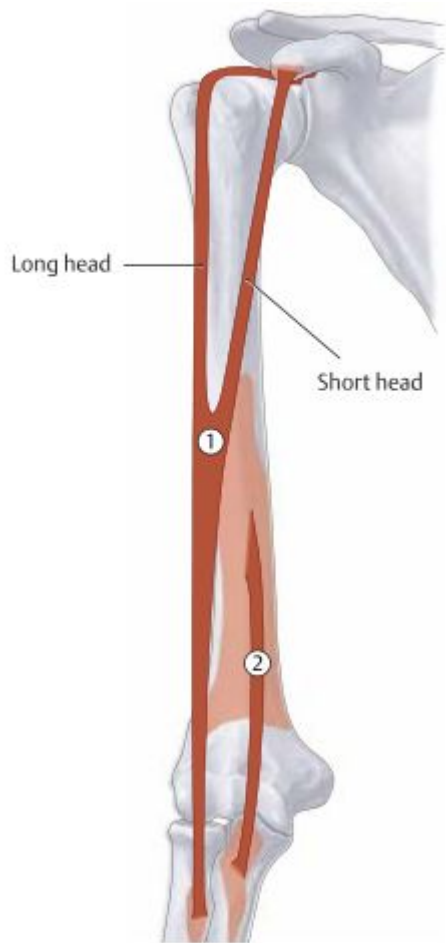


a

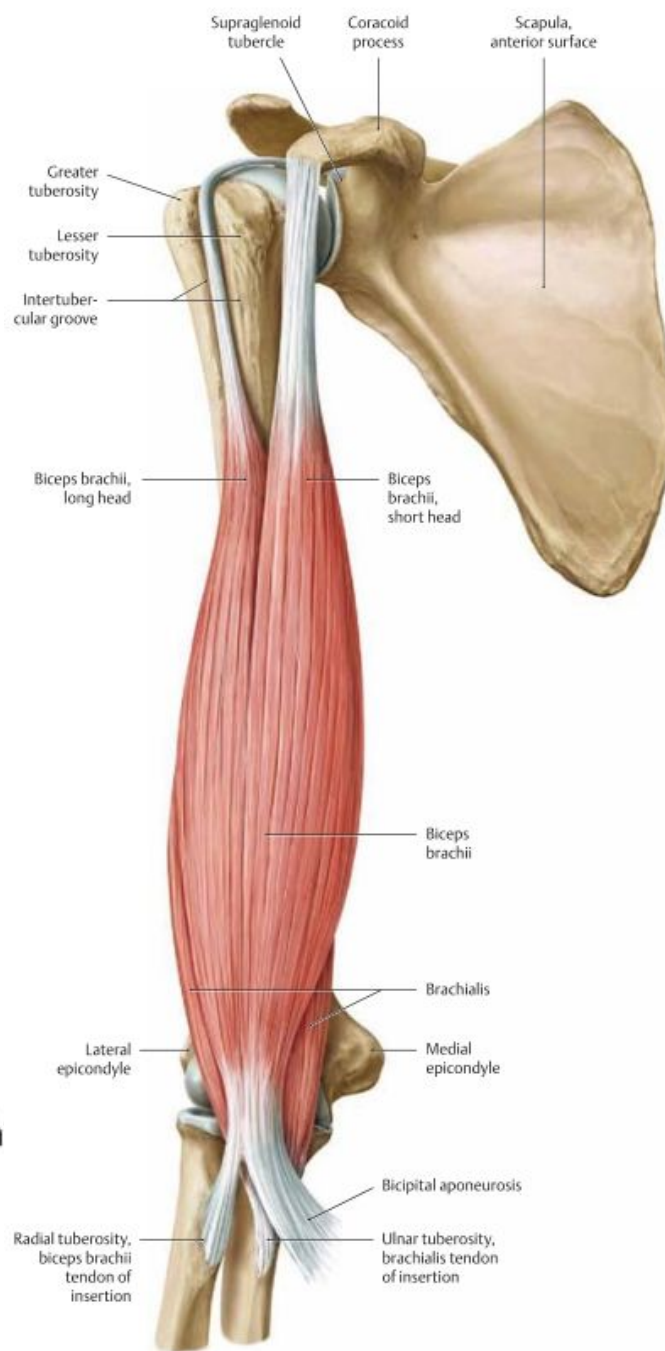
m. deltoideus



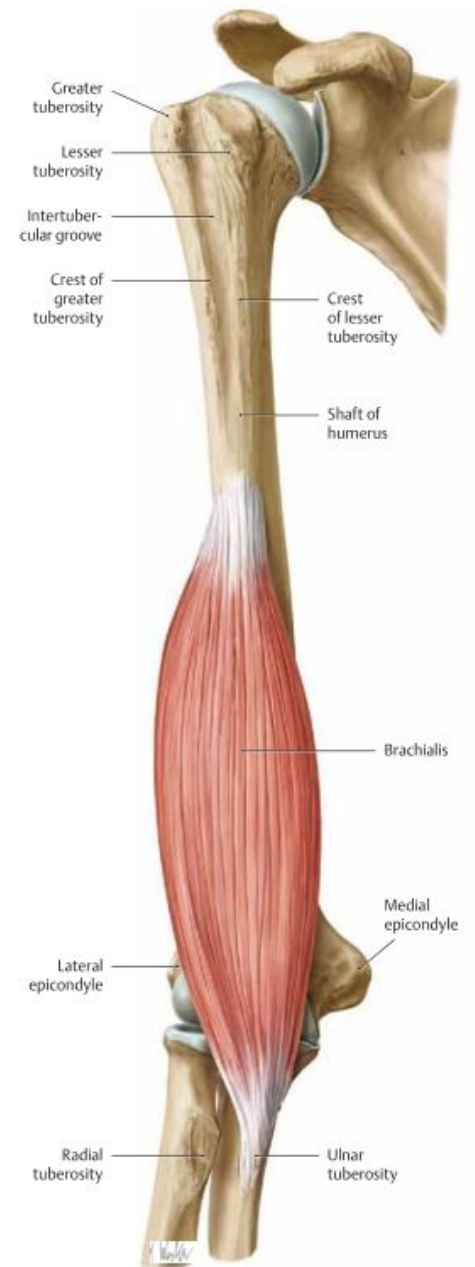
c



A Schematic of the biceps brachii and brach

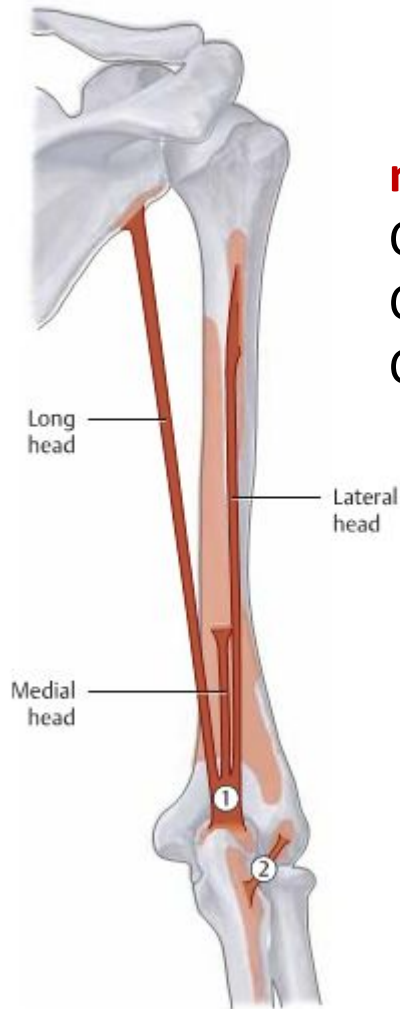


C The biceps brachii and brachialis
Right arm, anterior (ventral) view.

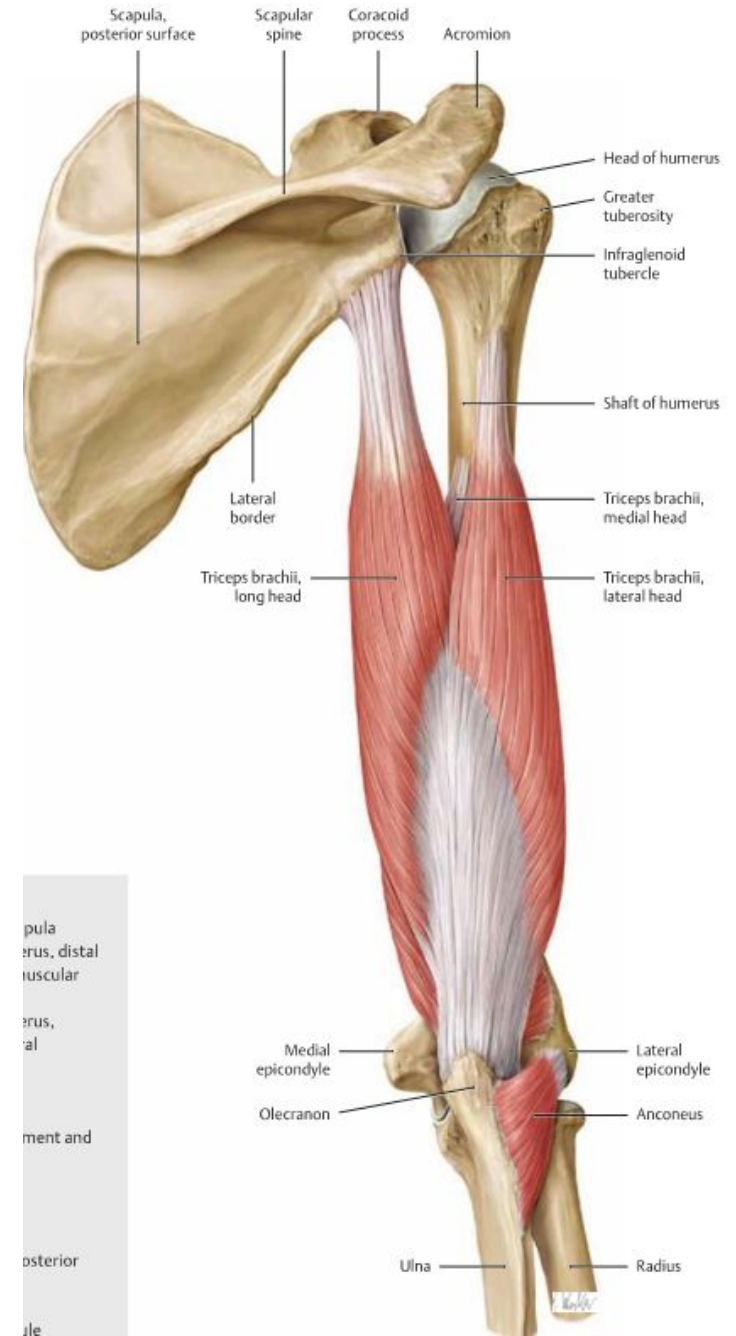


D The brachialis
Right arm, anterior (ventral) view.

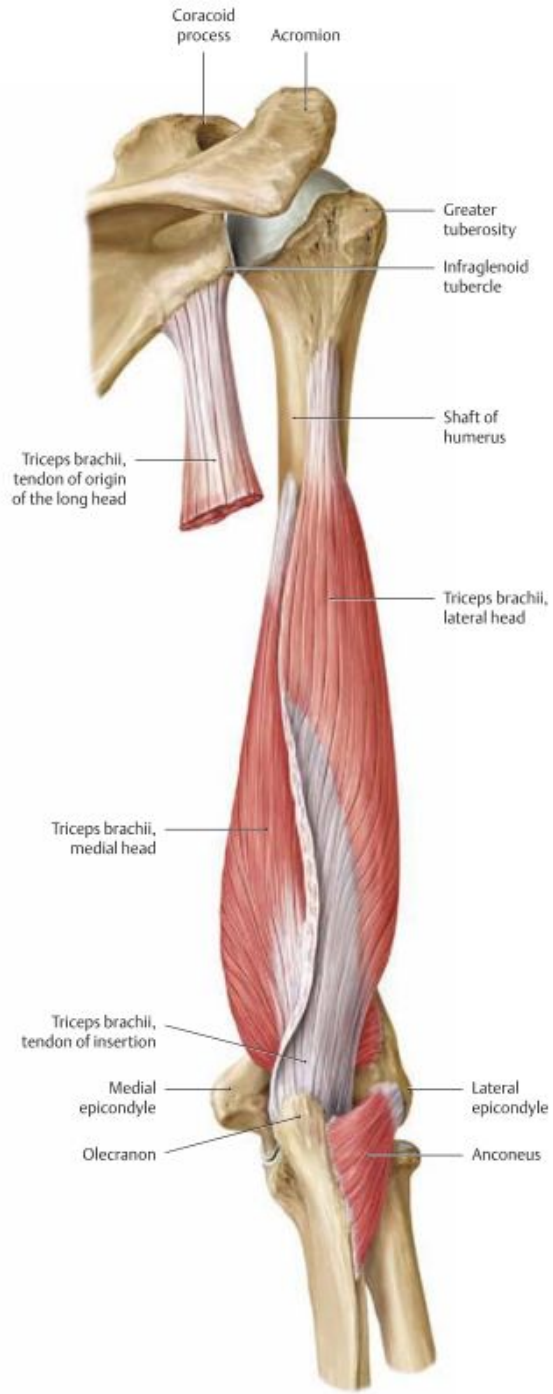
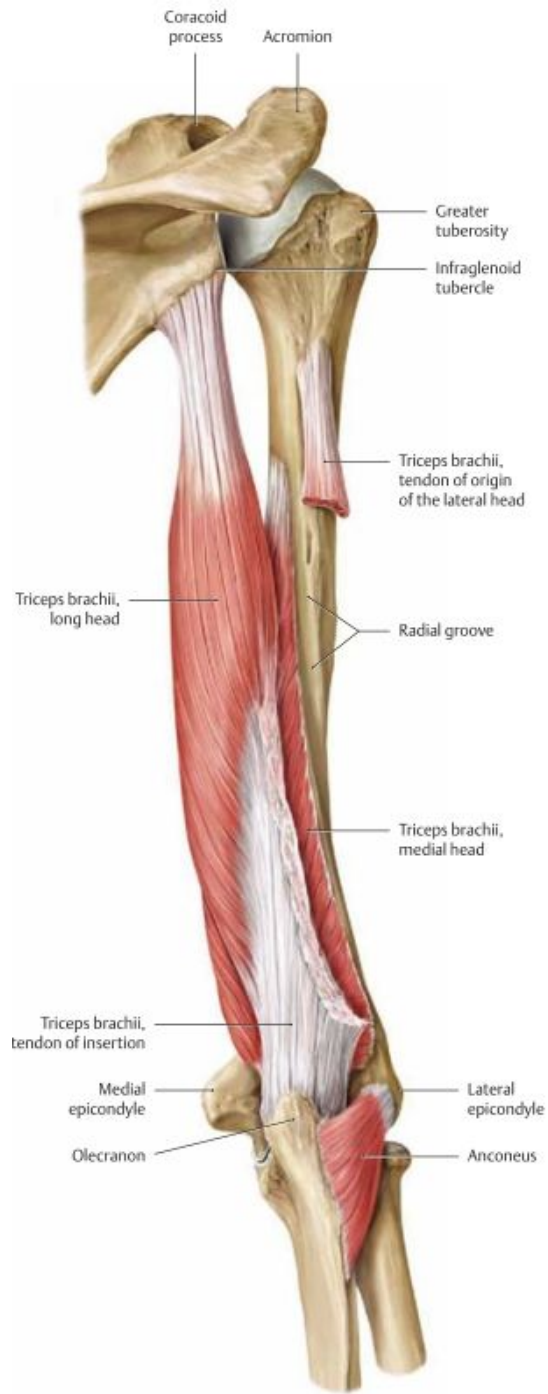
Triceps brachii and Anconeus



m. triceps brachii
 Caput longum
 Caput laterale
 Caput mediale



pula
 erus, distal
 uscular
 erus,
 al
 ment and
 osterior
 le

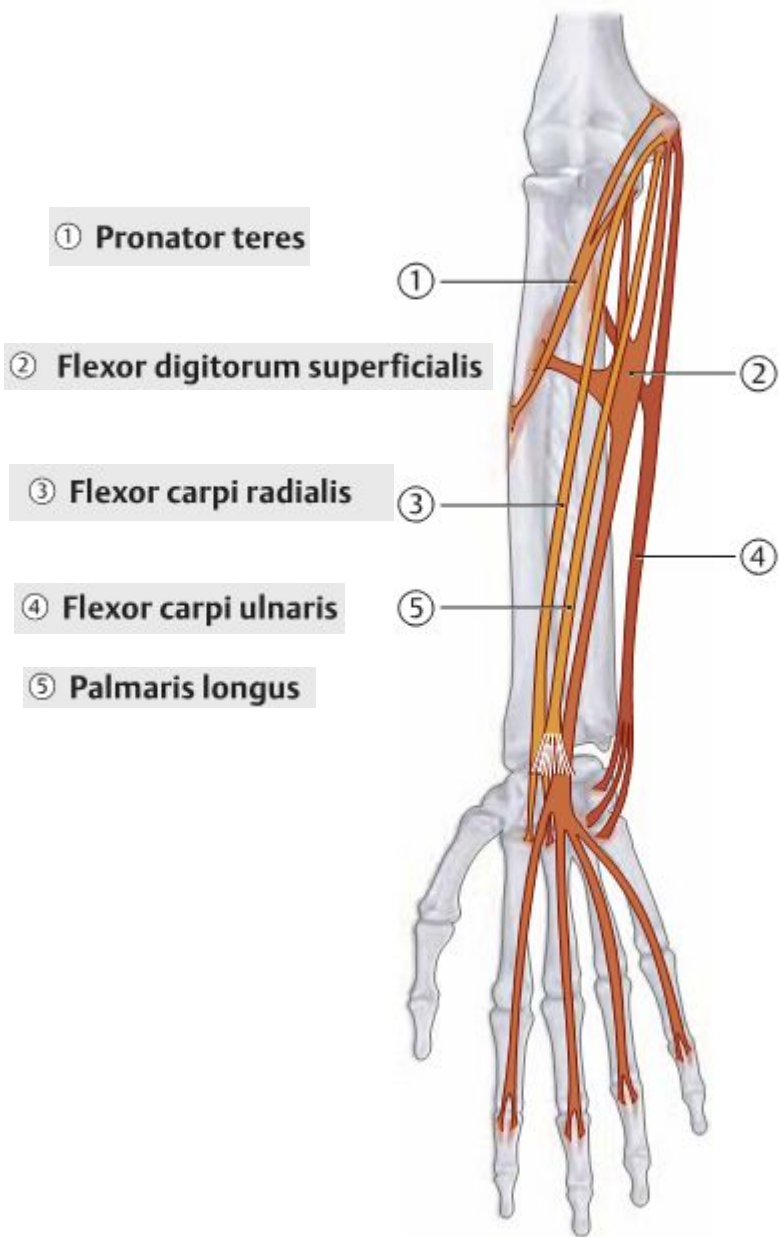


m. triceps brahii

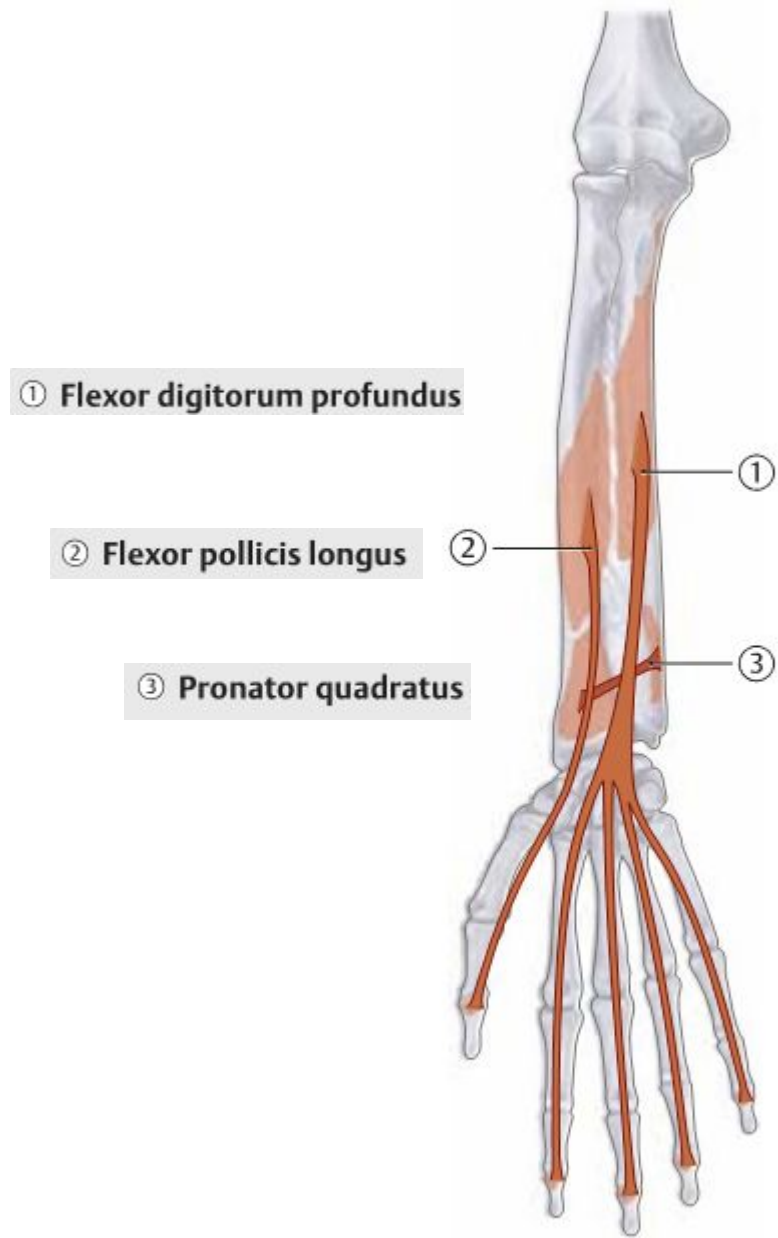
Caput longus

Caput lateralis

Caput medialis

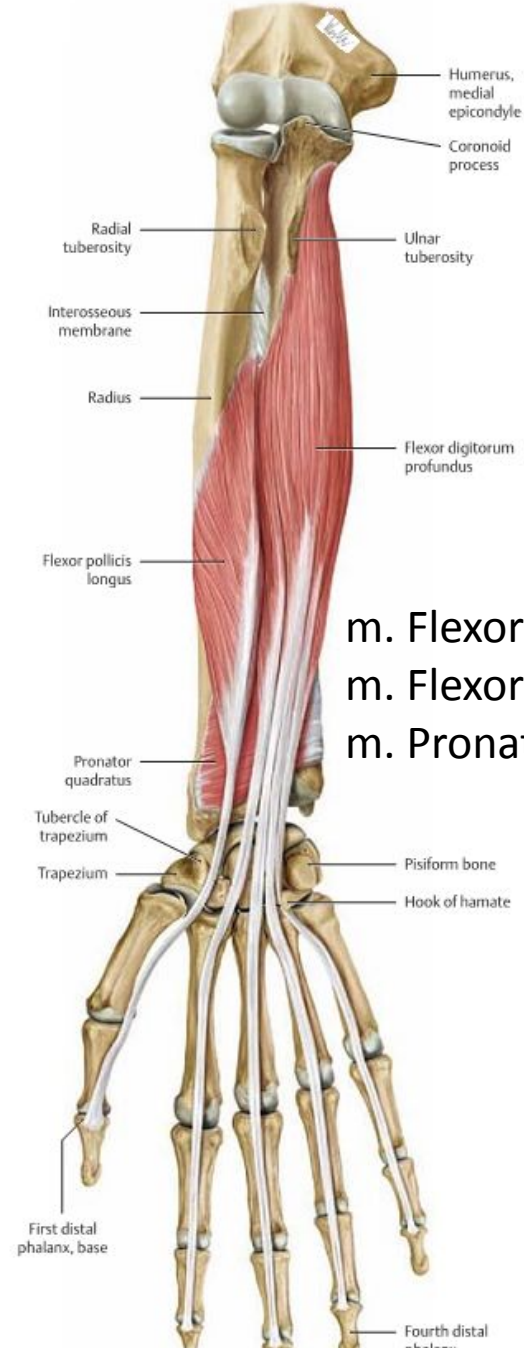
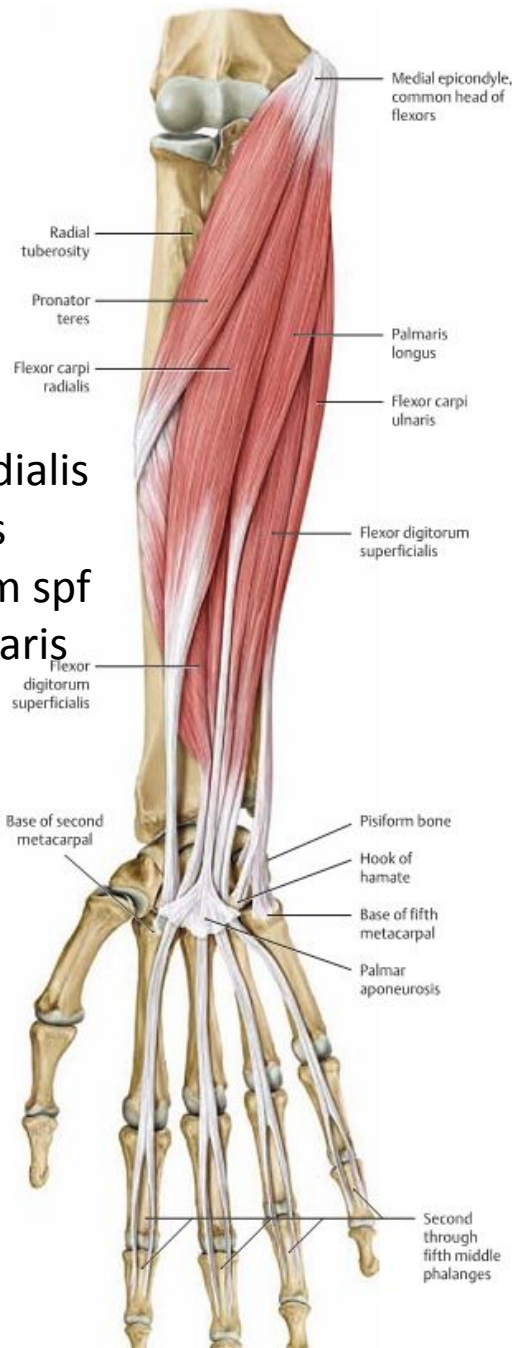

A Schematic of the superficial flexors

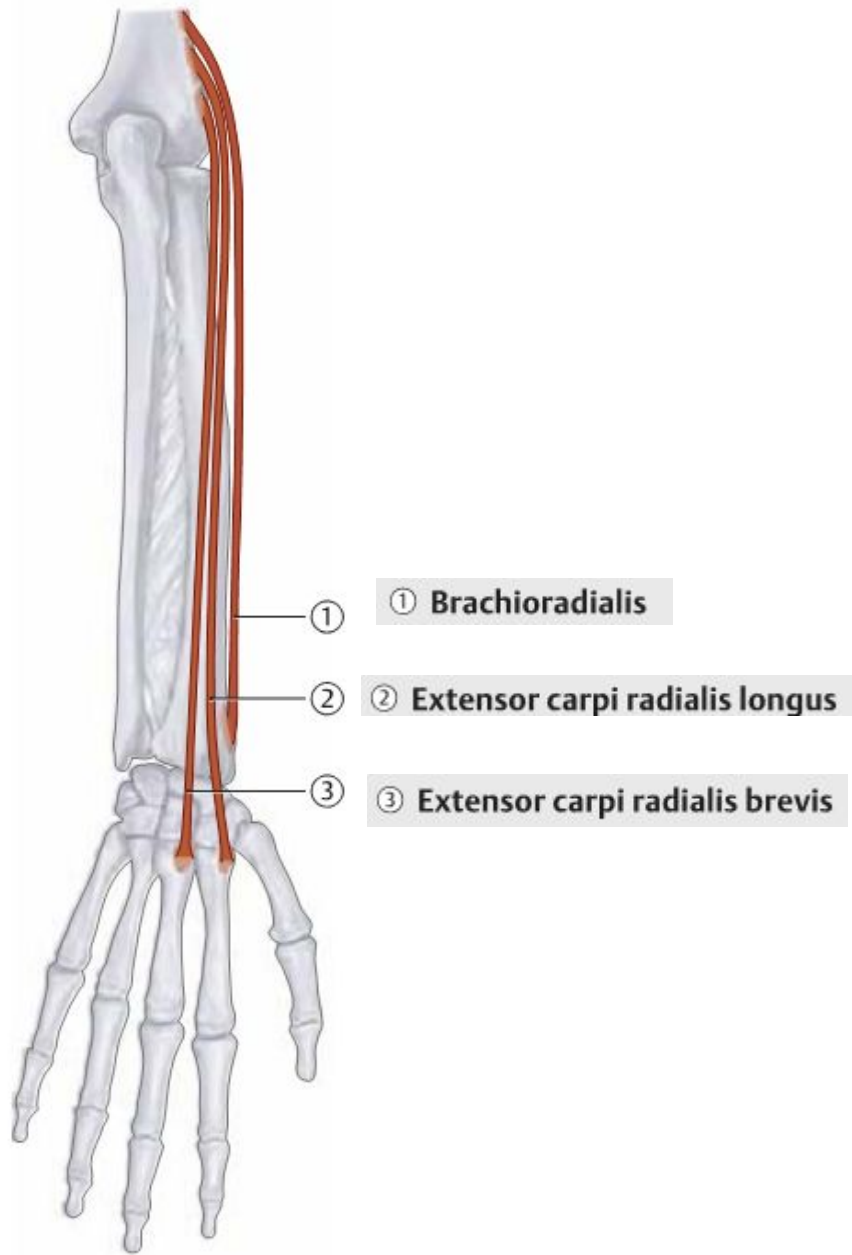


B Schematic of the deep flexors

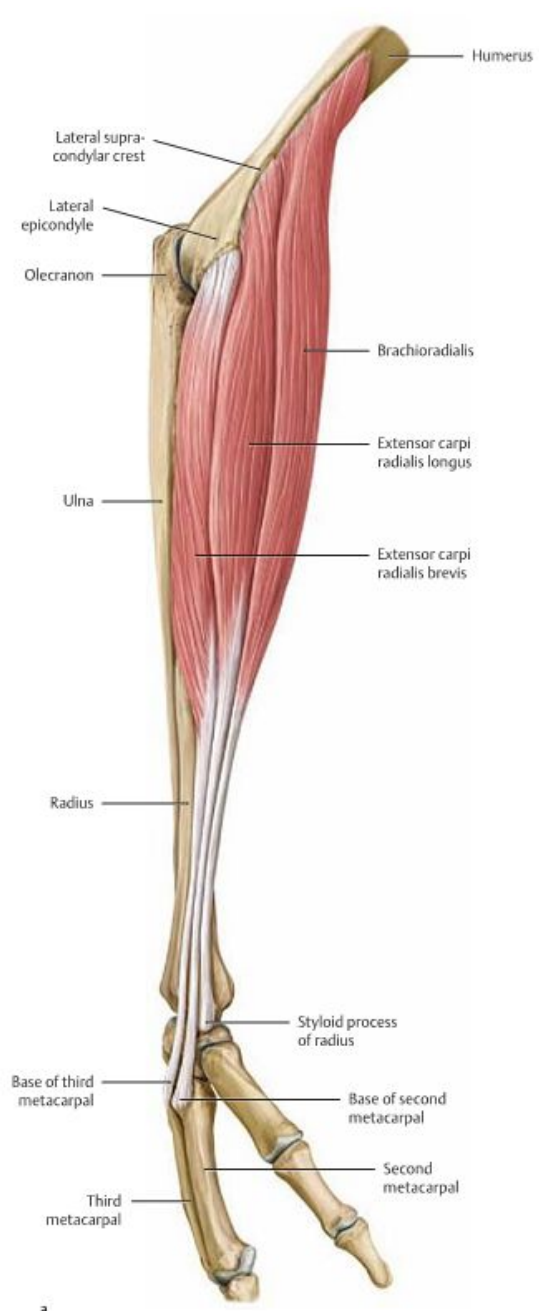
- m. Pronator teres
- m. Flexor carpi radialis
- m. Palmaris longus
- m. Flexor digitorum spf
- m. Flexor carpi ulnaris



- m. Flexor pollicis longus
- m. Flexor digitorum profundus
- m. Pronator quadratus

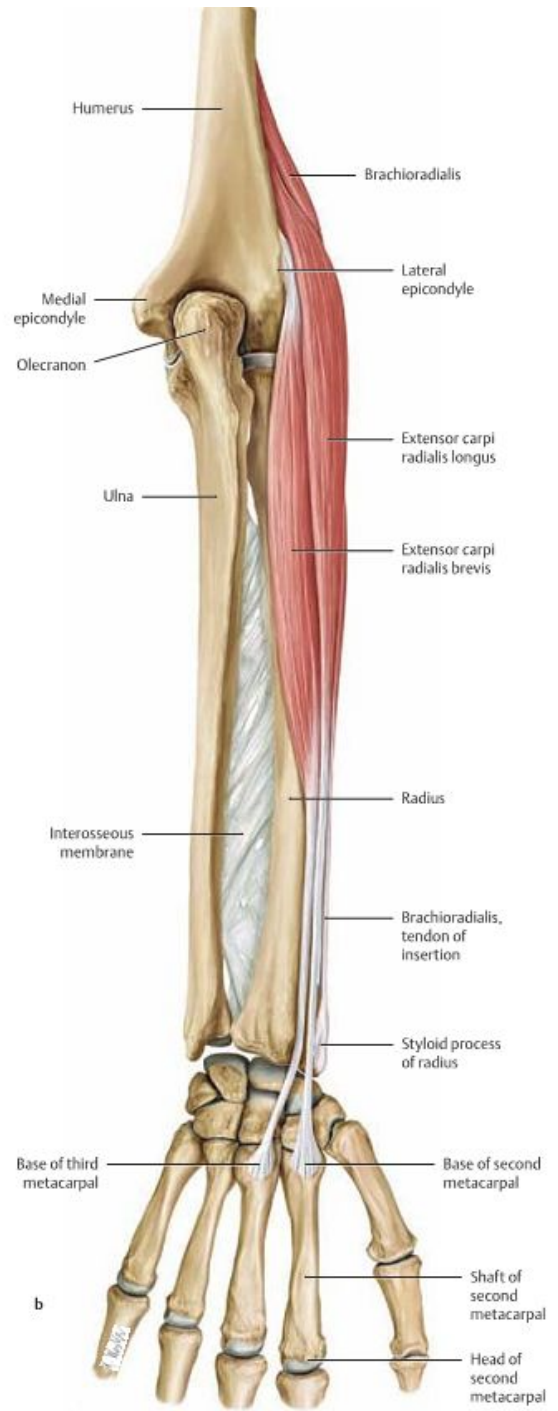


A Schematic of the radial muscles

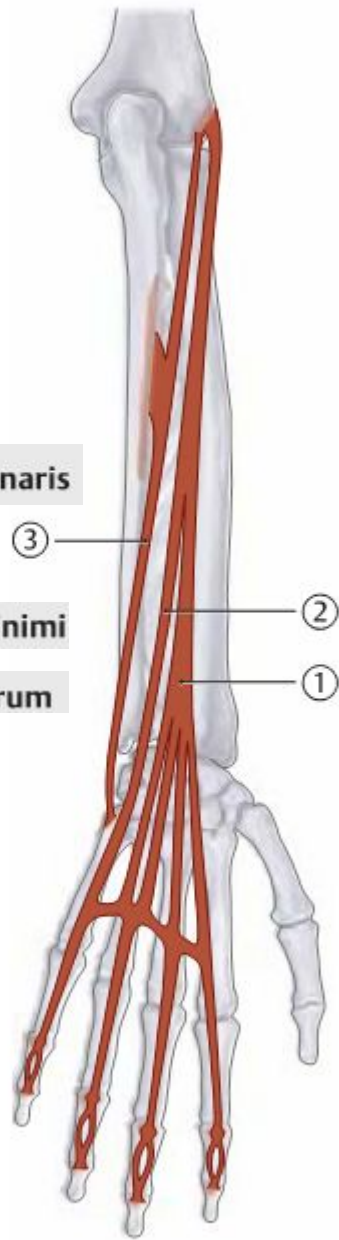


a

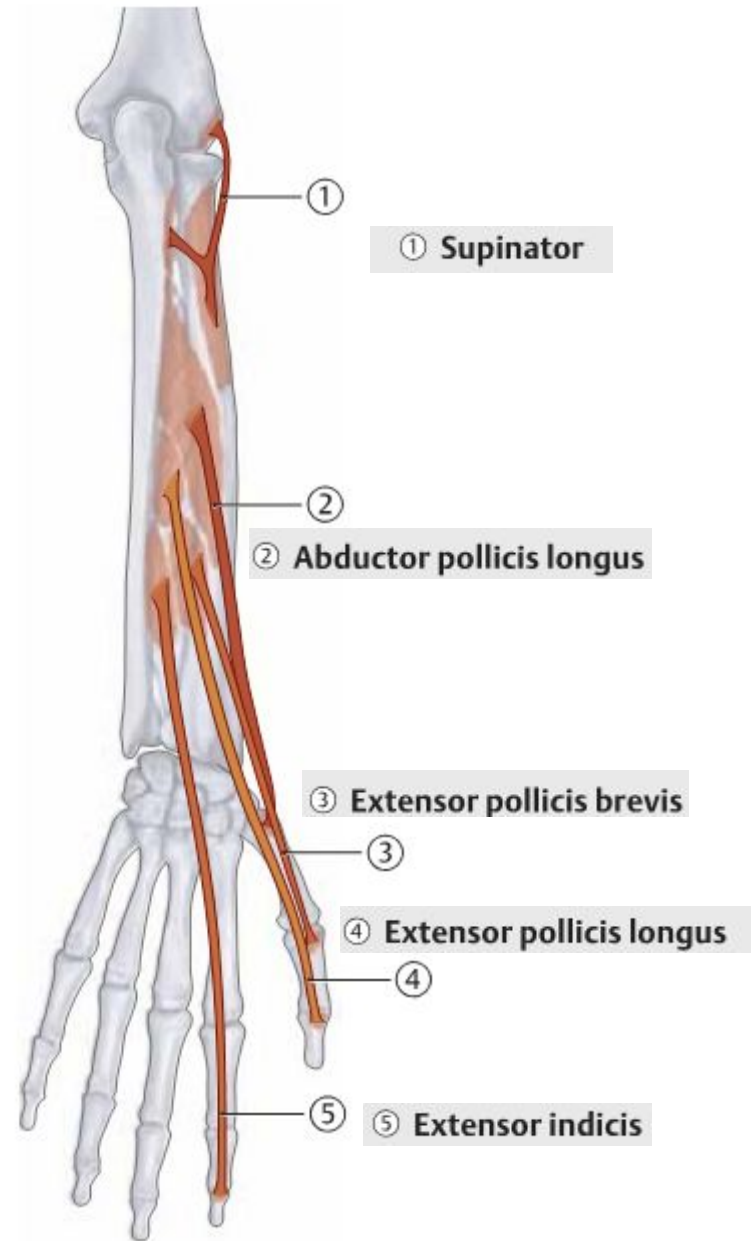
B The radialis muscles (brachioradialis, extensor carpi radialis longus, and extensor carpi radialis brevis)
Right forearm.



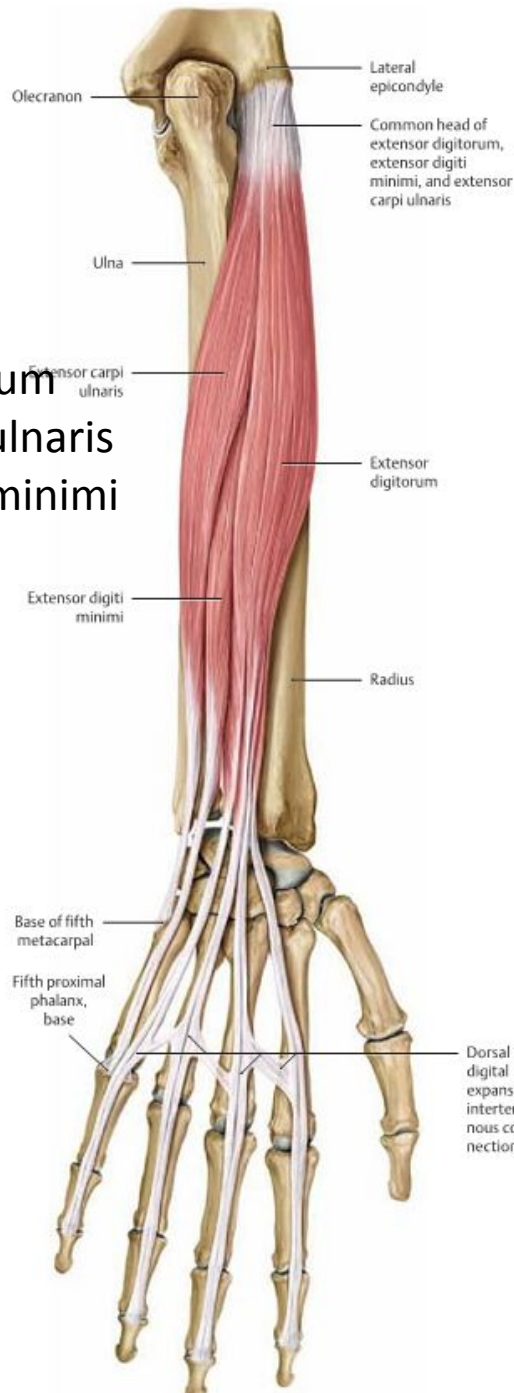
b



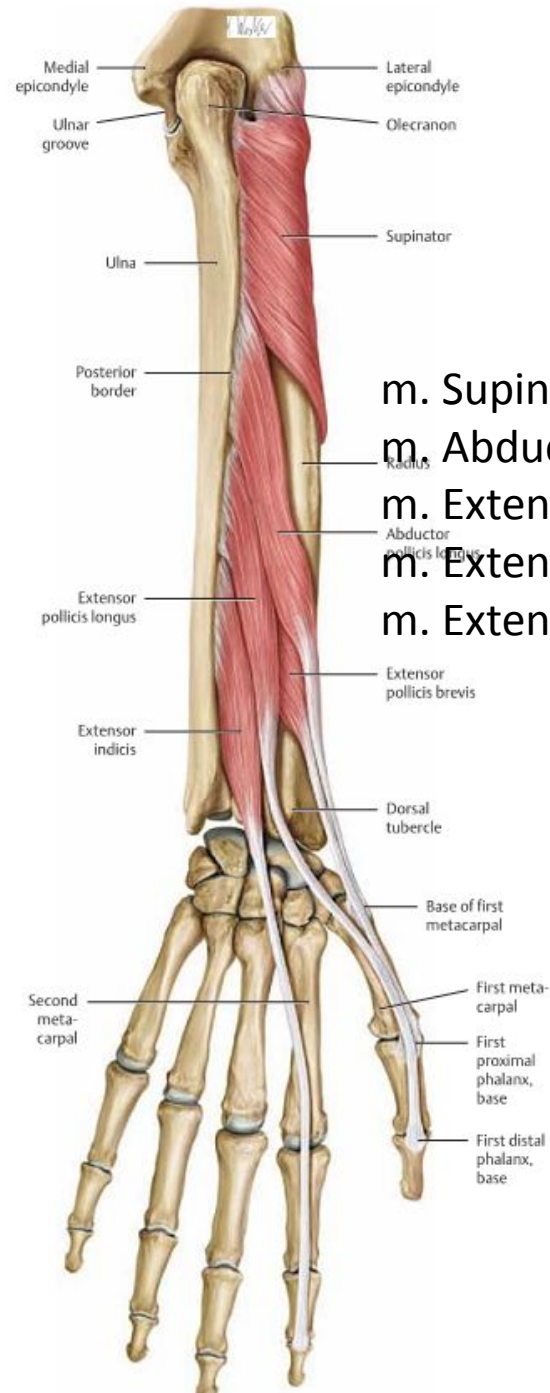
A Schematic of the superficial extensors



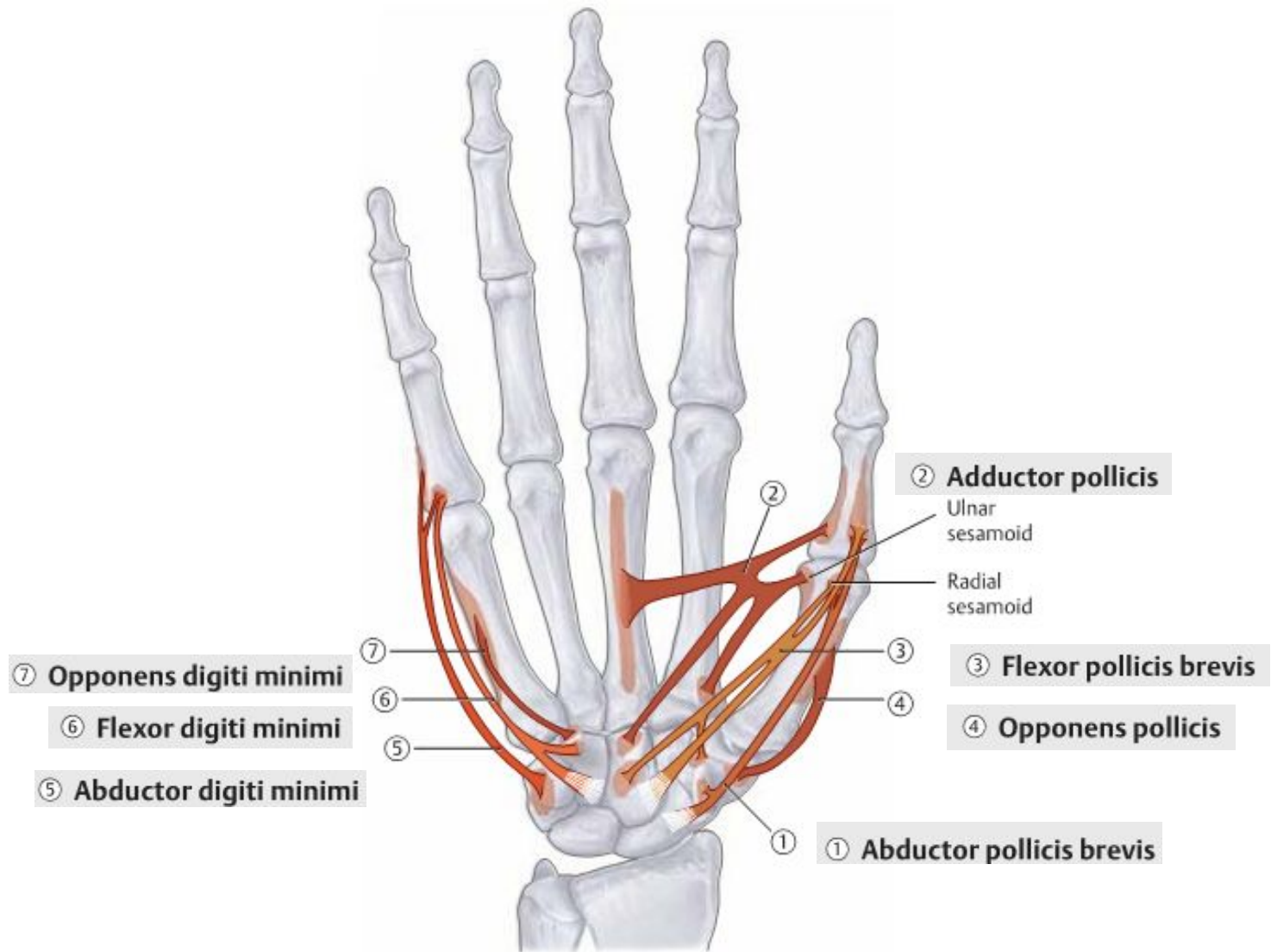
B Schematic of the deep extensors



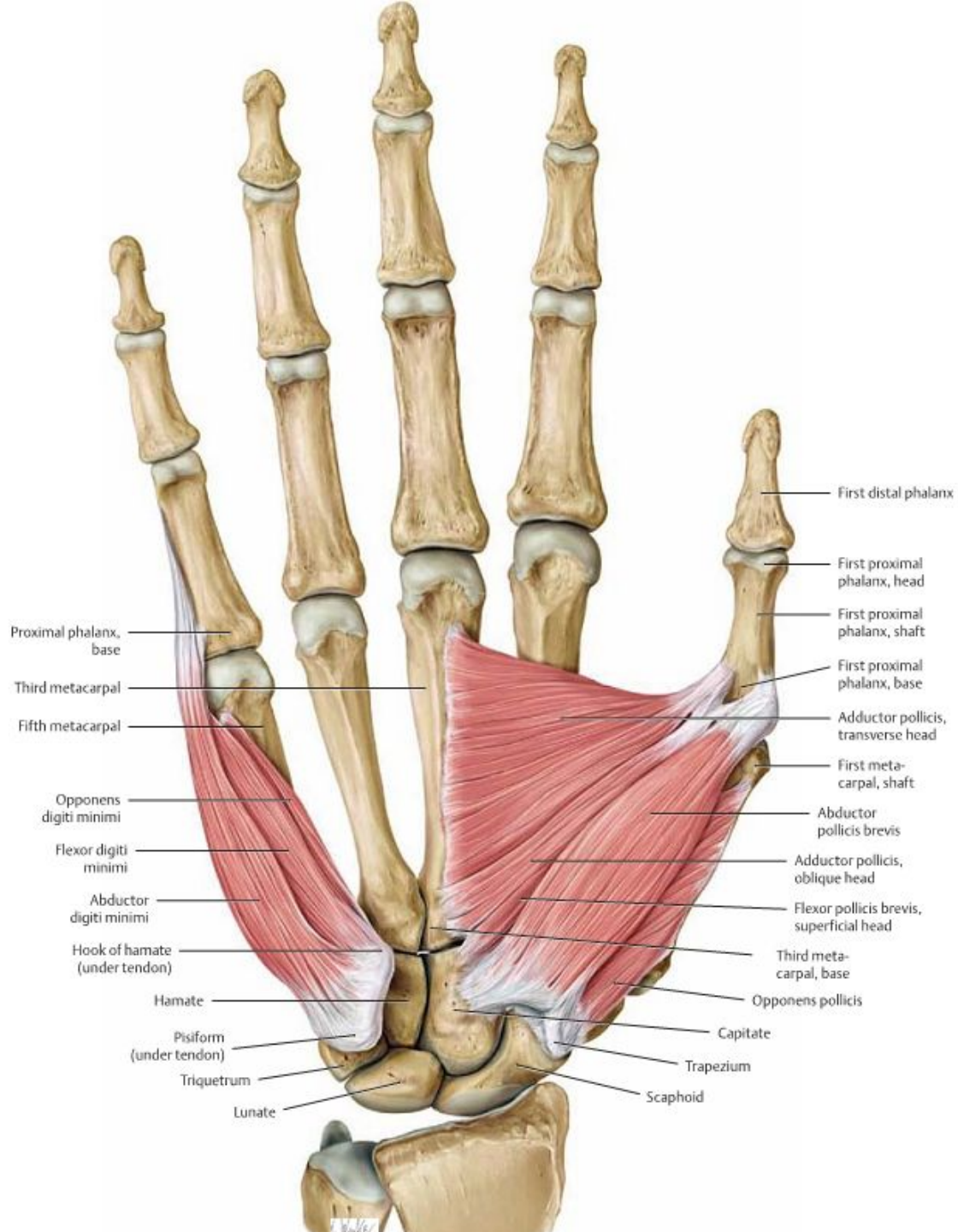
m. Extensor digitorum
 m. Extensor carpi ulnaris
 m. Extensor digiti minimi

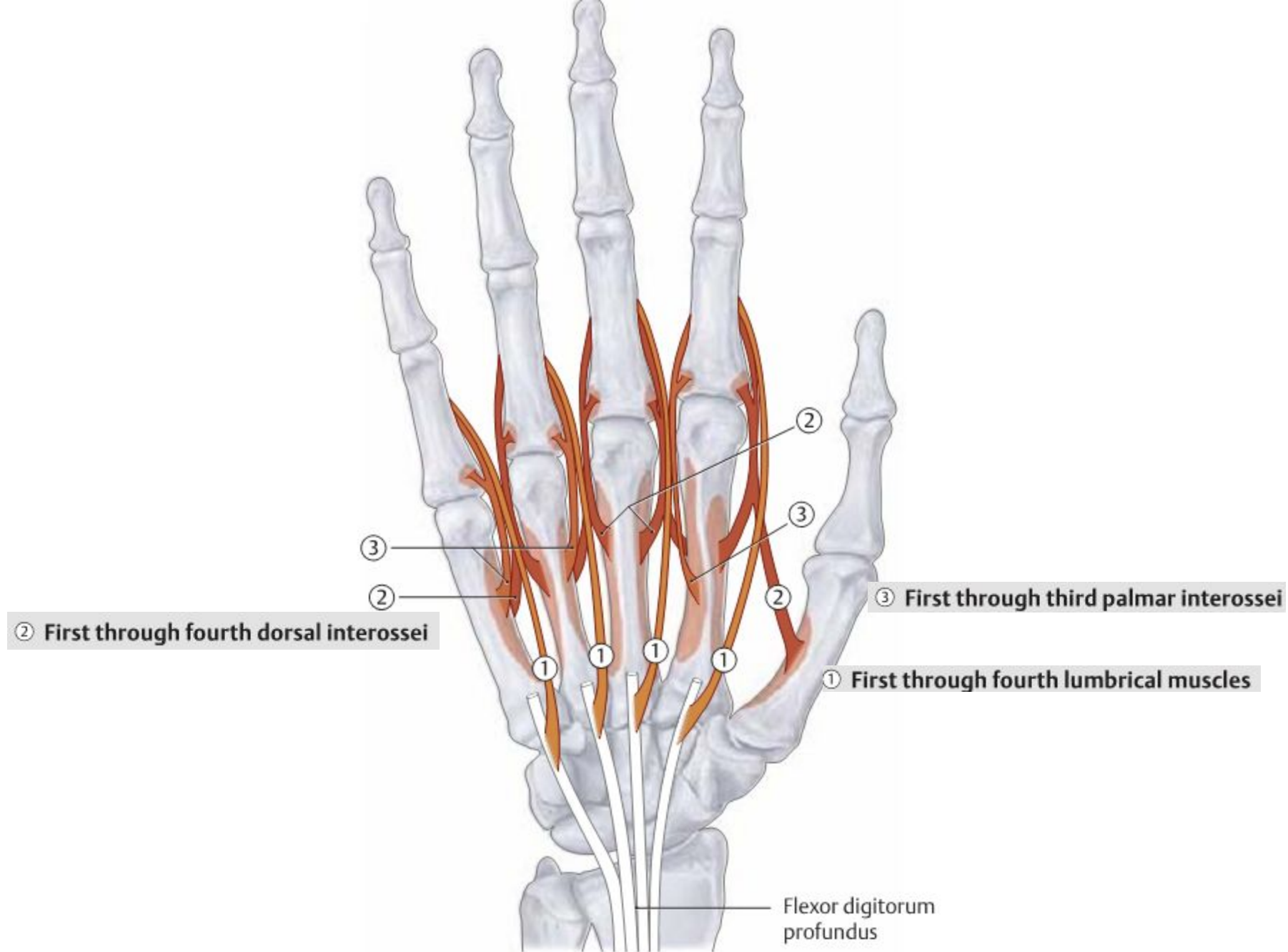


m. Supinator
 m. Abductor pollicis longus
 m. Extensor pollicis longus
 m. Extensor pollicis brevis
 m. Extensor indicis

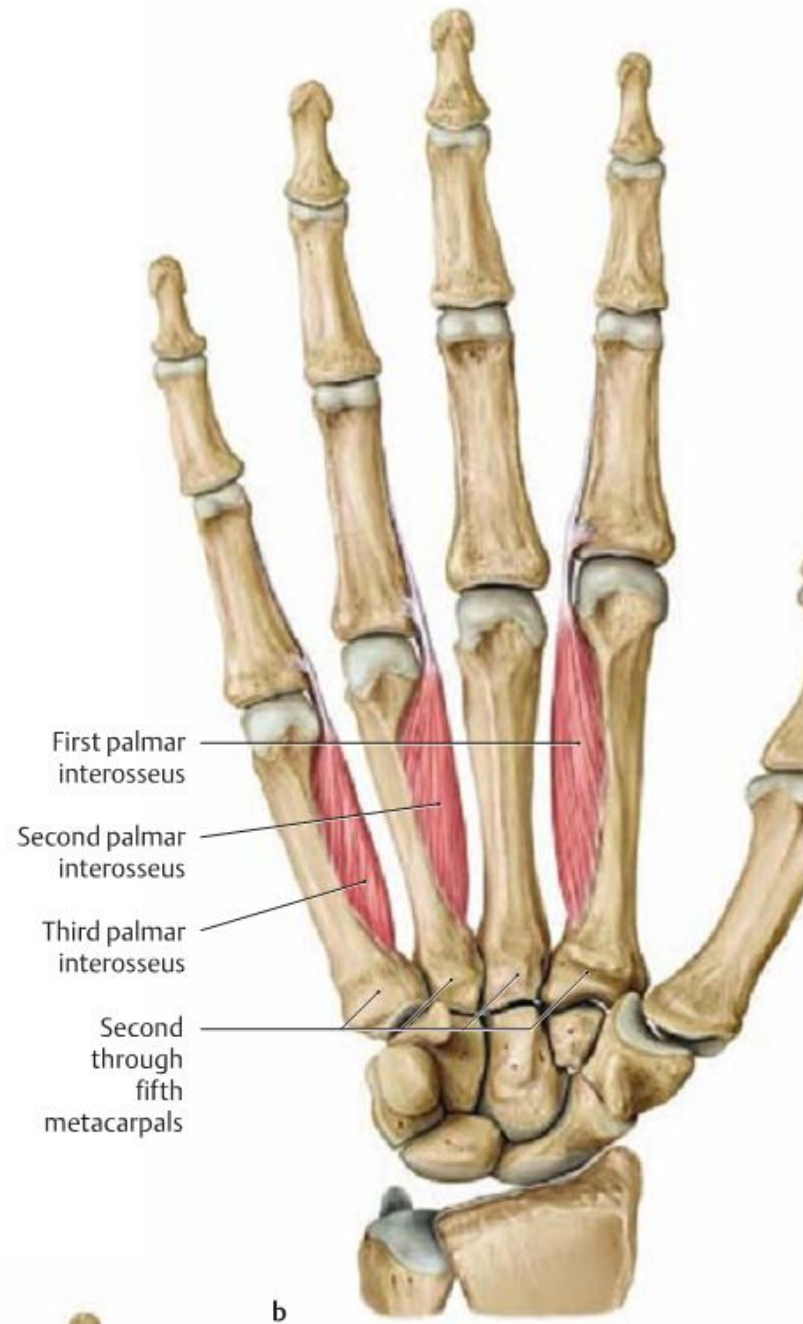
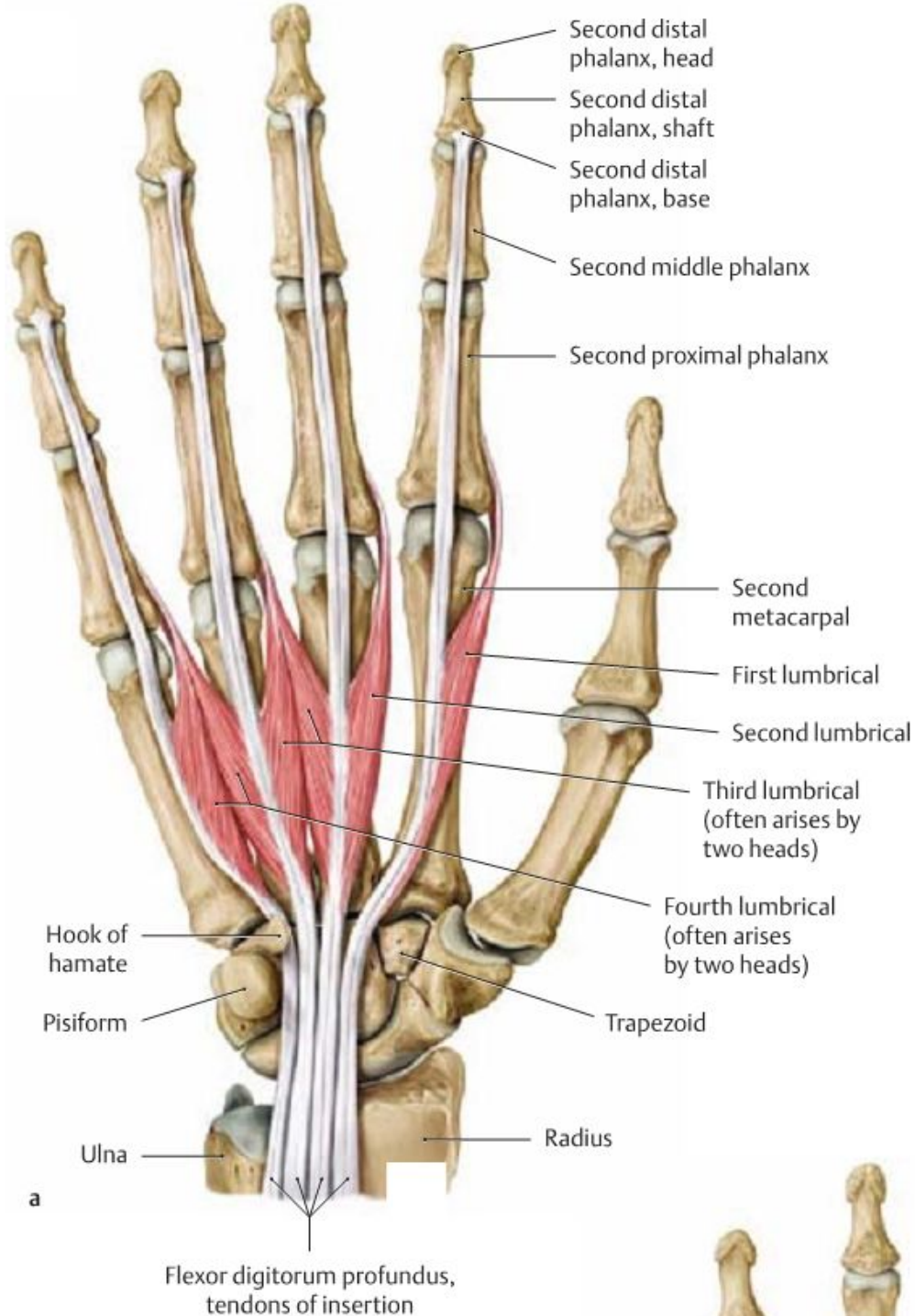


A Schematic of the thenar (①–④) and hypothenar muscles (⑤–⑦)





A Schematic of the metacarpal muscles



profundus,
sertion

