

Astana medical university

Department of children's surgery

*

Appendicitis in children
Mistakes of diagnostics

Performed Baisyn B
Checked Asem Zh

Plan

Contents

- 1 Definition
- 2 Pathophysiology
- 3 Clinical Features
- 4 Diagnosis
- 5 Differential Diagnosis
- 6 Treatment

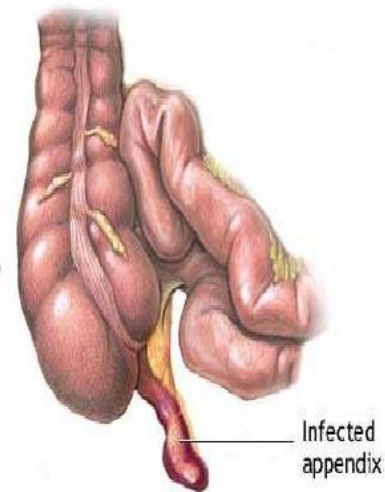
Introduction

- * Appendicitis represents one of the most common causes of abdominal pain of children patients referred to the emergency department. More than 250,000 cases of appendicitis are diagnosed in the United States each year, and appendectomy is the most frequent emergent surgery performed worldwide [1,2]. Despite its prevalence, the diagnosis of appendicitis can be elusive and fraught with pitfalls because of the absence of a pathognomonic sign or symptom, the poor predictive value of associated laboratory testing, and its varied presentation diagnosis [3-5].

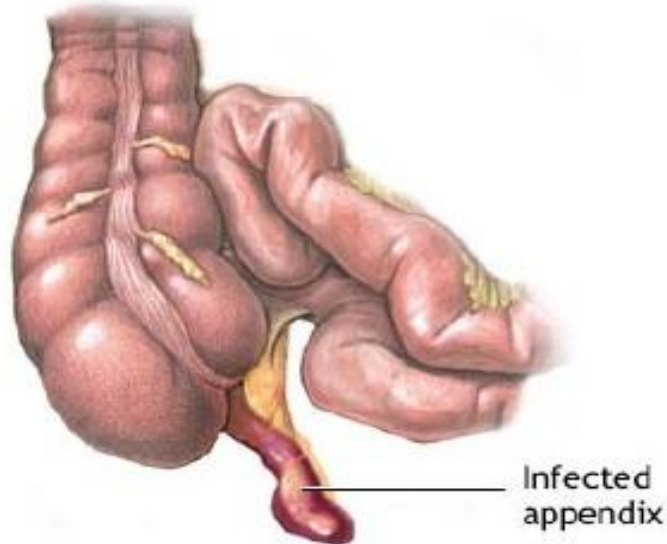
Appendicitis

**INFLAMMATION OF
APPENDIX IS
APPENDICITIS**

**Generally Caused by
an obstruction:
Faecalith. Lymphoid
obstruction, Infection.**



Surgical Anatomy



- The appendix is attached at the point of convergence of the three taeniae coli of the caecum on its posteromedial wall
- The meso-appendix is a peritoneal fold containing fat & appendicular artery
- Commonly behind the caecum (Retrocaecal)
- On psoas muscle at or below pelvic brim (Pelvic)
- Rarely : Pre-ileal – Post-ileal – Paracaecal
- Length less than 1 to greater than 30cm (most are 6-9 cm in length)
- After age of 60 no lymphoid tissue remains

Alvarado Score

- Abdominal pain that migrates to the right iliac fossa
- Anorexia (loss of appetite) or ketones in the urine
- Nausea or vomiting
- Pain on pressure in the right iliac fossa
- Rebound tenderness
- Fever of 37.3 °C or more
- Leukocytosis, or more than 10000 white blood cells per microliter in the serum
- Neutrophilia, or an increase in the percentage of neutrophils in the serum white blood cell count

RIF pain and leucocytosis score 2 points each

0-3: Sensitivity no AA 96% -> Discharge


4-6: Sensitivity of AA 36% -> Imaging

>7: Sensitivity of AA 78% -> +/- theatre

[11]

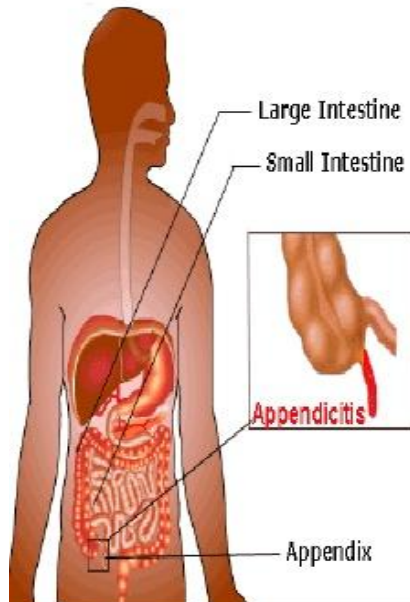
Positions

POSITIONS OF APPENDIX



Pathophysiology

Surgical Anatomy



Predisposing factors :

1- Obstructive agents

2- Infective agents

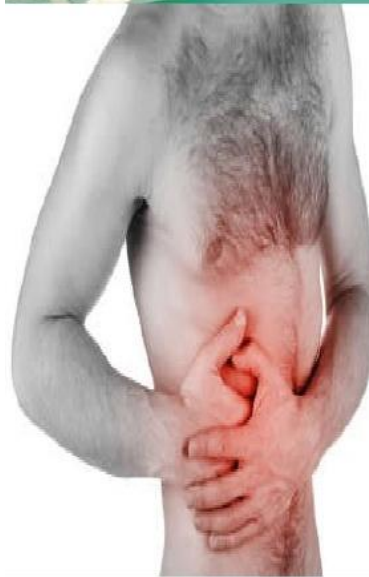Obstructive agents

Foreign bodies :

- **animal** (e.g. thread worms ,round worms) ,
- **vegetables** (e.g. seeds , date stones)
- **mineral** (faecalith = common cause)
- **submucous lymphoid tissue hyperplasia** leads to obstruction

Aetiology

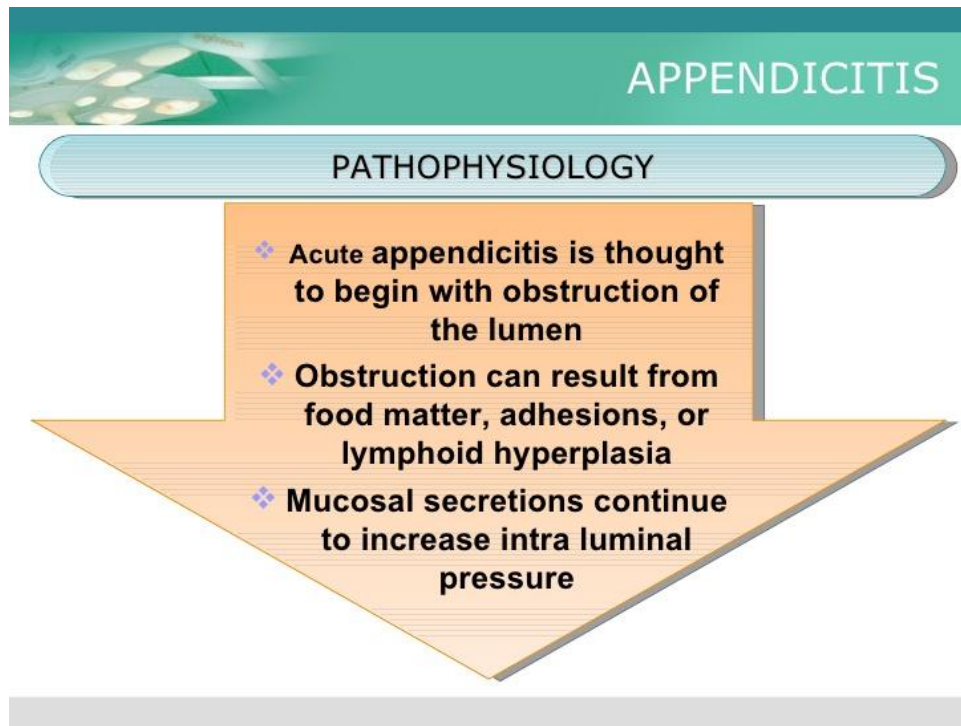
Causes



Infective agents :

- **Primary infection** leading to lymphoid hyperplasia
- **Secondary infection** caused by pressure of an obstructed agent leads to epithelial erosion and bacteria gain access to the wall
- **Both aerobic & anaerobic organisms** are involved including (coliforms , enterococci , bacteroids & other intestinal commensals)

Pathophysiology





pathophysiology

APPENDICITIS

PATHOPHYSIOLOGY

- ❖ **Eventually the pressure exceeds capillary perfusion pressure and venous and lymphatic drainage are obstructed.**
- ❖ **With vascular compromise, epithelial mucosa breaks down and bacterial invasion by bowel flora occurs.**

Pathophysiology

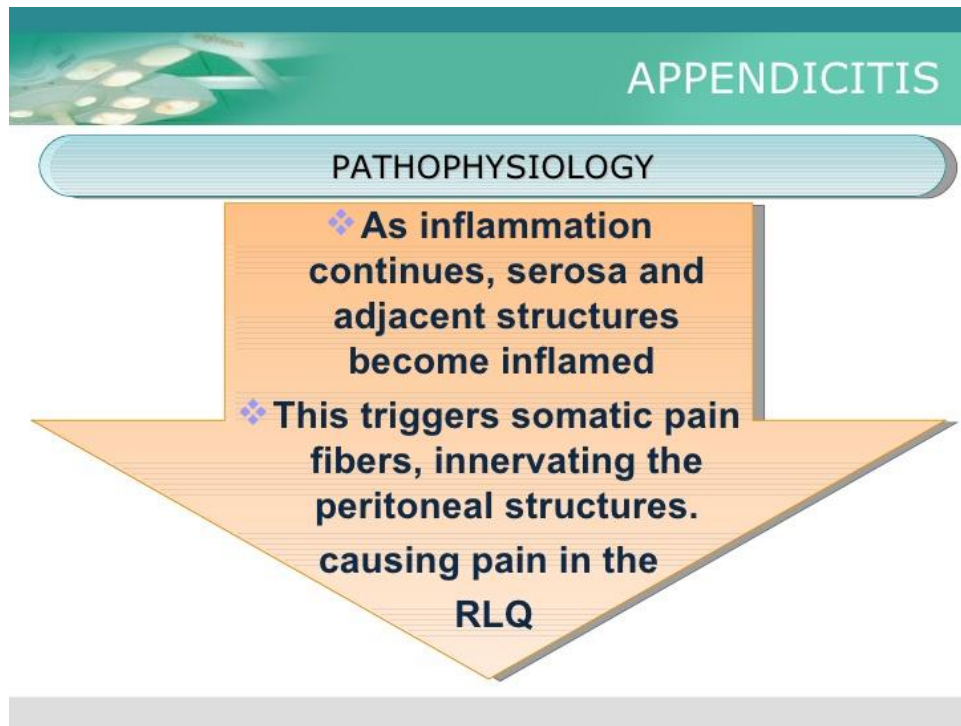


APPENDICITIS

PATHOPHYSIOLOGY

- ❖ **Increased pressure also leads to arterial stasis and tissue infarction**
- ❖ **End result is perforation and spillage of infected appendiceal contents into the peritoneum**

Pathophysiology



pathophysiology

APPENDICITIS

PATHOPHYSIOLOGY

- ❖ **As inflammation continues, serosa and adjacent structures become inflamed**
- ❖ **This triggers somatic pain fibers, innervating the peritoneal structures. causing pain in the RLQ**

pathophysiology

APPENDICITIS

PATHOPHYSIOLOGY

The change in stimulation form visceral to somatic pain fibers explains the classic migration of pain in the peri-umbilical area to the RLQ seen with acute appendicitis.

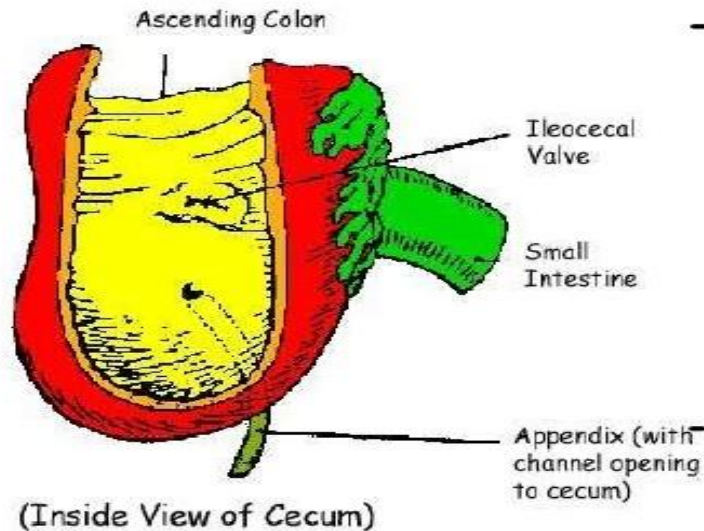
pathophysiology

APPENDICITIS

PATHOPHYSIOLOGY

- ❖ **Exceptions exist in the classic presentation due to anatomic variability of the appendix**
- ❖ **Appendix can be retrocecal causing the pain to localize to the right flank**
- ❖ **In pregnancy, the appendix can be shifted and patients can present with RUQ pain**

Acute appendicitis with peritonitis



- Free perforation following obstruction + infection allows infected material to disperse widely in peritoneal cavity lead to intense peritoneal reaction with outpouring of fluid

Serosal surfaces of bowel become injected flaked with clotted lymph

Clinical Features

1

Abdominal pain periumbilical at first , then to right iliac fossa within a few hours it becomes persistent . Onset is usually sudden , may arise in right iliac fossa and remains there

2

Retrocaecal appendix may cause flank or back pain
Pelvic appendix may cause suprapubic pain

3

Anorexia nearly always accompanies appendicitis
Vomiting occurs in about 75% of patients
(most vomit once or twice)

Clinical Features

4

Most patients give history of constipation before onset of pain , diarrhea in some particularly children

5

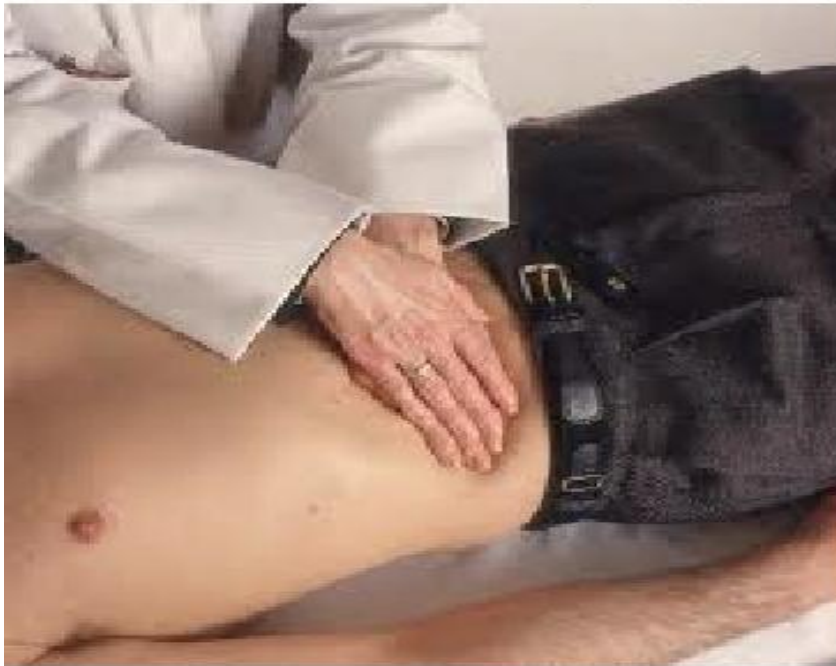Fever
Low grade
Around 100 degree F
Oc. Haematuria

6

Murphy's Triad
Pain
Vomiting
Fever

CLINICAL FEATURES

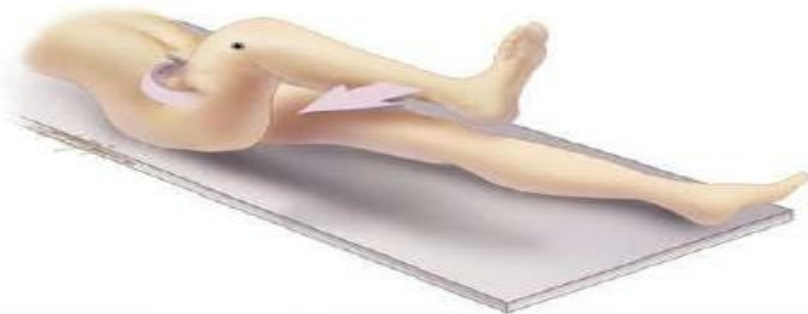ROVSING'S SIGN



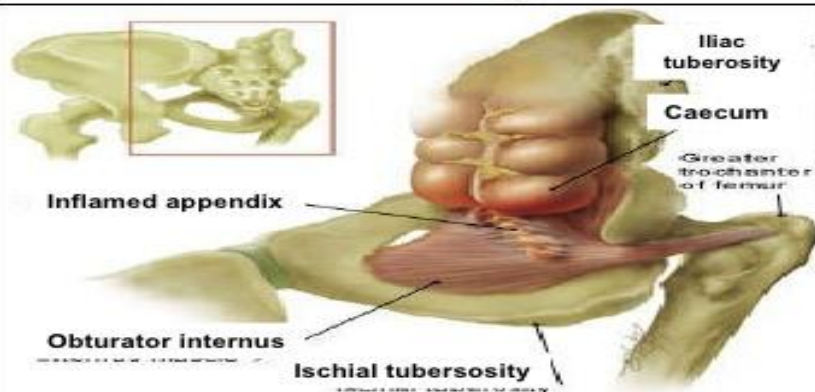
Continuous deep palpation starting from the left iliac fossa upwards (anti clockwise along the colon) may cause pain in the right iliac fossa, by pushing bowel contents towards the ileocaecal valve and thus increasing pressure around the appendix. This is the Rovsing's sign.

CLINICAL FEATURES

OBTURATOR'S SIGN



The obturator sign. Pain on passive internal rotation of the flexed thigh. Examiner moves lower leg laterally while applying resistance to the lateral side of the knee (asterisk) resulting in internal rotation of the femur..



Differential Diagnosis

Eterocolitis
Ileo caecal TB
Ca Caecum
Perforated P.U.
Empyema GB
Crohn's disease
Rt Lobar Pneumonia
Worm Ball



Pancreatitis
Liver and GB inflamm.
Renal Mass
Ovarian cyst
Fibroid uterus
Ureteric calculus
Ectopic gestation
Oophoritis



Differential Diagnosis

CHILD

Gastroenteritis, Mesenteric adenitis, Meckel's diverticulum, Intussusception

ADULT

Regional enteritis, Ureteric Colic, Perforated P.U., Torsion of Testis, Pancreatitis

FEMALE

Pelvic Inflammatory Diseases, Pyelonephritis, Ectopic Pregnancy, Ovarian Cyst, Endometriosis, uterine fibroids.

OLD

Diverticulitis, intestinal obstruction, carcinoma colon etc.

Treatment

Open Appendicectomy

- ❑ Transverse incision
 - ❑ Protect wound
 - ❑ Swab out pelvis
 - ❑ Muscle cutting laparotomy in presence of peritonitis
-

Laparoscopic Appendicectomy

- Most recent prospective RCT had a mean operation time of 44min in laparoscopic perforated appendicectomy[39]
- Evidence heavily in favour of LA

39 / St Peter S.D., Tsao K., Spilde T.L., et al: Single daily dosing ceftriaxone and metronidazole vs. standard triple antibiotic regimen for perforated appendicitis in children: A prospective randomized trial. *J Pediatr Surg* 2008; 43:981-985.

Laparoscopic Appendicectomy

- ❑ Substantially lower complication rate in obese patients[37]
- ❑ Shorter duration of hospital stay[36]
- ❑ Earlier return to work and normal activity[36]
- ❑ Prospective RCT quality of life, GIT complication and overall complications lower for laparoscopy (N=43757)[38]
- ❑ Recent Cochrane review: LA 1^o operation[36]

36 / Sauerland S., Lefering R., Neugebauer E.A.: Laparoscopic versus open surgery for suspected appendicitis.

Cochrane Database Syst Rev 2004; 18:CD001546

37 / Cornelle M.G., Steigelman M.B., Myers J.G., et al:

Laparoscopic appendectomy is superior to open appendectomy in obese patients. *Am J Surg* 2007; 194:877-880.

38 / Guller U., Hervey S., Purves H., et al:

Laparoscopic versus open appendectomy: Outcomes comparison based on a large administrative database.

Ann Surg 2004; 239:43-52.

Laparoscopic Appendectomy

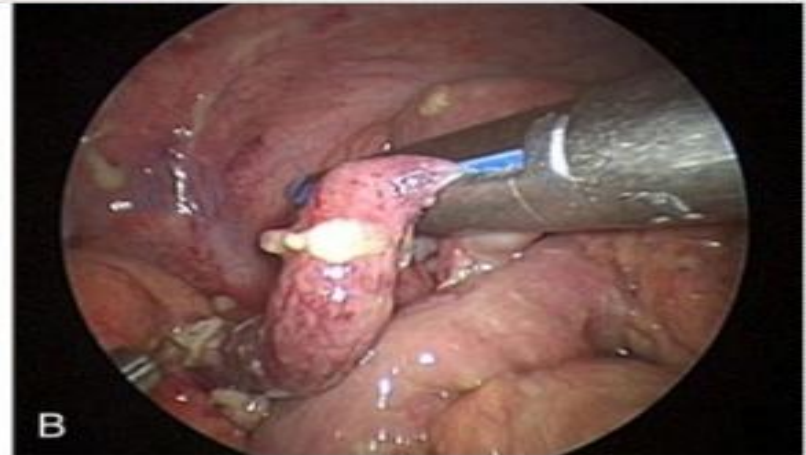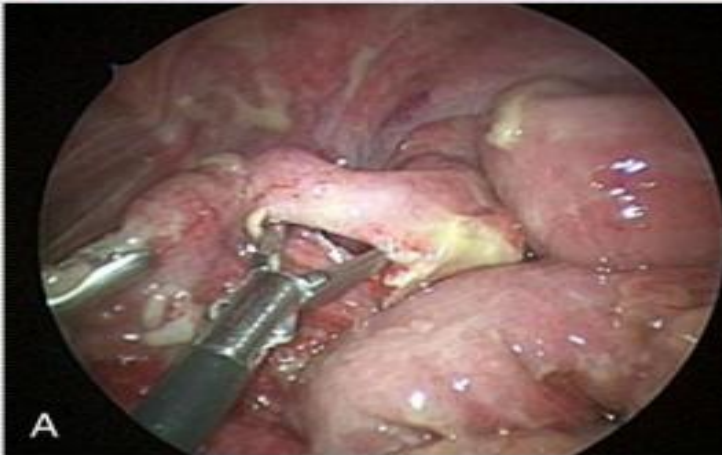- Umbilical port and two working ports (open)
- Initial data, longer operative time and more intra-abdominal complications in LA[34]
- Newer evidence suggests no difference in operative time and IAA in the 2 groups[35]
- Risk of abscess formation justification for continued use of open surgery
- Substantially lower risk of wound infection[36]

34 / Horwitz J.R., Custer M.D., May B.H., et al:
Should laparoscopic appendectomy be avoided for complicated appendicitis in children?. *J Pediatr Surg* 1997; 32:1601-1603.

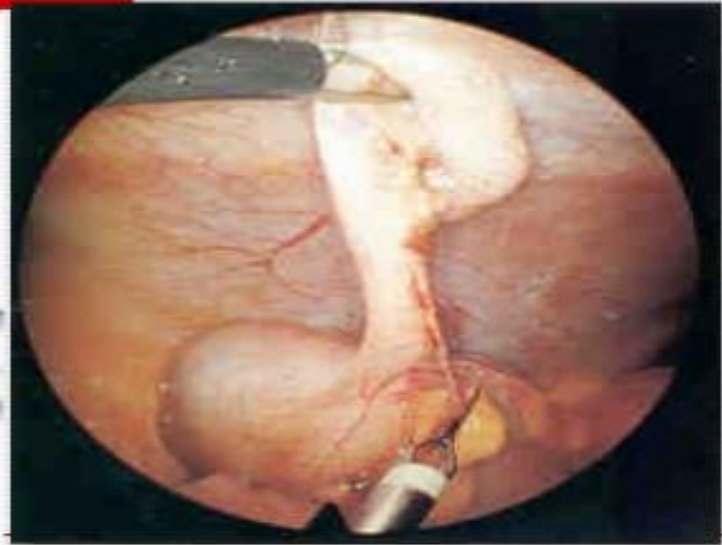
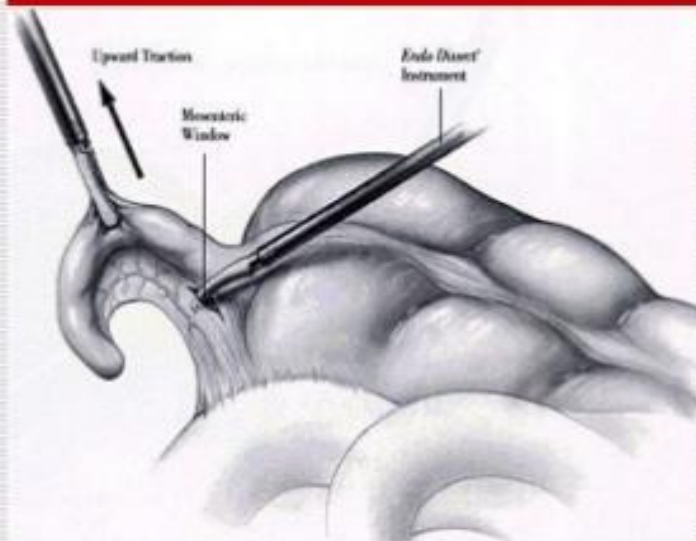
35 / Aziz O., Athanasiou T., Tekkis P.P., et al:
Laparoscopic versus open appendectomy in children: A meta-analysis. *Ann Surg* 2006; 243:17-27.

36 / Sauerland S., Lefering R., Neugebauer E.A.: Laparoscopic versus open surgery for suspected appendicitis. *Cochrane Database Syst Rev* 2004; 18:CD001546

Laparoscopic Appendicectomy



Laparoscopic Appendectomy



Conclusions

- * Imaging is necessary in adult patients referred with clinically suspected acute appendicitis: in fact, there is wide agreement that the outcome of acute appendicitis is best with early diagnosis. Graded-compression US remains our first-line method in the evaluation of patients referred with clinically suspected acute appendicitis. It can be performed at any time, regardless of specific patient's preparation. Nevertheless, due to variable diagnostic accuracy, individual skill is requested not only to perform a successful exam, but also to triage those equivocal cases that, subsequently, will have to undergo Computed Tomography assessment