


An anatomical illustration of the pancreas and its associated structures. The pancreas is shown as a yellow, elongated organ with a network of red blood vessels and a network of light-colored ducts. It is surrounded by a pinkish-red, textured background. The illustration is framed by a teal border with decorative elements. The word "Pancre" is written in large, bold, black letters across the center of the pancreas, and "cis" is written in smaller, bold, black letters below it.

Pancre

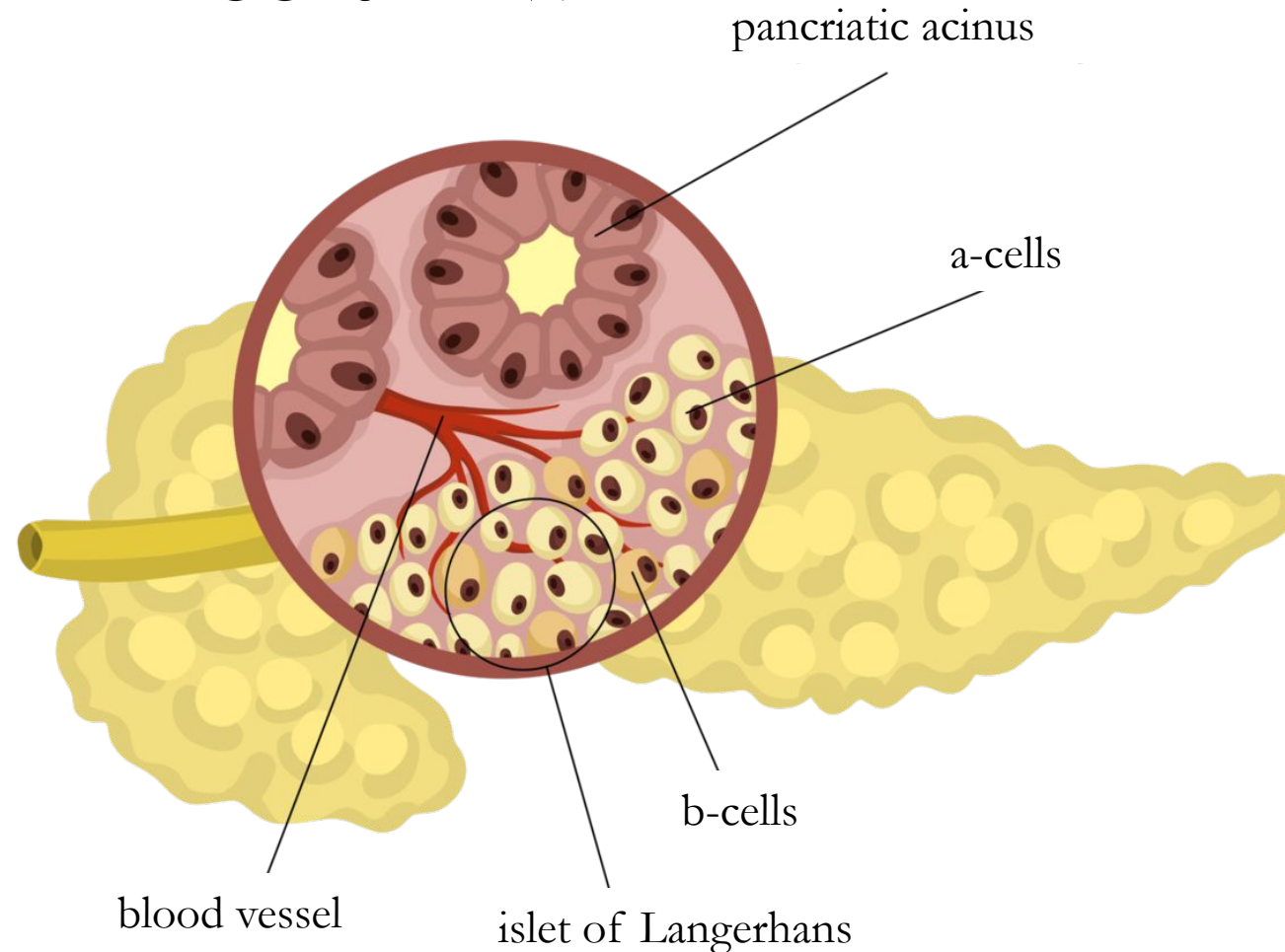
cis

- AN ORGAN OF THE DIGESTIVE SYSTEM WITH EXOCRINE AND ENDOCRINE SECRETORY FUNCTIONS.




EXOCRINE PART (97% OF THE MASS OF THE GLAND): PRODUCES PANCREATIC JUICE THAT ENTERS THE DUODENUM.

ENDOCRINE PART (3% OF THE MASS OF THE GLAND): ISLETS OF LANGERHANS, WHICH FORM THE HORMONES GLUCAGON AND INSULIN, WHICH ENTER THE BLOODSTREAM.



THE PANCREAS



GIVE ME SOME
SUGAR!

