СОННЫЕ АРТЕРИИ

Наружная сонная артерия

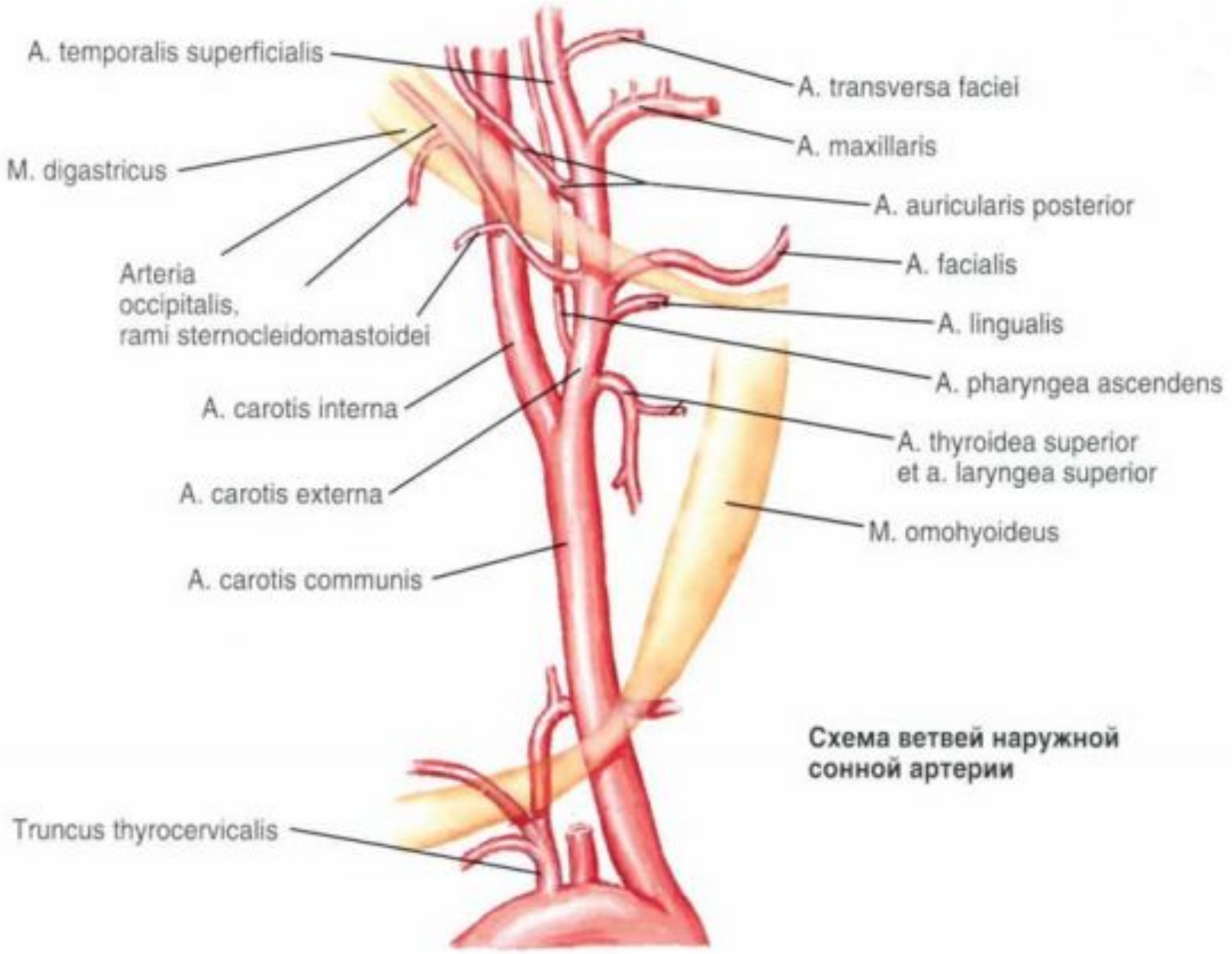

Схема ветвей наружной сонной артерии

Сонные артерии

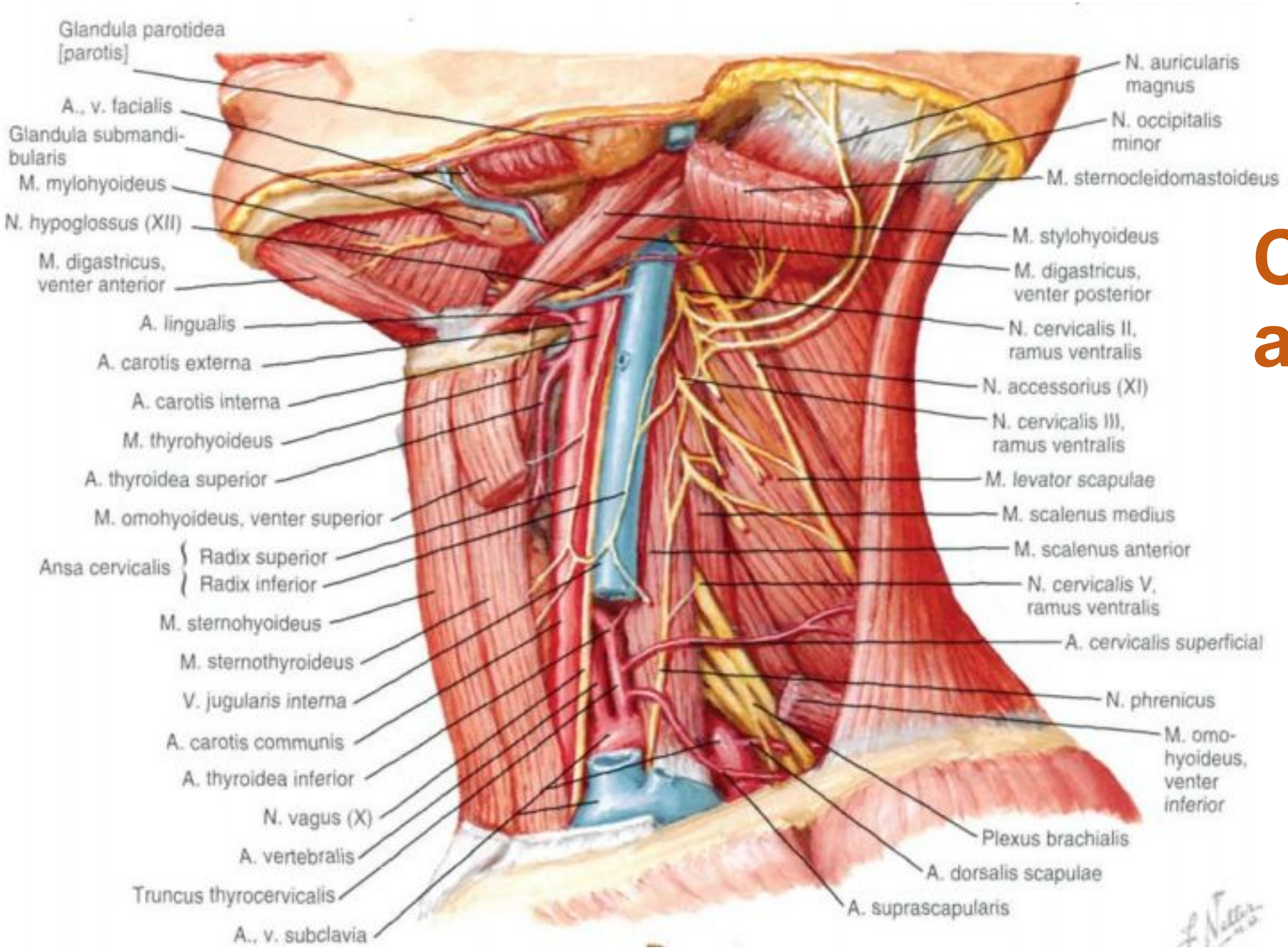

Сонные артерии

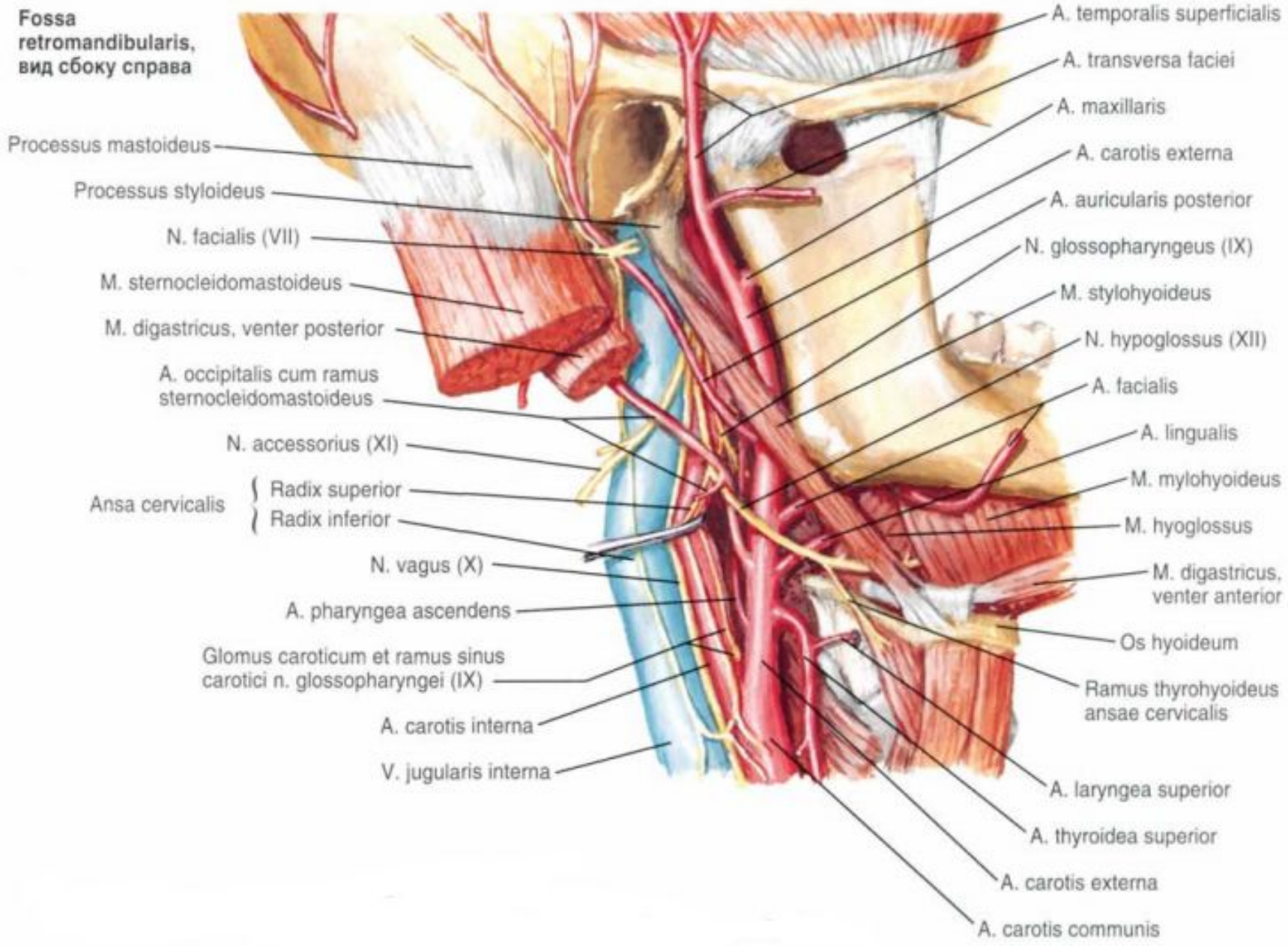

Наружная сонная артерия

A. facialis

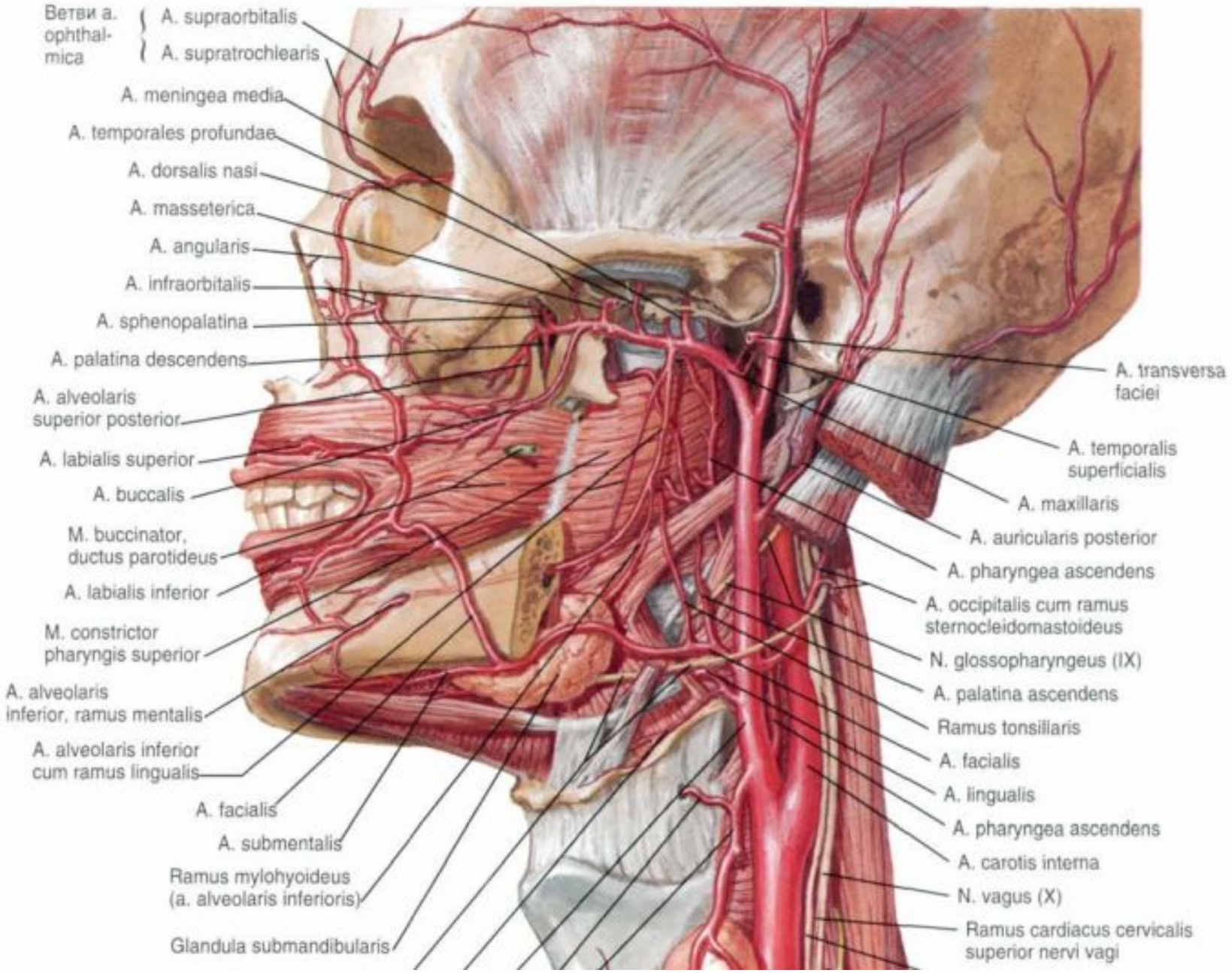

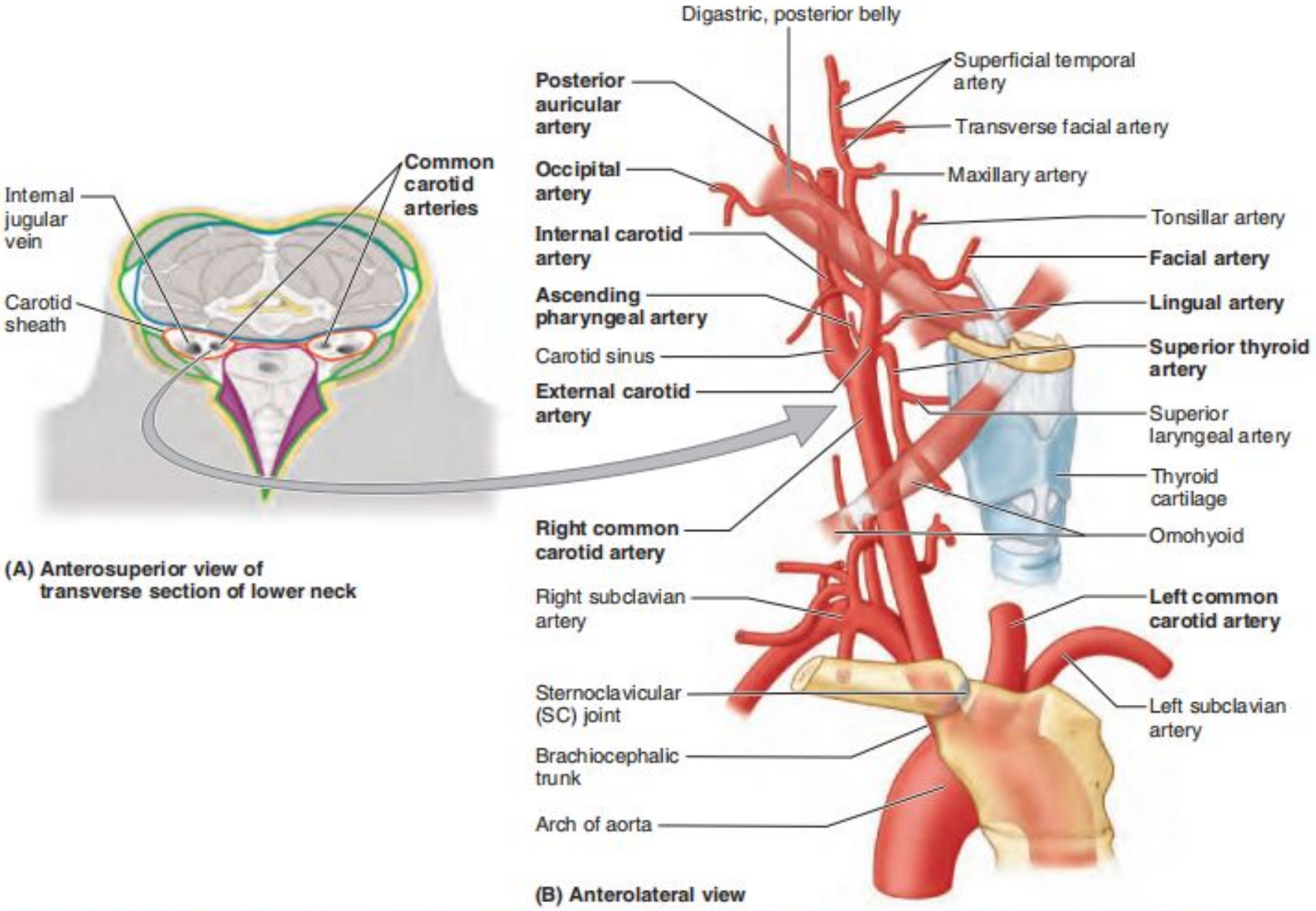

FIGURE 8.19. Subclavian and carotid arteries and their branches. A. The positions of the carotid sheaths are demonstrated. **B.** The muscles (posterior belly of the digastric and omohyoid muscles) indicate the superior and inferior boundaries of the carotid triangle.

Сонные артерии

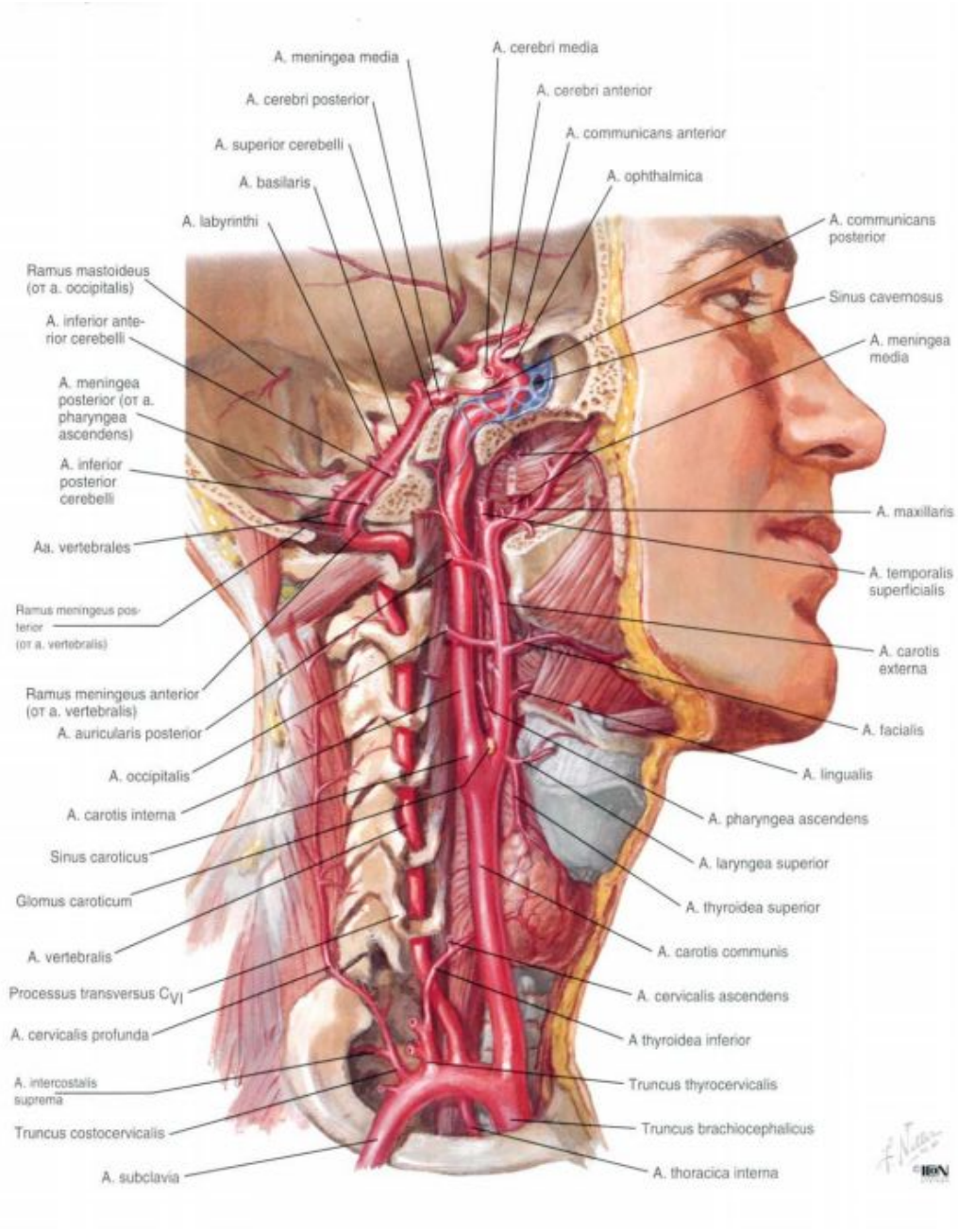

Общая сонная артерия

Подключичная артерия

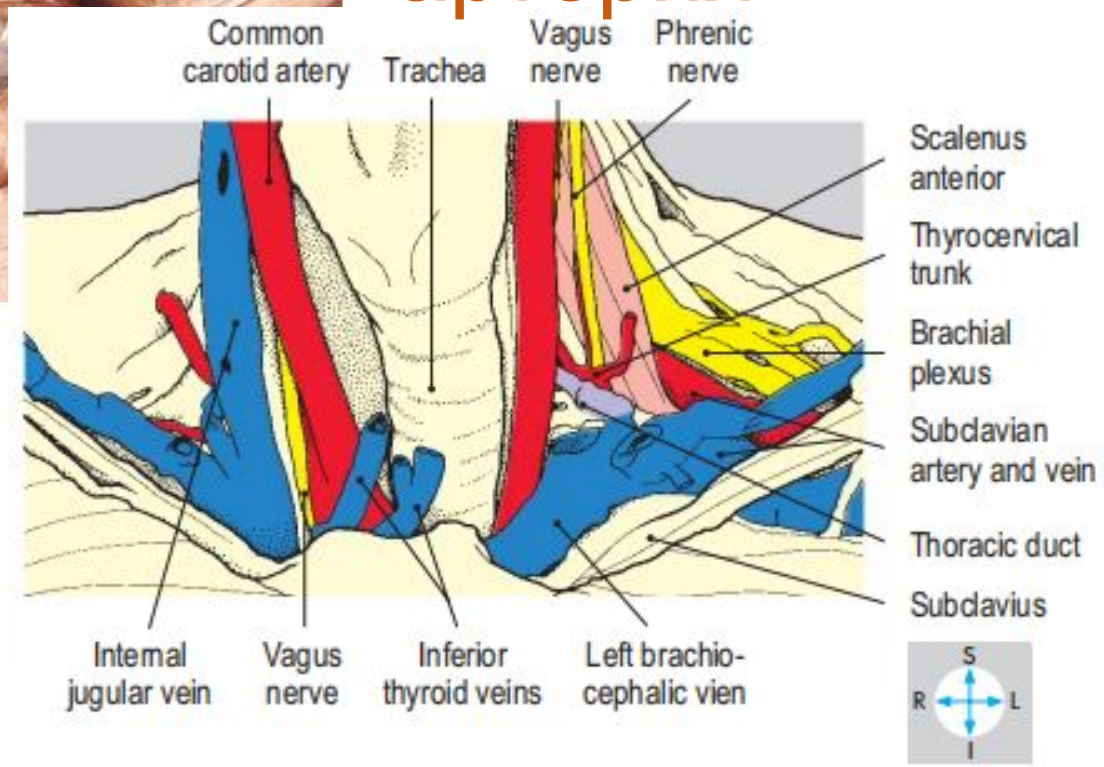

Верхние щитовидные артерии

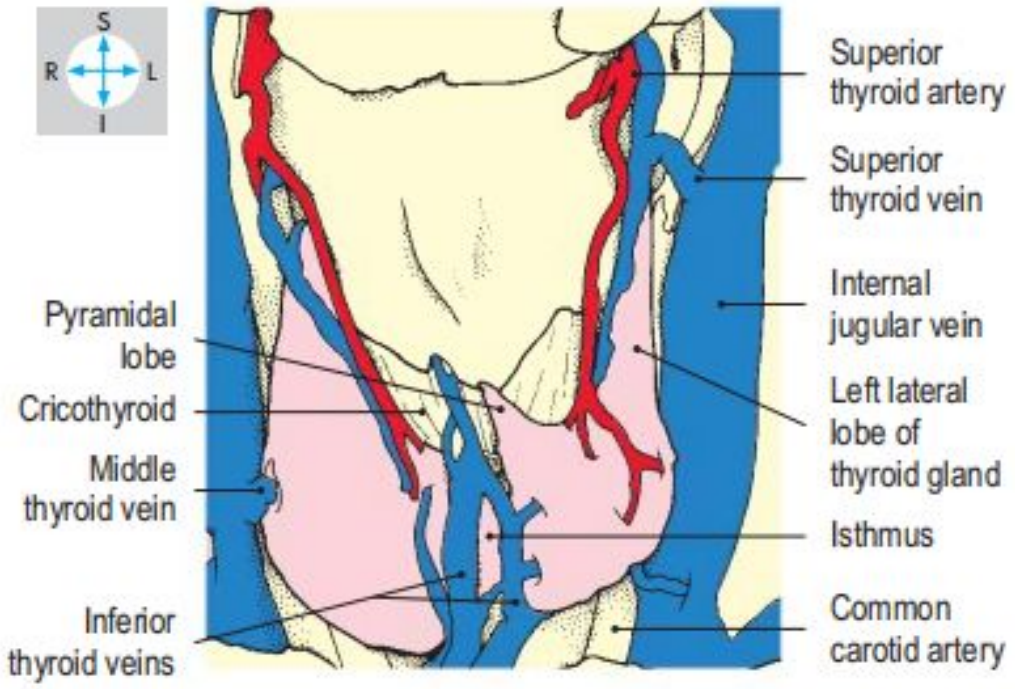

Fig. 7.13 Thyroid gland and its immediate blood supply, revealed by removal of the pretracheal fascia.

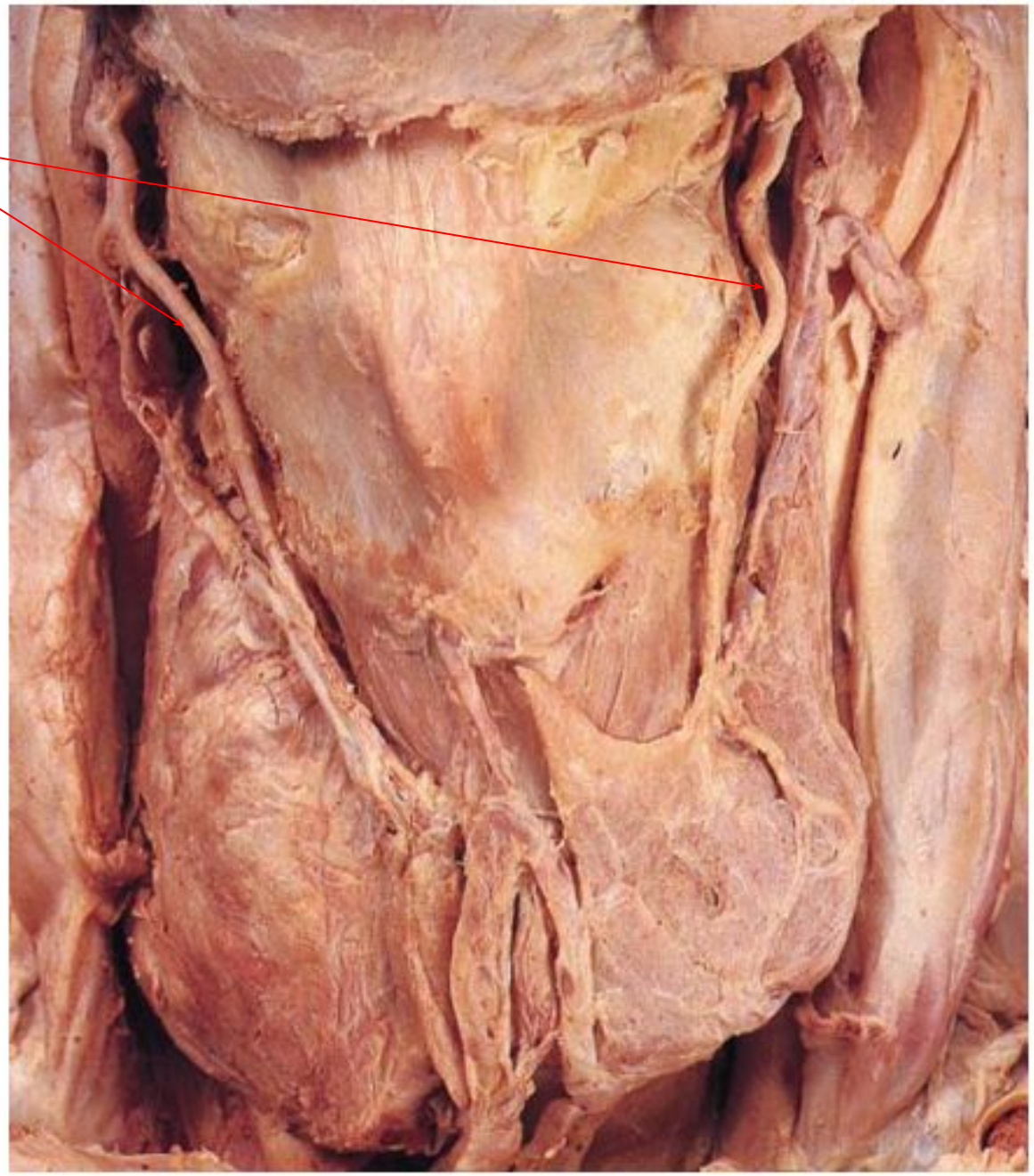

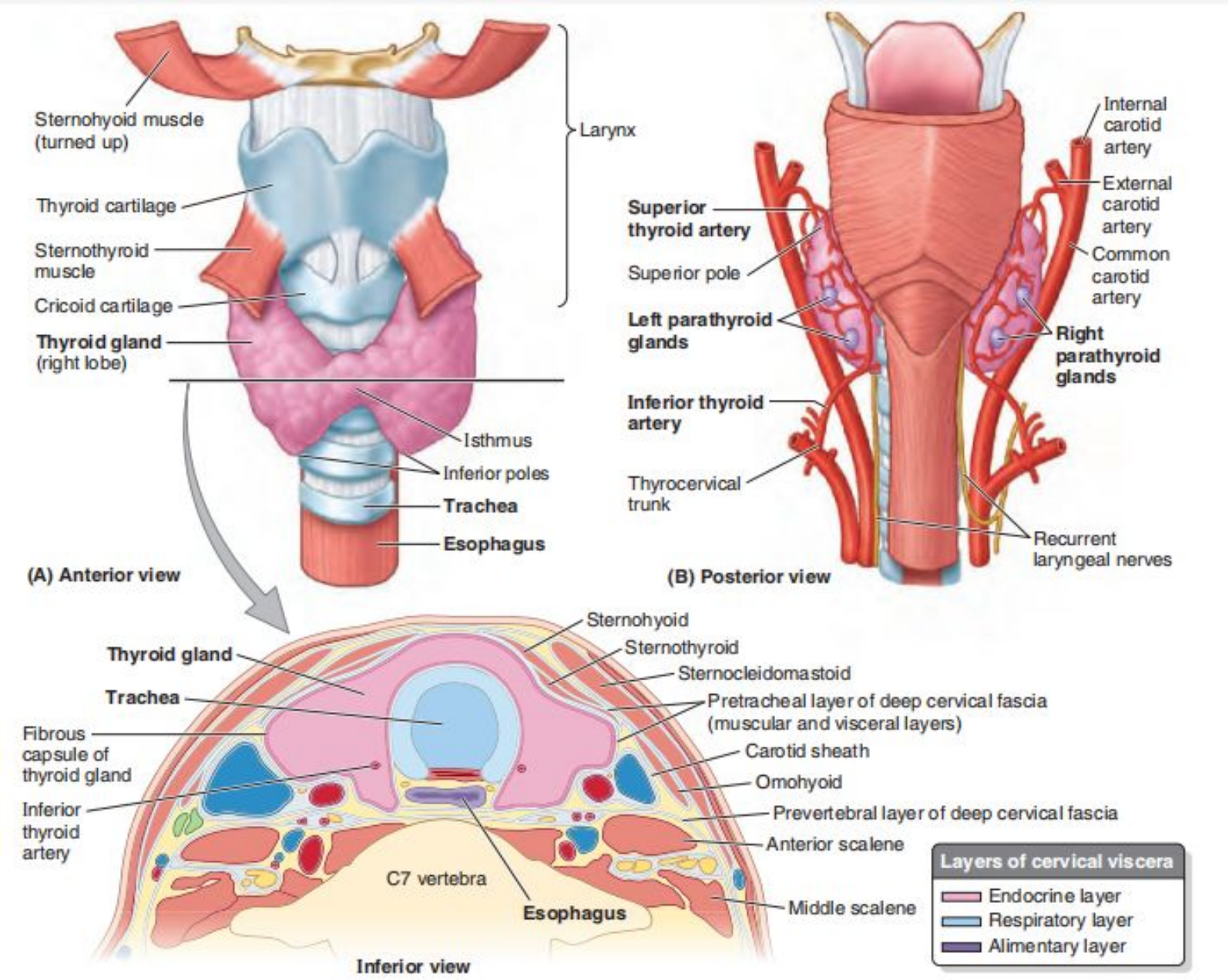
Sternohyoid muscle (turned up)
Thyroid cartilage
Sternothyroid muscle
Cricoid cartilage
Thyroid gland (right lobe)
Larynx
Isthmus
Inferior poles
Trachea
Esophagus
(A) Anterior view
Internal carotid artery
External carotid artery
Common carotid artery
Superior thyroid artery
Superior pole
Left parathyroid glands
Right parathyroid glands
Inferior thyroid artery
Thyrocervical trunk
Recurrent laryngeal nerves
(B) Posterior view
Sternohyoid
Sternothyroid
Sternocleidomastoid
Thyroid gland
Trachea
Pretracheal layer of deep cervical fascia (muscular and visceral layers)
Fibrous capsule of thyroid gland
Carotid sheath
Omohyoid
Inferior thyroid artery
Prevertebral layer of deep cervical fascia
Anterior scalene
C7 vertebra
Esophagus
Middle scalene
Inferior view
Layers of cervical viscera
Endocrine layer
Respiratory layer
Alimentary layer

Позвоночная артерия
Реберно-шейный ствол

Надлопаточная артерия
Внутренняя грудная артерия
Поперечная артерия шеи
Нижняя щитовидная артерия

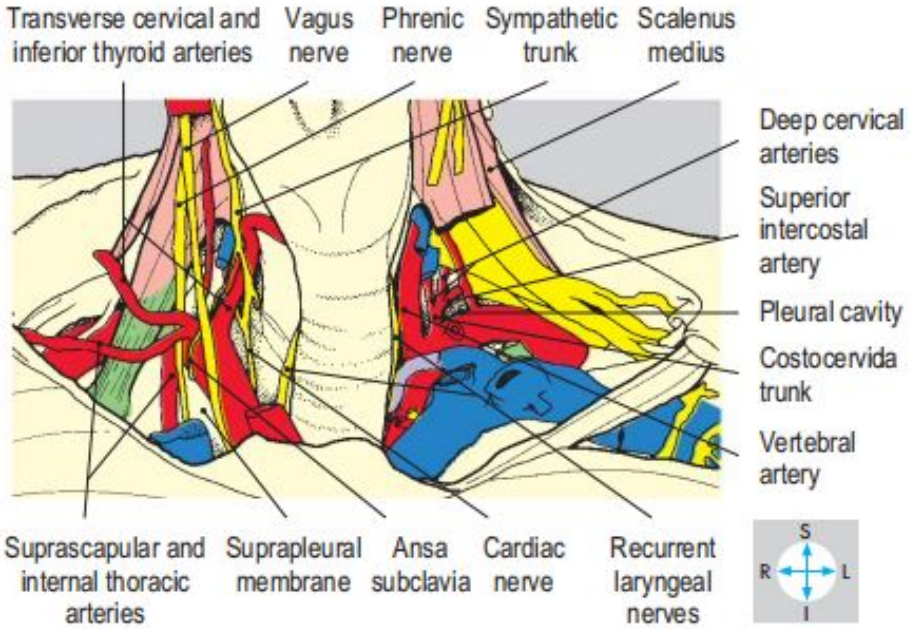

Fig. 7.15 Deeper structures of the root of neck, revealed by removal of most of the left vagus and phrenic nerves, the left scalenus anterior, both common carotid arteries and the large veins.

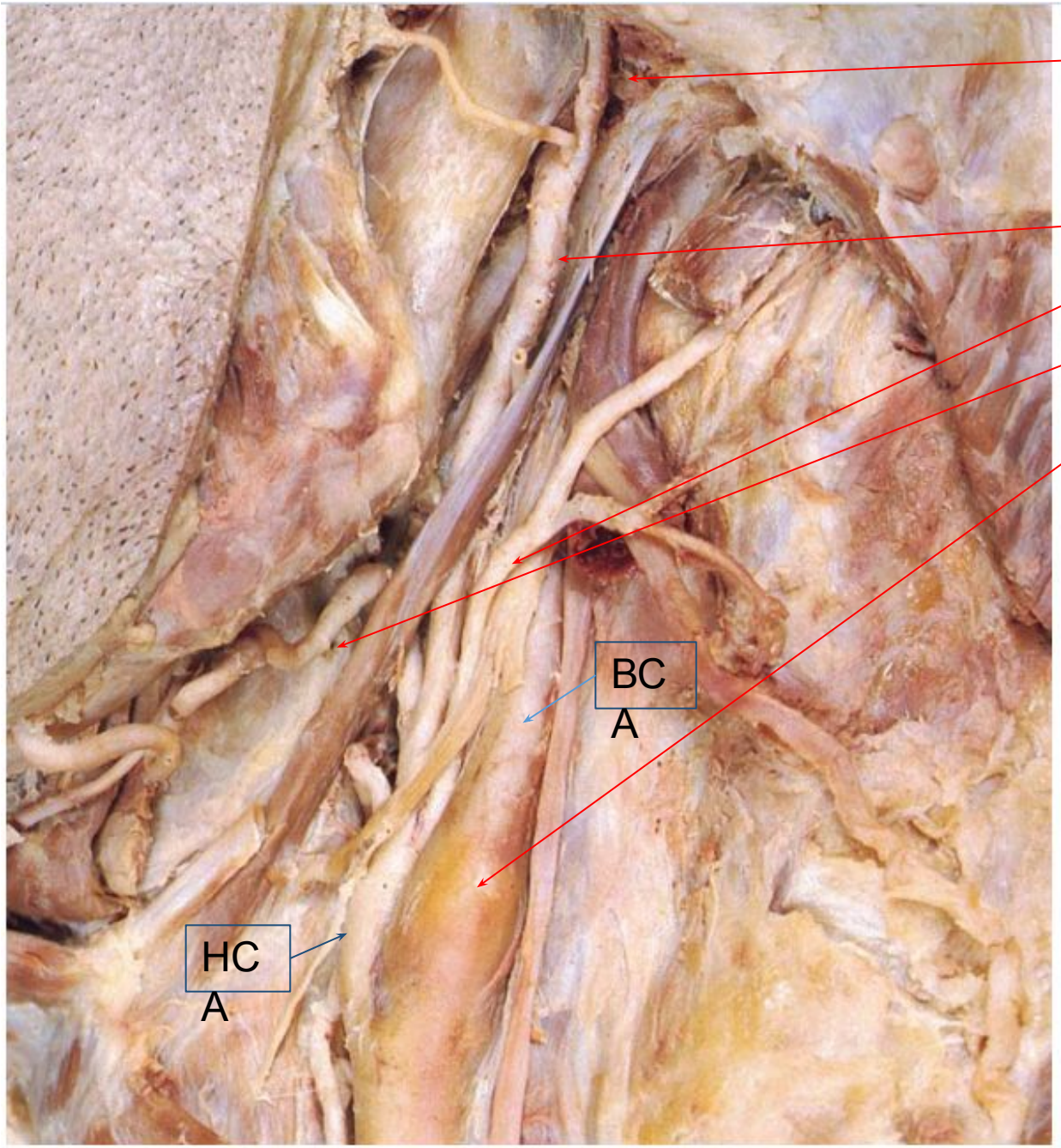

Поверхностная височная атерия
Наружная сонная артерия
Затылочная артерия
Лицевая артерия
Сонный синус

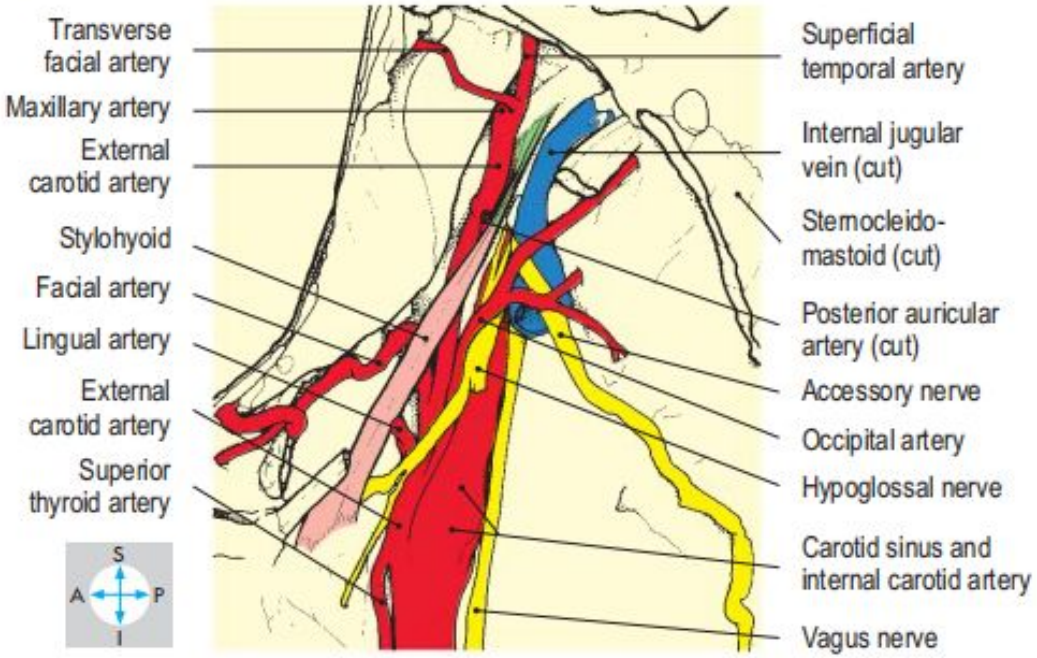

Fig. 7.17 Branches of the external carotid artery and the vagus, accessory and hypoglossal nerves, after removal of part of the internal jugular vein, carotid sheath and posterior belly of digastric.

Сонный синус

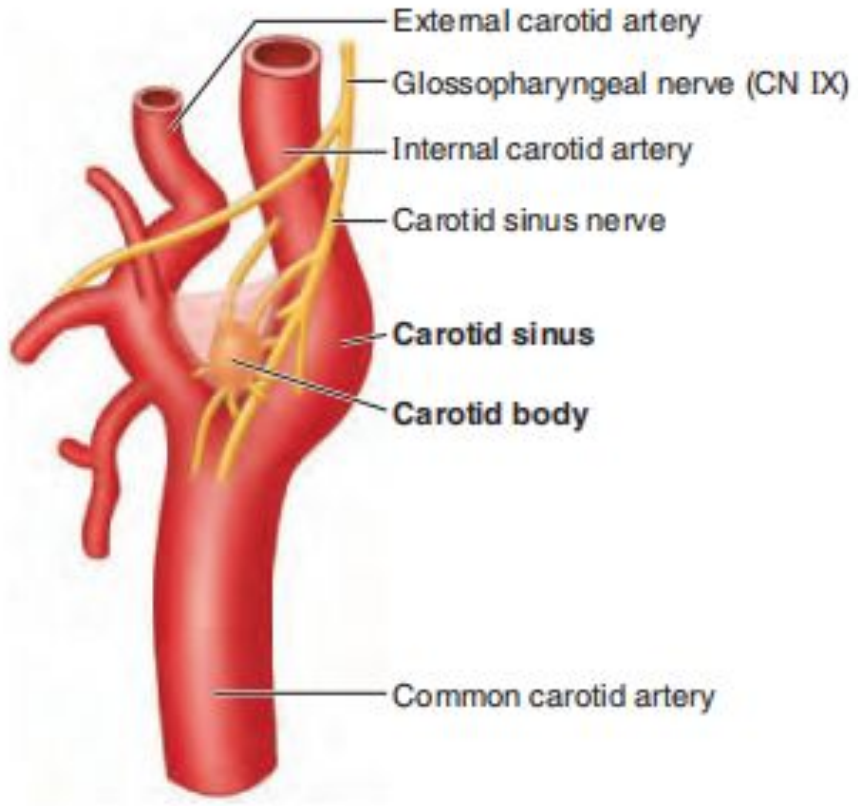

Medial view of right carotid artery

FIGURE 8.17. Carotid body and carotid sinus. This small epithelioid body lies within the bifurcation of the common carotid artery. The carotid sinus and the associated network of sensory fibers of the glossopharyngeal nerve (CN IX) are also shown.

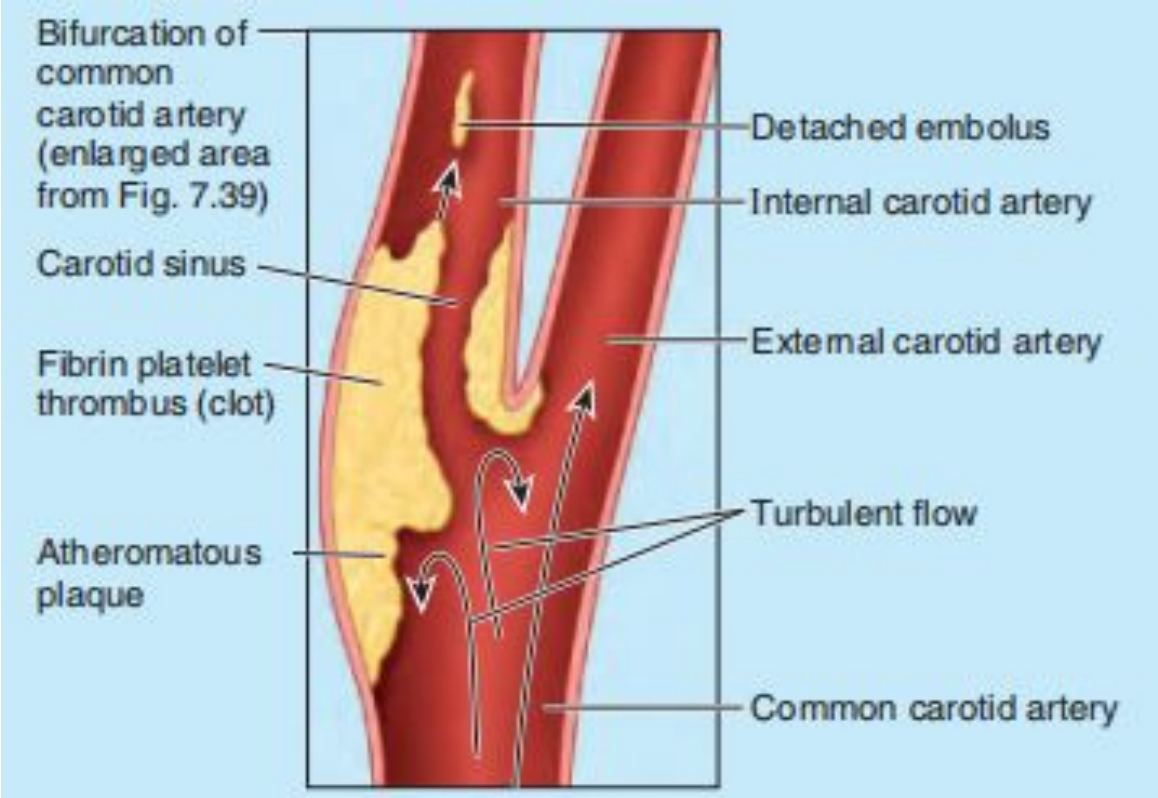

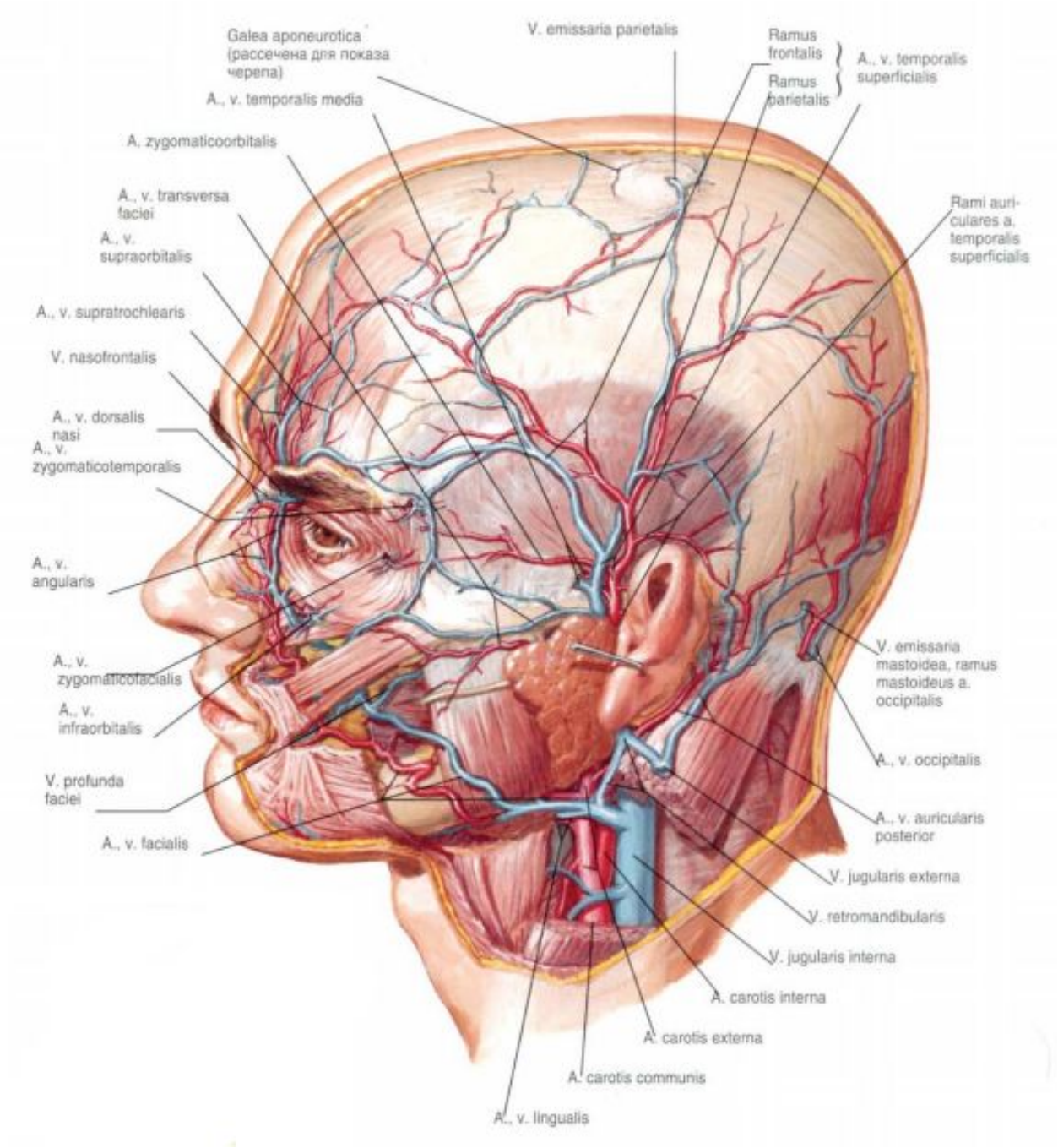

Лицевая артерия

A. temporalis superficialis

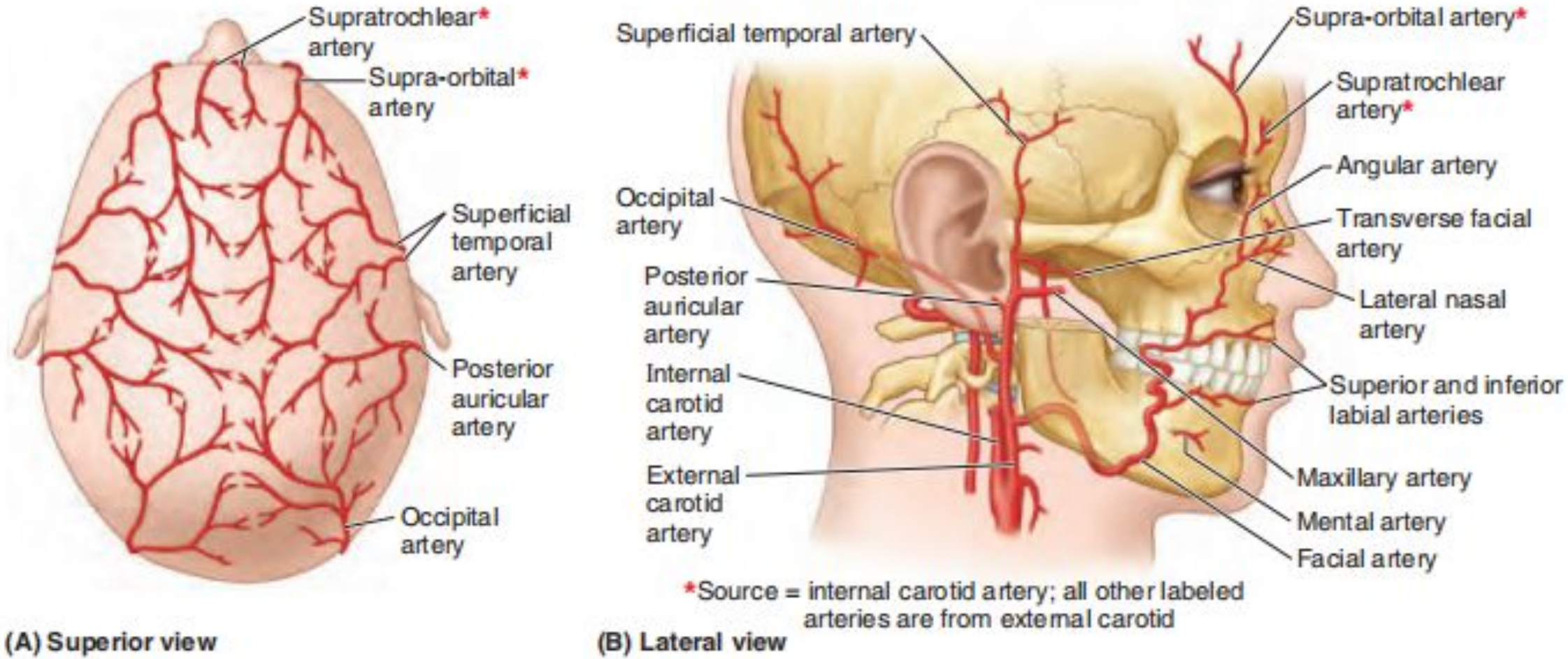

FIGURE 7.24. Superficial arteries of face and scalp.

Лицевая артерия

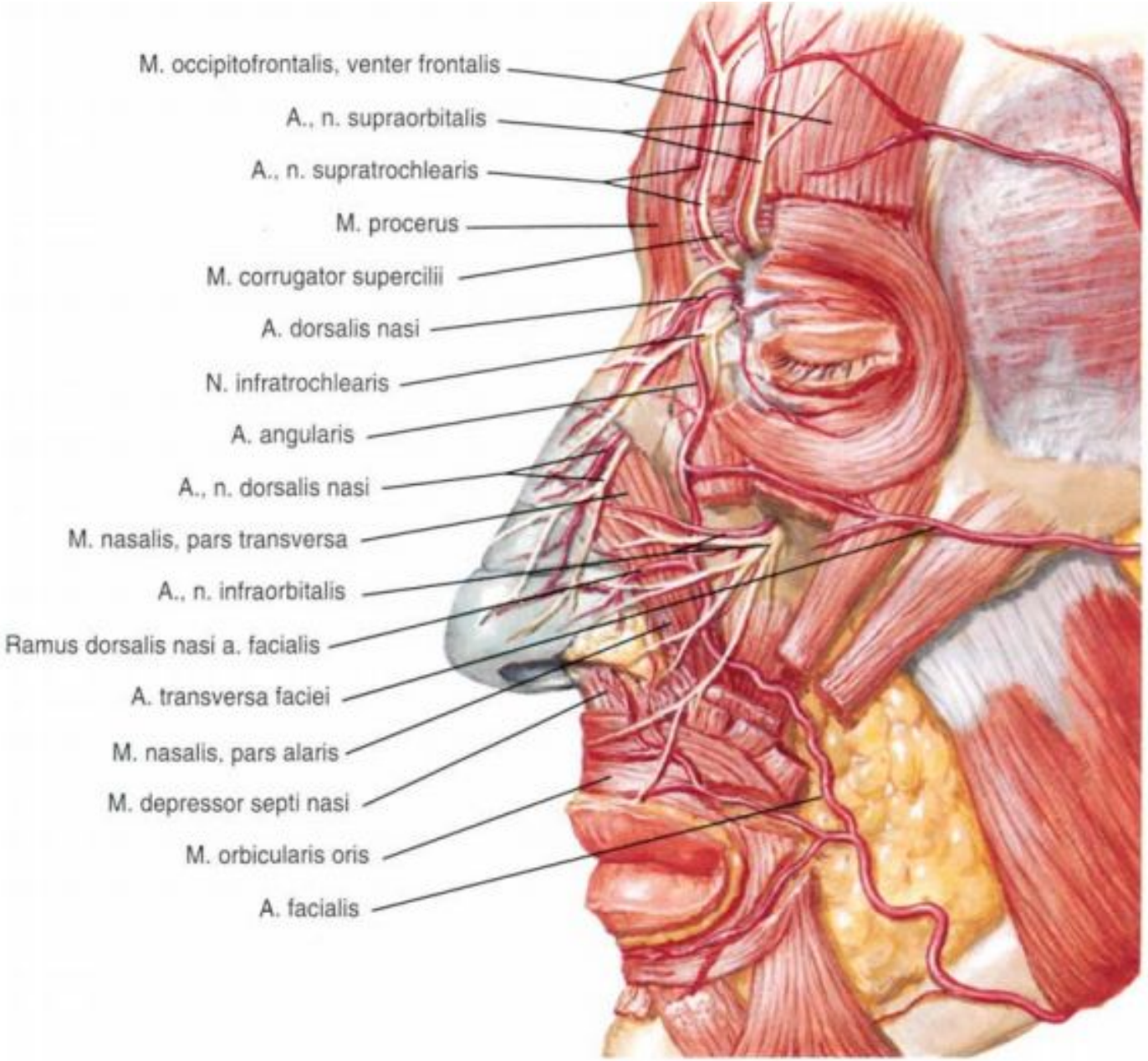

Поверхностная височная артерия

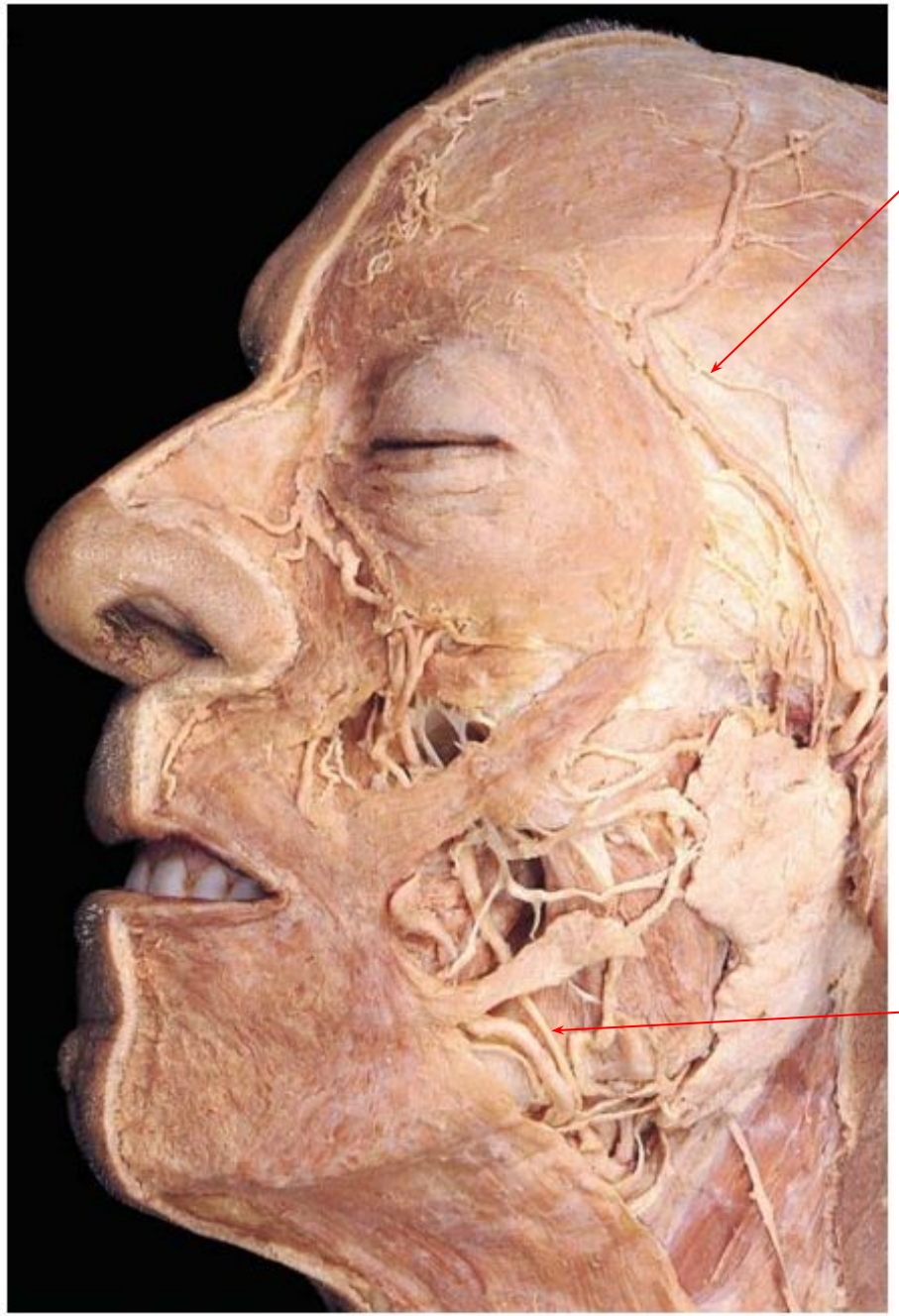

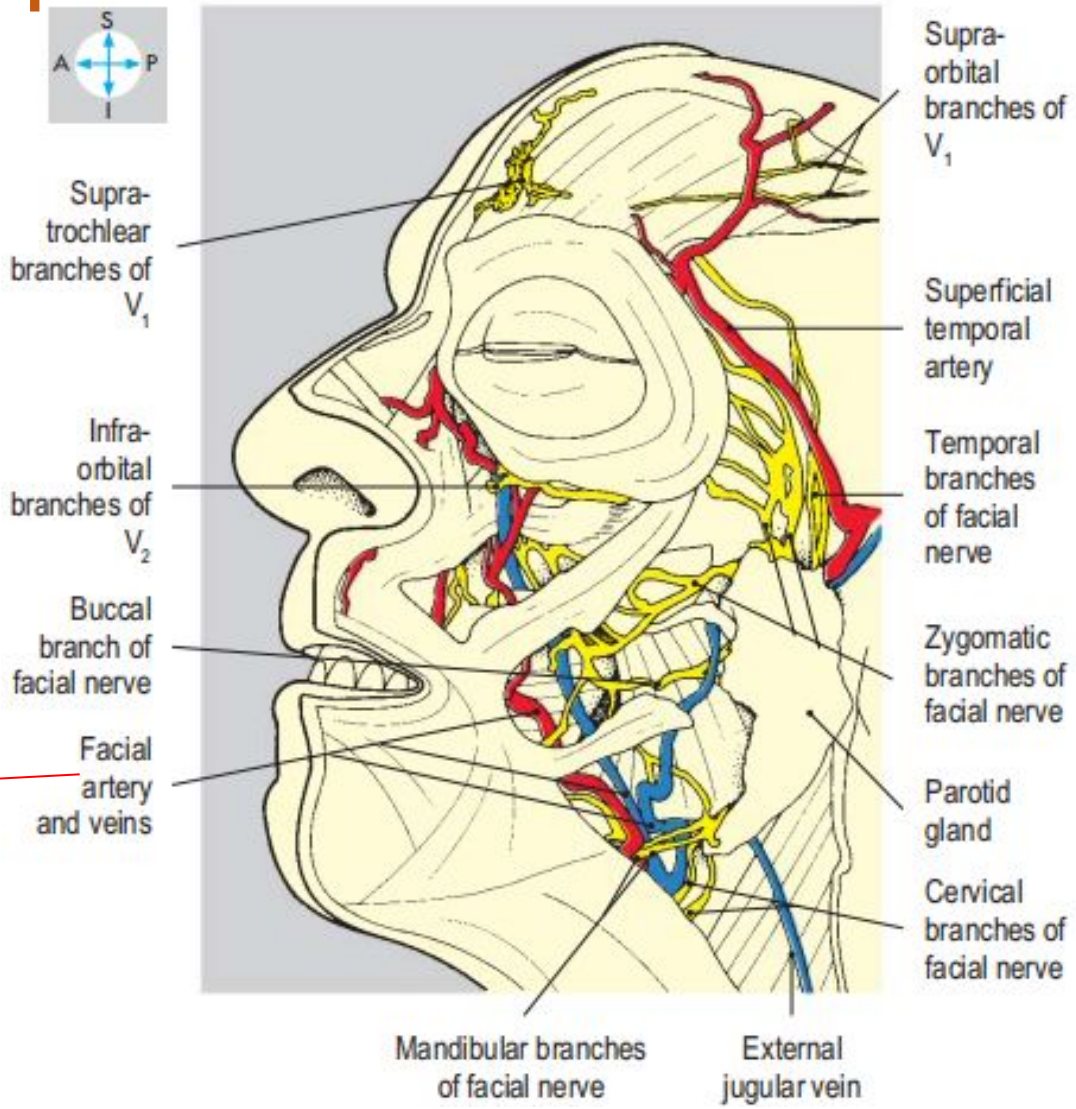

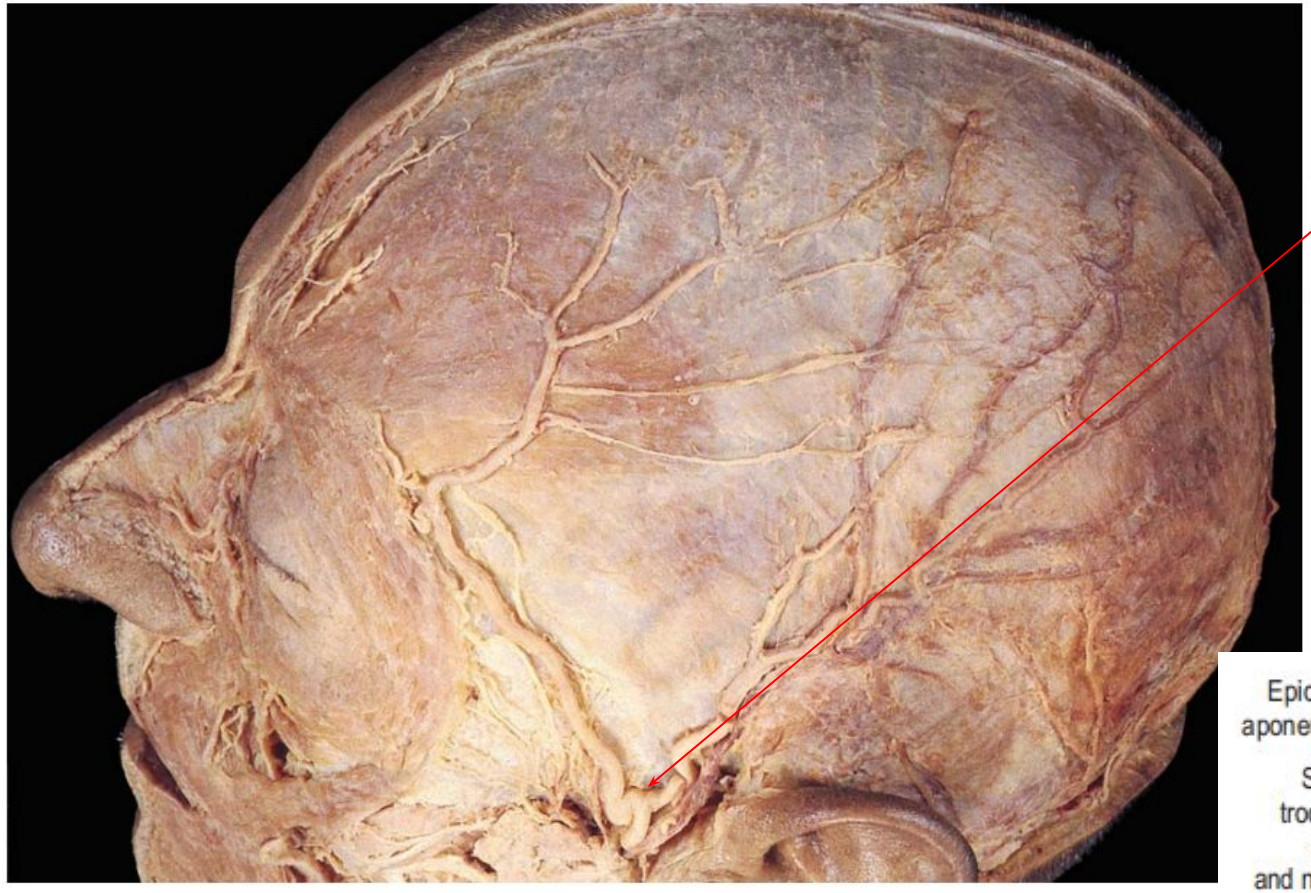

Поверхностная височная артерия

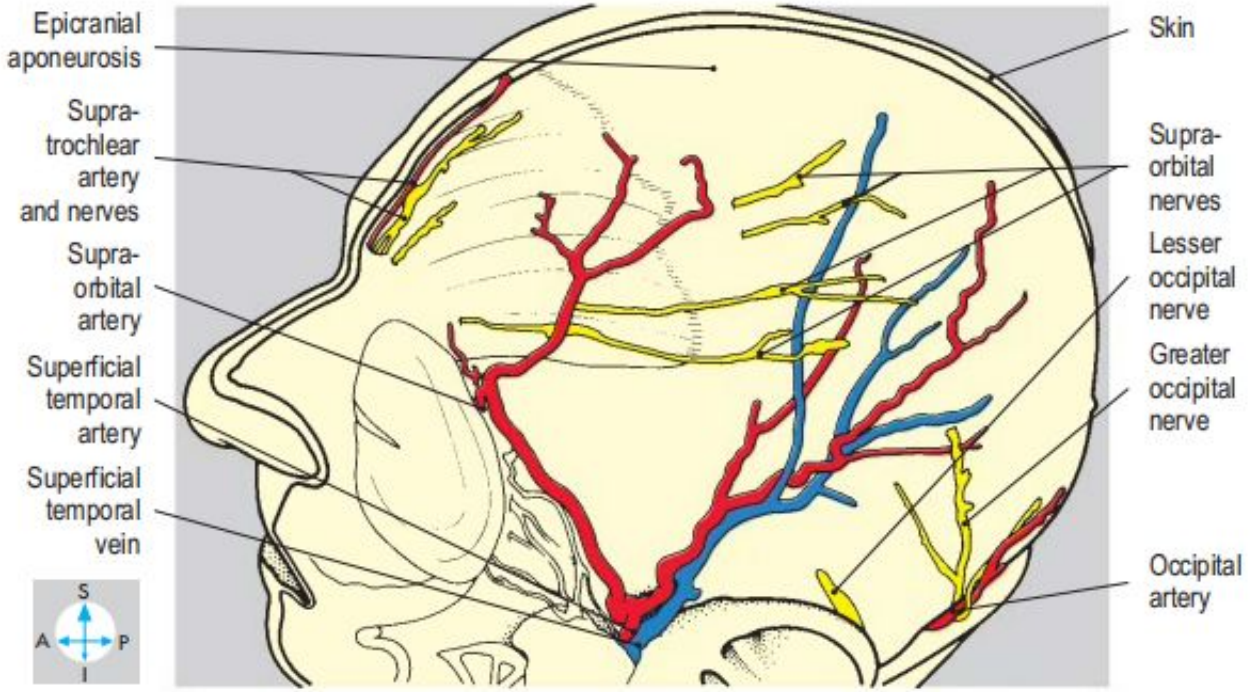

Верхнечелюстная артерия

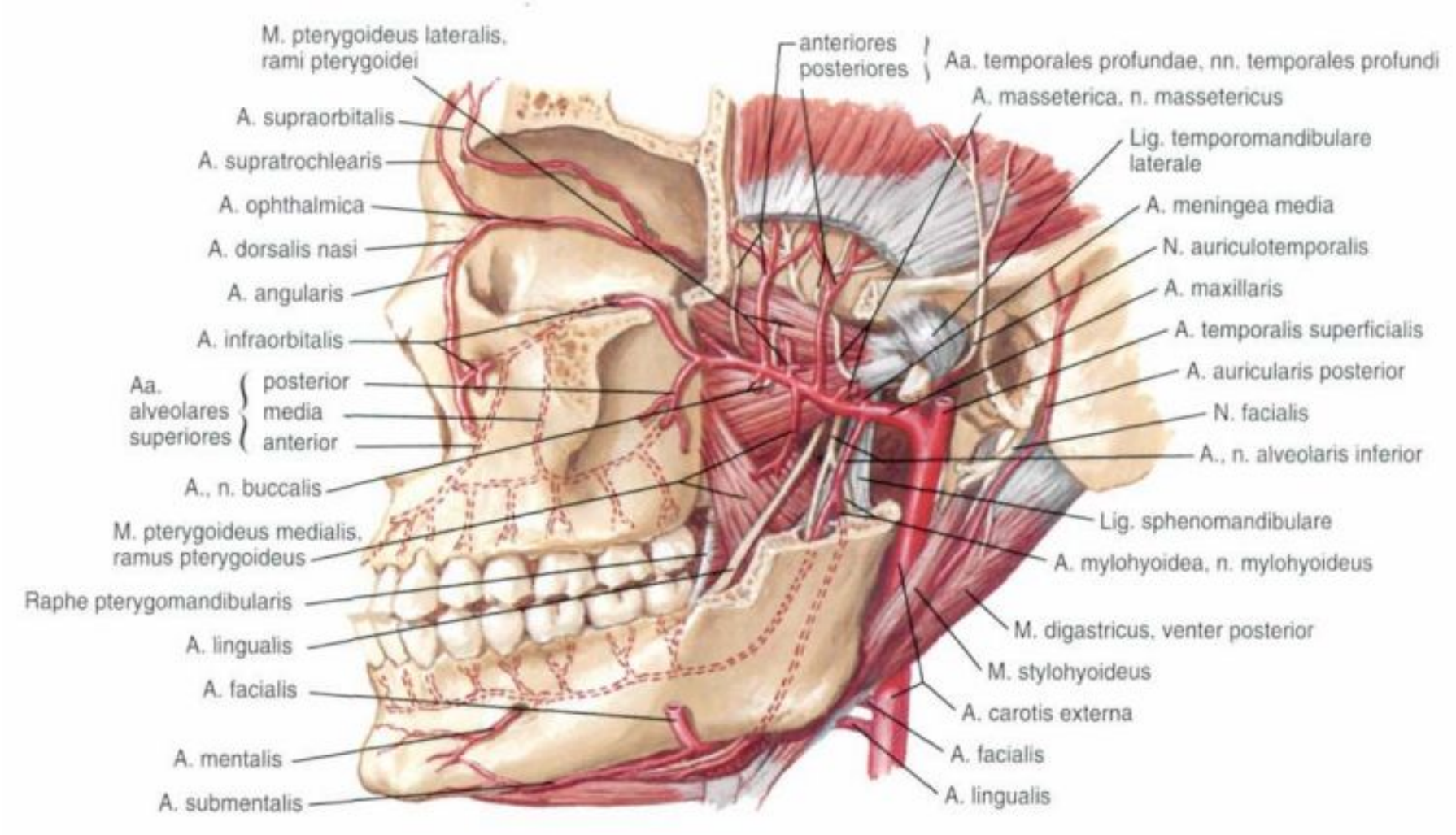

Верхнечелюстная артерия

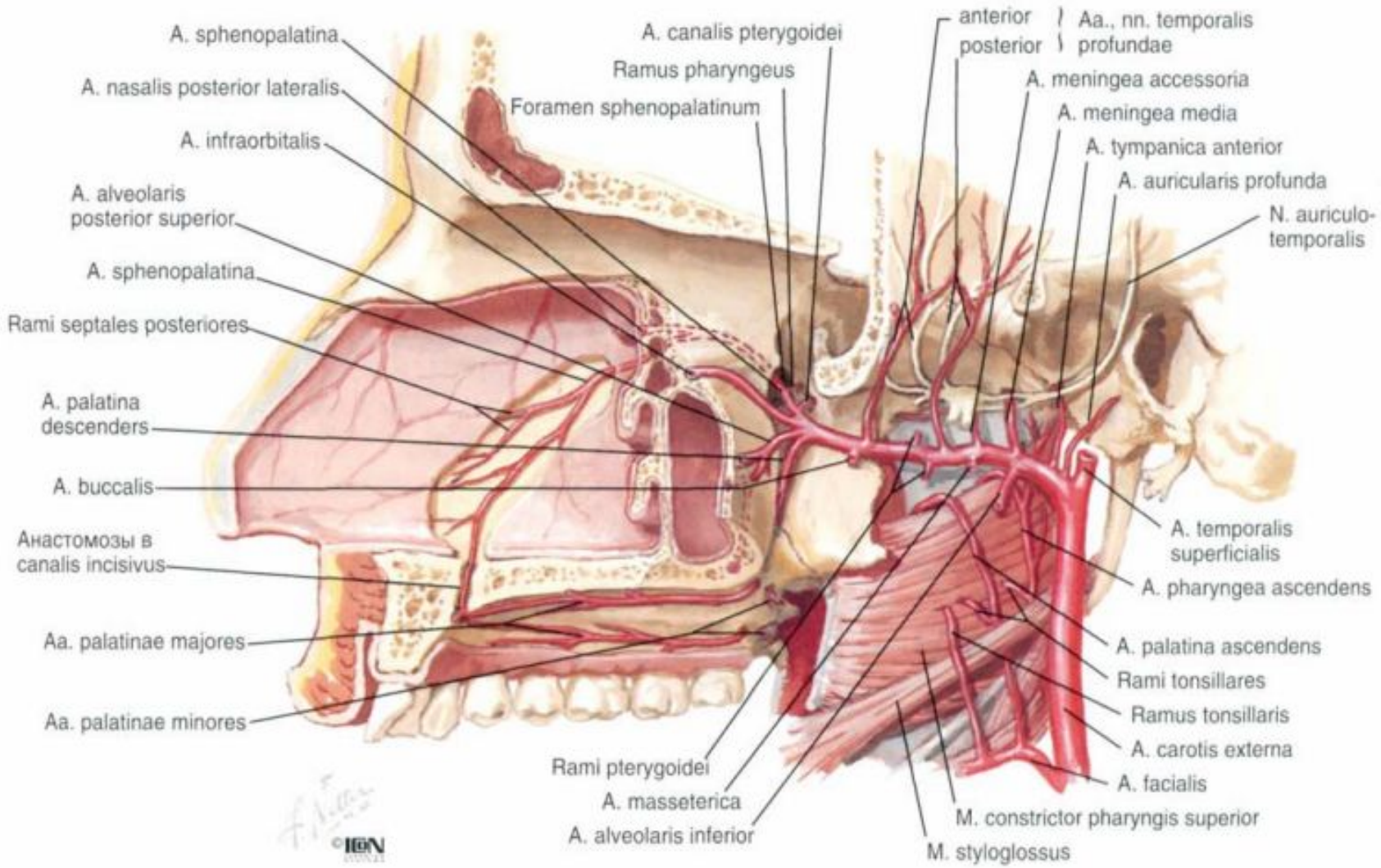

Верхнечелюстная артерия

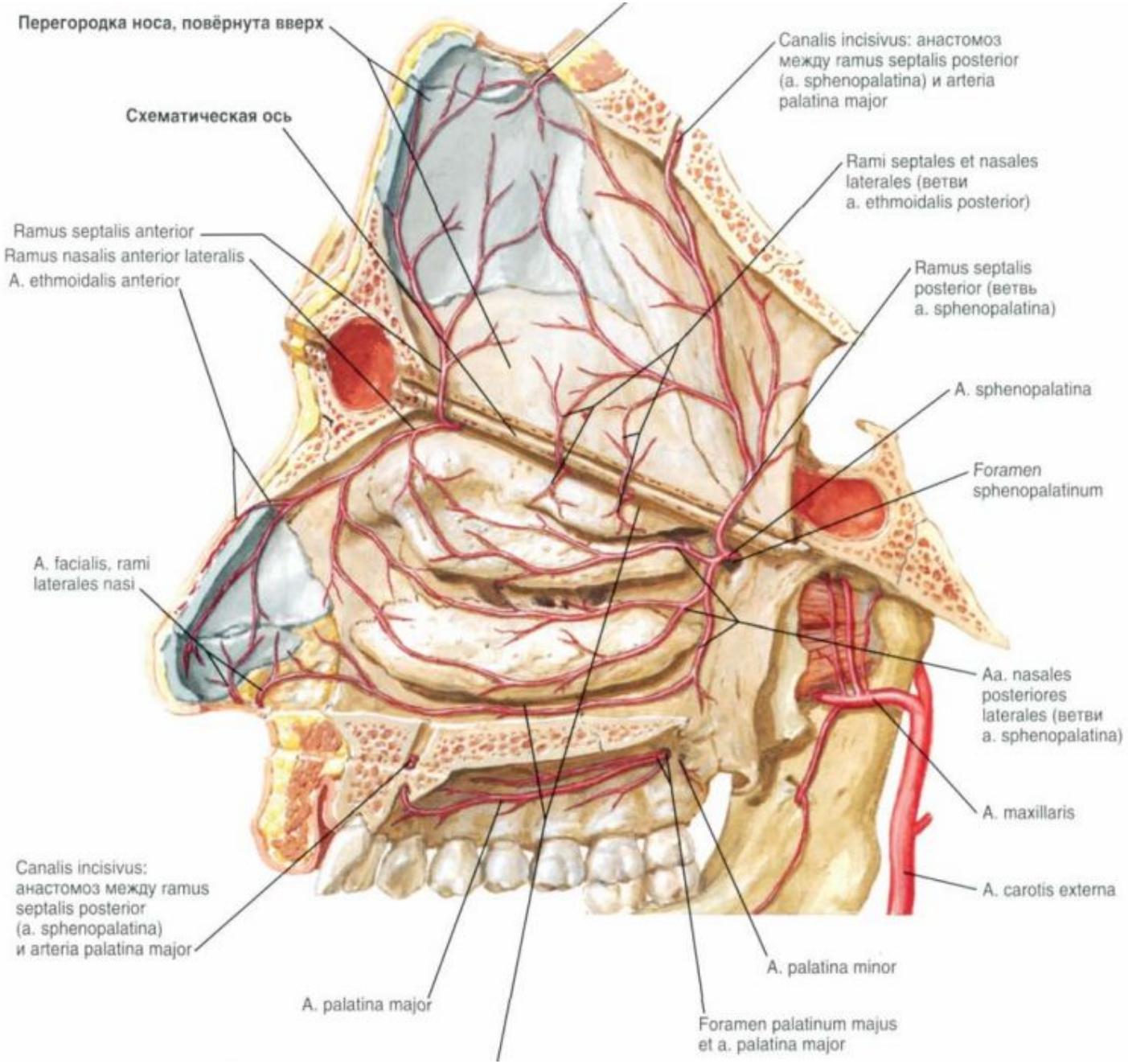

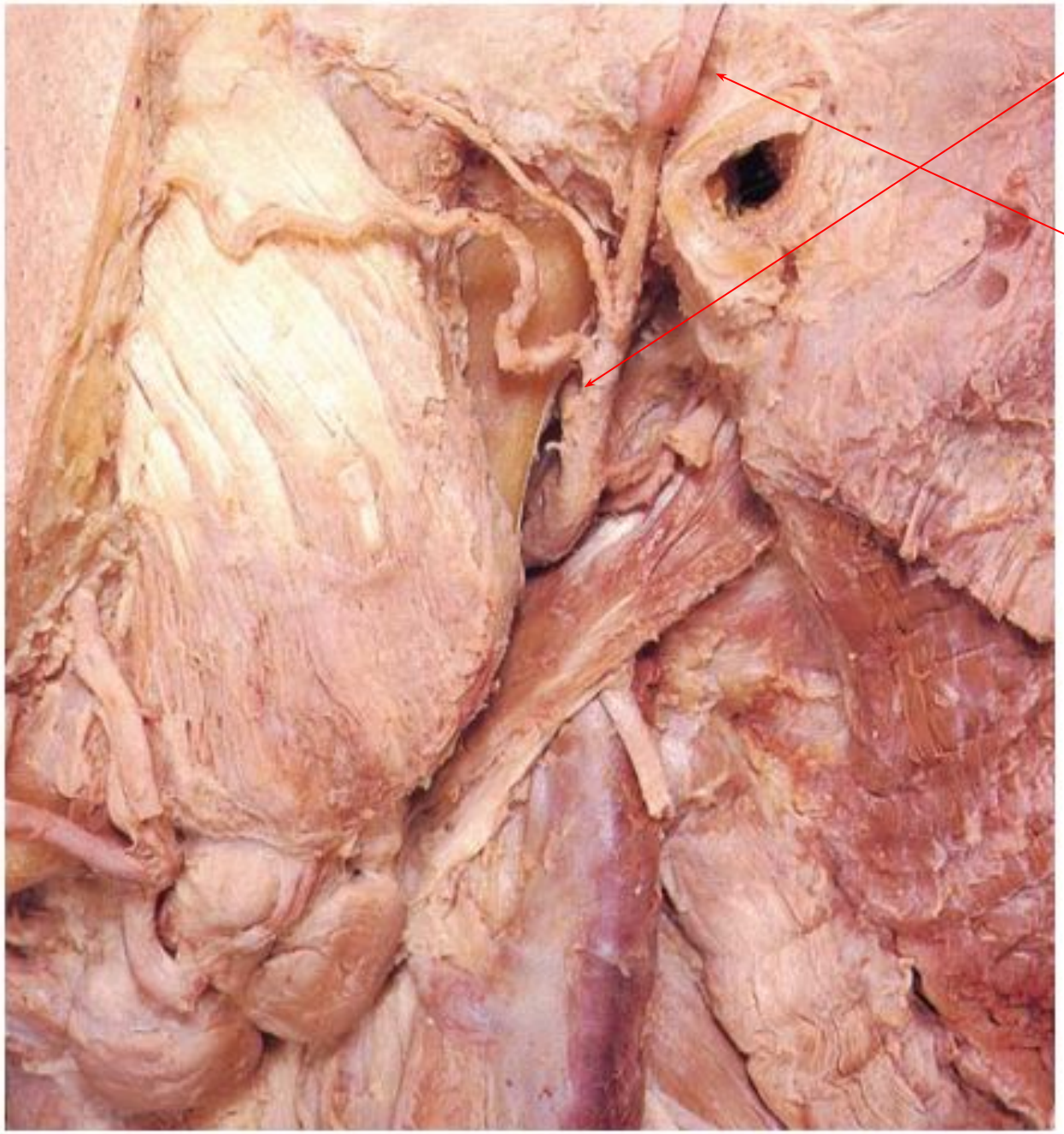

Верхнечелюстная артерия

Поверхностная височная артерия

Fig. 7.28 External carotid artery and its terminal branches, revealed by complete excision of the parotid gland.

Верхнечелюстная артерия

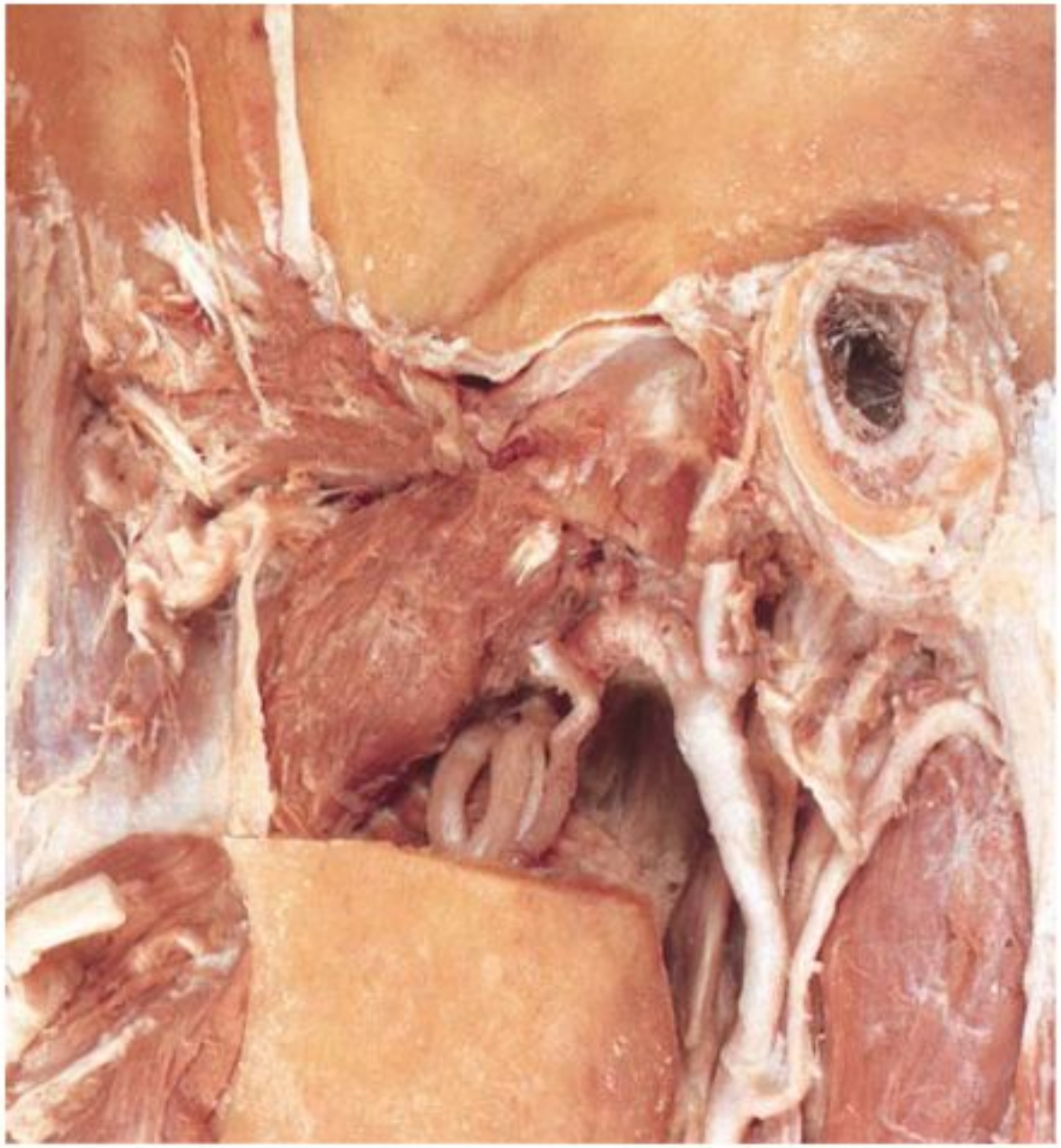

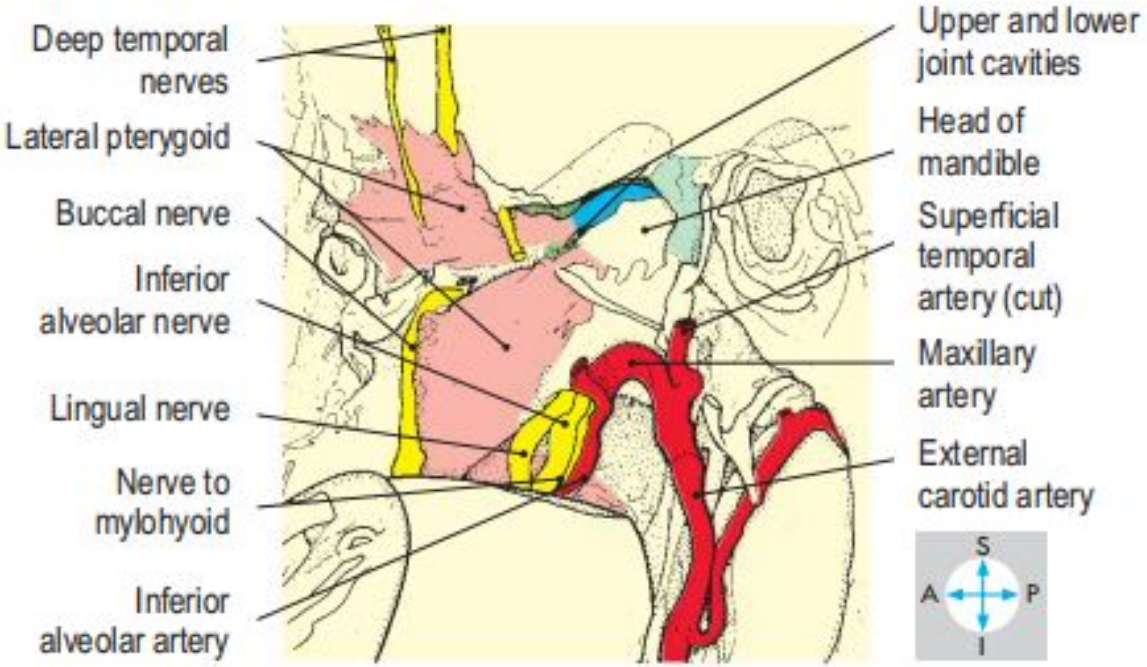

Верхнечелюстная артерия

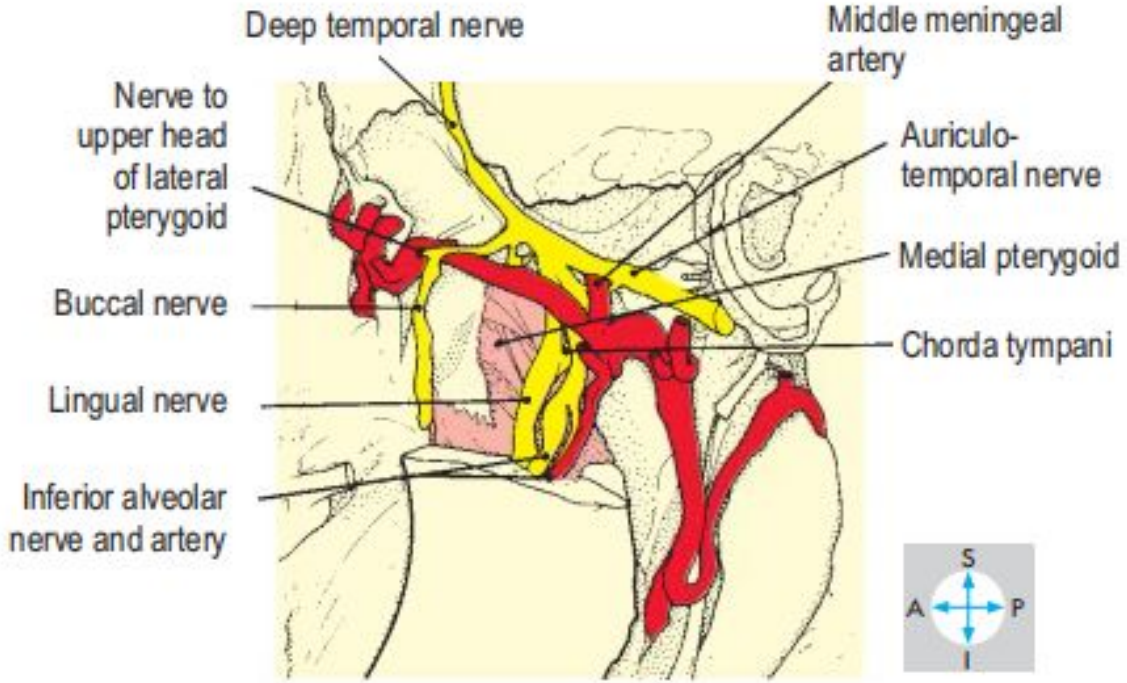

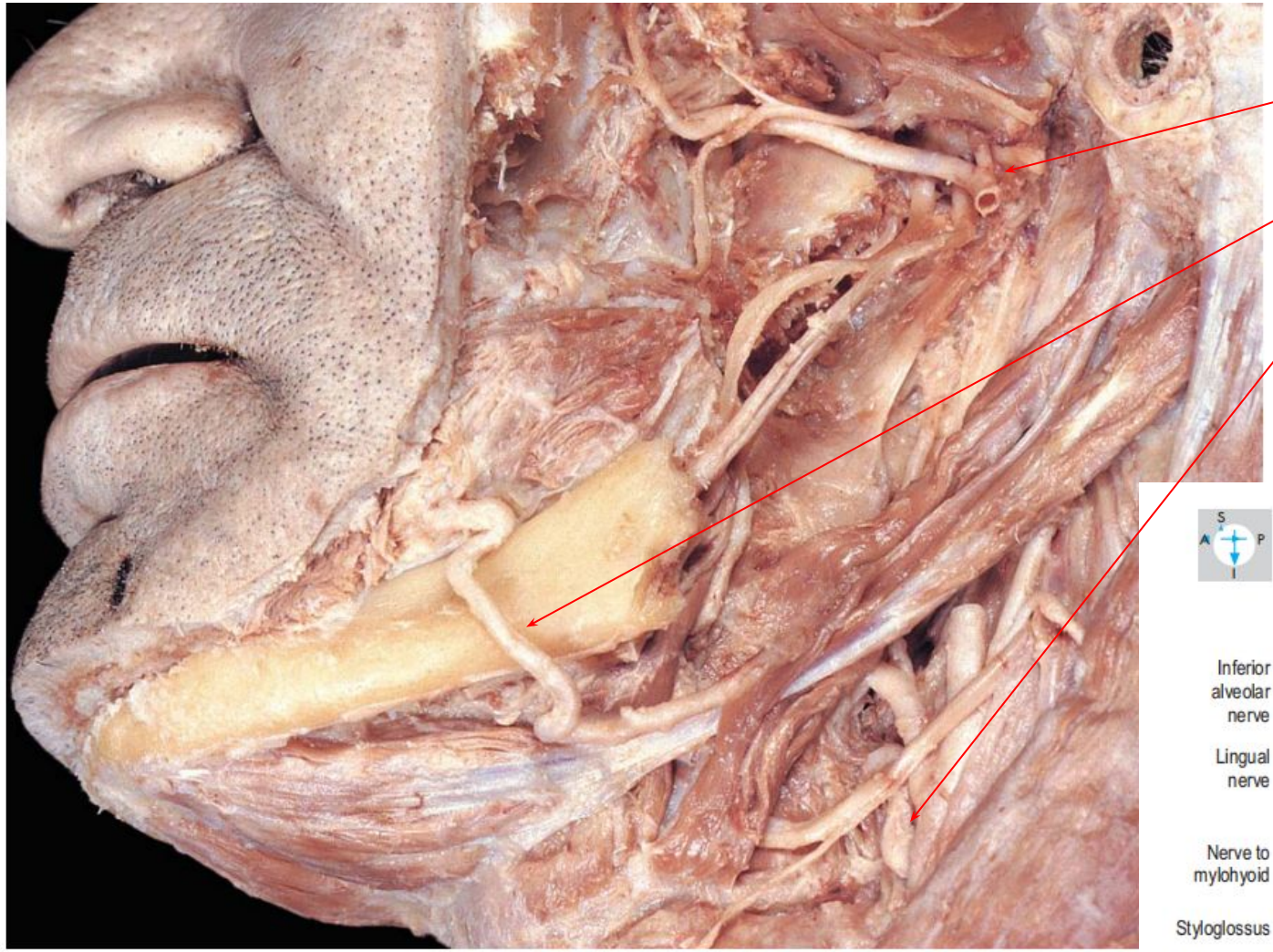

Верхнечелюстная а.
Лицевая а.
Язычная а.

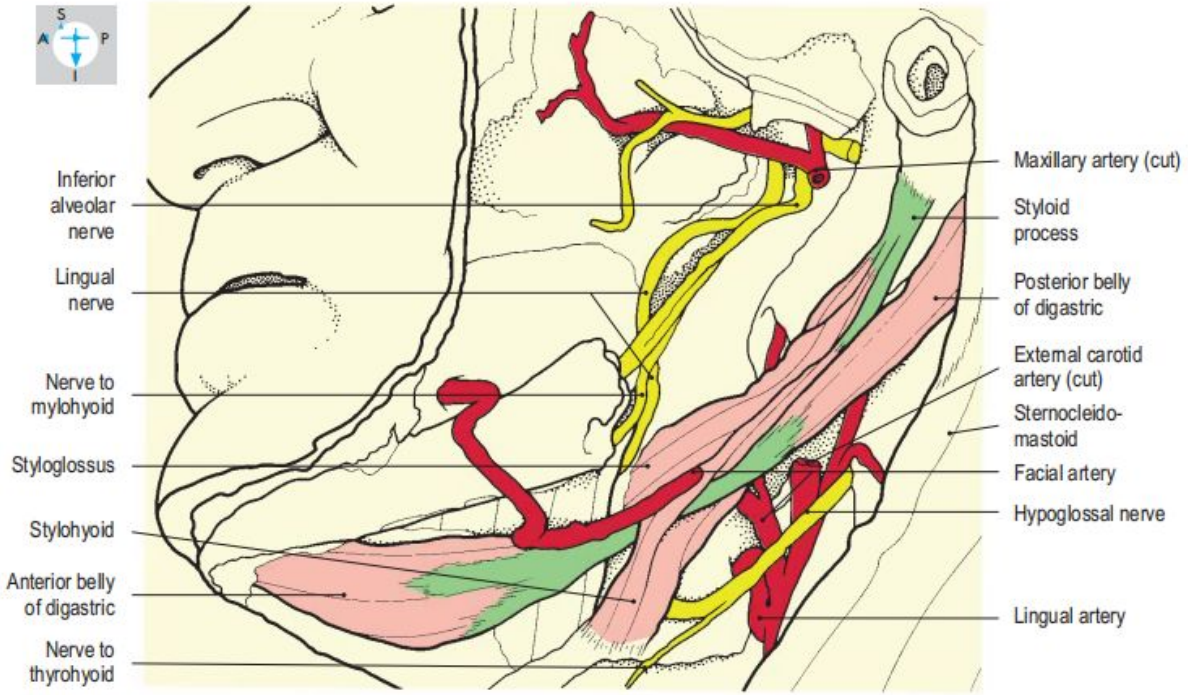

Fig. 7.35 Digastric and stylohyoid seen after removal of part of the mandible. The superficial part of the submandibular gland has also been excised.

Затылочная артерия

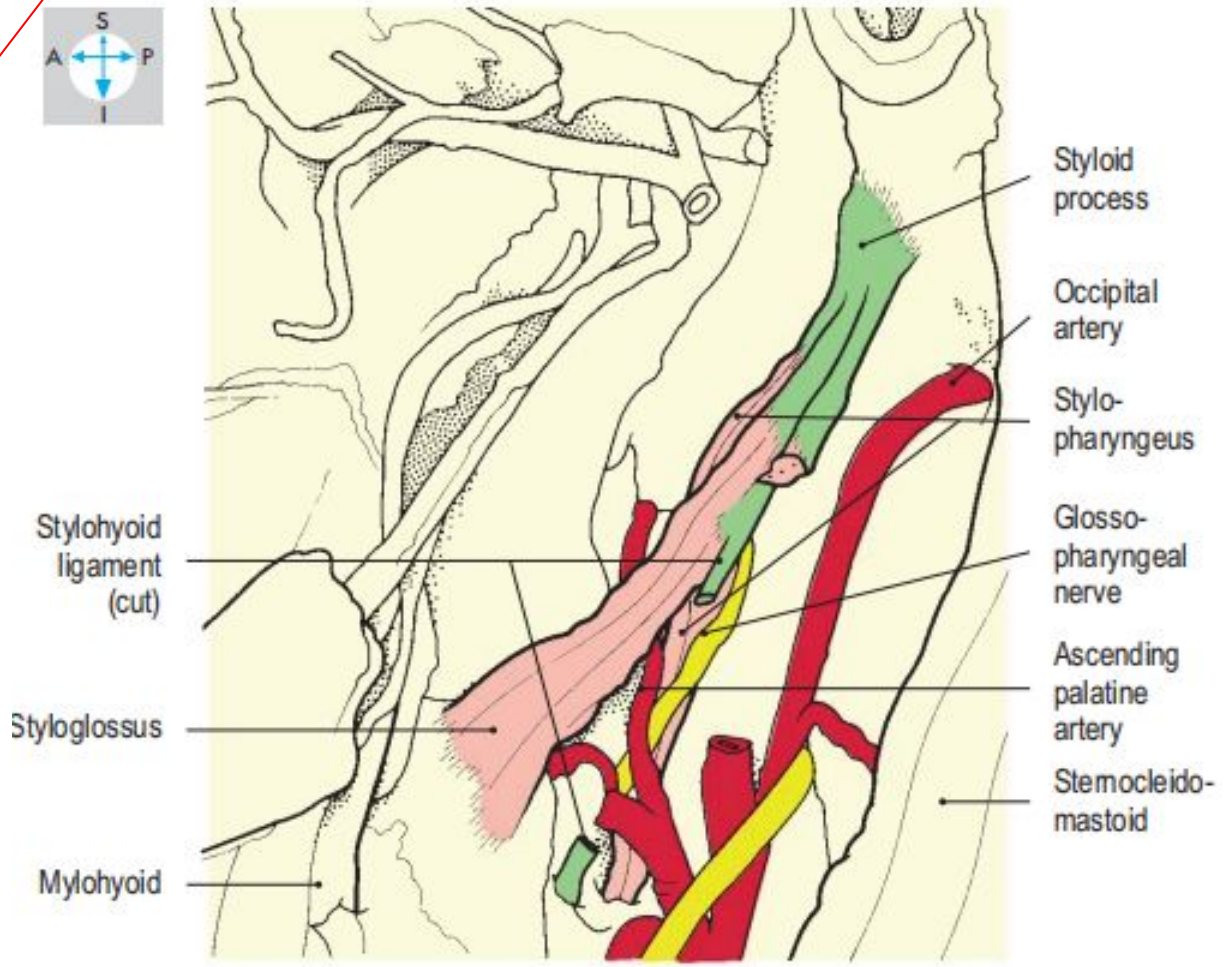

Язычная и лицевая артерии

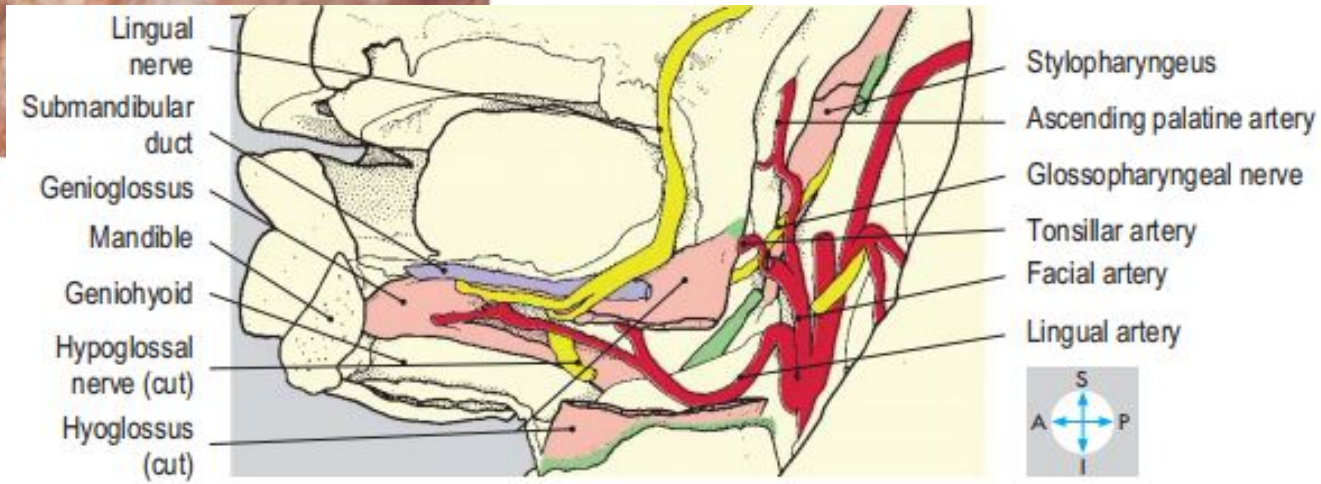

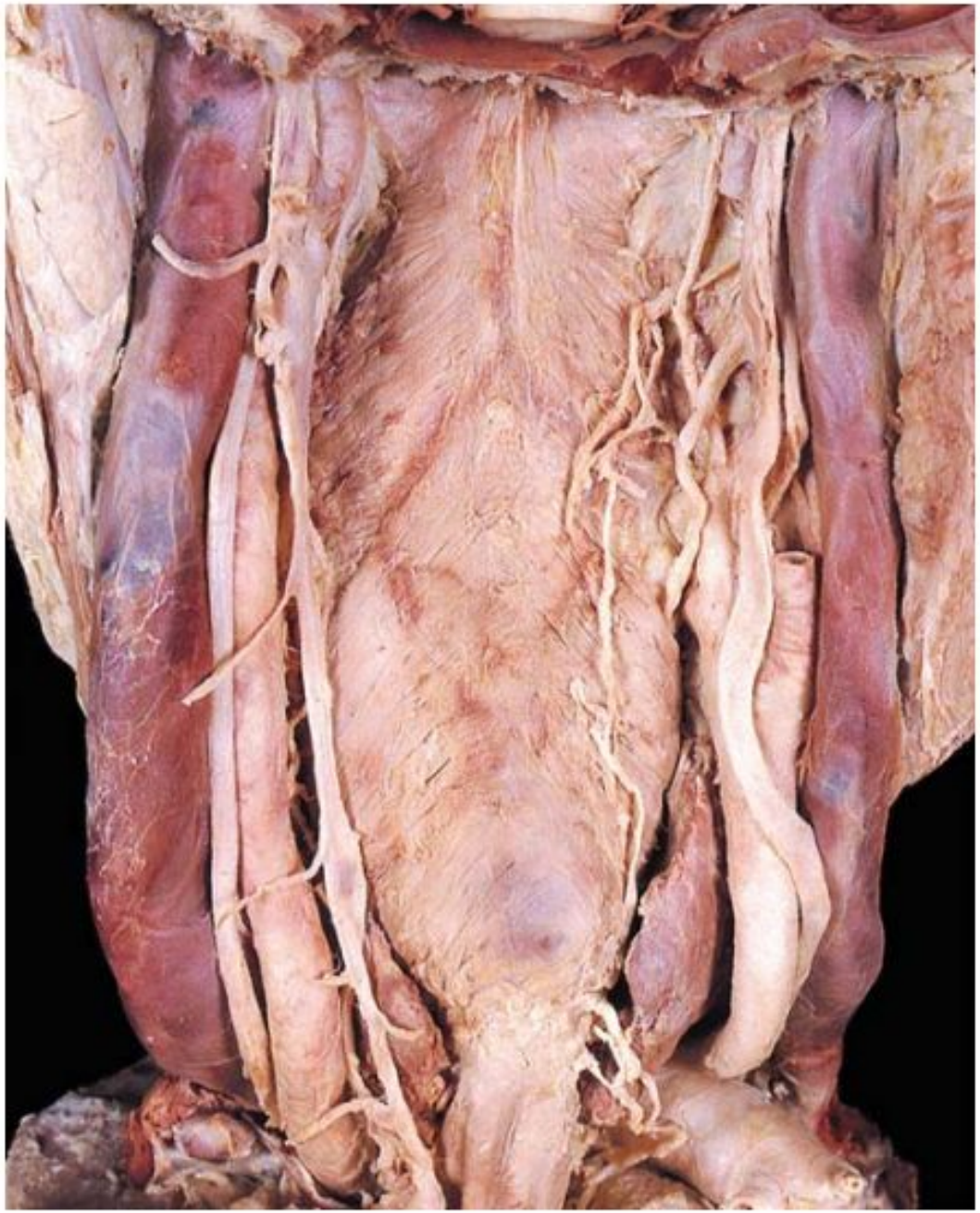

Внутренняя сонная артерия

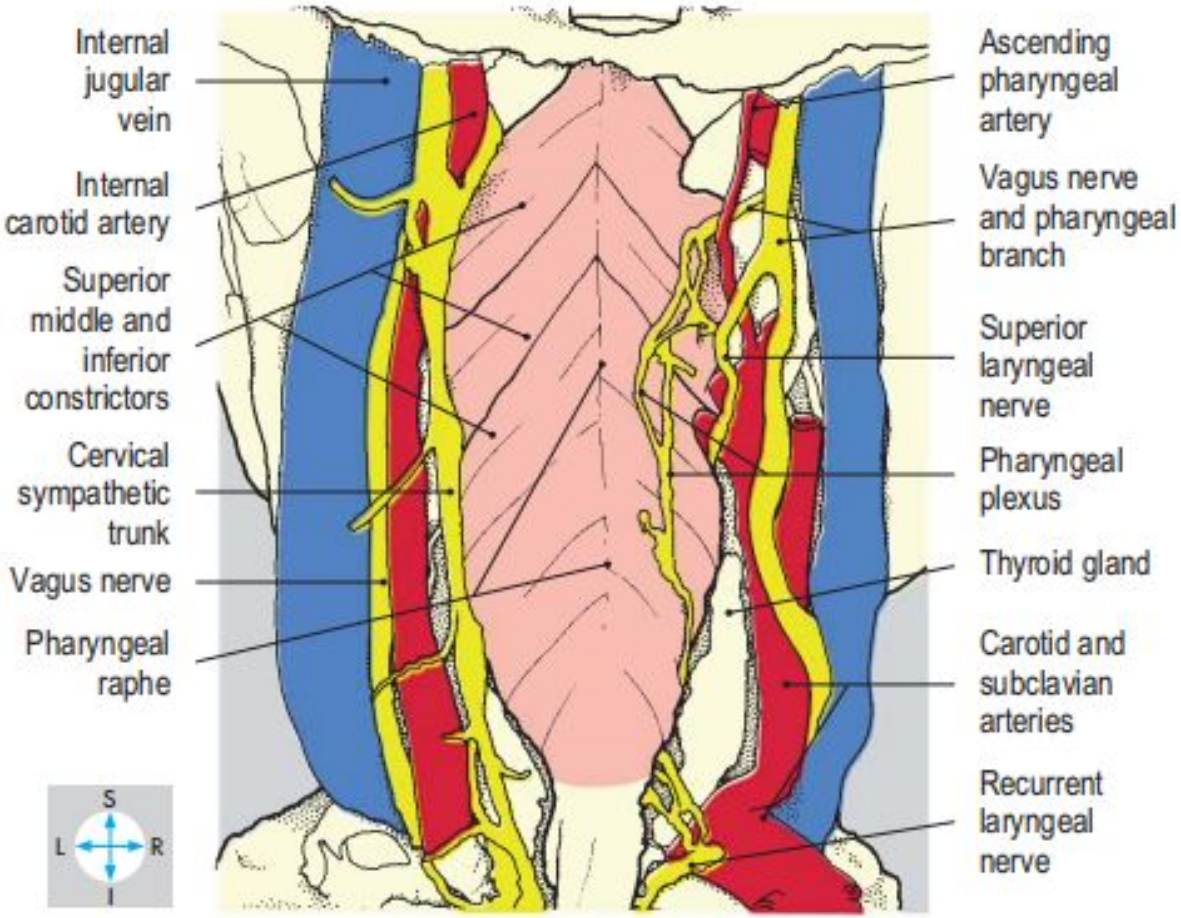

Fig. 7.57 Posterior view of pharyngeal musculature after removal of cervical vertebral column, posterior part of the skull, right sympathetic trunk and part of the right internal carotid artery.

Отделы внутренней сонной артерии

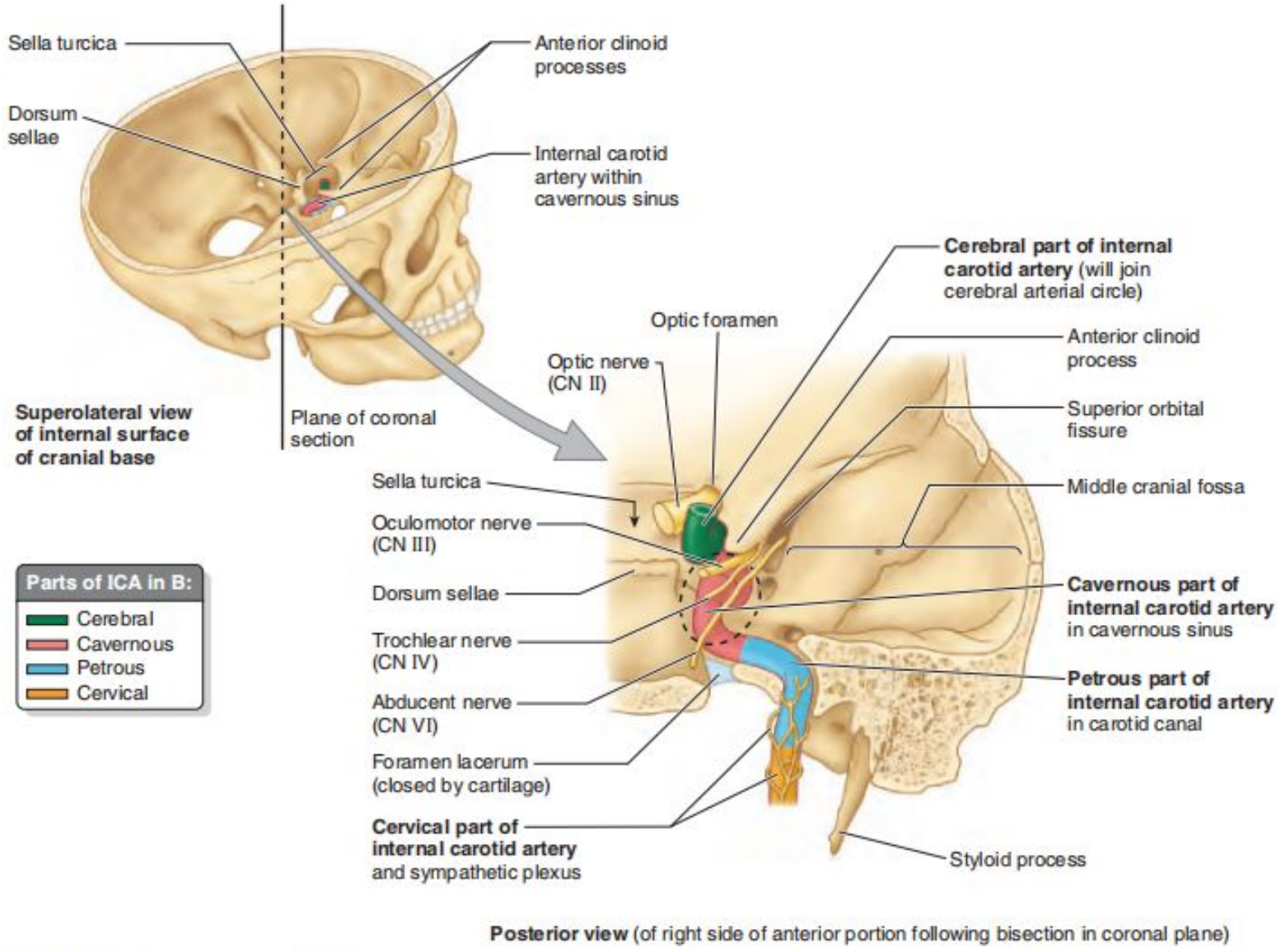

FIGURE 7.40. Course of internal carotid artery. The orientation drawing (*left*) indicates the plane of the coronal section that intersects the carotid canal

Глазная артерия

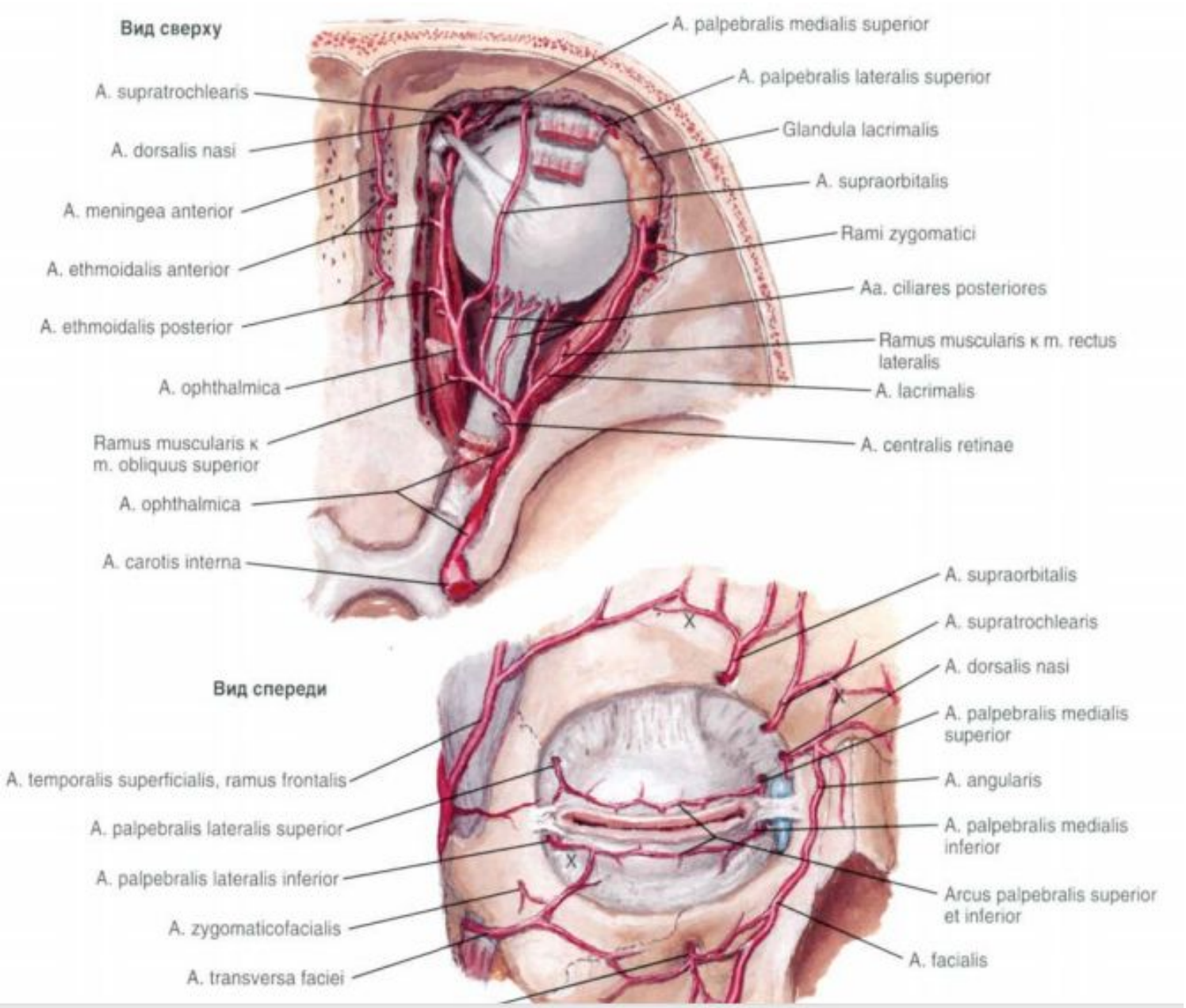

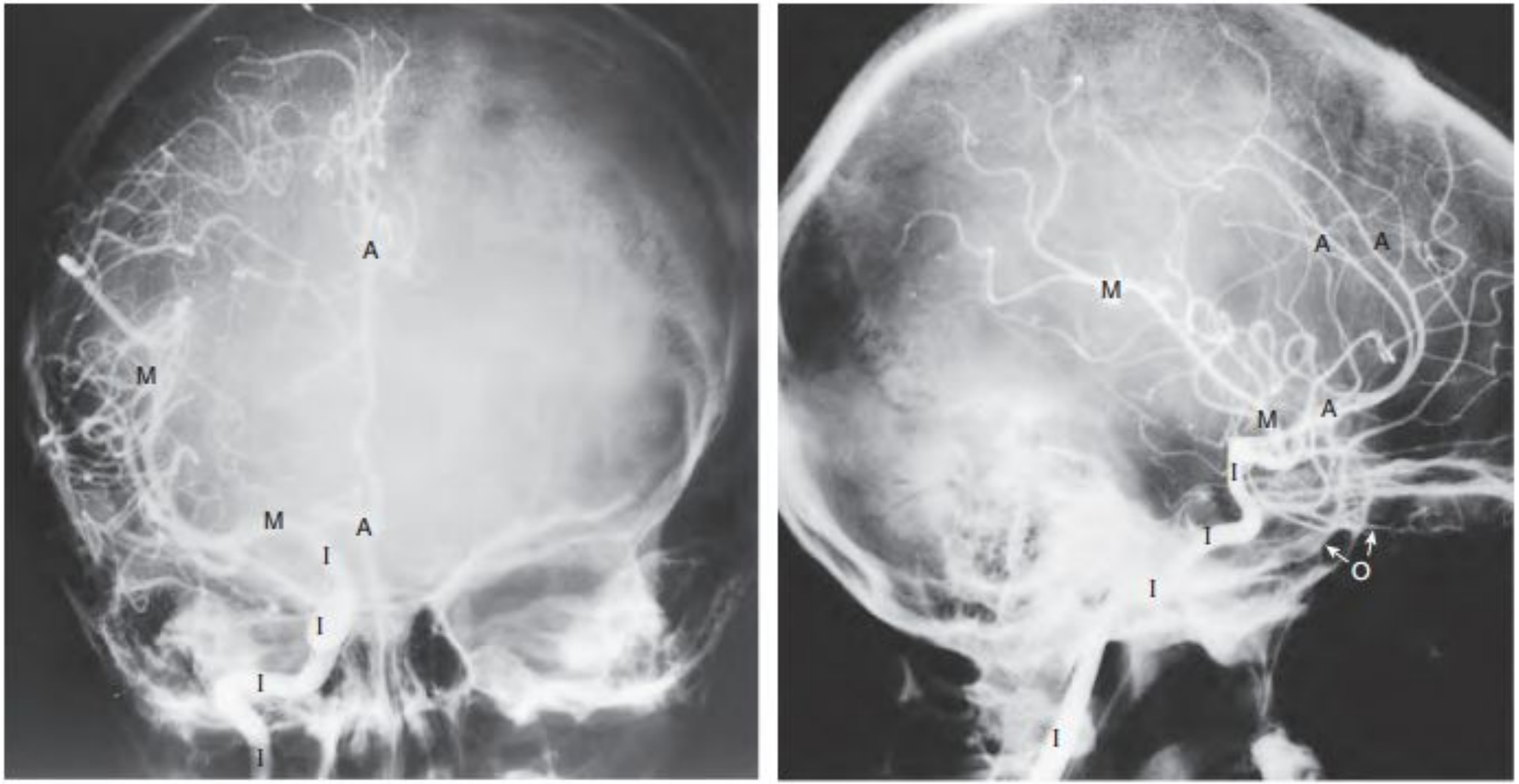

(A) Anteroposterior view

(B) Lateral view

FIGURE 7.41. Carotid arteriograms. A and B. Radiopaque dye injected into the carotid arterial system demonstrates unilateral distribution to the brain from the internal carotid artery. *A*, anterior cerebral artery and its branches; *I*, the four parts of the internal carotid artery; *M*, middle cerebral artery and its branches; *O*, ophthalmic artery. (Courtesy of Dr. D. Armstrong, Associate Professor of Medical Imaging, University of Toronto, Ontario, Canada.)

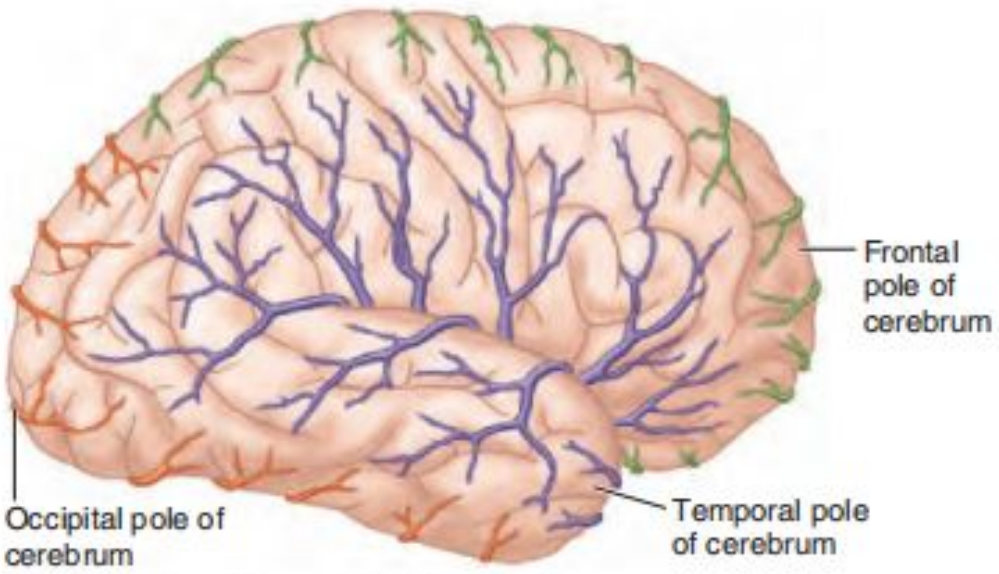

(A) Right lateral view of right hemisphere

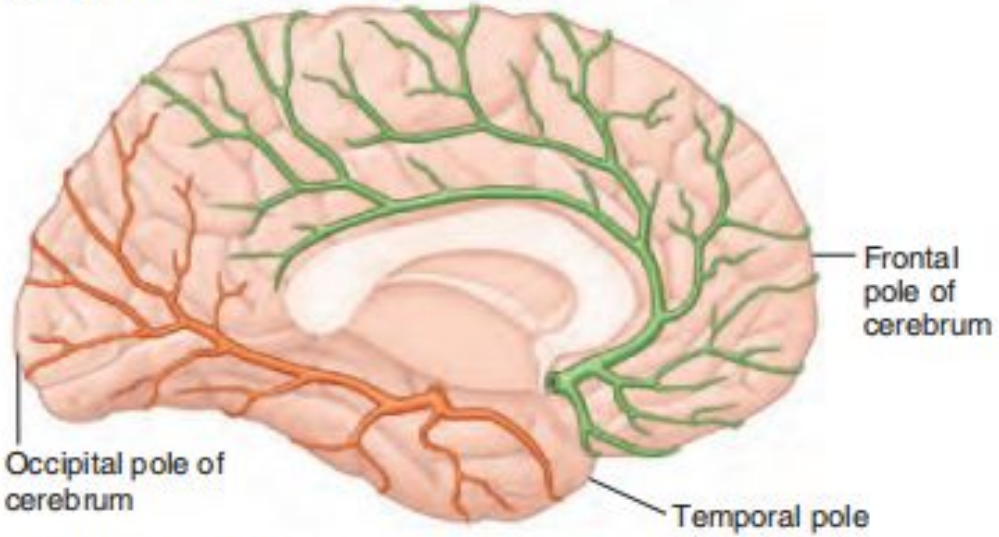

(B) Medial view of left hemisphere

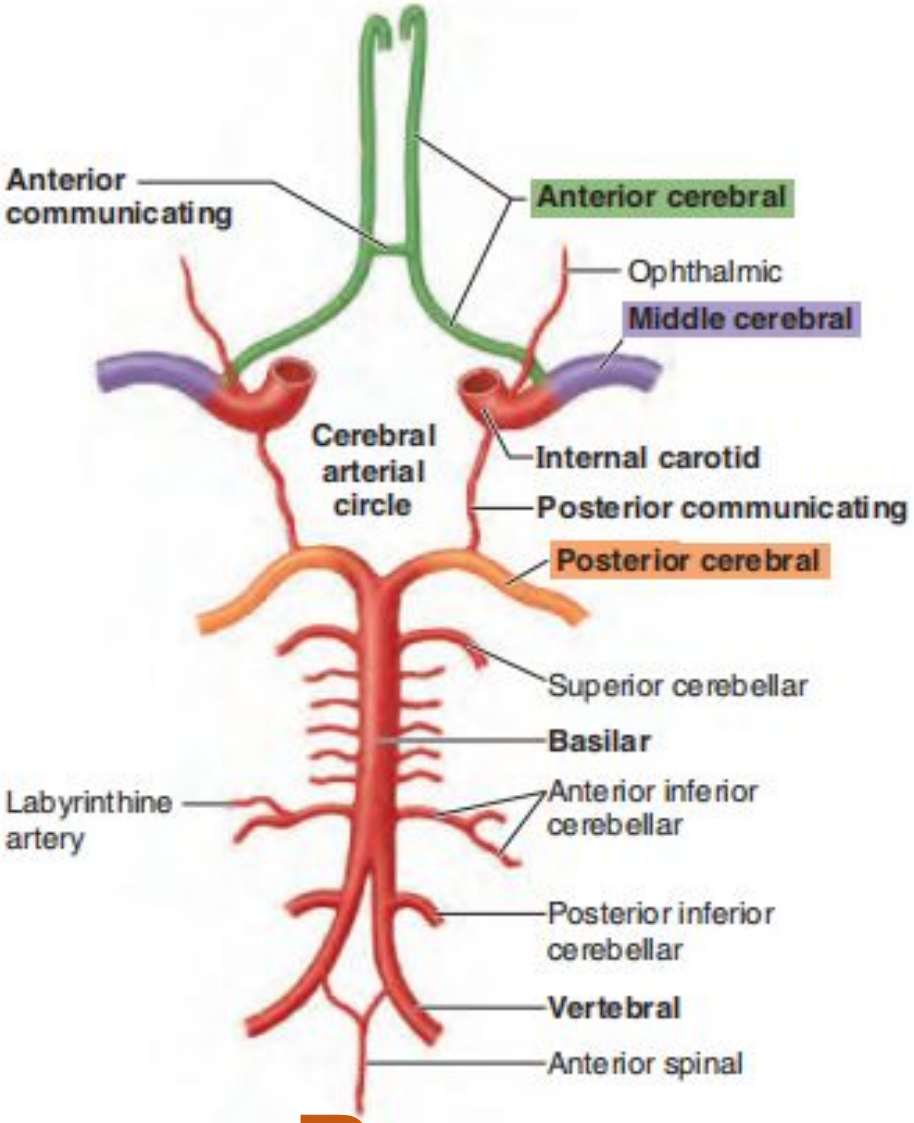

(C) Inferior view

FIGURE 7.43. Arterial blood supply of cerebrum.

Виллизиев круг

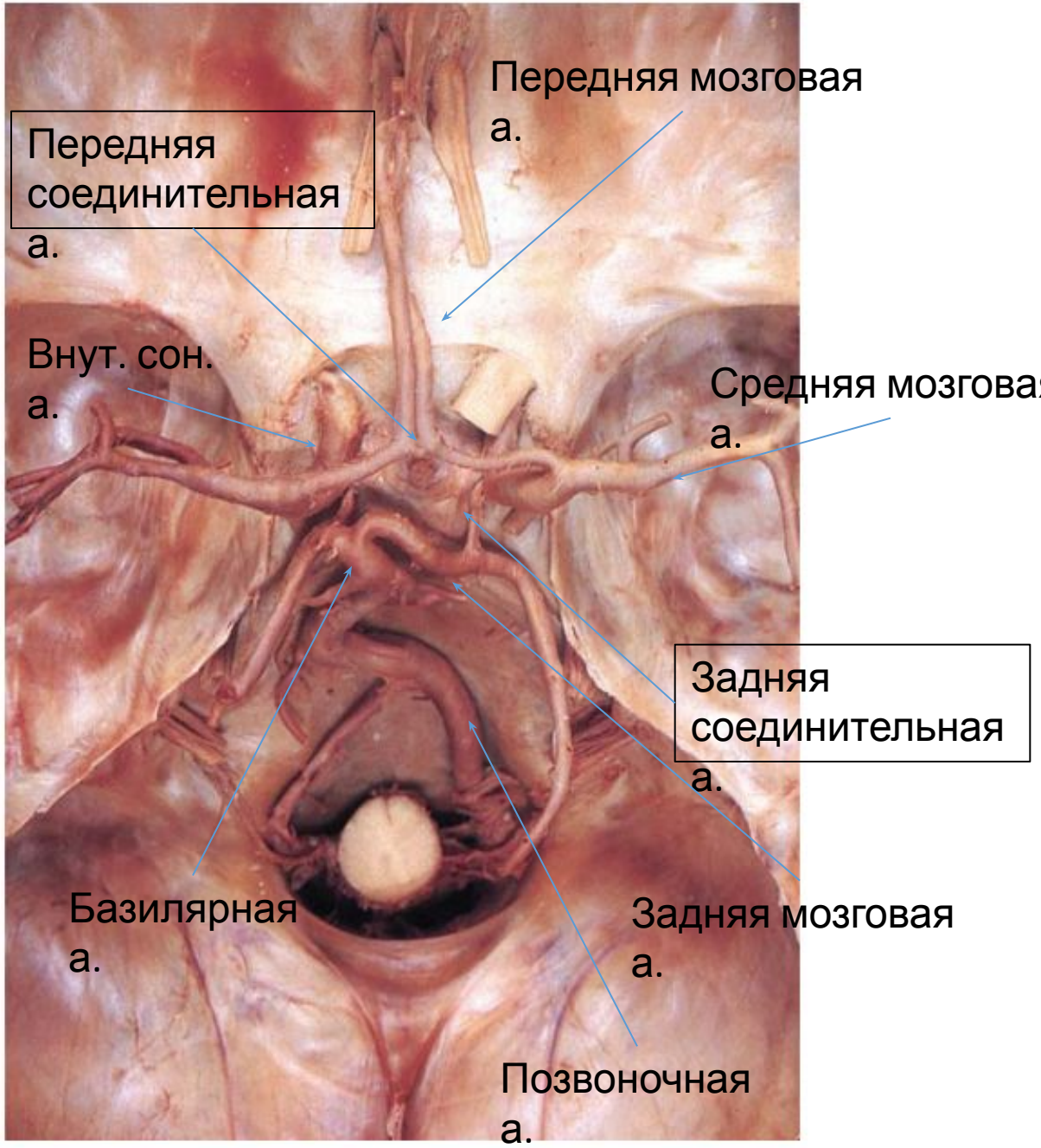

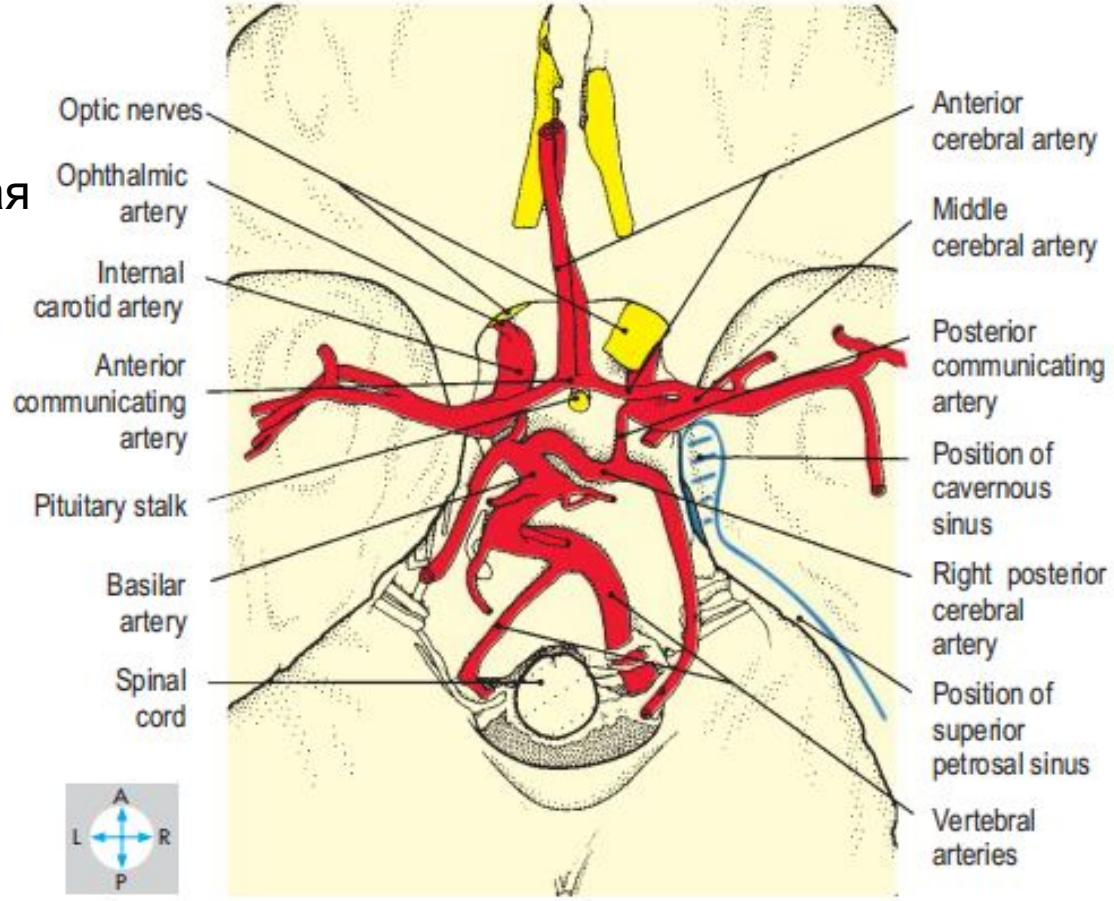

Fig. 7.79 Arterial circle, exposed by complete removal of the brain. The basilar and vertebral arteries are asymmetrical in this specimen.

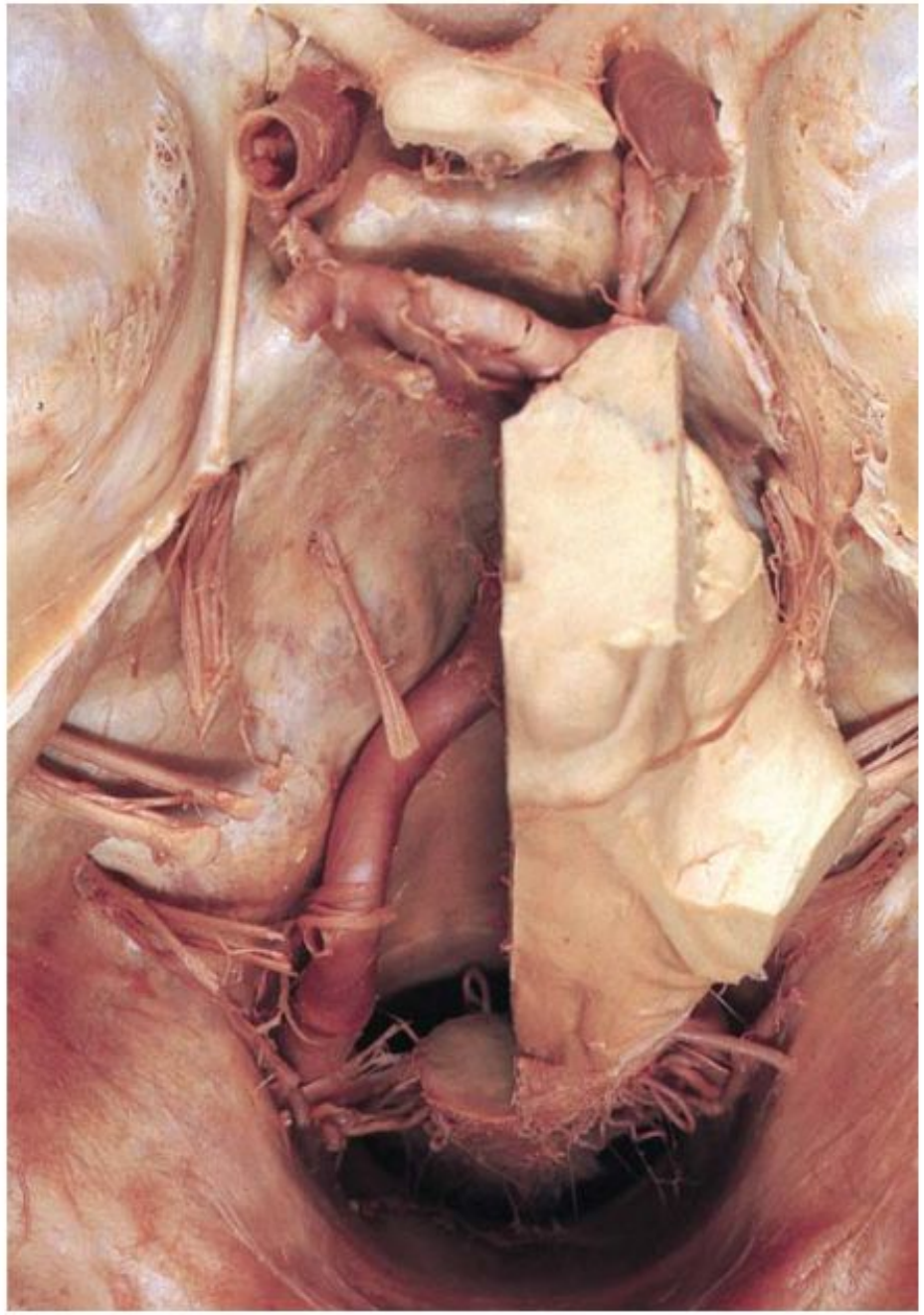

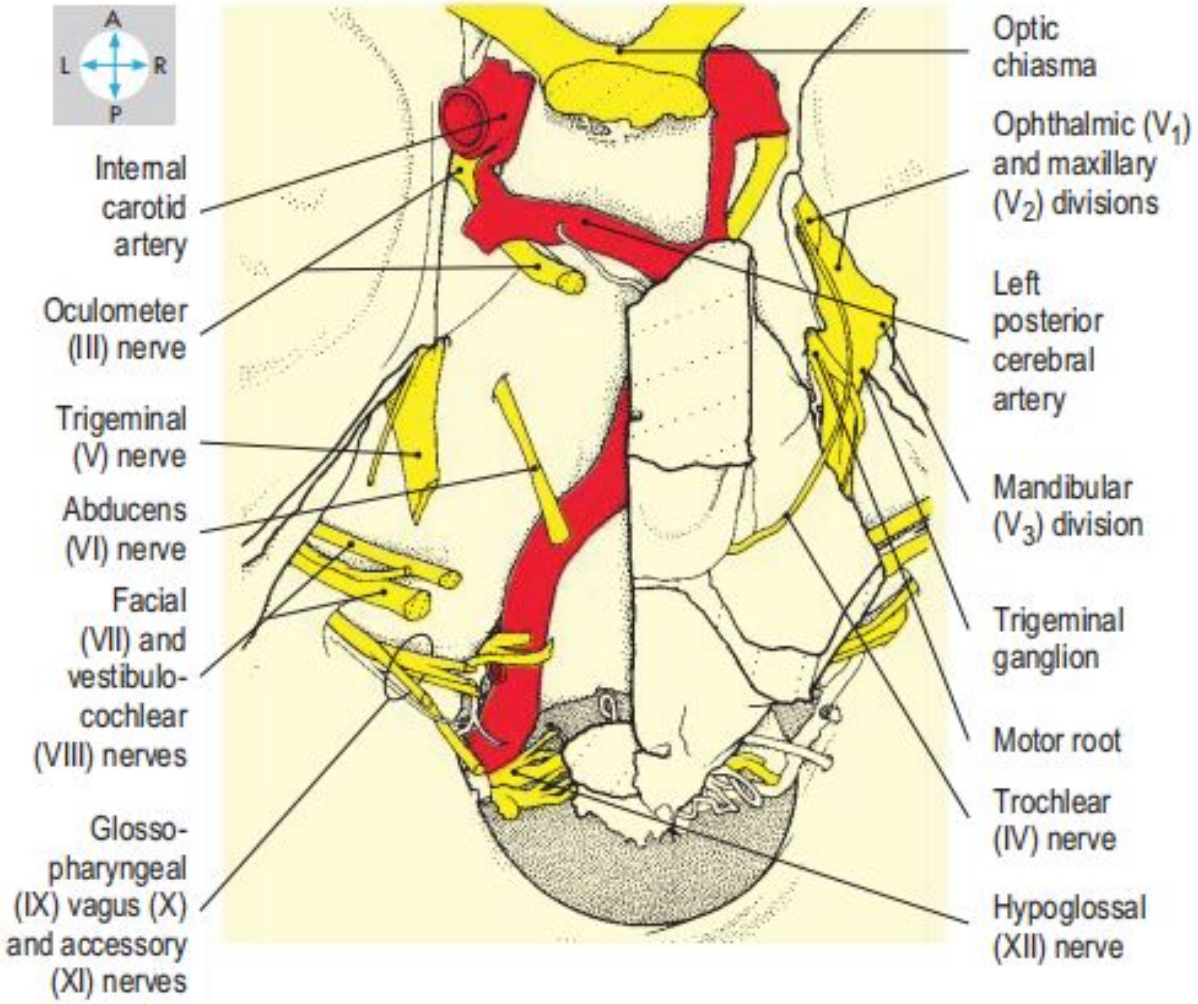

Fig. 7.80 Cranial nerves revealed by removal of most of the brain. The dura over the right trigeminal ganglion has been excised.

Виллизиев и Захарченко круги

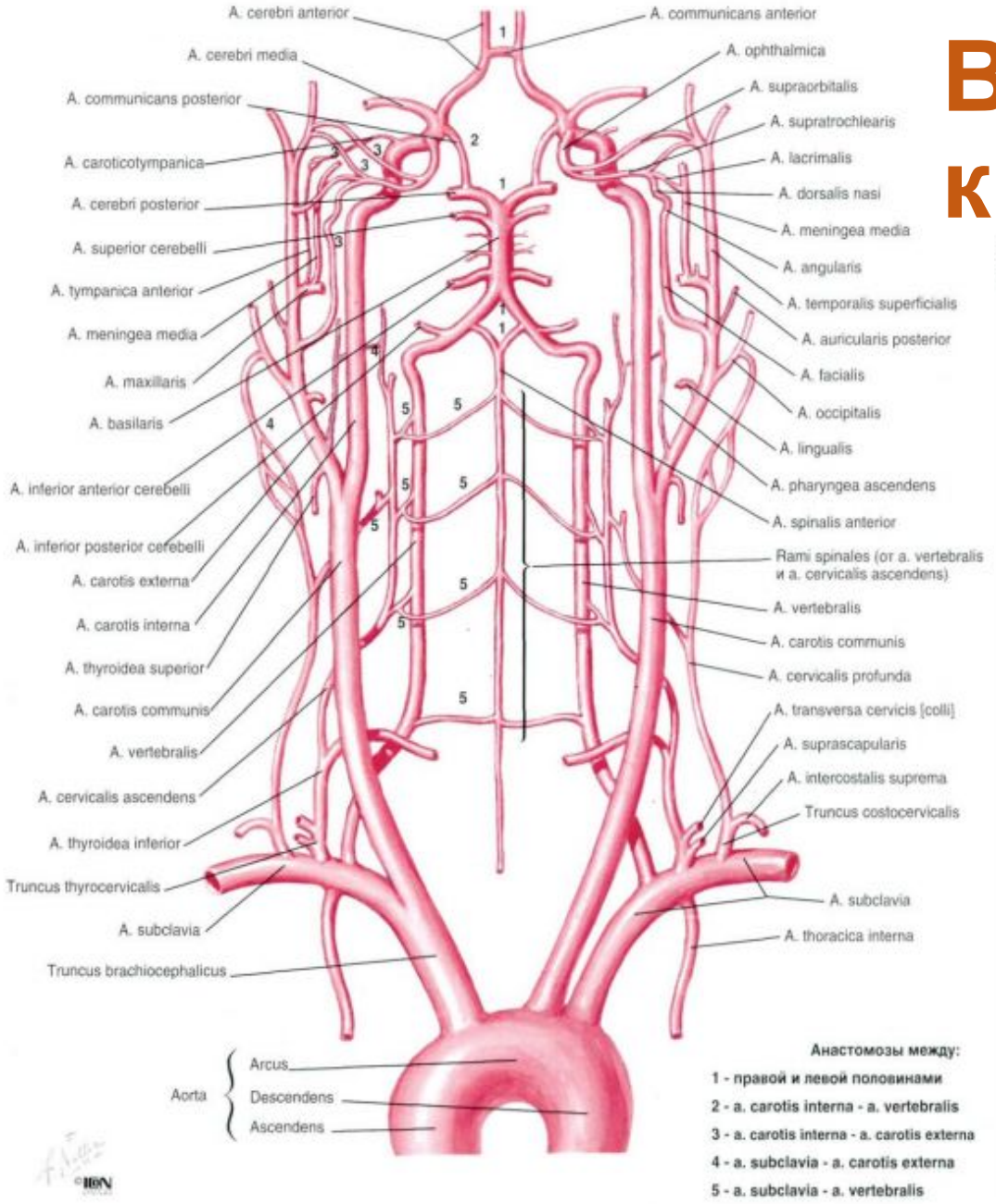

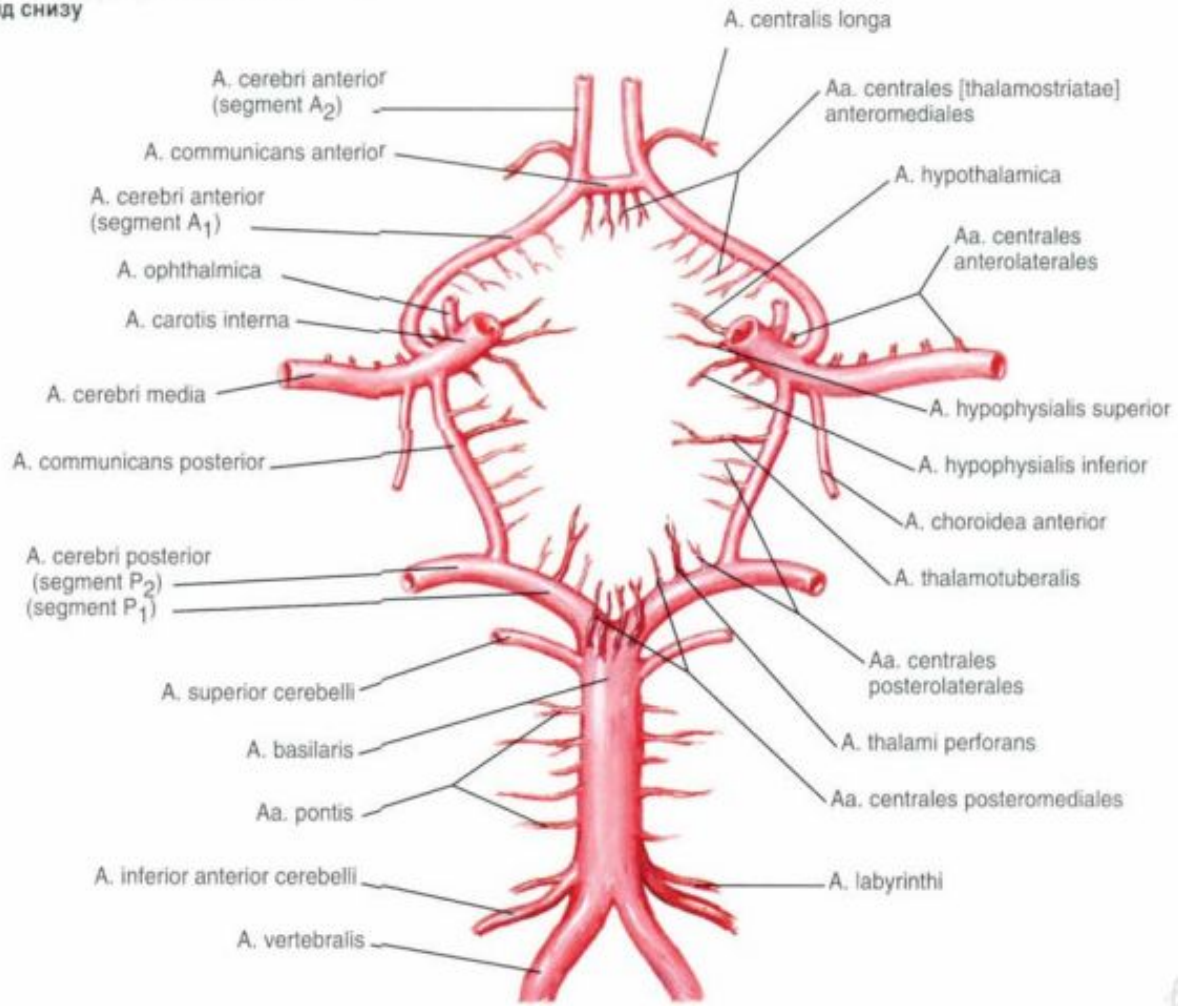

Взаимоотношения кровеносных сосудов с другими анатомическими структурами: вид снизу

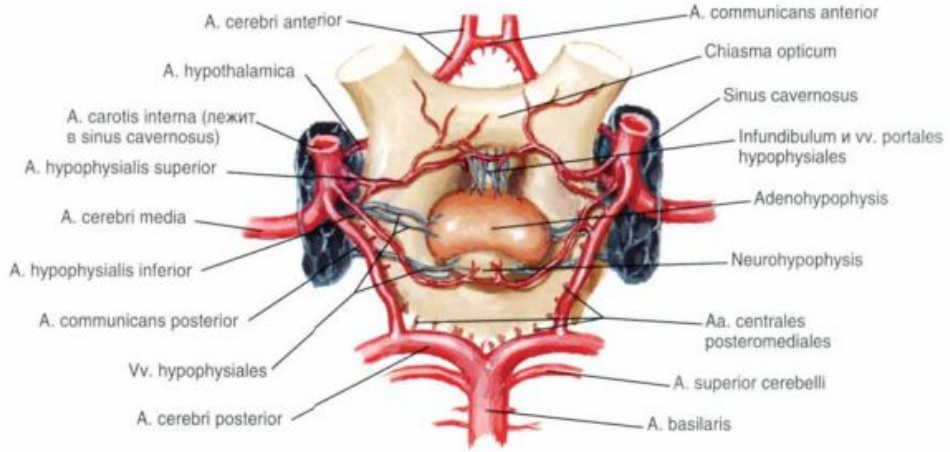

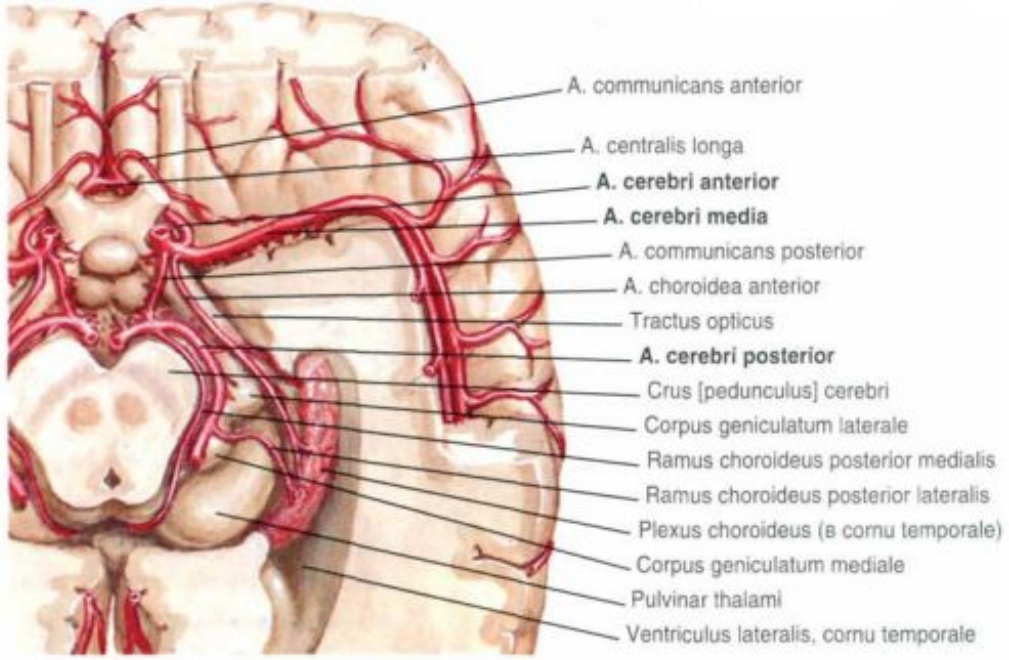

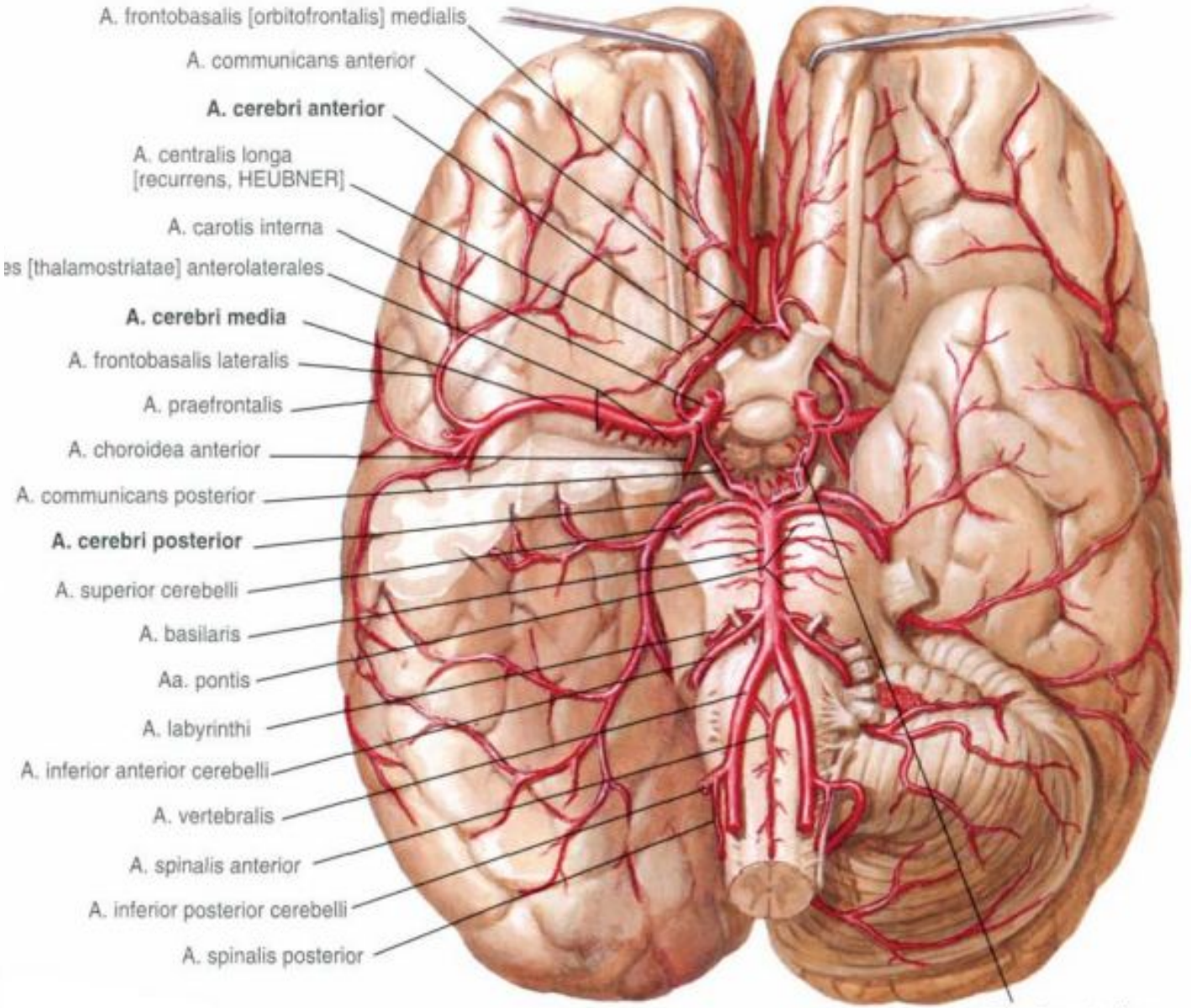

Circulus arteriosus cerebri (Виллизия круг) обозначен пунктирной линией

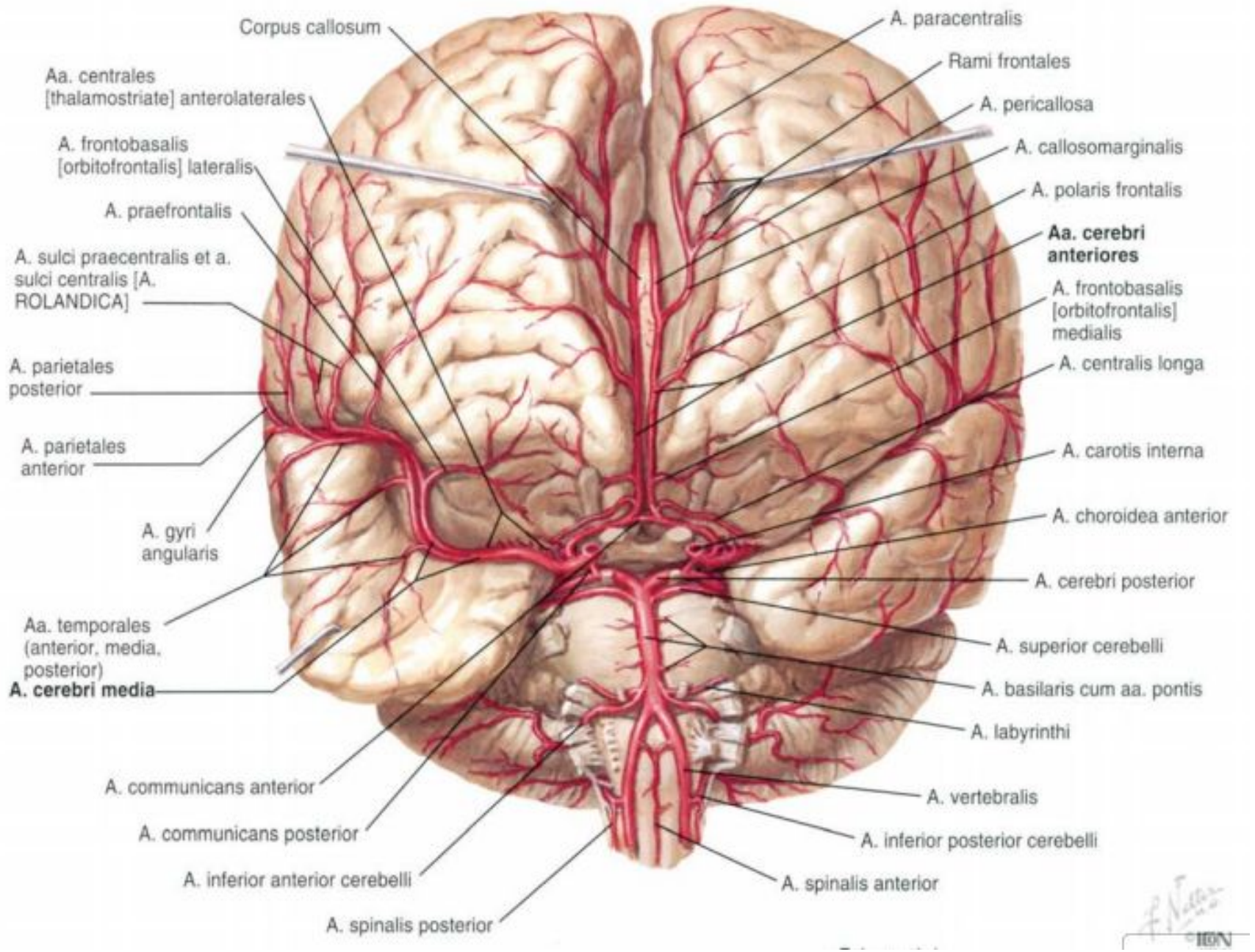
Corpus callosum
Aa. centrales [thalamostriate] anterolaterales
A. frontobasalis [orbitofrontalis] lateralis
A. praefrontalis
A. sulci praecentralis et a. sulci centralis [A. ROLANDICA]
A. parietales posterior
A. parietales anterior
A. gyri angularis
Aa. temporales (anterior, media, posterior)
A. cerebri media
A. communicans anterior
A. communicans posterior
A. inferior anterior cerebelli
A. spinalis posterior
A. paracentralis
Rami frontales
A. pericallosa
A. callosomarginalis
A. polaris frontalis
Aa. cerebri anteriores
A. frontobasalis [orbitofrontalis] medialis
A. centralis longa
A. carotis interna
A. choroidea anterior
A. cerebri posterior
A. superior cerebelli
A. basilaris cum aa. pontis
A. labyrinthi
A. vertebralis
A. inferior posterior cerebelli
A. spinalis anterior

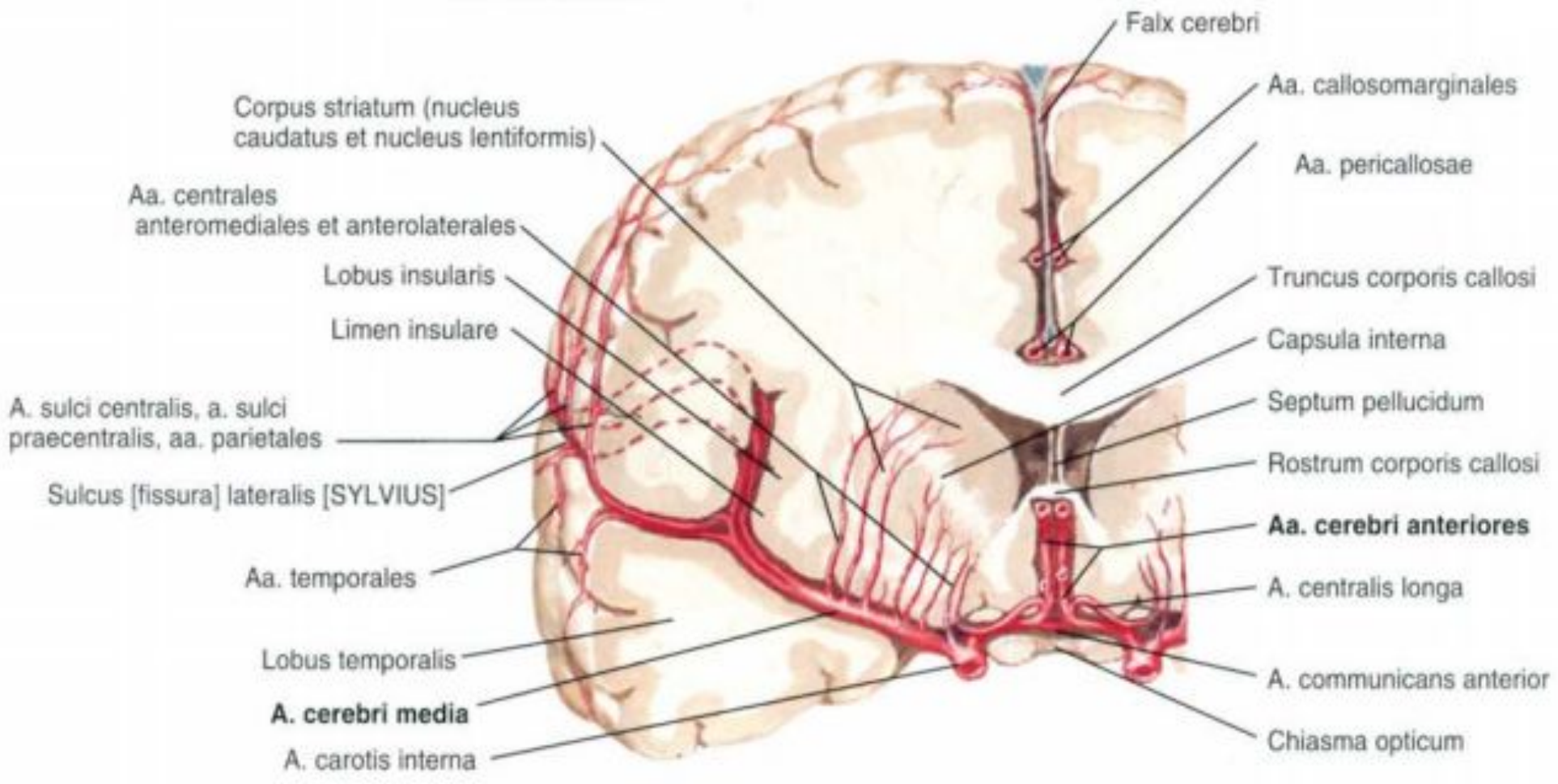
Falx cerebri
Aa. callosomarginales
Aa. pericallosae
Corpus striatum (nucleus caudatus et nucleus lentiformis)
Aa. centrales anteromediales et anterolaterales
Lobus insularis
Limen insulare
Truncus corporis callosi
Capsula interna
Septum pellucidum
Rostrum corporis callosi
A. sulci centralis, a. sulci praecentralis, aa. parietales
Sulcus [fissura] lateralis [SYLVIUS]
Aa. cerebri anteriores
A. centralis longa
Aa. temporales
Lobus temporalis
A. cerebri media
A. carotis interna
A. communicans anterior
Chiasma opticum

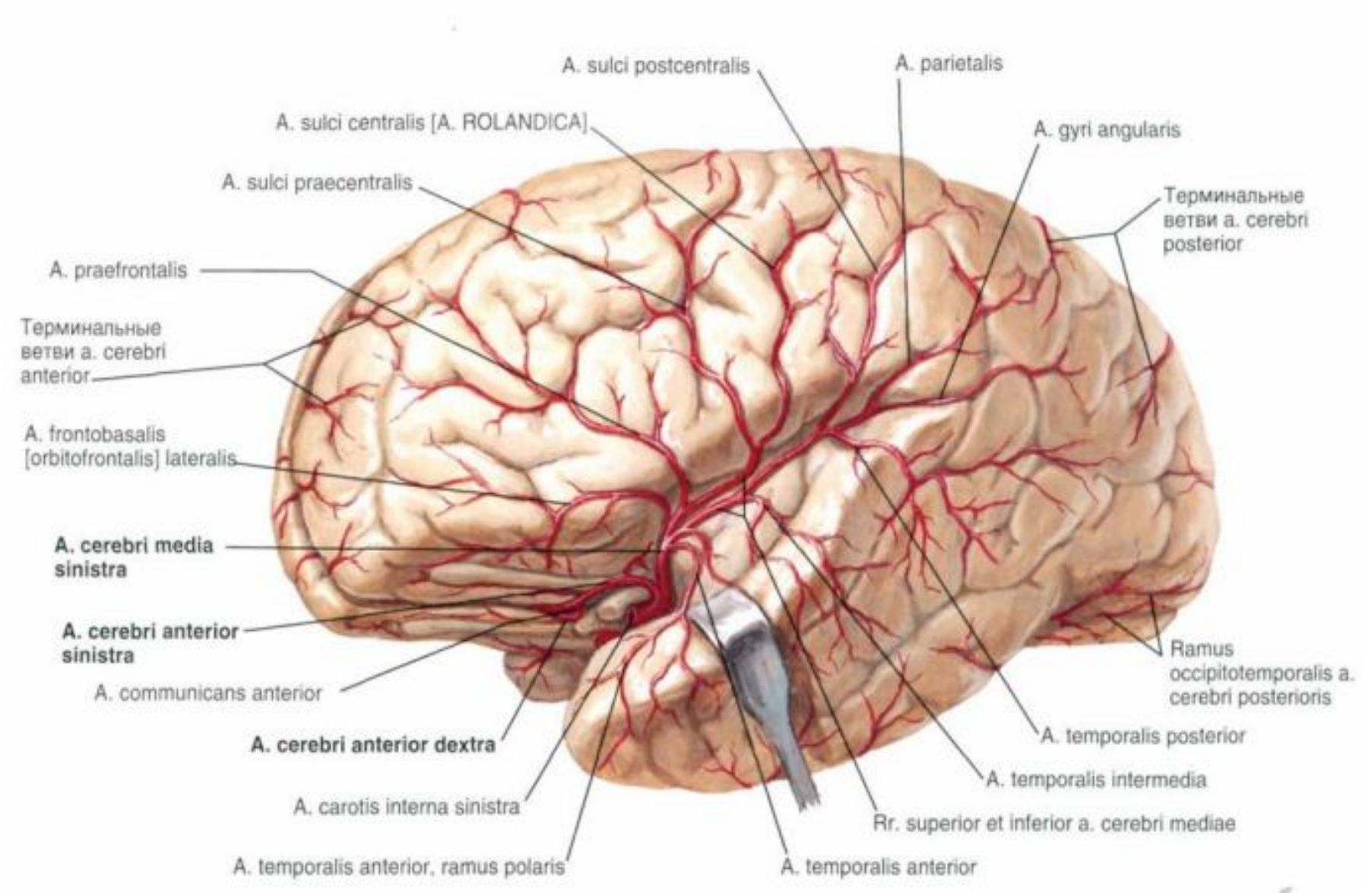
A. sulci postcentralis
A. parietalis
A. sulci centralis [A. ROLANDICA]
A. gyri angularis
A. sulci praecentralis
Терминальные ветви a. cerebri posterior
A. praefrontalis
Терминальные ветви a. cerebri anterior
A. frontobasalis [orbitofrontalis] lateralis
A. cerebri media sinistra
A. cerebri anterior sinistra
Ramus occipitotemporalis a. cerebri posterioris
A. communicans anterior
A. temporalis posterior
A. cerebri anterior dextra
A. temporalis intermedia
A. carotis interna sinistra
Rr. superior et inferior a. cerebri mediae
A. temporalis anterior, ramus polaris
A. temporalis anterior

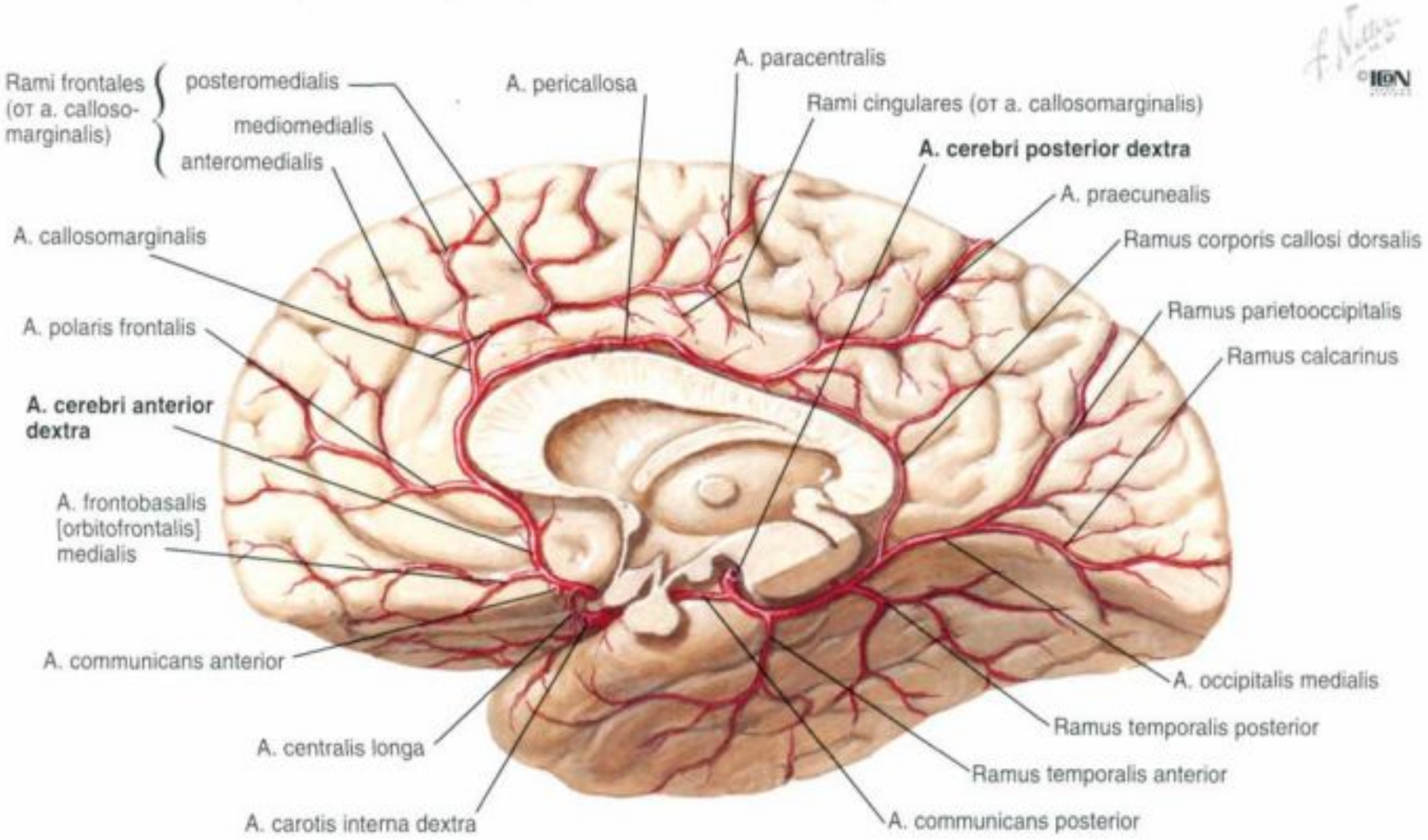
Rami frontales (от a. calloso-marginalis)
posteromedialis
mediomedialis
anteromedialis
A. pericallosa
A. paracentralis
Rami cingulares (от a. callosomarginalis)
A. cerebri posterior dextra
A. praecunealis
Ramus corporis callosi dorsalis
Ramus parietooccipitalis
Ramus calcarinus
A. callosomarginalis
A. polaris frontalis
A. cerebri anterior dextra
A. frontobasalis [orbitofrontalis] medialis
A. communicans anterior
A. centralis longa
A. carotis interna dextra
A. occipitalis medialis
Ramus temporalis posterior
Ramus temporalis anterior
A. communicans posterior

Подключичная артерия

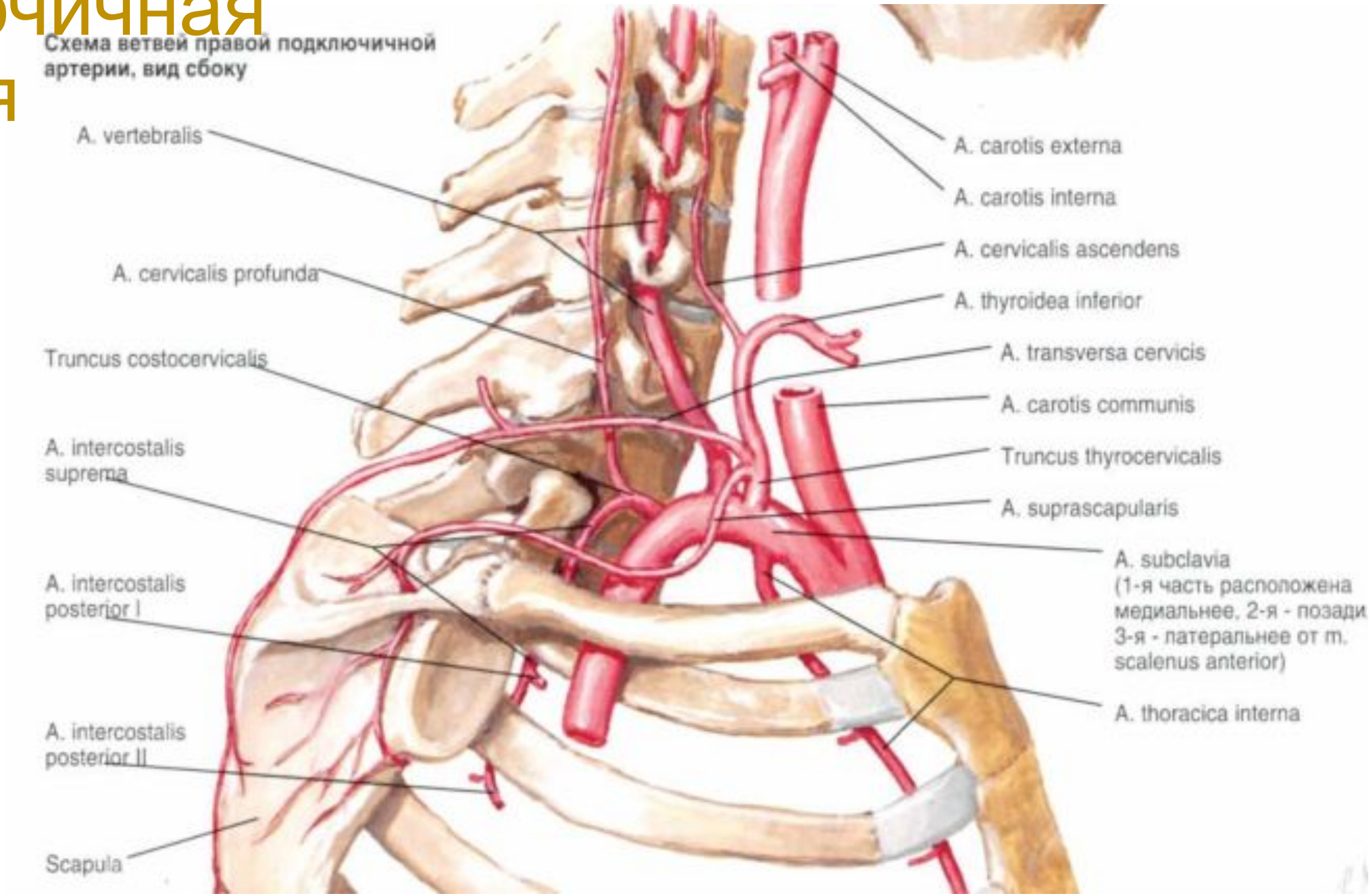

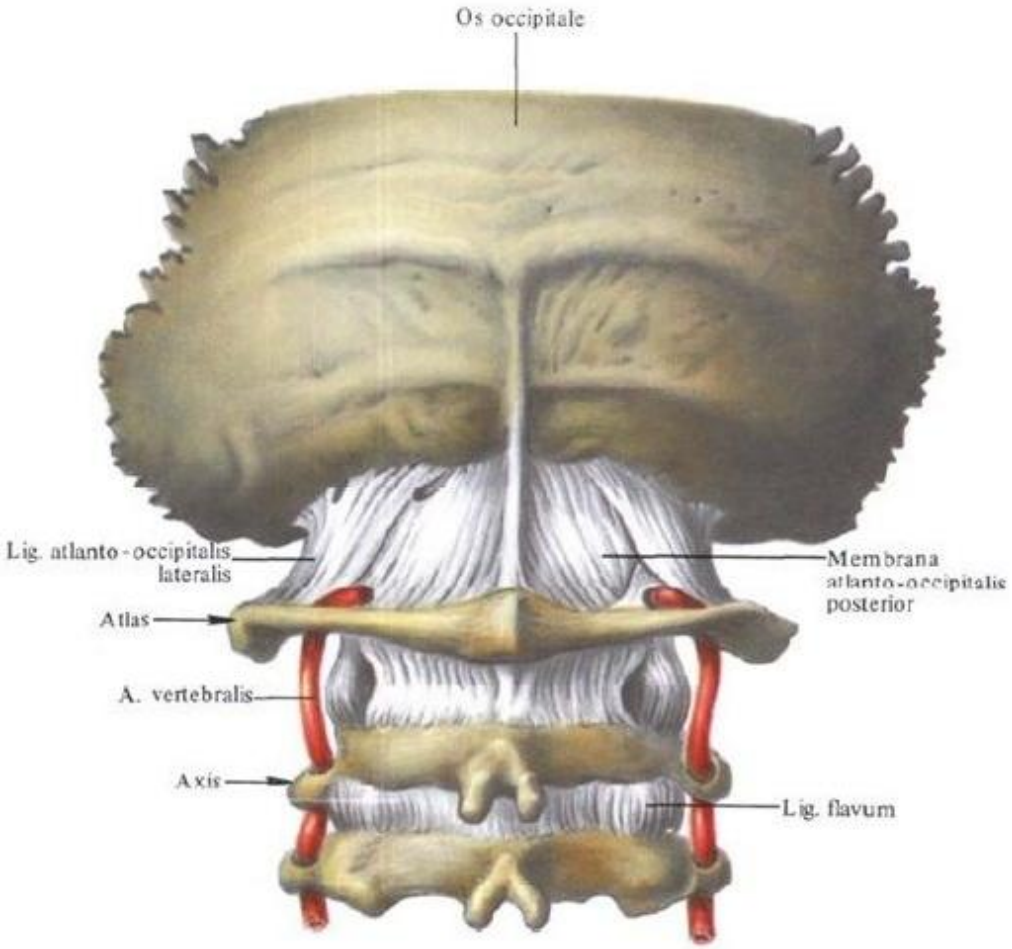
Os occipitale
Lig. atlanto-occipitalis lateralis
Atlas
A. vertebralis
Axis
Membrana atlanto-occipitalis posterior
Lig. flavum

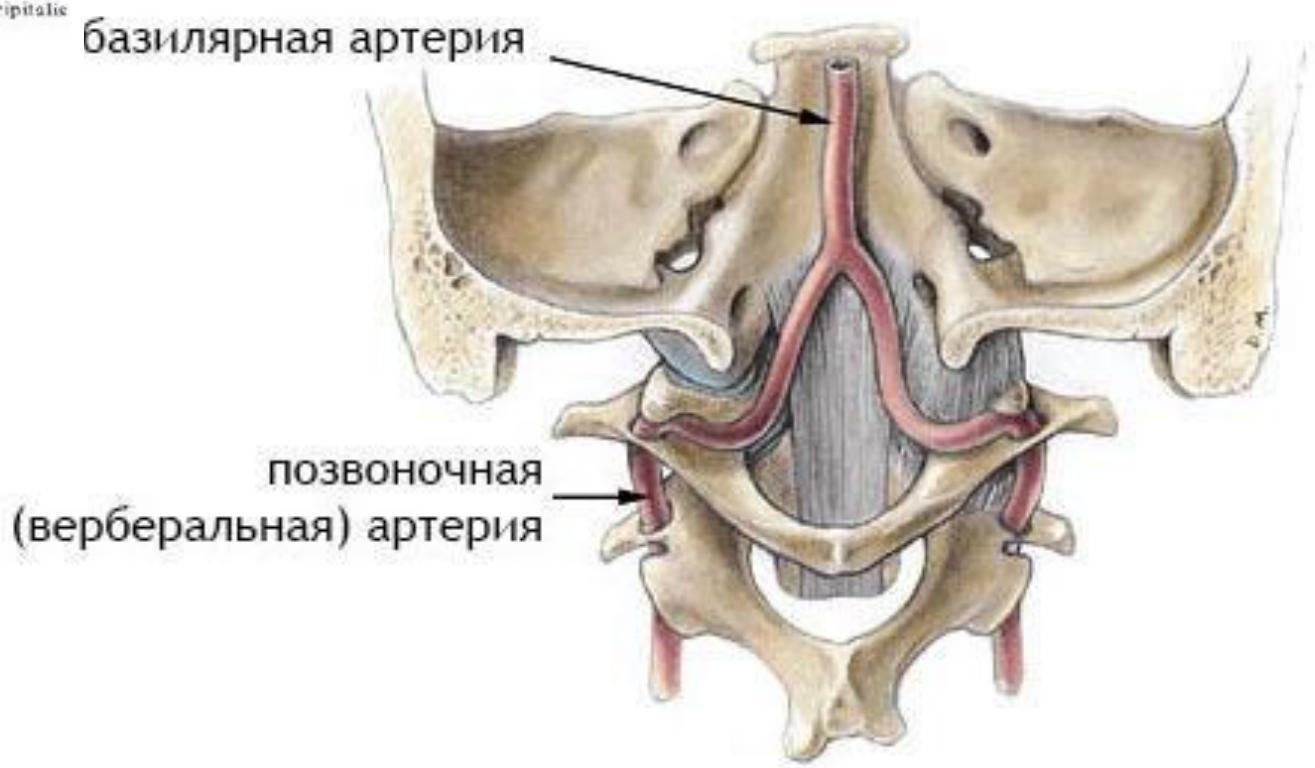
базилярная артерия
позвоночная
(верберальная) артерия

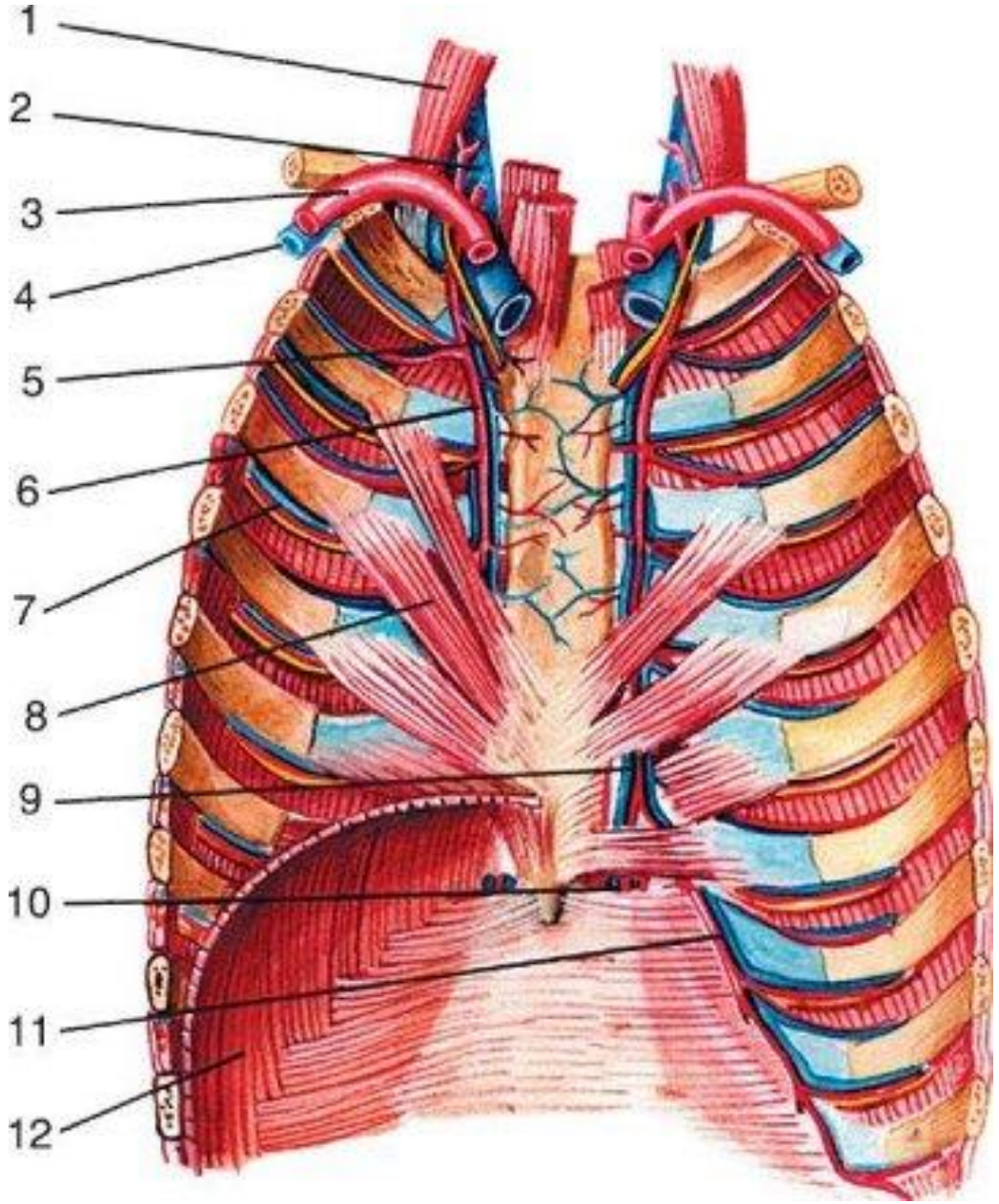
1
2
3
4
5
6
7
8
9
10
11
12

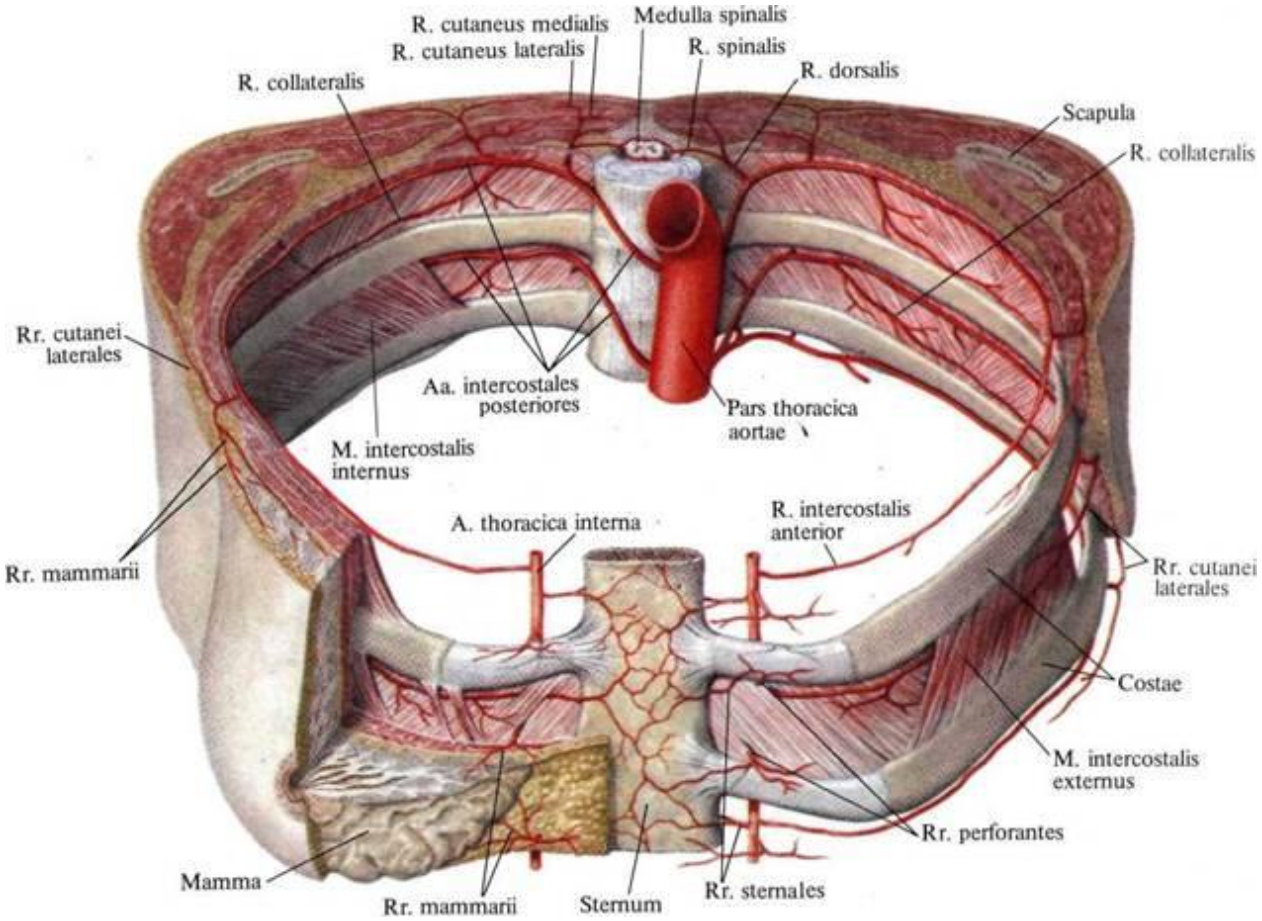
R. cutaneus medialis
R. cutaneus lateralis
Medulla spinalis
R. spinalis
R. dorsalis
R. collateralis
Scapula
R. collateralis
Rr. cutanei laterales
Aa. intercostales posteriores
Pars thoracica aortae
M. intercostalis internus
A. thoracica interna
R. intercostalis anterior
Rr. mammarii
Rr. cutanei laterales
Costae
M. intercostalis externus
Rr. perforantes
Mamma
Rr. mammarii
Sternum
Rr. sternales

Сердце

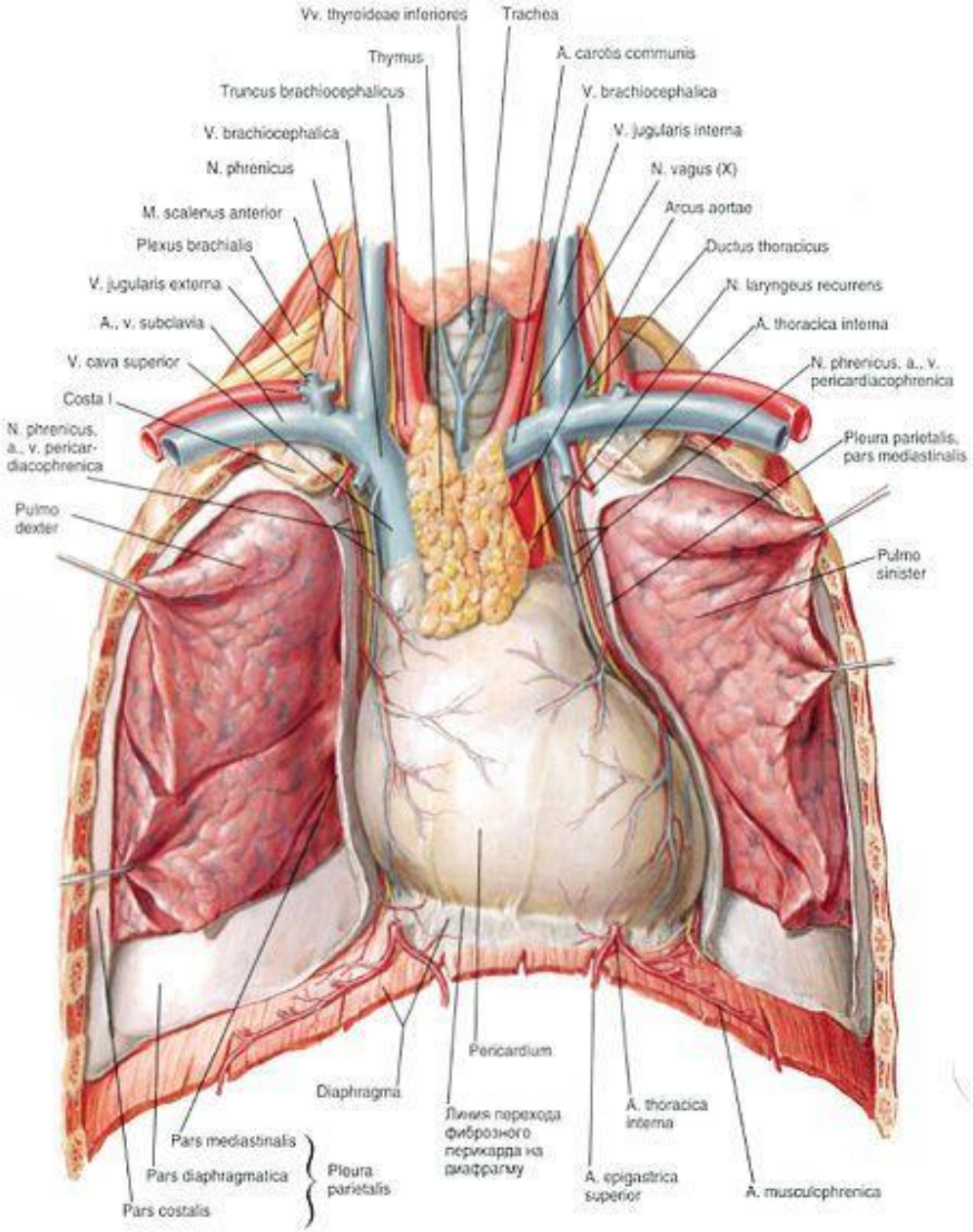
Vv. thyroideae inferiores
Trachea
Thymus
A. carotis communis
Truncus brachiocephalicus
V. brachiocephalica
V. brachiocephalica
V. jugularis interna
N. phrenicus
N. vagus (X)
M. scalenus anterior
Arcus aortae
Plexus brachialis
Ductus thoracicus
V. jugularis externa
N. laryngeus recurrens
A., v. subclavia
A. thoracica interna
V. cava superior
N. phrenicus, a., v. pericardiacophrenica
Costa I
N. phrenicus, a., v. pericardiacophrenica
Pleura parietalis, pars mediastinalis
Pulmo dexter
Pulmo sinister
Pericardium
Diaphragma
Линия перехода фиброзного перикарда на диафрагму
A. thoracica interna
Pars mediastinalis
Pars diaphragmatica
Pars costalis
Pleura parietalis
A. epigastrica superior
A. musculophrenica

Конец