эпителий - плотный контакт



Общую концепцию тестового контроля изложил один из основоположников внедрения средств мультимедиа в учебном процессе в России, профессор **Данилов Р.К.**, заведующий кафедрой гистологии Санкт-Петербургской Военно-медицинской академии .

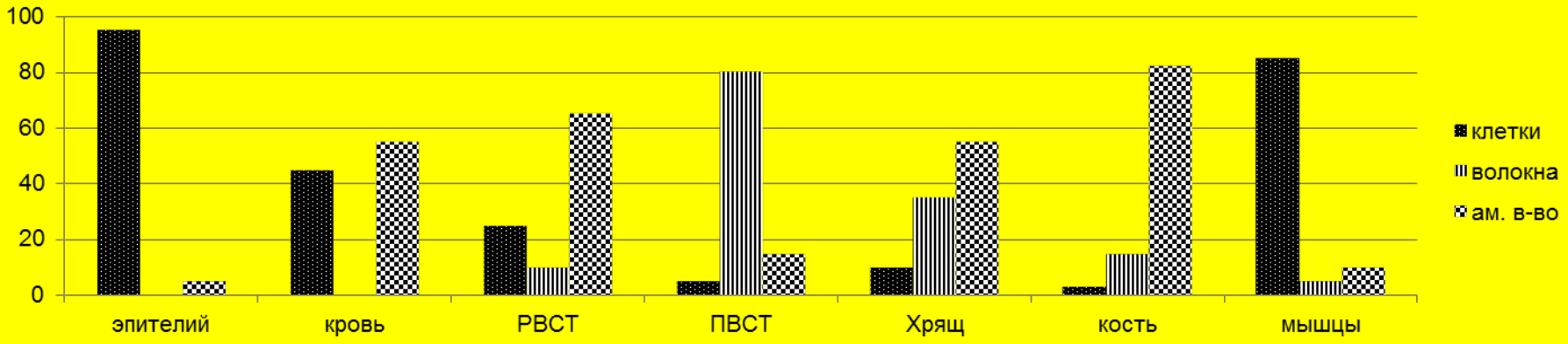
100
80
60
40
20
0
эпителий
кровь
РВСТ
ПВСТ
Хрящ
кость
мышцы
клетки
волокна
ам. в-во

Photosynthesis:

СОЕДИНИТЕЛЬНАЯ ТКАНЬ

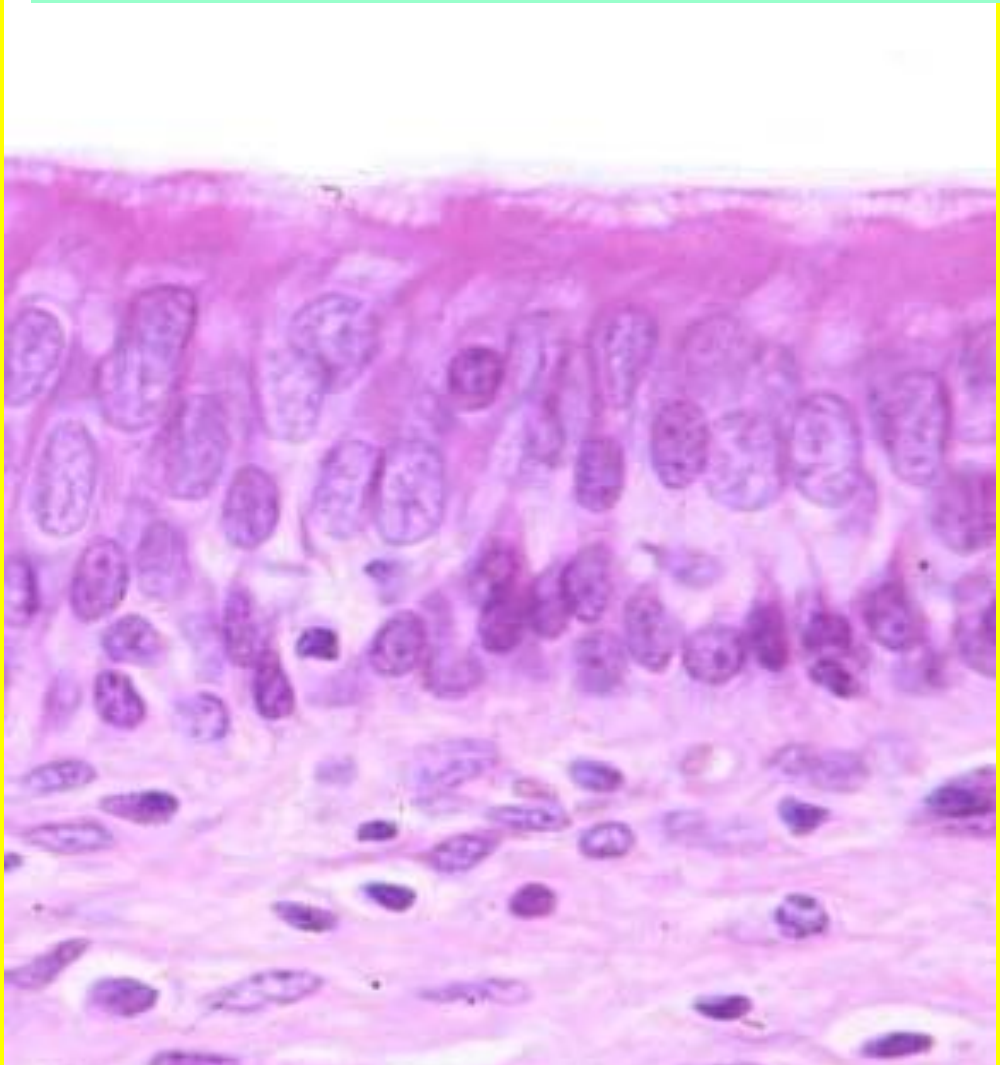

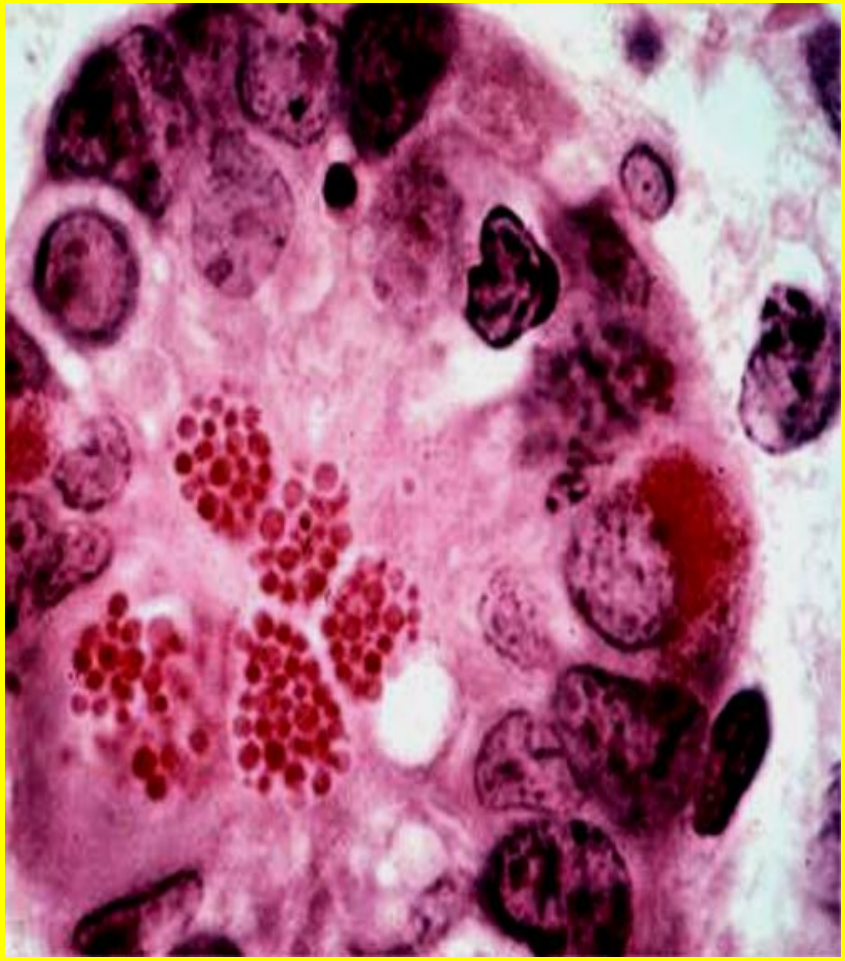

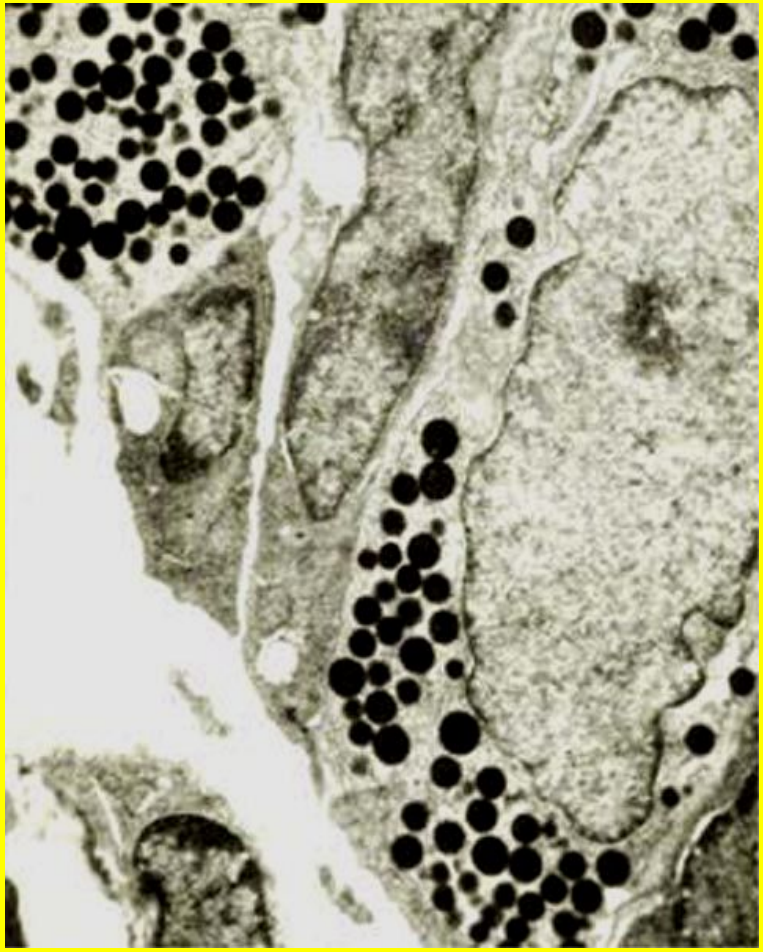

~~1.~~

~~2.~~

~~3.~~

День 1 утро
День 1 вечер
День 2
День 3
День 4
День 5
День 7
День 10
День 11
День 15

ПЛАСТИНКА

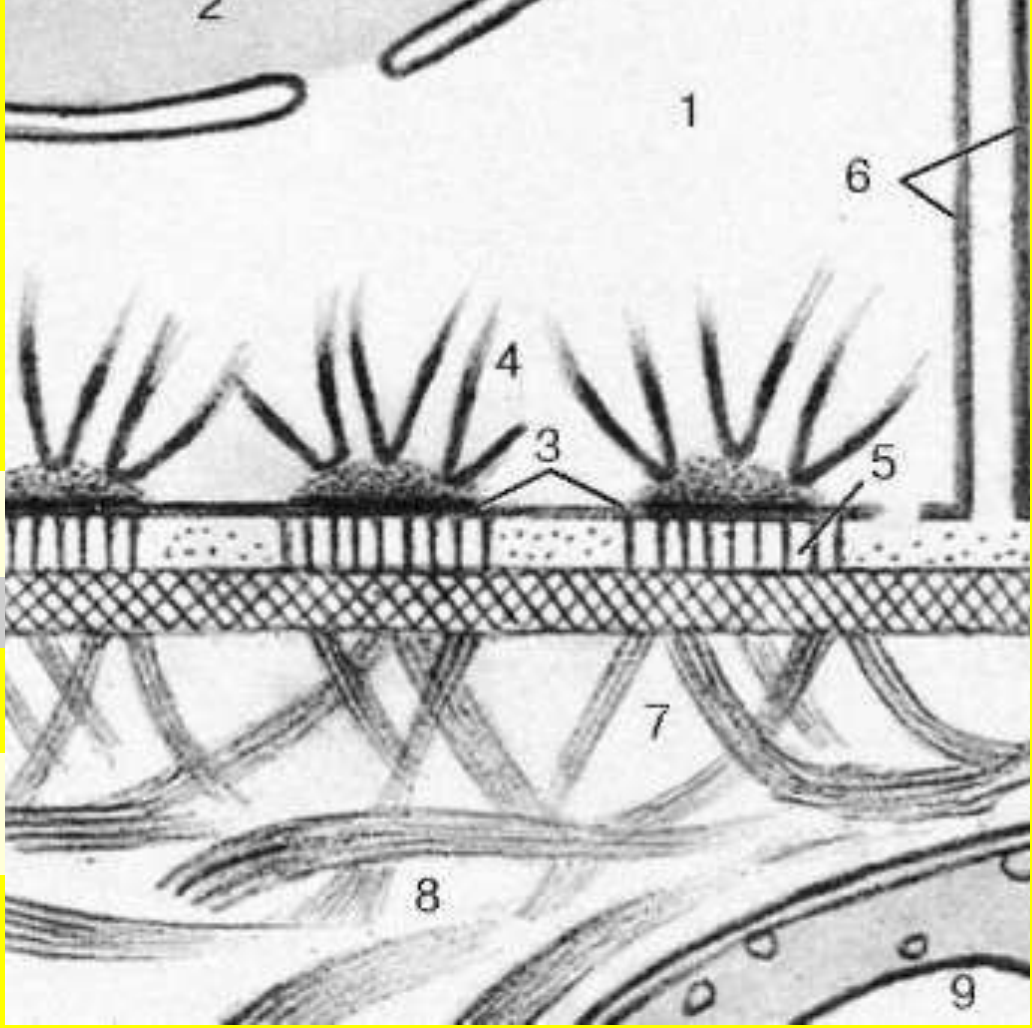

NB! НАРУШЕНИЕ ЦЕЛОСТНОСТИ БАЗАЛЬНОЙ МЕМБРАНЫ ПРЕДШЕСТВУЕТ ВОСПАЛЕНИЮ.

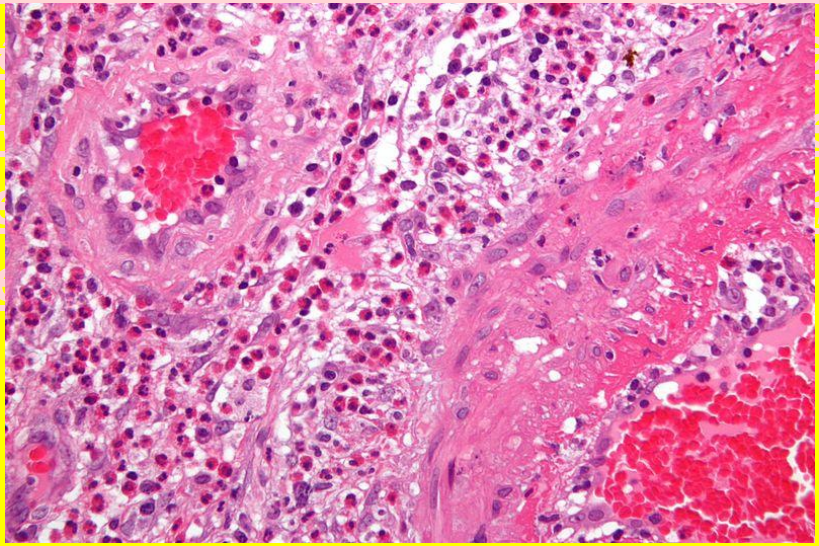



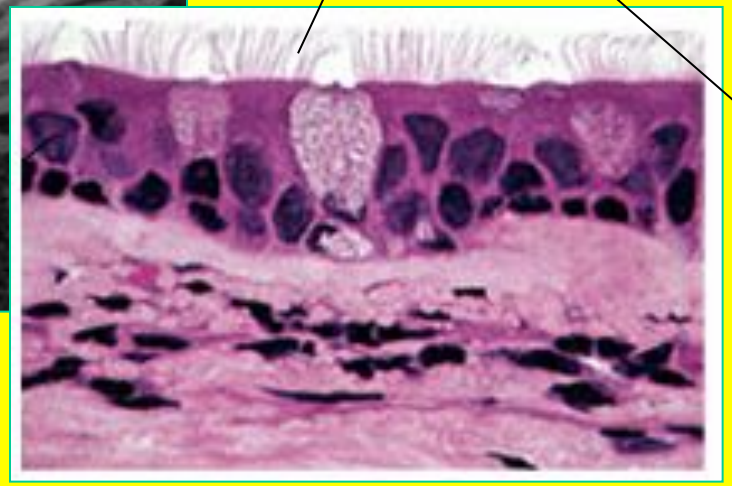

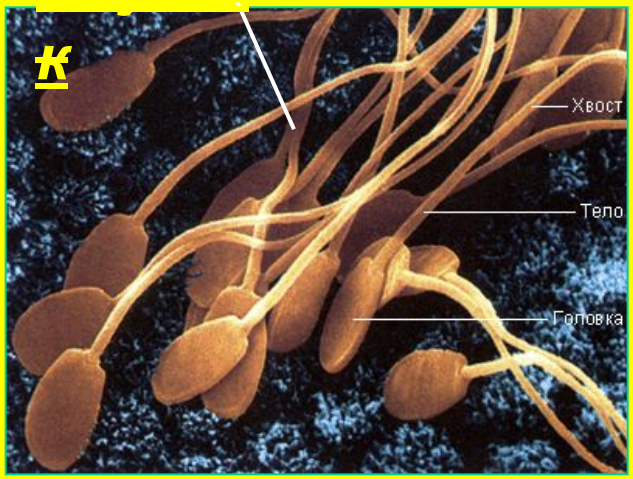
Хвост
Тело
Головка

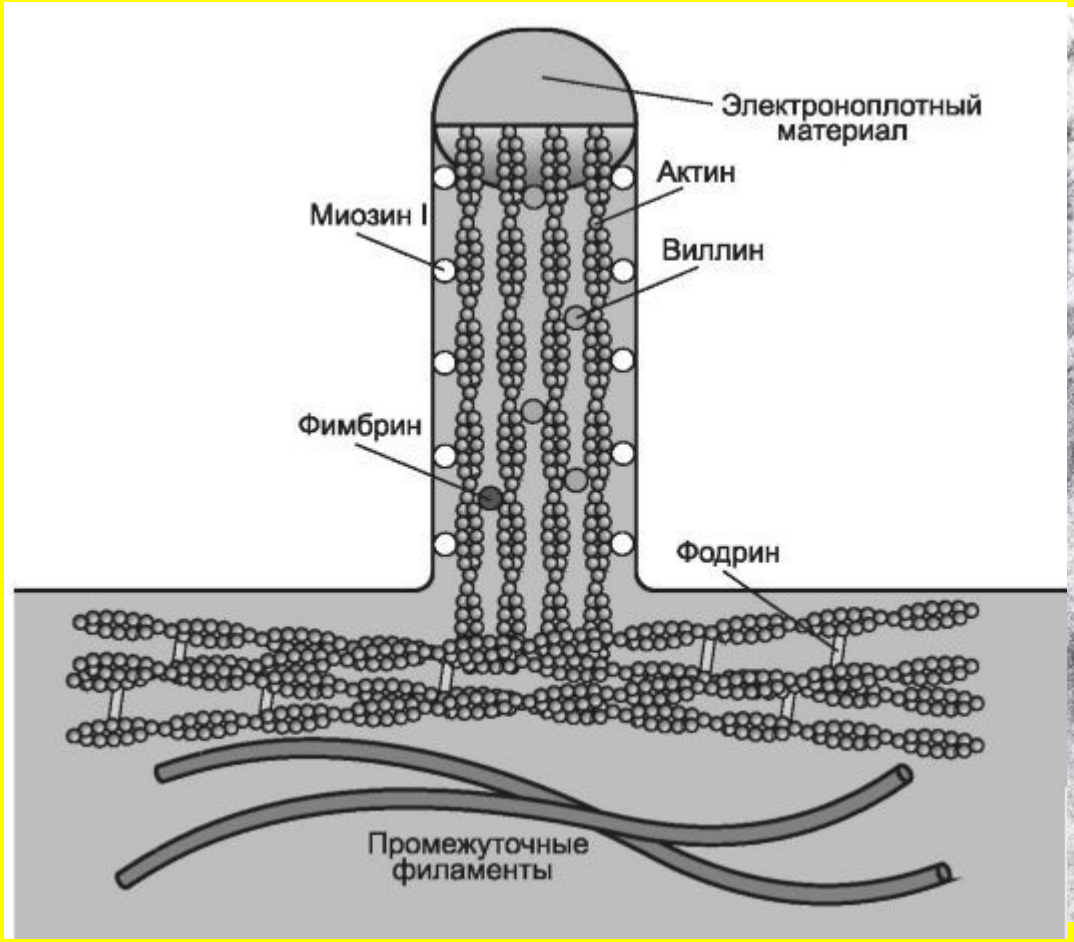
Электроноплотный материал
Актин
Миозин I
Виллин
Фимбрин
Фодрин
Промежуточные филаменты



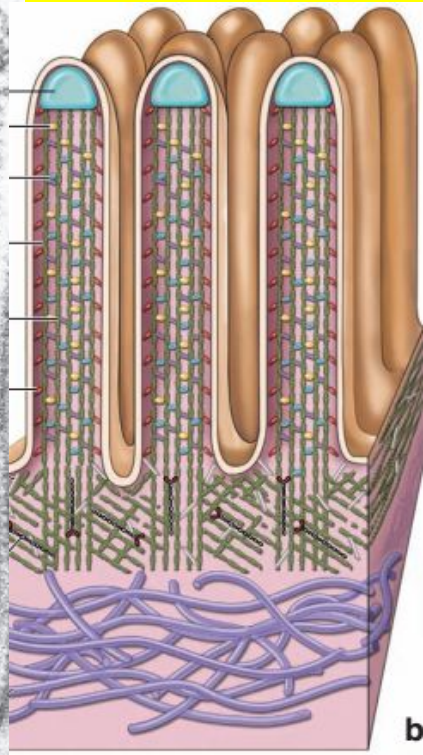
b

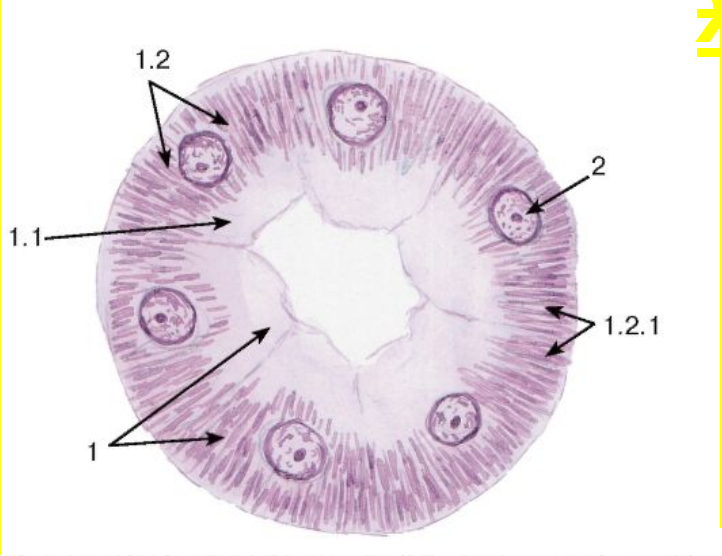
1.2
2
1.1
1.2.1
1

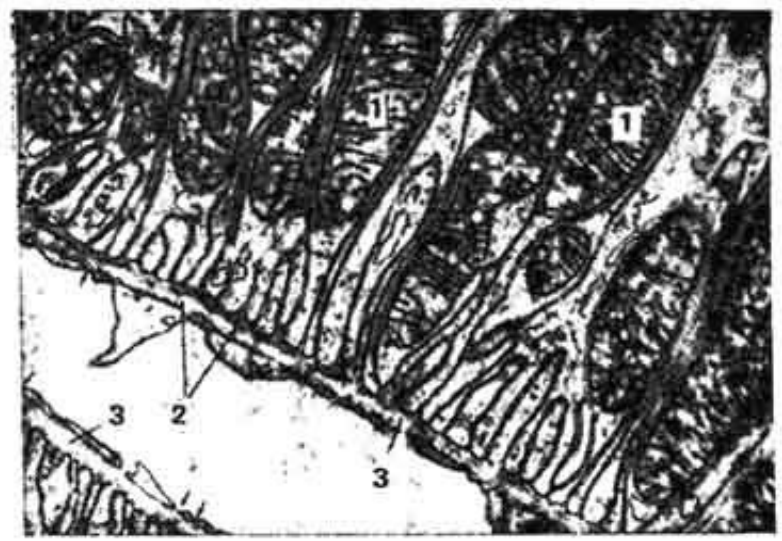
1
1
3
2
3

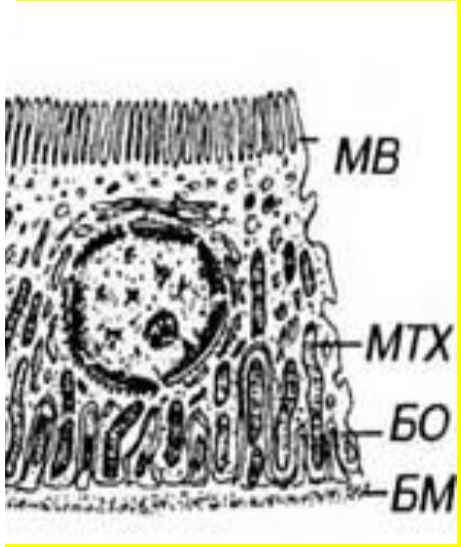
МВ
МТХ
БО
БМ

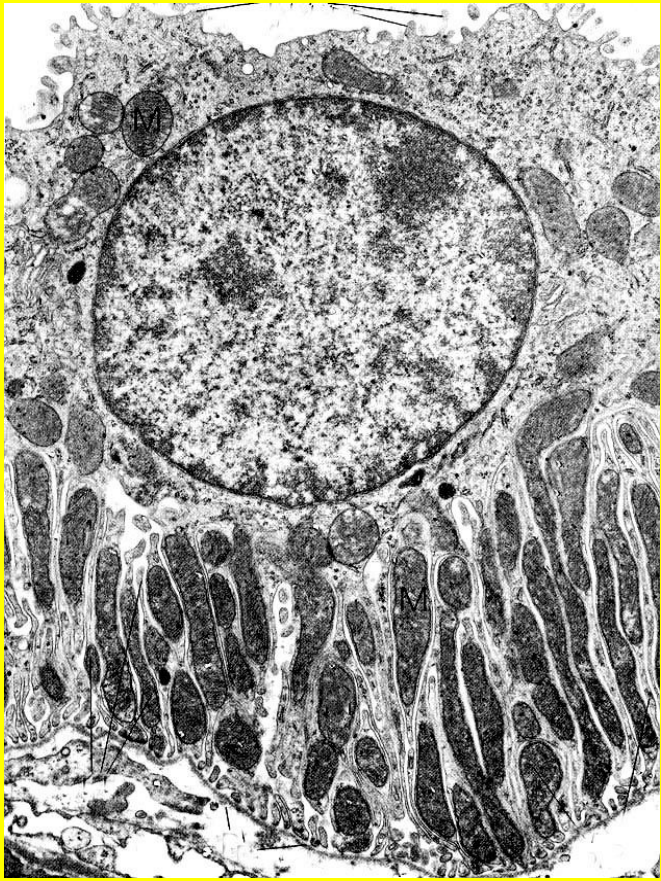
М
М

NB! У ДЕТЕЙ ЭПИТЕЛИЙ СЛАБО ДИФФЕРЕНЦИРОВАН, А ЗНАЧИТ - НЕ ПОЛНОСТЬЮ ФУНКЦИОНАЛЕН.

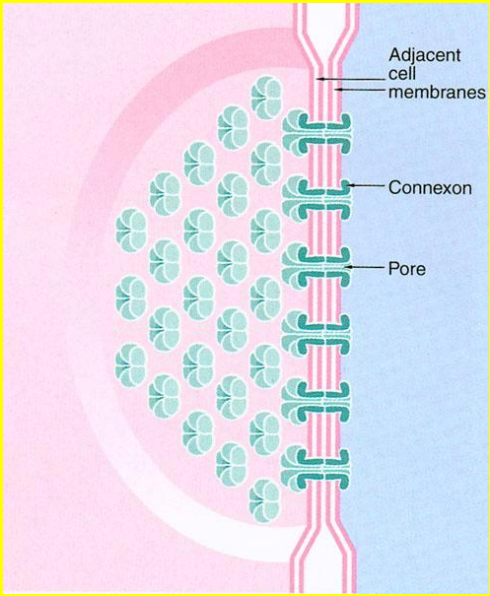
Adjacent cell membranes
Connexon
Pore

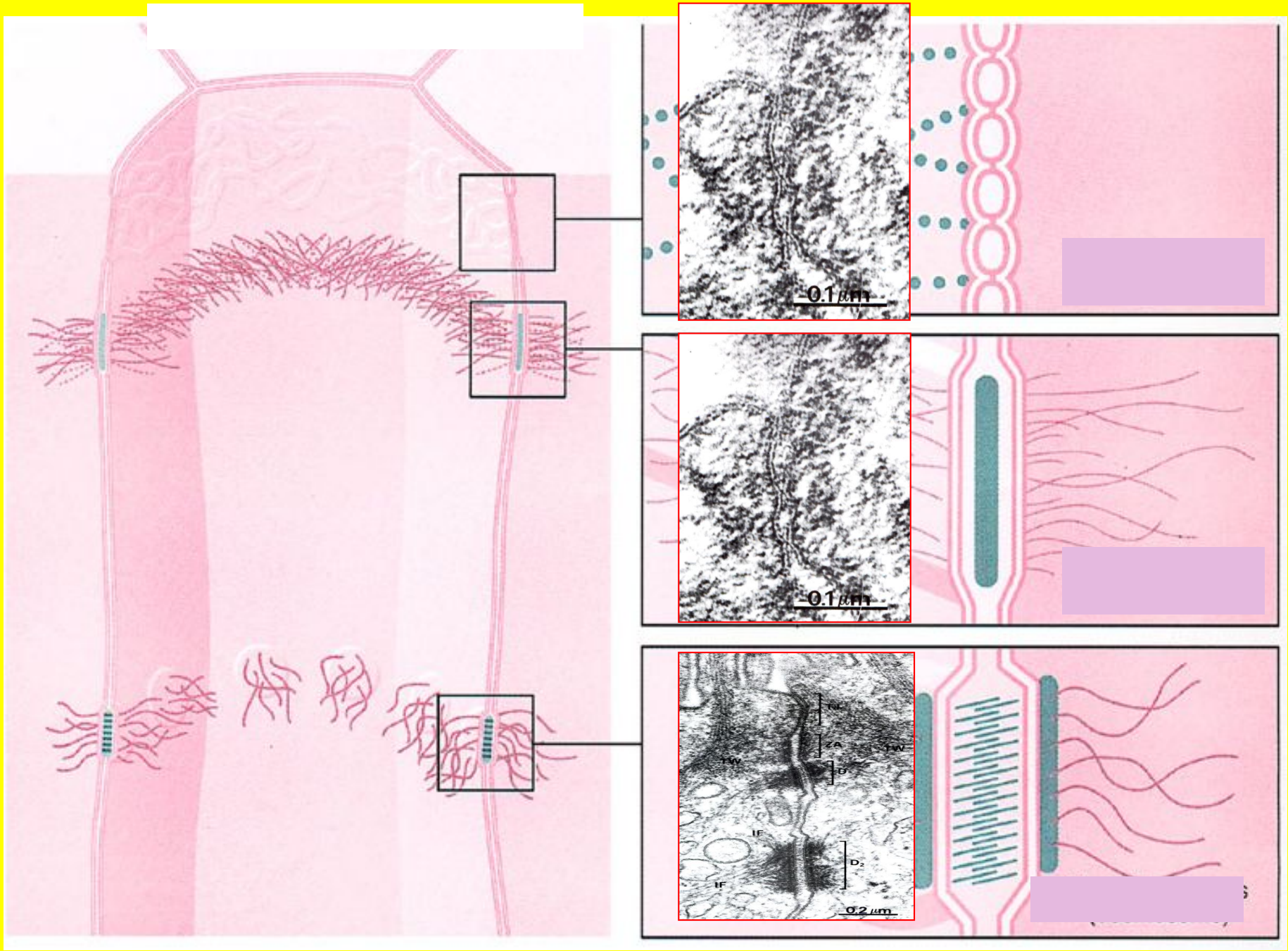
0.1 μm
0.1 μm
TW
ZA
D
TW
IF
D2
IF
0.2 μm

Figure 4-2 Cell Junctions.

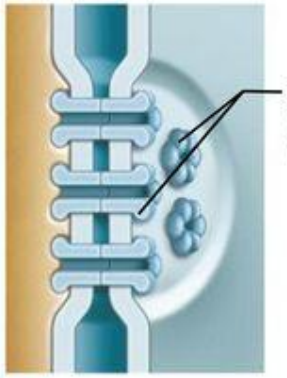

b Gap junctions permit the free diffusion of ions and small molecules between two cells.

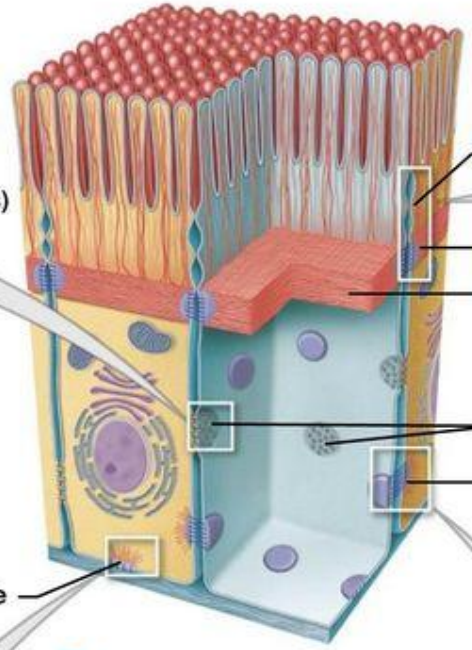

a This is a diagrammatic view of an epithelial cell, showing the major types of intercellular connections.

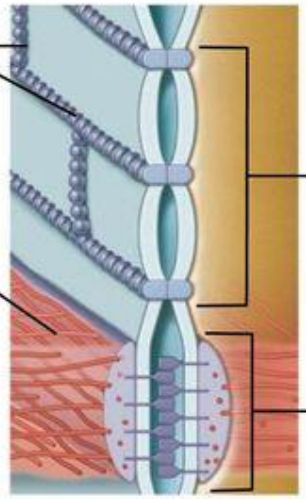

c A tight junction is formed by the fusion of the outer layers of two plasma membranes. Tight junctions prevent the diffusion of fluids and solutes between the cells. A continuous adhesion belt lies deep to the tight junction. This belt is tied to the microfilaments of the terminal web.

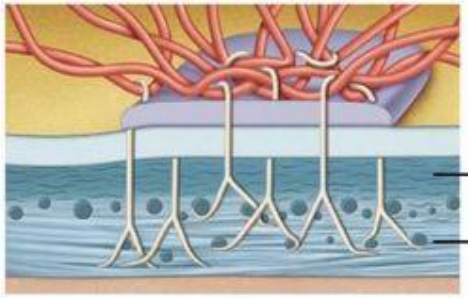

e Hemidesmosomes attach a cell to extracellular structures, such as the protein fibers in the basement membrane.

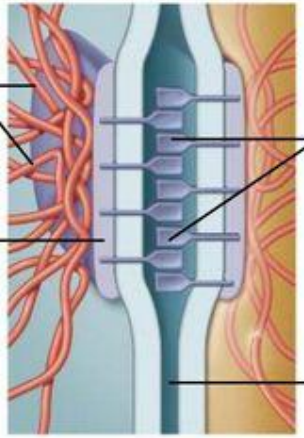

d A spot desmosome ties adjacent cells together.

© 2015 Pearson Education, Inc.

Macula Adherens (desmosome)

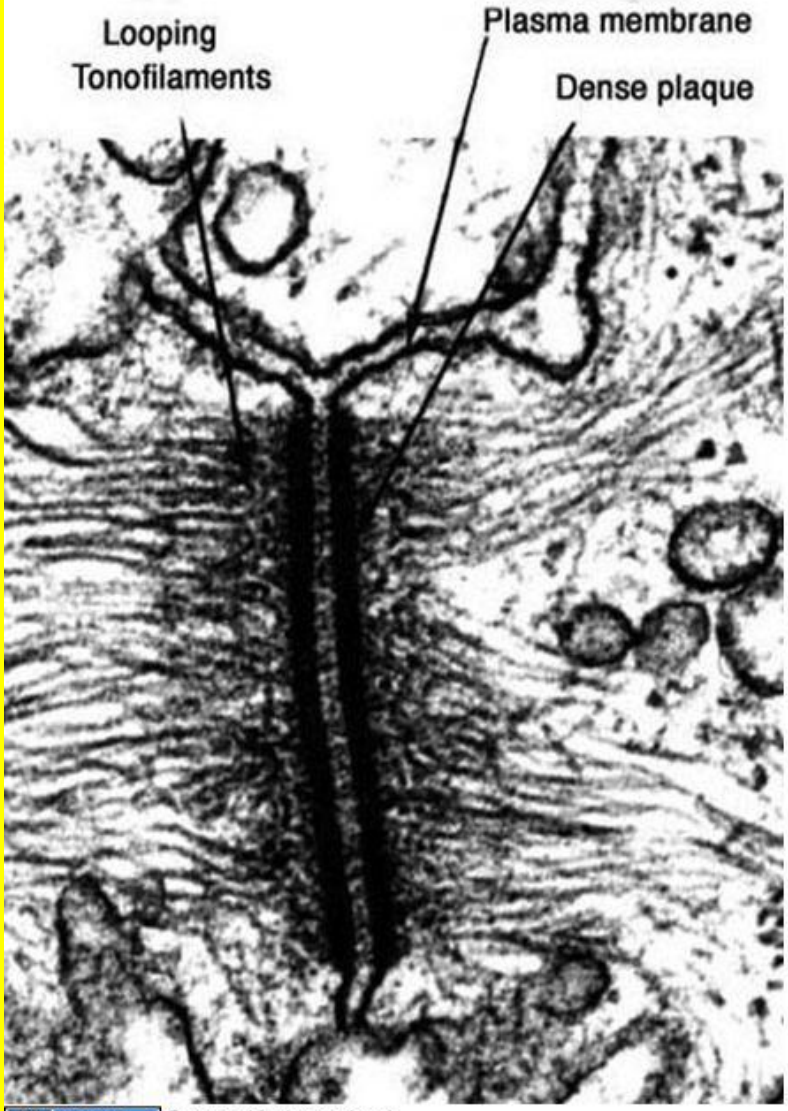

PD-INEL Source Undetermined

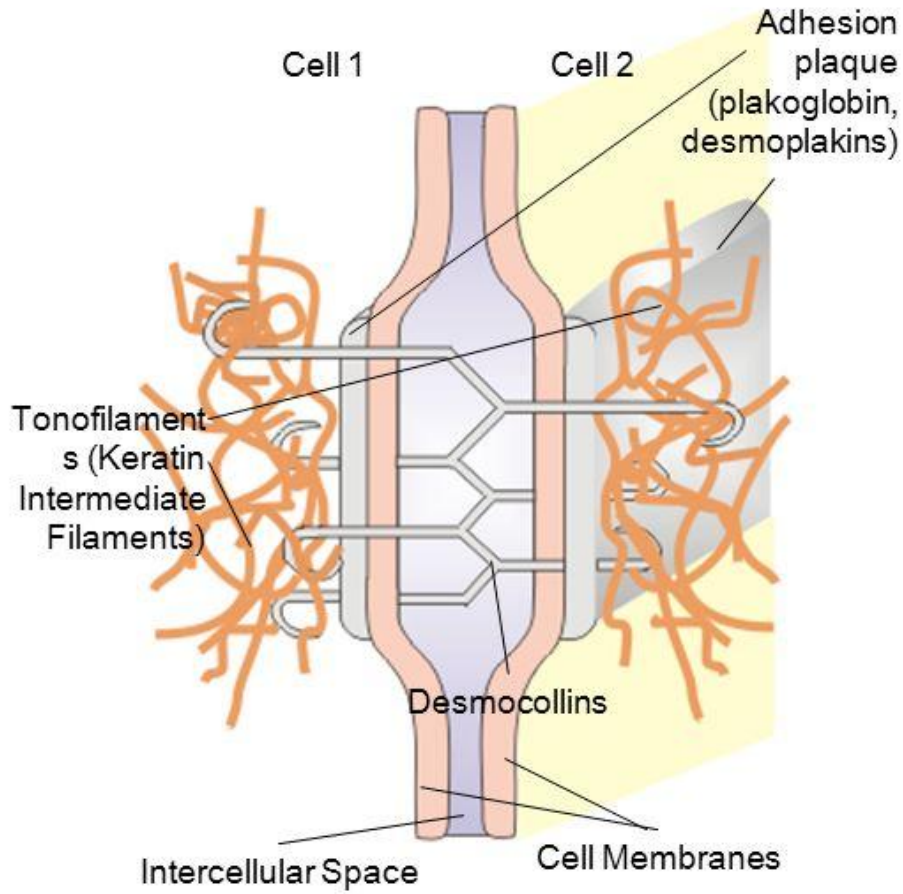

Desmosome

BY-SA Boumphreyfr, Wikimedia Commons (adapted)

ОДНОРЯДНЫЙ (**один ряд ядер**) по форме клеток: плоский, кубический, призматический.

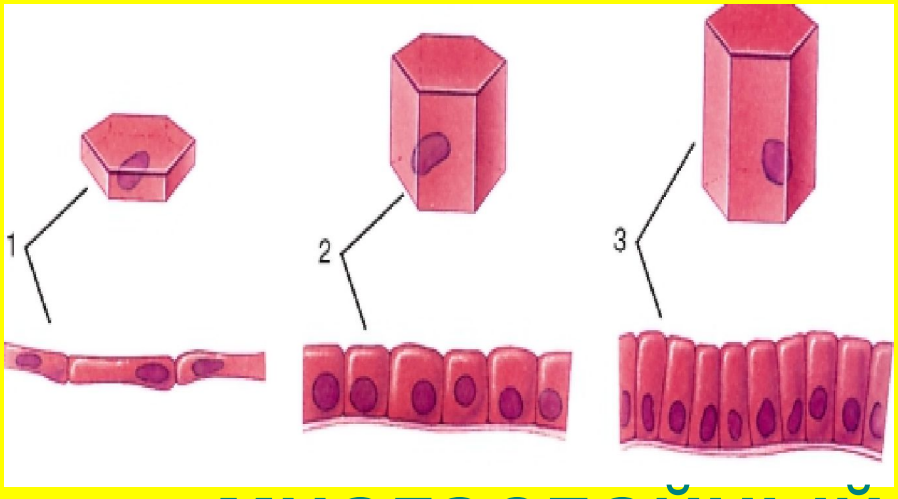

МНОГОРЯДНЫЙ (**много рядов ядер**) однослойный многорядный реснитчатый эпителий.

МНОГОСЛОЙНЫЙ (**много слоев клеток**)

многослойный плоский ороговевающий, НЕороговевающий, переходный.

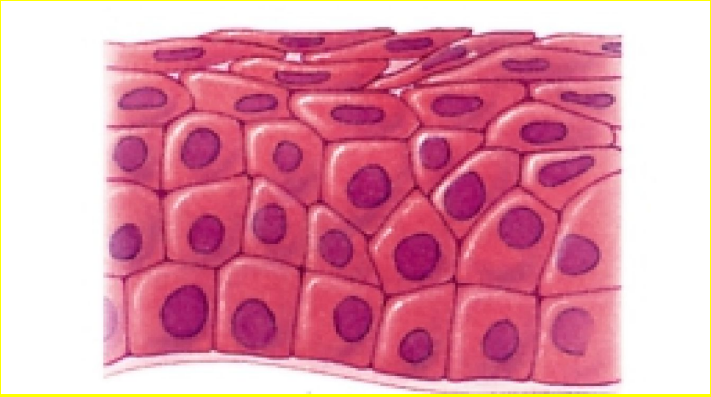

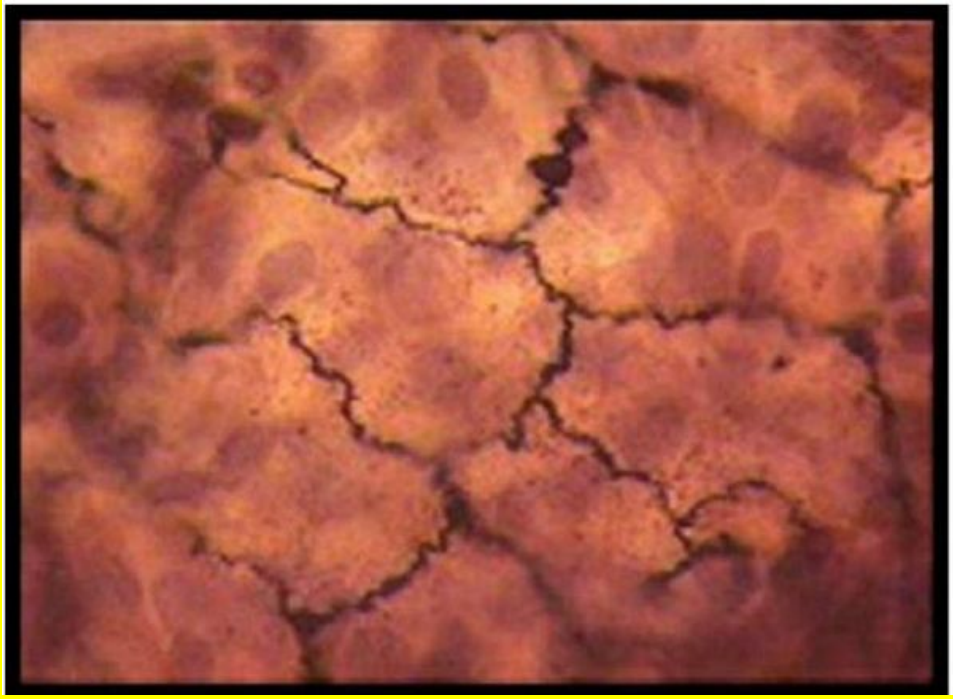

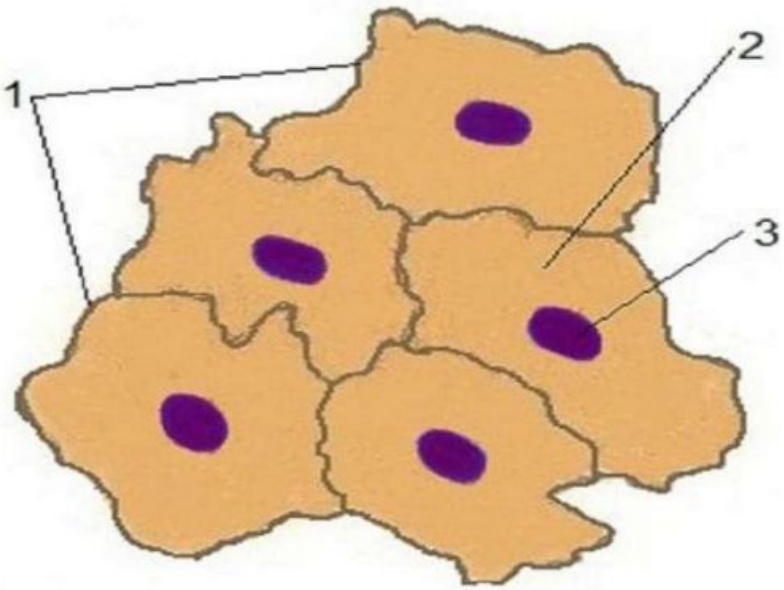
1
2
3

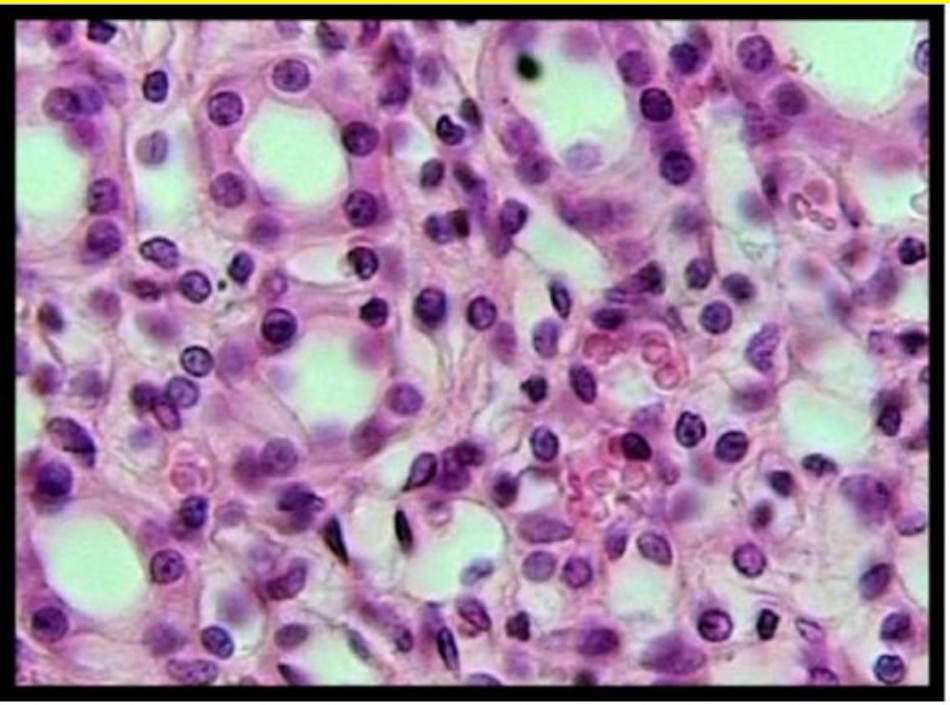

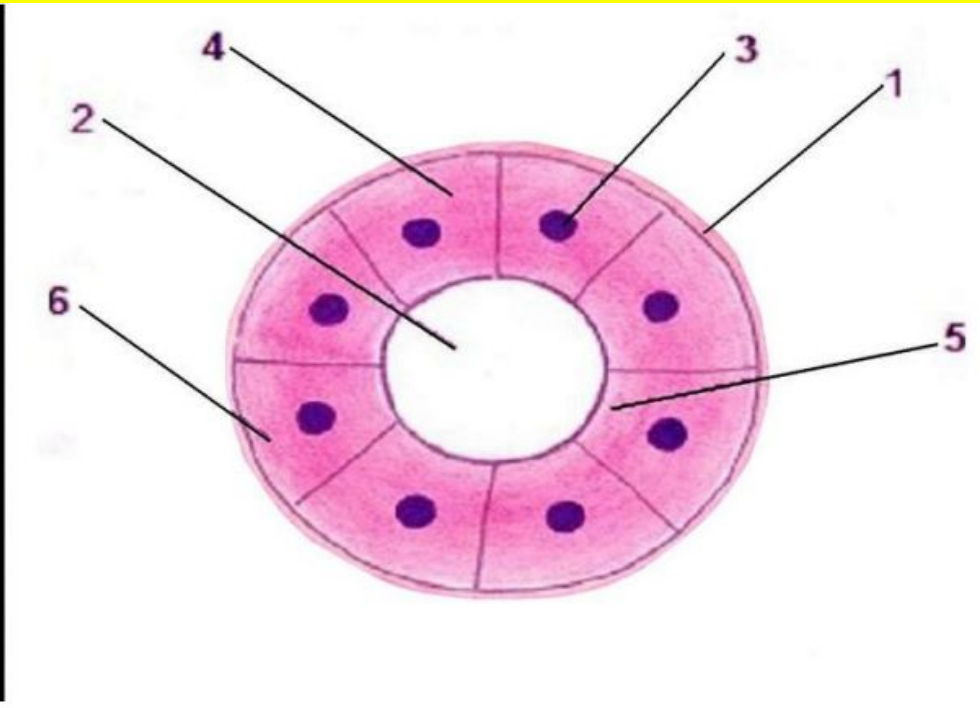
4
3
1
2
6
5

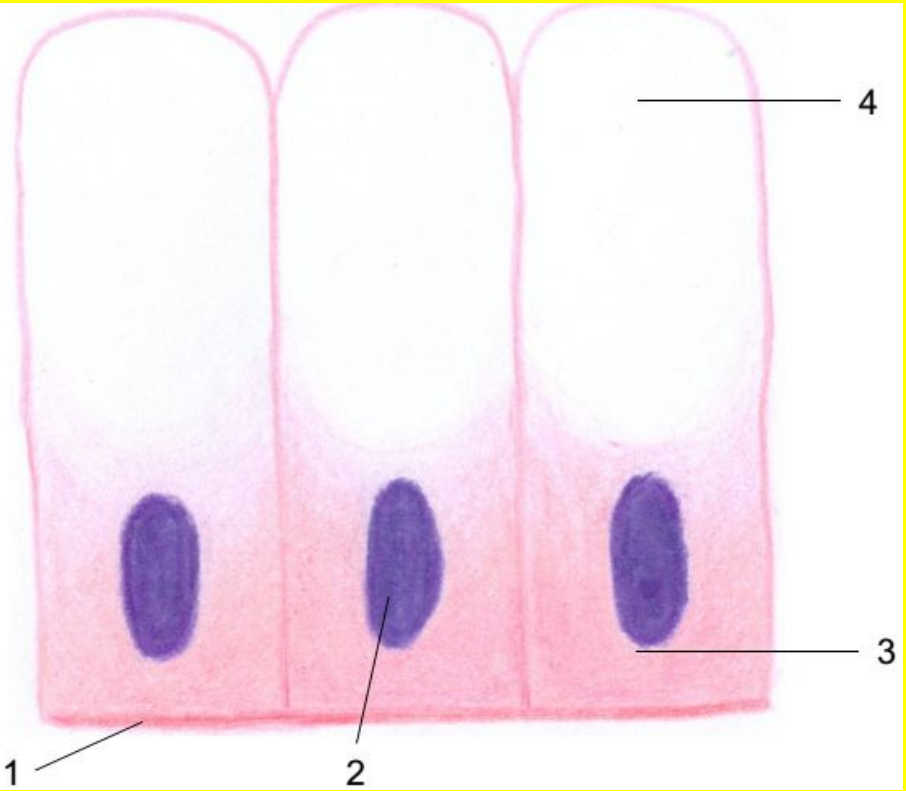
4
3
1
2

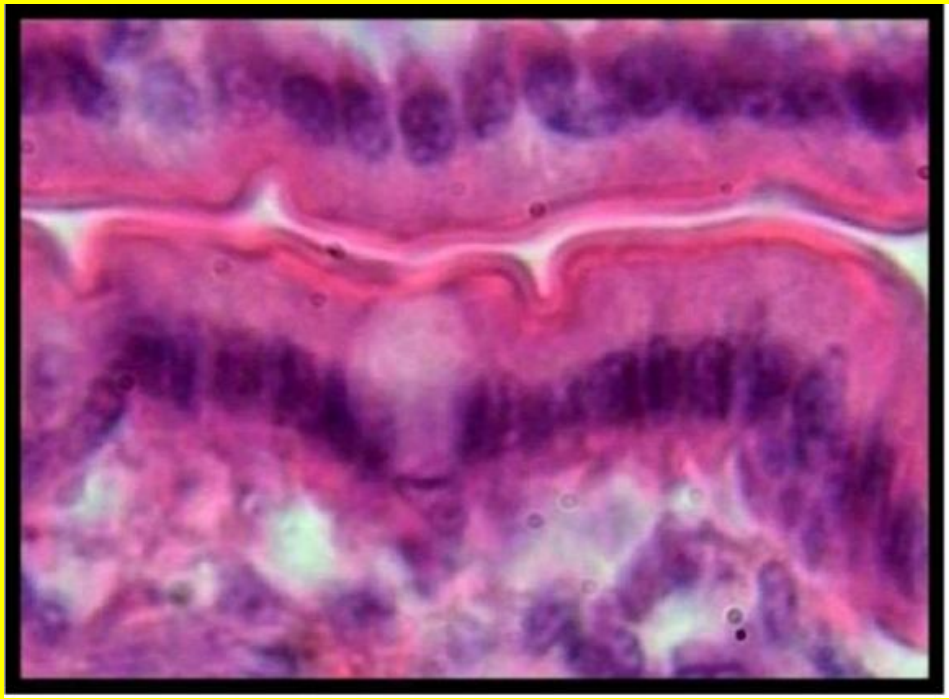

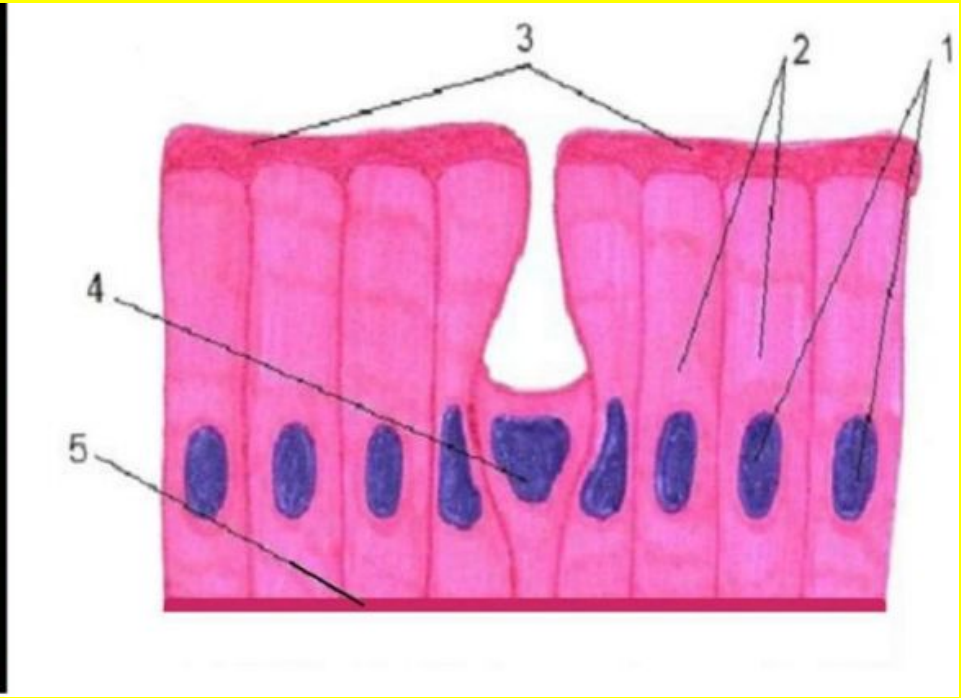
3
2
1
4
5

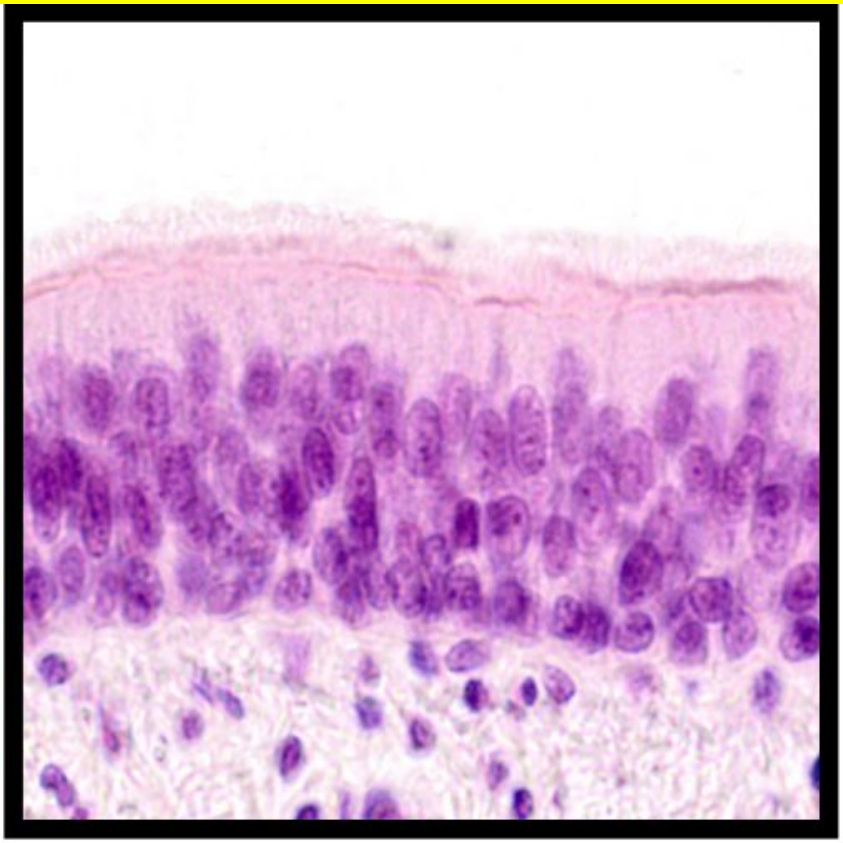

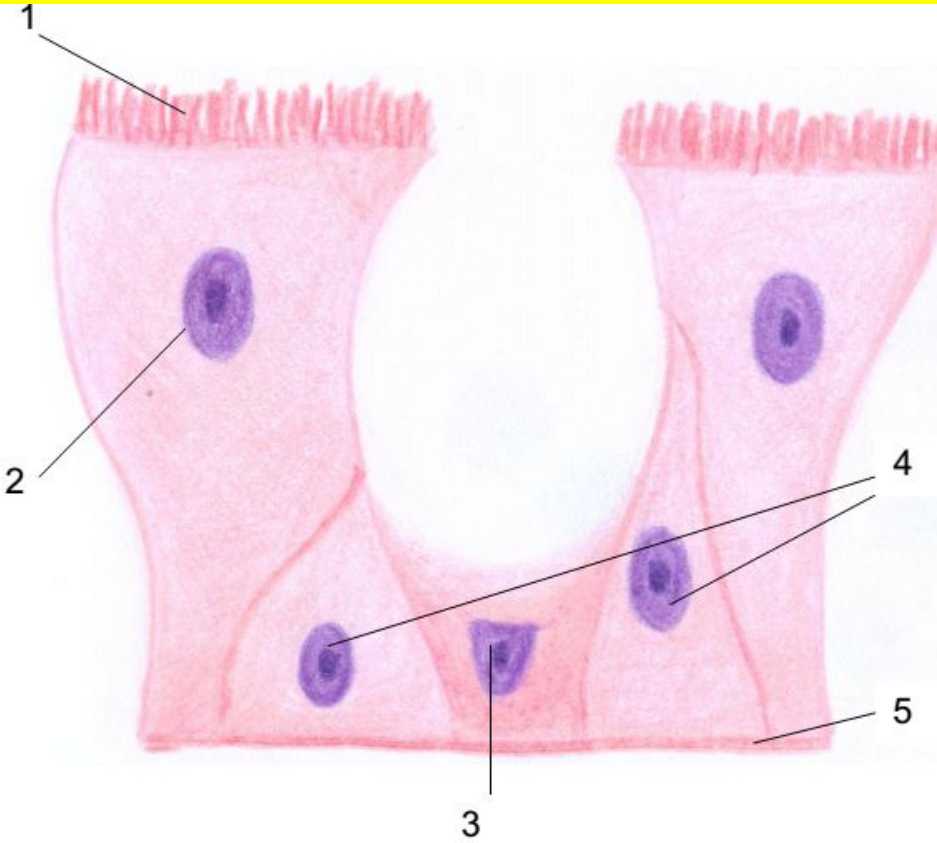
1
2
4
5
3

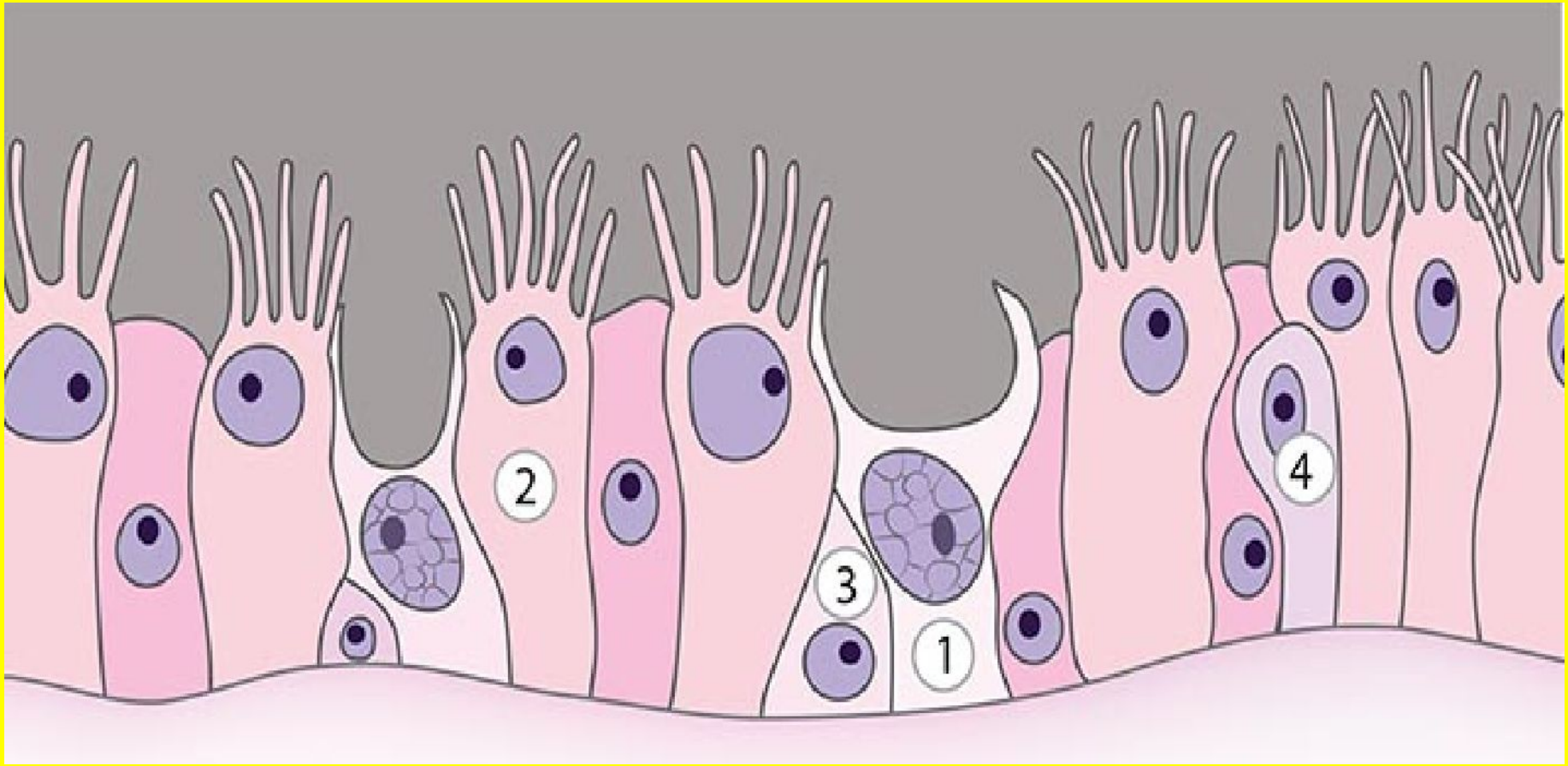

~~1.~~

~~2.~~

~~3.~~

~~4.~~

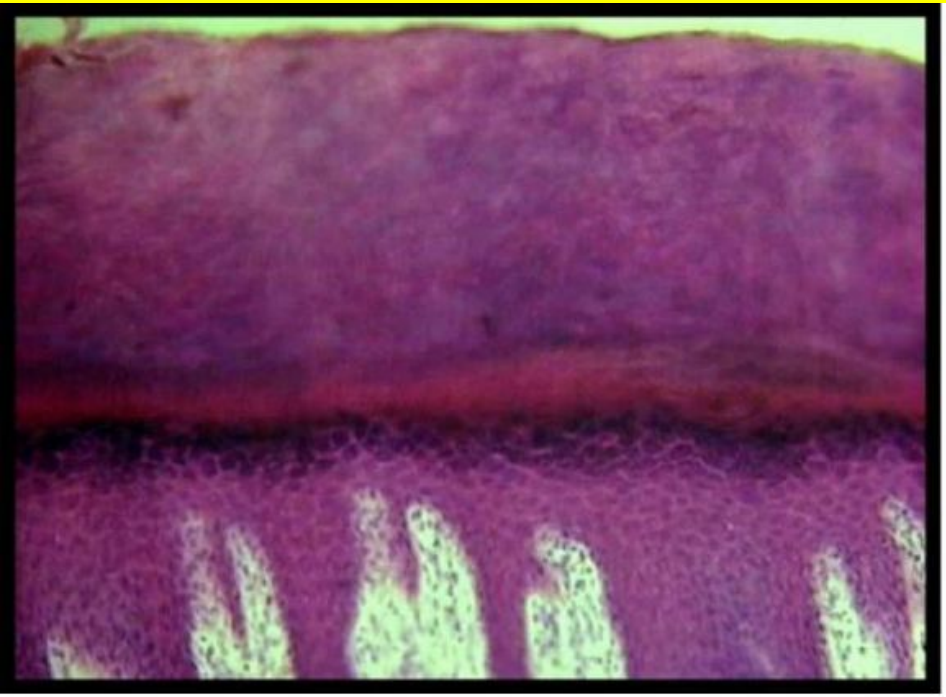

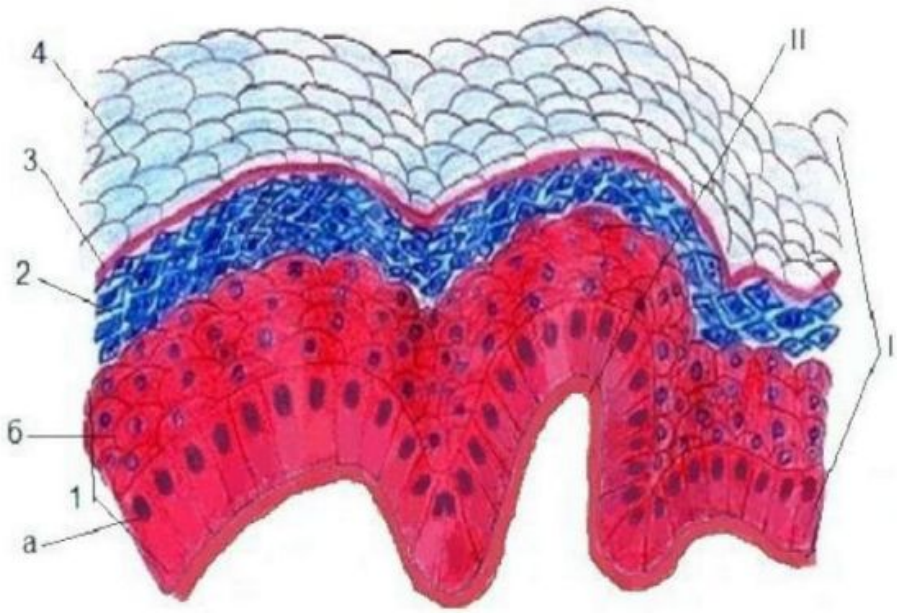
4
3
2
б
1
а
II
I



ся ее избыточным ороговением с деформацией по типу рыбьей чешуи.

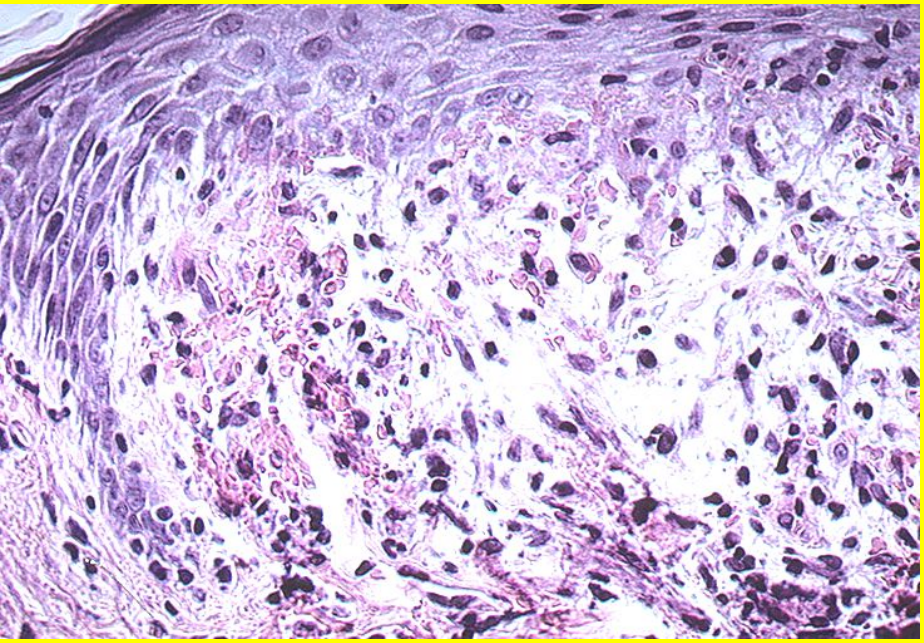

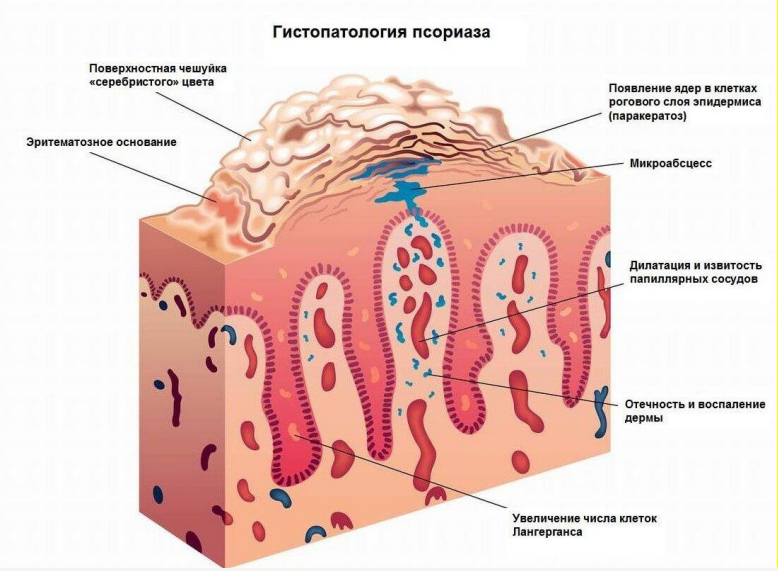
Гистопатология псориаза
Поверхностная чешуйка «серебристого» цвета
Эритематозное основание
Появление ядер в клетках рогового слоя эпидермиса (паракератоз)
Микроабсцесс
Дилатация и извитость папиллярных сосудов
Отечность и воспаление дермы
Увеличение числа клеток Лангерганса

80–90%
вульгарный псориаз
<10%
каплевидный псориаз
<5%
инверсный псориаз
<5%
пустулёзный псориаз
<2%
эритродермический псориаз

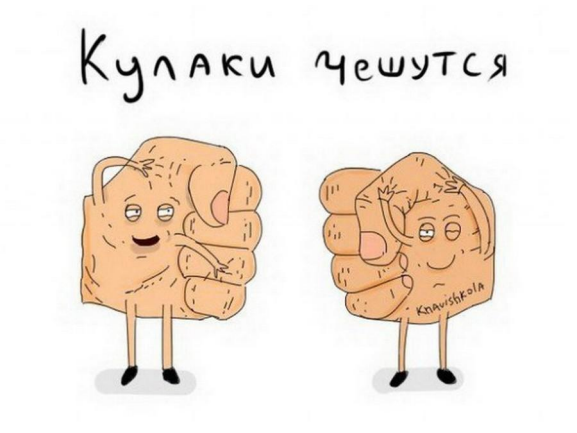
Кулаки чешутся
Knavishkola

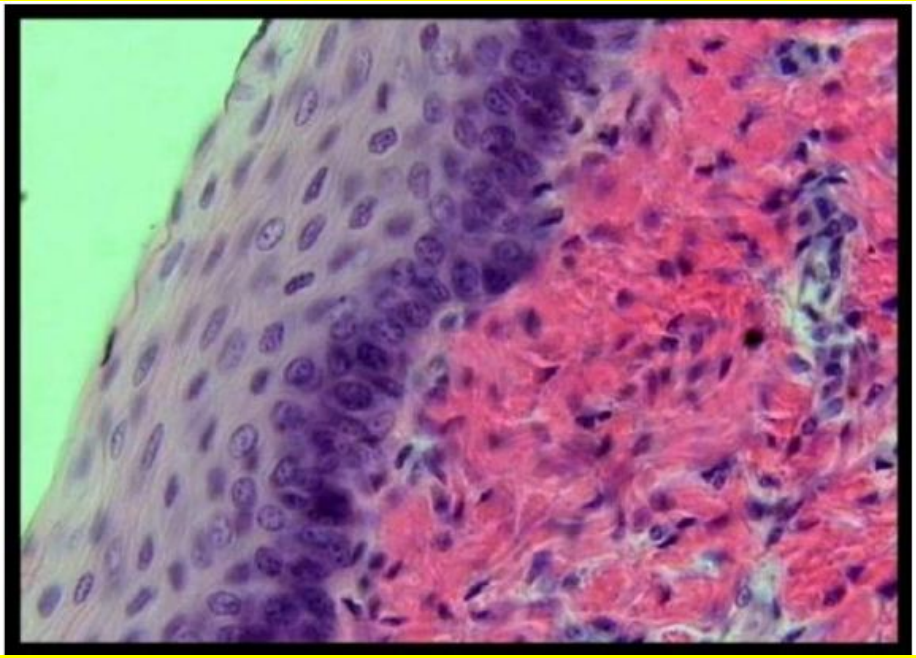

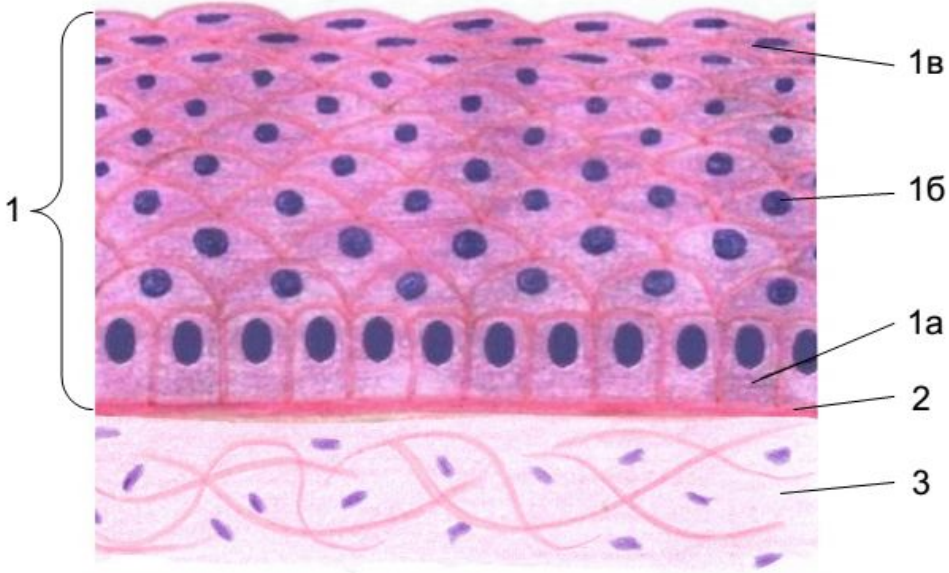
1
1в
1б
1а
2
3

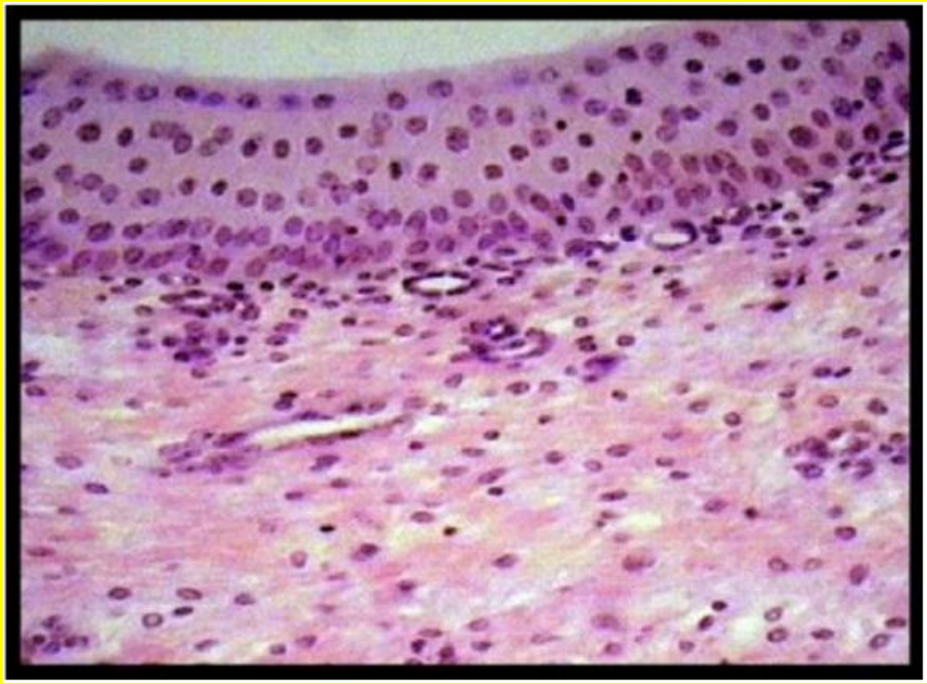

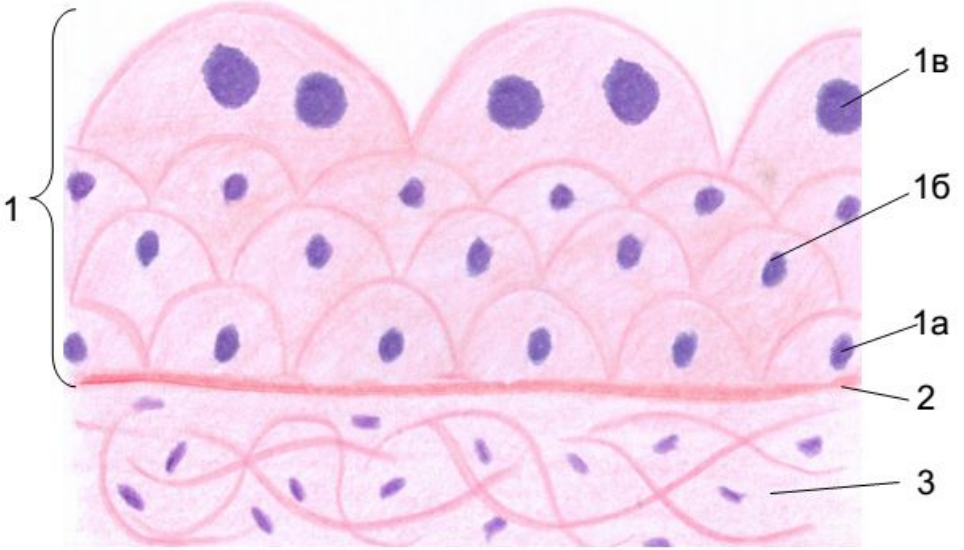
1
1в
1б
1а
2
3

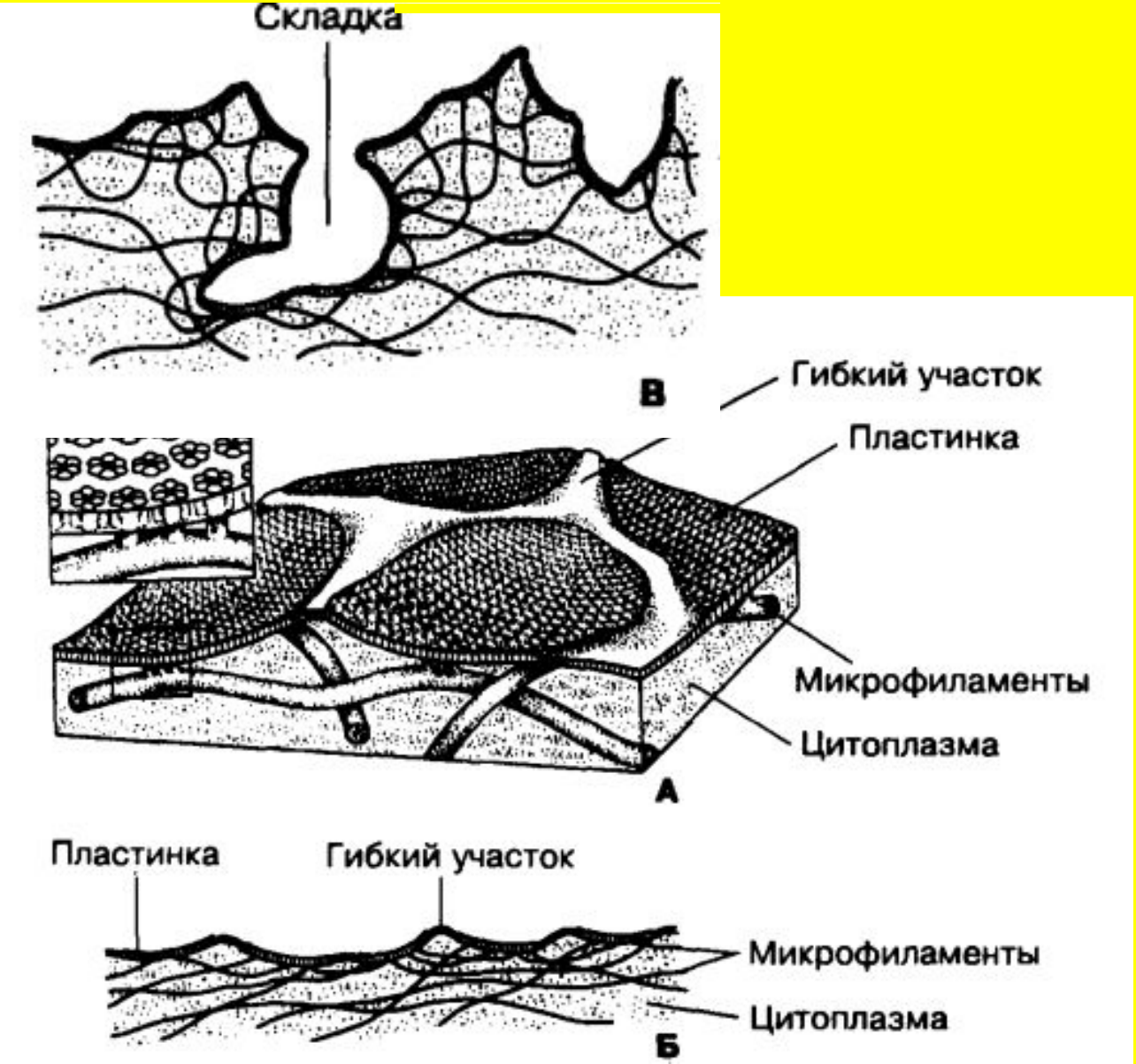
Складка
В
Гибкий участок
Пластинка
Микрофиламенты
Цитоплазма
А
Пластинка
Гибкий участок
Микрофиламенты
Цитоплазма
Б

NB! У ДЕТЕЙ МНОГОСЛОЙНЫЙ ЭПИТЕЛИЙ СОСТОИТ ИЗ МЕНЬШЕГО ЧИСЛА СЛОЕВ, А ЗНАЧИТ, В МЕНЬШЕЙ СТЕПЕНИ ВЫПОЛНЯЕТ ЗАЩИТНУЮ ФУНКЦИЮ.

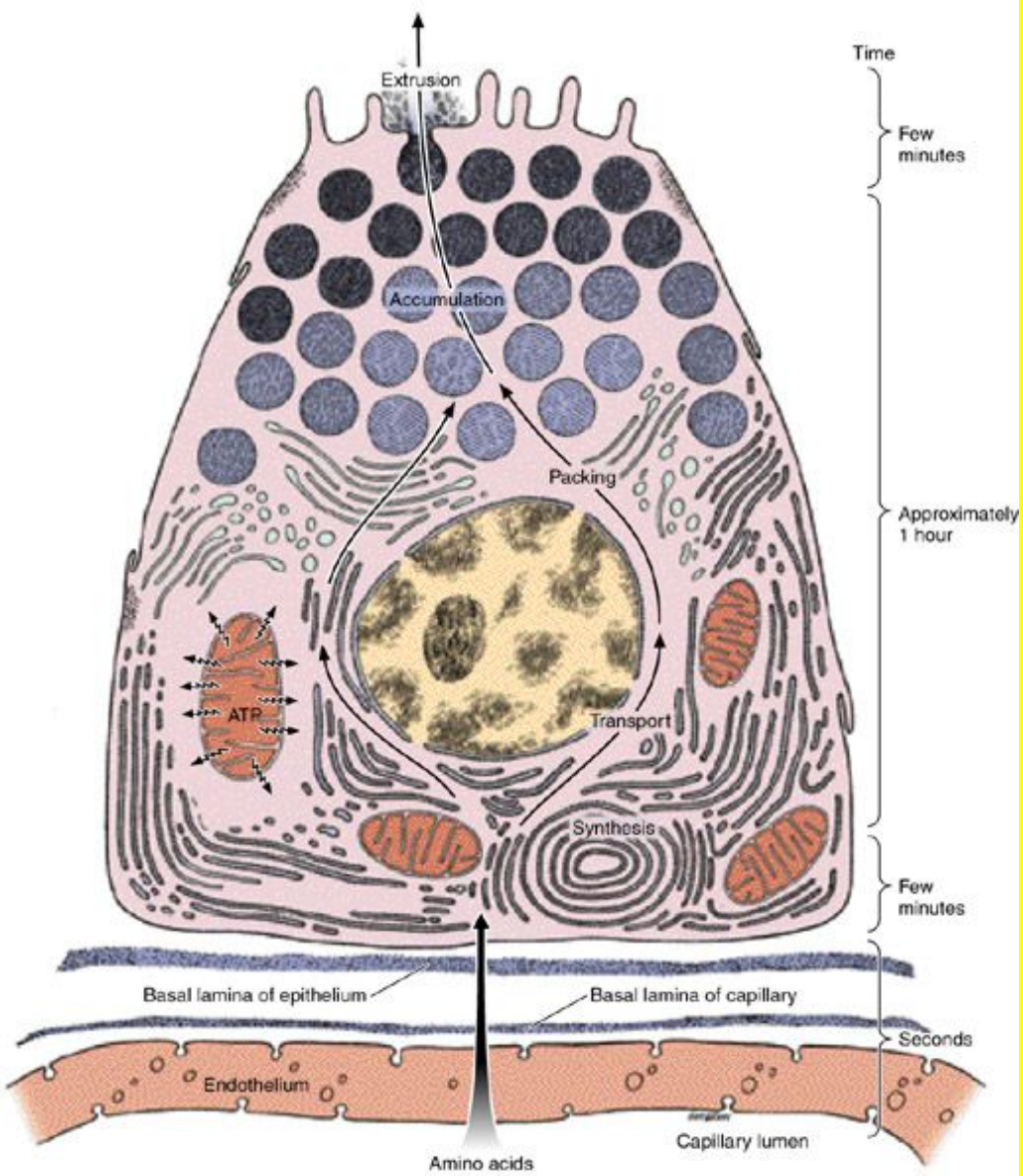
Time
Extrusion
Few minutes
Accumulation
Packing
Approximately 1 hour
ATP
Transport
Synthesis
Few minutes
Basal lamina of epithelium
Basal lamina of capillary
Seconds
Endothelium
Capillary lumen
Amino acids

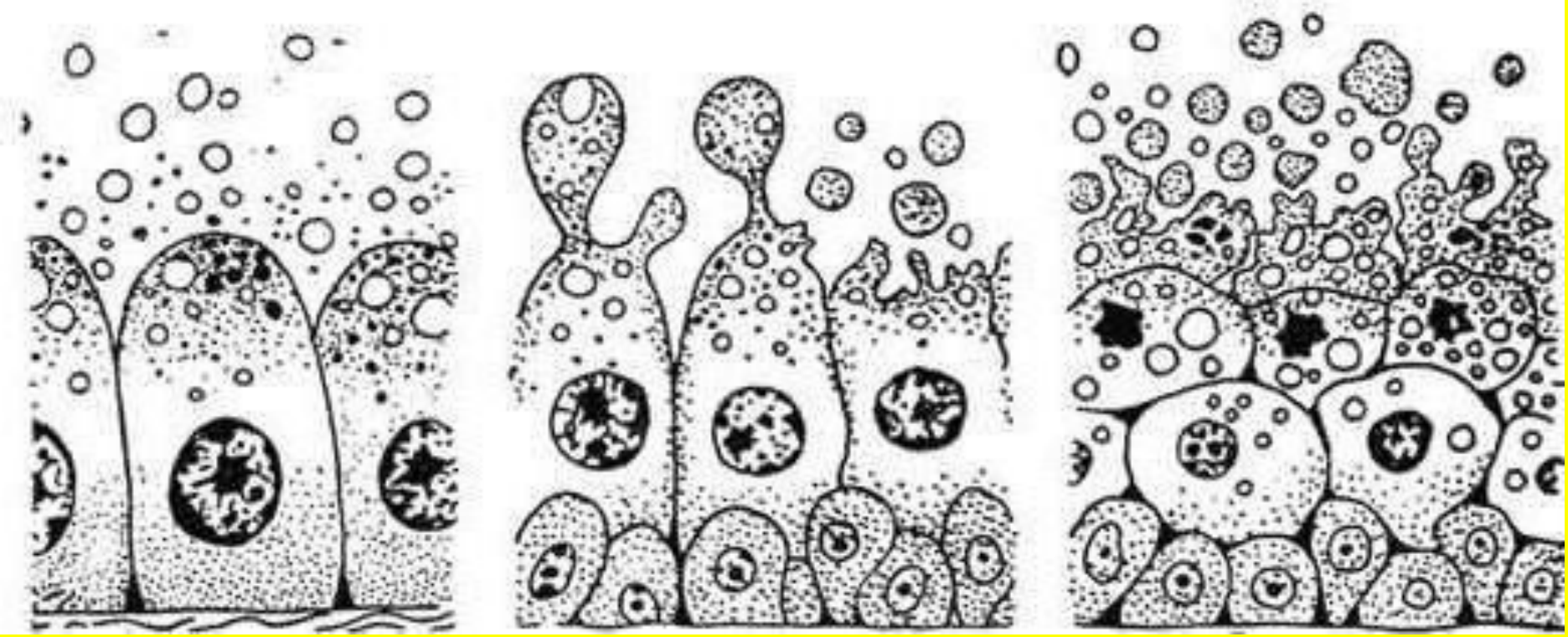

Мерокриновый (без разрушения)

Апокриновый (разруш.апикальный полюс клетки)микро- и макроапокриновый

Голокриновый (разруш. полностью)

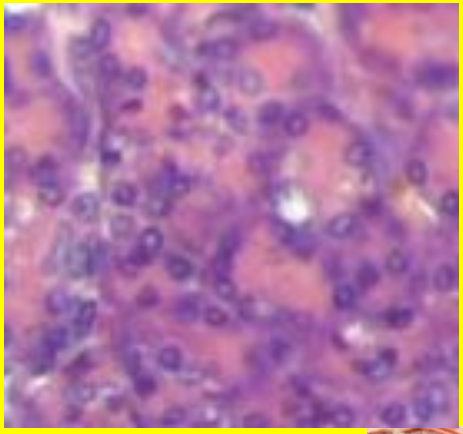

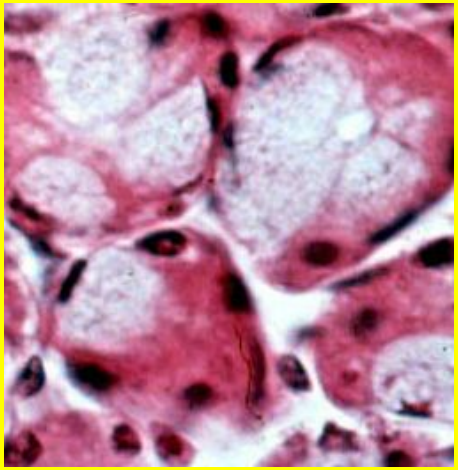

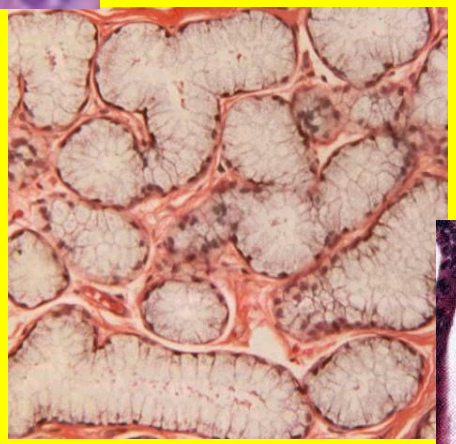

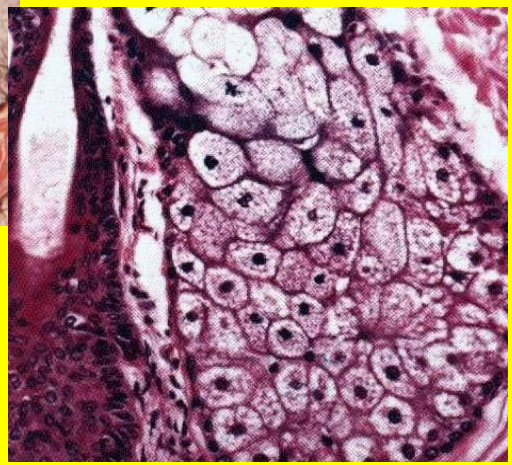

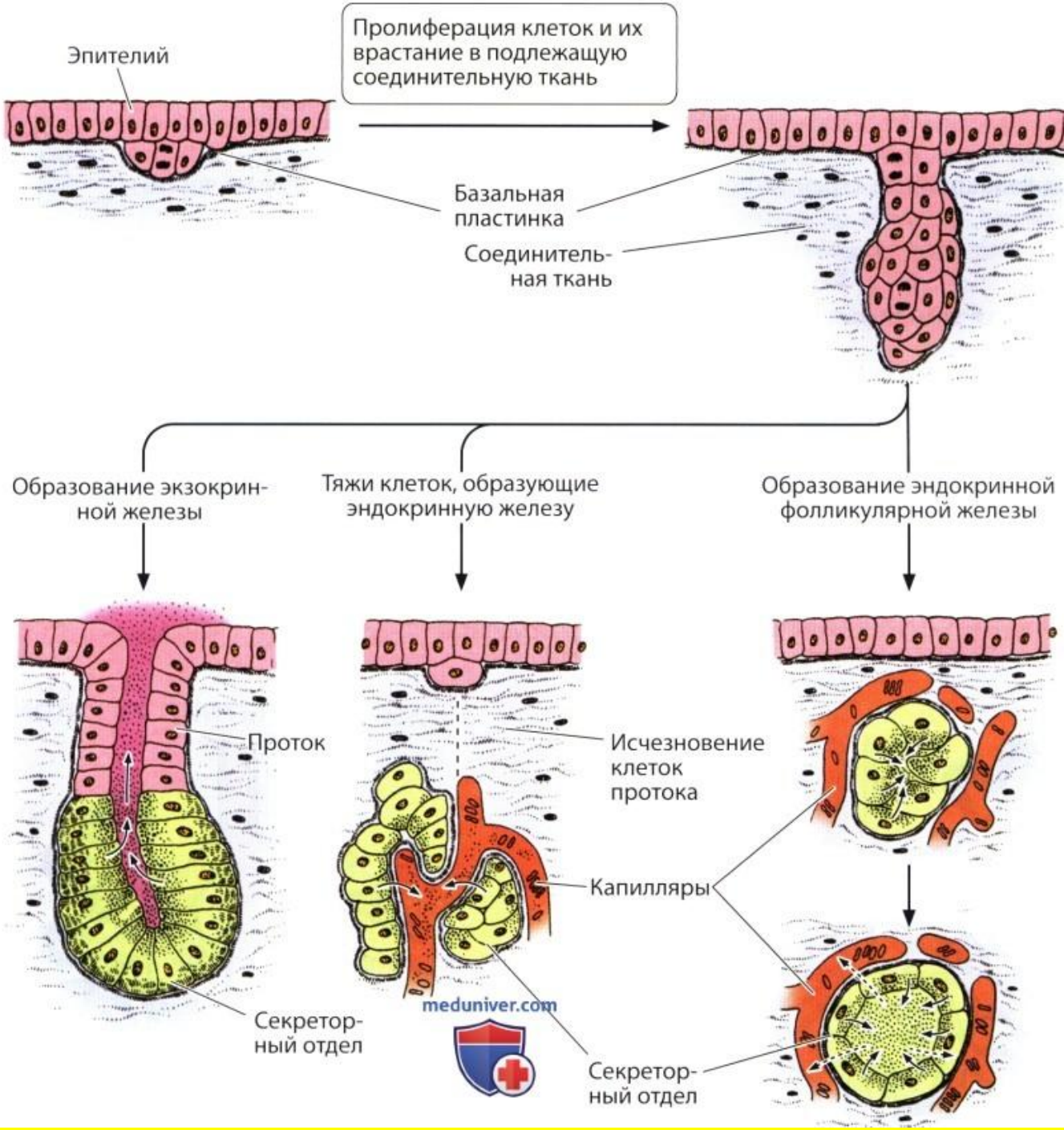
Эпителий
Пролиферация клеток и их врастание в подлежащую соединительную ткань
Базальная пластинка
Соединитель-ная ткань
Образование экзокрин-ной железы
Тяжи клеток, образующие эндокринную железу
Образование эндокринной фолликулярной железы
Проток
Исчезновение клеток протока
Капилляры
Секретор-ный отдел
Секретор-ный отдел
meduniver.com

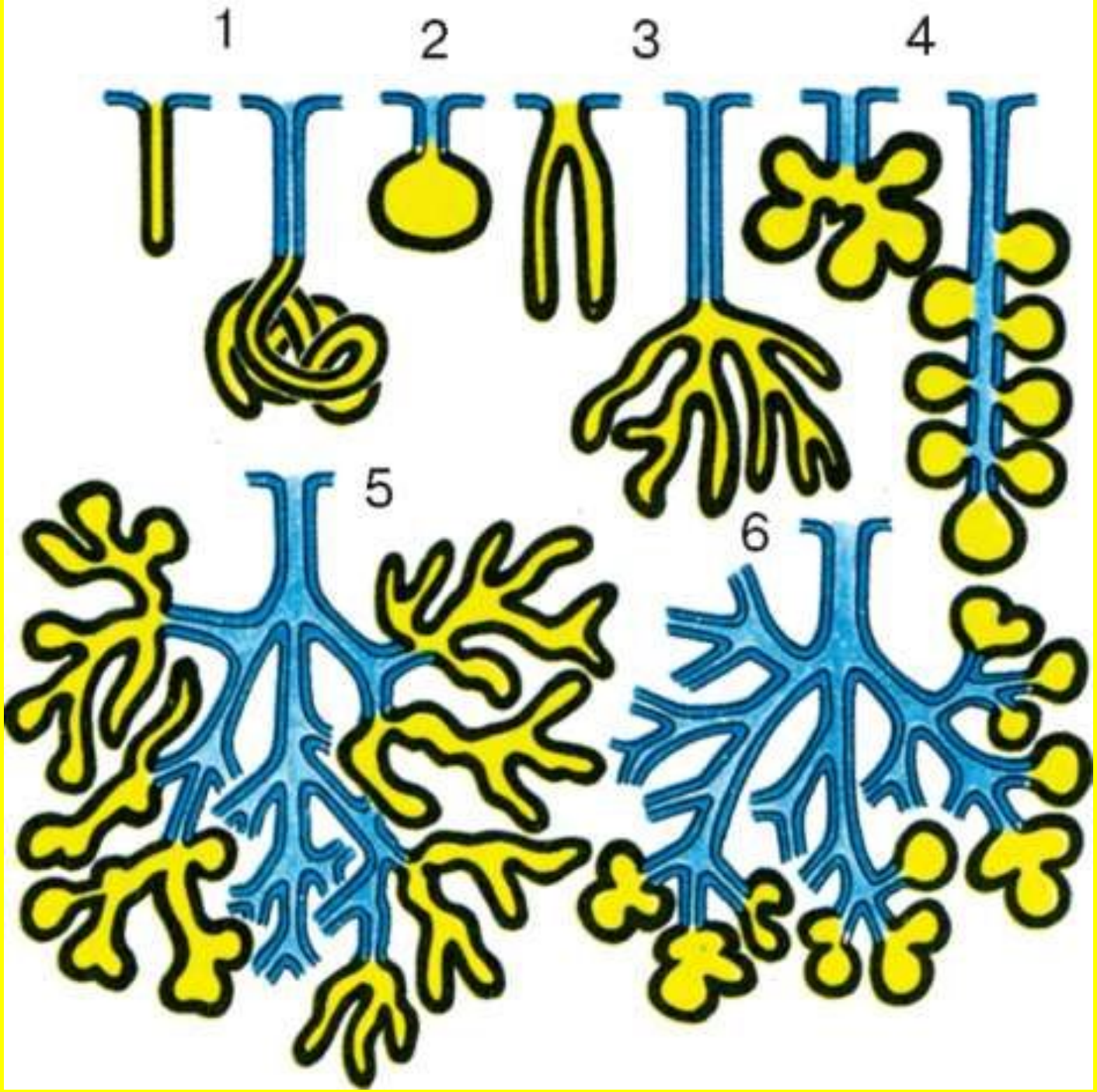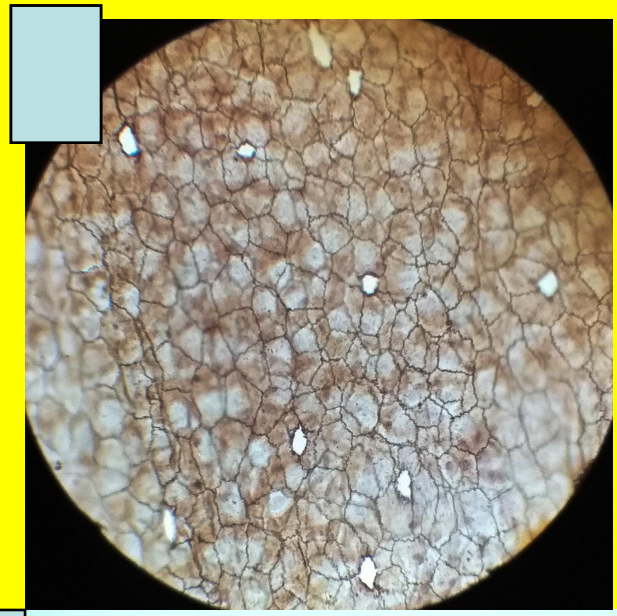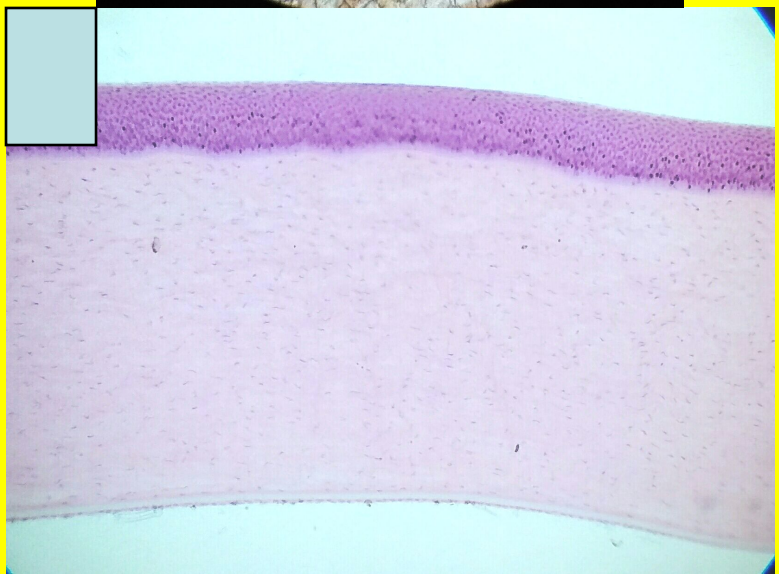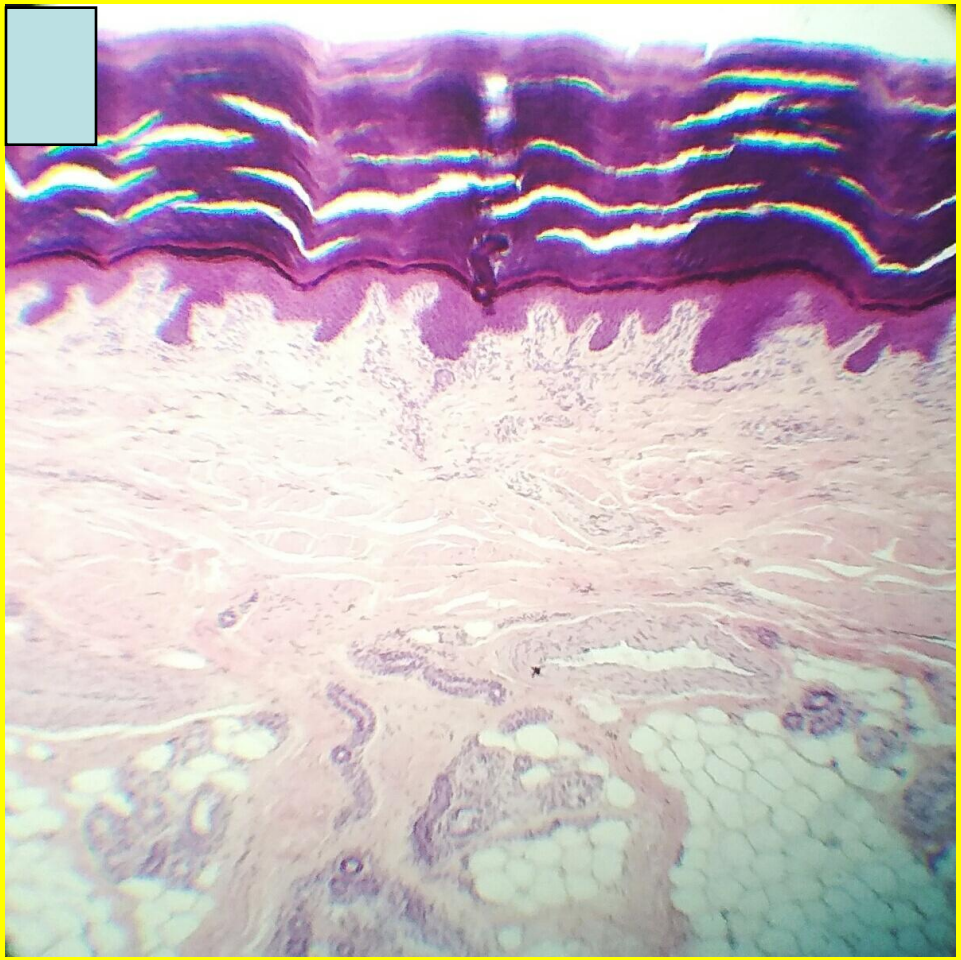
1
2
3
4
5
6