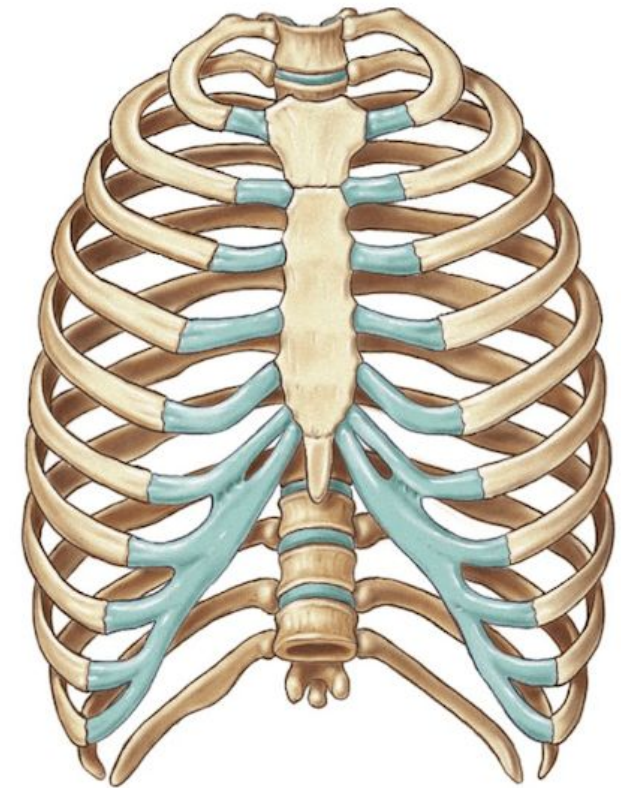
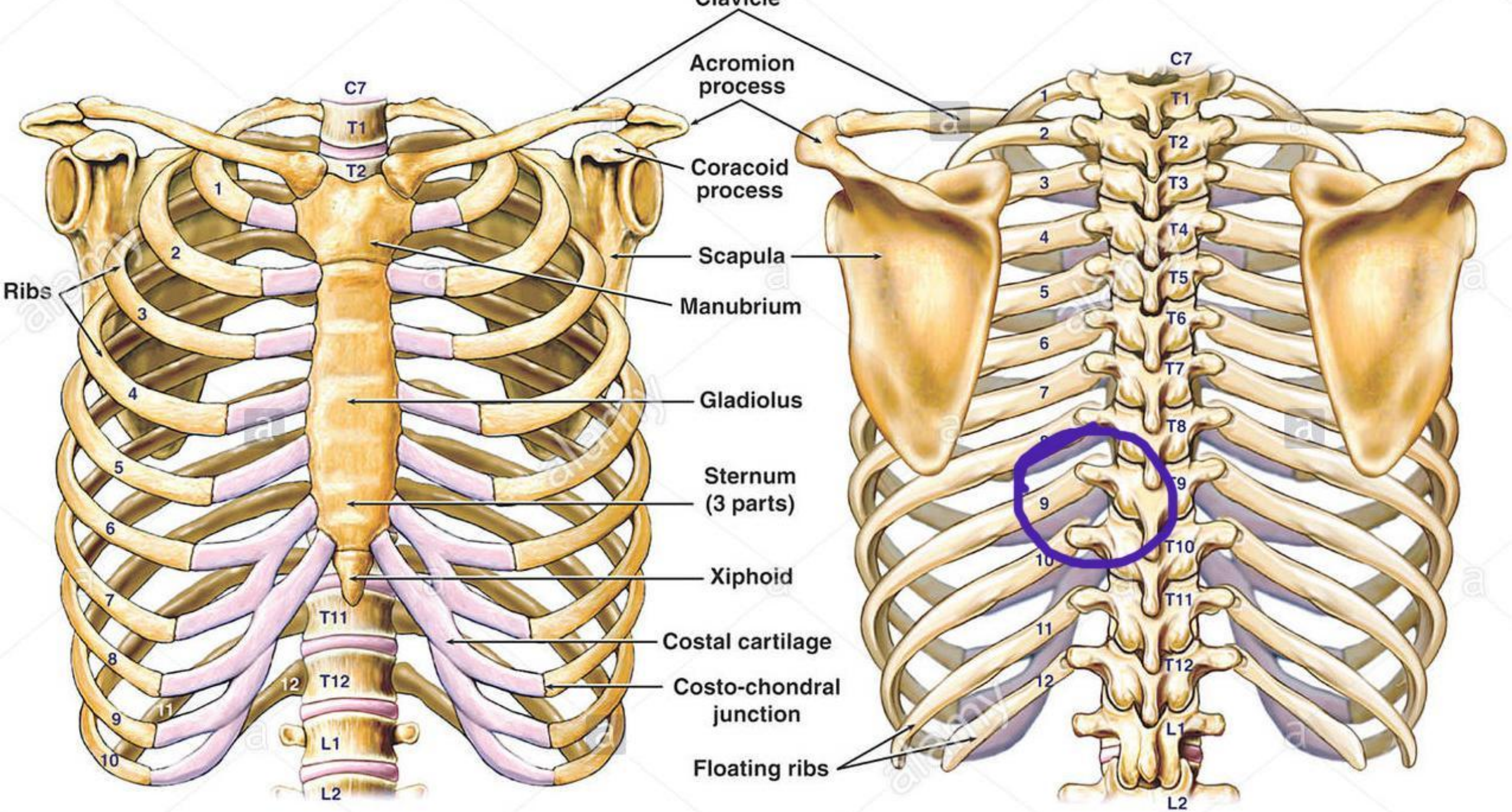
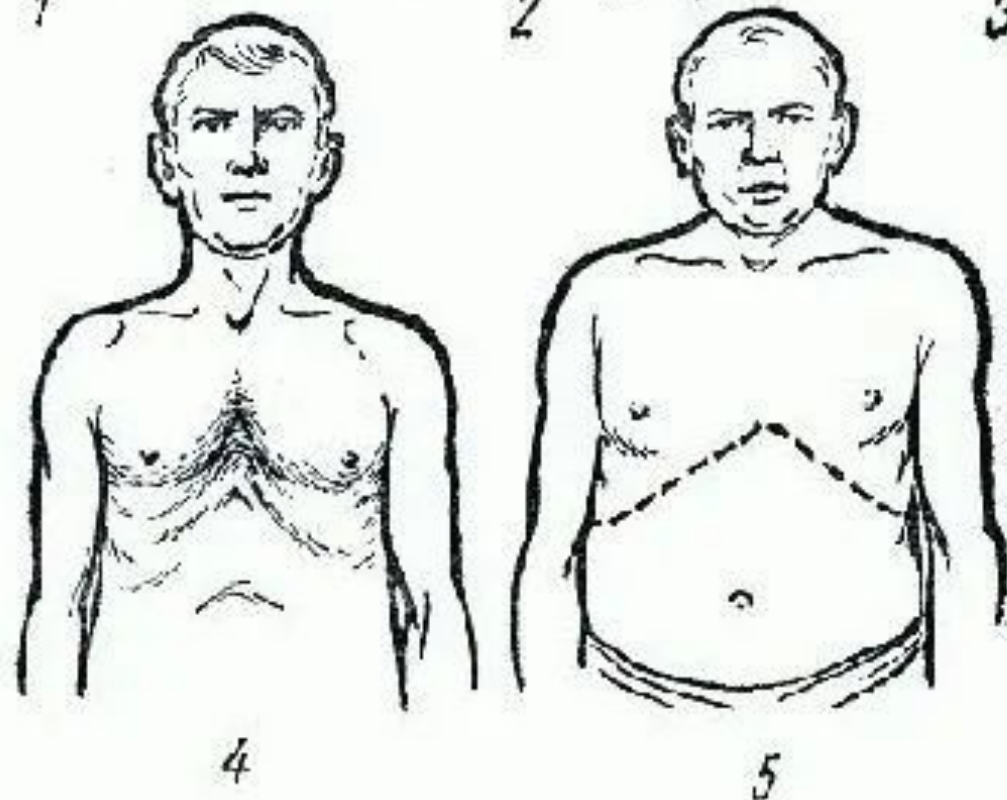
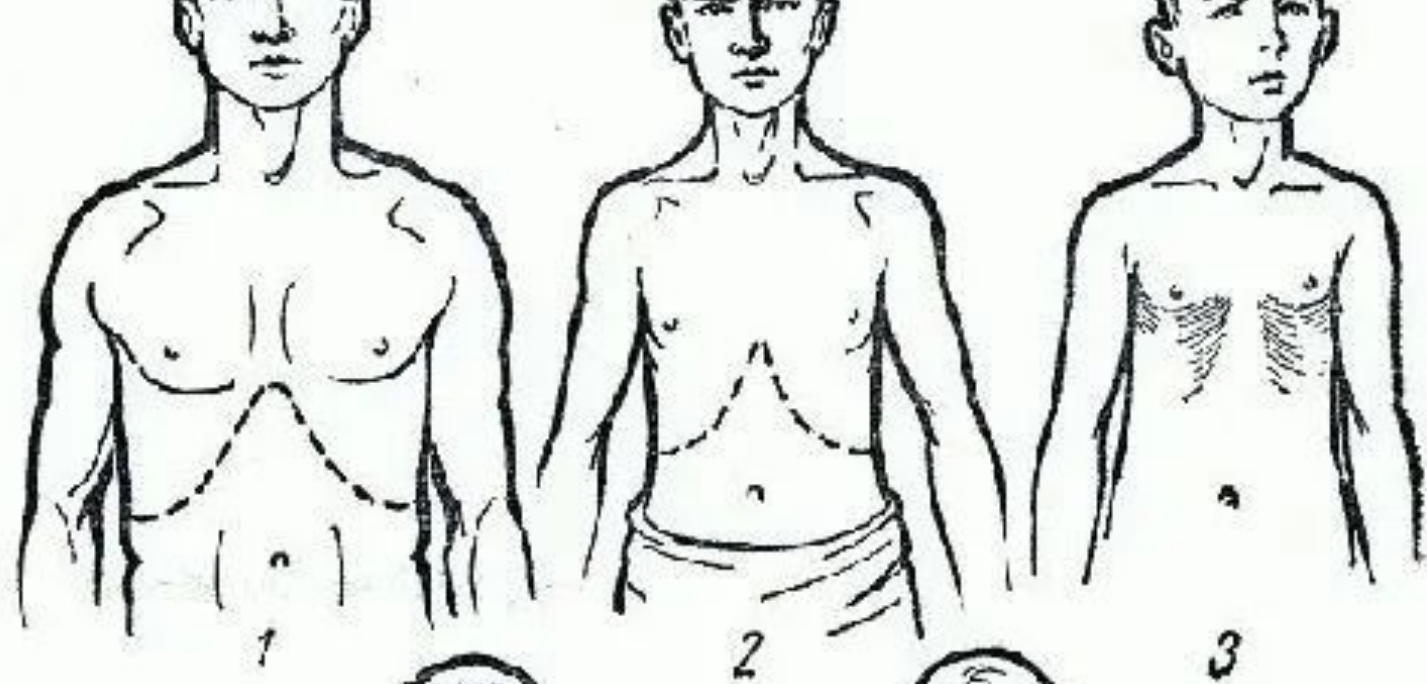


Грудная клетка

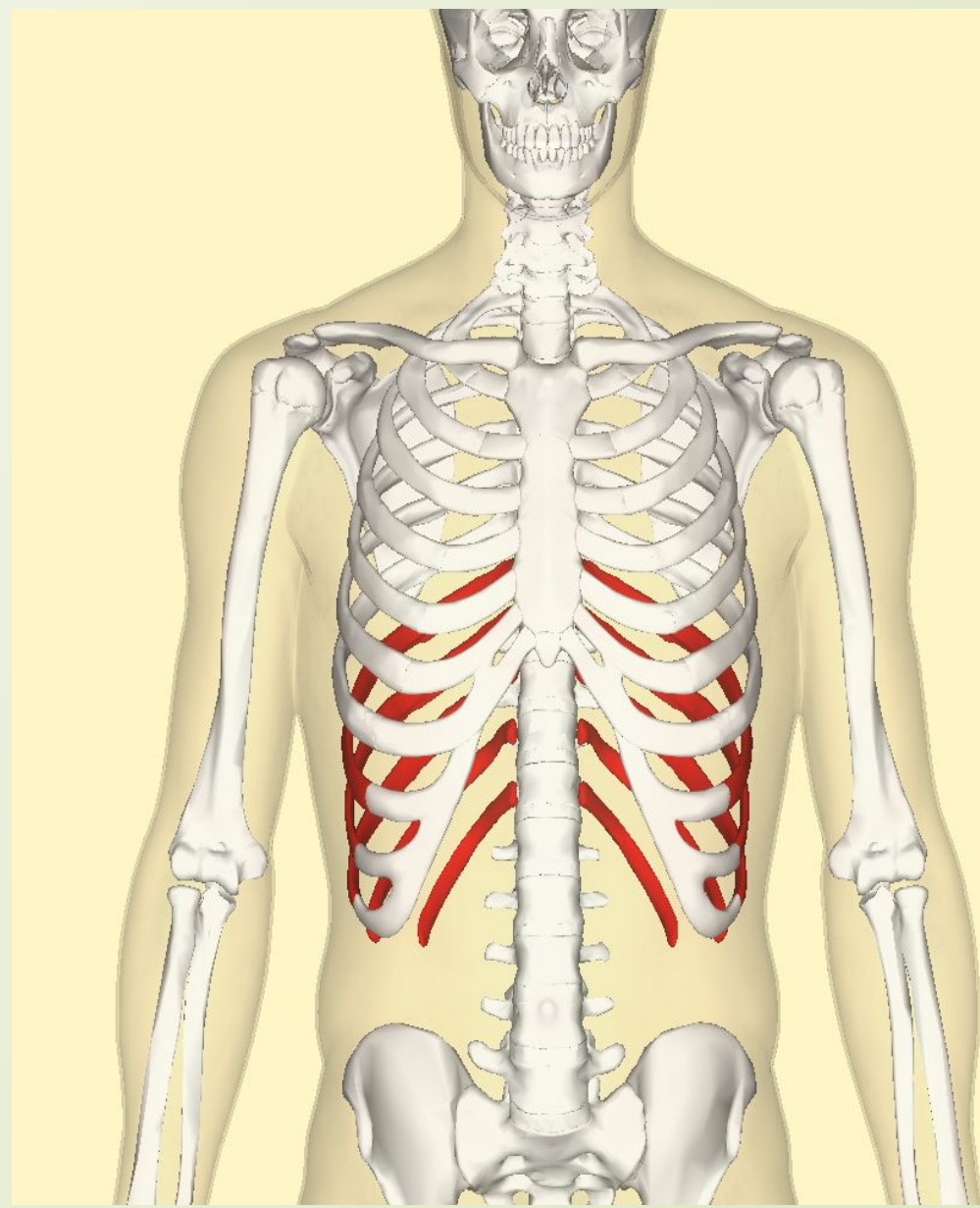
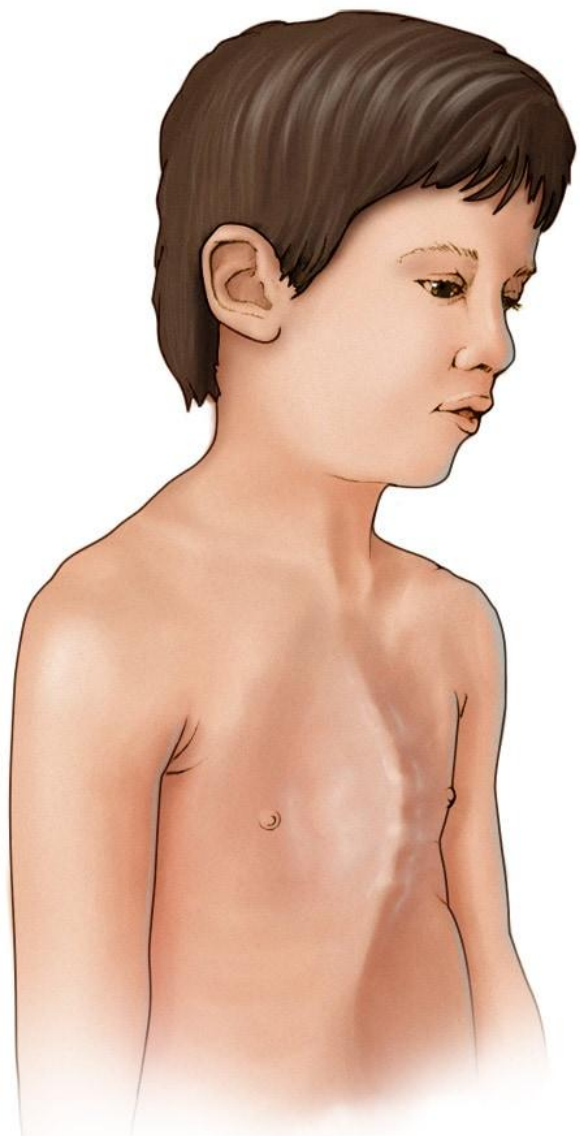


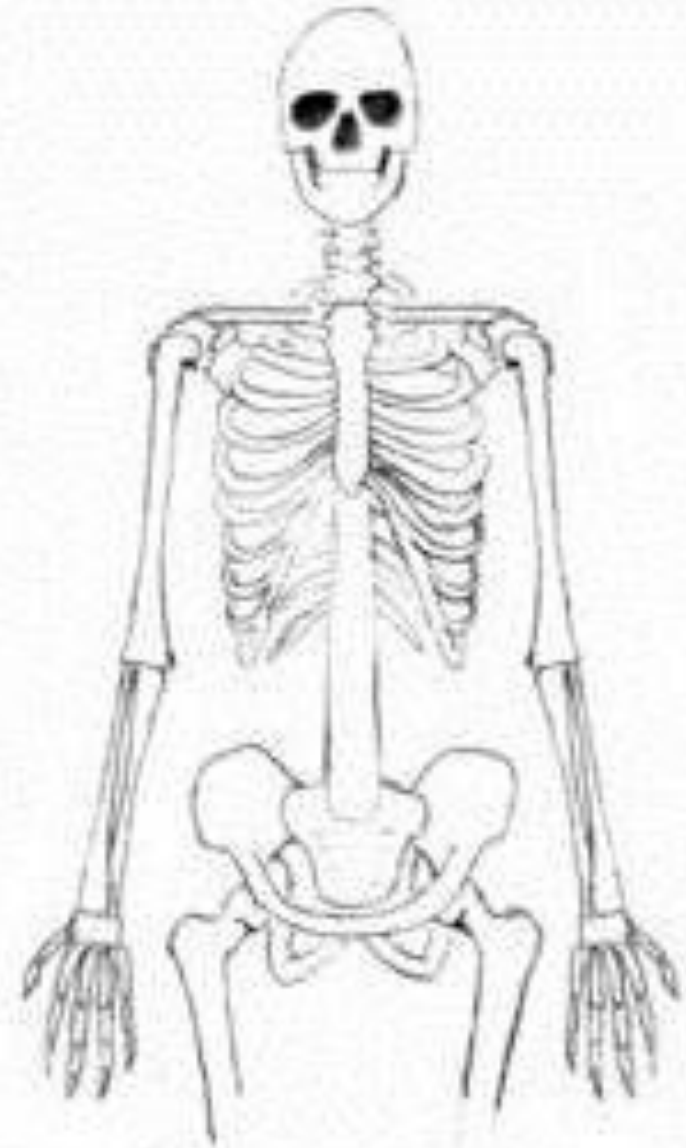
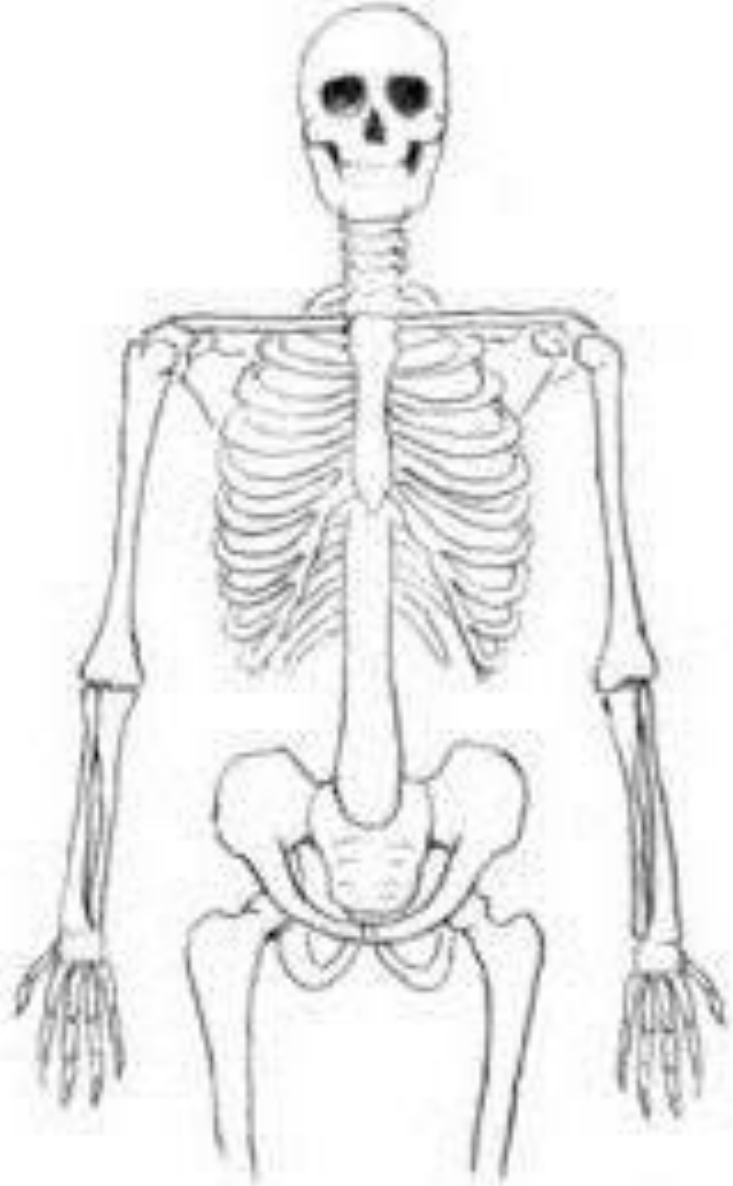
Подготовила Мосякова Инна гр.72101





Patology





*Thank you
for attention!*

