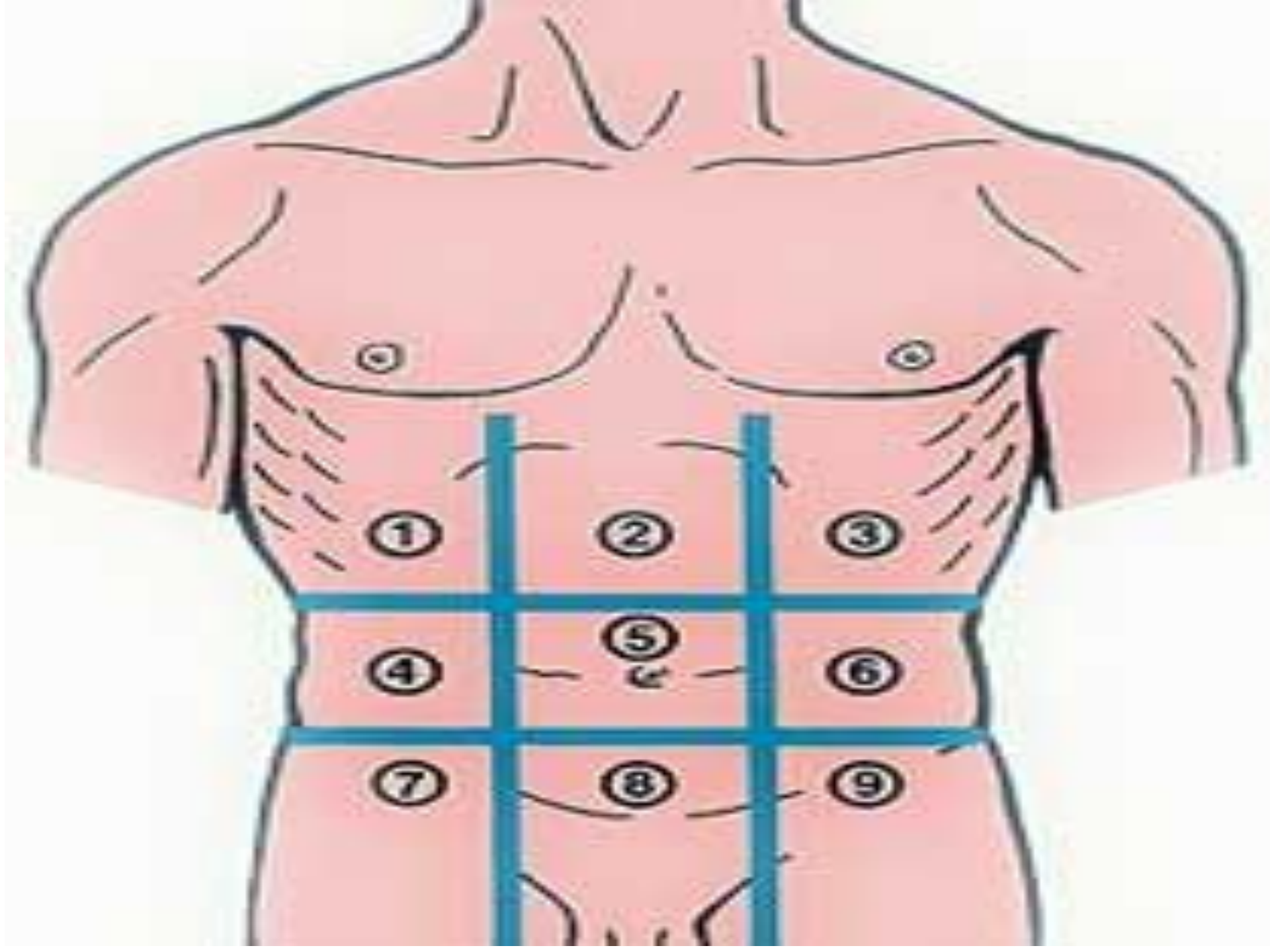
1
2
3
4
5
6
7
8
9

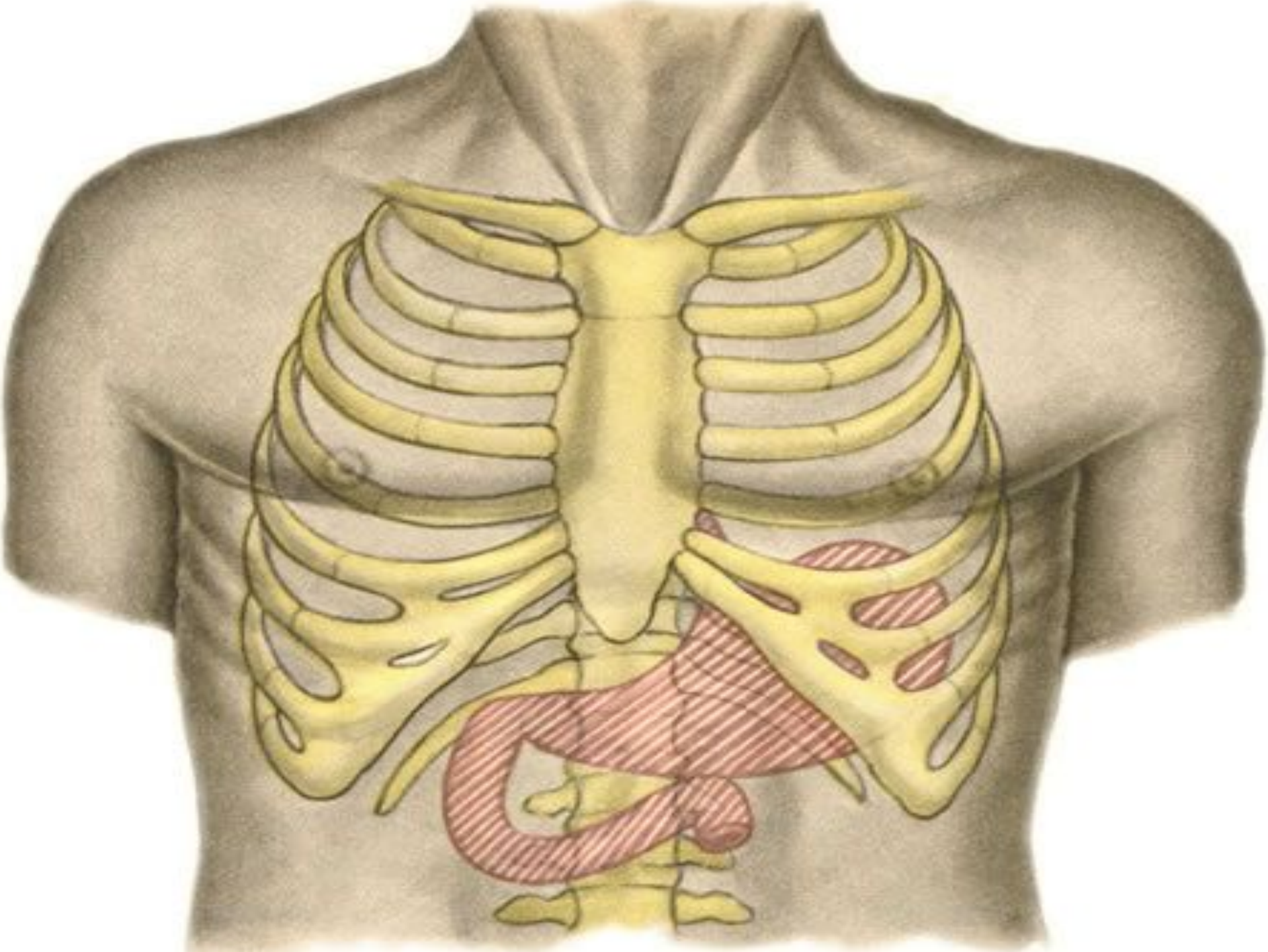

Синтопия желудка

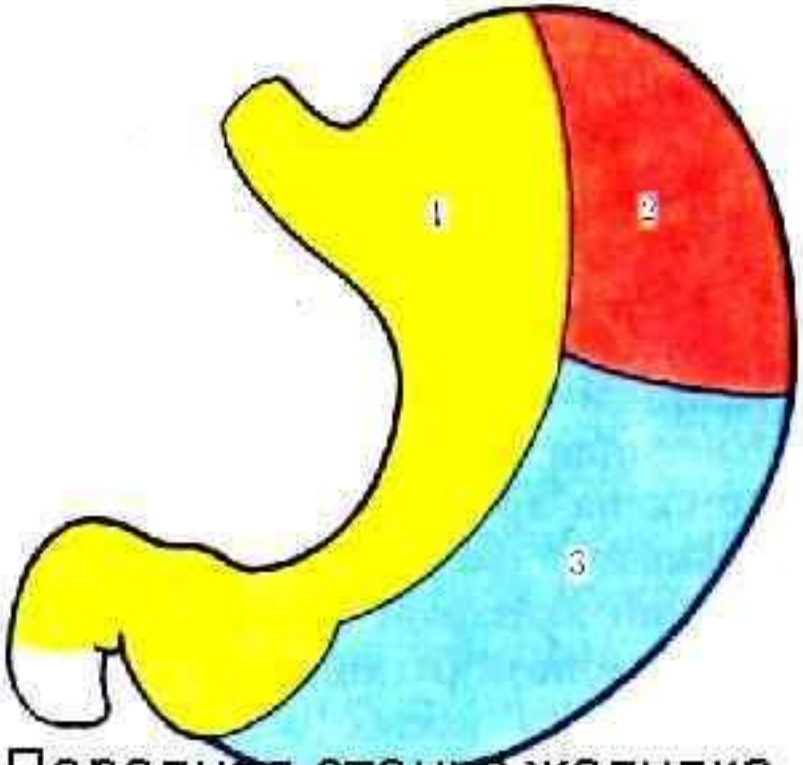

Передняя стенка желудка

Поля соприкосновения:

1. С печенью
2. С диафрагмой
3. С передней брюшной стенкой

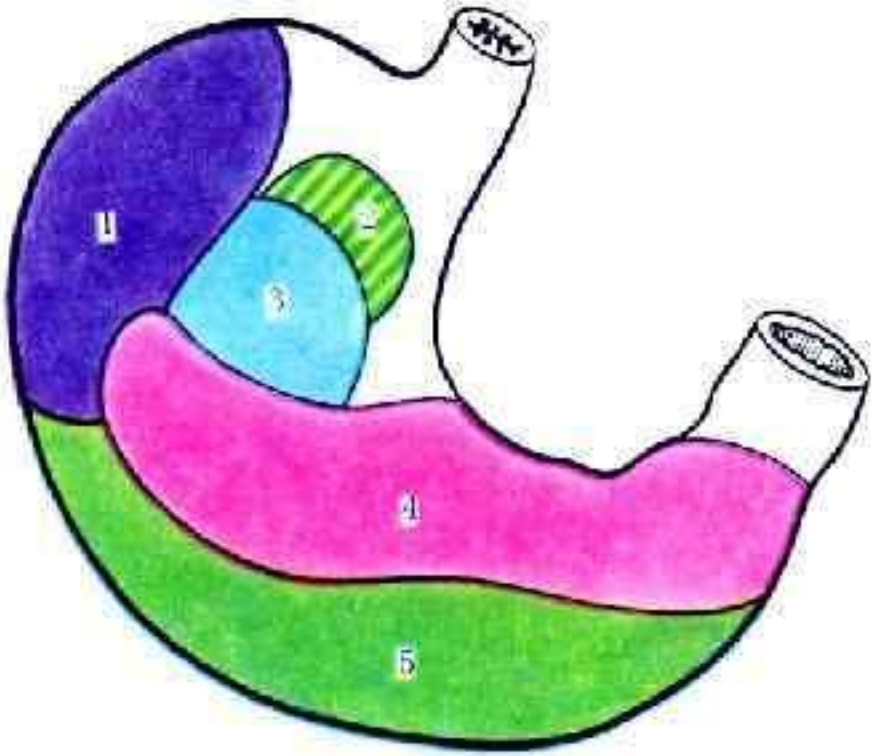

Задняя стенка желудка

Поля соприкосновения:

1. С селезёнкой
2. С левым надпочечником
3. С левой почкой
4. С поджелудочной железой
5. С поперечной ободочной кишкой и её брыжейкой

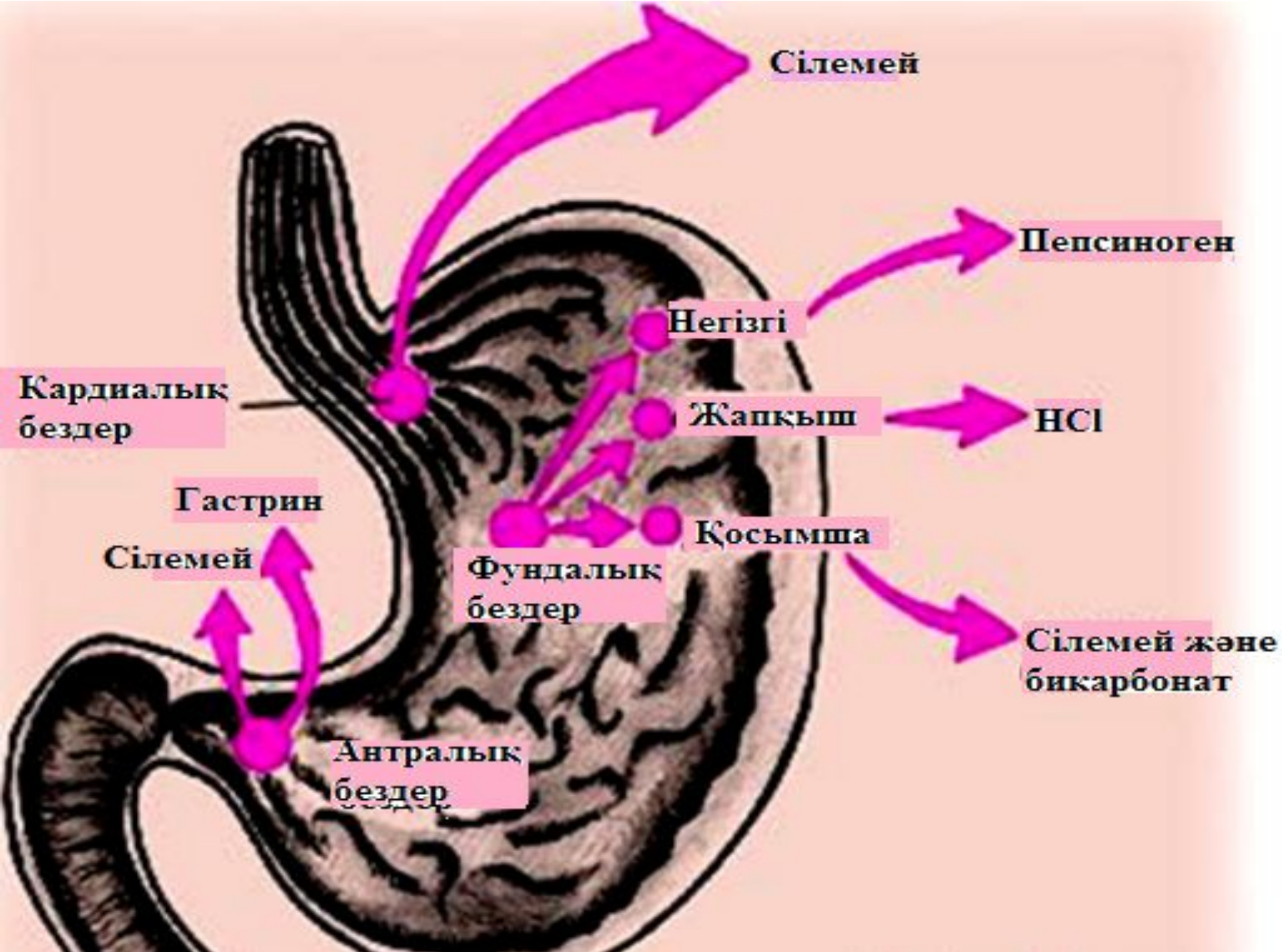
Сілемей
Пепсиноген
Негізгі
Кардиалық бездер
Жапқыш
HCl
Гастрин
Сілемей
Қосымша
Фундалық бездер
Сілемей және бикарбонат
Антралық бездер

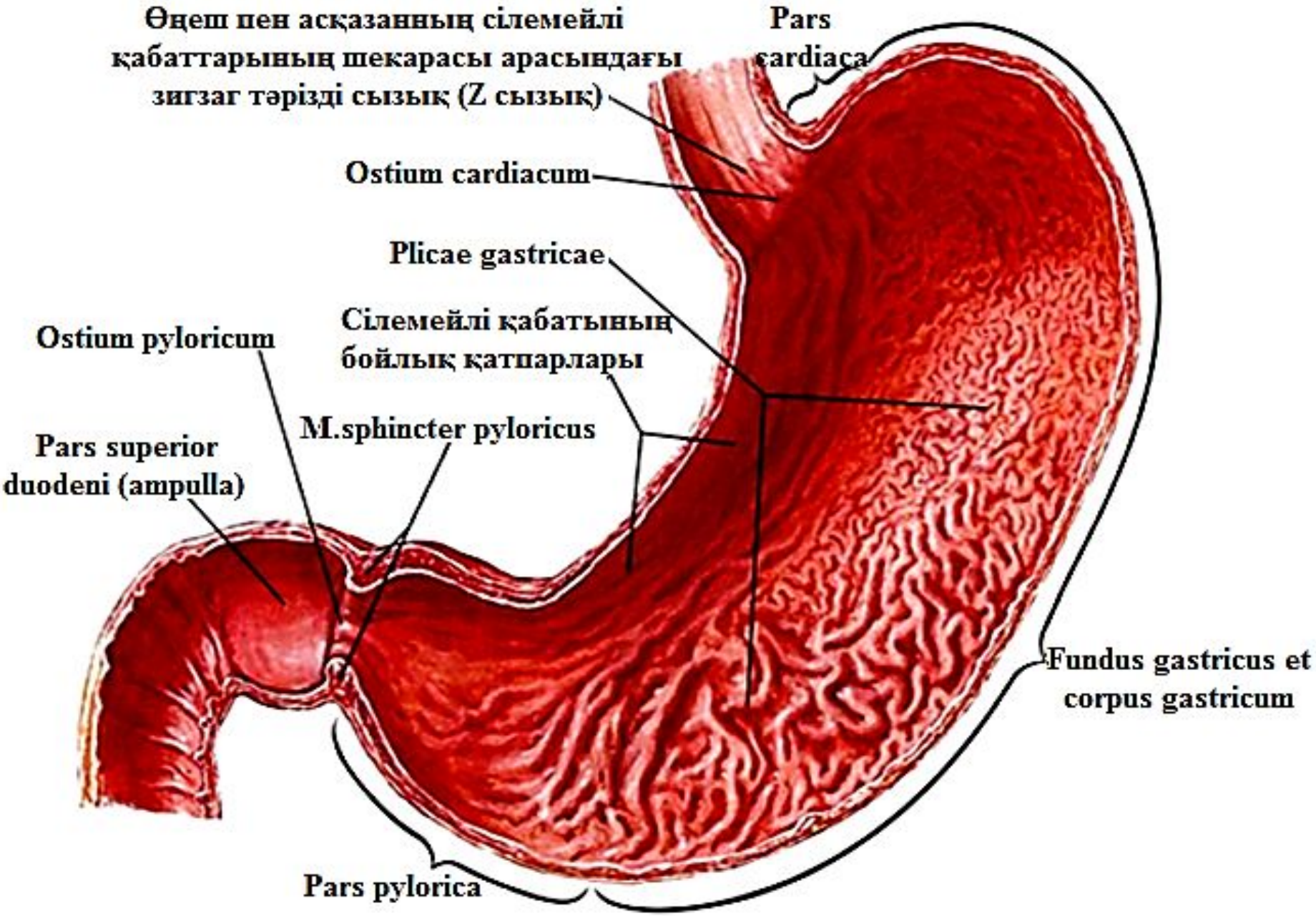
Өңеш пен асқазанның сілемейлі қабаттарының шекарасы арасындағы зигзаг тәрізді сызық (Z сызық)
Pars cardiaca
Ostium cardiacum
Plicae gastricae
Сілемейлі қабатының бойлық қатпарлары
Ostium pyloricum
M.sphincter pyloricus
Pars superior duodeni (ampulla)
Fundus gastricus et corpus gastricum
Pars pylorica

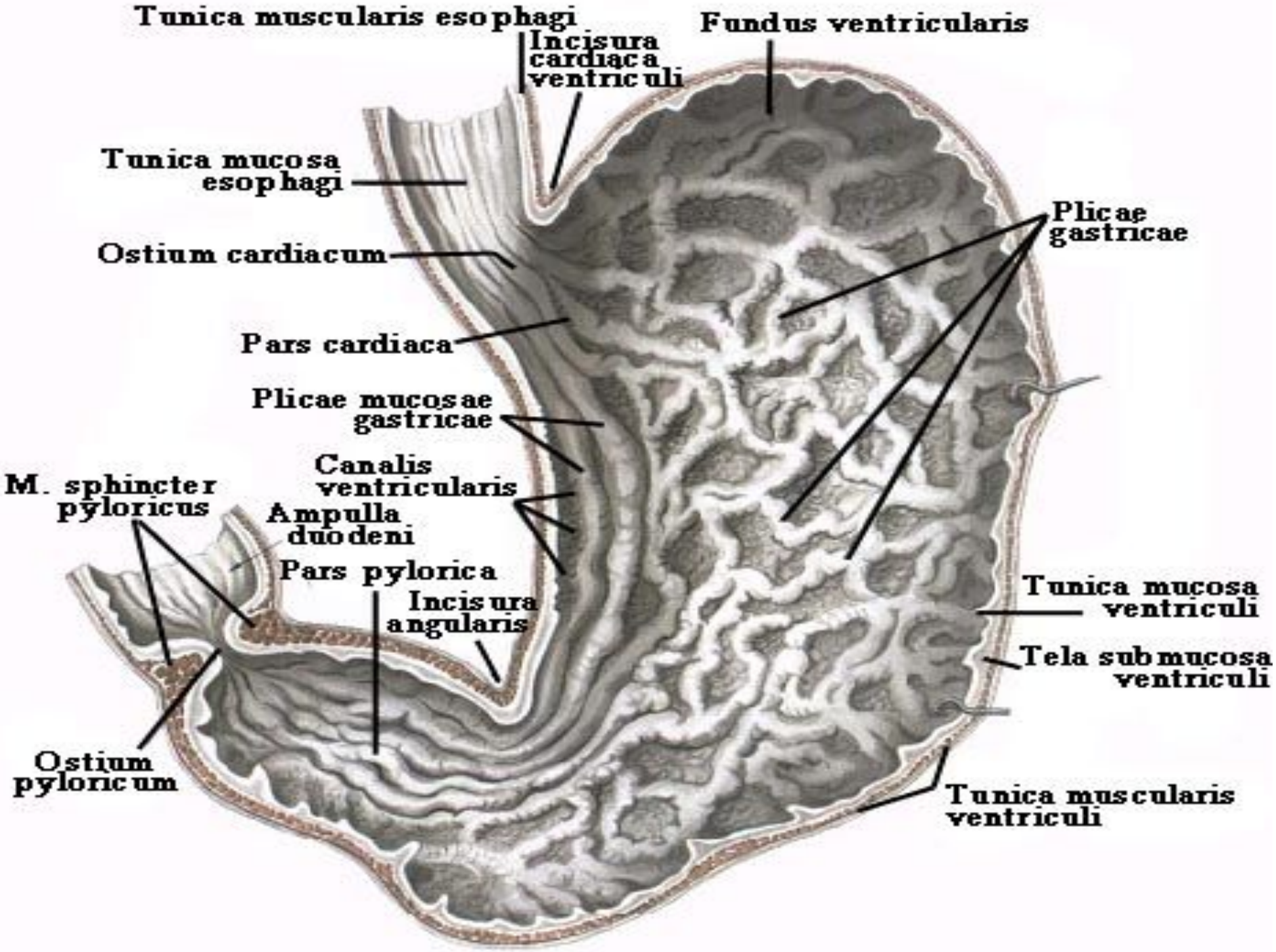
Tunica muscularis esophagi
Incisura cardiaca ventriculi
Fundus ventricularis
Tunica mucosa esophagi
Plicae gastricae
Ostium cardiacum
Pars cardiaca
Plicae mucosae gastricae
Canalis ventricularis
M. sphincter pyloricus
Ampulla duodeni
Pars pylorica
Incisura angularis
Tunica mucosa ventriculi
Tela submucosa ventriculi
Ostium pyloricum
Tunica muscularis ventriculi

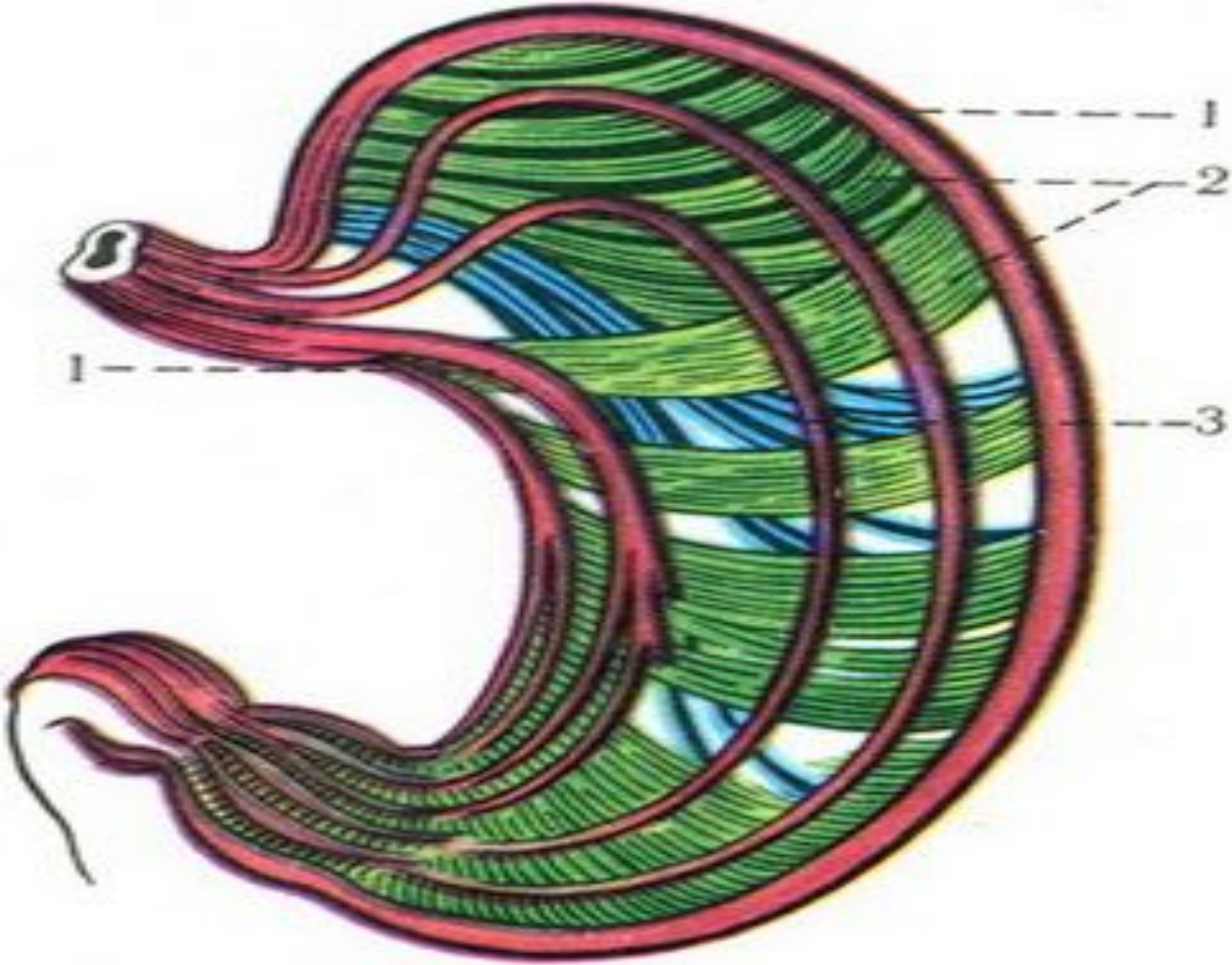
1
2
1
3

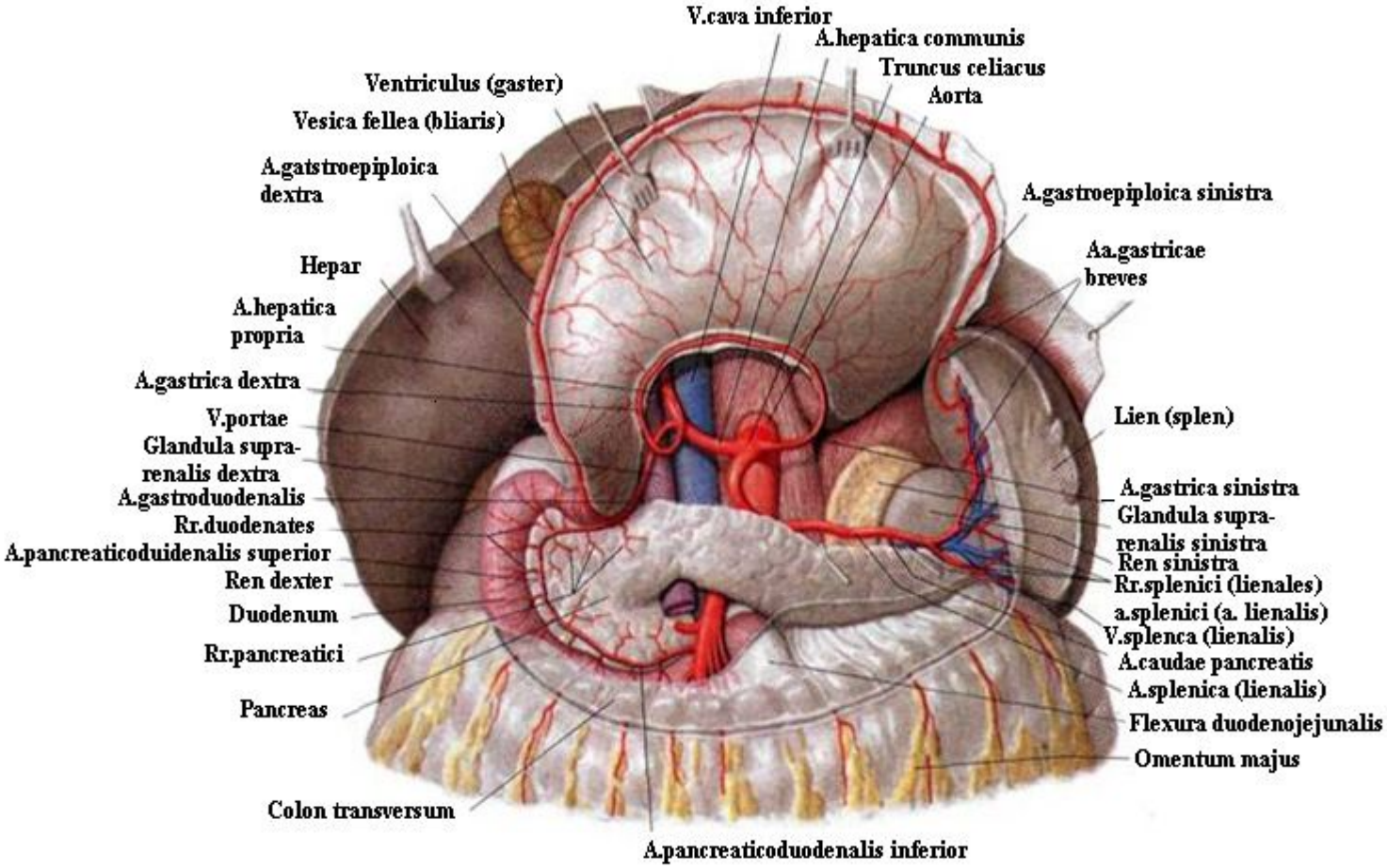
V.cava inferior
A.hepatica communis
Truncus celiacus
Aorta
Ventriculus (gaster)
Vesica fellea (bliaris)
A.gatstroepiploica dextra
A.gastroepiploica sinistra
Hepar
Aa.gastricae breves
A.hepatica propria
A.gastrica dextra
V.portae
Glandula supra-renalis dextra
A.gastroduodenalis
Rr.duodenates
A.pancreaticoduidenalis superior
Ren dexter
Duodenum
Rr.pancreatici
Pancreas
Colon transversum
A.pancreaticoduodenalis inferior
Lien (splen)
A.gastrica sinistra
Glandula supra-renalis sinistra
Ren sinistra
Rr.splenici (lienales)
a.splenici (a. lienalis)
V.splenca (lienalis)
A.caudae pancreatis
A.splenica (lienalis)
Flexura duodenojejunalis
Omentum majus

Двенадцатиперстная кишка

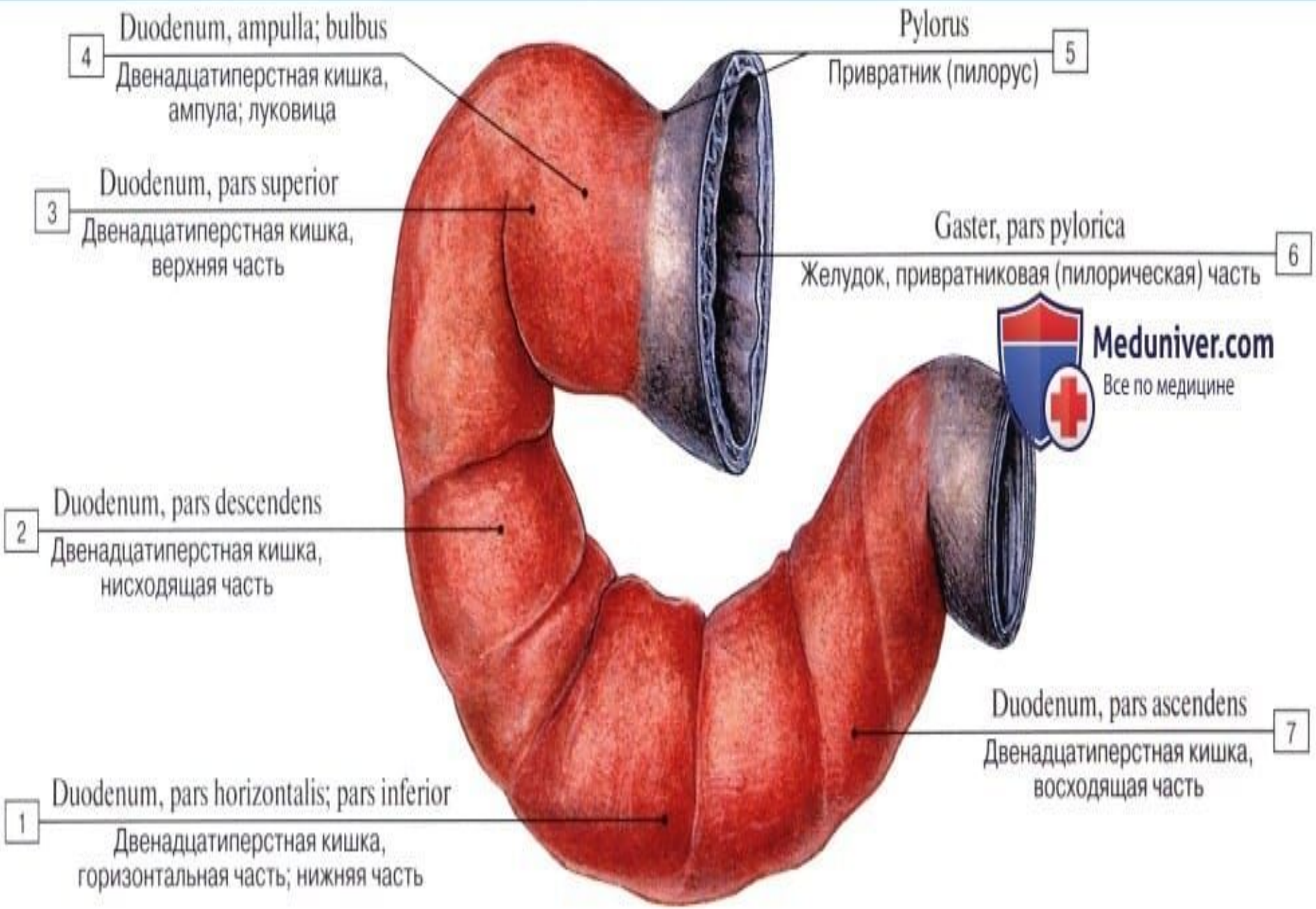

Топография двенадцатиперстной кишки

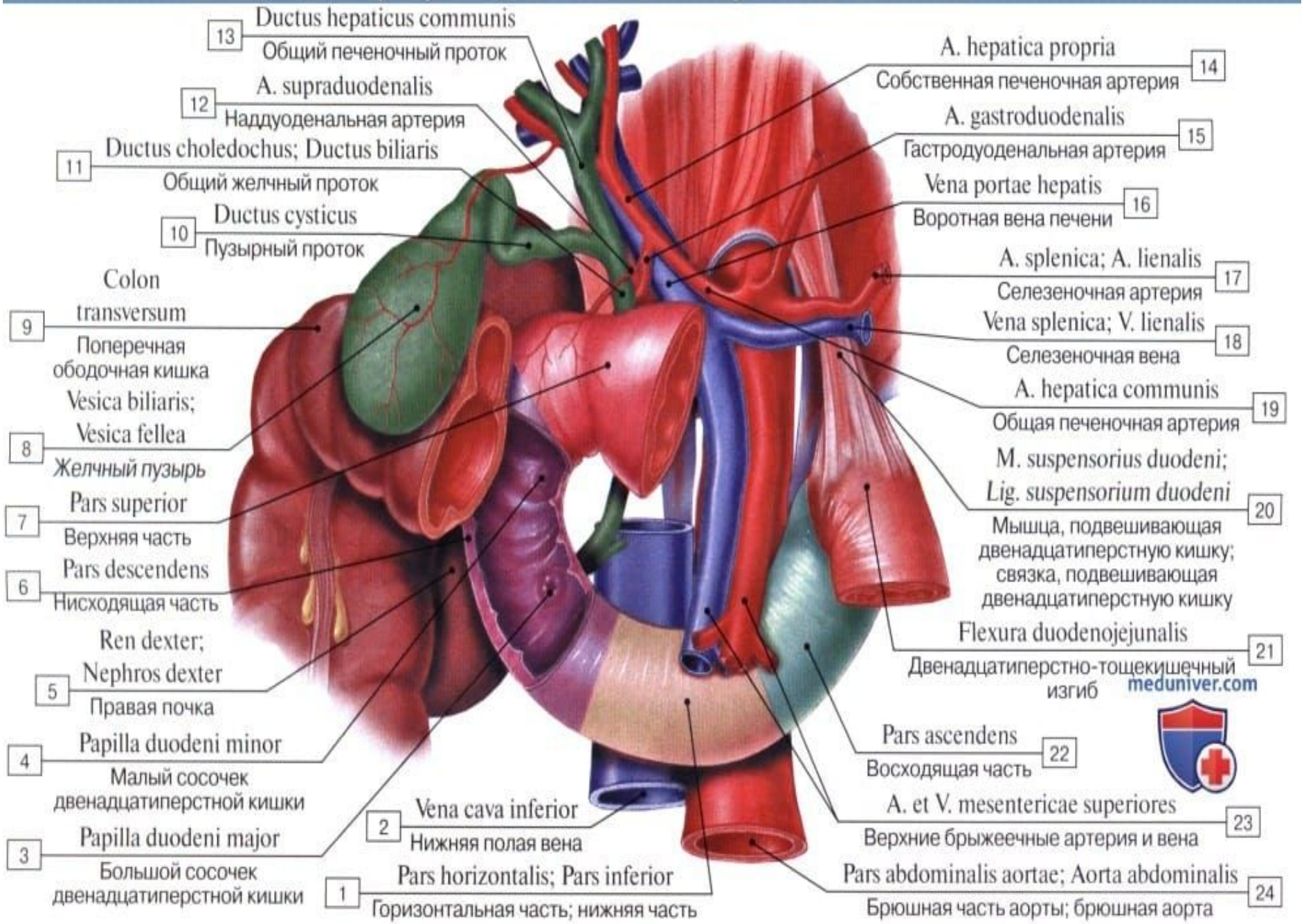

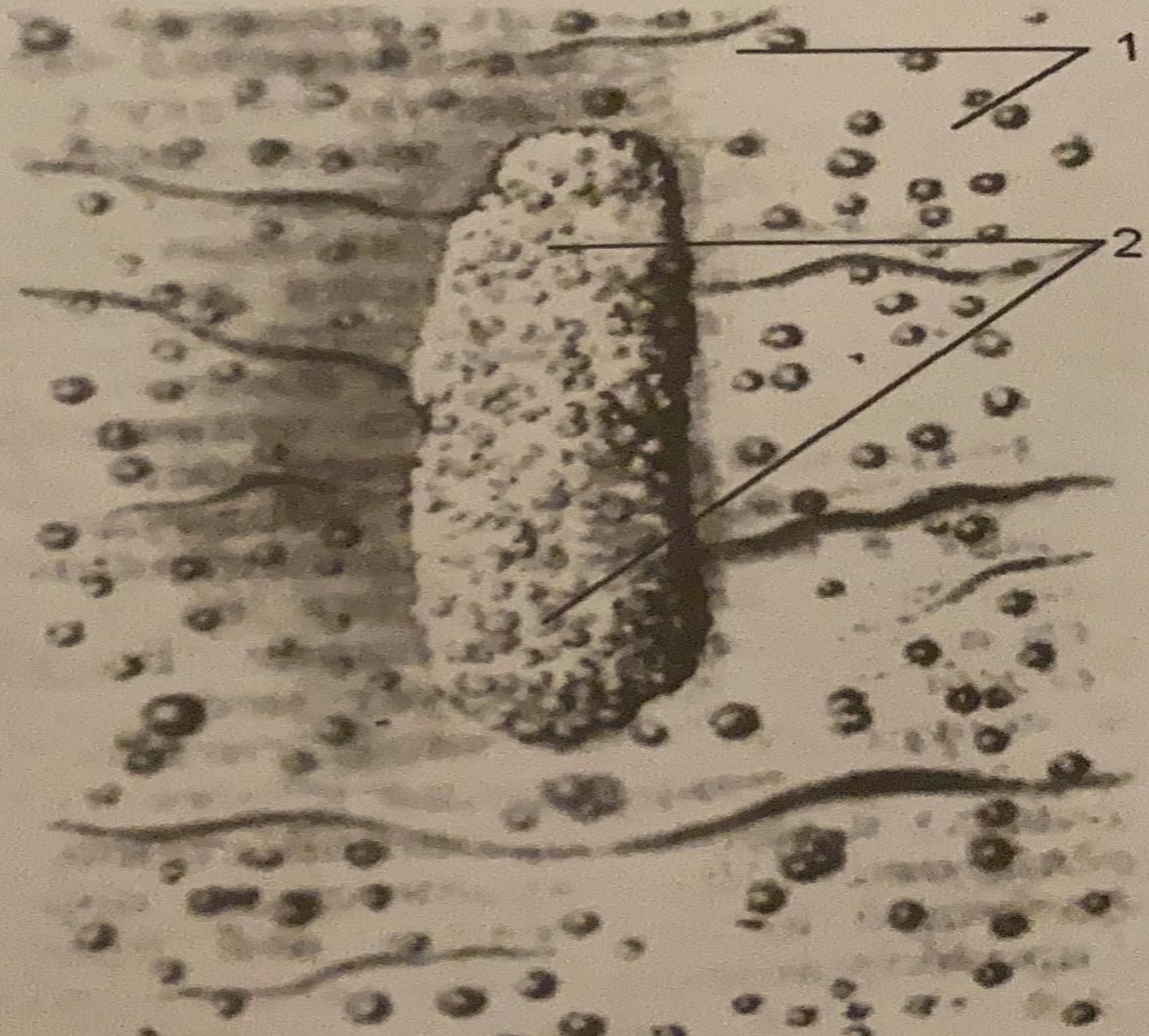
1
2
3

сірлі қабық өсінділерінің

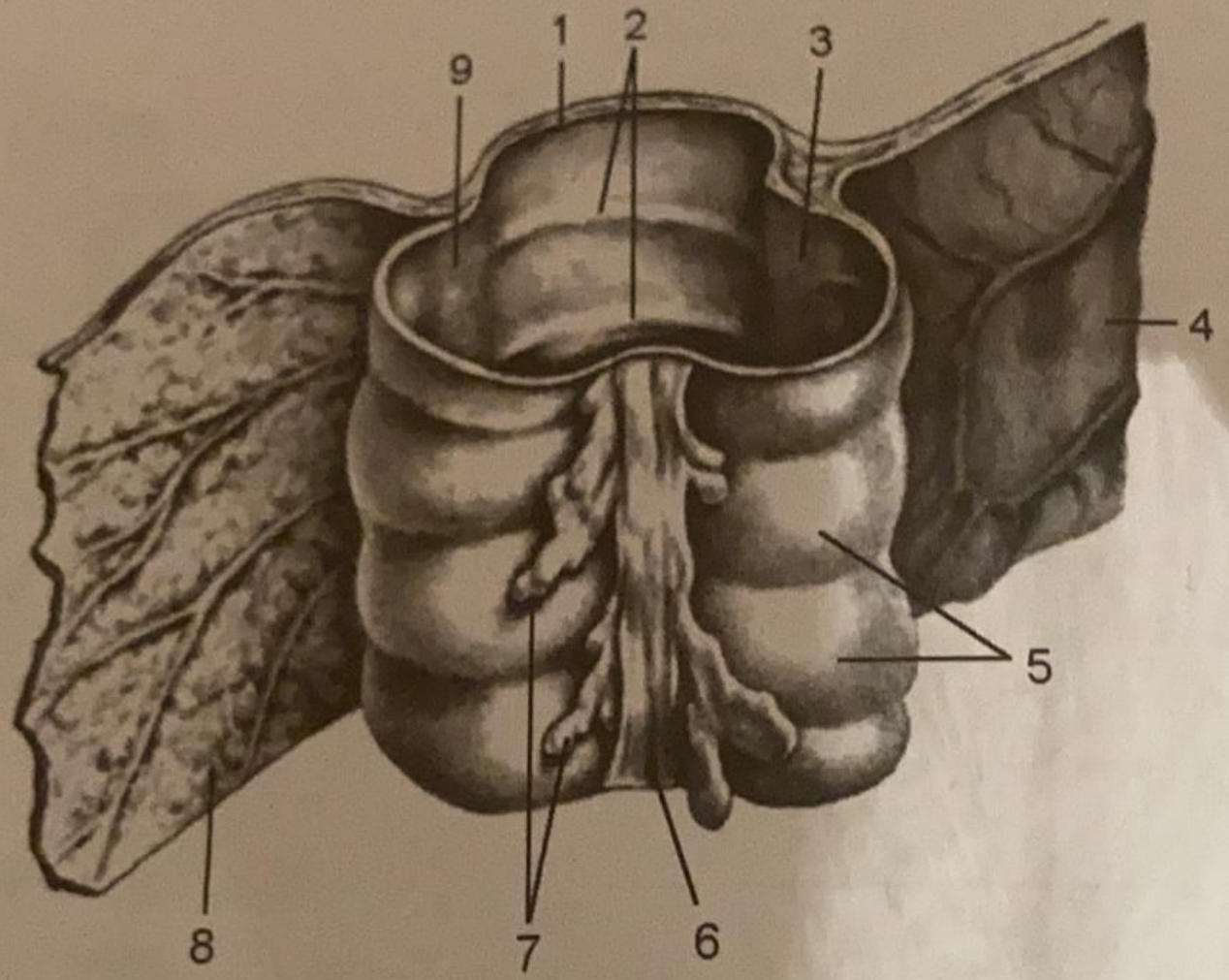

217 - с у р е т. Көлденең жиек ішектің бөлігі.
1 - ішектің қабырғасы; 2 - plica semilunaris colis; 3 - taenia mesocolica; 4 - mesocolon; 5 - haustrae coli; 6 - taenia libera; 7 - appendices epiploicae; 8 - omentum majus; 9 - taenia omentalis.

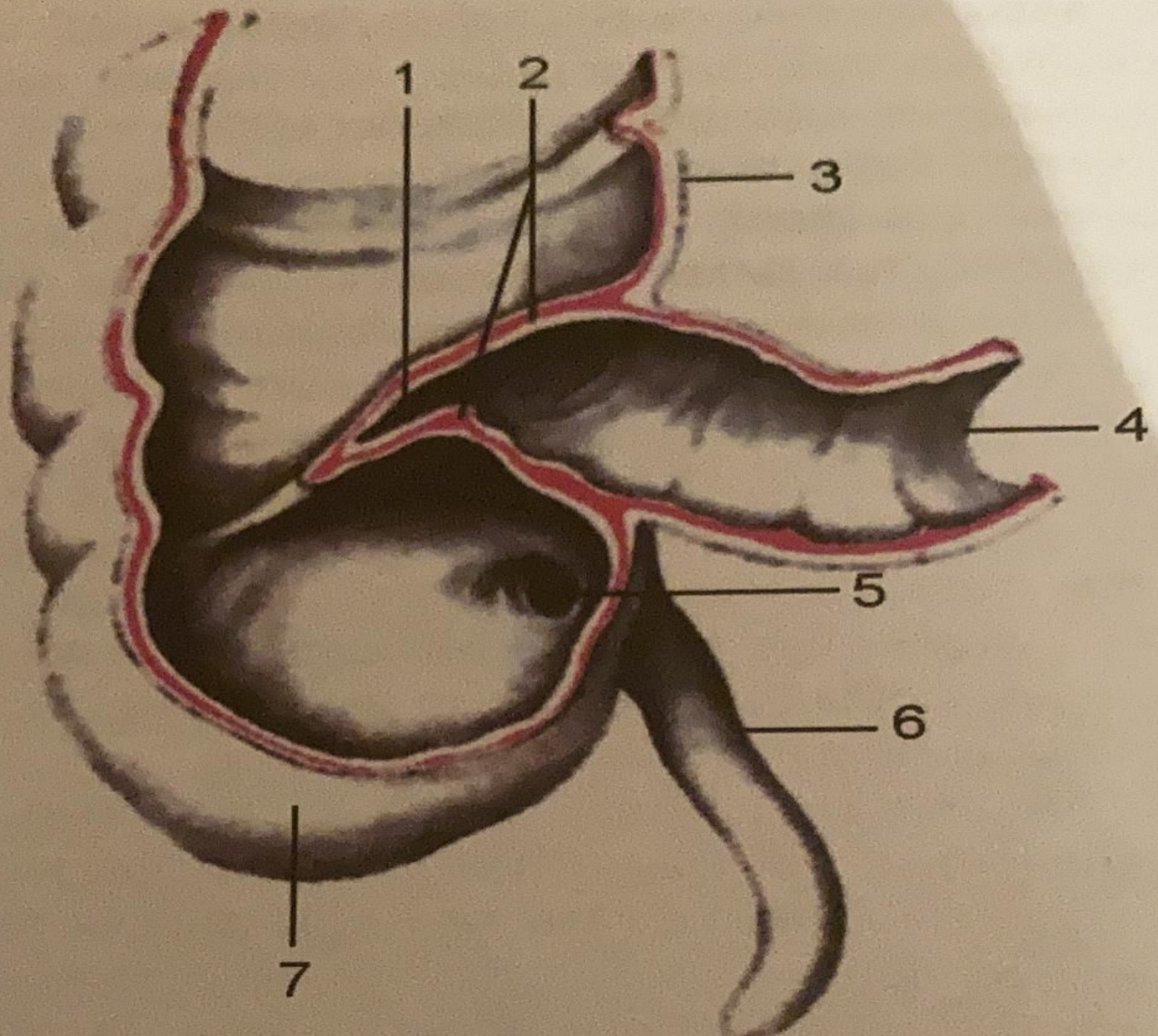
1
2
3
4
5
6
7

Толстая кишка

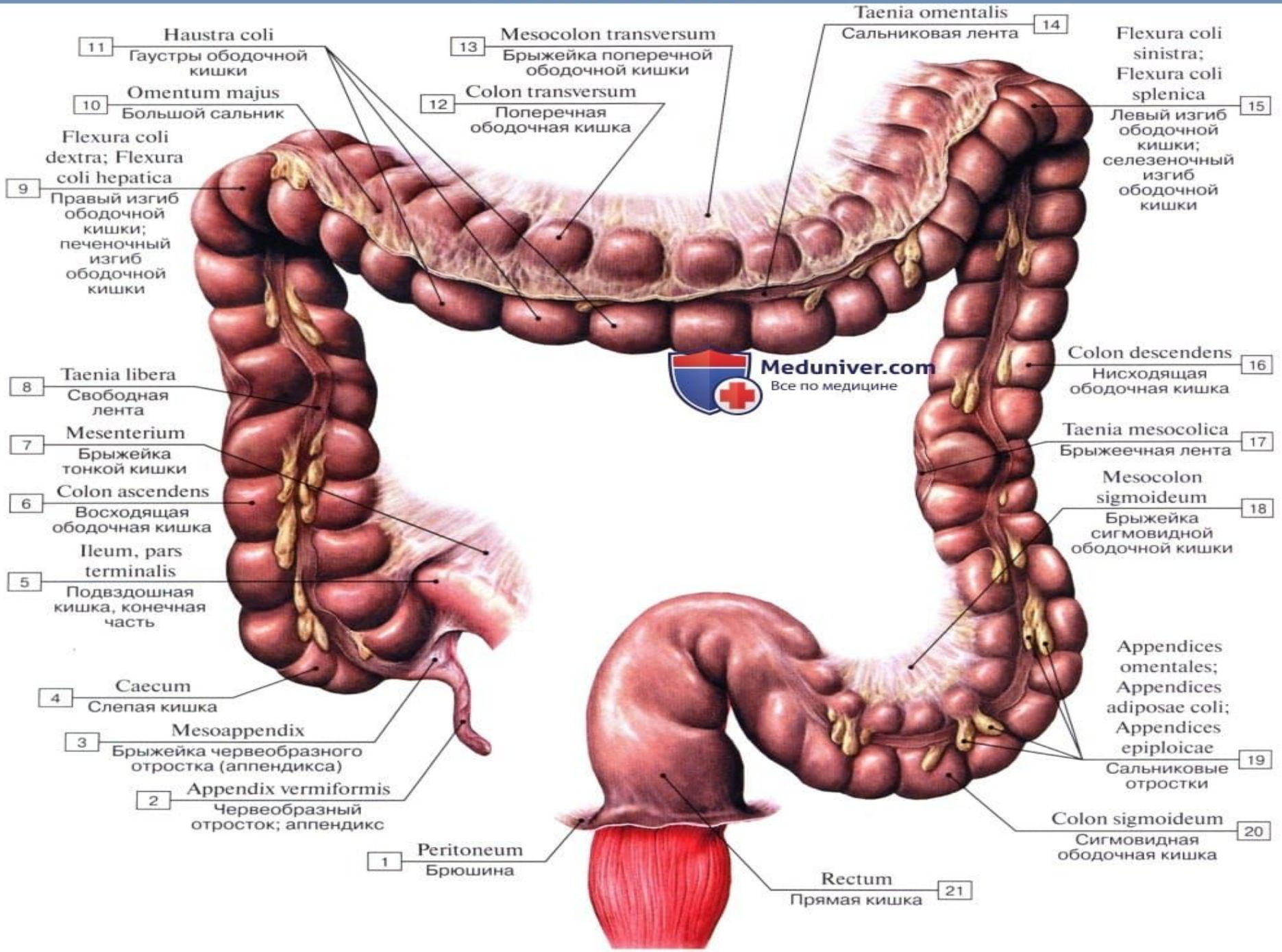

Скелетотопия ободочной кишки

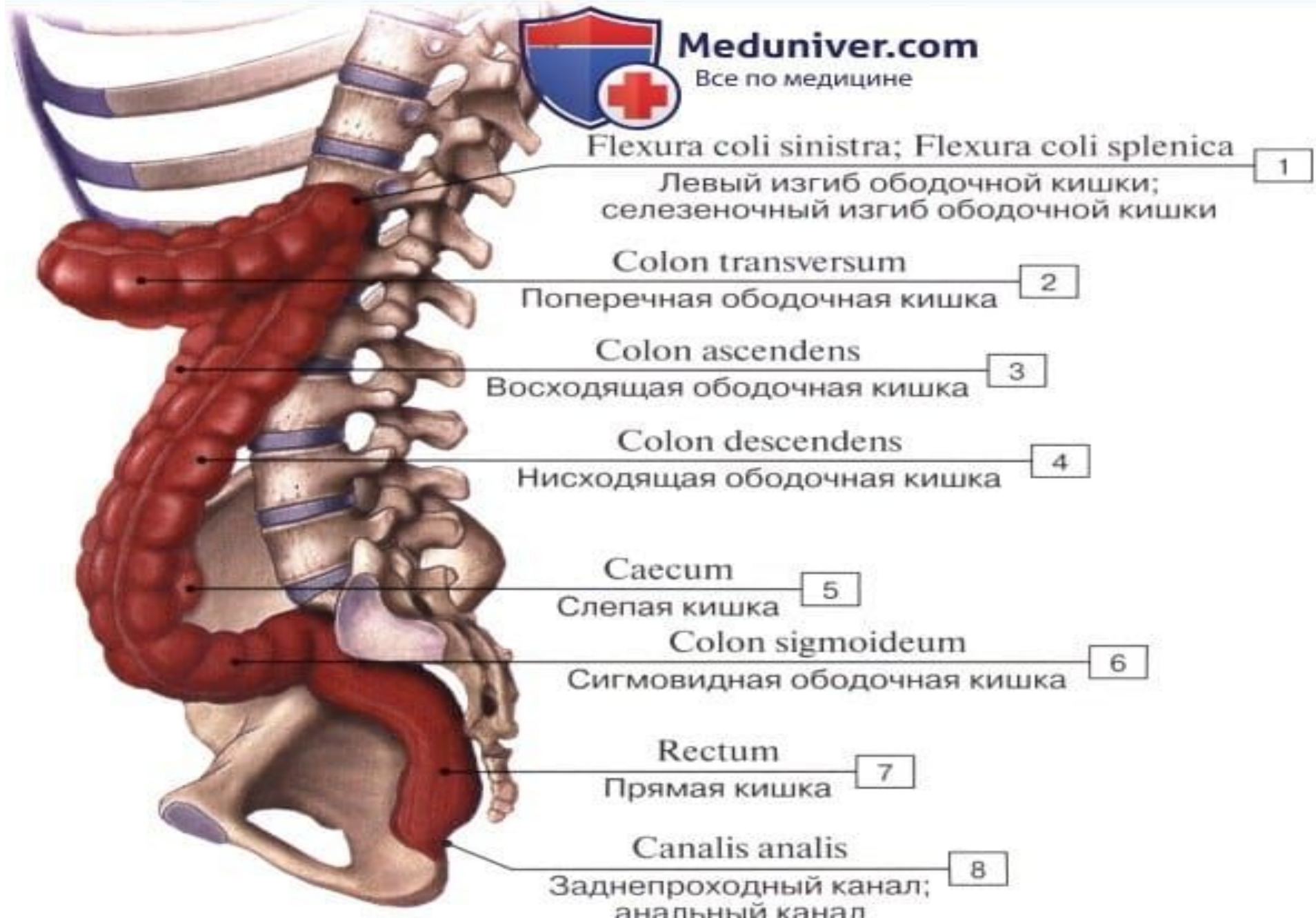

Участок толстой кишки

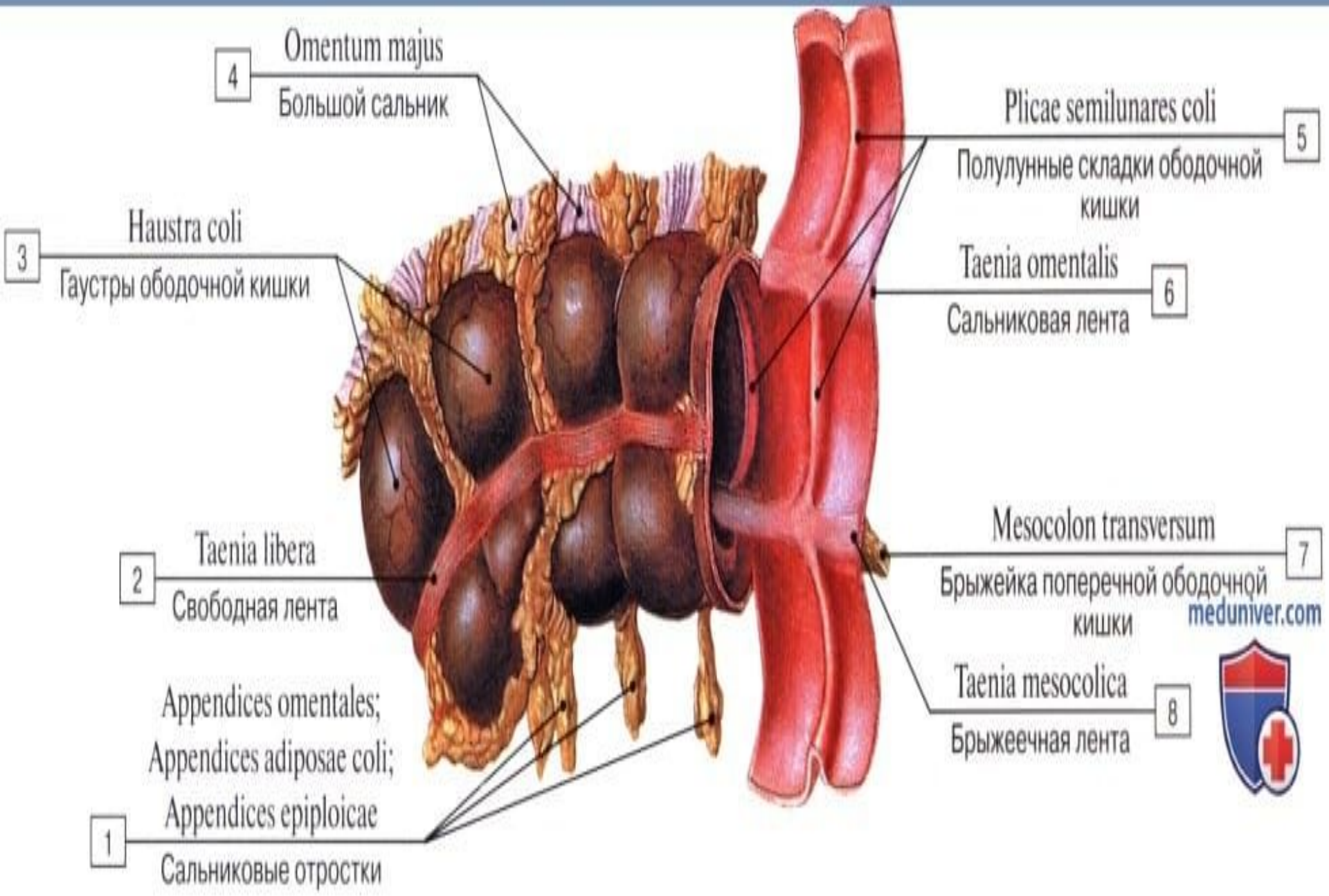
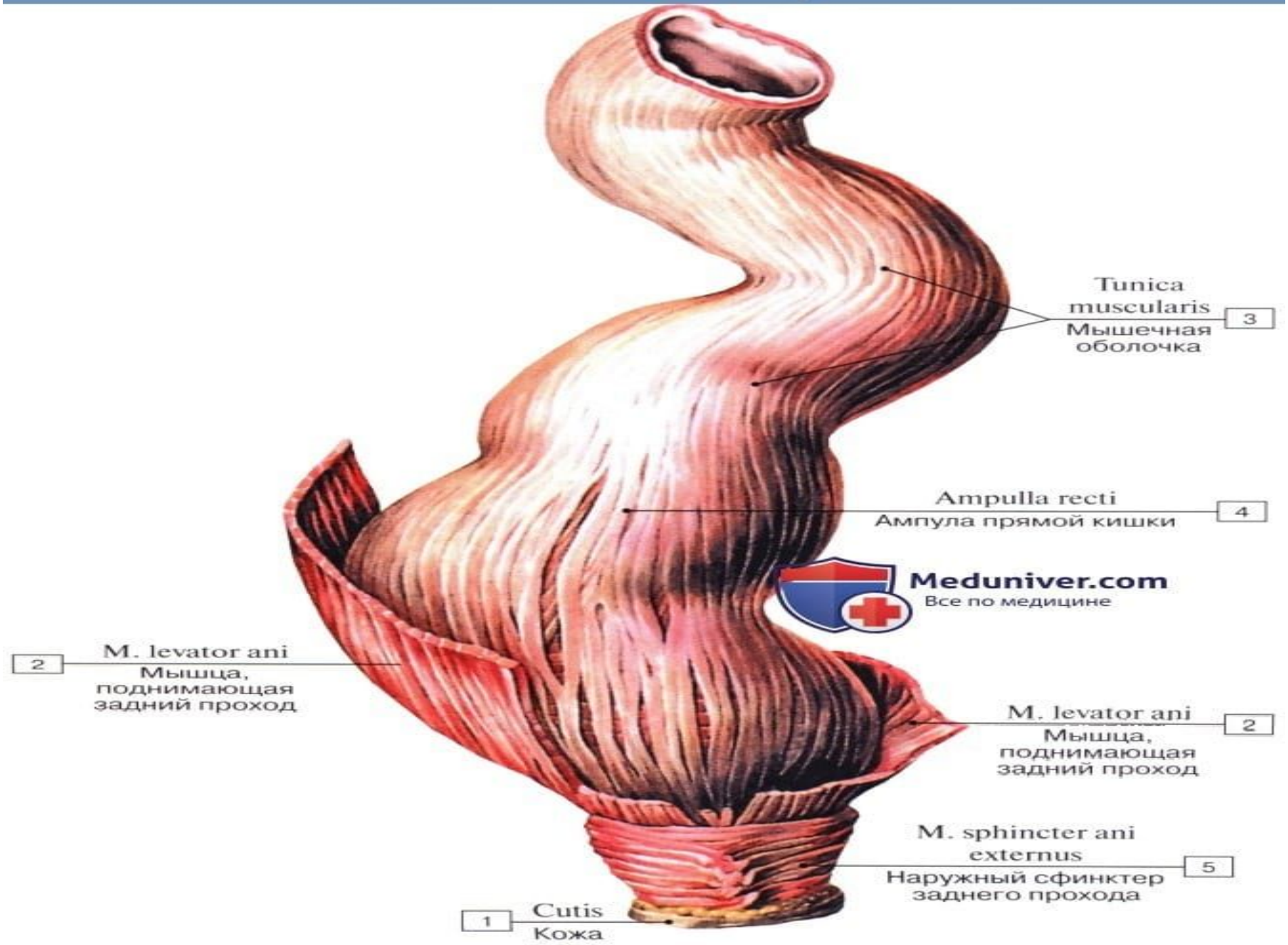
Мышечная оболочка прямой кишки