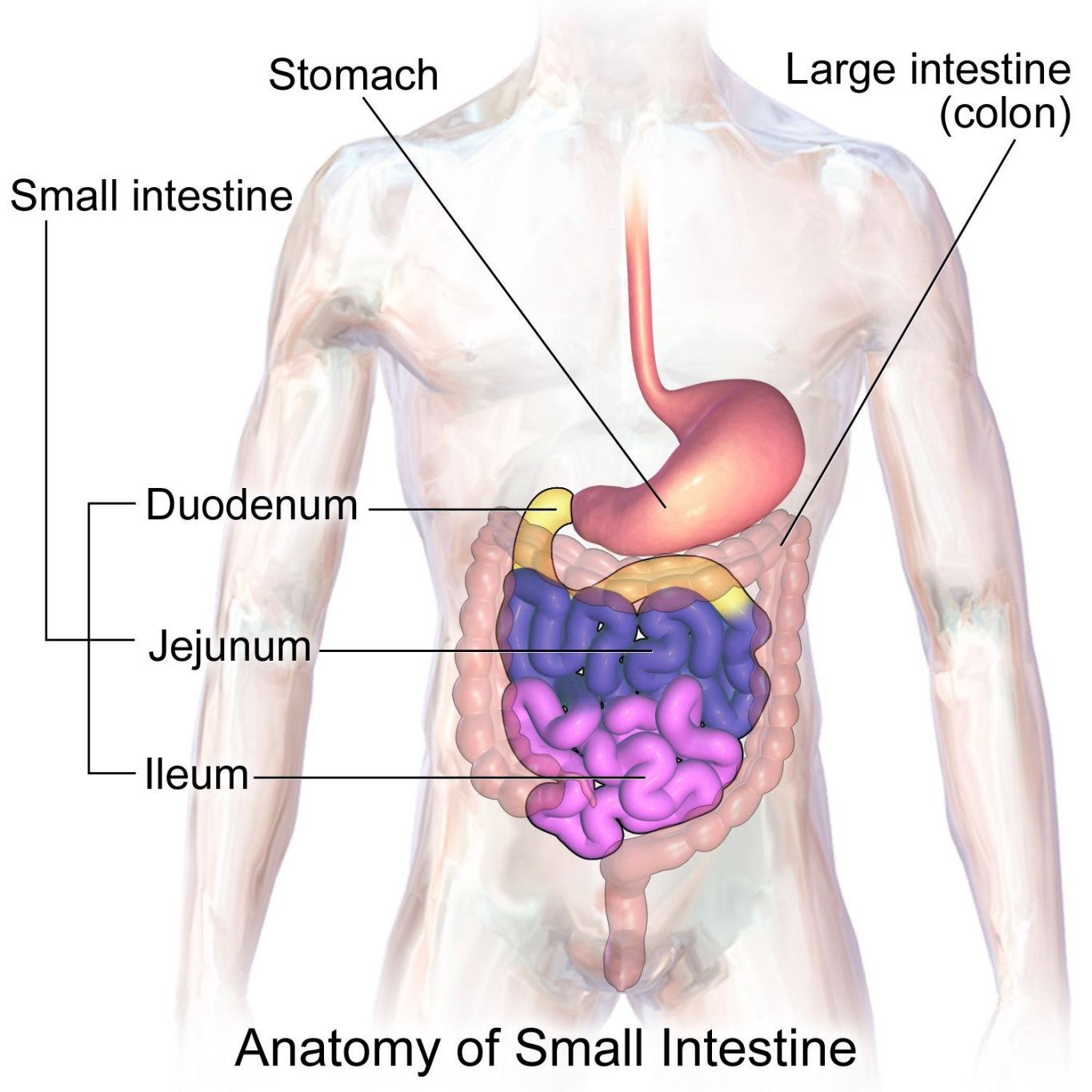
Stomach
Large intestine
(colon)
Small intestine
Duodenum
Jejunum
Ileum
Anatomy of Small Intestine

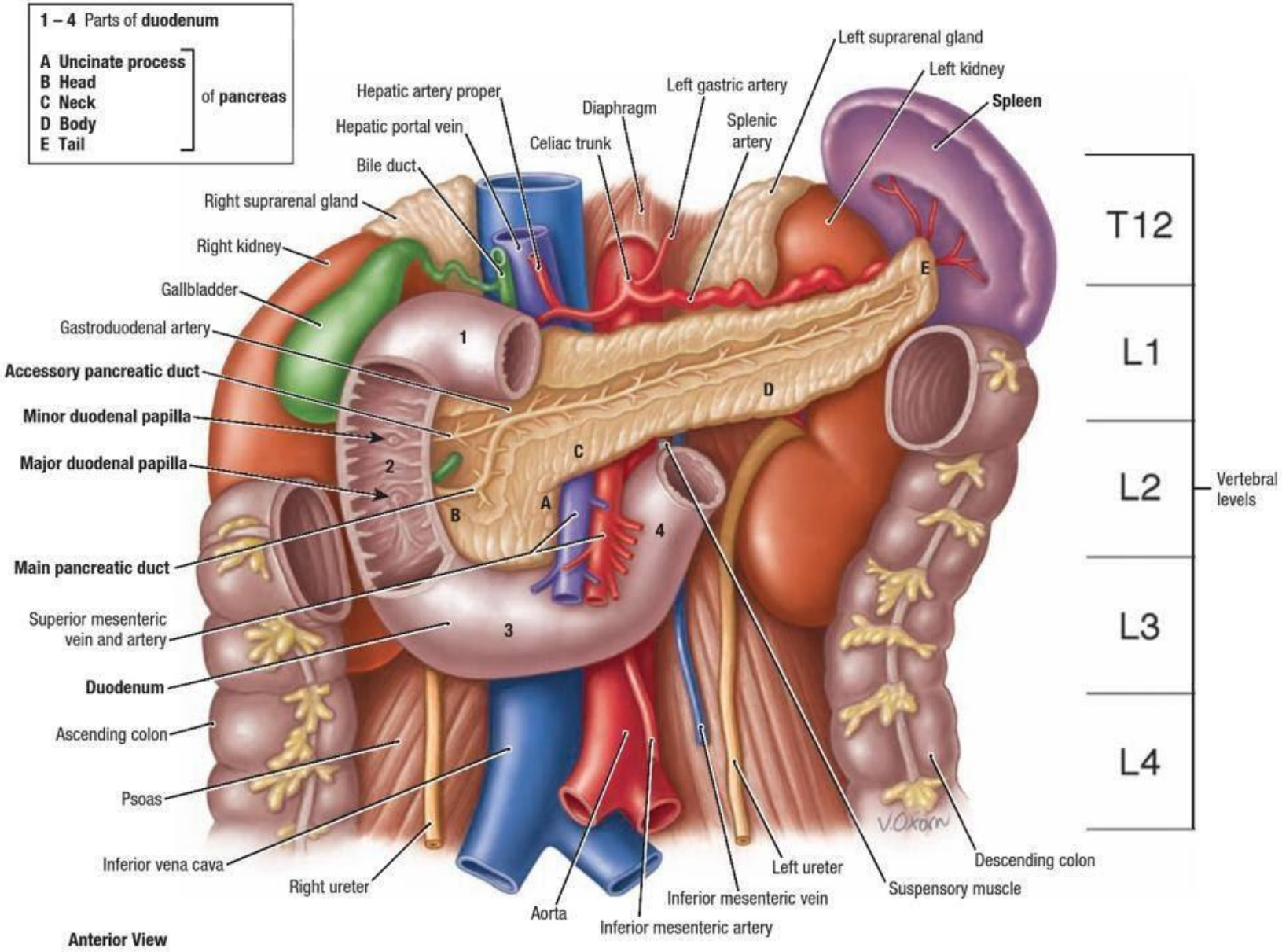


**2.37** PARTS AND RELATIONSHIPS OF PANCREAS AND DUODENUM

**A.** Pancreas and duodenum in situ.

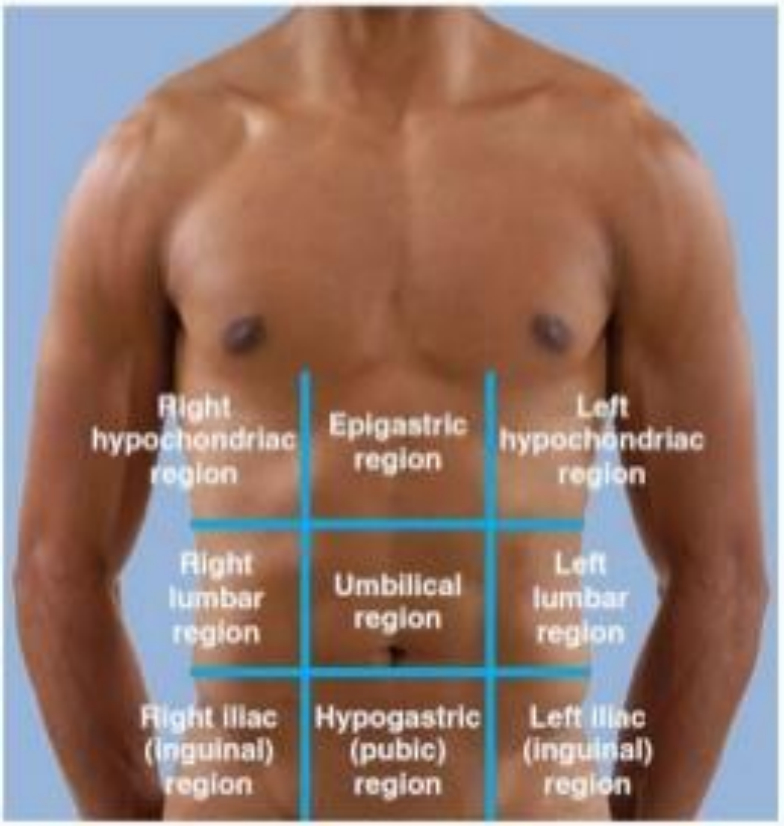
Right hypochondriac region
Epigastric region
Left hypochondriac region
Right lumbar region
Umbilical region
Left lumbar region
Right iliac (inguinal) region
Hypogastric (pubic) region
Left iliac (inguinal) region

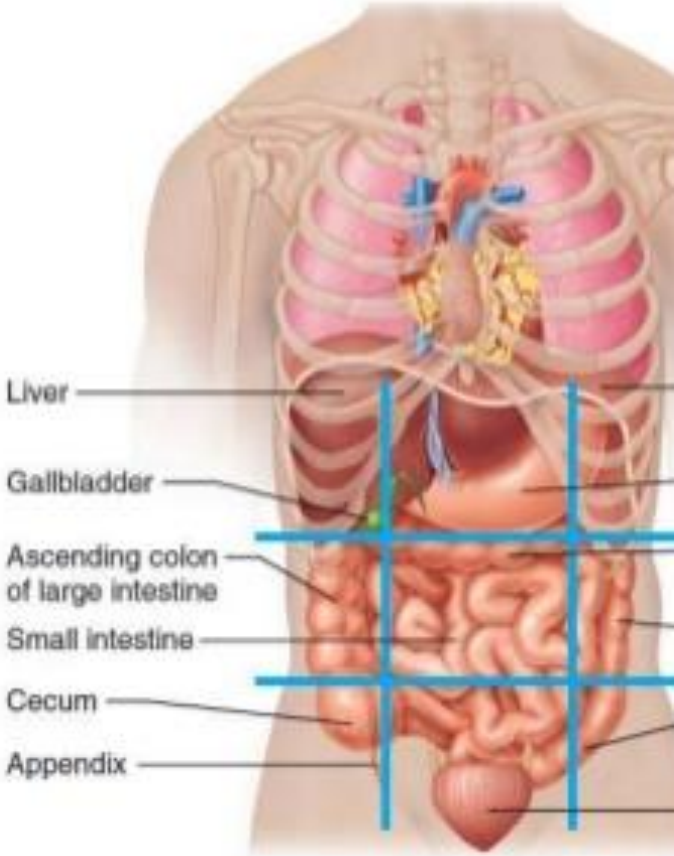
Liver
Gallbladder
Ascending colon of large intestine
Small intestine
Cecum
Appendix

# Duodenum

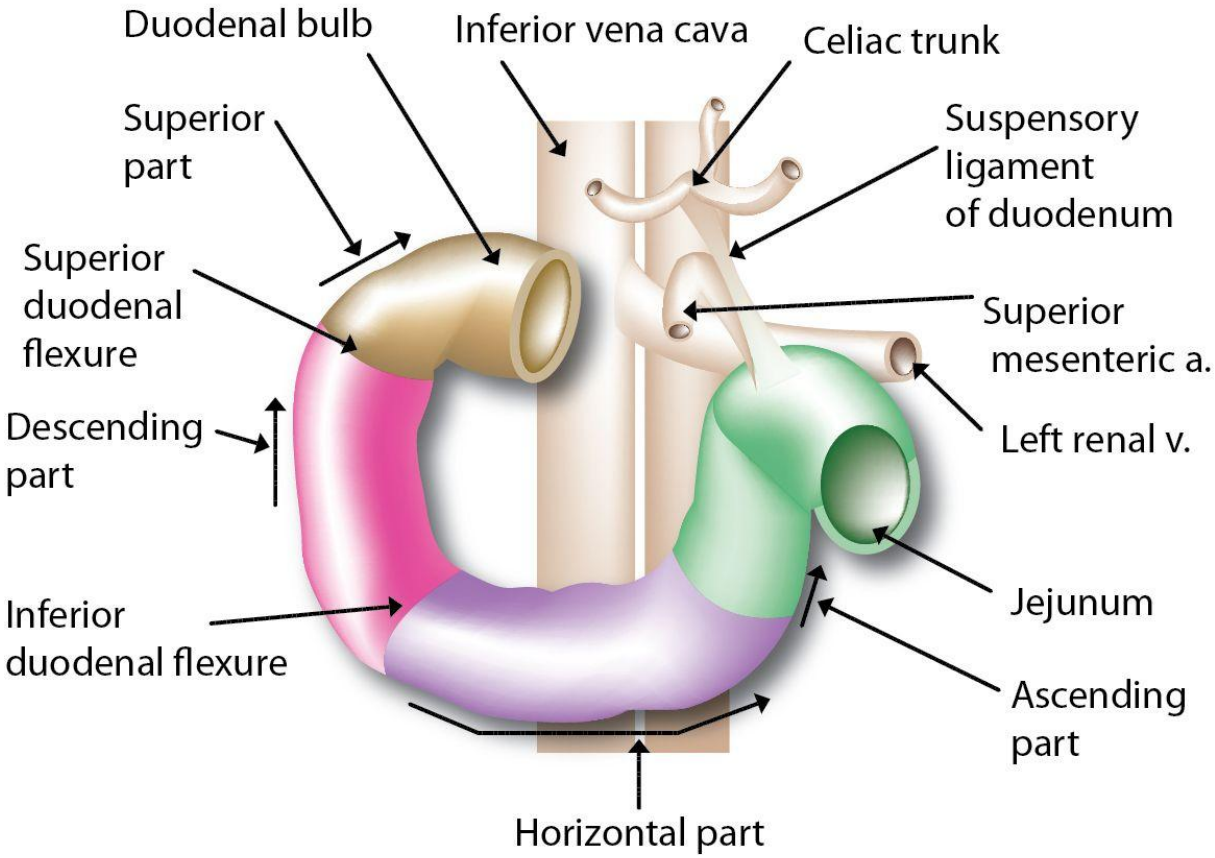


HELP
Health Education Library for People
©2013 www.healthlibrary.com

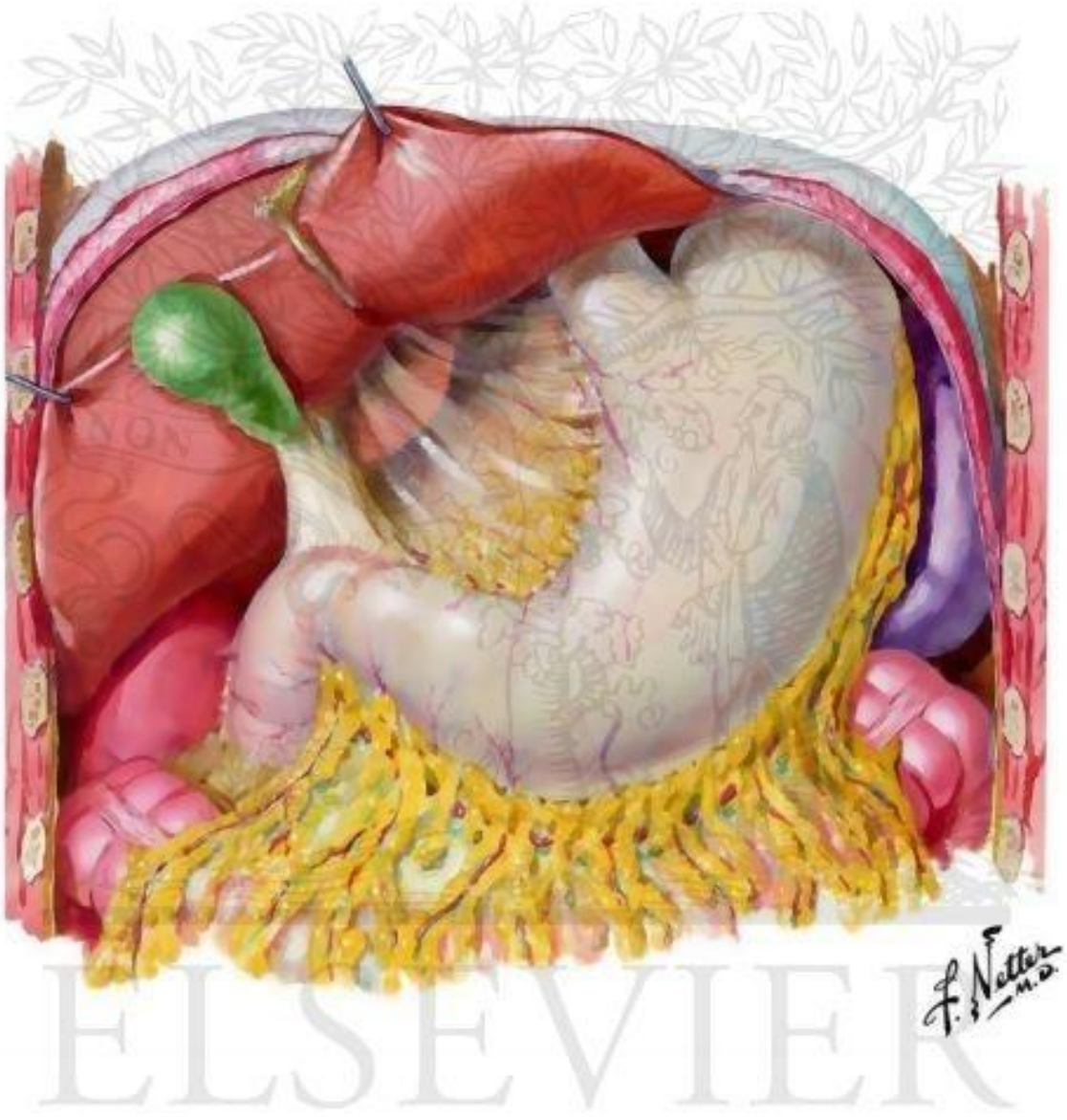


© ELSEVIER, INC. – NETTERIMAGES.COM

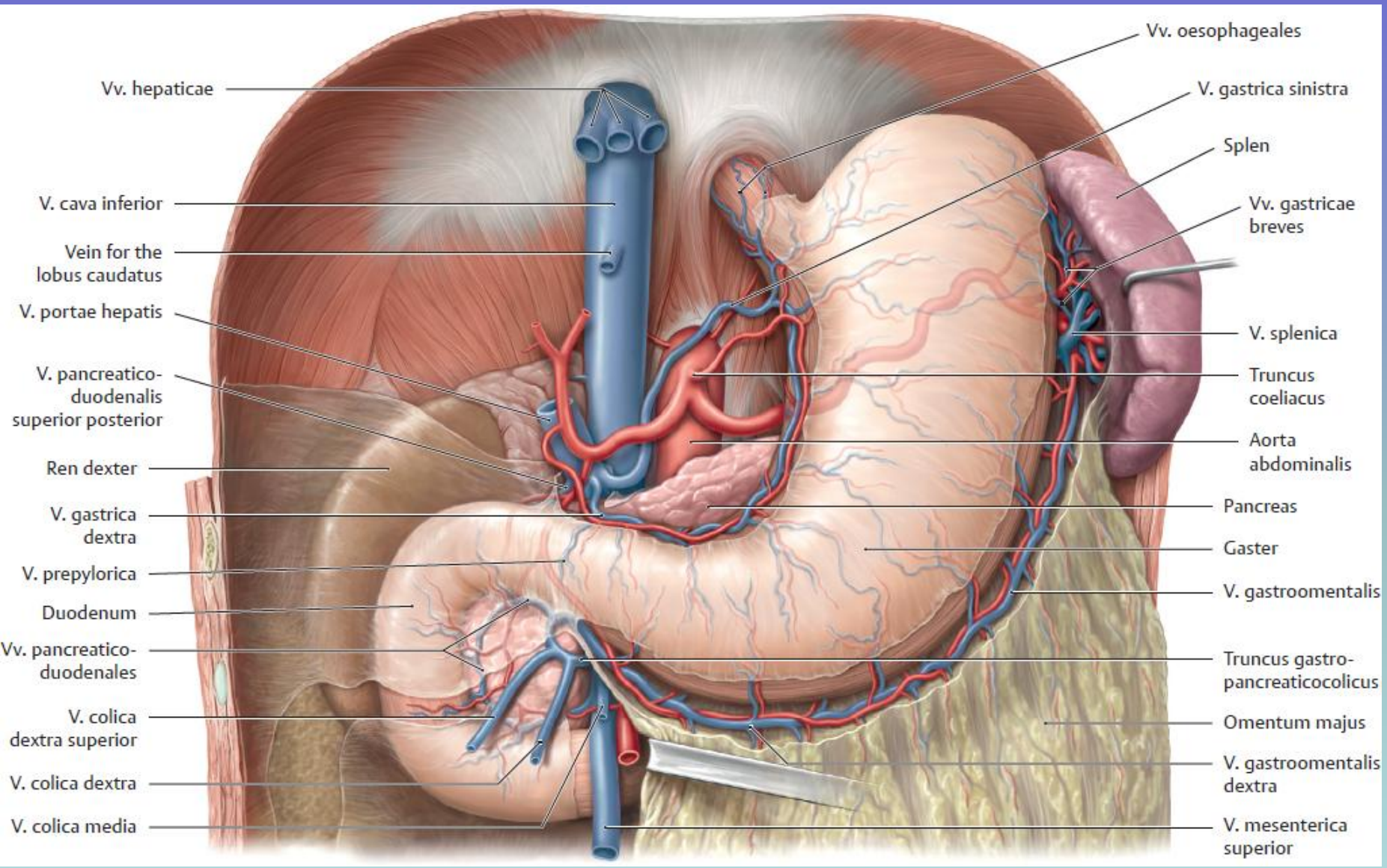
Vv. hepaticae
V. cava inferior
Vein for the lobus caudatus
V. portae hepatis
V. pancreatico-duodenalis superior posterior
Ren dexter
V. gastrica dextra
V. prepylorica
Duodenum
Vv. pancreatico-duodenales
V. colica dextra superior
V. colica dextra
V. colica media
Vv. oesophageales
V. gastrica sinistra
Splen
Vv. gastricae breves
V. splenica
Truncus coeliacus
Aorta abdominalis
Pancreas
Gaster
V. gastroomentalis
Truncus gastro-pancreaticocolicus
Omentum majus
V. gastroomentalis dextra
V. mesenterica superior

# Peritoneum of Posterior Abdominal Wall

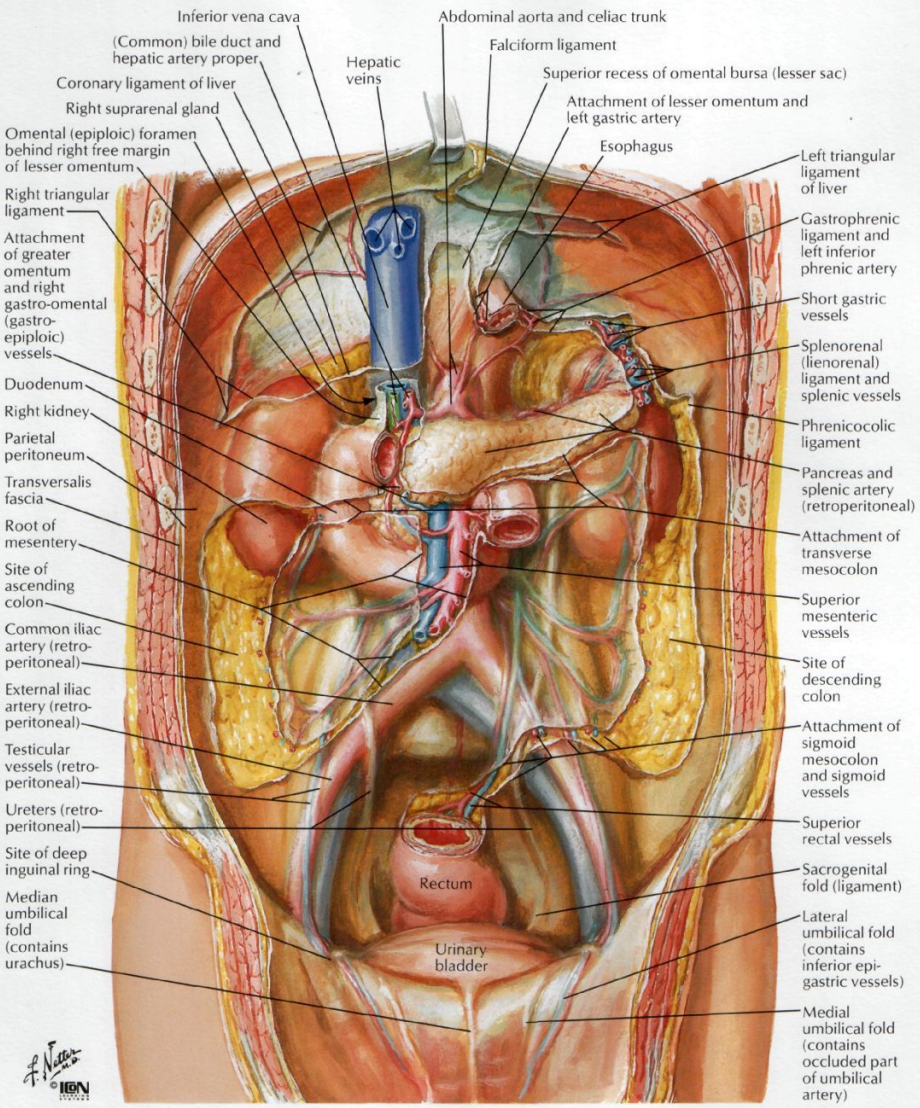

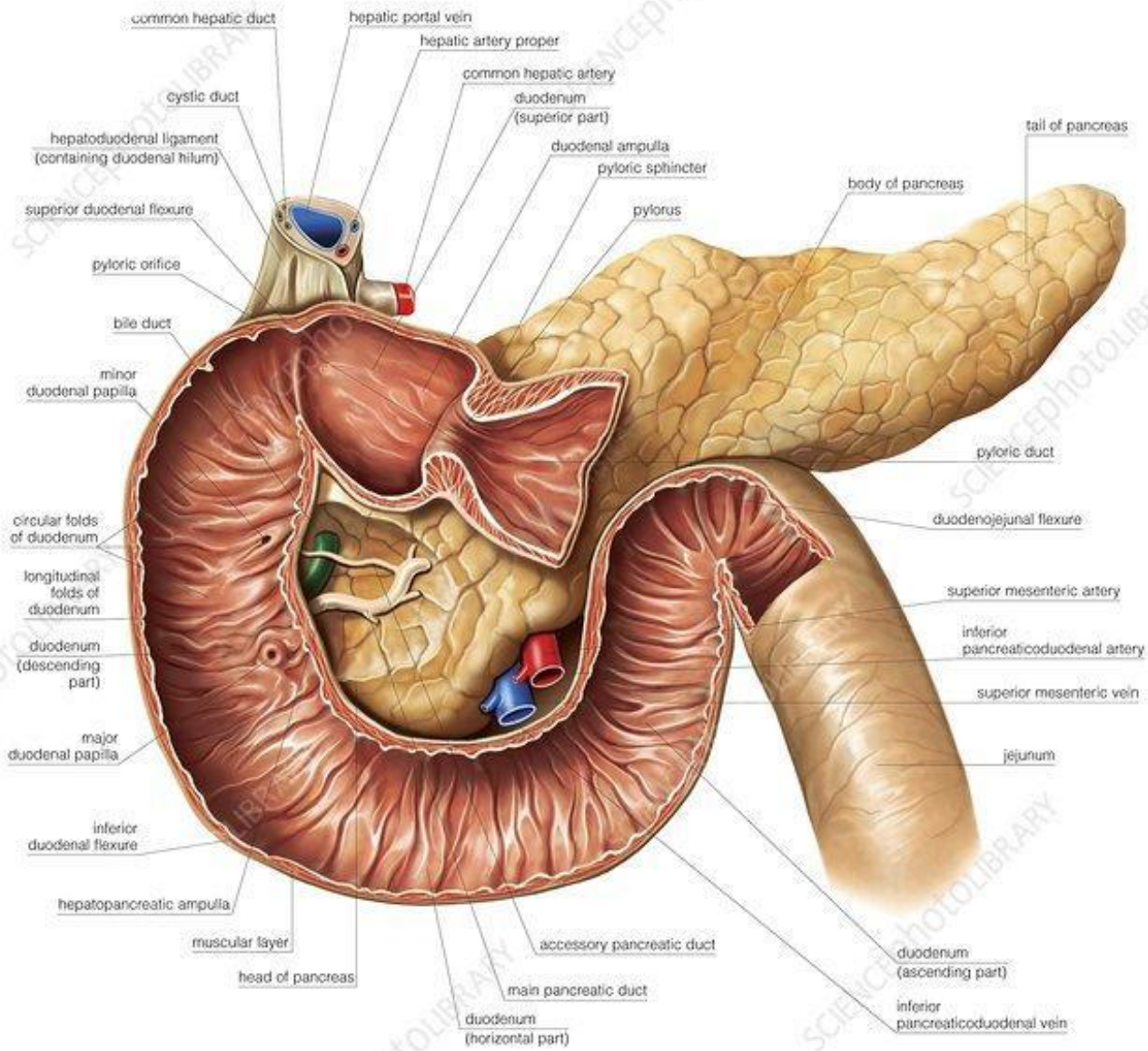
common hepatic duct
hepatic portal vein
hepatic artery proper
common hepatic artery
cystic duct
duodenum (superior part)
hepatoduodenal ligament (containing duodenal hilum)
duodenal ampulla
pyloric sphincter
tail of pancreas
body of pancreas
superior duodenal flexure
pylorus
pyloric orifice
bile duct
minor duodenal papilla
pyloric duct
circular folds of duodenum
duodenojejunal flexure
longitudinal folds of duodenum
superior mesenteric artery
inferior pancreaticoduodenal artery
duodenum (descending part)
superior mesenteric vein
major duodenal papilla
jejunum
inferior duodenal flexure
hepatopancreatic ampulla
muscular layer
accessory pancreatic duct
duodenum (ascending part)
head of pancreas
main pancreatic duct
inferior pancreaticoduodenal vein
duodenum (horizontal part)

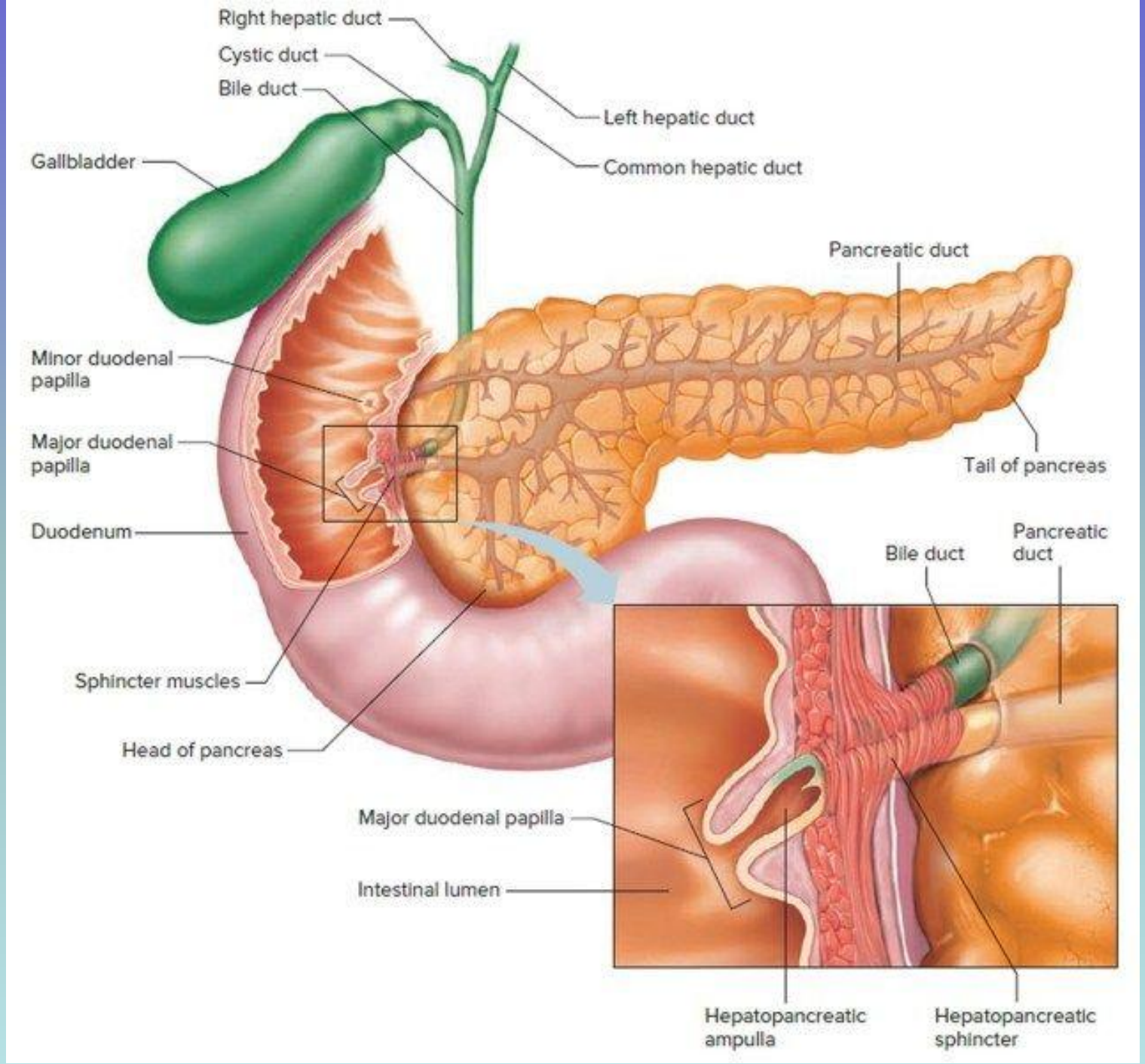
Right hepatic duct
Cystic duct
Bile duct
Left hepatic duct
Common hepatic duct
Gallbladder
Pancreatic duct
Minor duodenal papilla
Major duodenal papilla
Tail of pancreas
Duodenum
Bile duct
Pancreatic duct
Sphincter muscles
Head of pancreas
Major duodenal papilla
Intestinal lumen
Hepatopancreatic ampulla
Hepatopancreatic sphincter

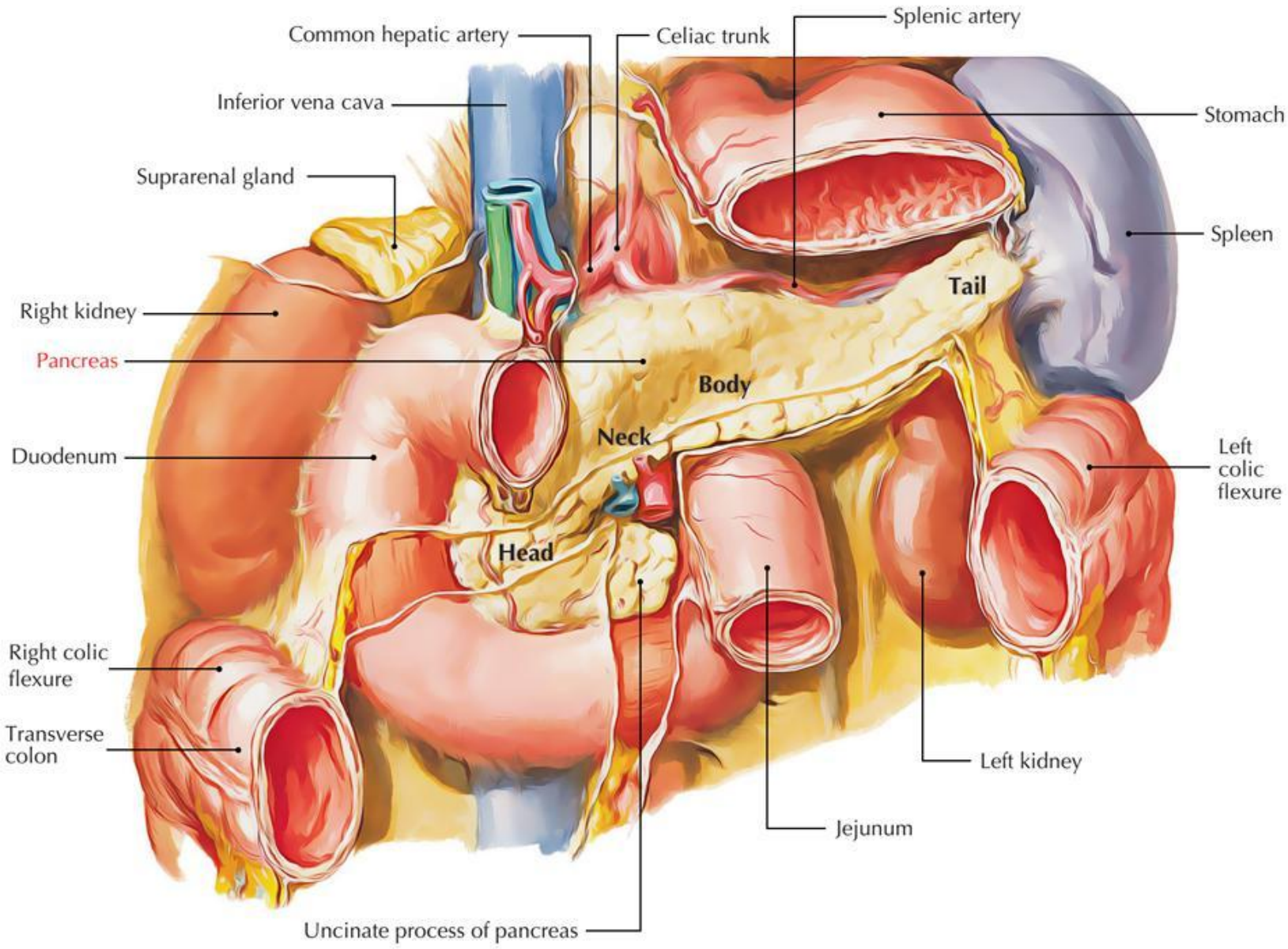
Common hepatic artery
Celiac trunk
Splenic artery
Inferior vena cava
Stomach
Suprarenal gland
Spleen
Tail
Right kidney
Pancreas
Body
Neck
Duodenum
Left colic flexure
Head
Right colic flexure
Transverse colon
Left kidney
Jejunum
Uncinate process of pancreas

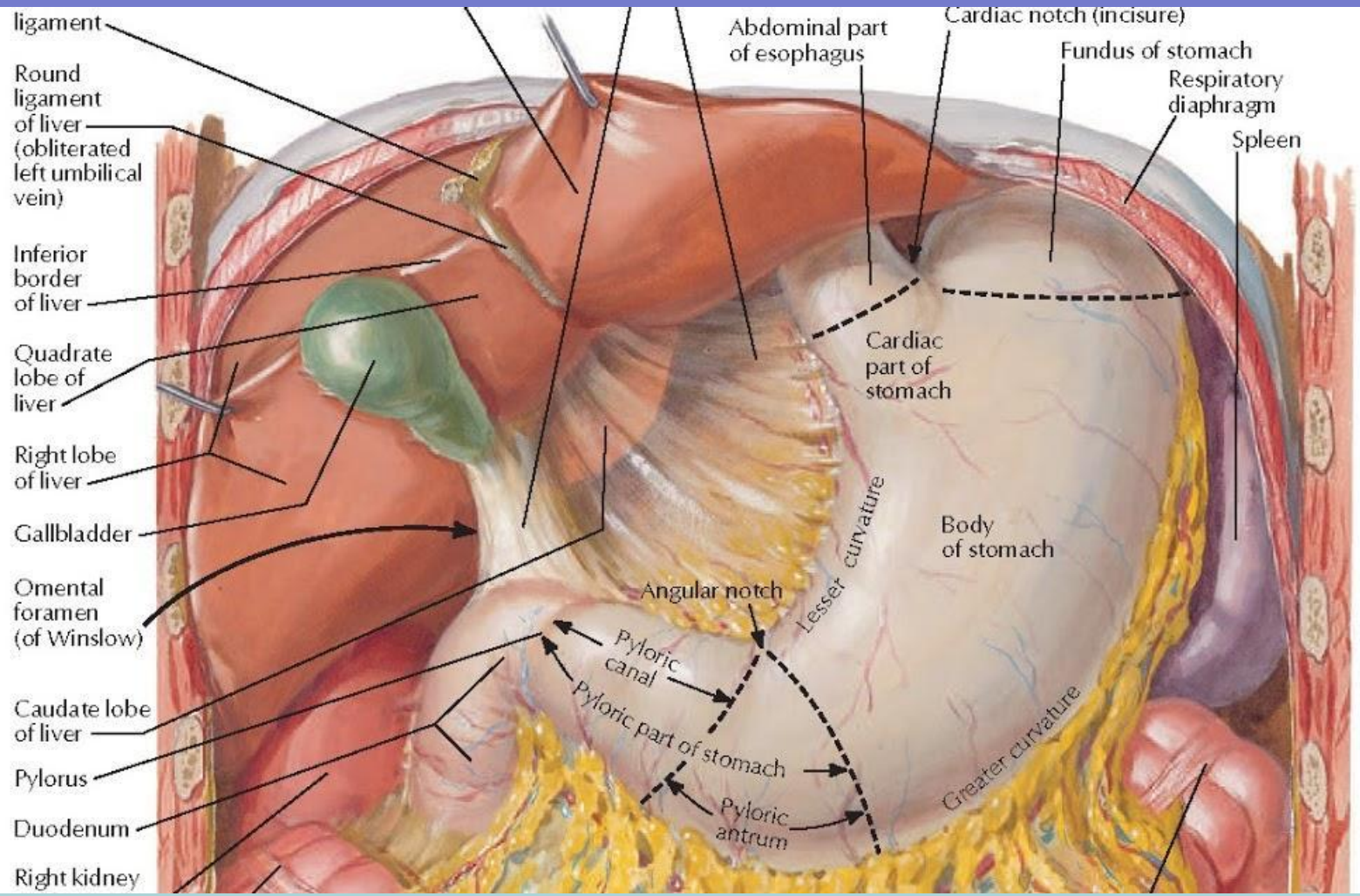
ligament
Round ligament of liver (obliterated left umbilical vein)
Inferior border of liver
Quadrate lobe of liver
Right lobe of liver
Gallbladder
Omental foramen (of Winslow)
Caudate lobe of liver
Pylorus
Duodenum
Right kidney
Abdominal part of esophagus
Cardiac notch (incisure)
Fundus of stomach
Respiratory diaphragm
Spleen
Cardiac part of stomach
Lesser curvature
Body of stomach
Angular notch
Pyloric canal
Pyloric part of stomach
Pyloric antrum
Greater curvature

# Mucosa and Musculature of Small Intestine

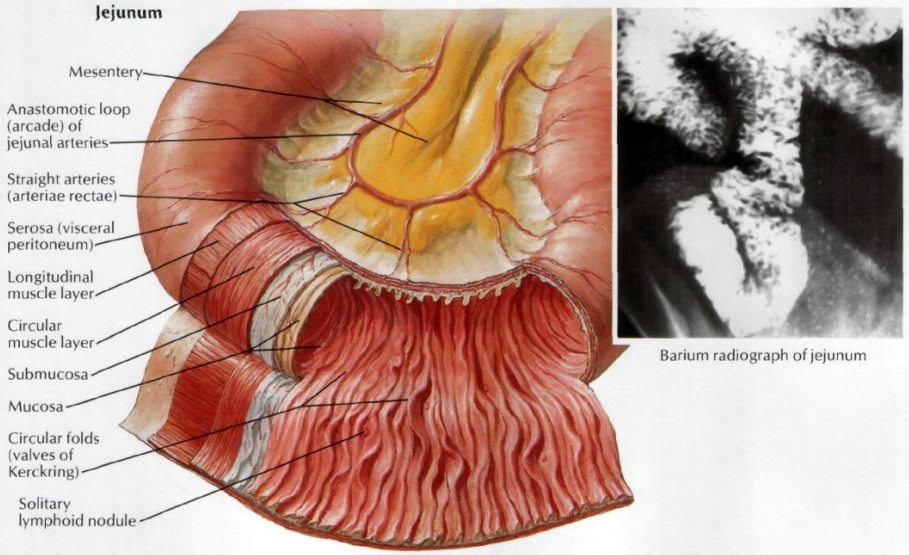




Barium radiograph of jejunum

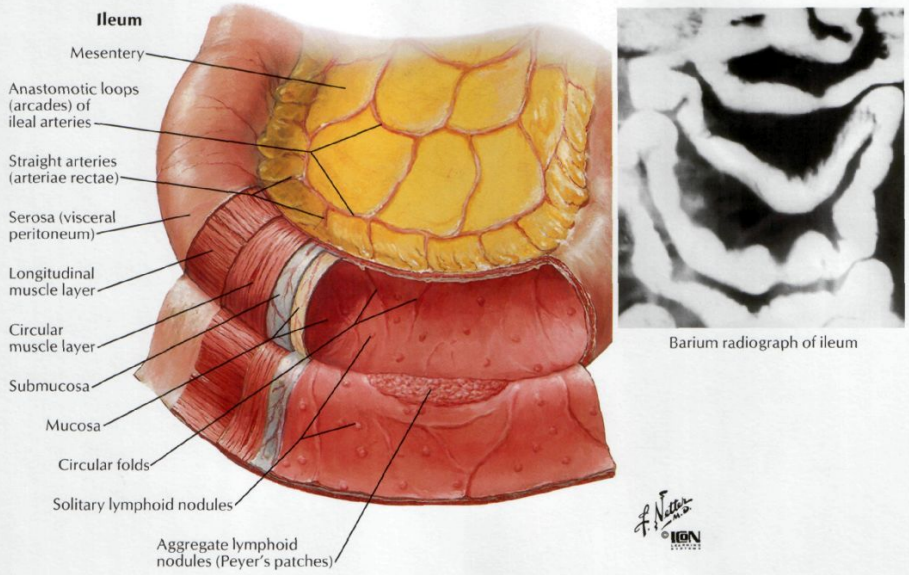




Barium radiograph of ileum

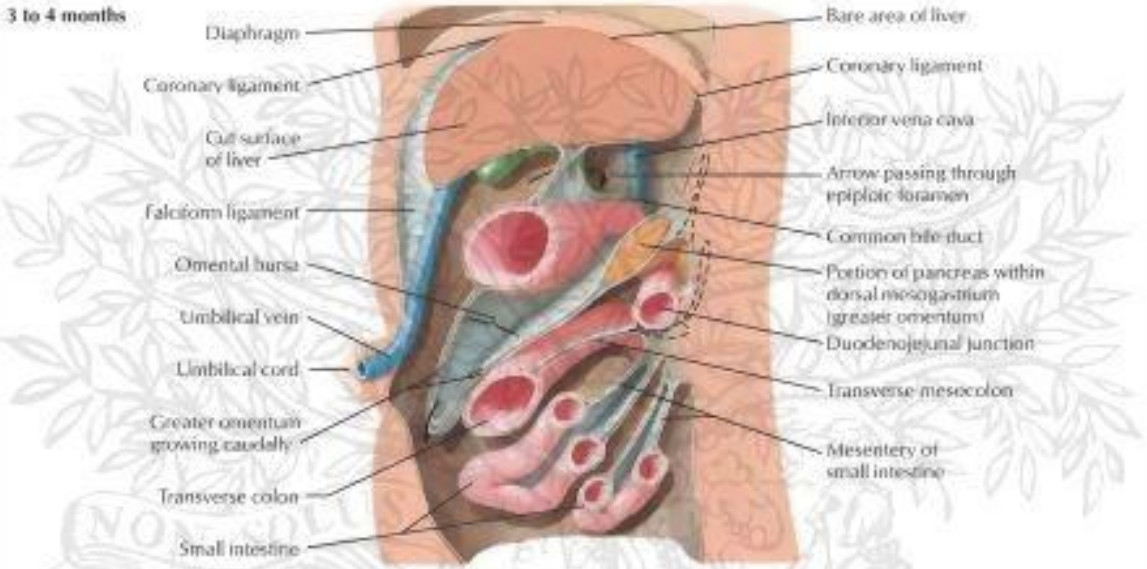


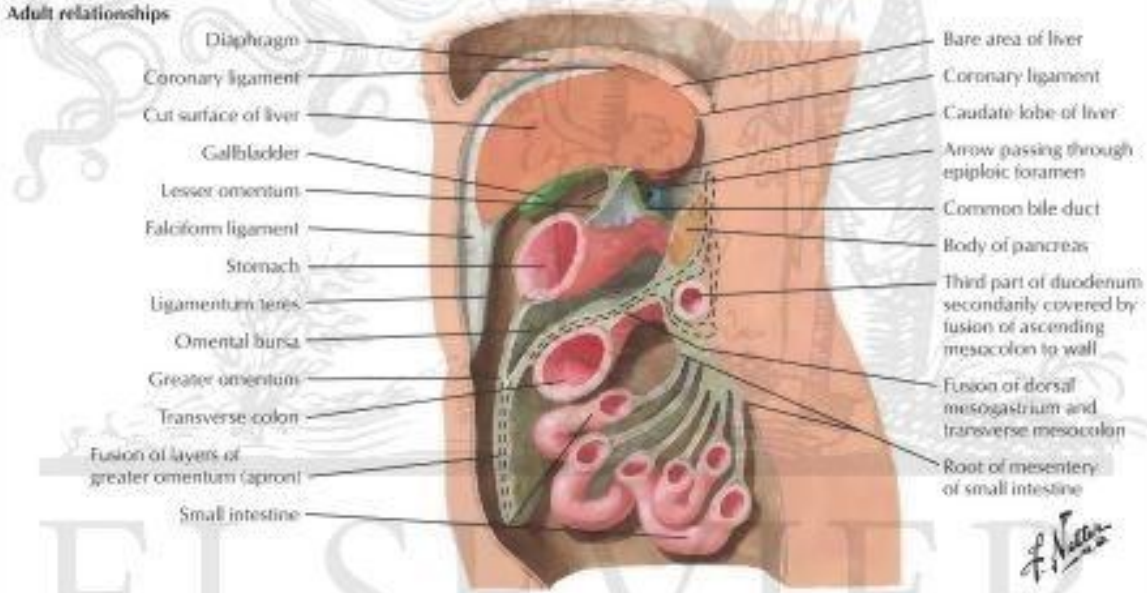


© Elsevier, Inc. - Netterimages.com
© ELSEVIER, INC. – NETTERIMAGES.COM

## A sagittal section showing the orientation of the mesenteries in an adult

The mesentery associated with the initial portion of the small intestine and the pancreas fuses with the posterior abdominal wall

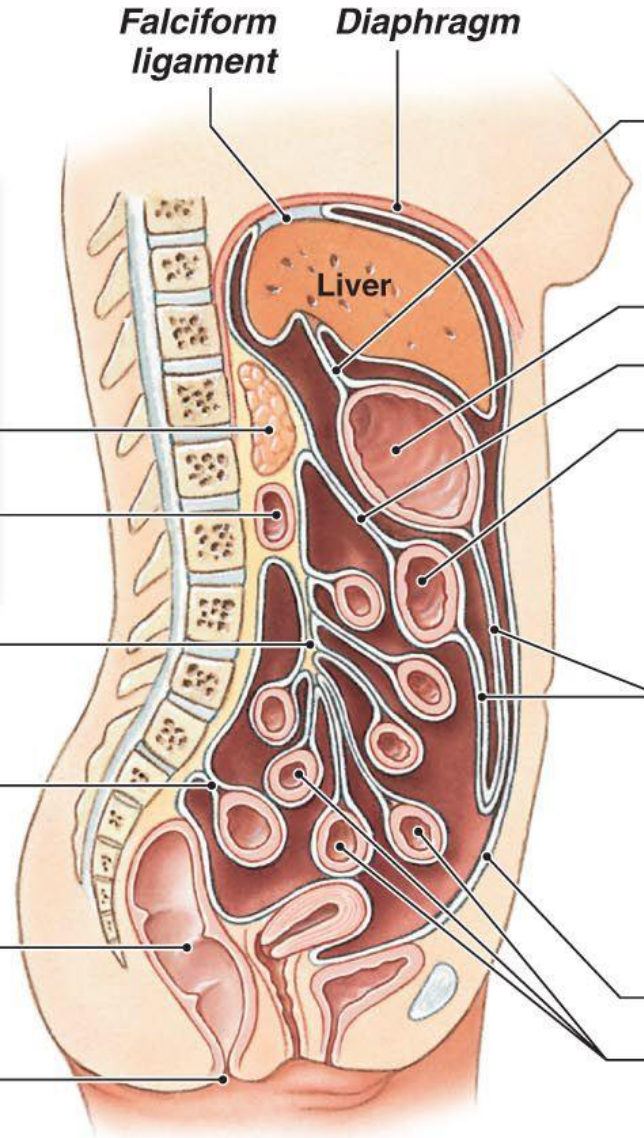


© 2011 Pearson Education, Inc.

# Mesentery & Mesenteric Vessels of the Small Intestine

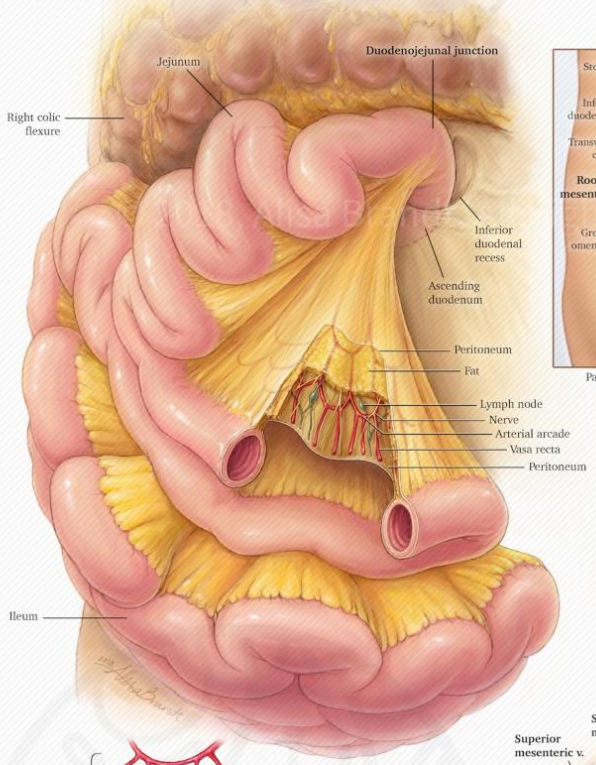


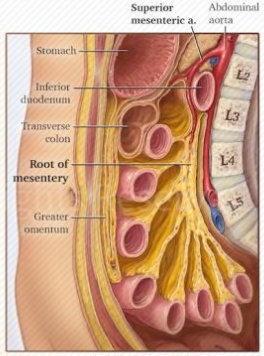


Parasagittal oblique view of abdomen

**The mesentery** connects the jejunum and ileum of the small intestine to the posterior abdominal wall. This border of attachment is called the **root of the mesentery** and runs obliquely from the **duodeno-jejunal junction** down to the **ileocecal junction.** Though the root is only about six inches long, the mesentery suspends about 22 feet of small intestine. In between the two peritoneal layers of the mesentery is fat containing lymph nodes and vessels, nerves, and numerous branches of the **superior mesenteric artery** and **vein.**

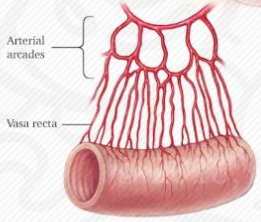


Jejunum

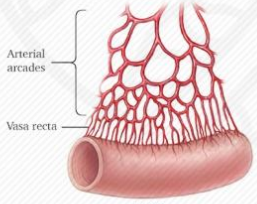


Ileum

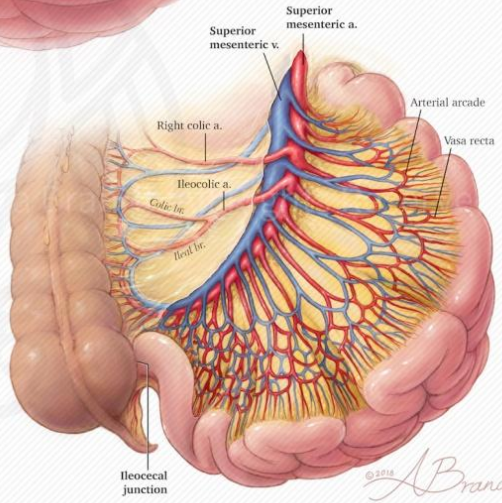


© 2018, Alisa Brandt. All Rights Reserved.

# Overview of Abdominal Cavity

Peritoneal ligaments

**Mesentery proper**—mesentery of the small intestine
- -contains varying amounts of fat
- -anchored from upper left to lower right

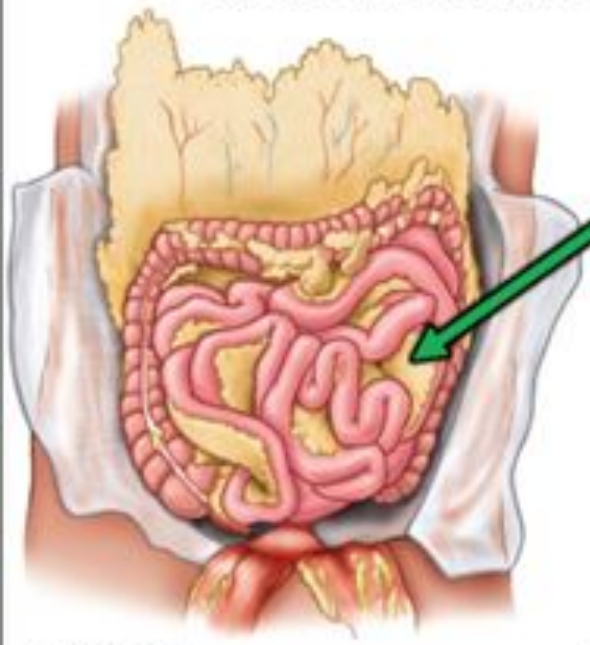

~MDA 220

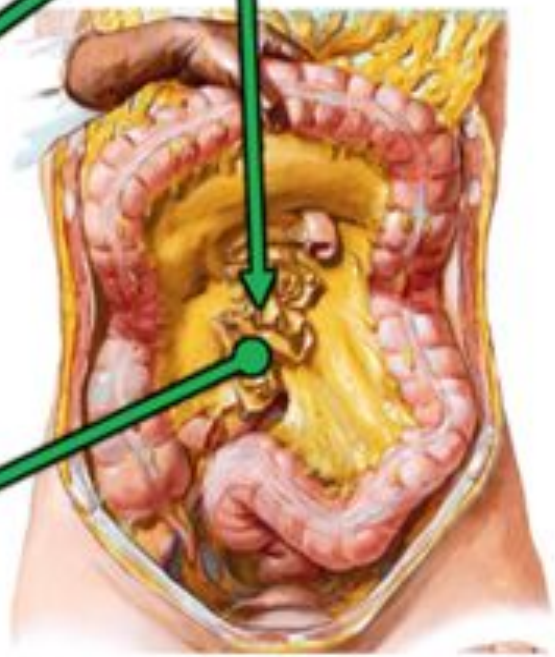

N 265

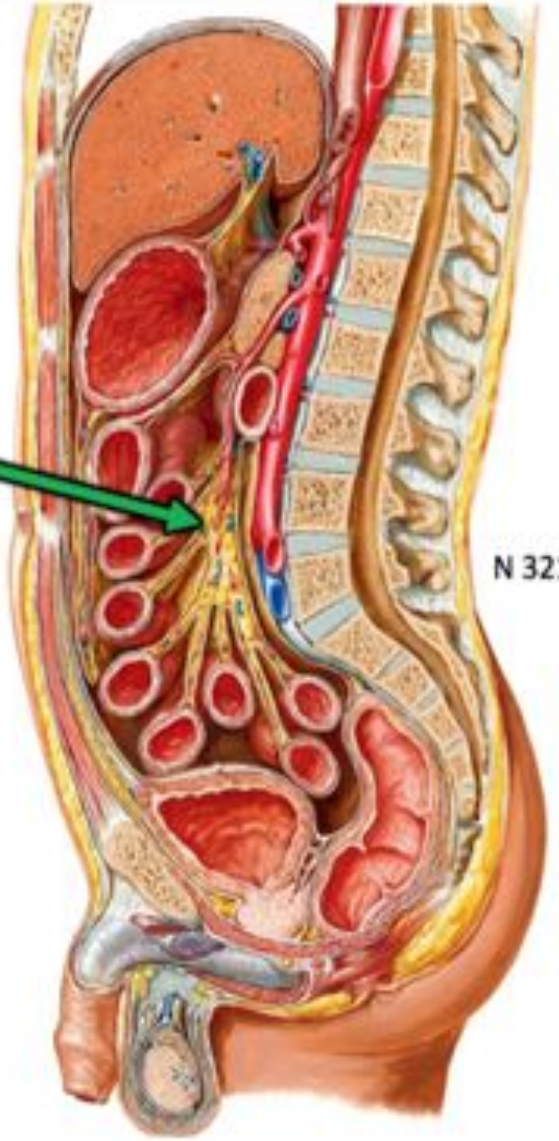

N 321

**"Root of mesentery"**
-origin from posterior abdominal wall

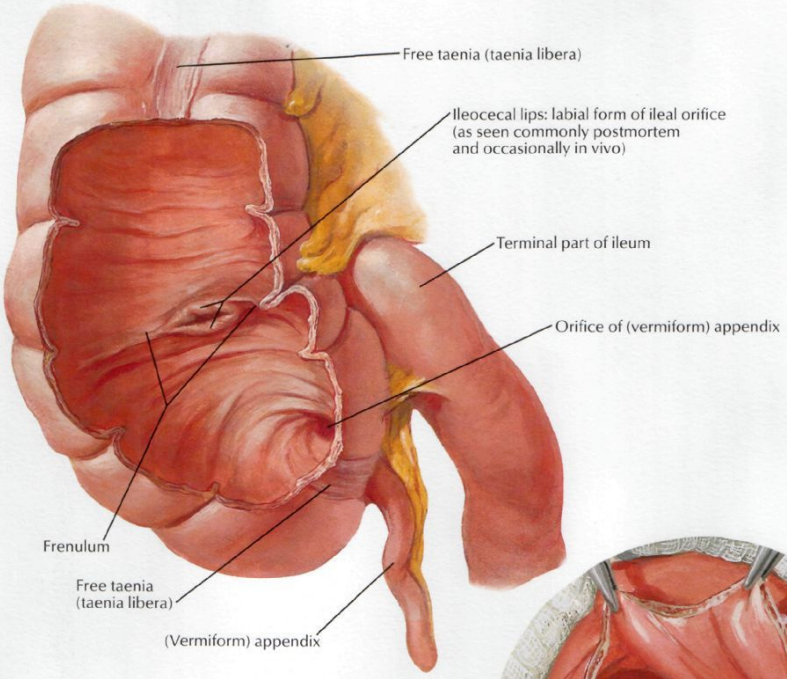


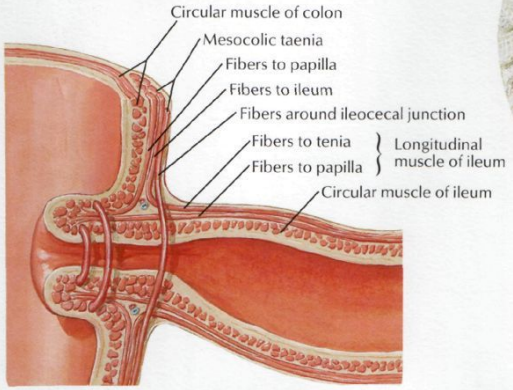


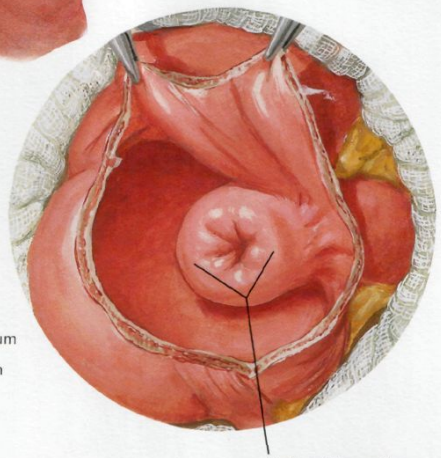


**Schema of muscle fibers at ileal orifice**

# Mesenteric Relations of Intestines (continued)

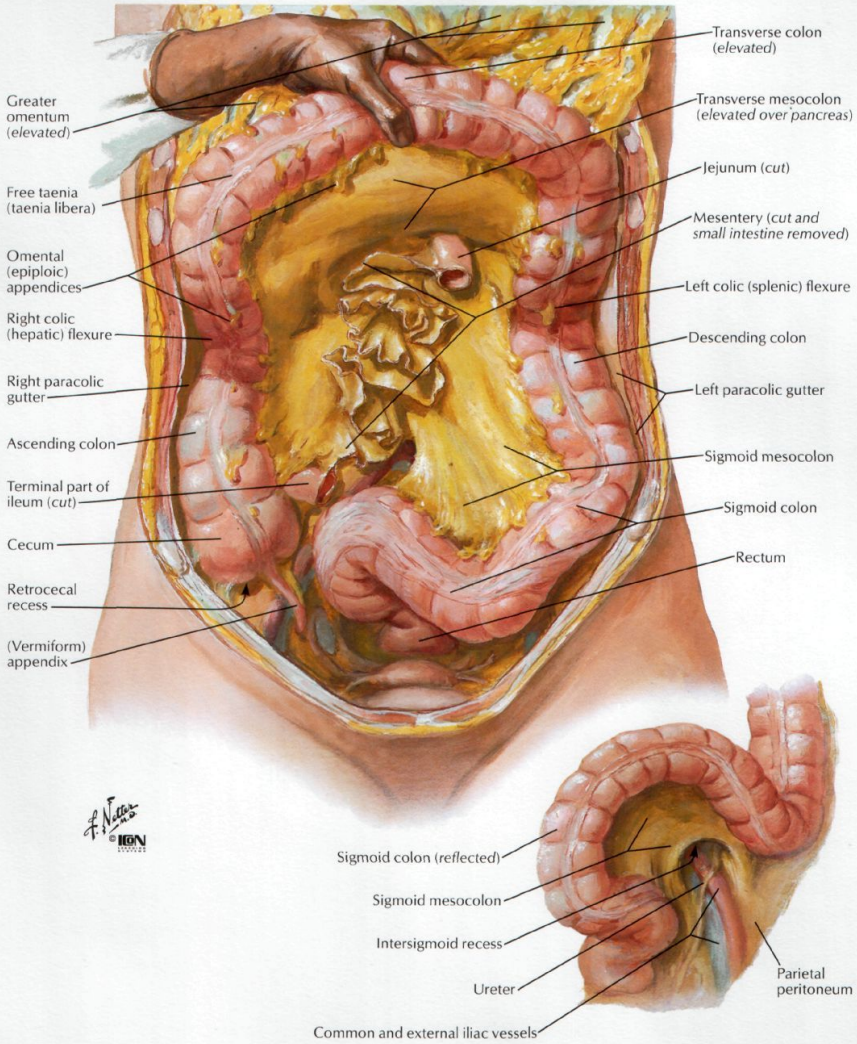

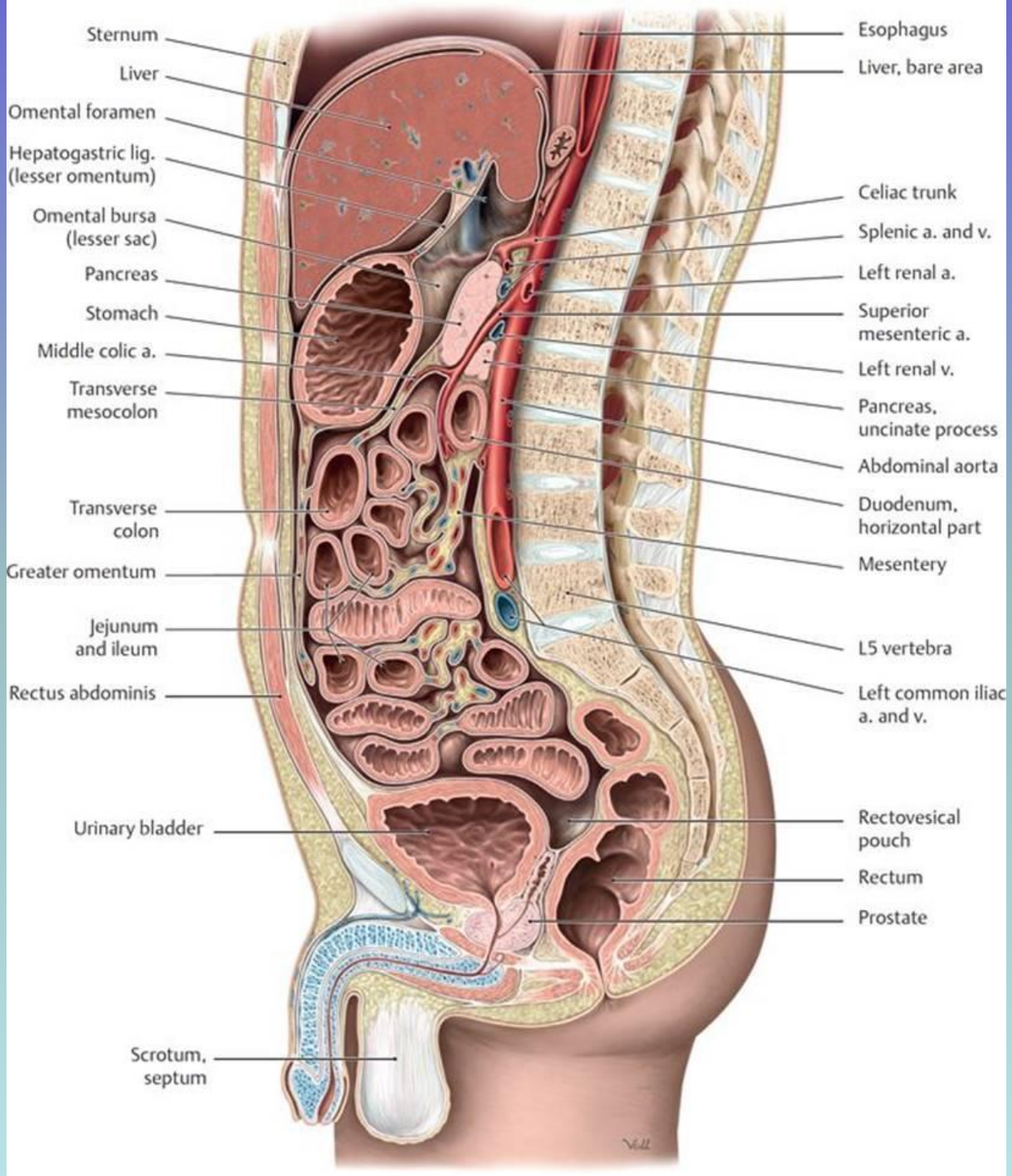
Sternum
Liver
Omental foramen
Hepatogastric lig. (lesser omentum)
Omental bursa (lesser sac)
Pancreas
Stomach
Middle colic a.
Transverse mesocolon
Transverse colon
Greater omentum
Jejunum and ileum
Rectus abdominis
Urinary bladder
Scrotum, septum
Esophagus
Liver, bare area
Celiac trunk
Splenic a. and v.
Left renal a.
Superior mesenteric a.
Left renal v.
Pancreas, uncinate process
Abdominal aorta
Duodenum, horizontal part
Mesentery
L5 vertebra
Left common iliac a. and v.
Rectovesical pouch
Rectum
Prostate

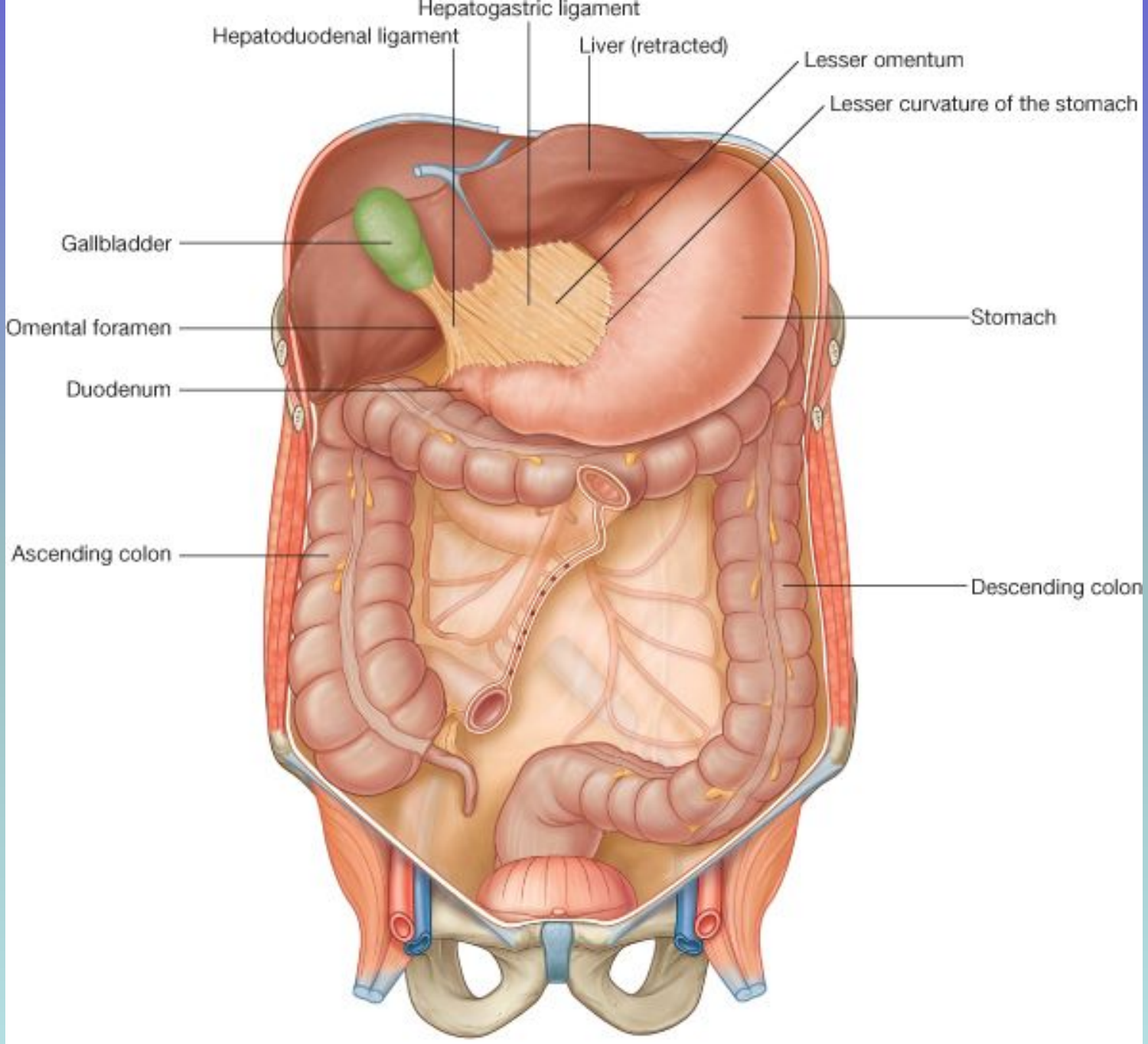


© Elsevier Ltd. Drake et al: Gray's Anatomy for Students www.studentconsult.com

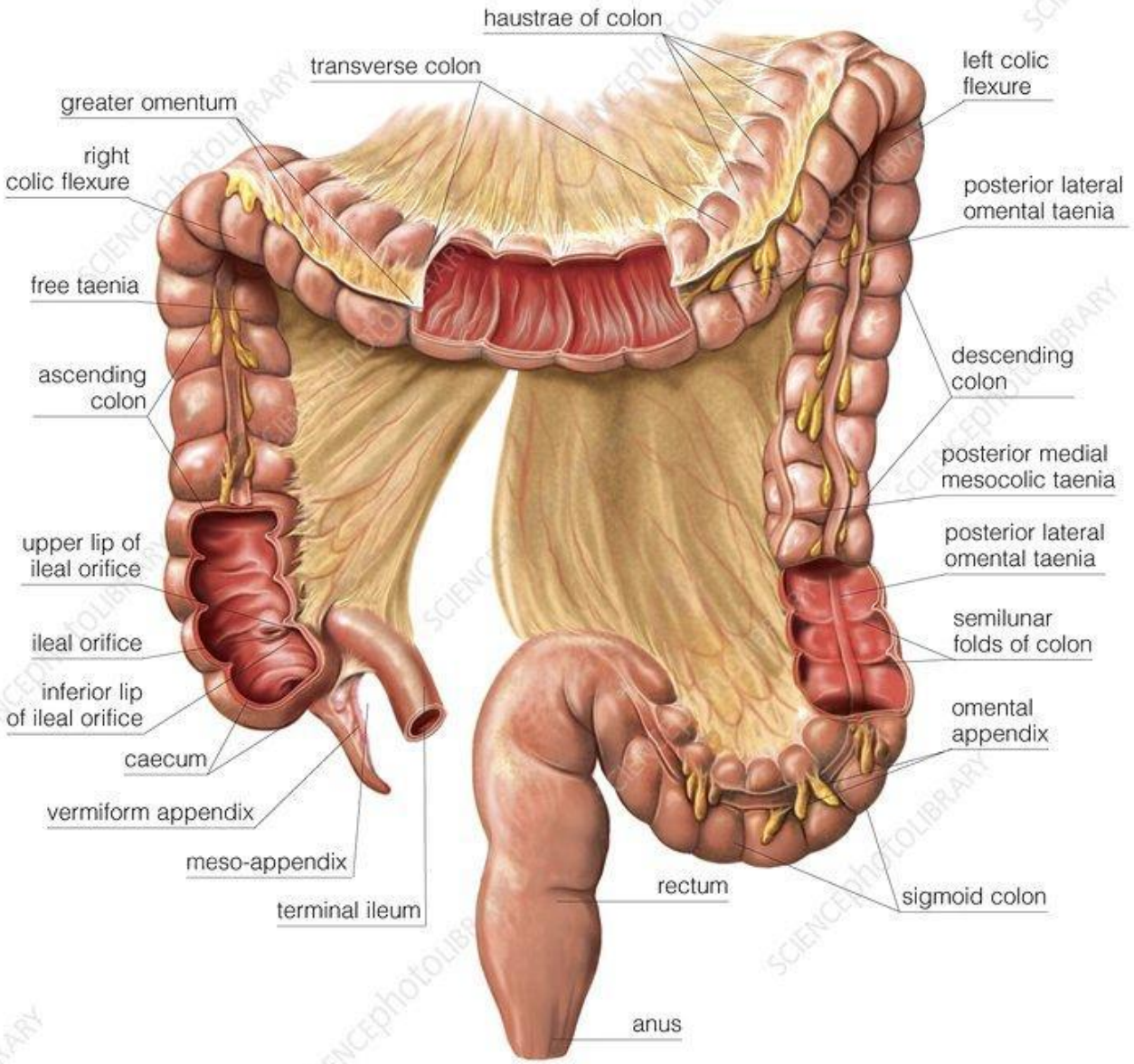
haustrae of colon
transverse colon
greater omentum
right
colic flexure
free taenia
ascending
colon
upper lip of
ileal orifice
ileal orifice
inferior lip
of ileal orifice
caecum
vermiform appendix
meso-appendix
terminal ileum
left colic
flexure
posterior lateral
omental taenia
descending
colon
posterior medial
mesocolic taenia
posterior lateral
omental taenia
semilunar
folds of colon
omental
appendix
rectum
sigmoid colon
anus

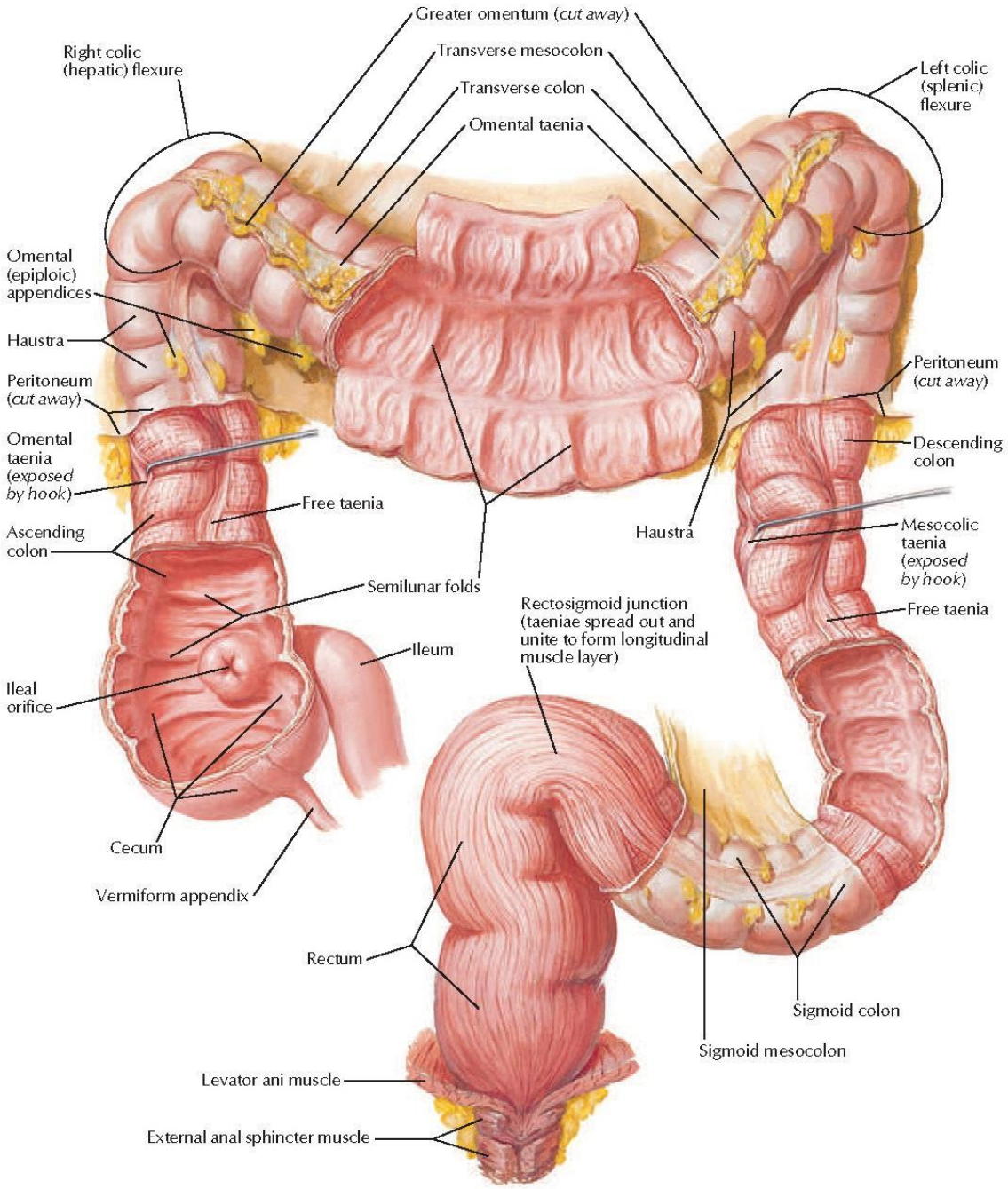
Greater omentum (cut away)
Right colic (hepatic) flexure
Transverse mesocolon
Transverse colon
Omental taenia
Left colic (splenic) flexure
Omental (epiploic) appendices
Haustra
Peritoneum (cut away)
Omental taenia (exposed by hook)
Ascending colon
Free taenia
Semilunar folds
Ileum
Ileal orifice
Cecum
Vermiform appendix
Rectum
Levator ani muscle
External anal sphincter muscle
Rectosigmoid junction (taeniae spread out and unite to form longitudinal muscle layer)
Haustra
Peritoneum (cut away)
Descending colon
Mesocolic taenia (exposed by hook)
Free taenia
Sigmoid colon
Sigmoid mesocolon

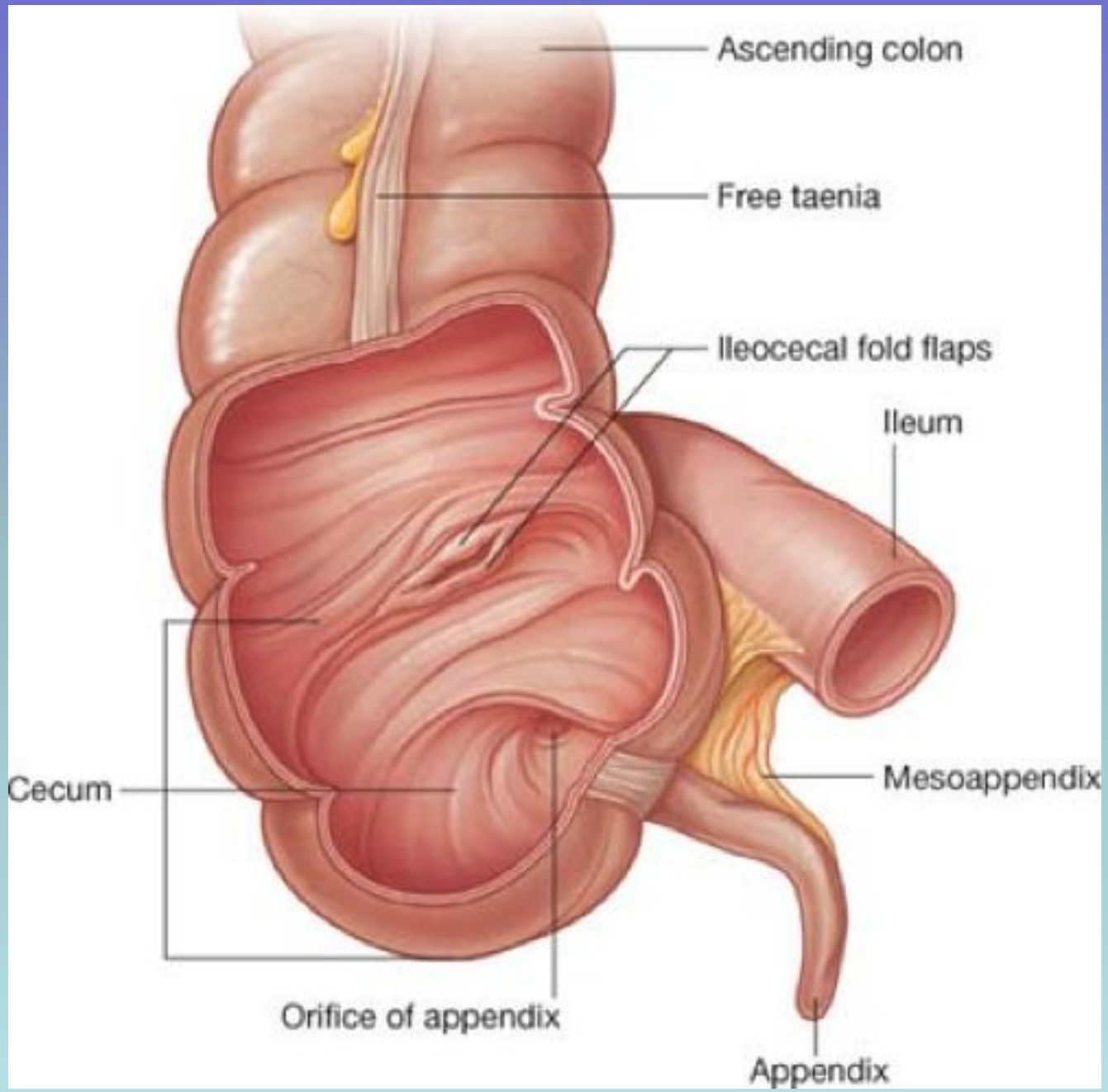
Ascending colon
Free taenia
Ileocecal fold flaps
Ileum
Cecum
Mesoappendix
Orifice of appendix
Appendix

# Rectum of Male in Situ

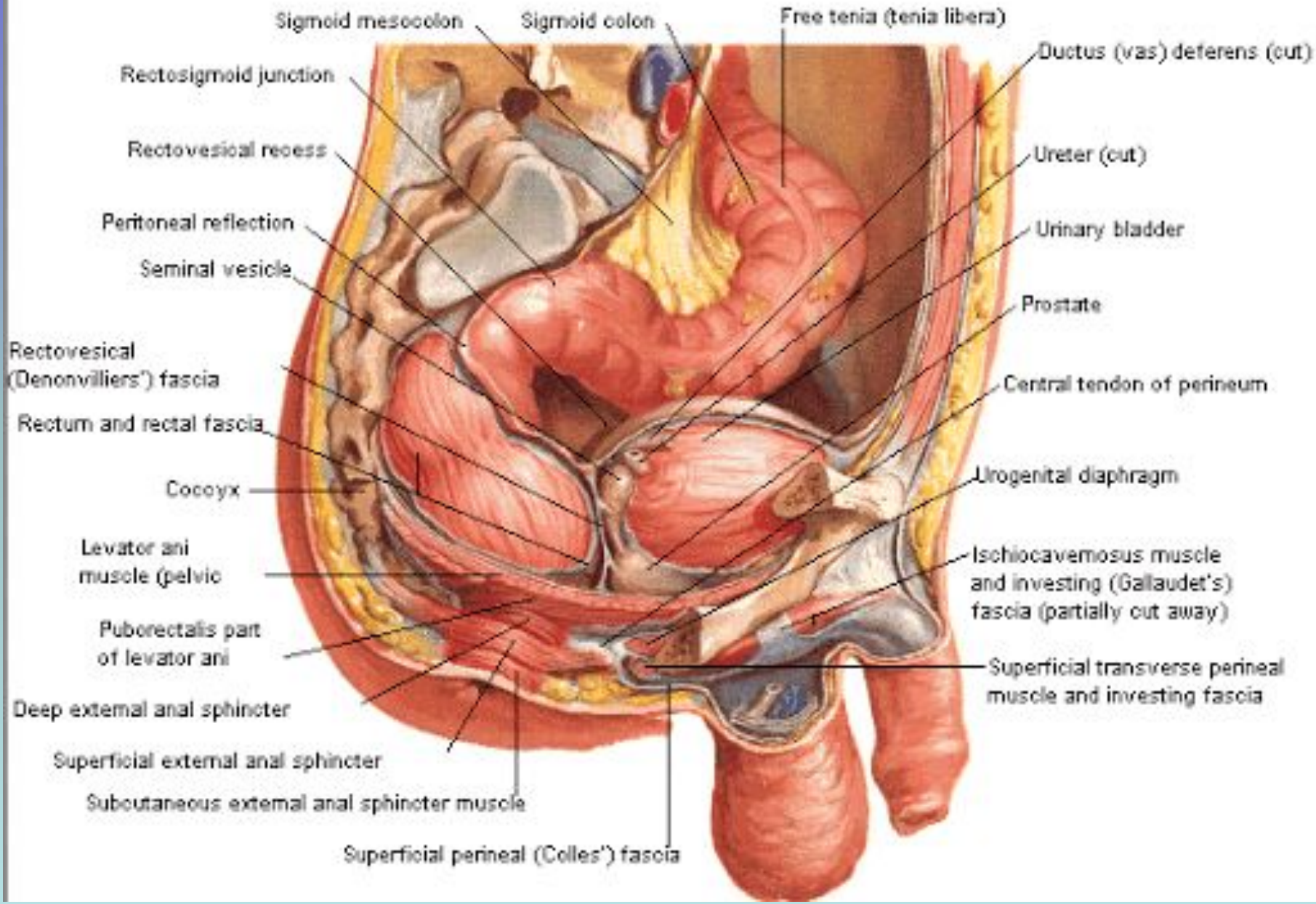

# MALE UROGENITAL SYSTEM (MIDSAGITTAL VIEW)

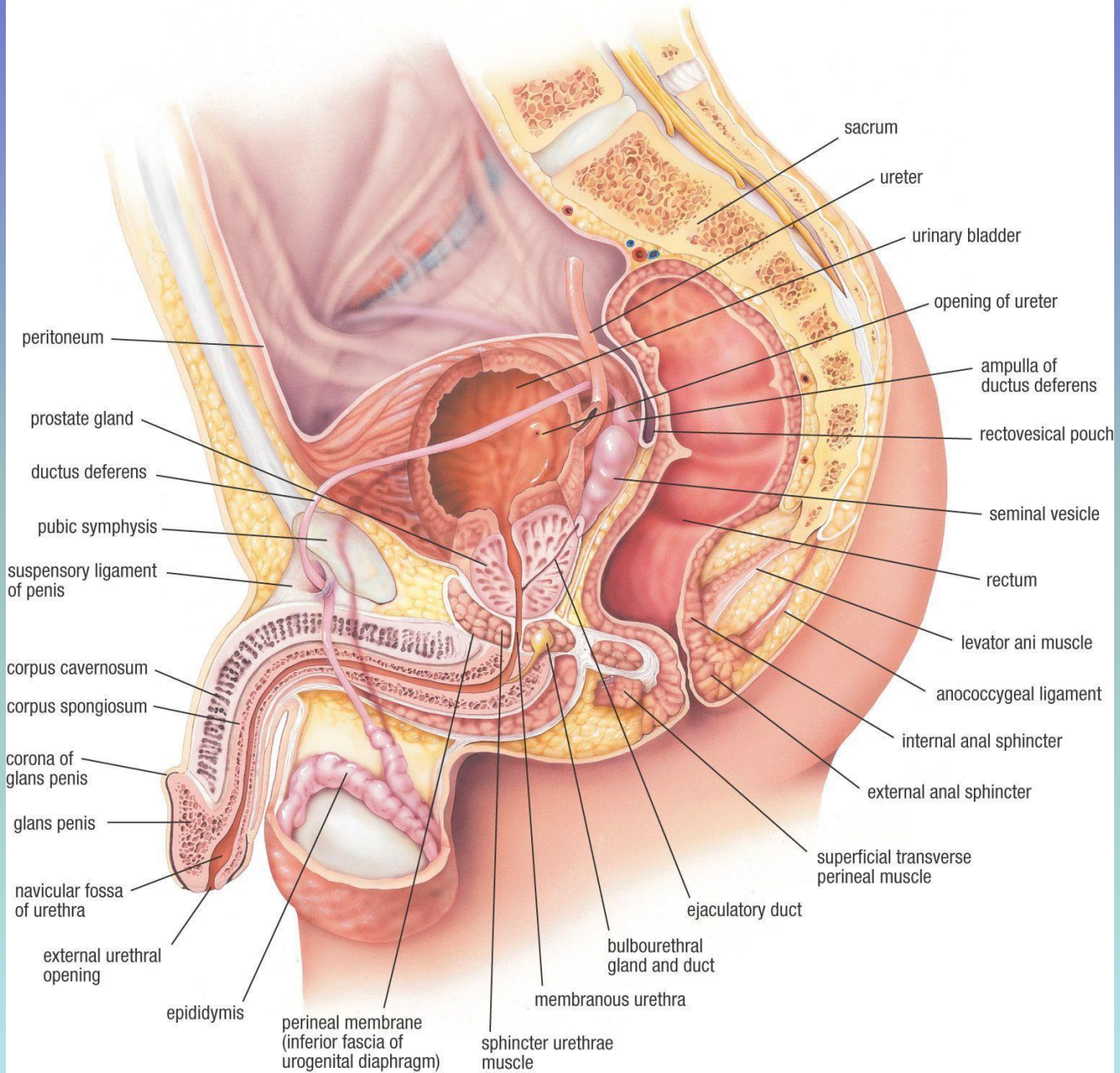

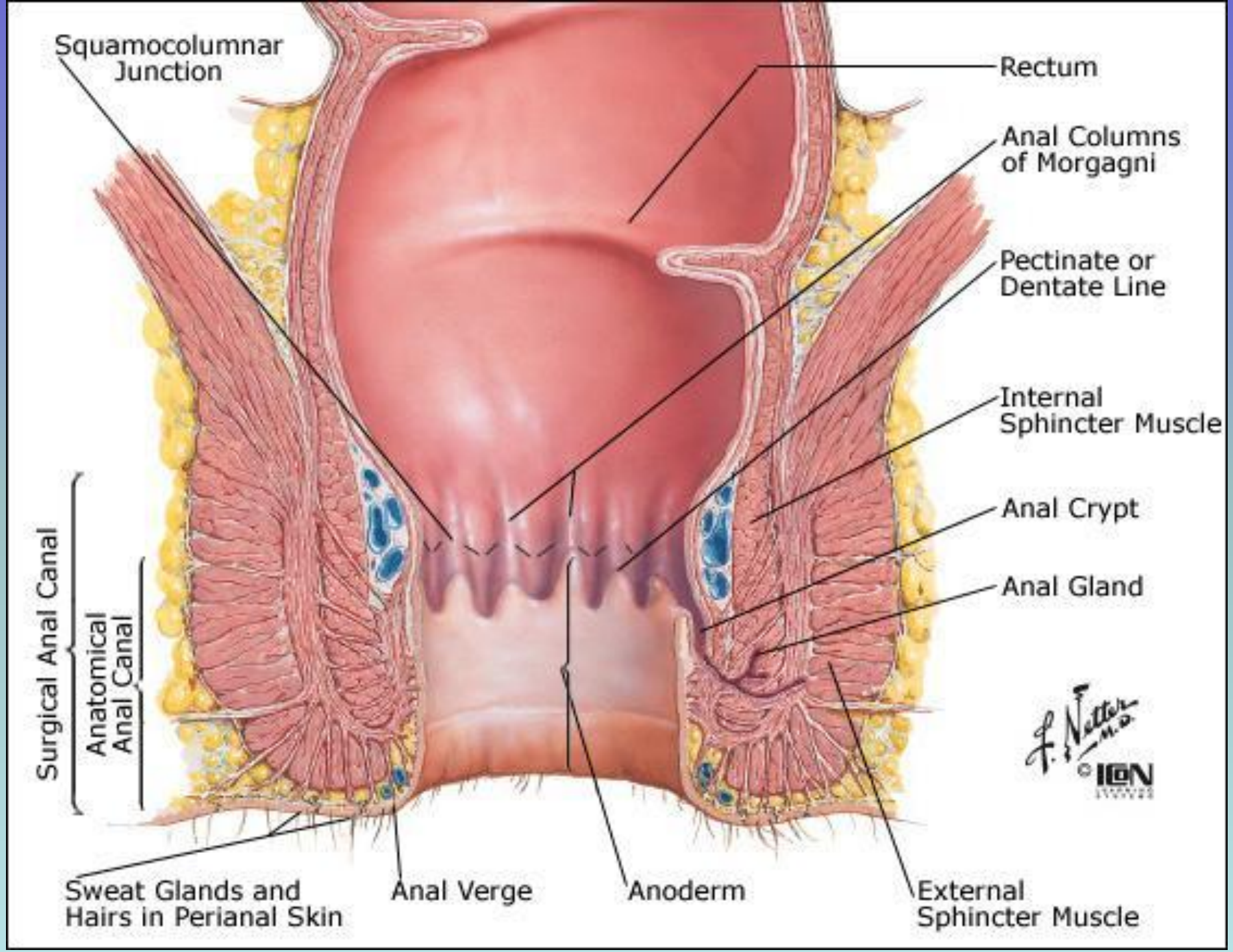
Squamocolumnar Junction
Rectum
Anal Columns of Morgagni
Pectinate or Dentate Line
Internal Sphincter Muscle
Anal Crypt
Anal Gland
Surgical Anal Canal
Anatomical Anal Canal
Sweat Glands and Hairs in Perianal Skin
Anal Verge
Anoderm
External Sphincter Muscle
F. Netter M.D.
© ICON

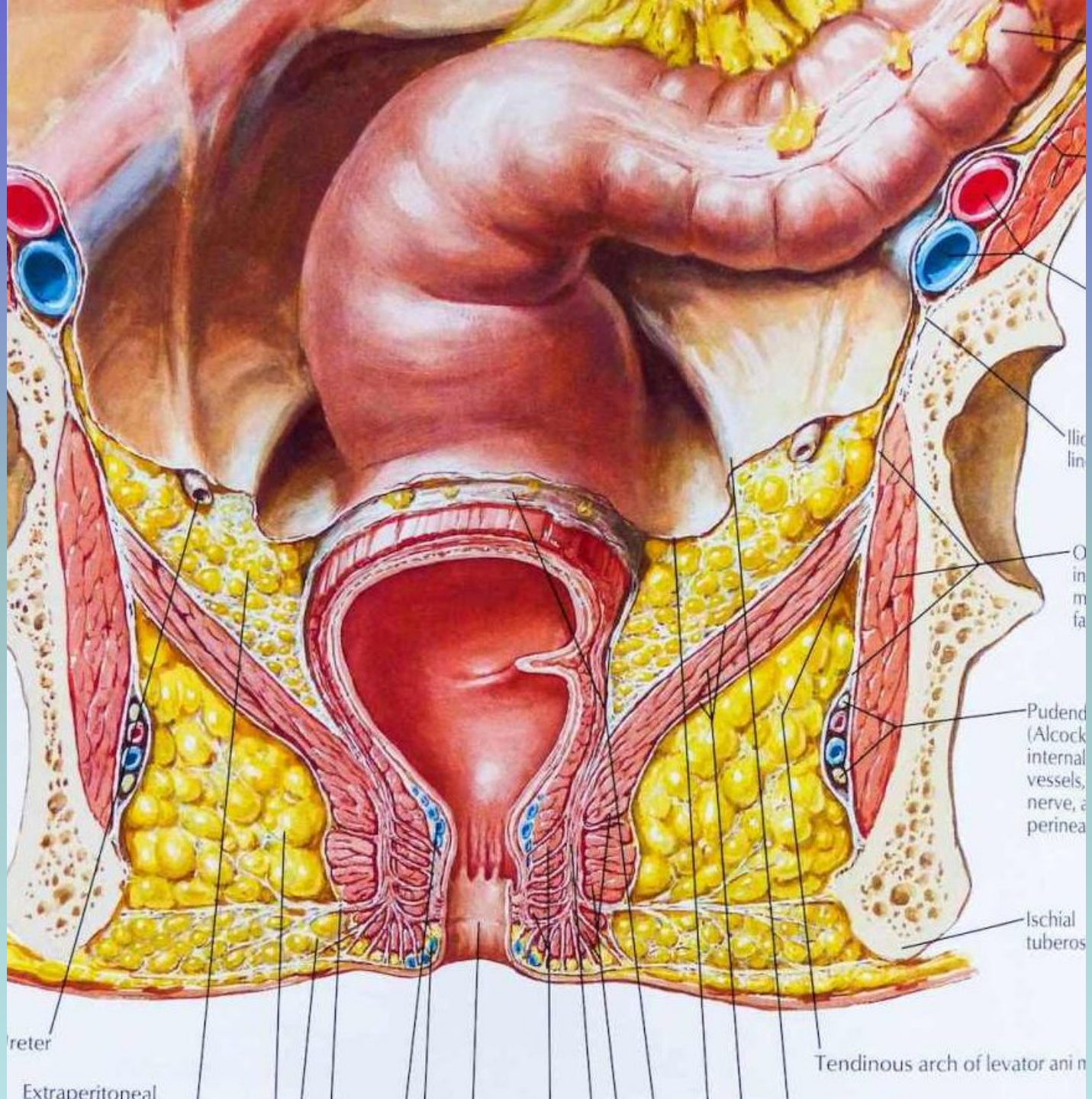
Ilio
lin
O
in
m
fa
Pudend
(Alcock
internal
vessels,
nerve, a
perinea
Ischial
tuberos
reter
Tendinous arch of levator ani m
Extraperitoneal