Ромбовидный мозг Продолговатый мозг, Мост,

Рисунки Зимина М.А.

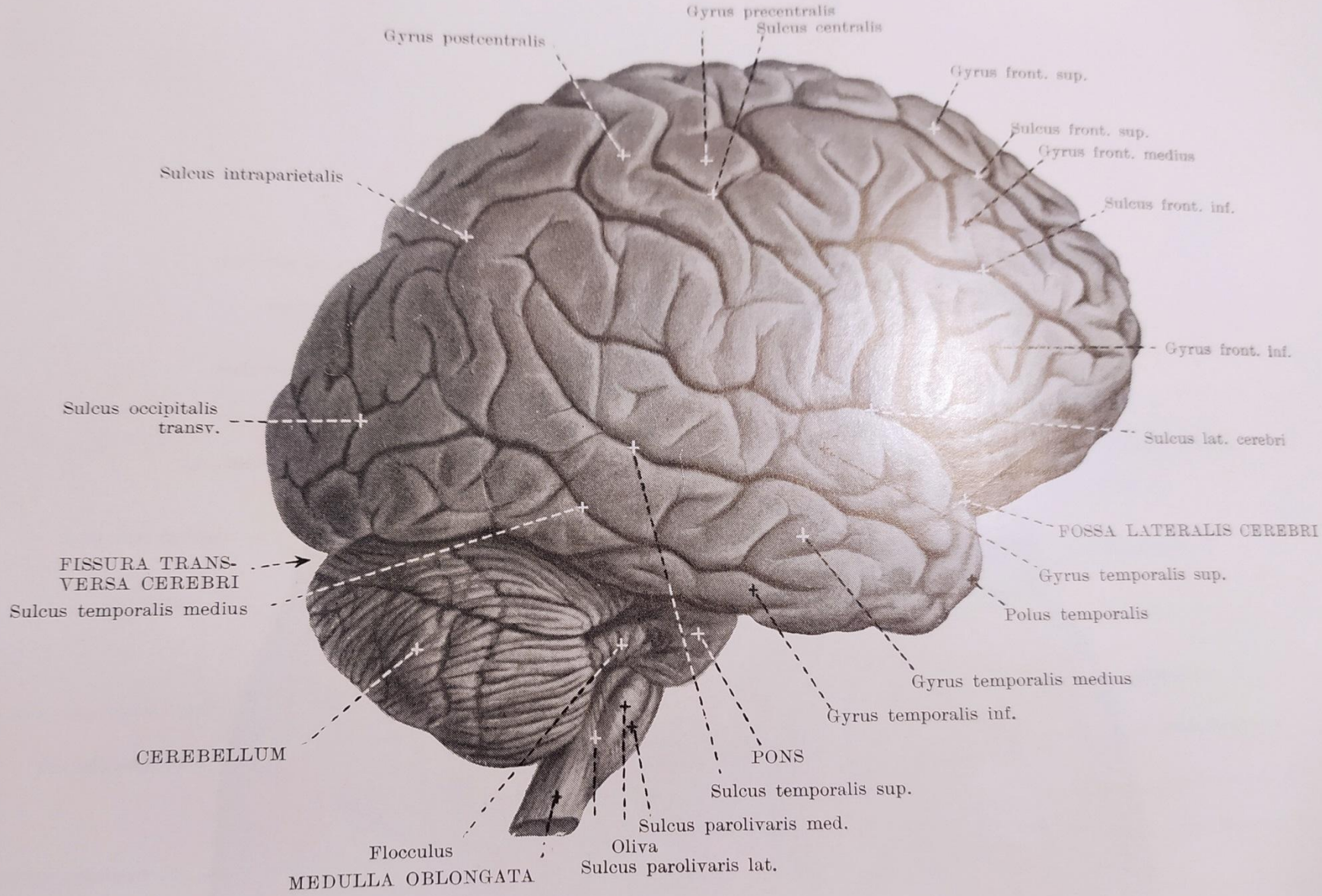

Fig. 2. ENCEPHALON I.
(aspectus lateralis dext.)

Tr. corporis callosi
Fornix
Lobulus paracentralis
Gyrus cinguli
Sulcus subparietalis
Precuneus
Gyrus front. sup.
Adhesio interthalamica
Splenium corporis callosi
Sulcus cinguli
Sulcus parietooccipitalis
Septum pellucidum
Polus frontalis
Cuneus
Genu corporis callosi
Corpus pineale
Colliculus sup.
Rostrum corporis callosi
Sulcus calcarinus
Aqueductus cerebri
Colliculus inf.
Commissura ant.
Polus occipitalis
Area subcallosa
Lamina terminalis
Recessus opticus
MESENCEPHALON
Tuber cinereum (hypothalamus)
CEREBELLUM
Hypophysis
Fastigium
Lobus temporalis
PONS
Corpus mamillare
Thalamus
Velum medullare sup.
MEDULLA OBLONGATA

Fig. 4. ENCEPHALON II.
(sectio sagittalis, aspectus medialis, l. dext.)

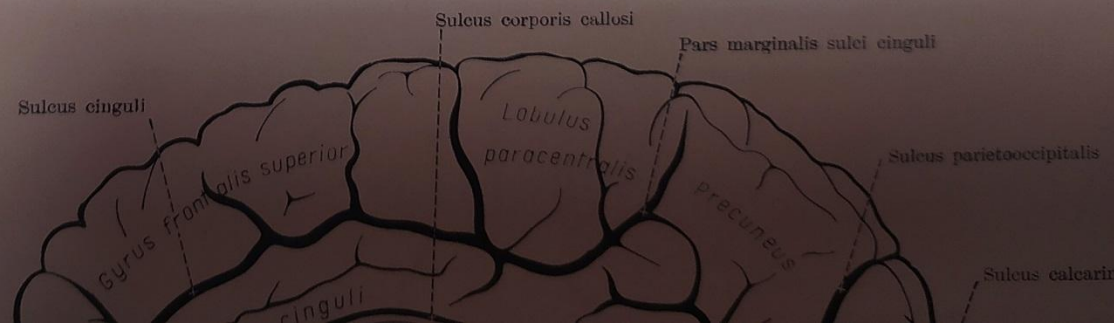

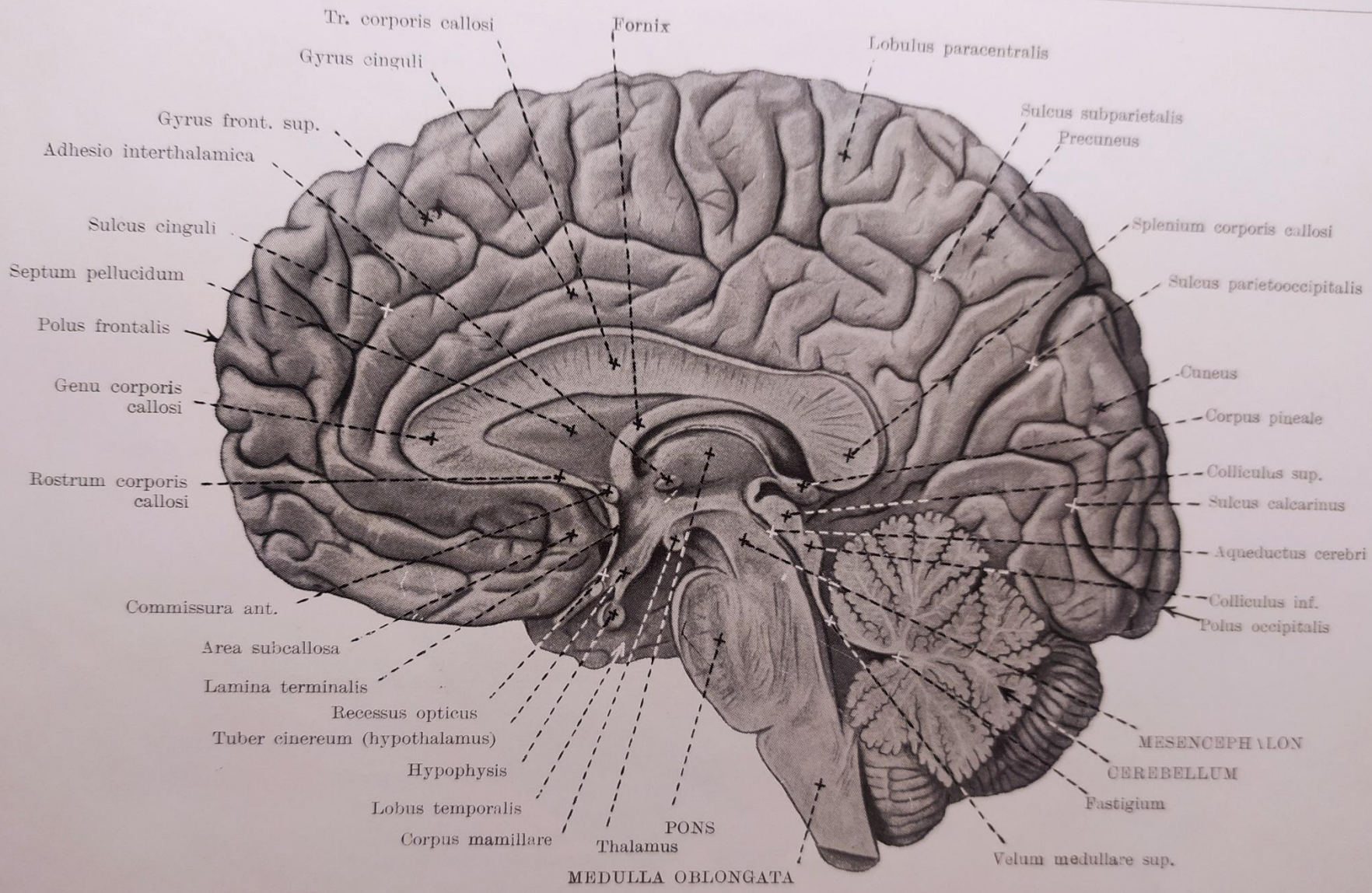

Fig. 4. ENCEPHALON II.

(sectio sagittalis, aspectus medialis, l. dext.)

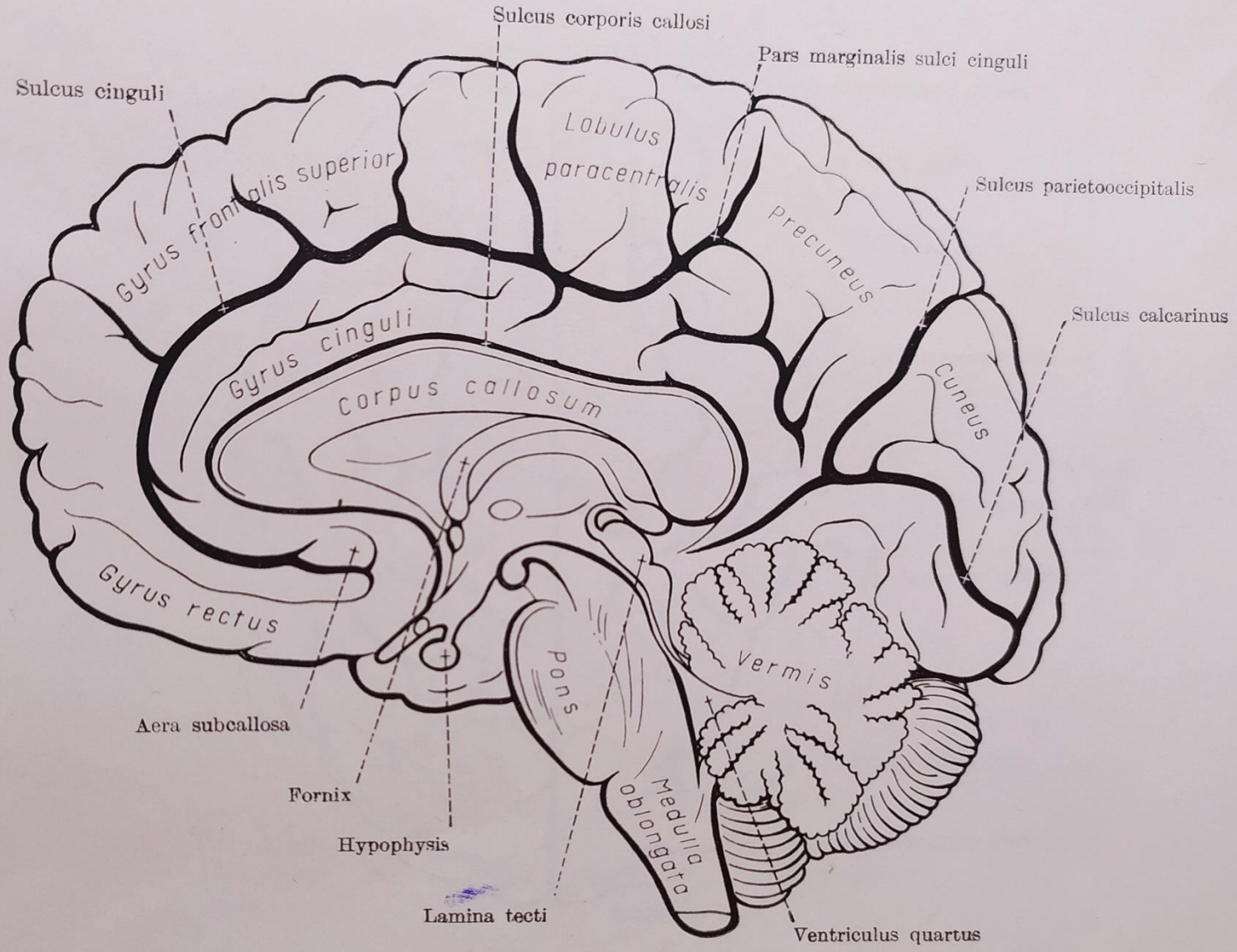

Fig. 5. SULCI ET GYRI CEREBRI II.
(facies medialis hemispherii, sectio sagittalis encephali)

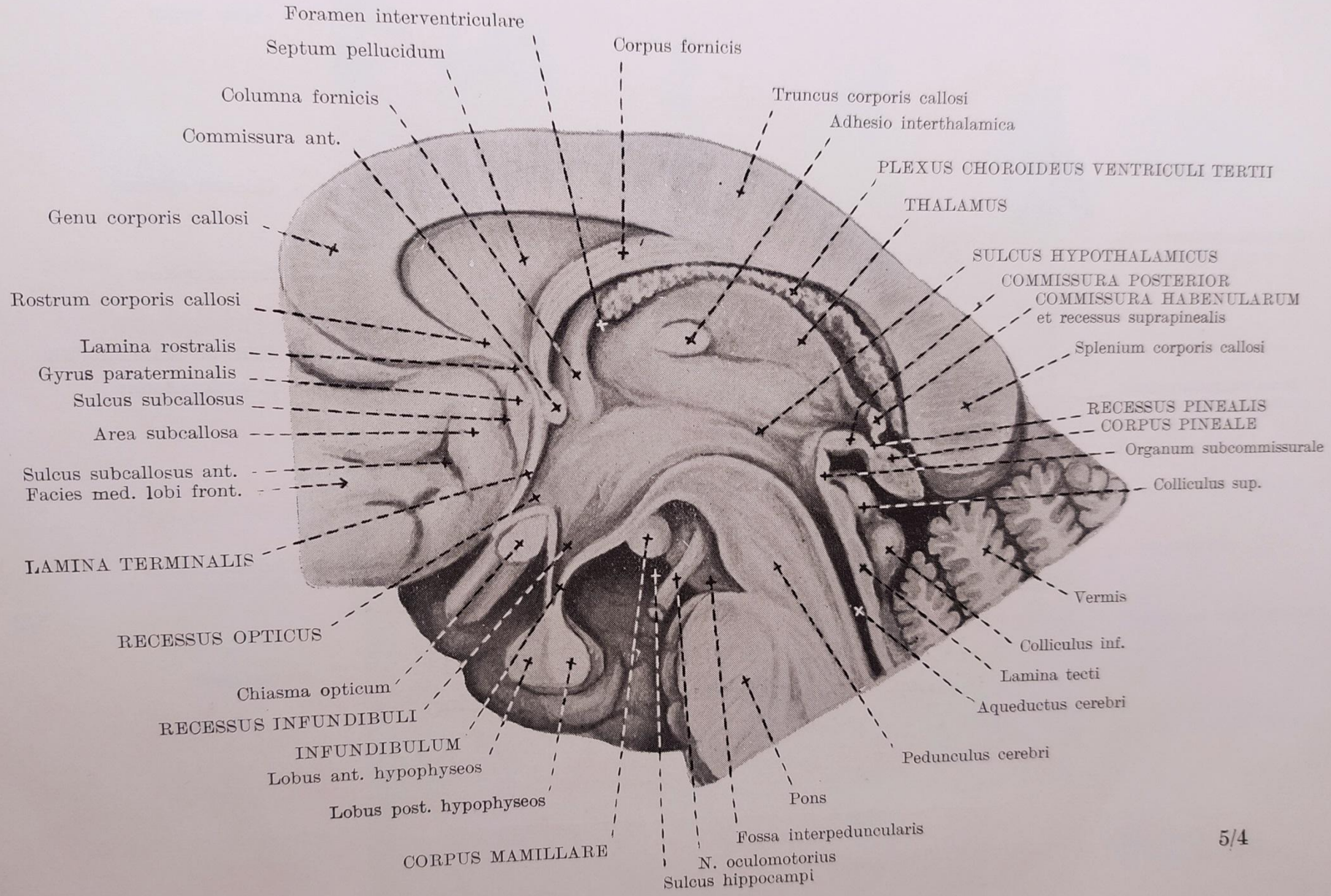
Foramen interventriculare
Septum pellucidum
Corpus fornicis
Columna fornicis
Truncus corporis callosi
Adhesio interthalamica
Commissura ant.
PLEXUS CHOROIDEUS VENTRICULI TERTII
THALAMUS
Genu corporis callosi
SULCUS HYPOTHALAMICUS
COMMISSURA POSTERIOR
COMMISSURA HABENULARUM
et recessus suprapinealis
Rostrum corporis callosi
Lamina rostralis
Splenium corporis callosi
Gyrus paraterminalis
Sulcus subcallosus
RECESSUS PINEALIS
CORPUS PINEALE
Area subcallosa
Organum subcommissurale
Sulcus subcallosus ant.
Facies med. lobi front.
Colliculus sup.
LAMINA TERMINALIS
Vermis
RECESSUS OPTICUS
Colliculus inf.
Lamina tecti
Chiasma opticum
Aqueductus cerebri
RECESSUS INFUNDIBULI
INFUNDIBULUM
Pedunculus cerebri
Lobus ant. hypophyseos
Lobus post. hypophyseos
Pons
Fossa interpeduncularis
CORPUS MAMILLARE
N. oculomotorius
Sulcus hippocampi

5/4

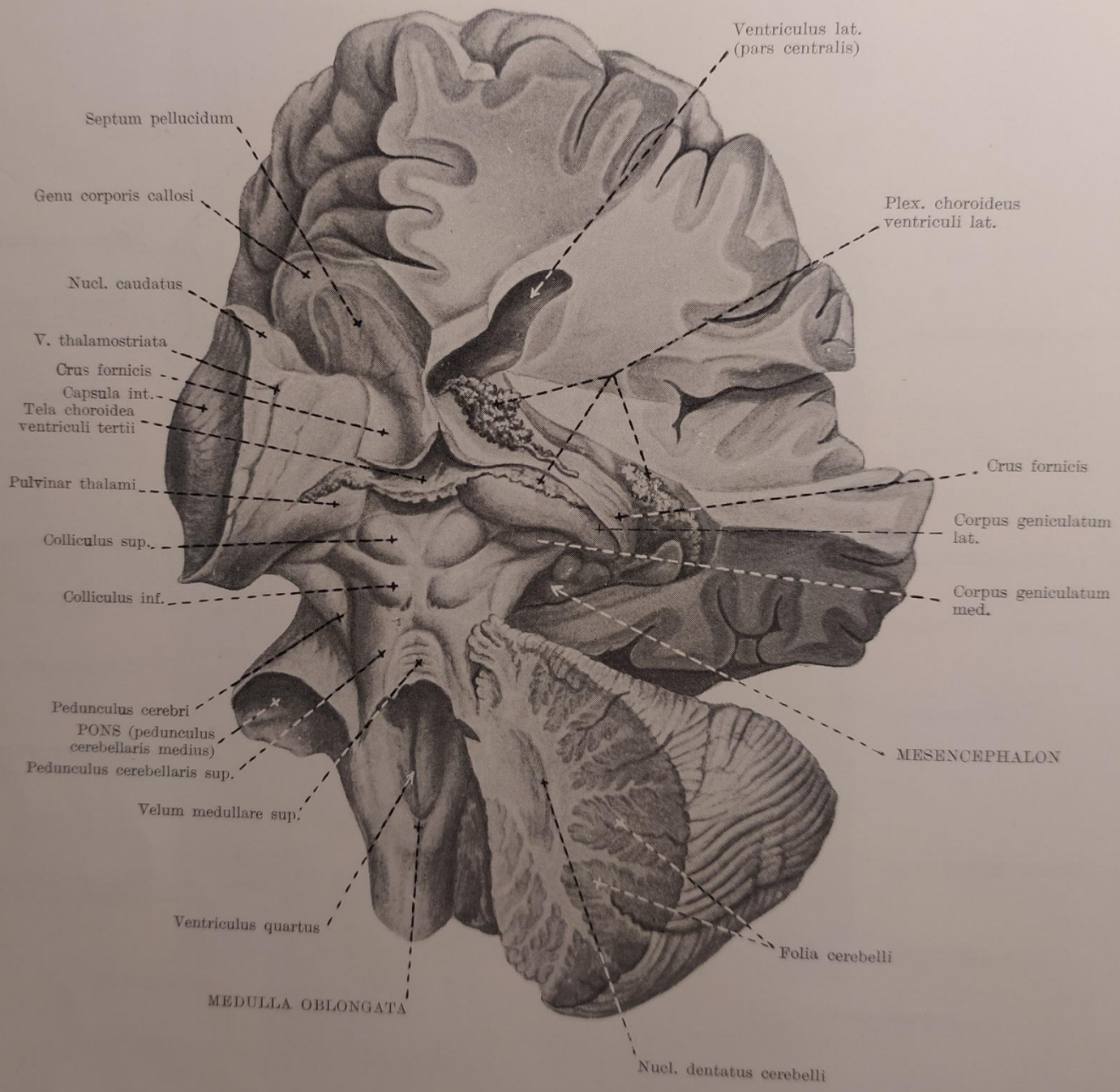
Ventriculus lat.
(pars centralis)
Septum pellucidum
Genu corporis callosi
Plex. choroideus
ventriculi lat.
Nucl. caudatus
V. thalamostriata
Crus fornicis
Capsula int.
Tela choroidea
ventriculi tertii
Crus fornicis
Pulvinar thalami
Corpus geniculatum
lat.
Colliculus sup.
Colliculus inf.
Corpus geniculatum
med.
Pedunculus cerebri
PONS (pedunculus
cerebellaris medius)
Pedunculus cerebellaris sup.
MESENCEPHALON
Velum medullare sup.
Ventriculus quartus
Folia cerebelli
MEDULLA OBLONGATA
Nucl. dentatus cerebelli

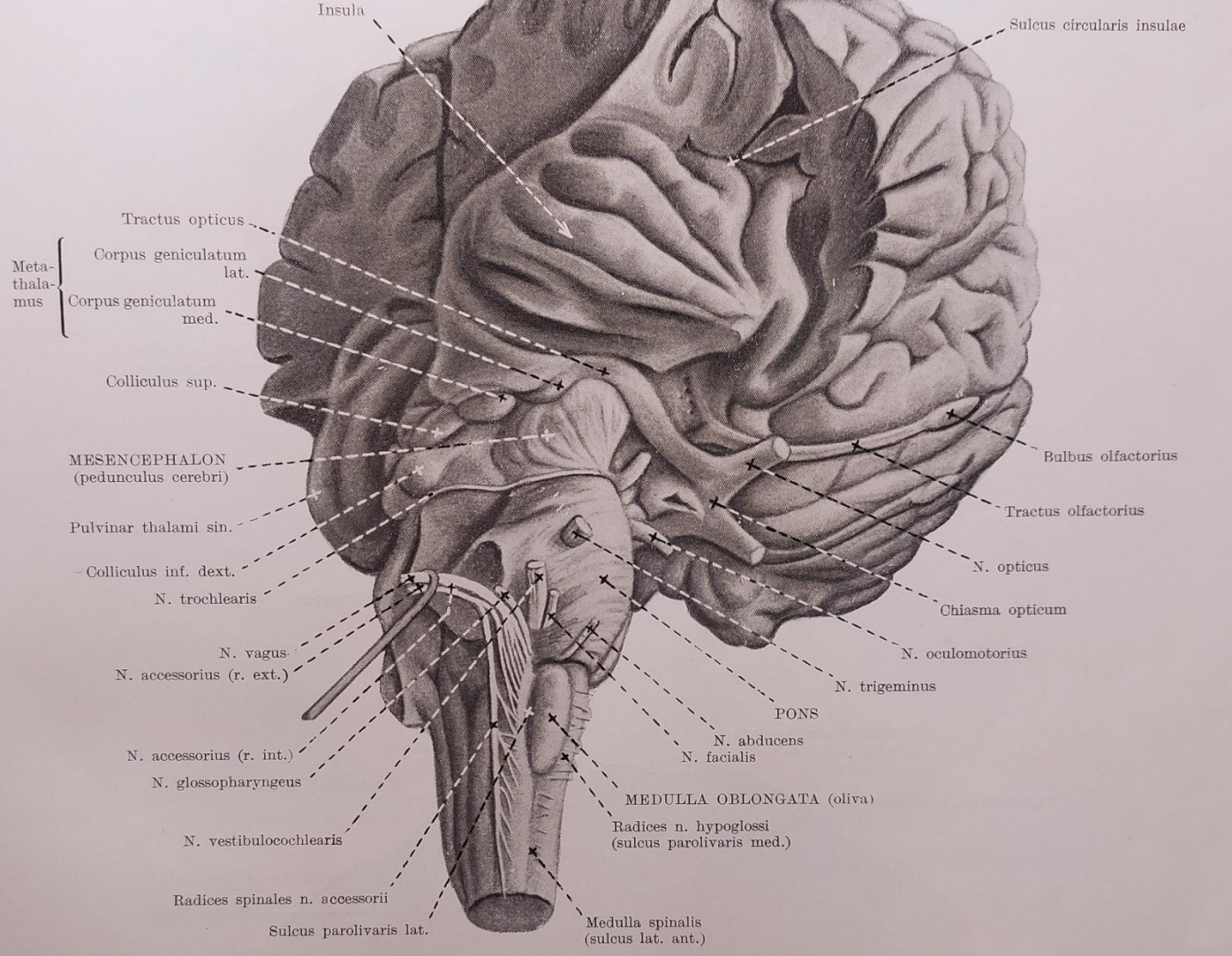
Insula
Sulcus circularis insulae
Tractus opticus
Meta-thalamus
Corpus geniculatum lat.
Corpus geniculatum med.
Colliculus sup.
MESENCEPHALON (pedunculus cerebri)
Pulvinar thalami sin.
Colliculus inf. dext.
N. trochlearis
N. vagus
N. accessorius (r. ext.)
N. accessorius (r. int.)
N. glossopharyngeus
N. vestibulocochlearis
Radices spinales n. accessorii
Sulcus parolivaris lat.
Bulbus olfactorius
Tractus olfactorius
N. opticus
Chiasma opticum
N. oculomotorius
N. trigeminus
PONS
N. abducens
N. facialis
MEDULLA OBLONGATA (oliva)
Radices n. hypoglossi (sulcus parolivaris med.)
Medulla spinalis (sulcus lat. ant.)

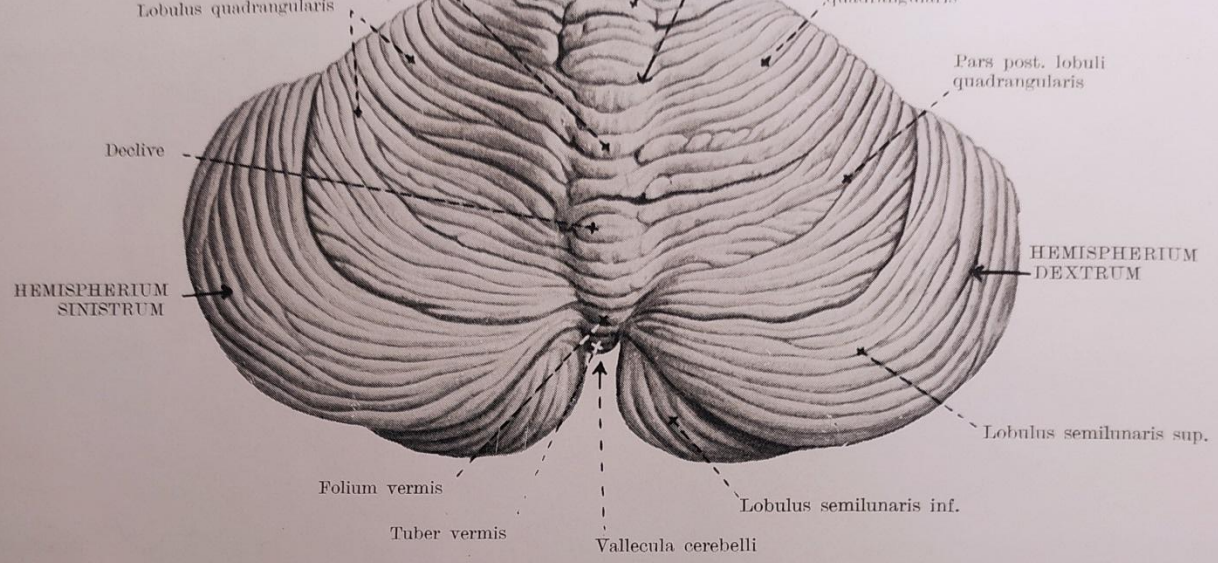

Fig. 27. CEREBELLUM I.
(vermis et facies superiores hemispheriorum, aspectus superior)

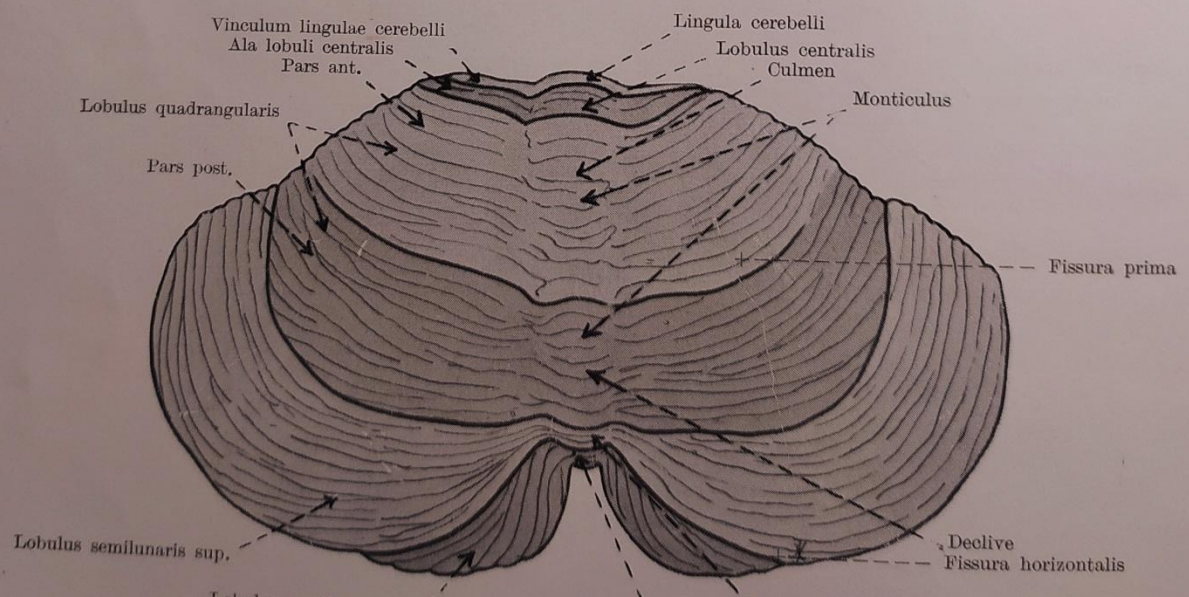

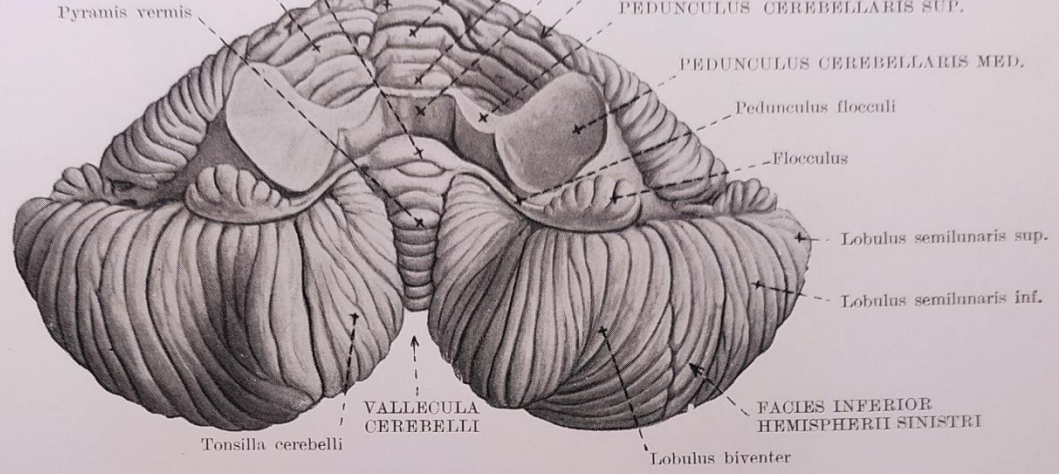

Fig. 29. CEREBELLUM III.
(vermis et hemispherii, aspectus anterior)

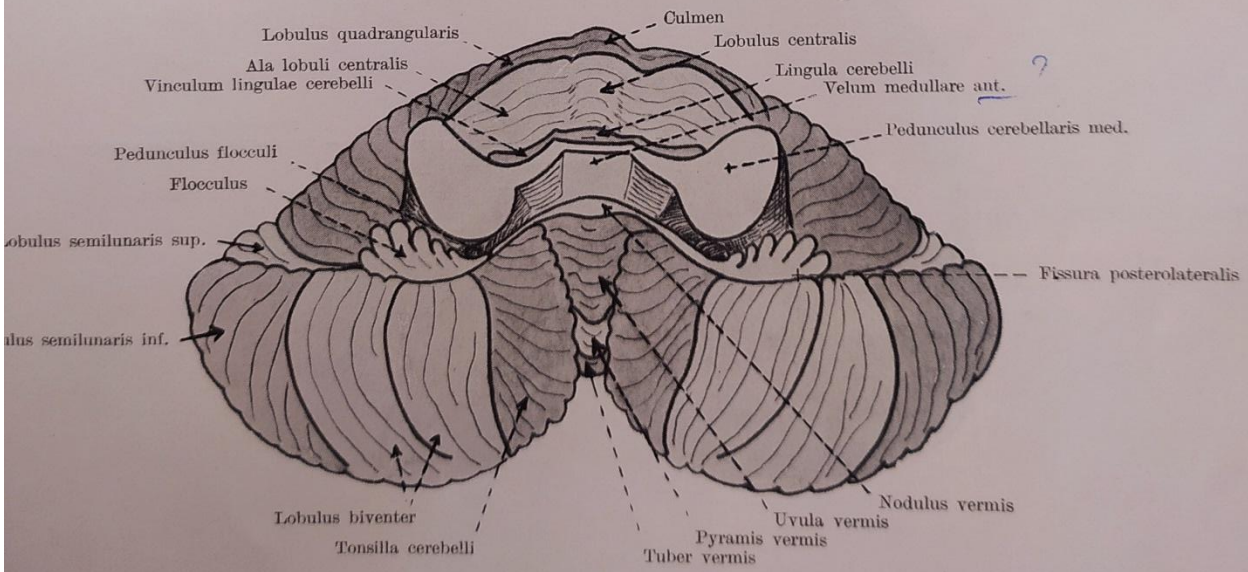

(aspectus dexter)

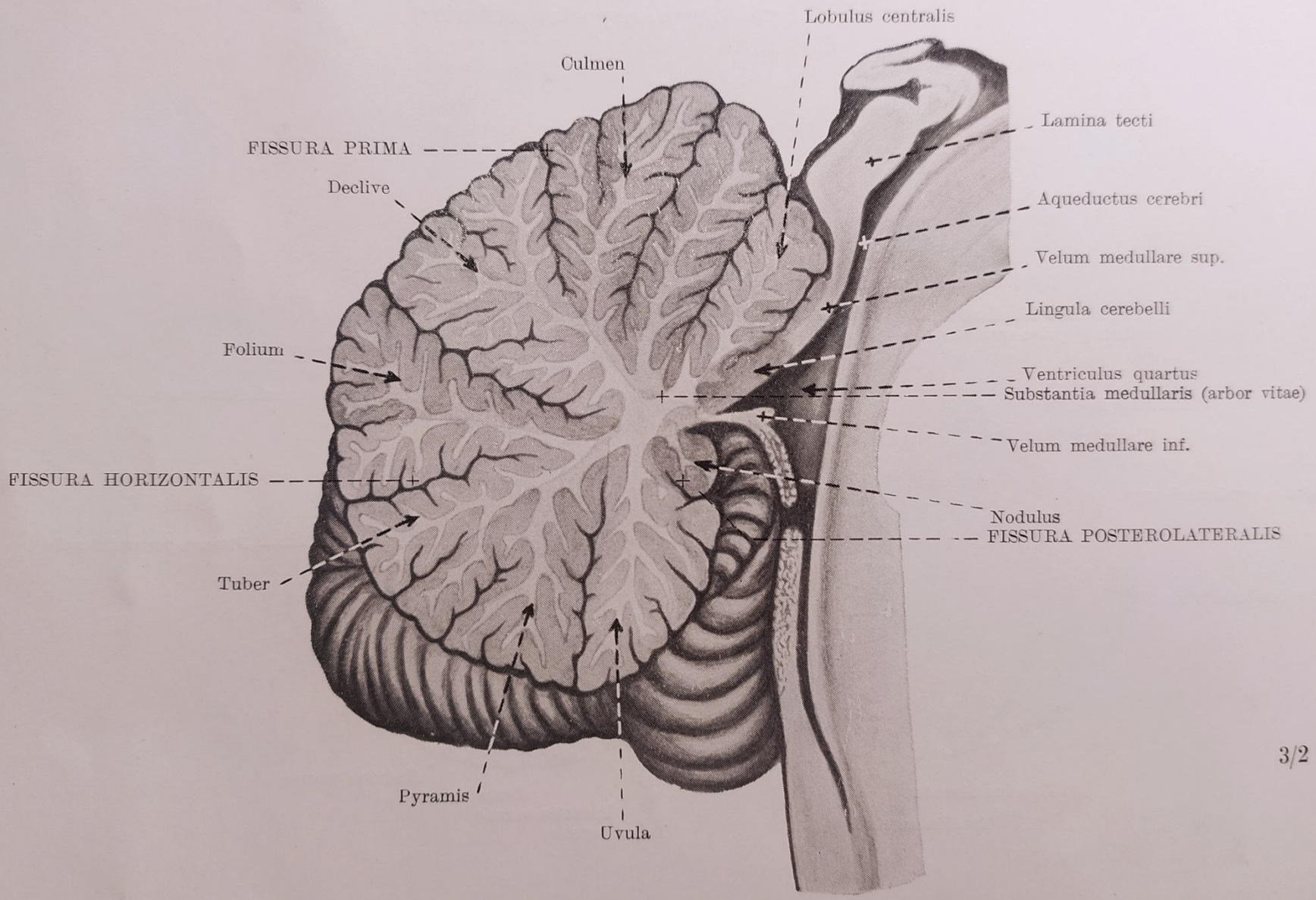

3/2

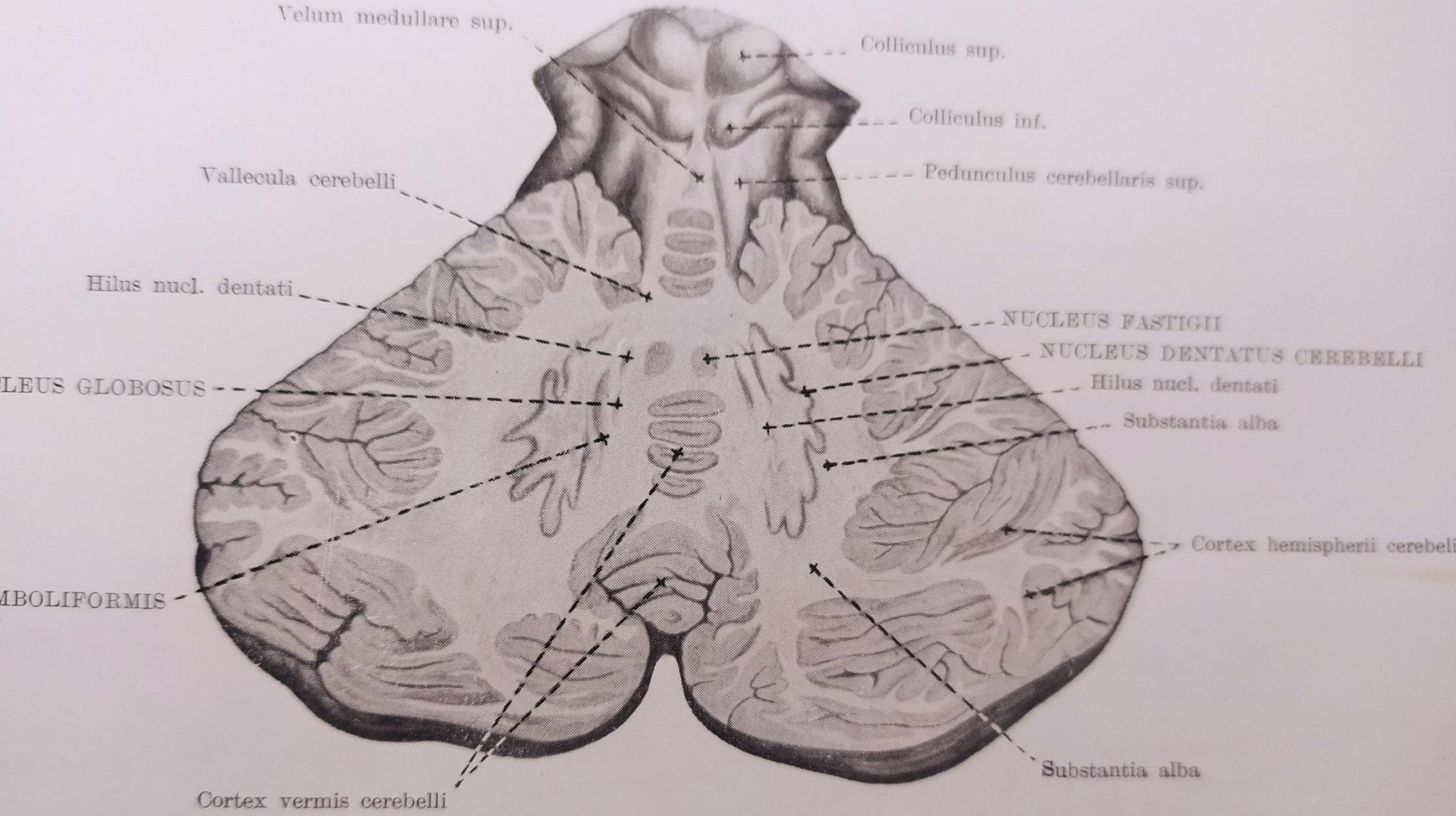

1/1

Fig. 33. CEREBELLUM VII.

(nuclei cerebelli, sectio transversalis obliqua, aspectus superior)

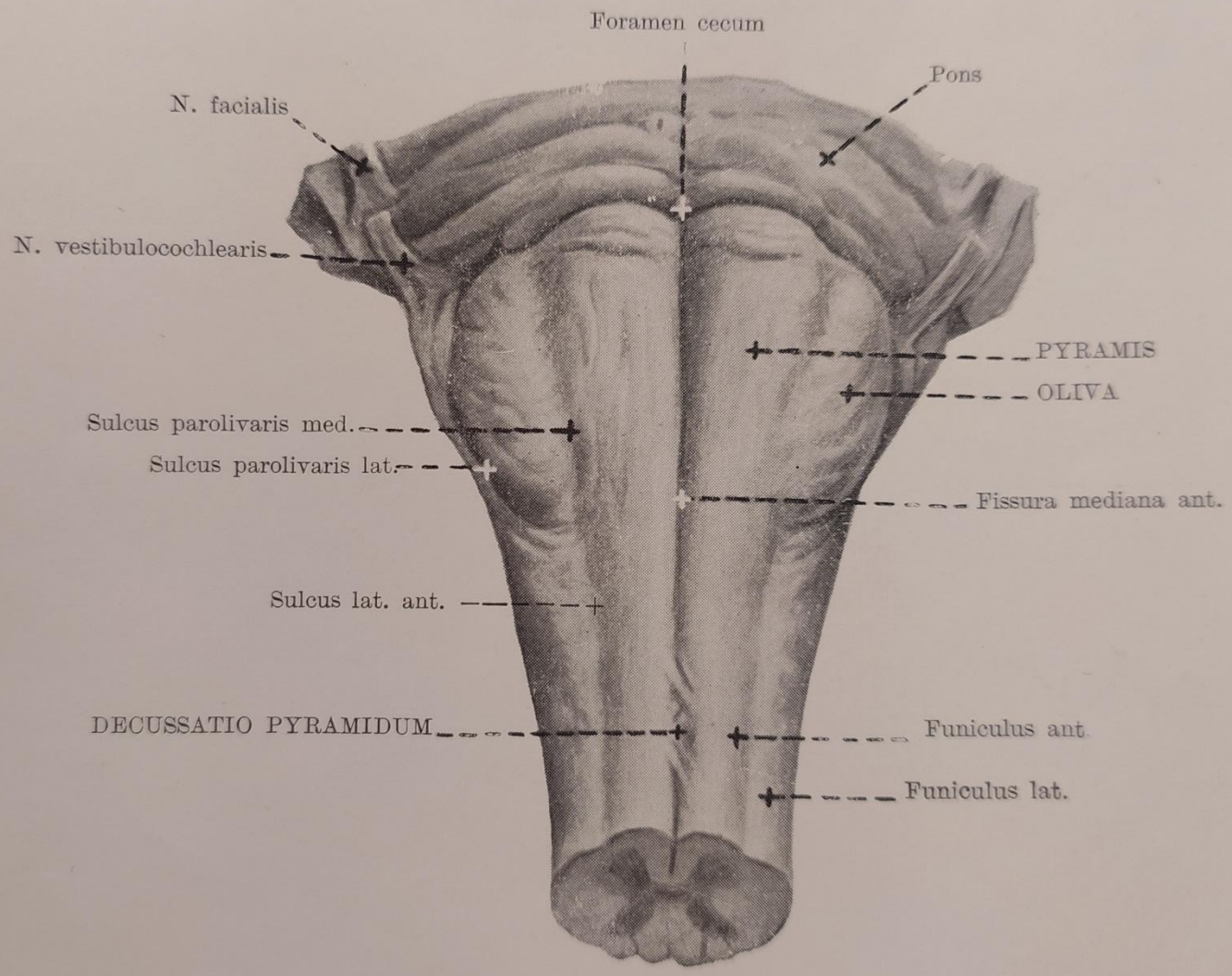

Fig. 34. MYELENCEPHALON
(medulla oblo

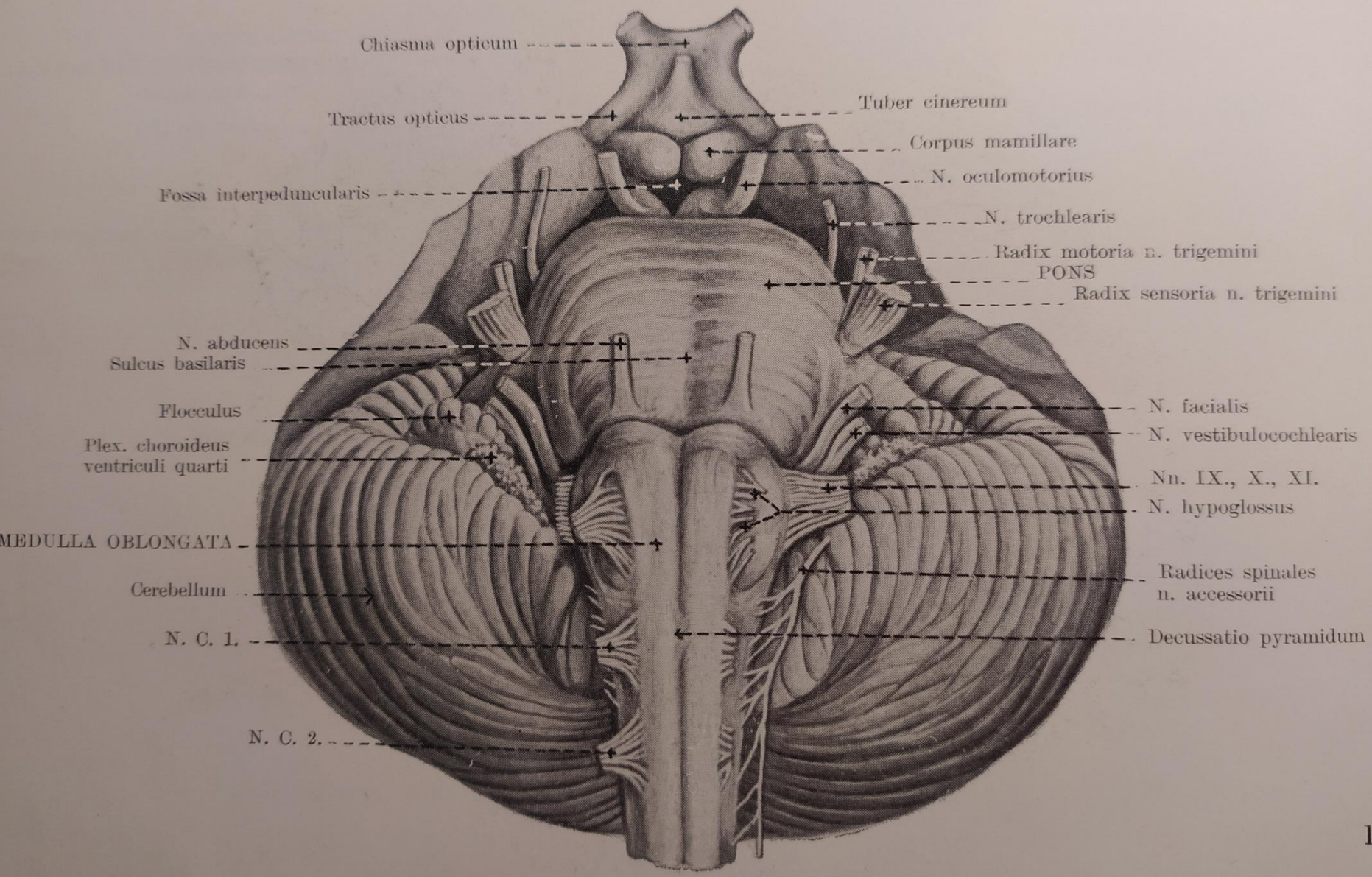
Chiasma opticum
Tractus opticus
Tuber cinereum
Corpus mamillare
N. oculomotorius
Fossa interpeduncularis
N. trochlearis
Radix motoria n. trigemini
PONS
Radix sensoria n. trigemini
N. abducens
Sulcus basilaris
Flocculus
N. facialis
N. vestibulocochlearis
Plex. choroideus
ventriculi quarti
Nn. IX., X., XI.
N. hypoglossus
MEDULLA OBLONGATA
Radices spinales
n. accessorii
Cerebellum
N. C. 1.
Decussatio pyramidum
N. C. 2.

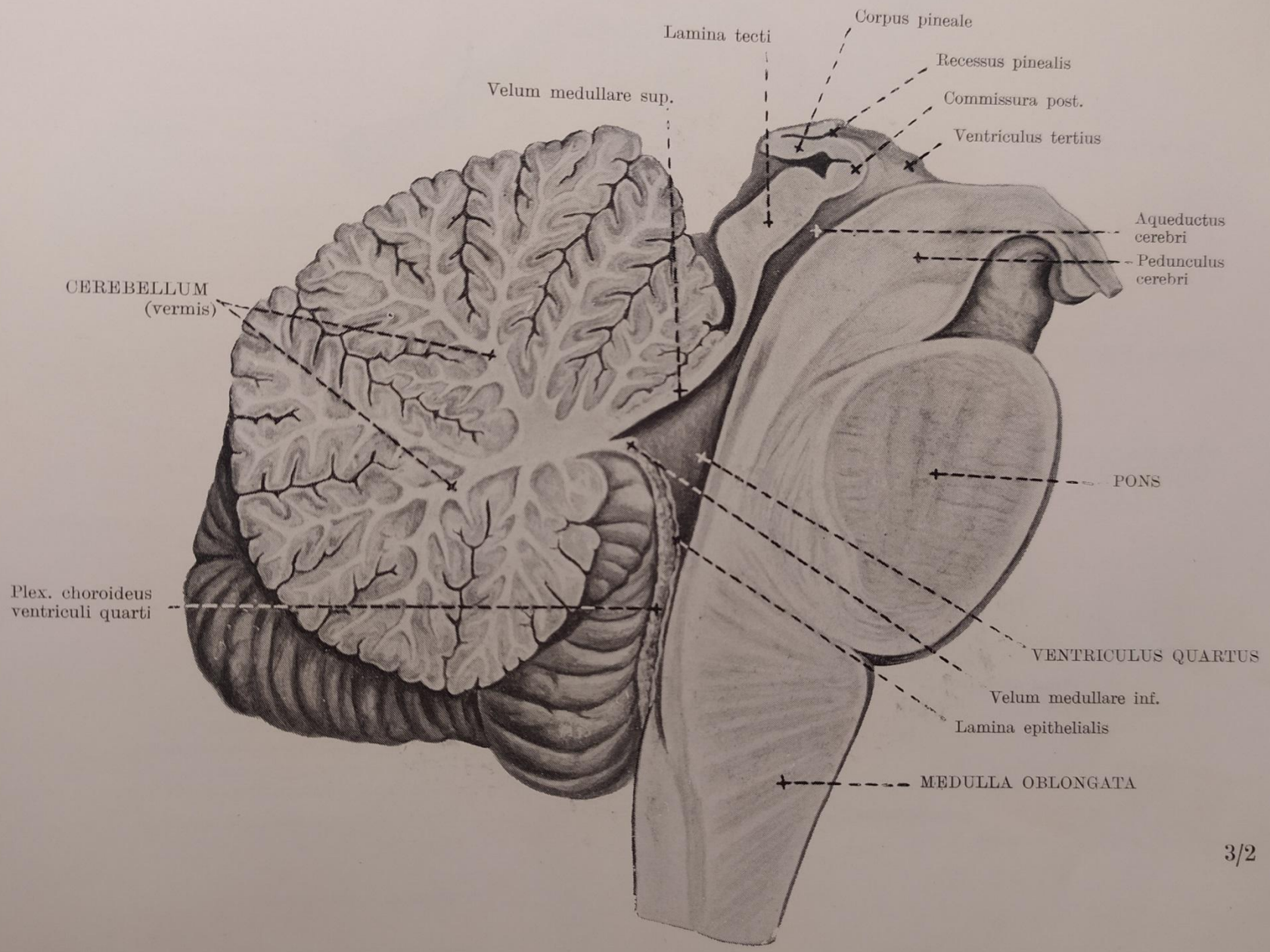
Corpus pineale
Lamina tecti
Recessus pinealis
Velum medullare sup.
Commissura post.
Ventriculus tertius
Aqueductus cerebri
Pedunculus cerebri
CEREBELLUM (vermis)
PONS
Plex. choroideus ventriculi quarti
VENTRICULUS QUARTUS
Velum medullare inf.
Lamina epithelialis
MEDULLA OBLONGATA

3/2

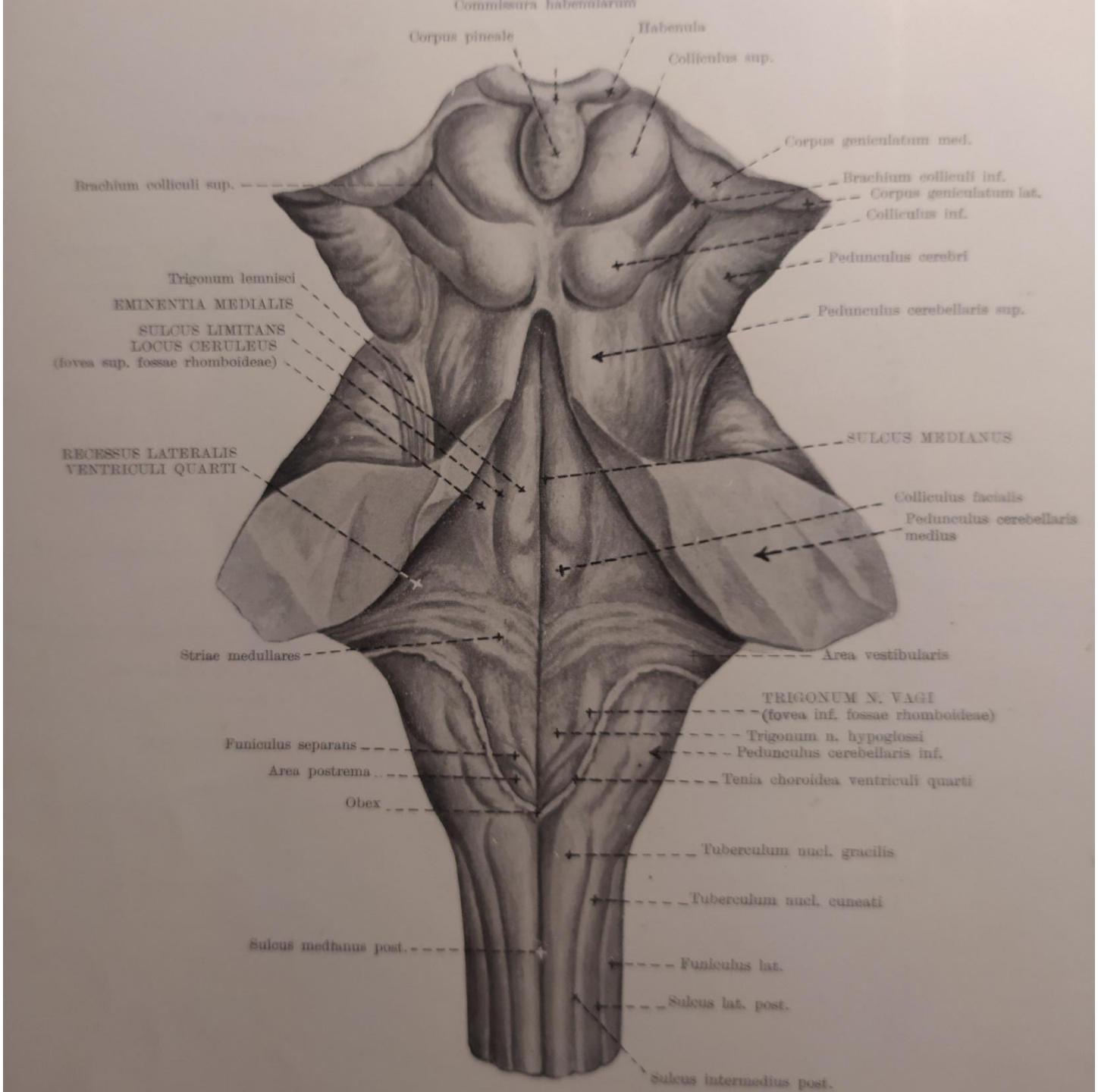
Commissura habenularum
Corpus pineale
Habenula
Colliculus sup.
Corpus geniculatum med.
Brachium colliculi sup.
Brachium colliculi inf.
Corpus geniculatum lat.
Colliculus inf.
Pedunculus cerebri
Trigonum lemnisci
EMINENTIA MEDIALIS
SULCUS LIMITANS
LOCUS CERULEUS
(fovea sup. fossae rhomboideae)
Pedunculus cerebellaris sup.
SULCUS MEDIANUS
RECESSUS LATERALIS
VENTRICULI QUARTI
Colliculus facialis
Pedunculus cerebellaris
medius
Striae medullares
Area vestibularis
TRIGONUM N. VAGI
(fovea inf. fossae rhomboideae)
Trigonum n. hypoglossi
Funiculus separans
Pedunculus cerebellaris inf.
Area postrema
Tenia choroidea ventriculi quarti
Obex
Tuberculum nucl. gracilis
Tuberculum nucl. cuneati
Sulcus medianus post.
Funiculus lat.
Sulcus lat. post.
Sulcus intermedius post.

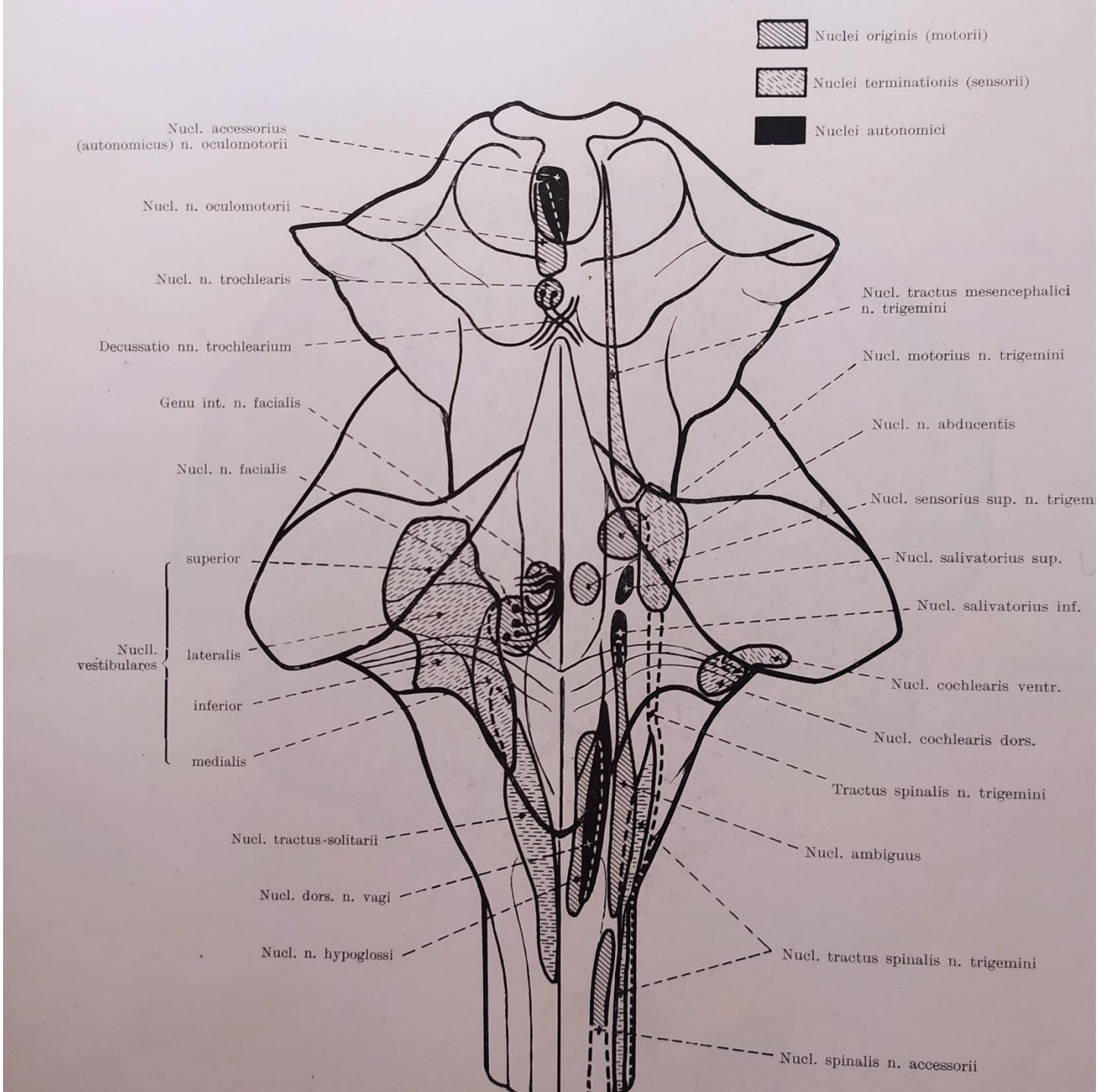
Nuclei originis (motorii)
Nuclei terminationis (sensorii)
Nuclei autonomici
Nucl. accessorius (autonomicus) n. oculomotorii
Nucl. n. oculomotorii
Nucl. n. trochlearis
Decussatio nn. trochlearium
Genu int. n. facialis
Nucl. n. facialis
Nucll. vestibulares
superior
lateralis
inferior
medialis
Nucl. tractus solitarii
Nucl. dors. n. vagi
Nucl. n. hypoglossi
Nucl. tractus mesencephalici n. trigemini
Nucl. motorius n. trigemini
Nucl. n. abducentis
Nucl. sensorius sup. n. trigemi
Nucl. salivatorius sup.
Nucl. salivatorius inf.
Nucl. cochlearis ventr.
Nucl. cochlearis dors.
Tractus spinalis n. trigemini
Nucl. ambiguus
Nucl. tractus spinalis n. trigemini
Nucl. spinalis n. accessorii

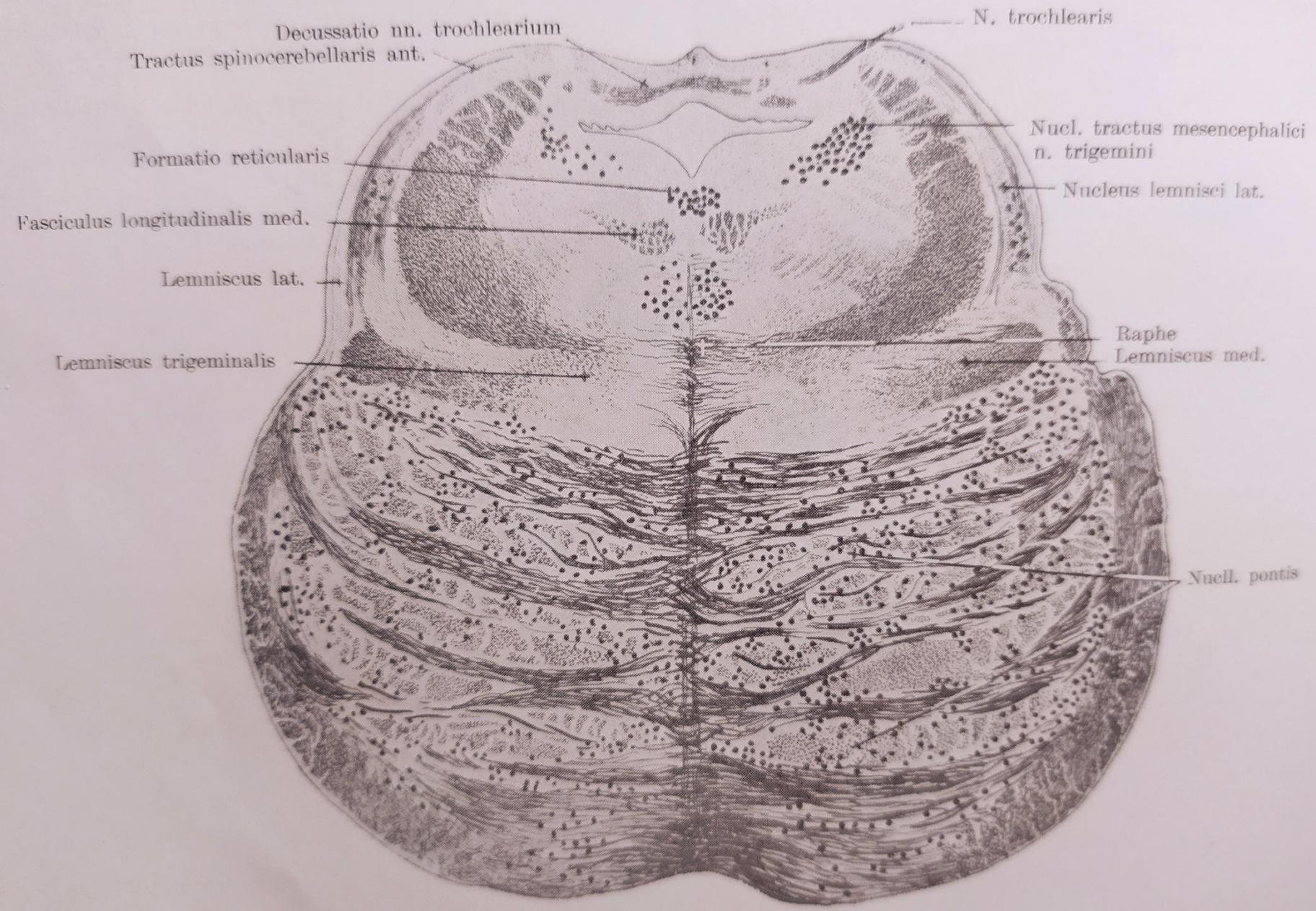
Decussatio nn. trochlearium
Tractus spinocerebellaris ant.
N. trochlearis
Nucl. tractus mesencephalici
n. trigemini
Formatio reticularis
Nucleus lemnisci lat.
Fasciculus longitudinalis med.
Lemniscus lat.
Raphe
Lemniscus med.
Lemniscus trigeminalis
Nucll. pontis

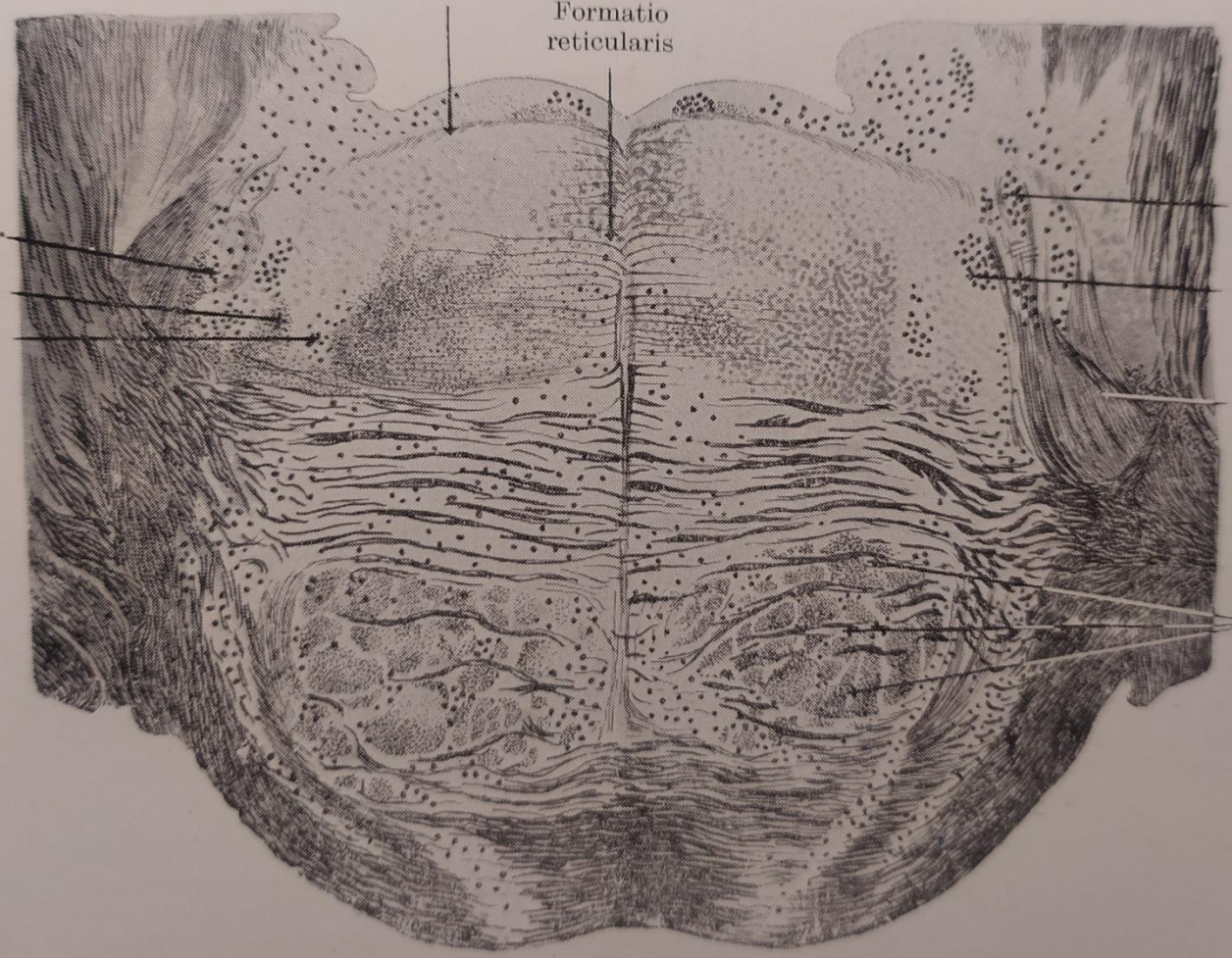
Fibrae n. V.
Formatio reticularis
ucl. motorius n. V.
Lemniscus lat.
ucl. post. corporis trapezoidei
Nucl. sensorius sup. n. V.
Nucl. motorius n. V.
Fila radicularia n. V.
Fibrae pontis longitudinales (tractatus corticospinalis et corticopontini)

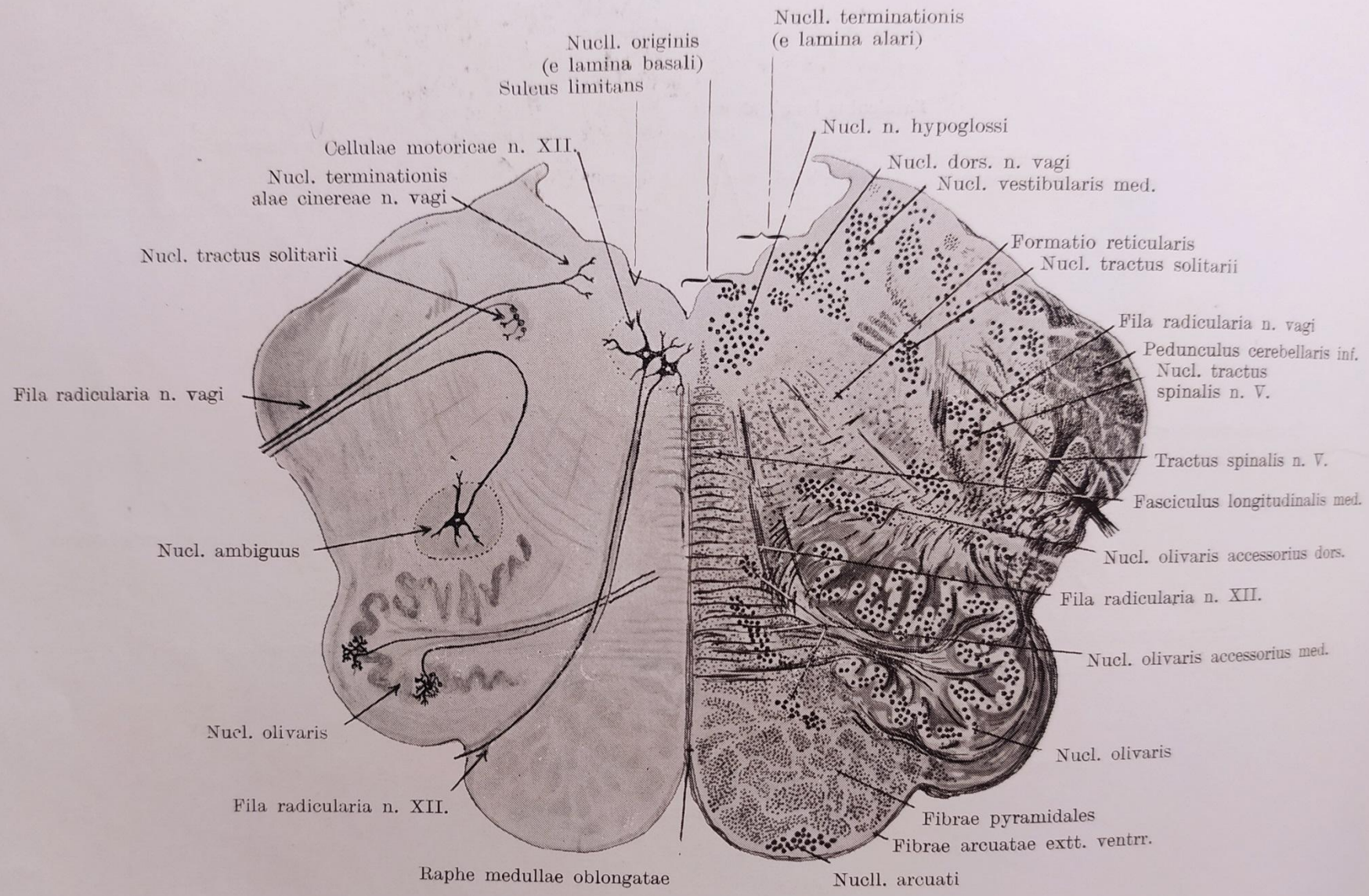

Fig. 54. SECTIO TRANSVERSA MEDULLAE OBLONGATAE II.
(pars media, cyto- et myeloarchitecturae)

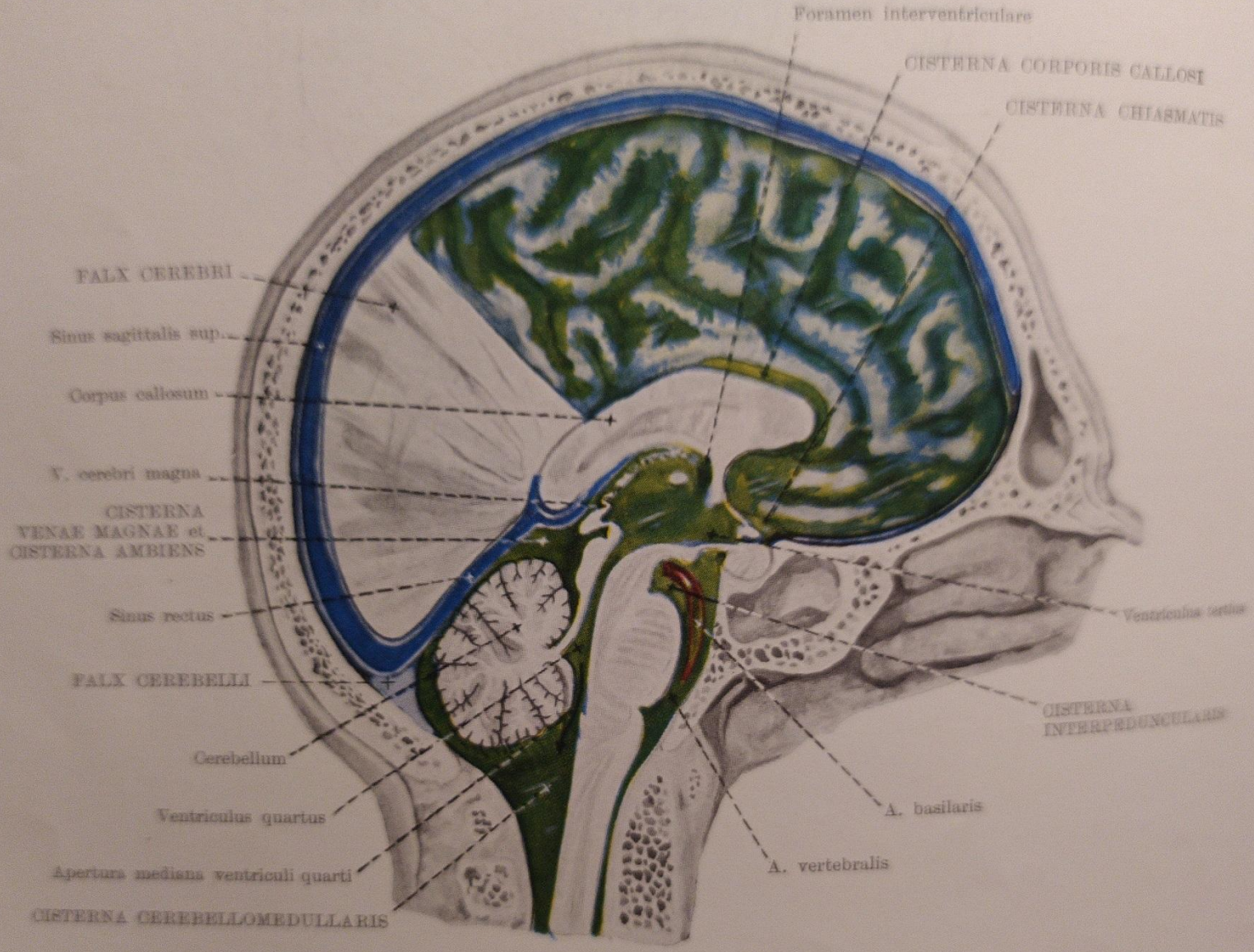

Fig. 80. MENINGES ENCEPHALI ET CISTERNAE SUBARACHNOIDEALES
(sectio sagittalis paramediana)

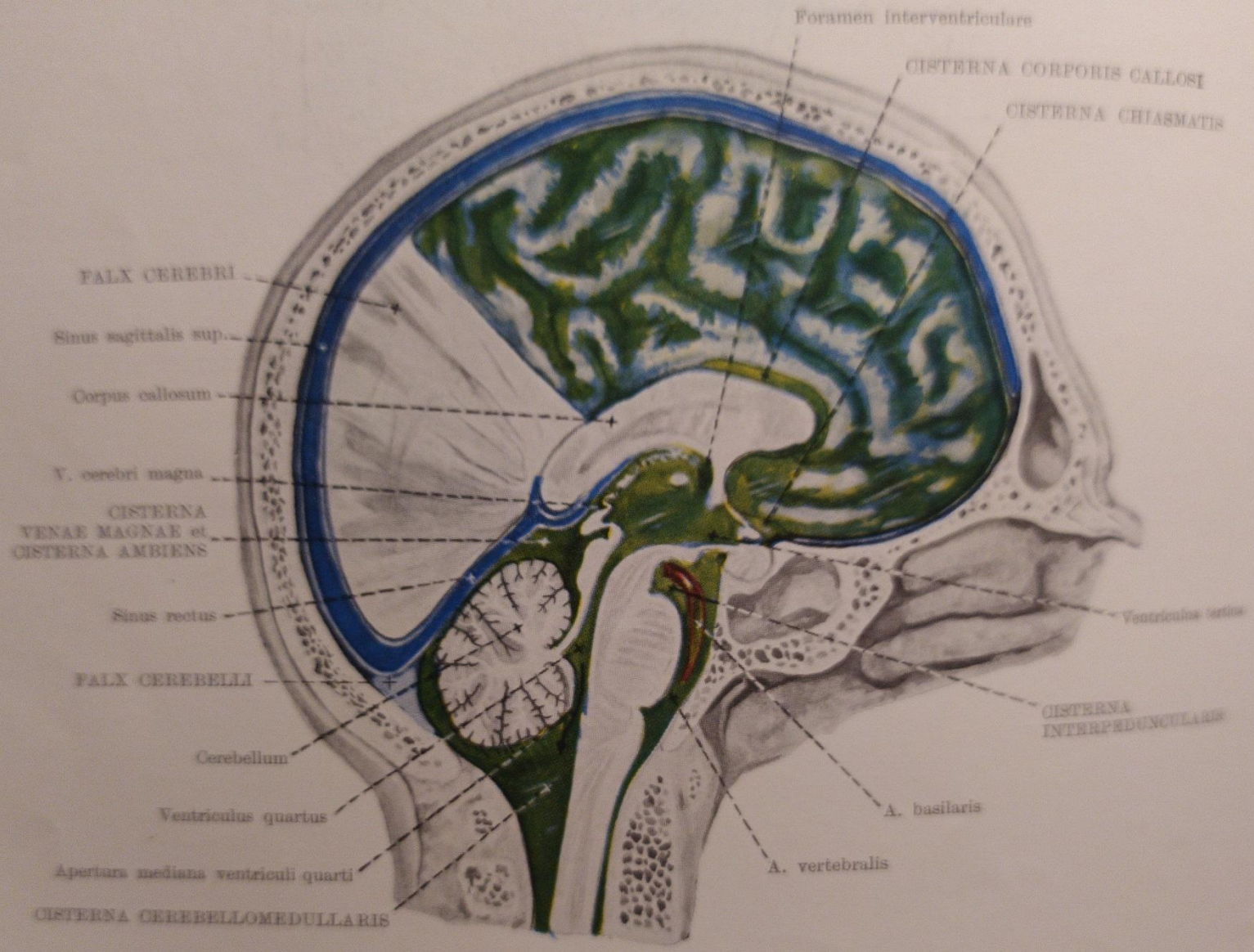

Fig. 80. MENINGES ENCEPHALI ET CISTERNAE SUBARACHNOIDEALES
(sectio sagittalis paramediana)

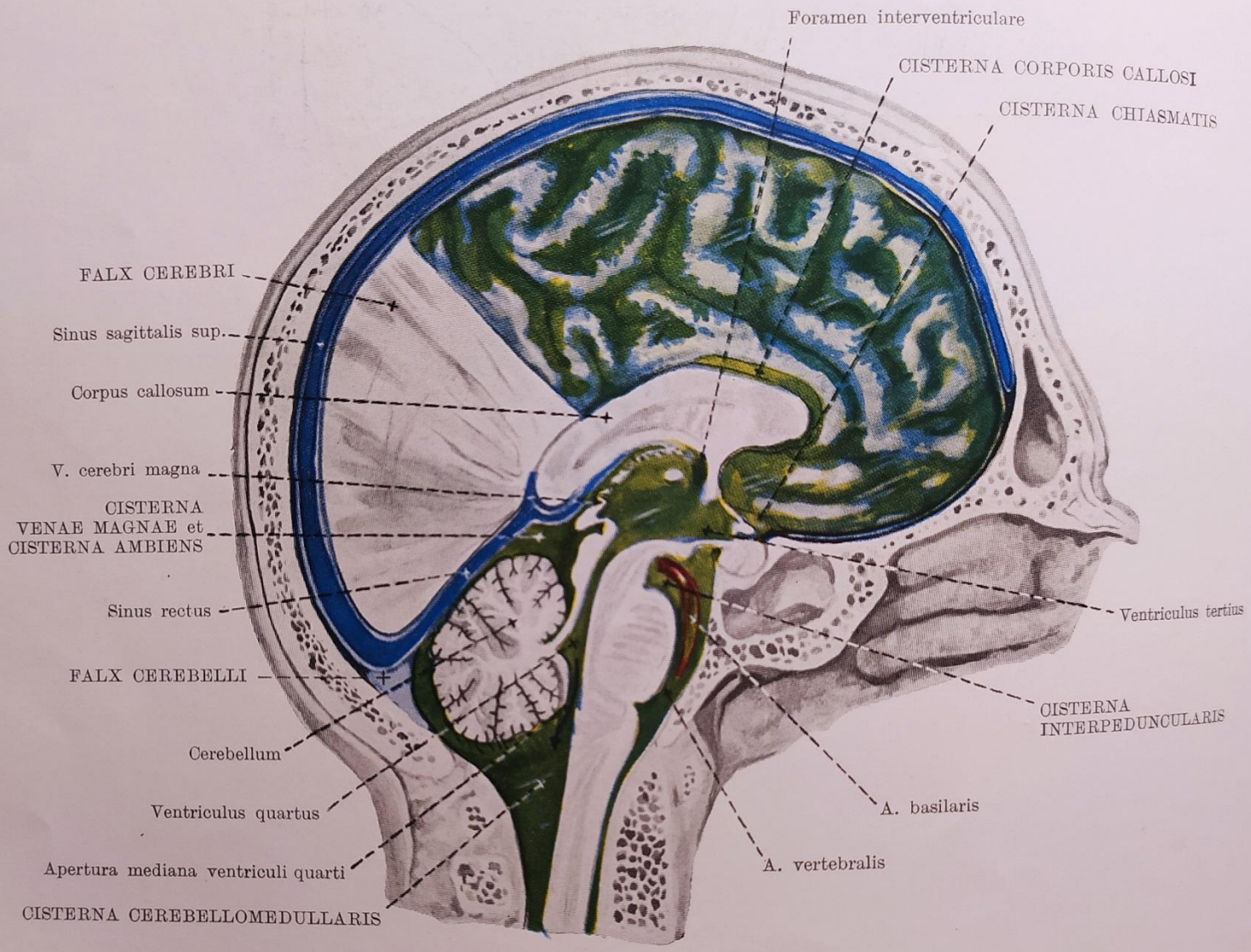

Fig. 80. MENINGES ENCEPHALI ET CISTERNAE SUBARACHNOIDEALES
(sectio sagittalis paramediana)

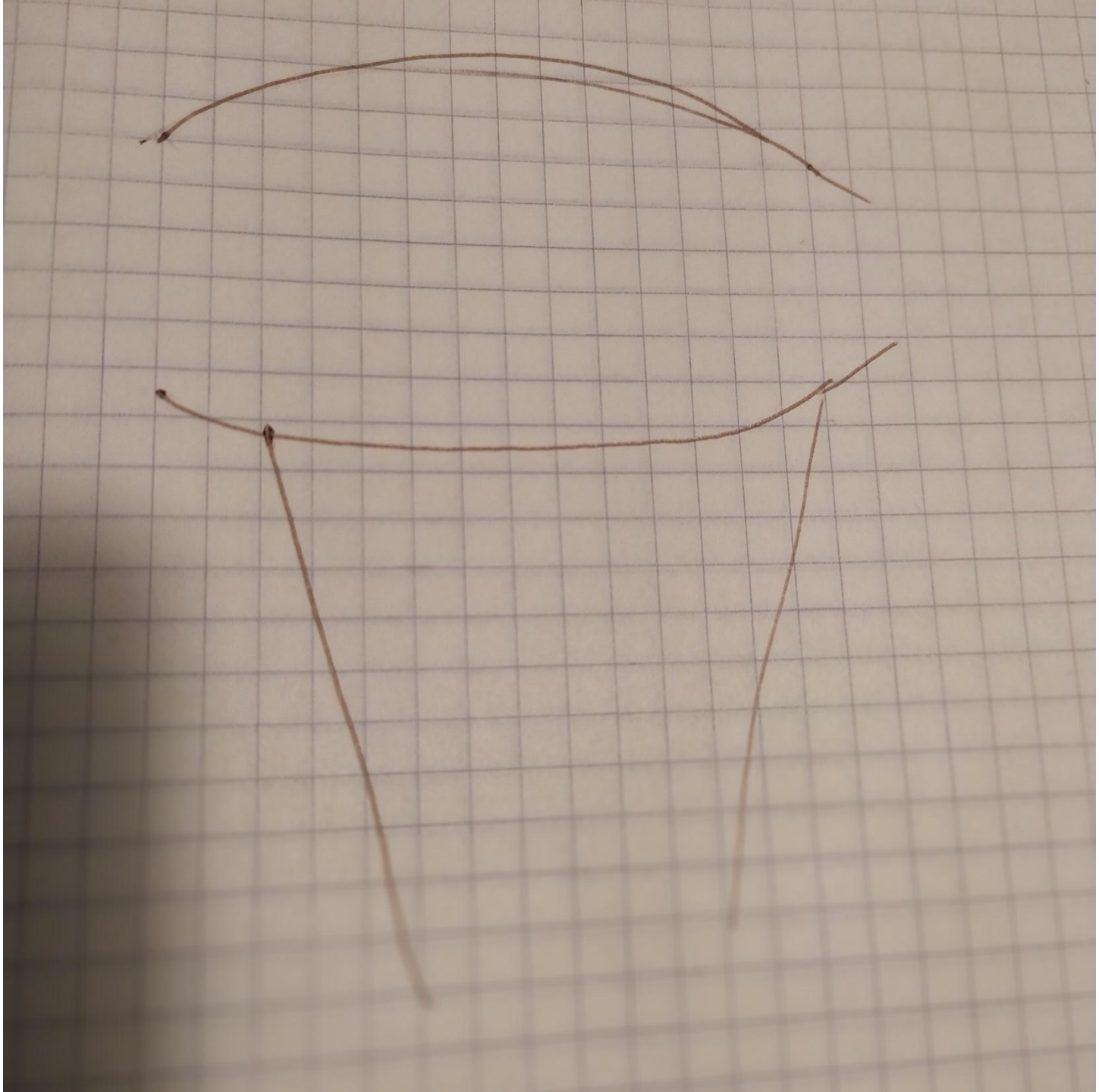

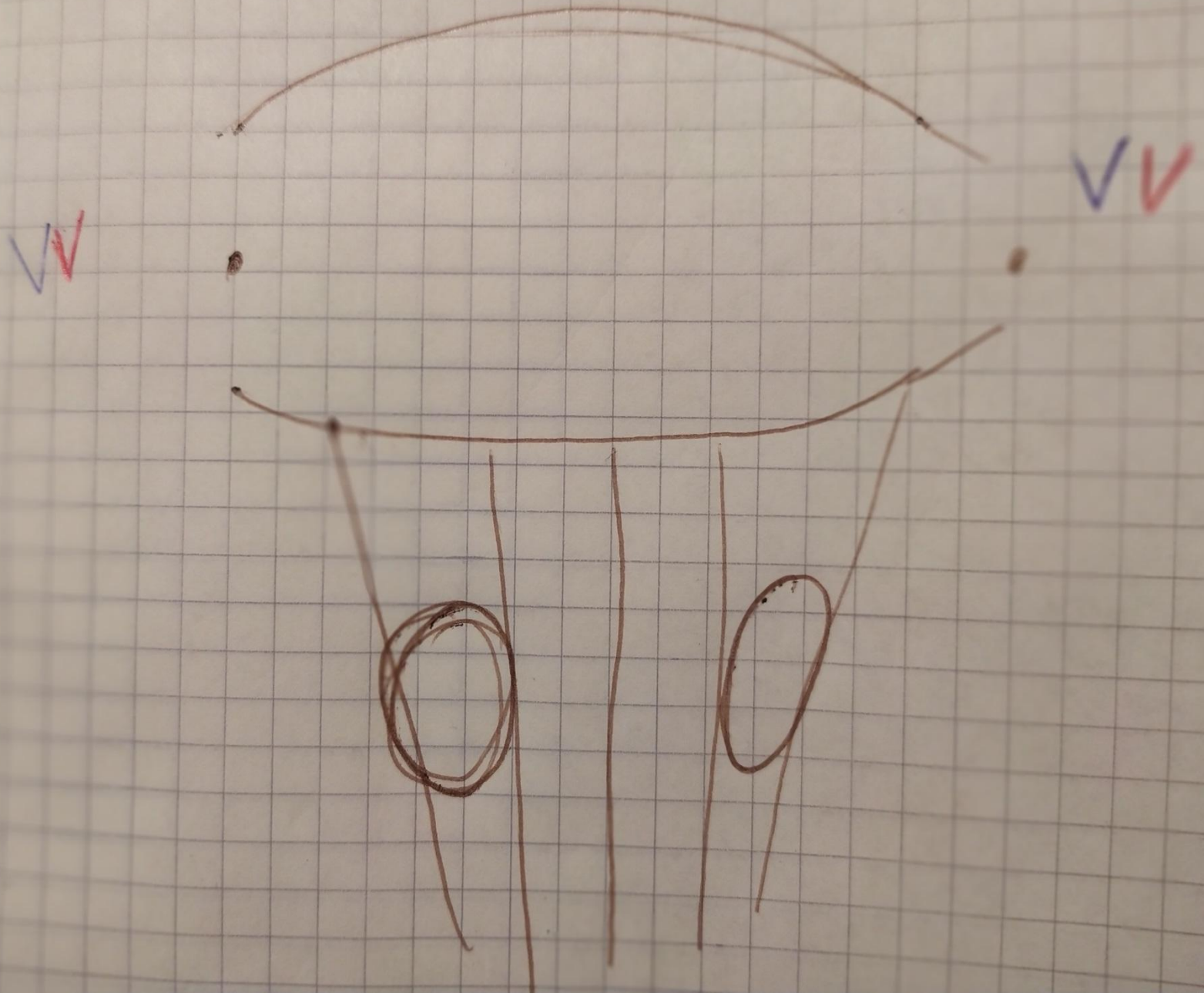
VV
VV

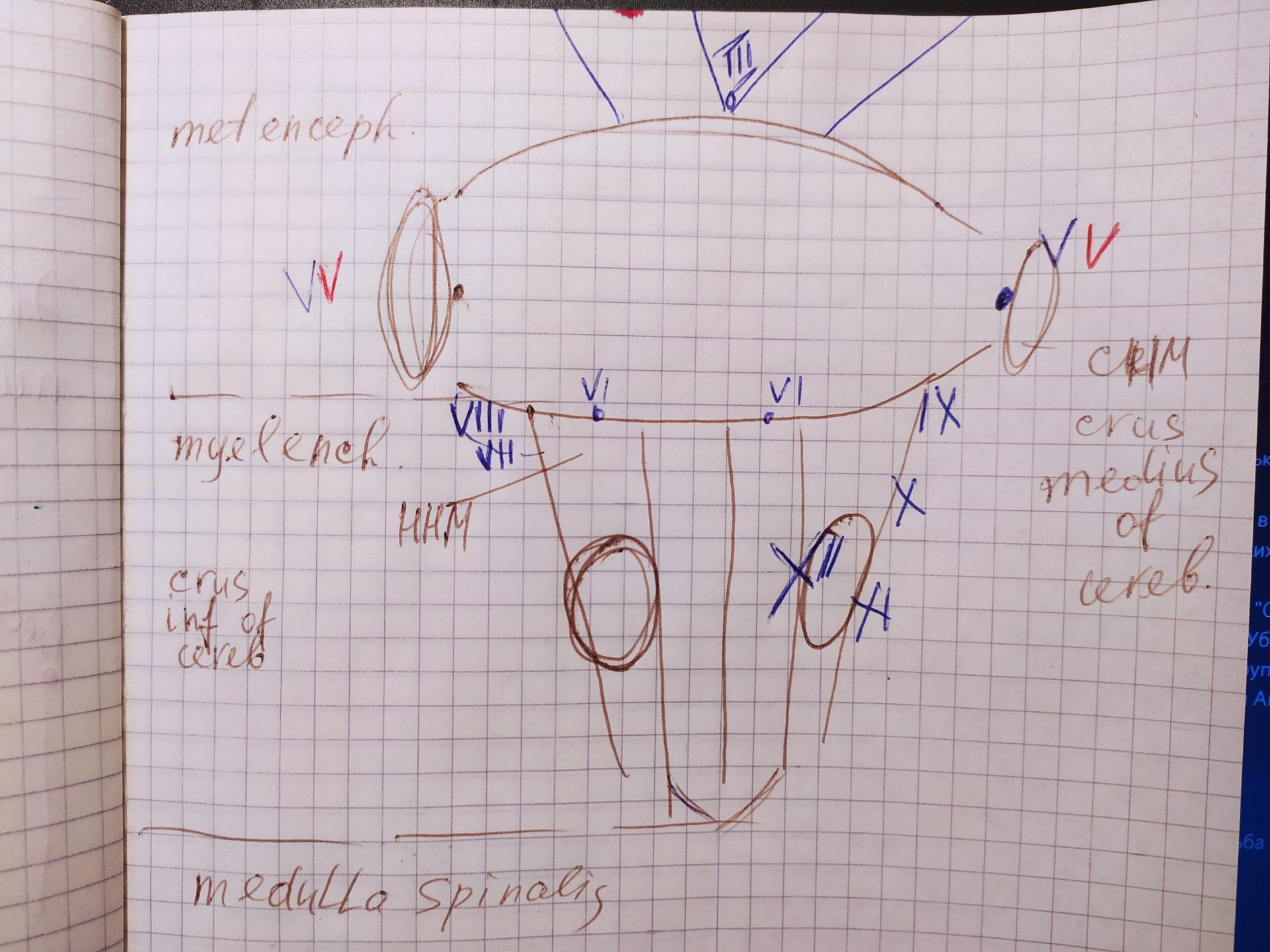
metencеph.
III
V
V
VI
VI
VIII
VII
IX
X
XII
XI
CRIM
crus medius of cereb.
myelench.
HHM
crus inf of cereb
medulla spinalis

1) VIII

2) 

XII

XI

X

IX

VII

VI

IV

III

X

IX

VII

III

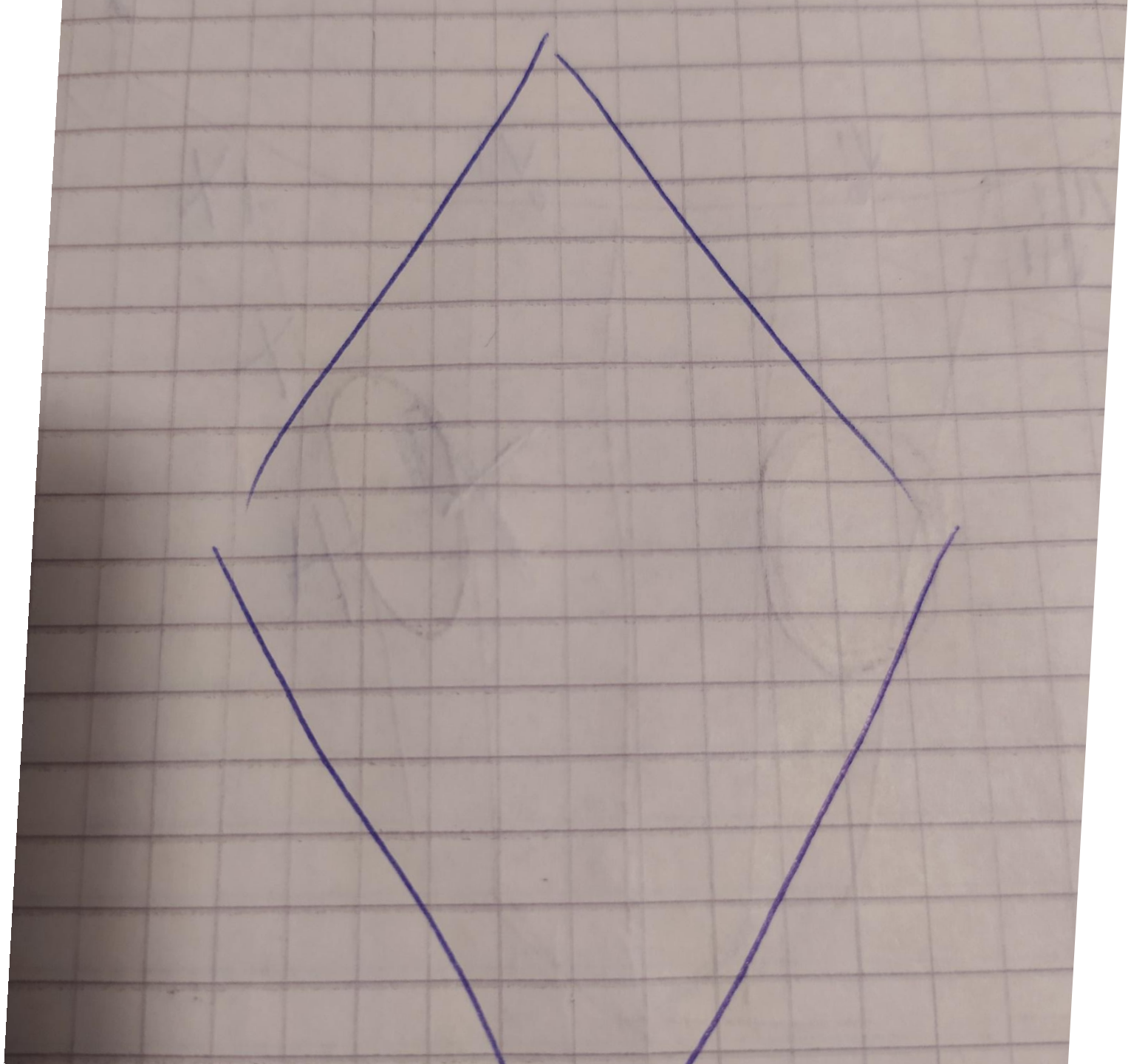

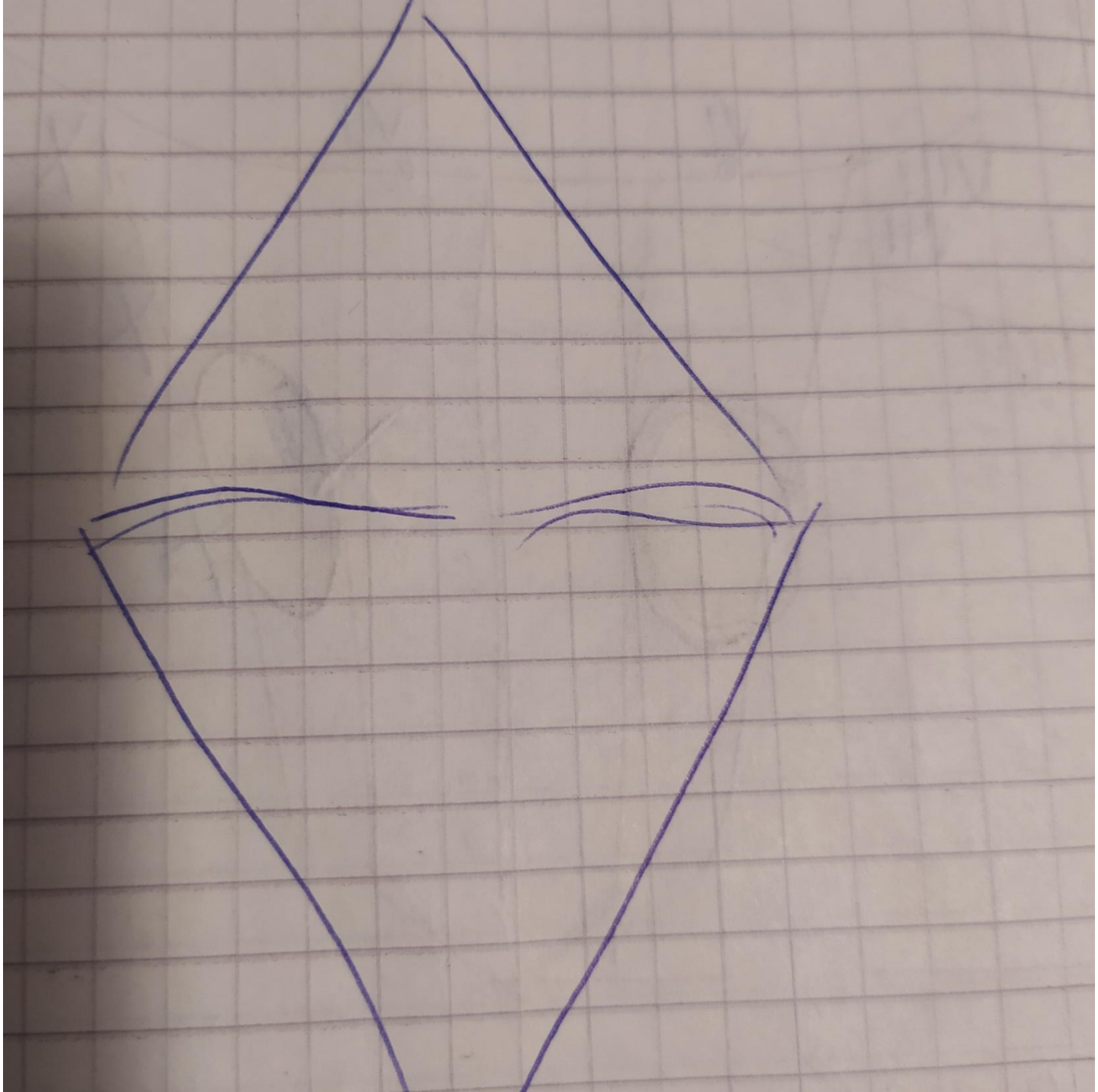

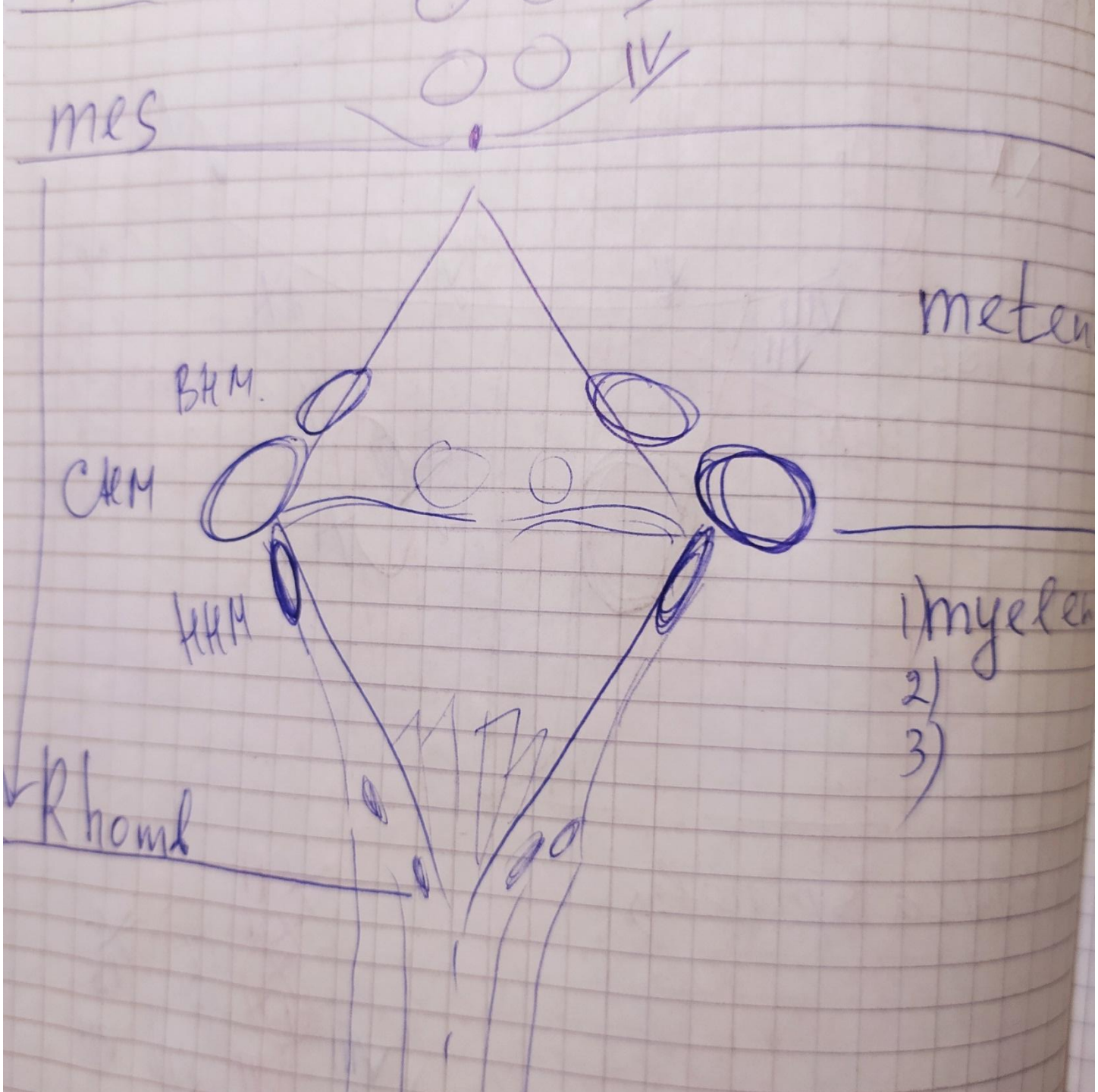
IV
mes
meten
BHM.
CHM
HHM
1) myele
2)
3)
Rhomb

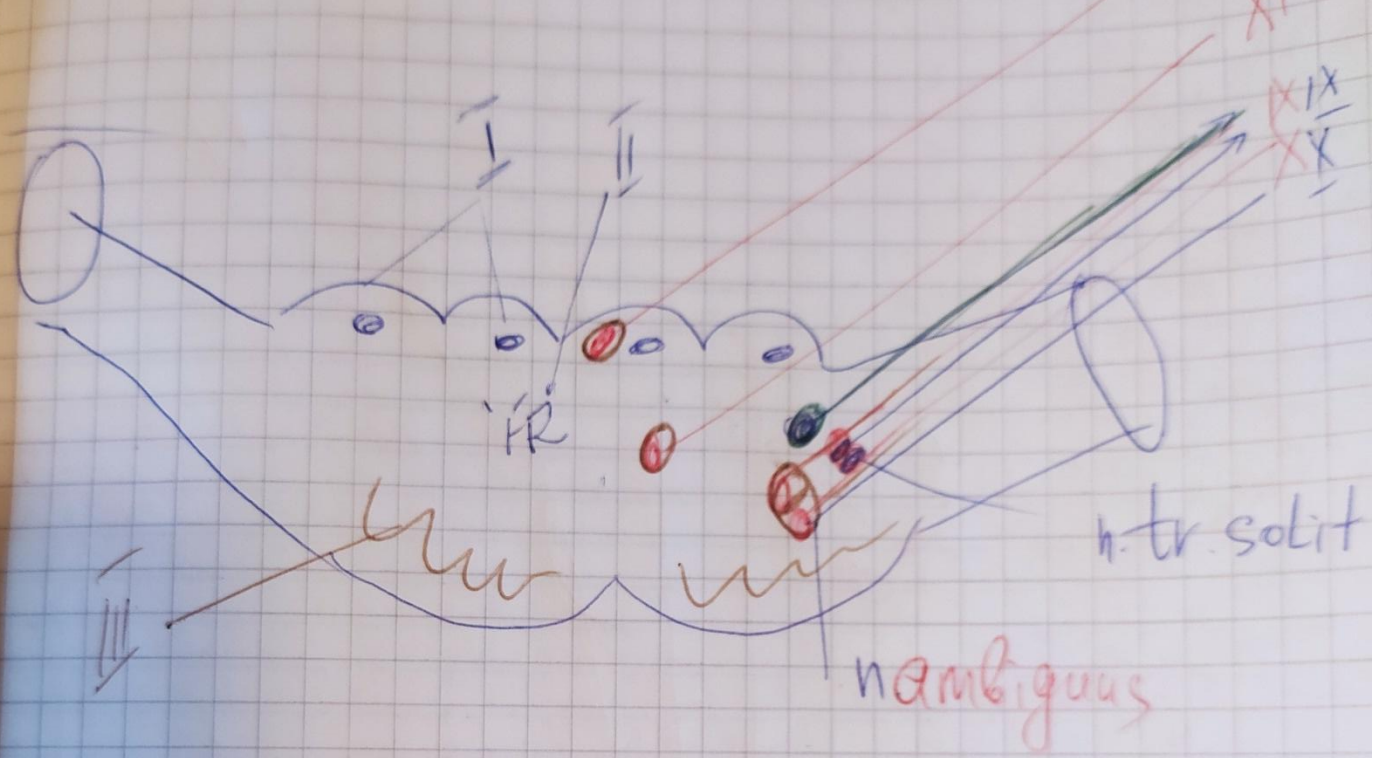



name

Назв.				из мозга	из черепа

S. grisea
4:4

myelench.

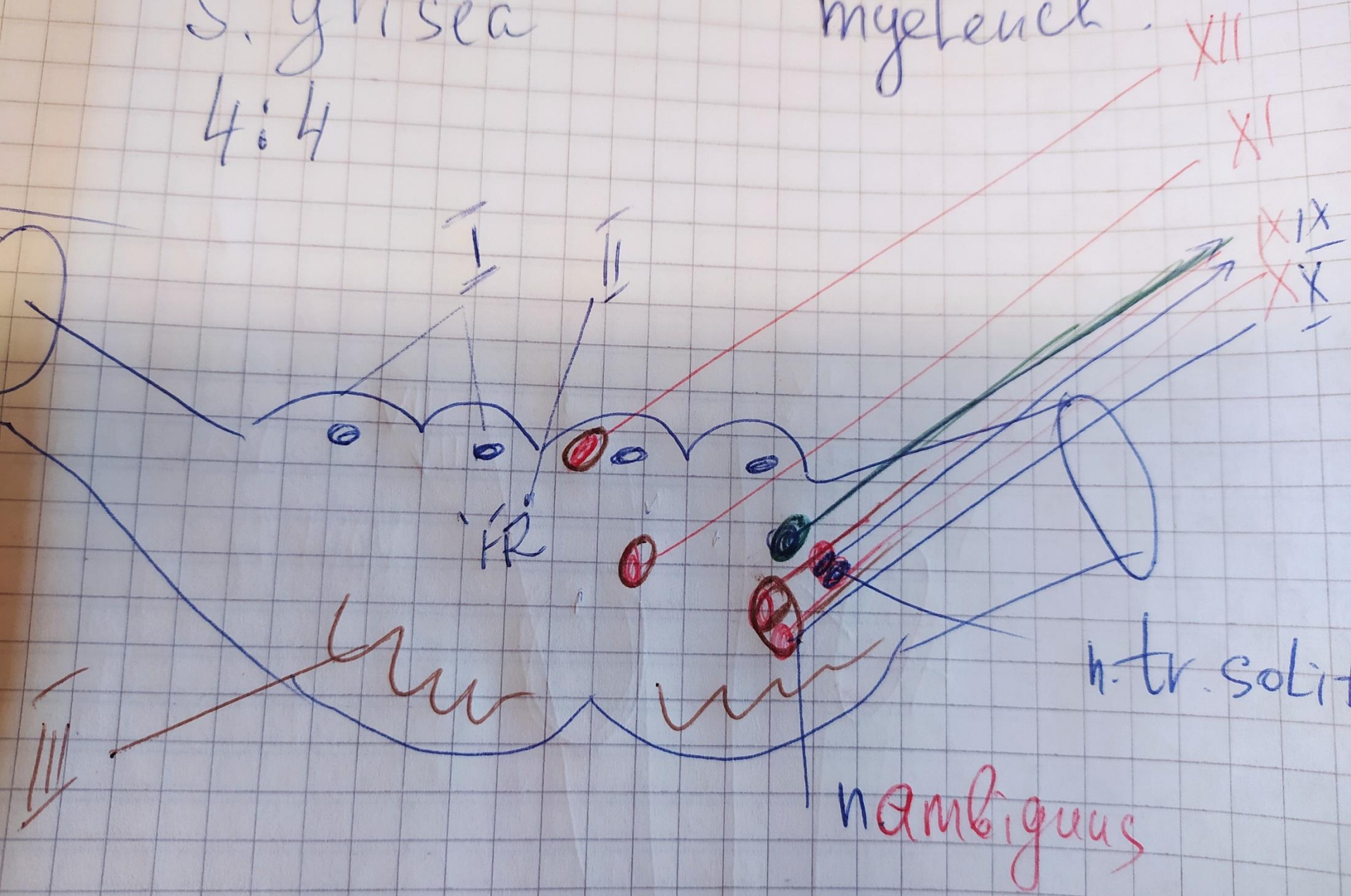

4:4

met.

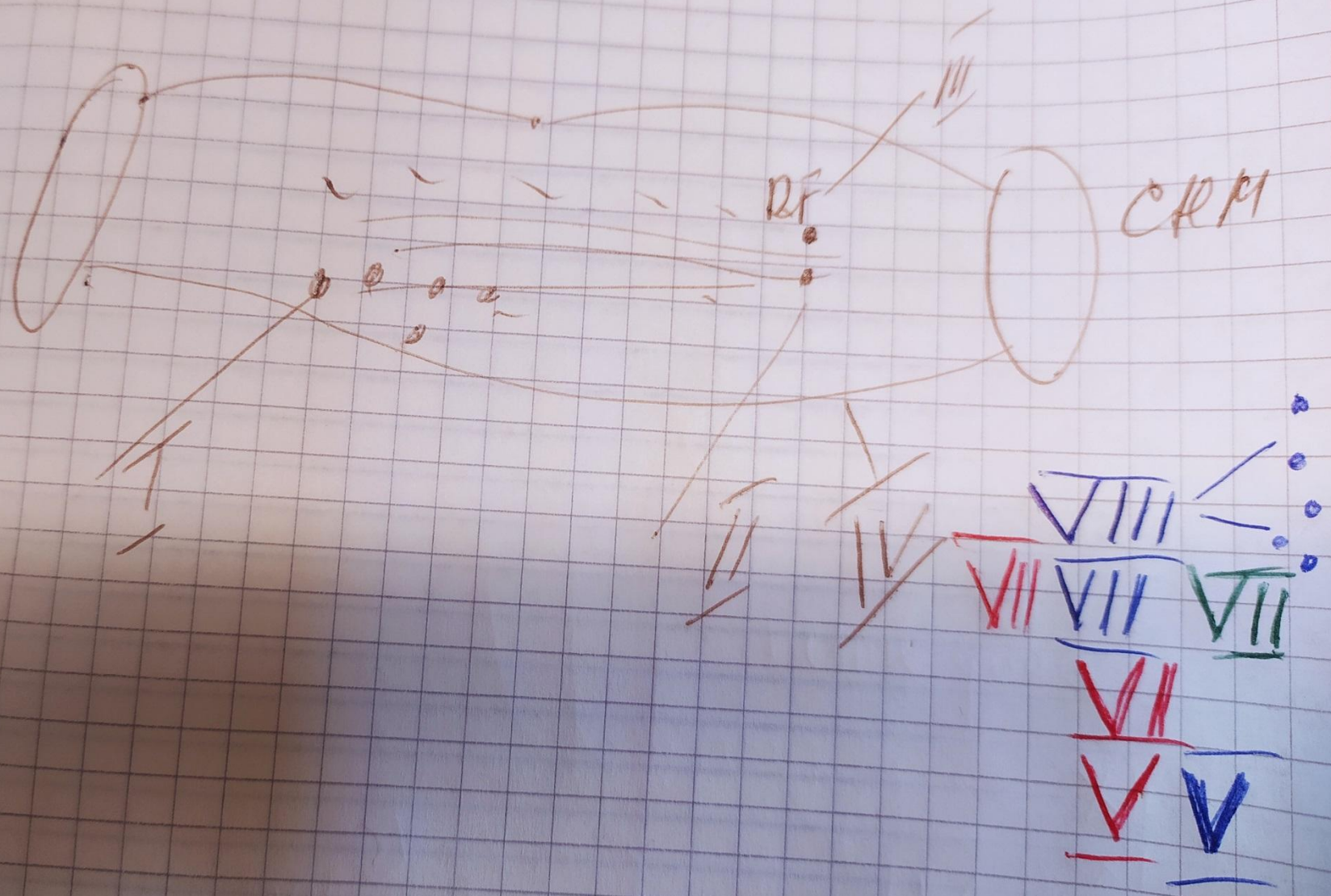

Aff → Eff.

1. Lemniscus spinalis
   - tractus

2. l. medialis
   - tractus

3. l. lateralis

4. l. trigeminalis
   - tractus.

myelencepl

(metencepl

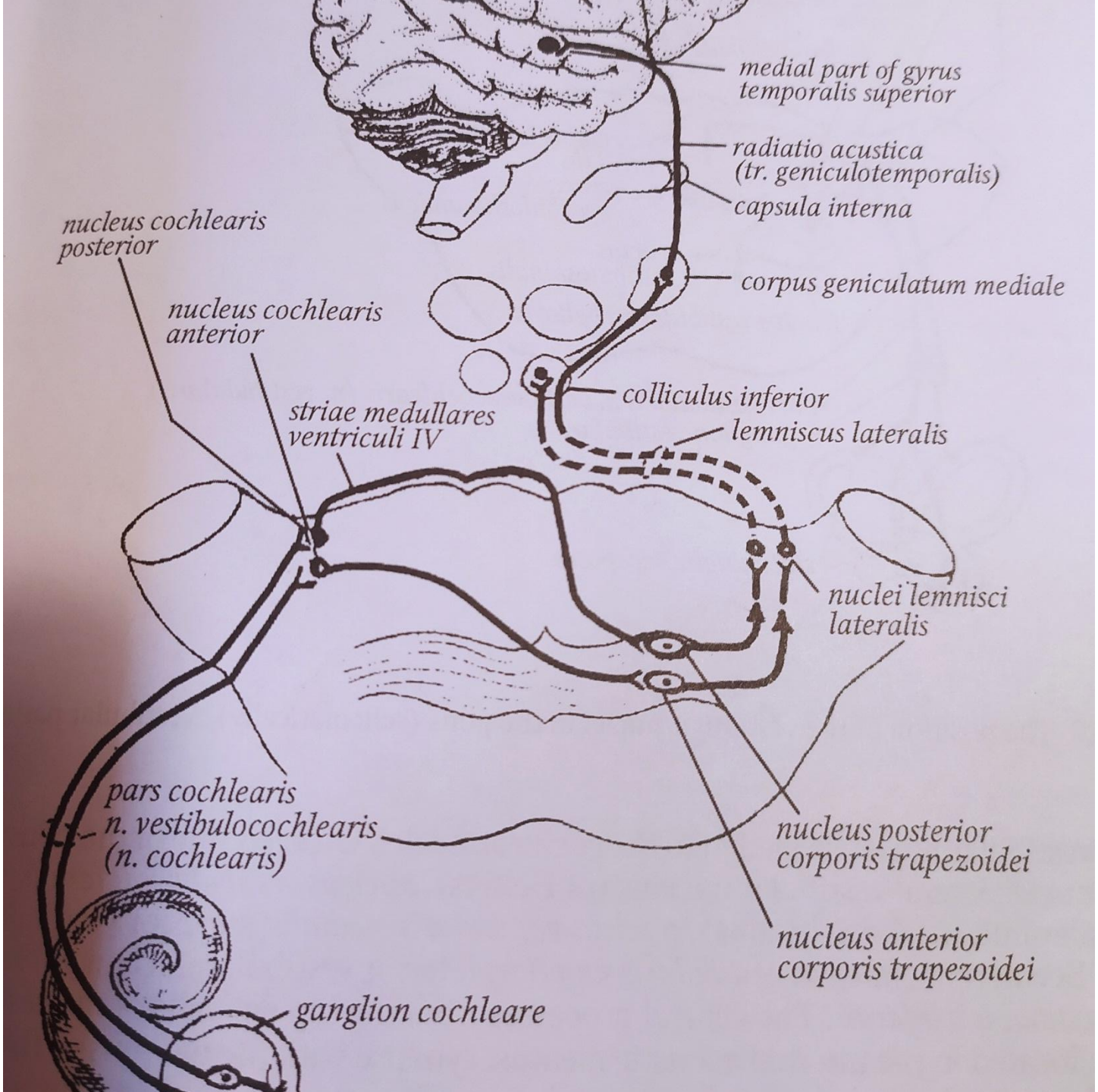
medial part of gyrus temporalis superior
radiatio acustica (tr. geniculotemporalis)
capsula interna
corpus geniculatum mediale
colliculus inferior
lemniscus lateralis
nucleus cochlearis posterior
nucleus cochlearis anterior
striae medullares ventriculi IV
nuclei lemnisci lateralis
pars cochlearis n. vestibulocochlearis (n. cochlearis)
nucleus posterior corporis trapezoidei
nucleus anterior corporis trapezoidei
ganglion cochleare

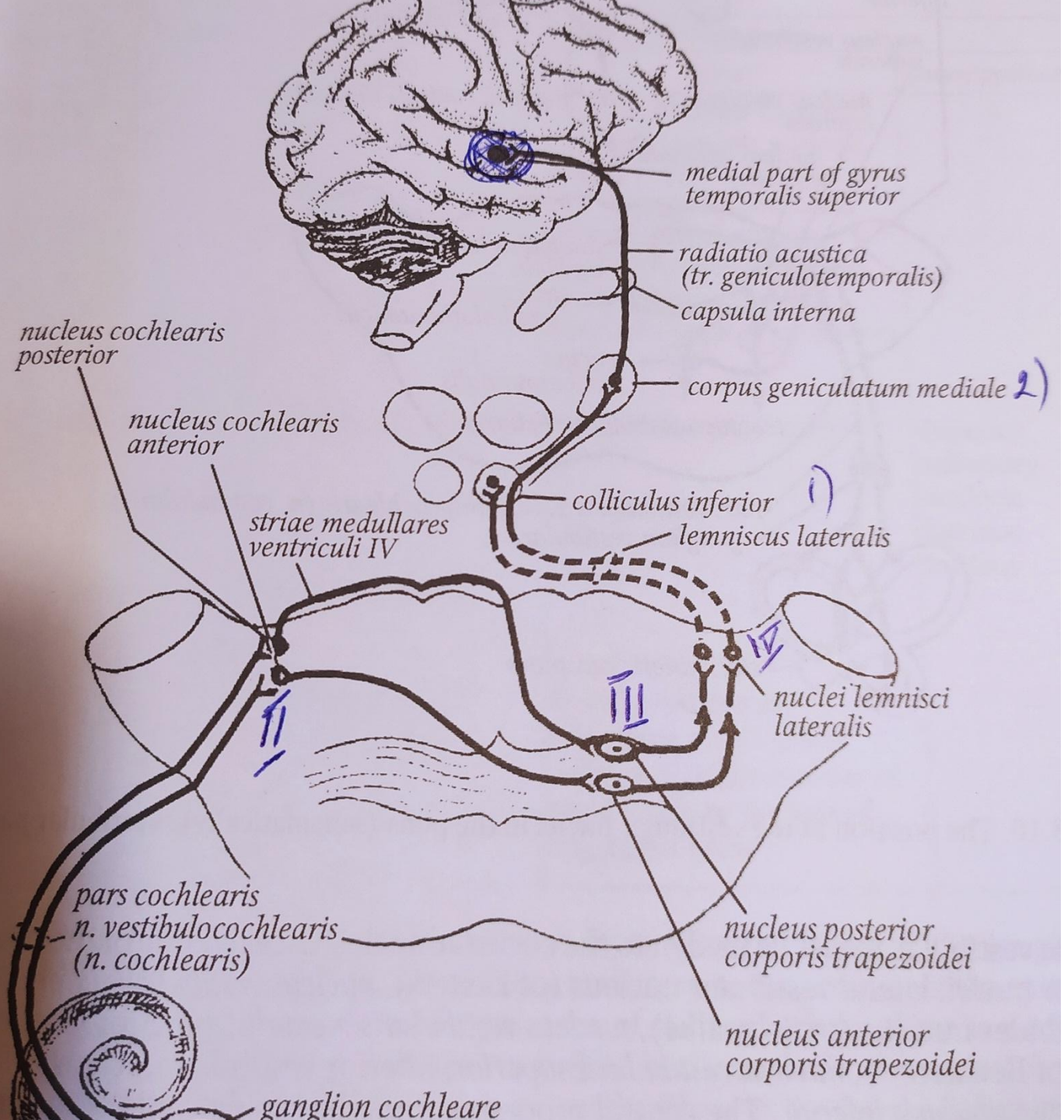
medial part of gyrus temporalis superior
radiatio acustica (tr. geniculotemporalis)
capsula interna
corpus geniculatum mediale 2)
nucleus cochlearis posterior
nucleus cochlearis anterior
colliculus inferior 1)
striae medullares ventriculi IV
lemniscus lateralis
IV
III
II
nuclei lemnisci lateralis
pars cochlearis n. vestibulocochlearis (n. cochlearis)
nucleus posterior corporis trapezoidei
nucleus anterior corporis trapezoidei
ganglion cochleare

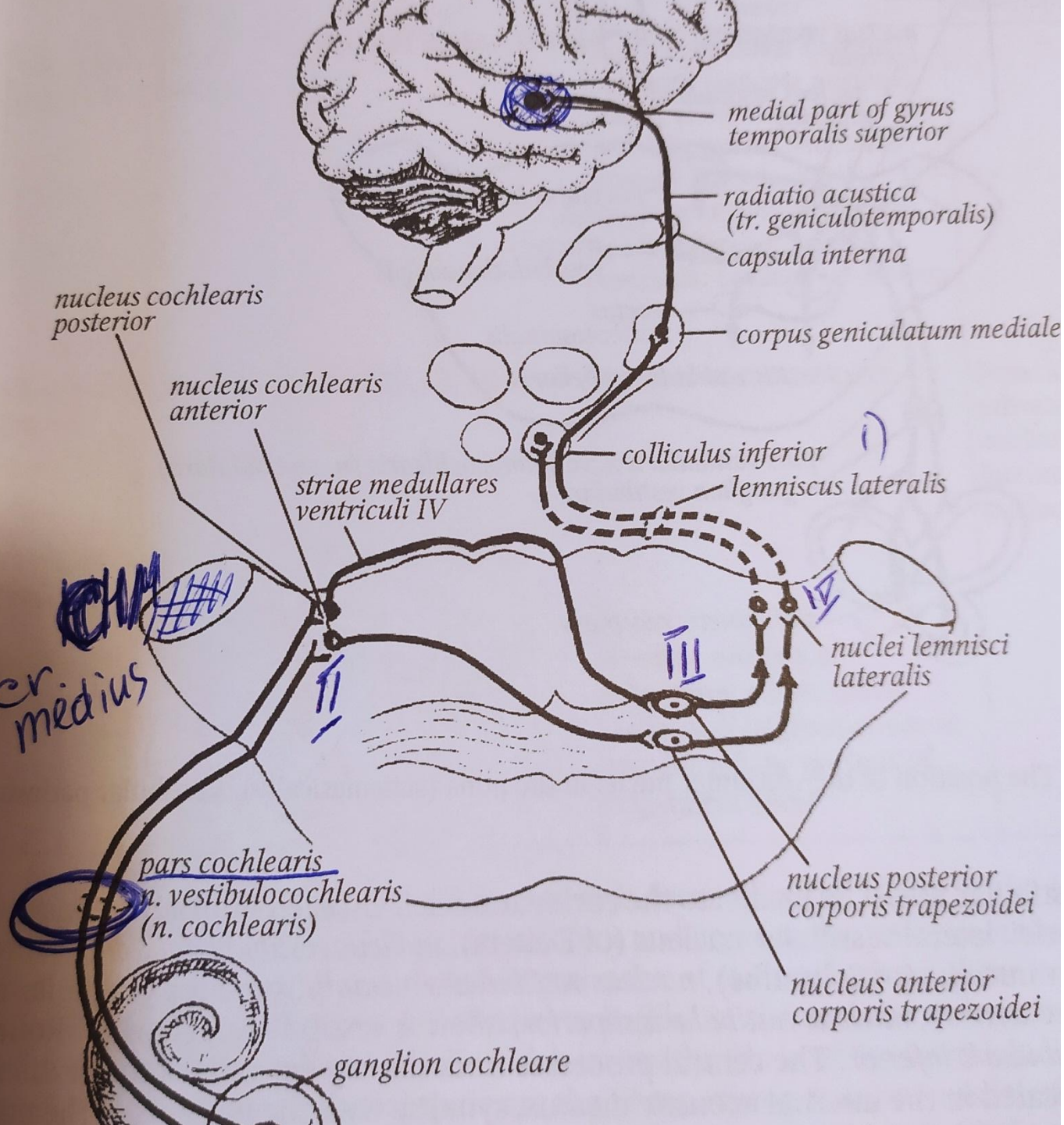
medial part of gyrus temporalis superior
radiatio acustica (tr. geniculotemporalis)
capsula interna
corpus geniculatum mediale
nucleus cochlearis posterior
nucleus cochlearis anterior
colliculus inferior
lemniscus lateralis
striae medullares ventriculi IV
nuclei lemnisci lateralis
pars cochlearis n. vestibulocochlearis (n. cochlearis)
nucleus posterior corporis trapezoidei
nucleus anterior corporis trapezoidei
ganglion cochleare

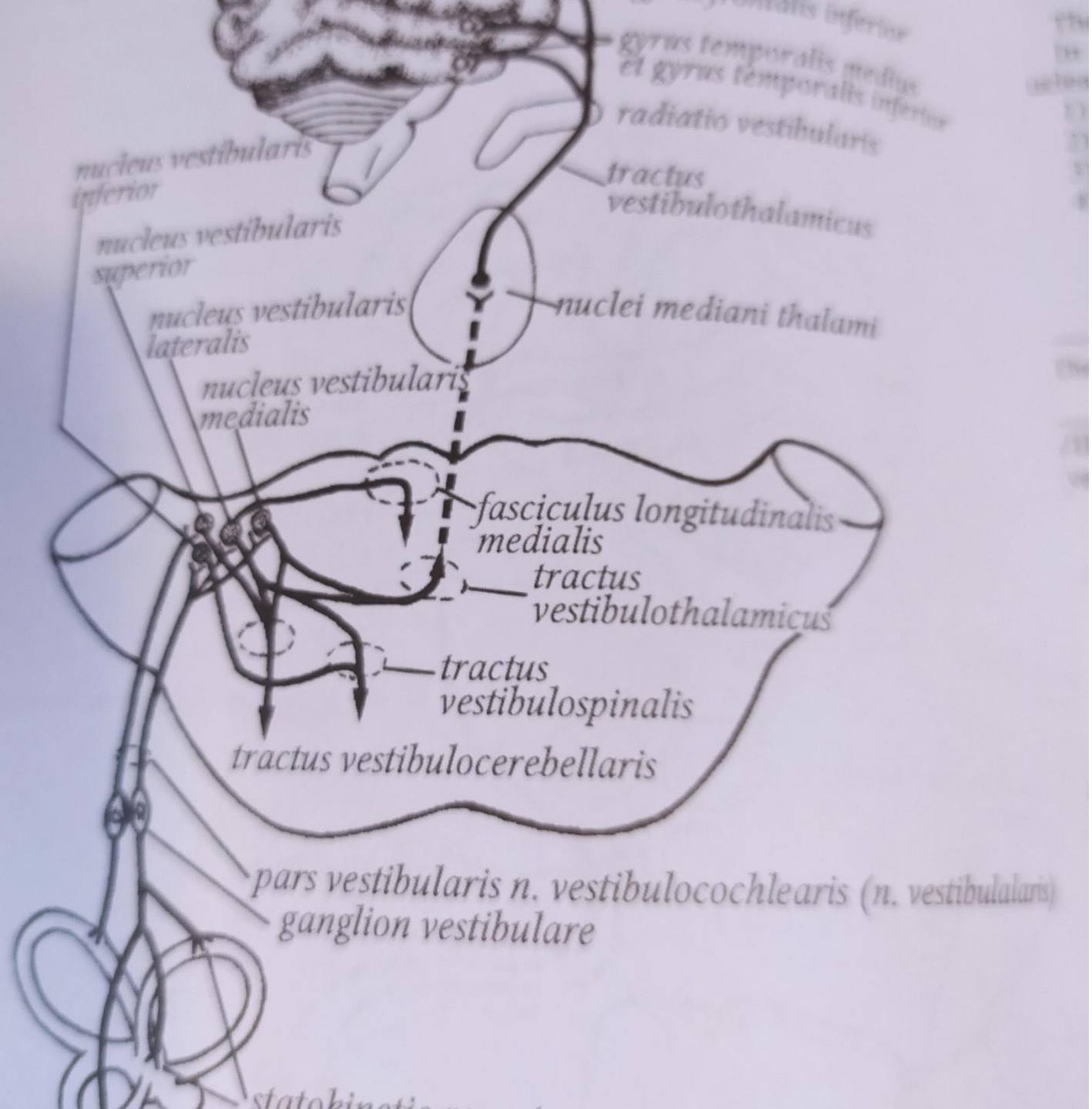
gyrus temporalis medius
et gyrus temporalis inferior
radiatio vestibularis
tractus
vestibulothalamicus
nucleus vestibularis
inferior
nucleus vestibularis
superior
nucleus vestibularis
lateralis
nucleus vestibularis
medialis
nuclei mediani thalami
fasciculus longitudinalis
medialis
tractus
vestibulothalamicus
tractus
vestibulospinalis
tractus vestibulocerebellaris
pars vestibularis n. vestibulocochlearis (n. vestibulalaris)
ganglion vestibulare

(medial to the

The descending fibres of

located in the brain.

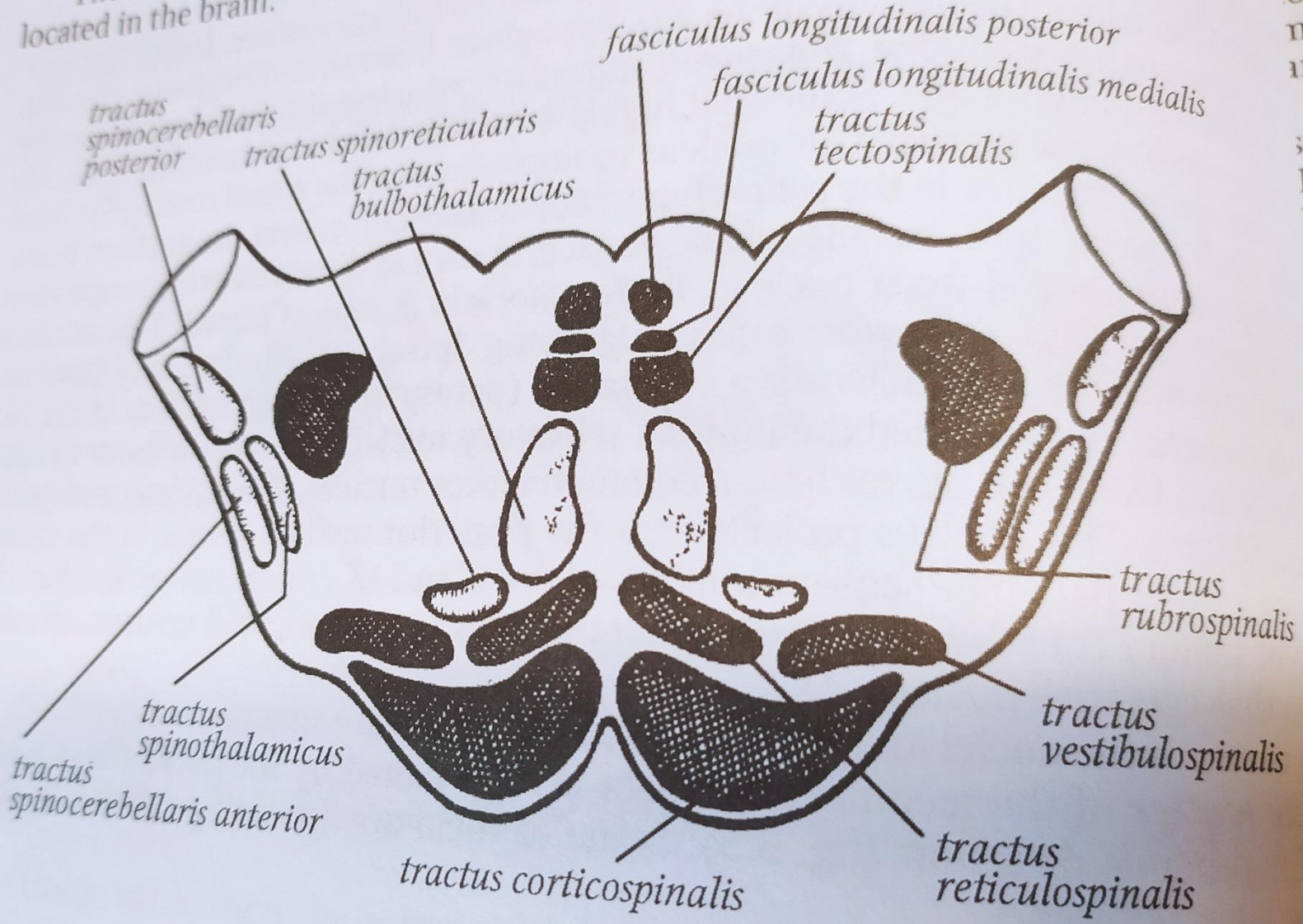

Fig. 3.5. Diagram showing the position of the conduction tracts in a transverse section of the medulla oblongata

The larg

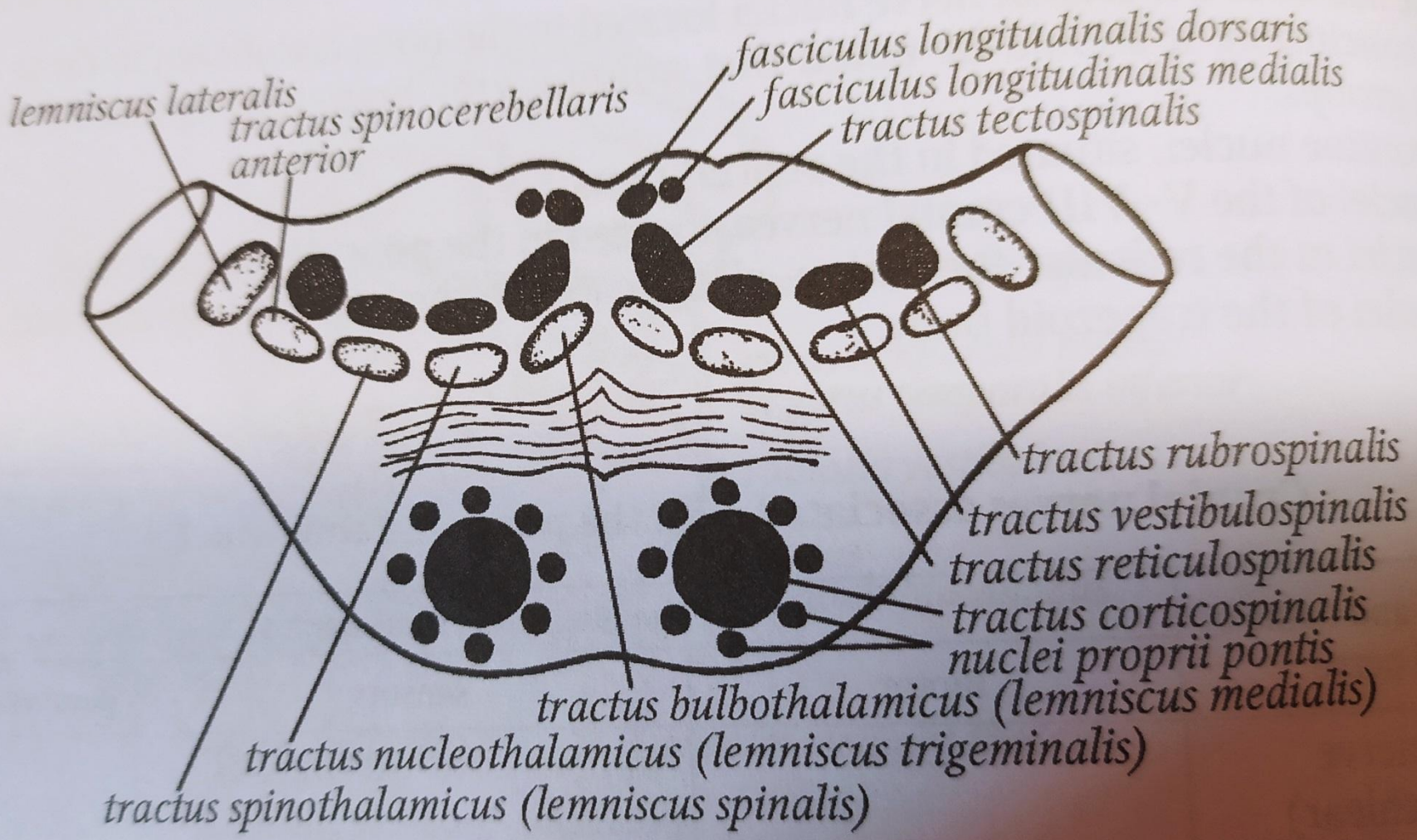

ig. 3.11. The position of the conduction tracts on a transverse section of the pons (sc